



Városmajori
Szív- és Érgyógyászati
Klinika

Kardiológia gyakorlat

Szív MR

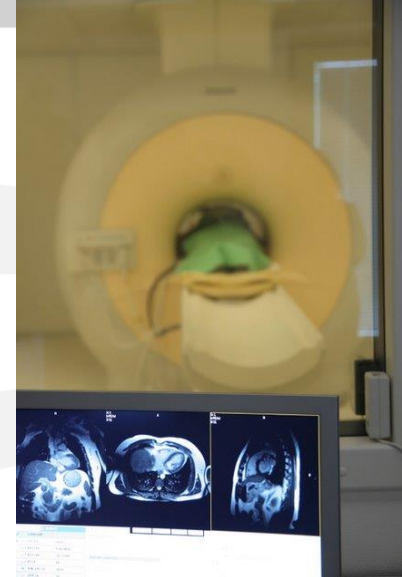Kontraindikációk

- Klausztofóbia (bezártságérzés)
- Agyi aneurizma klippek
- Fülbe vagy szembe ültetett implantátumok
- Nagy mágnesezhető fém a beteg testében (1995 után beültetett protézisek már nem mágnesezhető fémből vannak)
- Nem MR-kondicionális PM és ICD implantáció utáni állapot
- 1985 előtt beültetett szívbillentyűk



MR környezet kockázatai, biztonság 1.

- >300 millió diagnosztikus MR vizsgálat
- 15 publikált haláleset
 - (pacemaker n=10, inzulinpumpa n=2, neurostimulátor n=1, aneurysmaclip n=1, gyerekek: oxigénpalack n=1)
- Több száz súlyos sérülés (égés)
- 250 eset nephrogen systemás fibrózis (MR kontrasztanyag)
- Nem ismert rövid, ill. hosszú távú mellékhatás



MR környezet kockázatai, biztonság 2.

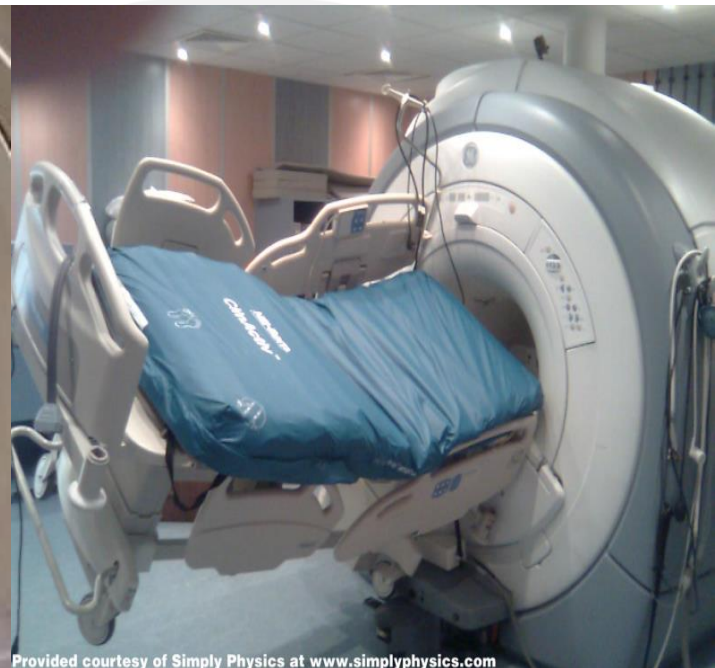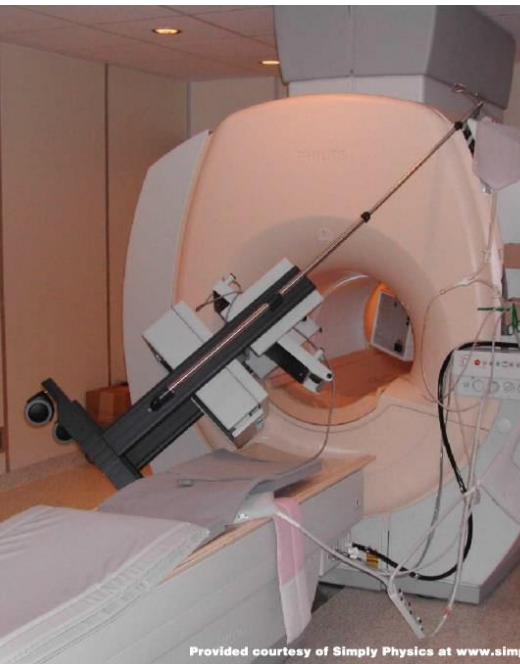Nagy térerejű mágnes (mindig!)

Mágneses erők/forgatónyomaték:

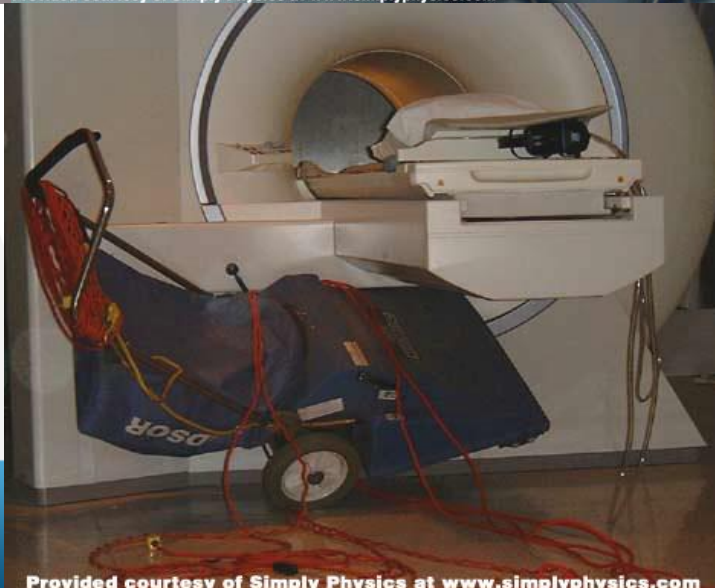- mágnesezhető fémimplantátum (beteg),
- kölcsönhatás az eszközökkel: **repülő tárgyak!**
(beteg és személyzet)



Lövedékhatás, repülő tárgyak



akár 50 km/h sebesség!



Szív MR vizsgálat

- Kamra volumenek, ejekciós frakciók, izomtömegek meghatározása
- Szöveti információ
 - Ödéma
 - Szívizomnekrózis, ill. hegszövet
 - Microvascularis obstructio
- Áramlásmérés

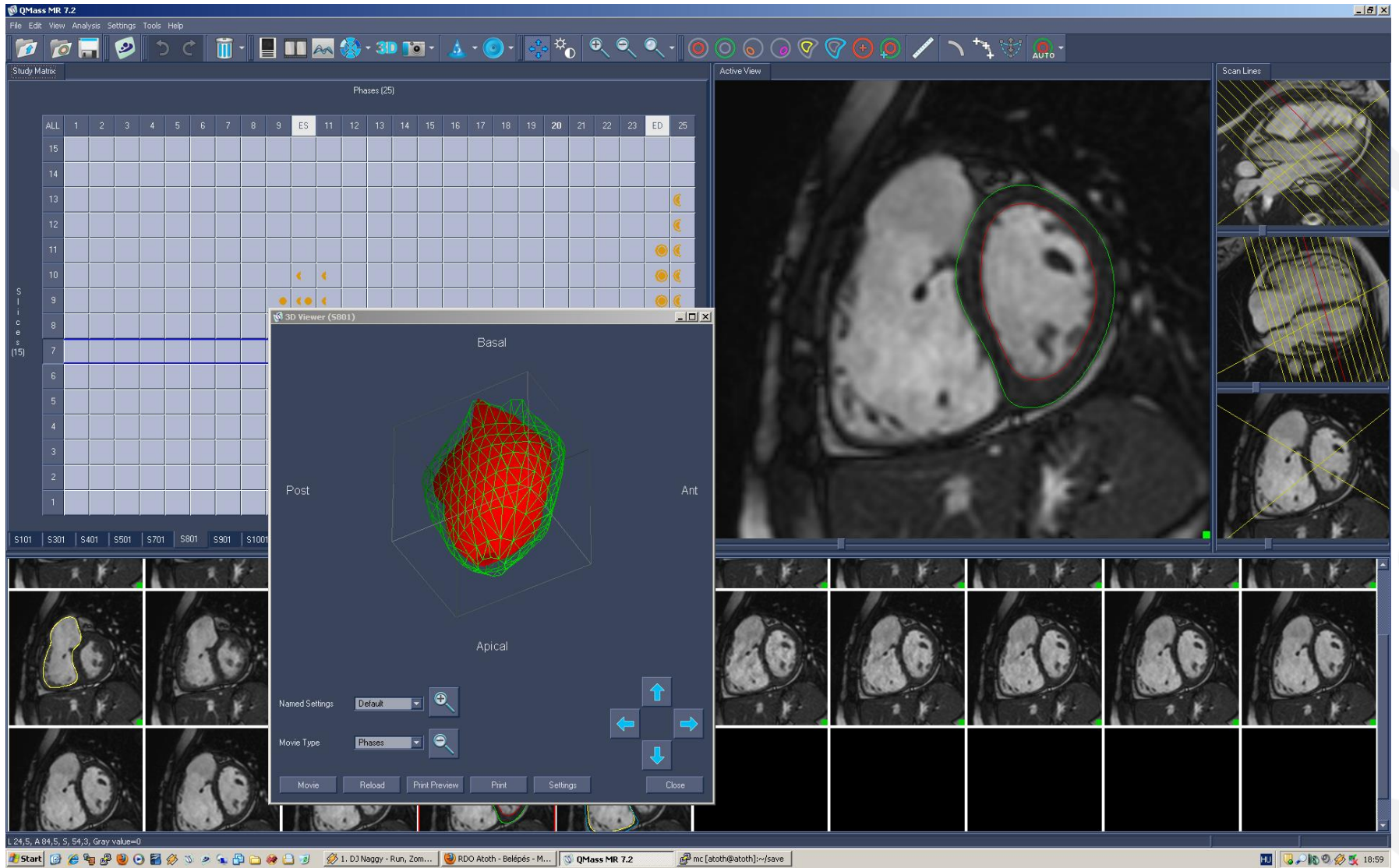


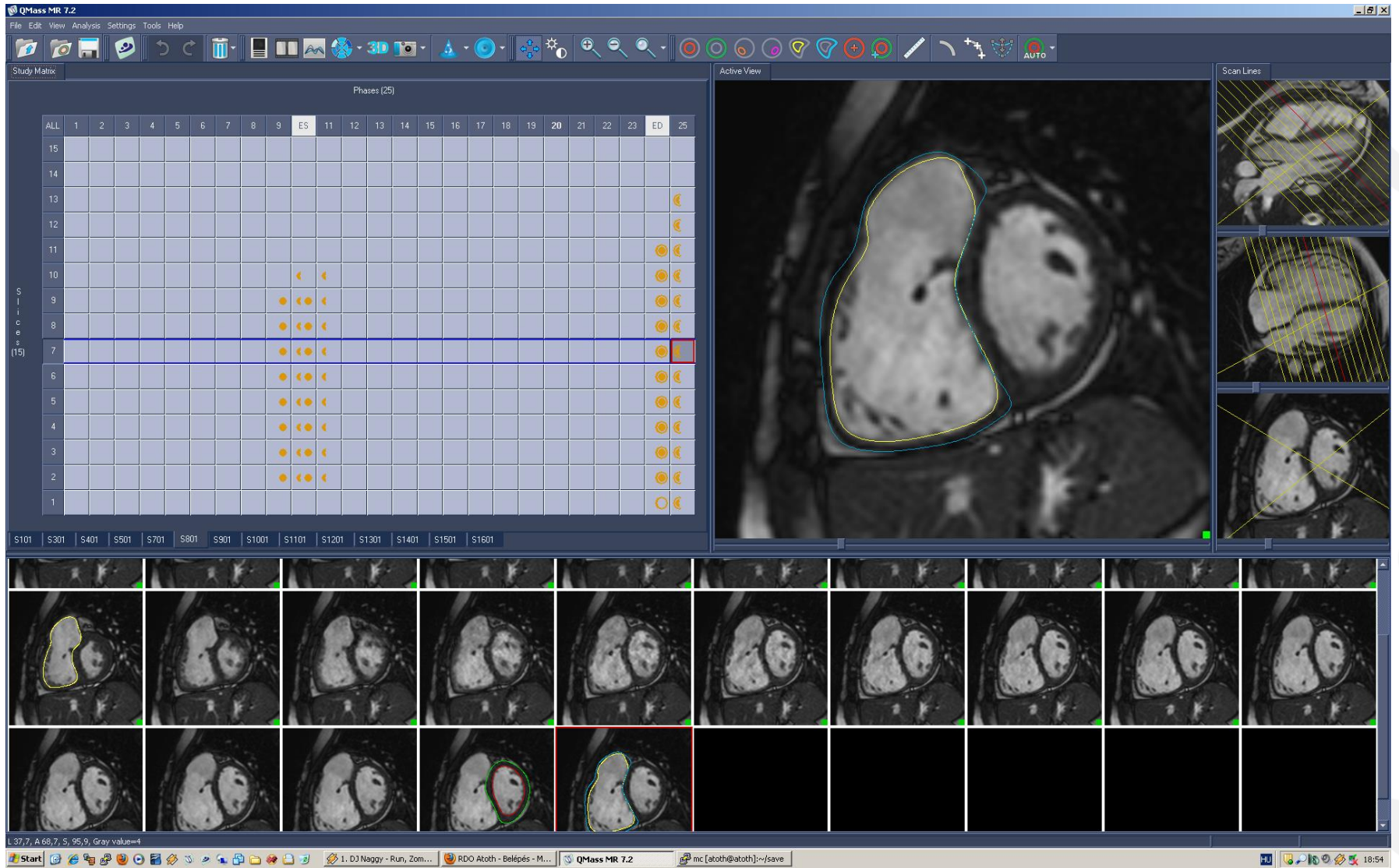
Volumenek, funkció

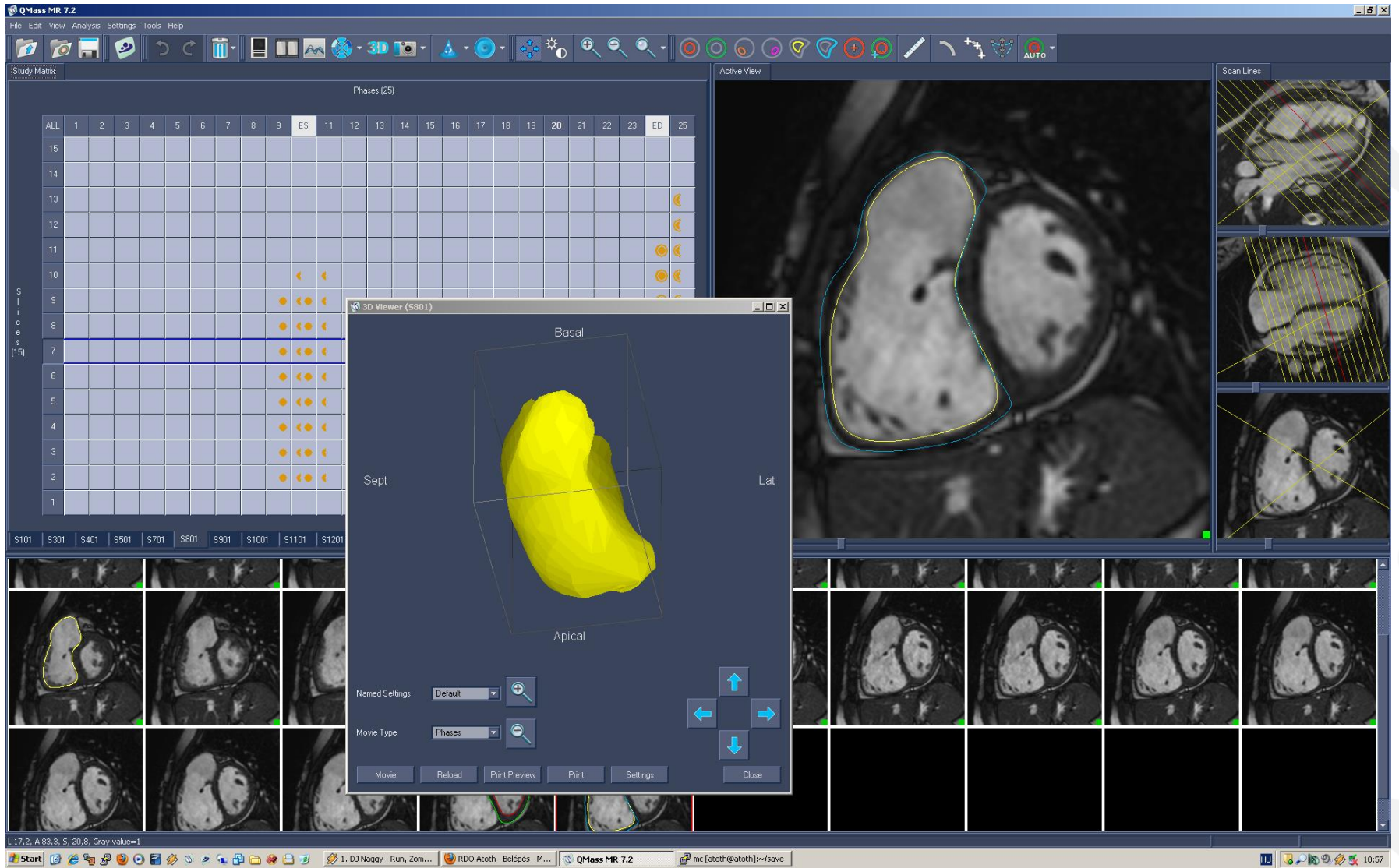
The screenshot displays the QMass MR 7.2 software interface. At the top, there is a menu bar (File, Edit, View, Analysis, Settings, Tools, Help) and a toolbar with various icons for navigation and analysis. Below the menu is the 'Study Matrix' section, which contains a grid of phases (1-25) and slices (1-15). The 'ES' phase is highlighted, and the 'ED' phase is also visible. The 'Active View' section shows a large MRI slice of a heart with a segmented volume outlined in green and red. To the right of the active view are 'Scan Lines' showing a series of yellow lines overlaid on the heart image. At the bottom, there is a row of small thumbnail images showing different slices of the heart, with one slice highlighted in red. The status bar at the bottom left shows 'L 28,4, A 85,2, S, 72,5, Gray value=1'. The taskbar at the bottom shows the Start button, several application icons, and the system tray with the time '18:57'.

Phases (25)	1	2	3	4	5	6	7	8	9	ES	11	12	13	14	15	16	17	18	19	20	21	22	23	ED	25
15																									
14																									
13																									
12																									
11																									
10																									
9																									
8																									
7																									
6																									
5																									
4																									
3																									
2																									
1																									

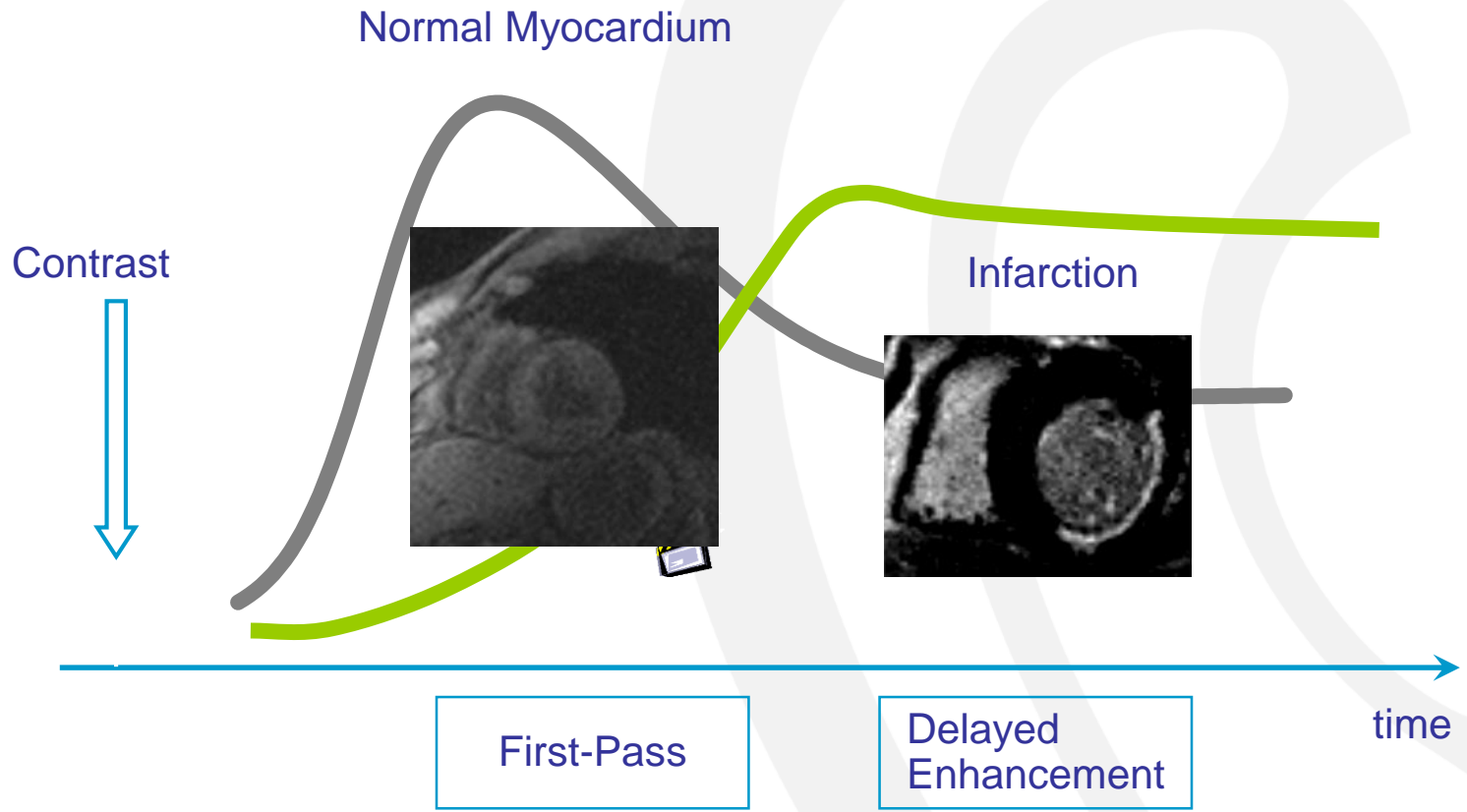








MR perfúzió, késői típusú kontrasztanyag-halmozás



Kontrasztanyag-halmozás

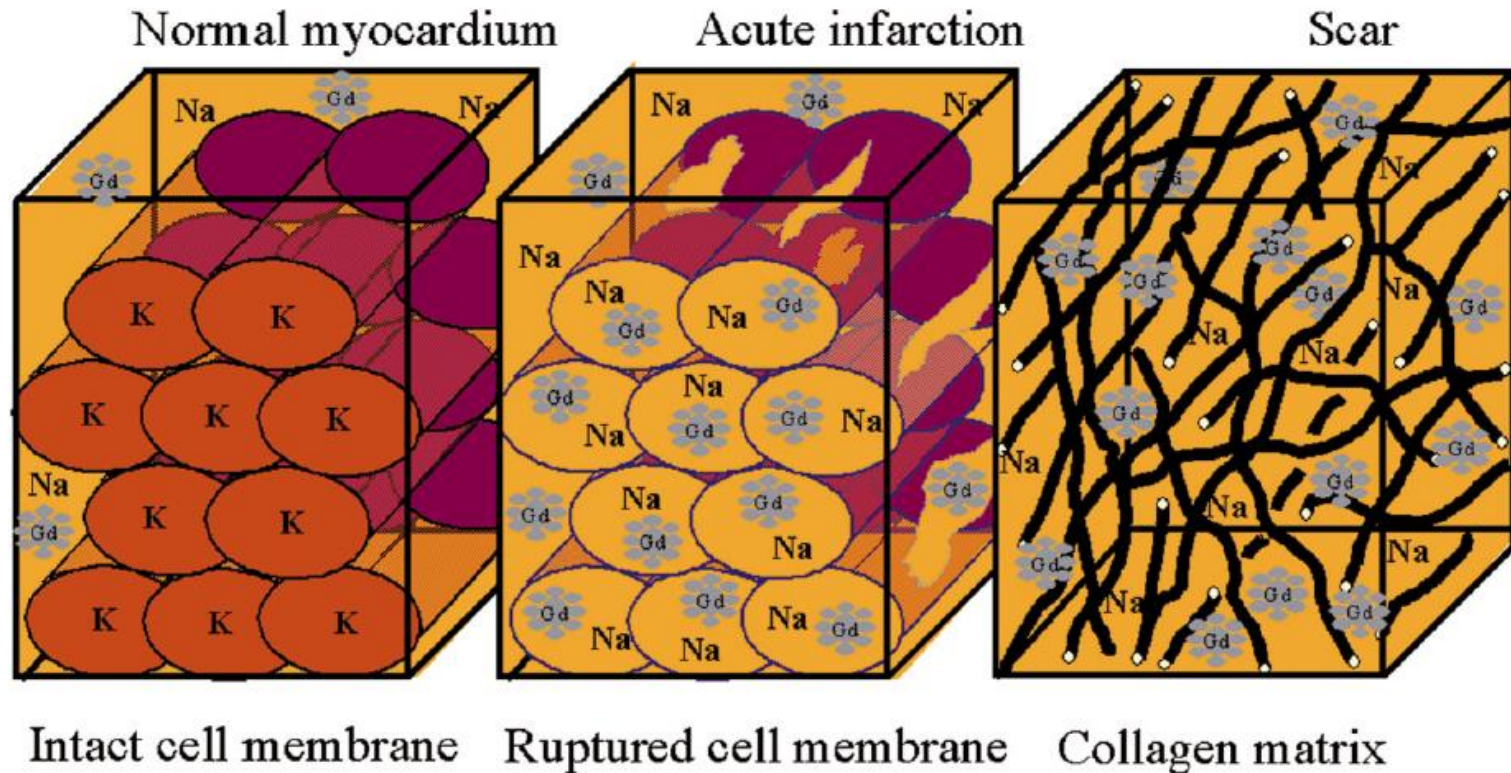
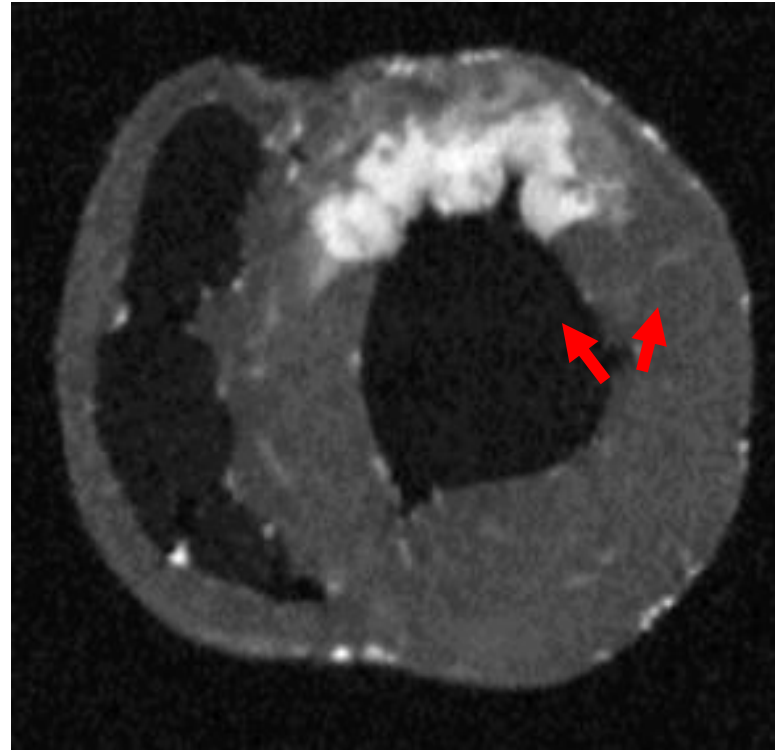
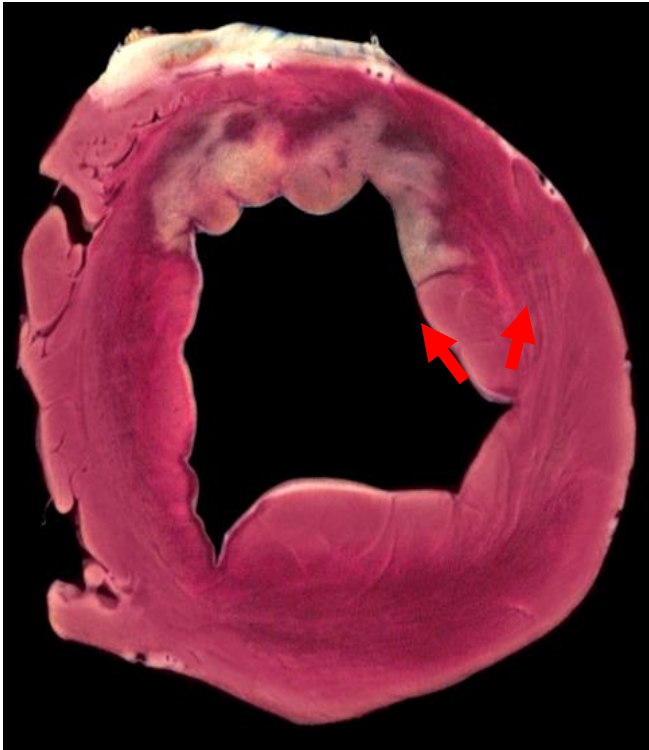


Figure 8. Potential mechanisms of hyperenhancement in acute and chronic MI. See text for details. (Reprinted with permission from Cardiovascular MRI and MRA. Charles B. Higgins, editor. Lippincott Williams & Wilkins, 2002.)

Késői kontrasztanyag-halmozás




Ischemic

A Subendocardial Infarct




B Transmural Infarct



Nonischemic

A Mid-wall HE

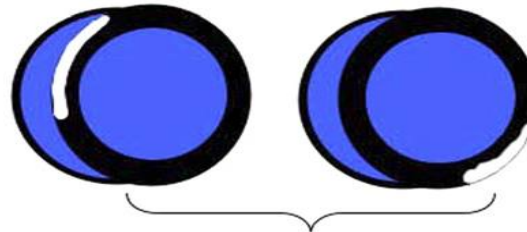


- Idiopathic Dilated Cardiomyopathy
- Myocarditis

- Hypertrophic Cardiomyopathy
- Right ventricular pressure overload (e.g. congenital heart disease, pulmonary HTN)

- Sarcoidosis
- Myocarditis
- Anderson-Fabry
- Chagas Disease

B Epicardial HE



- Sarcoidosis, Myocarditis, Anderson-Fabry, Chagas Disease

C Global Endocardial HE



- Amyloidosis, Systemic Sclerosis, Post cardiac transplantation

Karamitsos J Am Coll Cradiol 2009

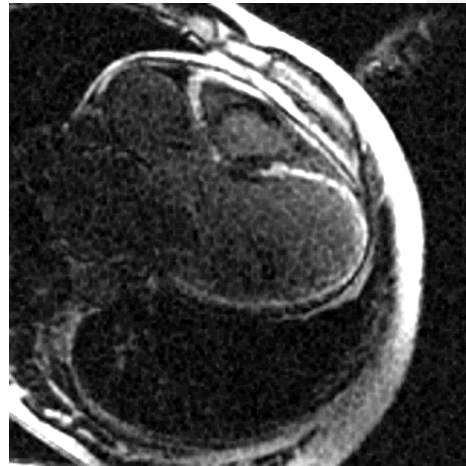
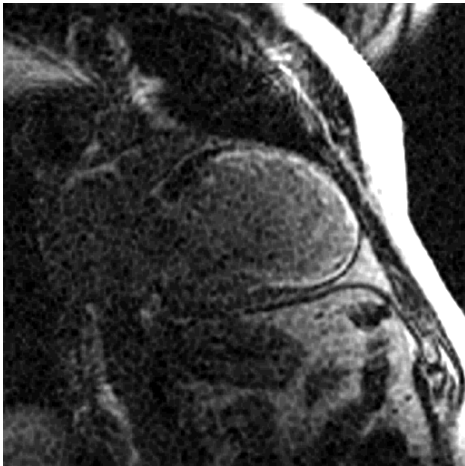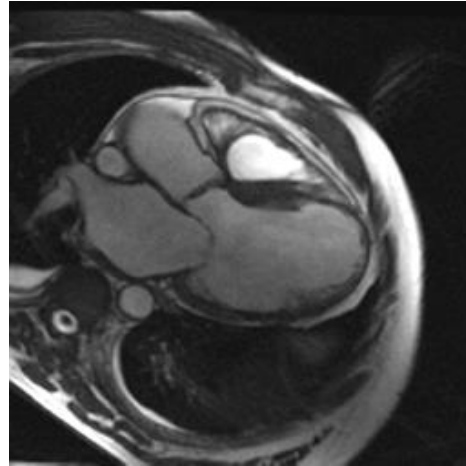
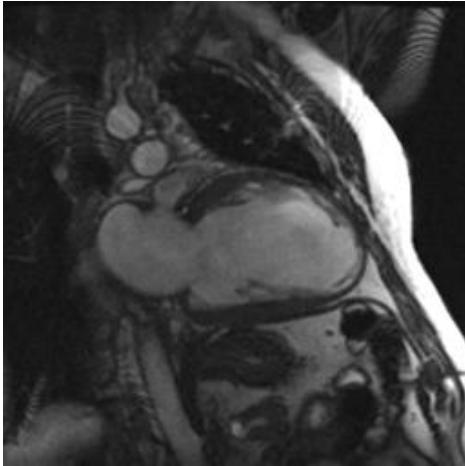


Indikációk

- **Ischaemiás szívbetegség**
- Cardiomyopathiák
- Veleszületett szívbetegség
- Myocarditis
- Pericardium betegségei
- Tumorok

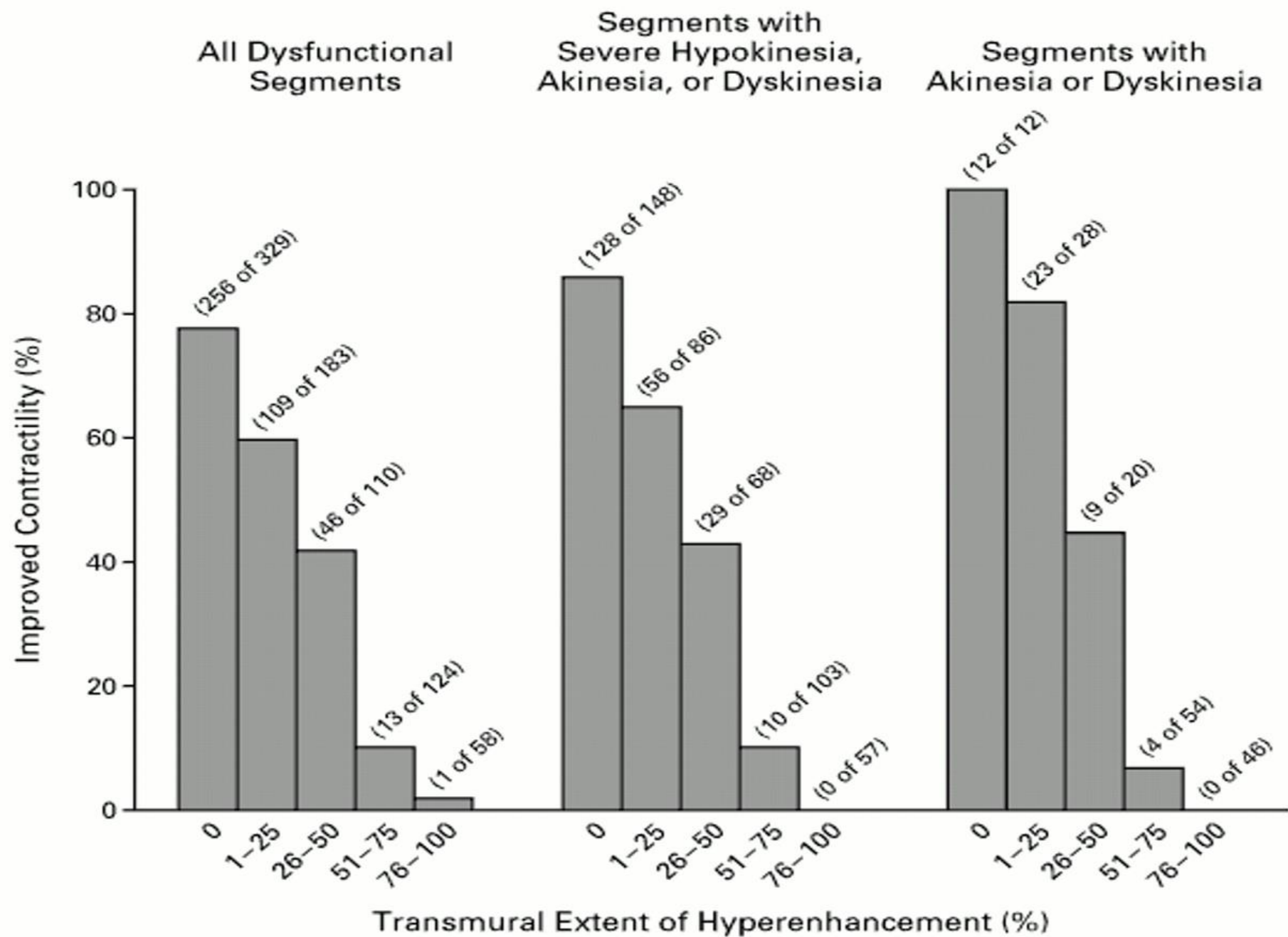


Ischaemiás szívbetegség



- ◆ Globális és regionális bal kamra funkció
- ◆ Viabilitás: „the bright is dead”





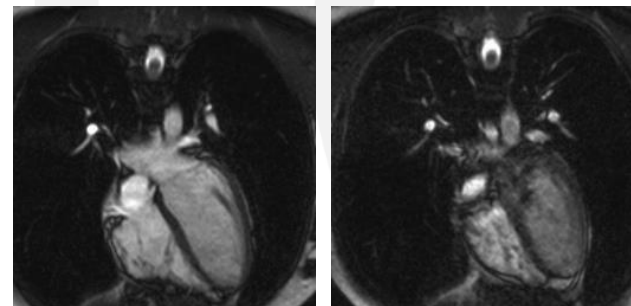
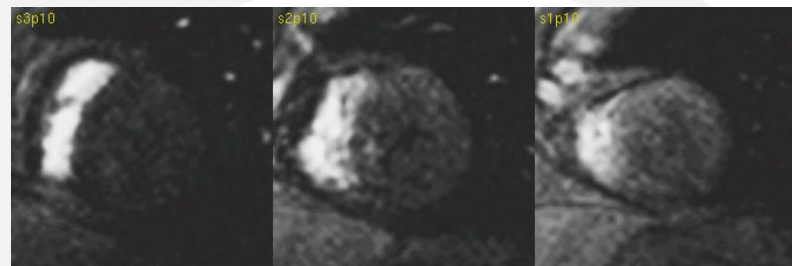
Stressz MR

- Adenozin stressz perfúzió
szenzitivitás ~91%, specificitás ~81%

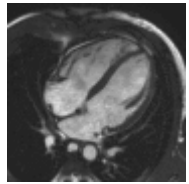
3 rövidtengelyi szelet: basalis, kp., csúcsi
minden szívciklusban

- Dobutamin/atropin stressz MR
szenzitivitás ~ 83%, specificitás ~ 86%
- 3 rövidtengelyi szelet: basalis, kp., csúcsi, ill.
hossztengelyi síkokban

- (Kerékpáros)

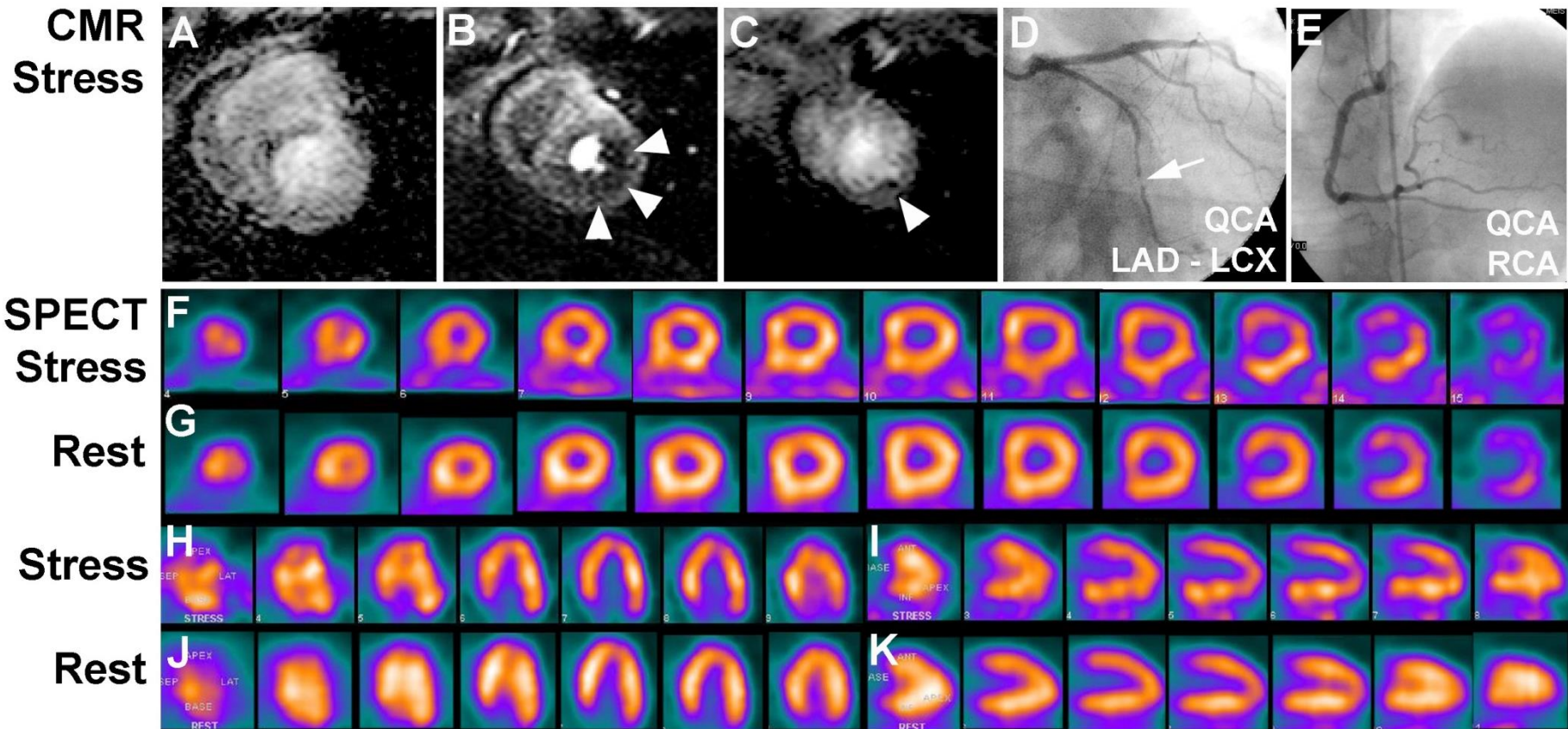


Terheléses protokoll



- **Dobutamin** (terheléses protokoll hasonló a stressz ECHO-hoz)
 - 0-tól 40 $\mu\text{g}/\text{kg}/\text{perc}$, 10-es lépésekben
 - 5 percenként, rövid és hossz tengelyi sorozat
 - Elégtelen célfrekvencia esetén: 0,25 – 1 mg atropin adható
- **Adenozin**
 - Dózis: 0,140 $\mu\text{g}/\text{ttkg}/\text{perc}$
 - Időtartam: 3-4 perc (0,84 mg/kg teljes dózis), hatás 1-2 perc, biztonságos
- **Terhelésben jártas személy jelenléte**
 - Asszisztens vagy szakorvos a vizsgáló helyiségben
 - Folyamatos kommunikáció
 - MR kondicionális monitorrendszer

Stressz MR – SPECT - coronarographia multicentrikus IMPACT-I study

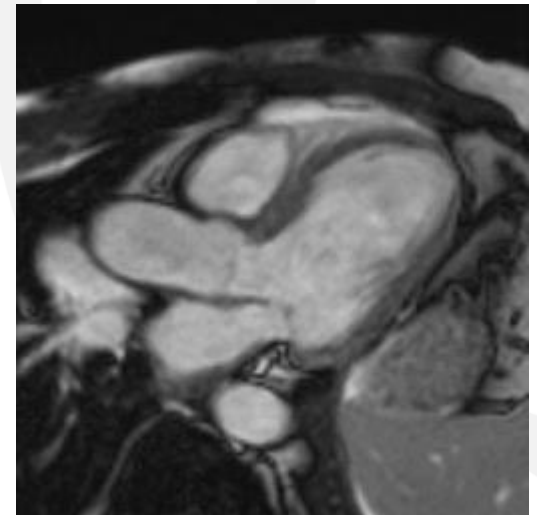
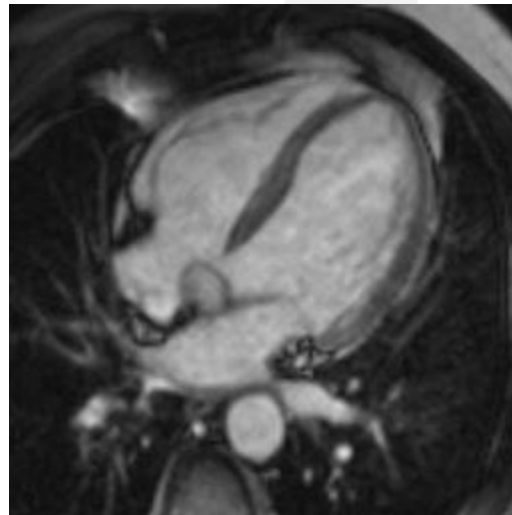
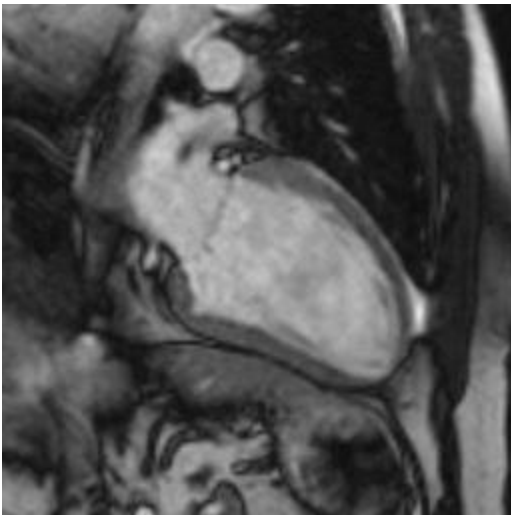
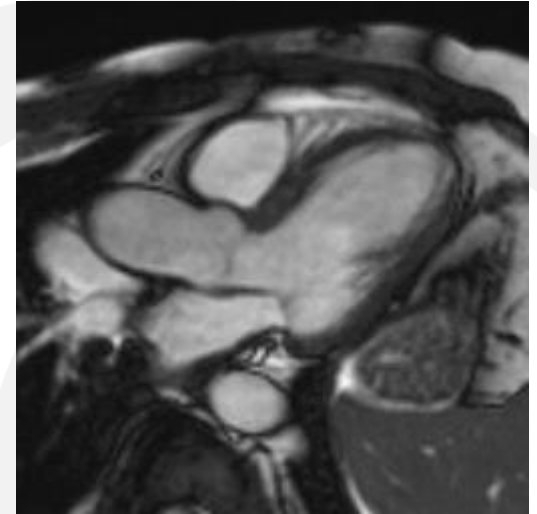
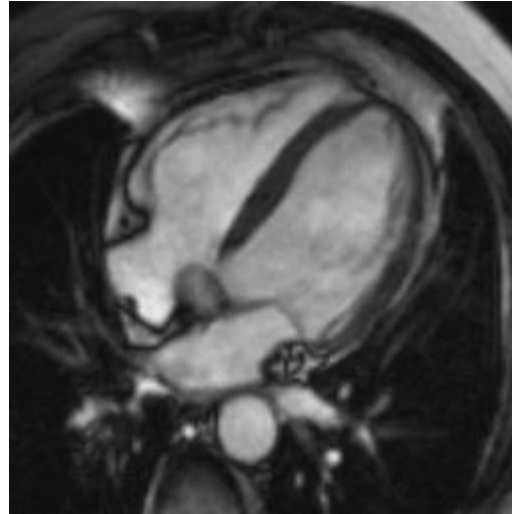
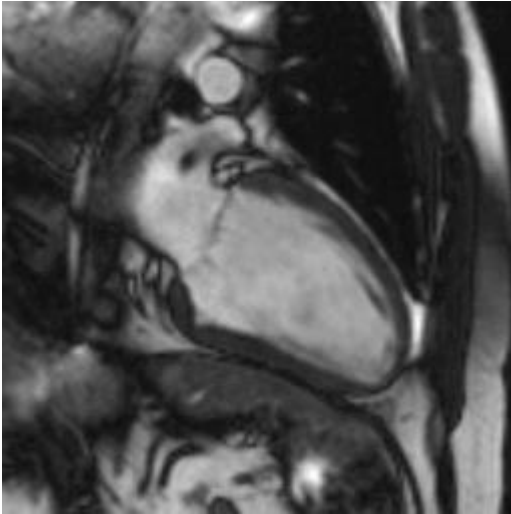


O.L. 61 éves férfi

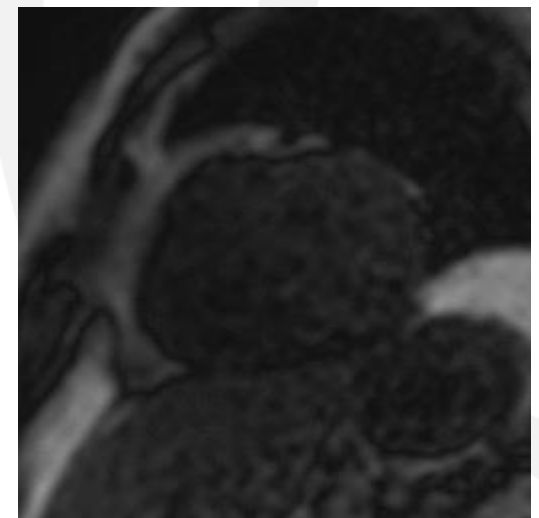
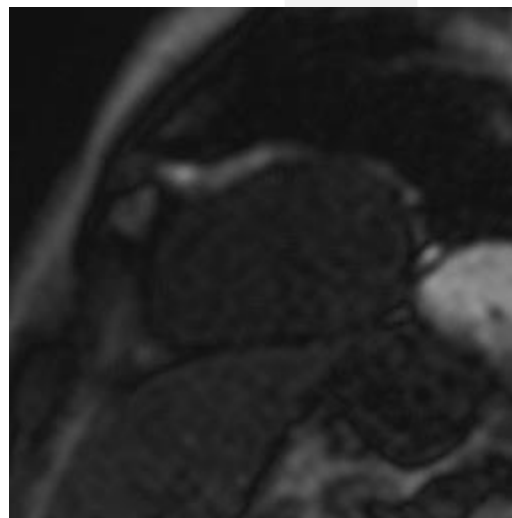
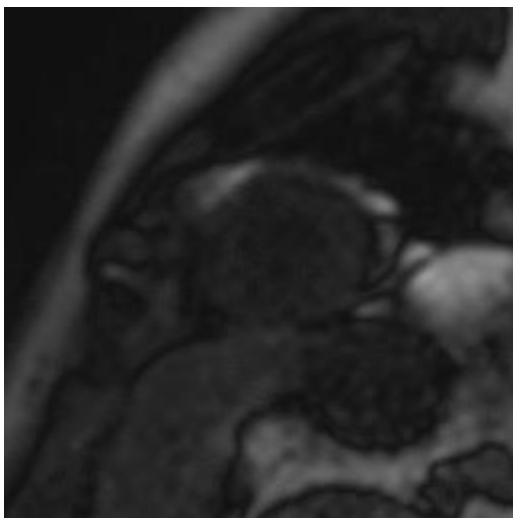
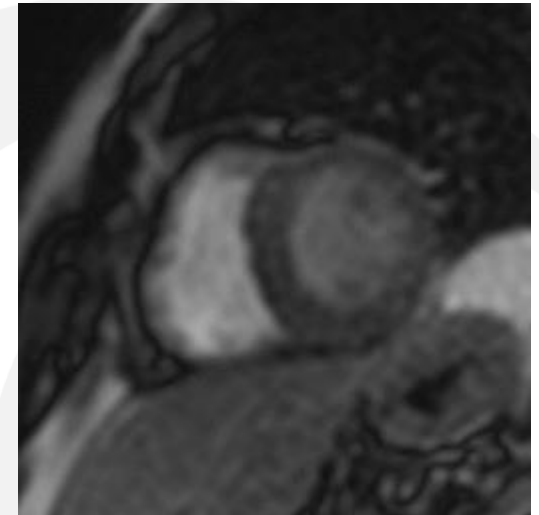
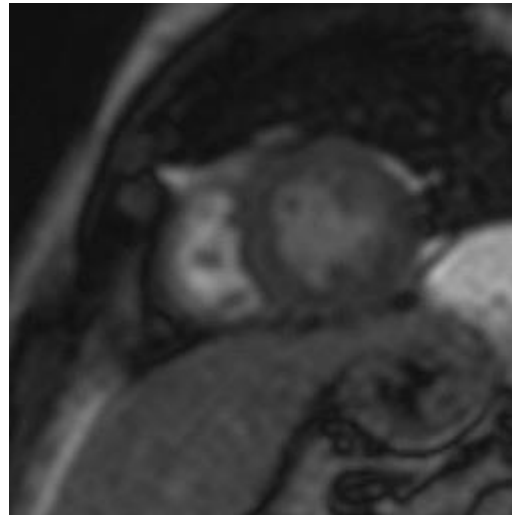
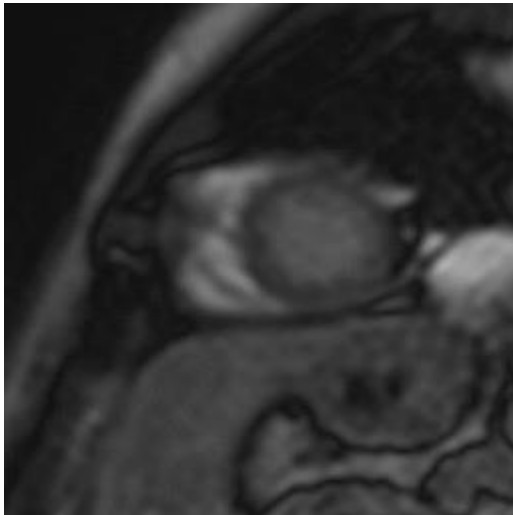
Típusos effort anginás
panaszok, közepes
kardiovaszkuláris rizikó,
inkonklúzív terheléses EKG



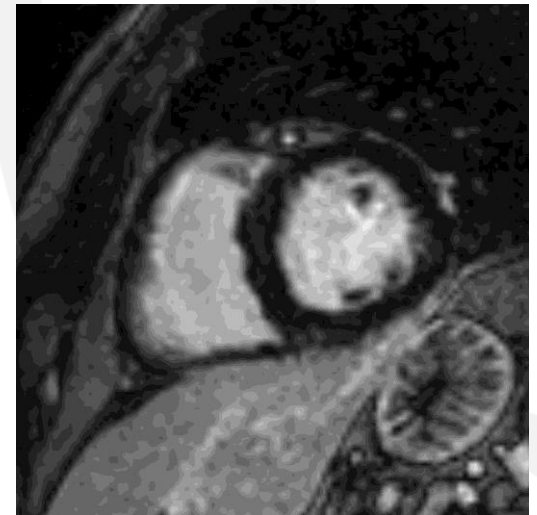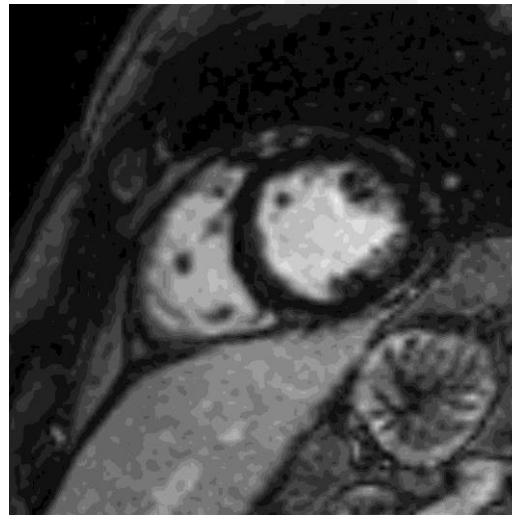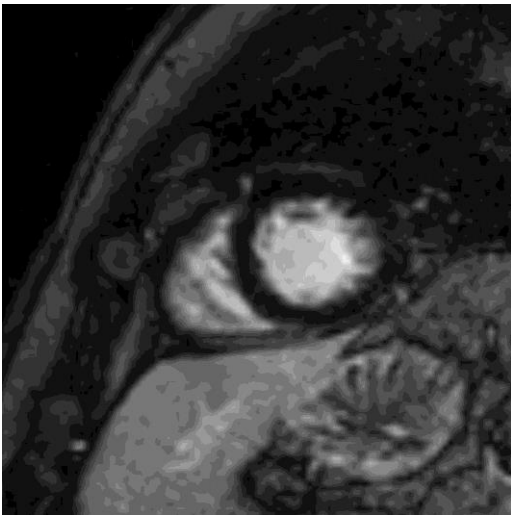
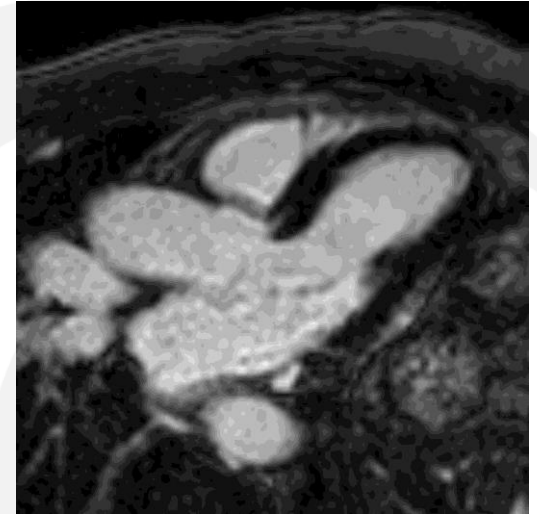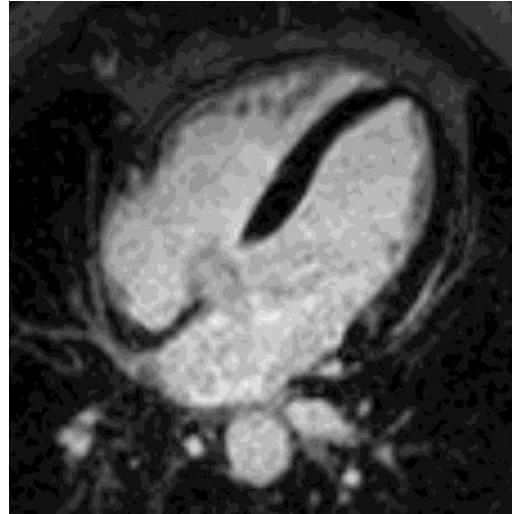
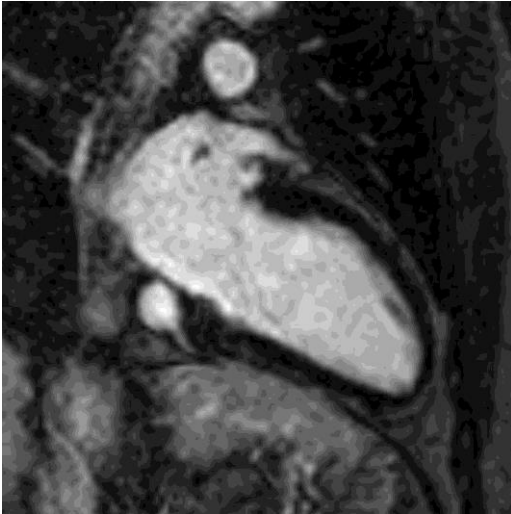Nyugalmi és terheléses LA cine



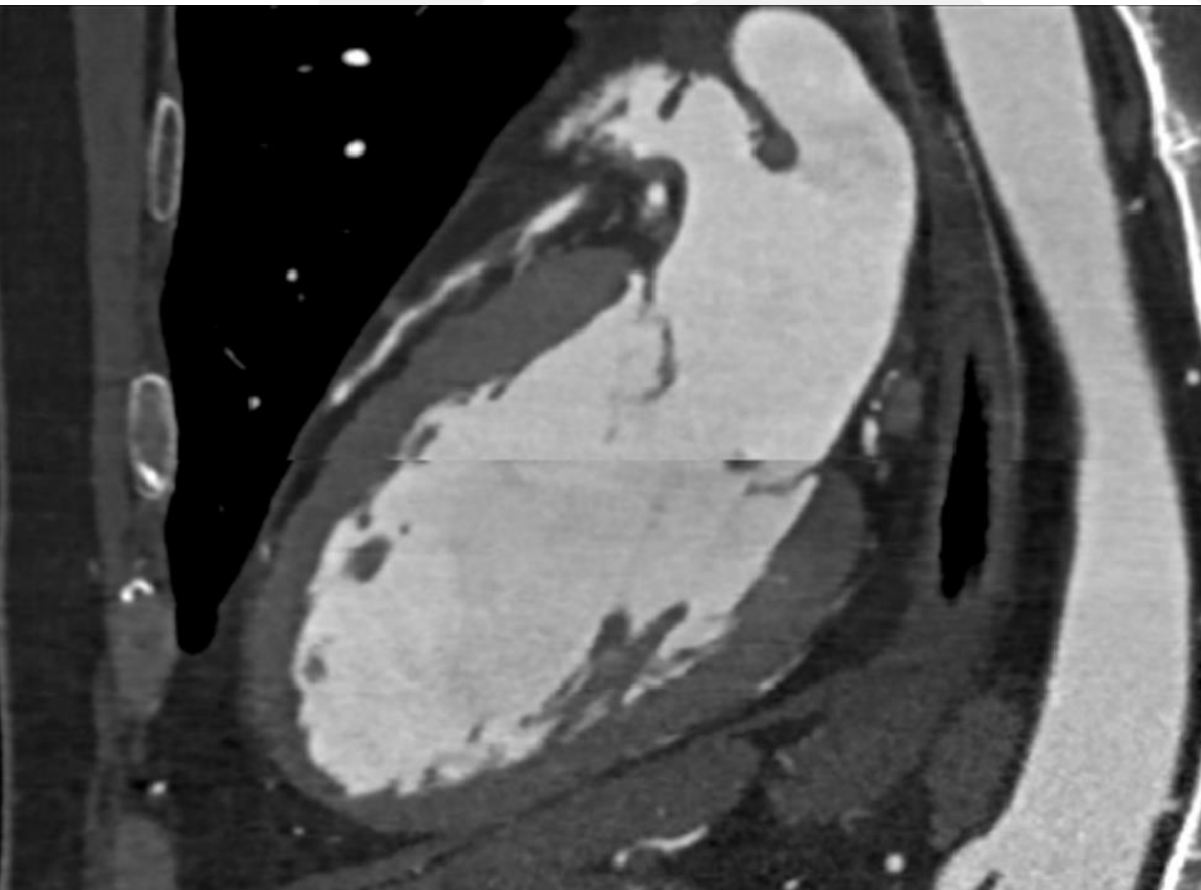
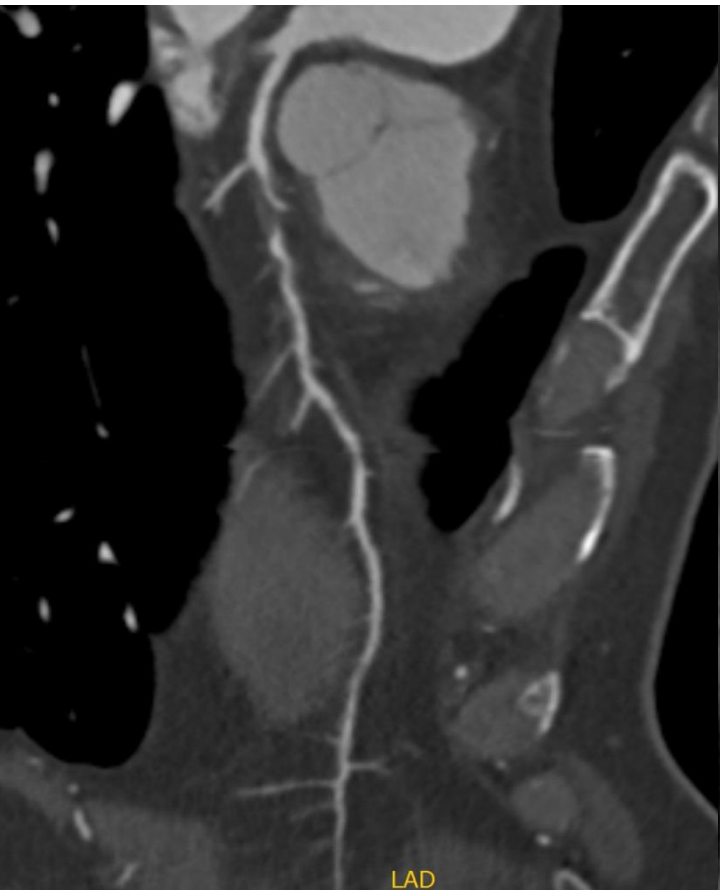
Nyugalmi és terheléses perfúzió



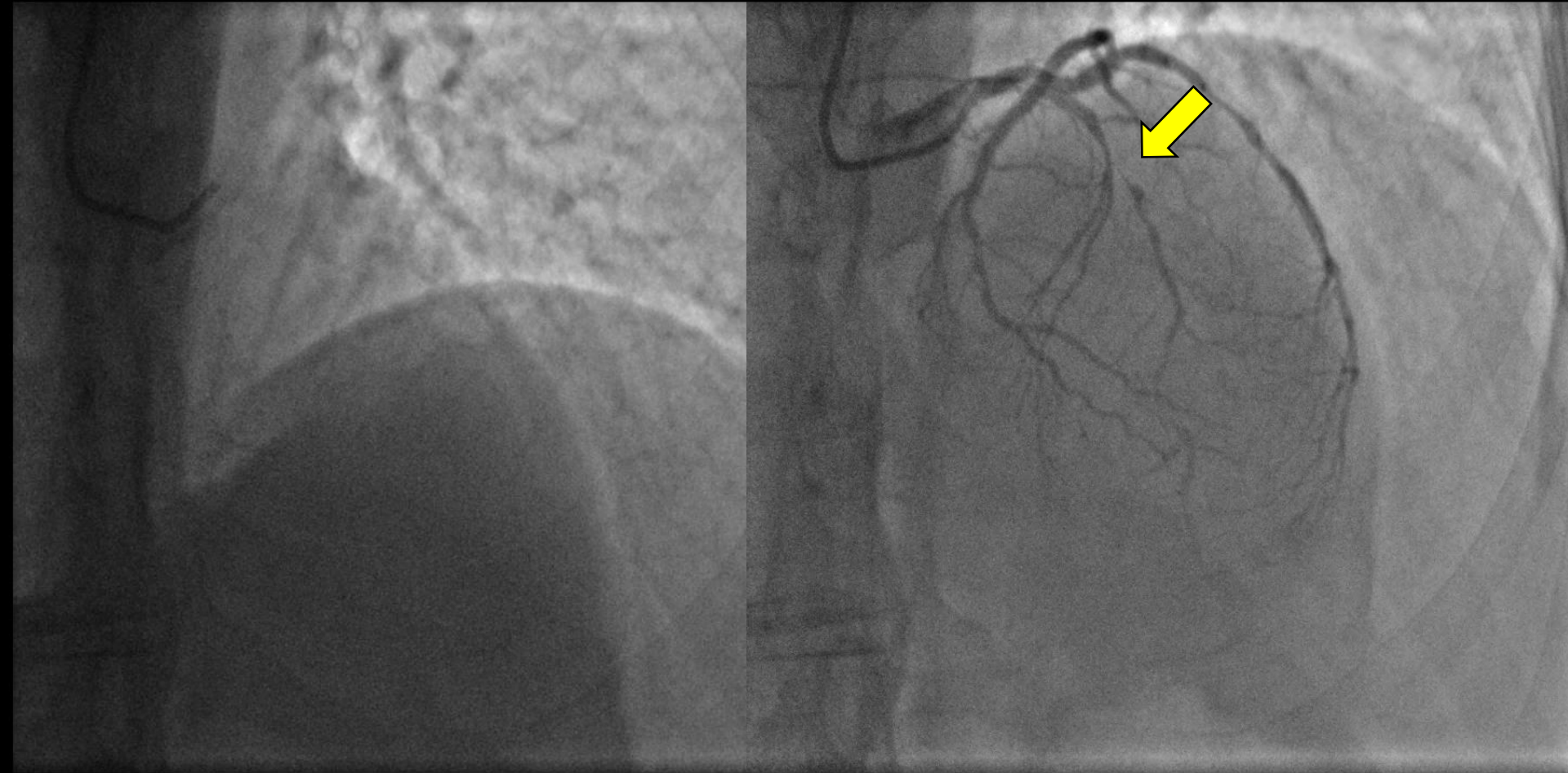
LA és SA DE



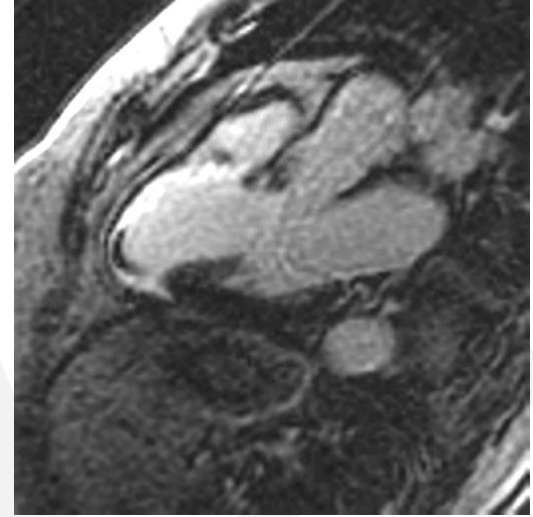
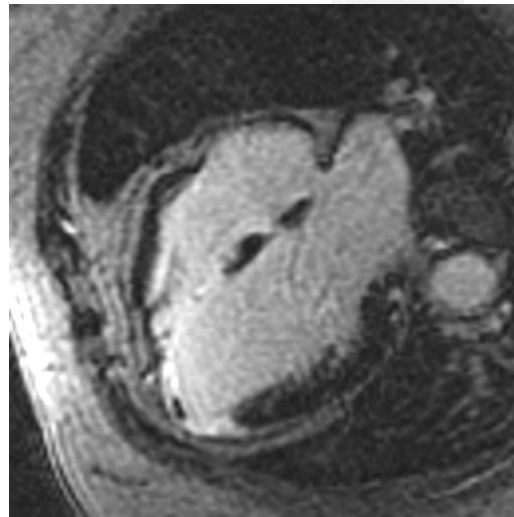
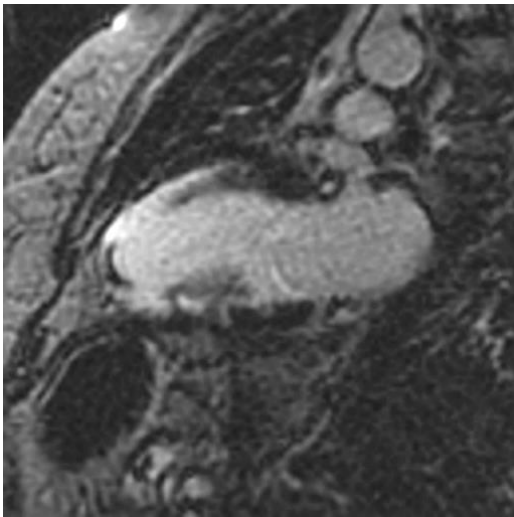
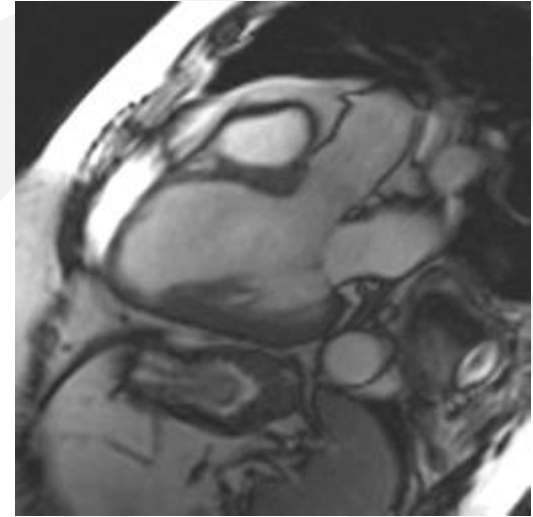
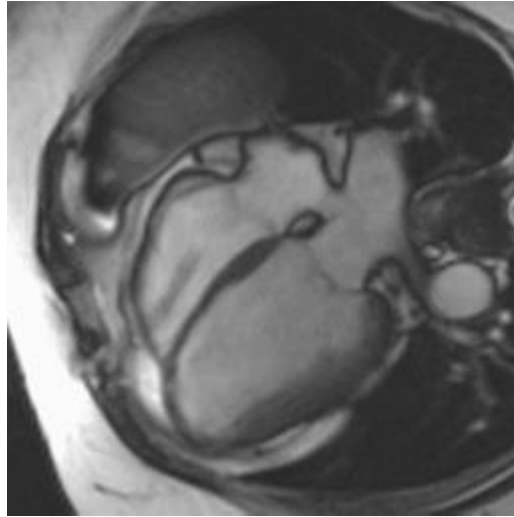
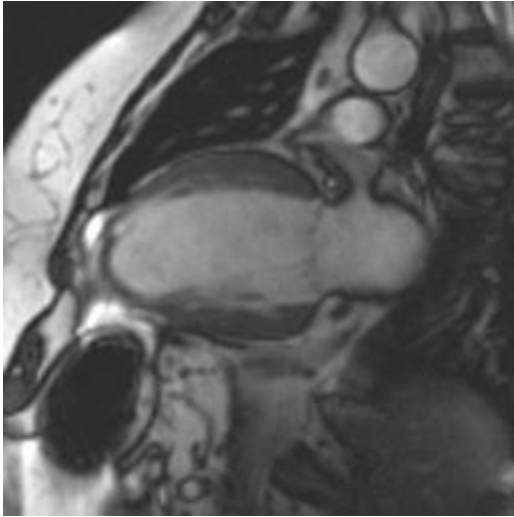
Coronaria CT: nem kalcifikált plakk súlyos fokú stenosis



Hemodinamika



Nem viábilis

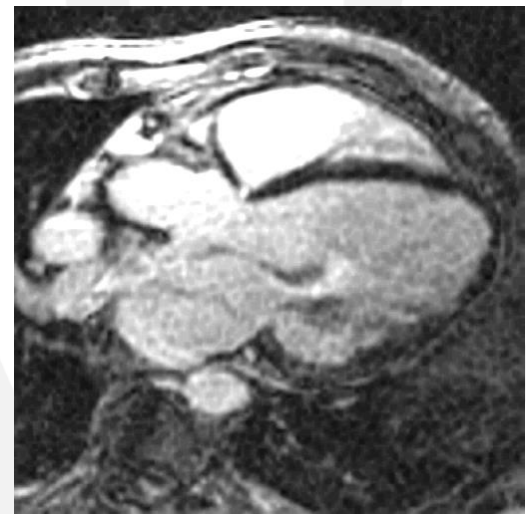
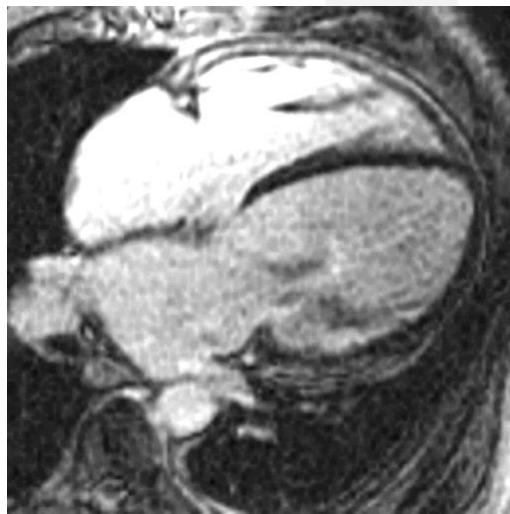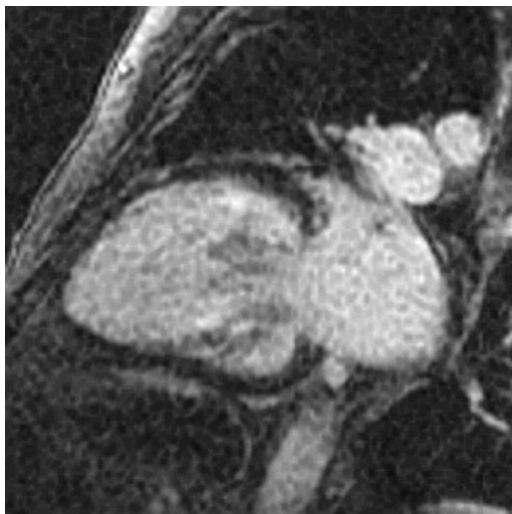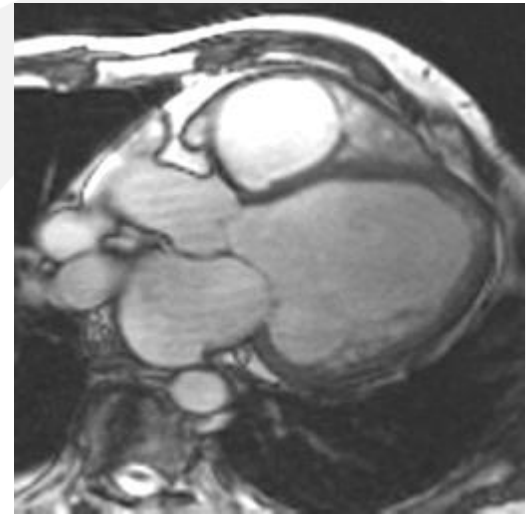
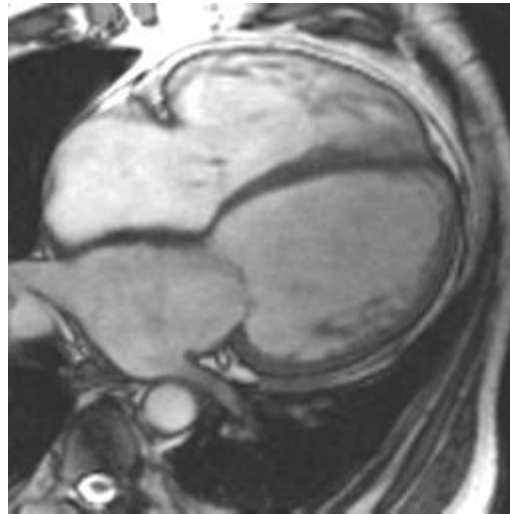
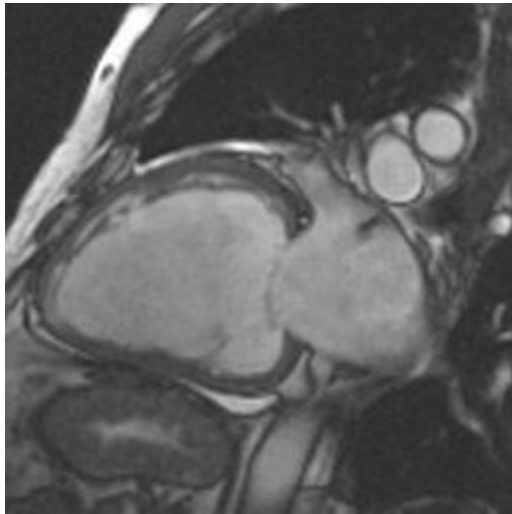


Indikációk

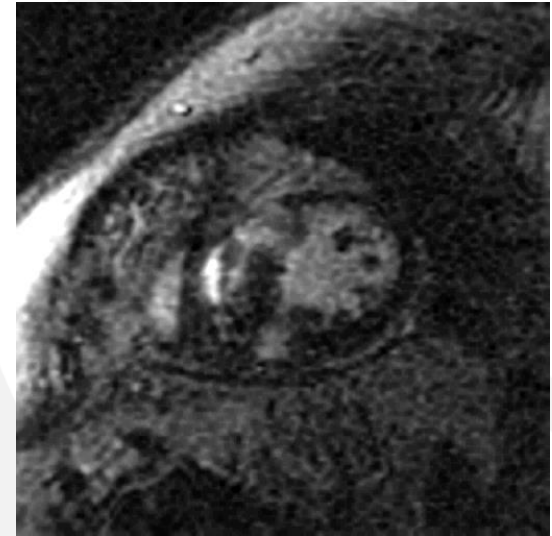
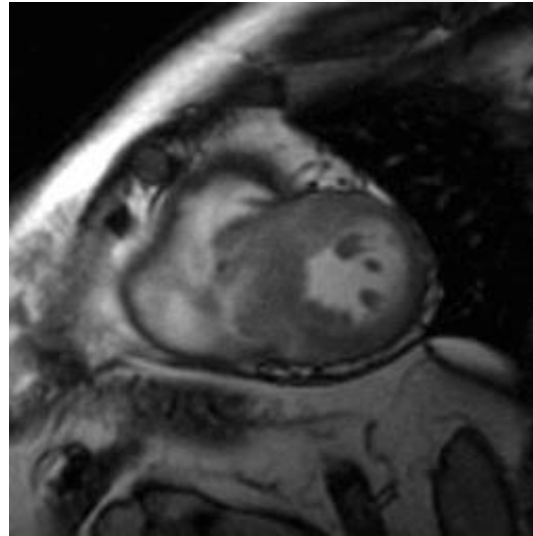
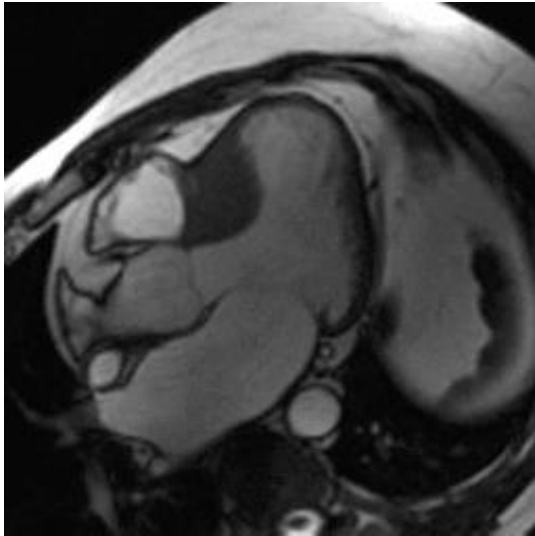
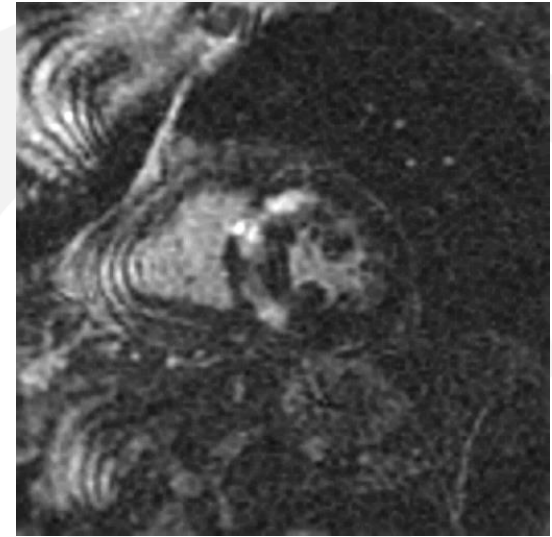
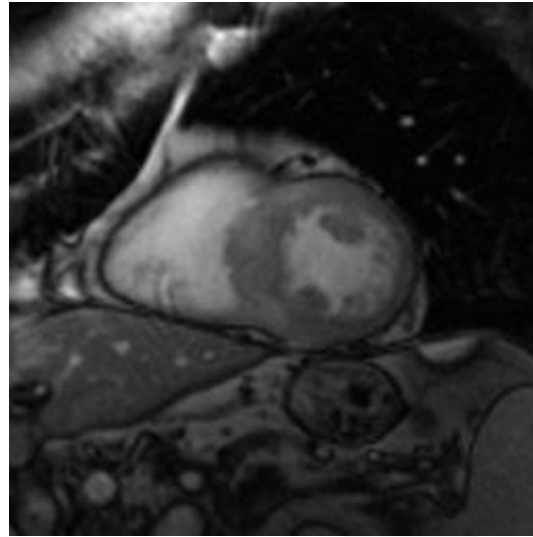
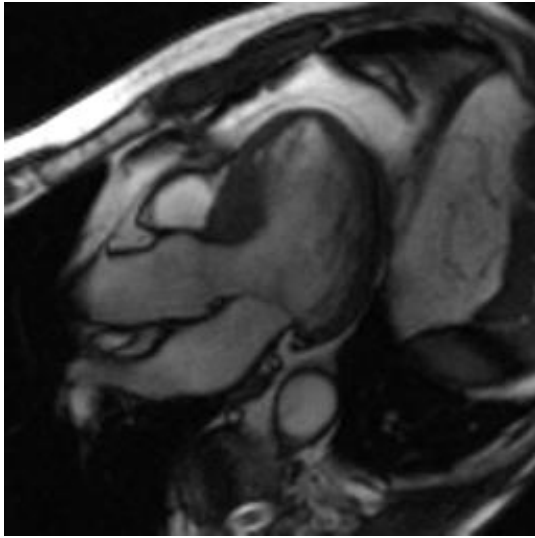
- Ischaemiás szívbetegség
- **Cardiomyopathiák**
- Veleszületett szívbetegség
- Myocarditis
- Pericardium betegségei
- Tumorok



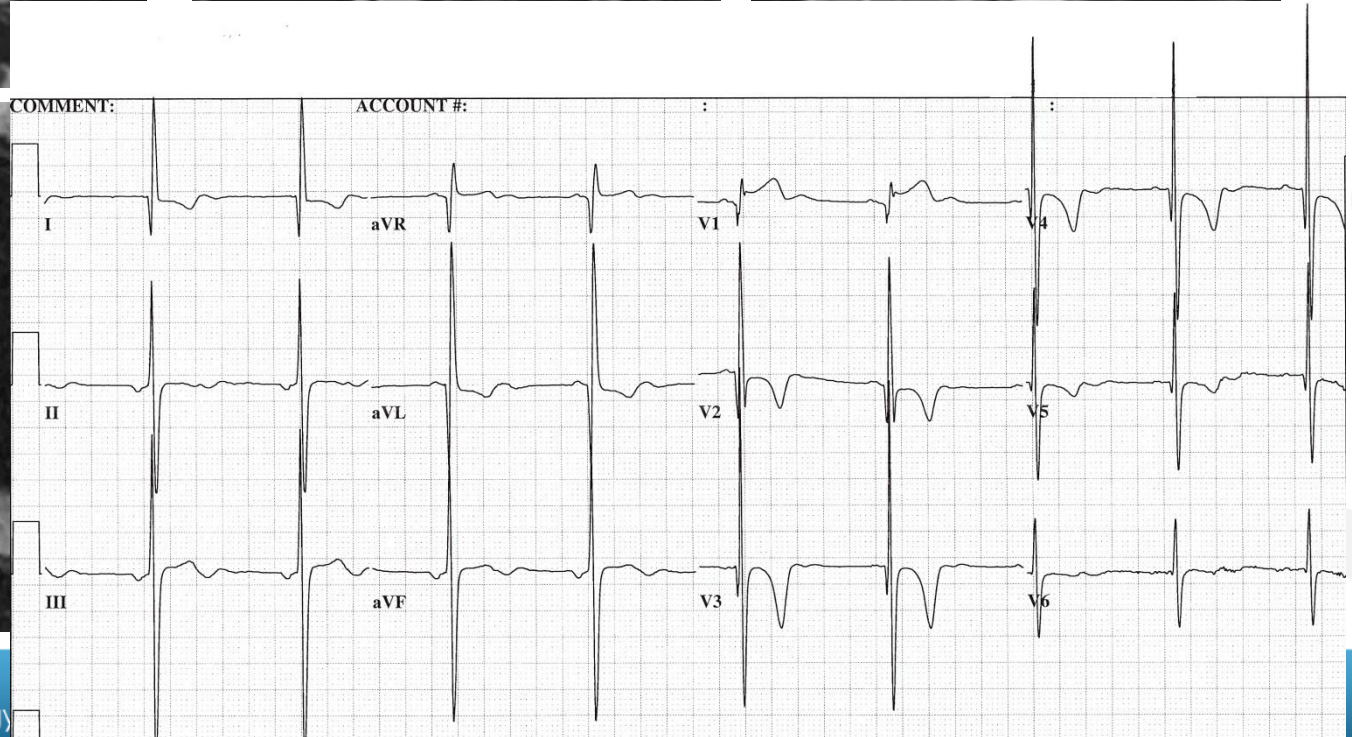
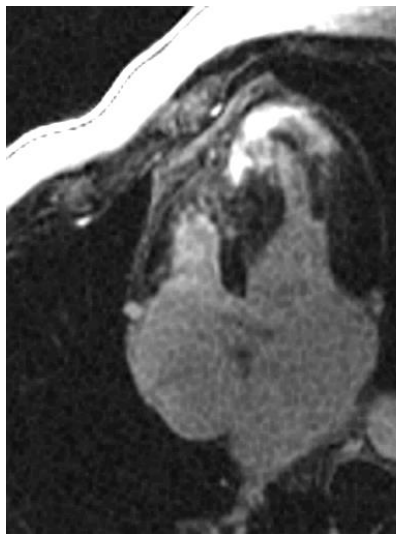
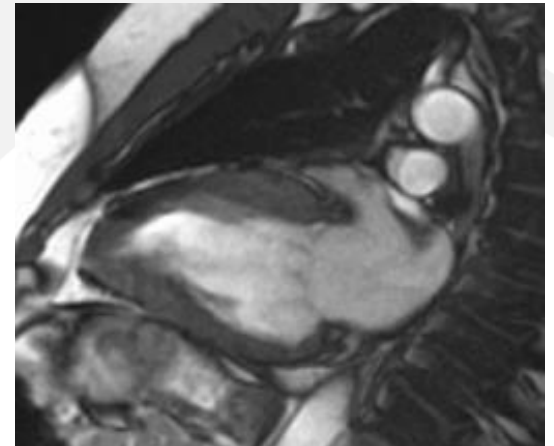
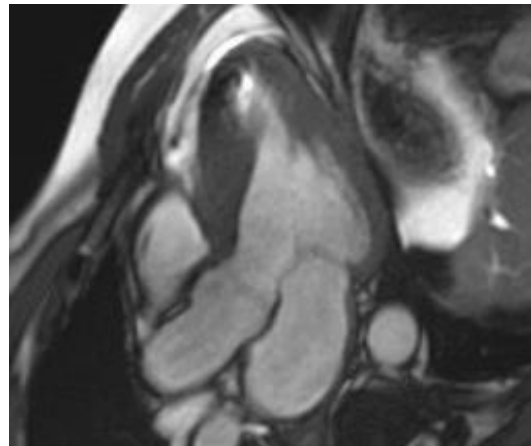
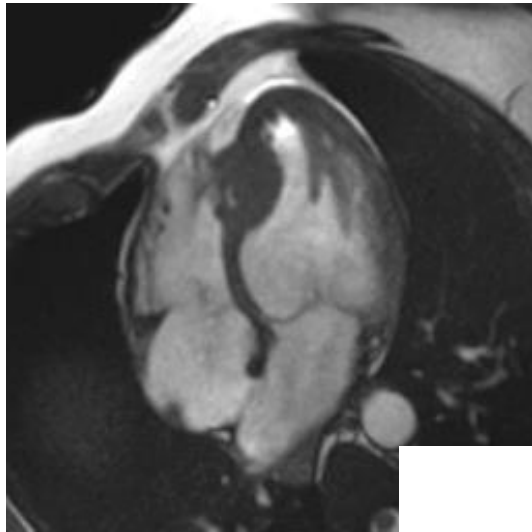
Dilatatív cardiomyopathia



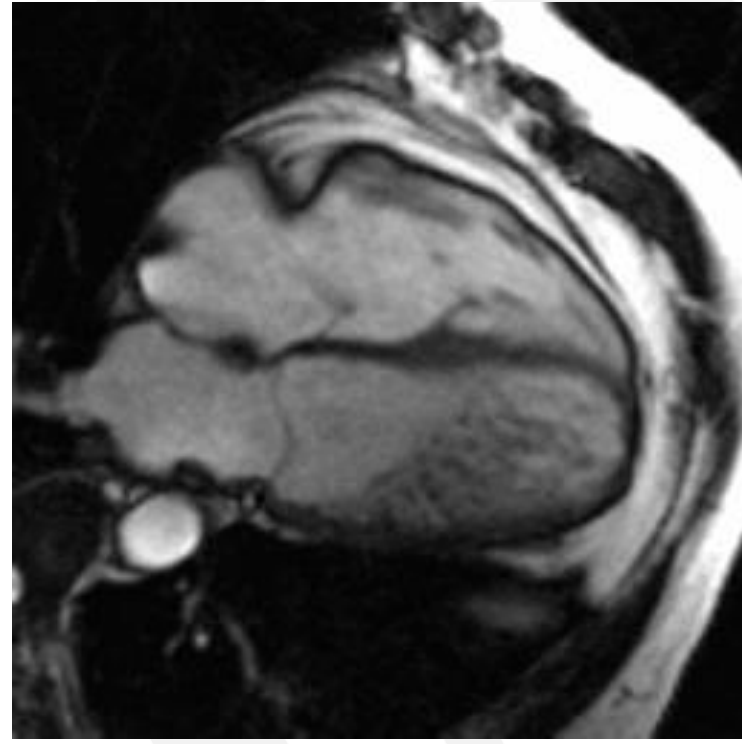
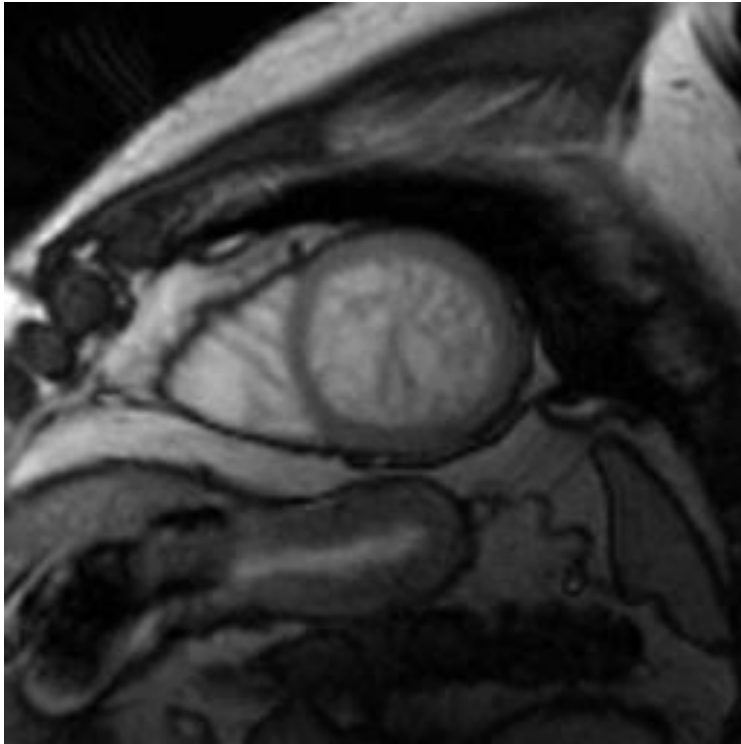
Hypertrophiás cardiomyopathia



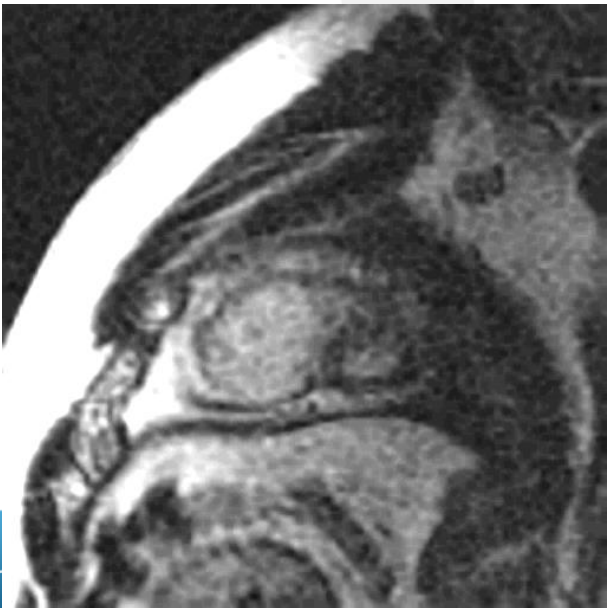
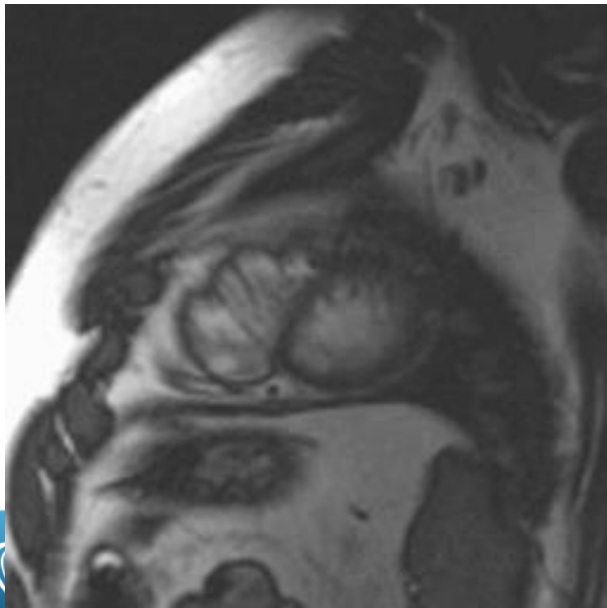
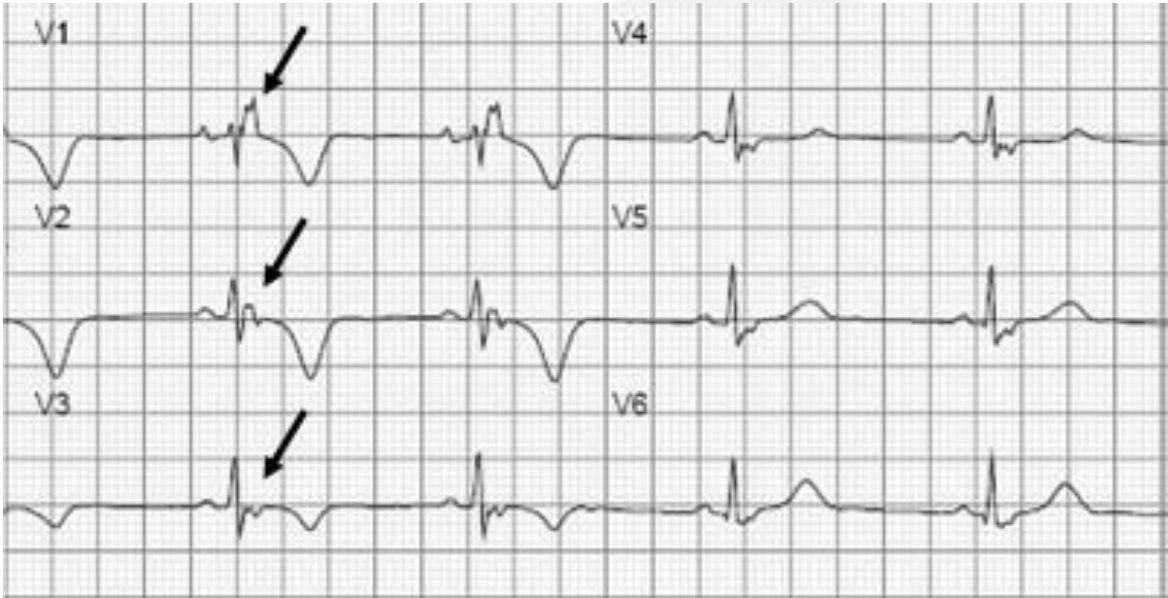
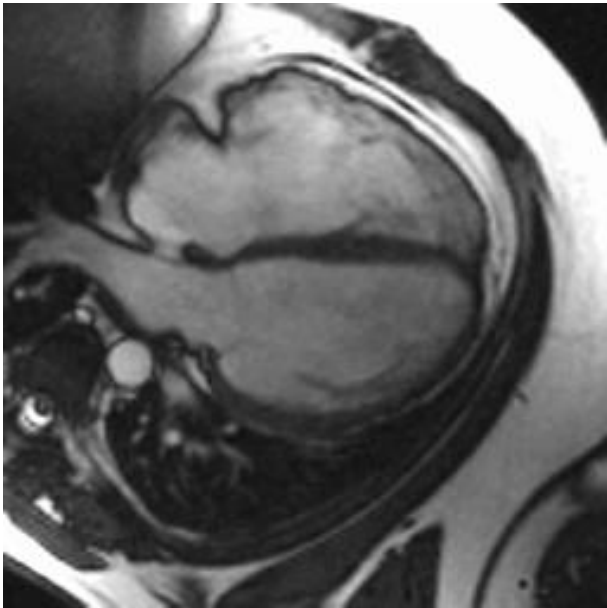
Hypertrophiás cardiomyopathia



Non-compact cardiomyopathy



Arrhythmogenic right ventricular cardiomyopathy/dysplasia (ARVD)



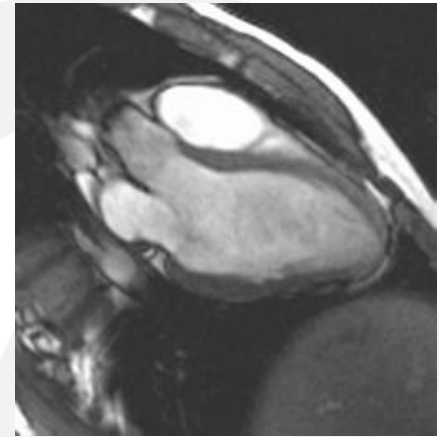
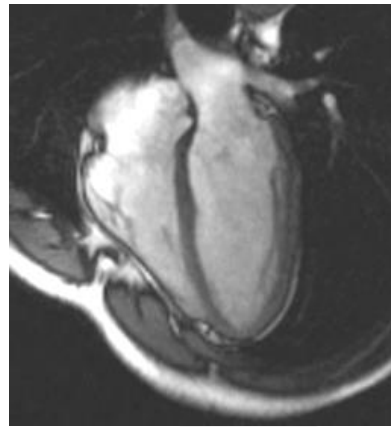
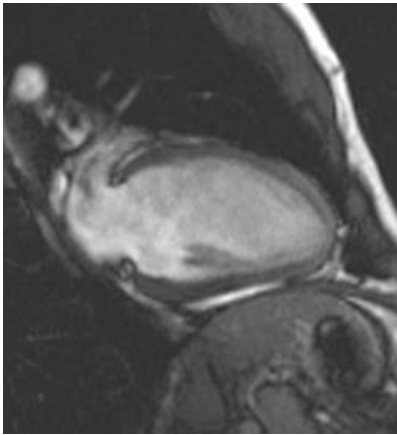
Indikációk

- Ischaemiás szívbetegség
- Cardiomyopathiák
- Veleszületett szívbetegség
- **Myocarditis**
- Pericardium betegségei
- Tumorok

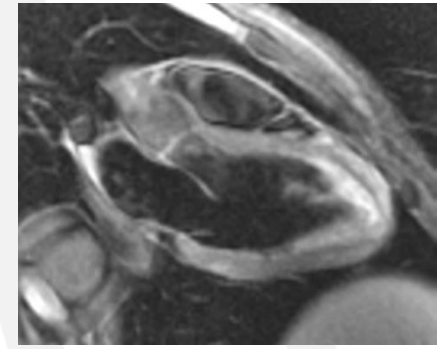
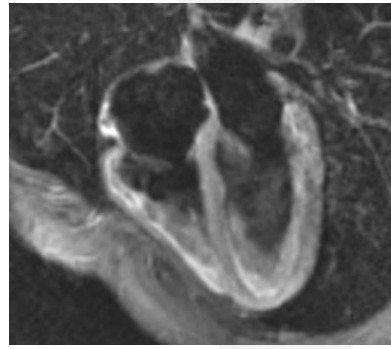
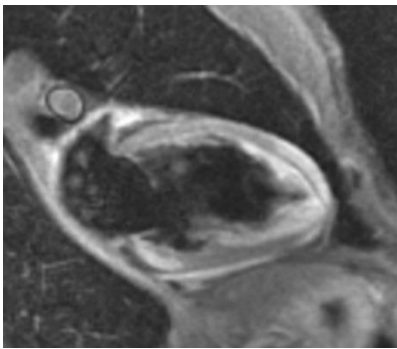


Acut myocarditis

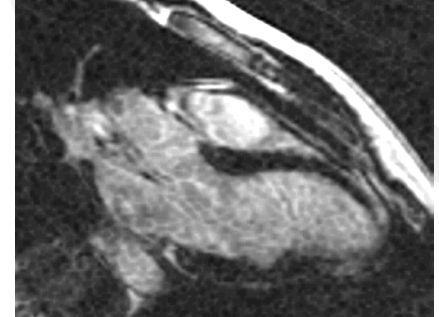
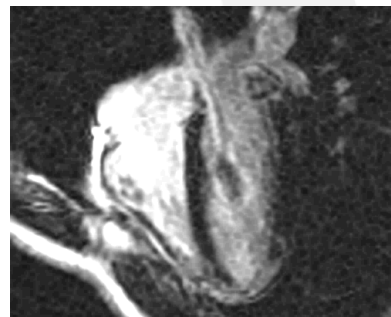
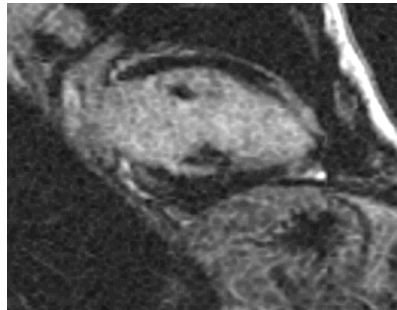
bSSFP



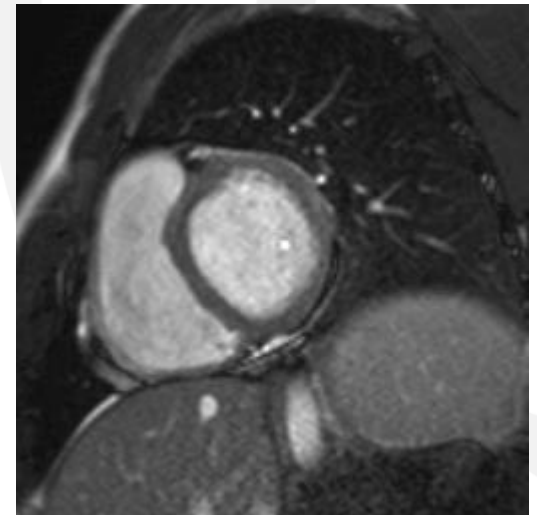
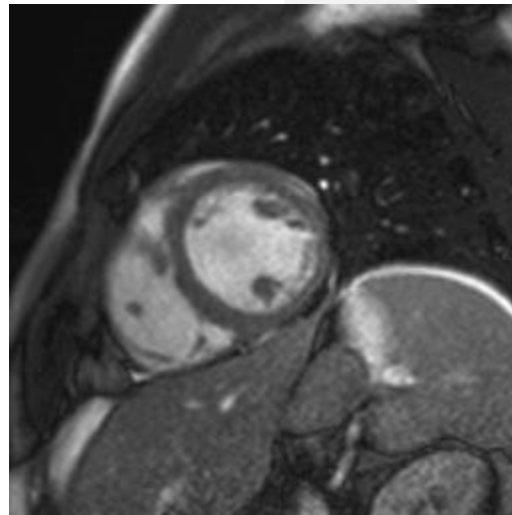
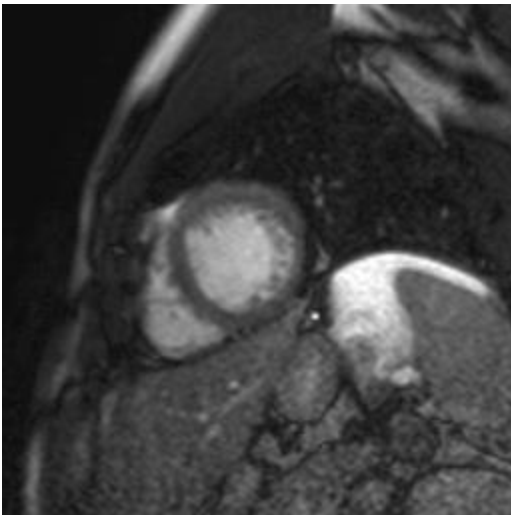
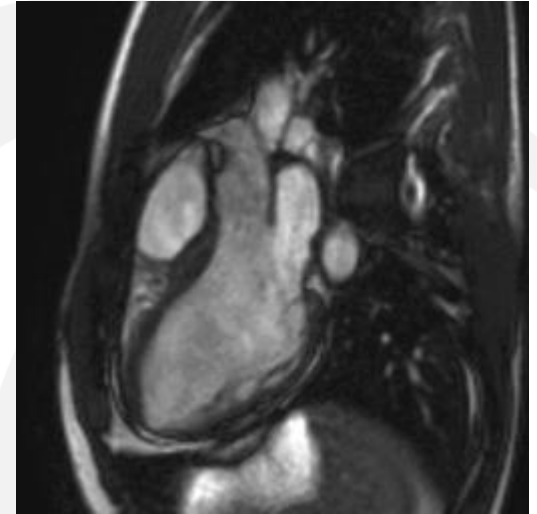
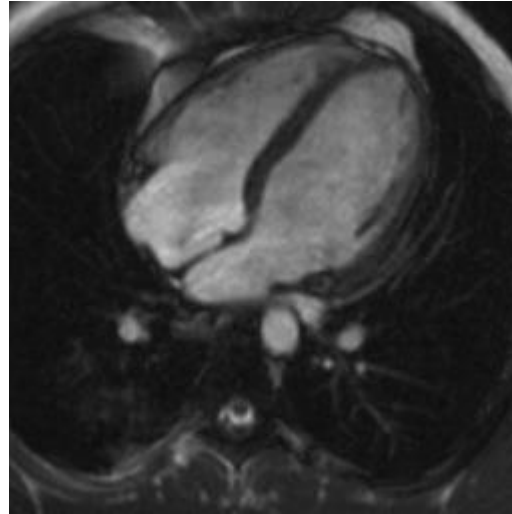
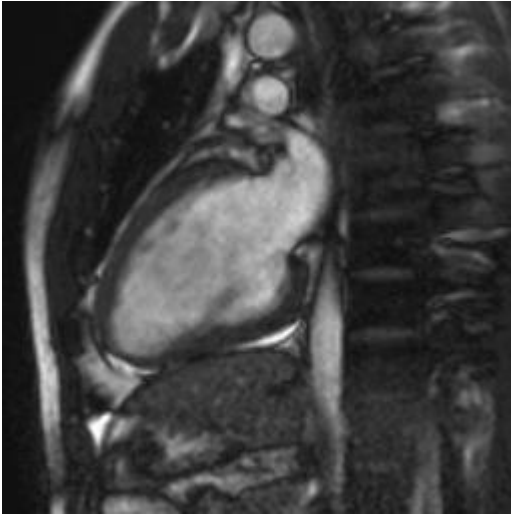
T2w

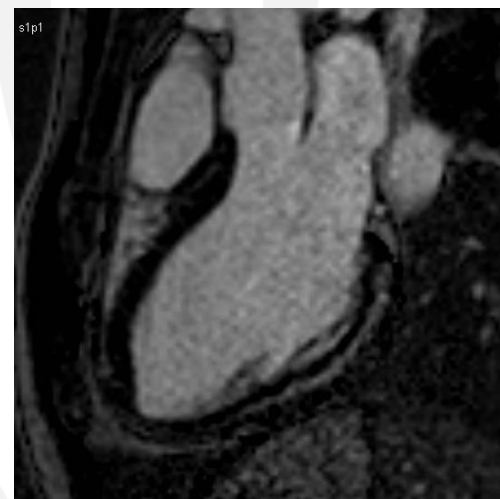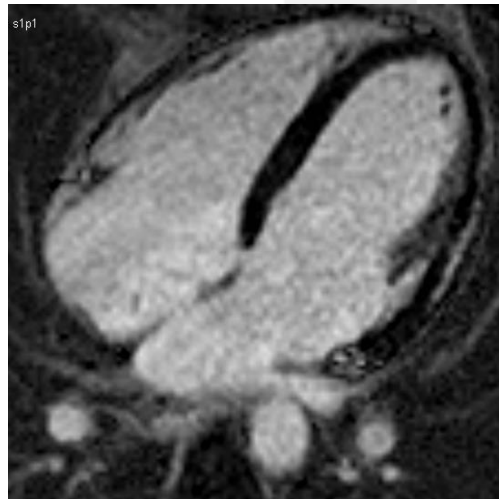
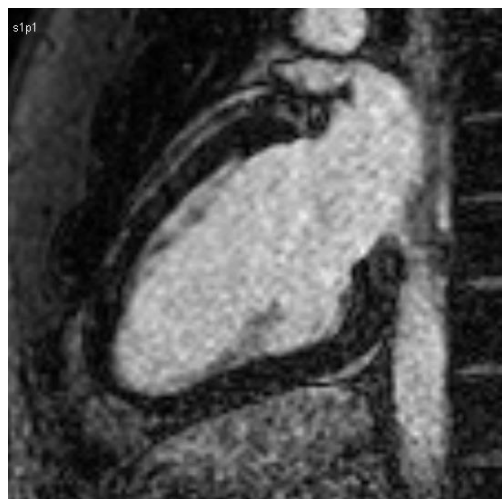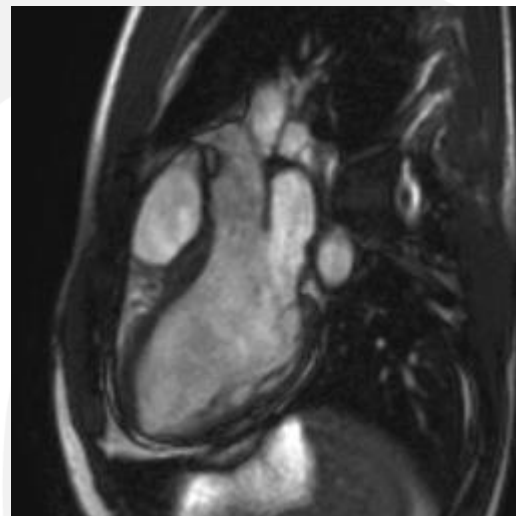
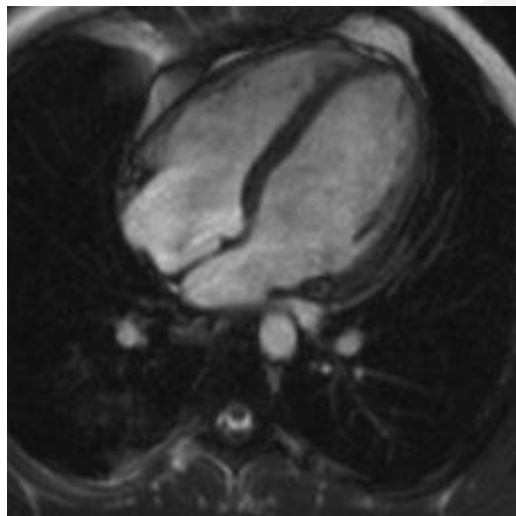
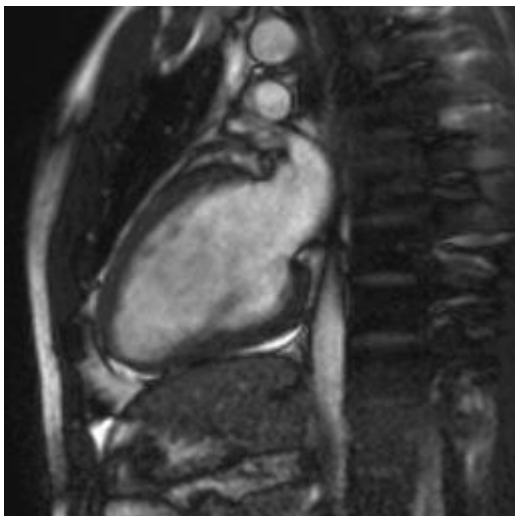


DE



Futballedző – abortált hirtelen szívhalál



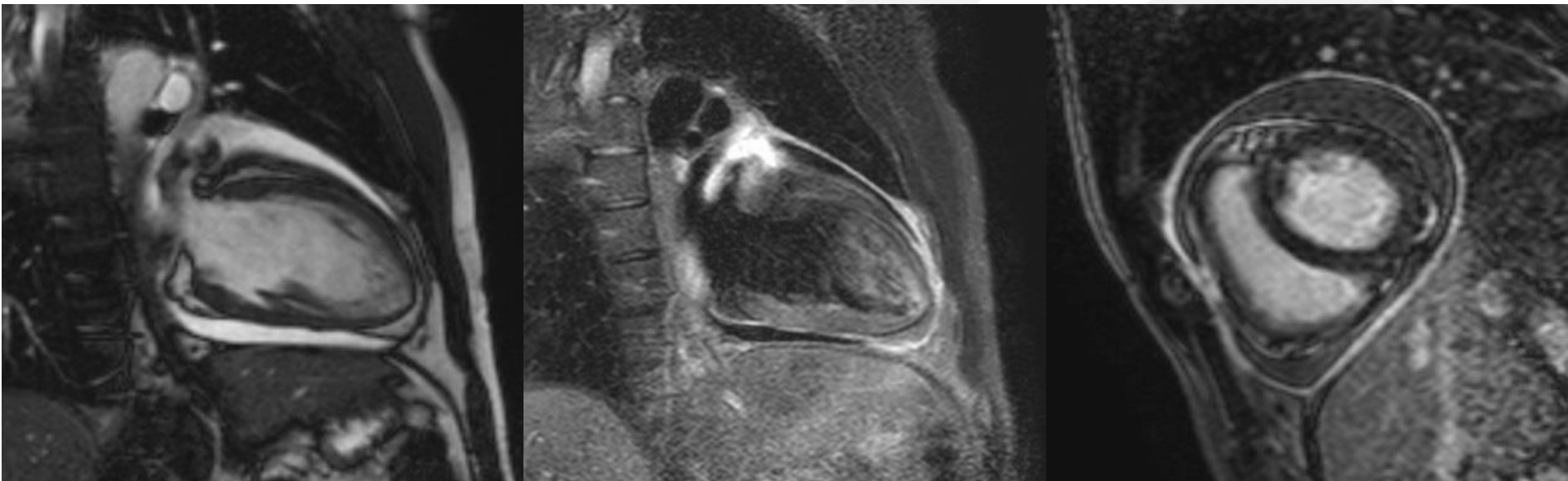


Indikációk

- Ischaemiás szívbetegség
- Cardiomyopathiák
- Veleszületett szívbetegség
- Myocarditis
- **Pericardium betegségei**
- Tumorok



Acut pericarditis

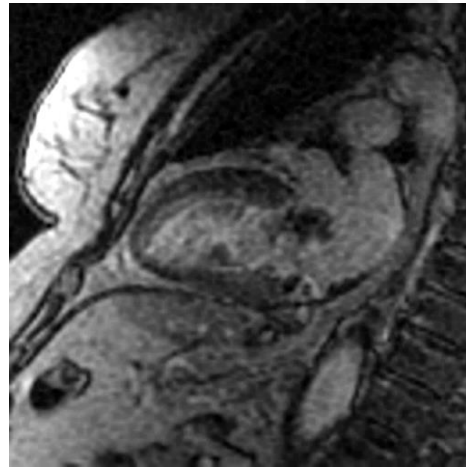
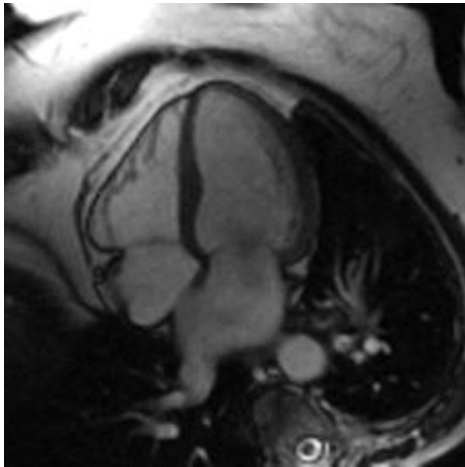
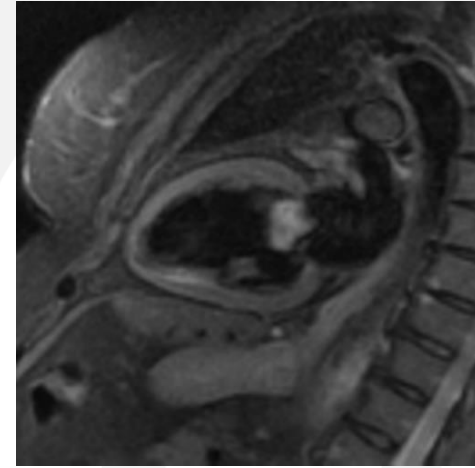
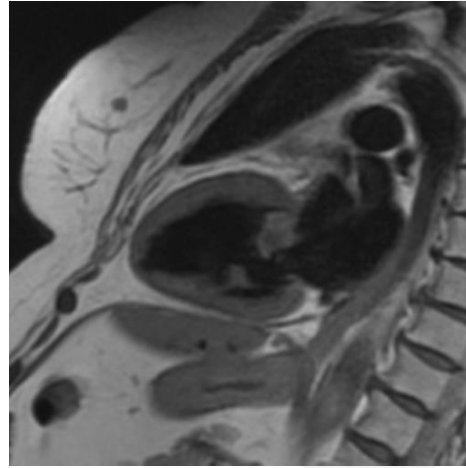
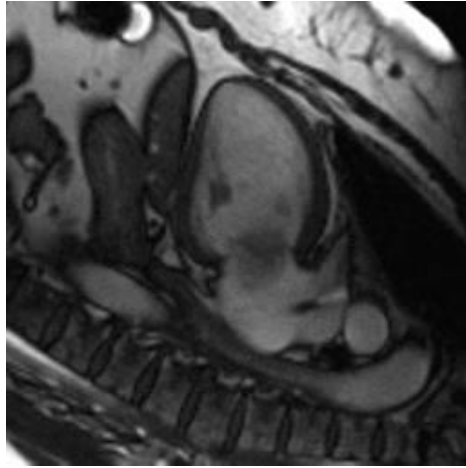


Indikációk

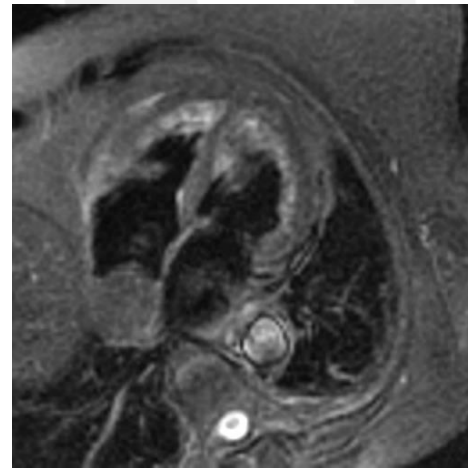
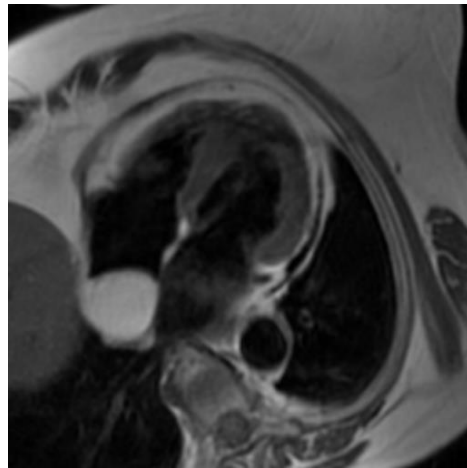
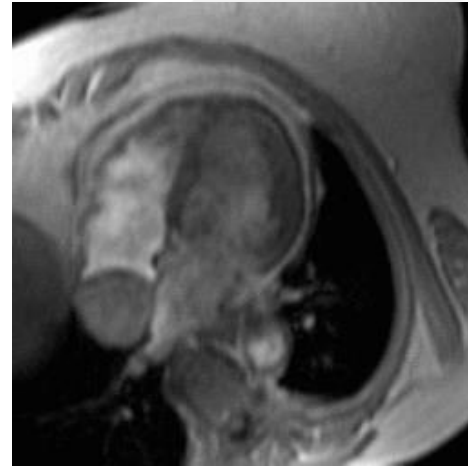
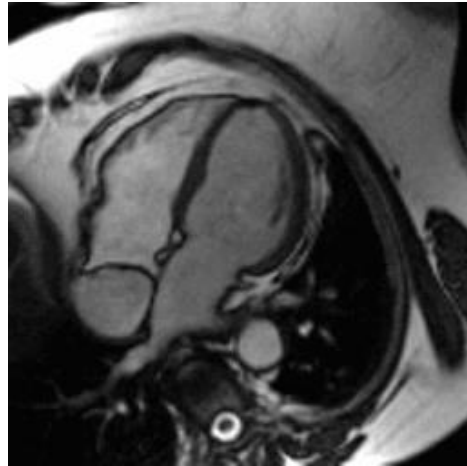
- Ischaemiás szívbetegség
- Cardiomyopathiák
- Veleszületett szívbetegség
- Myocarditis
- Pericardium betegségei
- **Tumorok**



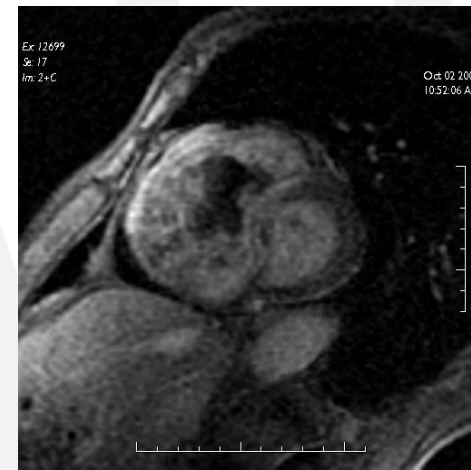
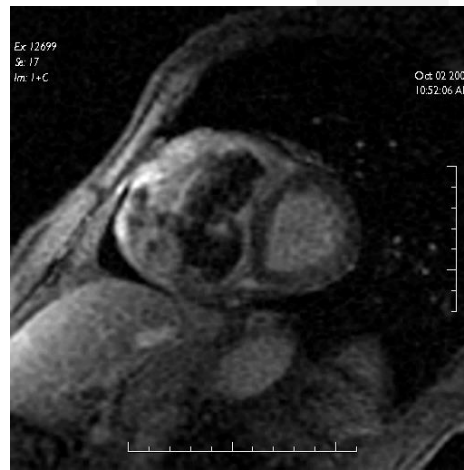
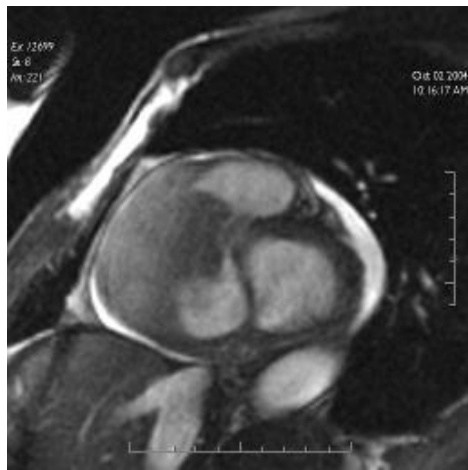
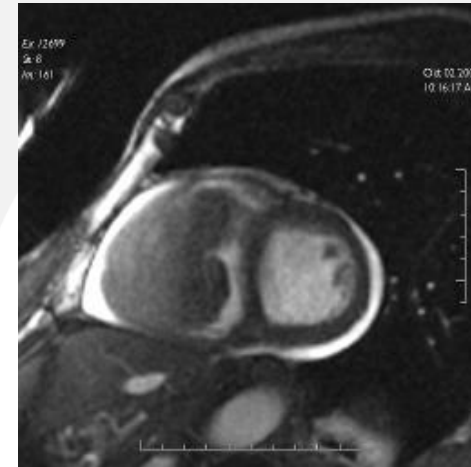
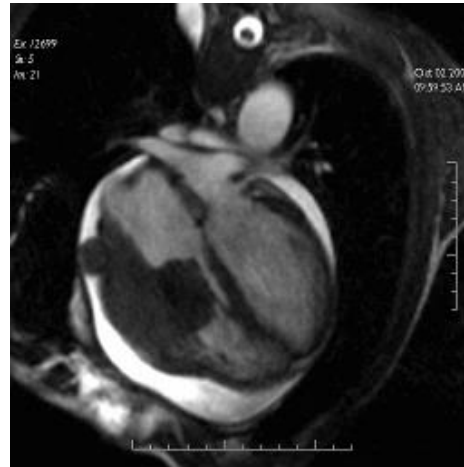Bal pitvari myxoma



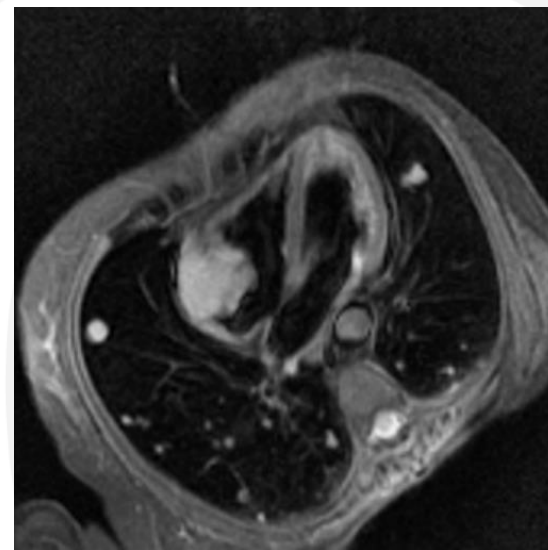
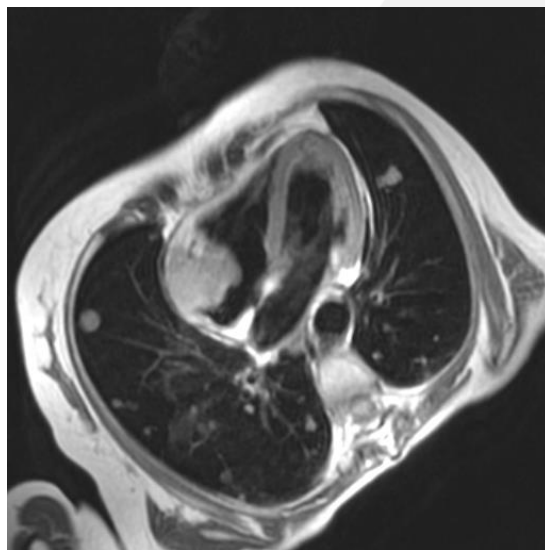
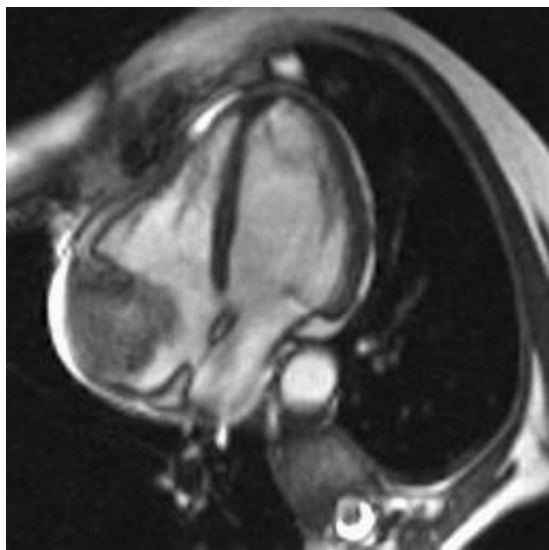
Jobb pitvari lipoma



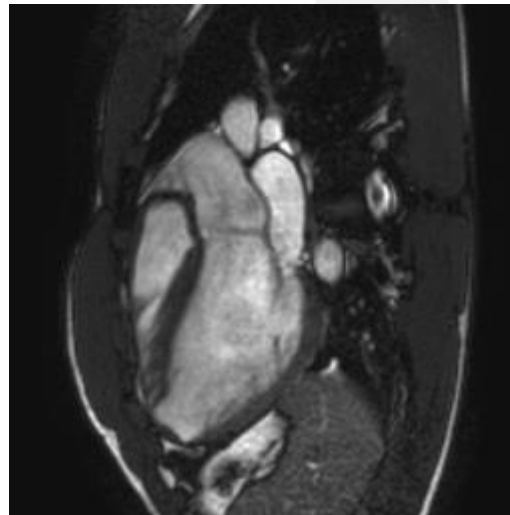
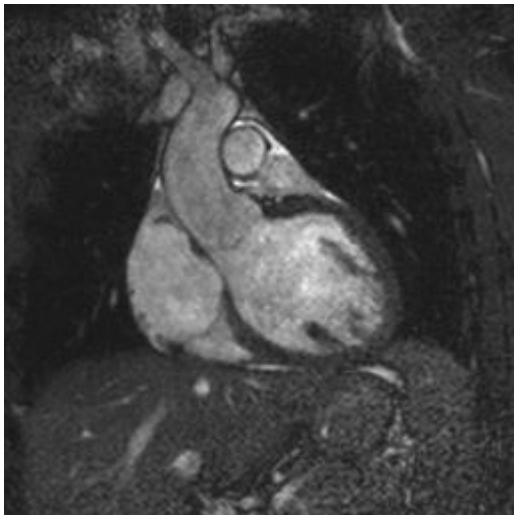
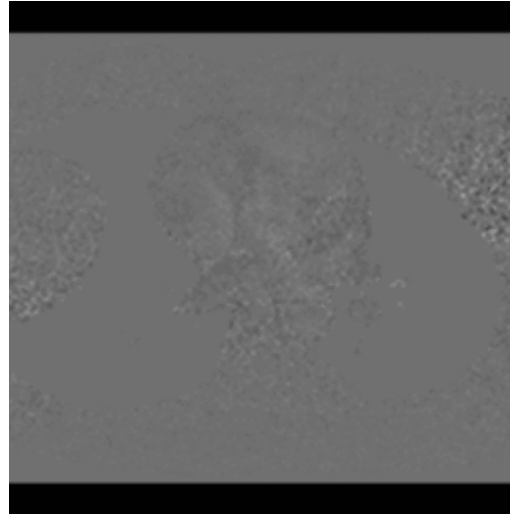
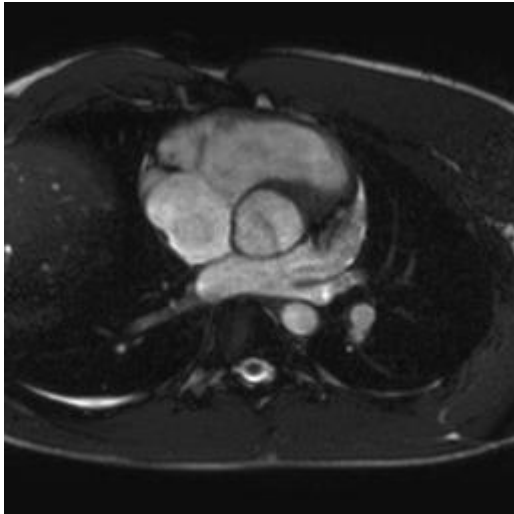
Rectum tumor metastasis



Breast cancer metastasis



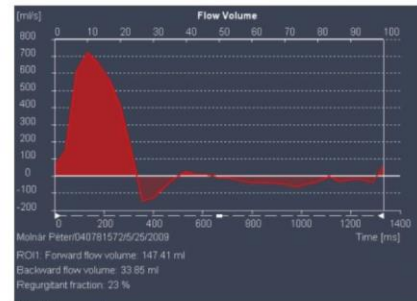
Kéthegyű aorta billentyű



Left Ventricular Volume Results					
Mass:	261.39 g	85 - 181	Mass index:	121.83 g/m ²	46 - 84
ED volume:	367.65 ml	101 - 236	ED volume index:	171.36 ml/m ²	52 - 112
ES volume:	181.97 ml	28 - 93	ES volume index:	84.81 ml/m ²	-
Stroke volume:	185.68 ml	66 - 150	Stroke volume index:	86.54 ml/m ²	-
Ejection fraction:	50.59 %	55 - 74			

Volume Results Slice 1			
ROI	Label	Flow / beat	Flow / minute
1		113.57 ml/beat	5.11 l/min
2		-	-
3		-	-
4		2.09 ml/beat	94.10 ml/min

Regurgitation Results Slice 1				
ROI	Label	Regurgitant fraction	Forward volume	Backward volume
1		22.96 %	147.41 ml/beat	33.85 ml/beat

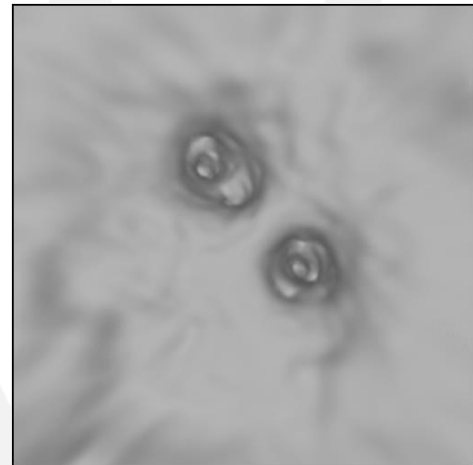
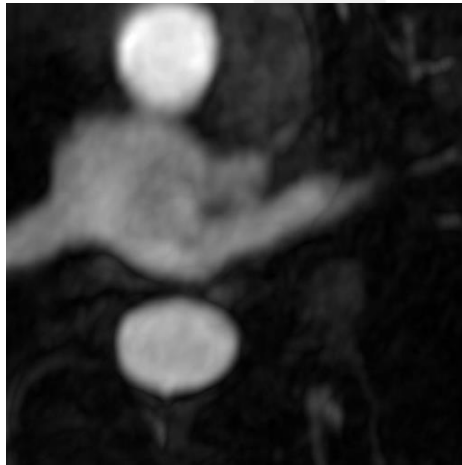
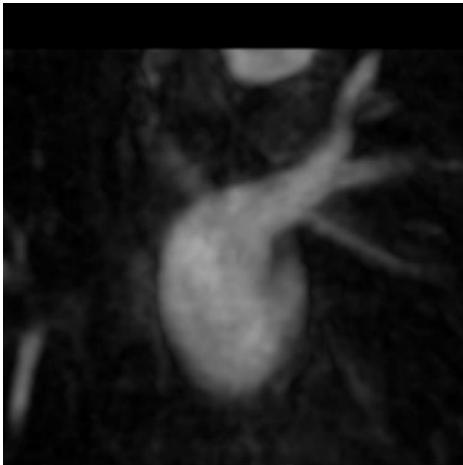

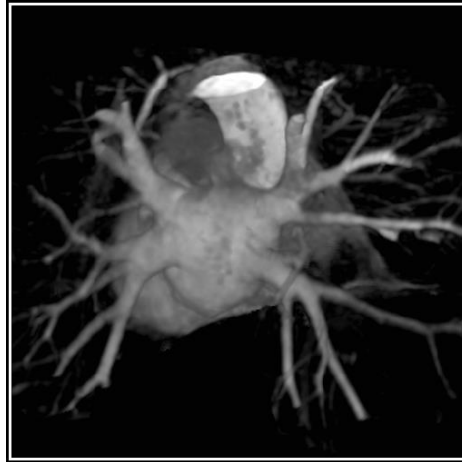
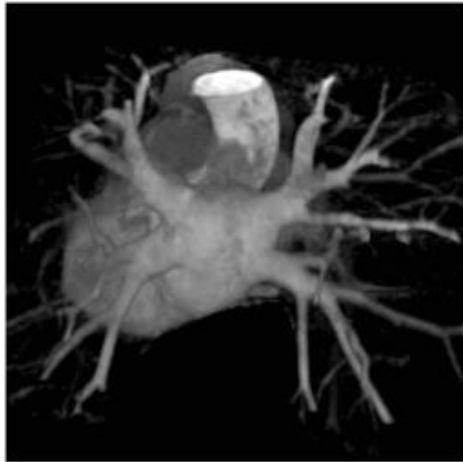


Flow Volume graph:


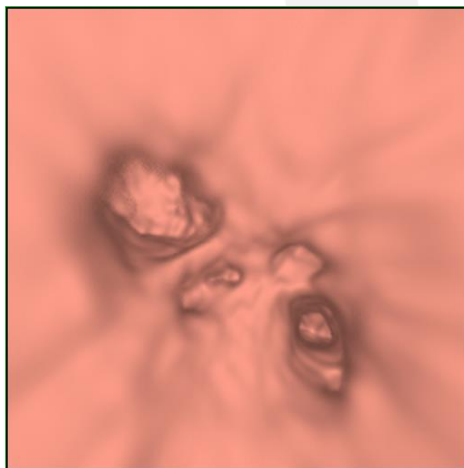
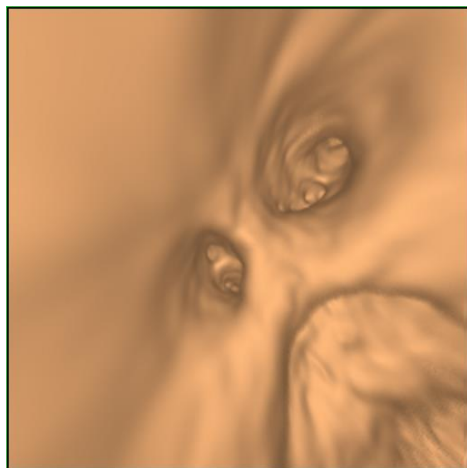
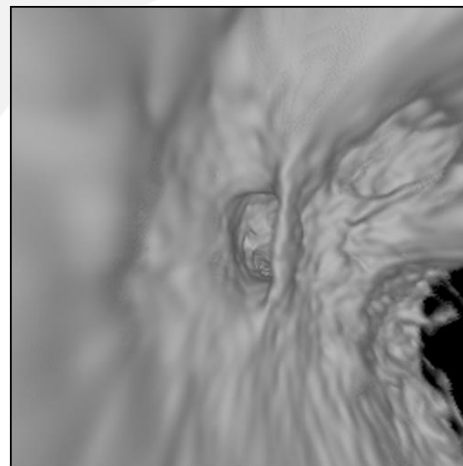
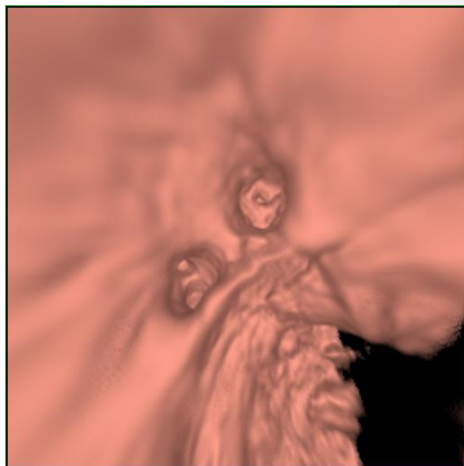

Fáziskontraszt áramlás mérés



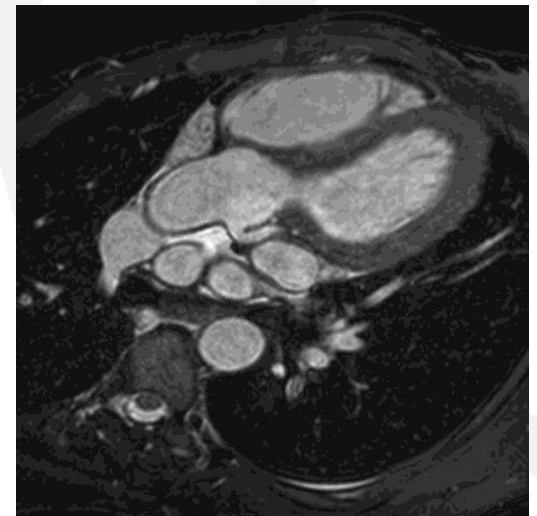
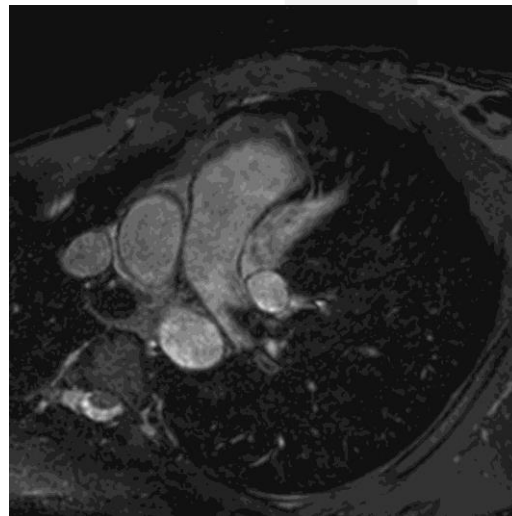
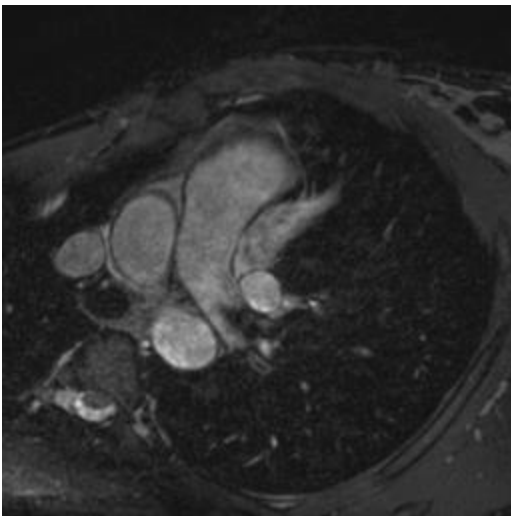
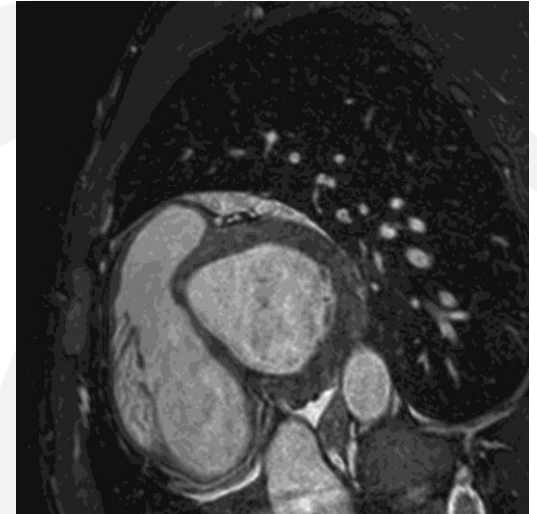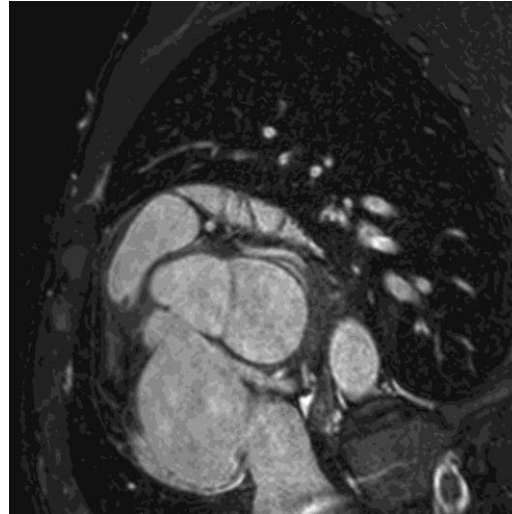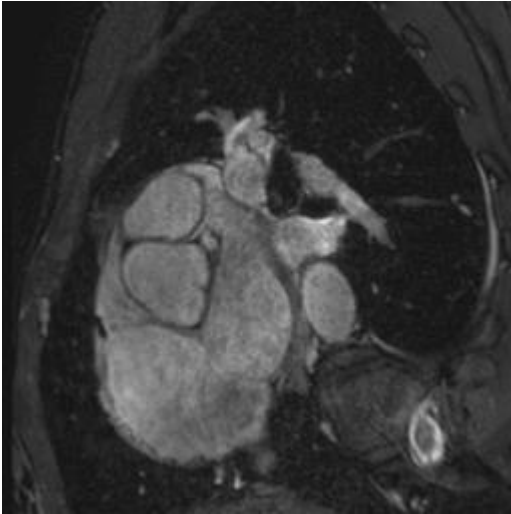Pulmonary vein isolation



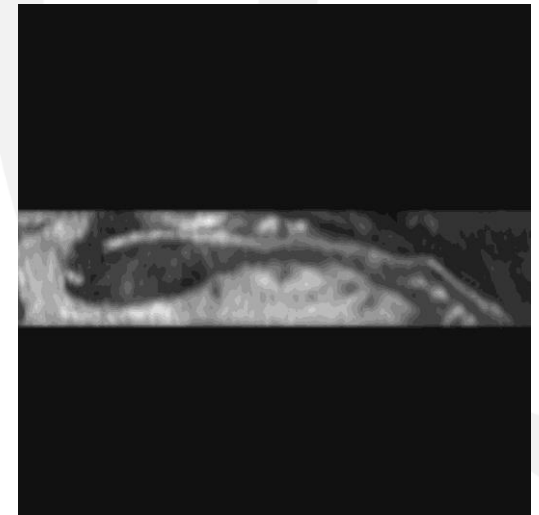
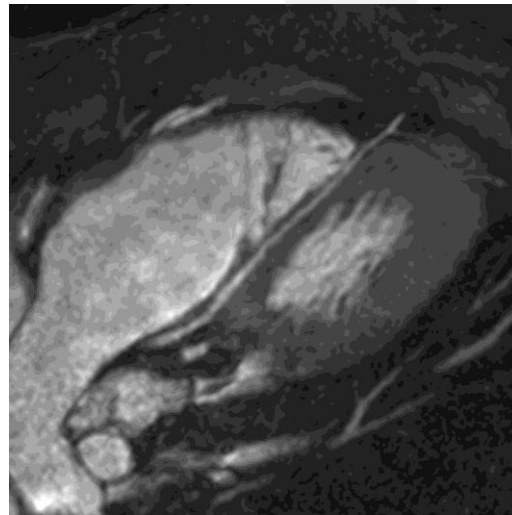
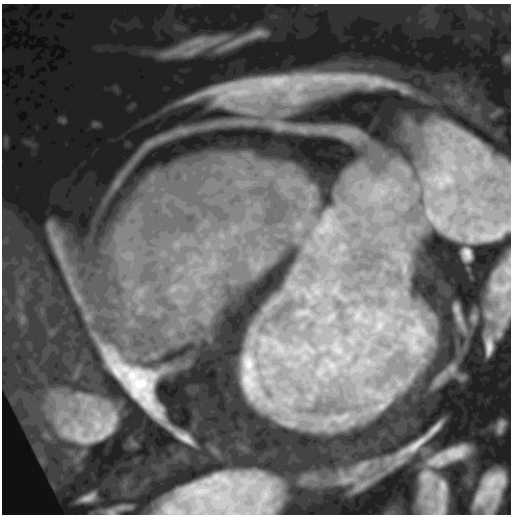
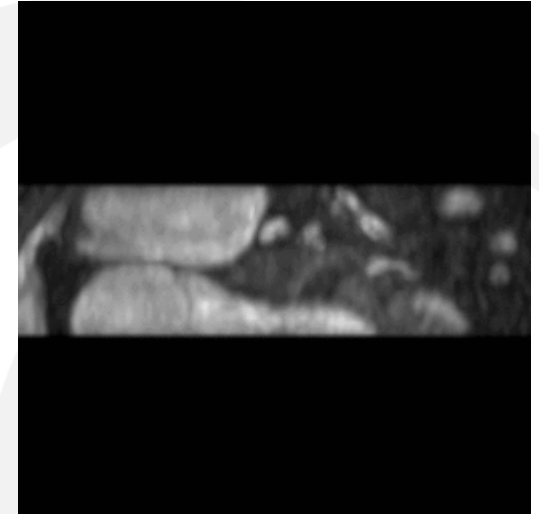
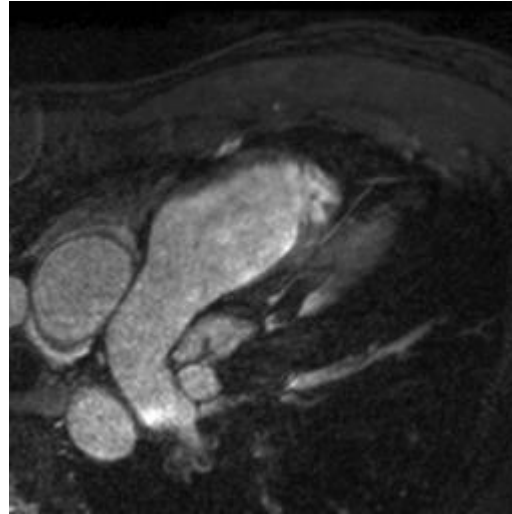
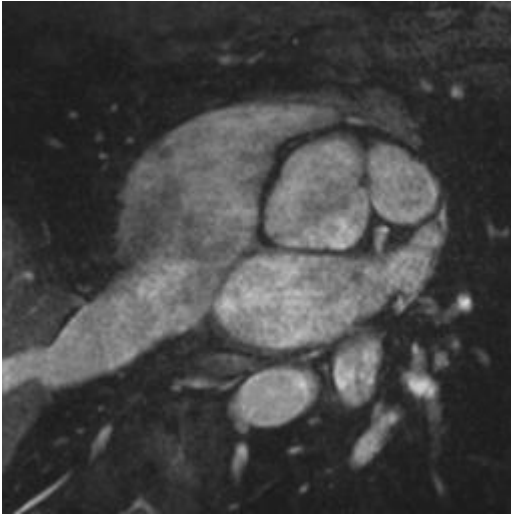
Virtual endoscopic images



MR angiographia



MRCA: LAD bridge



Köszönöm a figyelmet!

