



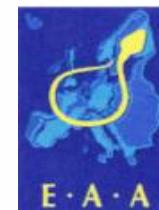*250 years of EXCELLENCE
in medical education,
research & innovation
and healthcare*

Webseminär I: Symptomen und Diagnostik in der Urologie

Attila Majoros



Certified Clinic



Certified Training Centre for Andrology

Semmelweis University
<http://semmelweis.hu>

DEPARTMENT OF UROLOGY

Urologische Symptomen

- ↪ Haematurie
- ↪ Harnverendärungen
- ↪ Harnverhalt
- ↪ Schmerzen
- ↪ Miktionsbeschwerden
- ↪ Andrologische Smyptomen
- ↪ Tastbefunden



Hämaturie

- Mikrohämaturie
- Makrohämaturie
- Grad
- Ursachen
- Diagnostik
- Behandlung



Rotfärbung des Urins in Abhängigkeit von der Blutbeimengung (Blutanteil in %)



0,25 %

1 %

5 %

Hämaturie Verdünnungsreihe – © Copyright 2011 Staffordshire Urology Clinic.



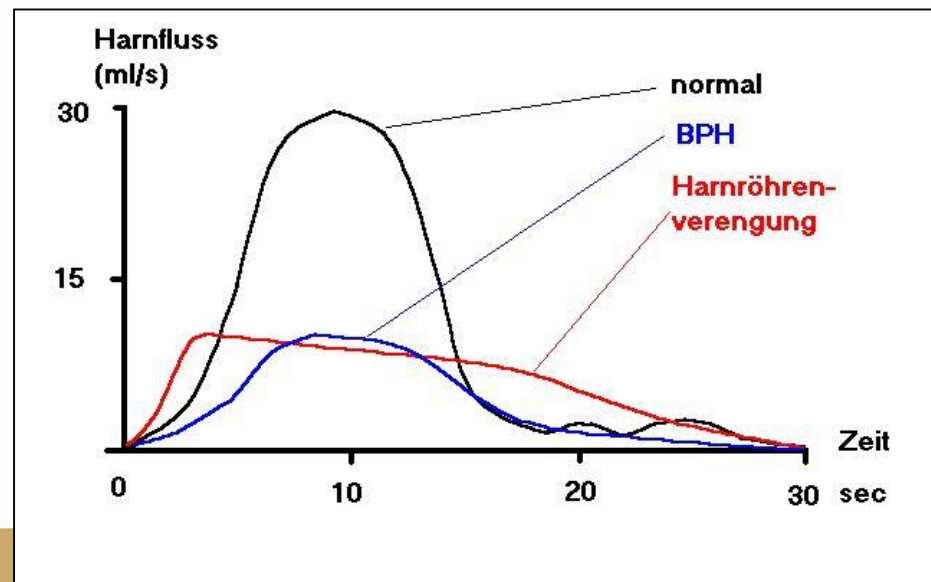
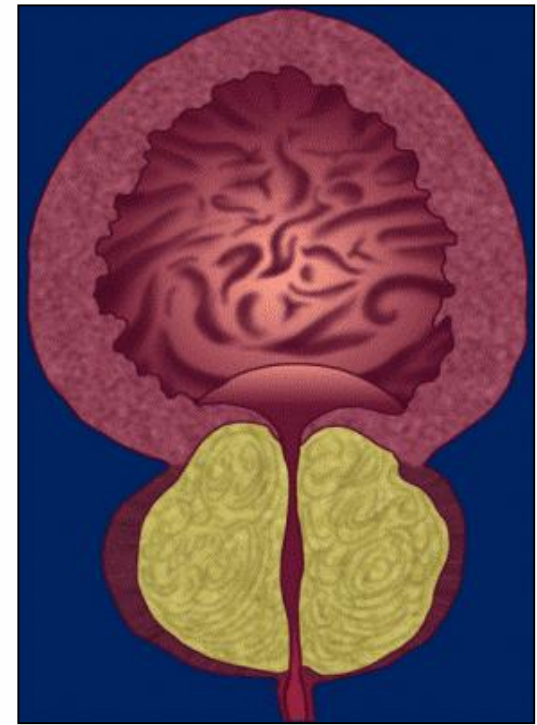
Harnveränderungen

- Reiner Urin
- Pyurie
- Konzentrierte



Harnverhalt

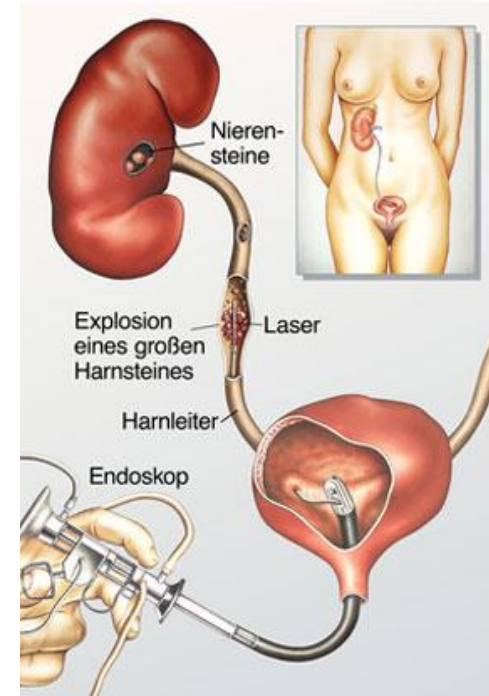
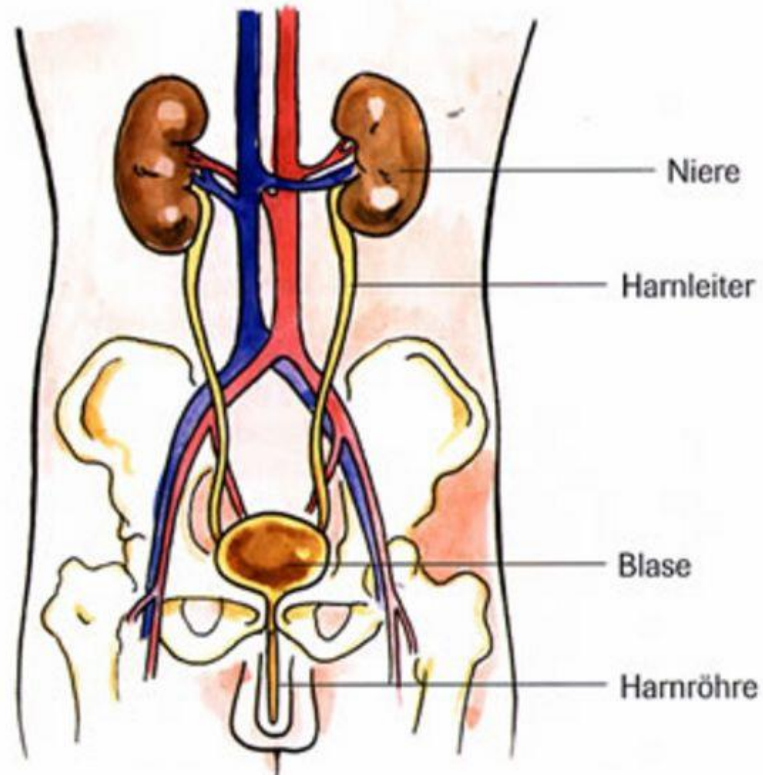
- Vollständig
- Partial
- Symptomen
- Diagnostik
- Therapie



Schmerzen

Lokalisation:

- Flanken
- Bauch
- Unterbauch
- Damm
- Hoden
- Scheidel



Miktionsbeschwerden

Obstruktiv

- verzögerter Miktionsbeginn
- verlängerte Miktionszeit
- abgeschwächter Harnstrahl
- Harnstottern
- Nachträufeln
- Gefühl der unvollständigen Entleerung

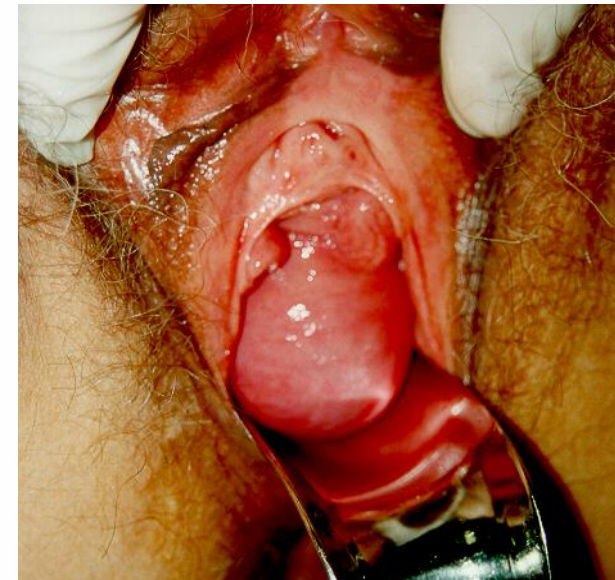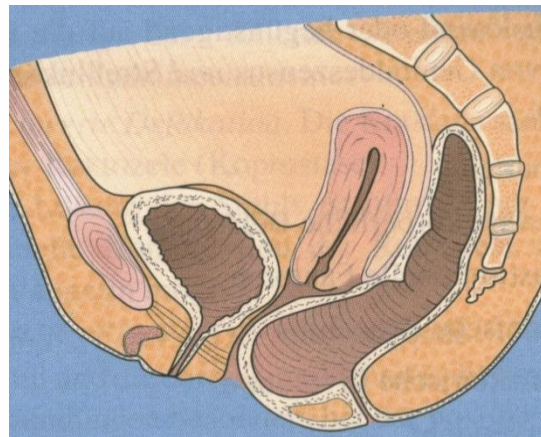
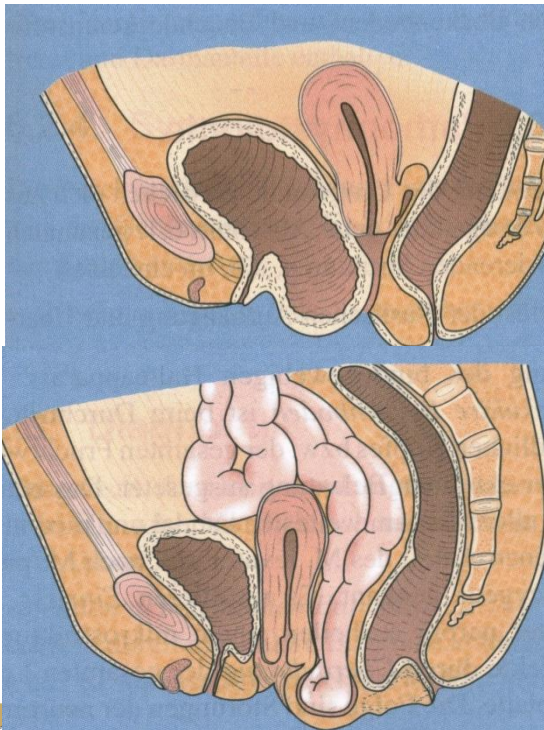
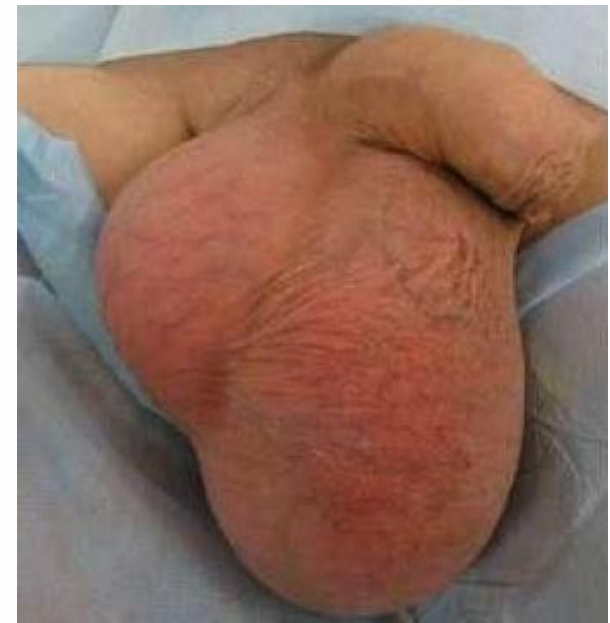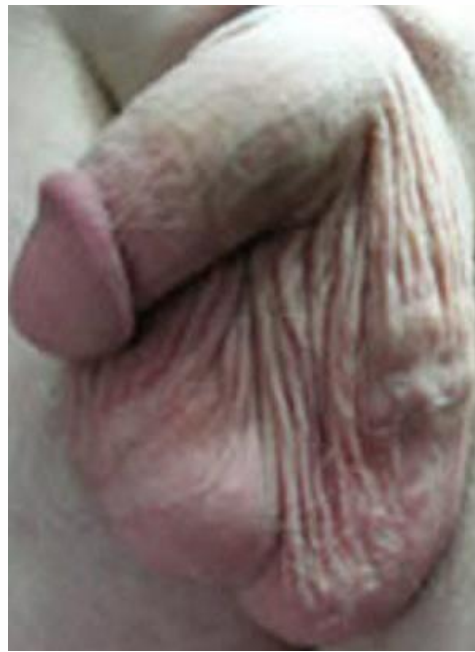Irritativ

- Pollakisurie
- Diurie
- Nykturie
- imperativer Harndrang
- Dranginkontinenz
- Algurie



Tastbefund

- Bauch
- Unterbauch
- Hoden
- Scheidel



Diagnostik

- Symptomen
- Körperliche Untersuchung
- Harnuntersuchung, Laboruntersuchung
- Ultraschall
- Röntgen
- CT
- Isotopen
- Zystoskopie
- Uroflowmetrie
- Urodinamik

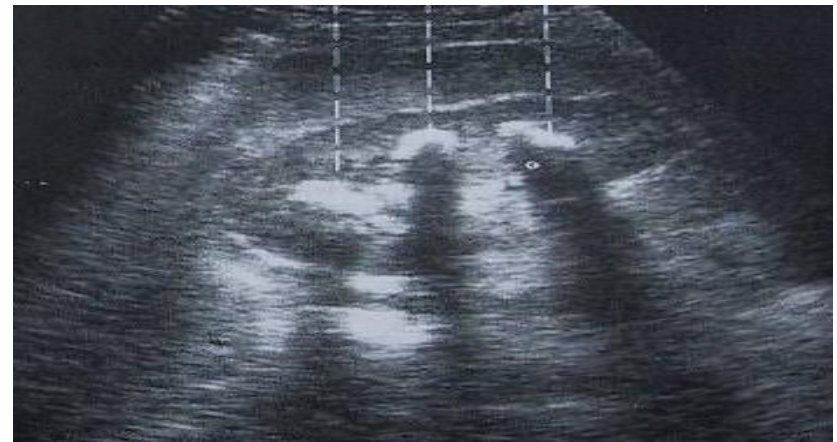
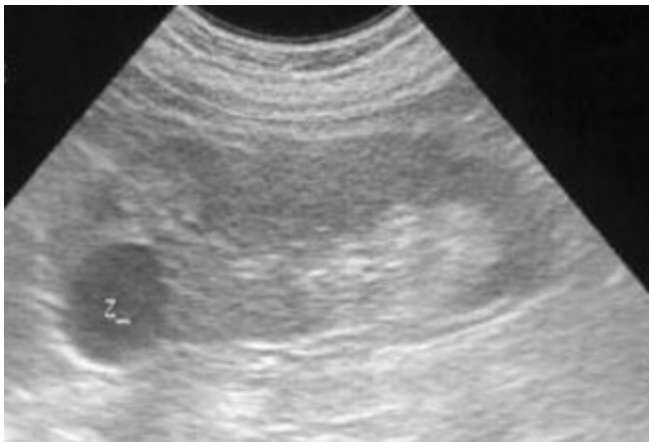
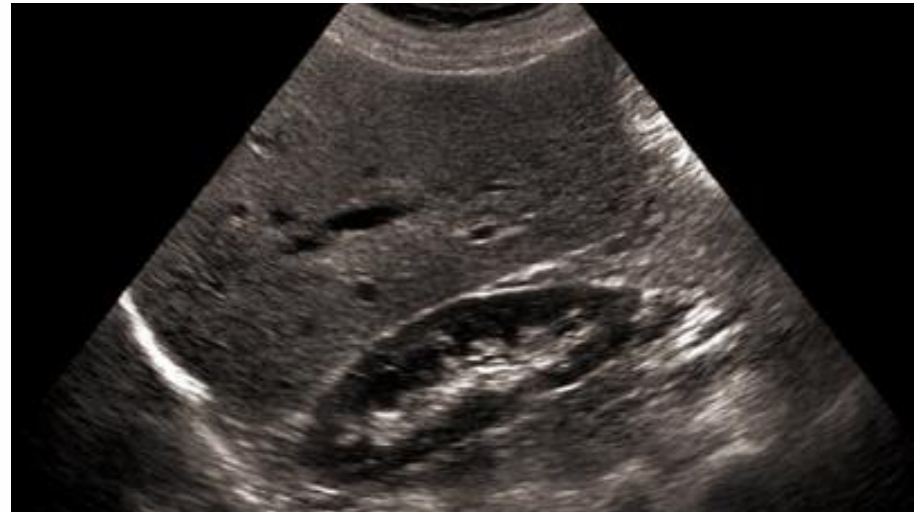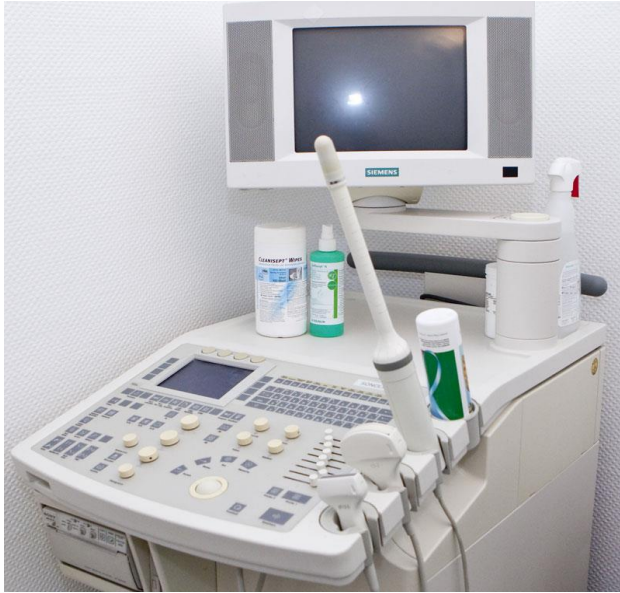Laboruntersuchungen

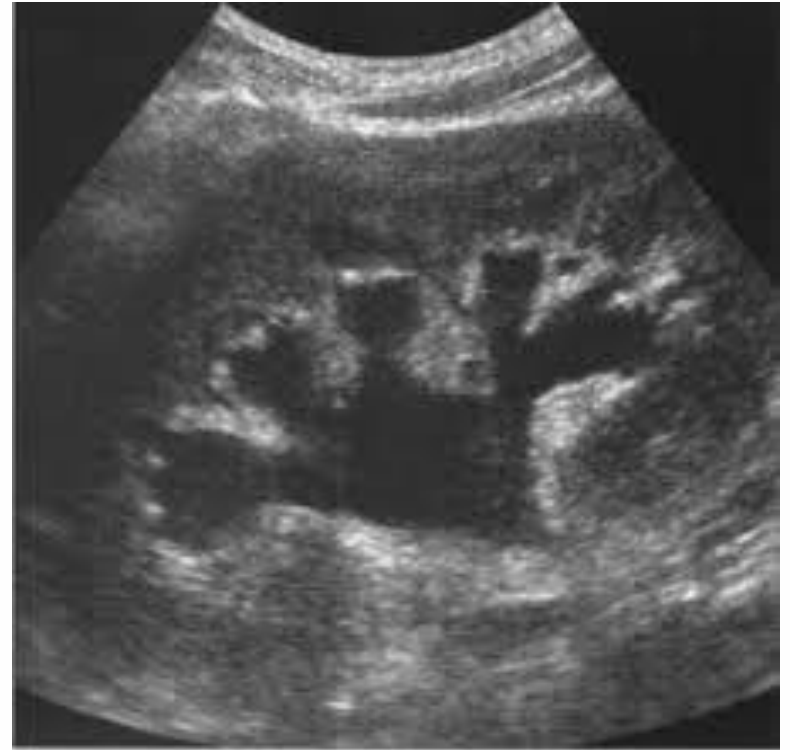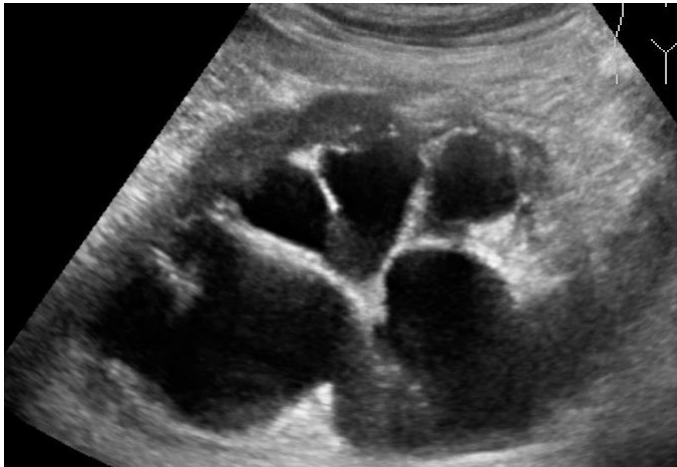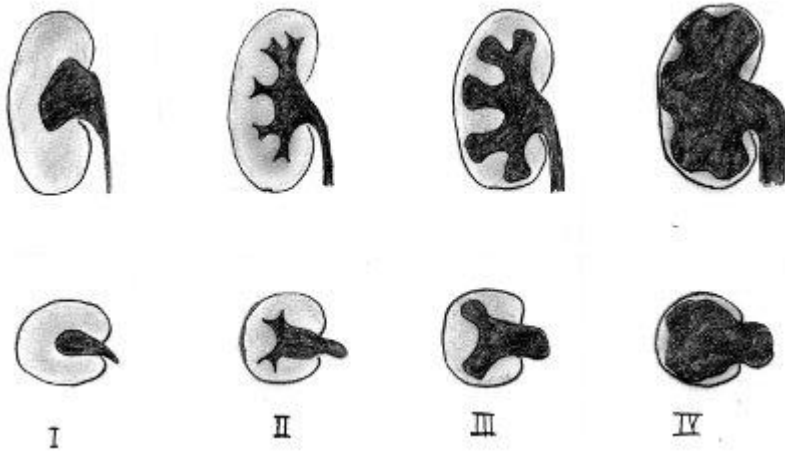
- Blutbild
- Nierenfunktion
- Na, K
- Tumormarker
 - PSA
 - AFP, B HCG, NSE



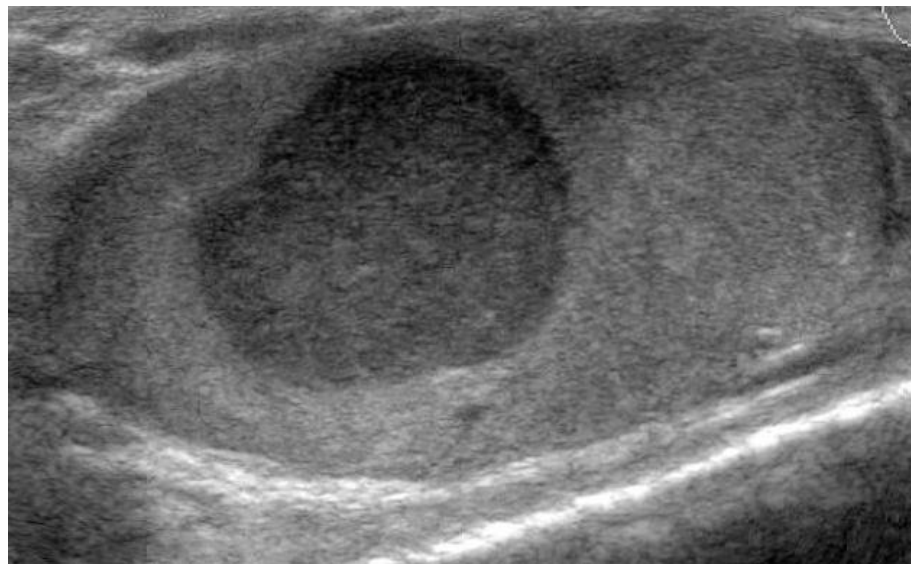
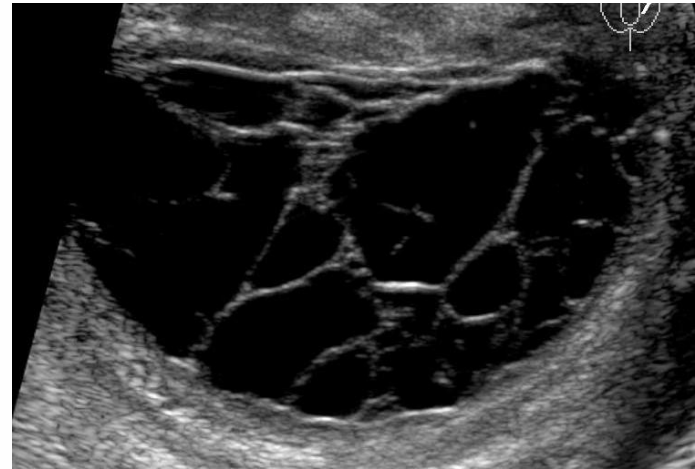
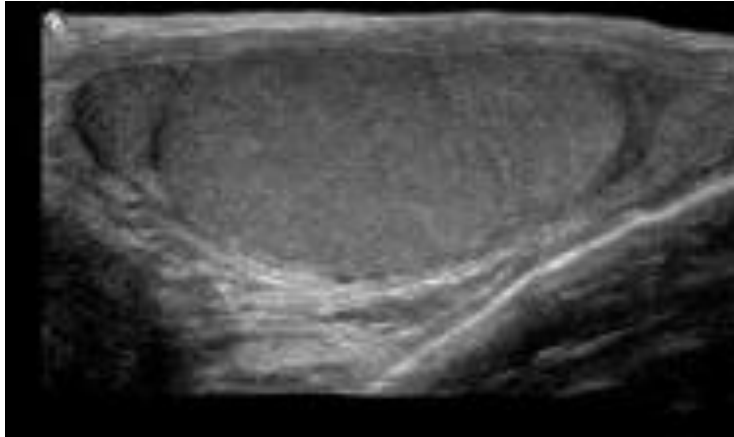
Ultraschall



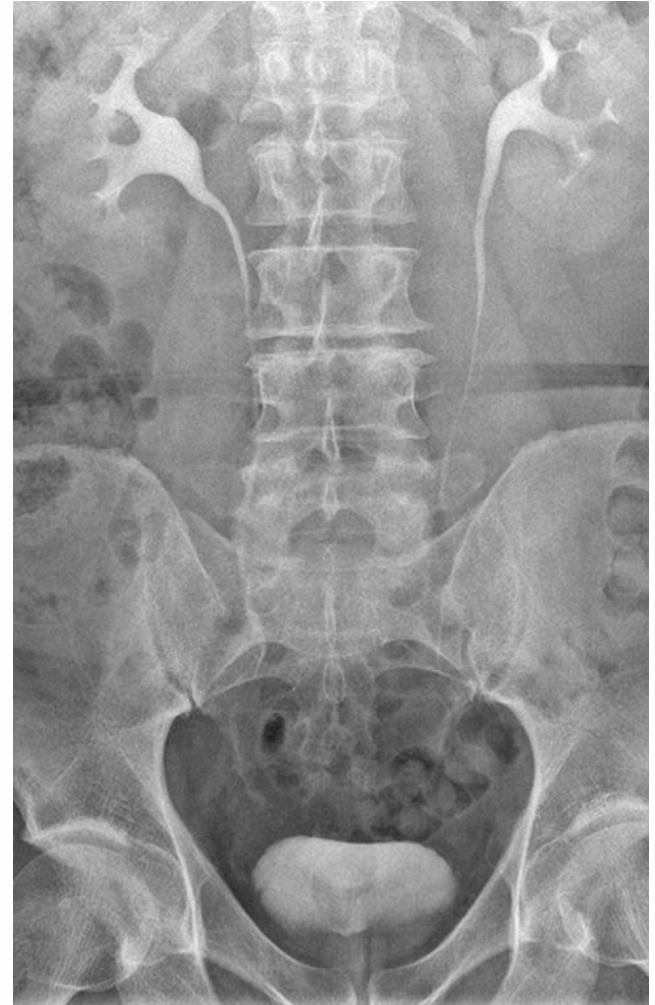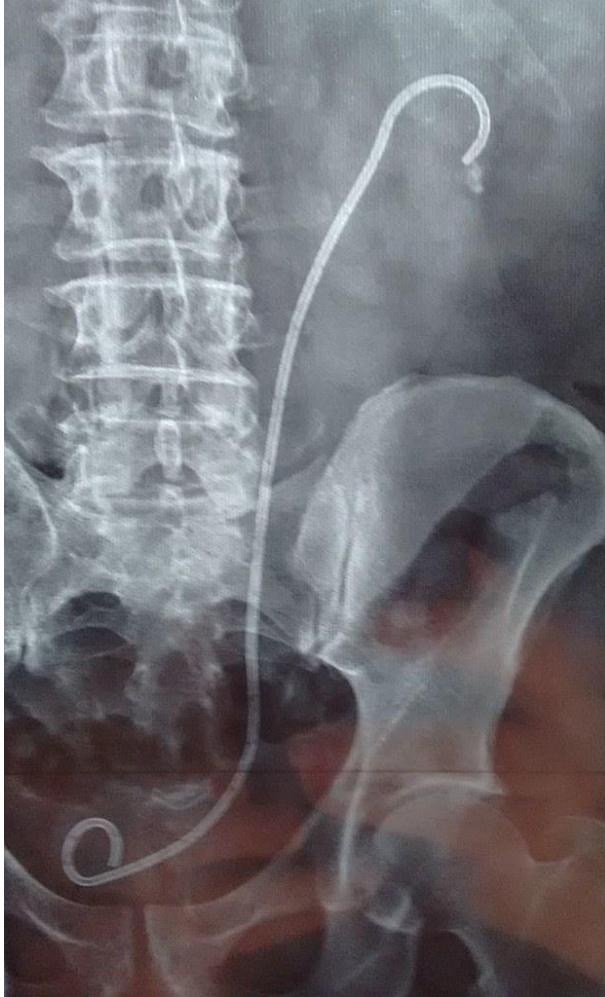Nierenstau



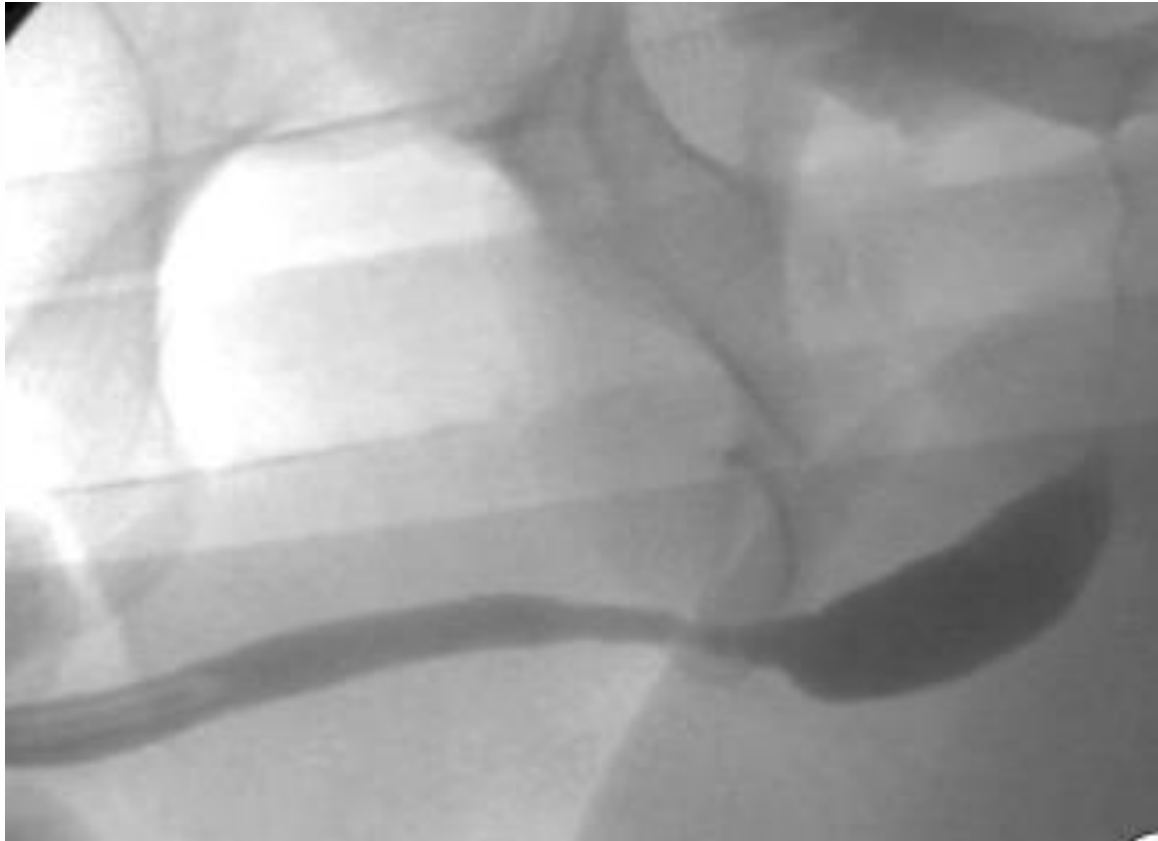
Hodenultrascall



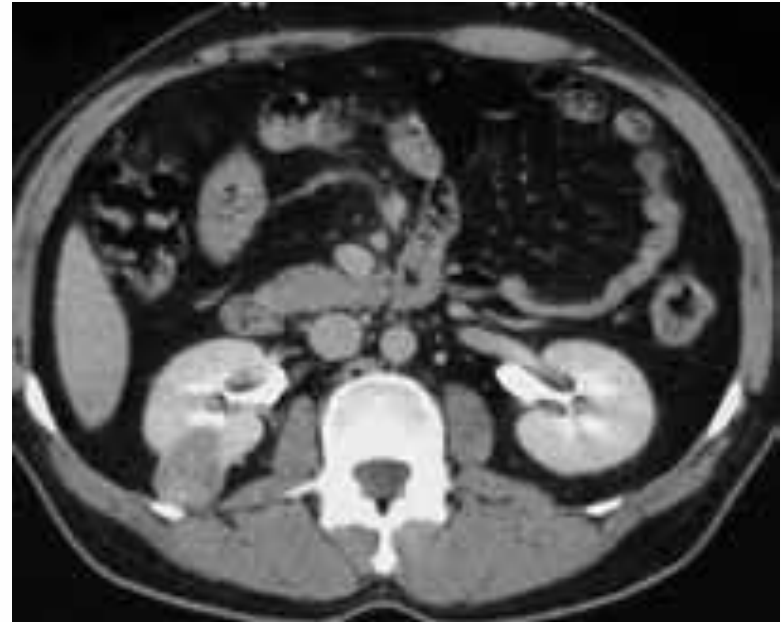
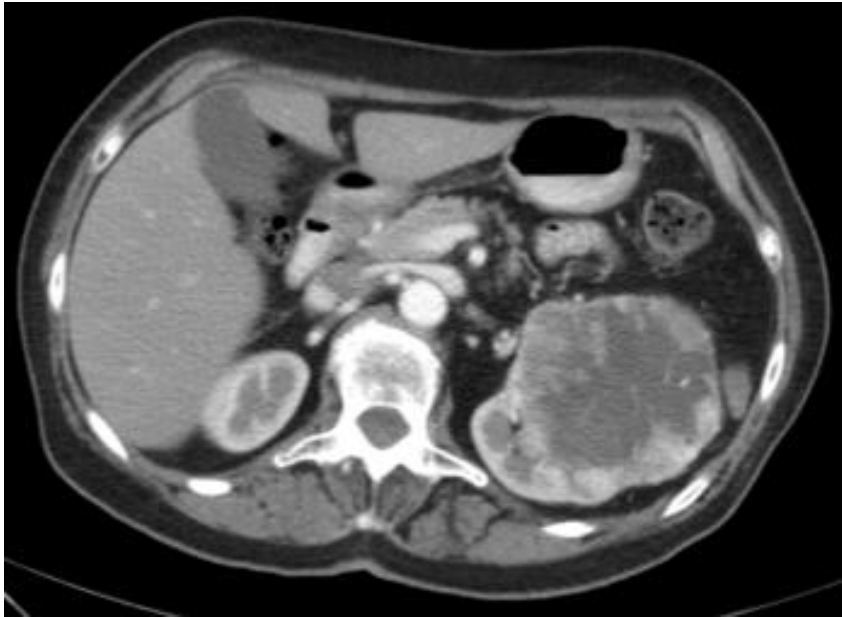
Röntgen

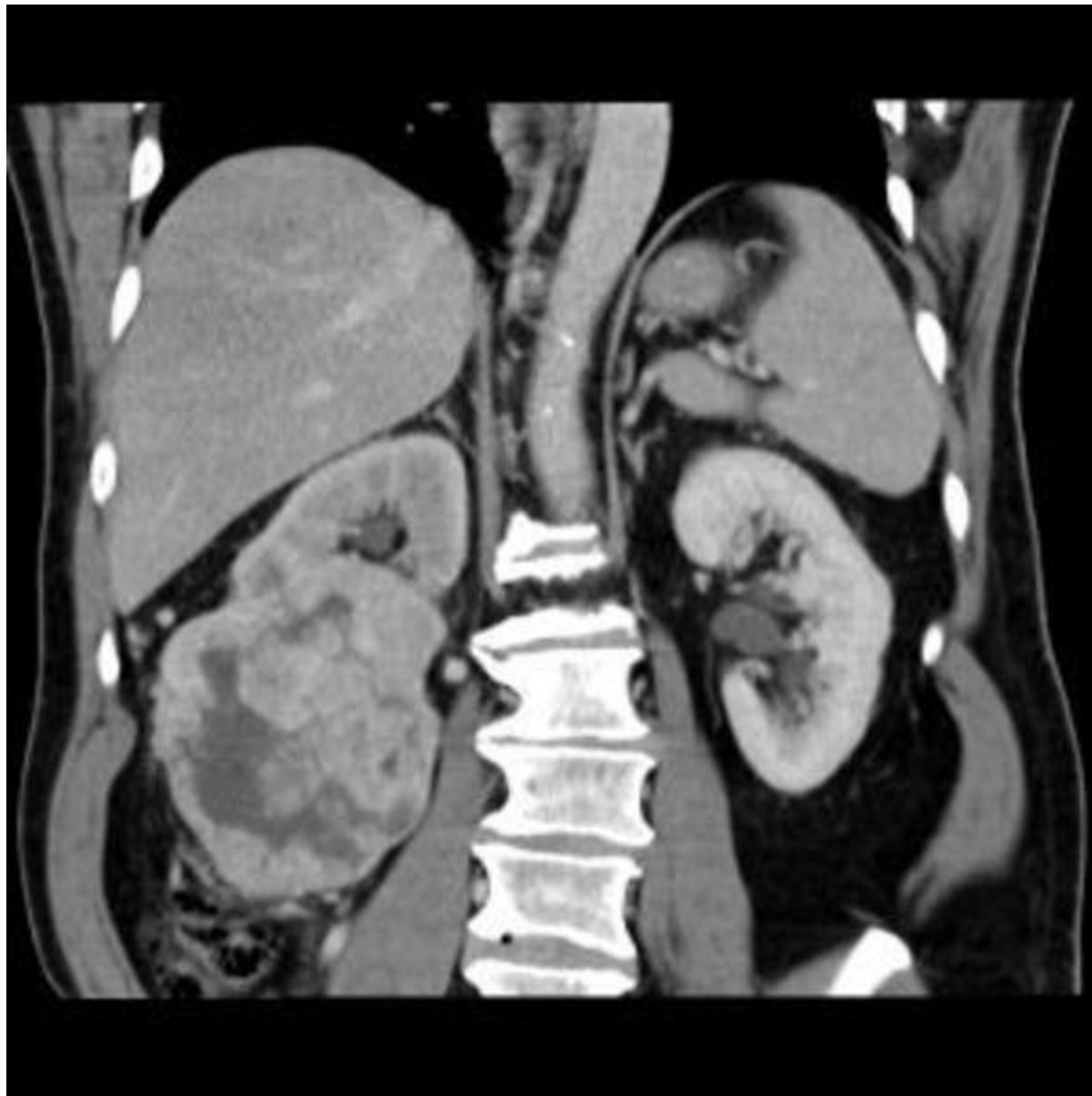

Retrograde Urethrographie

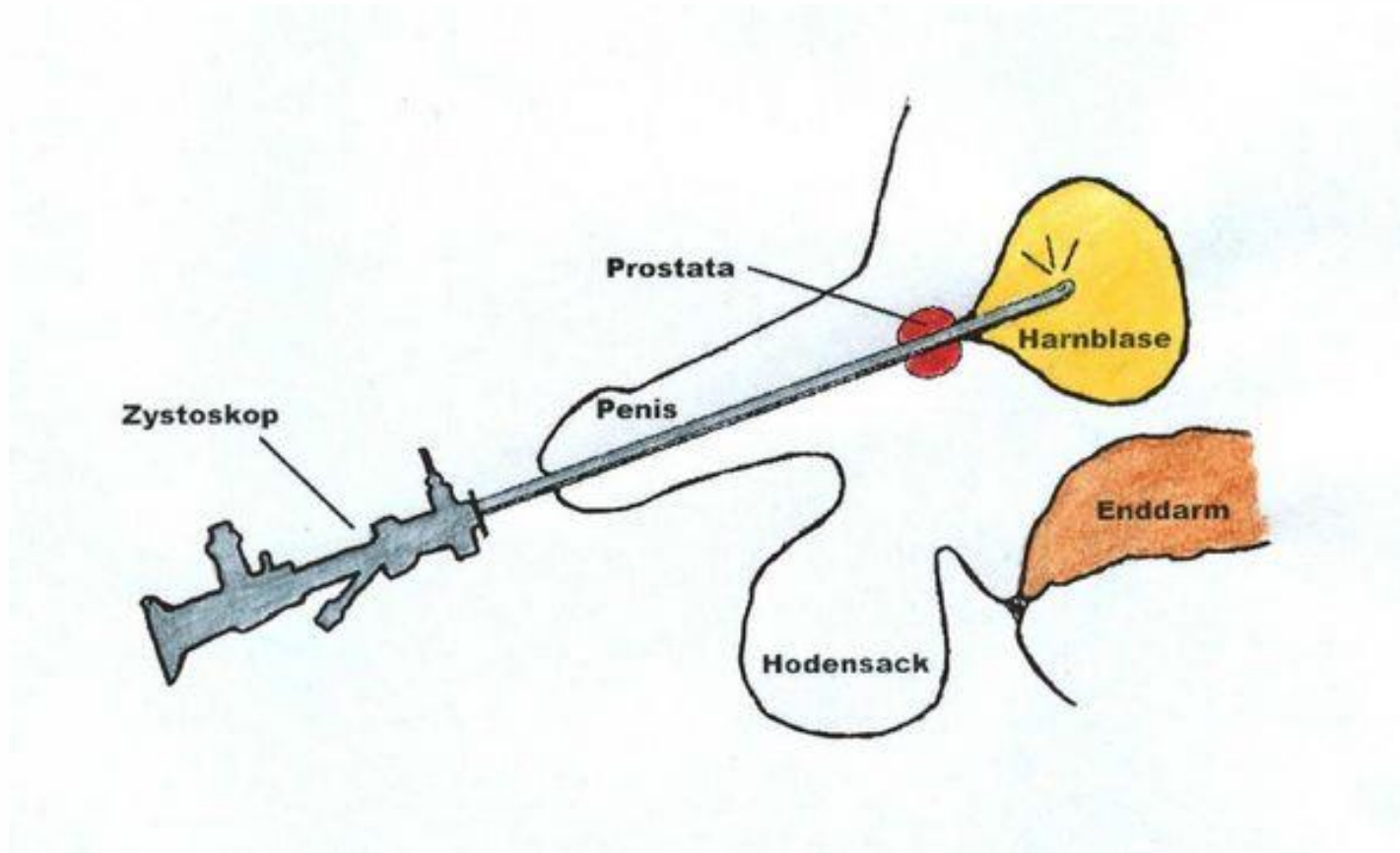


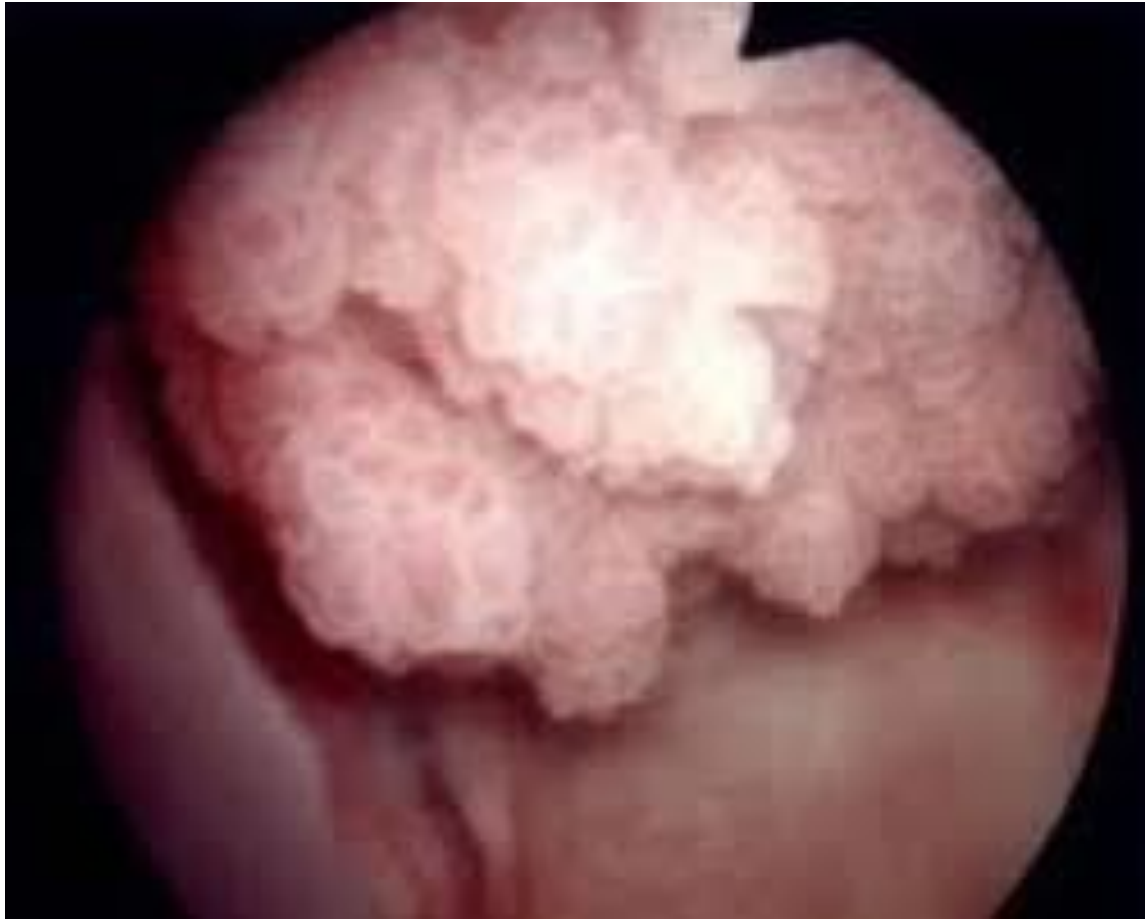CT

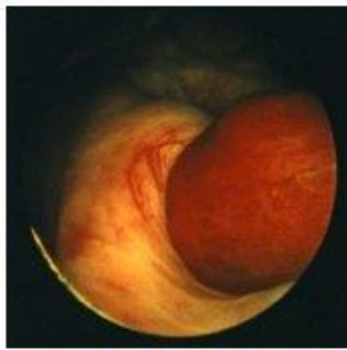




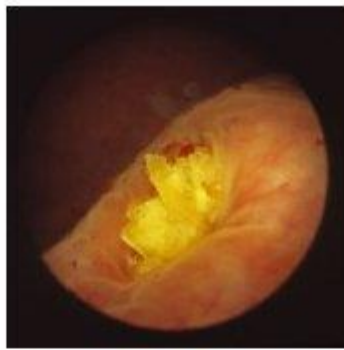
Zystoskopie



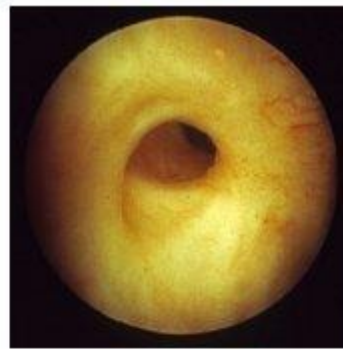



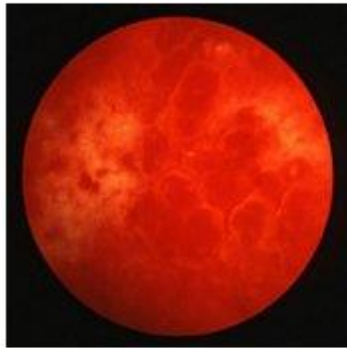(a) Ostium rechts mit Koagel



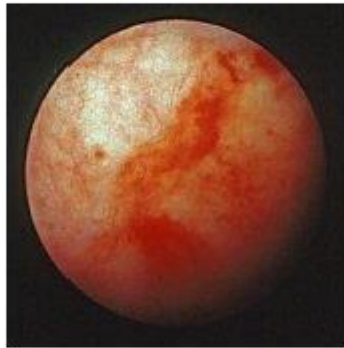(b) Ostium links mit Harnleiterstein



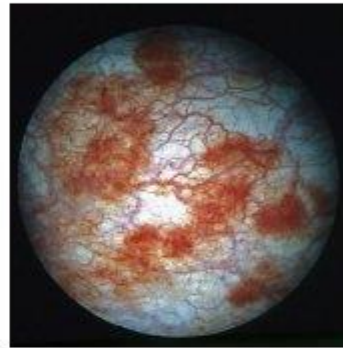(c) Refluxives Ostium



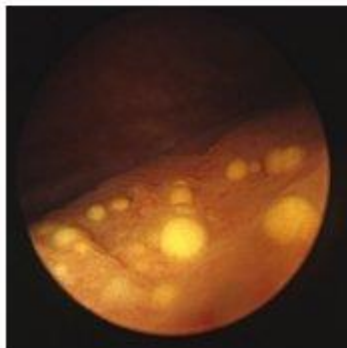
(d) Ausgeprägte hämorrhagische Zystitis



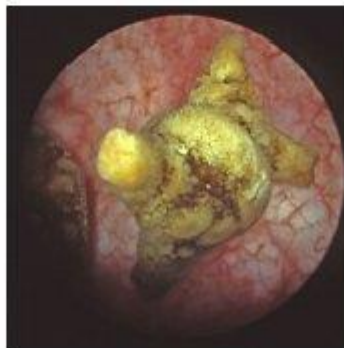
(e) Milde hämorrhagische Zystitis



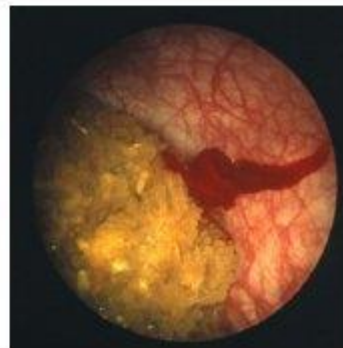
(f) Abheilende hämorrhagische Zystitis



(g) Cystitis glandularis



(h) Harnblasenstein



(i) Harnblasenstein

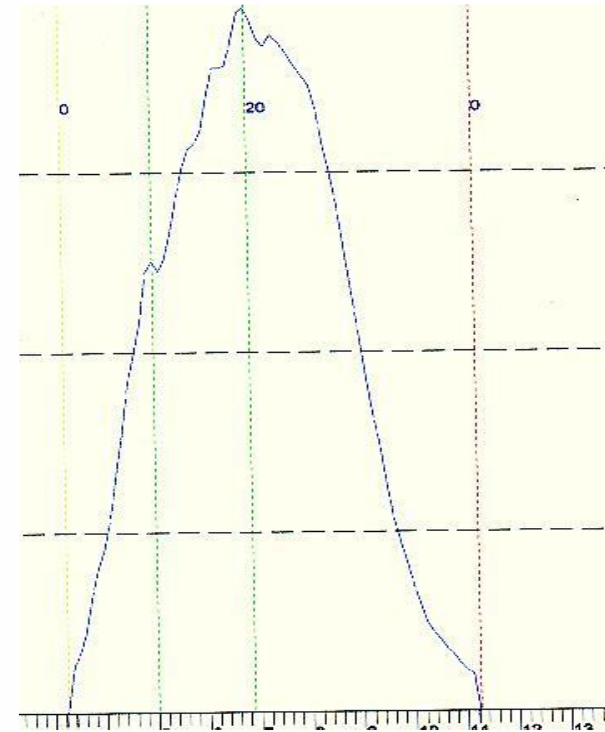
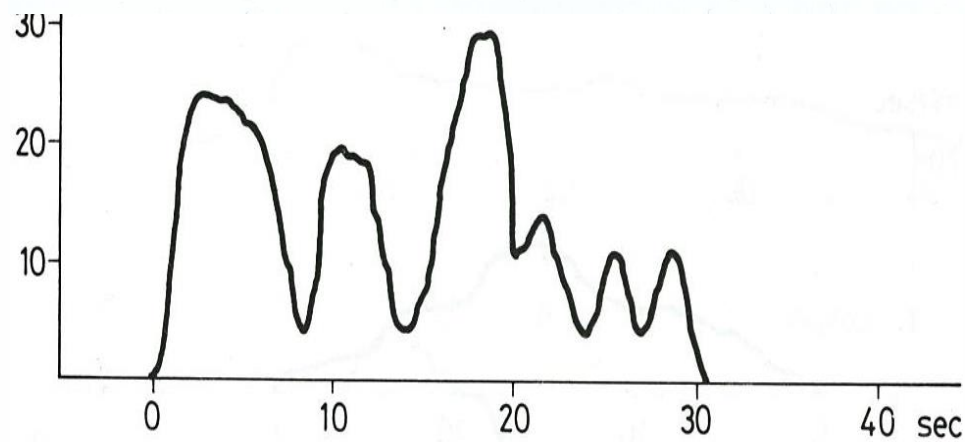
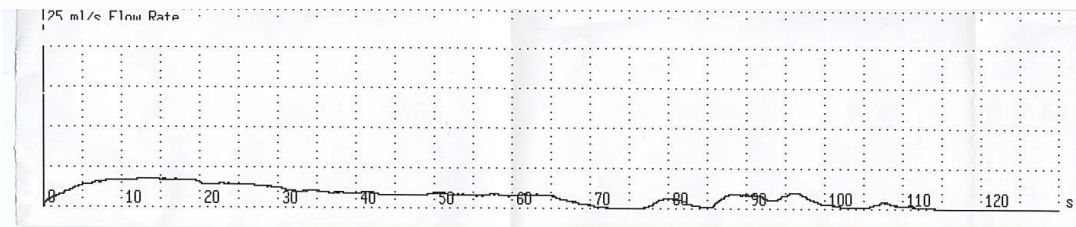
Urodynamik



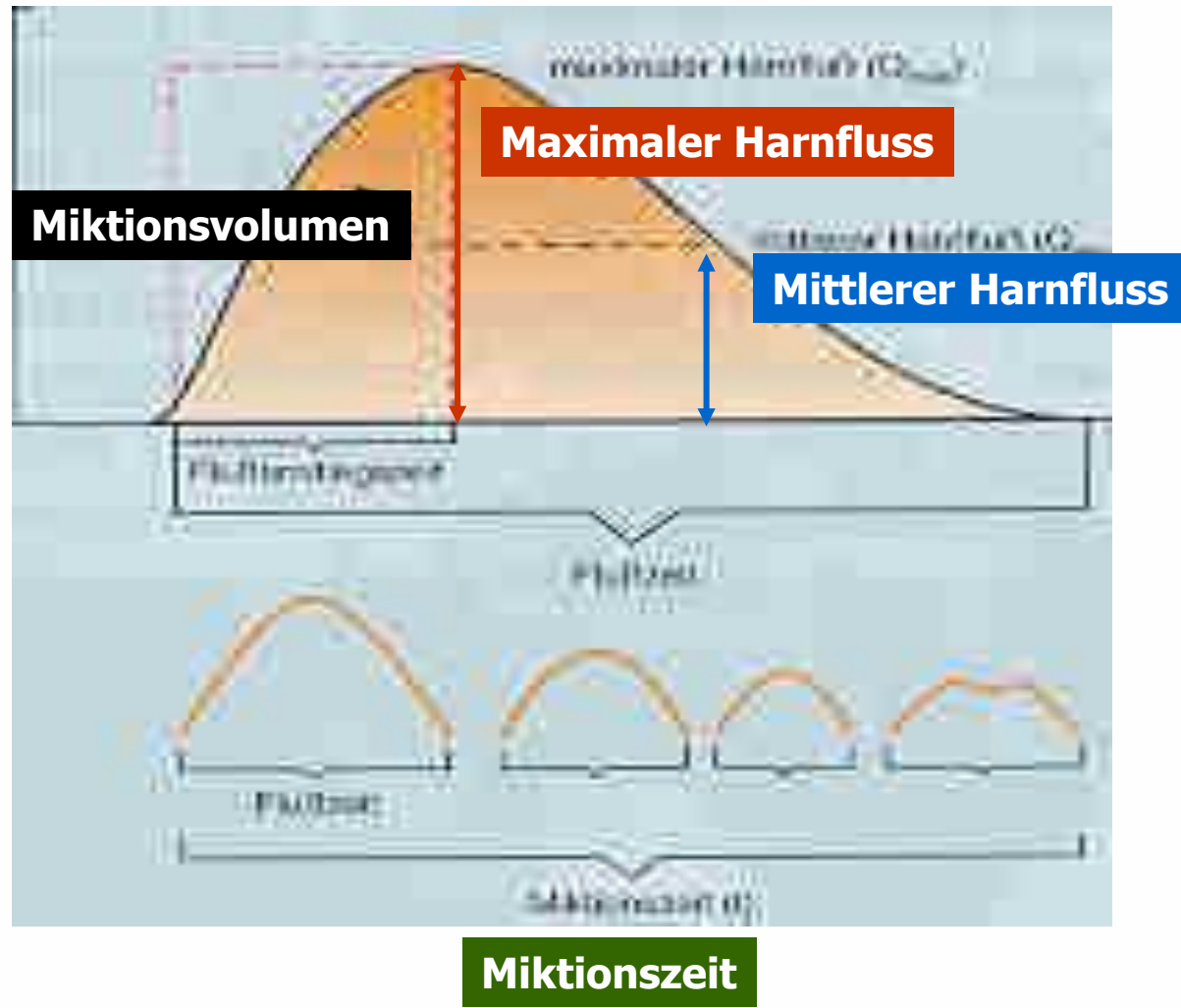
- ↪ Uroflowmetrie
- ↪ Zystometrie
- ↪ Druck-Fluss Messung
- ↪ Urethra Druckprofil
- ↪ Beckenboden EMG

Uroflowmetrie

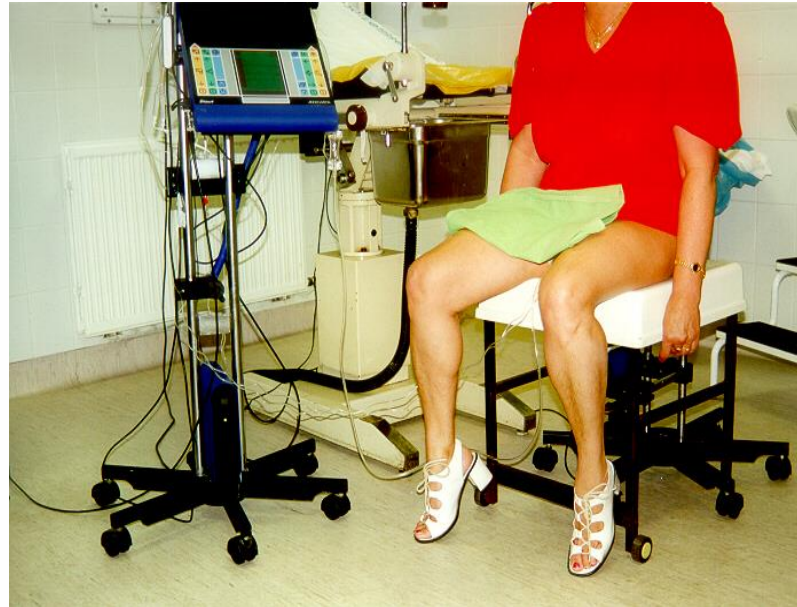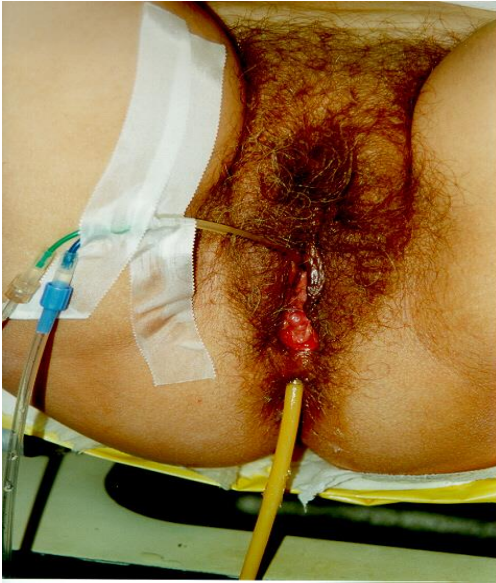
nicht invasive Messung des Urinvolumens (ml), das die Urethra in der Zeiteinheit (s) während der gesamten Miction verlässt



Uroflowmetrie: Definitionen



Zytomanometrie

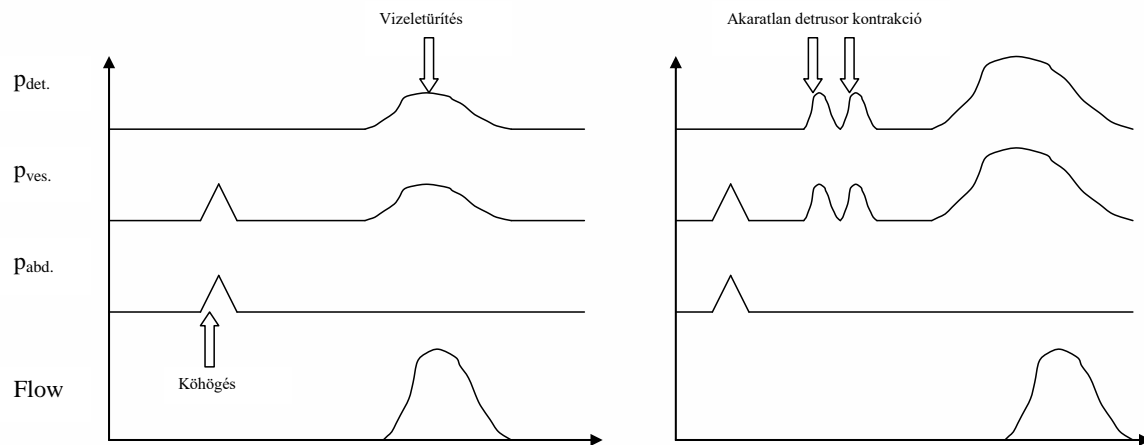


Definitionen

simultane Registrierung vom vesikalem und abdominalem Druck bei kontinuierlicher Blasenfüllung

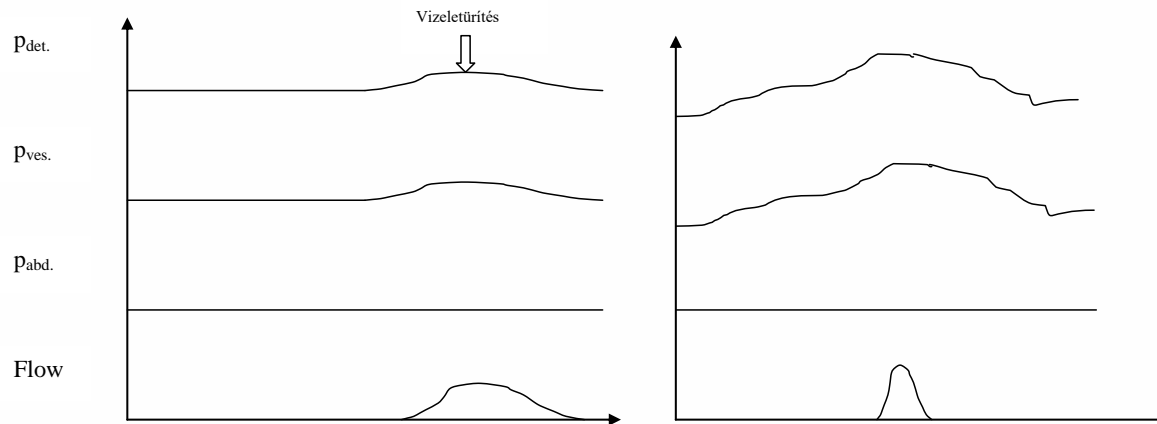
- ↳ ***Maximale Blasenkapazität***
- ↳ ***Compliance***
- ↳ ***Detrusorüberaktivität***

Zystometrie+Druck Fluss Messung



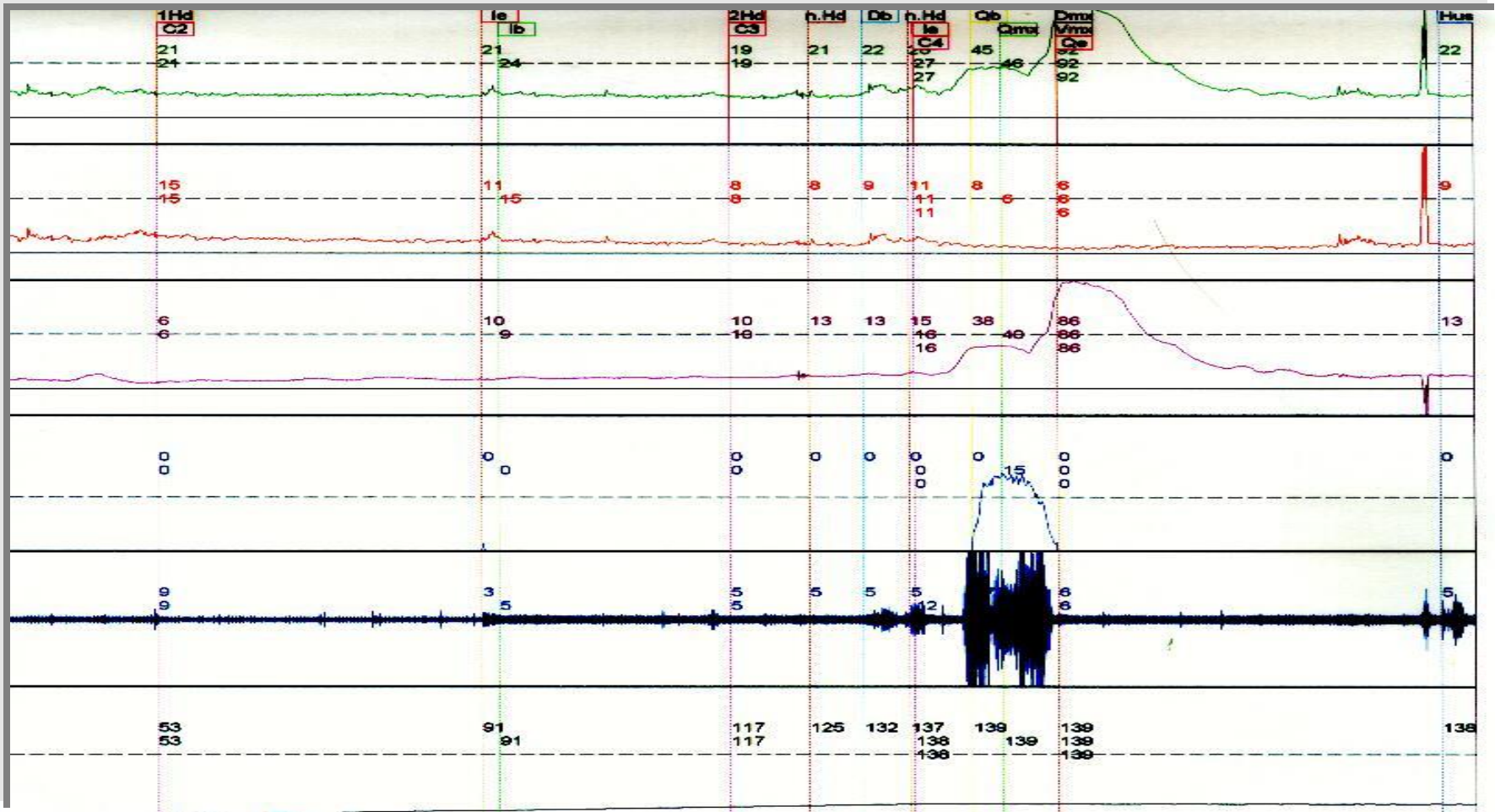
a, normális cystometriás görbe

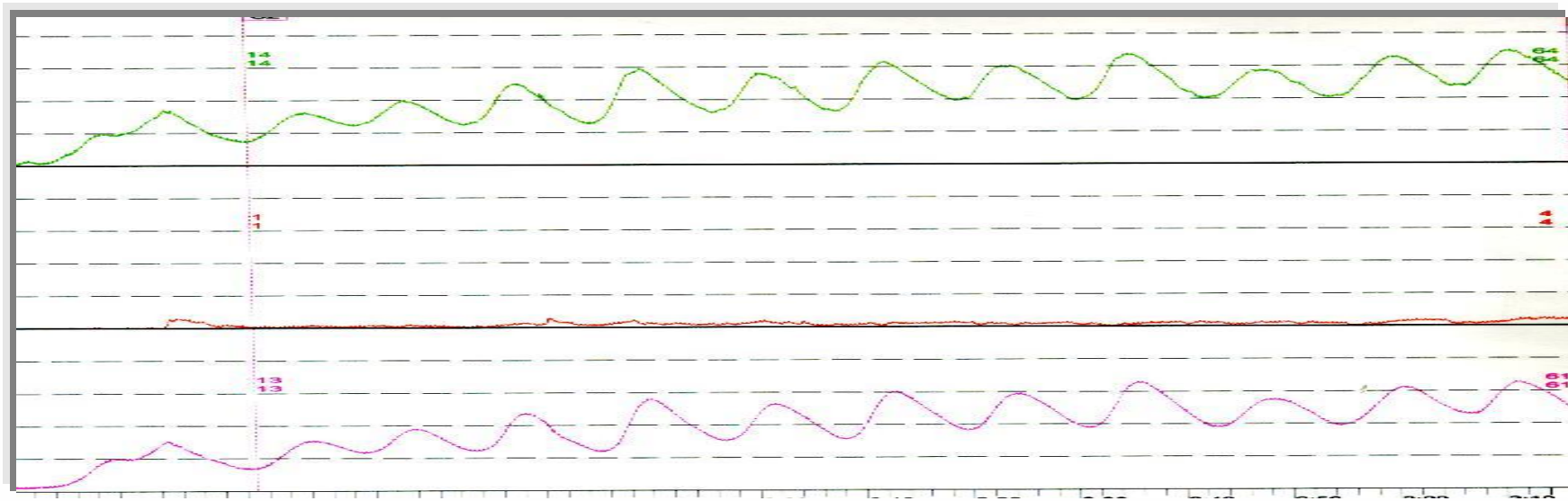
b, detrusor hyperaktivitás



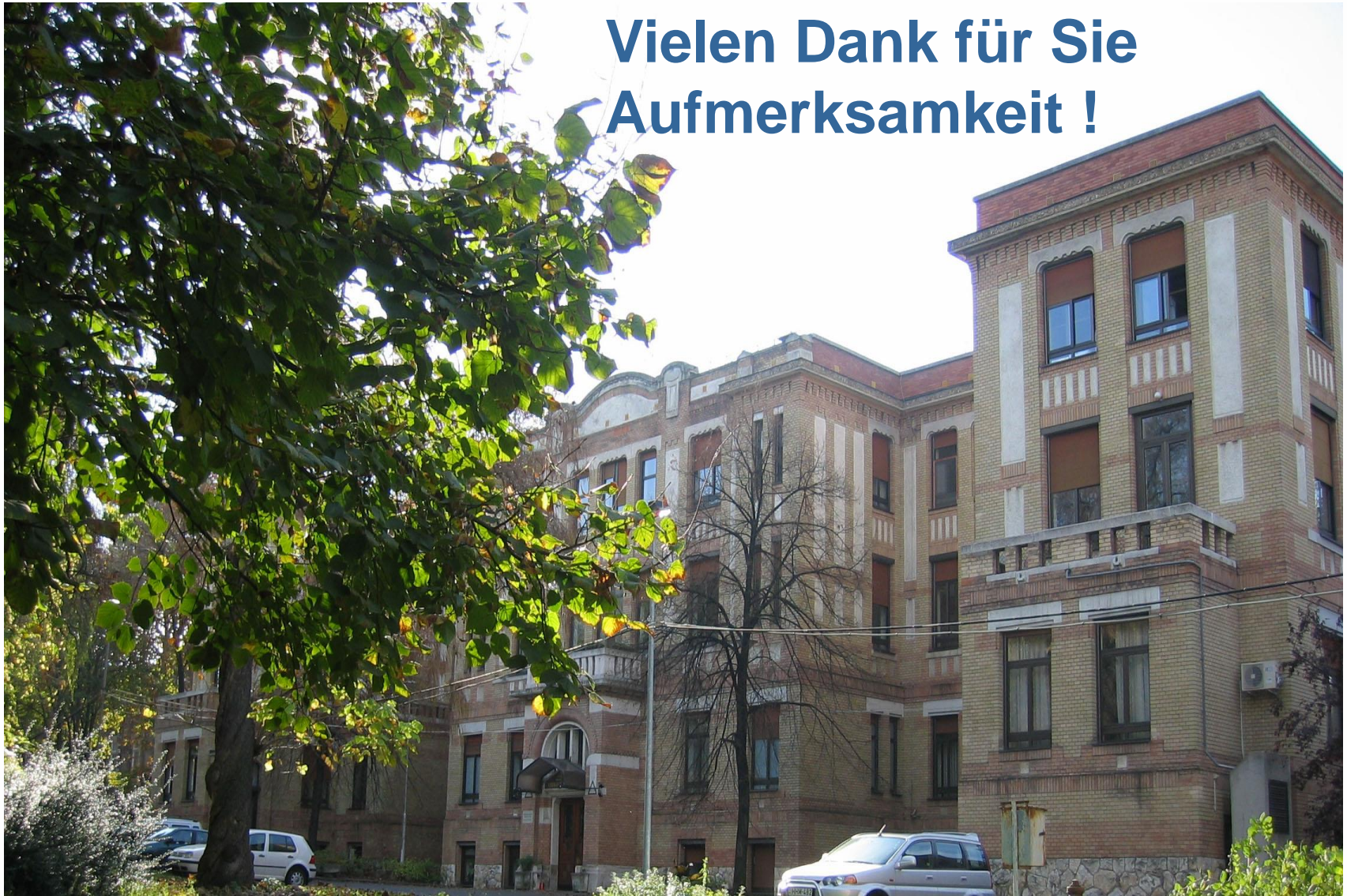c, detrusor hypokontaktilitás

d, beszűkült hólyag-compliance





**Vielen Dank für Sie
Aufmerksamkeit !**



Semmelweis University
<http://semmelweis.hu>