The clinical appearance and diagnosis of odontogenic cysts

SE Arc-Állcsont-Szájsebészeti és Fogászati Klinika
BUDAPEST

DEFINITION

- A cyst is a sac with walls of connective tissue, lined by epithelium, containing fluid or soft material

- expands, doesn't infiltrate
- caused by developmental disturbance or inflammation

ODONTOGENIC CYSTS

- *Cavity contains*: straw-yellow, serosus fluid, cholesterol crystals
- Continuosly growing → hydrostatic pressure, bone tissue is atrophied, roots are displaced
- In general, do not cause complaints – size, inflammation
- Detected as incidental findings on X-ray

CLASSIFICATION OF CYSTS

- Odontogenic / non odontogenic
- Developmental disturbance / inflammation
- Bone / soft tissue

CLASSIFICATION OF CYSTS (WHO)

CAUSED BY DEVELOPEMENTAL DISTURBANCES

Odontogenic

- Follicular cyst
- Primordial cyst /Keratocyst
- Perinatal cyst
- Adult gingival cyst
- Eruptional cyst

Non odontogenic (fissural cysts)

- Nasopalatine duct cyst
- Globulomaxillary cyst
- Median palatal or mandibular cyst

CAUSED BY INFLAMMATION

- Radicular cyst
- Residual cyst
- Periodontal cyst

Pseudocysts

- Simple bone cyst
- Aneurysmatic cyst
- Latent bone cyst

Soft part cysts

- Medial and lateral neck cyst
- Dermoid cyst
- Salivary retention cyst
- Nasolabial cyst

DIAGNOSTICS

- Clinical examination
- Radiologic examination
- Aspiration (soft-tissue cysts)

THE CLASSIFICATION OF ODONTOGENIC CYSTS

1. Radicular cyst
2. Residual cyst
3. Follicular cyst
4. Periodontal cyst
5. Primordial cyst (keratocyst)

RADICULAR CYST

- Arising from inflammatory origin
- Necrosis of the pulp → the cyst develops at the apex of the tooth
- The epithel lining is originates from epithelial rests of Malassez
- In case of inflammation the content of the cyst can be turbid or purulent

RADICULAR CYST

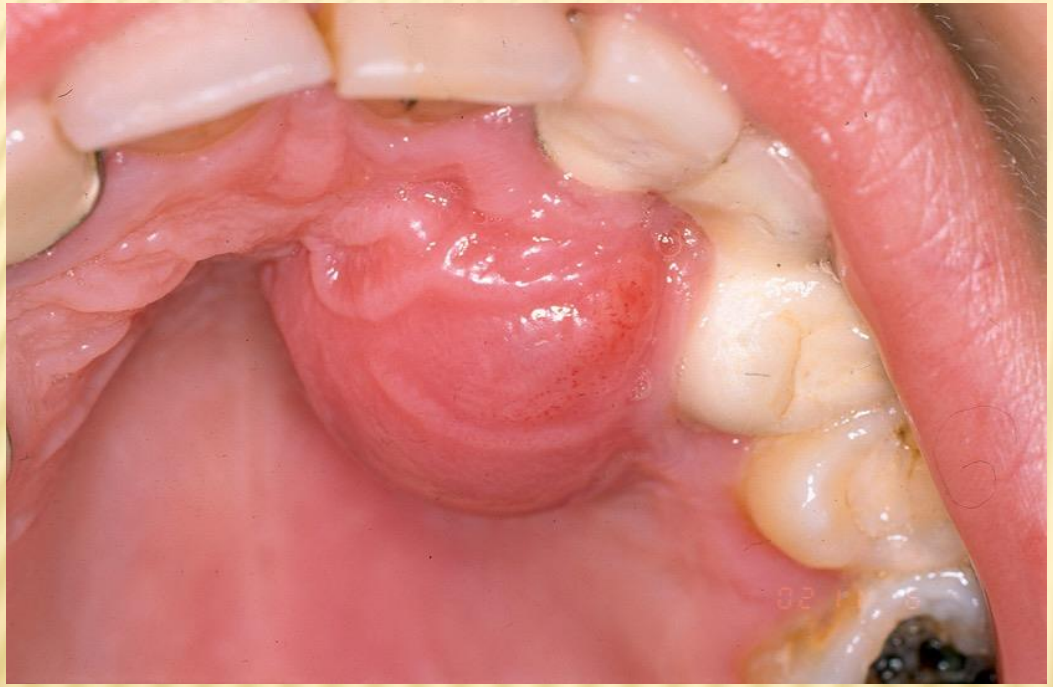

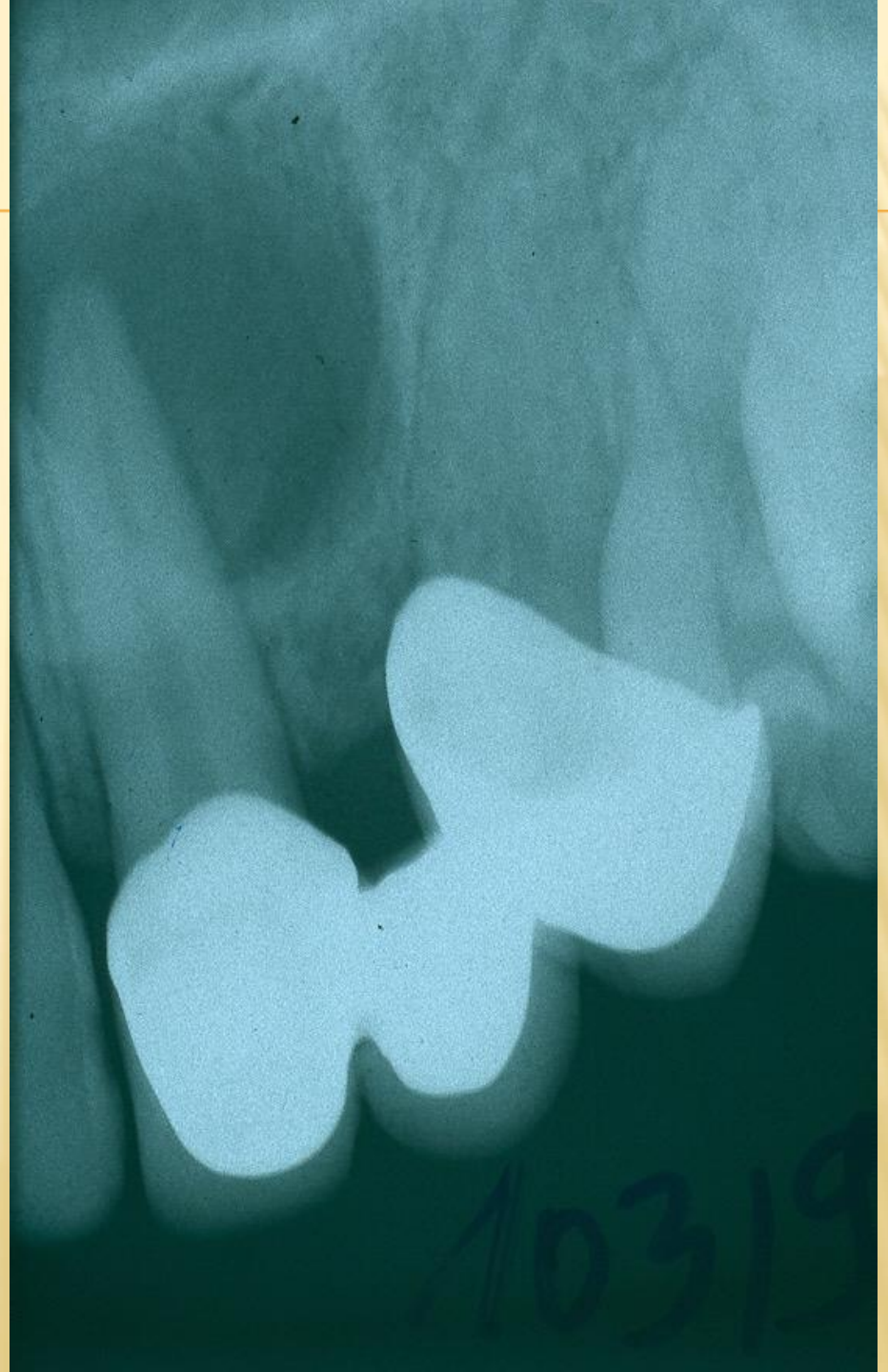

Kép forrása: Szabó Gy.: Szájsebészet (Semmelweis Kiadó, 2004)

RADICULAR CYST

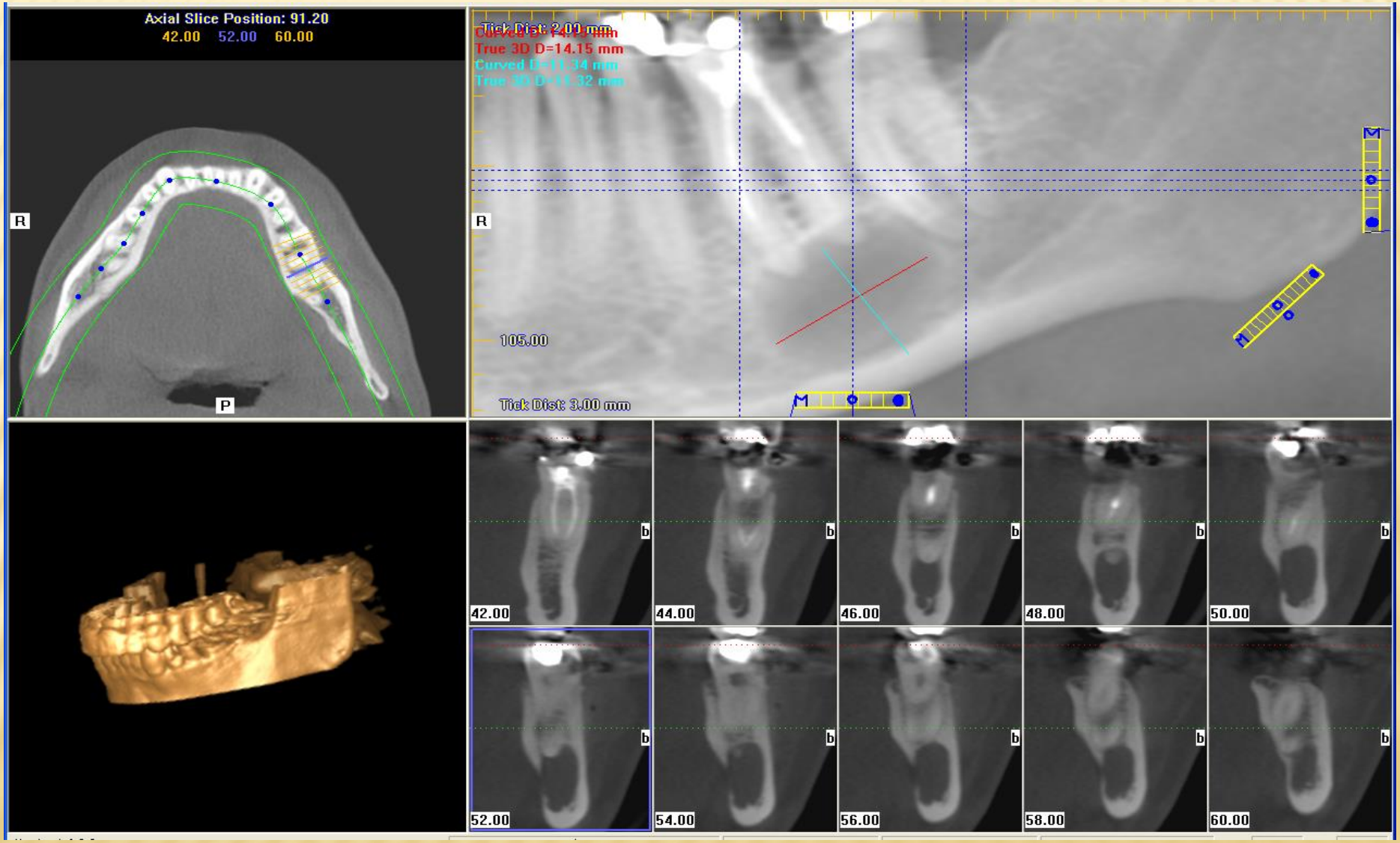

THE CLASSIFICATION OF ODONTOGENIC CYSTS

1. Radicular cyst
2. Residual cyst
3. Follicular cyst
4. Periodontal cyst
5. Primordial cyst (keratocyst)

RESIDUAL CYST

- Arising from inflammatory origin
- When a tooth is extracted, but the cyst remains
- Inadequate treatment

RESIDUAL CYST

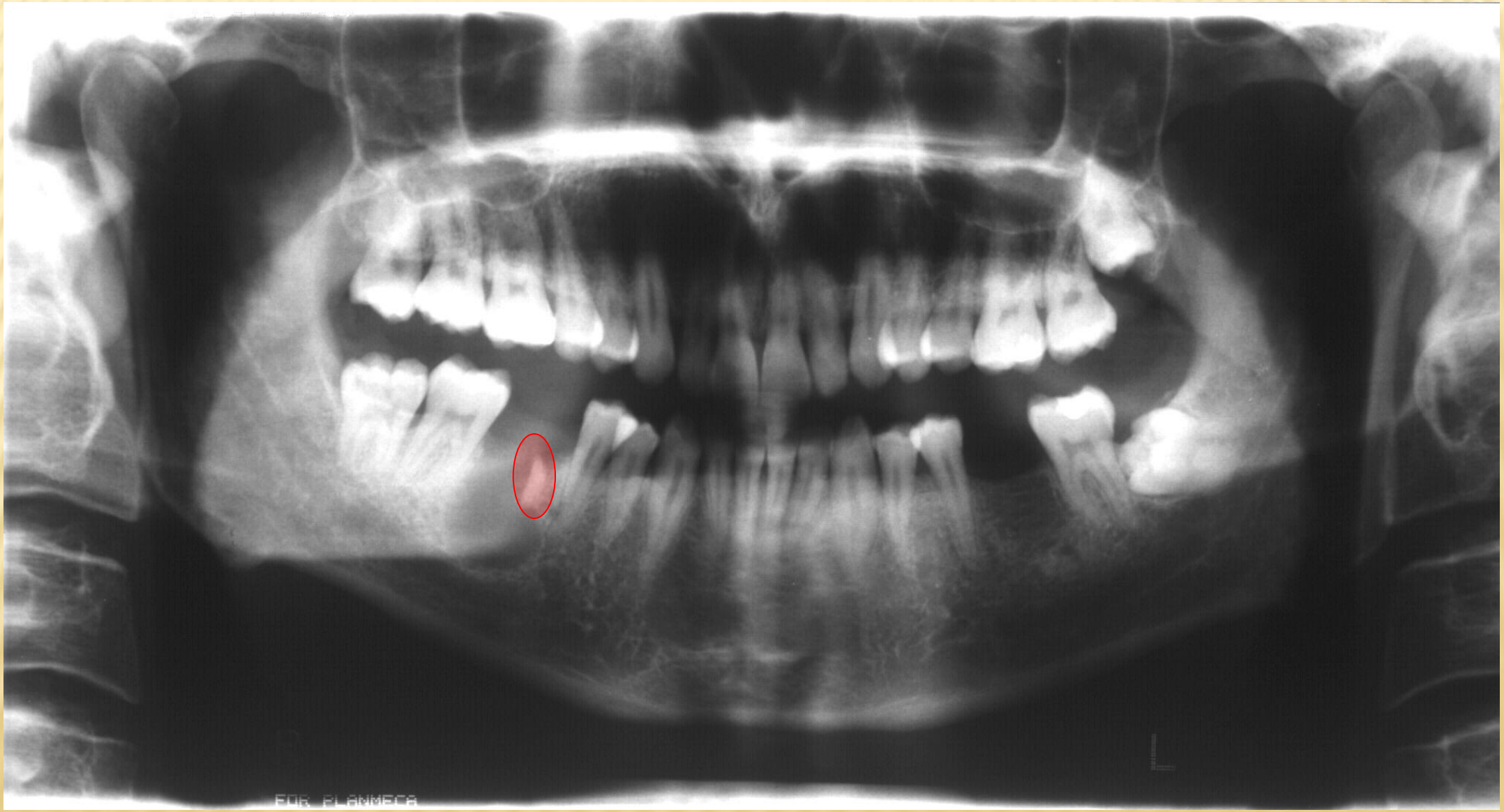

RESIDUAL CYST

THE CLASSIFICATION OF ODONTOGENIC CYSTS

1. Radicular cyst
2. Residual cyst
3. Follicular cyst
4. Periodontal cyst
5. Primordial cyst (keratocyst)

FOLLICULAR CYST

- Develomental origin
- The epithel lining is from the reduced enamel epithelium
- Around the crown of a tooth that has not erupted
- Cyst develops after the formation of the crown of a tooth
- Unilobular, but it may be multilobular

FOLLICULAR CYST

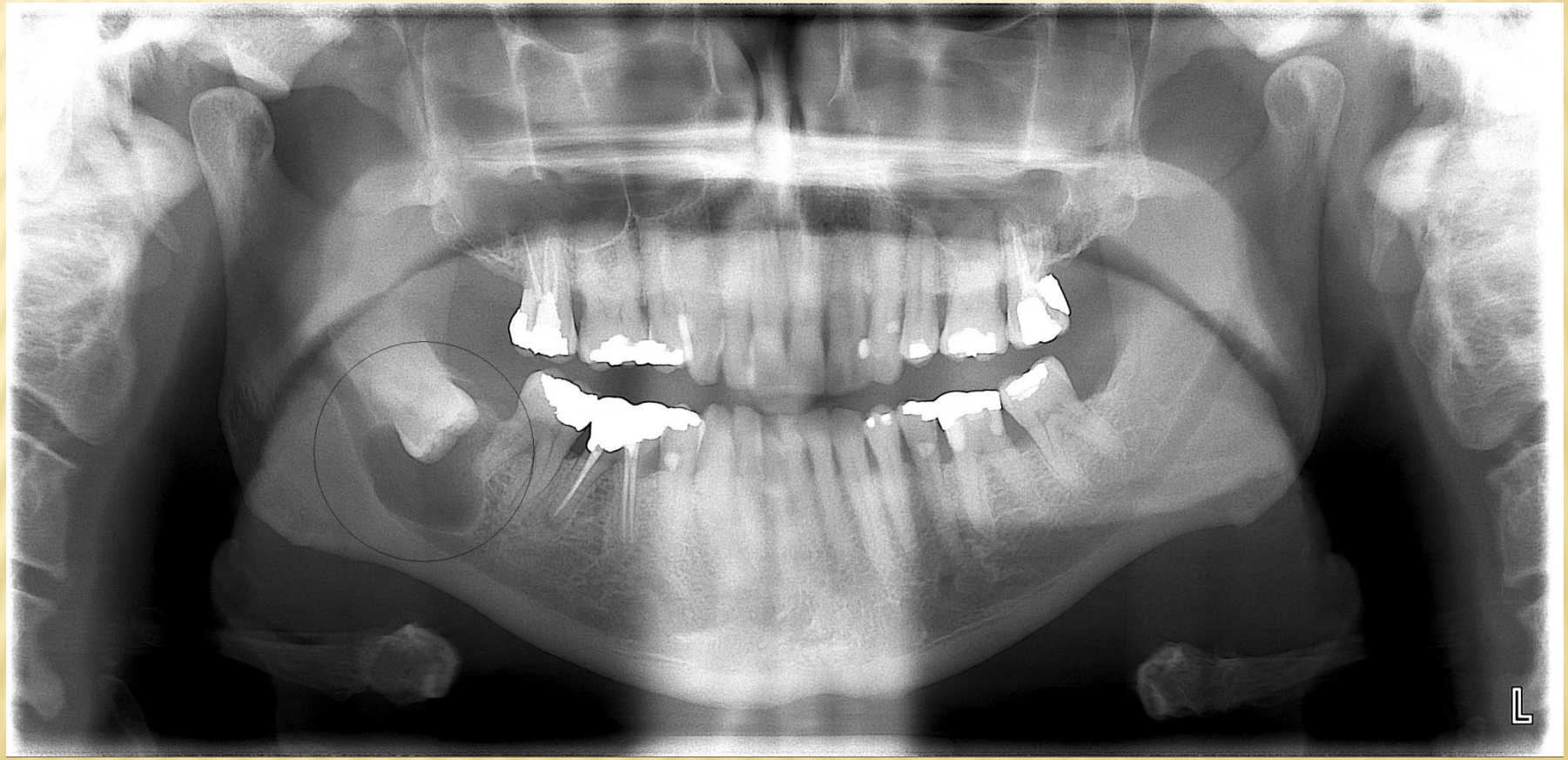

FOLLICULAR CYST

FOLLICULAR CYST

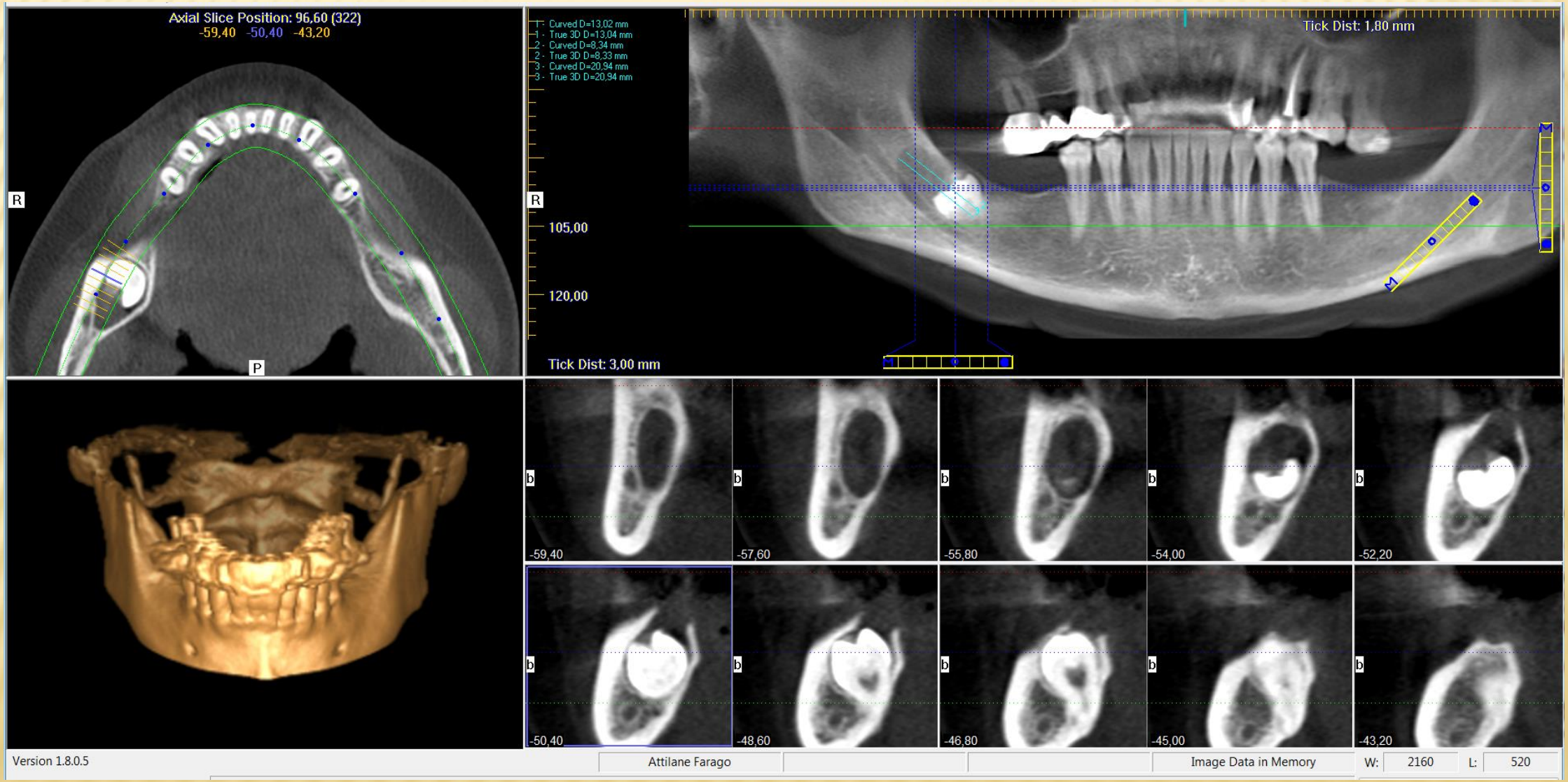

MULTIPLE FOLLICULAR CYSTS FORMATION

- Dentin dysplasia
- Cleidocranialis dysostosis

  /lack of clavicle, supernumerary teeth /
- Klippel-Feil syndrome

  /fusion of neck vertebrae/

THE CLASSIFICATION OF ODONTOGENIC CYSTS

1. Radicular cyst
2. Residual cyst
3. Follicular cyst
4. Periodontal cyst
5. Primordial cyst (keratocyst)

PERIODONTAL CYST

- Arising from periodontal inflamation
- In general it is located in the coronal third of te root

THE CLASSIFICATION OF ODONTOGENIC CYSTS

1. Radicular cyst
2. Residual cyst
3. Follicular cyst
4. Periodontal cyst
5. Primordial cyst (keratocyst)

KERATOCYST

- Developmental anomaly, originates from the dental lamina
- Rapidly proliferating epithelial lining
- The cystic lining exhibits hyperkeratosis
- The relaps is common /35%/
- Most frequent localisation; distal to the third molar
- Hystological diagnosis!

MICROGRAPH OF KERATOCYST

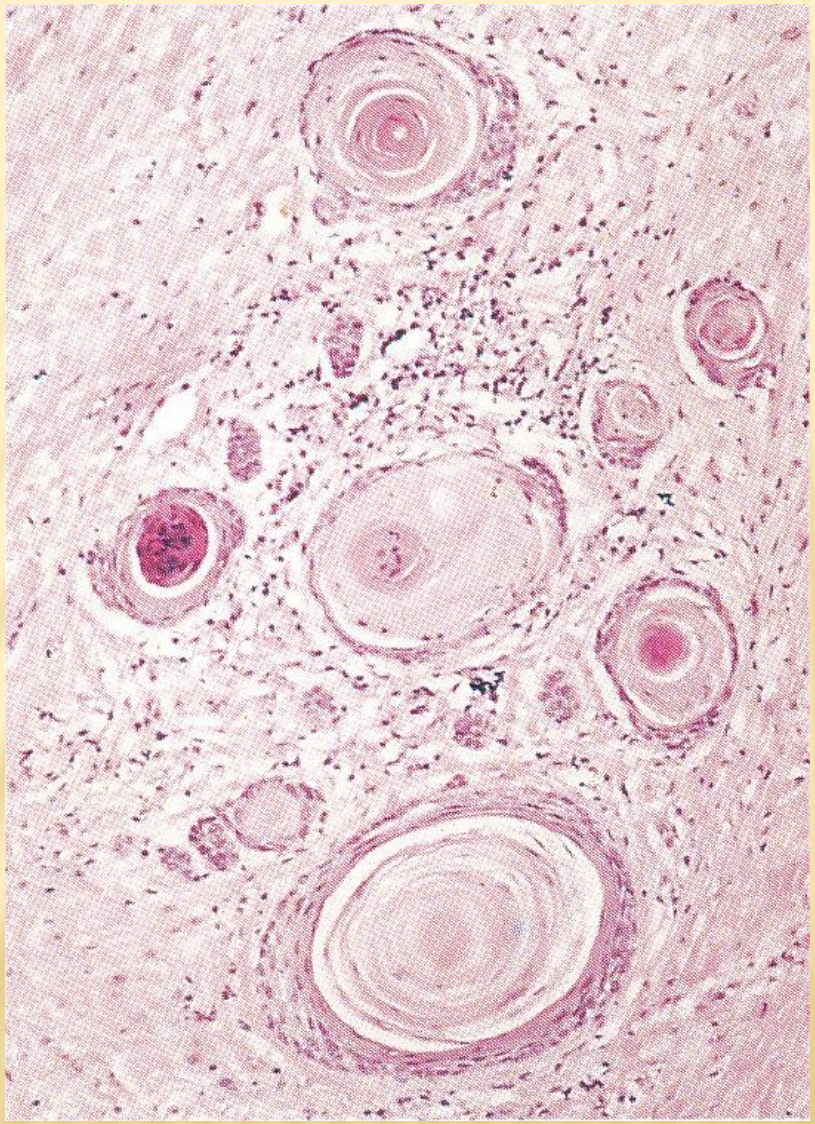

KERATOCYST

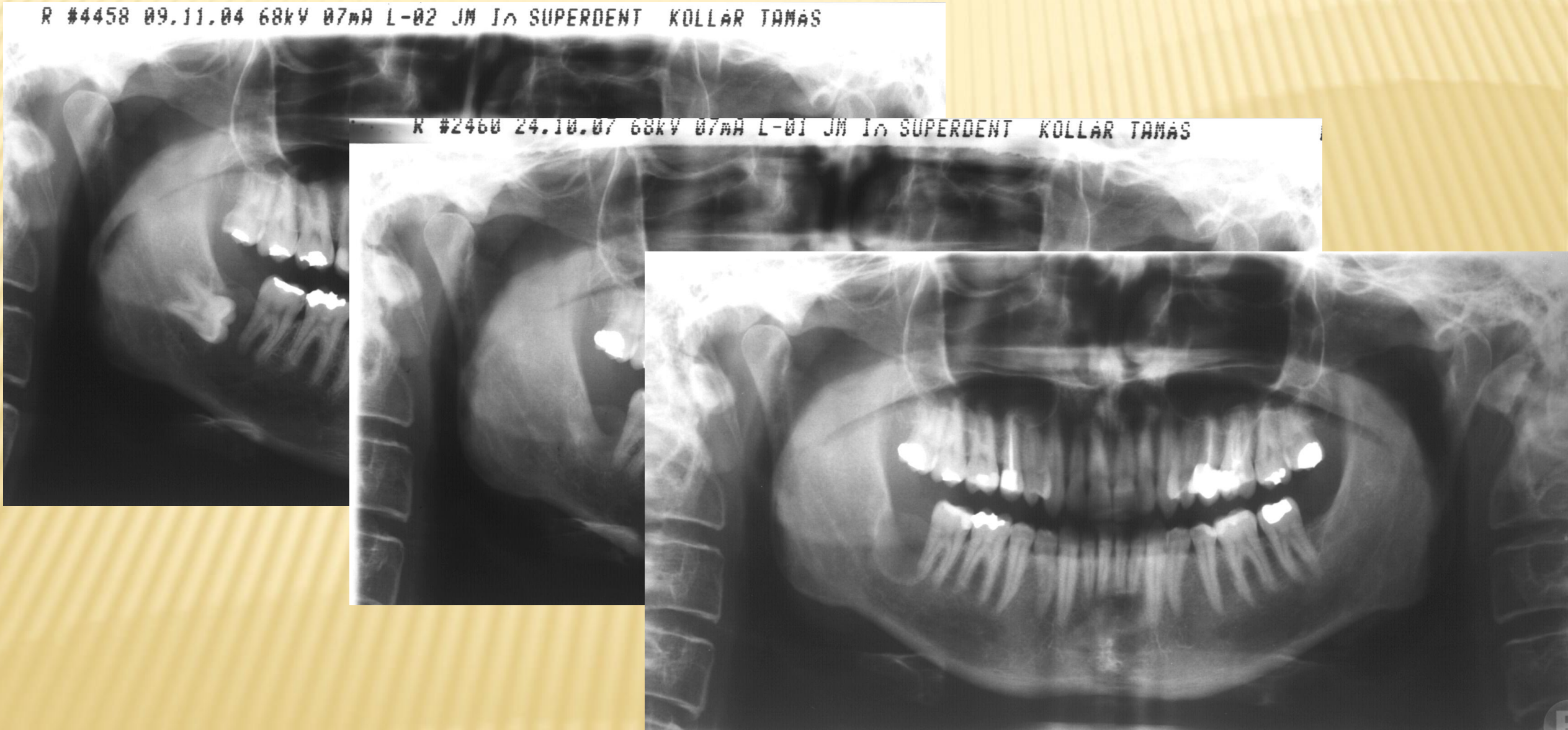
R #4458 09.11.04 68kV 07mA L-02 JM I∩ SUPERDENT KOLLAR TAMAS
R #2460 24.10.07 68kV 07mA L-01 JM I∩ SUPERDENT KOLLAR TAMAS

GORLIN-GOLTZ SYNDROME

- Nevoid basal-cell carcinoma syndrome
- multiplex keratocysts
- basal cell carcinomas of the skin
- rib and vertebrae anomalies

DIFFERENTIAL DIAGNOSIS OF RADICULAR CYSTS

- Dental granuloma
- Maxillary sinus
- Giant cell granuloma
- Pseudocyst
- Ameloblastoma
- Fibrous dysplasia

DIFFERENTIAL DIAGNOSIS OF RADICULAR CYSTS

- dental granuloma

they can be only differentiated through histology!

DIFFERENTIAL DIAGNOSIS OF RADICULAR CYSTS

- Maxillary sinus

The thin cortical layer of bone on the sinus floor is represented as a continuous white line.

The “sinus line” , following the apices of the neighbouring teeth can proceed interdentally

DIFFERENTIAL DIAGNOSIS OF RADICULAR CYSTS

- Maxillary sinus

Simmetry!

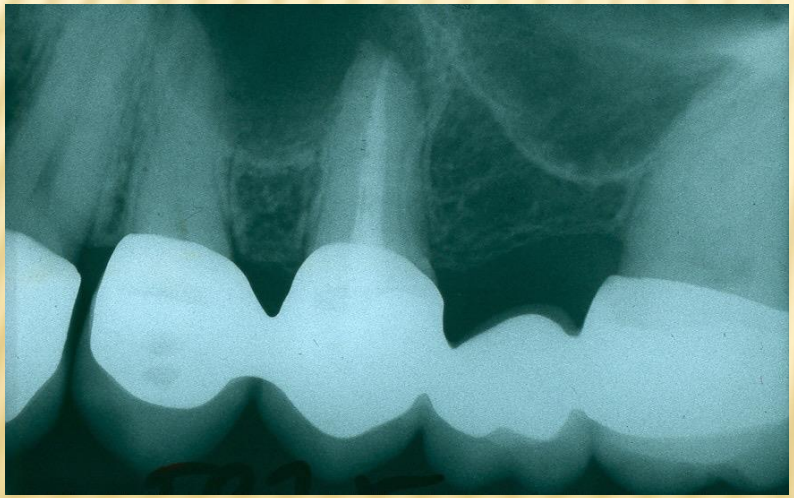

DIFFERENTIAL DIAGNOSIS OF RADICULAR CYSTS

Giant cell granuloma

- Not a real tumour – bone disease
- Extensive destruction of jawbones
- Mainly found in younger patients
- Facial and mucosal swelling,
- Affected teeth become mobile

X-ray image: Radiolucency with sharp contour. Projection is not round, intensive resorption of roots: unlikely to be a cyst

DIFFERENTIAL DIAGNOSIS OF RADICULAR CYSTS

- Pseudocyst
  - Traumatic bone cyst
  - Aneurysmatic bone cyst
  - Stafne cyst

Intraosseous lesions without epithelial lining. Most commonly found in the molar region and the mandibular angle.

DIFFERENTIAL DIAGNOSIS OF RADICULAR CYSTS

Ameloblastoma

- Most common type of odontogenic tumour
- May grow without complaints
- Migration of teeth, asymetric swelling of the jaw, facial deformity, lack of teeth in the molar region
- Roots of affected teeth might resorb

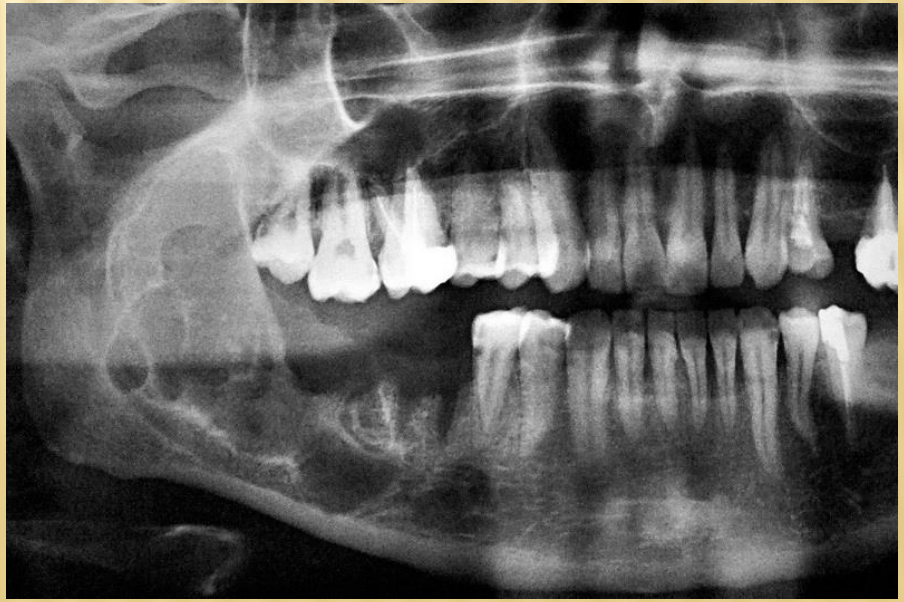

Tipically: multilocular lesion in the region of the mandibular angle or ramus. Sometimes the wisdom tooth is involved

DIFFERENTIAL DIAGNOSIS OF RADICULAR CYSTS

- Fibrous dysplasia

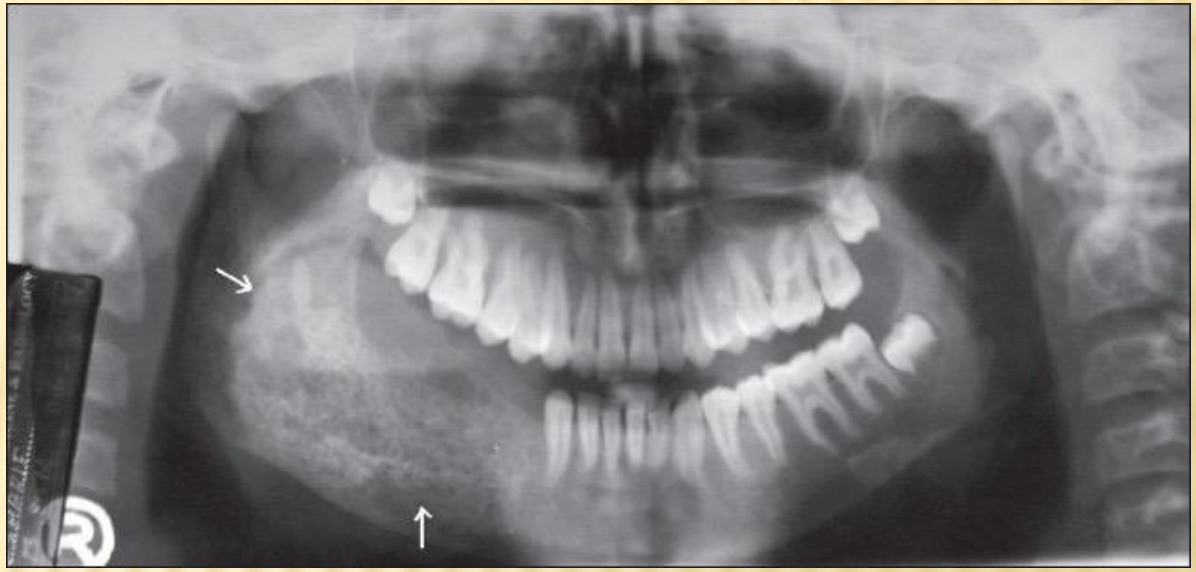

- Pathogenesis is unknown – bone development disorder
- X-ray image: variable, structure is blurred („foamy”, frosted glass like structure). Small or multilobular