OPERATION TECHNIQUES OF DENTOALVEOLAR SURGERY

Semmelweis University - Oral Surgery Department

MINOR ORAL SURGERY (DENTOALVEOLAR SURGERY)

MAXILLOFACIAL SURGERY
(Head and Neck Surgery)

SURGICAL THERAPY

SURGICAL THEORY

=

THE KNOWLEDGE OF THE METHODS & TECNIQUES (& BACKGROUND) OF SURGICAL INTERVENTIONS

SPECIFIC PROPERTIES OF DENTOALVEOLAR SURGERY

- **Frequent**
- **Bad reputation**
- **Outpatient**
- **Flap preparation surgery**
- **Bone surgery**
- **Unfavorable environment**

TOPICS OF THE LECTURE

INSTRUMENTS

INTRAORAL FLAPS

SUTURES

INSTRUMENTS

SURGICAL MOTOR

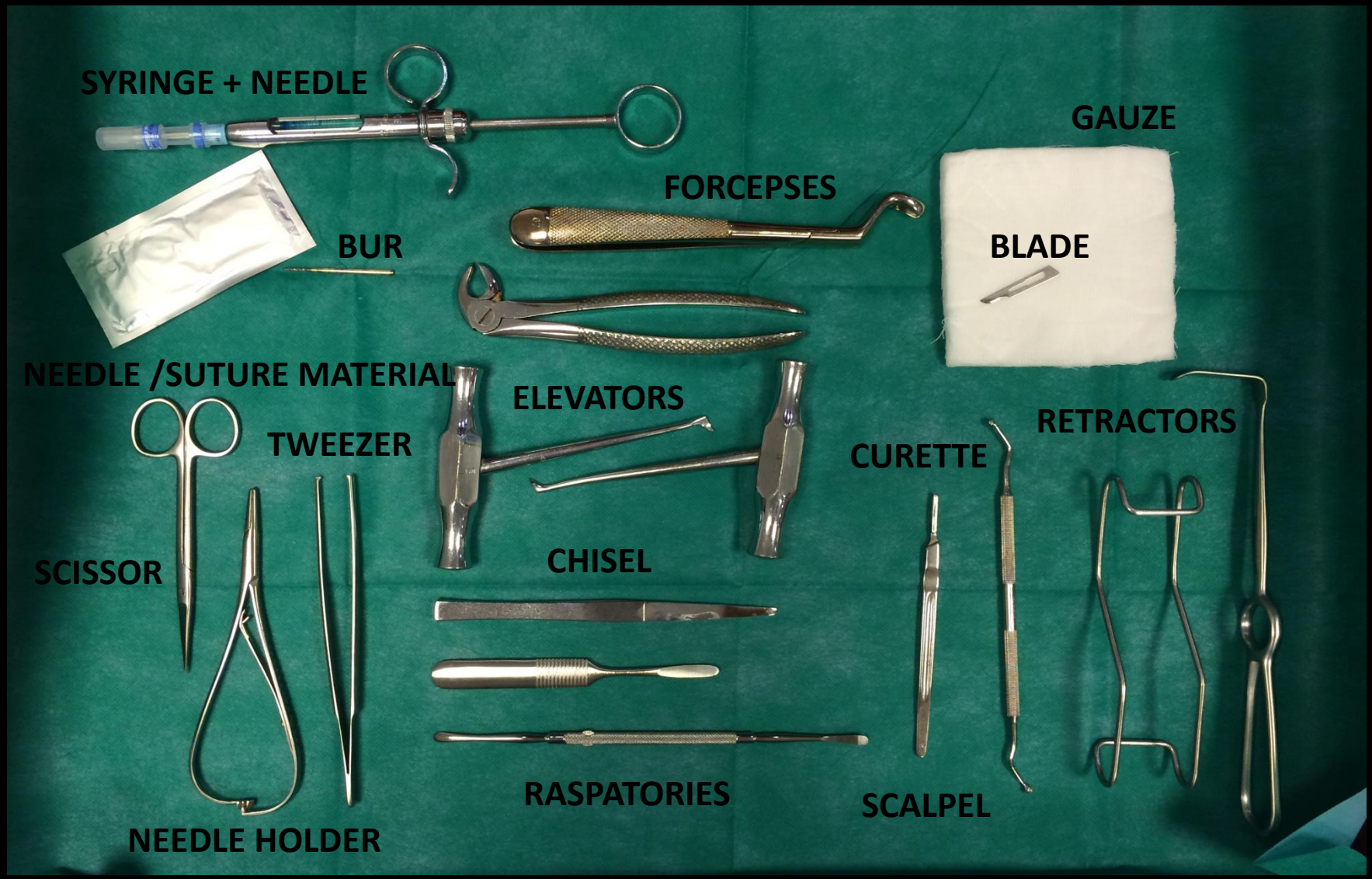
SYRINGE + NEEDLE
GAUZE
FORCEPSES
BLADE
BUR
NEEDLE /SUTURE MATERIAL
ELEVATORS
RETRACTORS
TWEEZER
CURETTE
SCISSOR
CHISEL
RASPATORIES
SCALPEL
NEEDLE HOLDER

Example: Surgical tooth removal

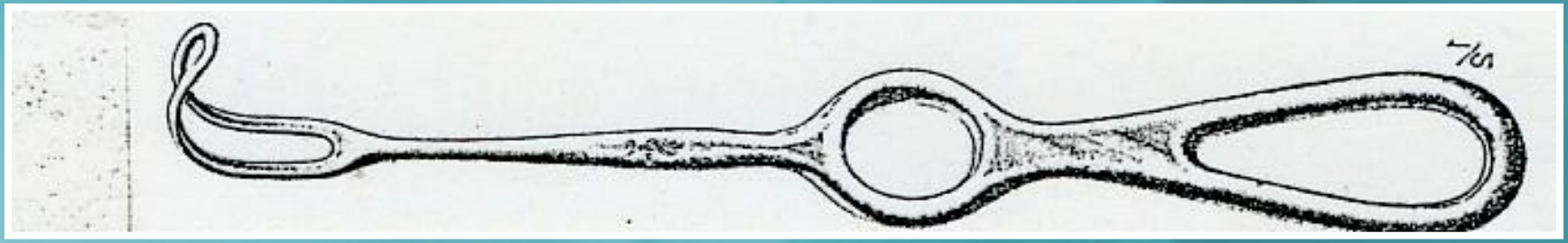

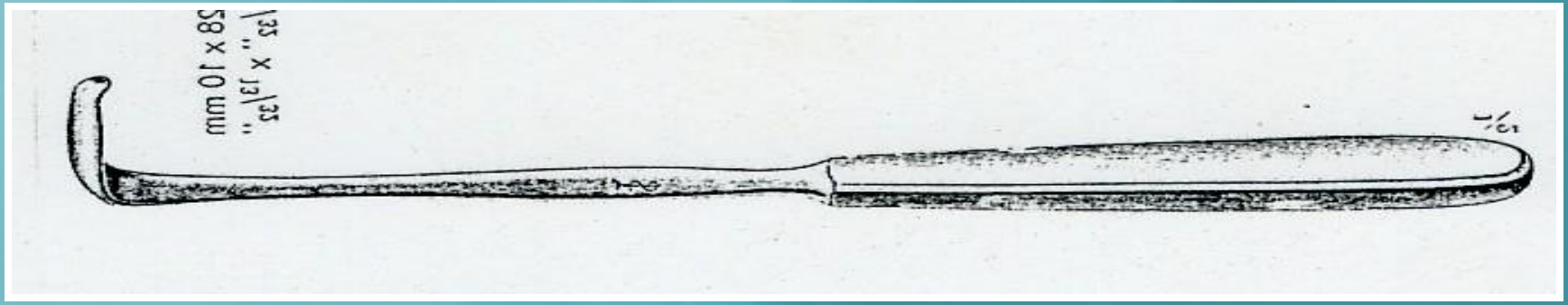

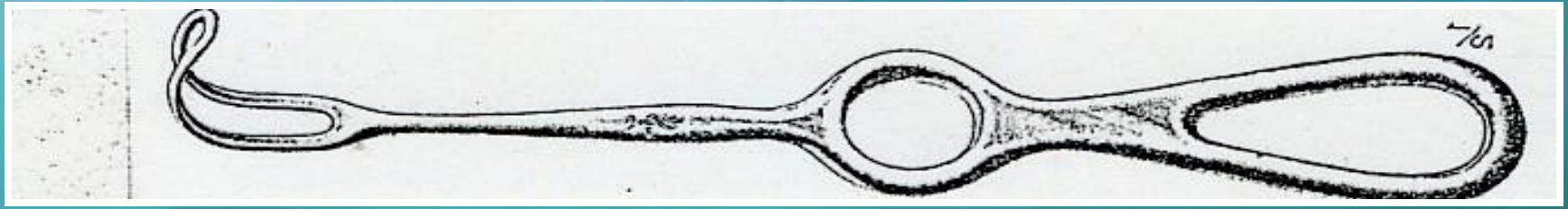

Scalpel

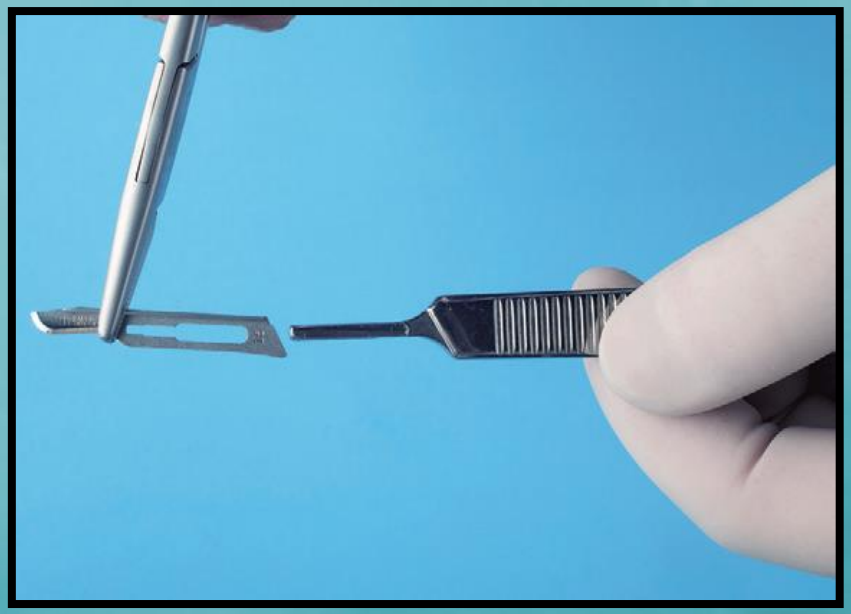



Raspatories (periosteal elevators)

Williger

Freer

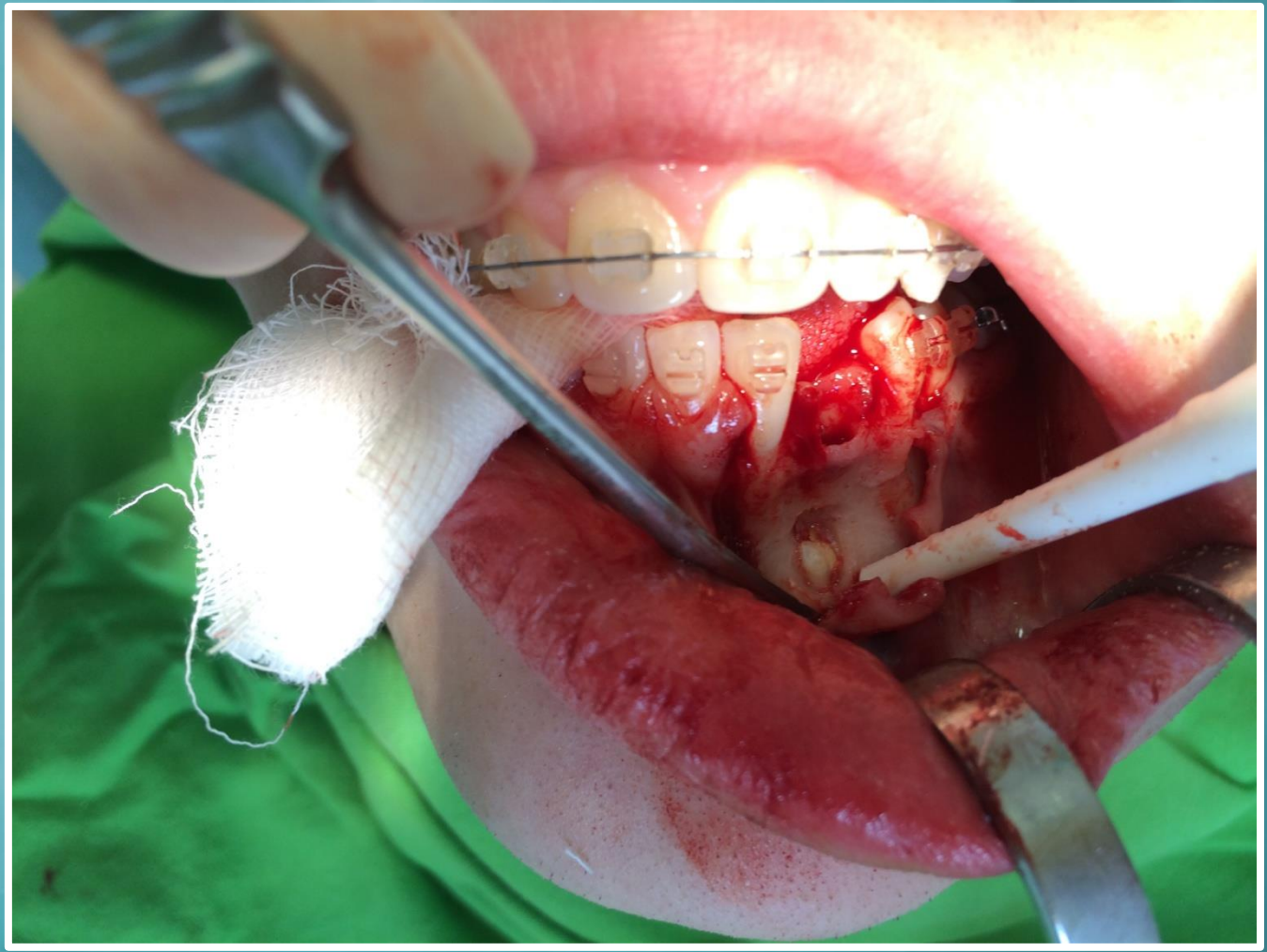

CASE by Dr. Katalin Csurgay

Chisels

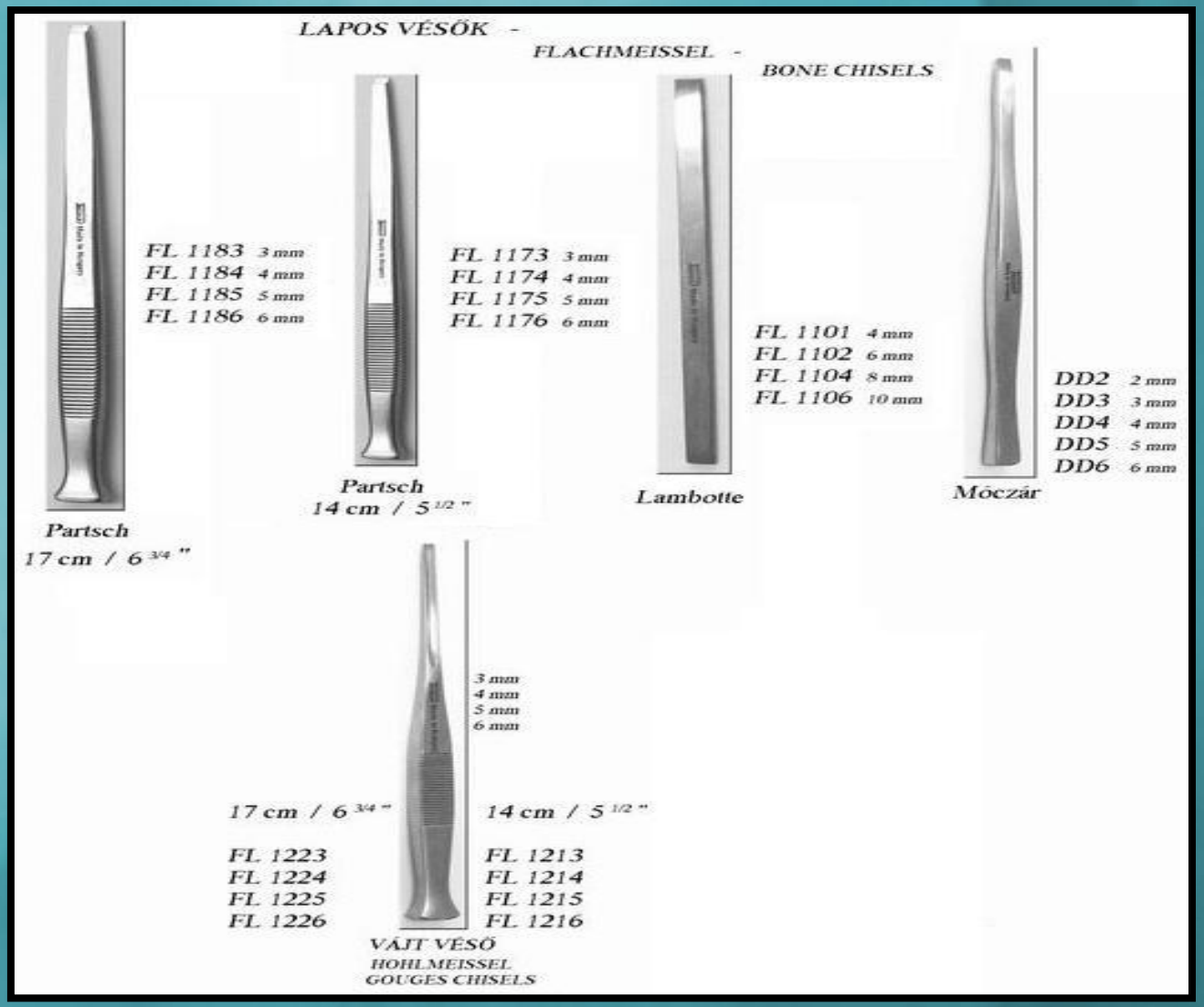
LAPOS VÉSŐK -
FLACHMEISSEL -
BONE CHISELS
FL 1183 3 mm
FL 1184 4 mm
FL 1185 5 mm
FL 1186 6 mm
Partsch
17 cm / 6 3/4 "
FL 1173 3 mm
FL 1174 4 mm
FL 1175 5 mm
FL 1176 6 mm
Partsch
14 cm / 5 1/2 "
FL 1101 4 mm
FL 1102 6 mm
FL 1104 8 mm
FL 1106 10 mm
Lambotte
DD2 2 mm
DD3 3 mm
DD4 4 mm
DD5 5 mm
DD6 6 mm
Móczár
3 mm
4 mm
5 mm
6 mm
17 cm / 6 3/4 "
FL 1223
FL 1224
FL 1225
FL 1226
14 cm / 5 1/2 "
FL 1213
FL 1214
FL 1215
FL 1216
VÁJT VÉSŐ
HOHLMEISSEL
GOUGES CHISELS

Chisels

MÓCZÁR

PARTSCH



Tweezers – *dental, surgical, anatomical*



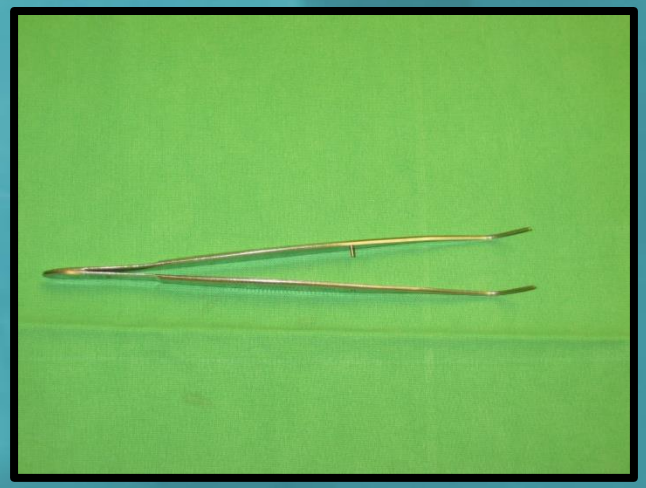

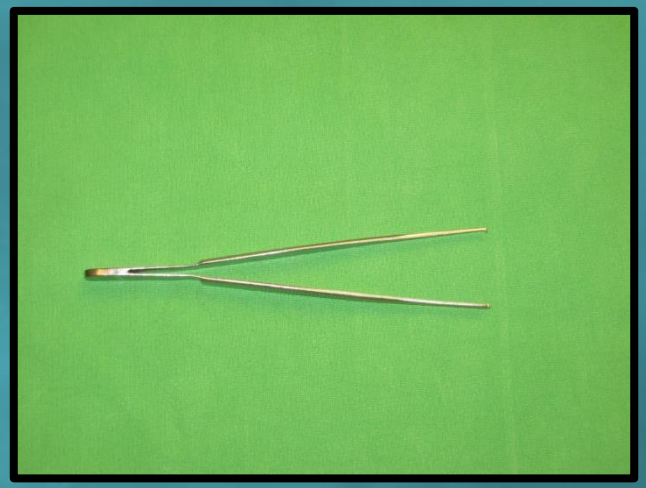

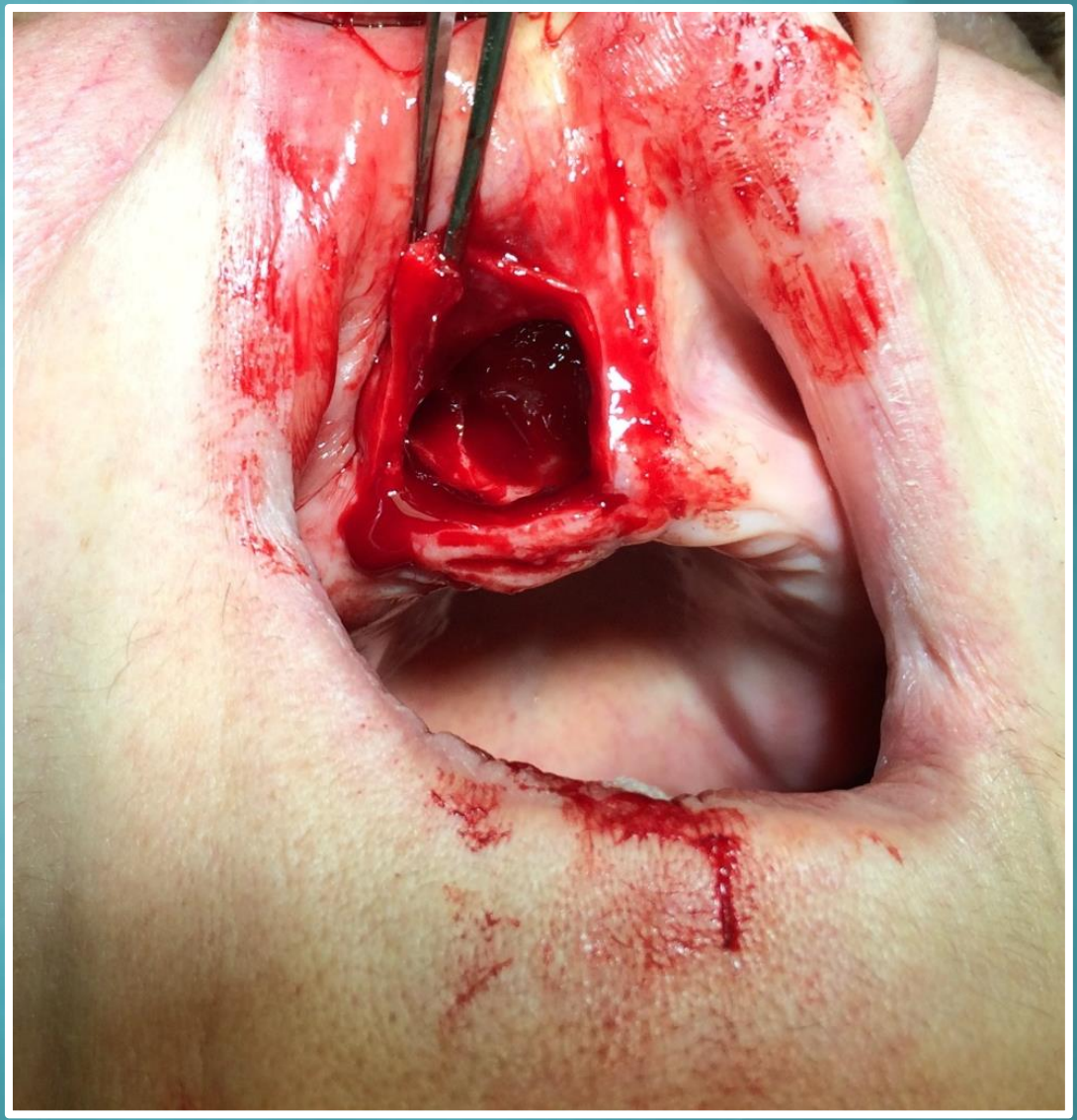

CASE by Dr. Fanni Sára Kálmán

Surgical burs



ROUND and LINDEMANN

Elevators and forcepses

Curettes



Kerpel



Volkmann

Curettes



Lucas

Needle holders

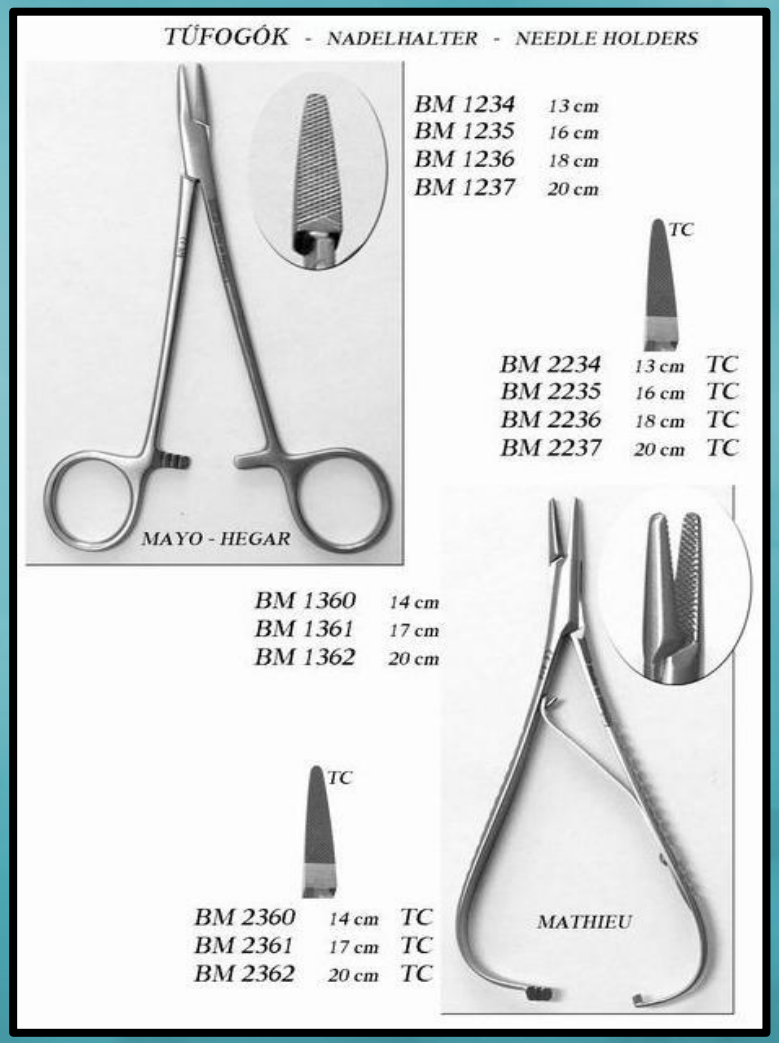

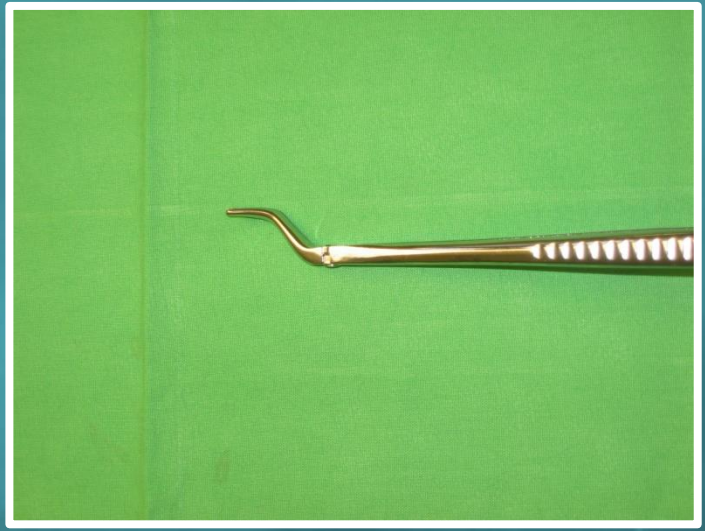

Needles

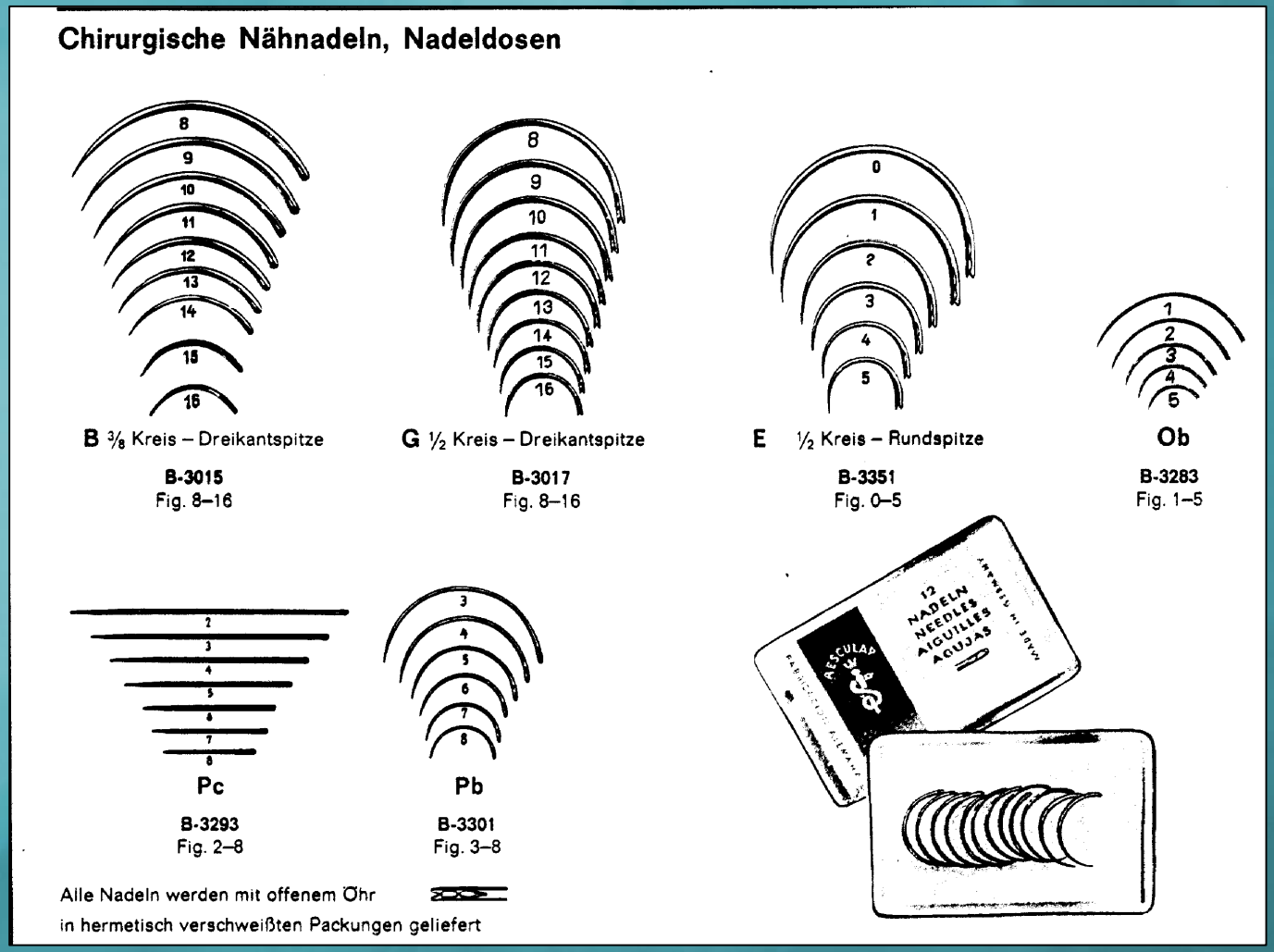
Chirurgische Nähnadeln, Nadeldosen
8
9
10
11
12
13
14
15
16
B 3/8 Kreis – Dreikantspitze
B-3015
Fig. 8–16
8
9
10
11
12
13
14
15
16
G ½ Kreis – Dreikantspitze
B-3017
Fig. 8–16
0
1
2
3
4
5
E ½ Kreis – Rundspitze
B-3351
Fig. 0–5
1
2
3
4
5
Ob
B-3283
Fig. 1–5
2
3
4
5
6
7
8
Pc
B-3293
Fig. 2–8
3
4
5
6
7
8
Pb
B-3301
Fig. 3–8
12
NADELN
NEEDLES
AIGUILLES
AGUJAS
AESCULAP
Alle Nadeln werden mit offenem Öhr
in hermetisch verschweißten Packungen geliefert

Needles

Patterns of the suture needle according to accessibility:

- Straight suture needles
  - For skin closure
- Curved suture needles
  - For intraoral suturing
  - For deep suturing
- Half circle suture needles
  - For intraoral suturing
  - For deep suturing

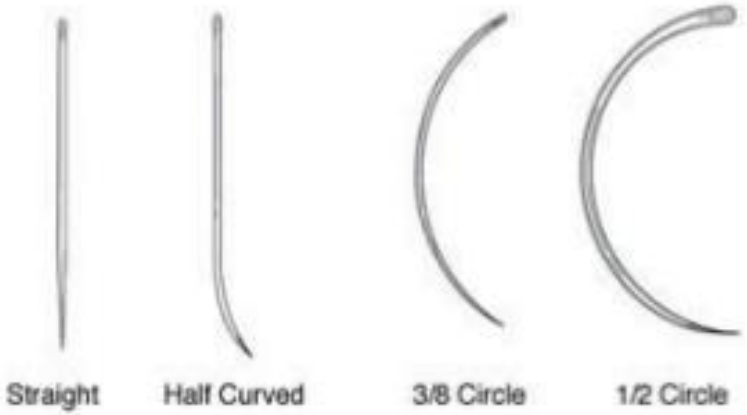

http://www.burtons.uk.com/products.asp?recnumber=424

INTRAORAL FLAPS

FLAPS - REQUIREMENTS

Preservation of important anatomical structures.

- *mentalis neurovascularis plexus*
- *palatal art.*
- *ducts*
- *nasopalatine art.*
- *infraorbital n.*
- *pterygoid plexus*

FLAPS - REQUIREMENTS

2. Mucoperiosteal flap preparation

FLAPS - REQUIREMENTS

3. Adequate size

FLAPS - REQUIREMENTS

4. Possibility of flap modification during surgery.

FLAPS - REQUIREMENTS

5. Good blood supply of the flap.

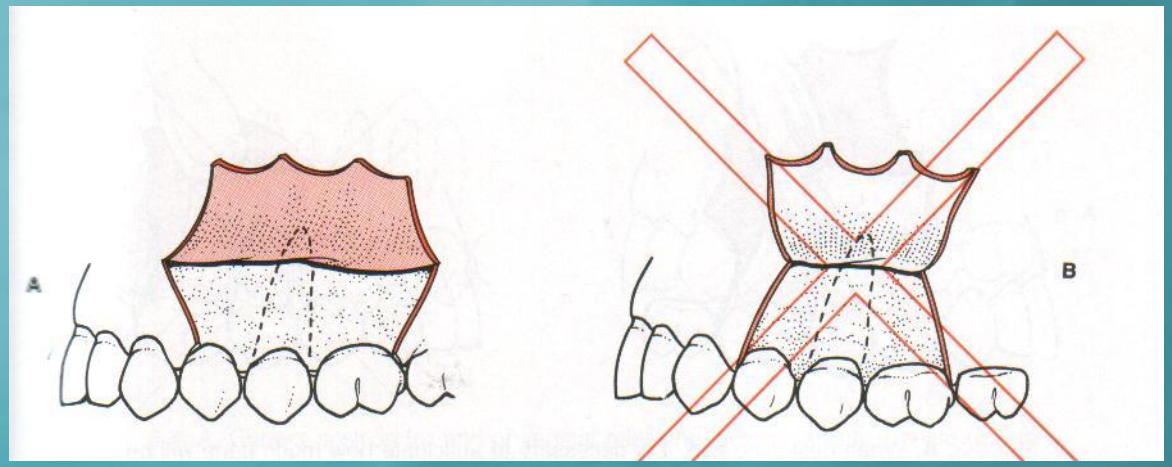

FLAPS - REQUIREMENTS

6. Tension free closure

FLAPS - REQUIREMENTS

7. Closure of the flap on the intact bony surface.

Types of the intraoral flaps

1. Marginal / gingival flap

Mesio-distally performed incision on the gingiva of the edentulous alveolar crest

2. Envelop flap

Advantage: no vertical incision, easy to reposition

Disadvantage: tension during the surgery

limited approach

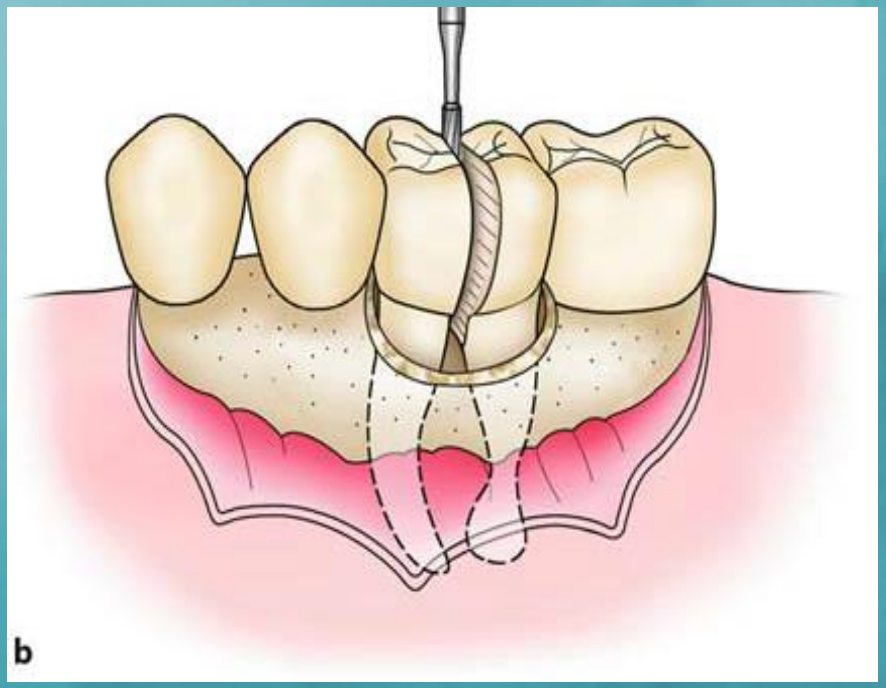

- Incision in the gingival sulcus
- Snip trough the papillas

3. Envelop flap on the palatal side

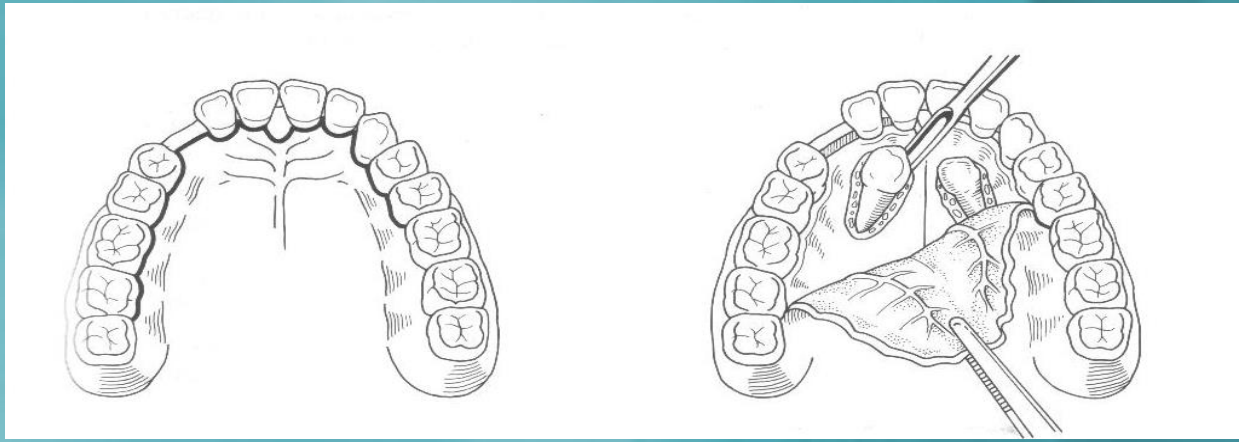

– Incision in the gingival sulcus

Advantage: easy to reposition

good approach

Disadvantage: difficult to prepare

SZABÓ GY: *Szájsebészet, maxillofacialis sebészet. Semmelweis Kiadó, Budapest,* 2004; 33-47, 49-58, 59-68, 69-84.
VÁMOS I, BERÉNYI B, INOVAY J: *Szájsebészet. Medicina Könyvkiadó, Budapest,* 1980; 120-122, 134-135, 156-157.

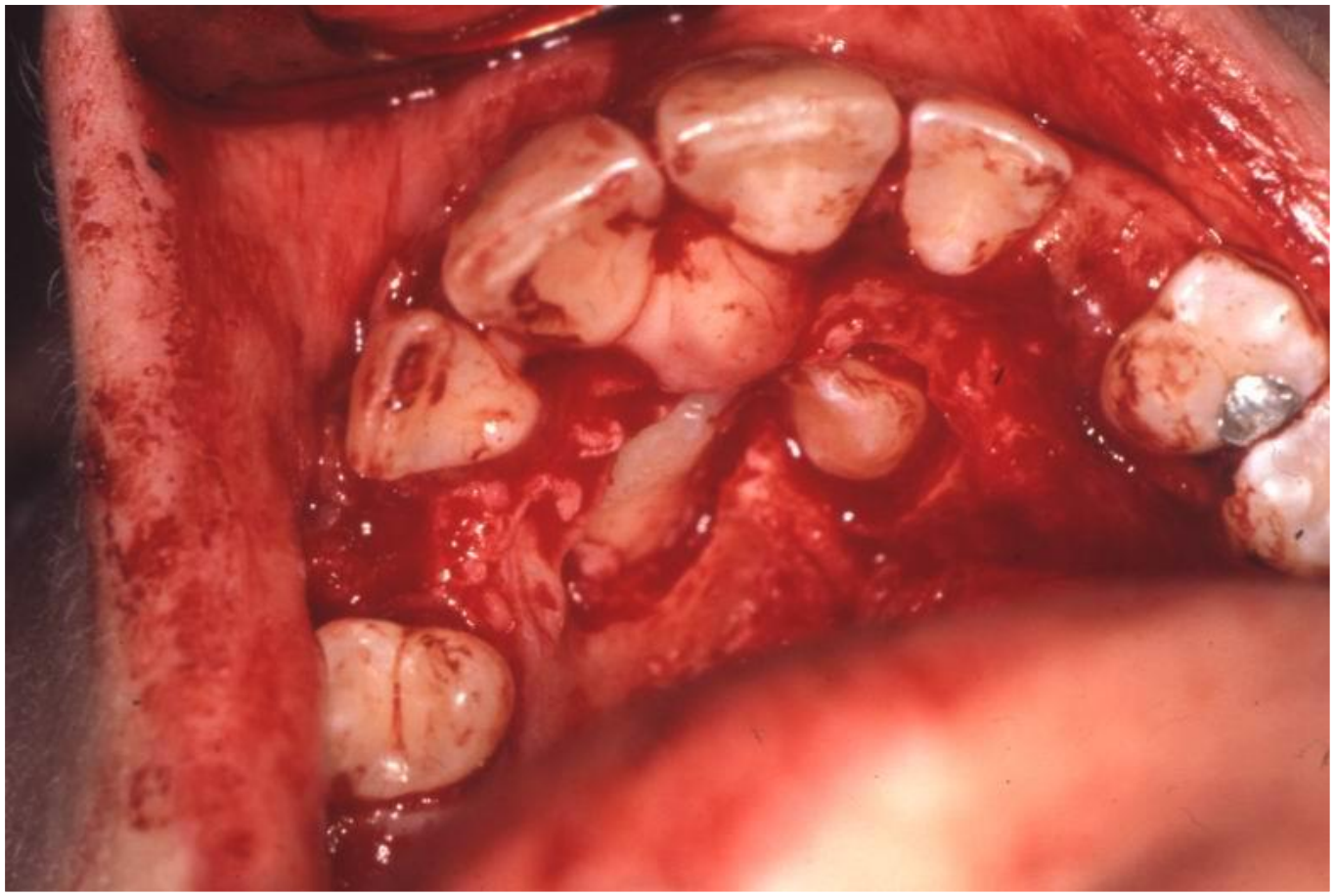

CASE by Dr. Attila Szűcs

4. L-shape incision, triangular flap on vestibular side

- Incision in the gingival sulcus + vertical incision
- The vertical incisions should be placed at relation **2/3 – 1/3** the crown of the neighbouring teeth

Application:

- Surgical tooth removal
- Apicoectomy
- Antral cystostomy
- Cystectomy
- Bone augmentation

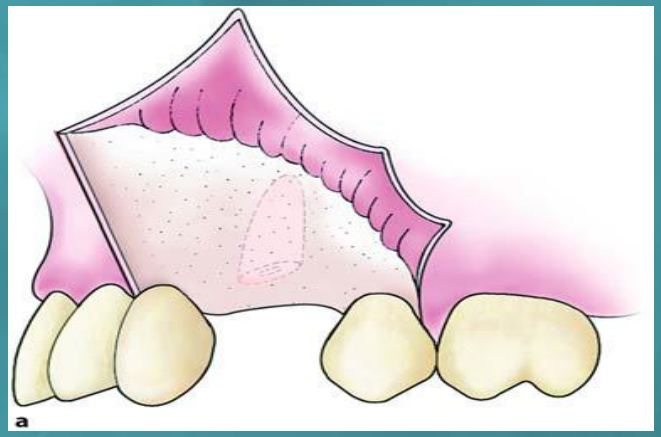

Advantage: good approach, easy to perform

Disadvantage: tension during the surgery

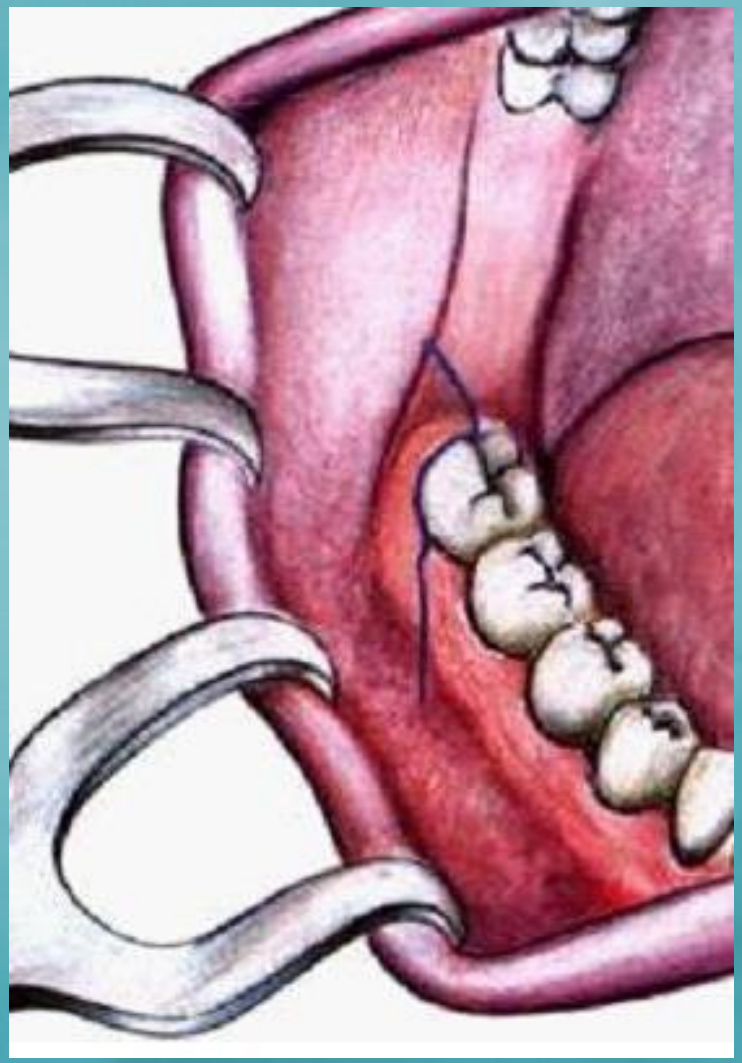

CASE by Dr. Fanni Sára Kálmán

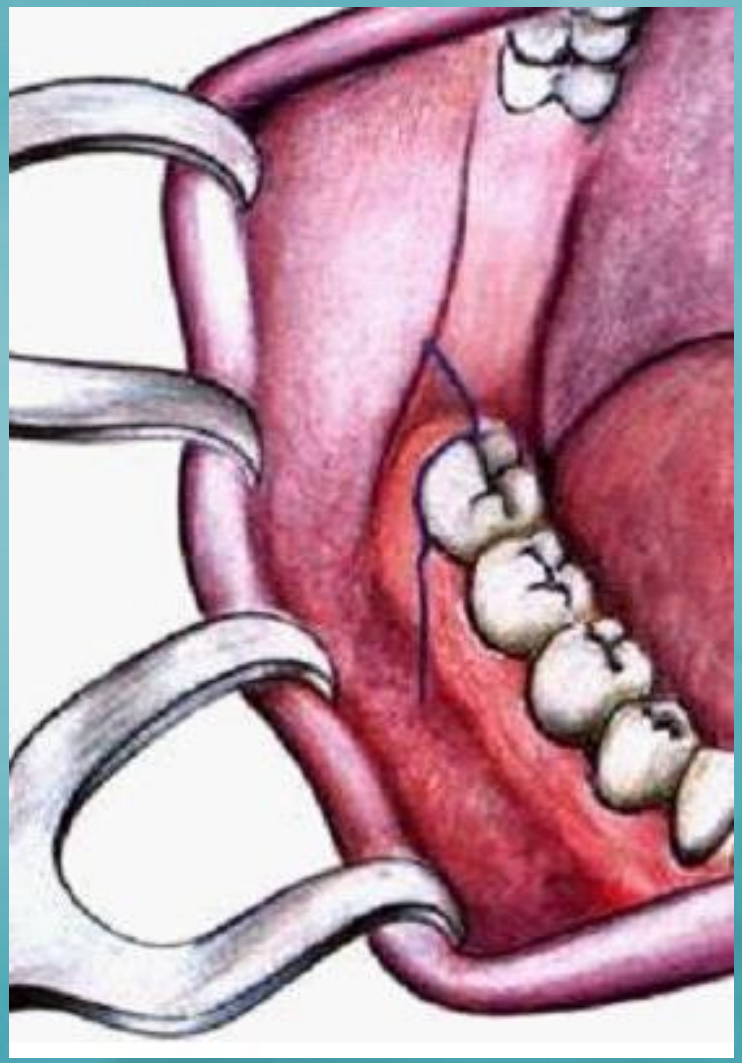

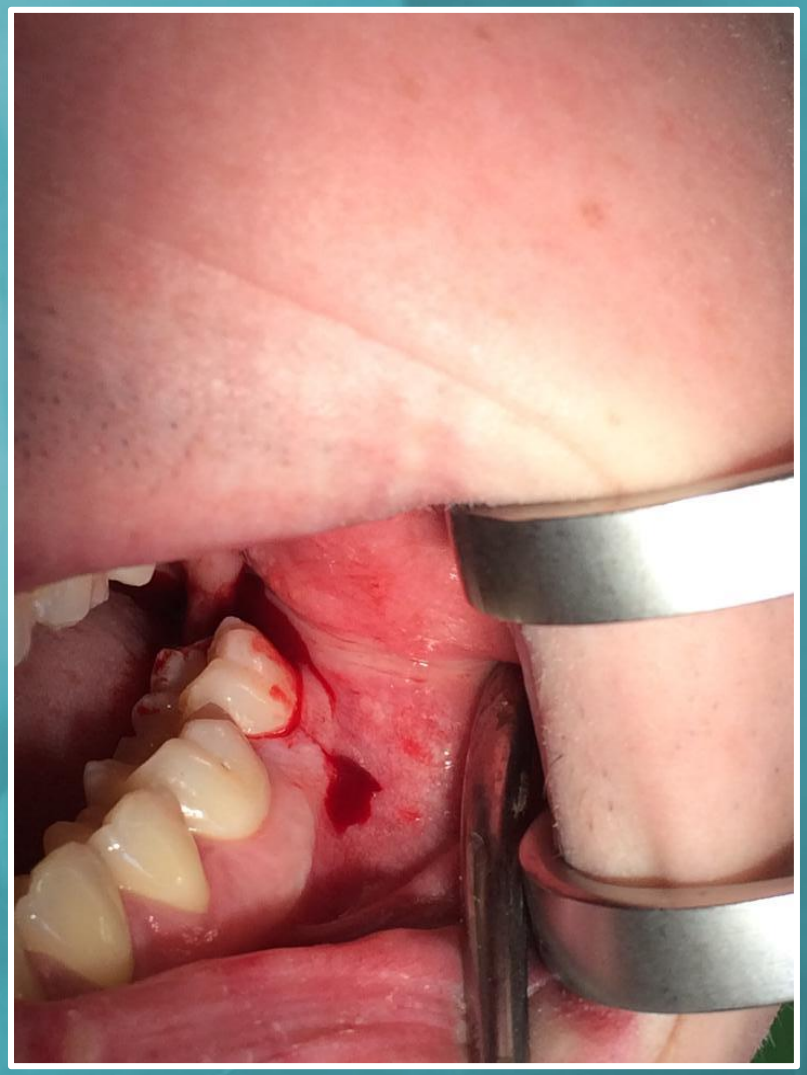

CASE by Dr. Fanni Sára Kálmán

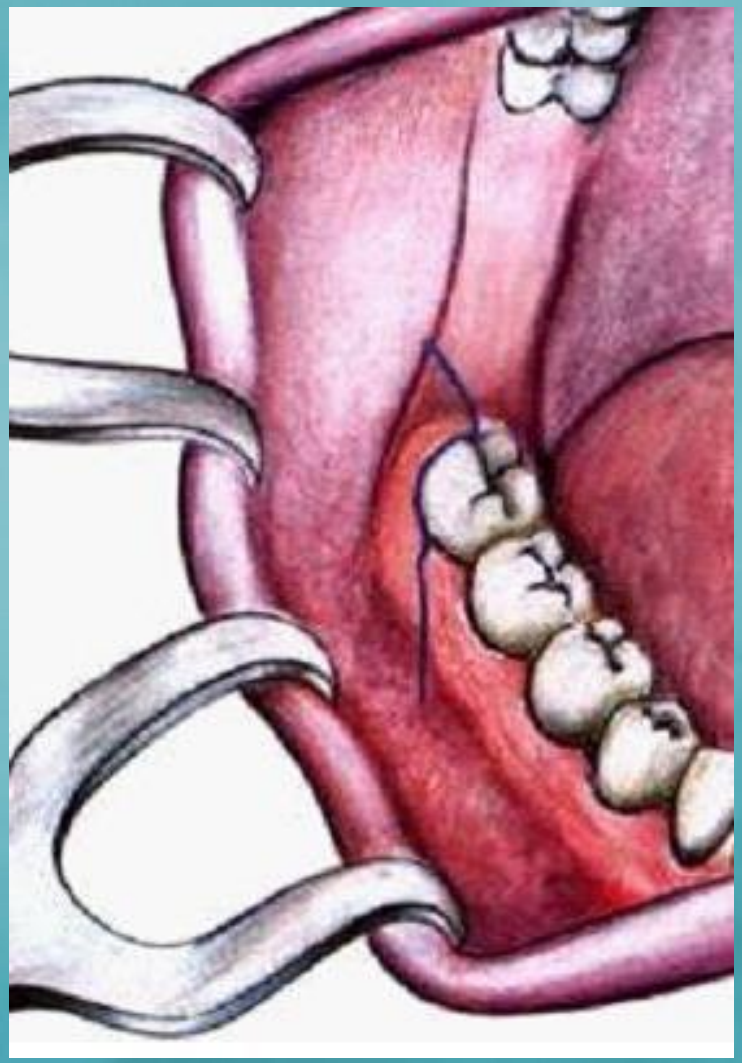

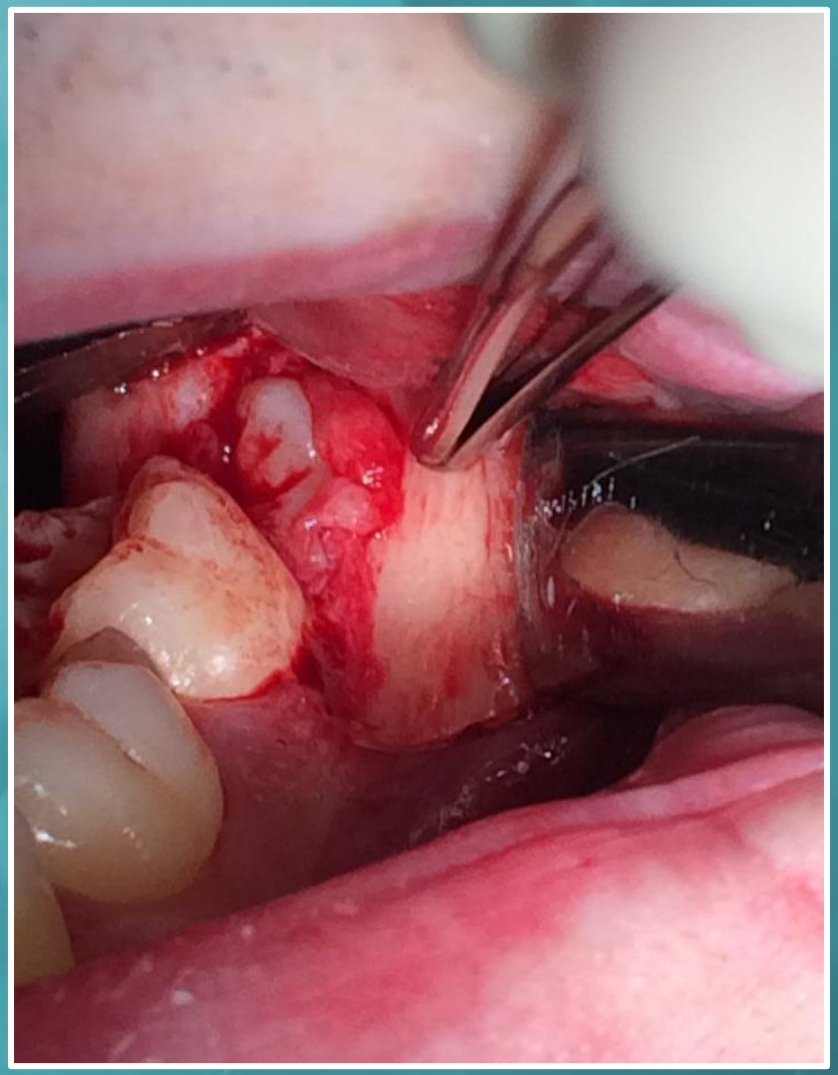

CASE by Dr. Fanni Sára Kálmán

5. L-shape incision, triangular flap on palatal side

– Incision in the gingival sulcus + vertical incision

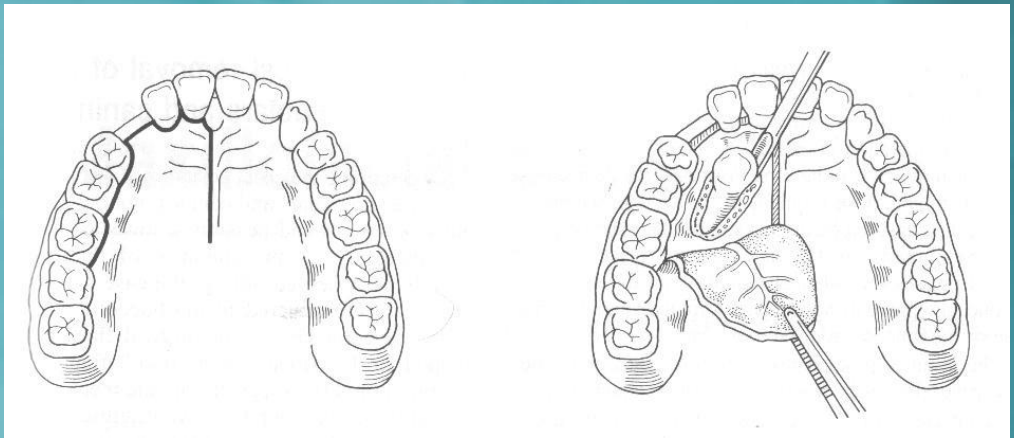

Application: in case of retained canine

Advantage: good approach

Disadvantage: difficullt to prepare

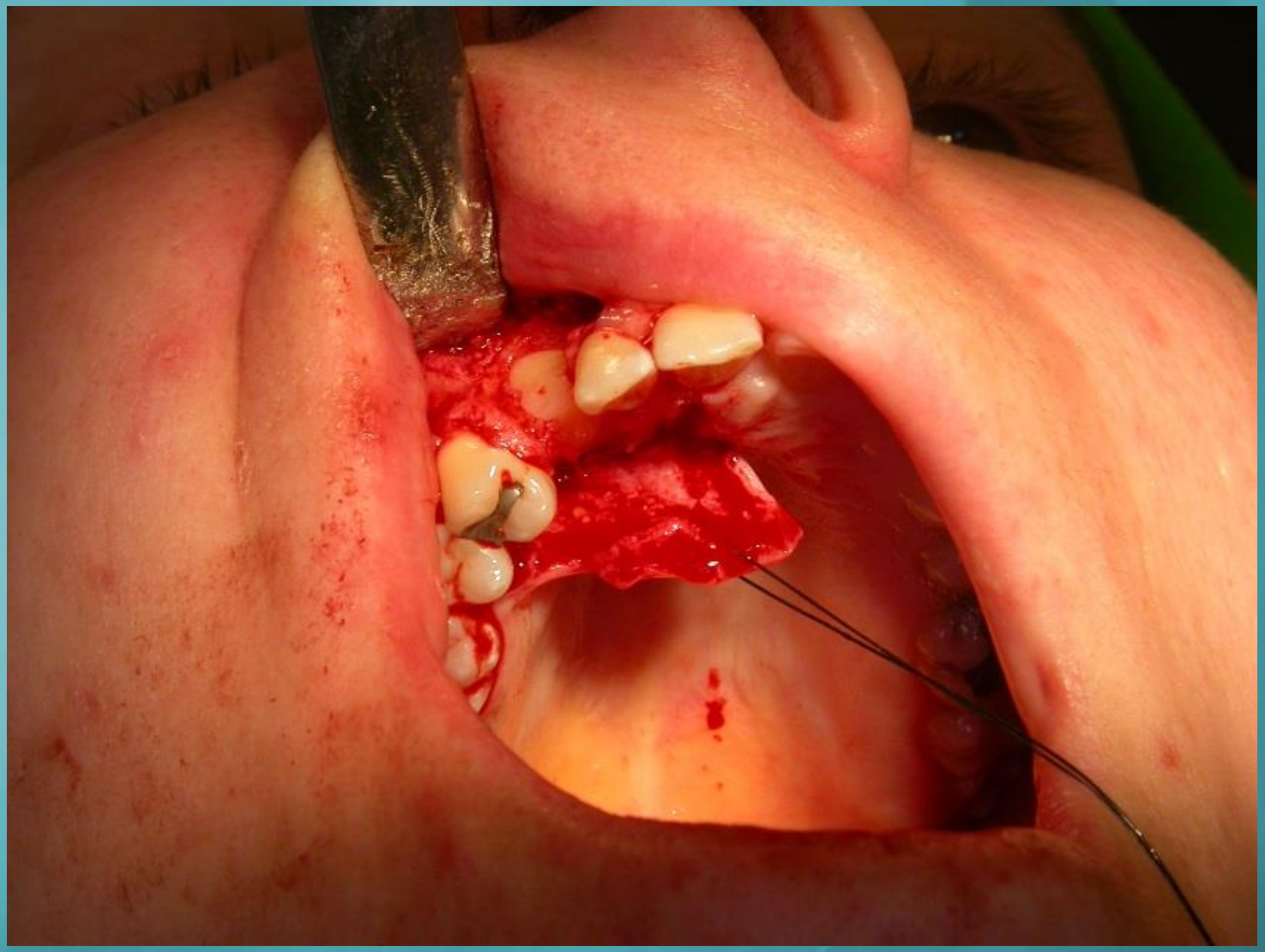

CASE by Dr. Attila Szűcs

6. Wassmund- flap (trapezoidal flap, four cornered)

– Incision in the gingival sulcus (horizontal) + 2 vertical incisions

- Divergating (in direction of the vestibular fornix) vertical incisions
- The vertical incisions should be placed at relation **2/3 – 1/3** the crown of the neighbouring teeth

Advantage: better approach

Disadvantage: gingival recession, narrowing of the vestibule

Application

- Apicoectomy
- Antral cystostomy
- Sinus closure

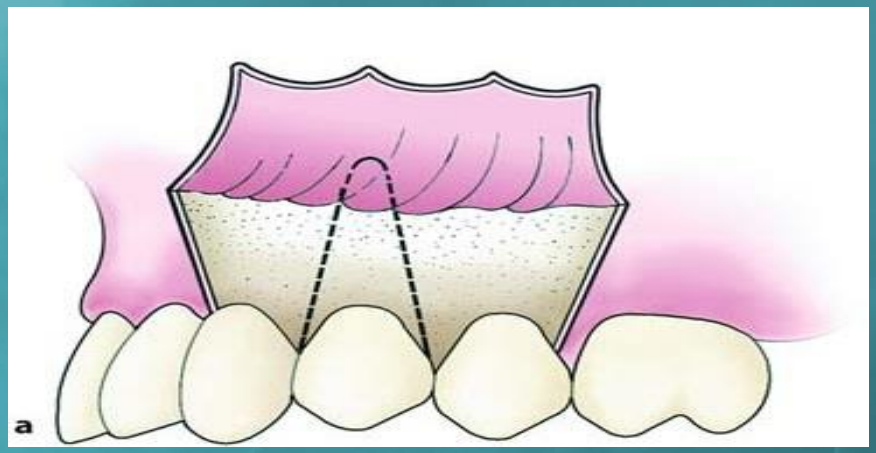

SZABÓ GY: *Szájsebészet, maxillofacialis sebészet. Semmelweis Kiadó, Budapest,* 2004; 33-47, 49-58, 59-68, 69-84.
VÁMOS I, BERÉNYI B, INOVAY J: *Szájsebészet. Medicina Könyvkiadó, Budapest,* 1980; 120-122, 134-135, 156-157.
GOPIKRISHNA, KANDASWAMY D, NANDINI S: Newer Classification of Endodontic Flaps. *Endodontology 2005; 17:14-19.*

CASE by Dr. Attila Szűcs

CASE by Dr. Attila Szűcs

CASE by Dr. Attila Szűcs

CASE by Dr. Attila Szűcs

7. Wassmund- Rehrmann flap

- enlarging the mesial vertical incision

∗ Avoid to have sharp corners on the flap !

- Application:
  - Sinus closure, radix in antro (corpus alienum)

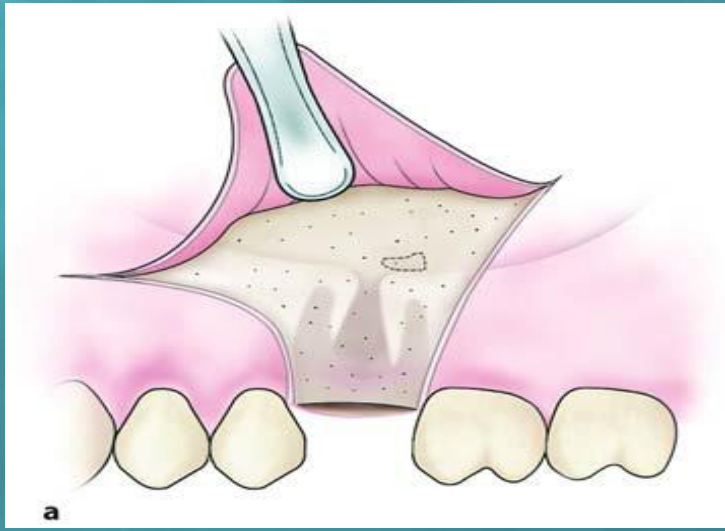

Advantage: good approach

Disadvantage: narrowing of the vestibule

SZABÓ J: Ambuláns szájsebészet. Medicina Könyvkiadó, Budapest, 1975; 275-284.
VÁMOS I, BERÉNYI B, INOVAY J: *Szájsebészet. Medicina Könyvkiadó, Budapest,* 1980; 120-122, 134-135, 156-157.

8. Reinmöller (submarginal) flap

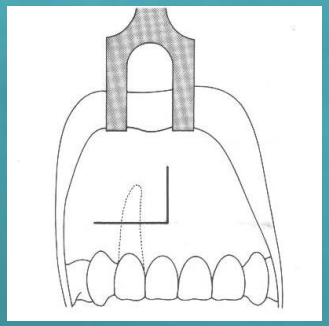

- **L**-shape
- vertical incision parallel with **frenulum**
- horisontal incison min. 4-5 mm from the **marginal gingiva** (parallel with it)

Application : apicoectomy, cystectomy

Advantage: - enlargebility in distal direction
- no gingiva recession

Disadvantage: - poor flap design = not adequate blood supply

Blunt edges are suggested!

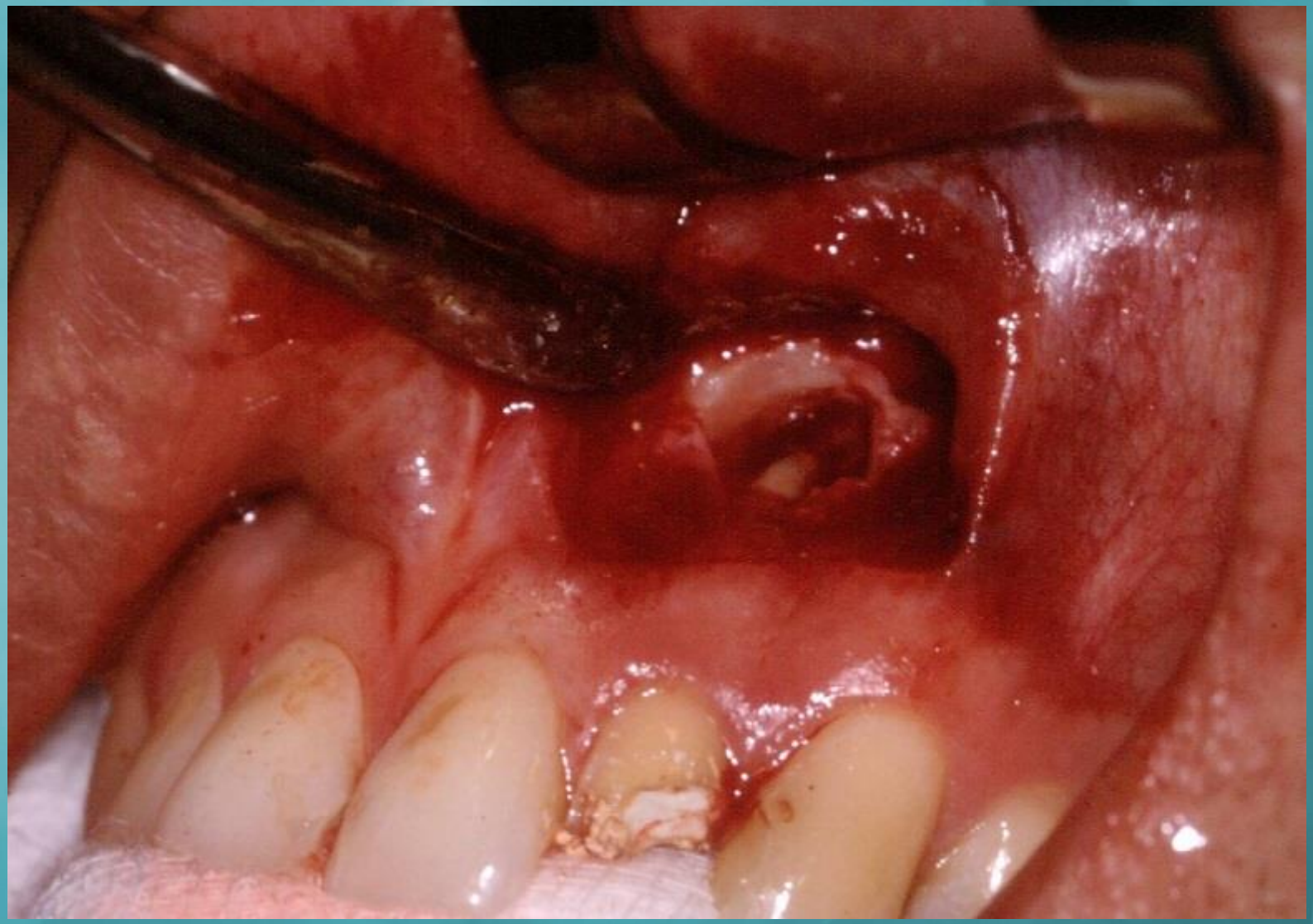

CASE by Dr. Attila Szűcs

9. Partsch flap

- **CONVEX in the direction of the gingival margin**
- **Semilunar**

} horizontal incision

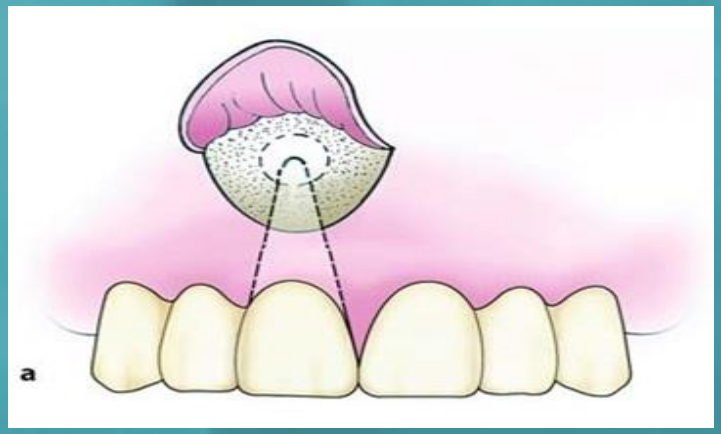

- Lower flap margin sholud be **4-5 mms** from the marginal gingiva

Application:
apicoectomy,
cystostomy and cystectomy

Advantage: enlargeable
easy to perform,
no gingival recession

Disadvantage: visible scar
limited approach

SZABÓ GY: *Szájsebészet, maxillofacialis sebészet. Semmelweis Kiadó, Budapest,* 2004; 33-47, 49-58, 59-68, 69-84.
VÁMOS I, BERÉNYI B, INOVAY J: *Szájsebészet. Medicina Könyvkiadó, Budapest,* 1980; 120-122, 134-135, 156-157.
GOPIKRISHNA, KANDASWAMY D, NANDINI S: Newer Classification of Endodontic Flaps. *Endodontology 2005; 17:14-19.*
CHINDIA ML, VALDERHAUG J: Periodontal status following trapezoidal and semilunar flaps in apicectomy. *East Afr Med J 1995; 72:564-567.*

CASE by Dr. Attila Szűcs

10. Pichler flap

INVERSE PARTSCH

11. Ochsenbein-Luebke (submarginal) flap

- Base sholud be **4-5 mms** from the marginal gingiva
- Follows the **contour of the gingiva**

Application : in esthetic zone
in case of fix prosthesises

Advantage: the gingival margin is not involved
no gingiva recession
safe closure

Disadvantage: visible scar tissue
corners on the flap can necrotize

AHMED MV, RASTOGI S, BAAD RK, GUPTA AK, NISHAD SG, BANSAL M ÉS MTSAI: Comparative Study Between Two Flaps-Trapezoidal flap (TZF) and Ocshenbein- Leubke Flap (OLF) in Periapical Surgeries. *J Maxillofac Oral Surg 2013; 12:440-* 446.
MUSHTAQ I, MALIK A. Evaluation of the Ochsenbein-Luebke flap technique in periapical surgery at Punjab Dental Hospital Lahore Pakistan. *J Ayub Med Coll Abbottabad 2003;15:50-53.*

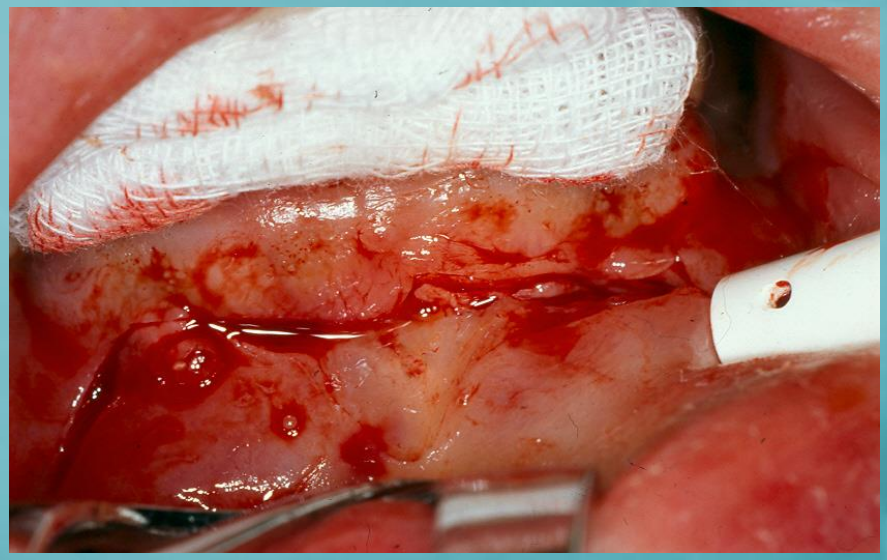

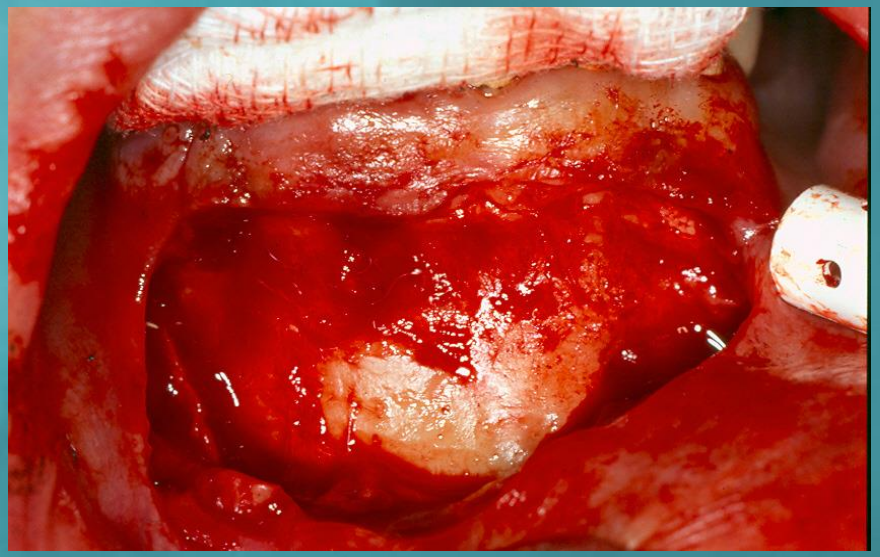

Dr. Attila Szűcs

12. Palatal Pichler flap

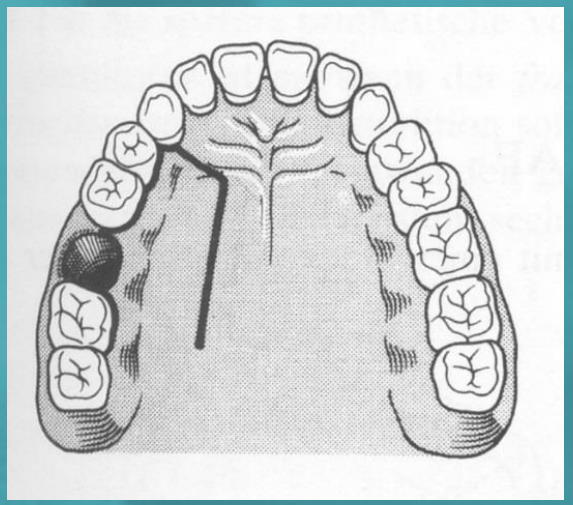

- Contains the palatal art.
- Angle it in 45 º

per secundam healing on the palate

Advantage: Good blood supply

Disadvantage: Rigid

Painful healing

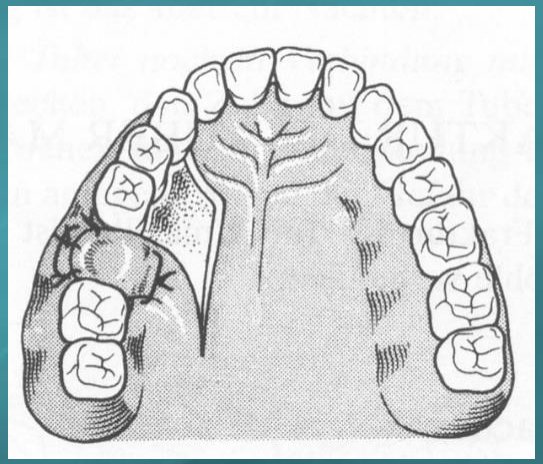

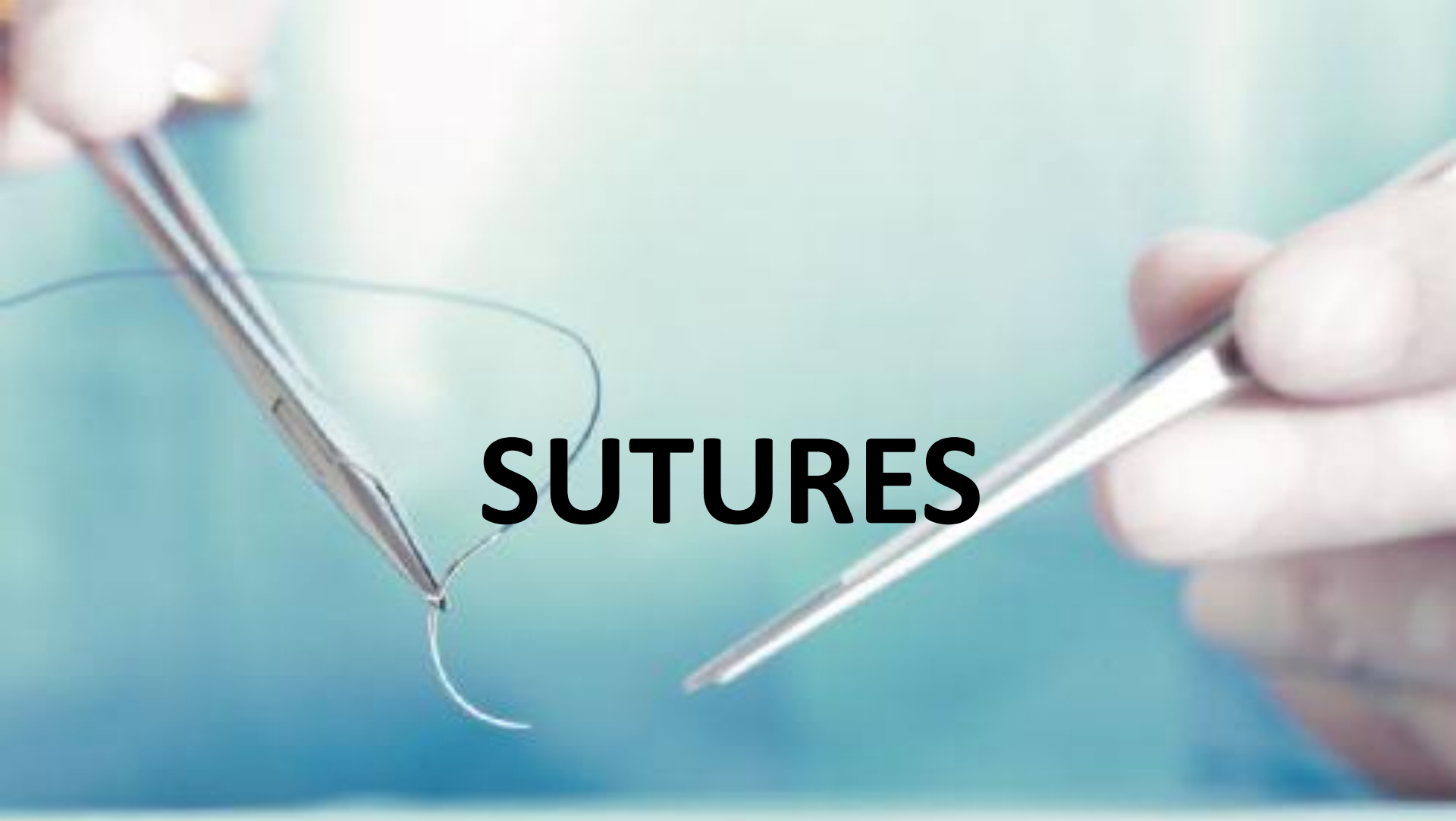

SUTURES

Principles of suturing

- Use suture needle of suitable shape and size
- Use suture material that is of suitable type and size for the tissue being sutured
- Good bite (2-3 mm from the free edge of the soft tissue)
- Sutures should **NOT** be placed under tension
- Knots should be tied **2-3 mm** away from the incision line
- Suture material is cut **4-5 mm** away from the knot
- Superficial sutures should be removed **5-7 days** after (exception: sinus closure) surgery to prevent infection / foreign body reaction

Advantages of suturing (closure)

- Promotes healing
- Prevents complications
  - INFECTION
  - HAEMORRHAGE
  - TISSUE NECROSIS
- Preserve the normal contur and shape of tissues

Suture **material / needle**

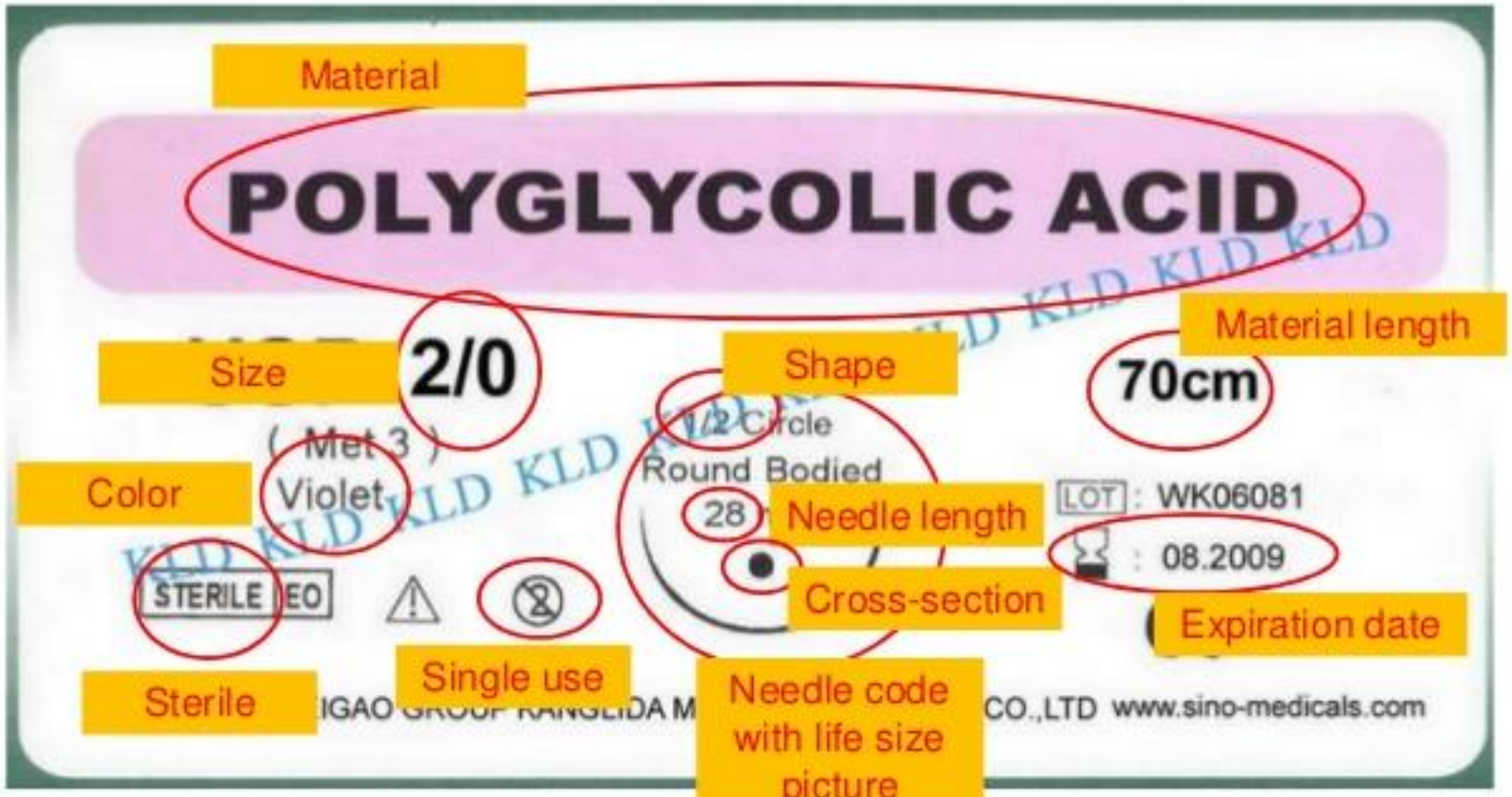

Grasping the needle

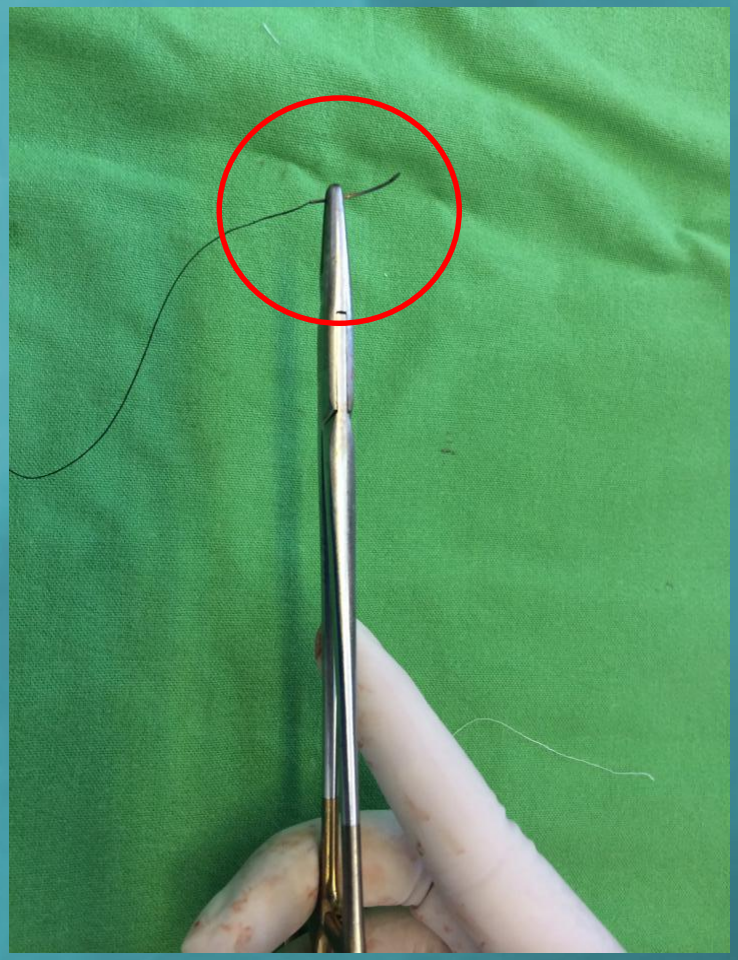

HOW TO MAKE A **KNOT**?

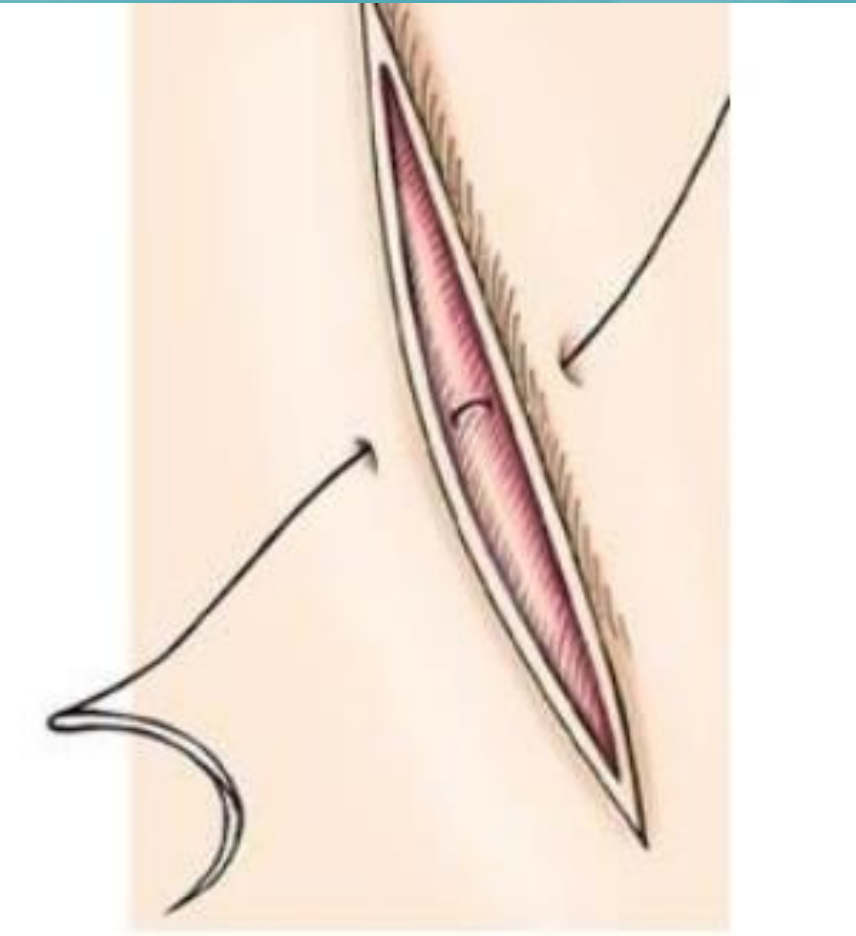

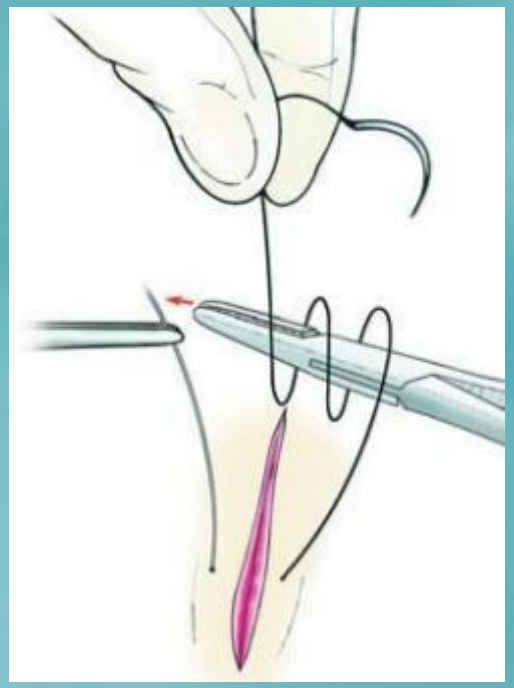

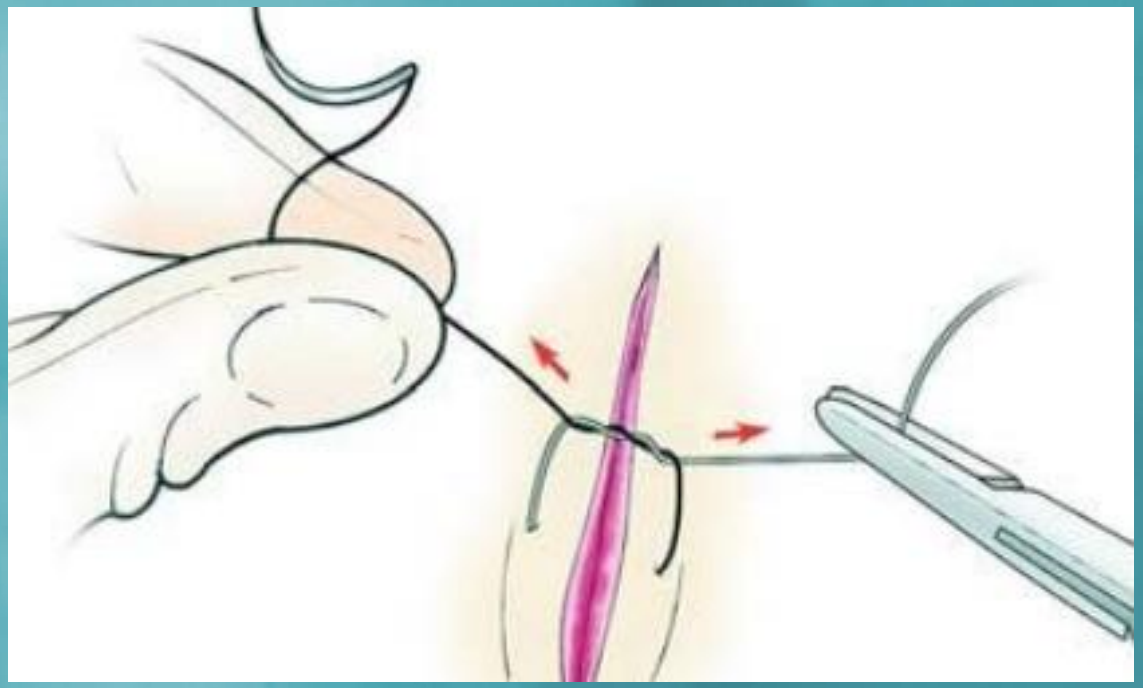

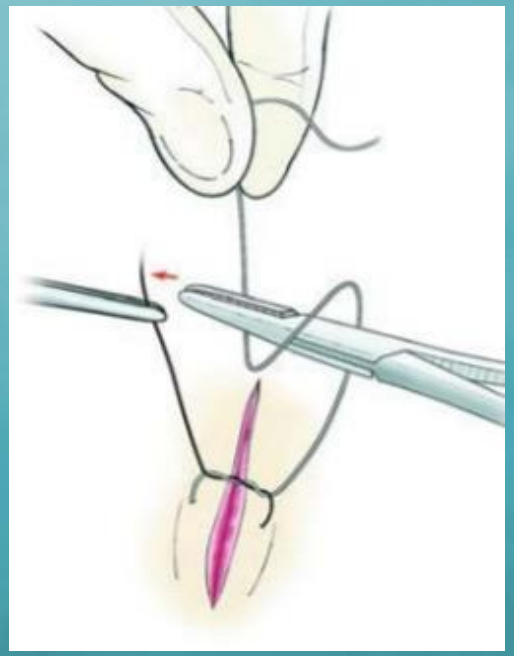

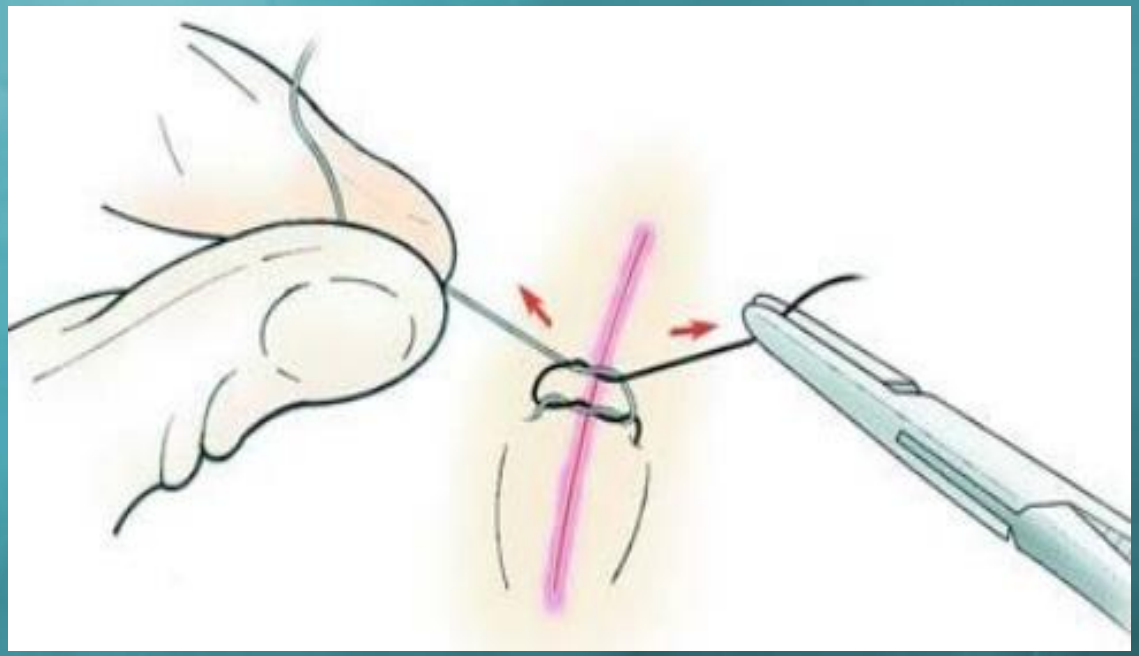

SUTURING TECHNIQUES

SINGLE INTERRUPTED SUTURE

CONTINUOUS INTERLOCKING SUTURES

HORIZONTAL MATRESS SUTURE

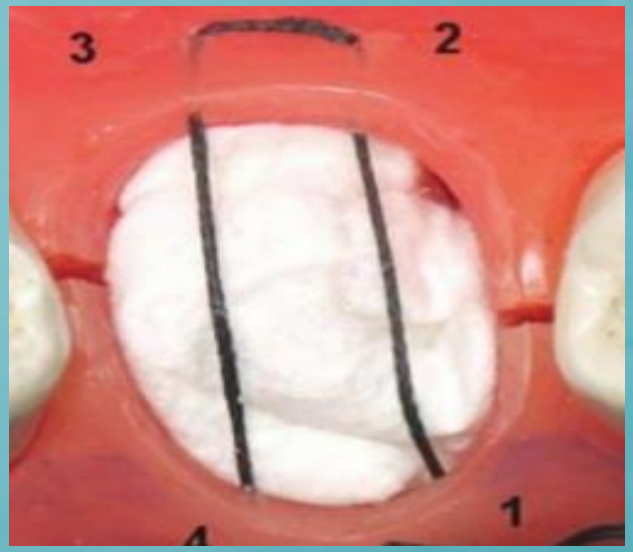

VERTICAL MATRESS SUTURE (Donáti)