Local anaesthesia III.
The technique of local anaesthesia. Generally used techniques for terminal (infiltrative) and block anaesthesia.

Semmelweis University
Faculty of Dentistry

Types of local anaesthesia

1. Terminal anaesthesia
   a) Mucosal anaesthesia
   b) Submucosal infiltration
   c) Subperiosteal infiltration
   d) Intraligamental anesthesia

2. Block anaesthesia

3. Ganglion anaesthesia

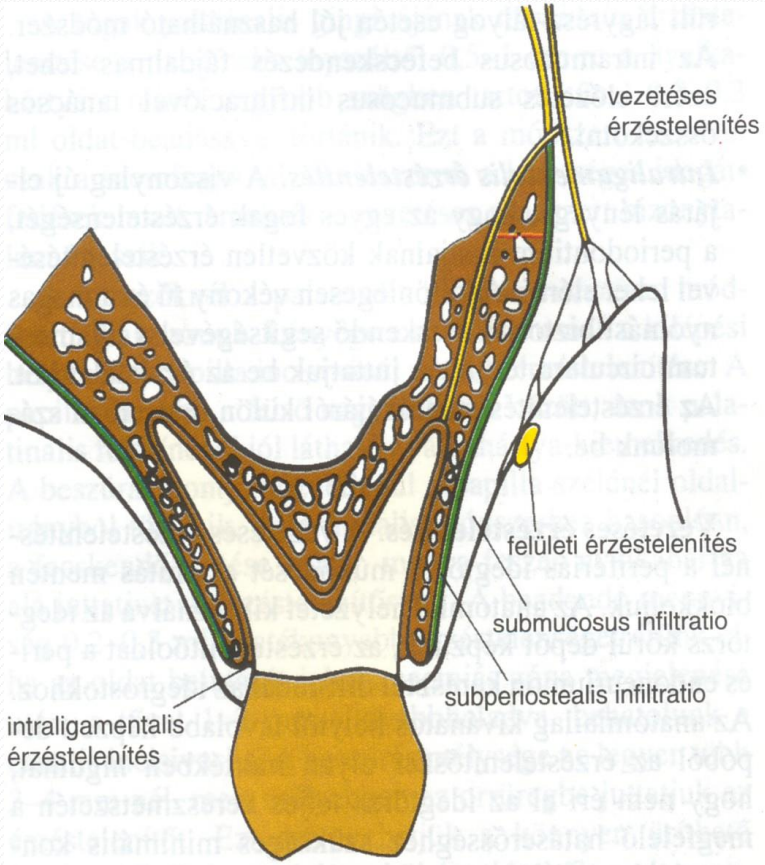

Spatial parameters of the local anaesthesia

- Insertion point

  (horizontal and perpendicular coordinate)

- Direction of the needle insertion

  (defined by plane and an angle in this plane)

- Depth of the insertion

- Volume of the injected solution

Sensory innervation of the upper front teeth nn. alveolares superiores anteriores

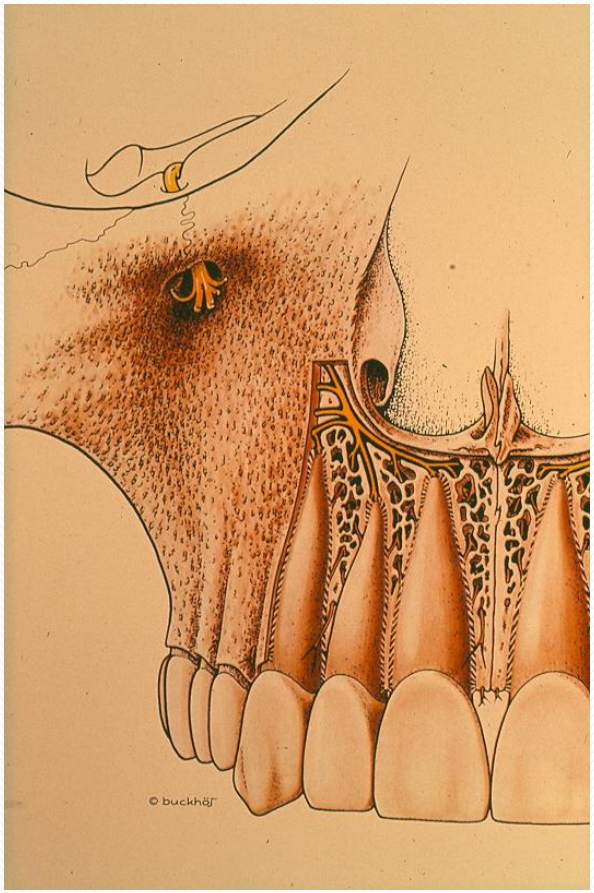

Infiltration anaethesia of upper first incisor teeth

- Insertion point: **from distal direction, in the axis of the 2. incisor tooth, border of the fixed and mobile mucosa**
- Direction: the needle is at 45 degree angle with the axis of the second incisor tooth
- Depth: 5-8 mm

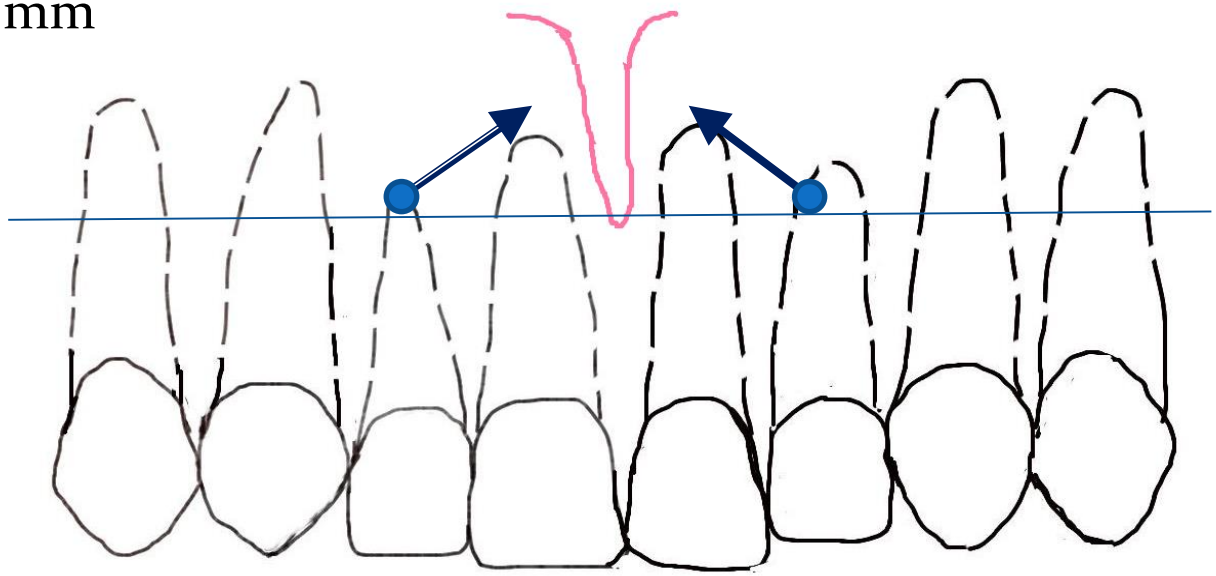

Local anaesthesia of first incisor tooth

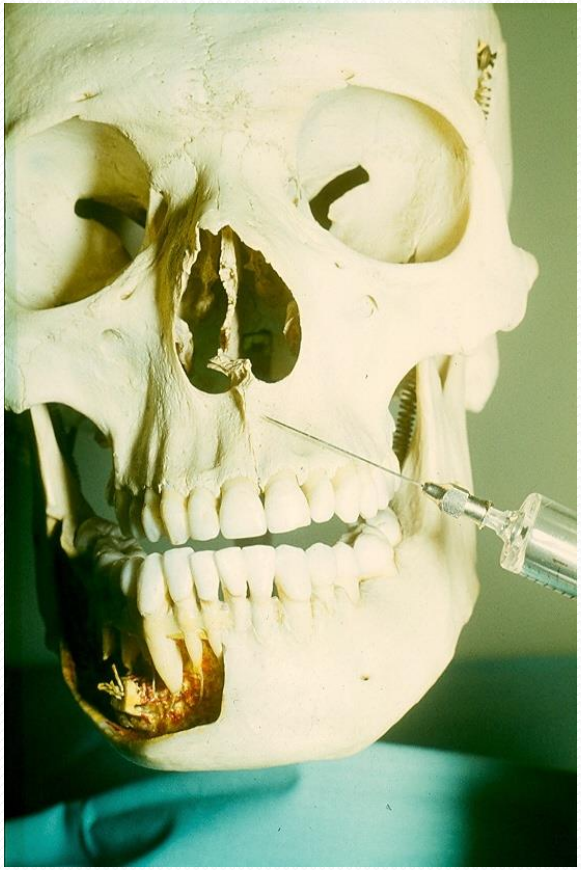

Infiltration anaethesia of the upper second incisor teeth

- Insertion point: from distal direction, axis of the canine, border of the fixed and mobile mucosa
- Direction: the needle is at 45 degree angle with the axis of the canine tooth
- Depth: 5-8 mm

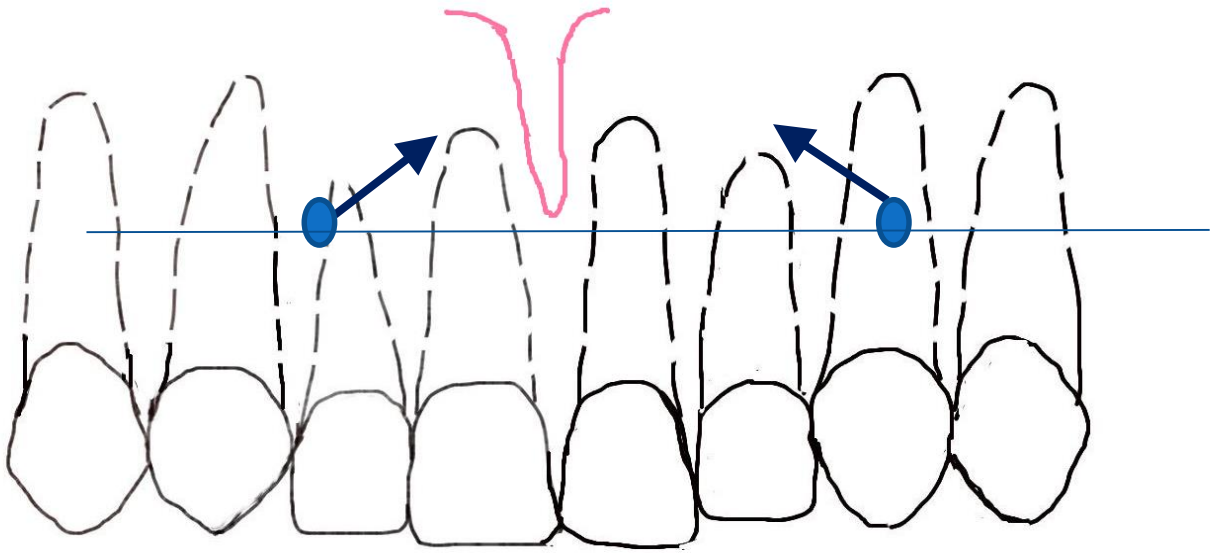

Infiltration anaethesia of the upper canine tooth

- Insertion point: axis of the canine tooth, border of the fixed and mobile mucosa
- Direction: axis of the canine tooth
- Depth: 10-12 mm

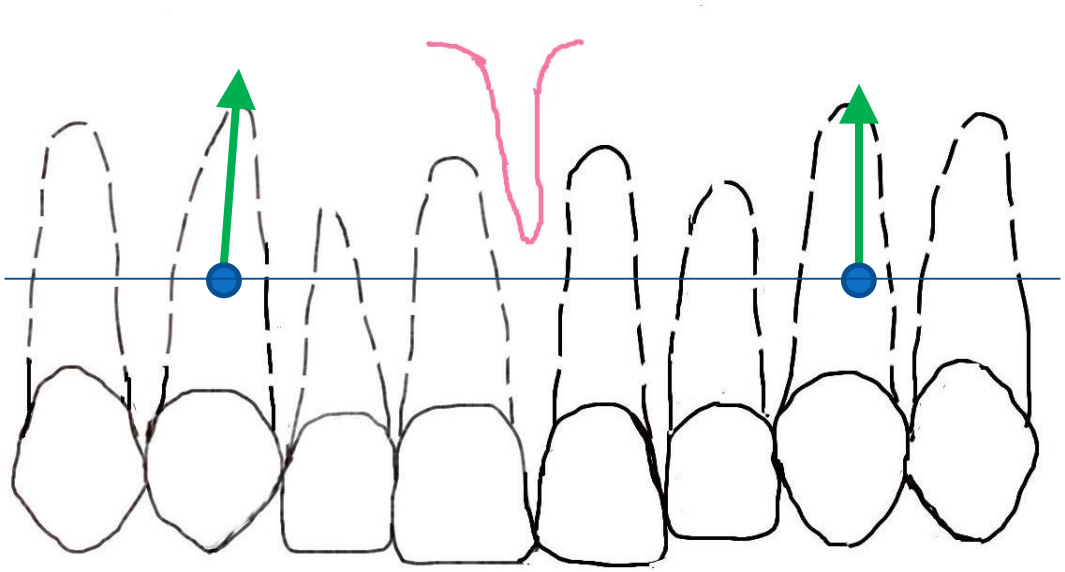

Sensory innervation of the upper premolar and molar teeth

nn. alveolares superiores medii et posteriores

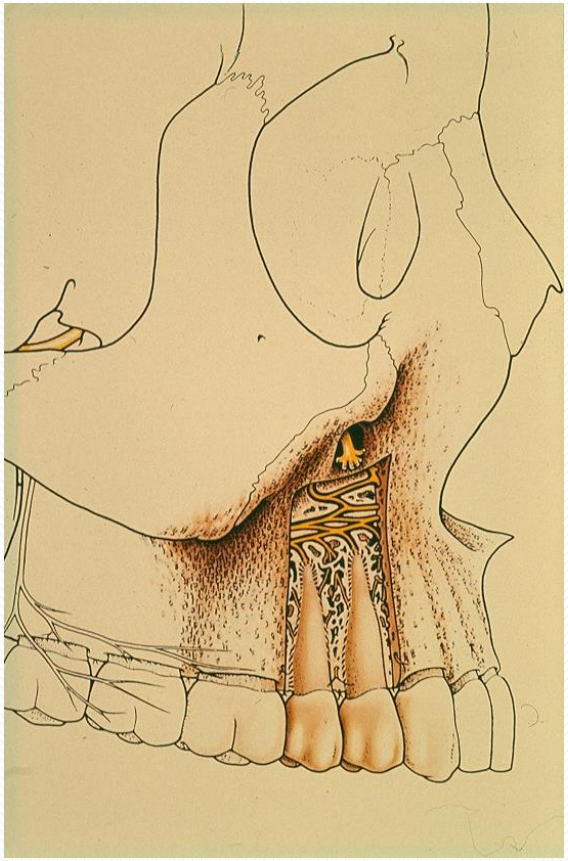

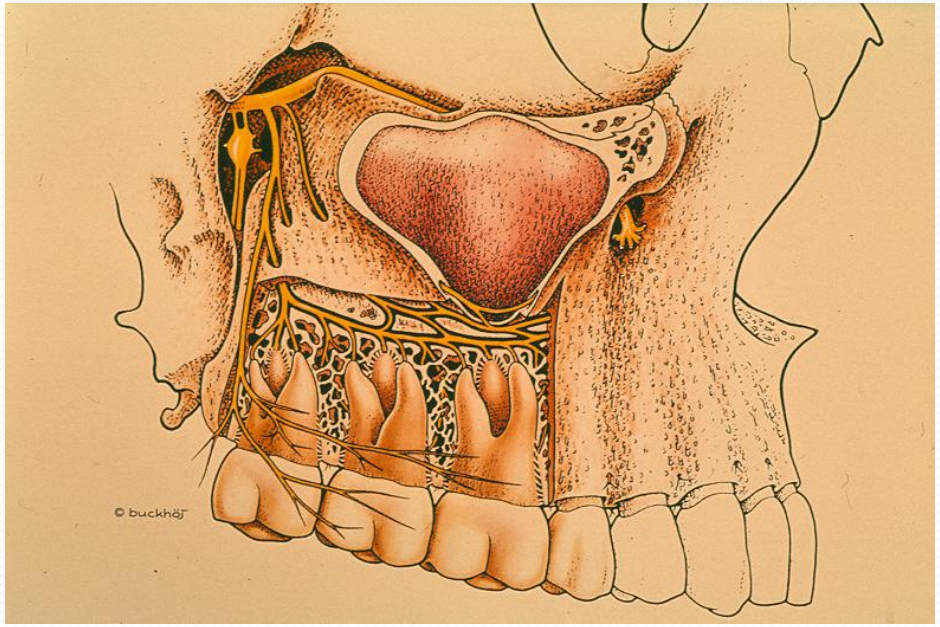

Infiltration anaethesia of the upper premolar and molar teeth

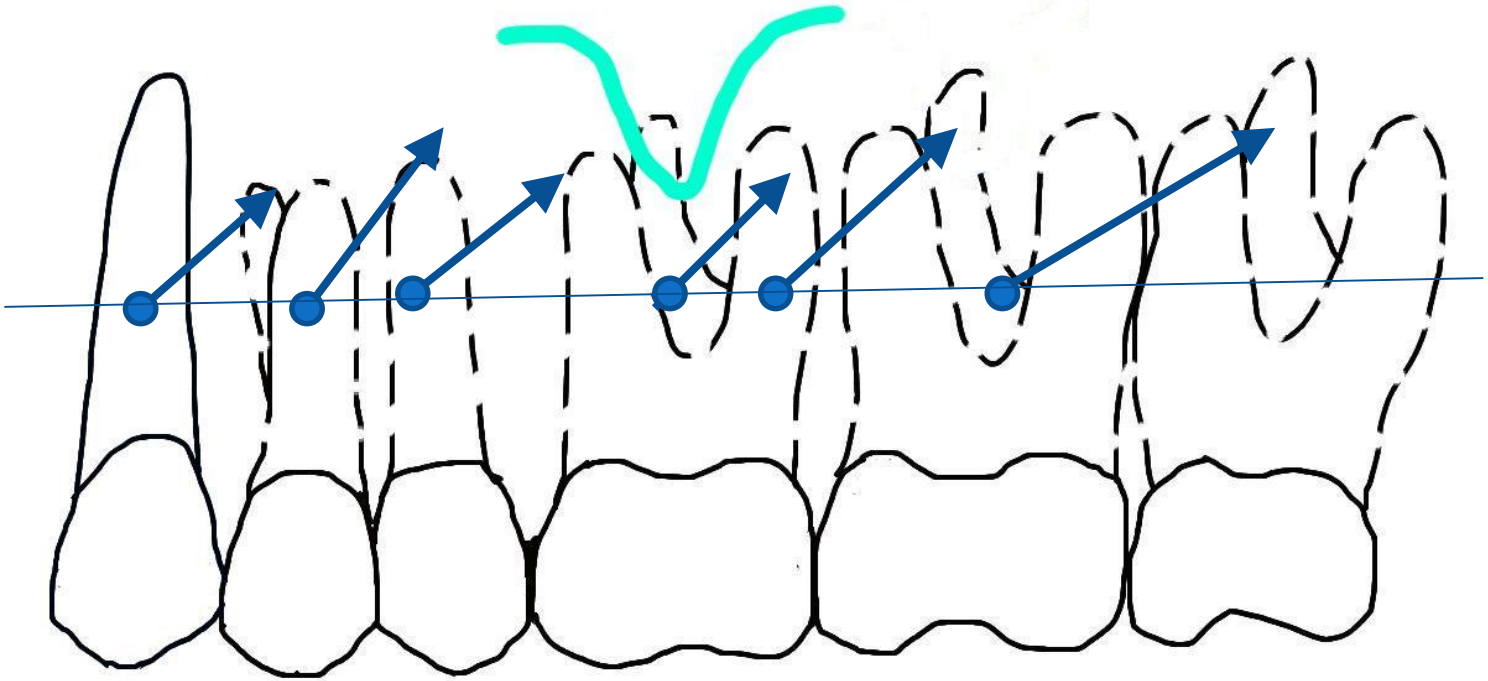

Infiltration anaesthesia of the upper first molar

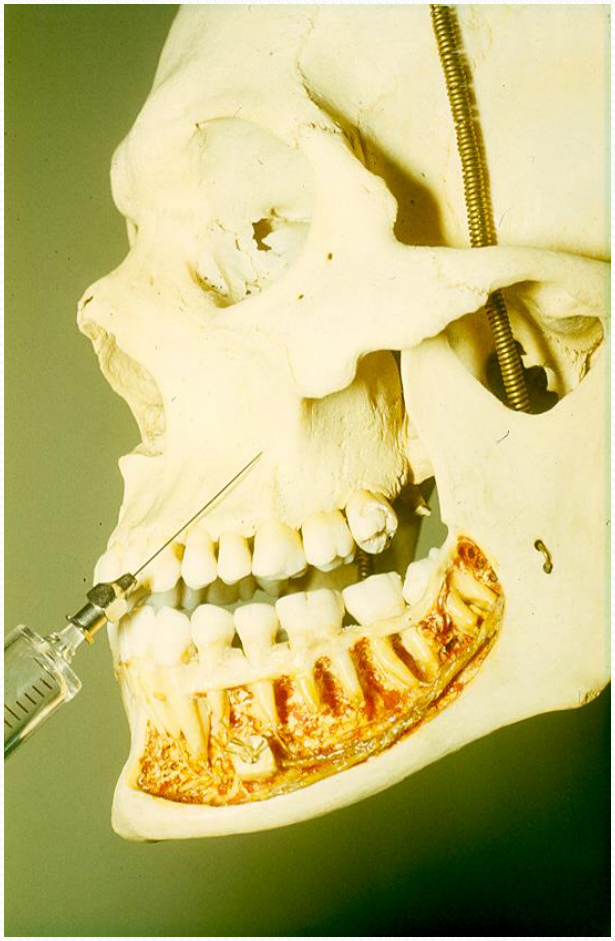

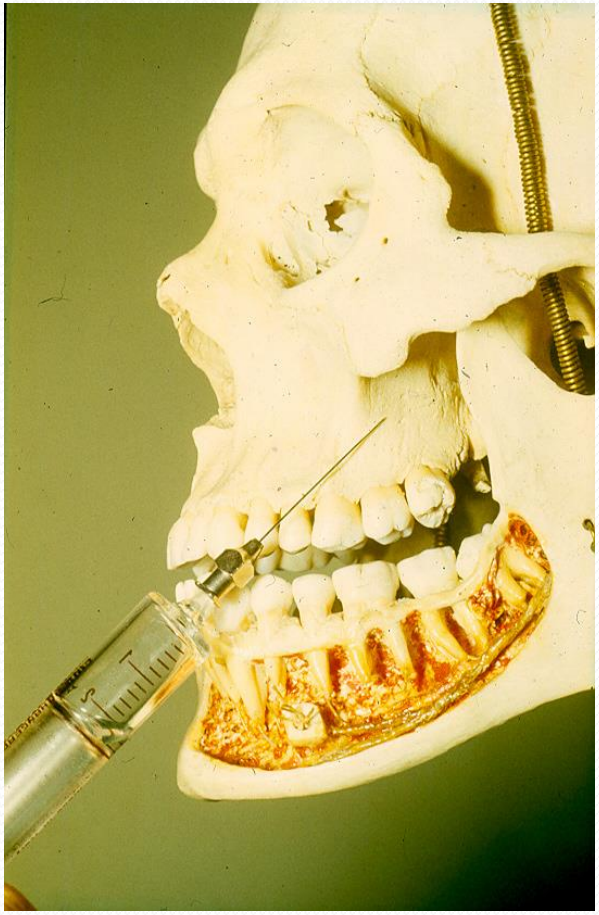

Block anaesthesia of the upper jaw

- n. incisivus
- n. palatinus major

Anaesthesia performed on the palatal side

- Maxillary N. (MATAS)
- n. infraobitalis
- Tuberal nerve block (n.alveloris sup. post.)

Innervation of the hard palate

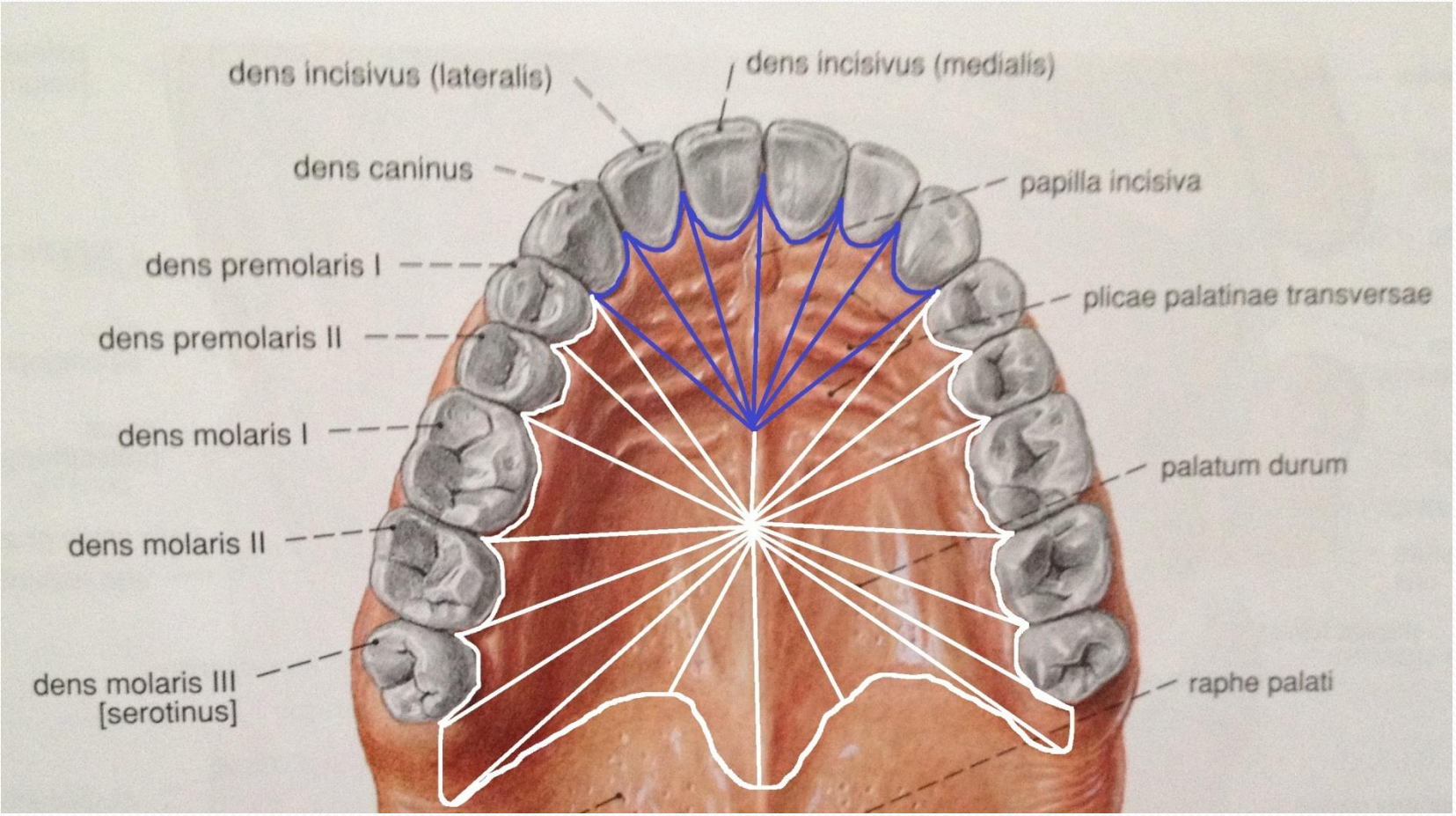

Anaesthesia of the incisive nerve

- Very sensitive area
- Insertion point: incisive papilla
- direction: the needle is at 20-30° angle with the mucosa of the palate
- depth: 2-3 mm
- Volume of the solution:

  max 0,2 ml

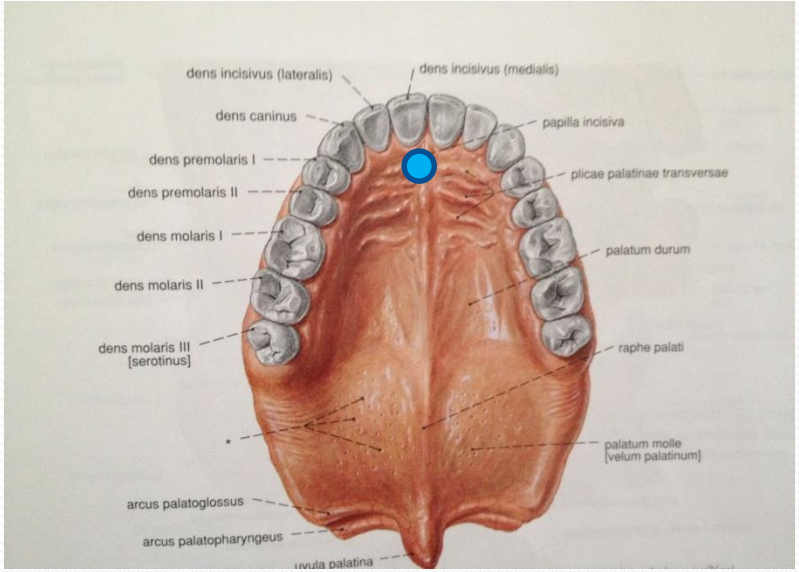

Anaesthesia of the incisive nerve

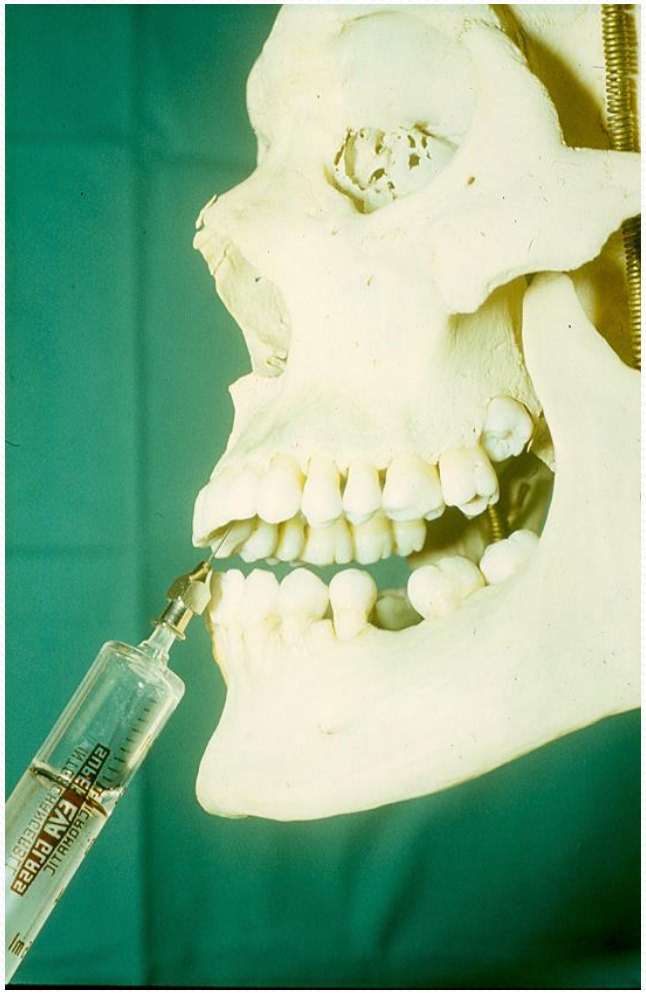

Anaesthesia of the major palatinal nerve

- Insertion point: imaginary line connecting the distopalatinal cusps of the second molars and on this line 1 cm from gumline towards the midline
- direction: insert the needle from the opposite side mouth corner
- Volume of the solution:

  0,2 mm

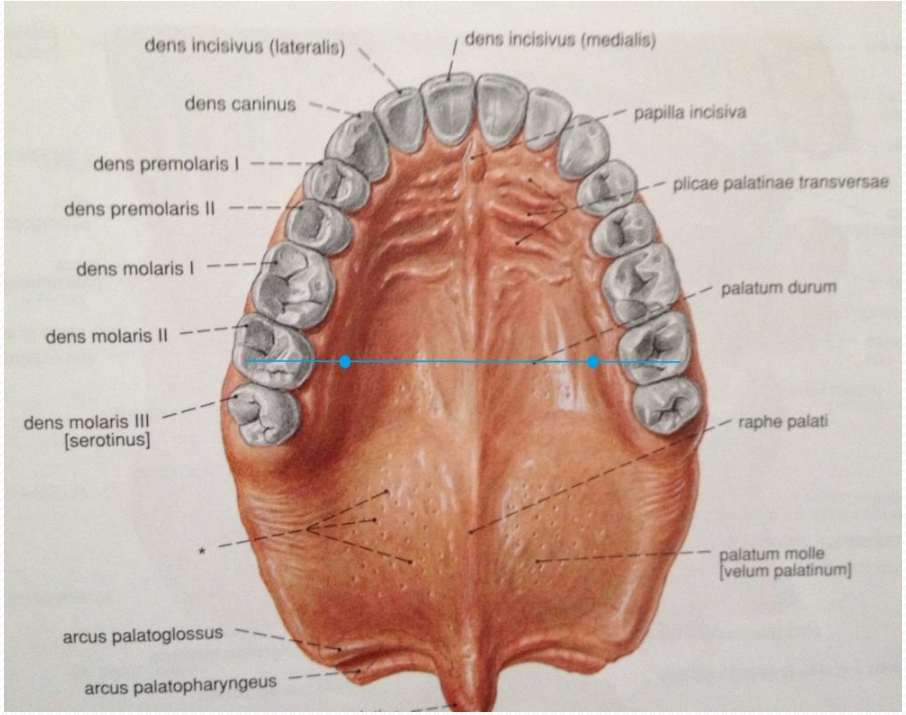

Anaesthesia of the major palatinal nerve

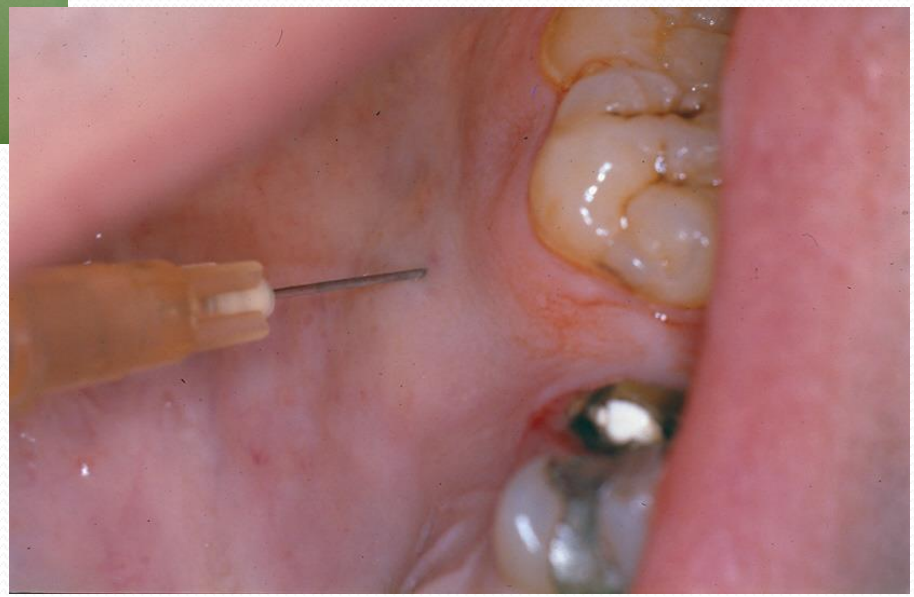

Anaesthesia of the maxillary nerve trunk

MATAS

- First step is the same as the anaesthesia of the greather palatine nerve
- Then needle is bent 45 degrees
- 42 mm long needle
- approx. 30 mm deep
- in case of the operations involving the sinus maxillaris

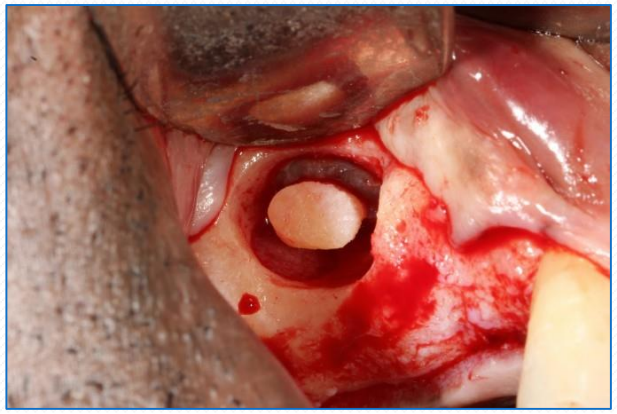

Anaesthesia of the infraorbital nerve

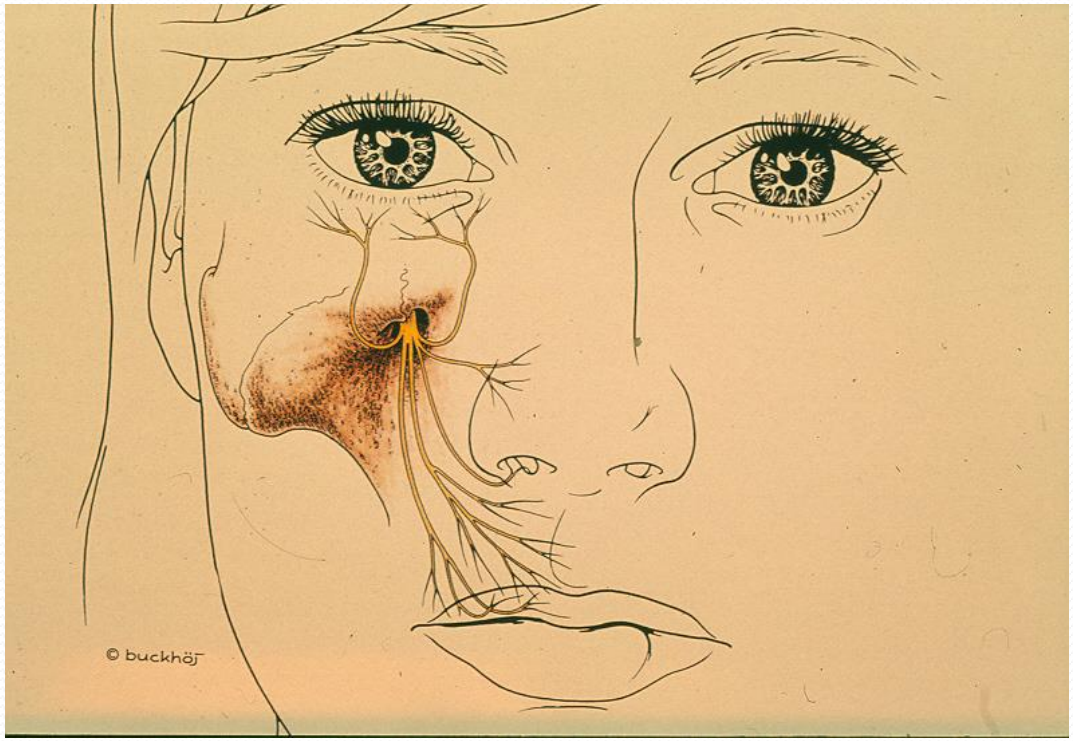

How can you find the infraorbital foramen?

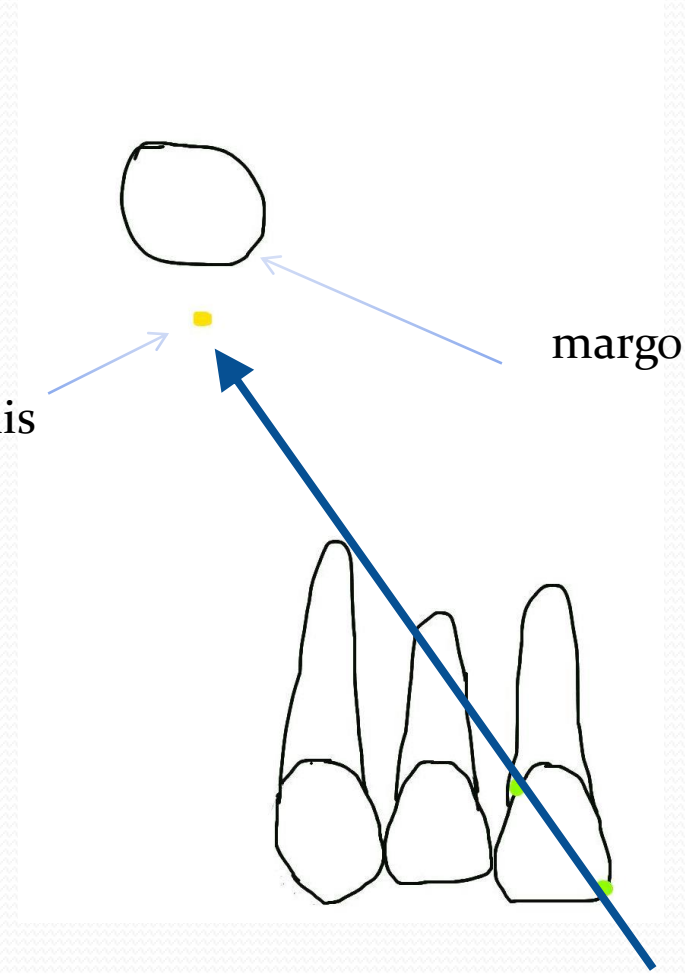

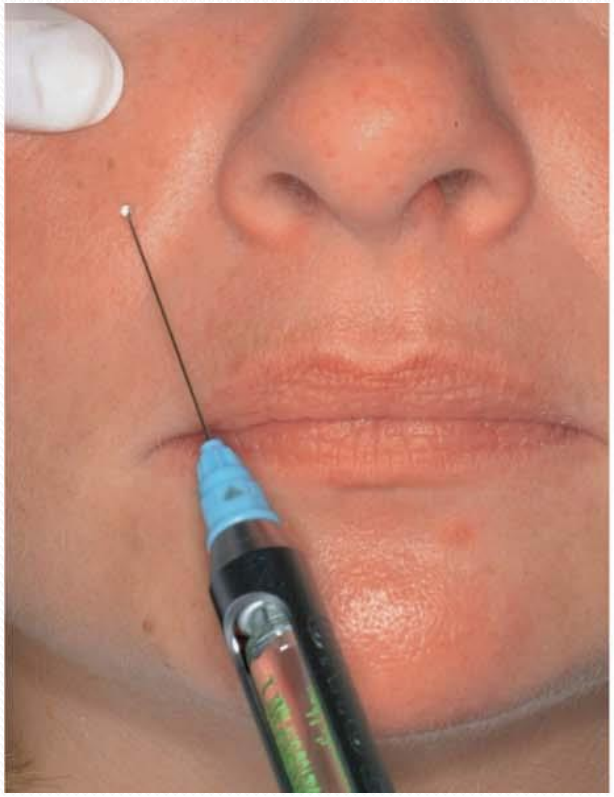

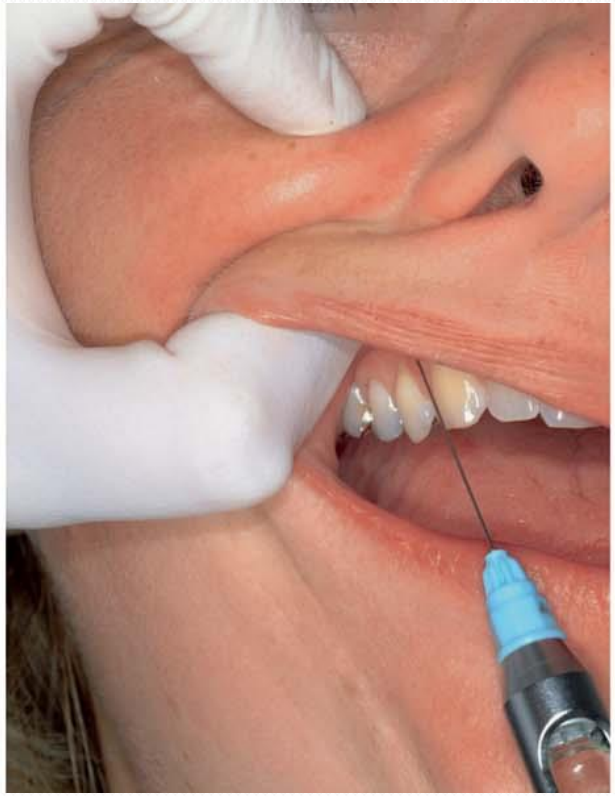

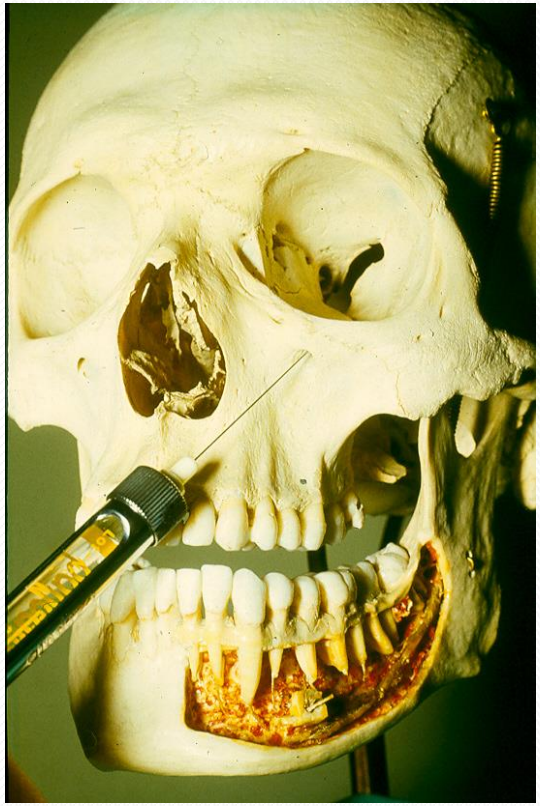

Sensory innervation of the upper molar teeth
nn. alveolares superiores posteriores

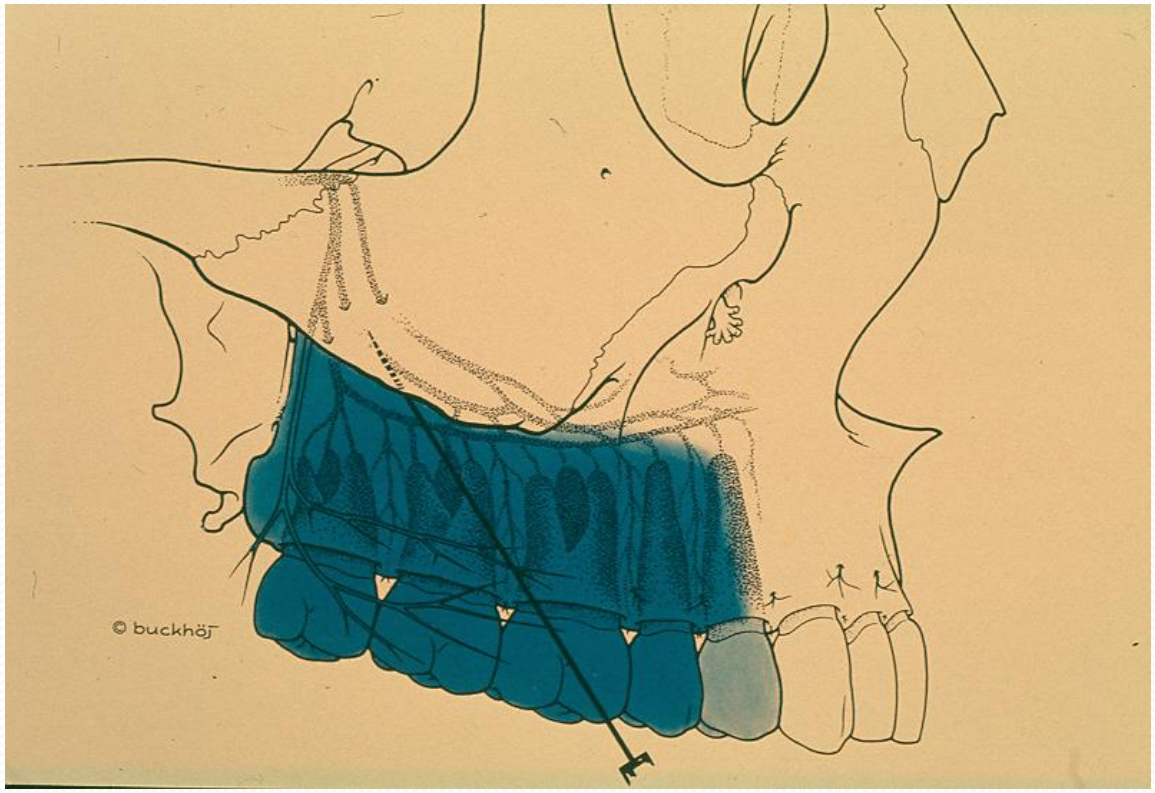

Tuberal nerve block anaesthesia

- Insertion point: in the axis of the distobuccal root of the upper 2. molar, the border of the fixed and mobile mucosa
- direction: parallel with the nasal ridge in the parasaggital plane
- depht: 10-18 mm

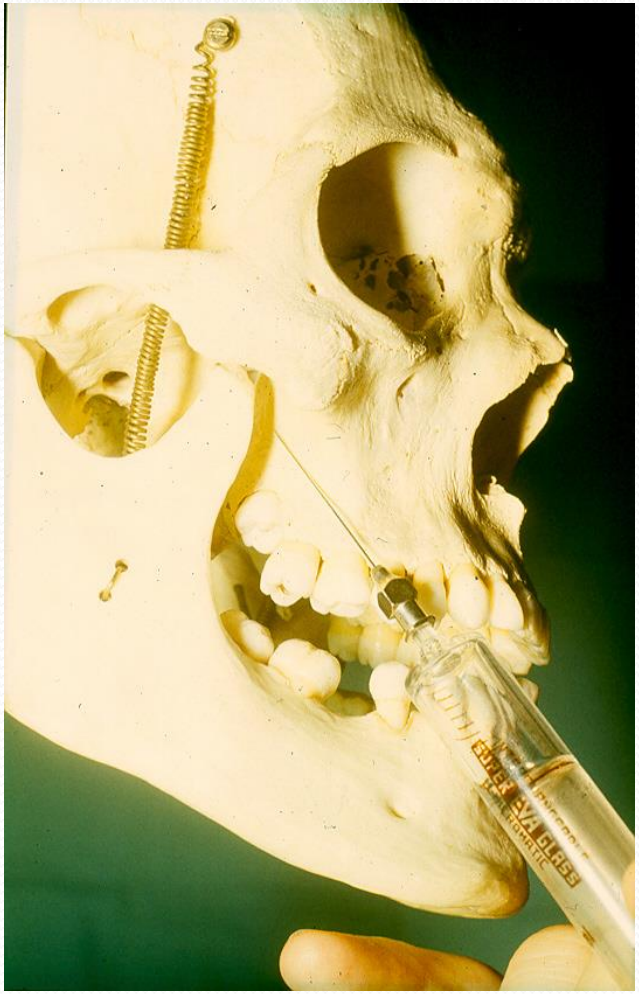
SUPER EVA GLASS

Block anaesthesia on the lower jaw

- n. alveolaris inferios = „Szokolóczy manoeuvre”
- n. mentalis
- n. lingualis
- n. buccalis

N. alveolaris inferior

N. alveolaris inferior

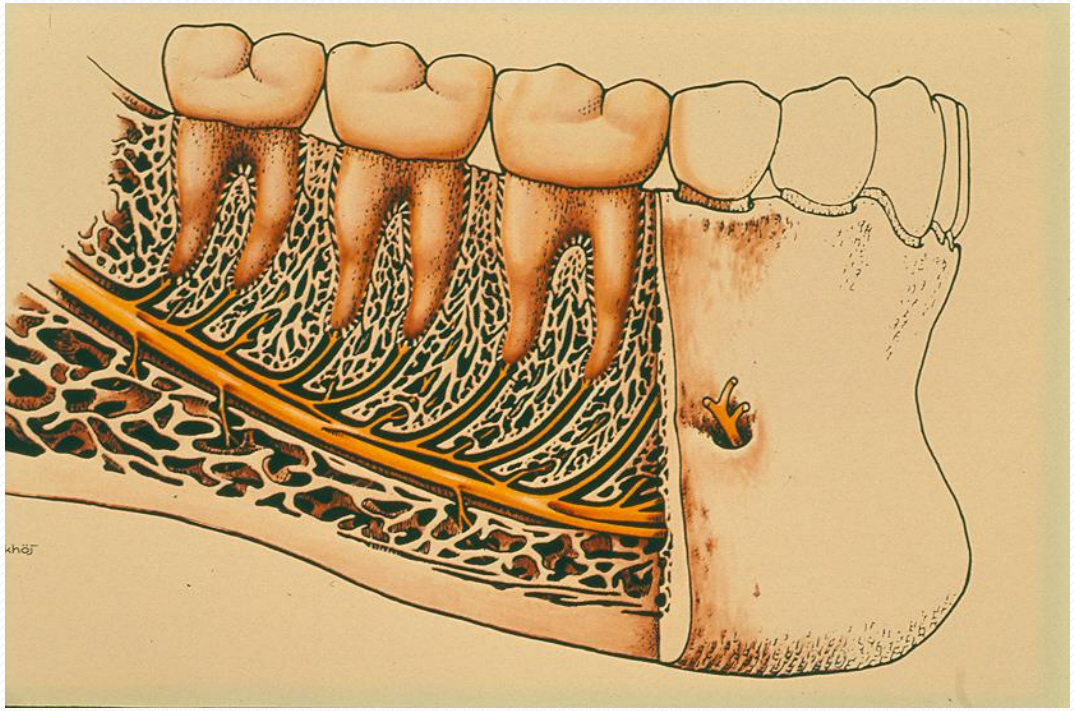

N. alveolaris inferior

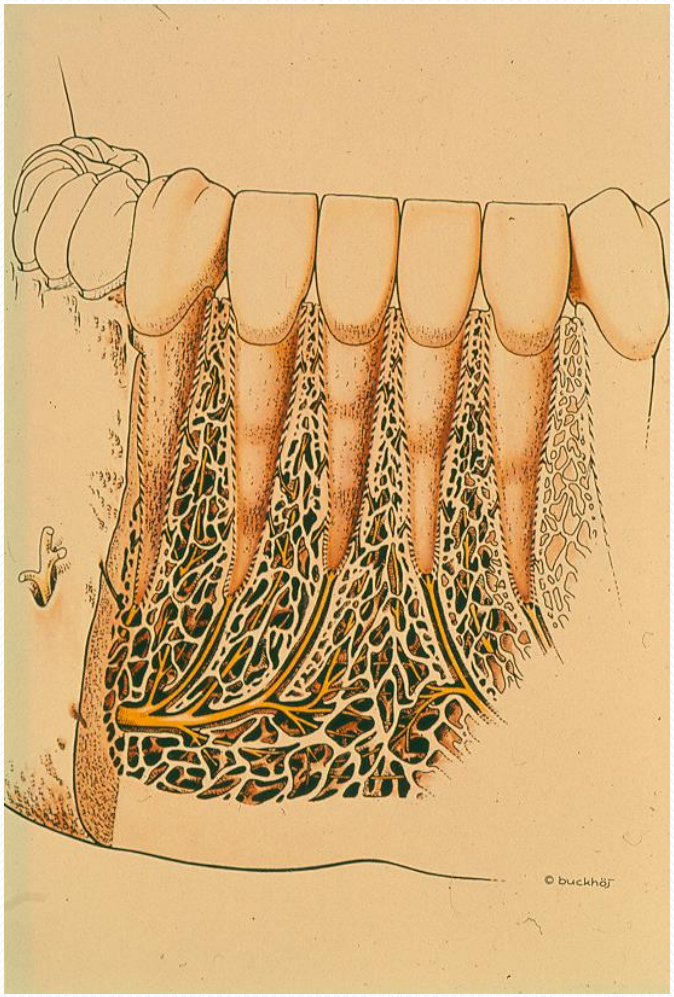

Szokolóczy manoeuvre
Block anaesthesia of the inf. alv. nerve

Spatial data of the mandible :

Width of the ramus mandible : 22-56 cm
Axis of the ramus closes 0-44° angle with the median saggital plane
Insertion depth: 11-28 mm

Lingula mandibulae is located in the half-way centre of the height and the width of the ramus mandibulae

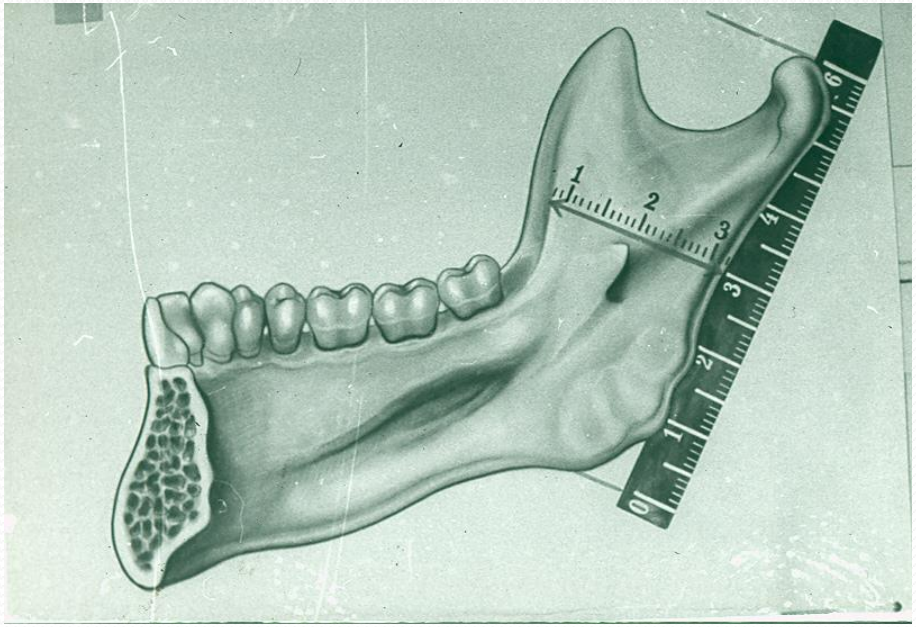

Szokolóczy manoeuvre
Block anaesthesia of the inf. alv. nerve

Szokolóczy manoeuvre
Block anaesthesia of the inf. alv. nerve

Szokolóczy manoeuvre
Block anaesthesia of the inf. alv. nerve

Szokolóczy manoeuvre
Block anaesthesia of the inf. alv. nerve

Block anaesthesia on the lower jaw

- n. alveolaris inferios = „Szokolóczy manoeuvre”
- n. mentalis
- n. lingualis
- n. buccalis

Mental Nerve

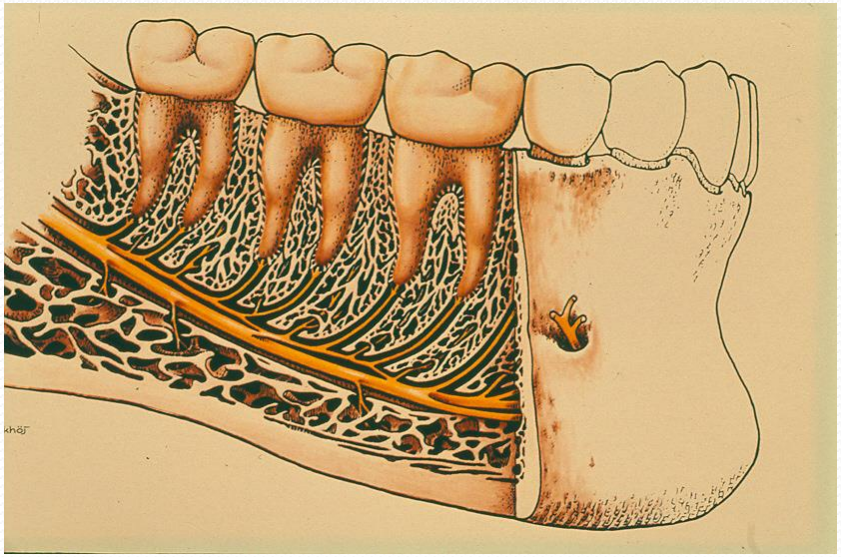

What does it happen, if the solution is not administered to the mandibular foramen?

1. „give it anteriorly”: the mucosa is numb, the tongue is numb
2. „give it to deep”: facial paresis
3. „give it to caudal direction”: adhesion of the medial pterygoideus m., trismus
4. „give it lateral direction”: injury of the periosteum
5. „give it medial direction”: injury of the medial pterygoid m., steril myositis, trismus
6. „give it overly to caudal direction and deep ”: the patient’s ear is numb /n. auriculotemporalis/