Knochenaugmentation in der präprotetischen Chirurgie

Dr. Bogdán Sándor
Semmelweis Universität, Budapest
Klinik für Mund-Kiefer-Gesichtschirurgie und Stomatologie

Implantation

- Die Vergangenheit
  - Nur unter optimalen anatomischen Bedingungen
  - <u>Kontraindikation: Knochendefekt</u>
- Heute
  - Der Ausmass vom Knochendefekt beeinflusst die Implantation nicht

    (in 40%- der Fälle wird zuerst Augmentation durchgeführt)

Wichtige Faktoren der Knochenbildung

Matrix

(Kollagen, trabekuläre Struktur,
Konochenersatzmaterialien)

Zeit

Geiegnete Umgebung

Zellen

(Osteoblasten, Fibroblasten)

Waschstum-Faktoren

(BMP, PDGF, TGF-β, IGF)

Die Knochenbildung beeinflussende Faktoren

- Osteoinduktion: Alle Prozesse die Knochenbildung aktivieren
- Osteokonduktion: Geeigneter Gerüst, welche eine 3D Wachstum steuert
- Osteogenese: osteogenetischer Potenz

Autogener Knochen

- Osteogenetische, osteoinduktive, osteokonduktive Eigenschafften
- **Goldener Standart -** für Knochenersatzmaterialien

Einheilungsverlauf des transplantierten Knochen

- Lokale Hyperämie
- An der Oberfläche vom Transplantat überleben viele Osteoblasten durch Diffusion
- Angiogenese - Kapilläre Invasion richtung Matrix (Nachschub wichtiger Faktoren und Zellen für die Osteogenese)
- Osteoklasten - Ursprung: Knochenresorption an der Peripherie vom Transplantat
- Es läuft eine dauerhafte Kompetition zwischen Knochenbildung und Weichgewebe-Invasion

Autogener Graft

- Spongiöser-, kortikaler Knochen oder beides
- Knochenbildung durch enchondrale Ossifikation (Tibia, Beckenkamm)
- Knochenbildung durch desmoide Ossifikation (Schädel, Kieferknochen)

Autogener Knochen

Spongiöser Knochen

Kortikaler Knochen

Knochenersatz im Ober- und Unterkiefer

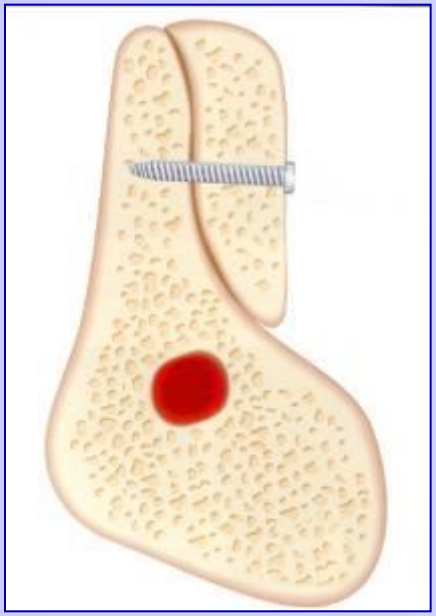

laterale Augmentation

vertikale Augmentation

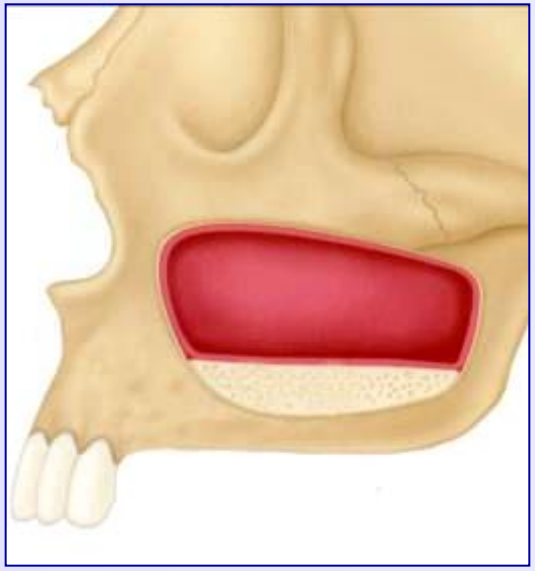

Sinus-lift

Intraorale Entnahmestellen

- Mentum (symphysis mandibulae)
- Retromolare Region
- Tuber maxillae
- Jochbein

Mentum (symphysis mandibulae)

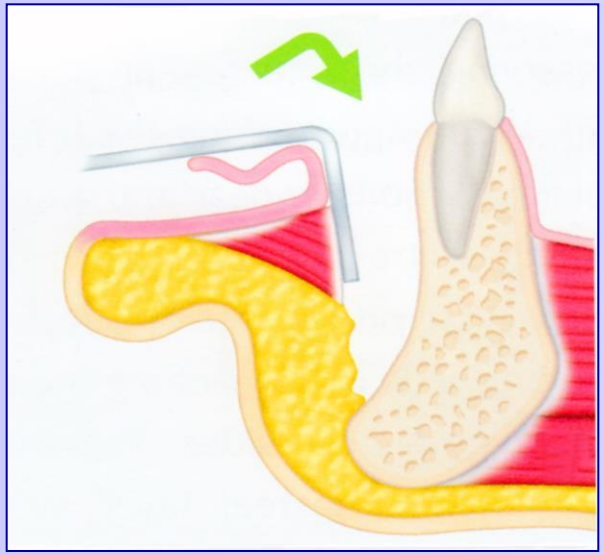

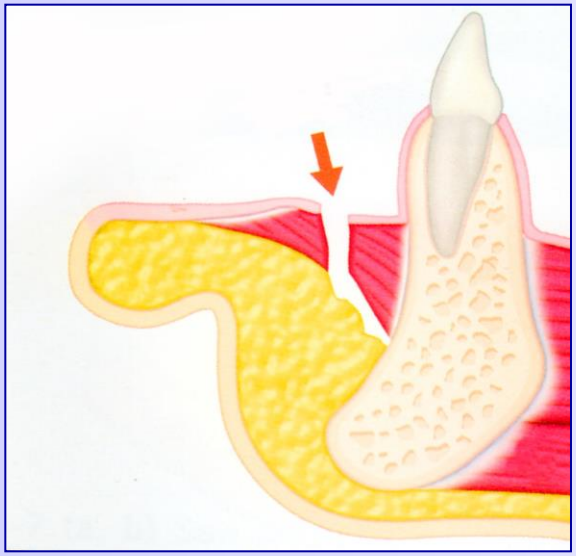

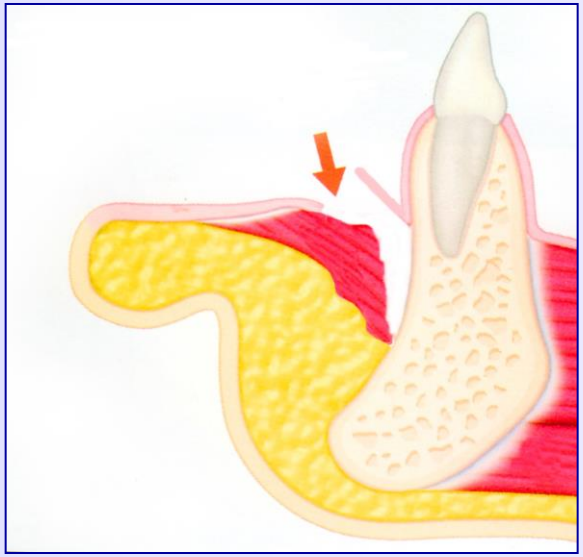

Exploration vom Kinn

Mentum (symphysis mandibulae)

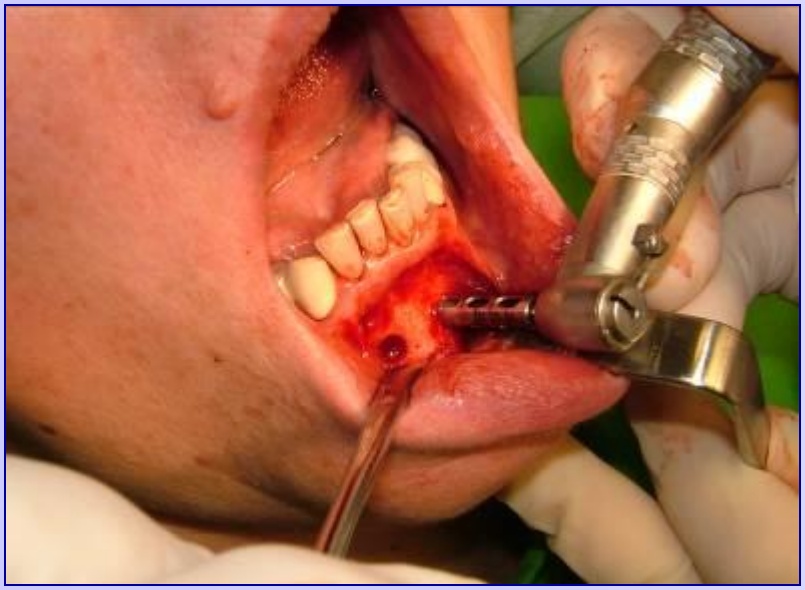

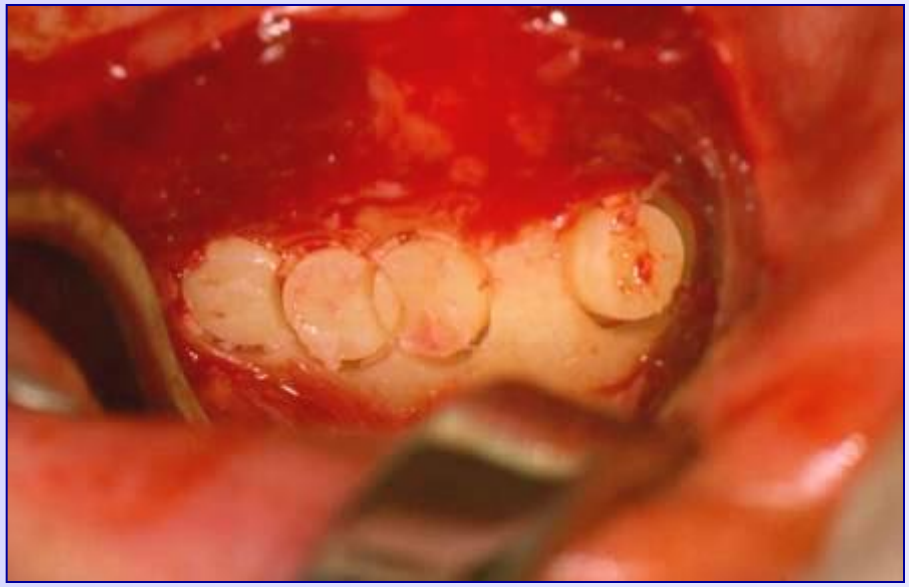

Knochenentnahme mit dem Trepan-Bohrer

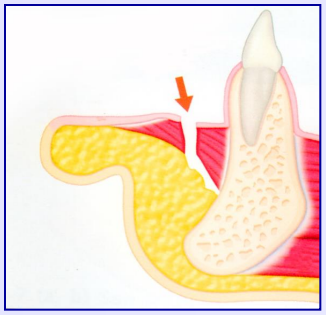

Mentum (symphysis mandibulae)

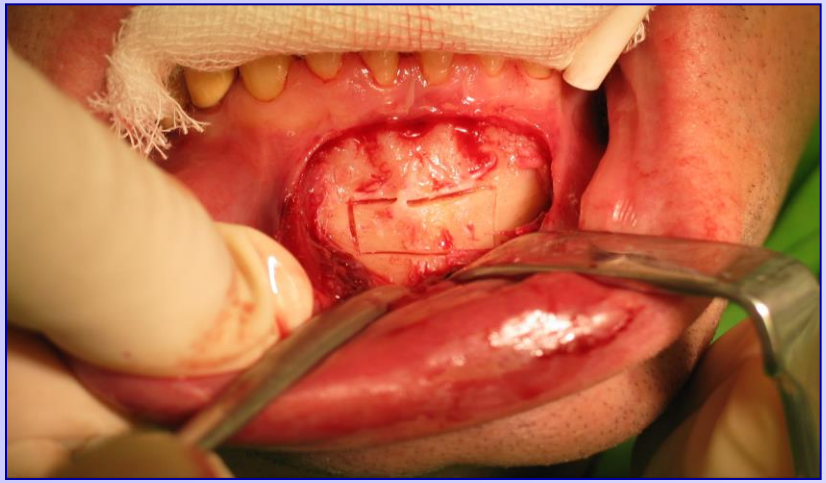

Knochenblock - Entnahme

Retromolare Region

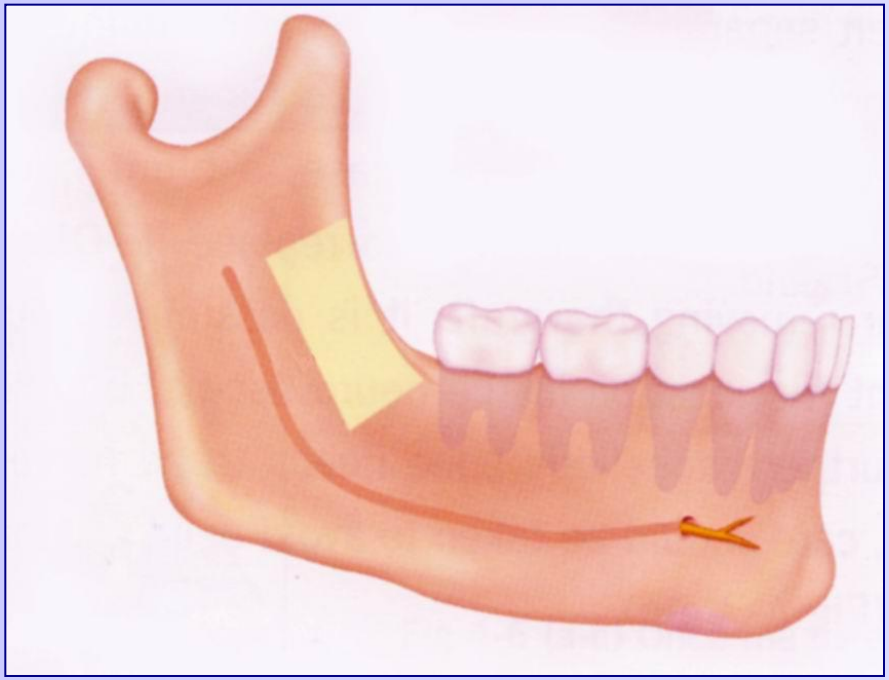

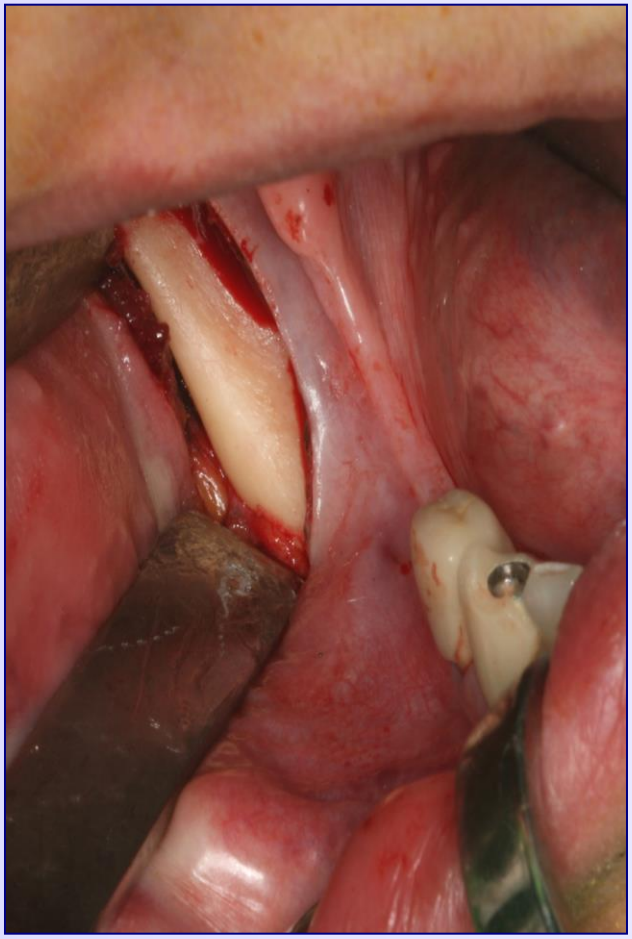

Retromolare Region

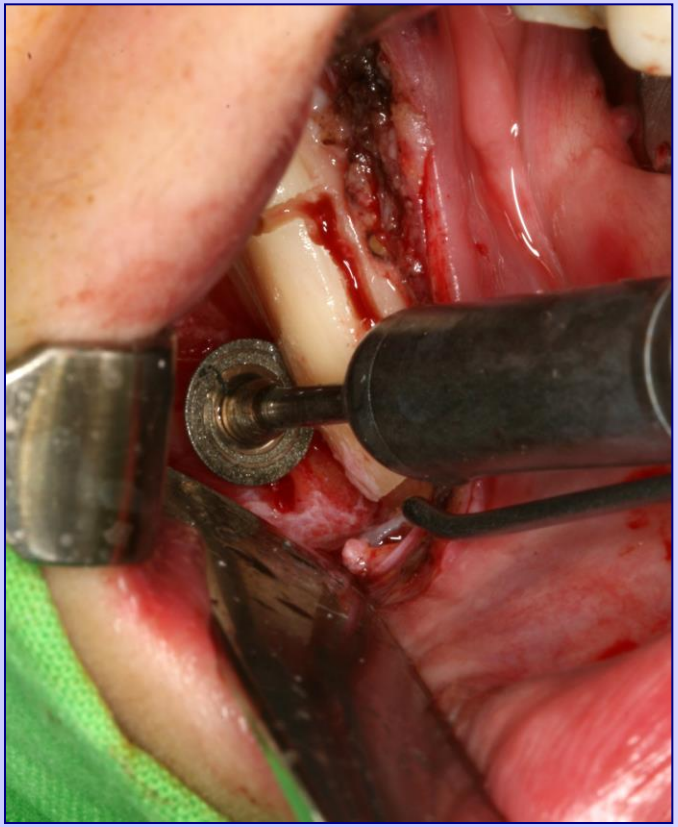

Knochenentnahme aus der retromolaren Region

Retromolare Region

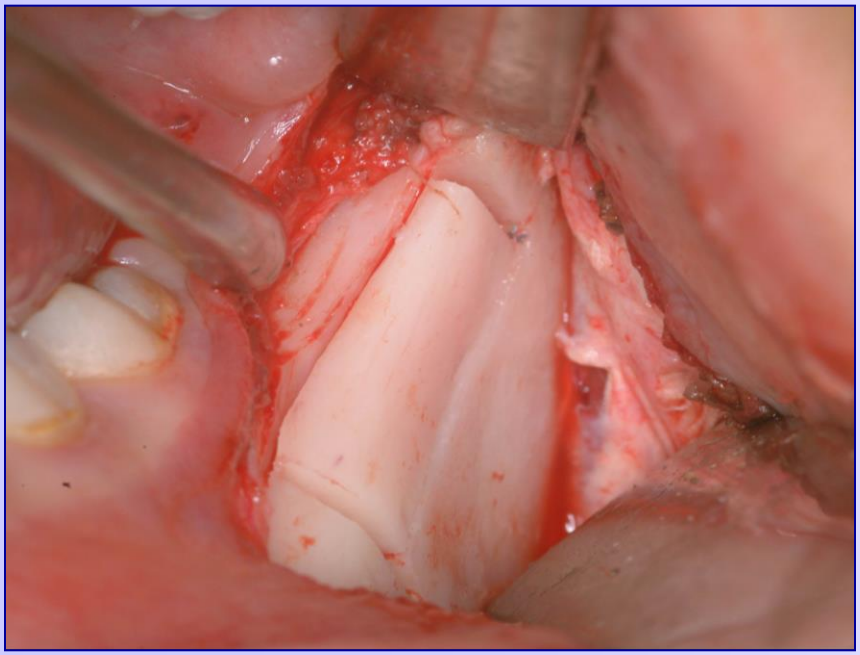

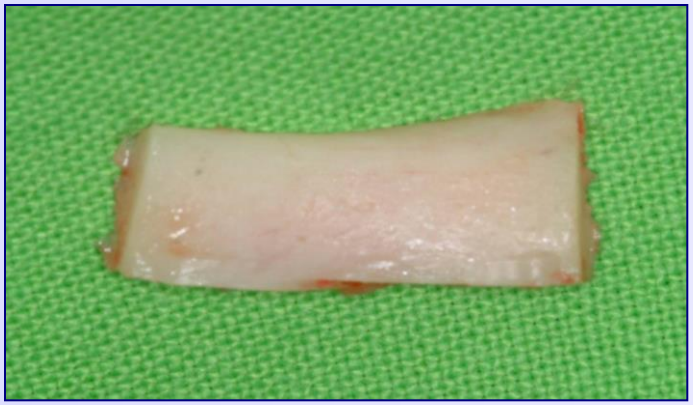

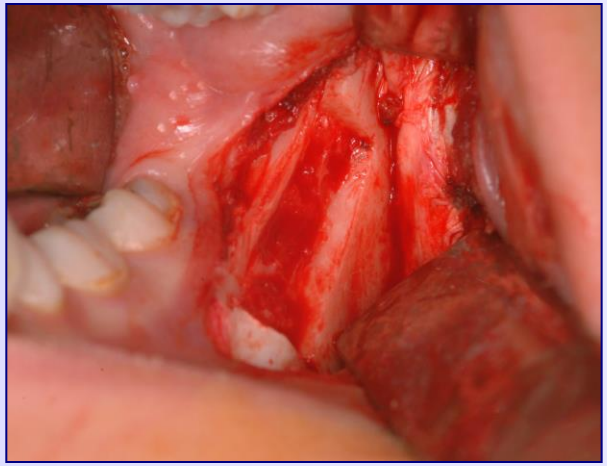

Laterale Augmentation mit retromolarem Graft

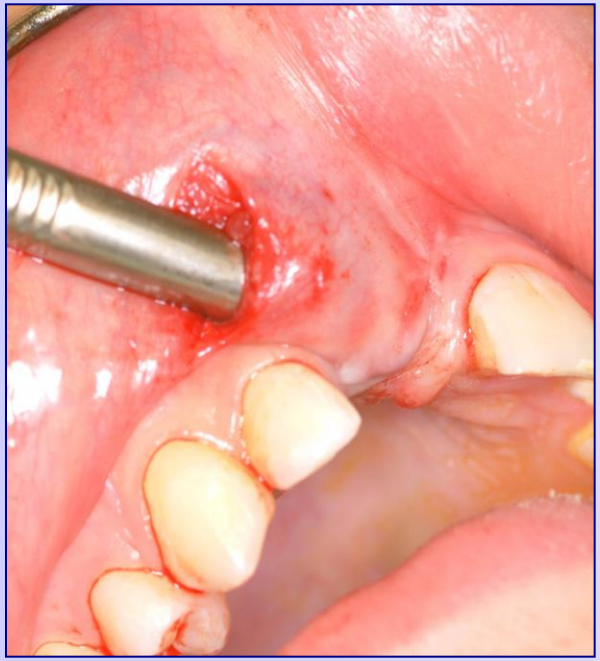

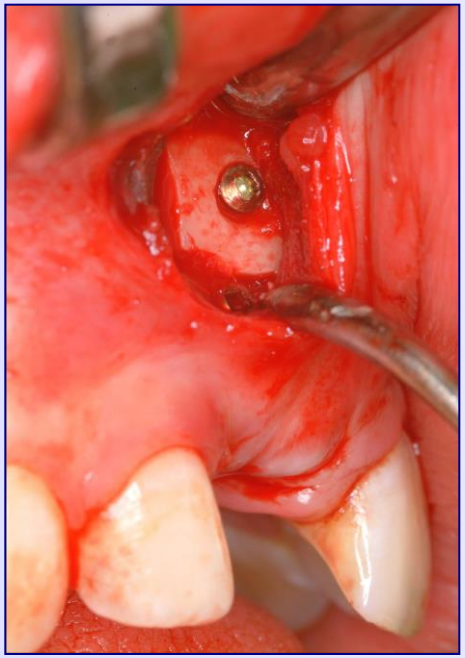

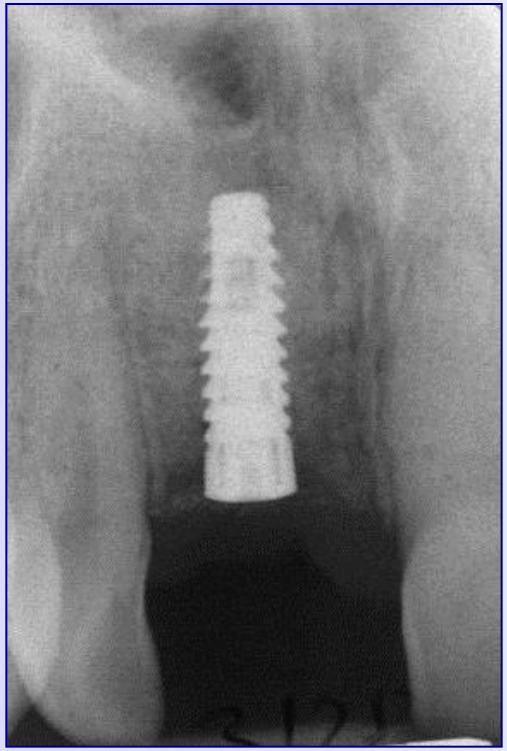

Vertikale Augmentation
mit retromolarem Graft

Extraorale Entnahmestellen

- Beckenkamm (anterior, posterior)
- Calvaria
- Proximale Epyphyse der Tibia

Beckenkamm

Die häufigste Entnahmestelle

Vorteile:
- „unlimitierter" Graft-Volumen
- spongiöser und kortikaler Knochen

Nachteile:
- zweite Operationsstelle
- häufigste Donorstellen-Morbidität
- enchondrale Ossifikation
- hohe Resorptionsrate (bis 40-60 %)
- intratracheale Narkose
- MKG Hintergrund

Beckenkamm Graft

Exploration vom Beckenkamm

Beckenkamm Graft

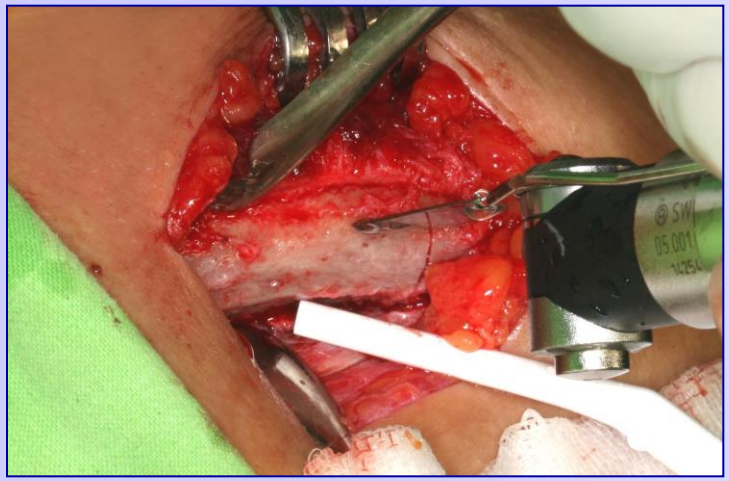

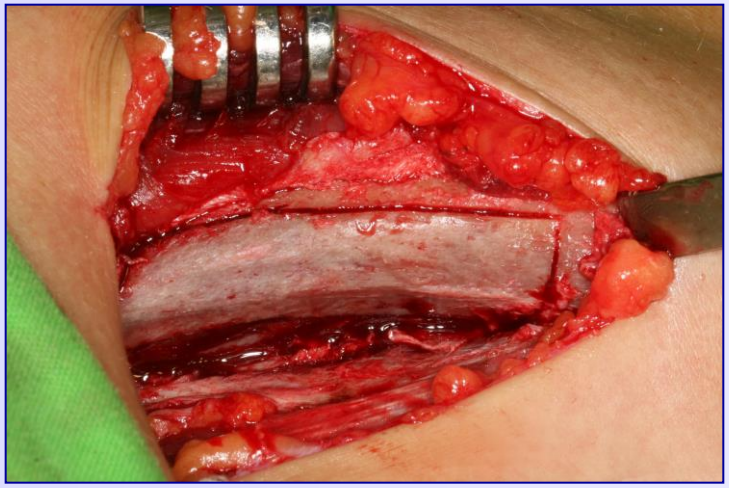

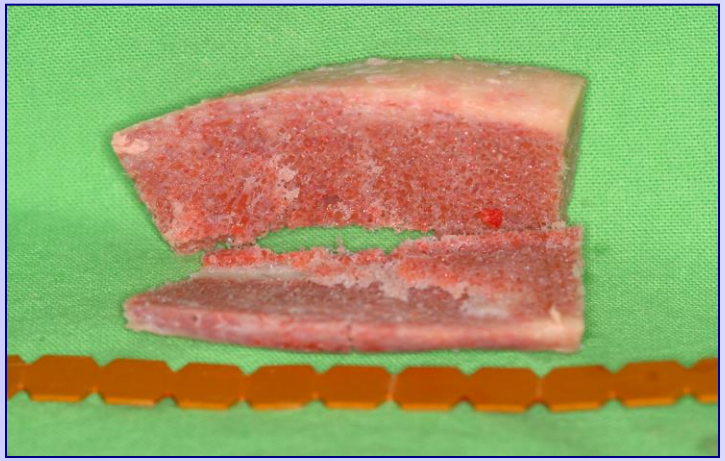

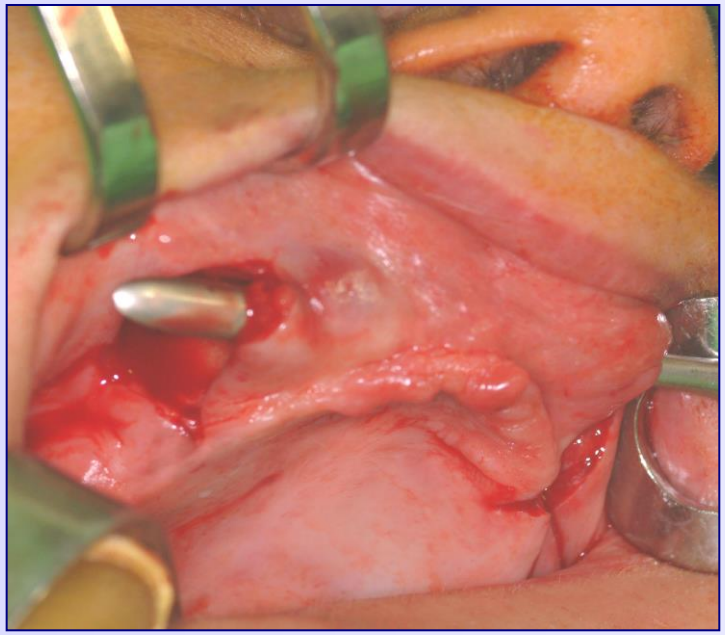

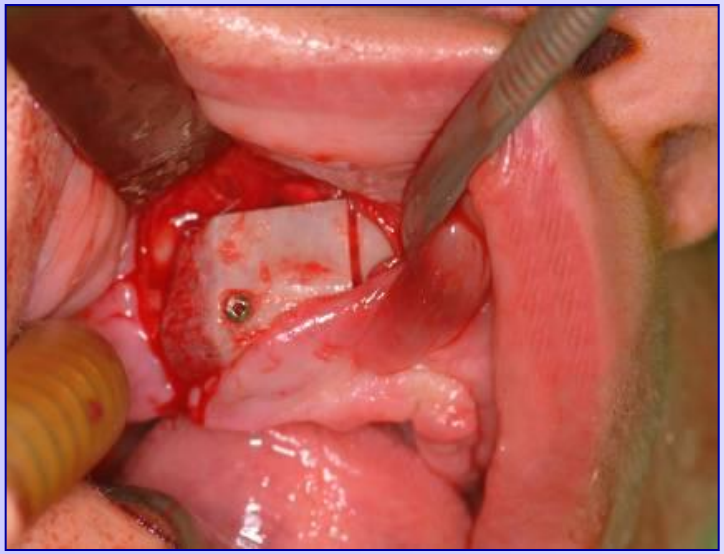

Laterale Augmentation

Laterale Augmentation aus vestibulärer Zugang

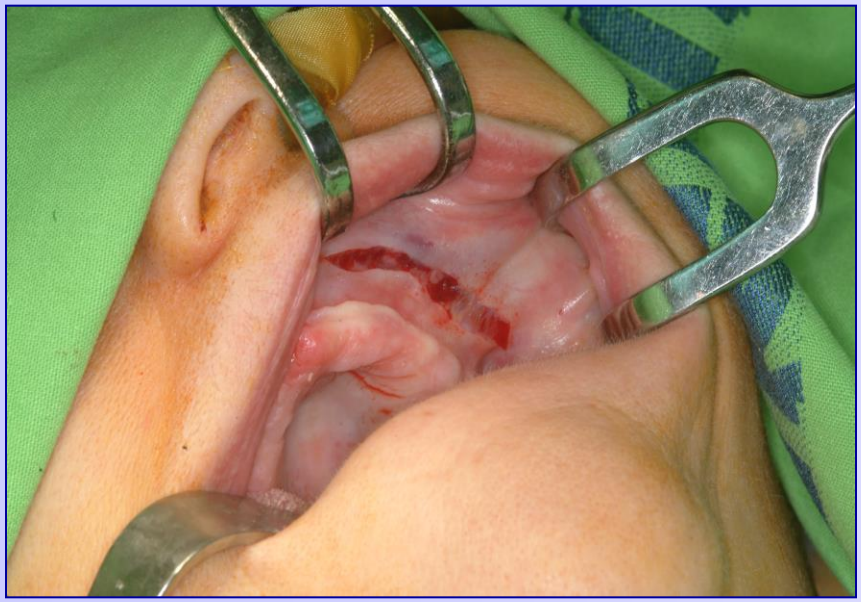

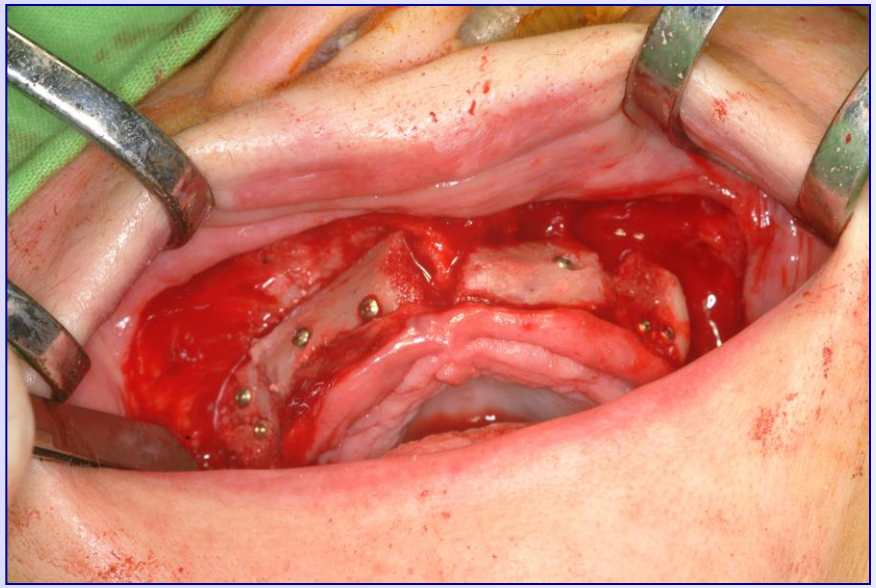

Präop. Situation

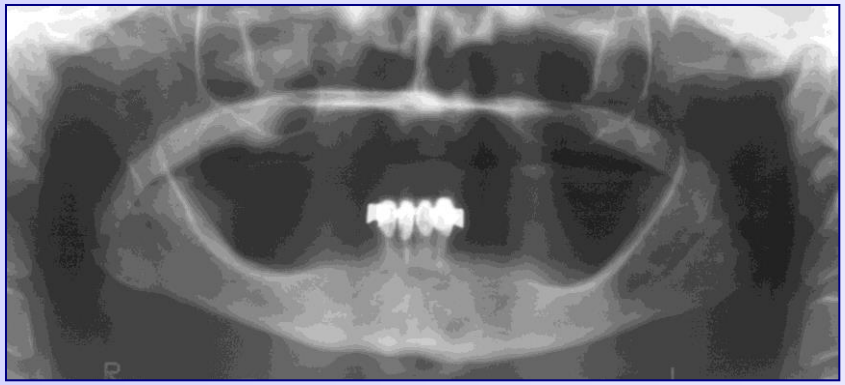

Postop. Situation

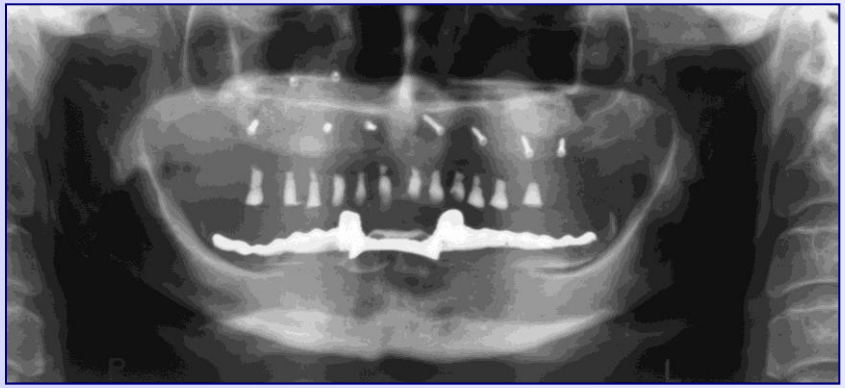

Nach Implantation

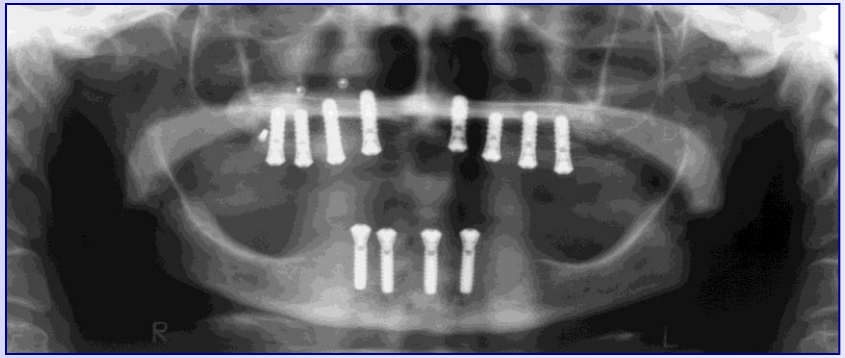

Calvaria

Vorteile:

- güstige kosmetische Ergebnisse
- dichter, desmaler Knochen
- niedriger Resorptionsrate
- minimale postoperative Komplikationen

Nachteile:

- zweite Operationsstelle
- Morbidität der Entnahmestelle in einer ungüstigen Region
- nur kortikaler Knochen
- intratracheale Narkose
- MKG Hintergrund

Knochenentnahme aus der Calvaria

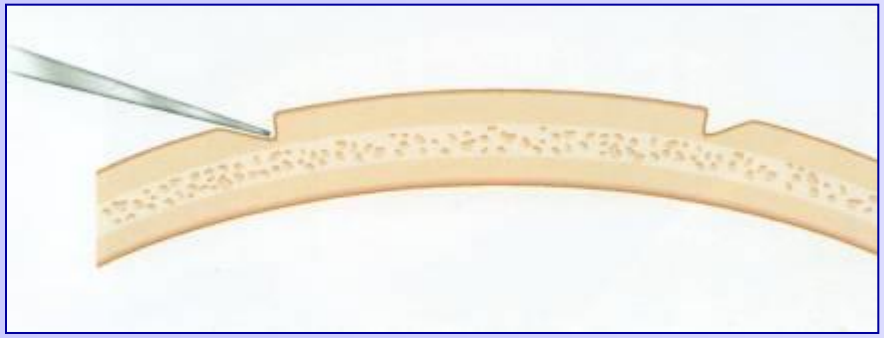

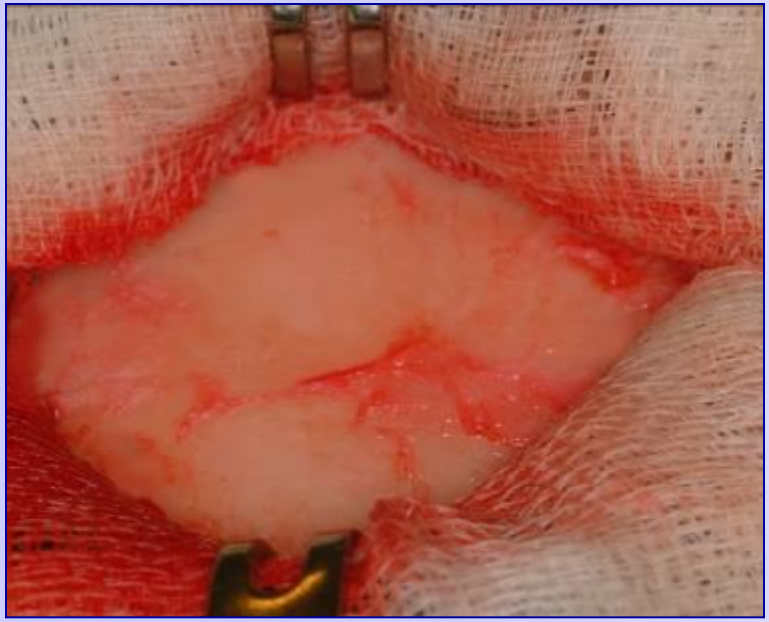

Knochenentnahme aus der Calvaria

Laterale Augmentation

Knochenentnahme aus der Calvaria

Präop. Situation

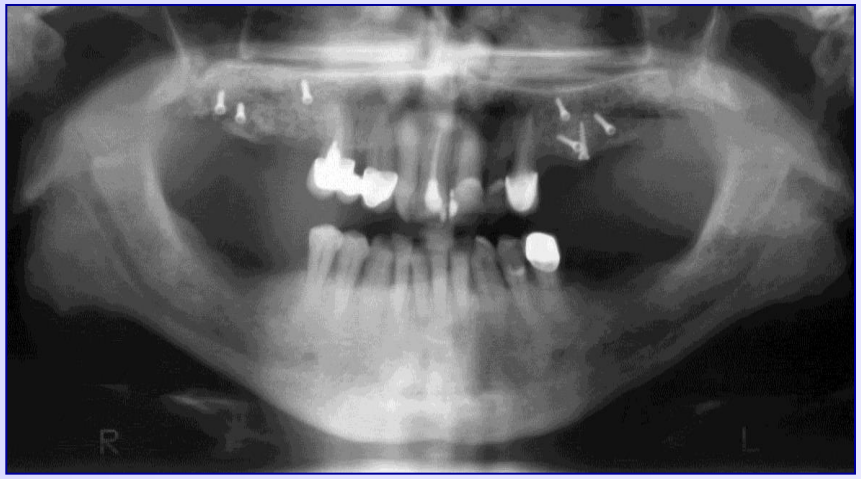

Postop. Situation

Die proximale Epyphyse der Tibia

Vorteile:

- minimale Invasivität
- 20-25 cm^3 spongiöser Knochen
- minimale postoperative Beschwerden

Nachteile:

- zweite Operationsstelle
- nur spongiöser Knochen
- MKG Hintergrund

Knochenentnahme aus der Tibia

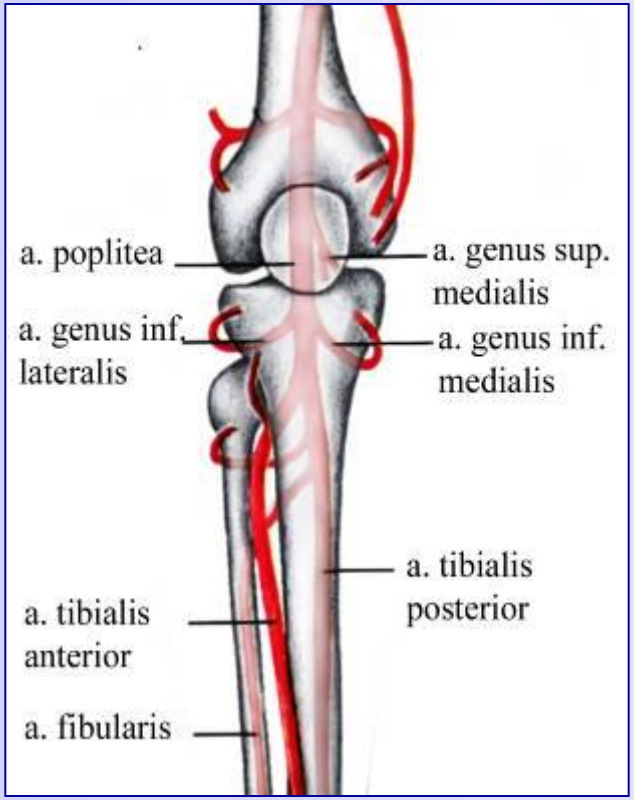

Blutversorgung der Tibia

Knochenentnahme aus der Tibia

Exploration

Knochenentnahme aus der Tibia

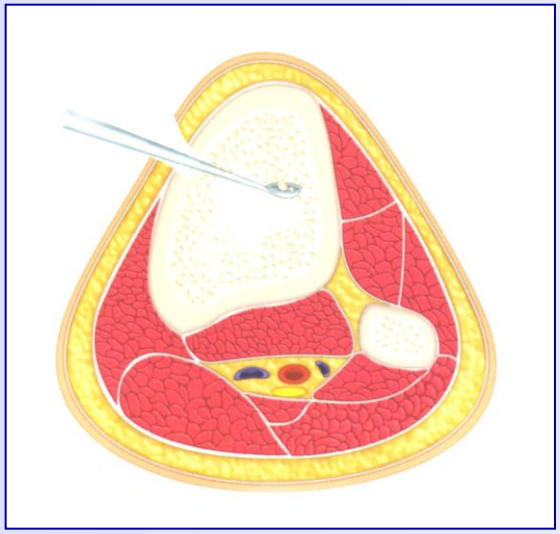

Alveoläre Distraktion

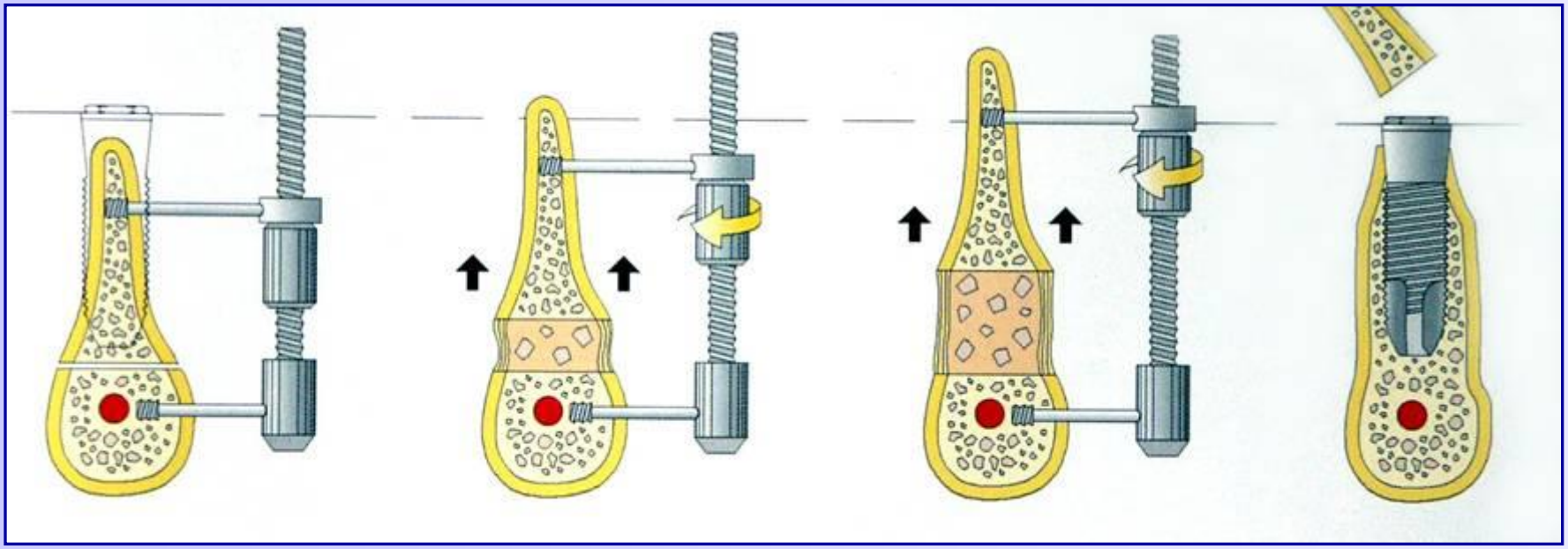

Alveoläre Distraktion

Alveoläre Distraktion

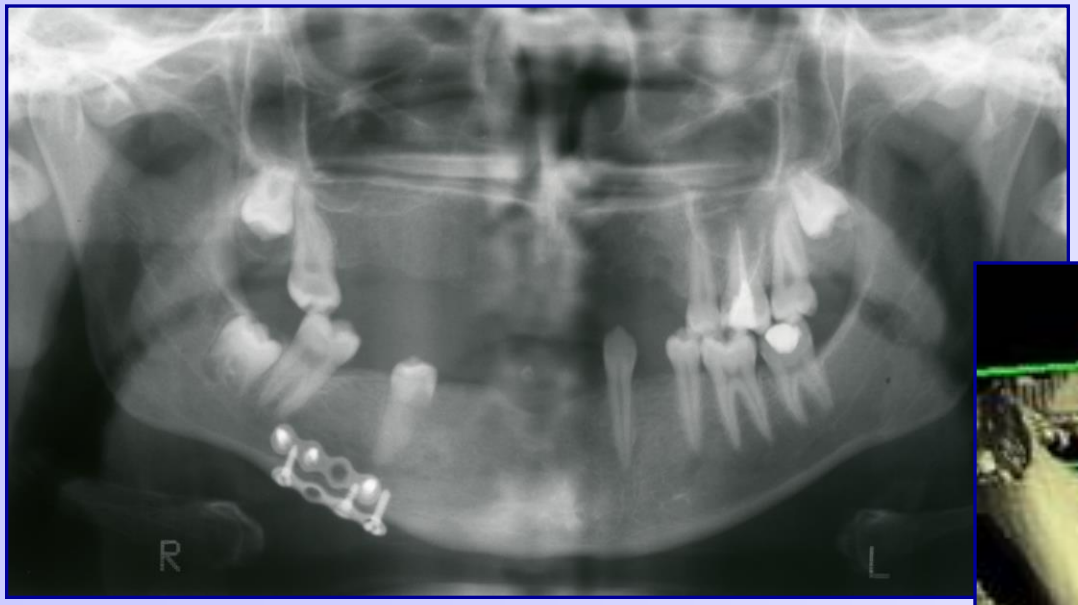

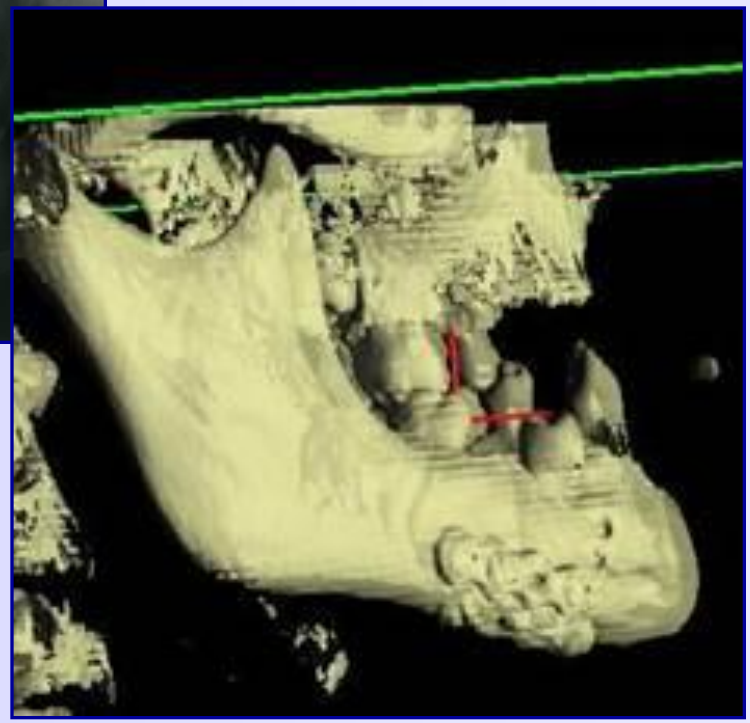

Alveoläre Distraktion

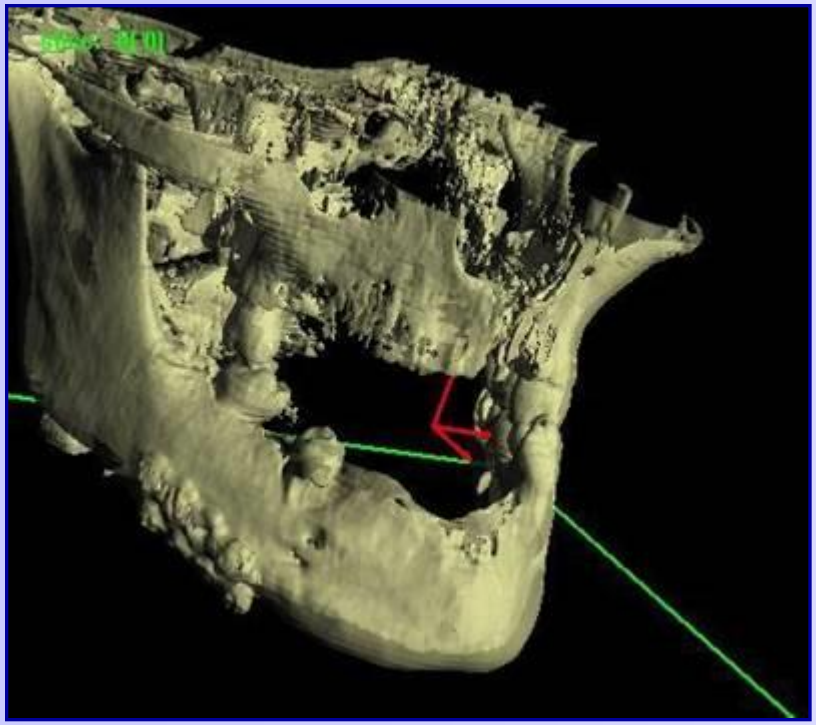

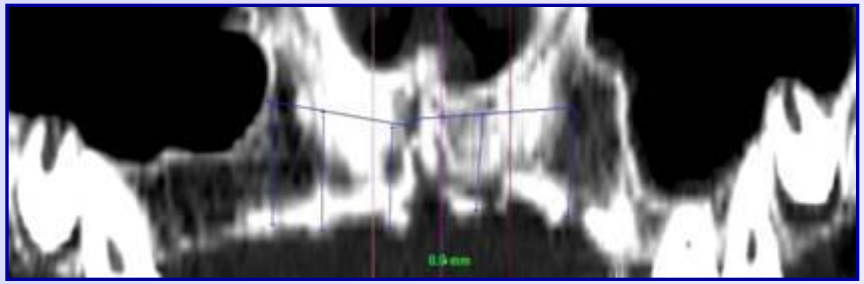

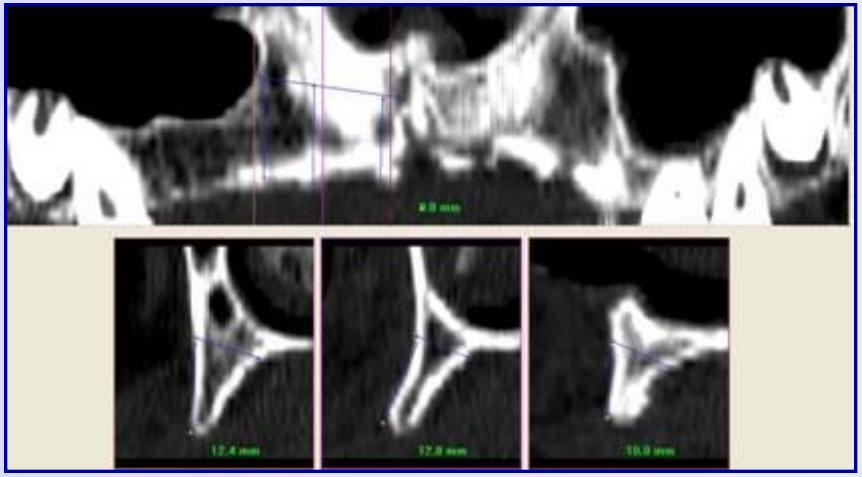

Alveoläre Distraktion

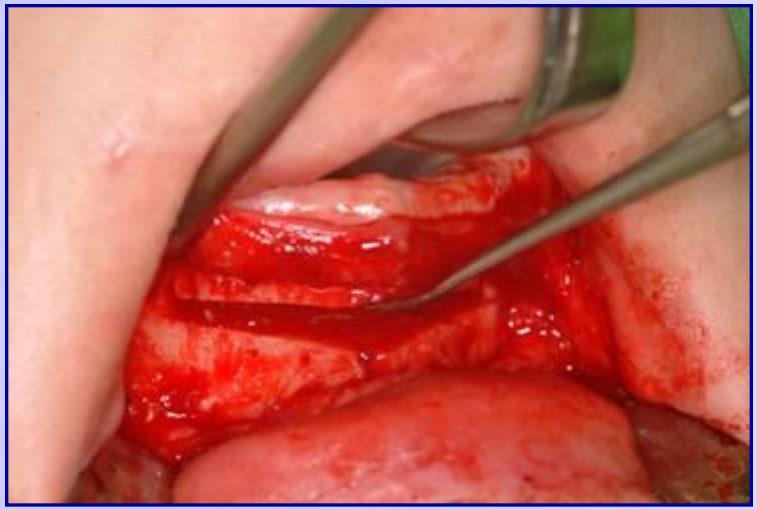

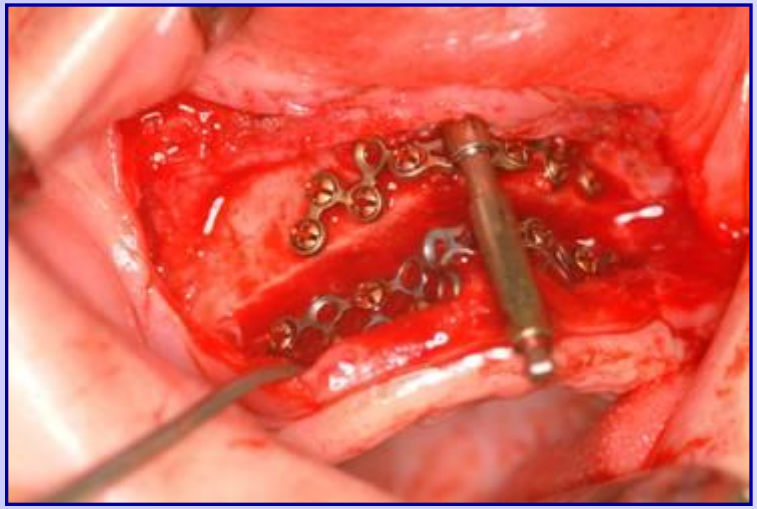

Präop. Situation

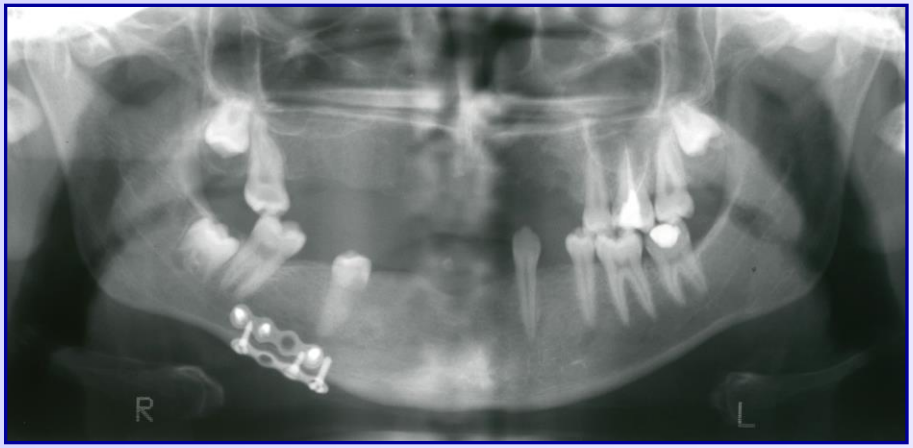

Während der Distraktion

Nach der Distraktion

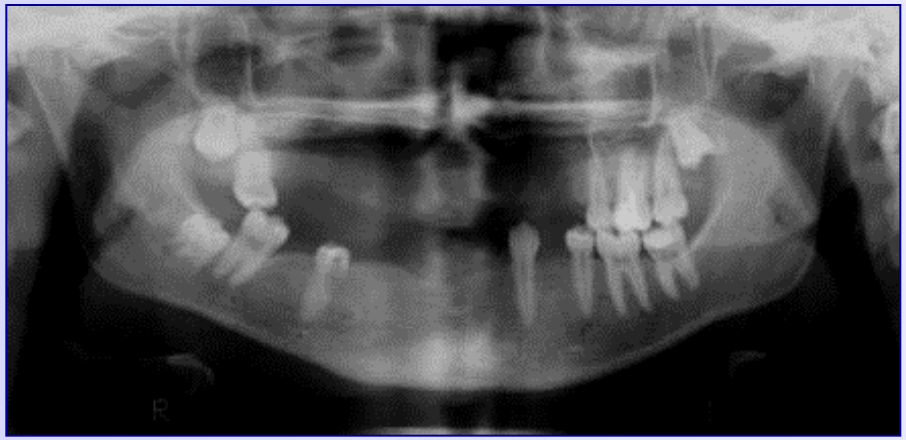























Alveoläre Distraktion

Präop. Situation

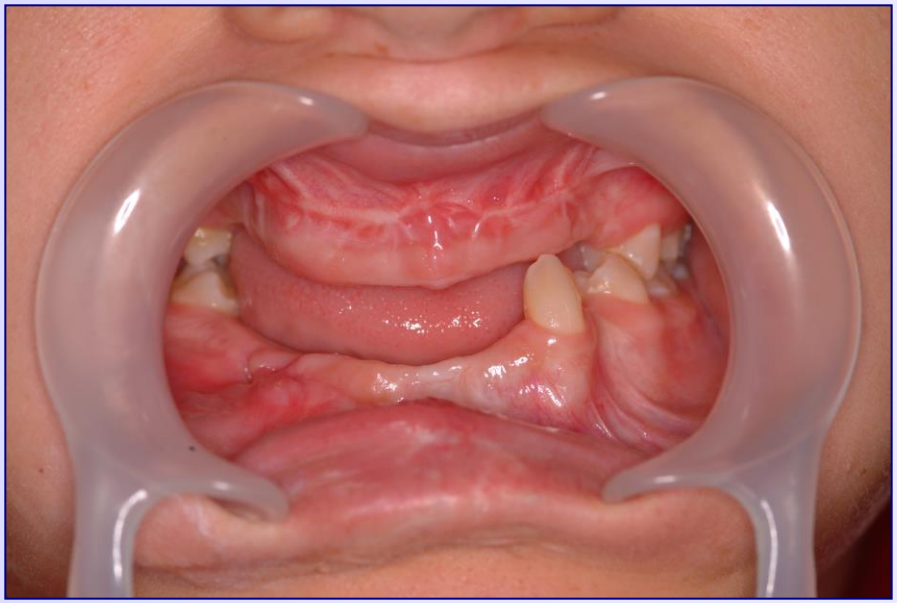

Resultat