

Dentoalveolar Surgery

Oral surgery

- Maxillofacial surgery
- Dentoalveolar surgery

Oral surgery

Dentoalveolar surgery

- Dental chair/office
- Clean
- Ex.: impacted wisdom tooth surgery, cyst surgery, surgical tooth removal

Maxillofacial surgery

- Operating room
- Sterile
- Ex.: tumors, developmental disorders, traumatology

Design of the operating room

- Should be isolated and located on an upper floor
- Min. 36-40 m² floor area
- North-facing if possible

Surface design in the operating room

- Seamless and easy to clean floor
- The walls are tiled to the ceiling
 - Rounded, practical
 - White or green

Cleaning the operating room

- Entering only in protective clothing
- At the end after each work day-HYPO
- Clean-up once a week

Design of the dentoalveolar operating room (dental office)

- Min. floor area: 14 m² or 9 m² for each chair
- Inner height minimum 2,5m
- Covering should be washable up to 2.1m, flooring should be antistatic, washable, disinfectable
- Furnishing should have a washable surface, should not be crowded
- No carpet or plants should be in the room
- Door handle, switch should be sleek and disinfectable

Recommendation of the National Center for Epidemiology (2016)

<http://www.oek.hu/oek.web?to=16&nid=444&pid=1&lang=hun>

Specifics of surgery

Invasive- indication is important

Causal

„we give a chance for the human body to cure itself” - MEDICUS CURAT, NATURA SANAT

Manual and instrumental profession

Concept of the surgical disease

**INTERNAL MEDICINE
DISEASE**



**SURGICAL
DISEASE**

Ex.: diabates,
hypertension

Ex.: dental abscess,
tumors

Can be cured with
medicaments

Major stages in the development of surgery:

- **Development of the surgical techniques and instruments**
- **Recognizing the importance of post-operative rehabilitation**
- **Development of the methods and techniques of anaesthesia**
- **Development of hygiene**

Historical overview of surgery

Anaesthesia

1842. : William E. Clarke+Elijah Pope performed tooth extraction under ether narcosis

1846 :William T. Morton dentist, tooth extraction under ether narcosis, then on the 16th of October, 1846 Dr. John Collins Warren removed a cervical tumor under the ethernarcosis provided by Morton

János Balassa, the surgeon professor of the University of Budapest was the first to operate under ethernarcosis on the 11th of January 1847.

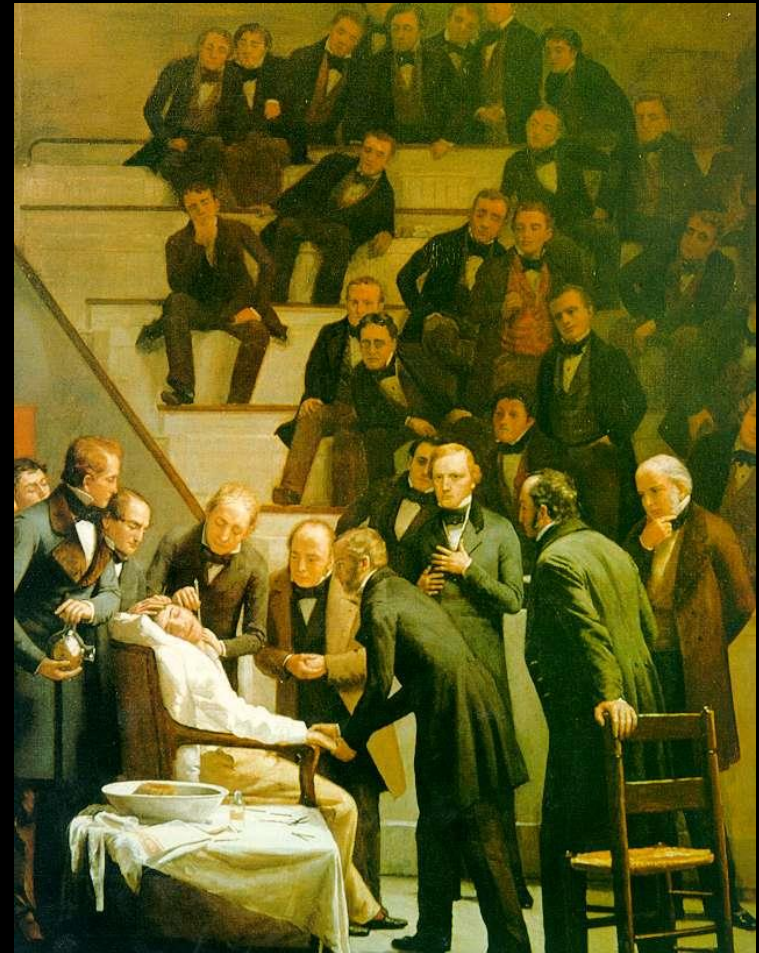
1844.: Horace Wells- laughing gas (N_2O)

1905. Discovery of Procain

/Novocain/Alfred Einhorn

1943.: N. Löfgren production of lidocain

1969.: discovery of Articain by Muscheweck



Historical overview of surgery

Hygiene

Ignaz Semmelweis (1818-1865)

1844 medical degree - Vienna

Due to the death of his friend (sepsis), he realized the cause of childbirth fever

1855 obstetrics teacher in Budapest

1865 dies in Paralysis progressiva



Historical overview of surgery

Development of the surgical technique

Theodor Billroth (1829-1894)

1871: first esophagostomia

1873: first laryngectomy

1881: first gastrectomia



Historical overview of surgery

Discovery of penicillin

Alexander Fleming (1881-1955)

Biologist-pharmacist

1922: isolation of lysozyme

1928: discovered penicillin

1945: Nobel-prize



Instruments



AESCULAP

AESCULAP-Skalpellklingen garantieren optimale Schärfe und Schnitthaltigkeit

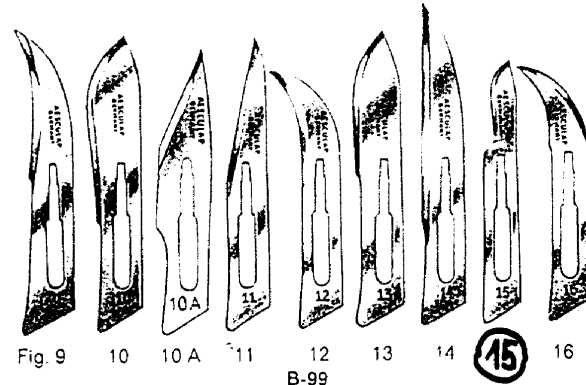
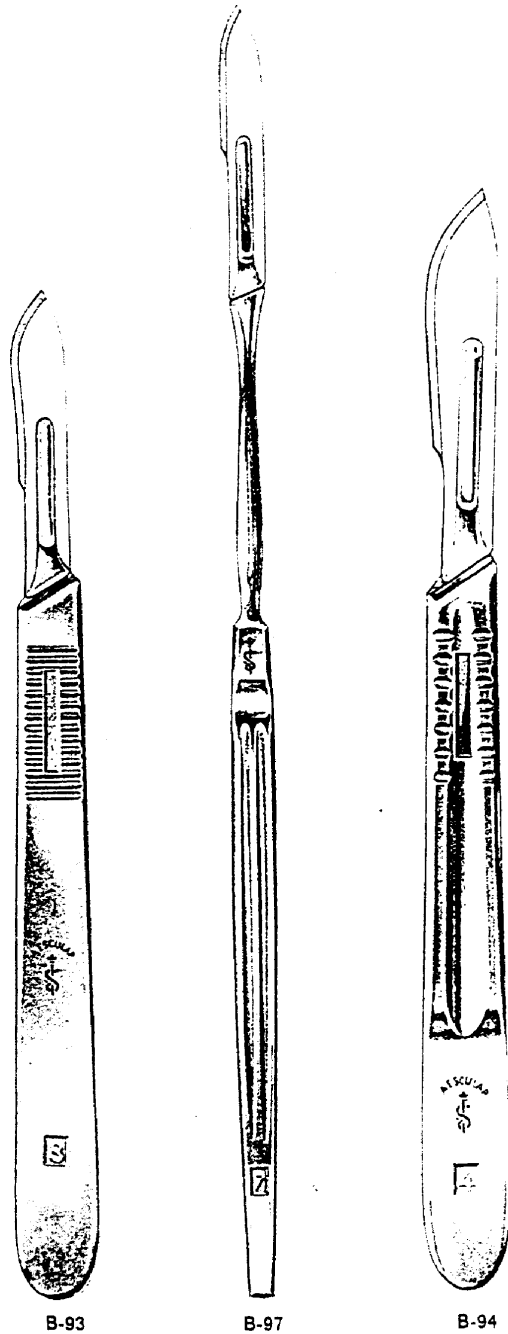
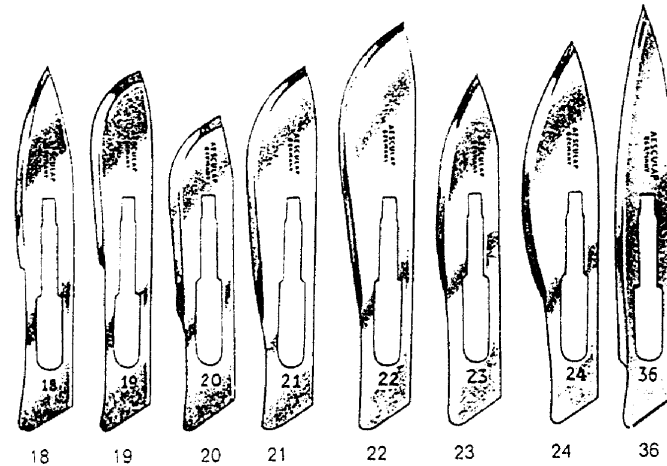


Fig. 9 10 10 A 11 12 13 14 15 16

B-99

passend zu den Griffen B-93 und B-97



18 19 20 21 22 23 24 36

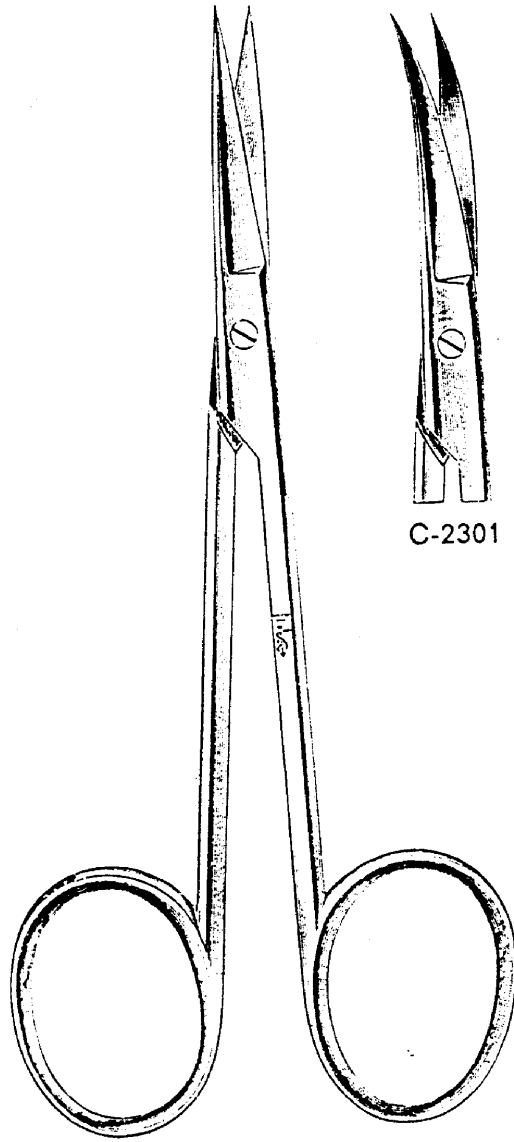
B-99

passend zum Griff B-94

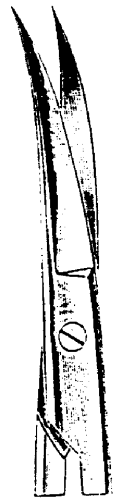6 Klingen einer Figur oder 6 Stück sortiert sind in einer luft- und feuchtigkeitsdichten Goldfolienpackung verpackt.

Sortiment I bestehend aus: Fig. 10, 11, 12, 13, 15, 16

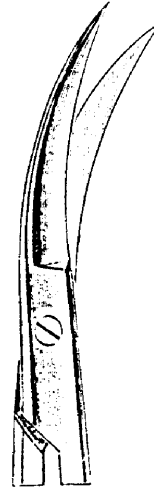
Sortiment II bestehend aus: Fig. 20, 21, 22, 23, 24, 36



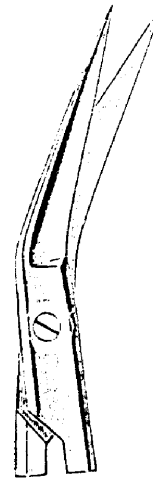
C-2300
11 cm, 4 1/4"



C-2301



C-2302



C-2303



B-1780 13 cm, 5"

B-1781 14½ cm, 5¾"



B-1353 11½ cm, 4½"

B-1355 13 cm, 5"

B-1357 14½ cm, 5¾"

B-1359 16 cm, 6¼"



Gillies
B-1344
16 cm, 6¼"



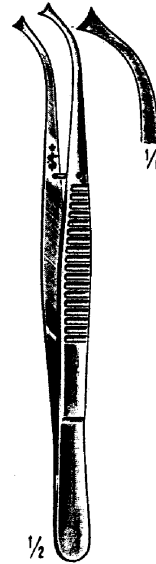
Waugh
B-1340
18 cm, 7"



Brophy
C-7967
20 cm, 8"



Brophy
C-7968
20 cm, 8"



König
C-7990
Fig. 10
16 cm, 6¼"

- B-1340 Hakenpinzette nach Waugh, schlank, 18 cm lang
- B-1344 Hakenpinzette nach Gillies, breite Querkehlen, 16 cm lang
- B-1353 Hakenpinzette, 1x2 Zähne, 11½ cm lang
- B-1355 Hakenpinzette, 1x2 Zähne, 13 cm lang
- B-1357 Hakenpinzette, 1x2 Zähne, 14½ cm lang
- B-1359 Hakenpinzette, 1x2 Zähne, 16 cm lang
- B-1780 Hakenpinzette, 1x2 Zähne, feines Modell, 13 cm lang
- B-1781 Hakenpinzette, 1x2 Zähne, feines Modell, 14½ cm lang
- C-3527 Pinzette nach Troeltsch, kniegebogen, mit Querriefen, 12½ cm lang
- C-3528 Pinzette nach Troeltsch, kniegebogen, 1x2 Zähne, 12½ cm lang
- C-7967 Hakenpinzette nach Brophy, gerade, 1x2 Zähne, 20 cm lang
- C-7968 Hakenpinzette nach Brophy, gebogen, 1x2 Zähne, 20 cm lang
- C-7990 Hakenpinzette nach König, Fig. 10, mit feiner Zahnung, gebogen, 16 cm lang



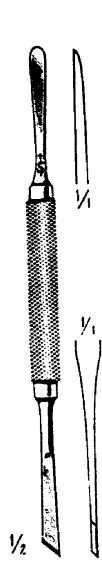
Troeltsch
C-3527-3528
12½ cm, 5"




C-3527




C-3528




Mead
DO 520
16½ cm, 6½"




Molt
DO 541
18 cm, 7"



Molt
DO 542
18 cm, 7"



Molt
DO 543
18 cm, 7"



Freer
C-5915
18½ cm, 7¼"




Kendzia
DO 560
17 cm, 6¾"



Williger
B-19585
16½ cm, 6½"



Williger
B-19586
17½ cm, 7"



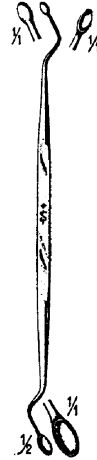
Lucas
DO 608



Lucas
DO 609



DO 650
15½ cm, 6¼"



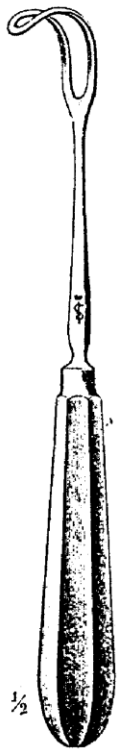DO 651



Hemingway
DO 655
16½ cm, 6½"

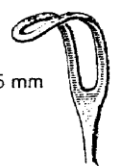


DO 656



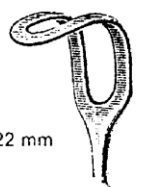
Middelдорpf

15 x 15 mm



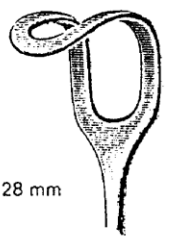
B-19780/B-19866

20 x 22 mm

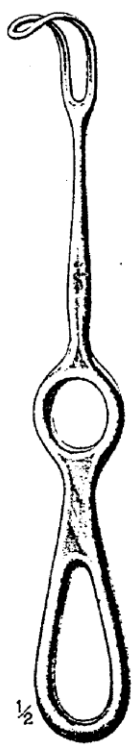

B-19781/B-19866 1/4


28 x 28 mm



B-19782/B-19866 1/2

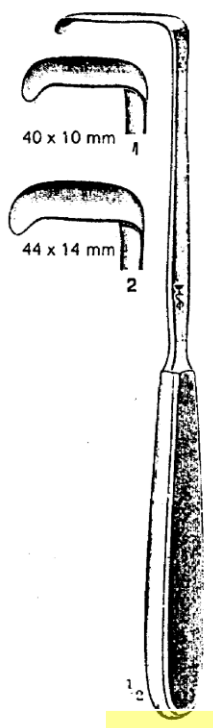


Middeldorpf



28 x 10 mm
1 3/32" x 13/32"

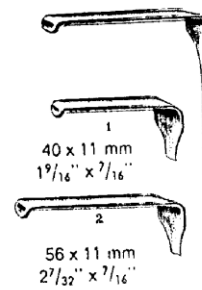
Langenbeck
B-19795
Fig. 1



40 x 10 mm 1

44 x 14 mm 2

Langenbeck
B-19795



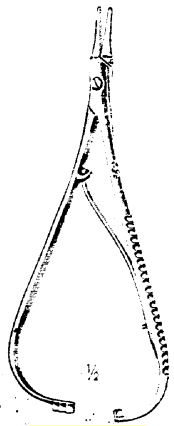
40 x 11 mm
1 9/16" x 7/16"

56 x 11 mm
2 1/32" x 7/16"

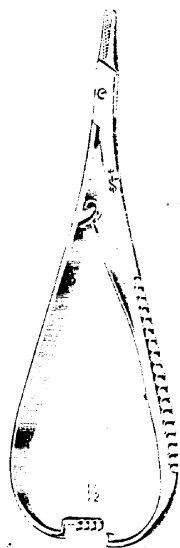
Kocher
B-19527
Fig. 1-2



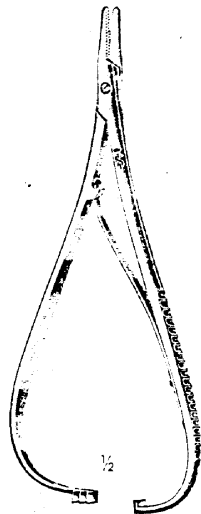
Kocher



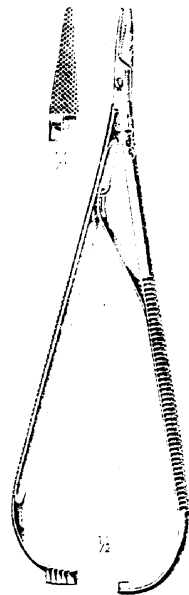
Mathieu
B-3936
14 cm, 5 1/2"



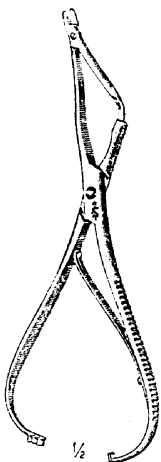
Mathieu
B-4074 17 cm, 6 3/4"
B-4076 20 cm, 8"



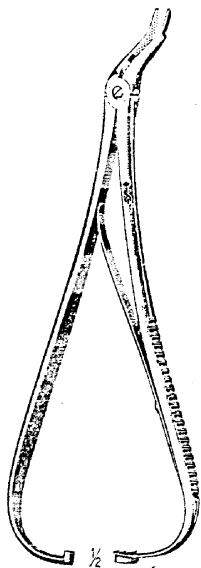
Mathieu
B-4082 14 cm, 5 1/2"
B-4084 17 cm, 6 3/4"
B-4086 20 cm, 8"



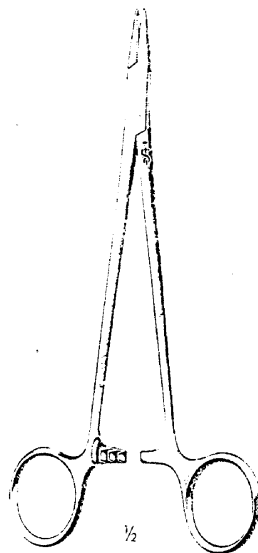
Lichtenberg
B-4068
20 cm, 8"



Kader-Mathieu
B-4145
15 cm, 6"

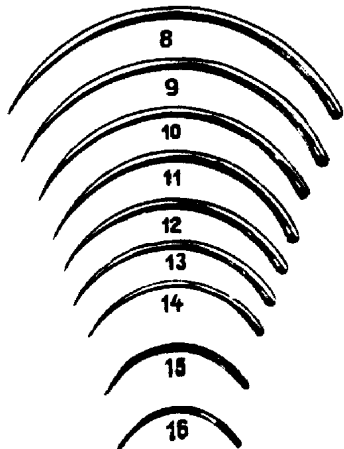


Eiselsberg-Mathieu
B-4368
18 1/2 cm, 7 1/4"



Hegar-Mayo
B-3965 15 cm, 6"
B-3966 18 cm, 7"
B-3967 20 cm, 8"

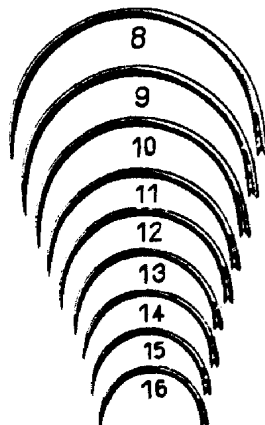
Chirurgische Nähnadeln, Nadeldosen



B $\frac{3}{8}$ Kreis – Dreikantspitze

B-3015

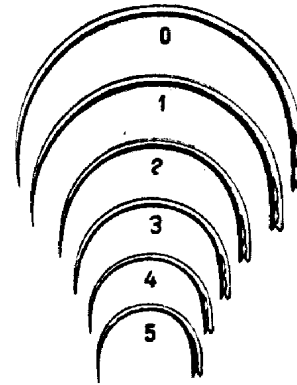
Fig. 8–16



G $\frac{1}{2}$ Kreis – Dreikantspitze

B-3017

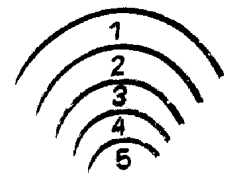
Fig. 8–16



E $\frac{1}{2}$ Kreis – Rundspitze

B-3351

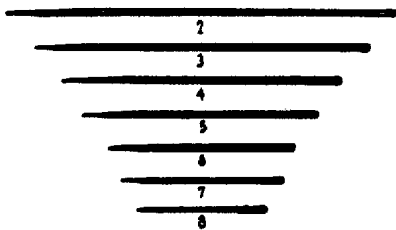
Fig. 0–5



Ob

B-3283

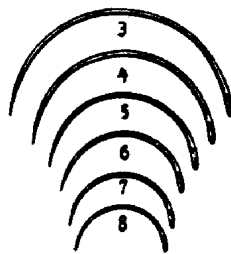
Fig. 1–5



Pc

B-3293

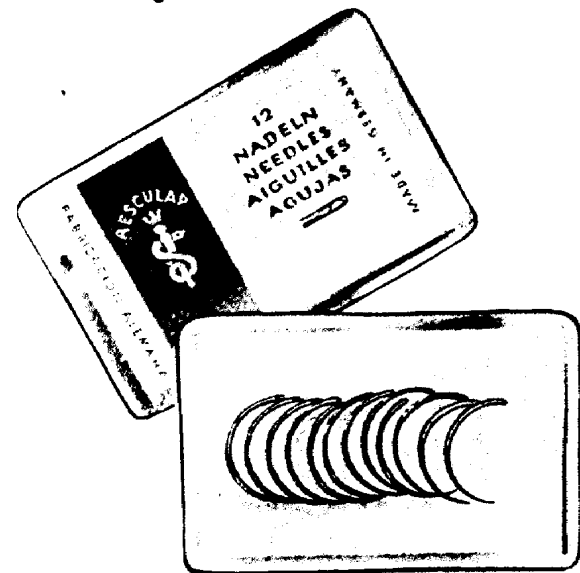
Fig. 2–8



Pb

B-3301

Fig. 3–8



Alle Nadeln werden mit offenem Ohr
in hermetisch verschweißten Packungen geliefert



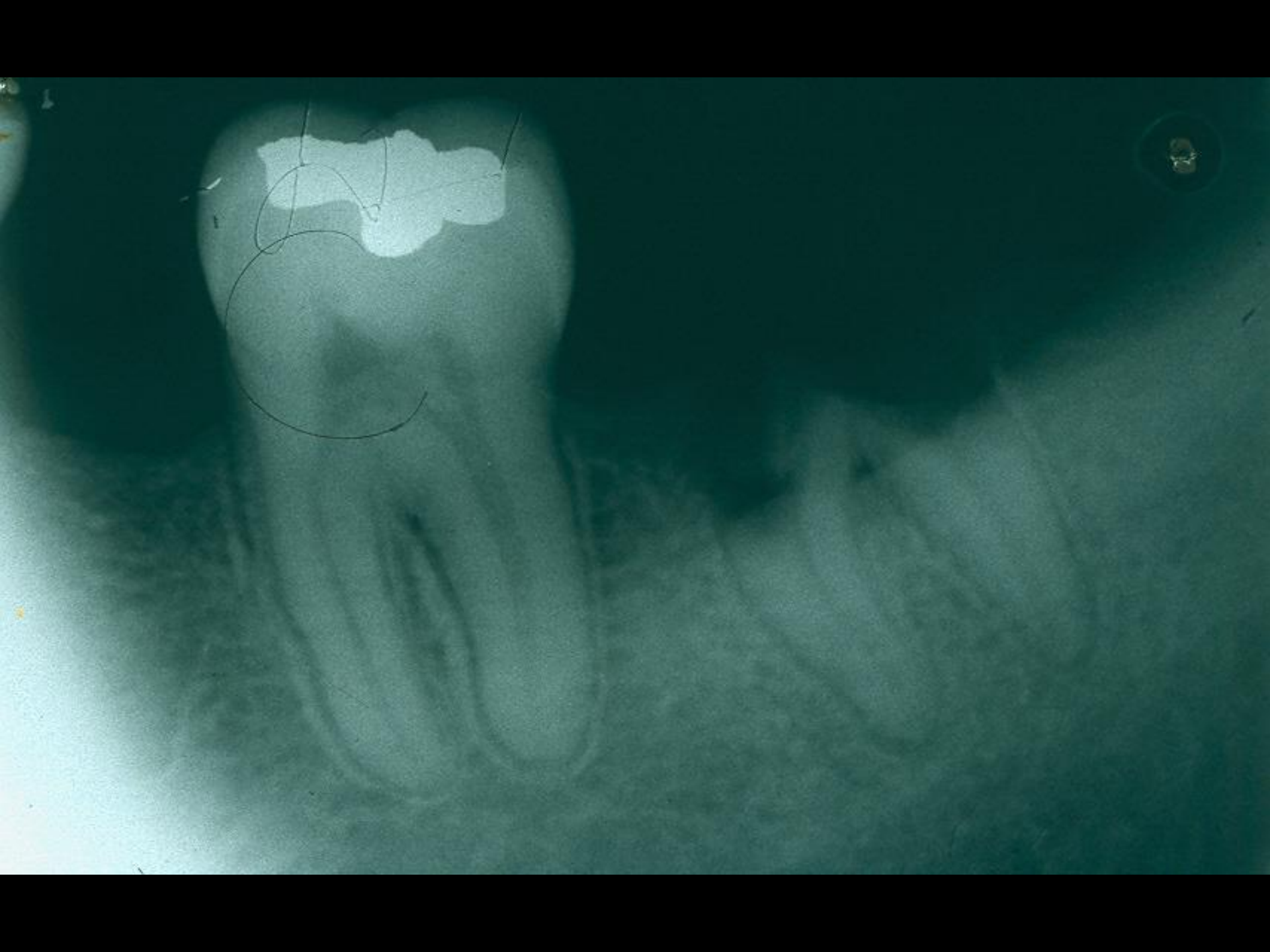Most common interventions

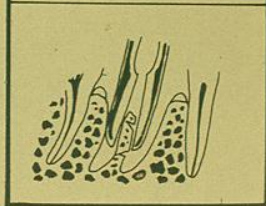
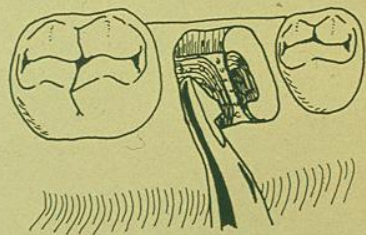

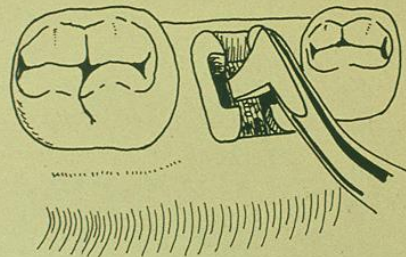

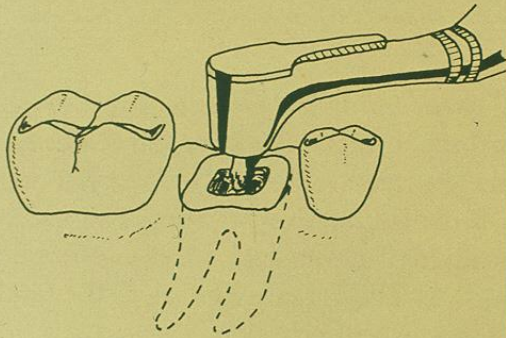
- Surgical removal of roots
- Surgical removal of impacted teeth
- Endodontic surgery (apicectomy + retrograde filling)
- Cyst surgeries
- Preprotetic surgical interventions
- Implantation

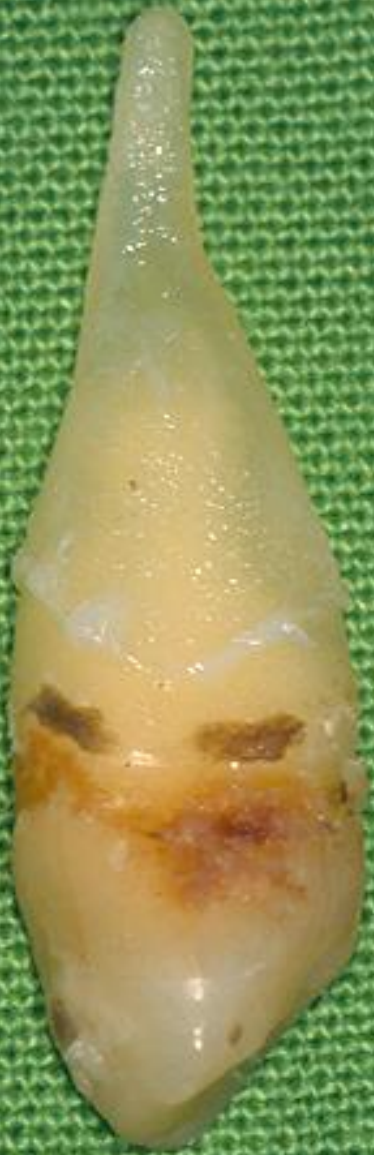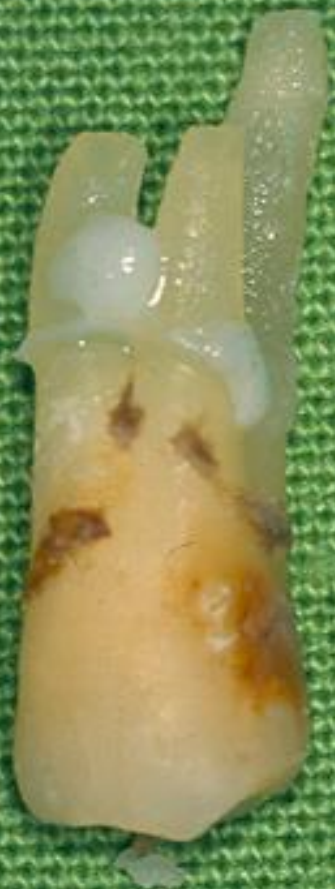Removal of roots

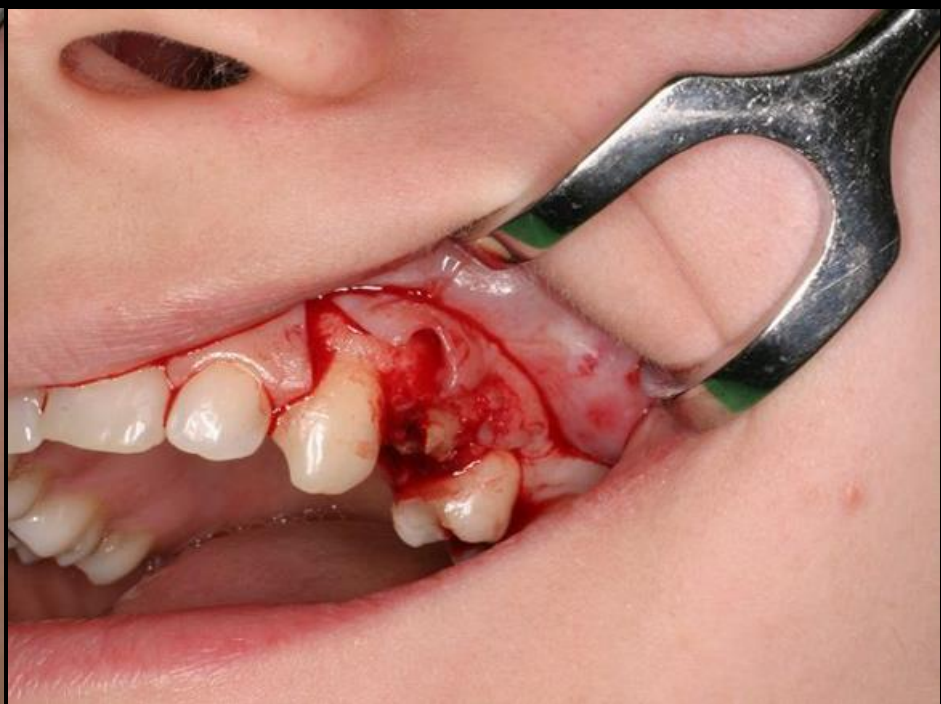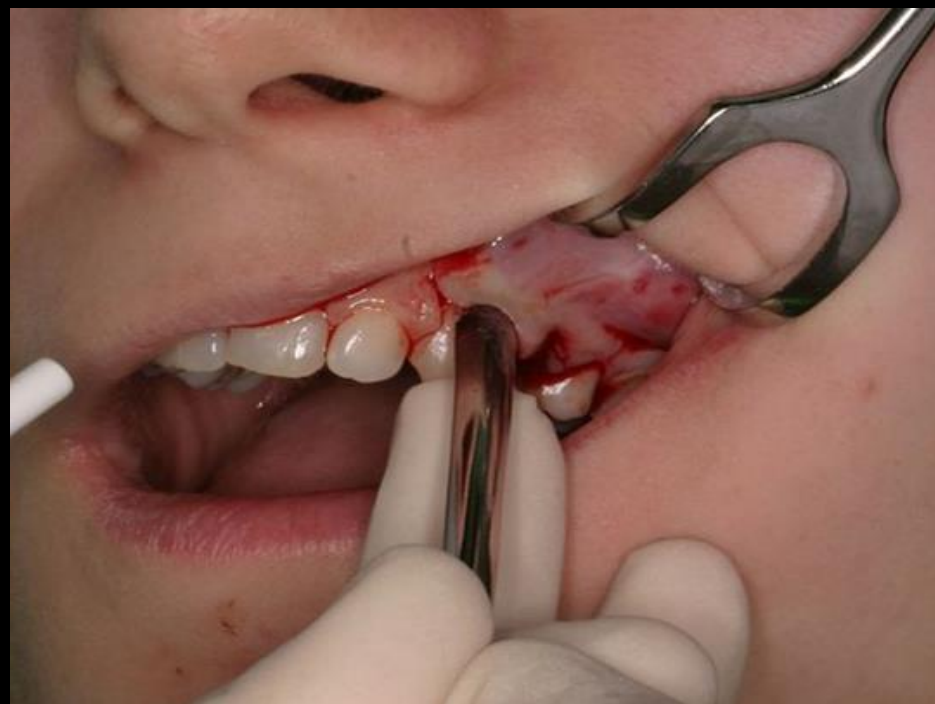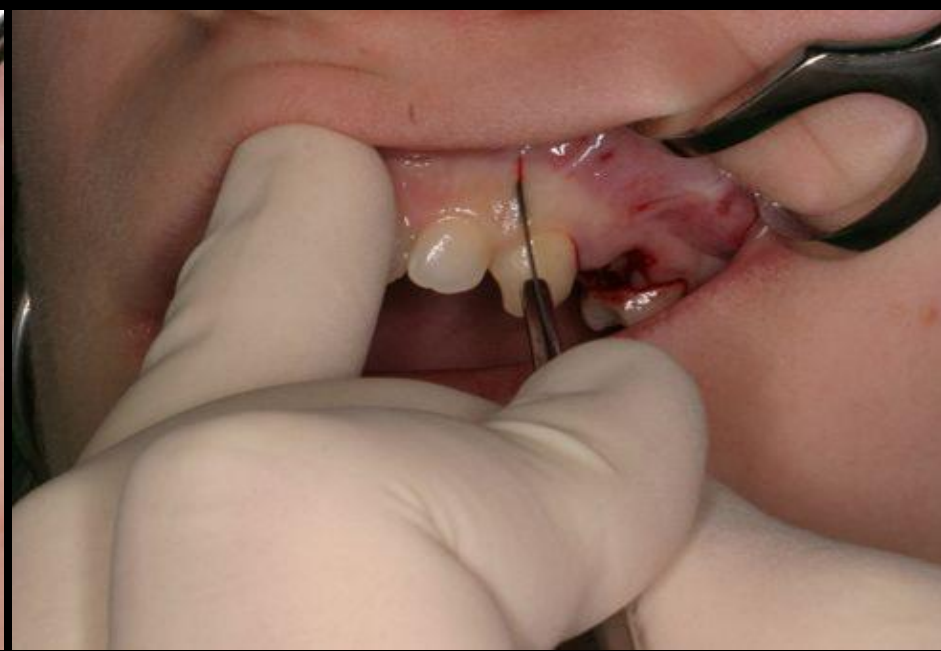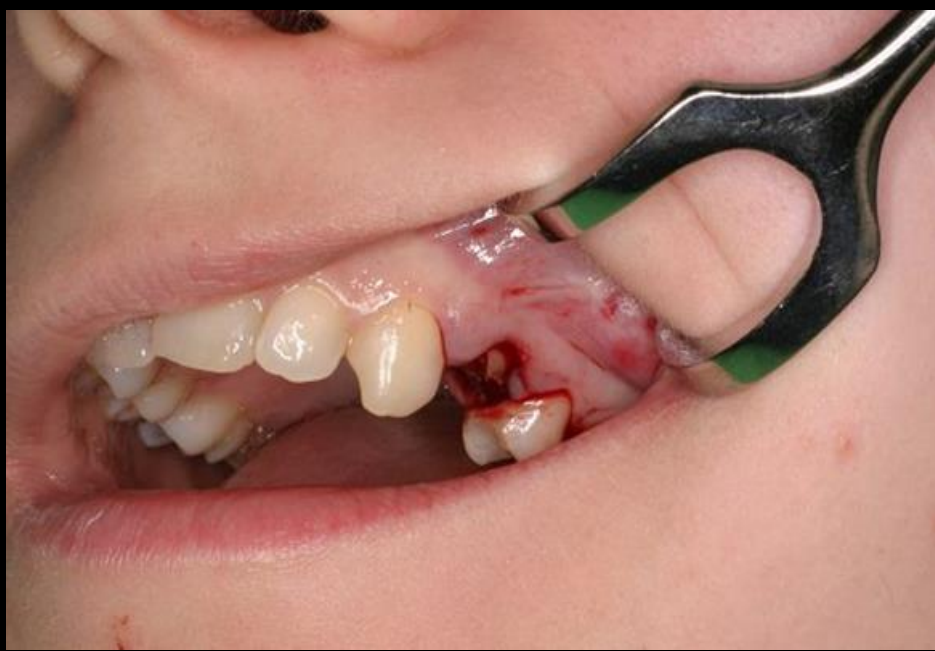- Fracture of the root
 - cervical
 - middle
 - apical
- root between the soft tissues

Removal : forceps
elevator
dissection
surgical





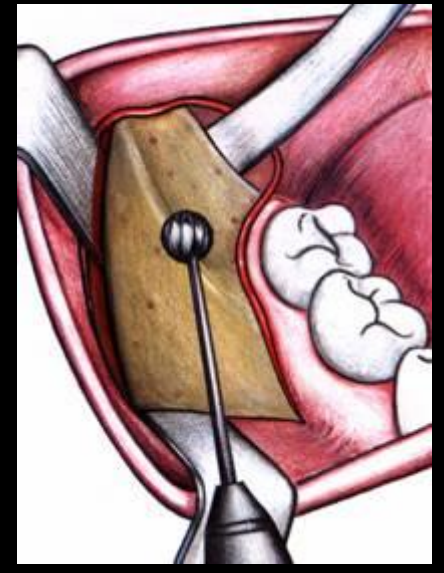
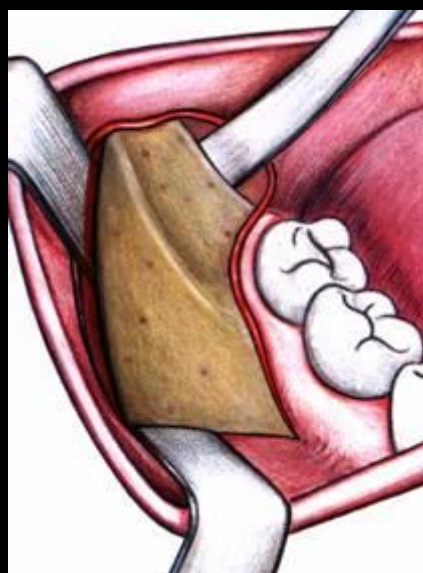
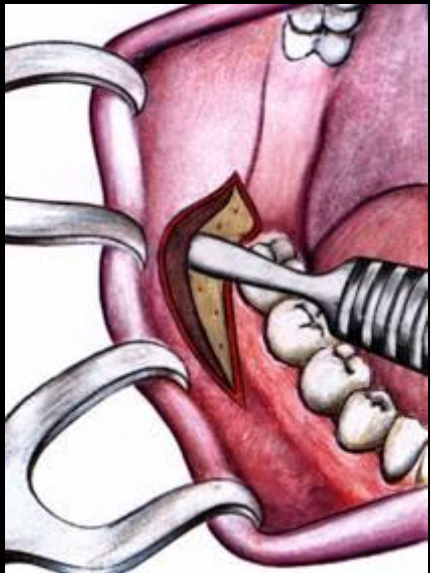
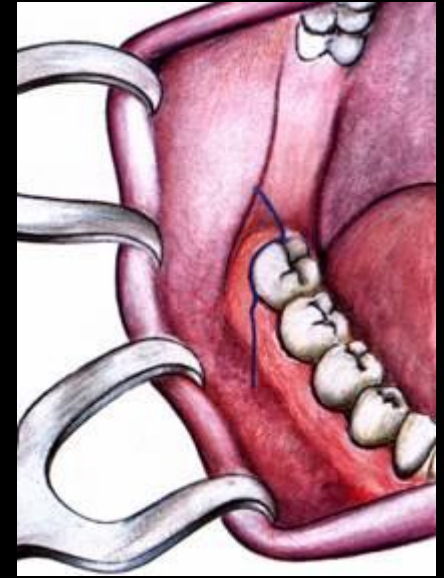
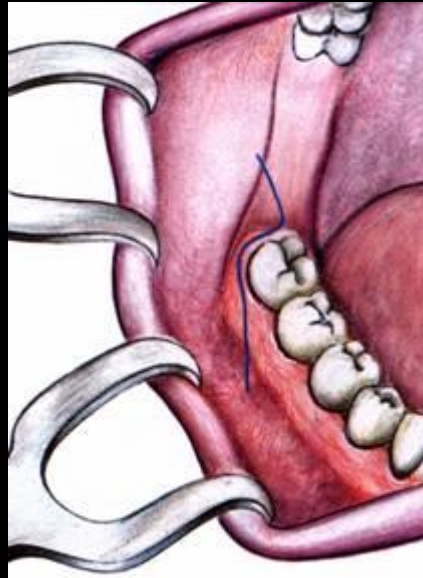
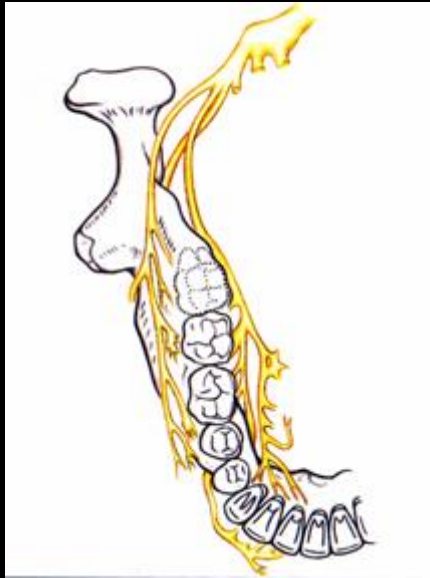




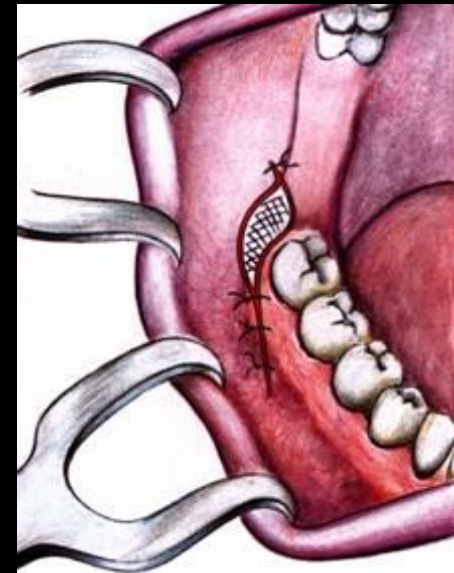
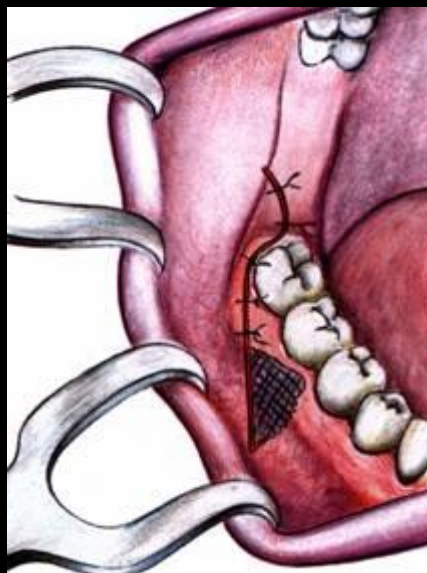
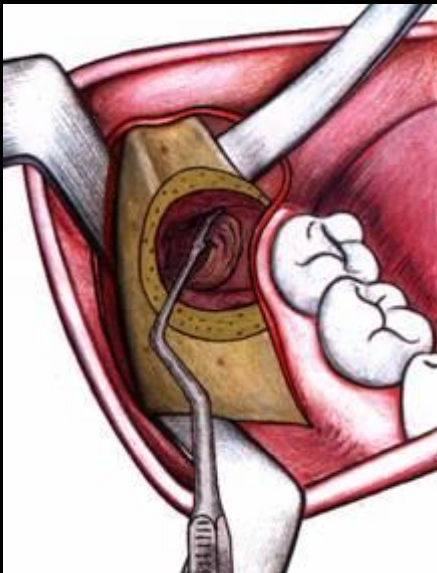
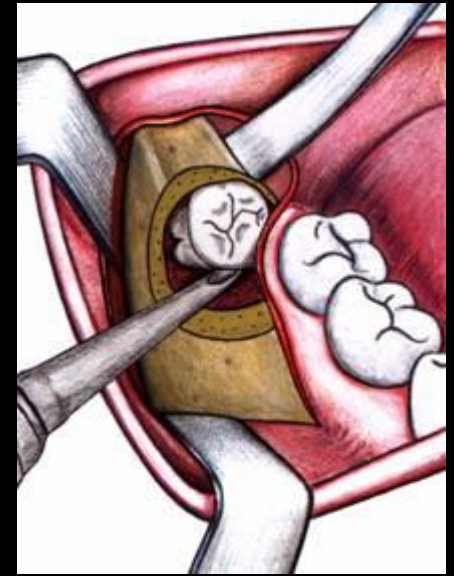
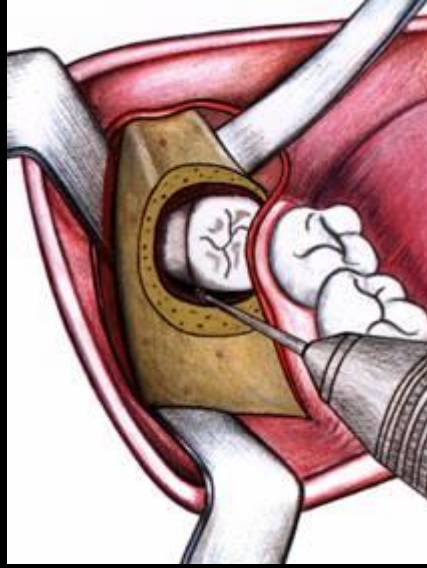
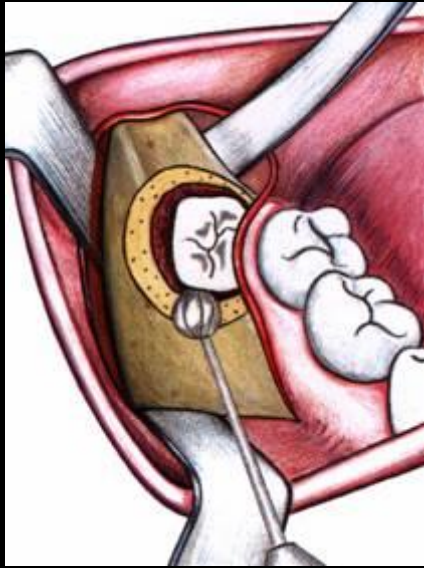
Removal of impacted teeth

- Impacted tooth = the development of the tooth is completed but its breakthrough is not realized due to a mechanical obstacle (usually in the case of lower third molars)
- Retained tooth = the development of the tooth is complete or partial and does not show a tendency to break through (there is no mechanical obstacle, usually in the case of upper canines)
- „partially erupted“: not completely surrounded by bone

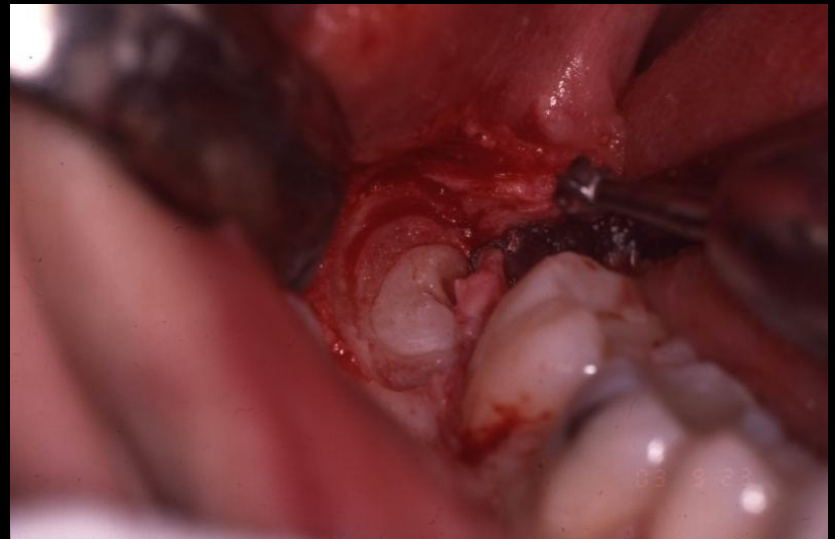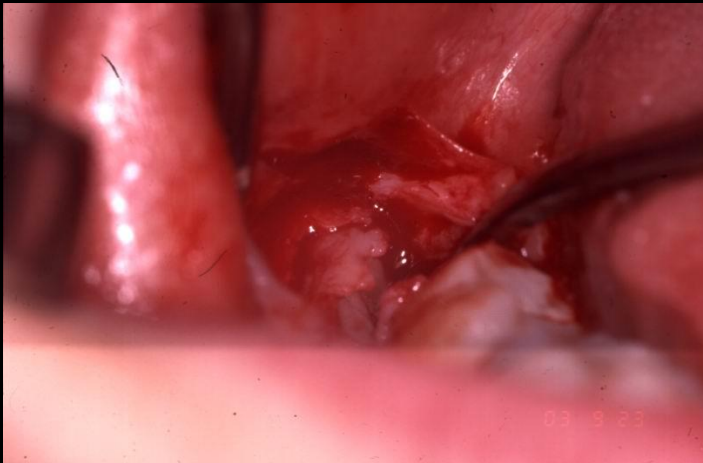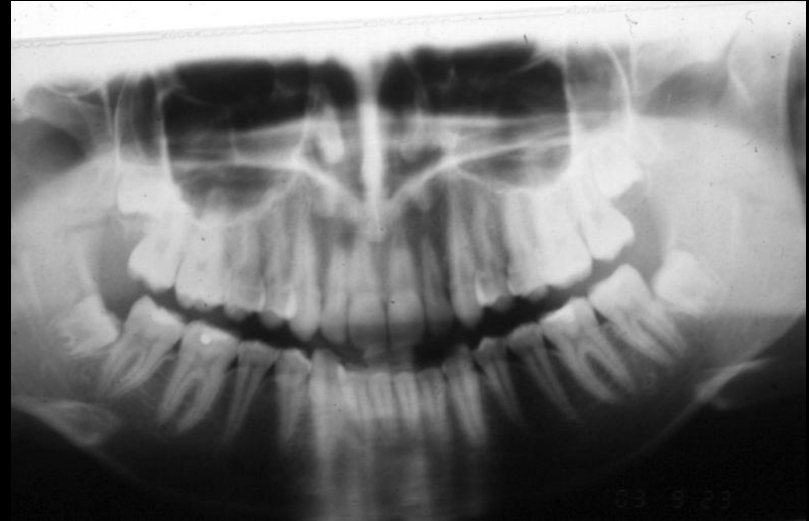
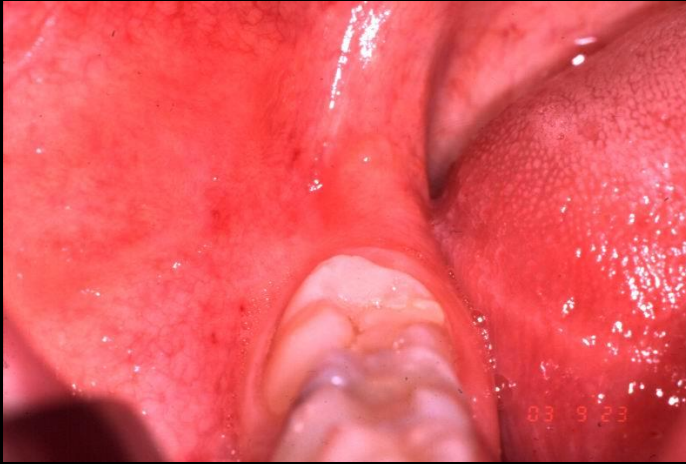Lower third molar



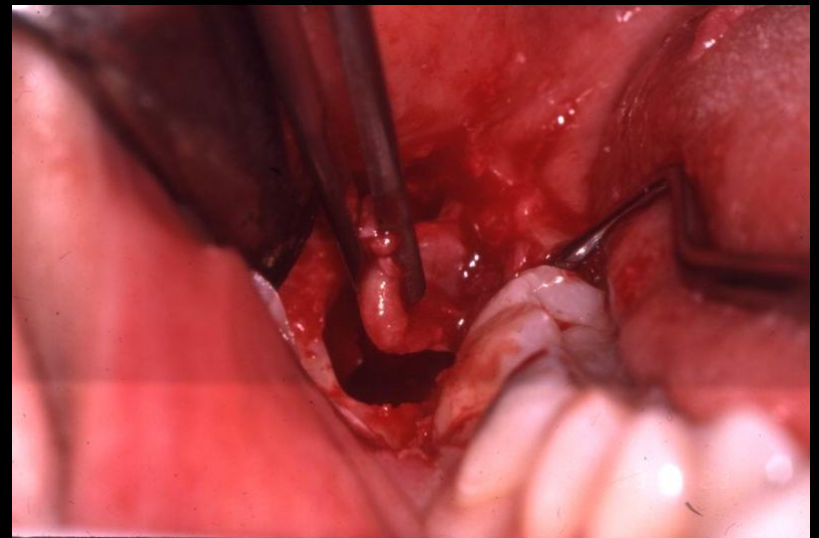
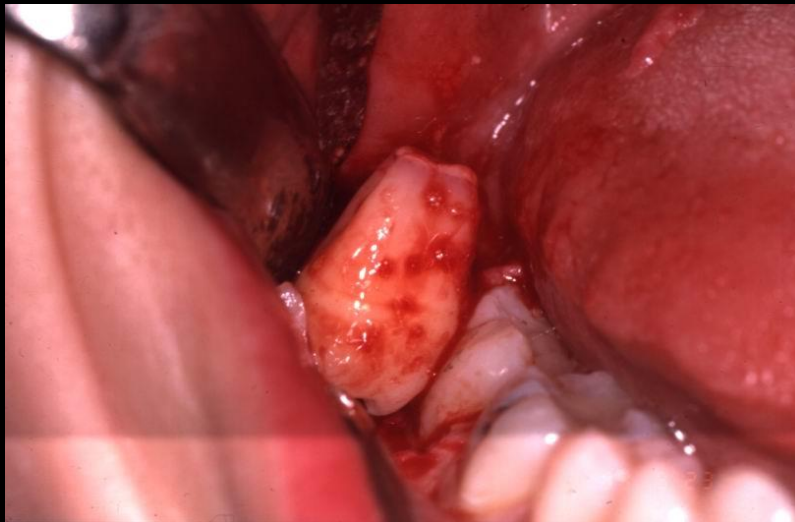
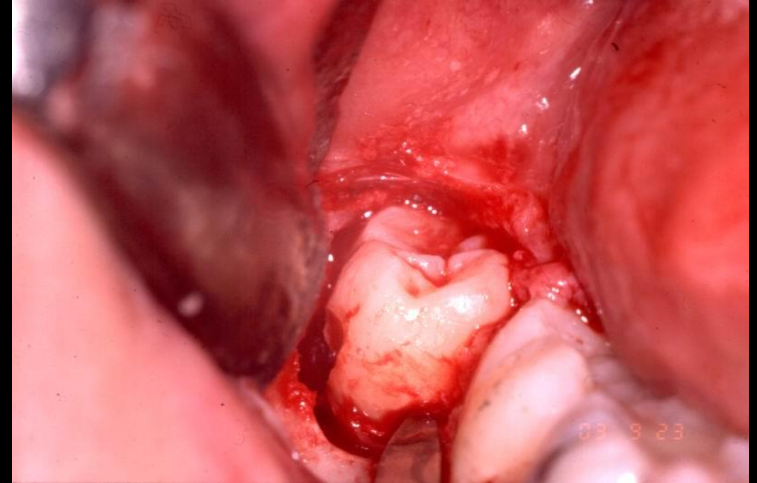
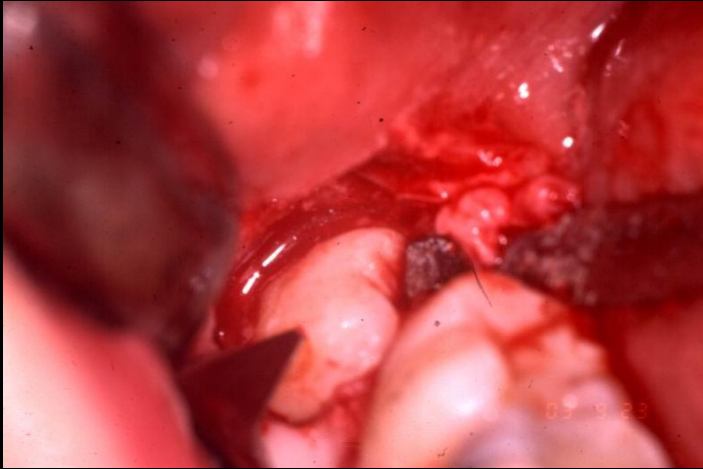
Lower third molar



Lower third molar



Lower third molar



Upper canines

Treatment

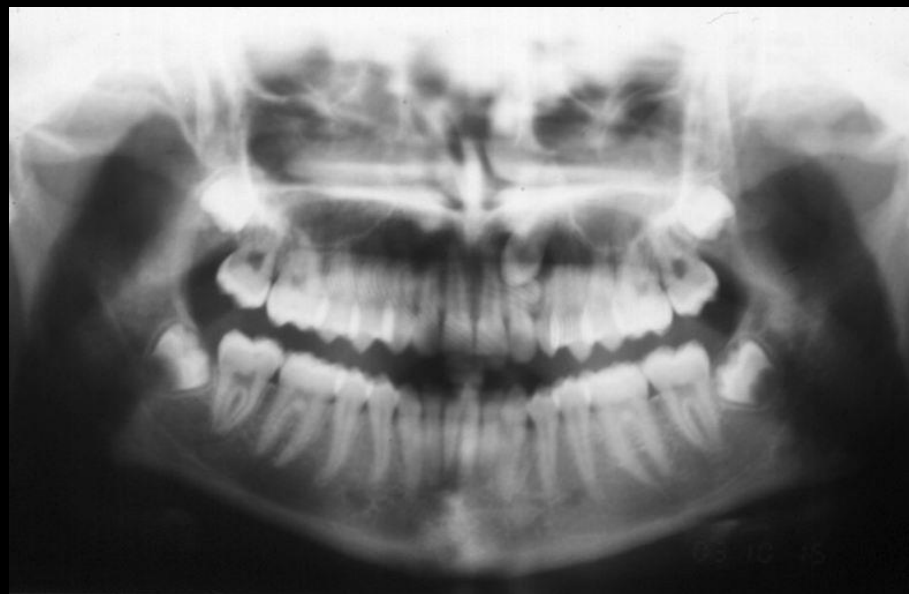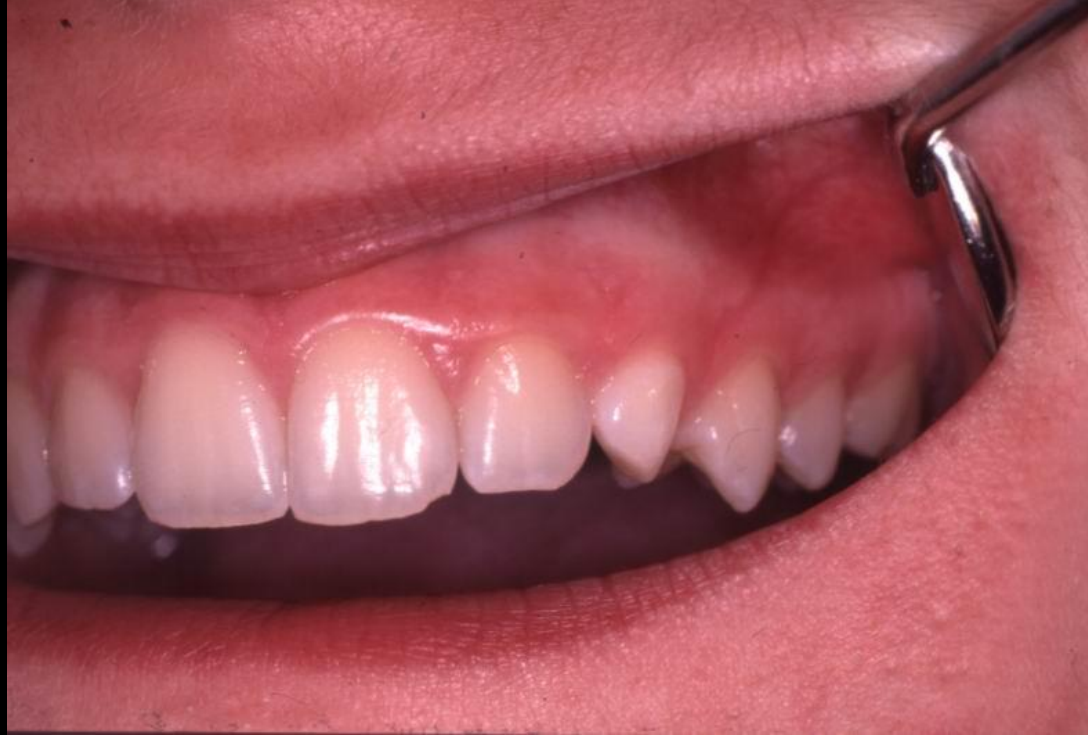- 1.Surgical-orthodontic**
- 2.Surgical: removal**
- 3.Surgical: transplantation**

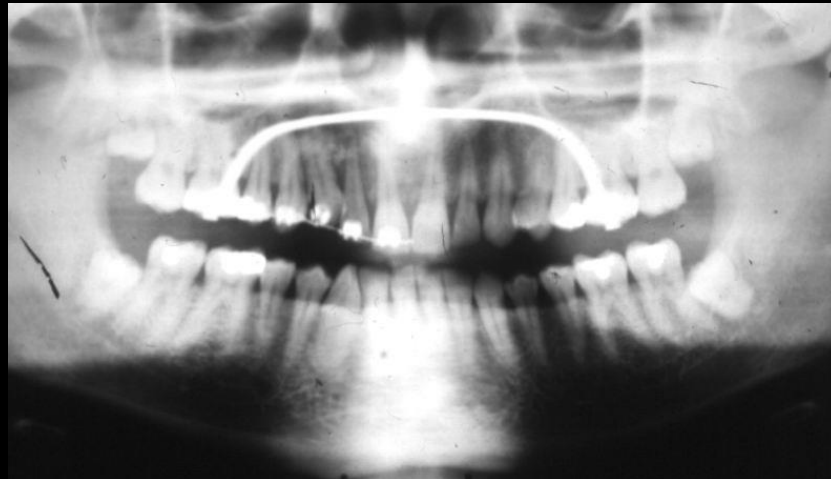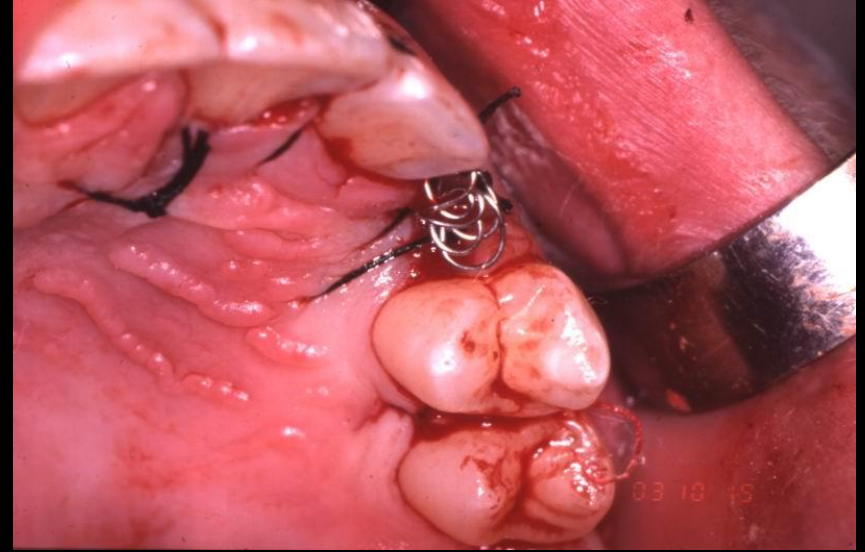
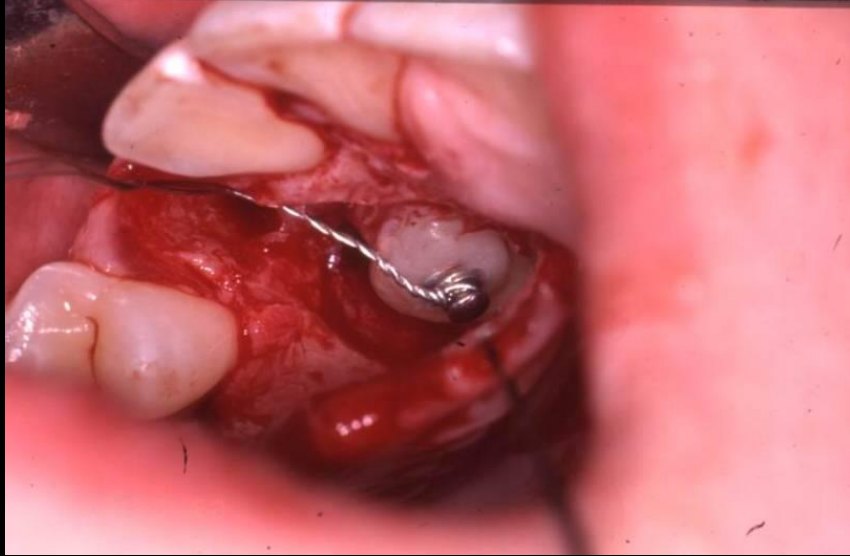Upper canines

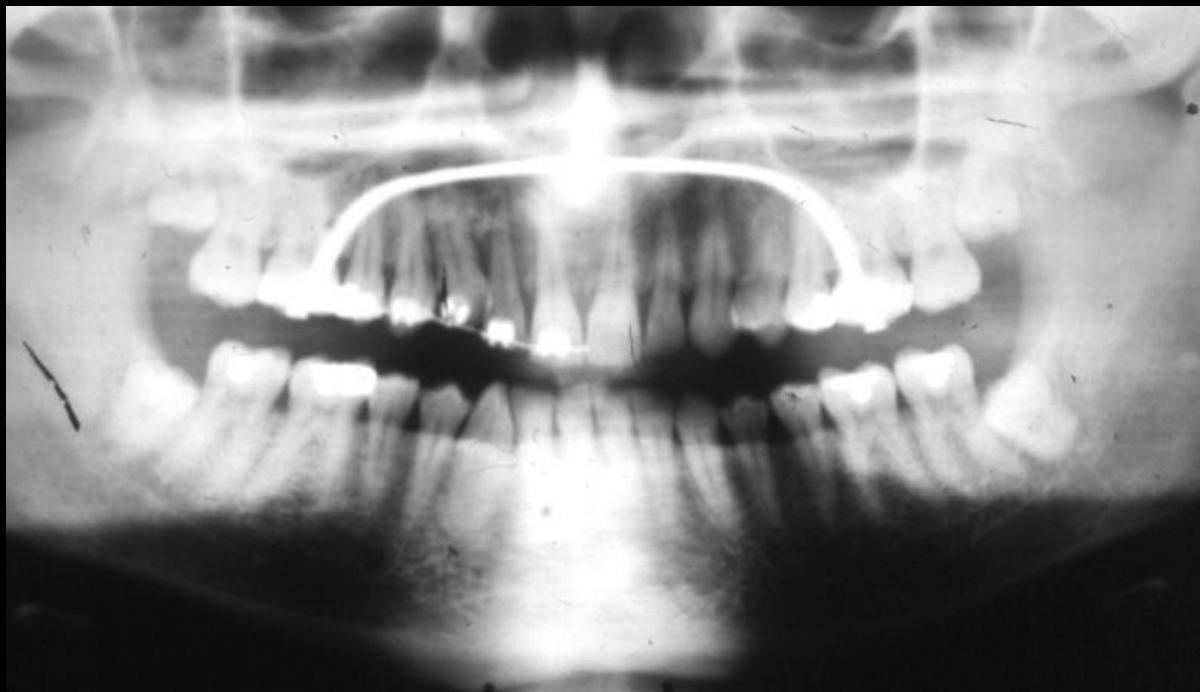
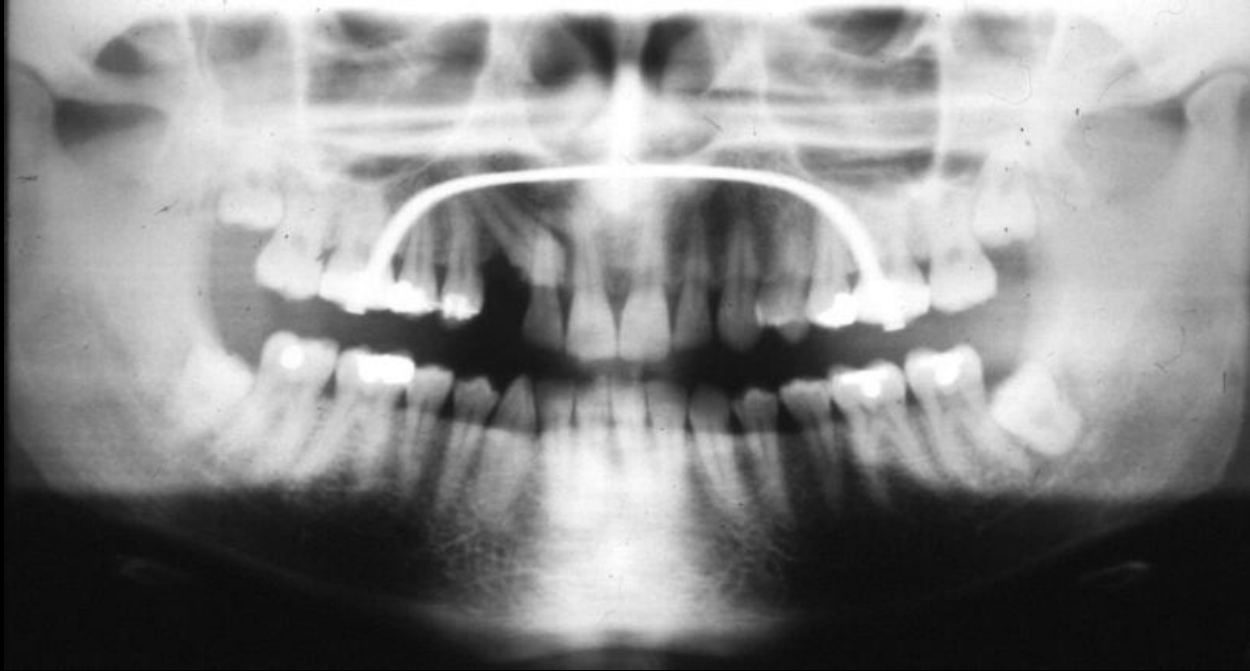
Localisation:

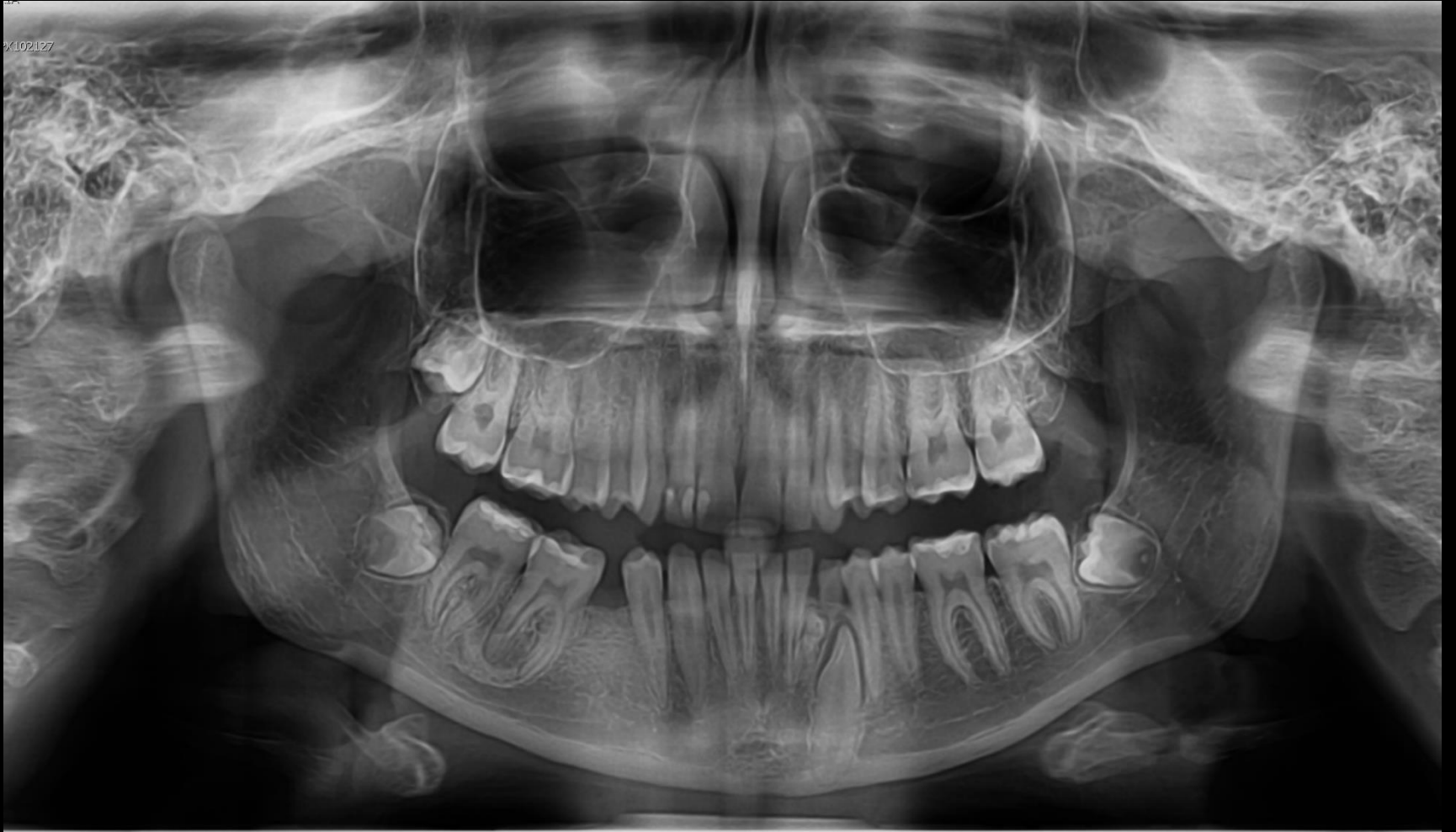Palatinal 85%

Buccal 15%









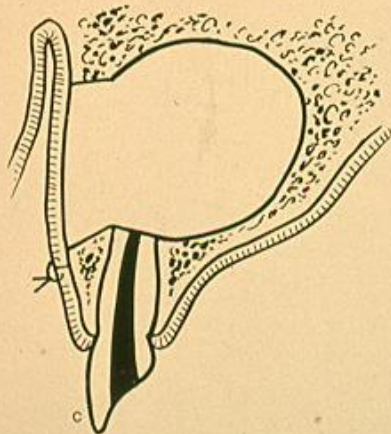
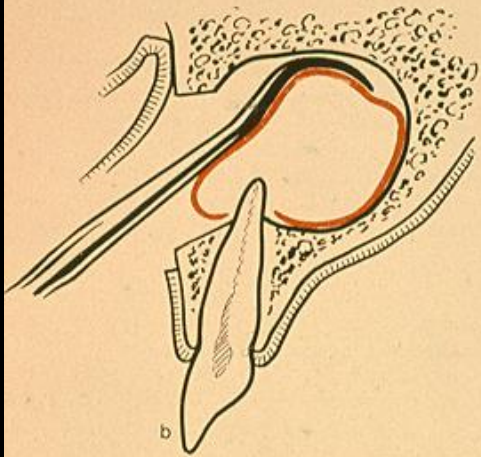
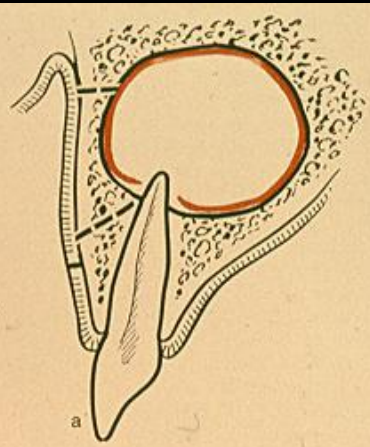
PX102127

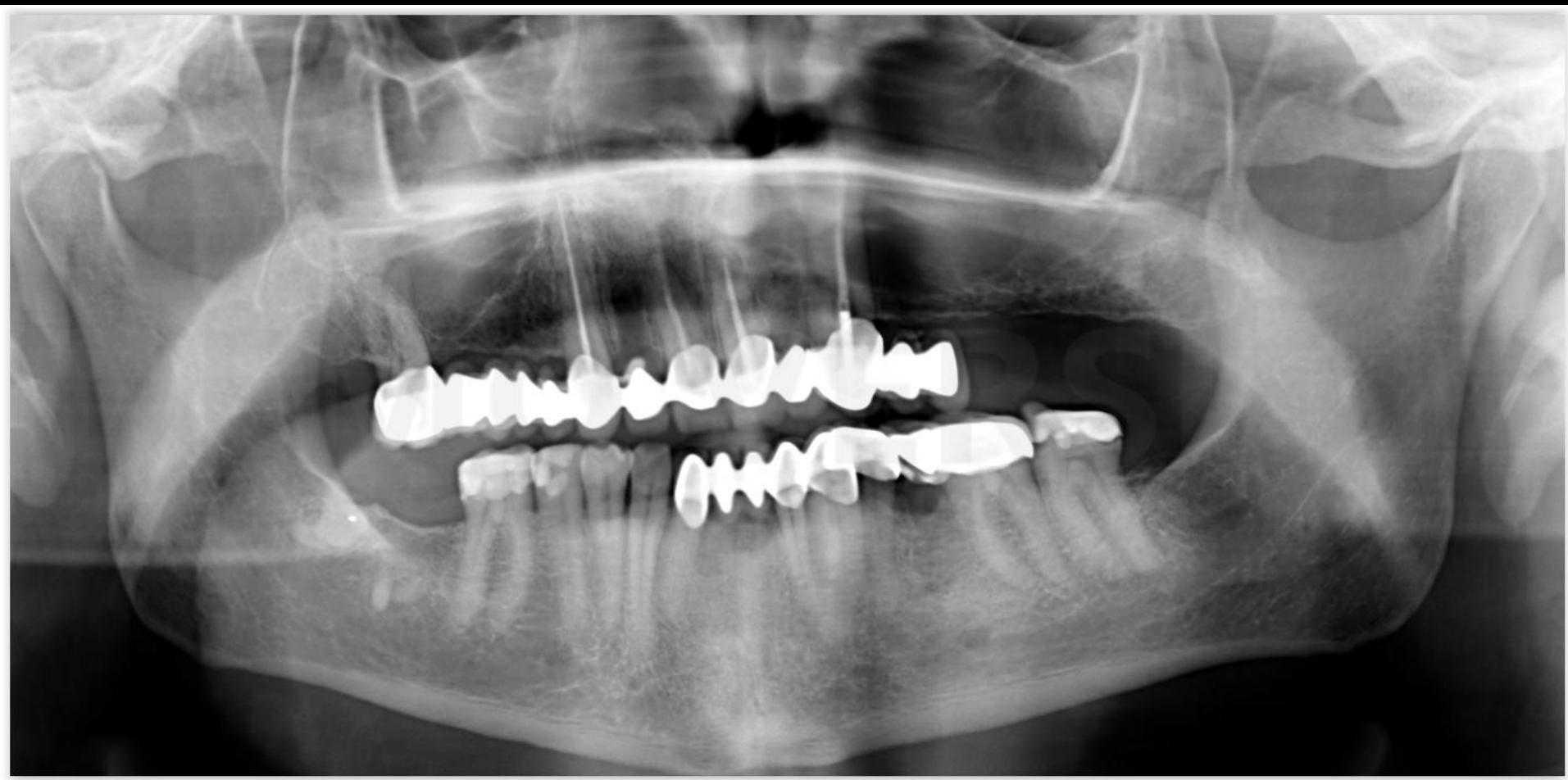Cysts

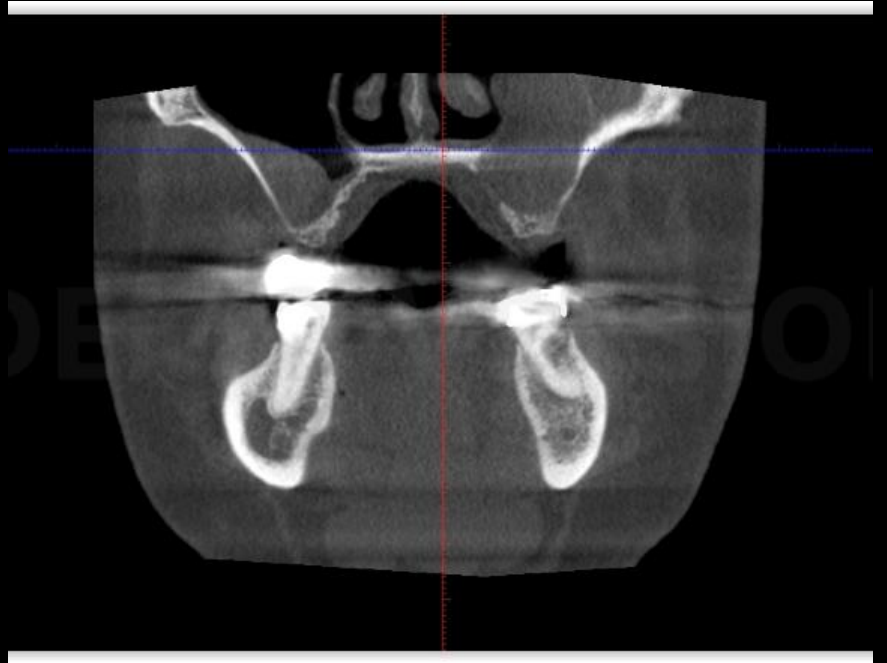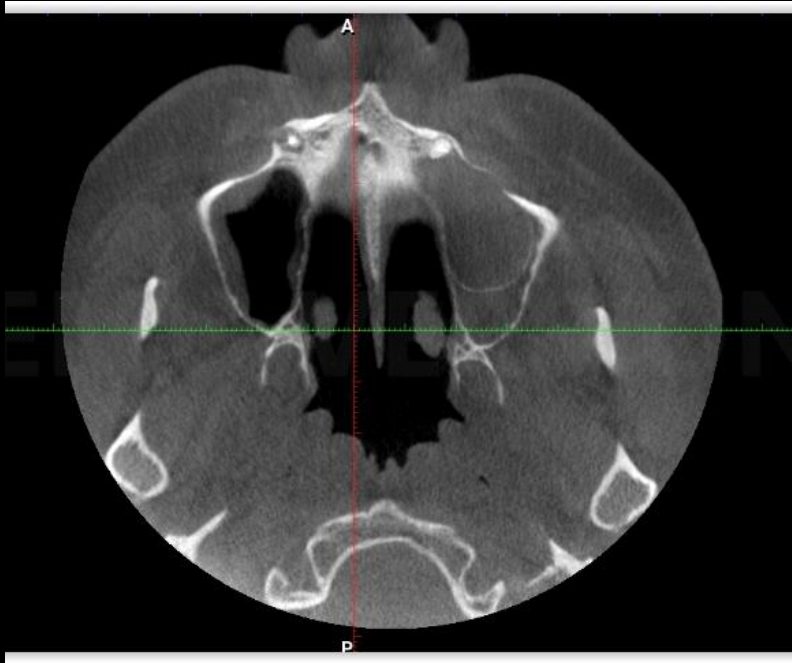
Cyst definition:

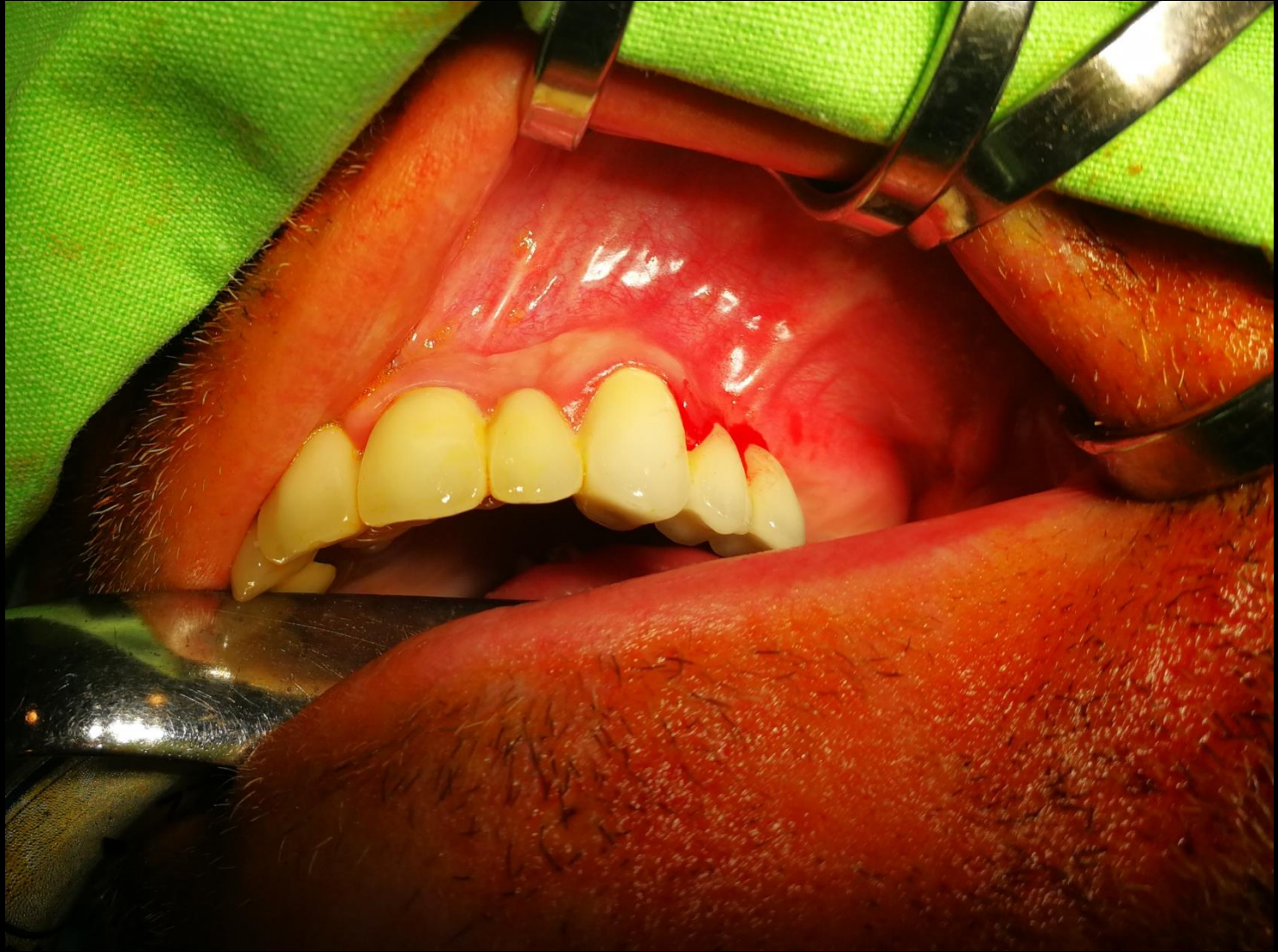An epithelium lined sac, surrounded by a connective tissue wall. It is usually filled with fluid or soft material.

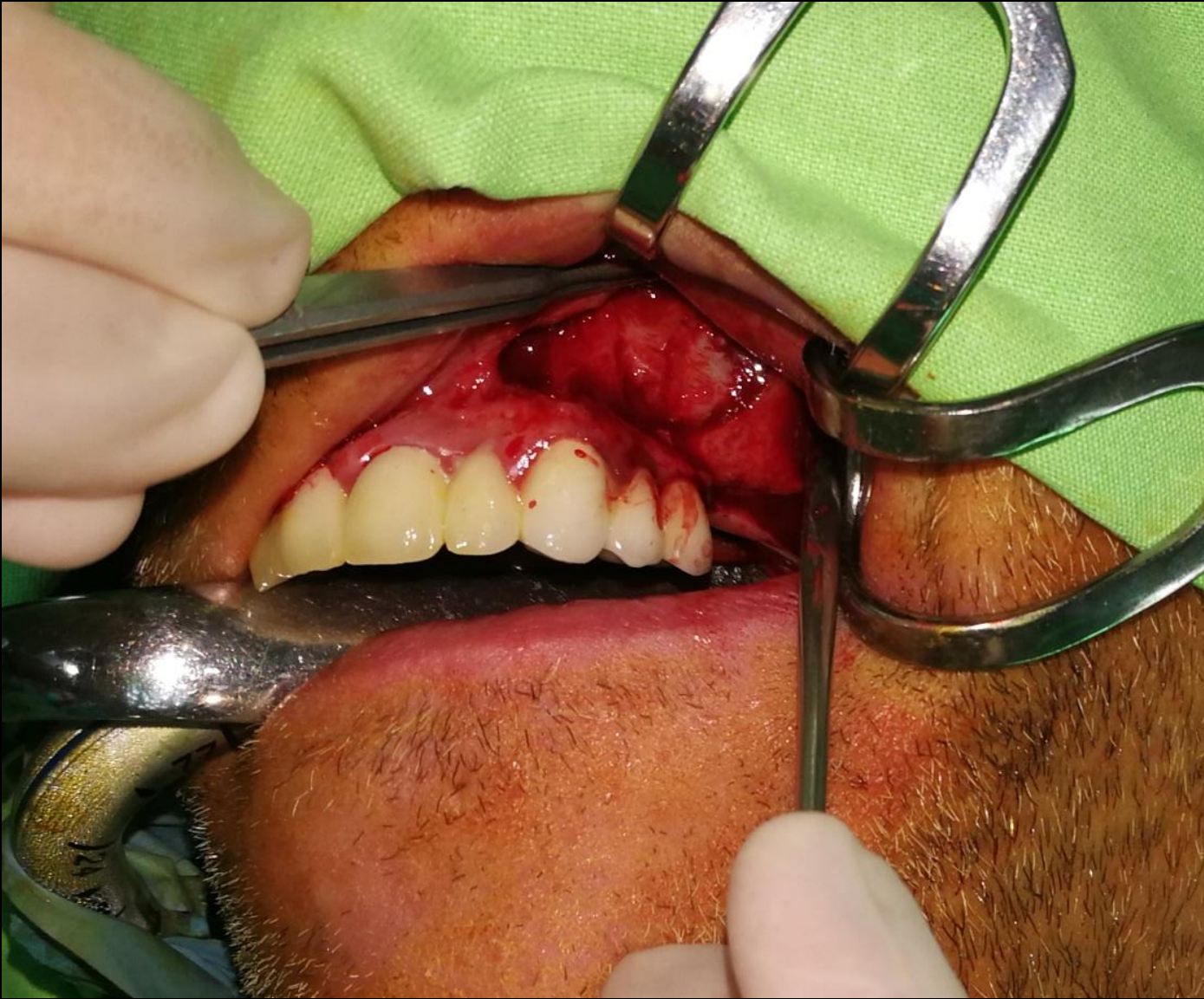A cyst is a tumor-like formation, that can originate from a developmental disorder, or an inflammatory process. It is actually not a tumor, because its growth is not due to cell proliferation (it expands, does not infiltrate).

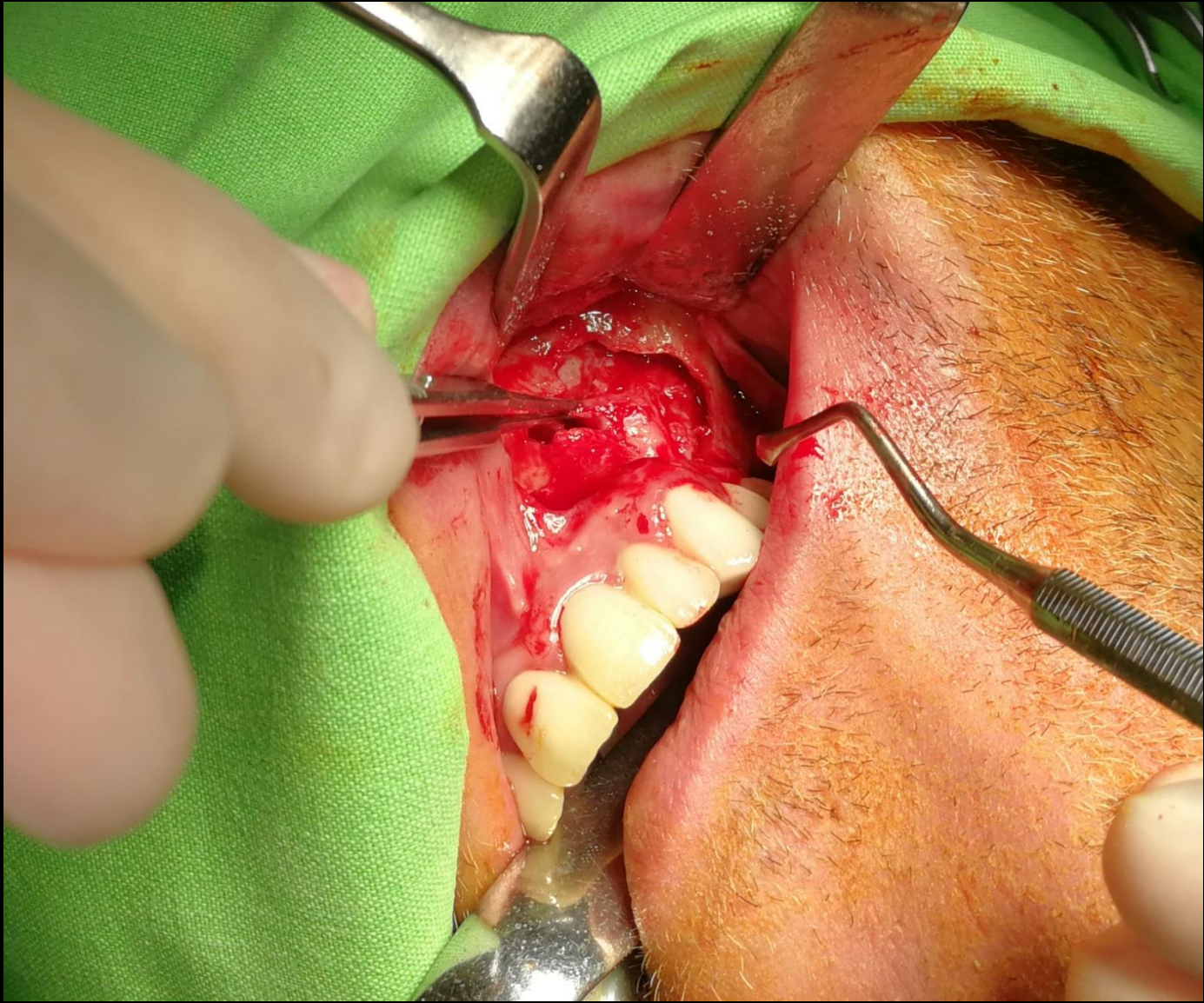


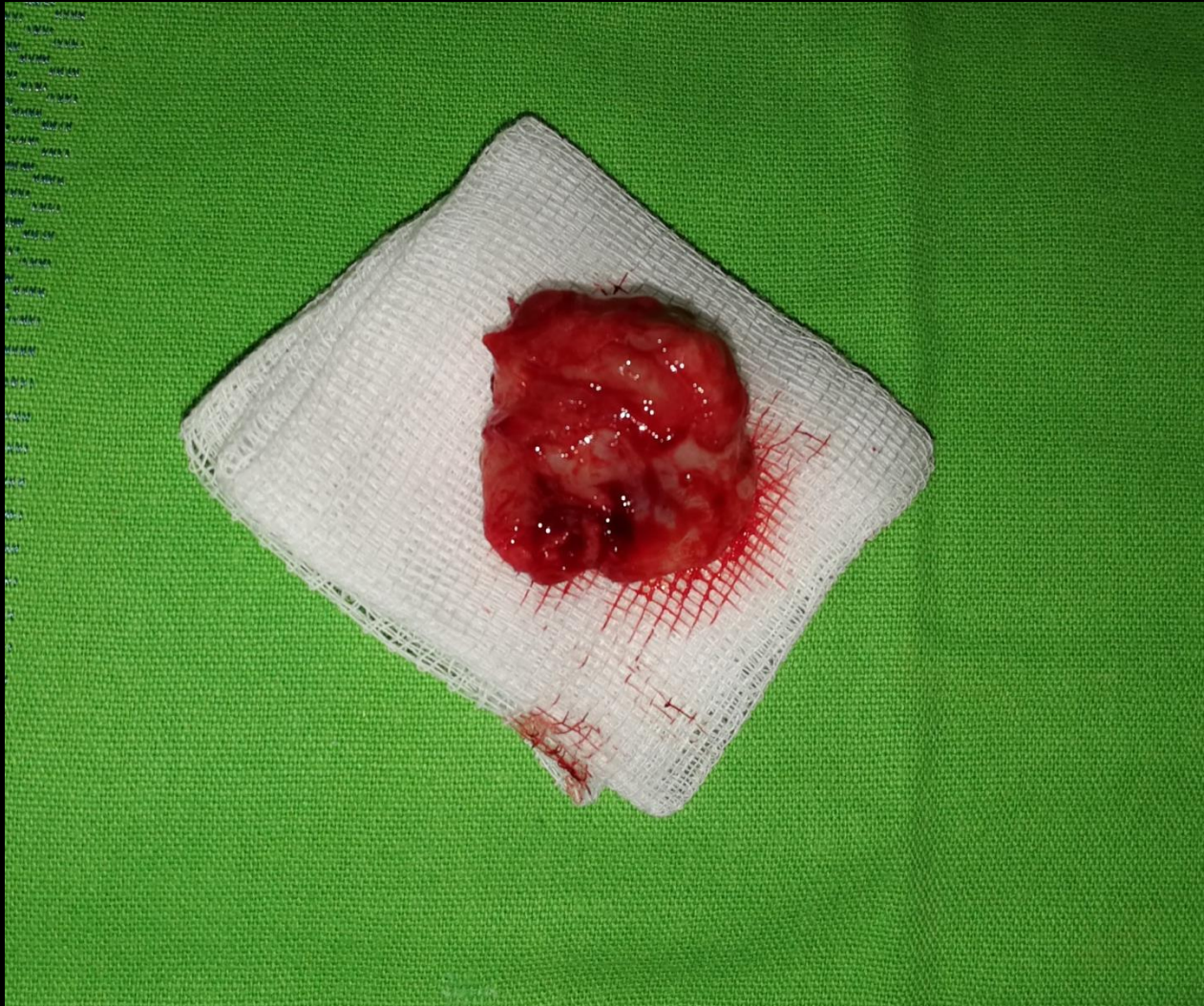


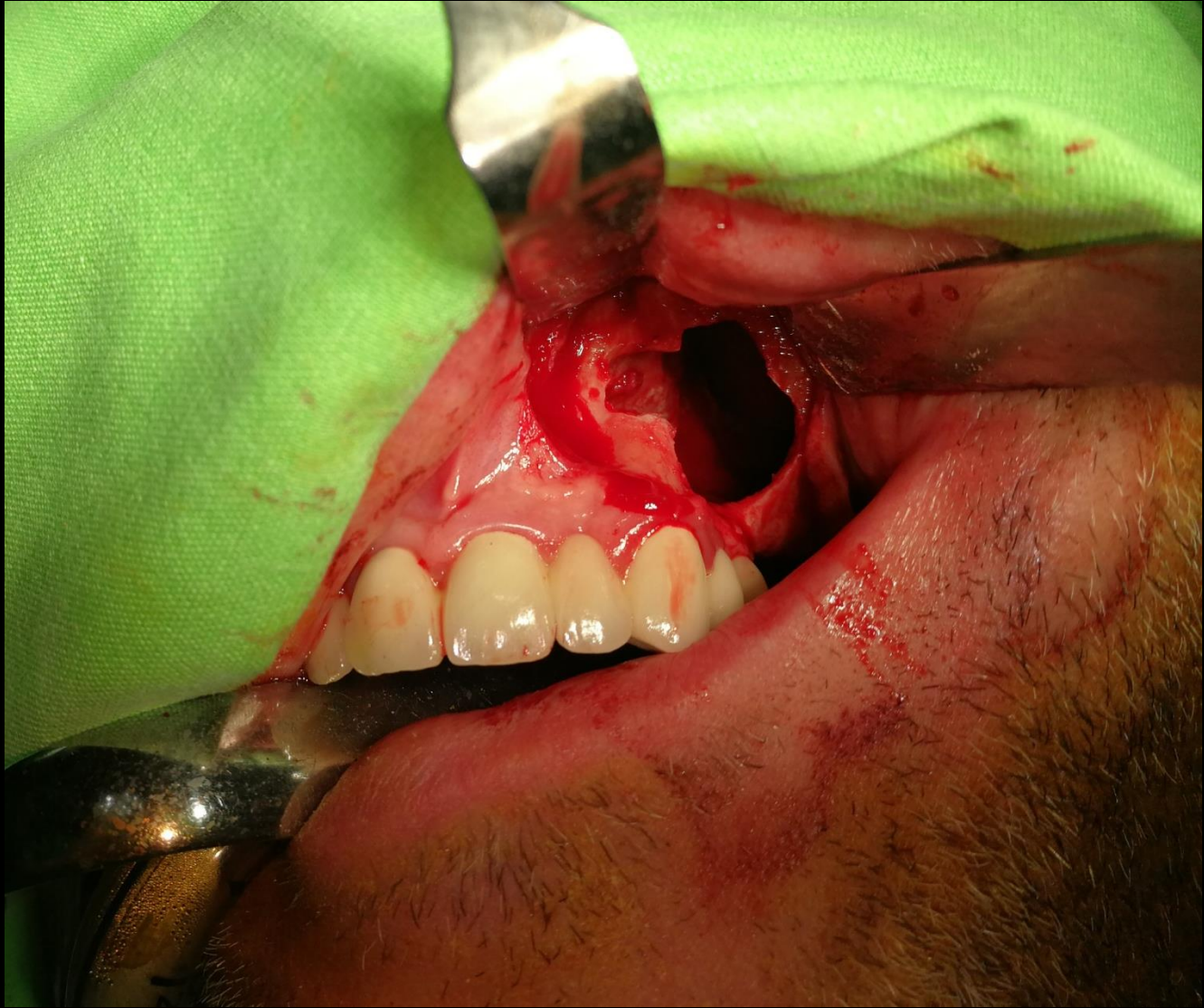


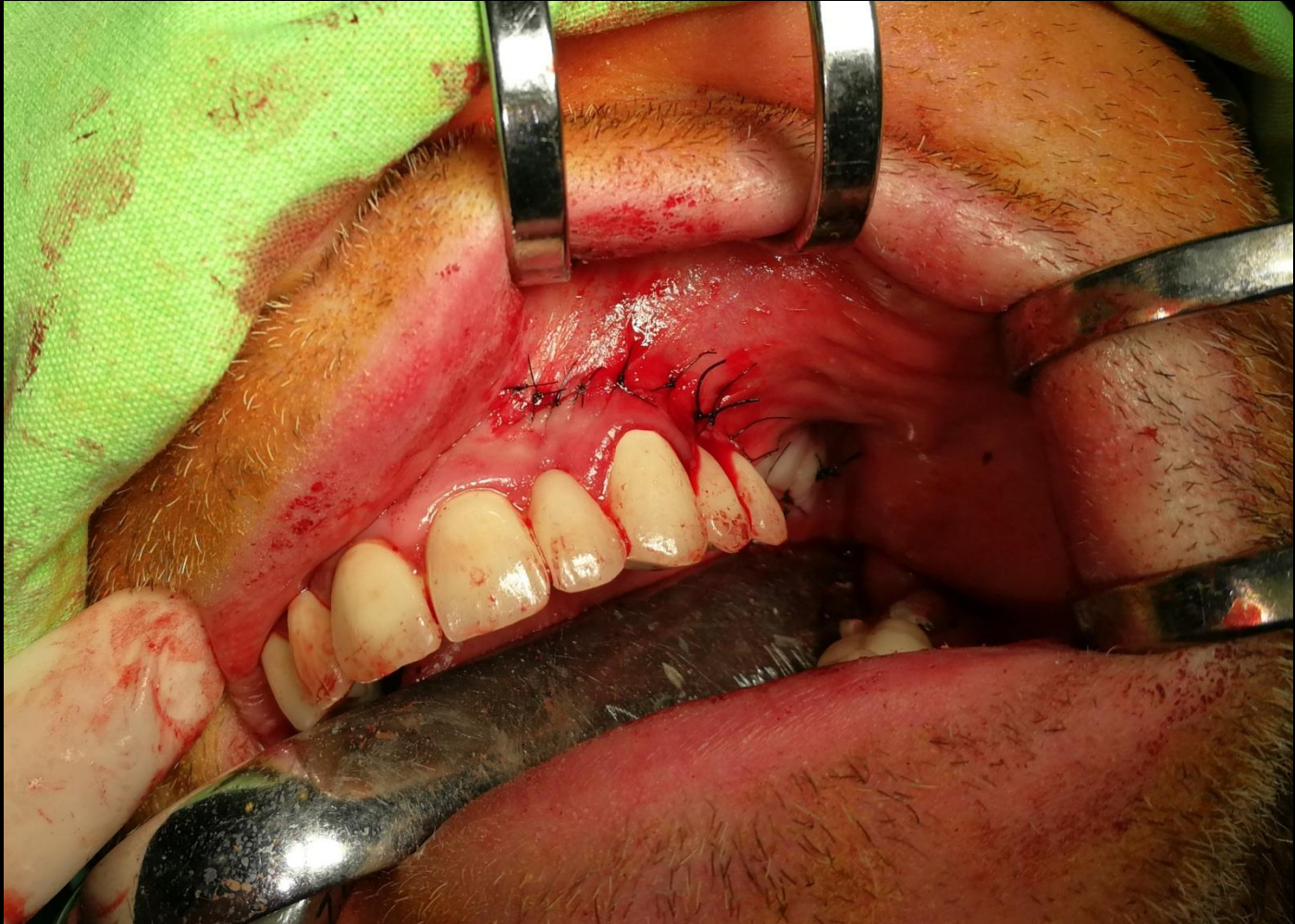




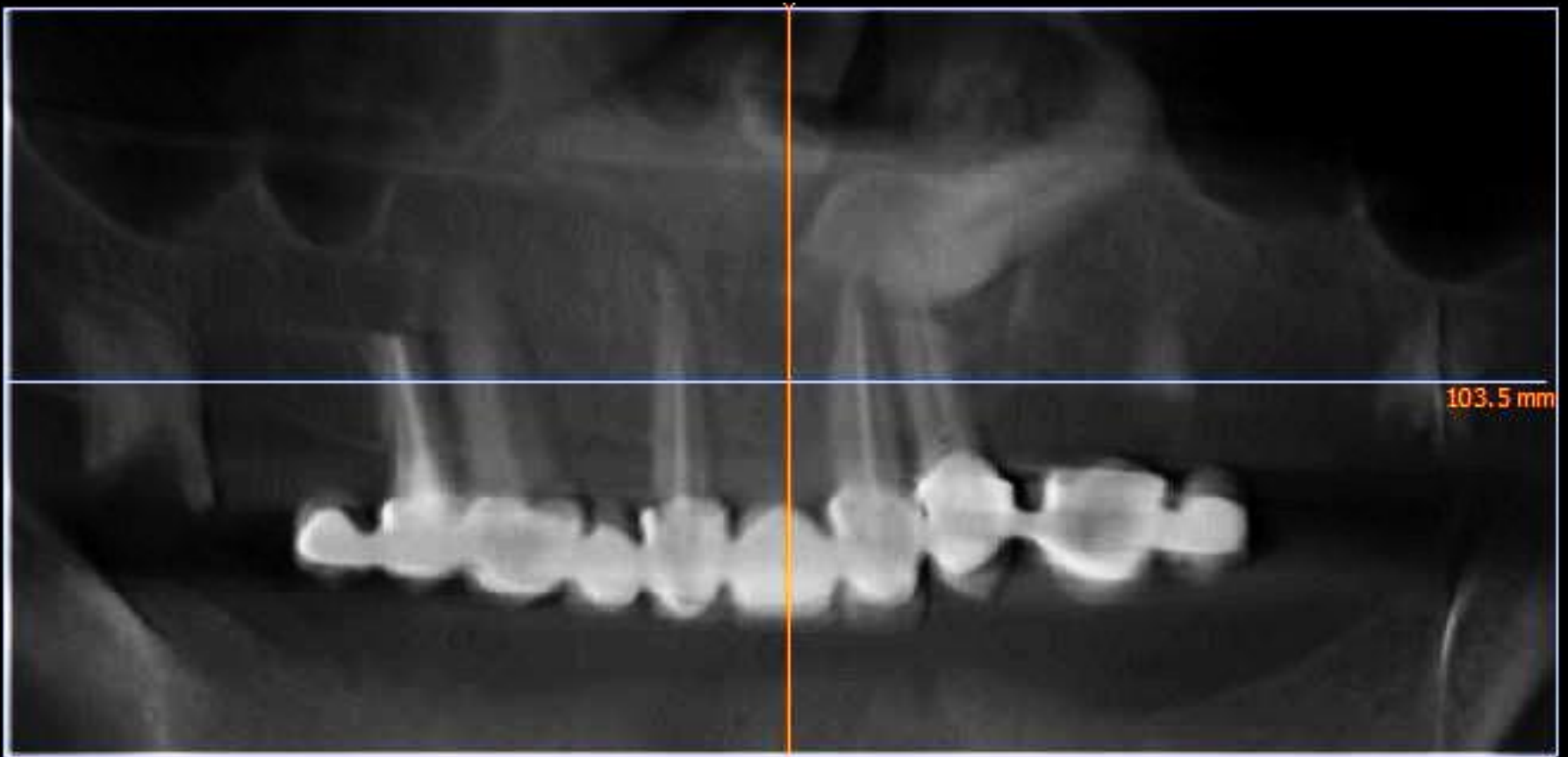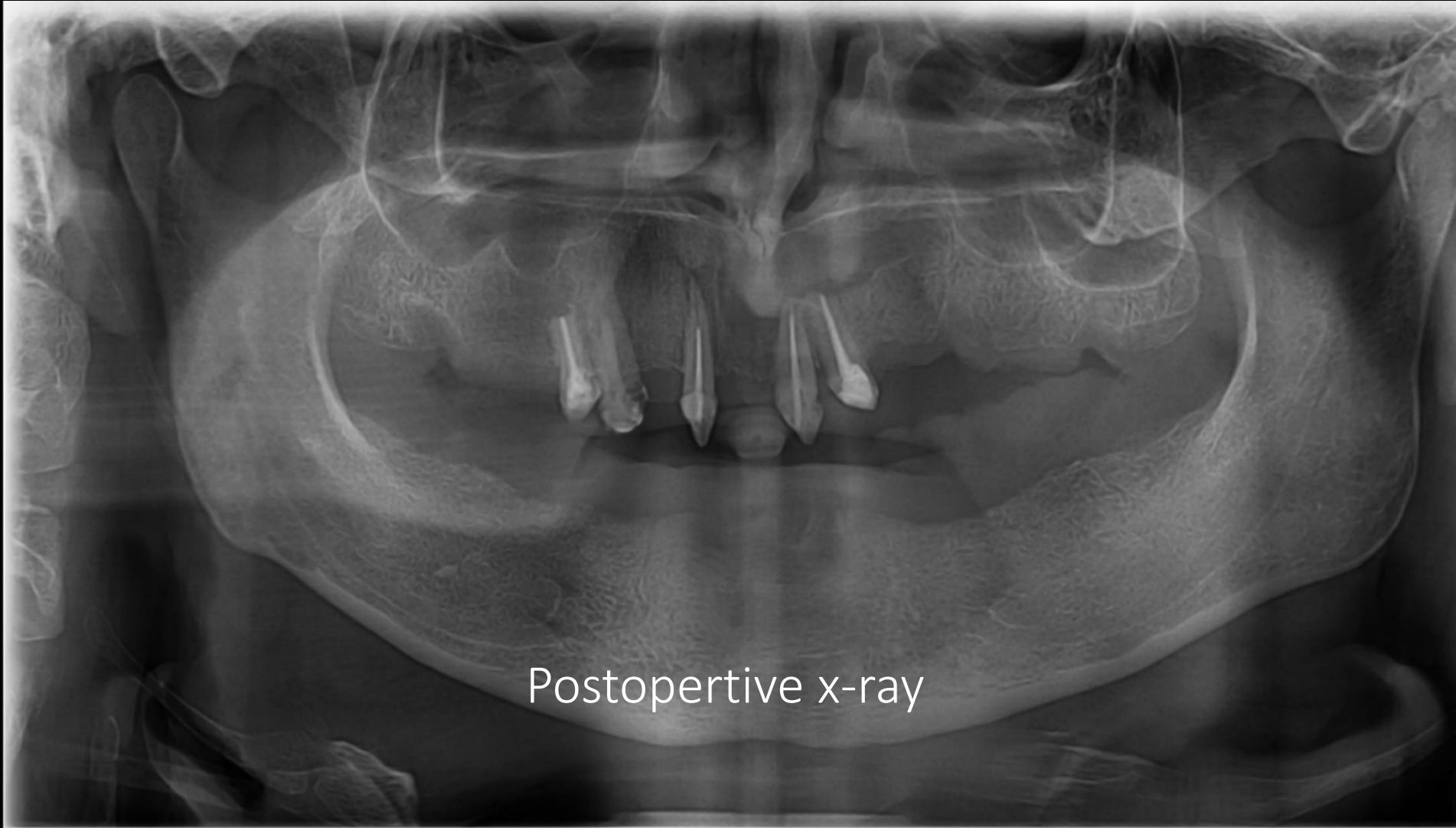






Retained upper canine+cyst removal





Postoperative x-ray

Dental implants

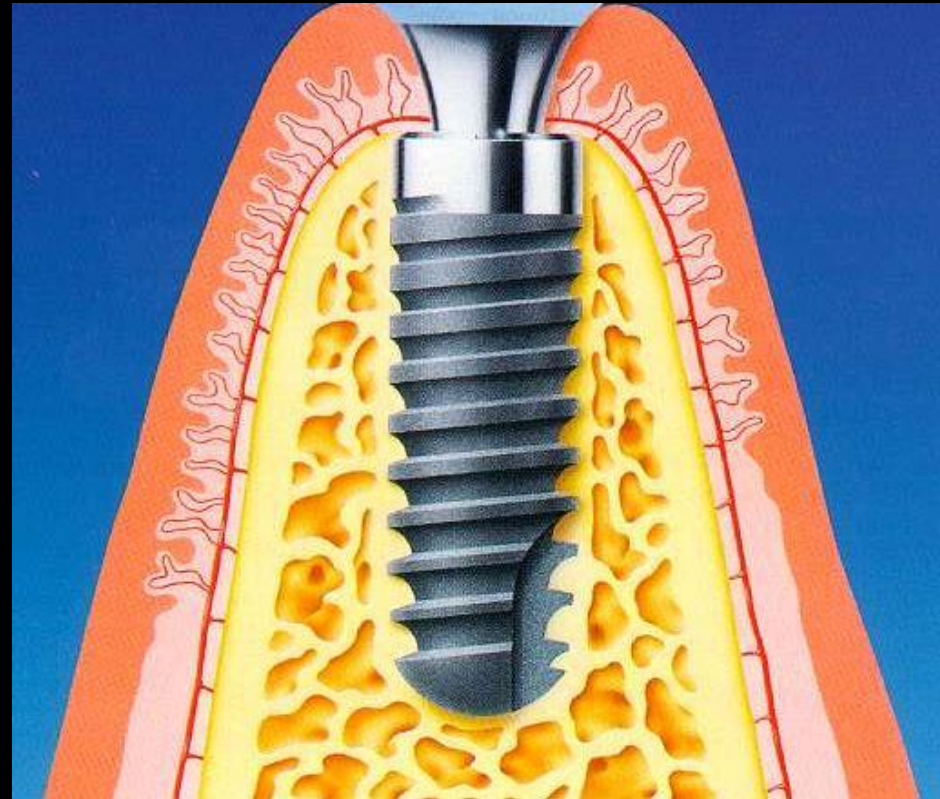


Enosseal screw type implants

Oral / dental / implantology is a new interdisciplinary field of dentistry, its aim is the prosthetic rehabilitation, but it also uses surgical, periodontal and orthodontic methods.

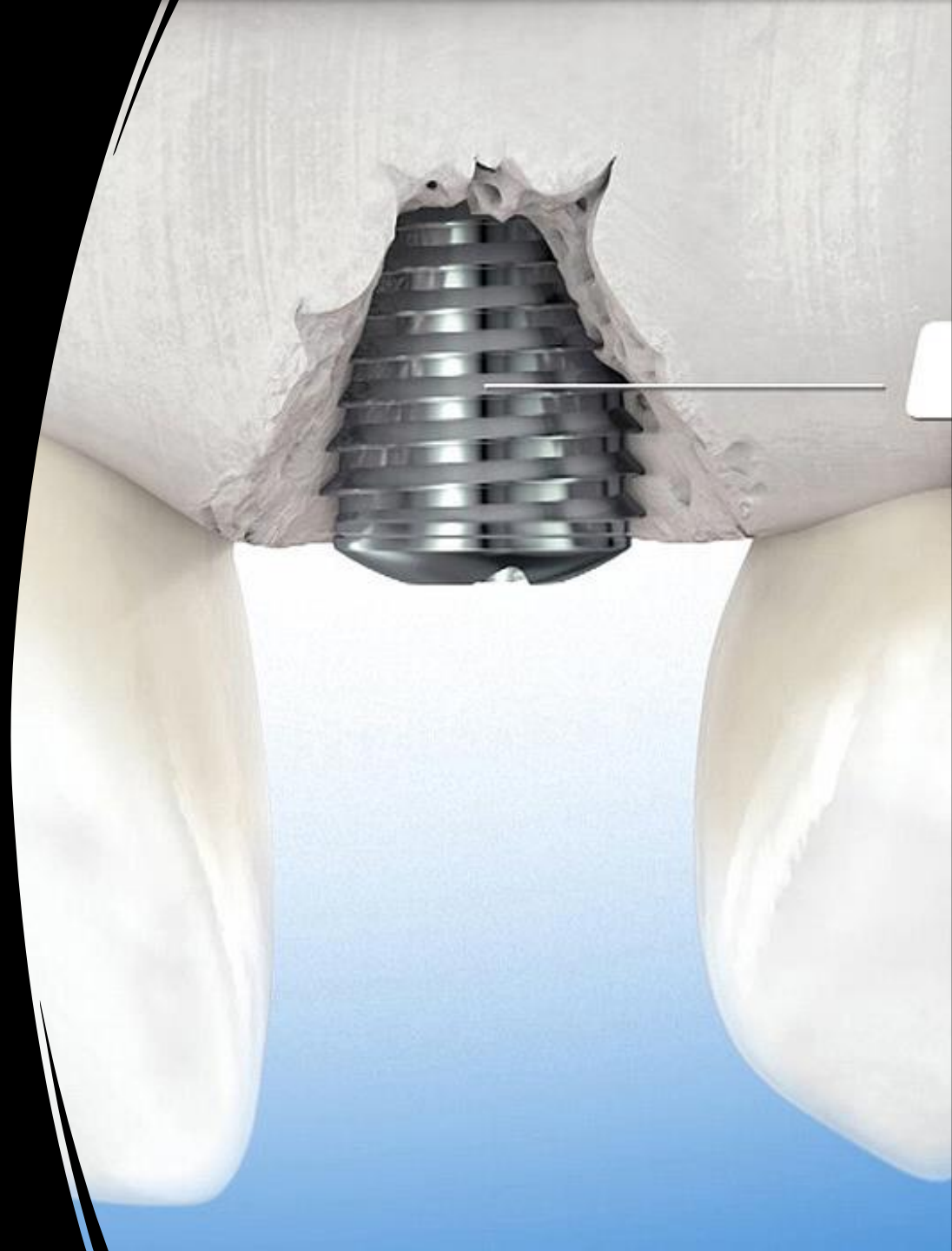
Titanium screw type implants

- Osseointegration: Direct contact between the implant and the osseous tissue



Modern implantology =
Discovery of bone integration
and the subsequent scientific
research.

Implant placement with lateral bone augmentation



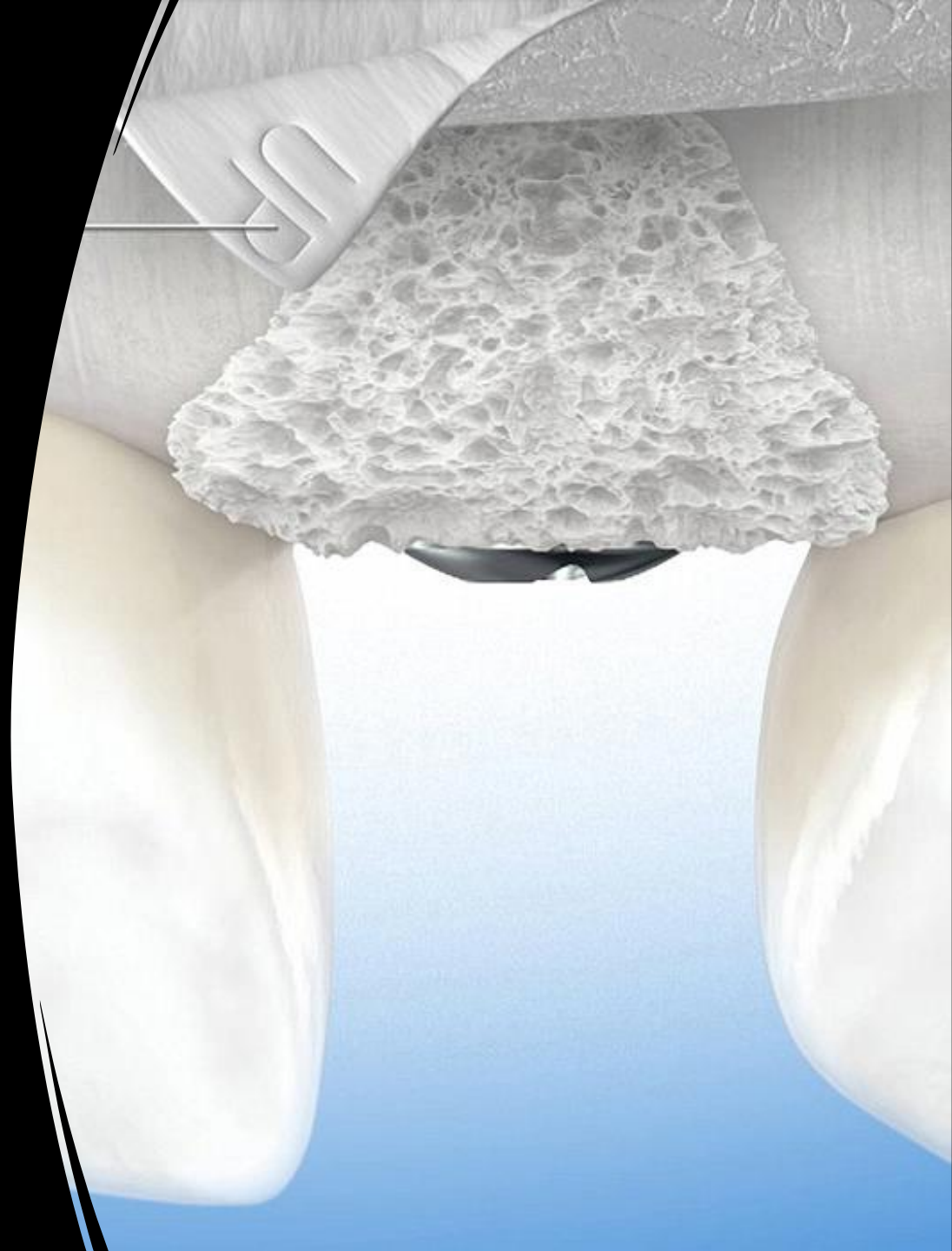Resource:

<https://www.geistlich-pharma.com/dental/therapeutic-areas/minor-bone-augmentation>

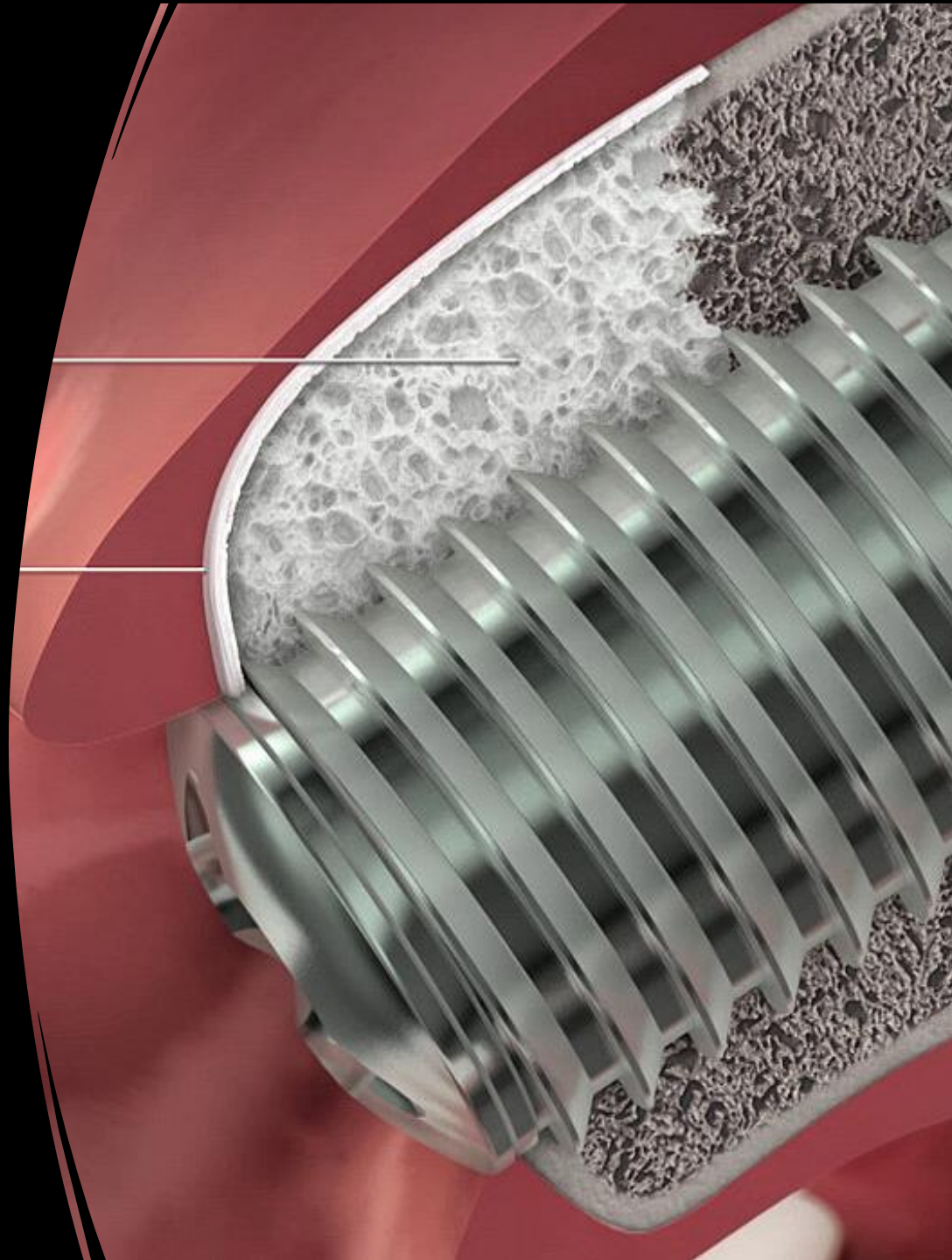
**Bone replacement
material + Collagen
barrier membrane
(Xenograft)**

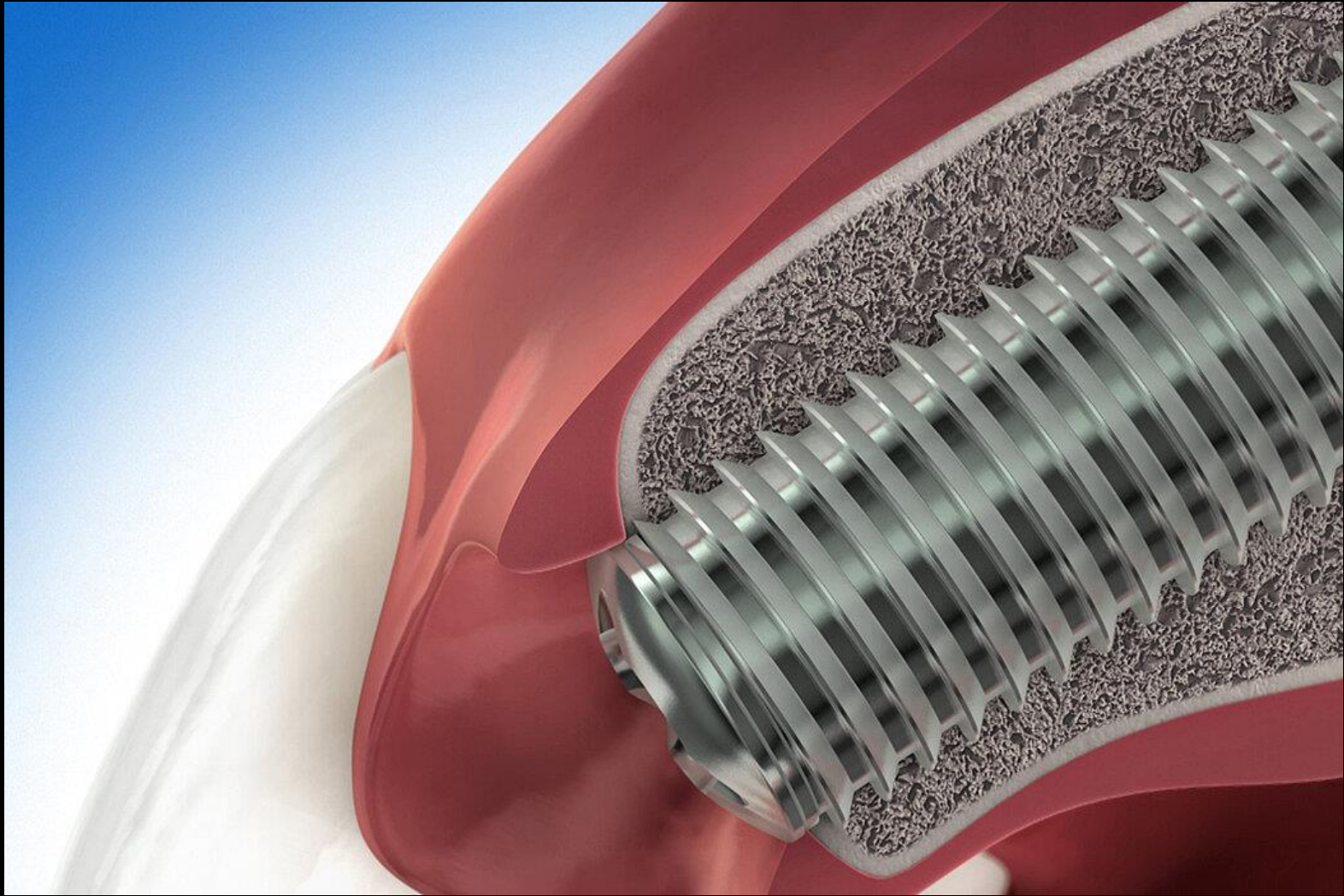
Resource:

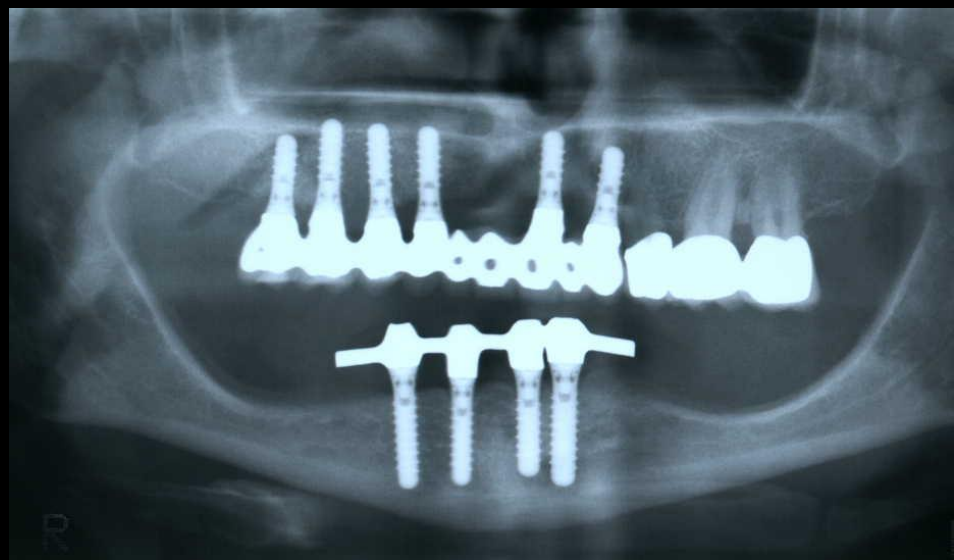
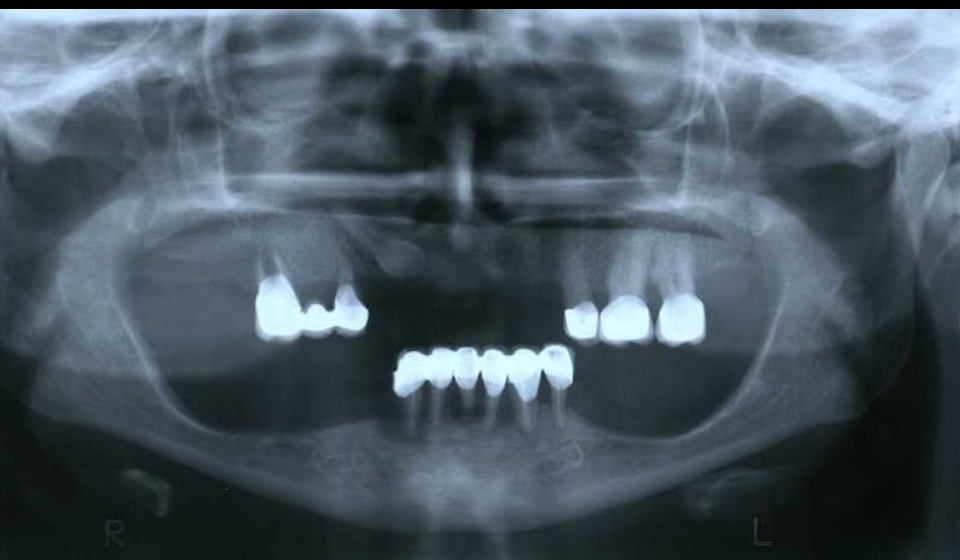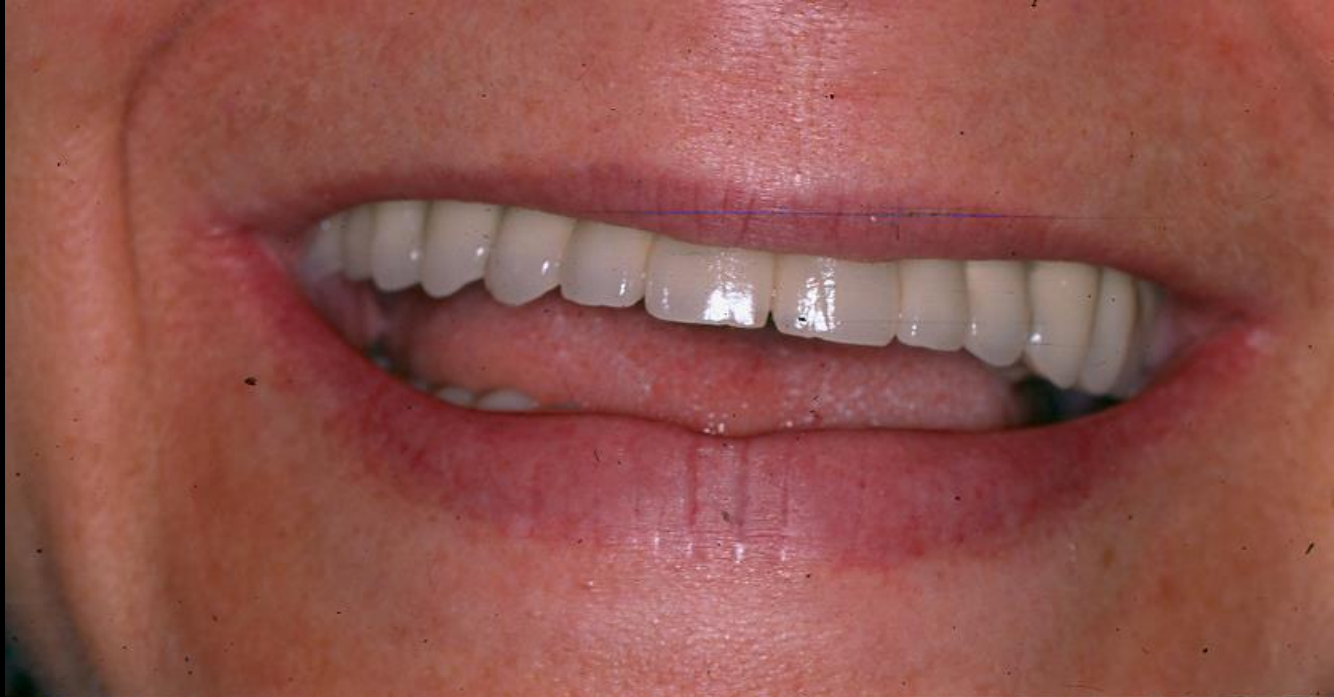<https://www.geistlich-pharma.com/dental/therapeutic-areas/minor-bone-augmentation>

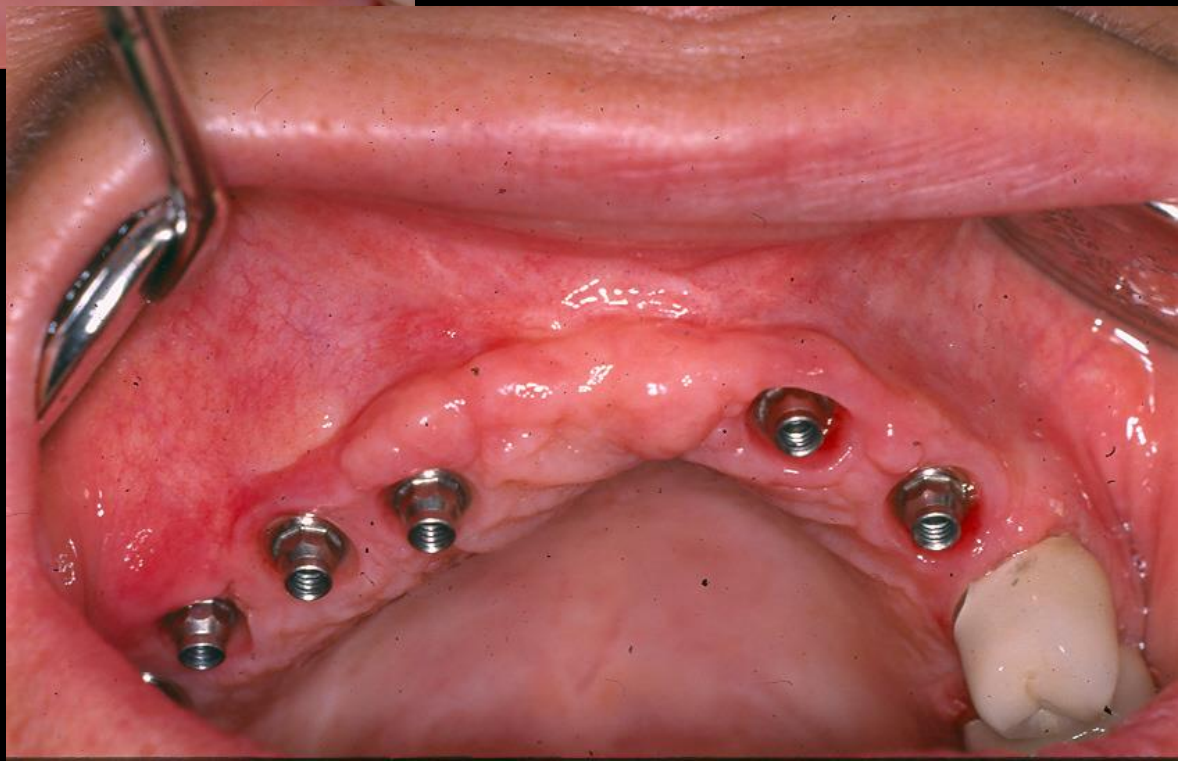
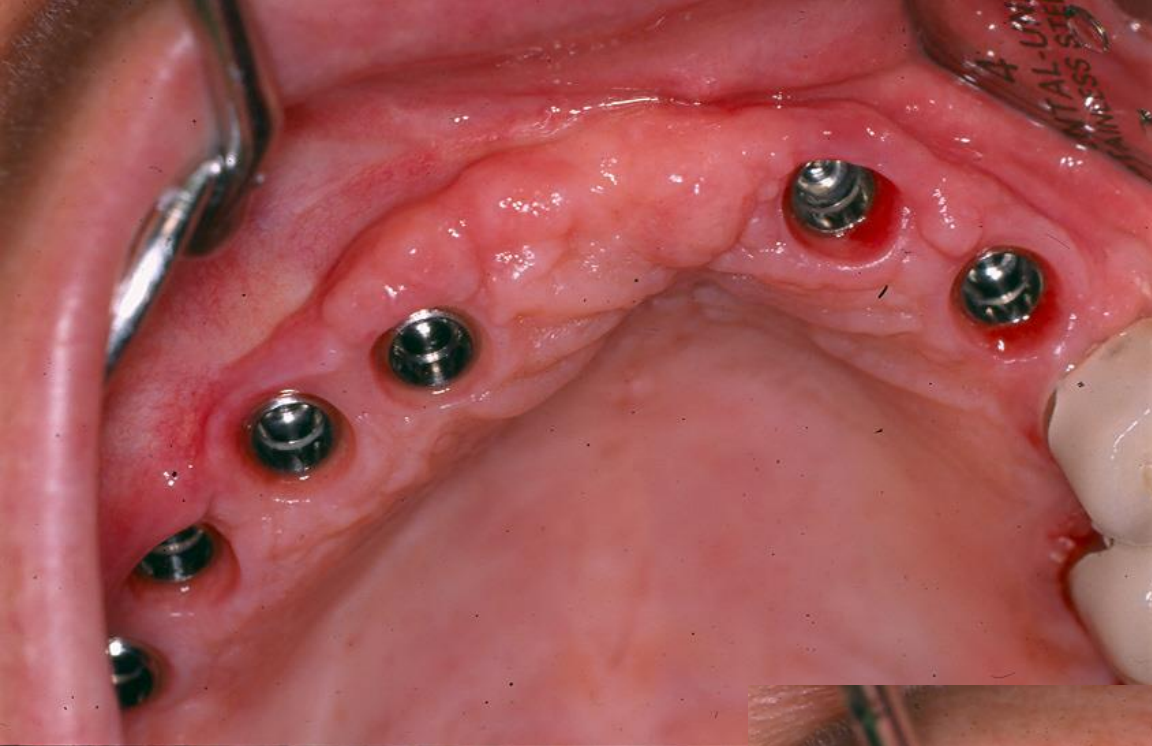


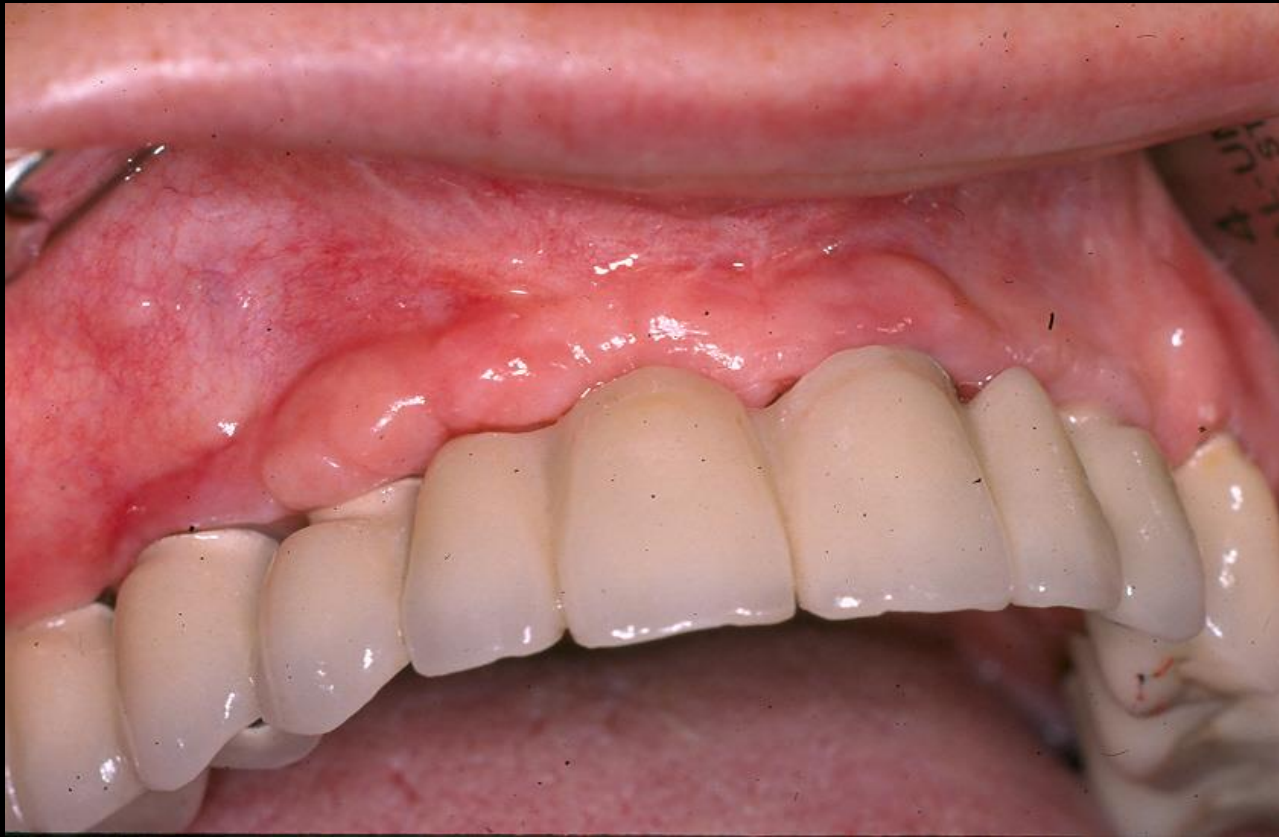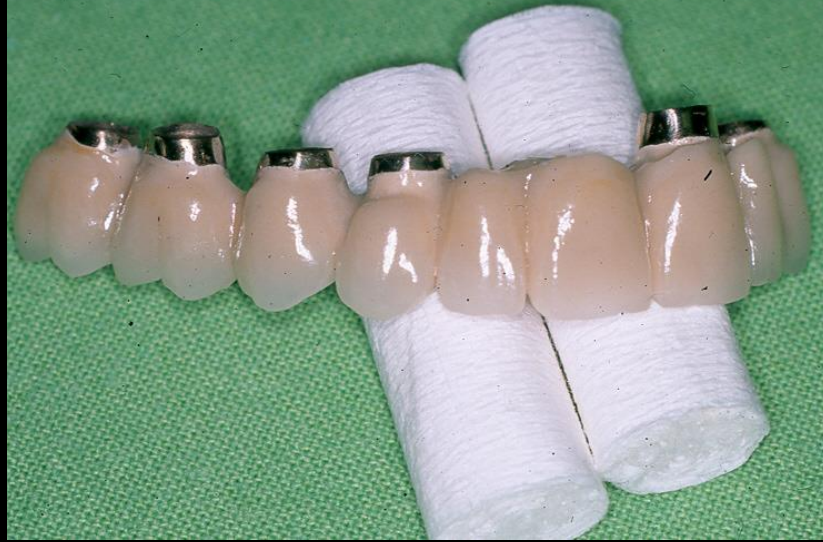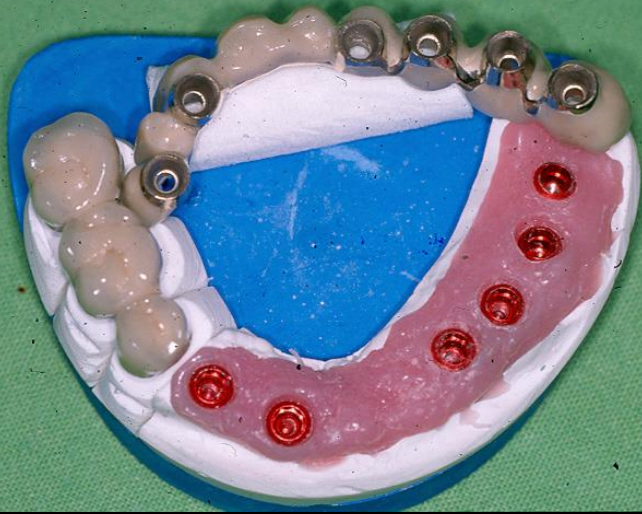Xenograft must be
combined with
harvested autogenous
bone

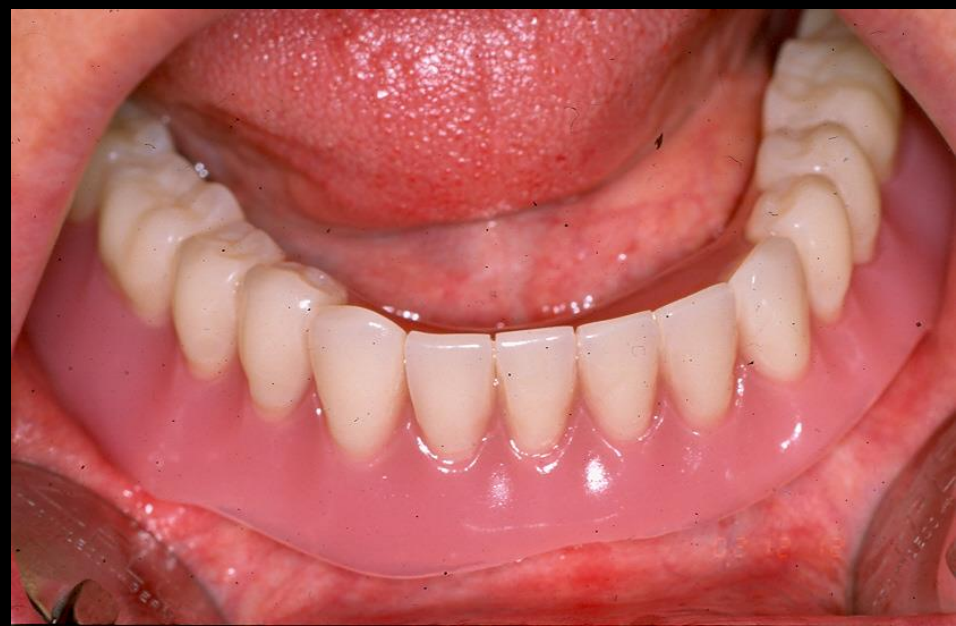
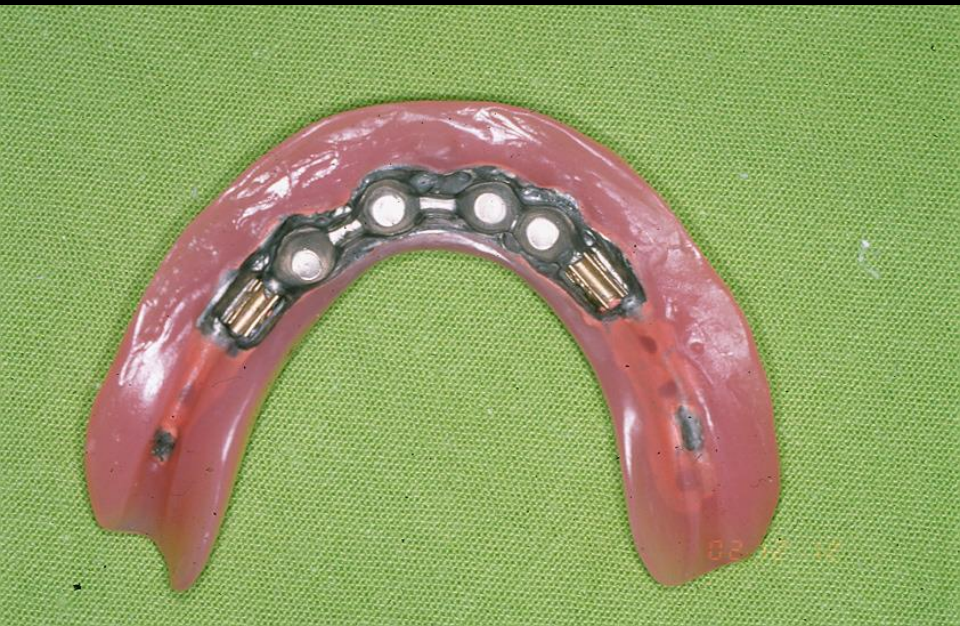
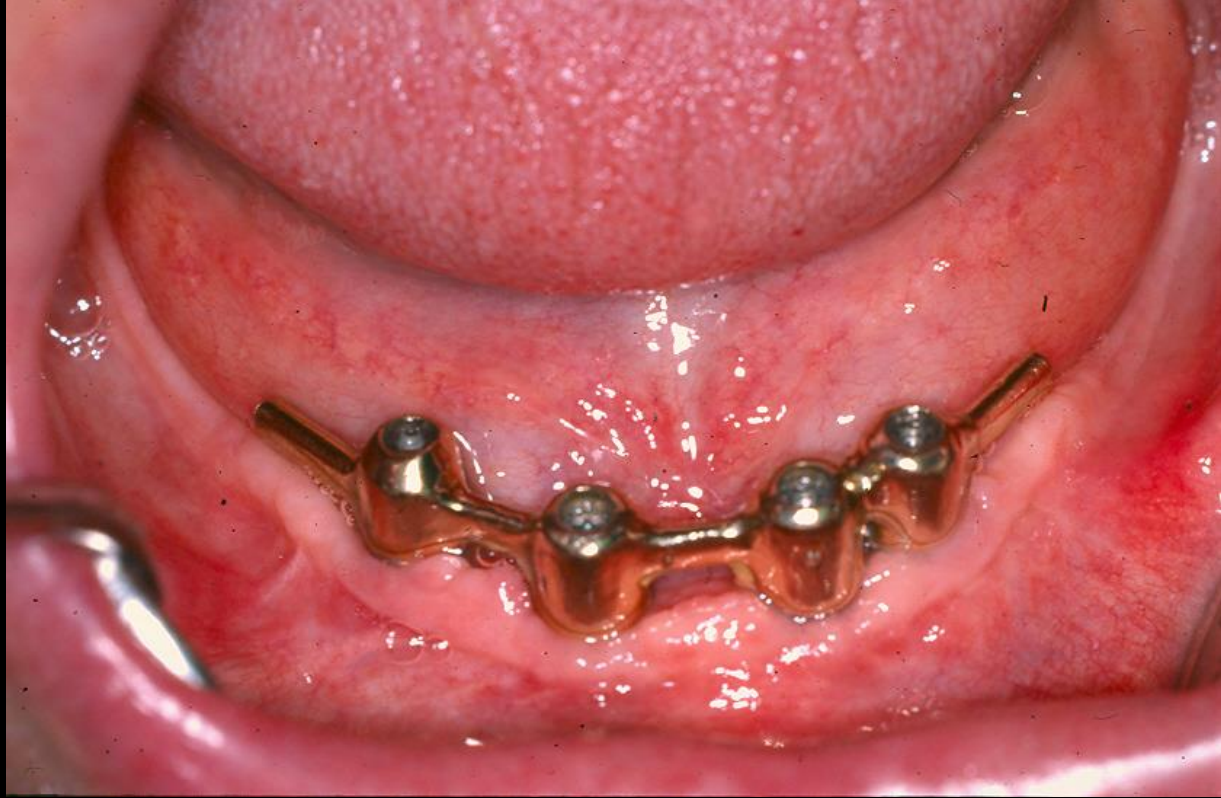









Thank you for your
attention!