



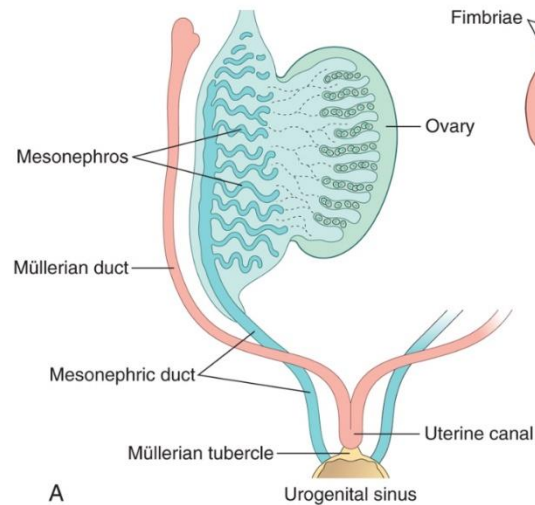
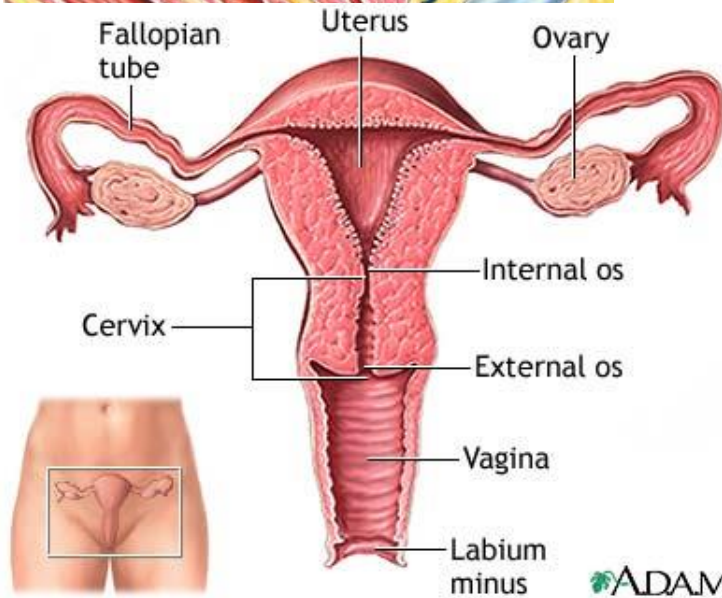
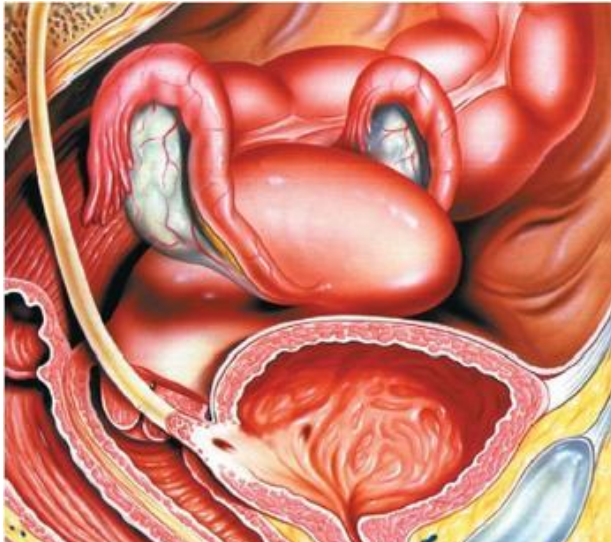
# Female genital tract-Part2. Pathology of the uterine corpus

Lilla Madaras MD PhD

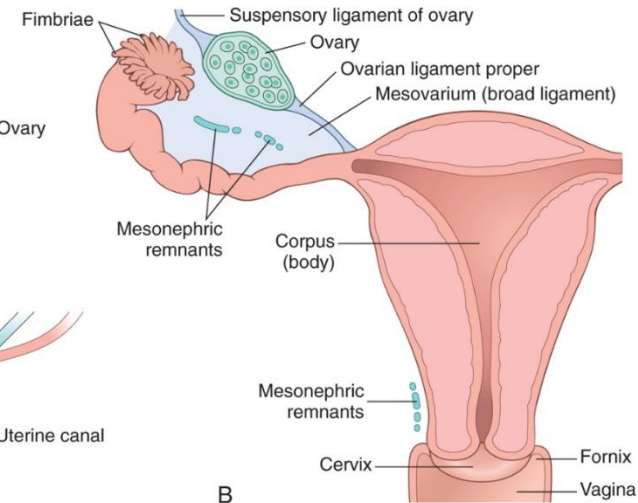
*250 years of EXCELLENCE  
in medical education,  
research & innovation  
and healthcare*

*26<sup>th</sup> April 2021*

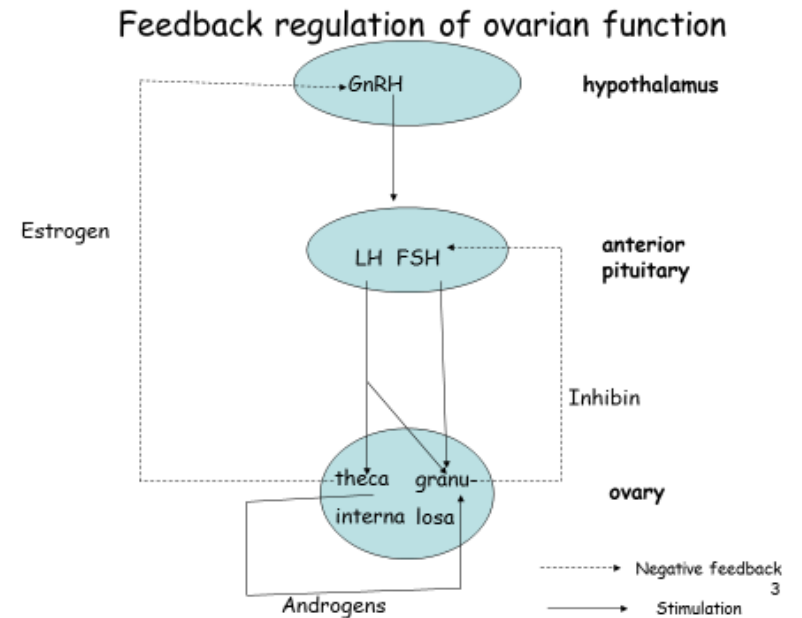
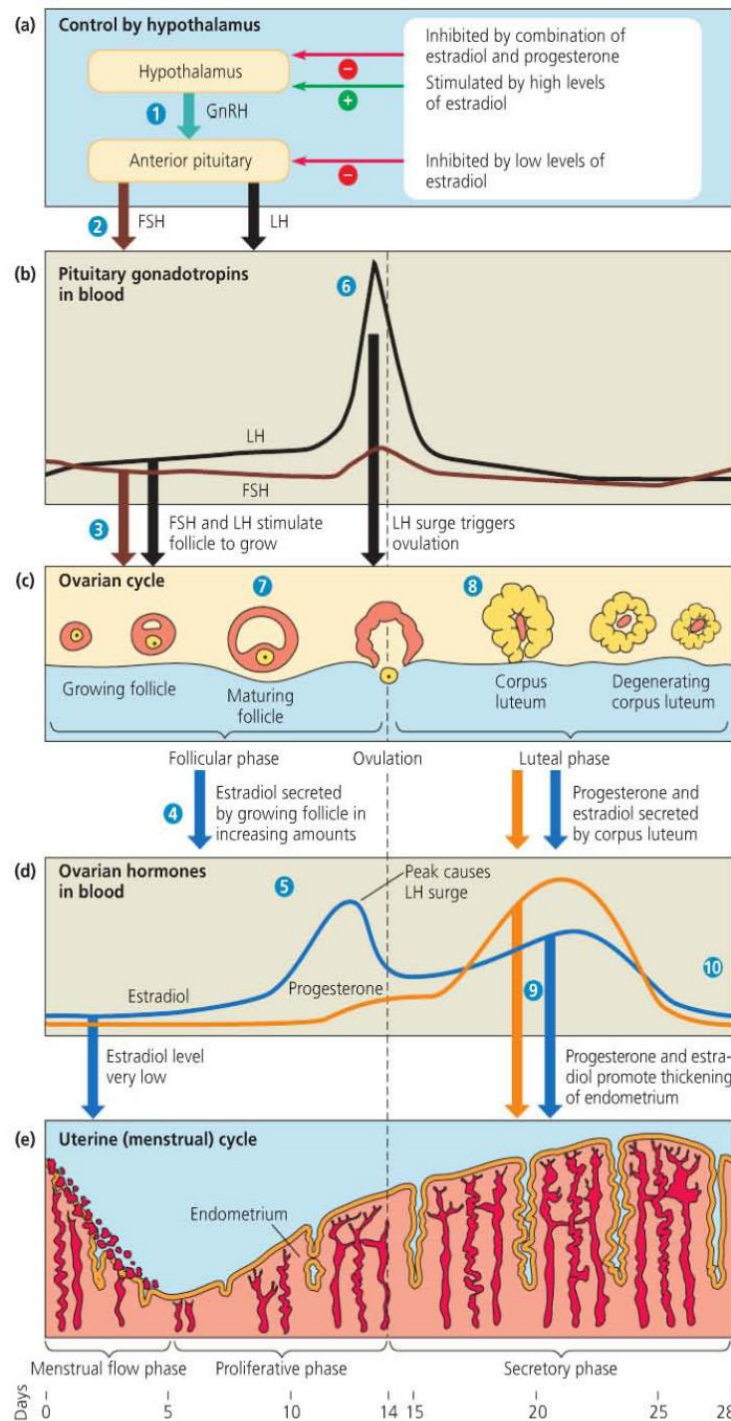
# Anatomy, development



A



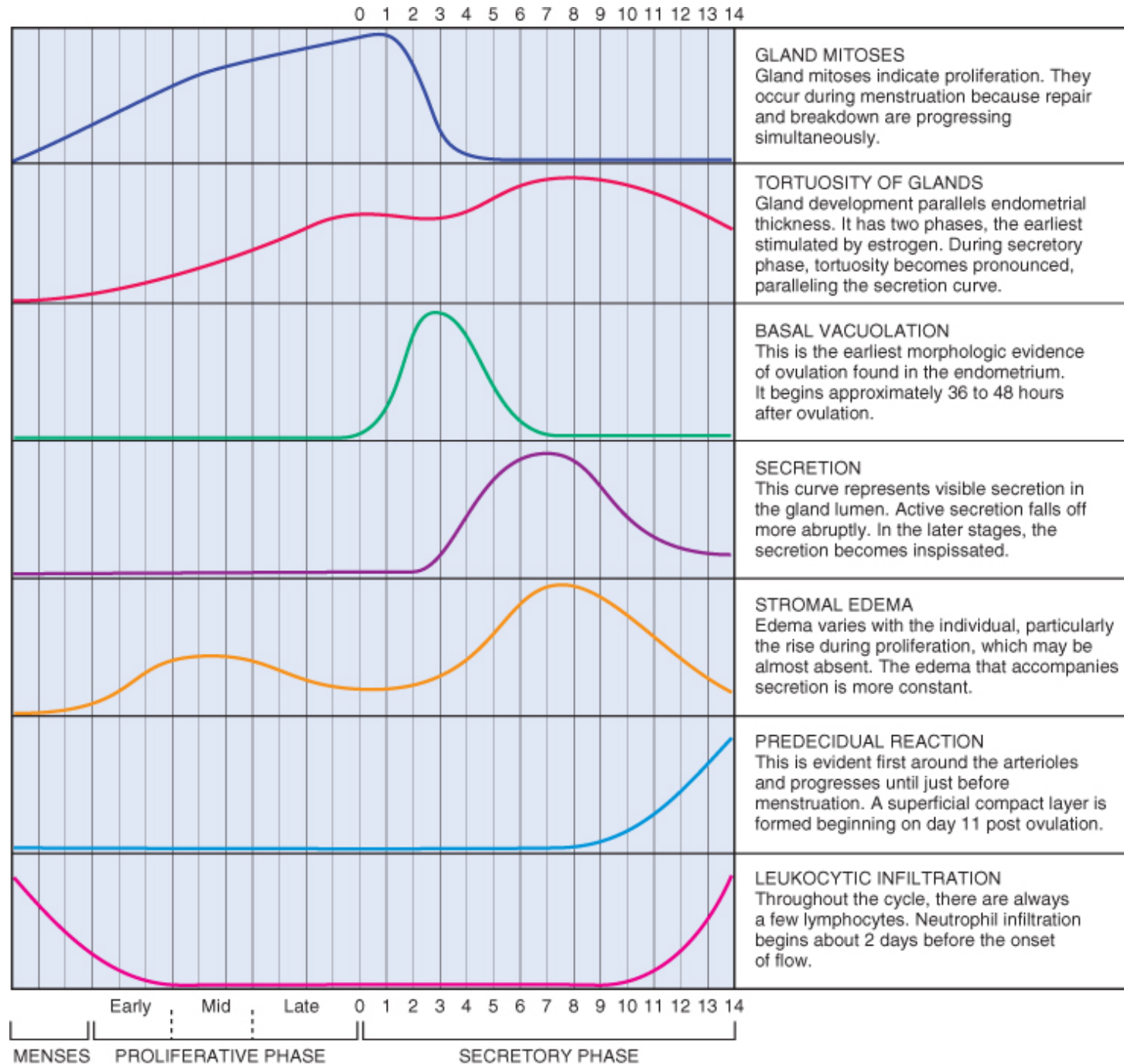
B

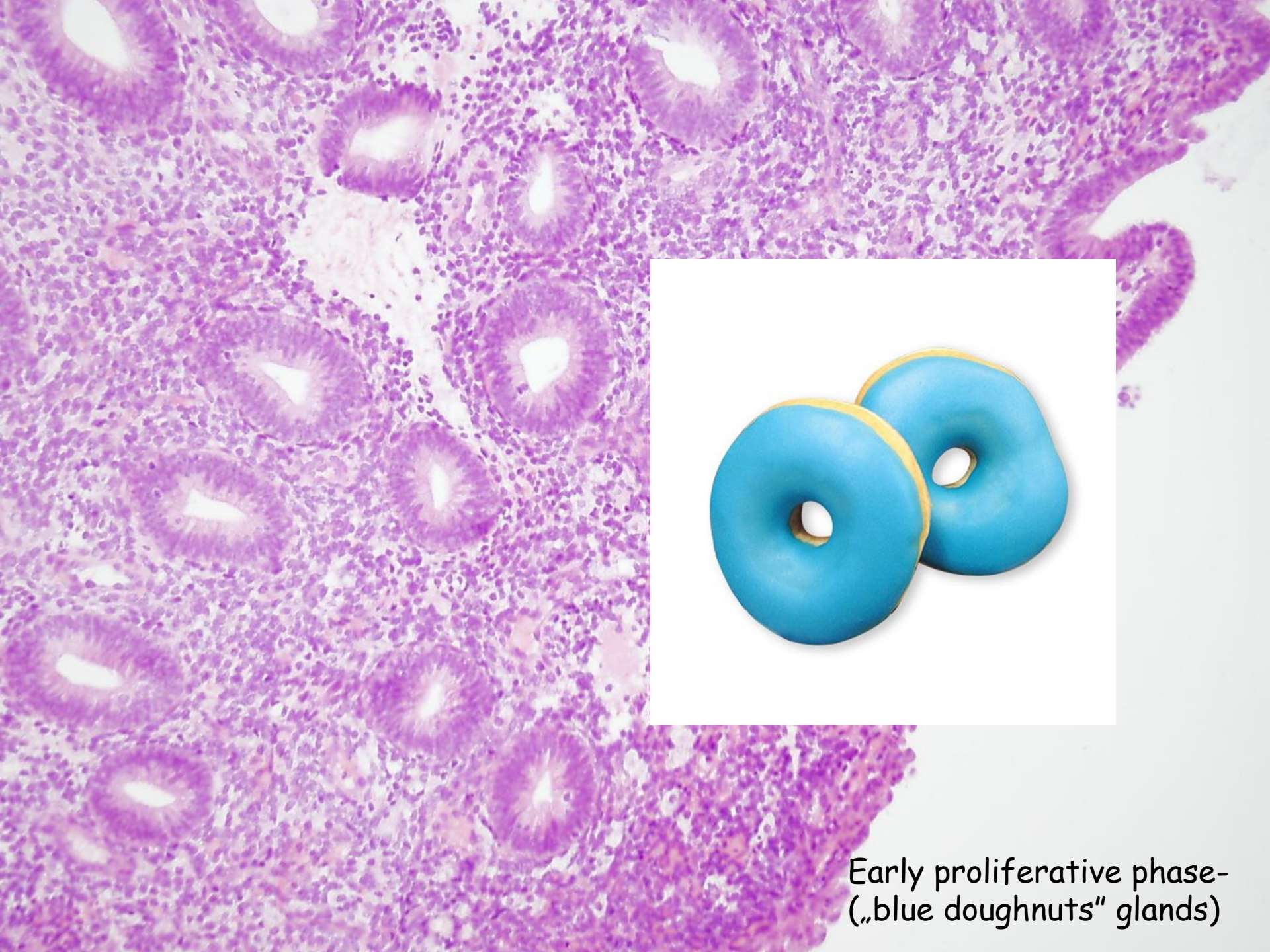


Ovarian and endometrial (menstrual) cycles and their regulation

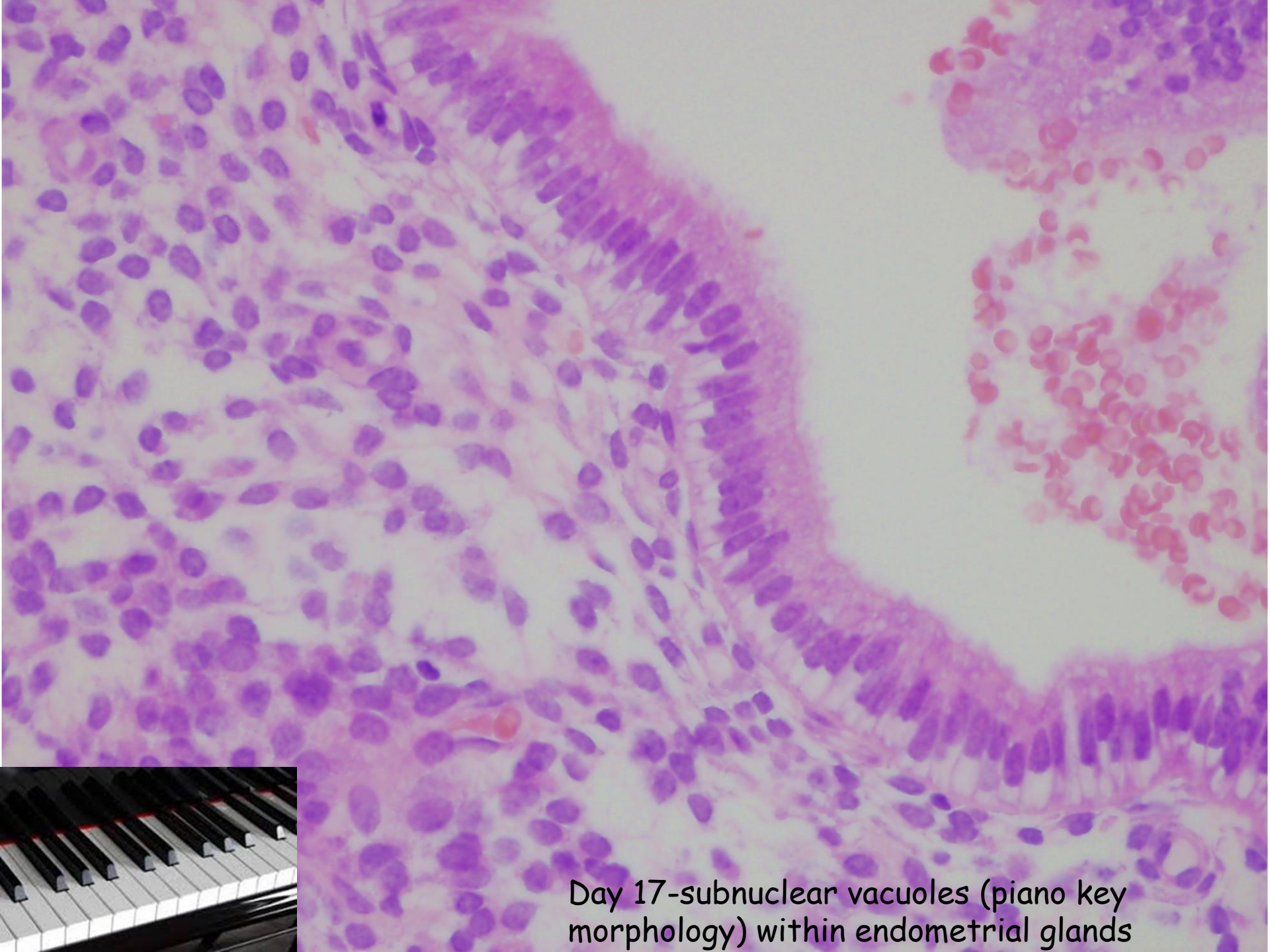
„Dating“ the  
endometrium

# Dating the endometrium

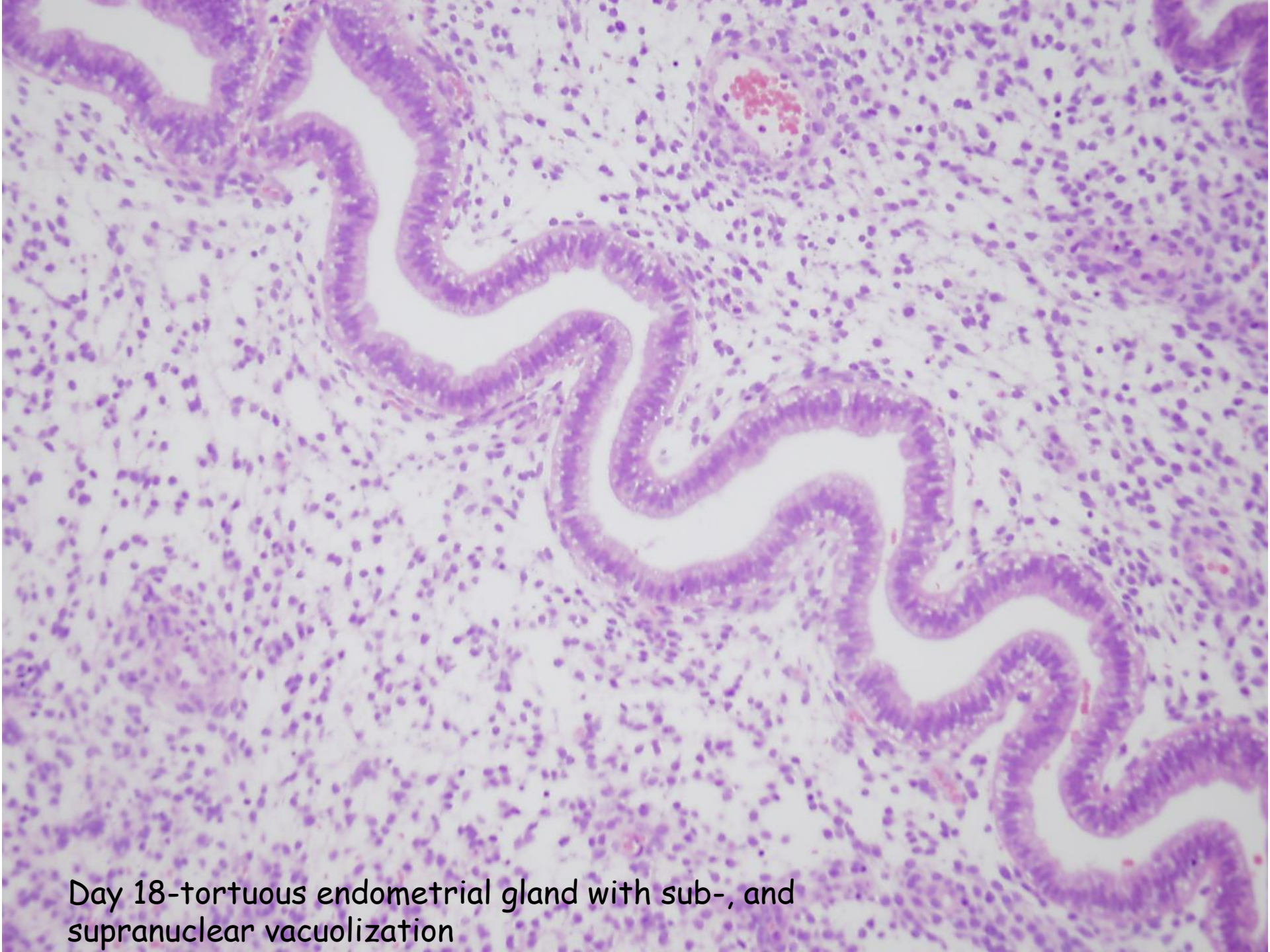




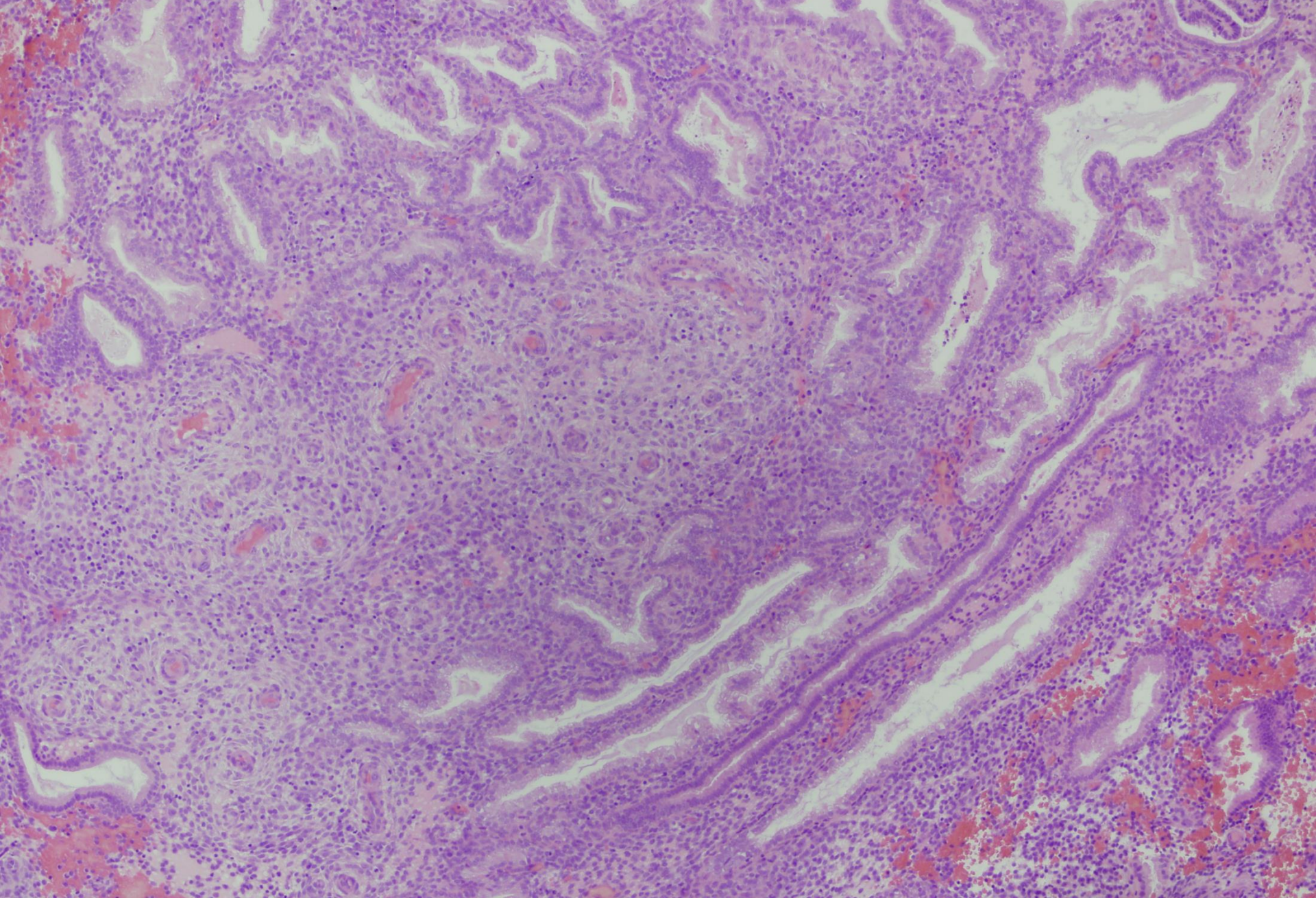
Early proliferative phase-  
 („blue doughnuts” glands)



Day 17-subnuclear vacuoles (piano key morphology) within endometrial glands

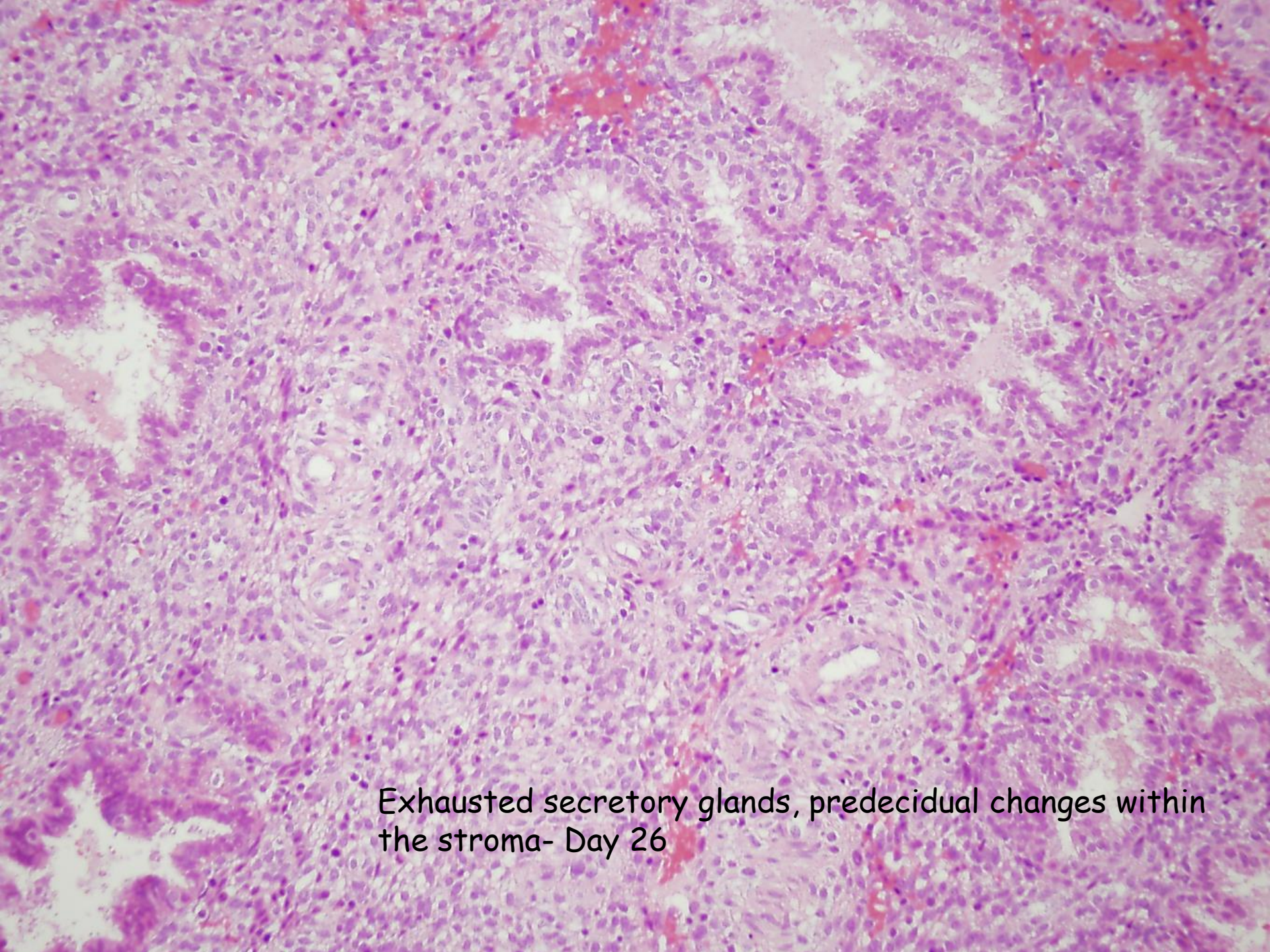


Day 18-tortuous endometrial gland with sub-, and supranuclear vacuolization

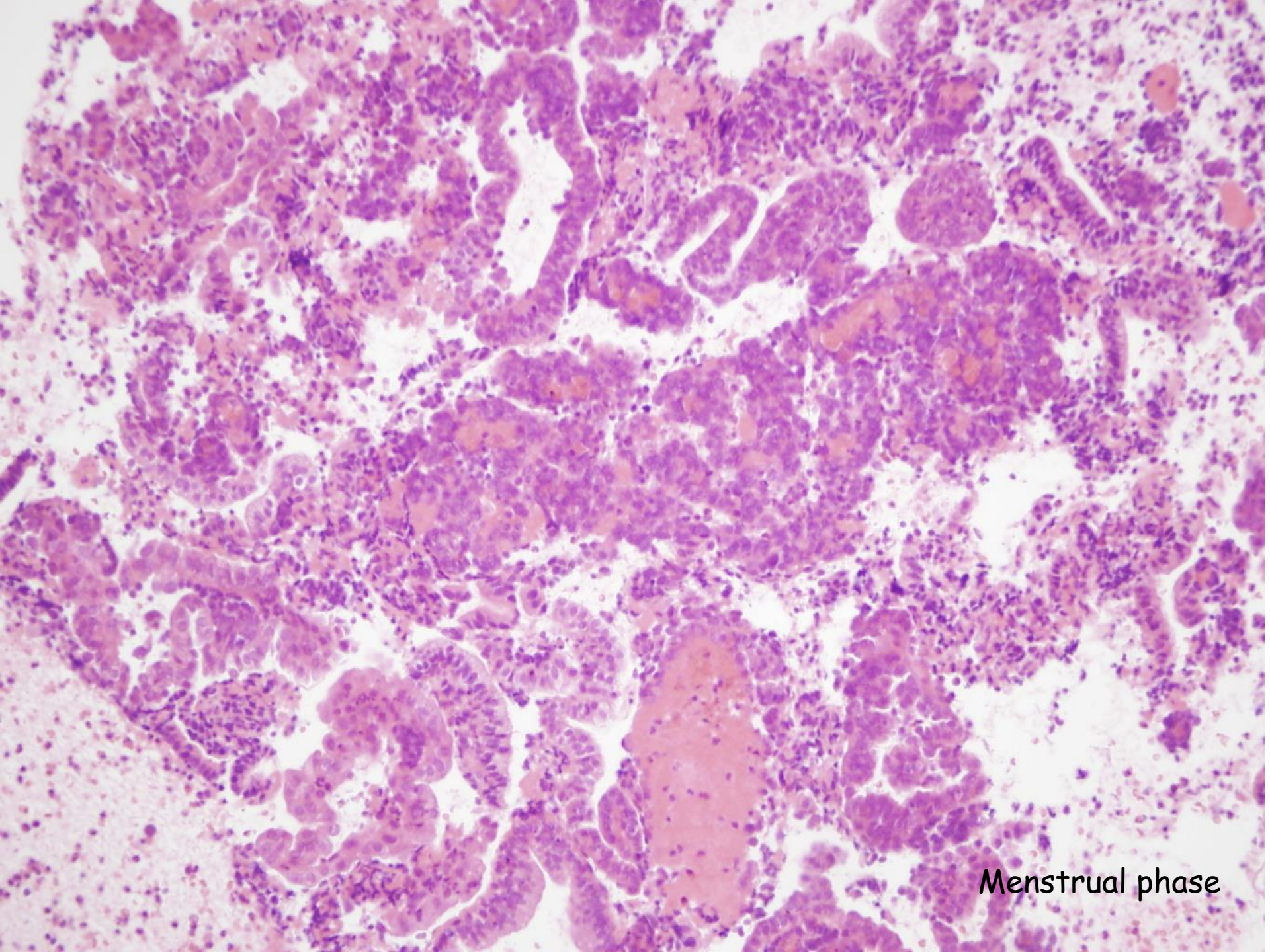


Day 24

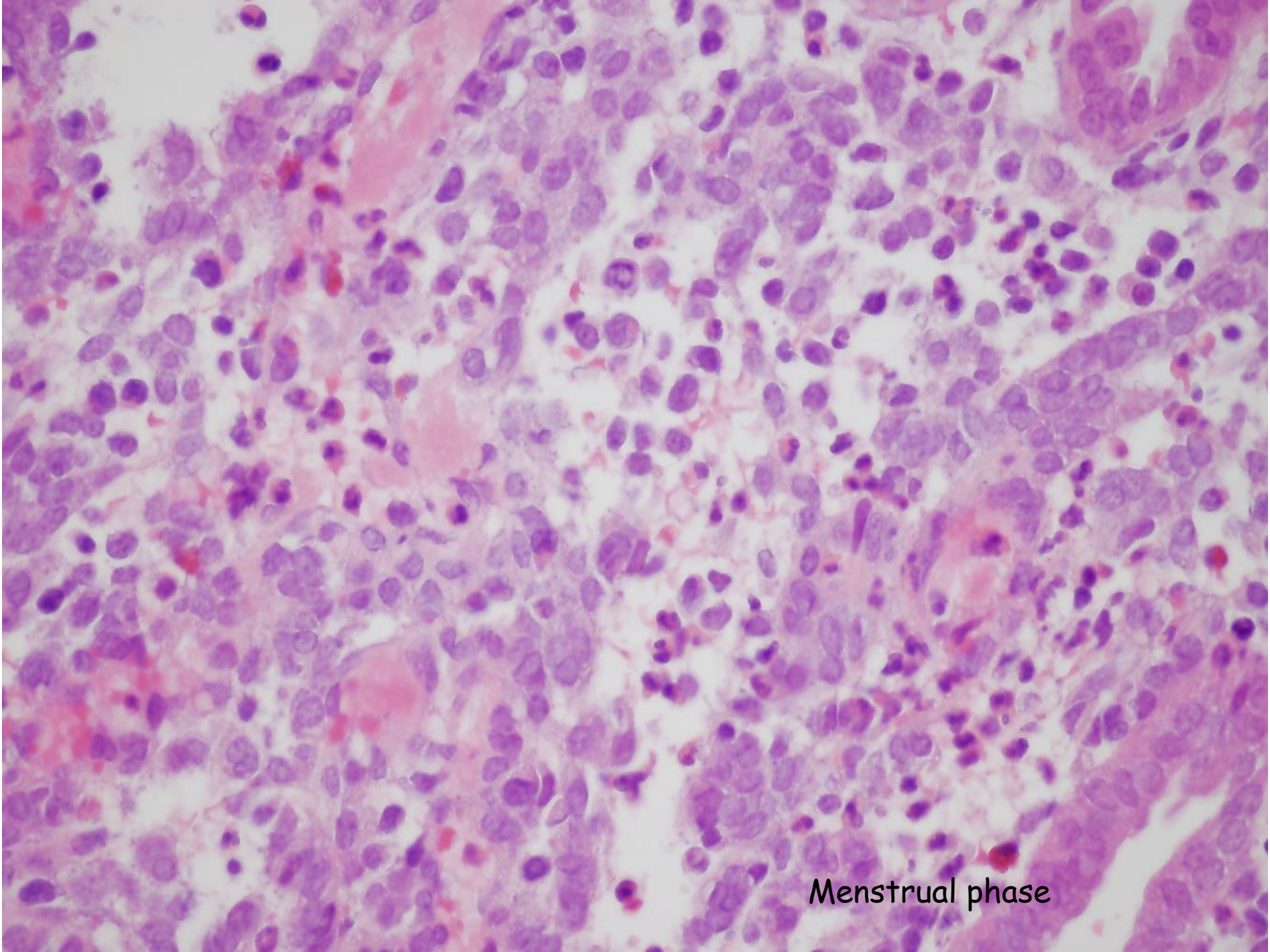
Exhausted secretory glands, predecidual changes around spiral arterioles

A histological slide of the endometrium stained with hematoxylin and eosin (H&E). The image shows a dense population of cells with prominent purple nuclei and pink cytoplasm/extracellular matrix. There are several areas of red staining, likely representing blood or hemorrhage. The overall architecture is disorganized, with many small, dark, round nuclei scattered throughout the tissue. The text 'Exhausted secretory glands, predecidual changes within the stroma- Day 26' is overlaid in the bottom right corner.

Exhausted secretory glands, predecidual changes within the stroma- Day 26



Menstrual phase



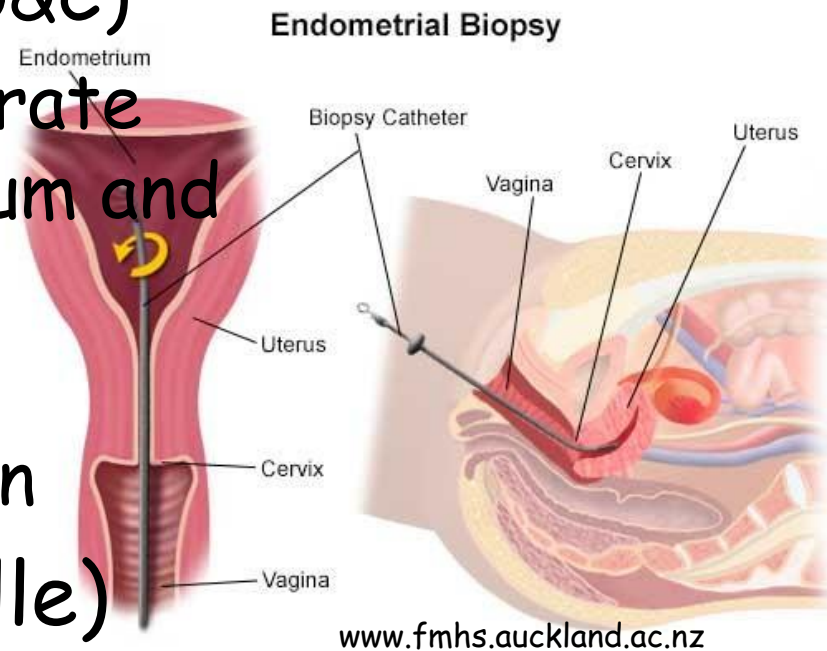
Menstrual phase

# How do we assess the endometrium?

1. By sampling procedures
2. In hysterectomy specimens (from TAH with or without BSO, laparoscopic hysterectomy, Chrobak surgery, Wertheim surgery...)

# Endometrium Sampling Techniques

1. Dilatation and Curettage(D&C)
2. Fractional curettage (separate sampling of the endometrium and endocervix)
3. Hysteroscopy+ polyp/endometrium ablation
4. Endometrial biopsy (Pipelle)



# Endometrial sampling-when?

- AUB (abnormal uterine bleeding)
- Abortion
- „Dating“ the endometrium in cases of infertility
- Hormone replacement therapy,  
Tamoxifen

# Pathology of the endometrium

- Inflammation
- Clinical terms
- AUB
- Endometrial hyperplasia
- Adenomyosis and endometriosis
- Tumors of the endometrium

# Inflamr

- **Acute endometritis**
  - in abortion, in a postpartum state
  - group A hemolytic streptococci
- **Chronic endometritis**
  - after retained gestational tissue
  - in PID
  - due to an IUD (actinomyces!)
  - tuberculosis (from tuberculosis in the western world)
  - chlamydial infection- plasma cell
- **Pyometra**
- **Asherman's syndrome** (intrauterine adhesions resulting in amenorrhea)



Semmelweis Ignác

(1818-1865)

*Semmelweis*

# Clinical terms (still in your book and in use)

- amenorrhea- primary or secondary
- Oligomenorrhea ↔ polymenorrhea
- hypomenorrhea ↔ menorrhagia
- metrorrhagia
- dysmenorrhea

# Clinical terms

- Dysfunctional uterine bleeding
- Oligomenorrhea, polymenorrhea
- hypomenorrhea ↔ menorrhagia
- Metrorrhagia, metropathia haemorrhagica
- Dysmenorrhea



www.figo.org

Contents lists available at ScienceDirect

International Journal of Gynecology and Obstetrics

journal homepage: [www.elsevier.com/locate/ijgo](http://www.elsevier.com/locate/ijgo)



## SPECIAL COMMUNICATION

FIGO classification system (PALM-COEIN) for causes of abnormal uterine bleeding in nongravid women of reproductive age

Malcolm G. Munro<sup>a,b,\*</sup>, Hilary O.D. Critchley<sup>c</sup>, Michael S. Broder<sup>d</sup>, Ian S. Fraser<sup>e</sup>; for the FIGO Working Group on Menstrual Disorders

<sup>a</sup> Department of Obstetrics and Gynecology, University of California, Los Angeles, USA

<sup>b</sup> Kaiser Permanente, Los Angeles Medical Center, Los Angeles, USA

<sup>c</sup> Centre for Reproductive Biology, University of Edinburgh, Queen's Medical Research Institute, Edinburgh, UK

<sup>d</sup> Partnership for Health Analytic Research, Beverly Hills, USA

<sup>e</sup> University of Sydney, Queen Elizabeth II Research Institute for Mothers and Infants, Sydney, Australia

- Abnormal Uterine Bleeding (AUB)

# AUB facts

- Premenop AUB- 1/3 of gynecological consultations
- Peri- and postmenop AUB- 70% of gynecological consultations
- FIGO Menstrual Disorders Working Group-2011
- American College of Obstetricians and Gynecologists (ACOG)-2013



www.igo.org

Contents lists available at ScienceDirect

International Journal of Gynecology and Obstetrics

journal homepage: [www.elsevier.com/locate/ijgo](http://www.elsevier.com/locate/ijgo)



## SPECIAL COMMUNICATION

FIGO classification system (PALM-COEIN) for causes of abnormal uterine bleeding in nongravid women of reproductive age

Malcolm G. Munro<sup>a,b,\*</sup>, Hilary O.D. Critchley<sup>c</sup>, Michael S. Broder<sup>d</sup>, Ian S. Fraser<sup>e</sup>; for the FIGO Working Group on Menstrual Disorders

<sup>a</sup> Department of Obstetrics and Gynecology, University of California, Los Angeles, USA

<sup>b</sup> Kaiser Permanente, Los Angeles Medical Center, Los Angeles, USA

<sup>c</sup> Centre for Reproductive Biology, University of Edinburgh, Queen's Medical Research Institute, Edinburgh, UK

<sup>d</sup> Partnership for Health Analytic Research, Beverly Hills, USA

<sup>e</sup> University of Sydney, Women's Health Research Institute for Mothers and Infants, Sydney, Australia

# AUB definitions

- AUB: bleeding from the uterine corpus that is abnormal in volume, regularity, and/or timing
  - Heavy menstrual bleeding (HMB)
  - Intermenstrual bleeding (IMB)

# AUB definitions (cont.)

- **Chronic AUB:** bleeding from the uterine corpus that is abnormal in volume, regularity, and/or timing, and has been present for 6 months
- **Acute AUB:** was defined as an episode of heavy bleeding that, in the opinion of the clinician, is of sufficient quantity to require immediate intervention to prevent further blood loss
- **Intermenstrual bleeding (IMB):** occurs between clearly defined cyclic and predictable menses

# AUB in reproductive ages

## PALM/COEIN

<b>P</b> olyp
<b>A</b> denomyosis
<b>L</b> eiomyoma
<b>M</b> alignancy & hyperplasia

Submucosal  
Other

<b>C</b> oagulopathy
<b>O</b> vulatory dysfunction
<b>E</b> ndometrial
<b>I</b> atrogenic
<b>N</b> ot yet classified



# PALM

- Polyp-AUB-P
  - Adenomyosis AUB-A
  - Leiomyoma AUB-L
  - Malignancy and hyperplasia AUB-M
- 
- These lesions are detected by imaging and assessed by histology

# Causes of Abnormal Uterine Bleeding by Age Group

<b>Prepuberty</b>	Precocious puberty (hypothalamic, pituitary or ovarian origin)
<b>Adolescence</b>	<b>Anovulatory cycle</b>
<b>Reproductive age</b>	Complication of pregnancy (abortion, trophobl.disease, ectopic pregnancy) Organic lesions (leiomyoma, polyp, adenomyosis, endometrial hyperplasia, carcinoma) Anovulatory cycle
<b>Perimenopausal</b>	<b>Anovulatory cycle</b> Organic lesions (carcinoma, hyperplasia, polyp)
<b>Postmenopausal</b>	Organic lesions (carcinoma, hyperplasia, polyp) Endometrial atrophy

# Dysfunctional endometrial bleeding (now AUB-COEIN group)

- **Inadequate proliferative phase**
  - discrepancy between the observed and the expected endometrial pattern in the proliferative phase
- **Inadequate luteal phase**
  - low progesteron level
  - infertility
  - amenorrhea or abnormal bleeding
  - sampling 2 days before expected menstruation!
- **Irregular shedding of the endometrium**
  - menstruation lasts longer than 7 days without prolongation of the cycle
  - sampling on the 5th day of the menstruation demonstrates menstruation type and late secretory type endometrium and early proliferative endometrium

Polyp
Adenomyosis
Leiomyoma
Malignancy & hyperplasia

Submucosal
Other



Coagulopathy
Ovulatory dysfunction
Endometrial
Iatrogenic
Not yet classified



# Dysfunctional endometrial bleeding

- **Anovulatory cycle (AUB-O)**
  - in adolescence and premenopausa **most commonly** due to slight hormonal imbalances and no apparent causes
  - **Less commonly:**
    - **endocrine** causes: thyroid, adrenal or pituitary disease
    - **ovarian** causes: PCO, granulosa-theca cell tumor
    - **systemic** metabolic causes: obesity, malnutrition (anorexia nervosa!), chronic systemic diseases etc.
  - no ovulation → prolonged unopposed estrogenic stimulation → persistent proliferative endometrium → endometrial hyperplasia or unscheduled breakdown of the stroma → abnormal bleeding

# Endometrial hyperplasia

- result of unopposed, prolonged **estrogenic stimulation** (due to anovulation or increased estrogen production- PCO, Stein-Leventhal sy, cortical stromal hppl, estrogen replacement therapy, functioning granulosa cell tumor)
- (Simple or Complex) Hyperplasia without atypia
- (Simple or Complex) Hyperplasia with atypia

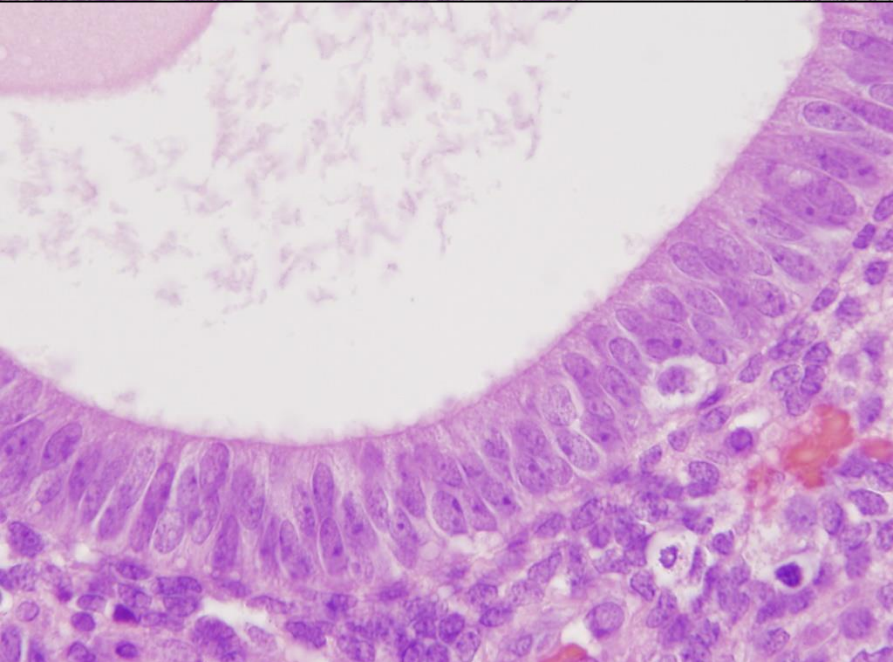
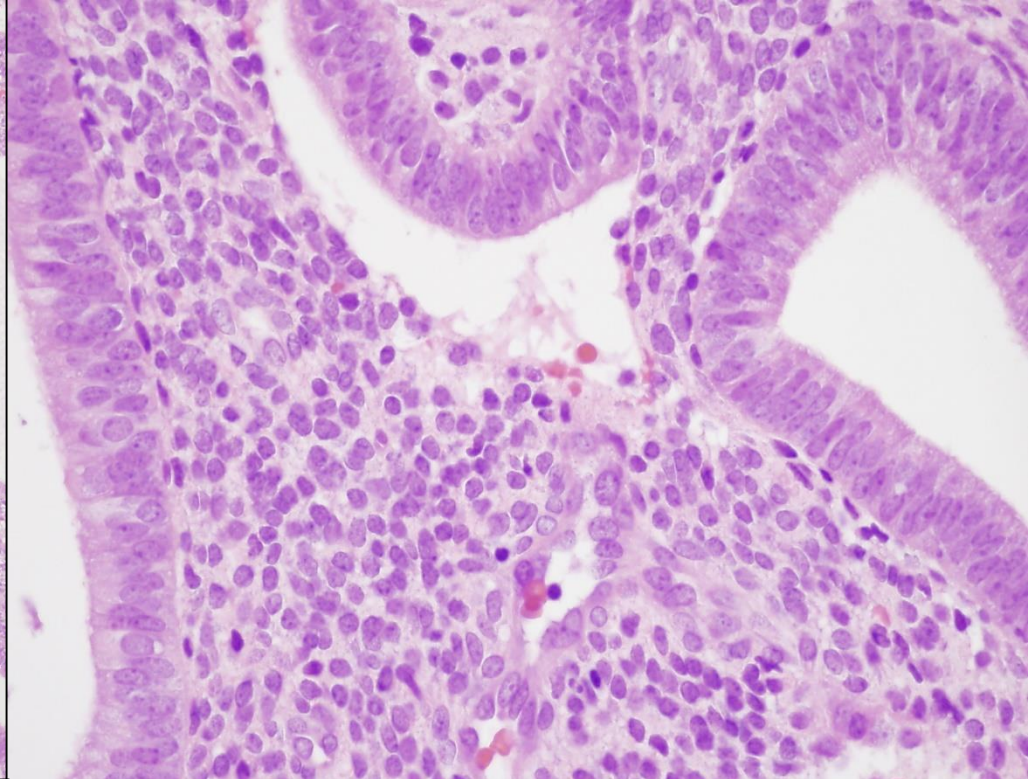
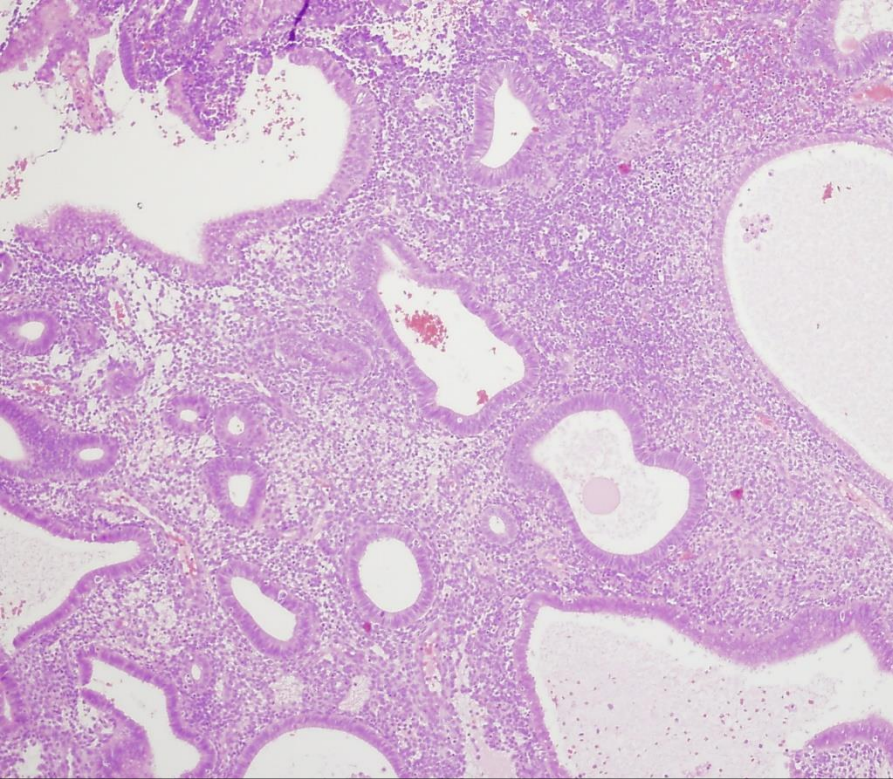
# Hyperplasia (formerly called simple hyperplasia)

- **Without atypia**

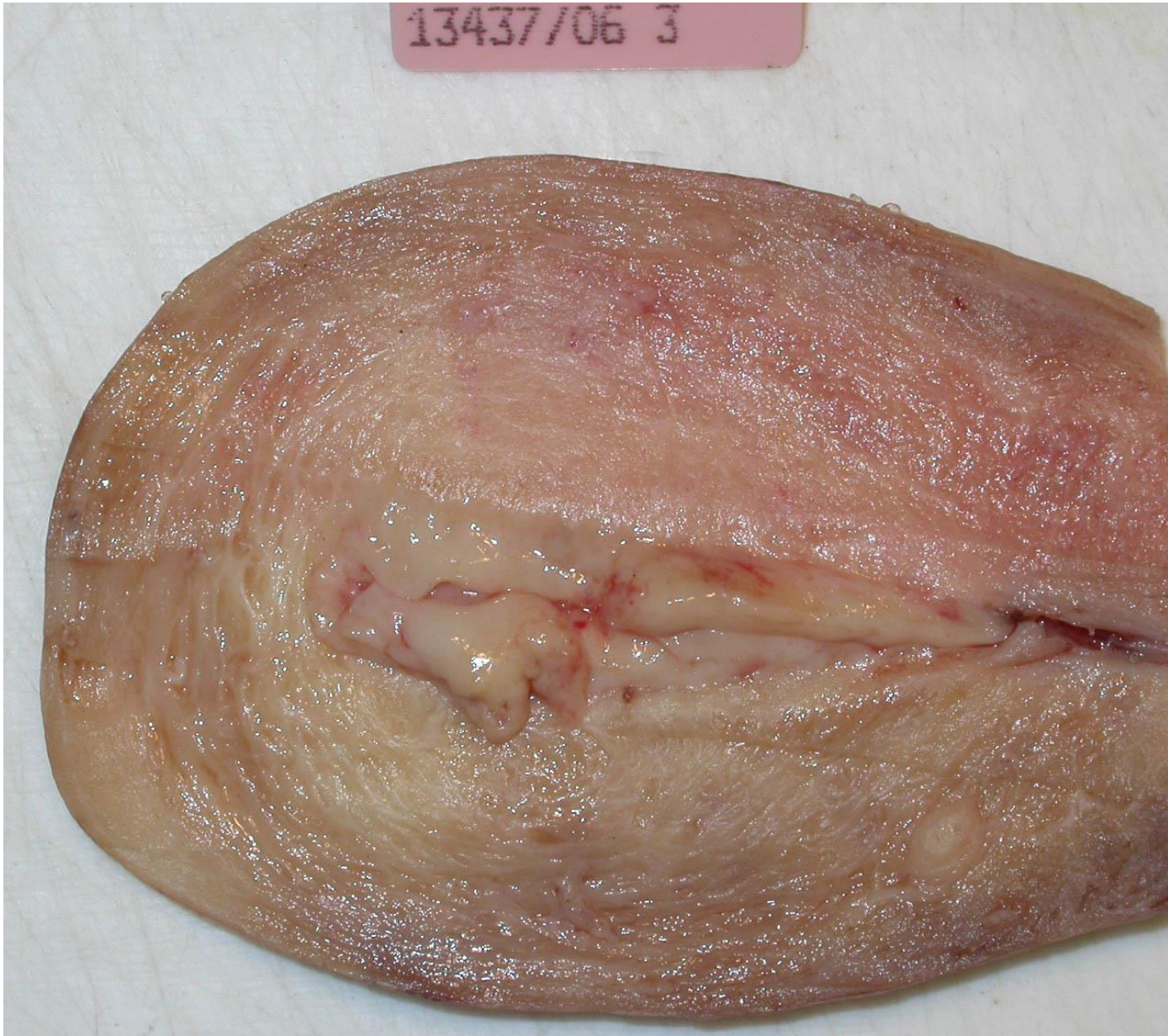- diffuse alteration
- increased amount of glands and stroma
- (Mildly increased) almost normal ratio of glands and stroma
- differences in glandular size and shape
- cystically dilated glands
- glandular epithelium: proliferative
- Usually no progression to adenocarcinoma (1%)

- **With atypia**

- the previous features + cytological atypia
- Uncommon
- Progression to adenocarcinoma 8%



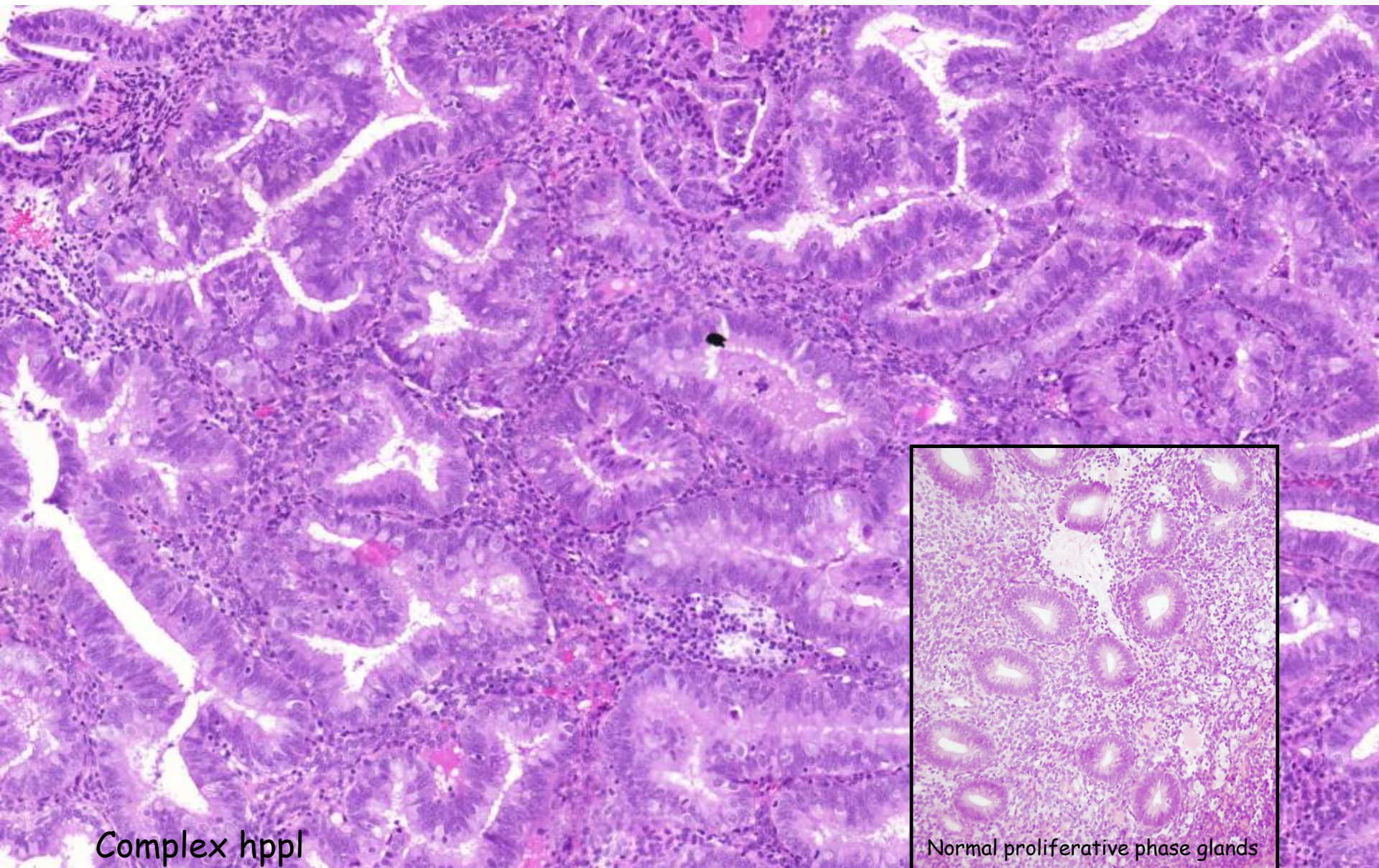
Simple hyperplasia



Simple hyperplasia- endometrium

# Formerly called complex hyperplasia

- Without atypia
  - focal alteration
  - irregular glands
  - increased ratio of glands to stroma (less intervening stroma, back-to-back placed glands)
  - Progression to adenocarcinoma 3%
- With atypia (Endometrioid Intraepithelial Neoplasia)
  - cytological atypia
  - Usually hysterectomy is done
  - Progression to adenocarcinoma 25-30%

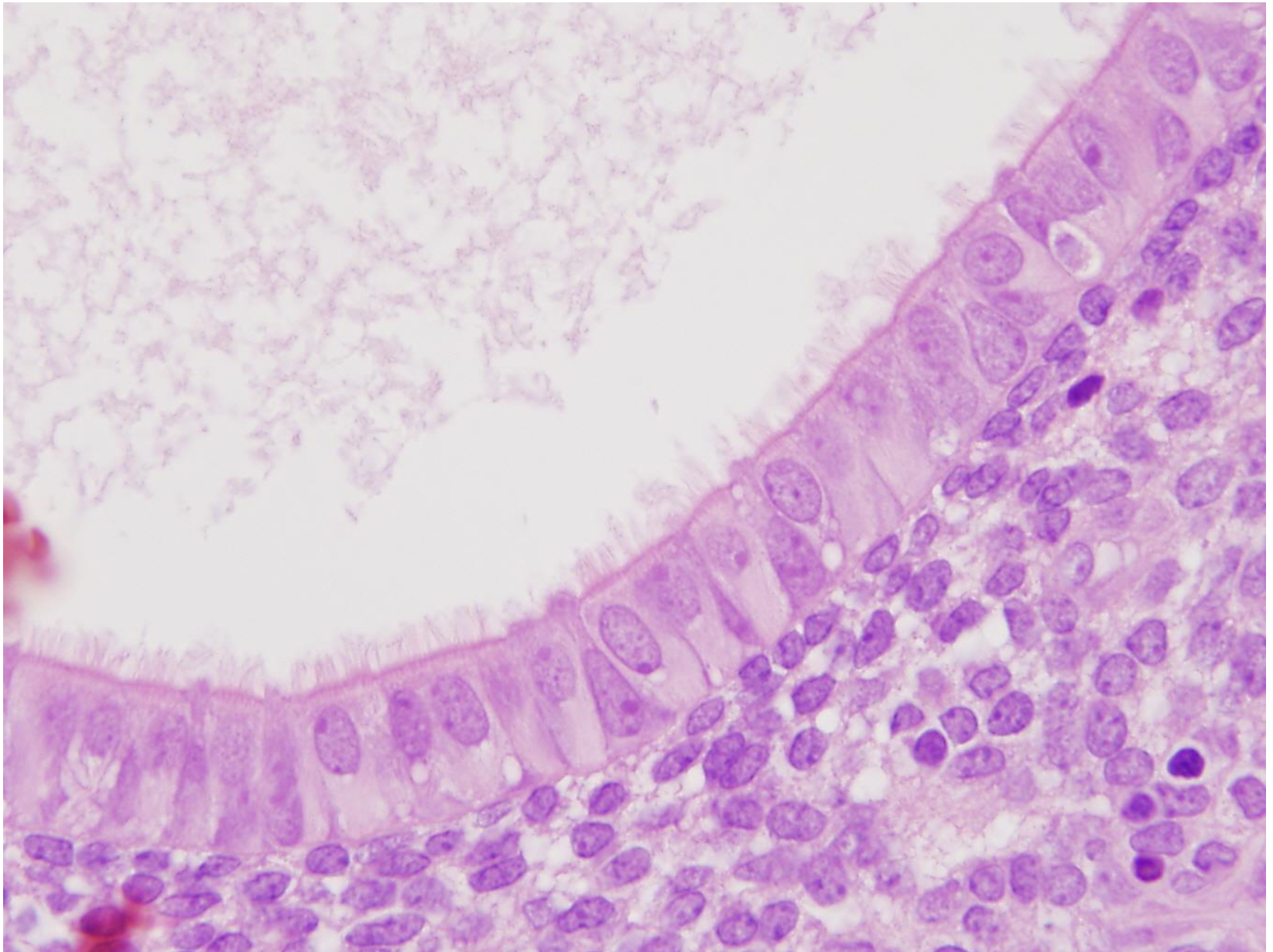


Complex hppl

Normal proliferative phase glands

# Metaplasias

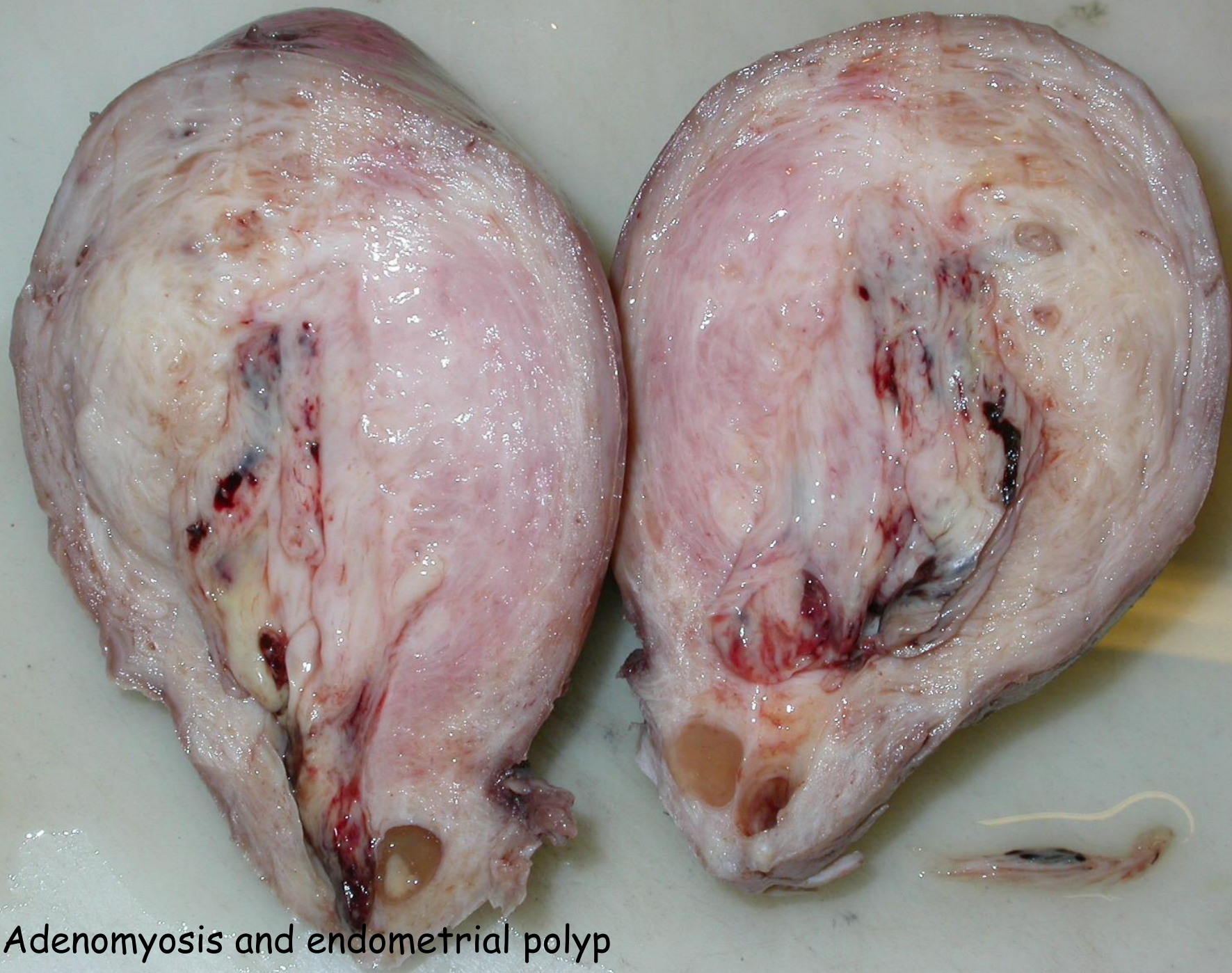- different forms: squamous, tubal, eosinophilic, mucinous, etc.
- frequently associated with hyperplasia



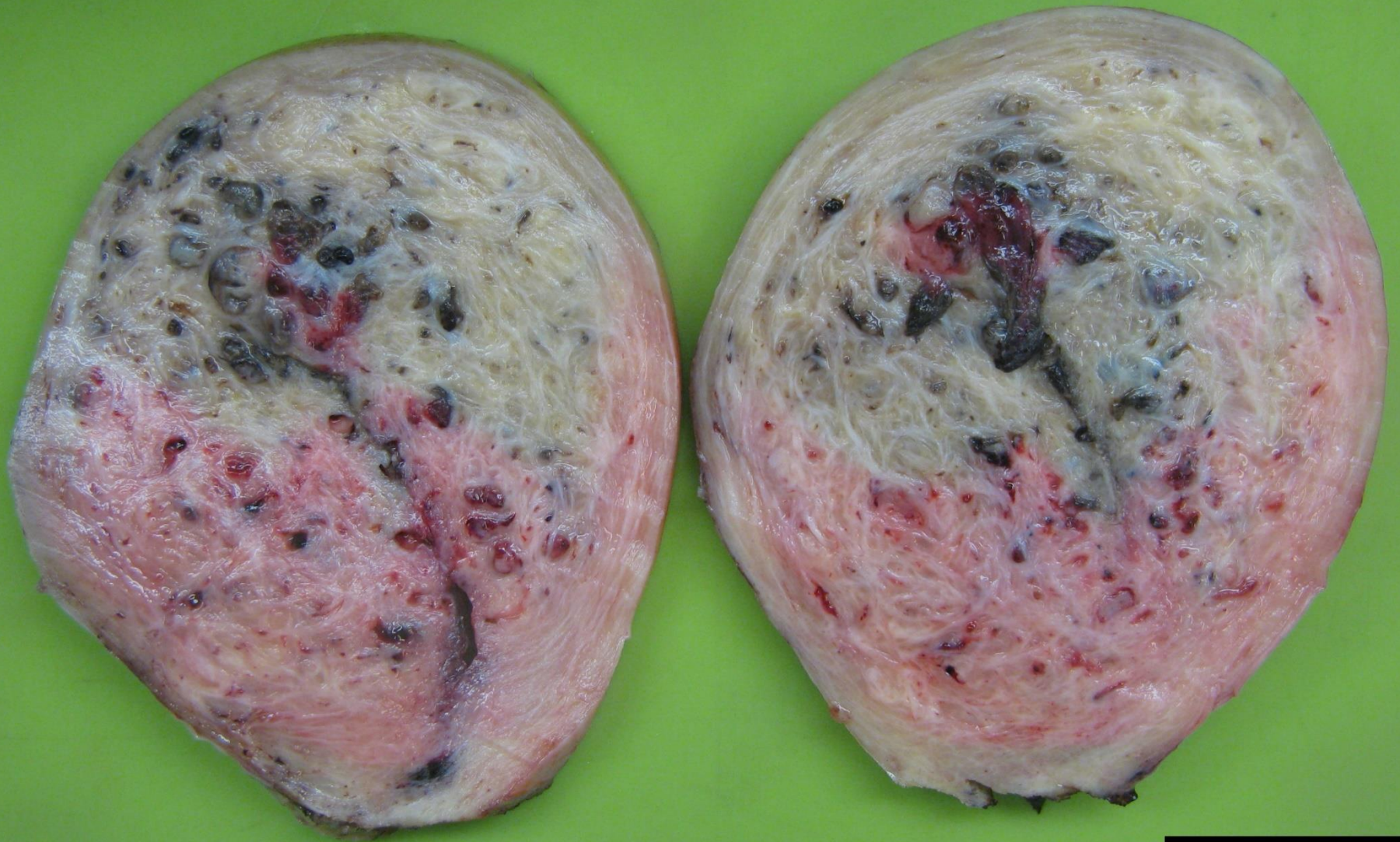Tubal metaplasia

# Adenomyosis and endometriosis

- **Adenomyosis:** endometrial glands and stroma deep within the myometrium (by at least 2-3 mm from endometrium)
- **Endometriosis:** endometrial tissue outside the uterus
  - made of functional endometrium undergoing cyclic changes
  - origin from müllerian rests?  
implantation? lymphatic or hematogenous spread?
  - most commonly within the ovaries, uterine ligaments, on the pelvic peritoneum, bowel, appendix, cervix, fallopian tube, laparotomy scars
  - pelvic pain, dysmenorrhea, infertility
  - Deep infiltrating endometriosis (DIE)

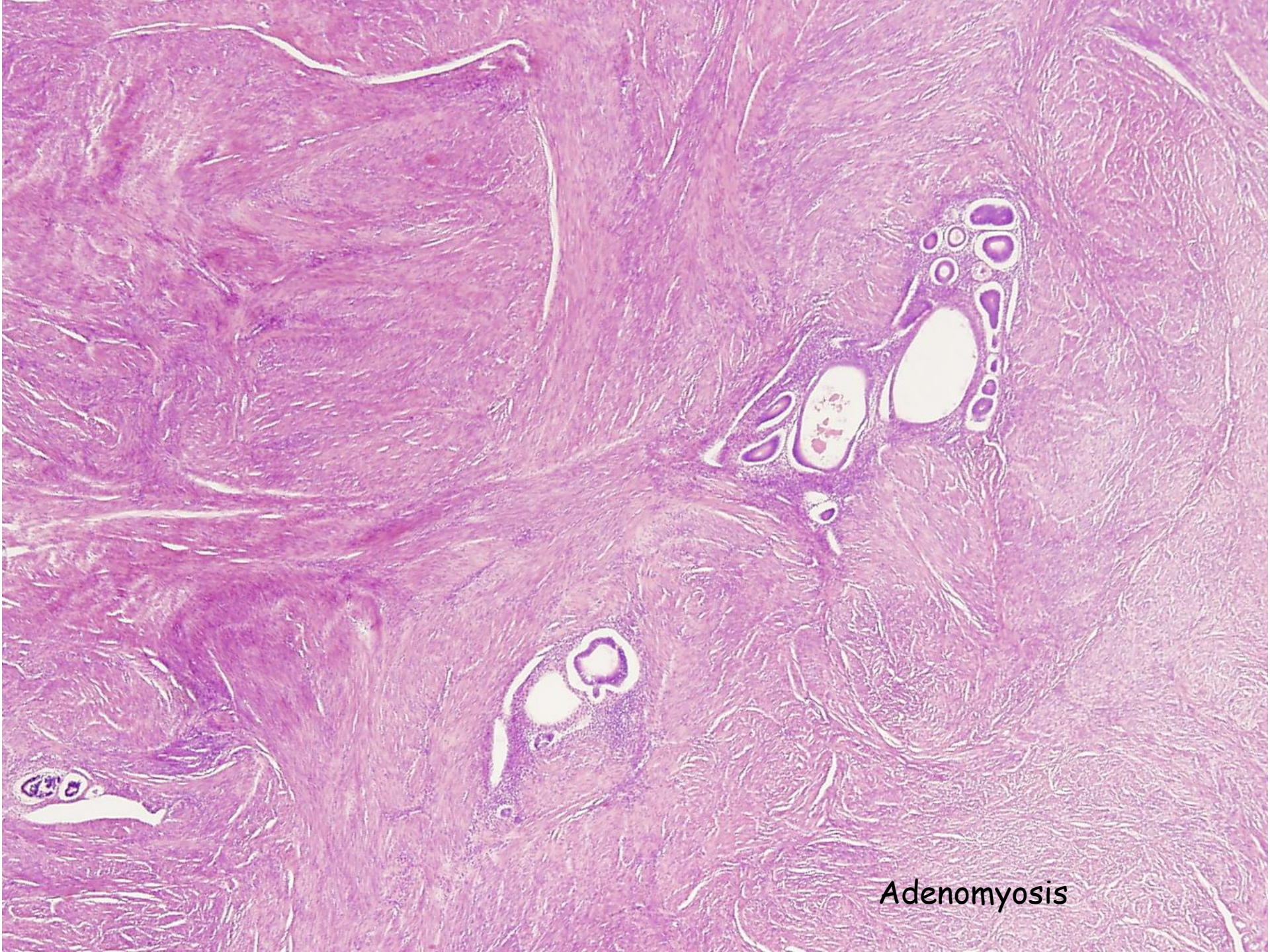


Adenomyosis and endometrial polyp

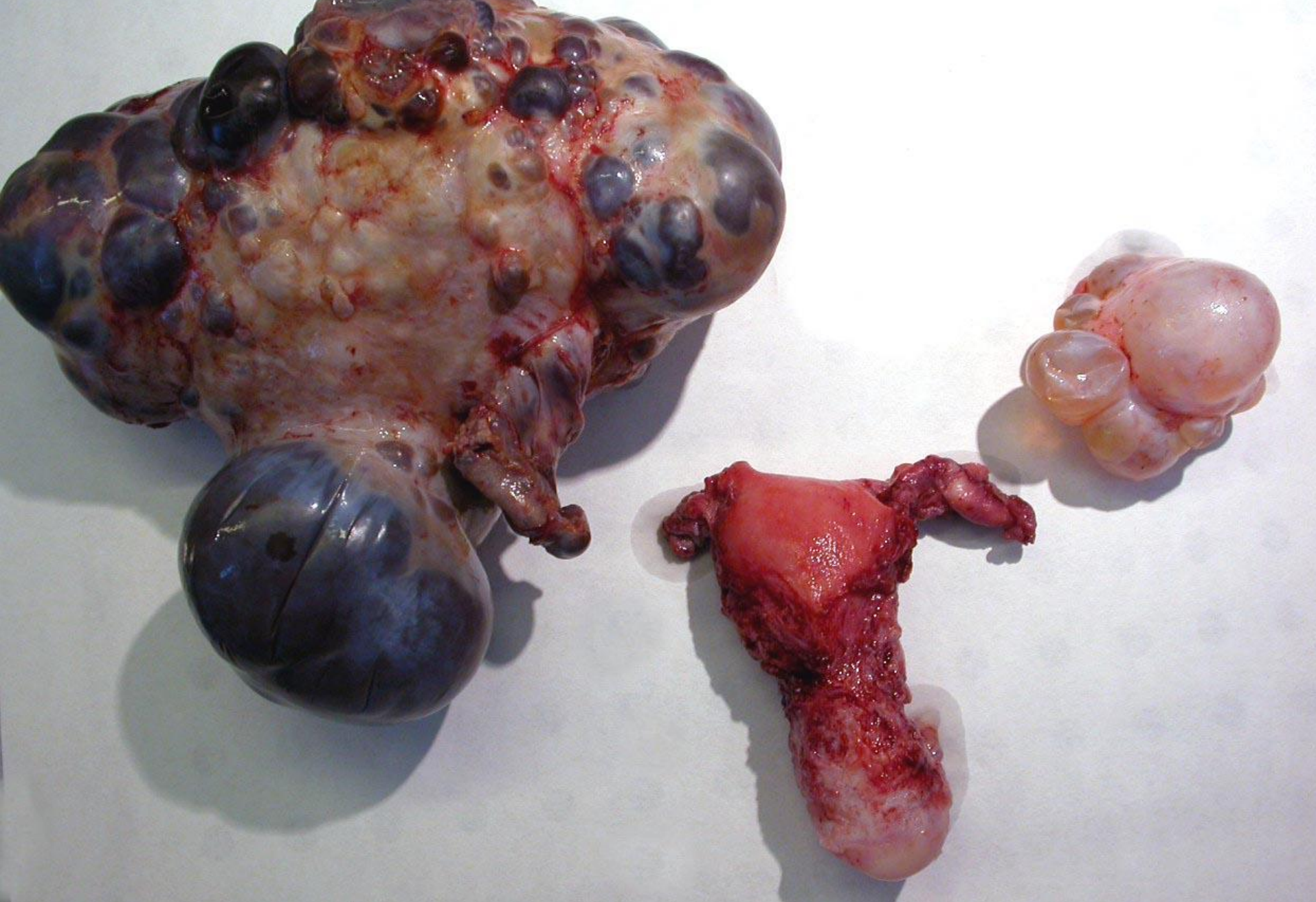

Adenomyosis

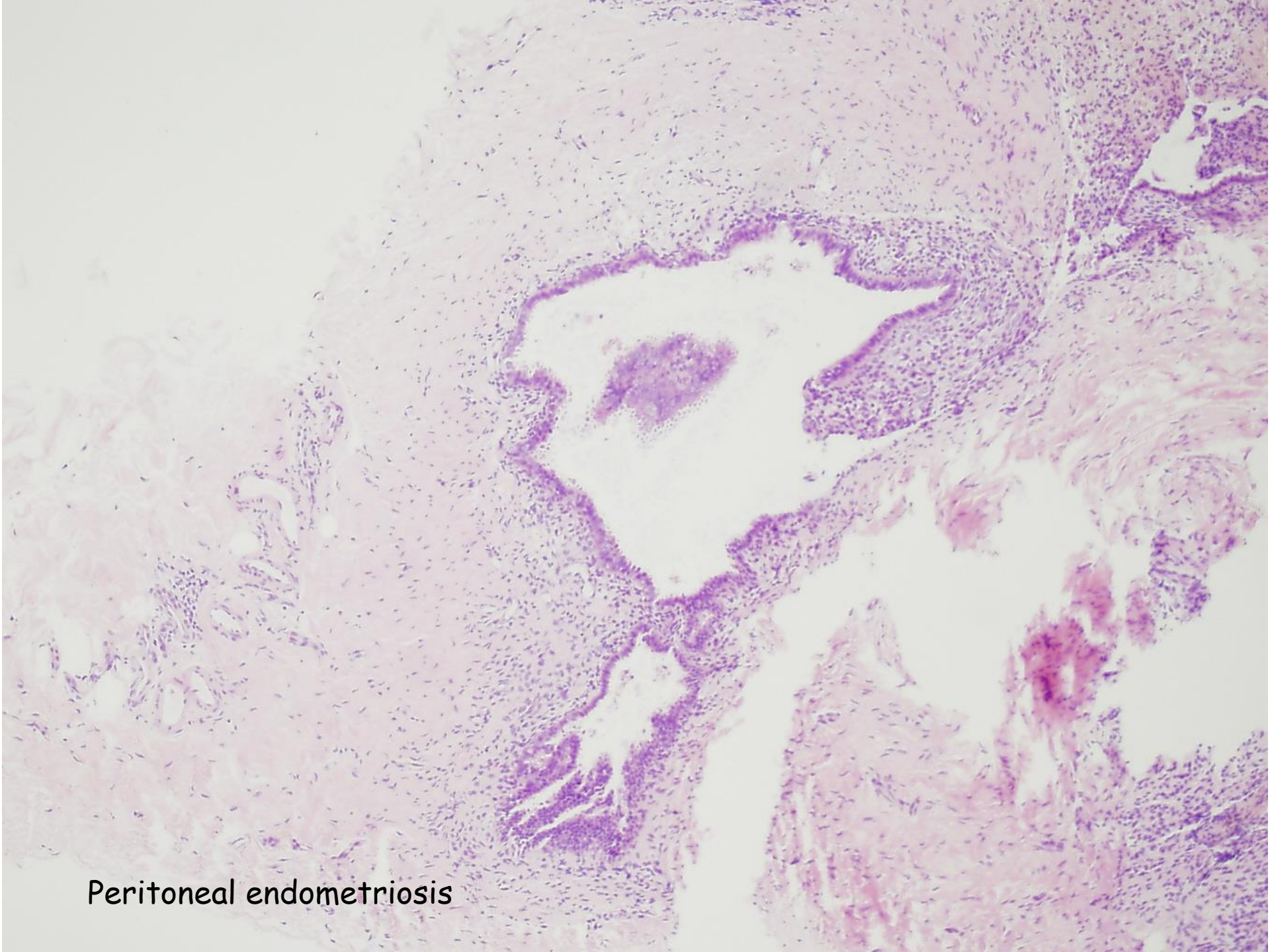
# 5081



Adenomyosis



Endometriosis of ovary- cyst formation (chocolate cyst)



Peritoneal endometriosis

# Endometrial polyps

- not true neoplasms, exophytic mass
- may occur after Tamoxifen (SERM) administration
- asymptomatic or may produce abnormal bleeding (AUB-P)
- MA: projects into the body cavity
- MI: cystically dilated glands, fibrous stroma and **thick-walled vessels**
- adenocarcinoma arising in ~ is possible

# UTERINE NEOPLASIAS

# Tumors of the uterine corpus

Arising from		Benign	Malignant
Endometrium	Endometrial glands	-	Endometrioid carcinoma Serous cc Clear cell cc
	Endometrial stroma	Stromal nodule	Stromal sarcoma
	Endometrial glands and stroma	Adenofibroma Adenomyoma	Carcinosarcoma Adenosarcoma
Myometrium		Leiomyoma	Leiomyosarcoma

# WHO classification of tumours of the uterine corpus

## Endometrial epithelial tumours and precursors

	Endometrial hyperplasia without atypia
8380/2	Atypical hyperplasia of the endometrium
8380/3	Endometrioid adenocarcinoma NOS
	POLE-ultramutated endometrioid carcinoma
	Mismatch repair-deficient endometrioid carcinoma
	p53-mutant endometrioid carcinoma
	No specific molecular profile (NSMP) endometrioid carcinoma
8441/3	Serous carcinoma NOS
8310/3	Clear cell adenocarcinoma NOS
8020/3	Carcinoma, undifferentiated, NOS
8323/3	Mixed cell adenocarcinoma
9110/3	Mesonephric adenocarcinoma
8070/3	Squamous cell carcinoma NOS
8144/3	Mucinous carcinoma, intestinal type
9111/3*	Mesonephric-like adenocarcinoma
8980/3	Carcinosarcoma NOS

## Tumour-like lesions

Endometrial polyp  
Endometrial metaplasia  
Arias-Stella reaction

## Mesenchymal tumours specific to the uterus

8890/0	Leiomyoma NOS
8890/0	Lipoleiomyoma
8890/0	Leiomyoma, apoplectic
8890/0	Leiomyoma, hydropic
8890/0	Dissecting leiomyoma
8892/0	Cellular leiomyoma
8896/0	Myxoid leiomyoma
8891/0	Epithelioid leiomyoma
8893/0	Symplastic leiomyoma
8890/1	Leiomyomatosis NOS
8890/1	Intravenous leiomyomatosis

8897/1	Smooth muscle tumour of uncertain malignant potential
8891/1*	Epithelioid smooth muscle tumour of uncertain malignant potential
8896/1*	Myxoid smooth muscle tumour of uncertain malignant potential
	Spindle smooth muscle tumour of uncertain malignant potential
8898/1	Metastasizing leiomyoma
8890/3	Leiomyosarcoma NOS
	Spindle leiomyosarcoma
8891/3	Epithelioid leiomyosarcoma
8896/3	Myxoid leiomyosarcoma
8930/0	Endometrial stromal nodule
8931/3	Endometrial stromal sarcoma, low grade
8930/3	Endometrial stromal sarcoma, high grade
8805/3	Undifferentiated sarcoma
8590/1	Uterine tumour resembling ovarian sex cord tumour
8714/0	Perivascular epithelioid tumour, benign
8714/3	Perivascular epithelioid tumour, malignant
8825/1	Inflammatory myofibroblastic tumour
	Epithelioid myofibroblastic sarcoma

## Mixed epithelial and mesenchymal tumours

8932/0	Adenomyoma NOS
8932/0	Atypical polypoid adenomyoma
8933/3	Adenosarcoma

## Miscellaneous tumours

9473/3	Primitive neuroectodermal tumour NOS
9064/3	Germ cell tumour NOS
9071/3	Yolk sac tumour NOS
9080/0	Mature teratoma NOS
9080/3	Immature teratoma NOS

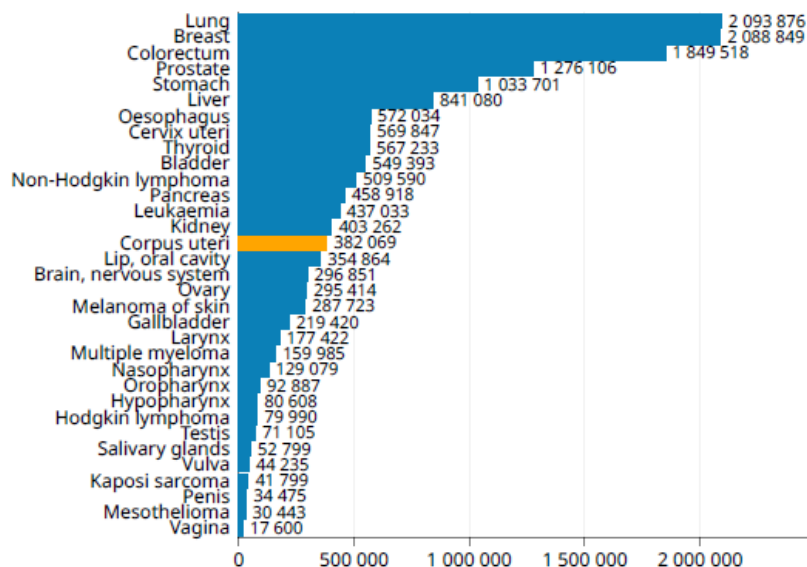
WHO, 5th edition, 2020

# Corpus uteri

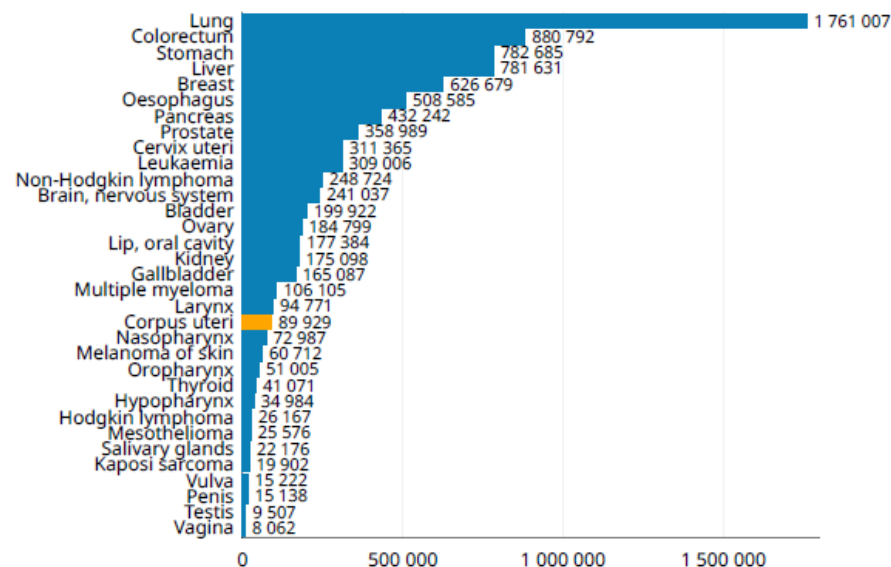
Source: Globocan 2018

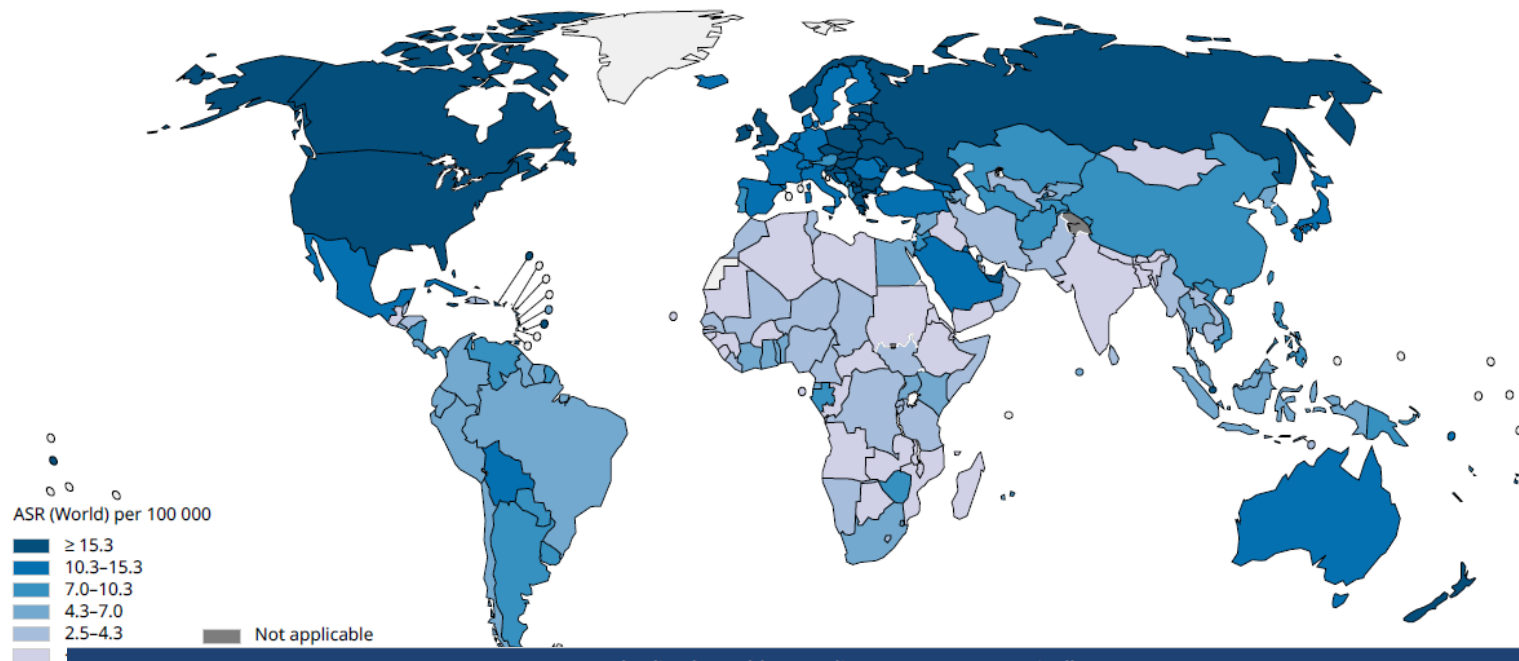


Number of new cases in 2018, both sexes, all ages

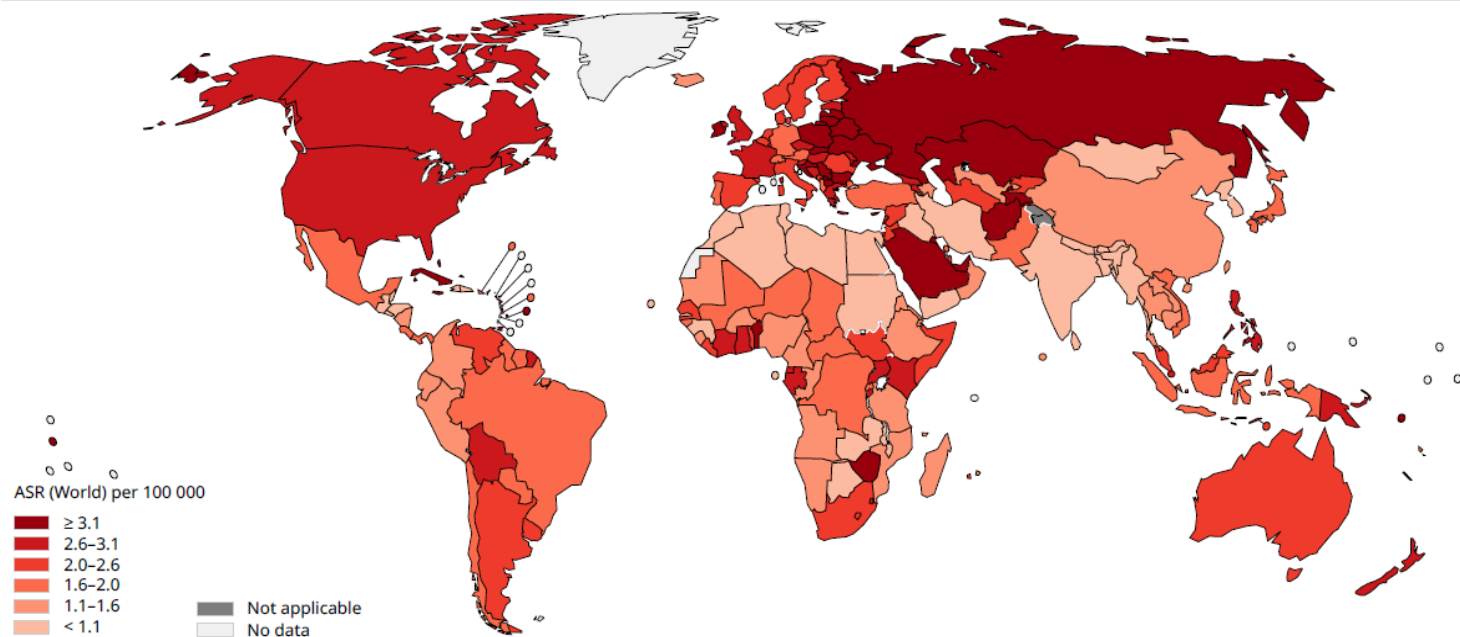


Number of deaths in 2018, both sexes, all ages





Age standardized (World) mortality rates, corpus uteri, all ages



# Endometrial carcinoma

- 7% of all (non-skin)cancers in women
- mainly in postmenopausal woman (55-65 y)
- If it affects women  $\leq 40$  y Lynch syndrome should be excluded
- SY: usually postmenopausal bleeding

# WHO classification of tumours of the uterine corpus

## Endometrial epithelial tumours and precursors

	Endometrial hyperplasia without atypia
8380/2	Atypical hyperplasia of the endometrium
8380/3	Endometrioid adenocarcinoma NOS
	<i>POLE</i> -ultramutated endometrioid carcinoma
	Mismatch repair-deficient endometrioid carcinoma
	p53-mutant endometrioid carcinoma
	No specific molecular profile (NSMP) endometrioid carcinoma
8441/3	Serous carcinoma NOS
8310/3	Clear cell adenocarcinoma NOS
8020/3	Carcinoma, undifferentiated, NOS
8323/3	Mixed cell adenocarcinoma
9110/3	Mesonephric adenocarcinoma
8070/3	Squamous cell carcinoma NOS
8144/3	Mucinous carcinoma, intestinal type
9111/3*	Mesonephric-like adenocarcinoma
8980/3	Carcinosarcoma NOS

## Tumour-like lesions

Endometrial polyp  
Endometrial metaplasia  
Arias-Stella reaction

## Mesenchymal tumours specific to the uterus

8890/0	Leiomyoma NOS
8890/0	Lipoleiomyoma
8890/0	Leiomyoma, apoplectic
8890/0	Leiomyoma, hydropic
8890/0	Dissecting leiomyoma
8892/0	Cellular leiomyoma
8896/0	Myxoid leiomyoma
8891/0	Epithelioid leiomyoma
8893/0	Symplastic leiomyoma
8890/1	Leiomyomatosis NOS
8890/1	Intravenous leiomyomatosis

8897/1	Smooth muscle tumour of uncertain malignant potential
8891/1*	Epithelioid smooth muscle tumour of uncertain malignant potential
8896/1*	Myxoid smooth muscle tumour of uncertain malignant potential
	Spindle smooth muscle tumour of uncertain malignant potential
8898/1	Metastasizing leiomyoma
8890/3	Leiomyosarcoma NOS
	Spindle leiomyosarcoma
8891/3	Epithelioid leiomyosarcoma
8896/3	Myxoid leiomyosarcoma
8930/0	Endometrial stromal nodule
8931/3	Endometrial stromal sarcoma, low grade
8930/3	Endometrial stromal sarcoma, high grade
8805/3	Undifferentiated sarcoma
8590/1	Uterine tumour resembling ovarian sex cord tumour
8714/0	Perivascular epithelioid tumour, benign
8714/3	Perivascular epithelioid tumour, malignant
8825/1	Inflammatory myofibroblastic tumour
	Epithelioid myofibroblastic sarcoma

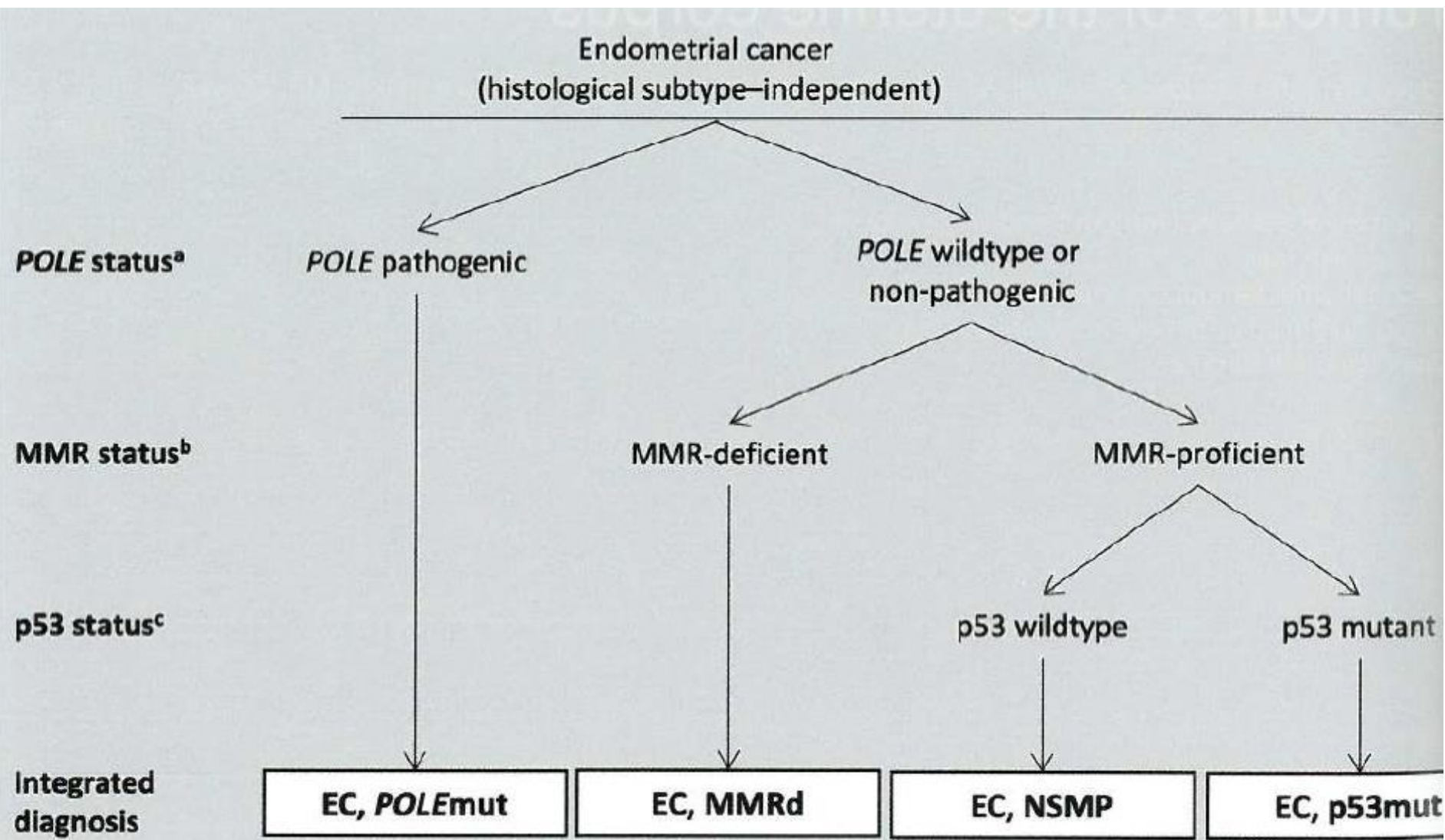
## Mixed epithelial and mesenchymal tumours

8932/0	Adenomyoma NOS
8932/0	Atypical polypoid adenomyoma
8933/3	Adenosarcoma

## Miscellaneous tumours

9473/3	Primitive neuroectodermal tumour NOS
9064/3	Germ cell tumour NOS
9071/3	Yolk sac tumour NOS
9080/0	Mature teratoma NOS
9080/3	Immature teratoma NOS

WHO, 5th edition, 2020



Az endometrialis endometrioid carcinoma molekuláris klasszifikációja

WHO 5.kiadás, 2020 (ProMisE (Proactive Molecular Risk Classifier for Endometrial Cancer))

*POLE*mut: hotspot mutációk a DNS polimeráz epsilon (*POLE*) exonukleáz doménjén

MMR: mismatch repair

# Endometrial carcinoma

- **Endometrioid carcinoma**
  - on a background of endometrial hyperplasia
  - Obesity, diabetes, hypertension, infertility, Stein- Leventhal sy, longstanding estrogen users, breast cancer patients treated with Tamoxifen
  - more favorable prognosis
  - usually well differentiated

# Endometrial carcinoma

- **Endometrioid carcinoma (cont)**
  - Grading
    - Grade 1: if < 5% solid growth,
    - Grade 2: if < 50% solid growth
    - Grade 3: if > 50% solid growth

# WHO classification of tumours of the uterine corpus

## Endometrial epithelial tumours and precursors

	Endometrial hyperplasia without atypia
8380/2	Atypical hyperplasia of the endometrium
8380/3	Endometrioid adenocarcinoma NOS
	POLE-ultramutated endometrioid carcinoma
	Mismatch repair-deficient endometrioid carcinoma
	p53-mutant endometrioid carcinoma
	No specific molecular profile (NSMP) endometrioid carcinoma
8441/3	Serous carcinoma NOS
8310/3	Clear cell adenocarcinoma NOS
8020/3	Carcinoma, undifferentiated, NOS
8323/3	Mixed cell adenocarcinoma
9110/3	Mesonephric adenocarcinoma
8070/3	Squamous cell carcinoma NOS
8144/3	Mucinous carcinoma, intestinal type
9111/3*	Mesonephric-like adenocarcinoma
8980/3	Carcinosarcoma NOS

## Tumour-like lesions

Endometrial polyp  
Endometrial metaplasia  
Arias-Stella reaction

## Mesenchymal tumours specific to the uterus

8890/0	Leiomyoma NOS
8890/0	Lipoleiomyoma
8890/0	Leiomyoma, apoplectic
8890/0	Leiomyoma, hydropic
8890/0	Dissecting leiomyoma
8892/0	Cellular leiomyoma
8896/0	Myxoid leiomyoma
8891/0	Epithelioid leiomyoma
8893/0	Symplastic leiomyoma
8890/1	Leiomyomatosis NOS
8890/1	Intravascular leiomyomatosis

8897/1	Smooth muscle tumour of uncertain malignant potential
8891/1*	Epithelioid smooth muscle tumour of uncertain malignant potential
8896/1*	Myxoid smooth muscle tumour of uncertain malignant potential
	Spindle smooth muscle tumour of uncertain malignant potential
8898/1	Metastasizing leiomyoma
8890/3	Leiomyosarcoma NOS
	Spindle leiomyosarcoma
8891/3	Epithelioid leiomyosarcoma
8896/3	Myxoid leiomyosarcoma
8930/0	Endometrial stromal nodule
8931/3	Endometrial stromal sarcoma, low grade
8930/3	Endometrial stromal sarcoma, high grade
8805/3	Undifferentiated sarcoma
8590/1	Uterine tumour resembling ovarian sex cord tumour
8714/0	Perivascular epithelioid tumour, benign
8714/3	Perivascular epithelioid tumour, malignant
8825/1	Inflammatory myofibroblastic tumour
	Epithelioid myofibroblastic sarcoma

## Mixed epithelial and mesenchymal tumours

8932/0	Adenomyoma NOS
8932/0	Atypical polypoid adenomyoma
8933/3	Adenosarcoma

## Miscellaneous tumours

9473/3	Primitive neuroectodermal tumour NOS
9064/3	Germ cell tumour NOS
9071/3	Yolk sac tumour NOS
9080/0	Mature teratoma NOS
9080/3	Immature teratoma NOS

WHO, 5th edition, 2020

# Endometrial carcinoma

- **Serous carcinoma**
  - not associated with endometrial hyperplasia
  - Usually in the setting of atrophy
  - Poorly differentiated, aggressive
  - high grade cytologic features, necrosis, lymphovascular invasion, transtubal spread
  - Papillary, glandular
  - mutation of TP53
  - Early lesion: Serous Endometrial Intraepithelial Carcinoma (SEIC)

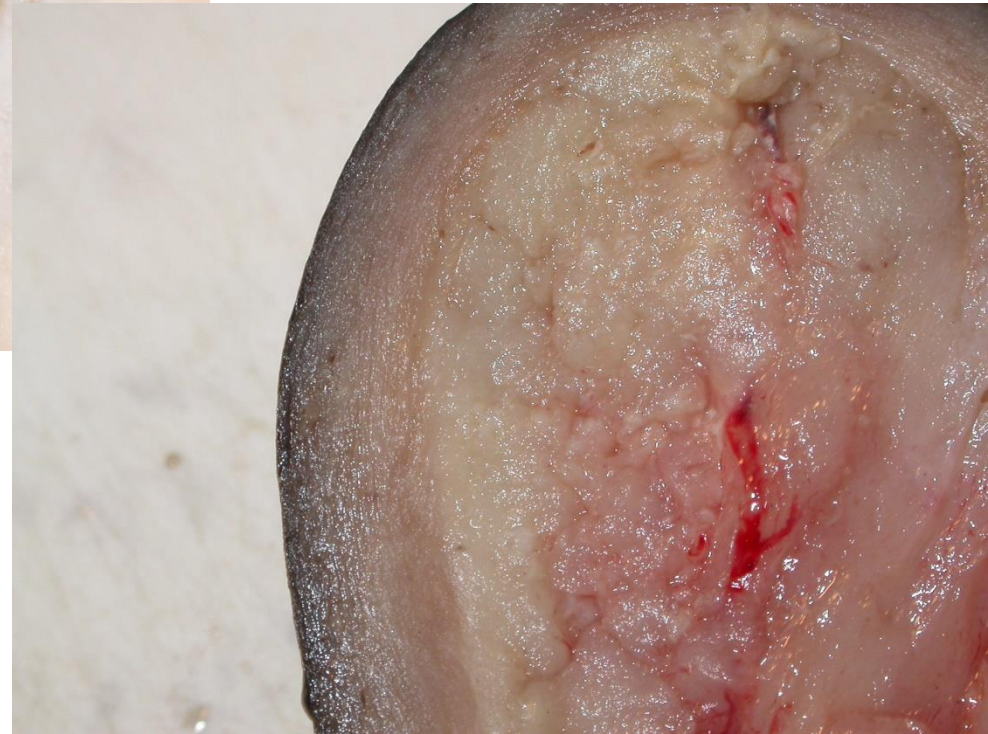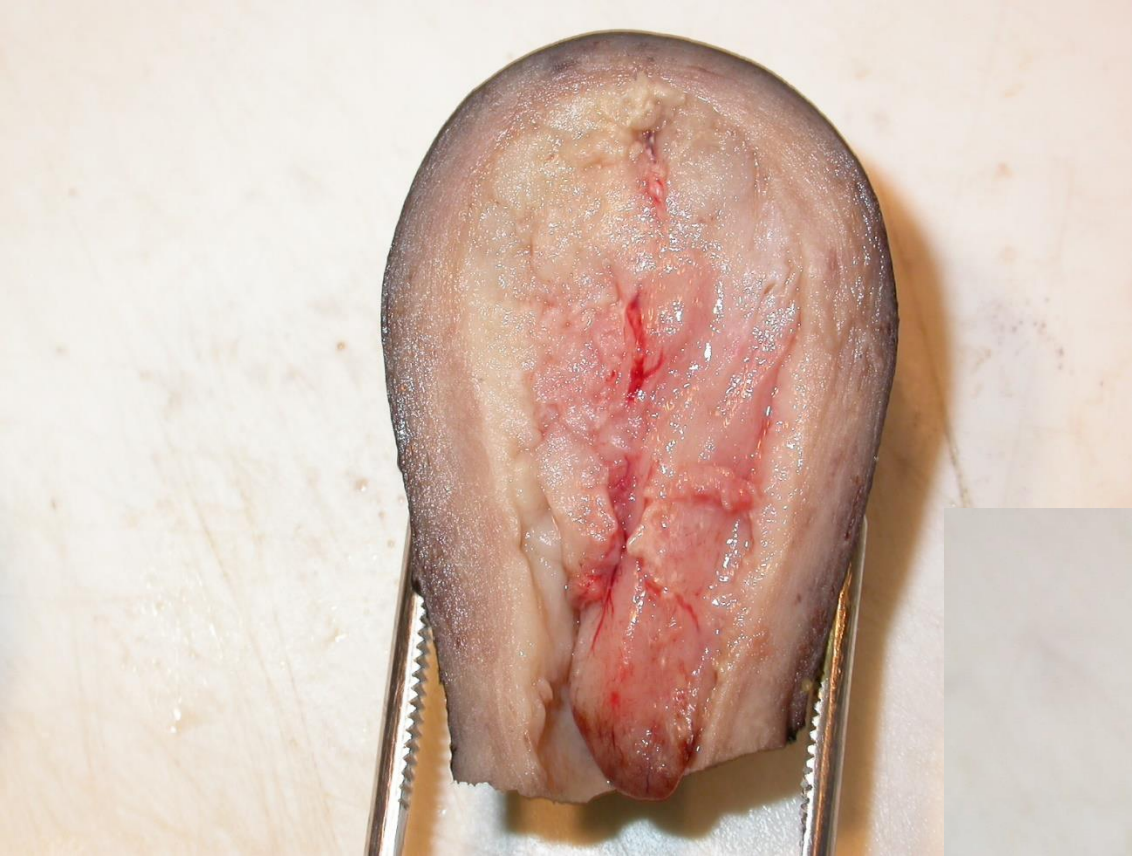# Endometrial carcinoma

## • Spread and metastases

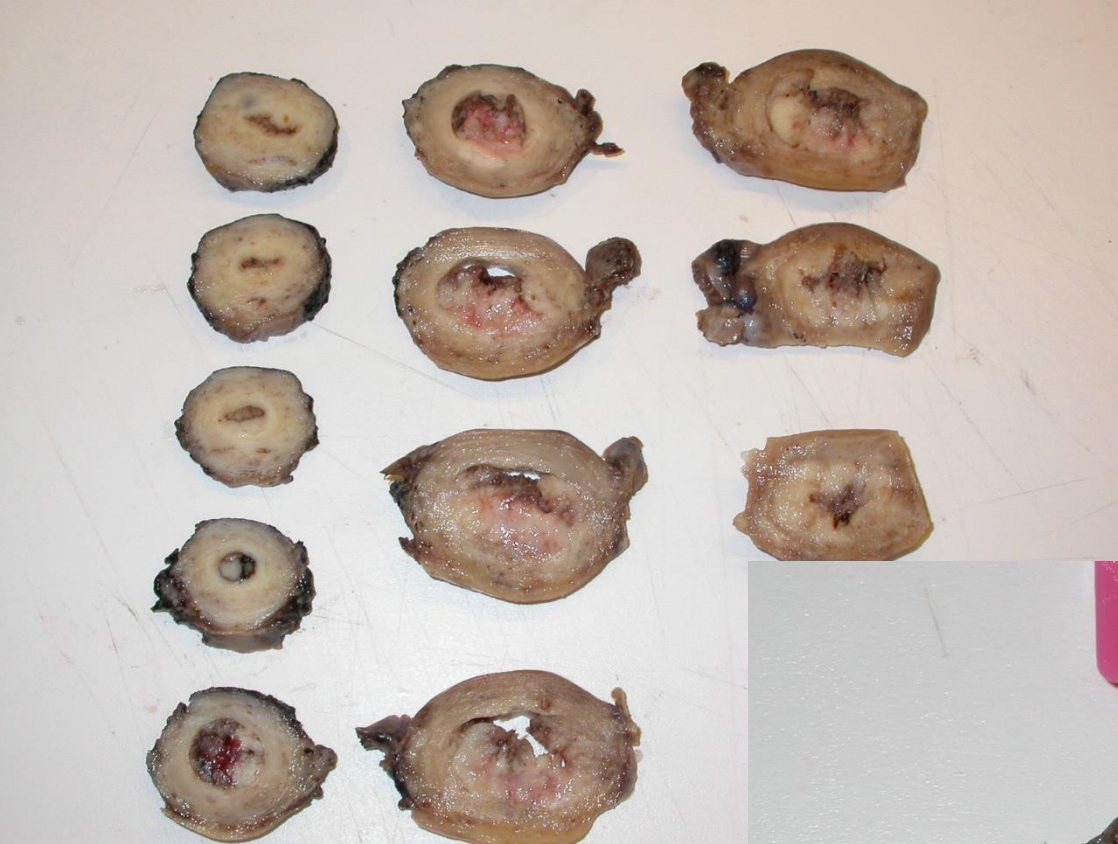- local spread: myometrium and cervix
- extrauterine spread: pelvic and paraaortic lymph nodes, ovaries
- serous carcinoma: early spread to the peritoneum, transtubal spread

TNM Categories	FIGO Stages	
TX		Primary tumour cannot be assessed
To		No evidence of primary tumour
T1	I <sup>a</sup>	Tumour confined to the corpus uteri <sup>a</sup>
	T1a IA <sup>a</sup>	Tumour limited to endometrium or invading less than half of myometrium
	T1b IB	Tumour invades one half or more of myometrium
T2	II	Tumour invades cervical stroma, but does not extend beyond the uterus
T3	III	Local and/or regional spread as specified here:
	T3a IIIA	Tumour invades the serosa of the corpus uteri or adnexae (direct extension or metastasis)
	T3b IIIB	Vaginal or parametrial involvement (direct extension or metastasis)
N1,N2	IIIC	Metastasis to pelvic or para.aortic lymph nodes <sup>b</sup>
	N1 IIIC1	Metastasis to pelvic lymph nodes
	N2 IIIC2	Metastasis to para.aortic lymph nodes with or without metastasis to pelvic lymph nodes
T4 <sup>c</sup>	IV	Tumour invades bladder/bowel mucosa

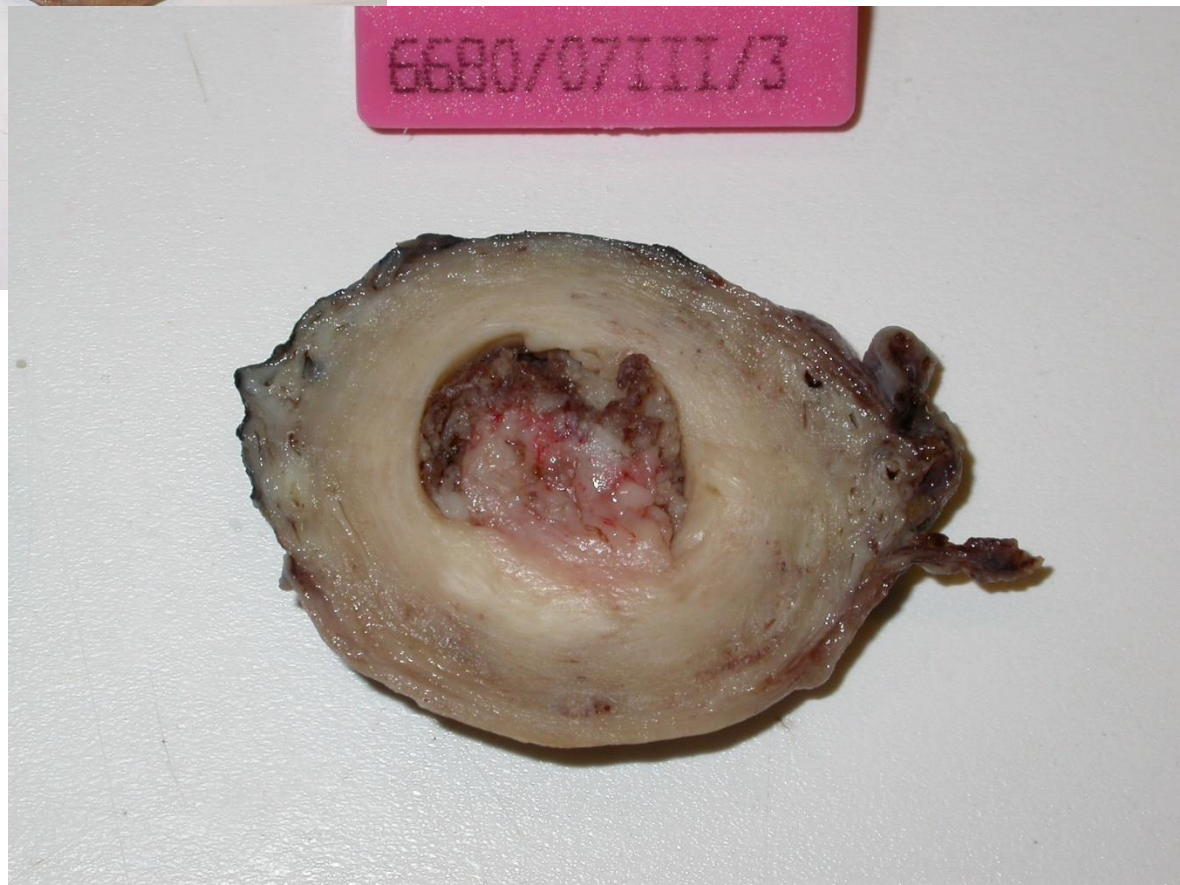TNM, 8th edition



Endometrioid carcinoma

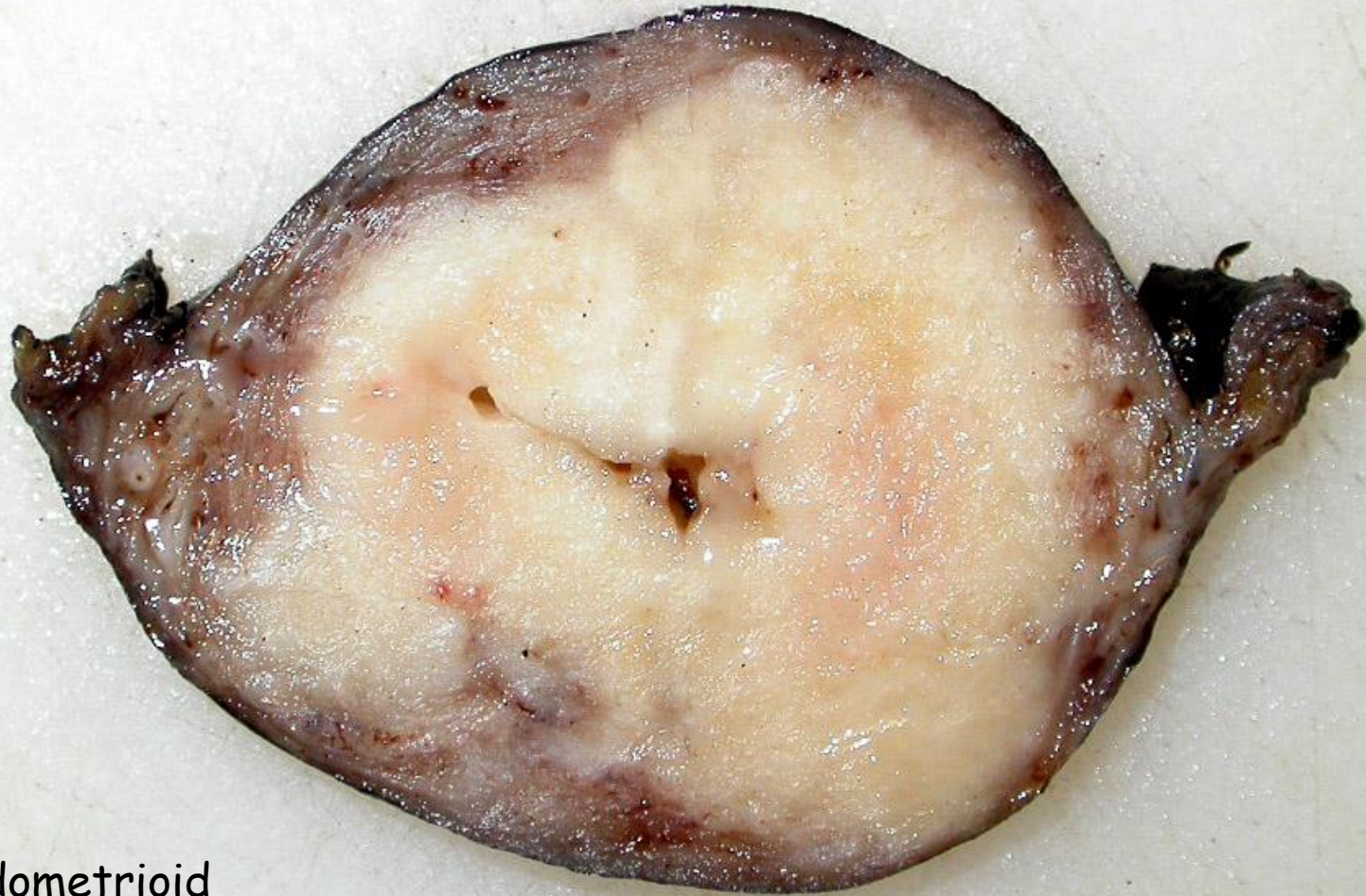

6680/07III/3

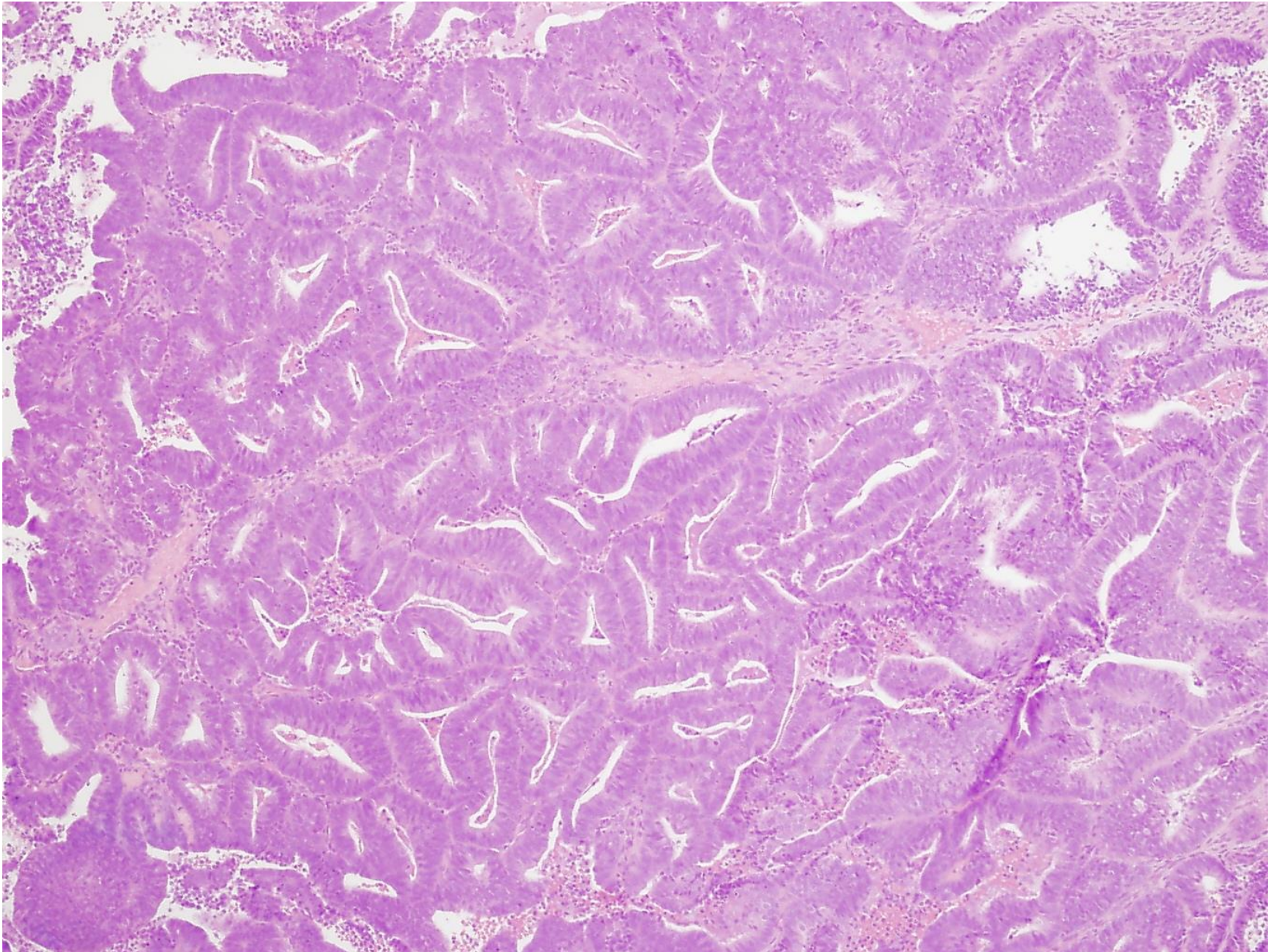


Endometrioid carcinoma

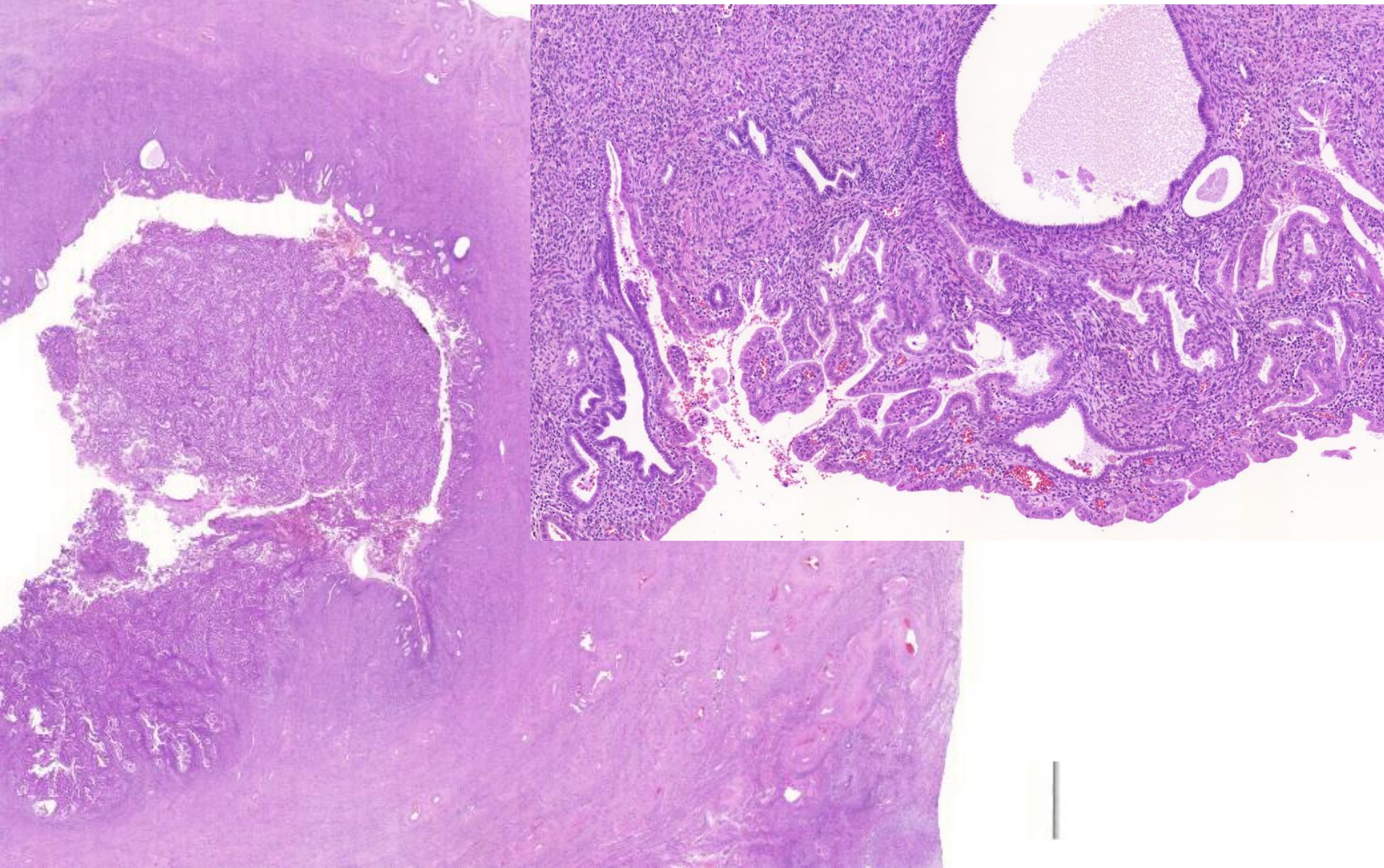
6180/05 2



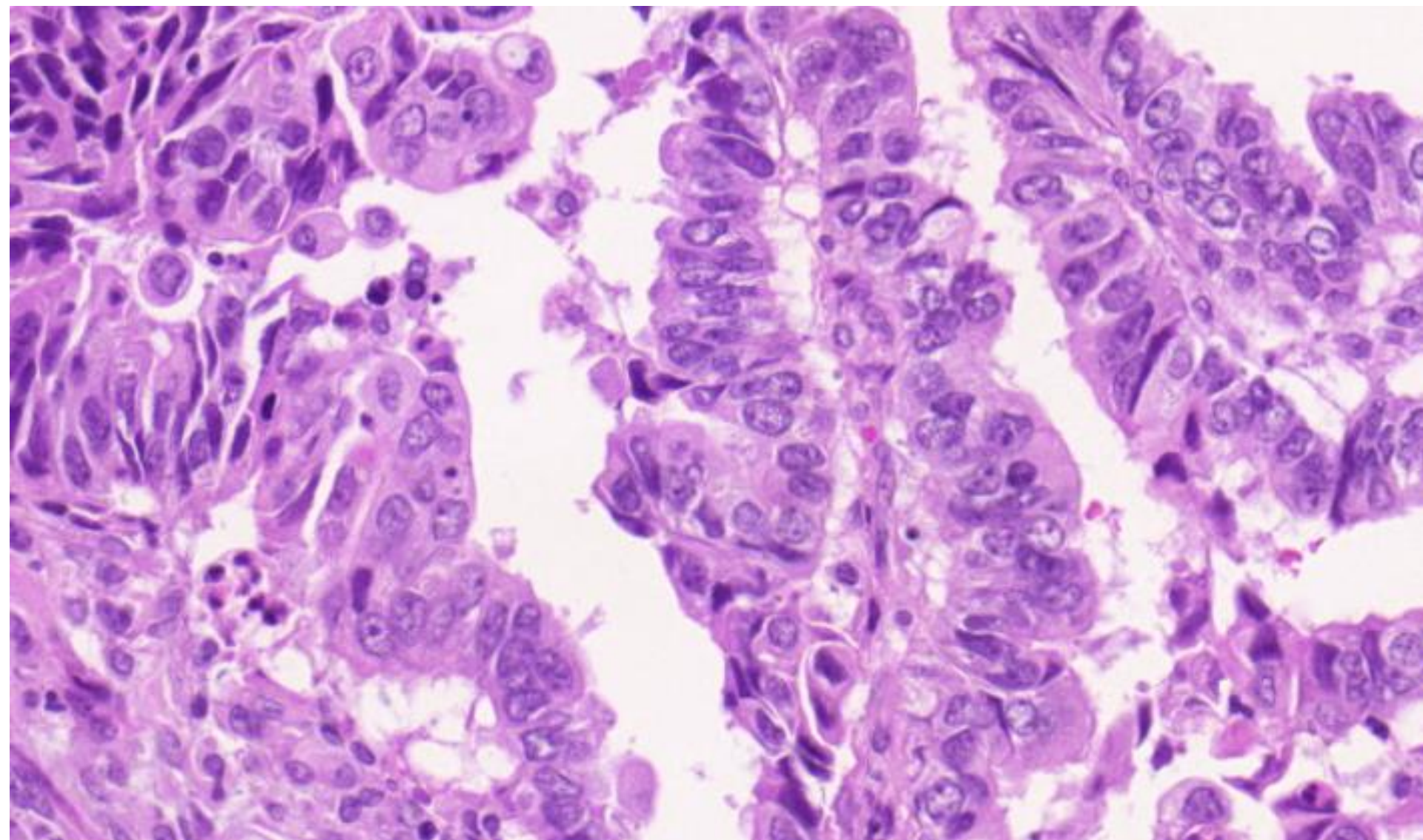
Endometrioid  
carcinoma



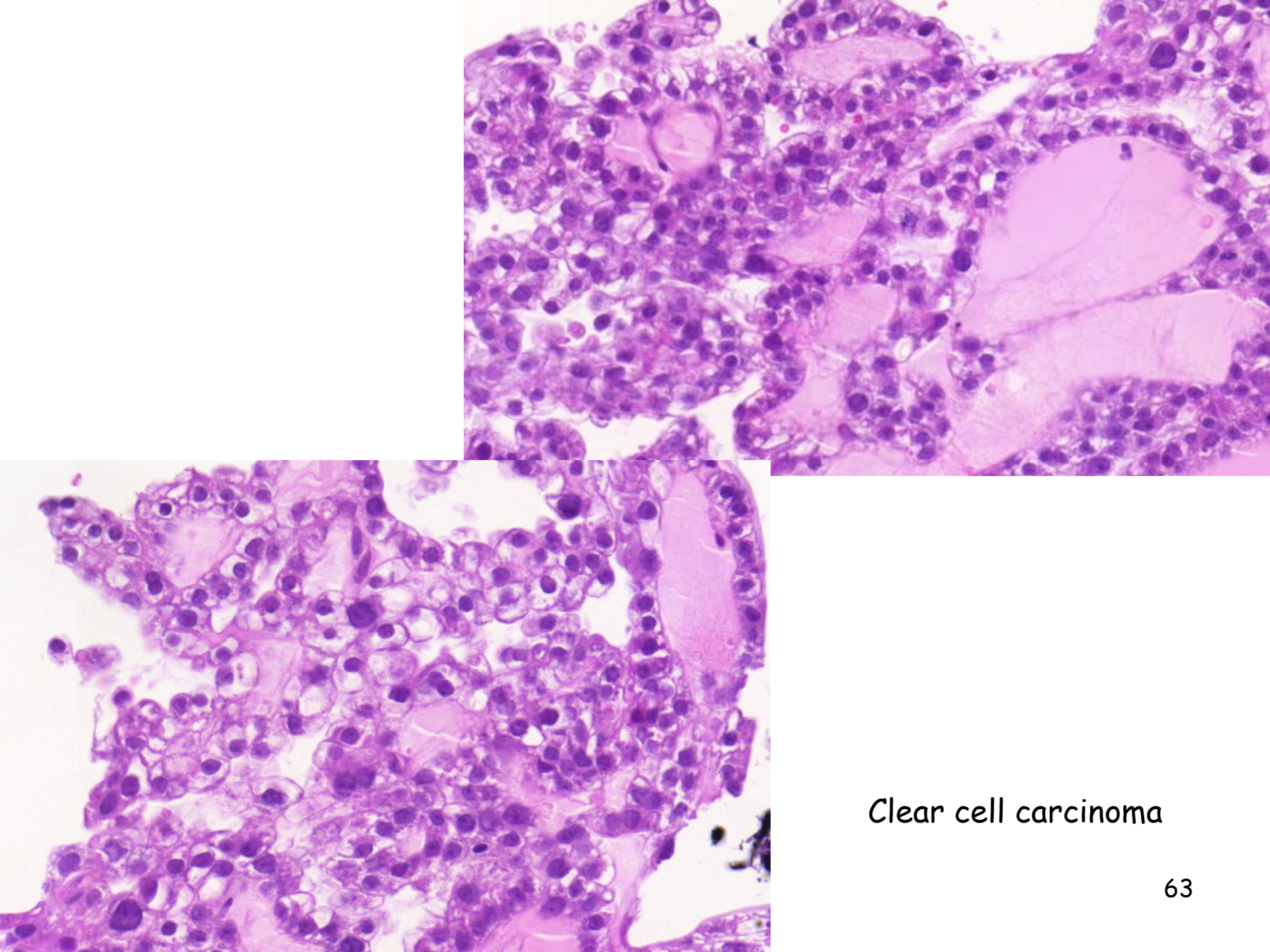
Endometrioid carcinoma



Serous carcinoma



Papillary structures-high grade cytomorphology- Serous carcinoma



Clear cell carcinoma

# Tumors of the uterine corpus

Arising from		Benign	Malignant
Endometrium	Endometrial glands	-	Endometrioid carcinoma Serous cc Clear cell cc
	Endometrial stroma	Stromal nodule	Stromal sarcoma
	Endometrial glands and stroma	Adenofibroma Adenomyoma	Carcinosarcoma Adenosarcoma
Myometrium		Leiomyoma	Leiomyosarcoma

# WHO classification of tumours of the uterine corpus

## Endometrial epithelial tumours and precursors

	Endometrial hyperplasia without atypia
8380/2	Atypical hyperplasia of the endometrium
8380/3	Endometrioid adenocarcinoma NOS
	POLE-ultramutated endometrioid carcinoma
	Mismatch repair-deficient endometrioid carcinoma
	p53-mutant endometrioid carcinoma
	No specific molecular profile (NSMP) endometrioid carcinoma
8441/3	Serous carcinoma NOS
8310/3	Clear cell adenocarcinoma NOS
8020/3	Carcinoma, undifferentiated, NOS
8323/3	Mixed cell adenocarcinoma
9110/3	Mesonephric adenocarcinoma
8070/3	Squamous cell carcinoma NOS
8144/3	Mucinous carcinoma, intestinal type
9111/3*	Mesonephric-like adenocarcinoma
8980/3	Carcinosarcoma NOS

## Tumour-like lesions

Endometrial polyp  
Endometrial metaplasia  
Arias-Stella reaction

## Mesenchymal tumours specific to the uterus

8890/0	Leiomyoma NOS
8890/0	Lipoleiomyoma
8890/0	Leiomyoma, apoplectic
8890/0	Leiomyoma, hydropic
8890/0	Dissecting leiomyoma
8892/0	Cellular leiomyoma
8896/0	Myxoid leiomyoma
8891/0	Epithelioid leiomyoma
8893/0	Symplastic leiomyoma
8890/1	Leiomyomatosis NOS
8890/1	Intravenous leiomyomatosis

8897/1	Smooth muscle tumour of uncertain malignant potential
8891/1*	Epithelioid smooth muscle tumour of uncertain malignant potential
8896/1*	Myxoid smooth muscle tumour of uncertain malignant potential
	Spindle smooth muscle tumour of uncertain malignant potential
8898/1	Metastasizing leiomyoma
8890/3	Leiomyosarcoma NOS
	Spindle leiomyosarcoma
8891/3	Epithelioid leiomyosarcoma
8896/3	Myxoid leiomyosarcoma
8930/0	Endometrial stromal nodule
8931/3	Endometrial stromal sarcoma, low grade
8930/3	Endometrial stromal sarcoma, high grade
8805/3	Undifferentiated sarcoma
8590/1	Uterine tumour resembling ovarian sex cord tumour
8714/0	Perivascular epithelioid tumour, benign
8714/3	Perivascular epithelioid tumour, malignant
8825/1	Inflammatory myofibroblastic tumour
	Epithelioid myofibroblastic sarcoma

## Mixed epithelial and mesenchymal tumours

8932/0	Adenomyoma NOS
8932/0	Atypical polypoid adenomyoma
8933/3	Adenosarcoma

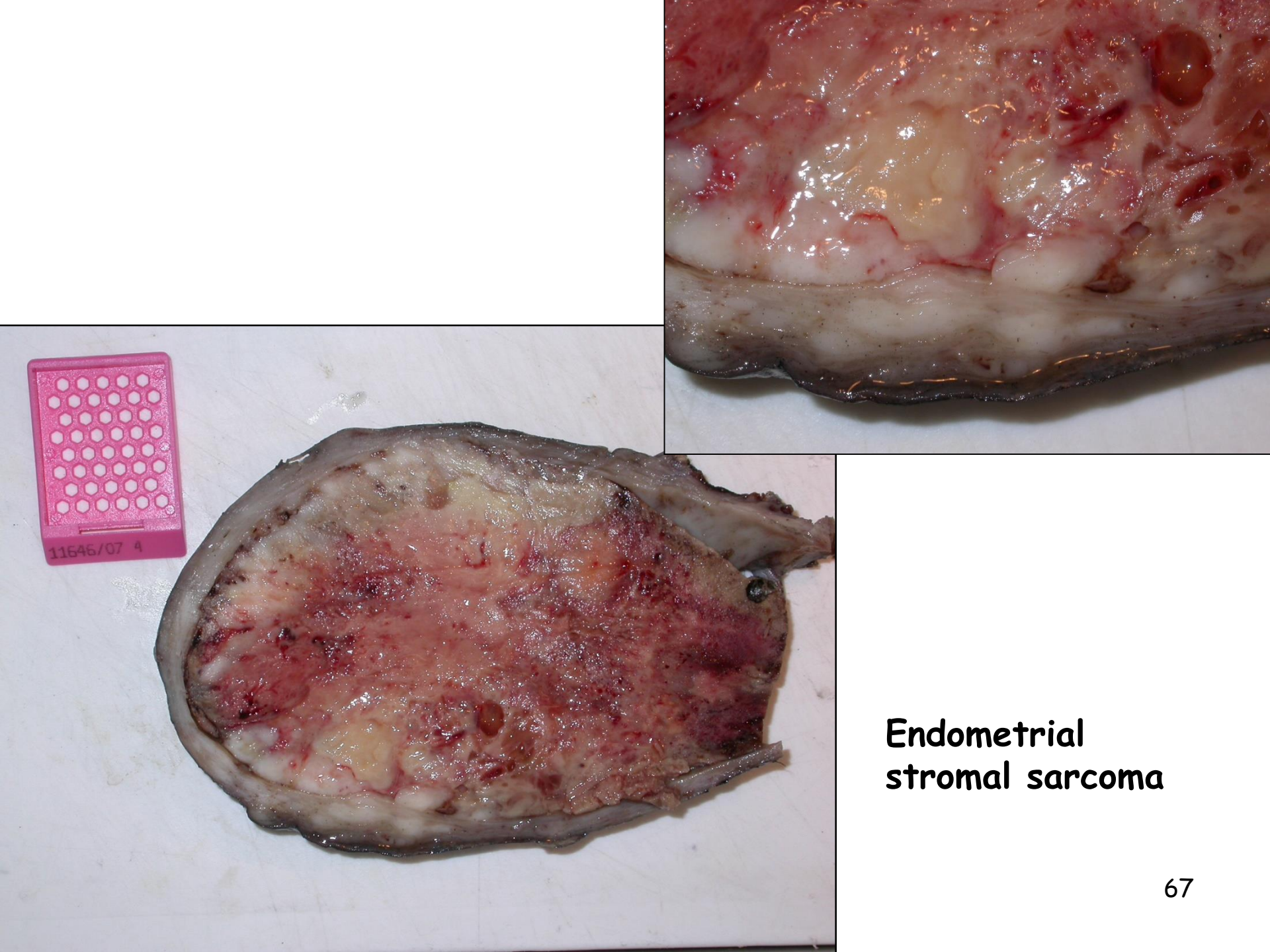
## Miscellaneous tumours

9473/3	Primitive neuroectodermal tumour NOS
9064/3	Germ cell tumour NOS
9071/3	Yolk sac tumour NOS
9080/0	Mature teratoma NOS
9080/3	Immature teratoma NOS

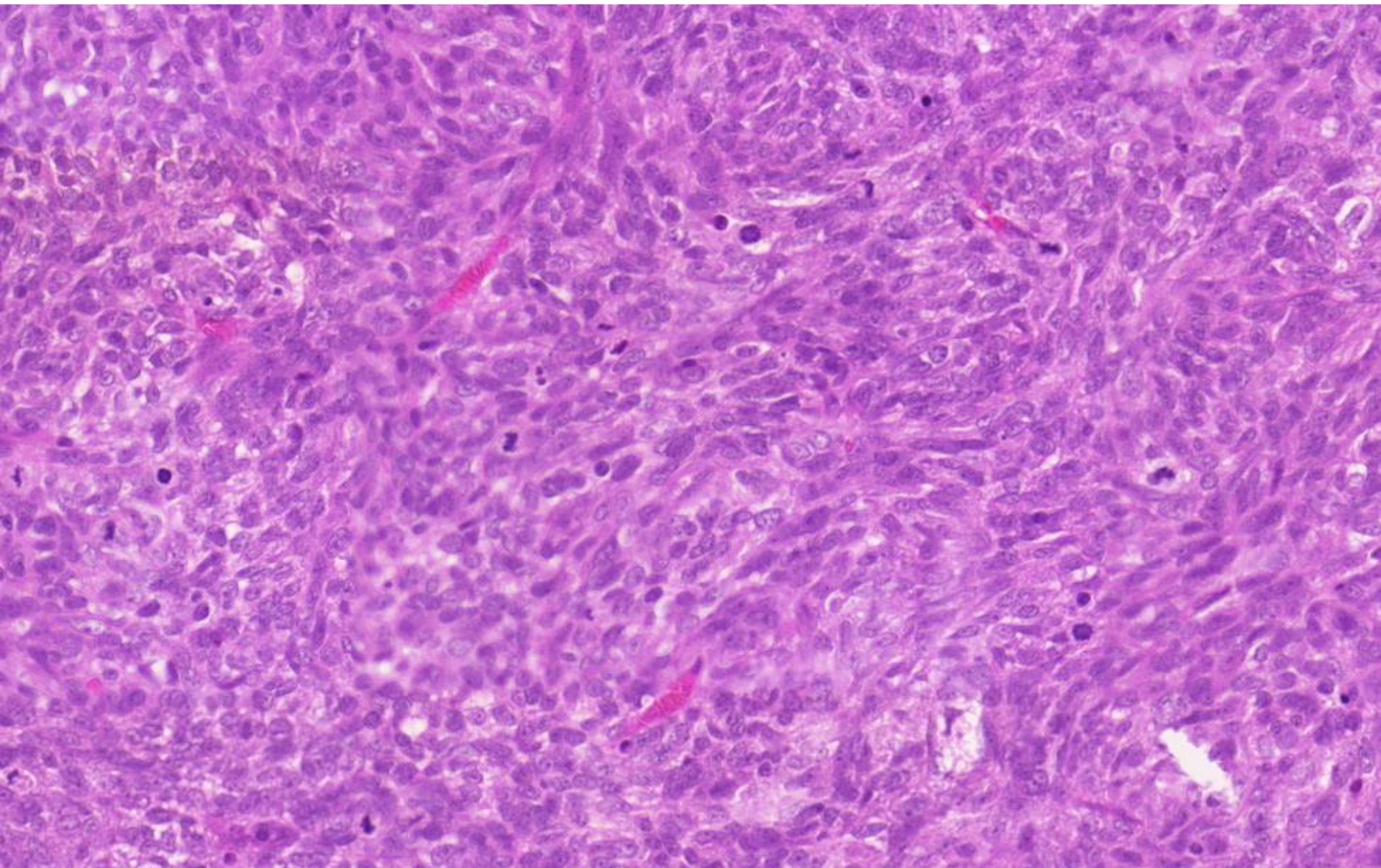
WHO, 5th edition, 2020

# Endometrial stromal tumors

- middle- aged (average 45 y) women
- tumor cells mimicking endometrial stromal cells
- **Endometrial stromal nodule**
- **Endometrial stromal sarcomas**
  - low and high grade group



**Endometrial  
stromal sarcoma**



Endometrial stromal sarcoma



# Tumors of the uterine corpus

Arising from		Benign	Malignant
Endometrium	Endometrial glands	-	Endometrioid carcinoma Serous cc Clear cell cc
	Endometrial stroma	Stromal nodule	Stromal sarcoma
	Endometrial glands and stroma	Adenofibroma Adenomyoma	Carcinosarcoma Adenosarcoma
Myometrium		Leiomyoma	Leiomyosarcoma

# WHO classification of tumours of the uterine corpus

## Endometrial epithelial tumours and precursors

	Endometrial hyperplasia without atypia
8380/2	Atypical hyperplasia of the endometrium
8380/3	Endometrioid adenocarcinoma NOS
	POLE-ultramutated endometrioid carcinoma
	Mismatch repair-deficient endometrioid carcinoma
	p53-mutant endometrioid carcinoma
	No specific molecular profile (NSMP) endometrioid carcinoma
8441/3	Serous carcinoma NOS
8310/3	Clear cell adenocarcinoma NOS
8020/3	Carcinoma, undifferentiated, NOS
8323/3	Mixed cell adenocarcinoma
9110/3	Mesonephric adenocarcinoma
8070/3	Squamous cell carcinoma NOS
8144/3	Mucinous carcinoma, intestinal type
9111/3*	Mesonephric-like adenocarcinoma
8980/3	Carcinosarcoma NOS

## Tumour-like lesions

Endometrial polyp  
Endometrial metaplasia  
Arias-Stella reaction

## Mesenchymal tumours specific to the uterus

8890/0	Leiomyoma NOS
8890/0	Lipoleiomyoma
8890/0	Leiomyoma, apoplectic
8890/0	Leiomyoma, hydropic
8890/0	Dissecting leiomyoma
8892/0	Cellular leiomyoma
8896/0	Myxoid leiomyoma
8891/0	Epithelioid leiomyoma
8893/0	Symplastic leiomyoma
8890/1	Leiomyomatosis NOS
8890/1	Intravenous leiomyomatosis

8897/1	Smooth muscle tumour of uncertain malignant potential
8891/1*	Epithelioid smooth muscle tumour of uncertain malignant potential
8896/1*	Myxoid smooth muscle tumour of uncertain malignant potential
	Spindle smooth muscle tumour of uncertain malignant potential
8898/1	Metastasizing leiomyoma
8890/3	Leiomyosarcoma NOS
	Spindle leiomyosarcoma
8891/3	Epithelioid leiomyosarcoma
8896/3	Myxoid leiomyosarcoma
8930/0	Endometrial stromal nodule
8931/3	Endometrial stromal sarcoma, low grade
8930/3	Endometrial stromal sarcoma, high grade
8805/3	Undifferentiated sarcoma
8590/1	Uterine tumour resembling ovarian sex cord tumour
8714/0	Perivascular epithelioid tumour, benign
8714/3	Perivascular epithelioid tumour, malignant
8825/1	Inflammatory myofibroblastic tumour
	Epithelioid myofibroblastic sarcoma

## Mixed epithelial and mesenchymal tumours

8932/0	Adenomyoma NOS
8932/0	Atypical polypoid adenomyoma
8933/3	Adenosarcoma

## Miscellaneous tumours

9473/3	Primitive neuroectodermal tumour NOS
9064/3	Germ cell tumour NOS
9071/3	Yolk sac tumour NOS
9080/0	Mature teratoma NOS
9080/3	Immature teratoma NOS

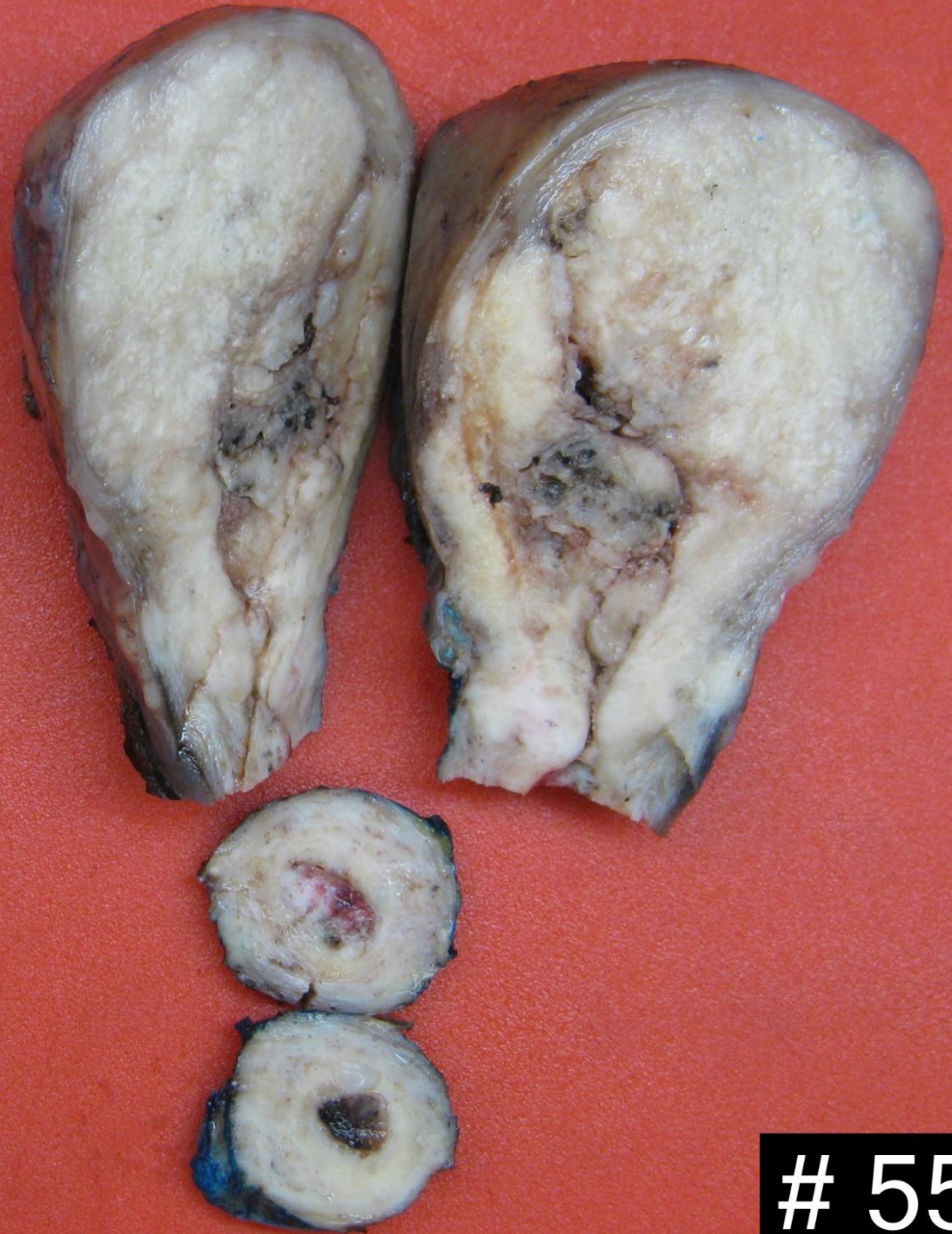WHO, 5th edition, 2020

# Mixed epithelial and mesenchymal tumors

- Adenomyoma
- Atypical polypoid adenomyoma
- Adenofibroma
- Adenosarcoma
- Carcinosarcoma (formerly malignant mixed müllerian tumor, now it is considered epithelial in origin with EMT)

# Carcinosarcoma

- postmenopausal patients
- uterine enlargement and bleeding
- MA: large, soft, polypoid masses
- MI: admixture of carcinoma and sarcoma-like elements
  - carcinoma: high grade, undifferentiated, necrosis, hemorrhage
  - sarcoma: homologous or heterologous (skeletal muscle, cartilage, bone or fat)
- now it is considered epithelial in origin with EMT



Carcinosarcoma-uterus

# 5560

# Adenosarcoma

- generally regarded as low grade
- MA: large polypoid growth filling the uterine cavity
- MI: abnormally shaped glands (but no cytologic atypia!) and malignant stroma (the whole resembling phyllodes tumor of the breast)

Myometrium

# Tumors of the uterine corpus

Arising from		Benign	Malignant
Endometrium	Endometrial glands	-	Endometrioid carcinoma Serous cc Clear cell cc
	Endometrial stroma	Stromal nodule	Stromal sarcoma
	Endometrial glands and stroma	Adenofibroma Adenomyoma	Carcinosarcoma Adenosarcoma
Myometrium		Leiomyoma	Leiomyosarcoma

# WHO classification of tumours of the uterine corpus

## Endometrial epithelial tumours and precursors

	Endometrial hyperplasia without atypia
8380/2	Atypical hyperplasia of the endometrium
8380/3	Endometrioid adenocarcinoma NOS
	POLE-ultramutated endometrioid carcinoma
	Mismatch repair-deficient endometrioid carcinoma
	p53-mutant endometrioid carcinoma
	No specific molecular profile (NSMP) endometrioid carcinoma
8441/3	Serous carcinoma NOS
8310/3	Clear cell adenocarcinoma NOS
8020/3	Carcinoma, undifferentiated, NOS
8323/3	Mixed cell adenocarcinoma
9110/3	Mesonephric adenocarcinoma
8070/3	Squamous cell carcinoma NOS
8144/3	Mucinous carcinoma, intestinal type
9111/3*	Mesonephric-like adenocarcinoma
8980/3	Carcinosarcoma NOS

## Tumour-like lesions

Endometrial polyp  
Endometrial metaplasia  
Arias-Stella reaction

## Mesenchymal tumours specific to the uterus

8890/0	Leiomyoma NOS
8890/0	Lipoleiomyoma
8890/0	Leiomyoma, apoplectic
8890/0	Leiomyoma, hydropic
8890/0	Dissecting leiomyoma
8892/0	Cellular leiomyoma
8896/0	Myxoid leiomyoma
8891/0	Epithelioid leiomyoma
8893/0	Symplastic leiomyoma
8890/1	Leiomyomatosis NOS
8890/1	Intravascular leiomyomatosis

8897/1	Smooth muscle tumour of uncertain malignant potential
8891/1*	Epithelioid smooth muscle tumour of uncertain malignant potential
8896/1*	Myxoid smooth muscle tumour of uncertain malignant potential
	Spindle smooth muscle tumour of uncertain malignant potential
8898/1	Metastasizing leiomyoma
8890/3	Leiomyosarcoma NOS
	Spindle leiomyosarcoma
8891/3	Epithelioid leiomyosarcoma
8896/3	Myxoid leiomyosarcoma
8930/0	Endometrial stromal nodule
8931/3	Endometrial stromal sarcoma, low grade
8930/3	Endometrial stromal sarcoma, high grade
8805/3	Undifferentiated sarcoma
8590/1	Uterine tumour resembling ovarian sex cord tumour
8714/0	Perivascular epithelioid tumour, benign
8714/3	Perivascular epithelioid tumour, malignant
8825/1	Inflammatory myofibroblastic tumour
	Epithelioid myofibroblastic sarcoma

## Mixed epithelial and mesenchymal tumours

8932/0	Adenomyoma NOS
8932/0	Atypical polypoid adenomyoma
8933/3	Adenosarcoma

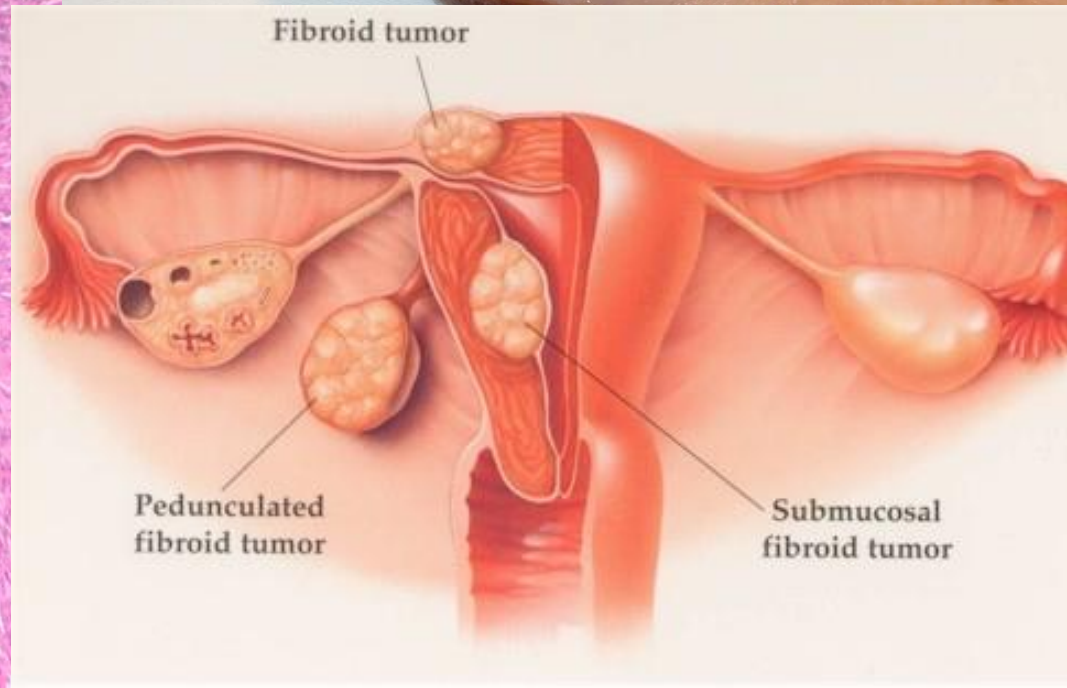
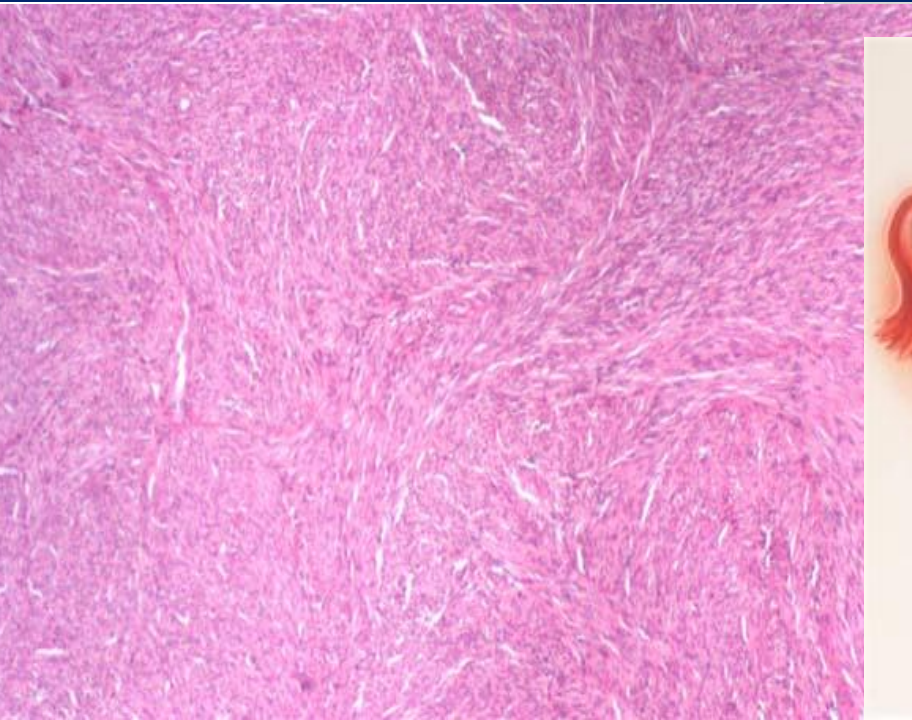
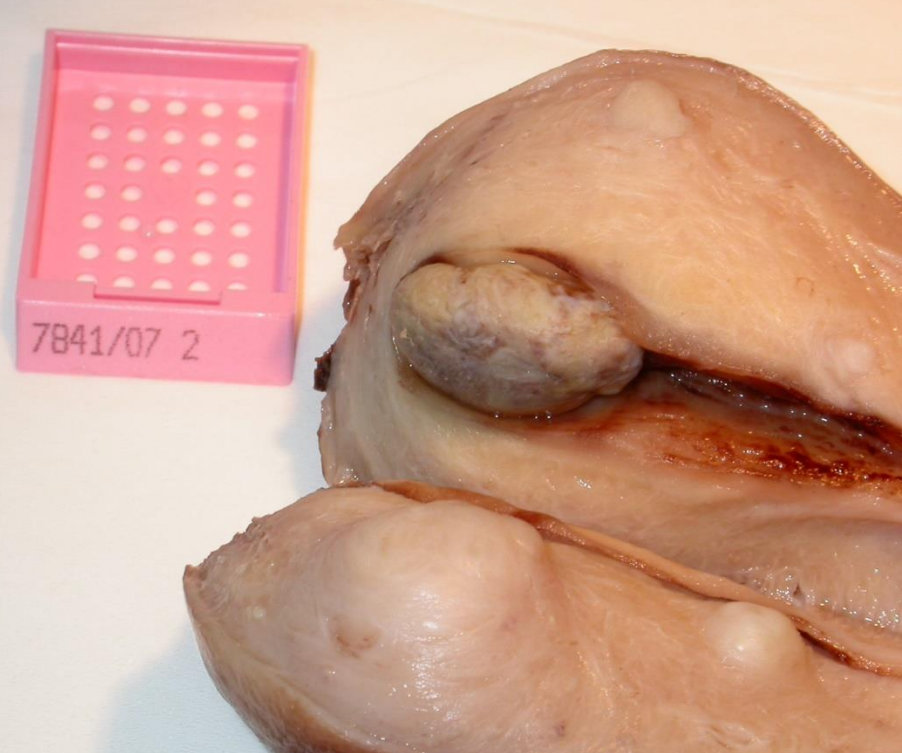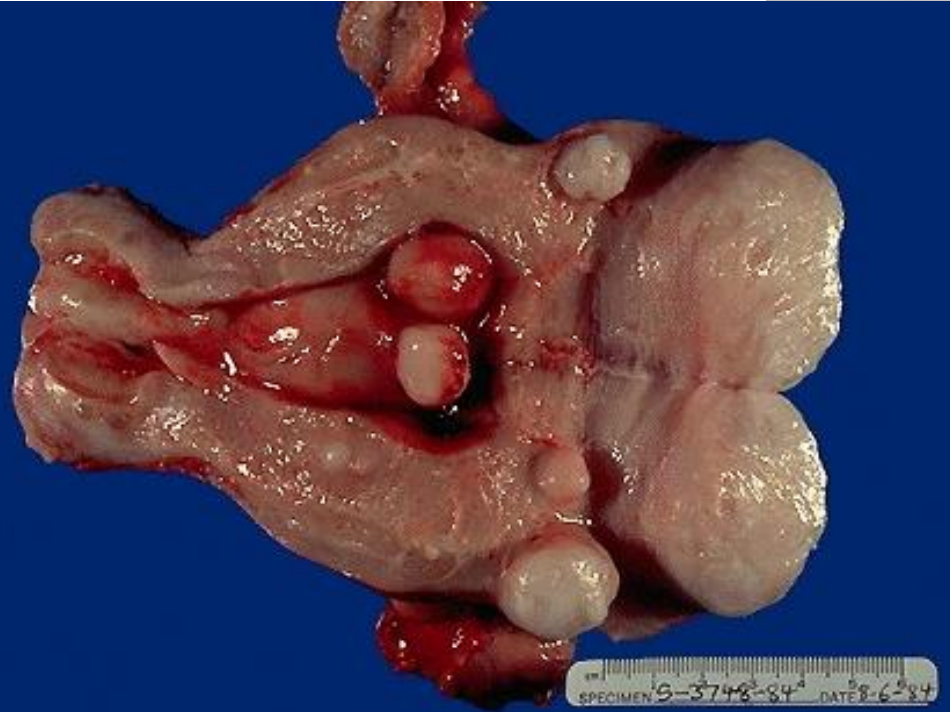
## Miscellaneous tumours

9473/3	Primitive neuroectodermal tumour NOS
9064/3	Germ cell tumour NOS
9071/3	Yolk sac tumour NOS
9080/0	Mature teratoma NOS
9080/3	Immature teratoma NOS

WHO, 5th edition, 2020

# Tumors of the Myometrium

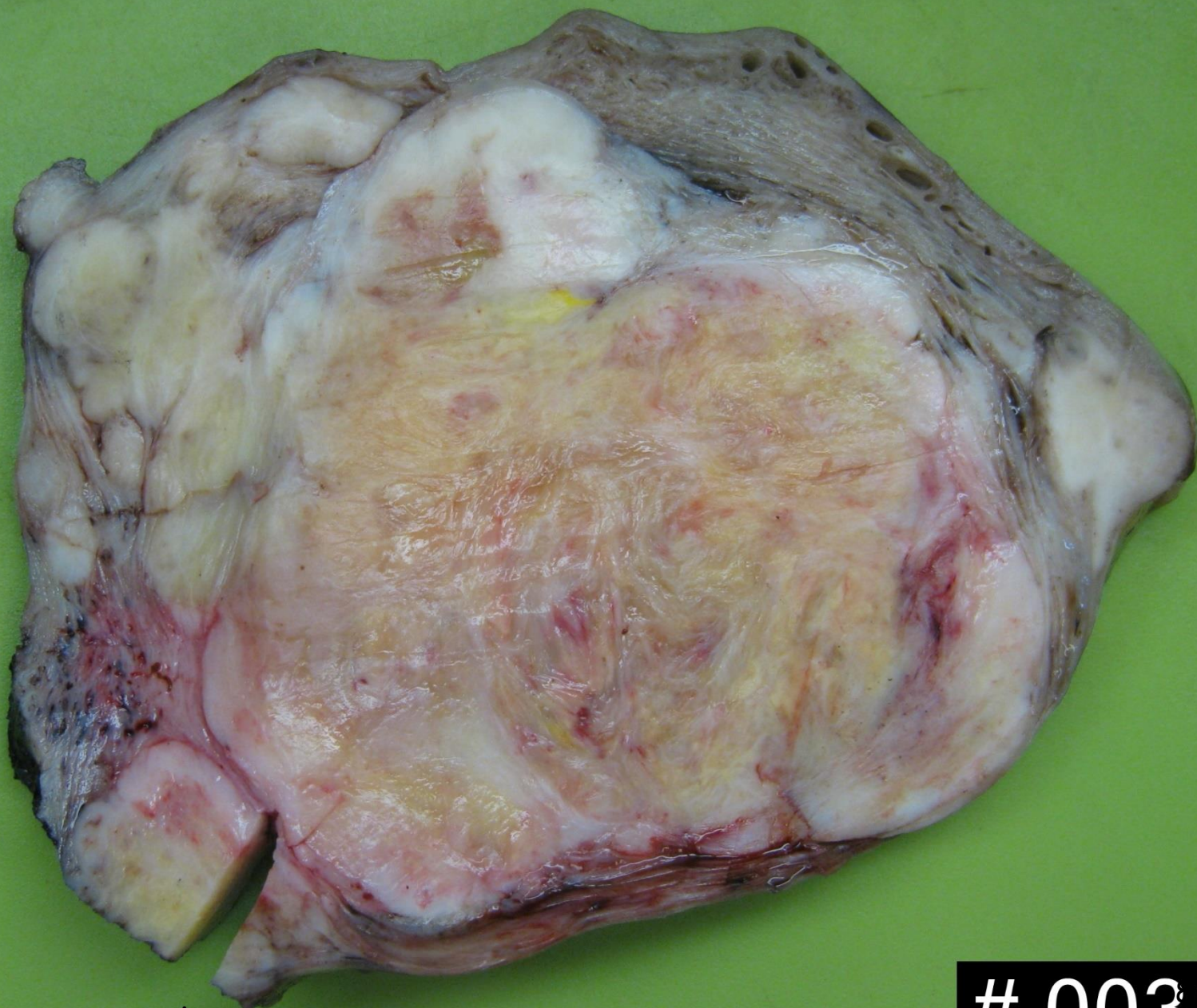
- **Leiomyoma**
  - in 40% of women over the age of 50 years
  - **location:** submucosal, intramural, subserosal
  - **symptoms:** abnormal bleeding, pain, spontaneous abortion, impaired fertility, compression of the urinary bladder ( frequency)
  - **MA:** well circumscribed, round, grayish-whitish nodule(s) with a whorling pattern
  - **MA:** uniform spindle shaped cells, no atypia, scanty mitoses



# Tumors of the Myometrium

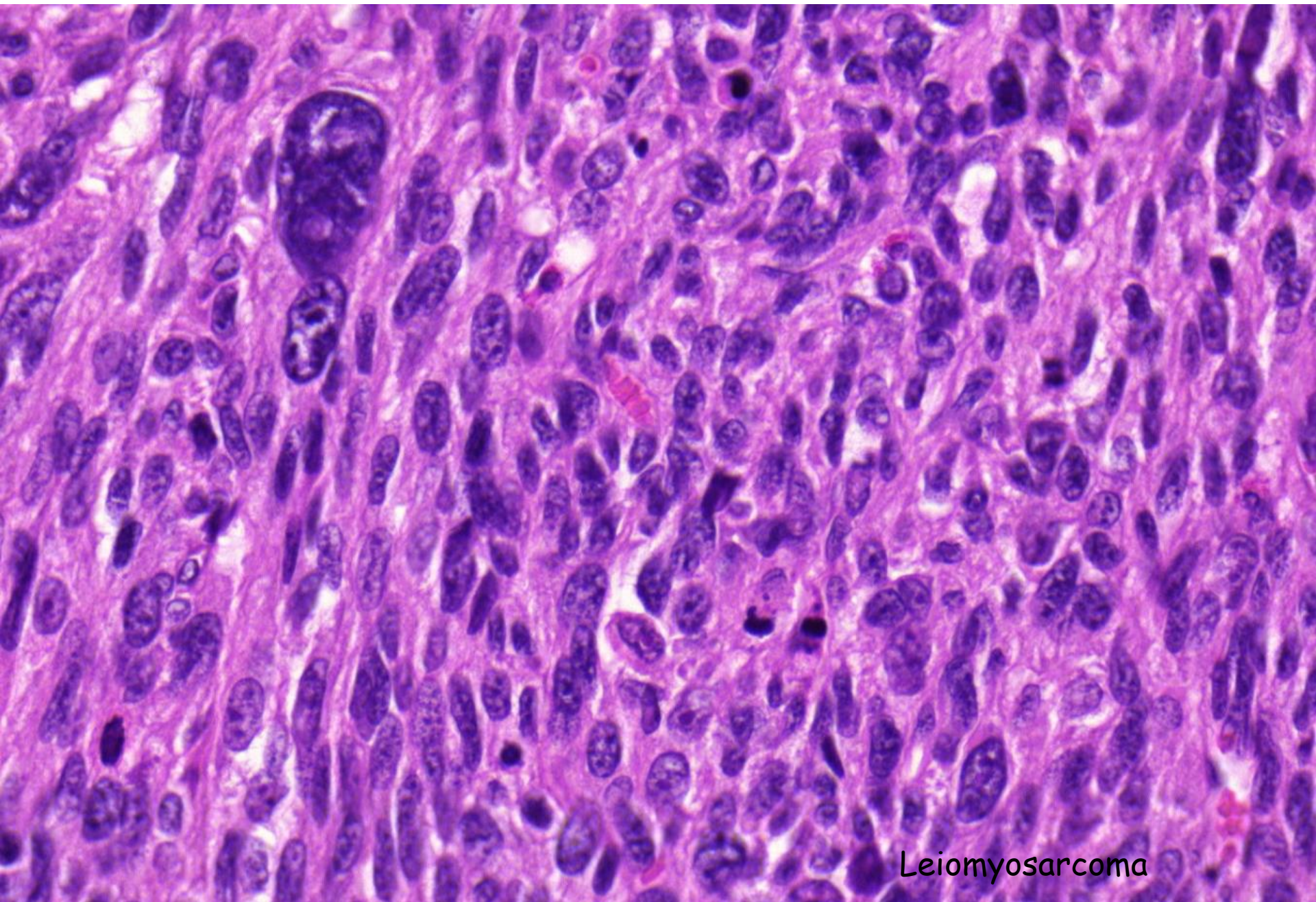
- **Leiomyosarcoma**

- in older patients (average 55 years)
- **MA**: fleshy with necrosis and hemorrhage
- **MI**: hypercellular, nuclear atypia, pleomorphism, increased mitotic index, atypical mitoses, necrosis
- **Metastases**: pelvis, lung, bone, brain but lymph node metastases exceptional!



Leiomyosarcoma-uterus

# 00381



Leiomyosarcoma