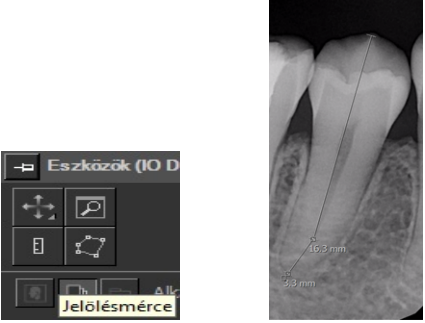


STEPS OF ROOT CANAL TREATMENT

STEPS	EXPLANATION
1. Examination of the patient	General and dental history, extra- / intraoral examination, dental status, examination of the tooth with the complaint (inspection, palpation, percussion, sensitivity test, mobility, periodontal probing, radiological finding)
2. Diagnosis	No treatment without a diagnosis!
3. Treatment plan	For the whole oral cavity and the tooth with the complaint
4. Estimated working length using a preoperative periapical X-ray	<p>Periapical X-ray made with parallel technique for proportional length measurement. The reference point should also be visible.</p> <p>On digital X-ray a calibrated length can be measured. (Click the ruler icon)</p> 
5. Patient's protection	PROTECTIVE EYEWEAR ALSO FOR THE PATIENT. NaOCl is a highly corrosive material.
6. Anesthesia	As required. In most cases, due to the rubber dam clamp, it might be necessary.
7. Cleaning the cavity	<ul style="list-style-type: none"> • Removing old restorations • Cleaning decayed tissues • Cusp reduction if the buccal and lingual walls are less than 2 mm wide. The type of the final restoration determines its ratio. • Pre-endo build-up with composite or glass ionomer cement - in the case of isolation complications • Surgical crown lengthening if needed
8. Absolute isolation	"No rubber dam, no endo."
9. Trepanation cavity	Straight line access (Gates-Glidden, Peeso burs)
10. Working length determination	<p>Determine the position of the foramen apicale using the apex locator up to "00" (K-file #10 or #15). Fix the file's rubber stopper at the reference point. Measure the distance from the tip of the file to the rubber stopper with an endoblock. After subtracting 0.5mm from this, you get the working length.</p> <p>The needle control x-ray is made after subtracting the 0.5 mm!</p>
11. Needle control X-ray	<p>You take a needle control x-ray with a needle size of min. #15, or the largest file that you can fix passively on the previously measured working length (Initial apical file (IAF)).</p> <p>Sometimes, it's necessary to take an excentric X-ray to distinguish the canals.</p>
12. Finding the master file	<p>Masterfile (MAF): 2-3 ISO number larger than the IAF but at least # 30. The apical stop is where the root canal filling will end (the suspected foramen physiologicum), and it is prepared with the MAF.</p> <p>The MAF must be used with active preparation through the entire working length using the balanced-force technique. If the canal is curved, it is necessary to bend the file beforehand.</p>
13. Step-back technique. Recapitulation and irrigation are essential after each file. Sodium hypochlorite (1,25%) EDDY sonic powered irrigation	<p>Using this technique, a conical shape is prepared. After making the apical stop with the MAF, step-backs are made in 0,5-1mm steps with one size larger files. Repeat 3 to 4 times. After each file, recapitulation and irrigation are obligatory.</p> <p>You must move the needle in the canal (filing motion) during irrigation to avoid getting stuck.</p>

	<p>Recapitulation: done with the MAF (or smaller files) after each step-back to remove the debris from the canal.</p> <p>Apical clearing: to check the apical patency and to remove apical debris using a #10 K-file.</p>
<p>14. Temporary closure (if there is not enough time or the canal can not be dried).</p>	<p>Dry the canal with MAF sized paper points. Premixed calcium-hydroxide (CaOH₂) paste should be introduced in the canal with a K-file on working length. Apply Teflon tape or cotton pellet in the pulp chamber and top it with GIC or temporary filling.</p>
<p>15. Obturation:</p> <p>Right before obturation, the irrigation protocol:</p> <ol style="list-style-type: none"> 1. NaOCl + activation with EDDY 2. Distilled water 3. 0,5ml 17 % EDTA (1 min.) 4. Distilled water 5. NaOCl. 6. Activate it with MAF sized GP 7. Distilled water 8. Drying with MAF sized paper points 	<p>Obturation: Lateral condensation.</p> <ol style="list-style-type: none"> 1. Try in the master guttapercha cone—ideally, the same size as the MAF. The master guttapercha should have an apical "tug-back" (resistance to withdrawal). Bend the GP at WL. Coat the cone with a sealer, line the canal walls evenly. Place the cone in the canal to working length. 2. Choosing the spreader: ideally #25-40 (the wider the canal, the larger the spreader). The right spreader is the biggest one that reaches the WL-1 mm. The size of the spreader does not depend on the size of the MAF! <ul style="list-style-type: none"> • If the spreader reaches working length -1 mm <u>and</u> has a significant resistance upon introducing it in the canal, leave it in its place and apply moderate pressure for 30 sec. • If it doesn't reach working length -1 mm, choose a smaller spreader. • If it's too easy to introduce the spreader in the canal (no resistance), choose a larger one. <p>The size of the spreader is not constant (it can change throughout the obturation process). The accessory GP is always one size smaller than the previously used spreader.</p> 3. While the spreader is "working" in the canal for 30 sec., choose an accessory GP point that is one size smaller than the spreader. Measure it to the length of the spreader and bend it with your forceps at the measured length. Dip it into the sealer, remove the spreader from the canal, and put it in place of the spreader. It is important to reach the length of the previously used spreader. If it does not reach the desired length, remove it and repeat the step. 4. Use a spreader again; this time, it has to reach 1-1.5 mm shorter than the previous length. Introduce a new accessory GP to the canal. 5. Repeat the previous steps using accessory guttapercha cones until you reach the 3-4 mm depth from the orifice.
<p>16. Removing the excess guttapercha and vertical condensation</p>	<p>The excess guttapercha has to be cut off with a heated excavator 1 mm below the orifices' level. Ask for excavators designated for this from the assistants. For additional vertical condensation, use a cold plugger.</p>
<p>17. Cleaning of the pulp chamber</p>	<p>Remove the remnants of the sealer from the pulp chamber using a cotton pellet soaked with alcohol. Use glass-ionomer cement (Ketac Bond) or self-etch bond and flow composite to cover the orifices and the pulp chamber's base. If the cavity is deep, temporary cement or long term GIC (Ketac Molar) is used.</p>
<p>18. Final control radiograph</p>	<p>Periapical, excentric (if it's necessary)</p>