

Symptoms of periapical pathosis



Dr. Zsuzsanna Tóth Ph.D.



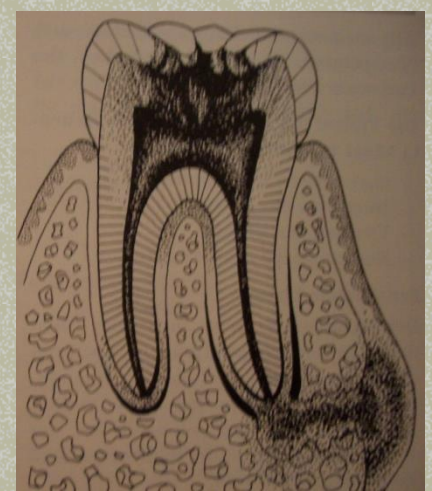
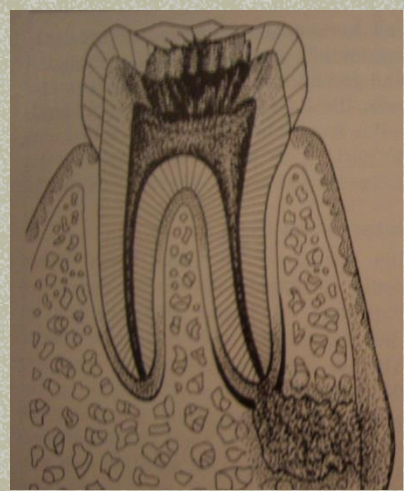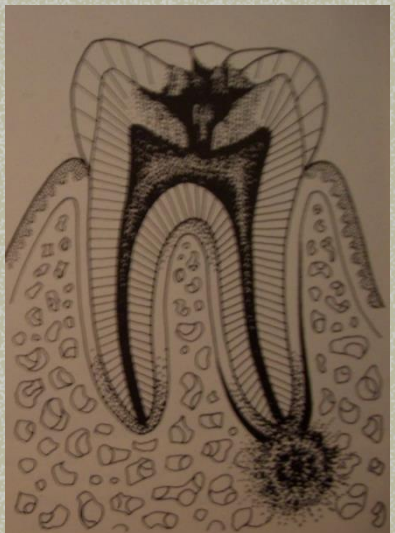
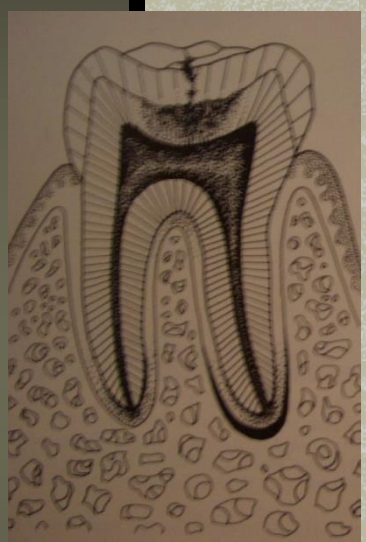
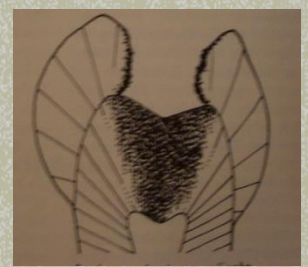
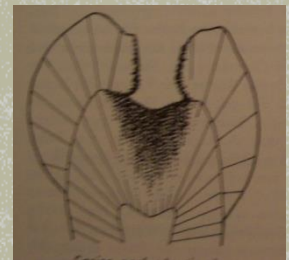
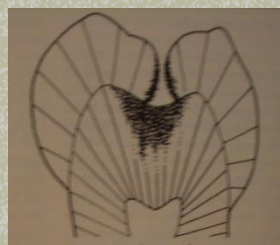

SEMMELWEIS UNIVERSITY

Faculty of Dentistry

Dept. of Conservative Dentistry

<http://semmelweis.hu>







Periapical pathosis

- Acute apical periodontitis
- Chronic apical periodontitis
- Condensing osteitis
- Acute apical abscess
- Suppurative apical periodontitis
(Chronic apical abscess)
- Nonendodontic periapical pathosis



Symptoms of periapical pathosis

Acute apical periodontitis

- spontaneous slight / severe / excruciating discomfort or pain
- no response to electrical or thermal stimuli
- application of pressure causes marked to excruciating pain
- radiographic feature: thickening of periodontal ligament space



Symptoms of periapical pathosis

Chronic apical periodontitis

- asymptomatic or slight discomfort
- no response to electrical or thermal stimuli
- percussion causes little or no pain
- slight palpation sensitivity
- radiographic feature range to extensive destruction of periapical tissue



Chronic apical periodontitis





Chronic apical periodontitis

chronic inflammation

granulation tissue



sealer at apex



Chronic apical periodontitis

radicular cyst



Symptoms of periapical pathosis

Condensing osteitis

- asymptomatic or discomfort or pain
- yes or no respond to electrical or thermal stimuli
- yes or no sensitivity to palpation or percussion
- radiographically diffuse, concentric radiopacity of periapical tissue



Symptoms of periapical pathosis

Acute apical abscess

- moderate to severe discomfort and / or swelling
- systemic manifestations of an infective process (fever, malaise, leukocytosis)
- no response to electrical or thermal stimuli
- painful to palpation or percussion
- radiographic feature: frank periapical lesion (infrequent: thickening of periodontal ligament space)



Acute apical abscess





Symptoms of periapical pathosis

Suppurative apical periodontitis or Chronic apical abscess

- sinus tract
- asymptomatic because of drainage
- closure of the sinus: pain
- radiographic feature range to extensive destruction of periapical tissue



Chronic apical abscess



Chronic apical abscess



And a true story...

