

*Original Article***Estradiol is nephroprotective in the rat remnant kidney**Balazs Antus¹, Peter Hamar¹, Gabor Kokeny¹, Zoltan Szollosi², Istvan Mucsi^{1,3}, Zoltan Nemes² and Laszlo Rosivall¹¹Department of Pathophysiology, Semmelweis University, Budapest, Hungary, ²Department of Pathology, Medical University, Debrecen, Hungary and ³First Department of Internal Medicine, Semmelweis University, Budapest, Hungary**Abstract**

Background. Female sex hormones may influence the progression of renal diseases. We therefore evaluated the effects of estradiol on the development of glomerulosclerosis in a remnant kidney model.

Methods. Ovariectomized or intact female Wistar rats underwent 5/6 nephrectomy. Ovariectomized animals were treated with vehicle, 17 β -estradiol alone or in combination with progesterone, intact rats received vehicle only. Twenty-four weeks after renal ablation, histological as well as molecular analysis were performed.

Results. Vehicle-treated ovariectomized animals developed severe proteinuria and glomerulosclerosis as compared with vehicle-treated intact rats. In addition, renal mRNA levels of platelet-derived growth factor-A chain (PDGF-A) were increased. Estradiol replacement reduced proteinuria, which was paralleled by a diminished glomerular injury and reduced transforming growth factor- β 1 (TGF- β 1) and PDGF-A mRNA expression. In animals that received combined hormone treatment there were no significant differences in proteinuria, creatinine clearance, renal histopathology and growth factor mRNA levels compared with those measured in vehicle-treated ovariectomized rats. Serum cholesterol and triglyceride levels were comparable between all groups during the whole follow-up period.

Conclusions. The data suggest that estrogens protect against the development of glomerulosclerosis in the rat remnant kidney model.

Keywords: estradiol; glomerulosclerosis; growth factors; interstitial fibrosis; progesterone

Introduction

Progression of chronic renal failure is slower in women than in men. Recently, it has been speculated that

female sex hormones, such as estrogens, may be responsible for the lower susceptibility of women to progressive renal injury [1].

Glomerulosclerosis and atherosclerosis may share common elements in their pathogenesis. It has been suggested that the renoprotective effects of estrogens may be related to their effects on glomerular mesangial cells in a manner analogous to the effects of estrogens on vascular smooth muscle cells in atherosclerosis. In support of this hypothesis, estradiol has been shown to suppress cellular proliferation as well as the synthesis of type I and IV collagen, and to inhibit transforming growth factor (TGF)- β - and/or platelet-derived growth factor (PDGF)-mediated type IV collagen expression in mesangial cells [2]. Furthermore, estradiol induces the synthesis of matrix metalloproteinases in mesangial cells, suggesting that estrogens may limit glomerular scarring by increasing matrix degradation as well [3].

The renoprotective properties of estrogens, however, have been recently challenged. Baylis *et al.* [4] reported that age-related glomerulopathy in female rats is not influenced by estrogens. Similarly, Mulroney *et al.* [5] demonstrated that ovariectomy has no effect on early development of glomerular hypertrophy and glomerular injury in uninephrectomized female rats. Finally, in obese Zucker rats and in Nagase analbuminemic rats, administration of estradiol impairs renal function and induces profound glomerulosclerosis [6,7].

It has been argued that co-administration of progesterone with estrogens can modulate the cardio- and atheroprotective effects of estrogens. Some investigators have observed a decrease in the beneficial effects of estrogens [8], while other studies demonstrated no adverse effects of progesterone addition [9]. Nevertheless, little information is available as to whether the addition of progesterone to estrogens influences the effects of estrogens in renal injury.

Thus, in the present study we investigated the role of estrogens in the development of progressive glomerulosclerosis after subtotal renal ablation in female Wistar rats. Furthermore, we tested whether co-administration of progesterone with estrogens

Correspondence and offprint requests to: Dr Balazs Antus, Semmelweis University, Department of Pathophysiology, Nagyvarad ter 4, H-1089 Budapest, Hungary. Email: antbal@net.sote.hu

modulates the effects of estrogens on this process. Finally, we studied whether growth factors such as TGF- β and PDGF, which are commonly associated with progressive glomerulosclerosis, are affected by these female steroids.

Subjects and methods

Animals

Seven-week-old female Wistar rats (Charles River, Hungary) weighing 160–200 g were used in these experiments. Animals were kept under standard conditions and given free access to tap water, and the same amount of standard rat chow (100 g/week/animal). All experiments were approved by a governmental committee on animal welfare.

Renal ablation

All rats were subjected to subtotal (5/6) renal ablation under sodium-pentobarbital (55 mg/kg, i.p.) anaesthesia as described previously [10]. Briefly, after removal of the right kidney, the left kidney was subtotally resected by removing from the cortex two-thirds of the weight of the resected right kidney. Special care was taken to avoid damage to pelvis and hilum. To stop bleeding, renal vessels of the left kidney were clamped for 5 min in all operated animals including ovariectomized and intact animals. The excised kidney tissue was weighed on an analytic scale. The average reduction of the total kidney mass was $74 \pm 1.4\%$.

Experimental design

Following renal ablation a total number of 32 animals were randomly allocated into the following four experimental groups ($n=8$ /group) according to gonadal status and hormonal treatment: animals in the first group remained intact and received vehicle (INT). In the second, third and fourth groups, rats were ovariectomized and treated with either 17 β -estradiol (E), 17 β -estradiol + progesterone (E + P) or vehicle (OVX). 17 β -Estradiol (20 μ g/kg; Sigma, Sigma Aldrich, Germany) and progesterone (10 mg/kg, Sigma) were dissolved in sesame oil and administered subcutaneously every second day (0.1 ml) until harvesting, similarly to our previous studies [11]. Vehicle-treated intact (INT) and ovariectomized (OVX) animals were given sesame oil alone. The reduction of the renal mass was similar between the groups (INT, $73.7 \pm 3.7\%$; OVX, $75.2 \pm 1.8\%$; E, $74.1 \pm 2.6\%$ and E + P, $73.1 \pm 3.1\%$).

Functional measurements

Every 4 weeks, body weights were measured and 24-h urine samples were collected using metabolic cages and a urine-cooling system. Urine protein was determined nephelometrically, while serum cholesterol and triglyceride concentrations were determined using a Reflotron analyzer (Boehringer, Roche, Germany).

At week 24, serum as well as urine creatinine levels were measured to determine creatinine clearance. Furthermore, serum 17 β -estradiol and progesterone concentrations were measured by radioimmunoassay using commercially available kits (Immunotech, Izinta, Hungary). Animals were then anaesthetized with diethyl-ether and intraaortic blood

pressure (Hemosys, Experimetria, Hungary) was measured. Thereafter, rats were bled and the kidneys and the uteri were removed. Remnant kidneys were cut into two pieces. One kidney sample was snap frozen in liquid nitrogen for molecular analysis, the other piece was fixed in buffered formalin (4%) for light microscopy.

Histology

Fixed kidney tissues were embedded in paraffin and stained using haematoxylin/eosin, periodic acid–Schiff (PAS) and Masson's trichrome methods. PAS reaction was performed to evaluate the extent of glomerulosclerosis. Glomerulosclerosis was defined as the accumulation of extracellular matrix in the mesangium. Collapse of capillaries and adhesion of obsolescent segments of Bowman's capsule were frequently seen in the sclerosed glomeruli. Glomerulosclerosis was evaluated according to the following scoring method: score 0, normal glomerulus; score 1, mild segmental glomerulosclerosis affecting <25% of the glomerular tuft; score 2, moderate segmental glomerulosclerosis affecting 25 to 50% of the glomerular tuft; score 3, diffuse severe glomerulosclerosis affecting >50% of the glomerular tuft. A minimum of 40 glomeruli per remnant kidney was examined, and the mean of the glomerular scores was taken to represent the severity of glomerulosclerosis for a given rat. The degree of tubulointerstitial fibrosis (tubulointerstitial damage index) was evaluated in trichrom-stained sections and graded according to the following scale: 0, no evidence of interstitial fibrosis; grade 1, lesions involving <25% of the tubulointerstitial area; grade 2, lesions affecting 25–50% of the tubulointerstitial area; grade 3, lesions involving >50% of the tubulointerstitial area. All histopathological evaluations were carried out by two independent observers (B. Antus and Z. Szollosi) blinded to the experimental code of the tissue.

RNA isolation

Total RNA was extracted with Trizol (Gibco/BRL, Life Technologies, Germany) according to the protocol provided by the manufacturer. Briefly, frozen tissues were mixed with 1 ml Trizol reagent, homogenized, mixed with 0.2 ml chloroform, and centrifuged at 12 000 g for 15 min at 4°C. RNA, from the aqueous phase, was precipitated with 0.5 ml isopropyl alcohol and centrifuged at 12 000 g for 10 min. The RNA pellet was washed with 0.75% ethanol, centrifuged at 7500 g for 5 min and dried. RNA was dissolved in DEPC-treated water and stored at –80°C.

Reverse transcriptase–polymerase chain reaction

RNA was amplified by reverse transcription (RT) with an Oligo(dT)_{12–18} primer (Perkin-Elmer, Applied Biosystem, Germany) using 1 μ g of total RNA added to 0.5 μ g of primer. The reaction mixture contained: buffer solution [TRIS hydrochloride (50 mM, pH 8.3); potassium chloride (75 mM); magnesium dichloride (5 mM); dithiothreitol (5 mM)], adenosine triphosphate, thymidine triphosphate, guanosine triphosphate and cytosine triphosphate each at a concentration of 0.2 mM (Gibco/BRL), 0.5 μ l of 40 U/ μ l of recombinant ribonuclease inhibitor (Perkin-Elmer) and 0.5 μ l of 200 U/ μ l M-MLV reverse transcriptase (Gibco/BRL). The reaction was allowed to proceed (42°C, 1 h), then it was halted by heating the samples to 95°C for 5 min followed by cooling on ice.

Specific cDNA products corresponding to mRNA for TGF- β 1, PDGF-A chain and β -actin were amplified using polymerase chain reaction (PCR) as described previously [10,11]. Briefly, 1 μ l from RT reaction was taken for PCR, which was performed in PCR buffer [750 mM Tris-HCl, pH 9.0, 200 mM (NH₄)₂SO₄, 0.1% (w/v) Tween 20, 20 mM magnesium dichloride (Qiagen, Germany)] using 0.2 mM of each deoxynucleoside triphosphates, 1 μ M of both primers and 2.5 U thermus Aquaticus (*Taq*) DNA polymerase (Qiagen). A Perkin-Elmer Thermal Cycler (Model 9600, Perkin-Elmer, Norwalk, CT) was used for amplification with the following sequence profile: initial denaturation at 94°C for 3 min followed by 30–35 cycles (denaturing: 94°C for 30 s; annealing: 55°C for 30 s; extension: 72°C for 30 s) and ending with a final extension at 72°C for 7 min.

The amplified PCR products were identified by electrophoresis of 10 μ l aliquots on 1.5% agarose gel stained with 0.5 μ g/ml of ethidium bromide. Specific products were visualized by UV transillumination and identified by size in relation to a 1 kb oligonucleotide DNA ladder (Gibco/BRL). Intensities of the specific bands were semiquantitated by densitometric analysis, and the ratios of the density of the specific bands to the bands of β -actin (internal control) were calculated.

Statistical analysis

Data are presented as mean \pm SEM. Parametric data were compared using one-way analysis of variance (ANOVA), followed by multiple pair-wise comparison according to the Newman-Keuls test. Non-parametric data were tested using Kruskal-Wallis one-way analysis of ranks. A *P* value of <0.05 was considered significant.

Results

Animals

At the beginning of this study, body weights were comparable between the groups (Table 1). At week 24, body weight was significantly higher in vehicle-treated ovariectomized (OVX) rats compared to intact (INT) or sex hormone-treated animals (E, E+P). Furthermore, sex hormone-treated animals tended to have a decreased body weight compared with intact rats.

Atrophy of the uterus is considered to be a sensitive indicator of the completeness of ovariectomy. Uterus

weight, as well as the uterus weight-to-body weight ratio, was significantly lower in vehicle-treated ovariectomized (OVX) animals as compared to vehicle-treated intact rats (INT) (Table 1). Estrogen replacement alone (E) or in combination with progesterone (E+P) maintained uterus weight similar to animals with intact ovaries.

Functional measurements

By week 24, vehicle-treated ovariectomized animals developed increased proteinuria as compared to vehicle-treated intact rats (OVX, 556.6 \pm 112.4 versus INT 283.2 \pm 47.5 mg/24 h, *P* < 0.05, ANOVA) (Figure 1). Furthermore, serum creatinine levels were elevated and there was a trend towards a decreased creatinine clearance in these rats (Table 2). Estradiol replacement reduced both proteinuria (E, 286.4 \pm 39.1 versus OVX, 556.6 \pm 112.4 mg/24 h, *P* < 0.05, ANOVA) and serum creatinine to approximately the same level as in vehicle-treated intact rats. Similarly, the creatinine clearance was better maintained in estradiol-treated animals as compared to vehicle-treated ovariectomized rats. Co-administration of progesterone with estradiol tended to reduce the beneficial effects of estradiol both on urinary protein excretion (E, 286.4 \pm 39.1 mg/24 h versus E+P, 383.6 \pm 62.6 mg/24 h) and serum creatinine, but these differences did not reach statistical significance.

Ovariectomy elicited a significant reduction of plasma 17 β -estradiol levels (Table 2). Estradiol levels in rats treated with estradiol alone (E) or in combination of progesterone (E+P) were within the range for intact female rats reported in the literature [12] and were not significantly different from values for vehicle-treated intact animals (taken randomly throughout the estrus cycle) in the present study. One estradiol-treated rat with extremely high estradiol levels (> 300 pg/ml) was excluded from this study.

Ovariectomy also reduced serum progesterone concentrations (Table 2). Addition of progesterone to estradiol treatment (E+P) resulted in plasma concentrations of progesterone similar to those reported previously in the literature [12] or obtained in vehicle-treated intact animals (INT) in the present study.

Table 1. Body and uterus weight at the time of renal ablation and after 24 weeks

Animals	Treatment	<i>n</i>	Body weight (g)		Uterus weight (g)	Uterus weight/body weight
			Renal ablation	Week 24		
Intact females	Vehicle (INT)	8	173 \pm 2.9	293 \pm 4.9	0.21 \pm 0.04	0.00064 \pm 0.00012
Ovariectomized females	Vehicle (OVX)	8	198 \pm 8.2	345 \pm 20.3 ^a	0.08 \pm 0.01 ^b	0.00022 \pm 0.00003 ^b
	Estradiol (E)	7	177 \pm 5.2	260 \pm 8.8 ^c	0.19 \pm 0.02	0.00081 \pm 0.00008
	Estradiol + progesterone (E+P)	8	180 \pm 4.1	256 \pm 9.1 ^c	0.18 \pm 0.02	0.00074 \pm 0.00009

^a*P* < 0.005 vs vehicle-treated intact animals (ANOVA).

^b*P* < 0.01 vs vehicle-treated intact animals (ANOVA).

^c*P* < 0.01 vs vehicle-treated ovariectomized animals (ANOVA).

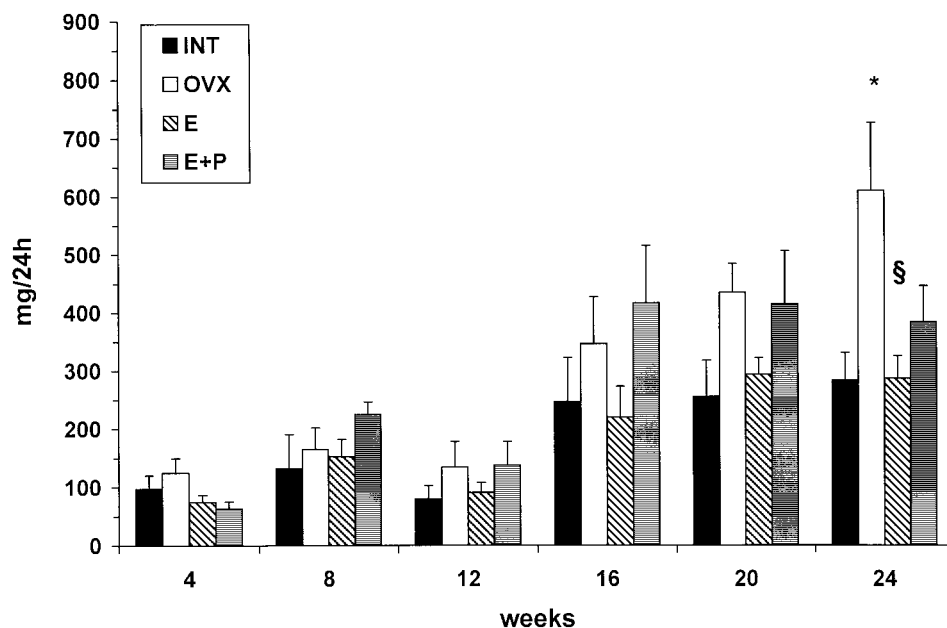


Fig. 1. Changes in 24-h urinary protein excretion throughout the study. (* $P < 0.05$ vs vehicle-treated intact animals; § $P < 0.05$ vs vehicle-treated ovariectomized animals).

Table 2. Mean arterial blood pressure and serum values

Animals	Treatment	Mean arterial blood pressure (mmHg)	Creatinine ($\mu\text{mol/l}$)	Creatinine clearance (ml/min/100 g body weight)	17 β -estradiol (pg/ml)	Progesterone (ng/ml)
Intact females	Vehicle (INT)	96.2 \pm 4.4	58.9 \pm 4.1	0.25 \pm 0.02	67.6 \pm 18.2	43.6 \pm 5.6
Ovariectomized females	Vehicle (OVX)	110.3 \pm 9.7	84.8 \pm 12.9 ^a	0.19 \pm 0.04	23.1 \pm 2.9 ^c	18.9 \pm 4.7 ^c
	Estradiol (E)	92 \pm 9.1	53.9 \pm 2.9 ^b	0.28 \pm 0.11	76.3 \pm 16.6 ^b	23.1 \pm 3.6
	Estradiol + progesterone (E + P)	93.5 \pm 4.3	62.7 \pm 3.9	0.20 \pm 0.01	68.4 \pm 9.3 ^b	50.7 \pm 4.6 ^d

^a $P < 0.05$ vs vehicle-treated intact animals (ANOVA).

^b $P < 0.01$ vs vehicle-treated ovariectomized animals (ANOVA).

^c $P < 0.01$ vs vehicle-treated intact animals (ANOVA).

^d $P < 0.005$ vs 17 β -estradiol-treated ovariectomized animals (ANOVA).

Mean arterial blood pressure seemed to be the highest in vehicle-treated ovariectomized animals, but the difference between the groups was not significant (Table 2). Similarly, lipid levels, both serum cholesterol and triglyceride were comparable between the groups during the whole follow-up period (Figure 2A and B). However, by week 24, cholesterol levels in all groups were somewhat elevated.

Histology

Glomerulosclerosis was significantly increased in ovariectomized vehicle-treated rats (OVX) as compared to intact rats (INT) (Table 3). Similarly, we noted a significantly higher degree of tubulointerstitial fibrosis in ovariectomized rats.

Glomerulosclerosis was significantly reduced in estradiol-treated animals (E) compared to vehicle-treated ovariectomized rats (OVX) (Table 3). The

diminished glomerular injury in these animals was accompanied by a significantly lower degree of tubulointerstitial damage.

Both glomerulosclerosis index and the degree of tubulointerstitial fibrosis were elevated in animals that received the combined sex hormone replacement (E + P) as compared with those given estradiol treatment alone (E); however, these differences were not statistically significant (Table 3). Similarly, neither glomerulosclerosis nor tubulointerstitial fibrosis differed significantly between animals that received the combined hormone replacement (E + P) or vehicle (OVX).

Molecular analysis

TGF- β 1 and PDGF-A chain mRNA expression detected by semiquantitative PCR paralleled development of renal fibrosis (Figure 3). Accordingly,

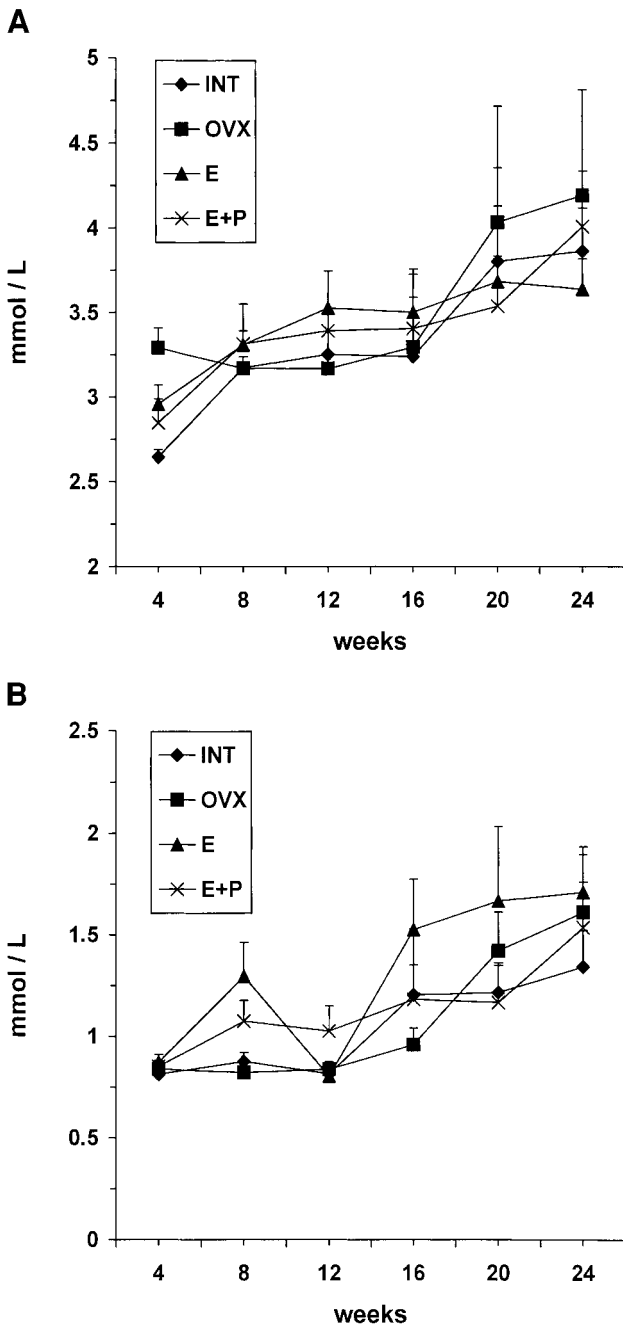


Fig. 2. (A) Changes in serum cholesterol levels throughout the study. (B) Changes in serum triglyceride levels throughout the study.

ovariectomy induced an ~2-fold increase in expression of PDGF-A in vehicle-treated animals (OVX, 2.1 ± 0.3 vs INT, 0.9 ± 0.1 , $P < 0.01$, ANOVA). TGF- β 1 mRNA levels were also increased in vehicle-treated ovariectomized rats (OVX, 2.7 ± 0.4 vs INT, 1.4 ± 0.2), however, these differences were not significant. Estradiol replacement reduced expression of both TGF- β 1 (OVX, 2.7 ± 0.4 vs E, 1.1 ± 0.2 , $P < 0.05$, ANOVA) and PDGF-A (OVX, 2.1 ± 0.3 vs E, 0.6 ± 0.1 , $P < 0.005$, ANOVA). Animals that received estradiol in combination with progesterone tended to have elevated TGF- β 1 (E+P, 1.5 ± 0.5 vs E, 1.1 ± 0.2) and PDGF-A (E+P, 1.6 ± 0.3 vs E, 0.6 ± 0.1) expression compared to estradiol-treated rats.

Discussion

In this study we found that estrogen status plays an important role in the progression of glomerulosclerosis after subtotal renal ablation in female rats. Estrogen deficiency in gonadectomized females was associated with a rapid loss of renal function that was prevented by estradiol replacement. The data suggest that estrogens are renoprotective in a model of chronic renal injury.

Depending on the experimental setting, estrogens may exert various and even opposite effects on progression of renal disease. In female hypercholesterolemic Imai rats, ovariectomy has been shown to accelerate renal injury, while estradiol replacement attenuated this response [13]. Similarly, we demonstrated previously that estrogens ameliorate chronic allograft nephropathy in transplanted rat kidneys [11]. However, there are reports in contradiction with these findings. For example, Baylis *et al.* [4] reported that age-related glomerulopathy is not influenced by estrogens. It is possible that different mechanisms may be involved in glomerulopathy due to age compared with renal ablation. For instance, glomerular hypertension is known to play a central pathogenic role in the remnant kidney model, while this risk factor may be less important for age-dependent glomerular injury [4]. Development of compensatory renal growth and glomerular damage in uninephrectomized female rats also seems to be independent of estrogens [5]. However,

Table 3. Histological characteristics of the remnant kidneys

Animals	Treatment	Glomerulosclerosis score (0–3)	Tubulointerstitial damage index (0–3)
Intact females	Vehicle (INT)	1.5 ± 0.18	0.75 ± 0.25
Ovariectomized females	Vehicle (OVX)	2.4 ± 0.25^a	1.88 ± 0.30^a
	Estradiol (E)	1.3 ± 0.11^b	0.71 ± 0.18^b
	Estradiol + progesterone (E + P)	1.9 ± 0.24	1.50 ± 0.33

^a $P < 0.05$ vs vehicle-treated intact animals (Kruskal–Wallis test).

^b $P < 0.05$ vs vehicle-treated ovariectomized animals (Kruskal–Wallis test).

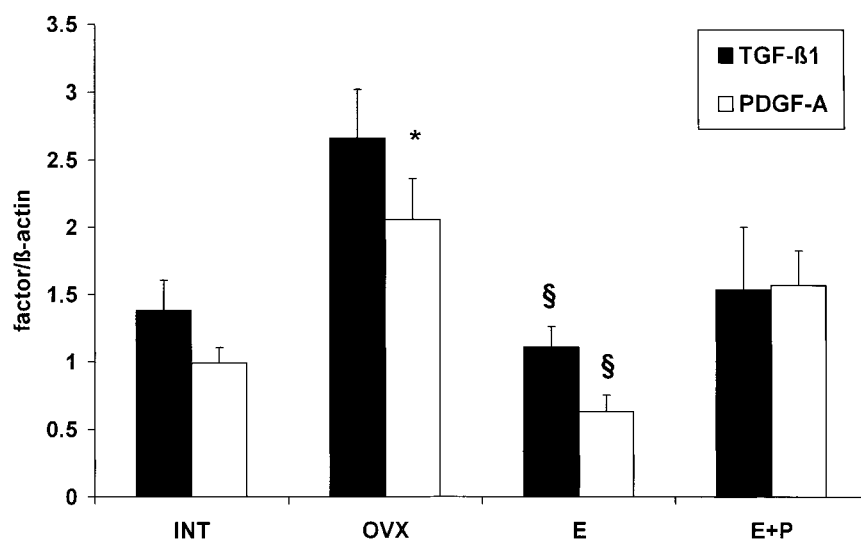


Fig. 3. TGF- β 1 and PDGF-A chain mRNA expression in the remnant kidneys at the end of the study. (* $P < 0.05$ vs vehicle-treated intact animals; § $P < 0.05$ vs vehicle-treated ovariectomized animals.)

renal function is relatively well preserved after uninephrectomy, thus conclusions concerning the role of estrogens in a progressive fibrotic process cannot be drawn from those experiments. Finally, in rat strains with spontaneous hypertriglyceridaemia, estrogens promote renal injury [6,7]. In these models, administration of estrogens causes further increases in lipid levels, which led to progressive renal injury. Wistar rats, used in our study, are normolipidaemic and neither gonadal status nor estradiol treatment influenced lipid parameters. Our data, therefore, do not support a role for lipids in the renal effects of estrogens.

It is well established that dietary protein intake influences the development of renal disease. In our study, animals were offered the same amount of food during the whole follow-up. Therefore, differences in renal injury between the groups cannot be due to various protein intake. Nevertheless, vehicle-treated ovariectomized rats gained more body weight than vehicle-treated intact or all sex hormone-treated rats. Therefore, one may argue that nephron/body weight mismatch is present and that may have contributed to the more marked renal damage in vehicle-treated ovariectomized rats. However, since these animals accumulate mostly adipose tissue, but not muscle mass, nephron/body weight mismatch may have had little effect on renal injury. Using a pair-feeding protocol would have maintained body weight equal between the groups. However, in this case, protein consumption would have been different between the groups. Since we believe that in the reported setting protein intake could have been a more important confounder than nephron/body weight mismatch, we controlled protein intake, but not body weight in our study.

As shown in Table 2, arterial blood pressure tended to be higher in vehicle-treated ovariectomized rats as compared to vehicle-treated intact animals. This somewhat higher blood pressure may have contributed

to the more pronounced renal injury in ovariectomized rats. It is unclear whether this tendency in blood pressure was due to the effects of estrogens, or was simply associated with the more pronounced renal failure in these rats. Furthermore, it should be noted that in our experiment blood pressure was measured in anaesthetized rats. It is possible that the differences in blood pressure between the groups would have reached statistical significance, if blood pressure would have been measured in awake animals, for example, with telemetry. This technology, however, was not available in our laboratory.

Serum creatinine levels paralleled the marked histological changes both in vehicle- and in estradiol-treated animals. In contrast, creatinine clearance did not show similar clear correlation with the histology. The reason for this discrepancy is not clear. However, creatinine clearance may be a somewhat inaccurate estimate of renal function in rats due to the relatively high tubular creatinine secretion. This may explain why differences in creatinine clearance were not statistically significant in our study.

The mechanism, by which progesterone tended to reduce the beneficial effects of estrogen, is unclear. Progestins are known to exert partial androgenic effects weakly binding to androgen receptors in various tissues, including the kidney [14]. As androgens promote renal fibrosis [4,11], it is feasible that activation of androgen receptors are responsible for the effects of progesterone. Furthermore, interactions between progesterone and estrogen or progesterone and angiotensin type I receptor expression [15] could have been involved in this process.

Glomerular injury in the rat remnant kidney model has been generally attributed to an altered regulation of matrix turnover by mesangial cells. Our data are in accordance with previous findings demonstrating that estradiol may directly limit glomerulosclerosis by either inhibiting collagen synthesis or increasing the

production of matrix metalloproteinases in mesangial cells [2,3].

Furthermore, a wide range of growth factors, including TGF- β 1 and PDGF have been implicated in the development of glomerulosclerosis [16]. TGF- β 1 promotes matrix synthesis and inhibits its degradation by several mechanisms, and is therefore one of the most important mediators of tissue fibrosis [17]. Similarly, PDGF, apart from its strong mitogenic properties, stimulates production of various components of extracellular matrix in human and experimental renal diseases [11,18]. Moreover, it has recently been suggested that estrogens may have a direct atheroprotective effect through inhibition of TGF- β 1 and PDGF-A expression in vascular smooth muscle cells [19]. As mesangial cells are phenotypically similar to smooth muscle cells, we hypothesized that the renoprotective effects of estradiol may be mediated, at least in part, by its inhibitory effects on growth factor synthesis in mesangial cells. Indeed, estradiol treatment down-regulated the increased TGF- β 1 and PDGF-A expression after ovariectomy, and this may have contributed to a better outcome in this group. The co-administration of progesterone, however, tended to reduce the beneficial effects of estradiol on expression of TGF- β 1 and PDGF-A that may be responsible for the more pronounced glomerular injury in the animals receiving combined hormone treatment. TGF- β 1 and PDGF-A are important mediators of tissue fibrosis in both the glomeruli and in the tubulointerstitial space. In this work we did not distinguish whether the observed changes in the mRNA expression reflect glomerular or interstitial changes in the remnant kidneys. However, since estradiol reduced both glomerulosclerosis and interstitial fibrosis, we assume that TGF- β and PDGF expression were down-regulated parallel in both compartments of the kidney by the hormone.

There are insufficient data available at present to determine whether estrogen replacement therapy can influence progression of renal disease in postmenopausal women. This issue, however, is of considerable importance since the number of postmenopausal women with end-stage kidney disease has increased sharply in the past decade. Our results suggest that estrogen replacement can retard the decline in renal function in this population of women. Importantly, Szekacs *et al.* [20] have recently demonstrated, in a small number of diabetic and hypertensive postmenopausal women, that hormone replacement therapy reduced proteinuria and improved creatinine clearance.

Doses of sex hormones administered in our experiment were determined in a pilot study. In those experiments we observed that estradiol and progesterone levels in sera increase up to 4 and 12 h after drug administration with doses that we applied in our present experiments, and then they return to the base line 48 h later. These hormone levels were comparable with those in naive cycling rats. Of note is the fact that steroid doses administered in our experiment seem to

be higher than therapeutic doses in humans. The reason for this difference is not clear, but variances between therapeutic doses in animal and human studies may perhaps be associated with differences in drug absorption or metabolism.

In conclusion, we demonstrated that estradiol has a protective effect on the kidney during progressive glomerulosclerosis in the female rat remnant kidney model. Further studies are clearly needed to assess the potential applicability of these experimental findings in the clinical setting.

Acknowledgements. This work was supported by Hungarian Research Foundations (OTKA 29260, 34409, F034498, ETT232 and FKFP 316) and the Hungarian Kidney Foundation. Dr Mucsi is a recipient of the Békésy Postdoctoral Scholarship from the Hungarian Ministry of Education. Dr. Hamar is a Bolyai Research Fellow of the Hungarian Academy of Sciences. The skilful assistance of Maria Godo at the Department of Pathophysiology, Semmelweis University and Agnes Kovacs at the 2nd Department of Internal Medicine, Semmelweis University was gratefully acknowledged.

References

- Silbiger SR, Neugarten J. The impact of gender on the progression of chronic renal disease. *Am J Kidney Dis* 1995; 25: 515–533
- Lei J, Silbiger S, Ziyadeh FN, Neugarten J. Serum stimulated α_1 type IV collagen gene transcription is mediated by TGF β and inhibited by estradiol. *Am J Physiol* 1998; 274: F252–258
- Potier M, Elliot SJ, Tack I, Lenz O, Striker GE, Striker LJ, Karl M. Expression and regulation of estrogen receptors in mesangial cells: influence on matrix metalloproteinase-9. *J Am Soc Nephrol* 2001; 12: 241–251
- Baylis C. Age-dependent glomerular damage in the rat. Dissociation between glomerular injury and both glomerular hypertension and hypertrophy. Male gender as a primer risk factor. *J Clin Invest* 1994; 94: 1823–1829
- Mulrony SE, Woda C, Johnson M, Pesce C. Gender-differences in renal growth and function after uninephrectomy in adult rats. *Kidney Int* 1999; 56: 944–953
- Gades MD, Sern JS, van Goor H, Nguyen D, Johnson PR, Kaysen GA. Estrogen accelerates the development of renal disease in female Zucker rats. *Kidney Int* 1998; 53: 130–135
- Joles JA, van Goor H, Koomans HA. Estrogen induces glomerulosclerosis in albuminemic rats. *Kidney Int* 1998; 53: 862–868
- Hanke H, Hanke S, Bruck B *et al.* Inhibition of the atheroprotective effects estrogens by progesterone in experimental atherosclerosis. *Atherosclerosis*. 1996; 121: 129–138
- Adams MR, Kaplan JR, Manuck SB *et al.* Inhibition of coronary artery atherosclerosis by 17 β -estradiol in ovariectomized monkeys. Lack of effects of added progesterone. *Arteriosclerosis* 1990; 10: 1051–1057
- Hamar P, Peti-Peterdi J, Szabo A *et al.* Interleukin-2-dependent mechanisms are involved in the development of glomerulosclerosis after partial renal ablation in rats. *Exp Nephrol* 2001; 9: 133–141
- Müller V, Szabo A, Viklicky O, Gaul I, Pörtl S, Philipp T, Heemann U. Sex hormones and gender related differences: their influence on chronic renal allograft rejection. *Kidney Int* 1999; 55: 2011–2020
- The control of progesterone secretion during the estrous cycle and early pseudopregnancy in the rat: prolactin, gonadotropin and steroid levels associated with rescue of the corpus luteum of pseudopregnancy. *Endocrinology* 1975; 96: 219–226

13. Sakemi T, Toyoshima H, Shouno Y, Morito F. Estrogen attenuates progressive glomerular injury in hypercholesterolemic male Imai rats. *Nephron* 1995; 69: 159–165
14. Bullock LP, Bardin CW, Sherman MR. Androgenic, antiandrogenic and synandrogenic actions of progestins: role of steric and allosteric interactions with androgen receptors. *Endocrinology* 1978; 103: 1768–1778
15. Nickening G, Strehlow K, Wassmann S *et al.* Differential effects of estrogen and progesterone on AT1 receptor gene expression in vascular smooth muscle cells. *Circulation* 2000; 102: 1828–1833
16. Muchaneta-Kubara EC, Sayed-Ahmed N, El Nahas AM. Subtotal nephrectomy: a mosaic of growth factors. *Nephrol Dial Transplant* 1995; 10: 320–327
17. Yamamoto T, Noble NA, Miller DE, Border WA. Sustained expression of TGF- β 1 underlies development of progressive kidney fibrosis. *Kidney Int* 1994; 45: 916–927
18. Floege J, Burns MW, Alpers CE. Glomerular cell proliferation and PDGF expression precede glomerulosclerosis in the remnant kidney model. *Kidney Int* 1992; 41: 297–309
19. Kikuchi N, Urabe M, Iwasa K *et al.* Atheroprotective effect of estradiol and estrone sulfate on human vascular smooth muscle cells. *J Steroid Biochem Mol Biol* 2000; 72: 71–78
20. Szekacs B, Vajo Z, Varbiro Sz *et al.* Postmenopausal hormone replacement improves proteinuria and impaired creatinine clearance in type 2 diabetes mellitus and hypertension. *BJOG* 2000; 107: 1017–1021

Received for publication: 7.1.02

Accepted in revised form: 20.8.02