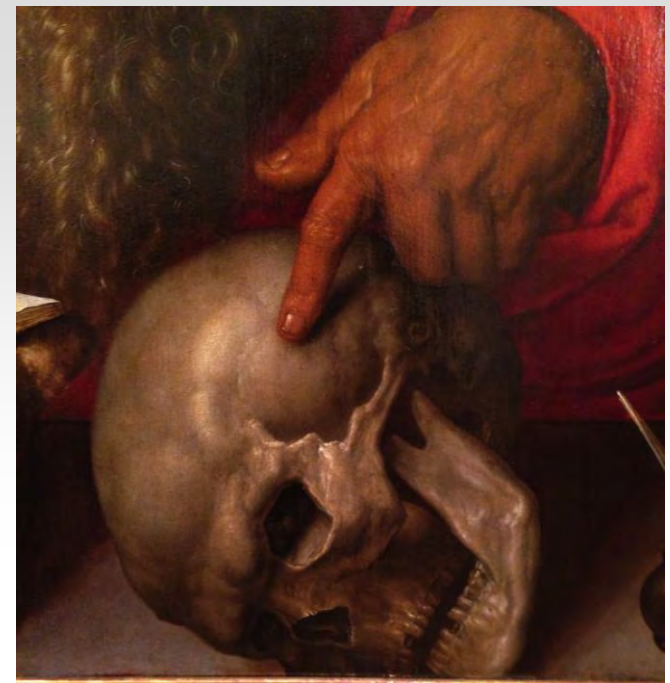

Brain Tumors

Surgical Neurooncology



Attila G Bagó, M.D., Ph.D.

**SE Dept. of Neurosurgery and
Neurointervention**

**Dept. of Surgical Neurooncology
Budapest, Amerikai út.**

Neurooncology

Complex therapy of CNS neoplasms

Essential role of neurosurgery!

Diagnostics (tumor? Inflammation)ztika:

Therapy: decompression, release mass effect, restore CSF pathways

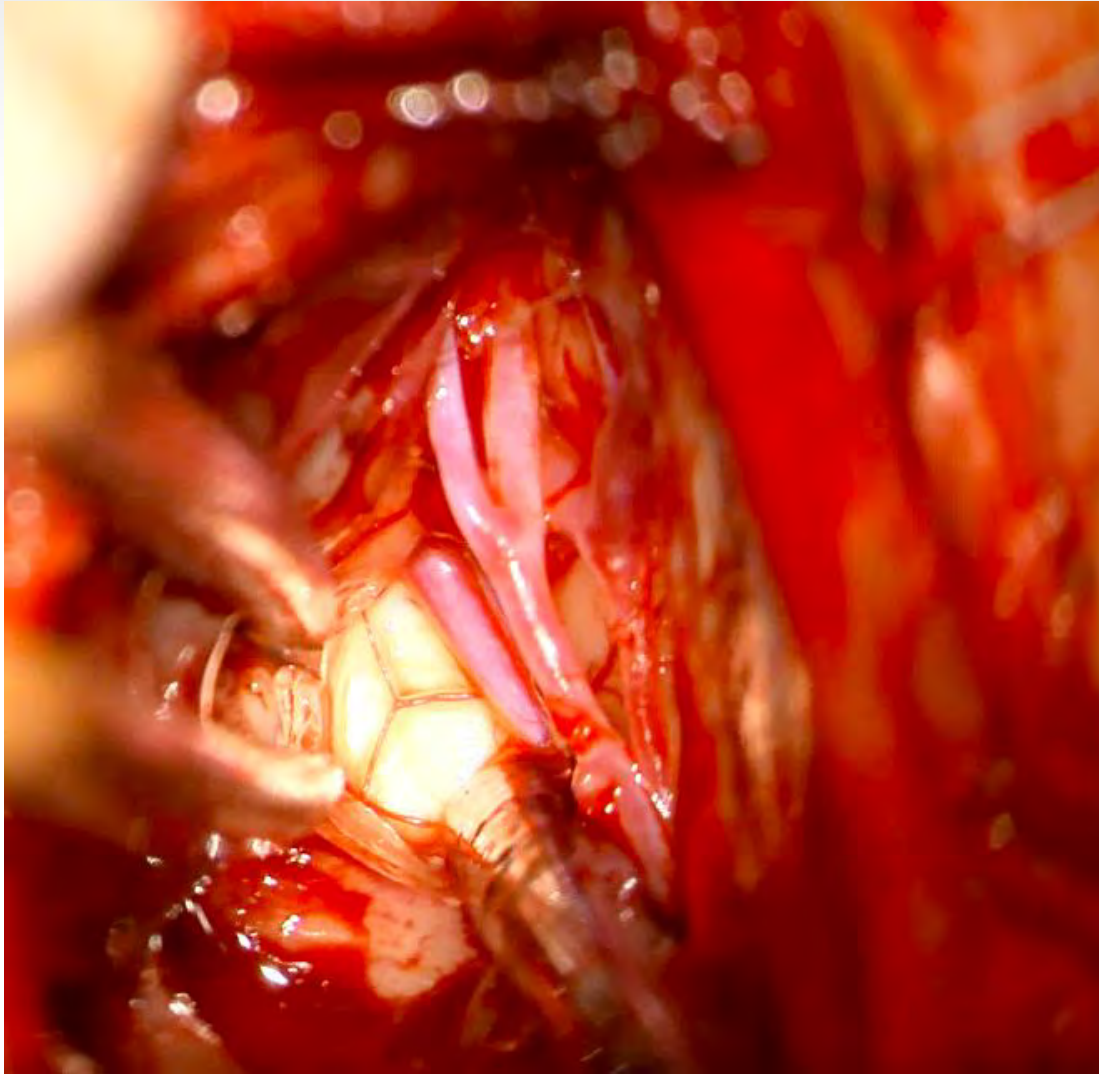
Histology: necessary for complex oncotherapy

Brain tumor - facts

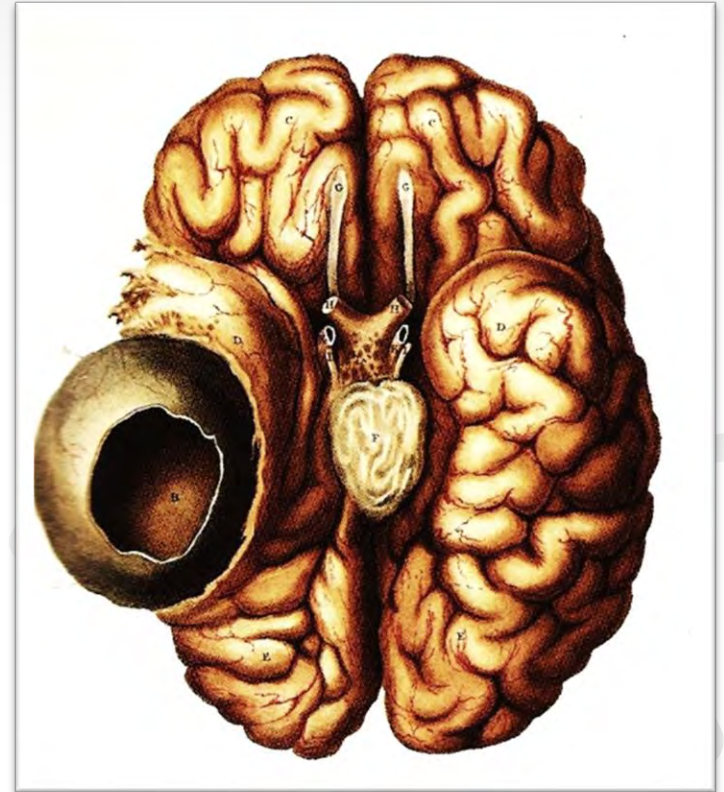
- Life threatening disease
- Number of brain tumor patients ↑
- Long surviving cancer patients ↑
CNS mets ↑
- **Neurooncology care – poorly organized
diffucult patients**

cca 3-5000 pts/year

Why do we operate brain tumors?




**Life threatening
condition**

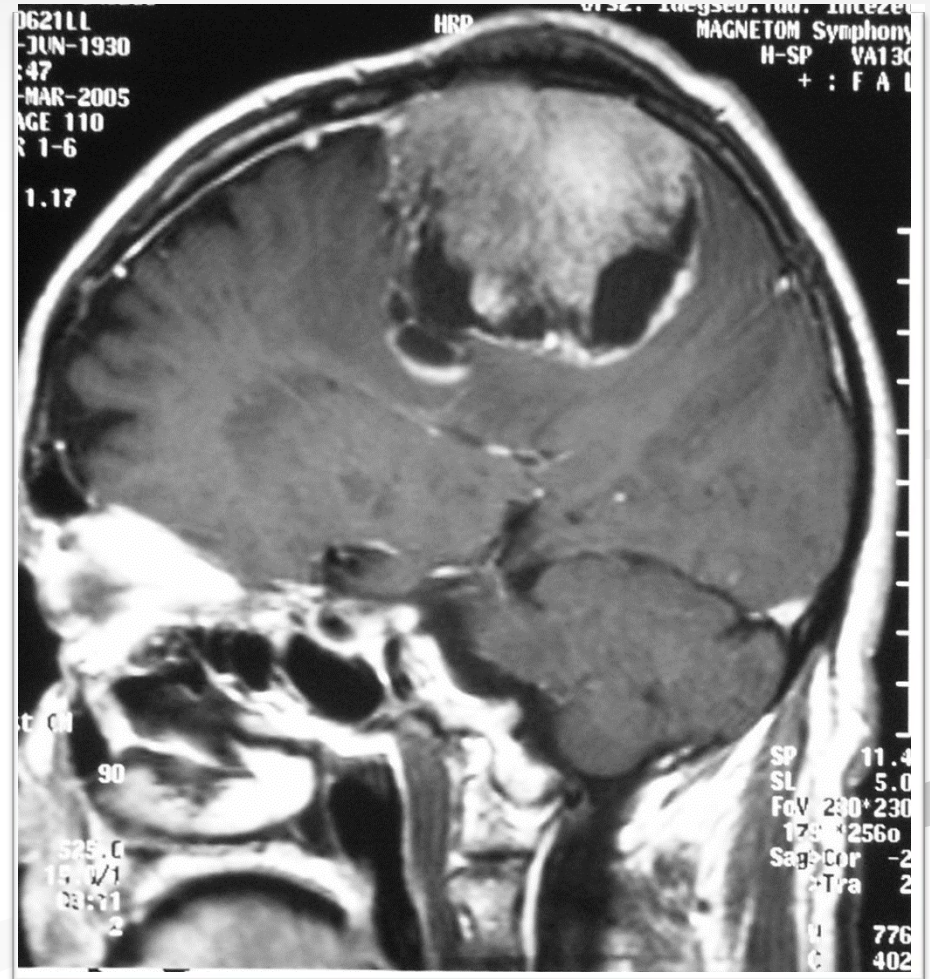

Monro-Kellie doctrine

- Skull- closed box
- Brain + CSF + blood
- Compensatory mechanism



herniation

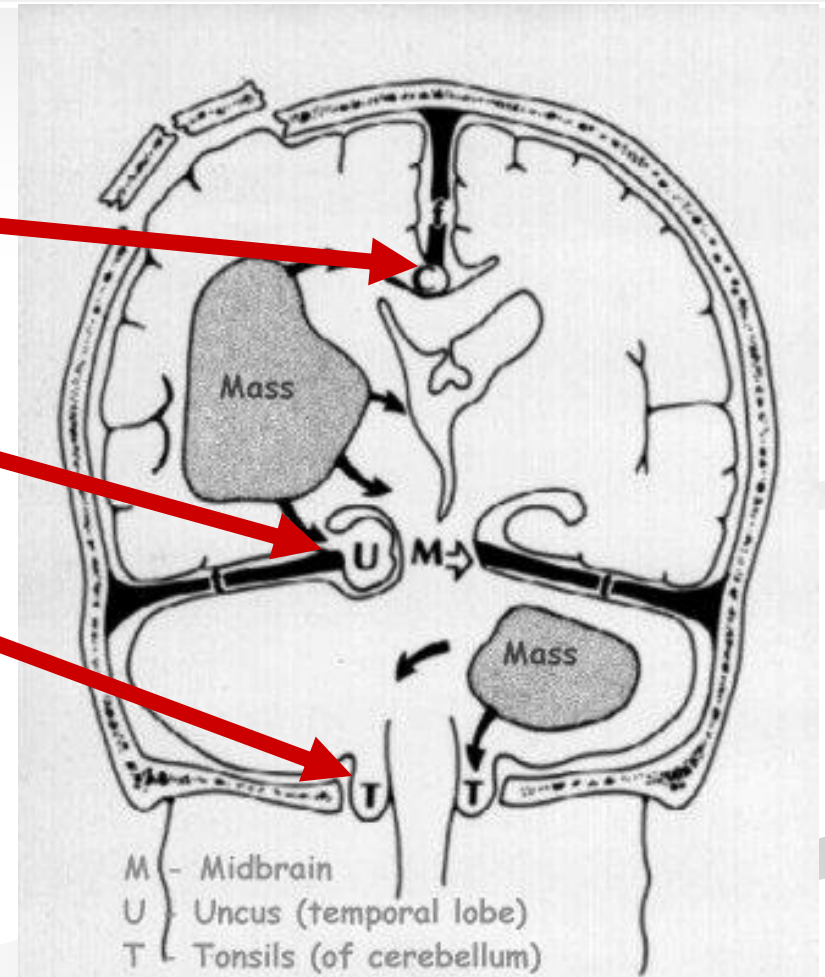


Herniations

Subfalcial

Temporal/uncal

Tonsillar



Most common brain tumors

Primary

Gliomas

low grade

high grade

Meningiomas

Pituitary adenomas

Vestibular schwannomas

Secondary (2x)

Metastases

lung cc

breast cc

colorectal cc

kidney cc

melanoma

CNS Lymphoma

Most common brain tumors

Primary

Gliomas

low grade

high grade

Meningiomas

Pituitary adenomas

Vestibular schwannomas

Secondary (2x)

Metastases

lung cc

breast cc

colorectal cc

kidney cc

melanoma

CNS Lymphoma

Most common brain tumors

Primary

**Glioblastoma Gr 4
(multiforme)**

meningiomas

Pituitary adenomas

Vestibular schwannomas

Secondary (2x)

Metastases

lung cc

breast cc

colorectal cc

kidney cc

melanoma

CNS Lymphoma

NEVER FORGET!

Primary malignant
brain tumors
(gliomas)

NOT
**surgical
diseases**

Metastases
Bening
extraparenchymal
tumors

**Surgically
removable
tumors**

Clinical symptoms

Focal neurological signs

+ excitatory **seizures, tinnitus, neuralgia**

– inhibitory **paresis, plegia, hemianopia**

General signs of elevated ICP

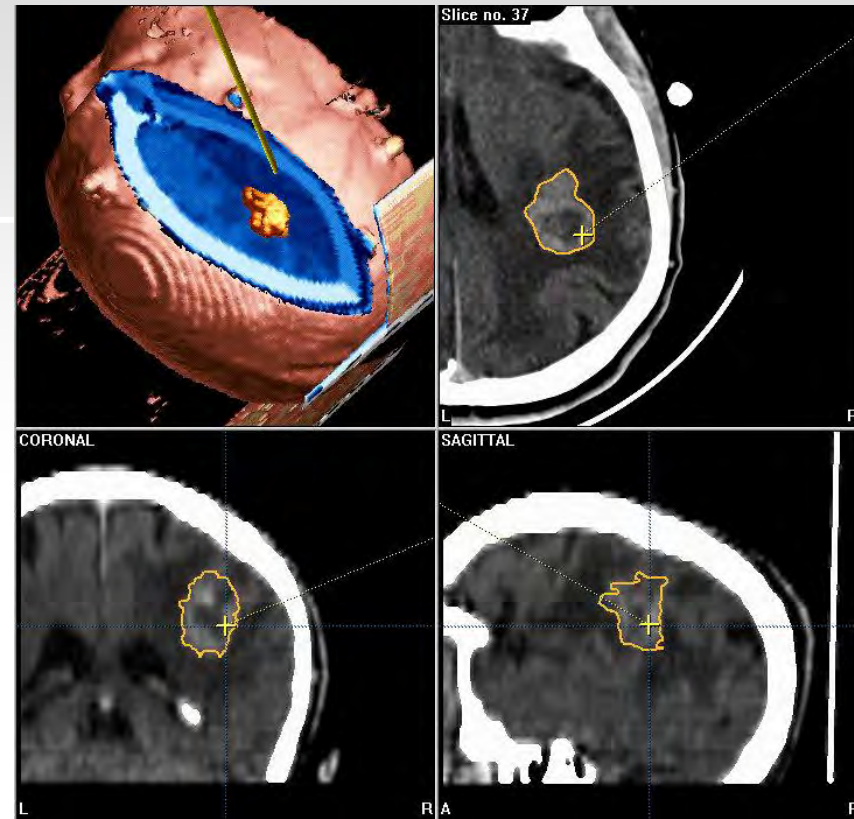
- headache, vomiting

- personality changes, confusion, loss consciousness

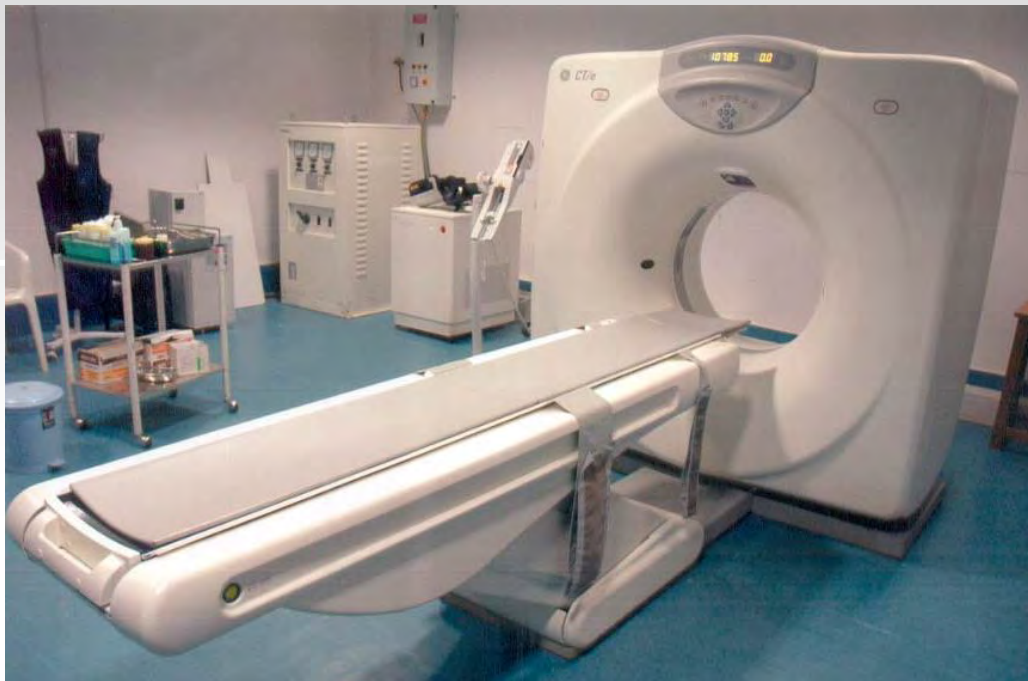Symptoms are progressive!

IMPORTANT

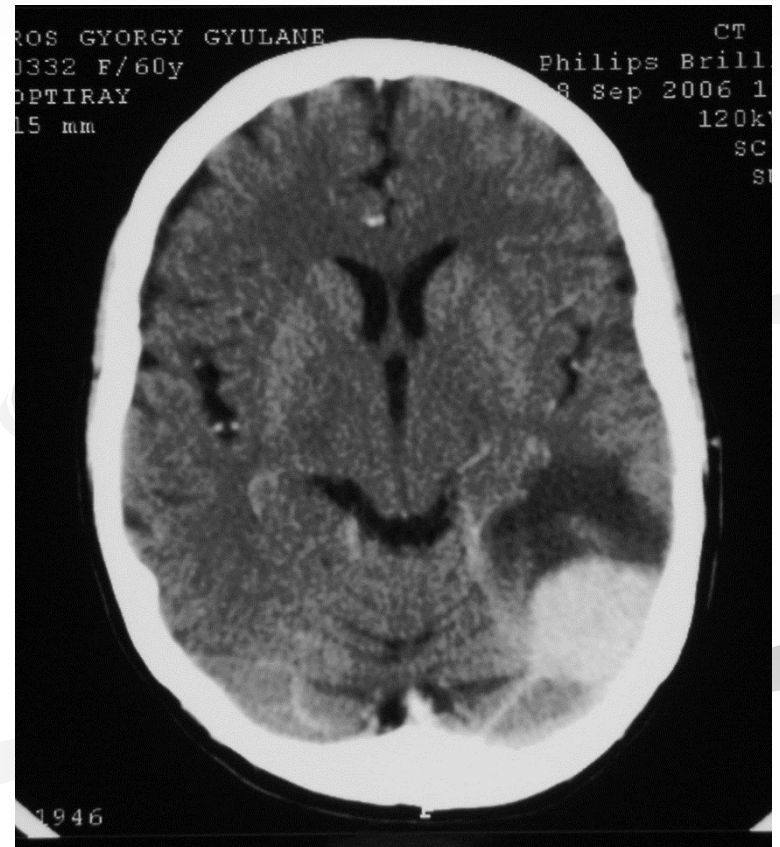- Cancer patient
- Neurological symptoms

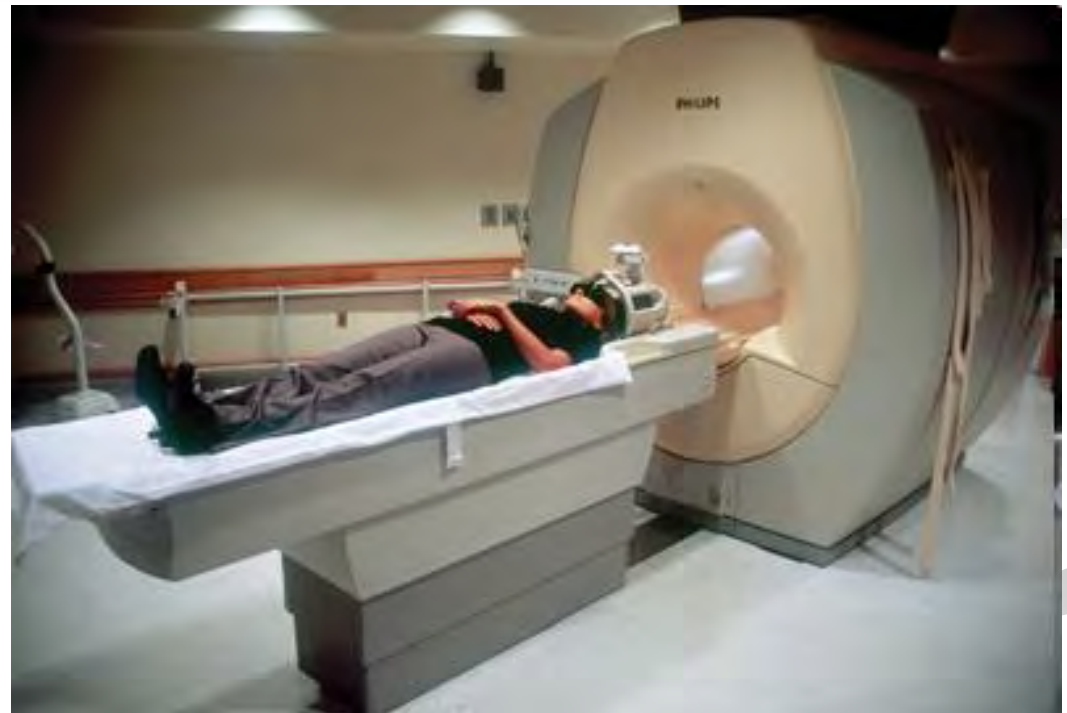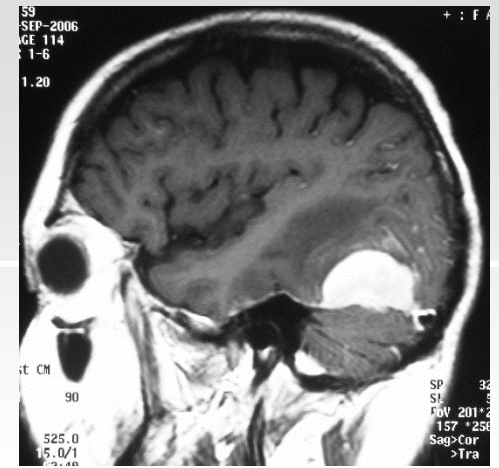
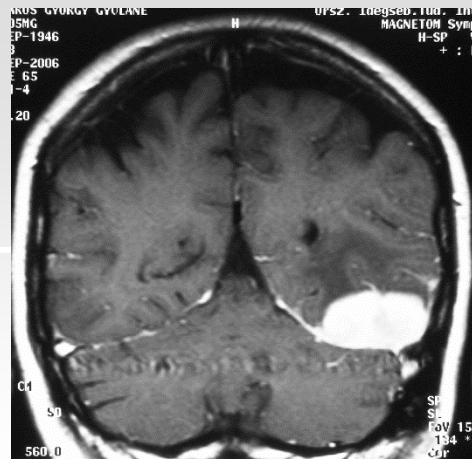

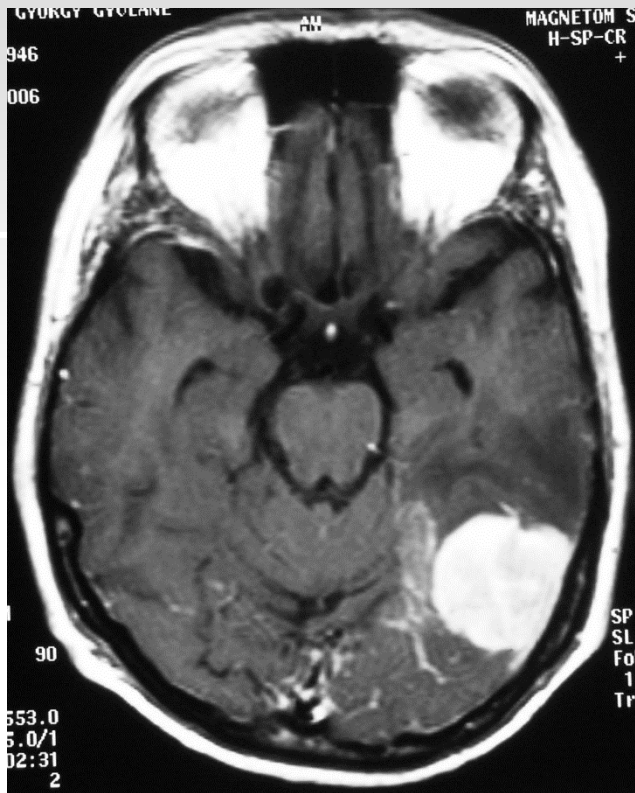
To rule out brain met!



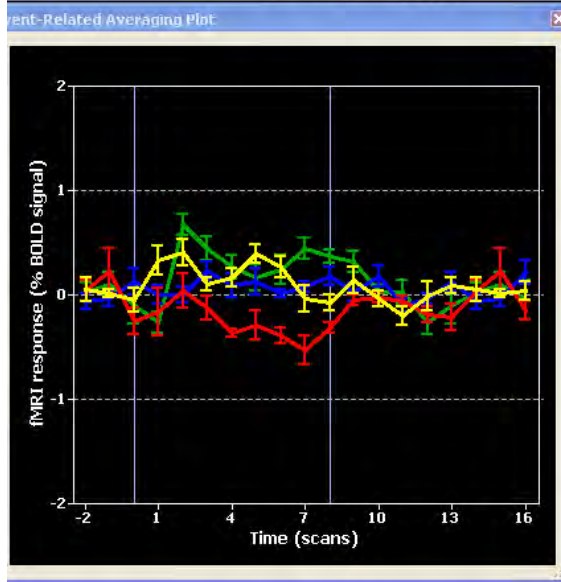
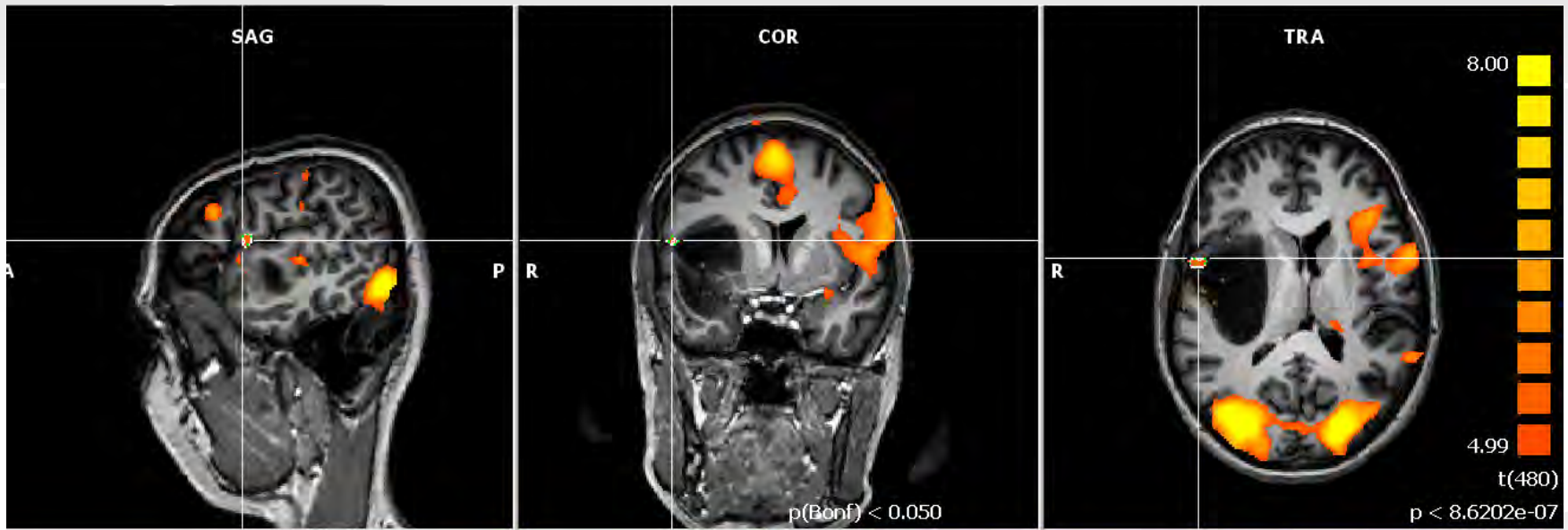
CT





MR

fMRI



3D Volume Tools

System coords

X: 76

Y: 123

Kép

Színen

Hallás

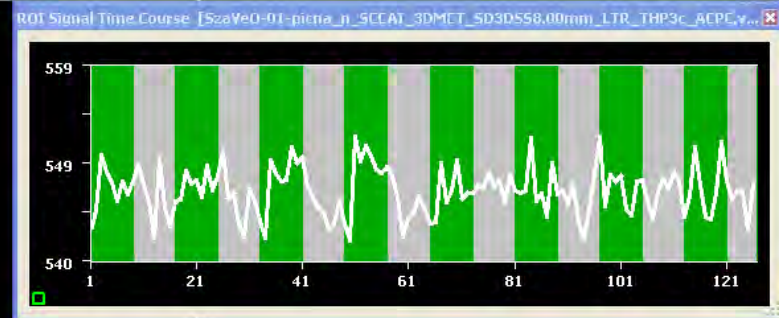
HDönt

Close

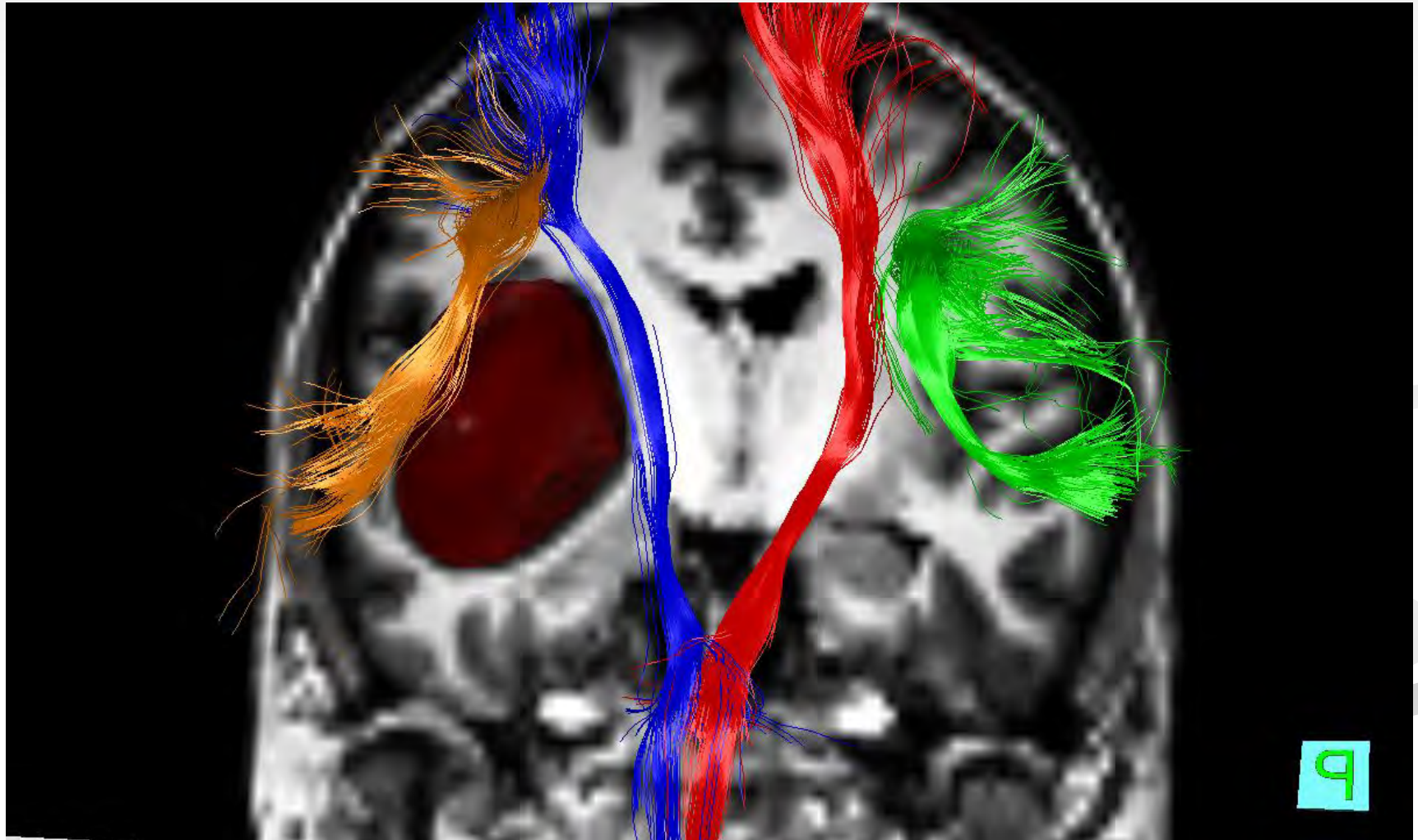
Full Dialog >>

Link VMRs

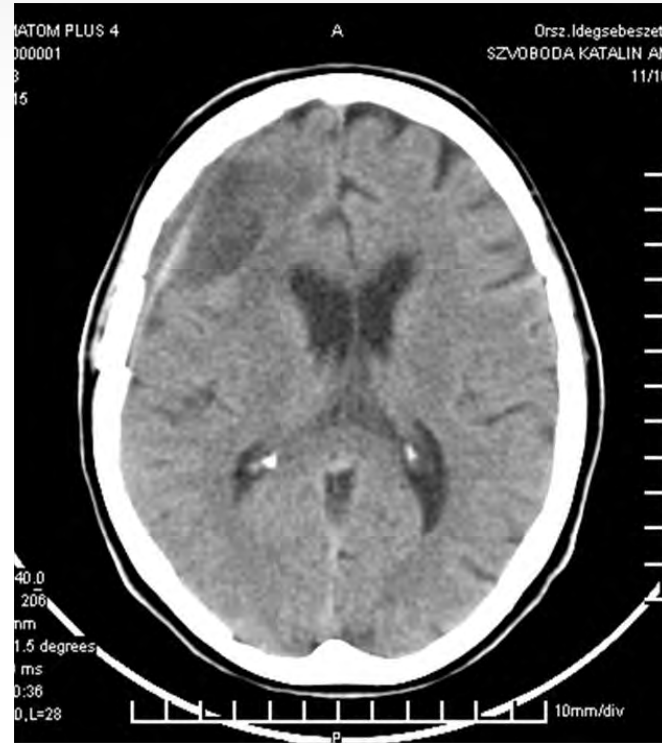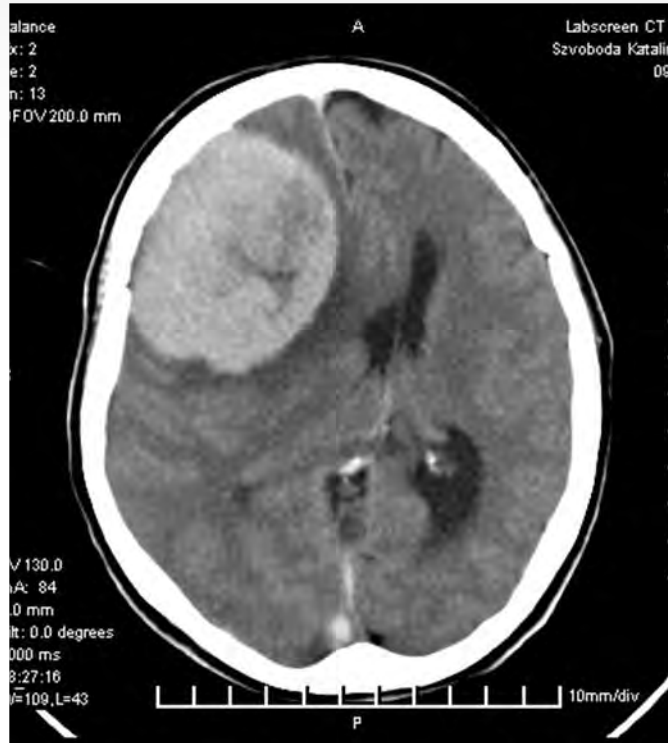Surf Module

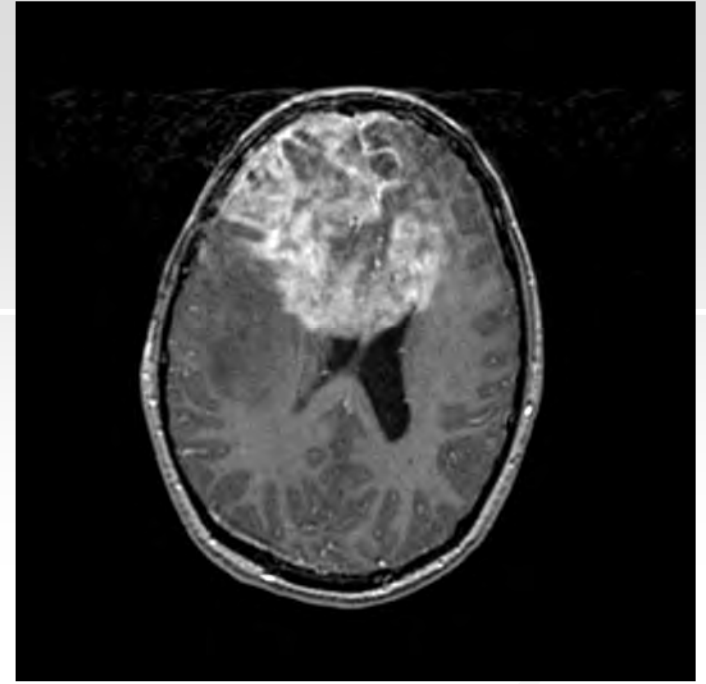
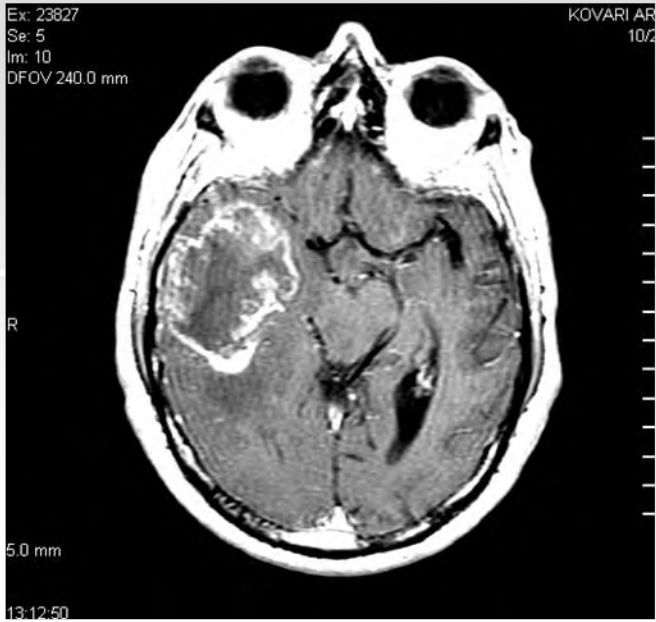

DTI tractography

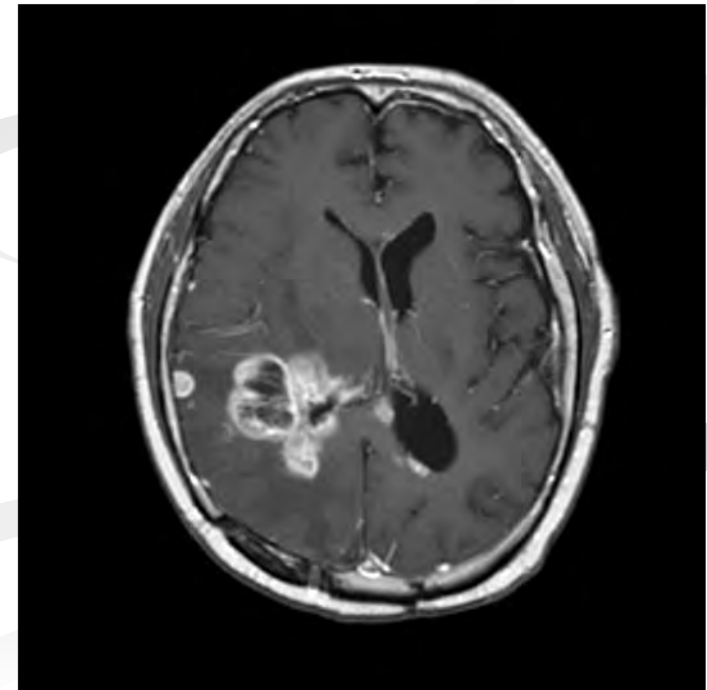
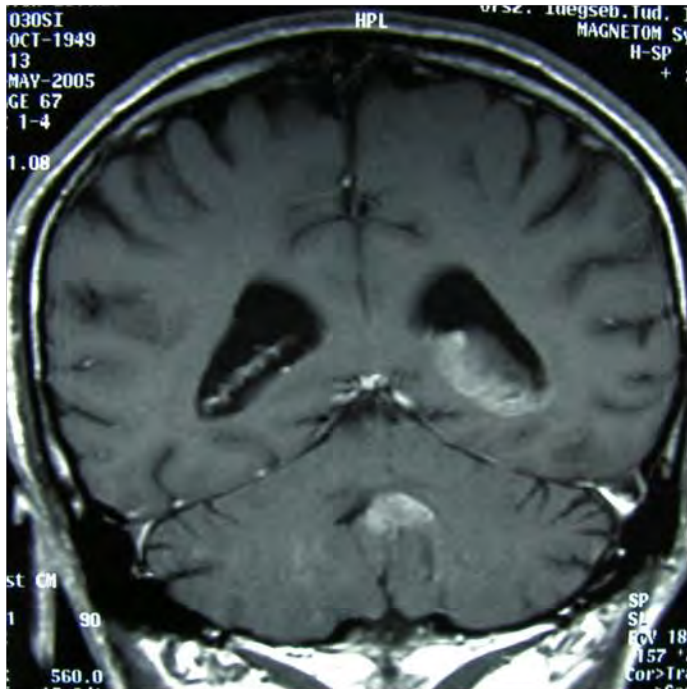


Meningioma



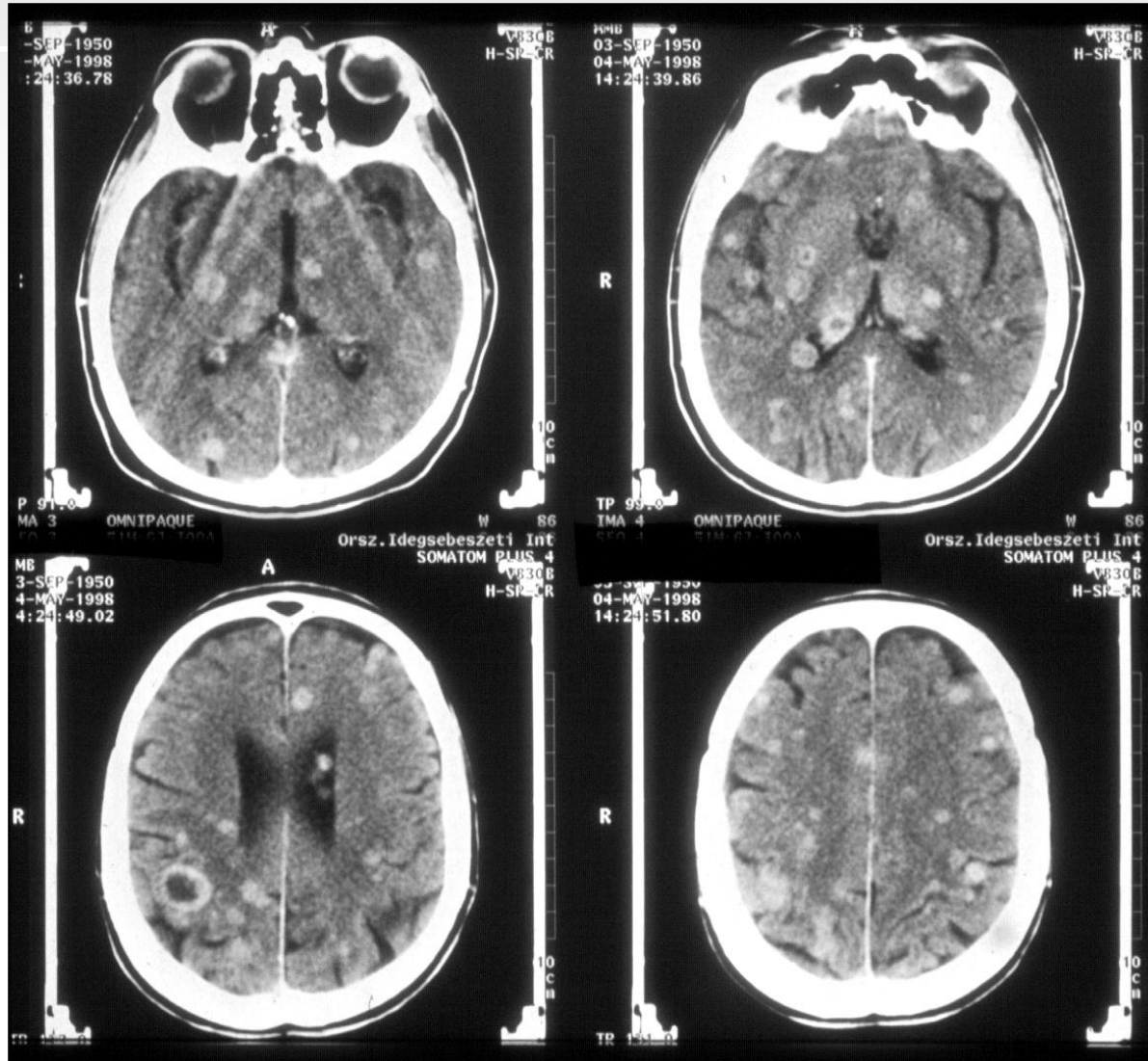


GBM

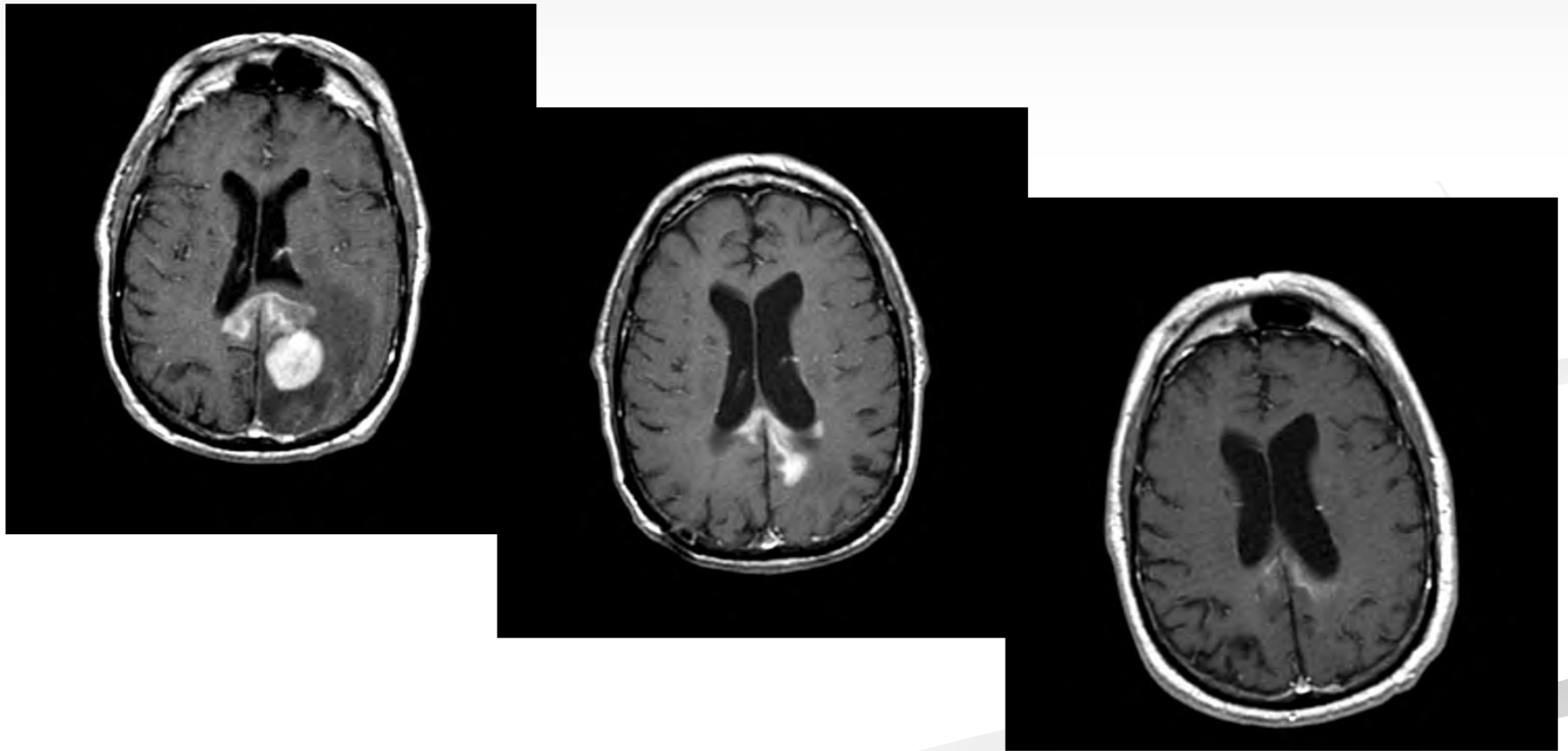


Bagó A : Agydaganatok, SE, 2022

Multiple met

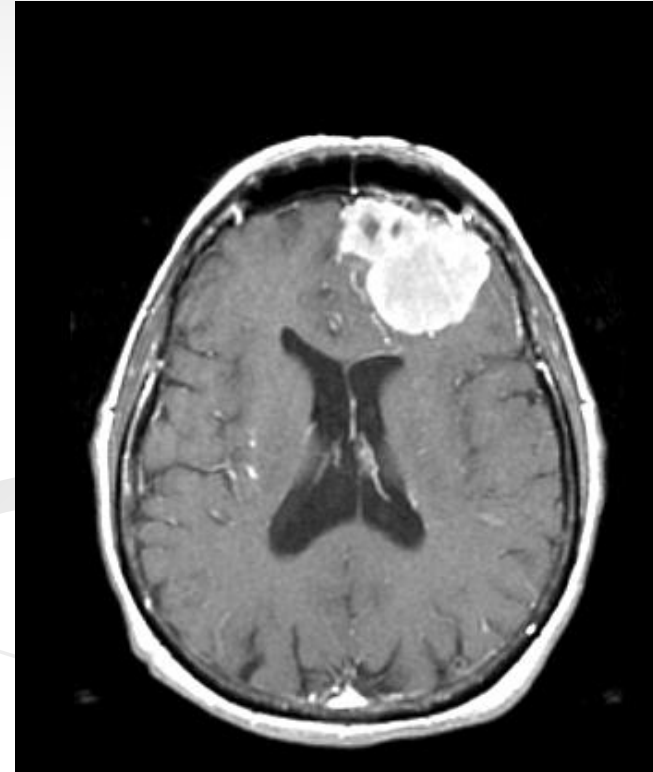


CNS Lymphoma



Brain tumor therapy

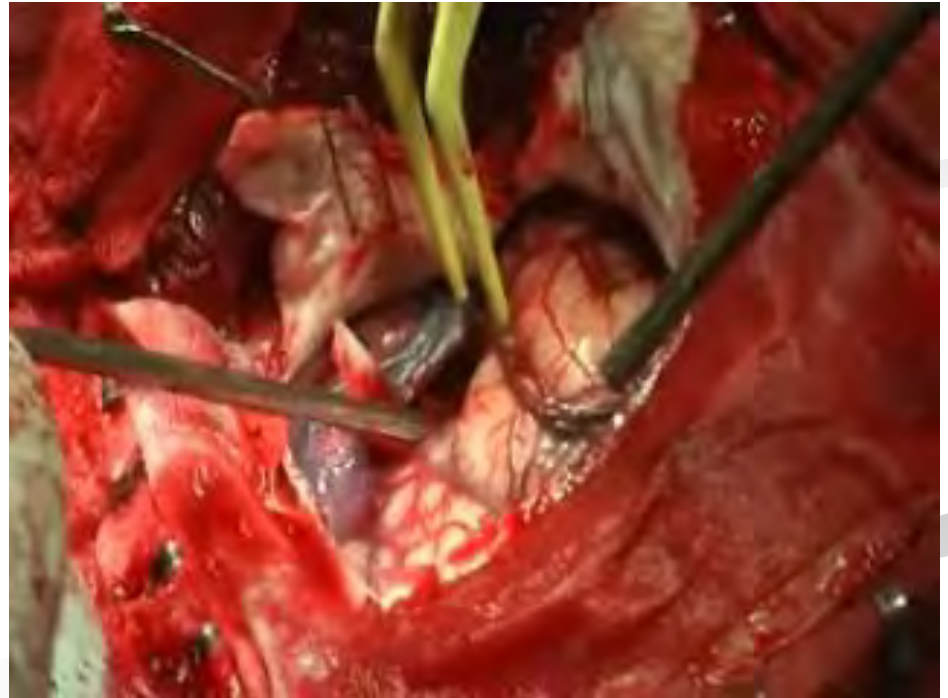
- **Surgery**
 - **Radiosurgery (SRS)**
- **Radiotherapy**
 - **Radiochemotherapy**
- **Chemotherapy**



Histology is mandatory!

Paradigms

- Maximal resection
- Minimal morbidity
- Accurate histology



Paradigms

- Maximal resection
- Minimal morbidity
- Accurate histology

- Age
- Performance status
- Mass effect
- Lokalization, multifocality
- Met: primary tumor, staging

Paradigms

- Maximal resection
- Minimal morbidity
- Accurate histology

- Gross total resection
- Debulking
- Stereotactic biopsy

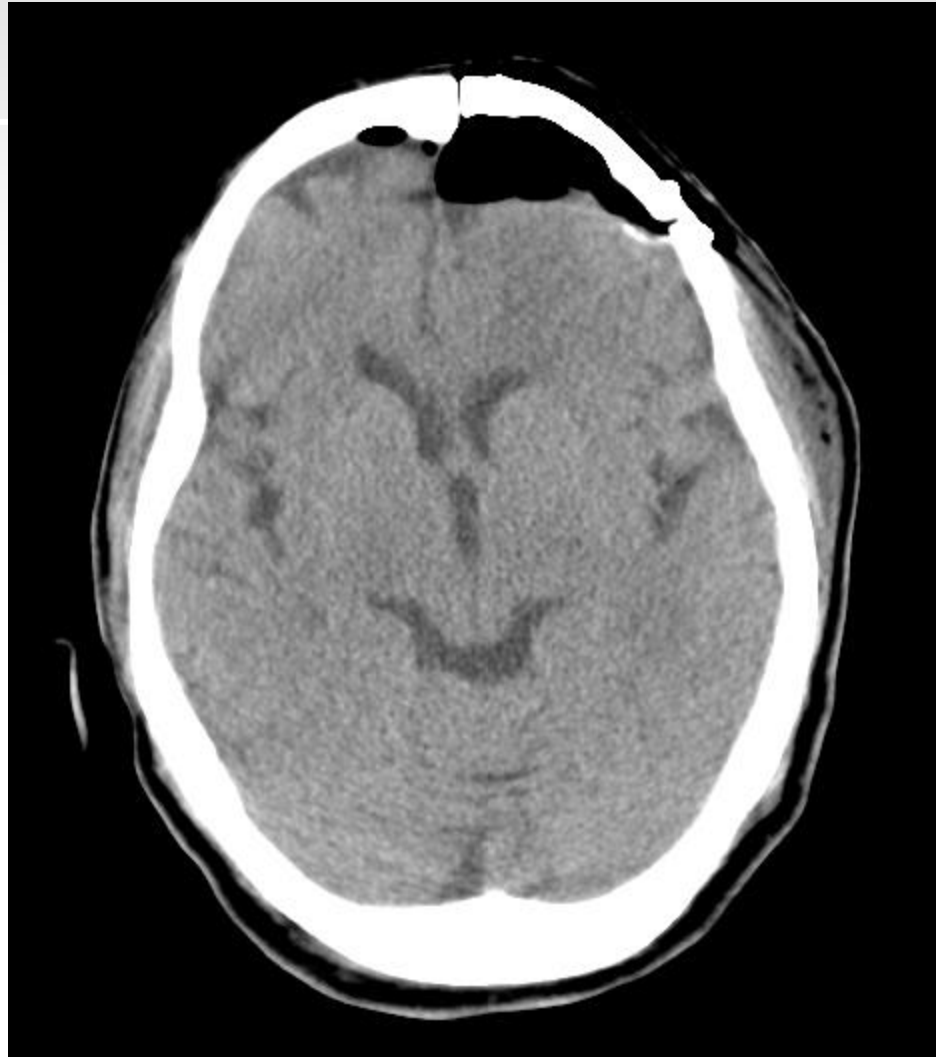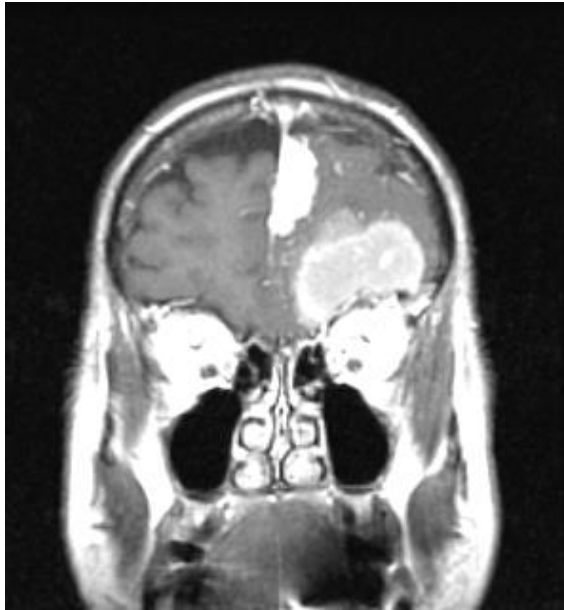
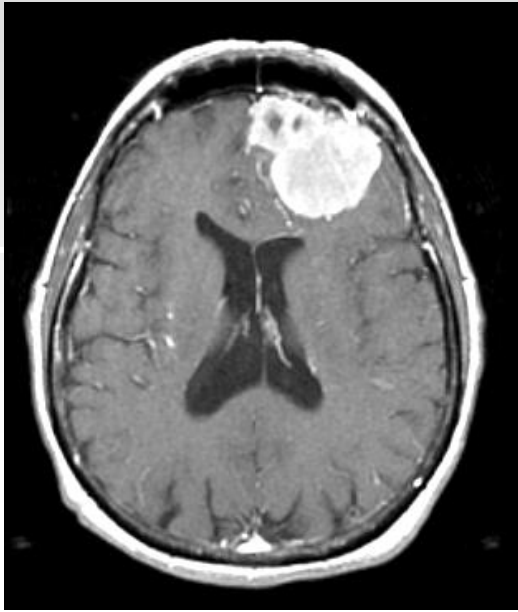
- Age
- Performance status
- Mass effect
- Lokalization, multifocality
- Met: primary tumor, staging

Paradigms

- Gross total resection
- Debulking
- Stereotactic biopsy

- Maximal safe resection
- Verified by postoperative imaging (NCCN 2009)

MR (CT) +/- CM
in 24-24h postop

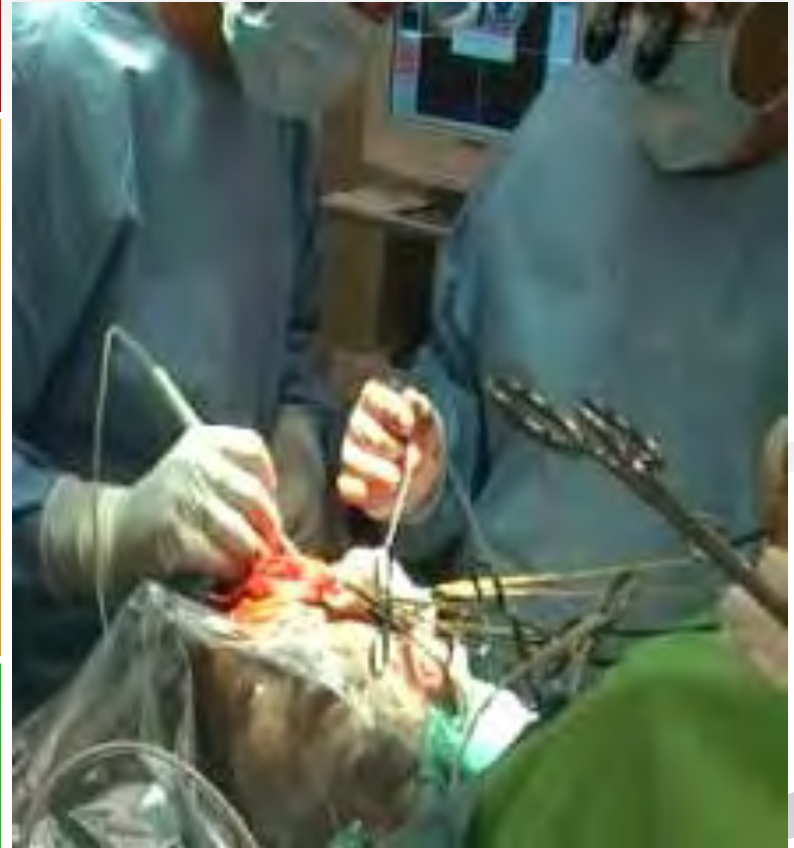

Modern neurosurgery

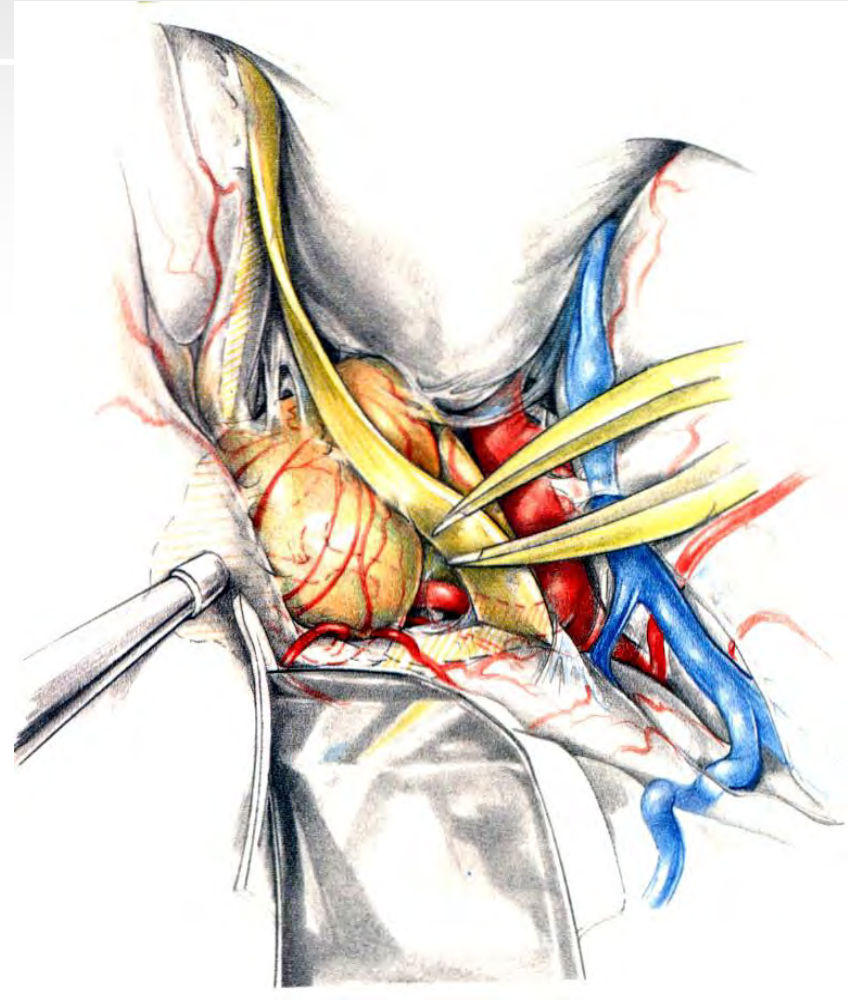- microneurosurgery

- Neuronavigation
- intraoperativ imaging
(UH, CT, MR)
- Fluorescent microscopy

- Intraop. neuromonitoring
- Awake craniotomy

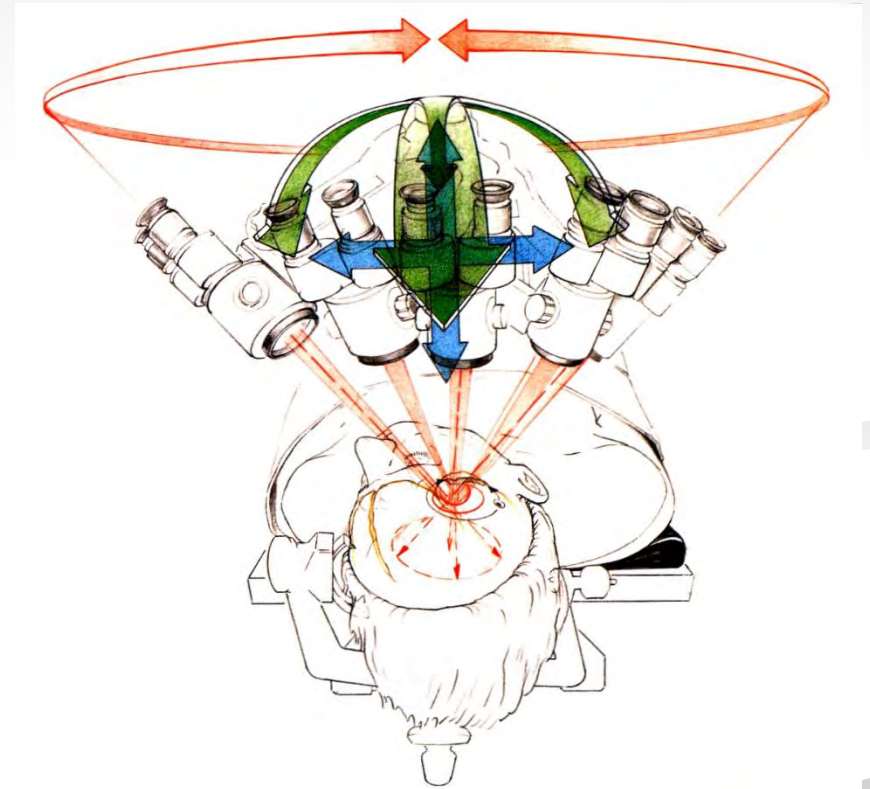
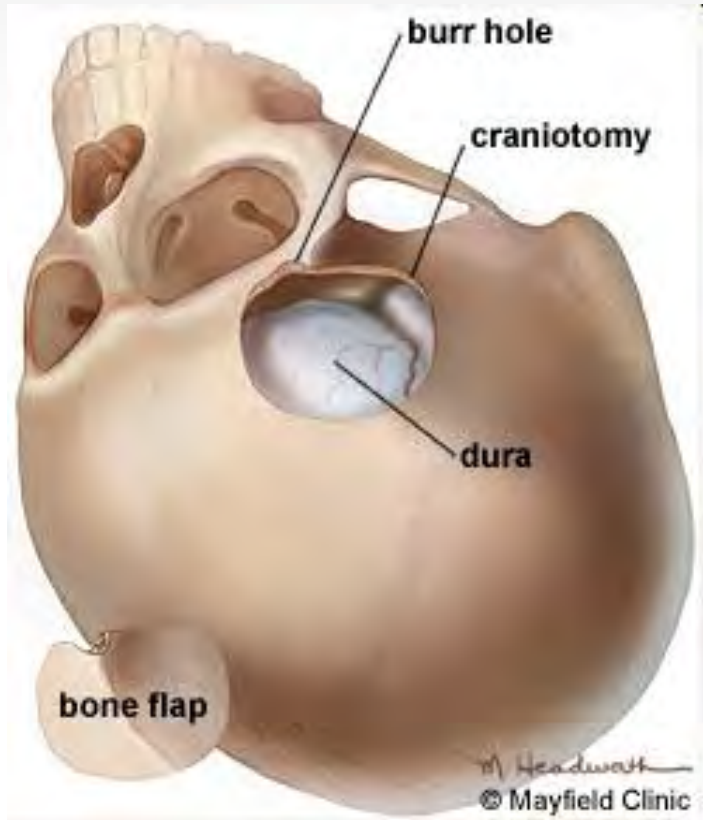


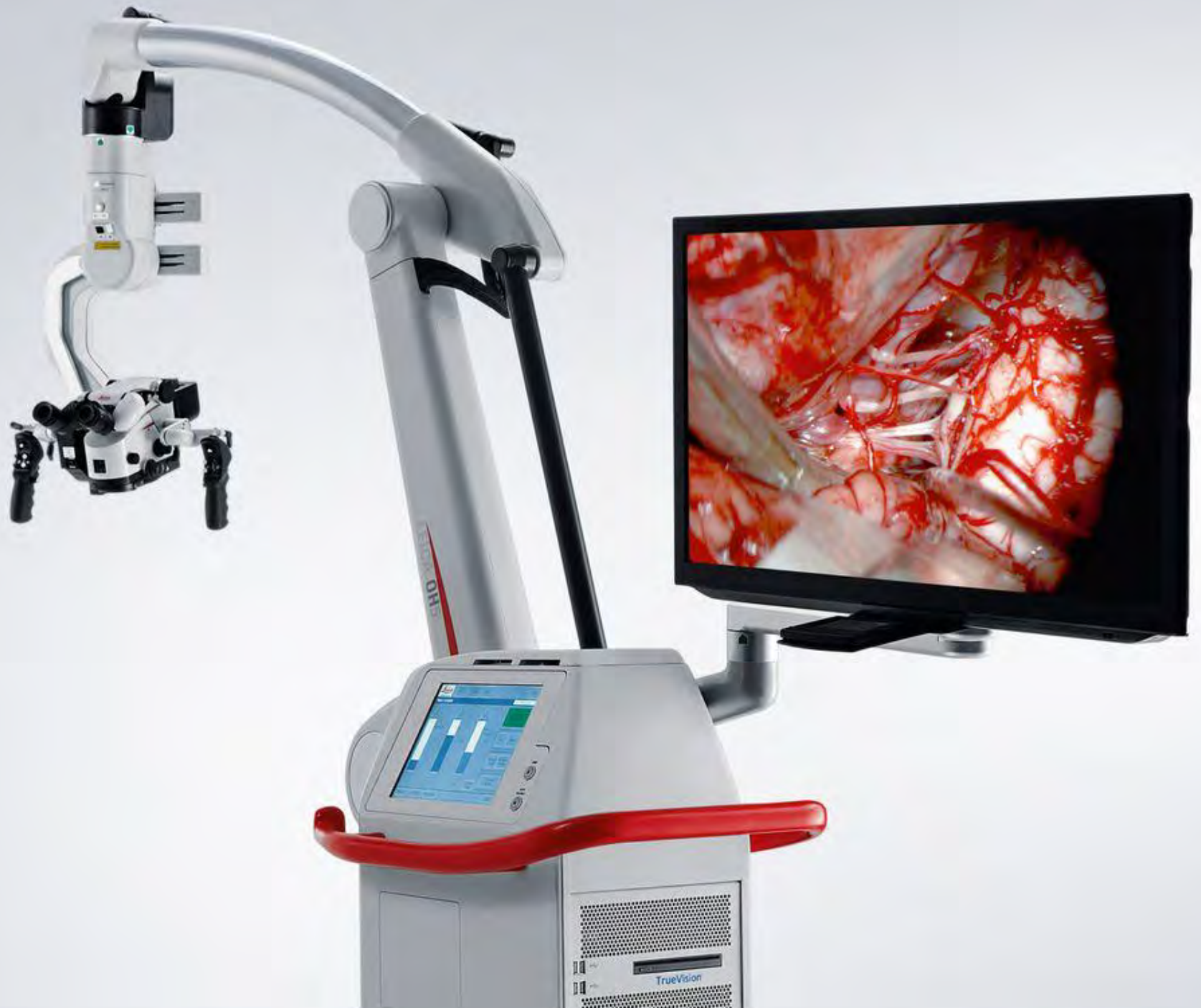Microneurosurgery

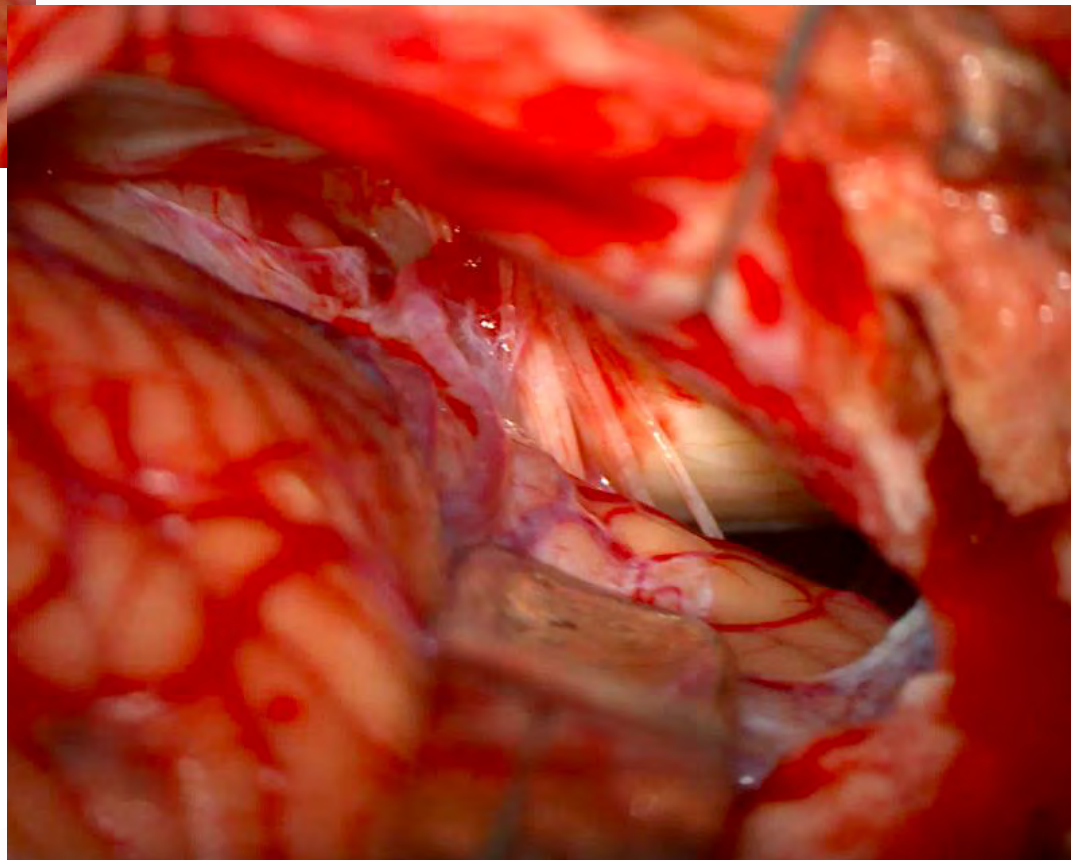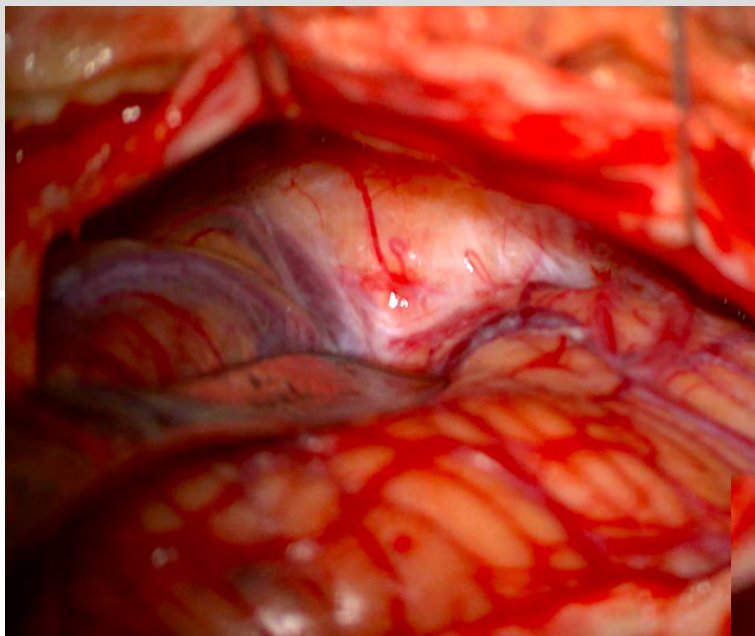


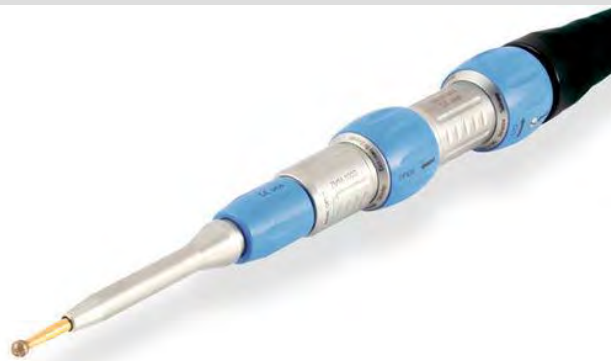asztári... is

Microneurosurgery

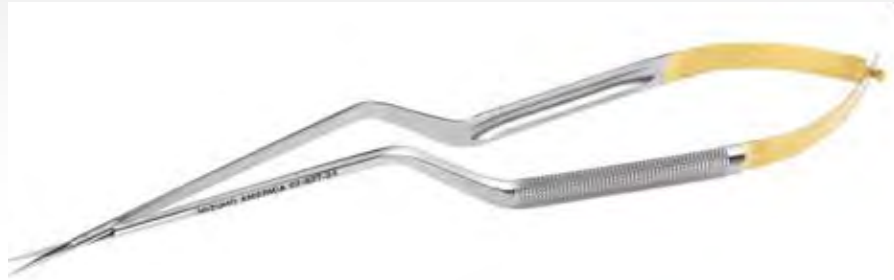




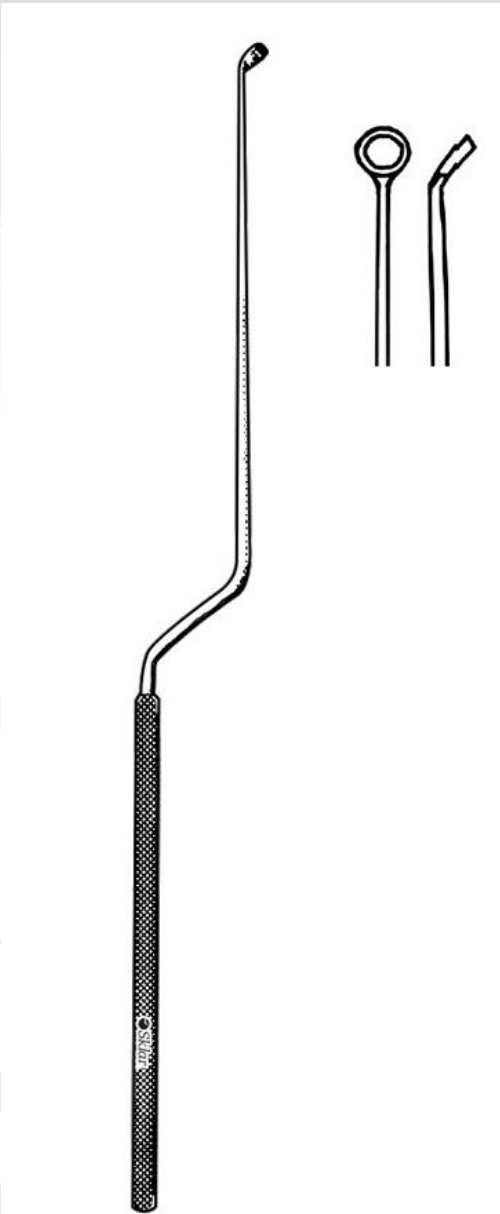


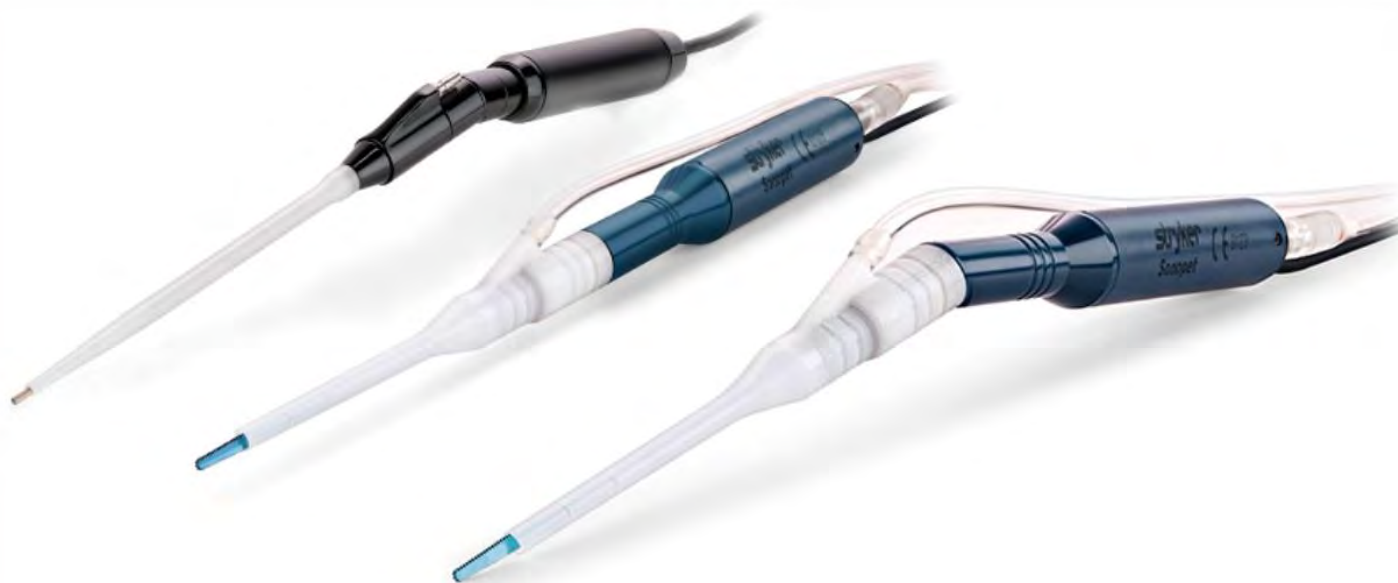

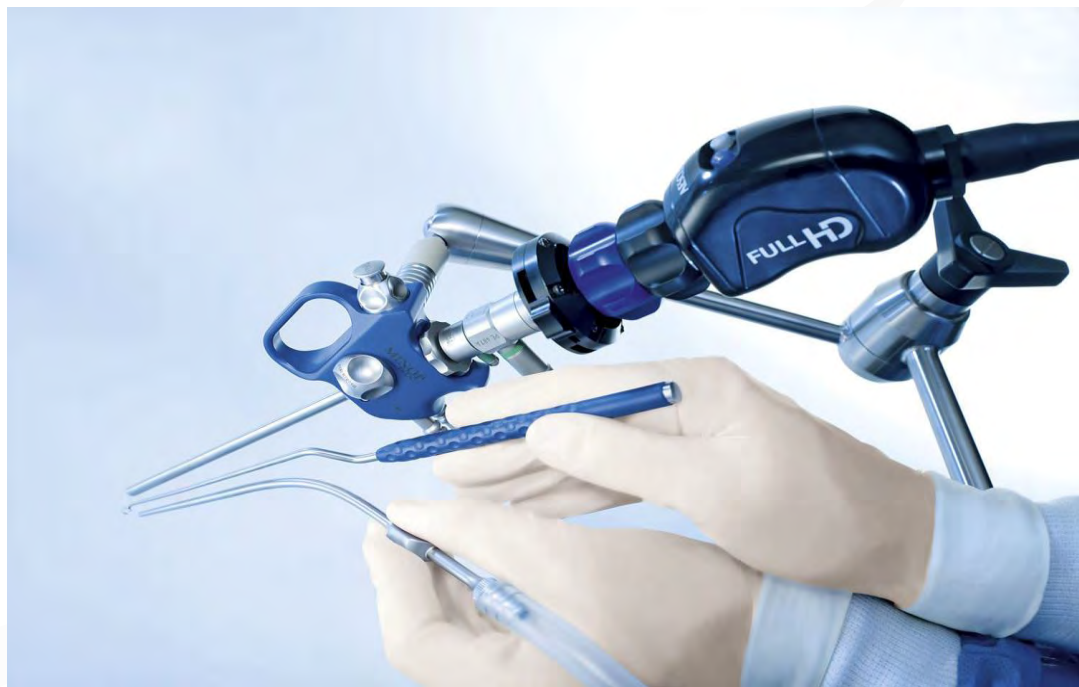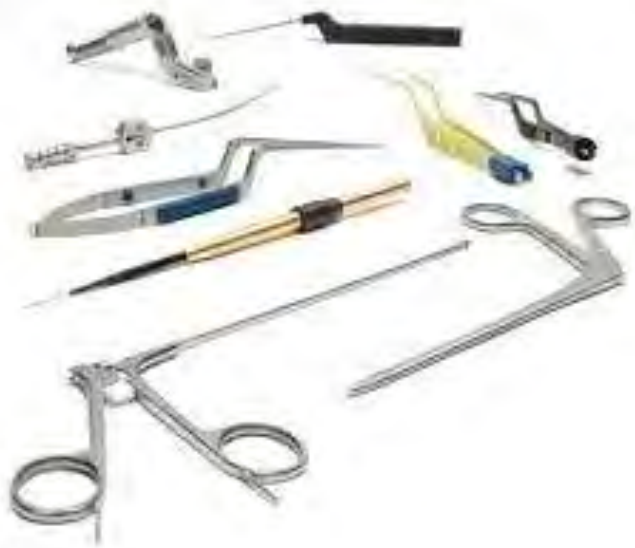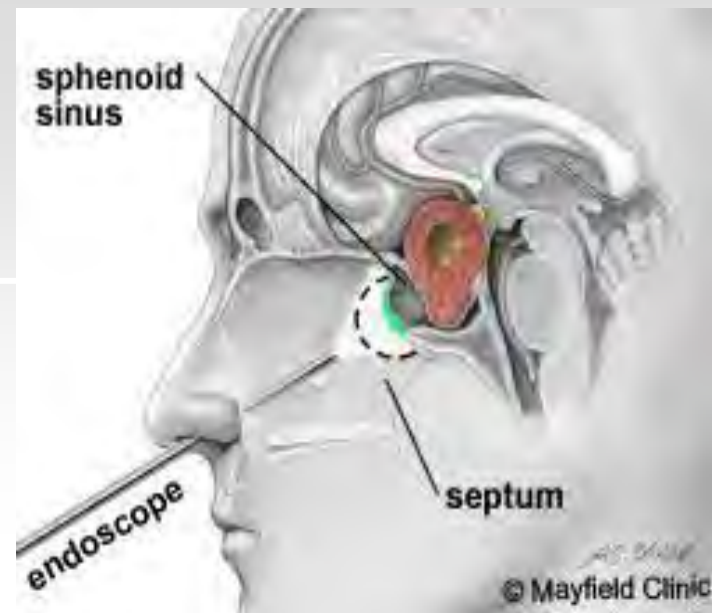
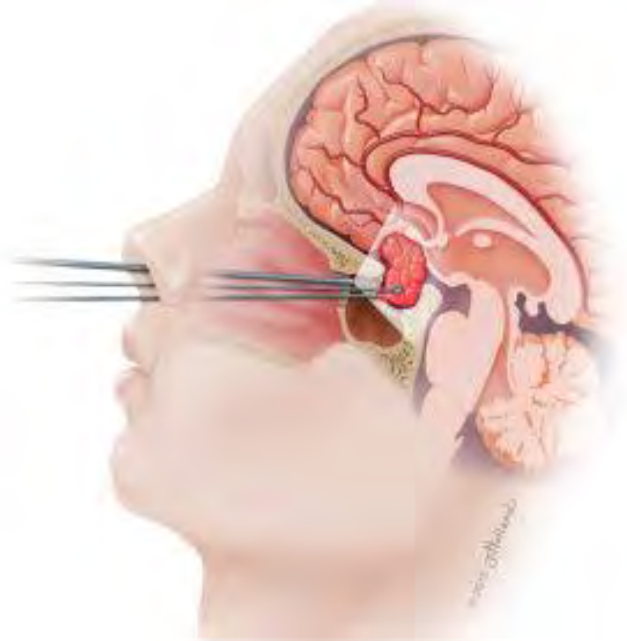
Bagó A : Agydaganatok, SE, 2022










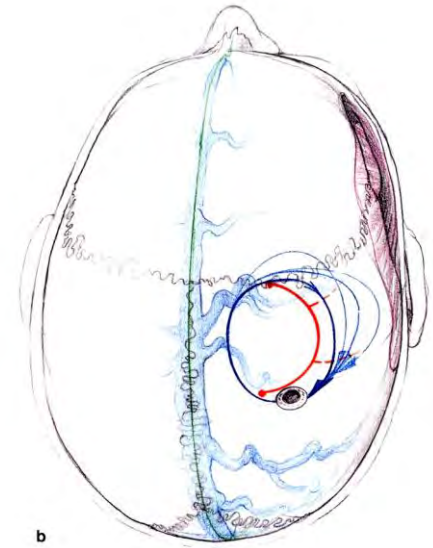
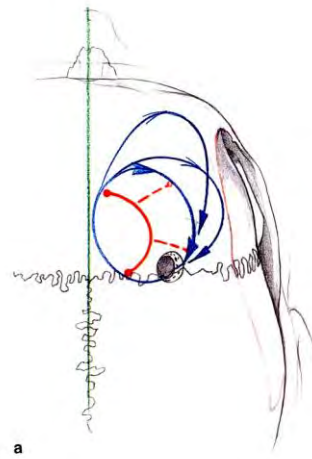
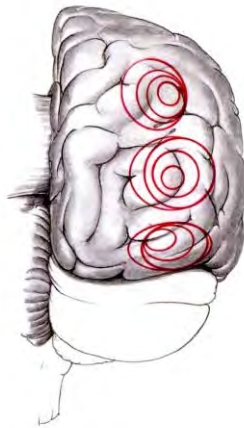
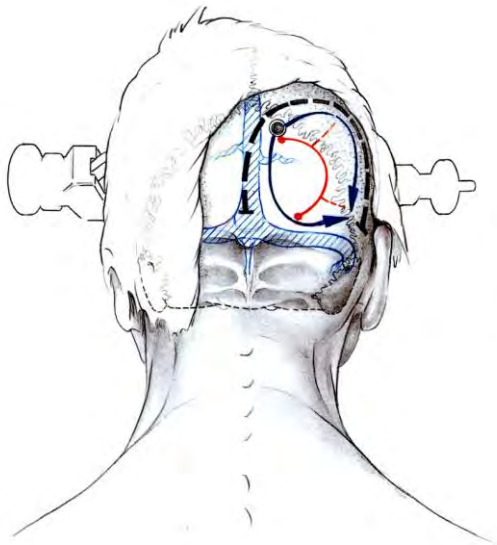
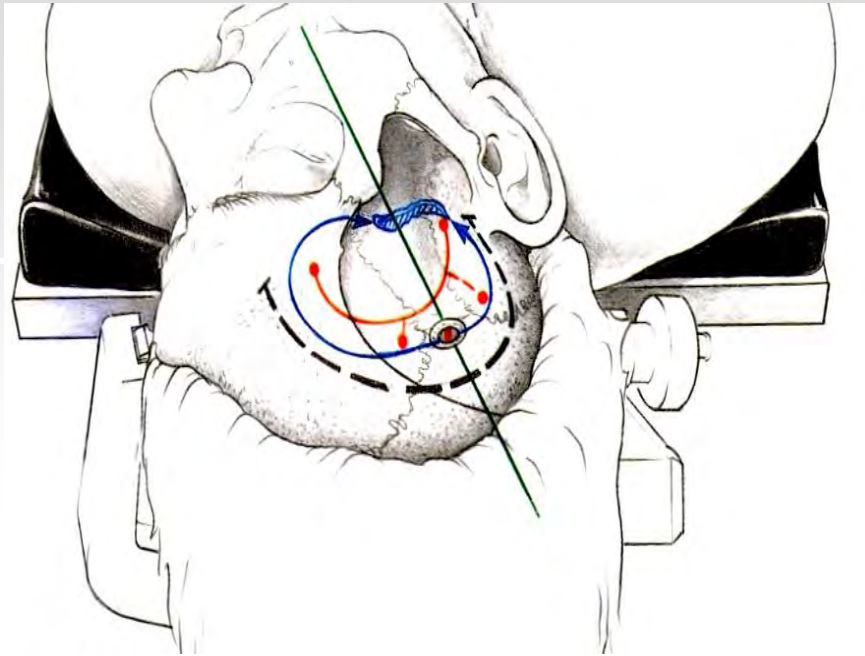


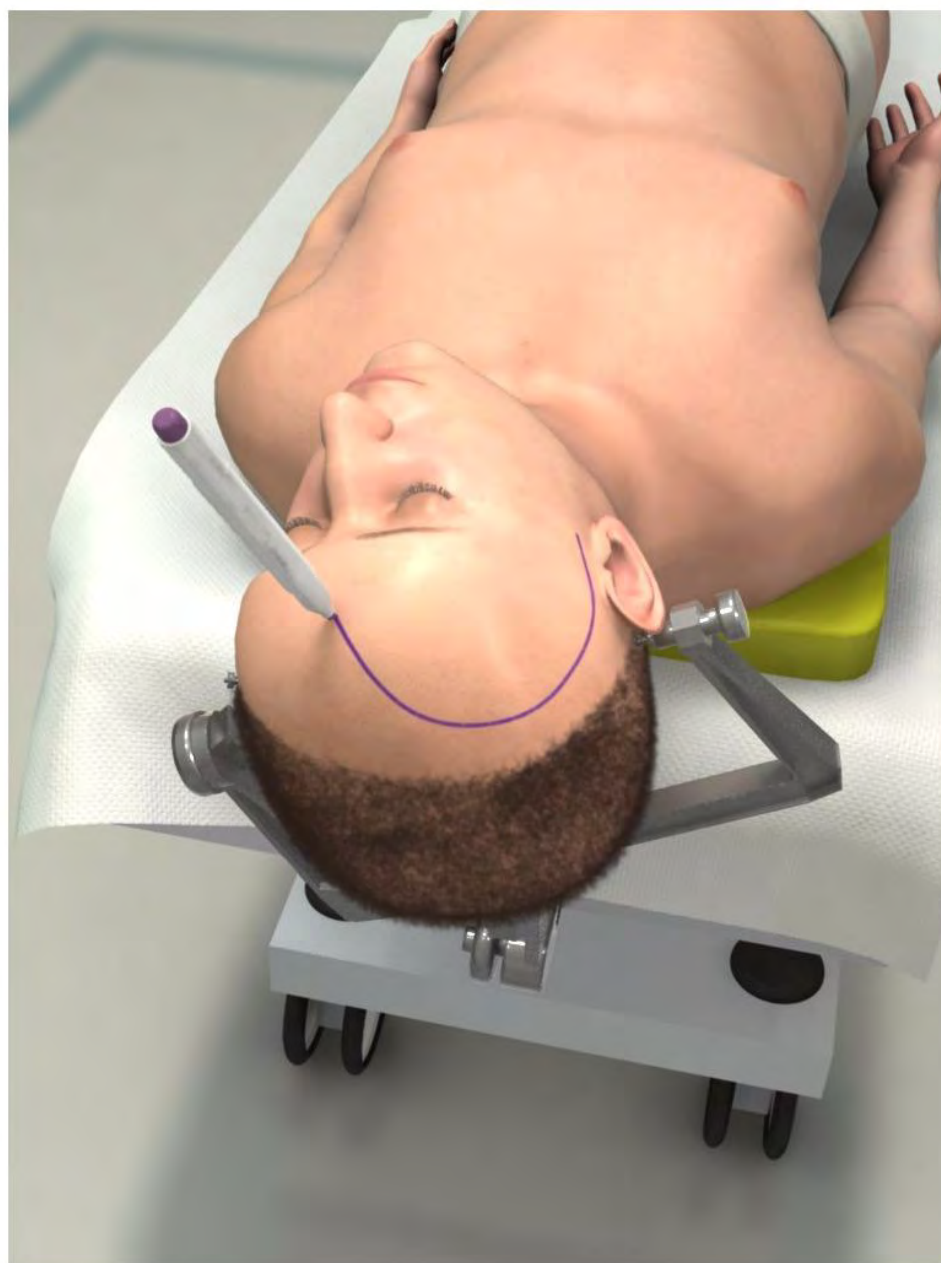

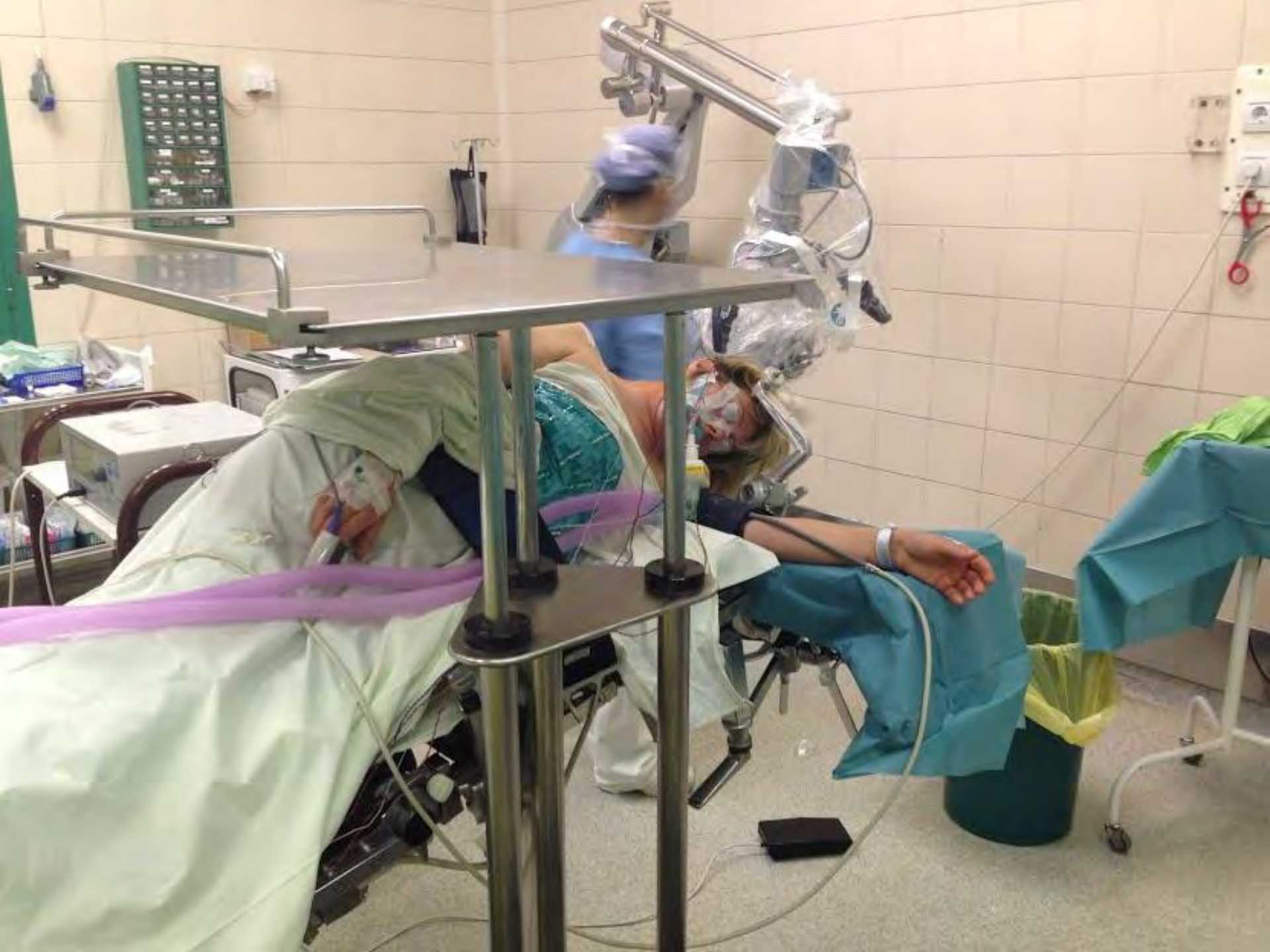
Brain tumor surgery 1.

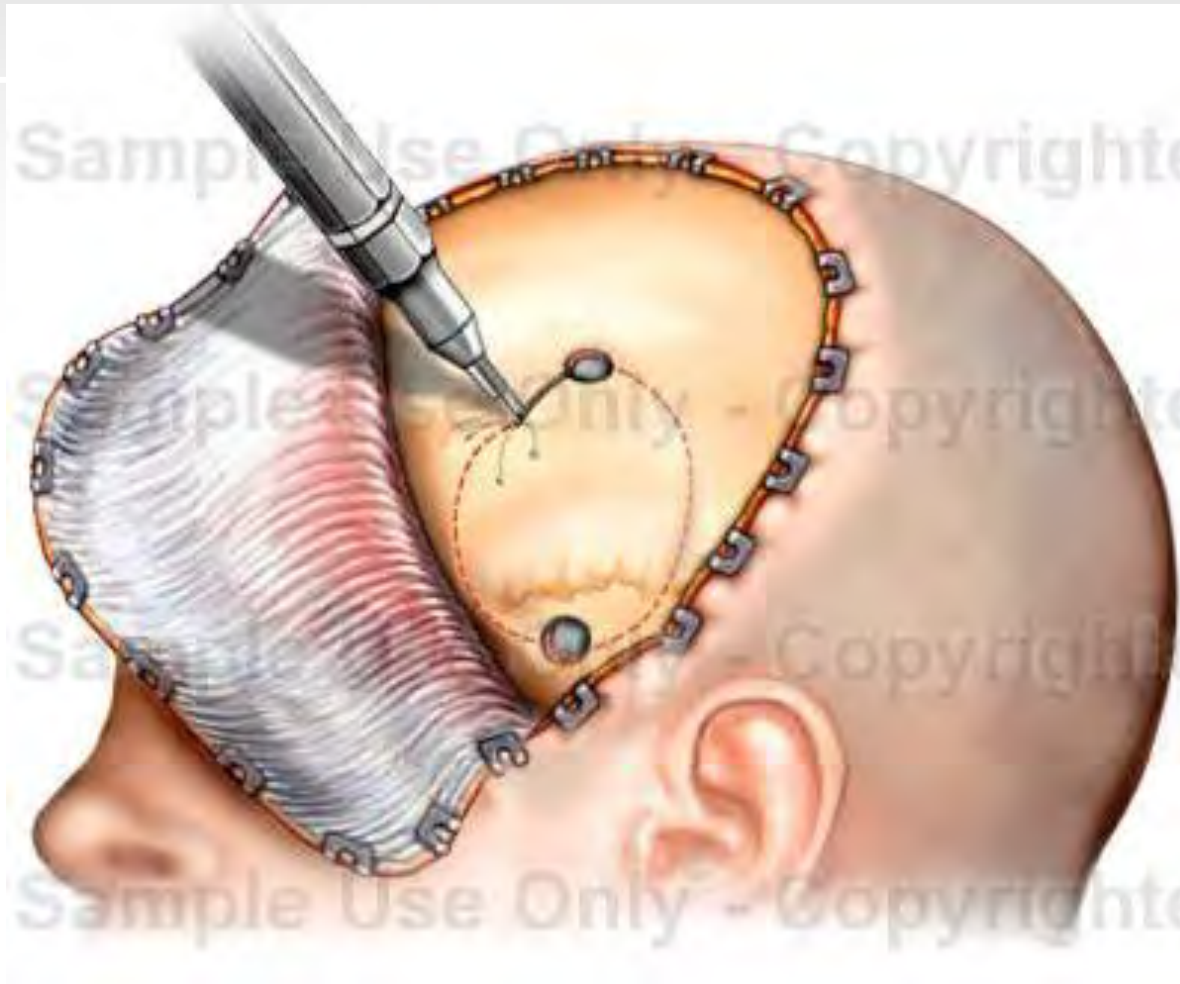
Exploration

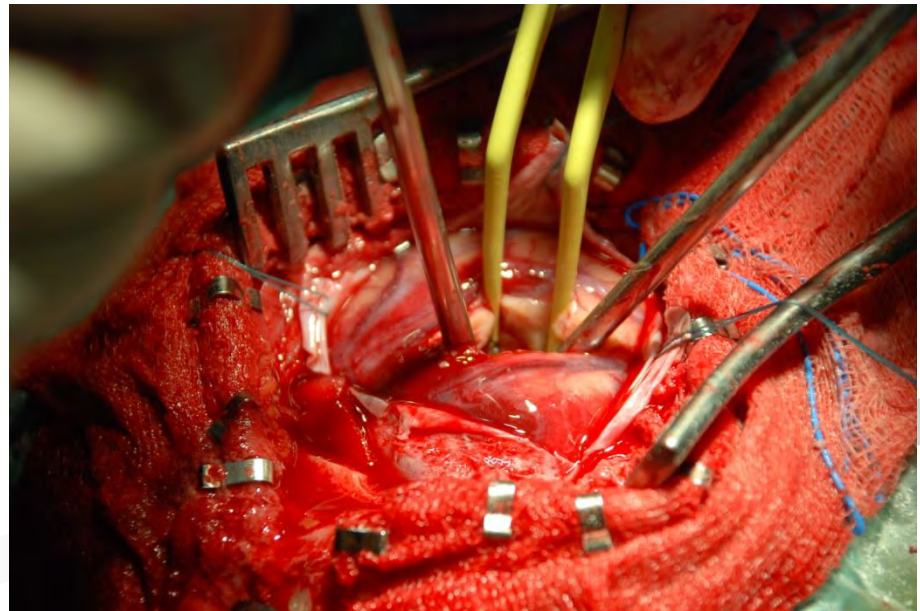
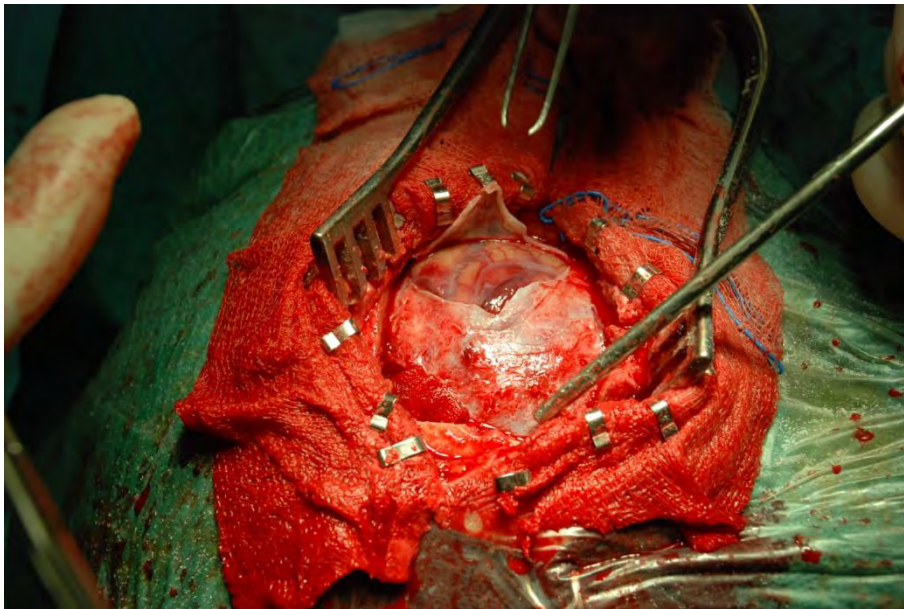
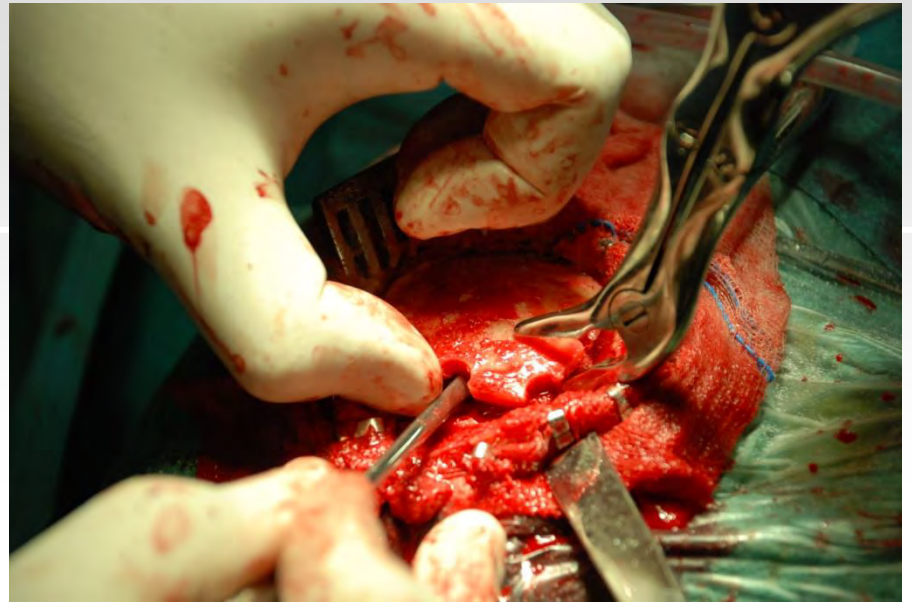
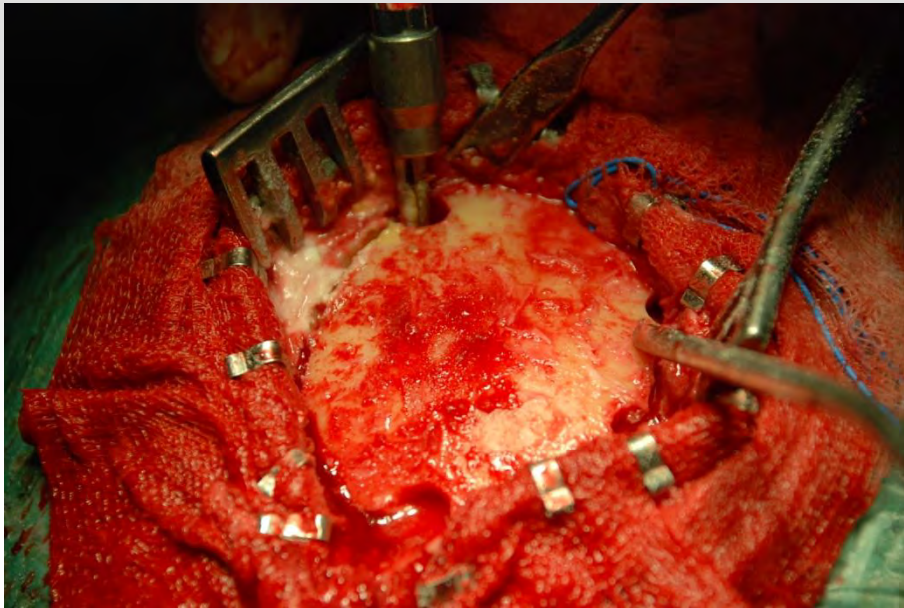
- surgery planning
- patient positioning
- craniotomy planning (neuronavigation)
- craniotomy/craniectomy
- dural opening
- CSF release -> relaxed brain

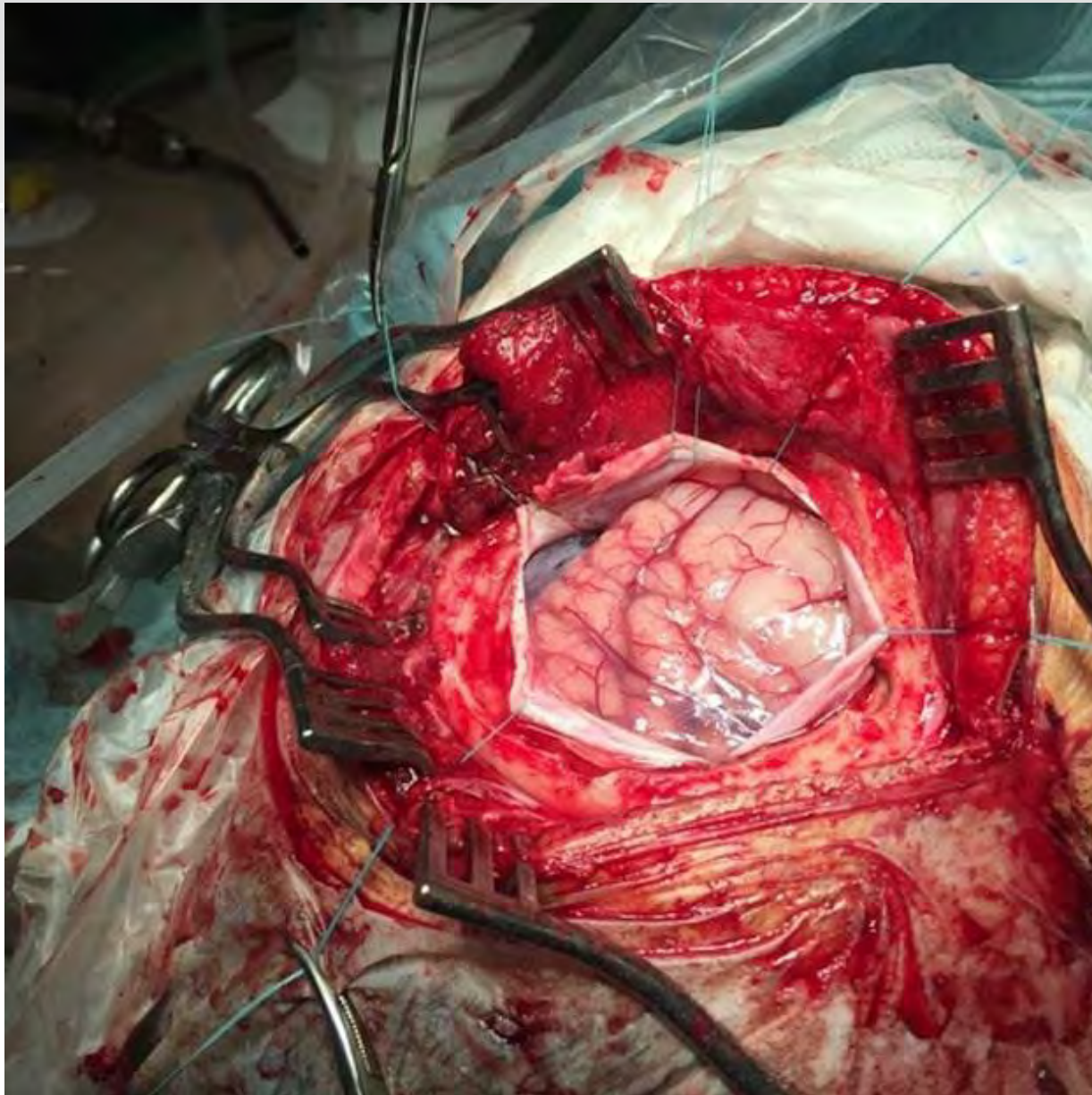








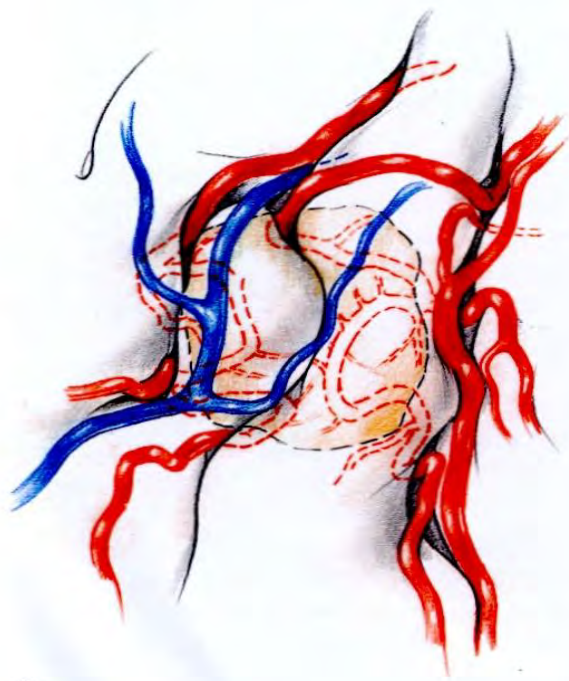



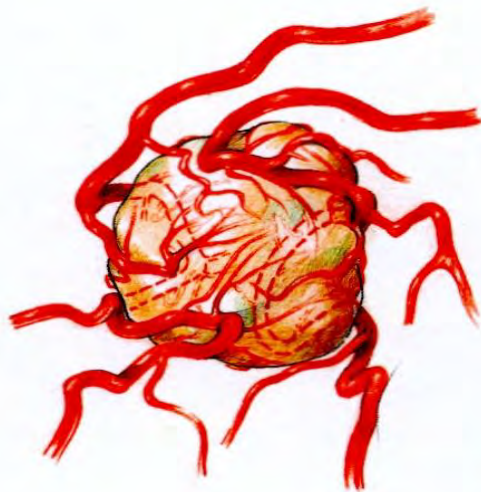Brain tumor surgery 2.

Tumor removal

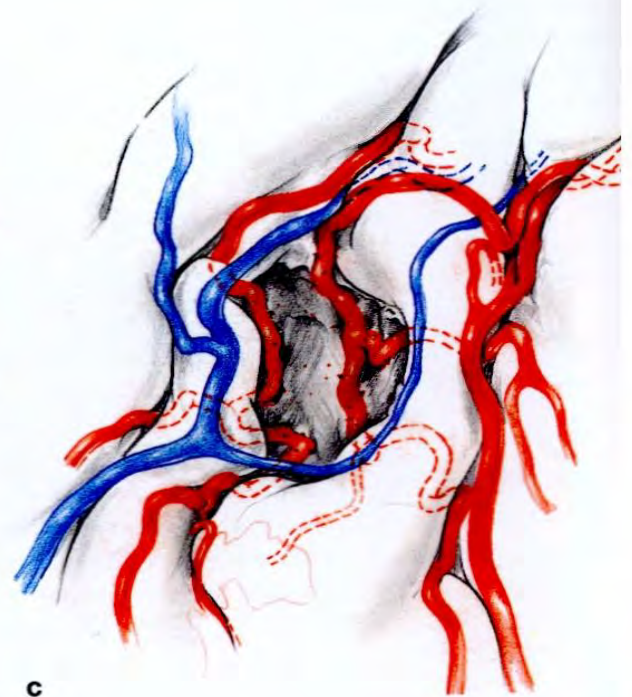
- cortical incision (deep seated tumors)
- tumor – internal decompression
- devascularization
- preparation of brain tumor – interface
- tumor removal
- hemostasis



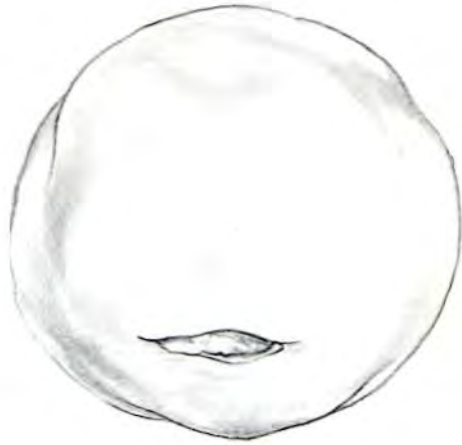a



b



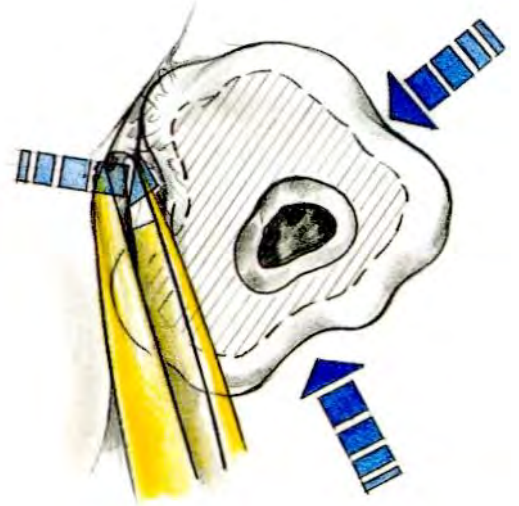
c



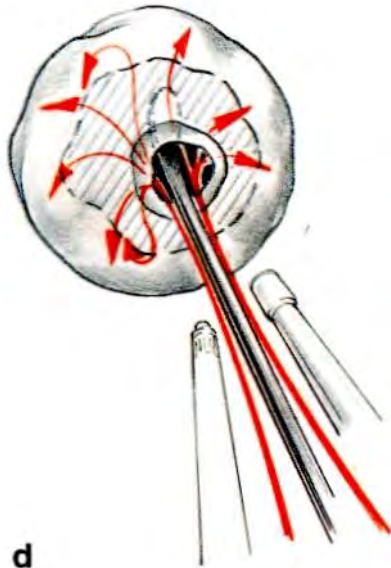
a



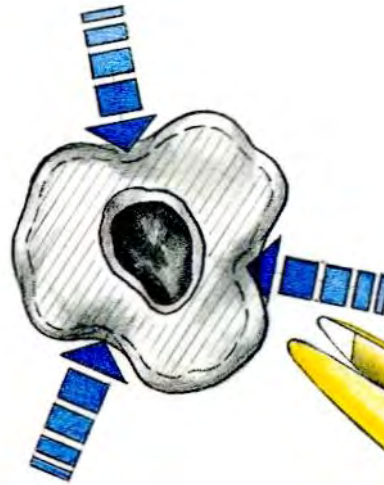
b



c



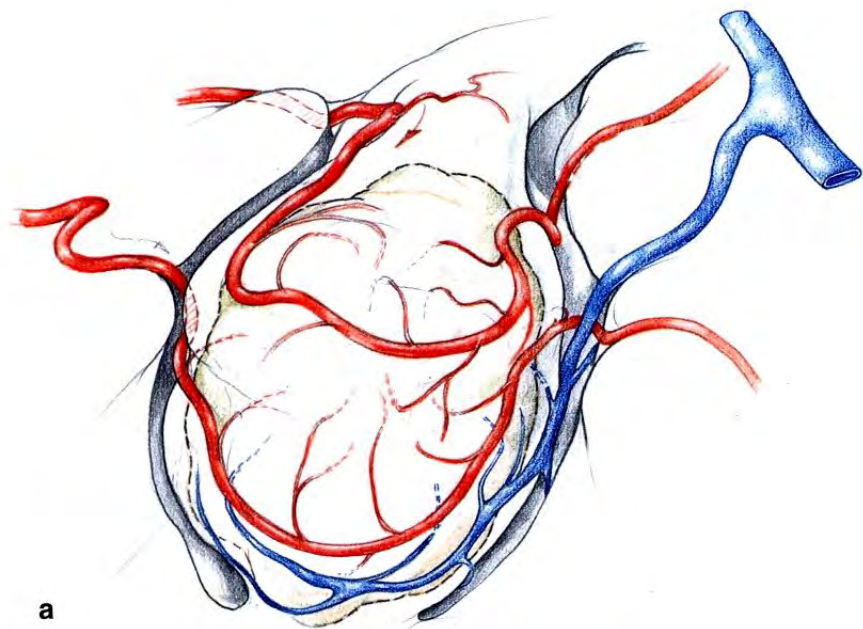
d



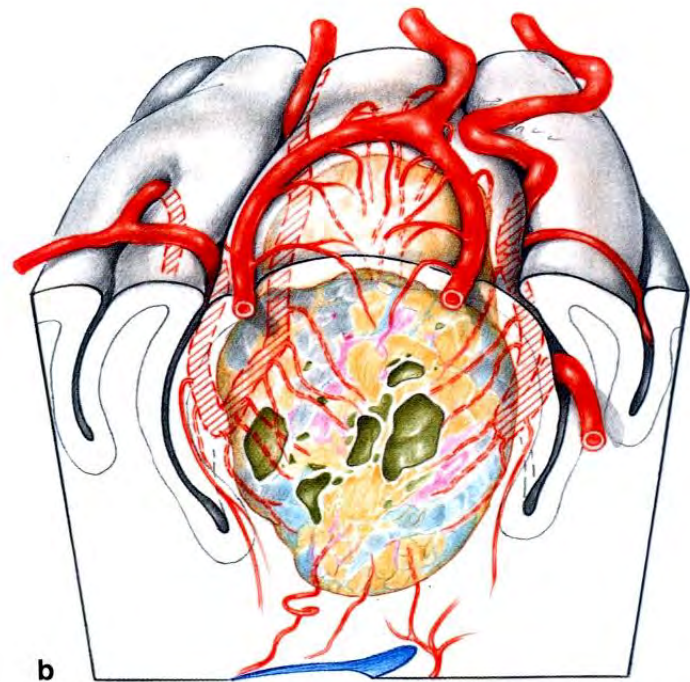
e



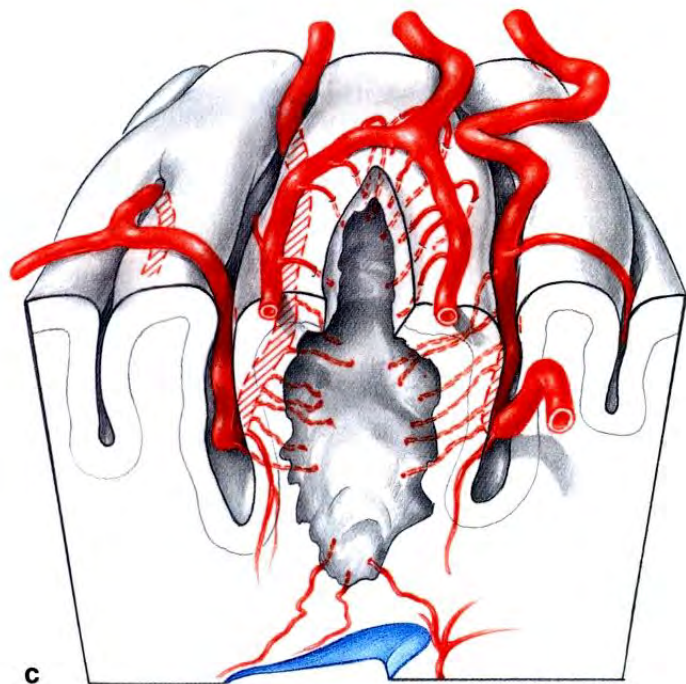
f



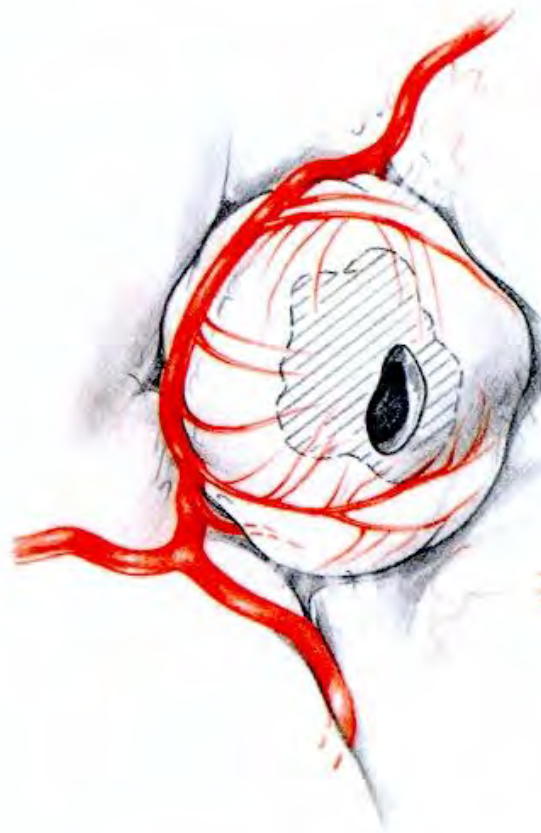
a



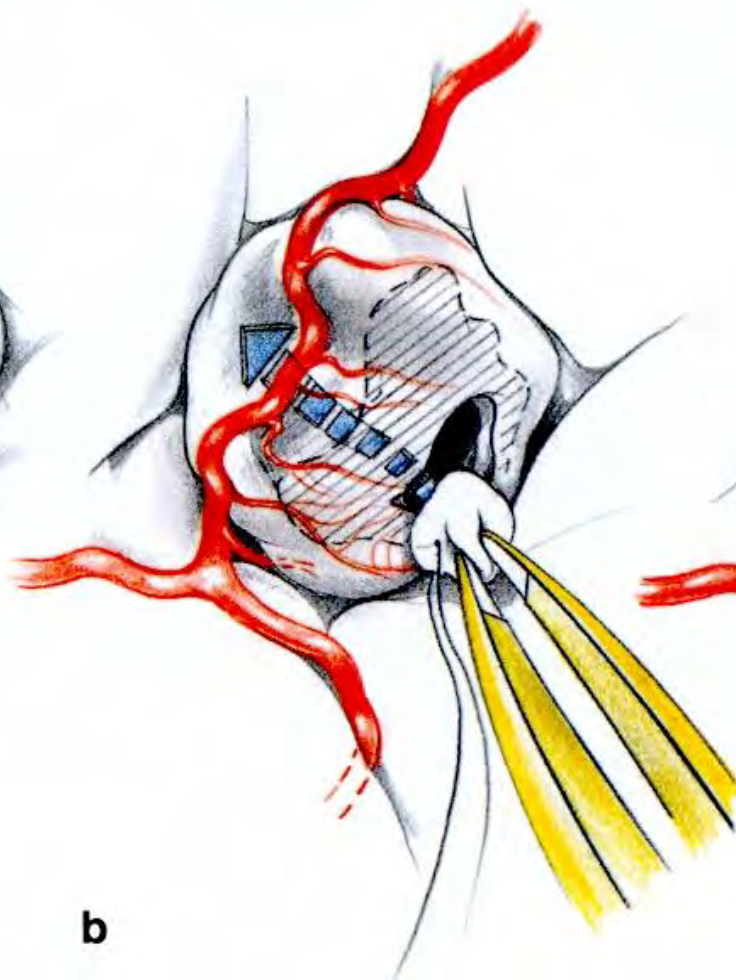
b



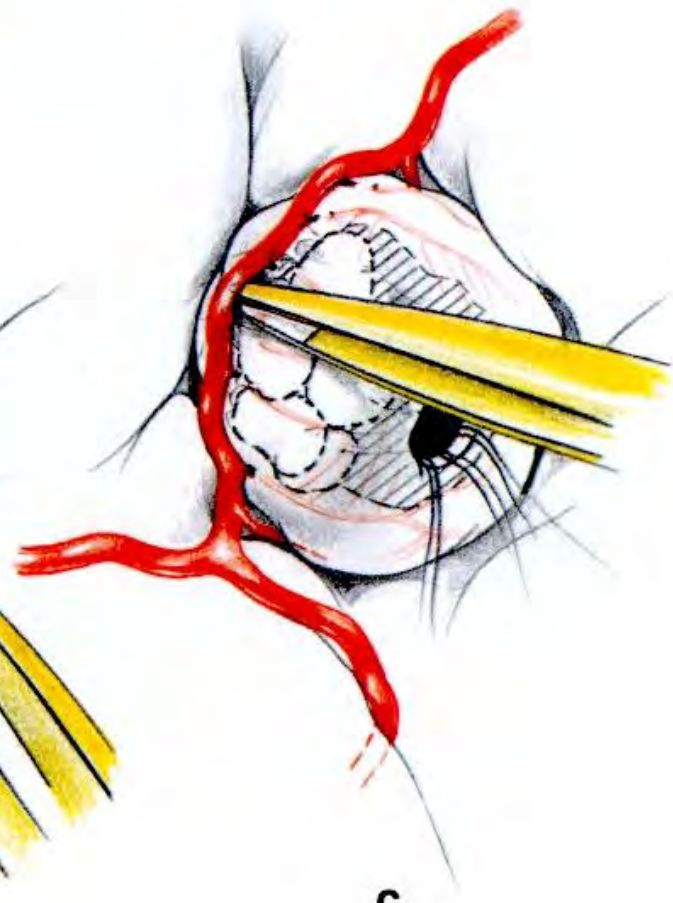
c



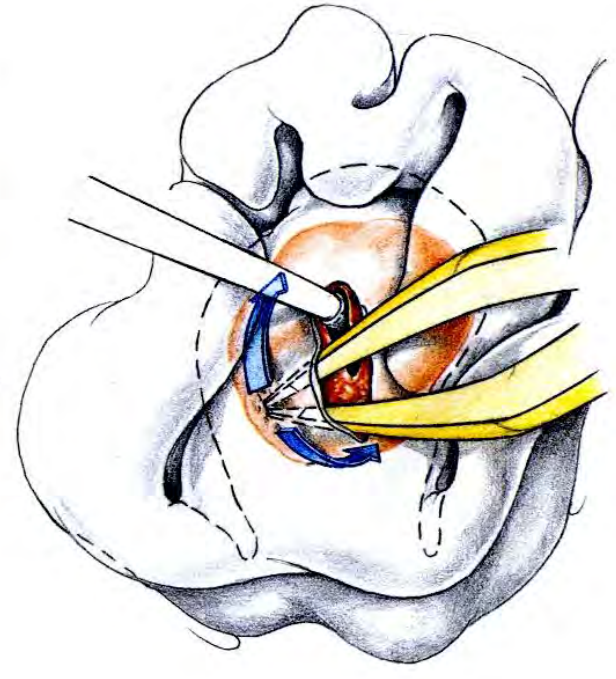
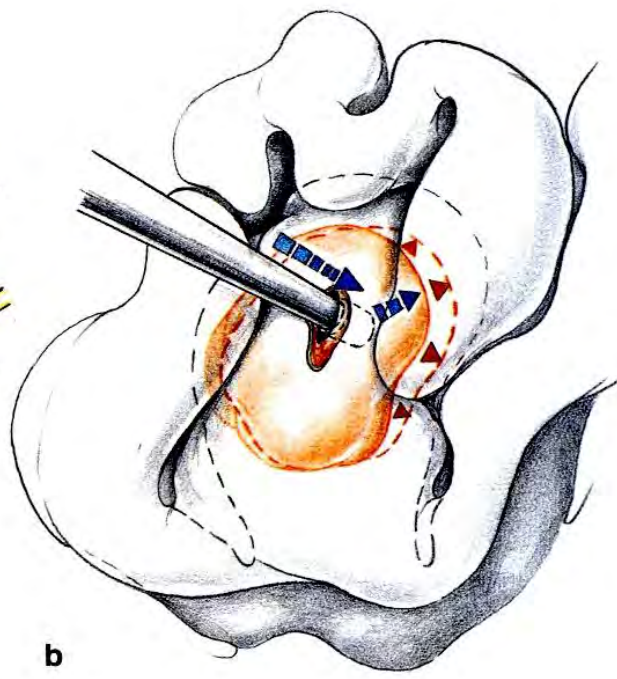
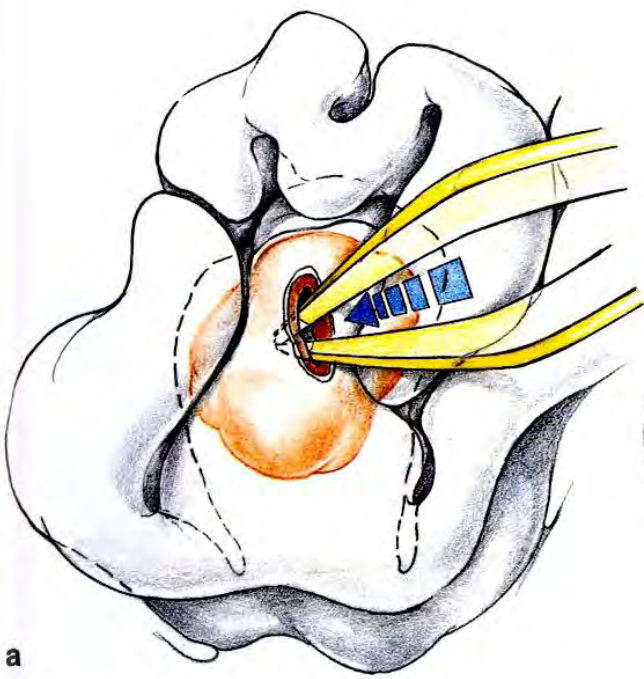a

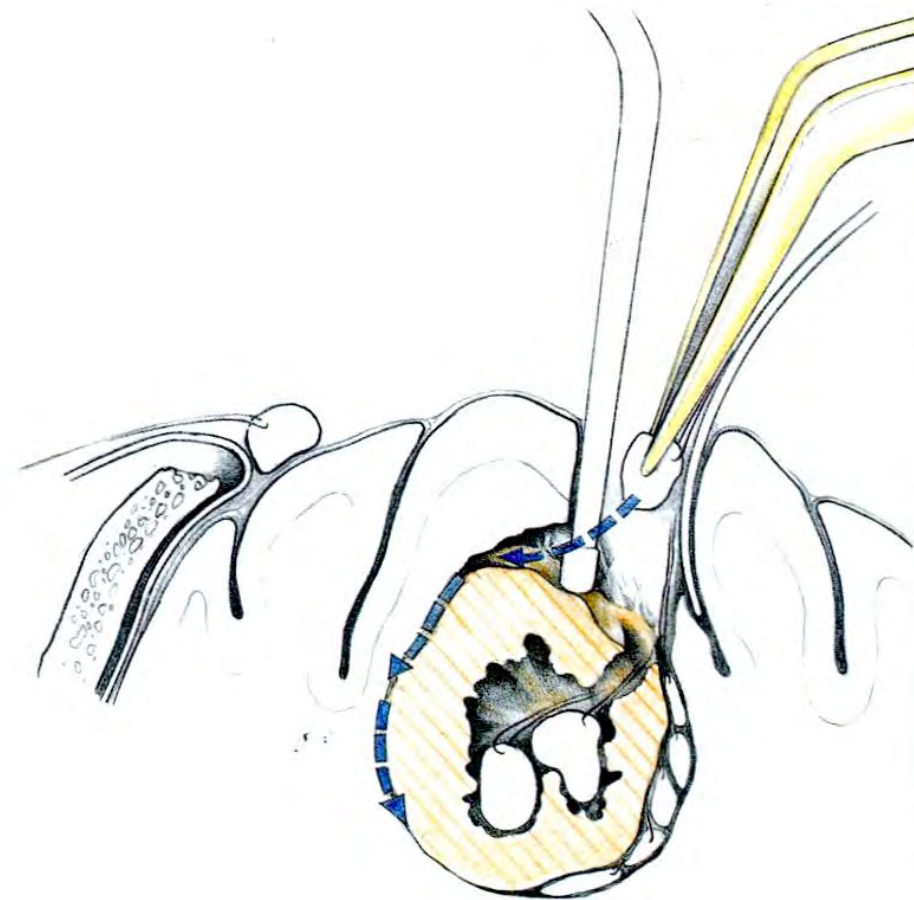
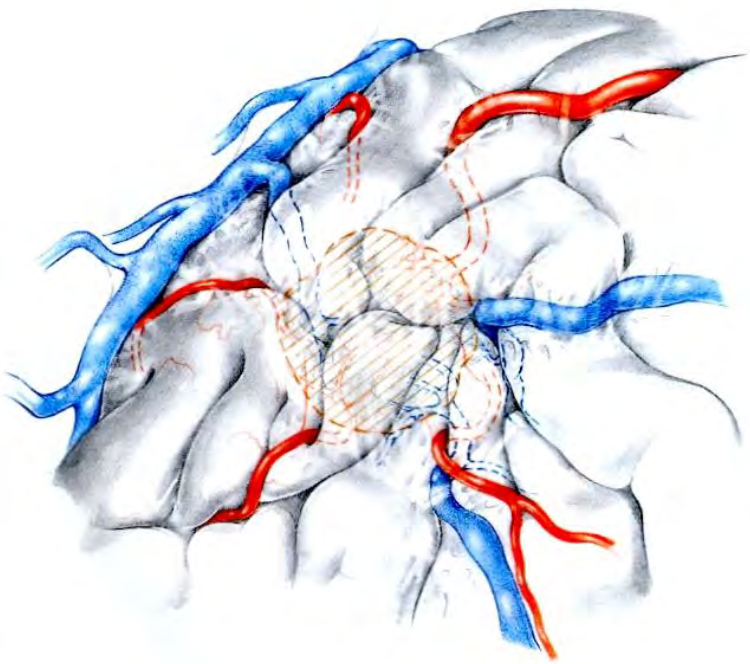


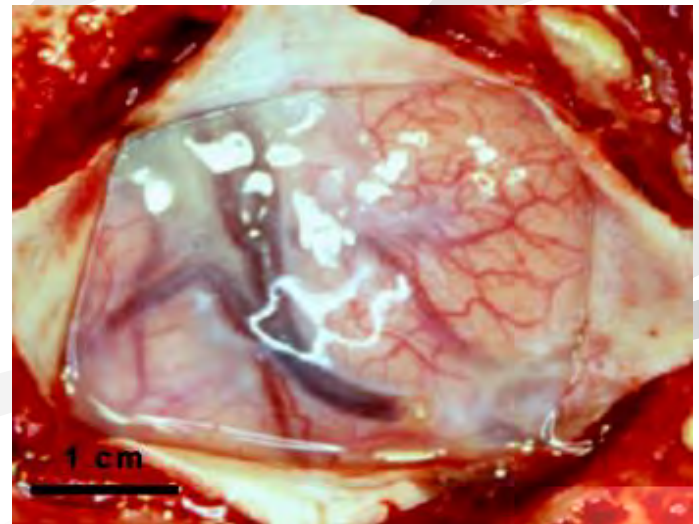
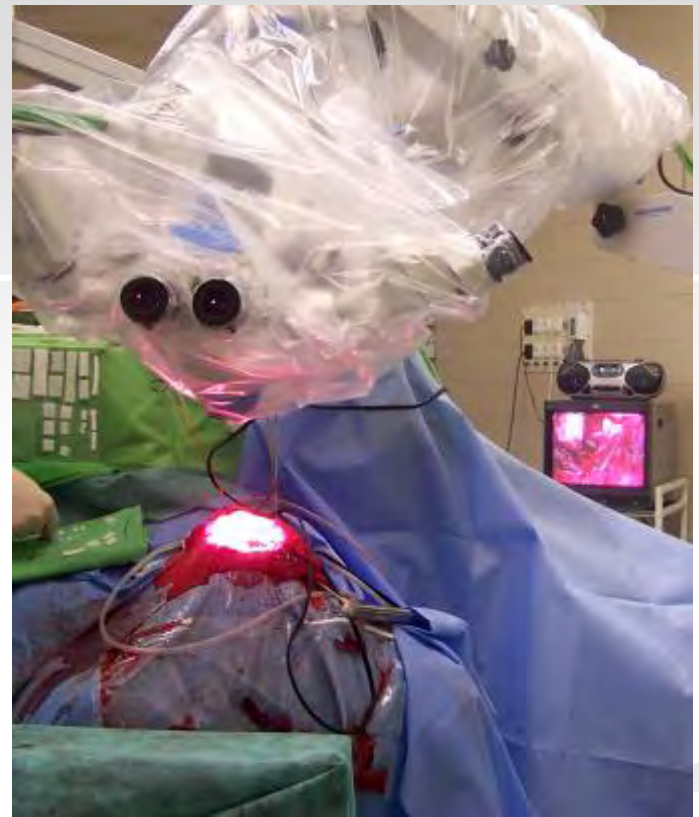
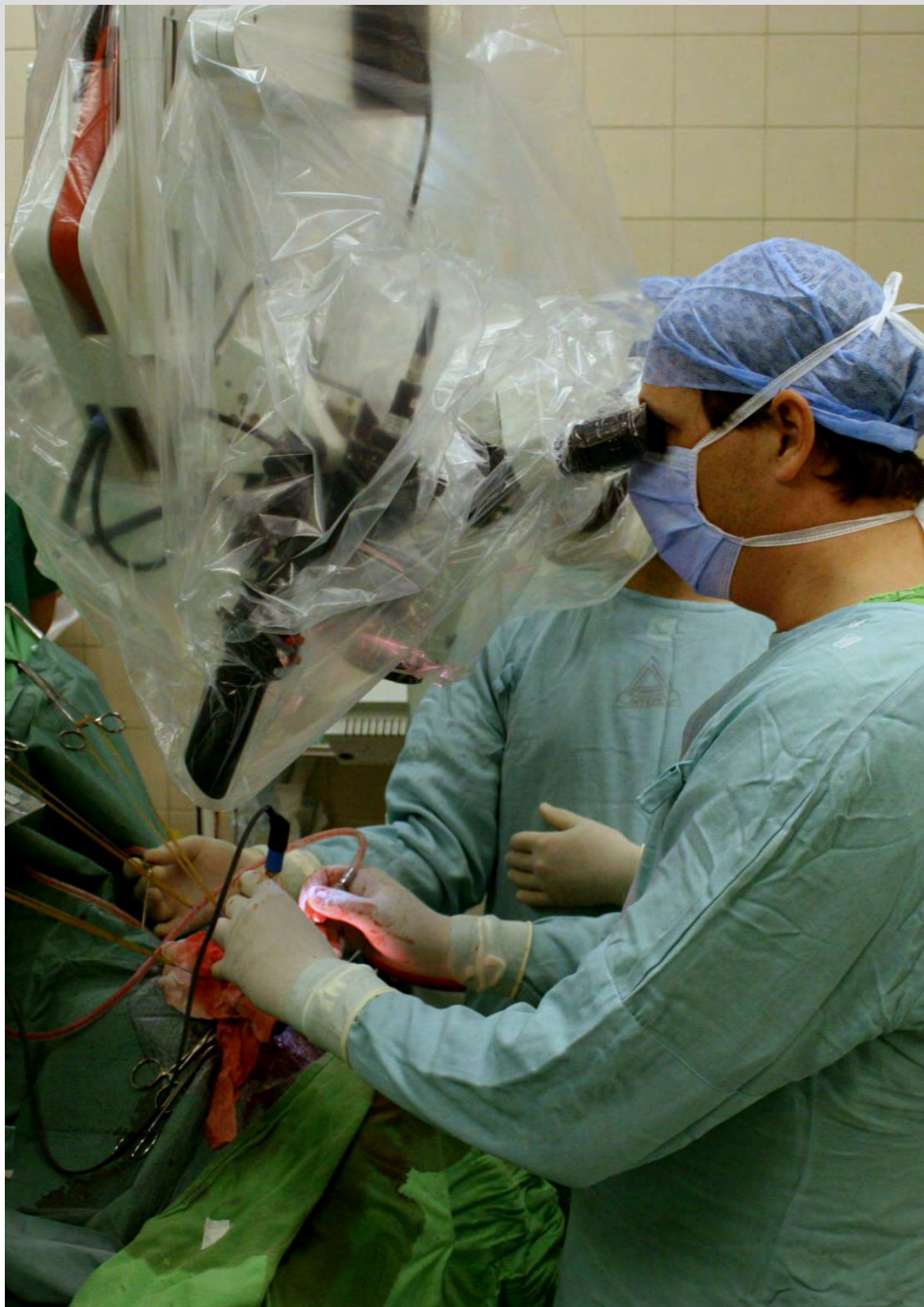b

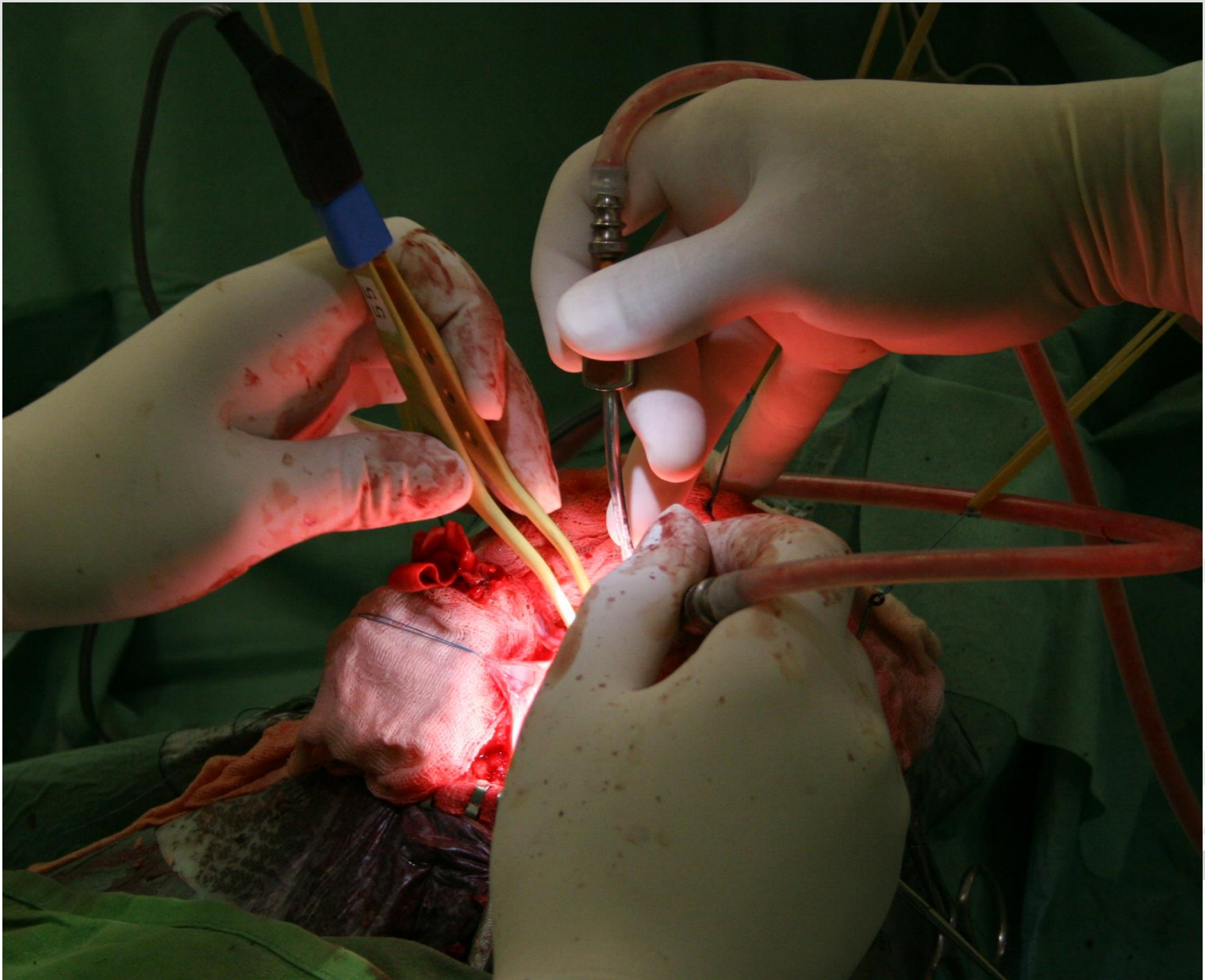


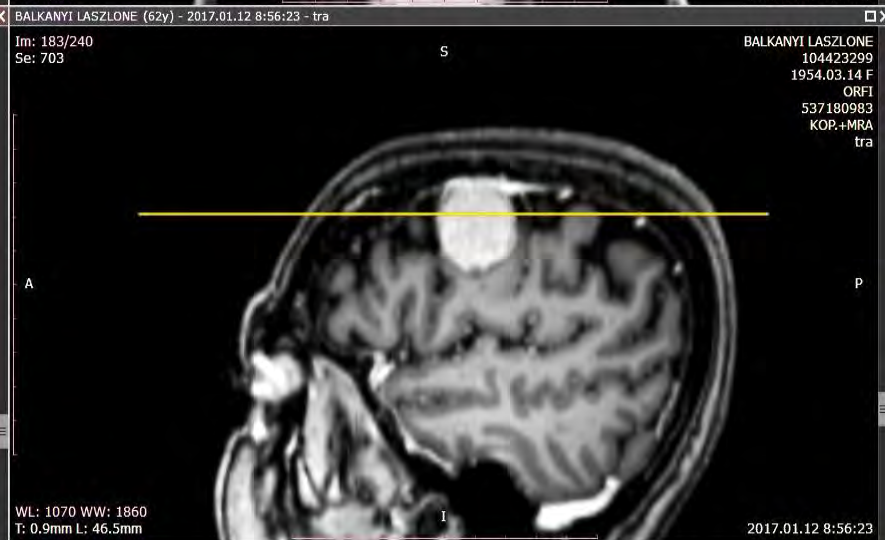
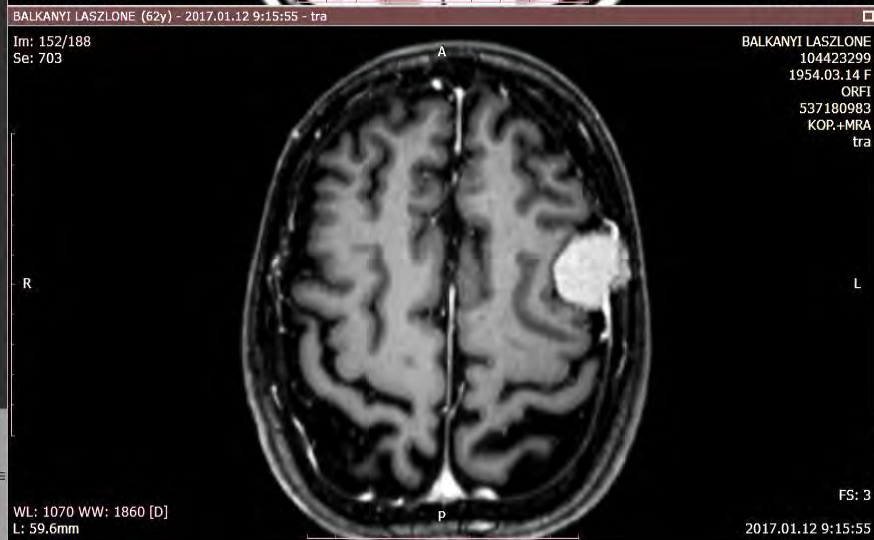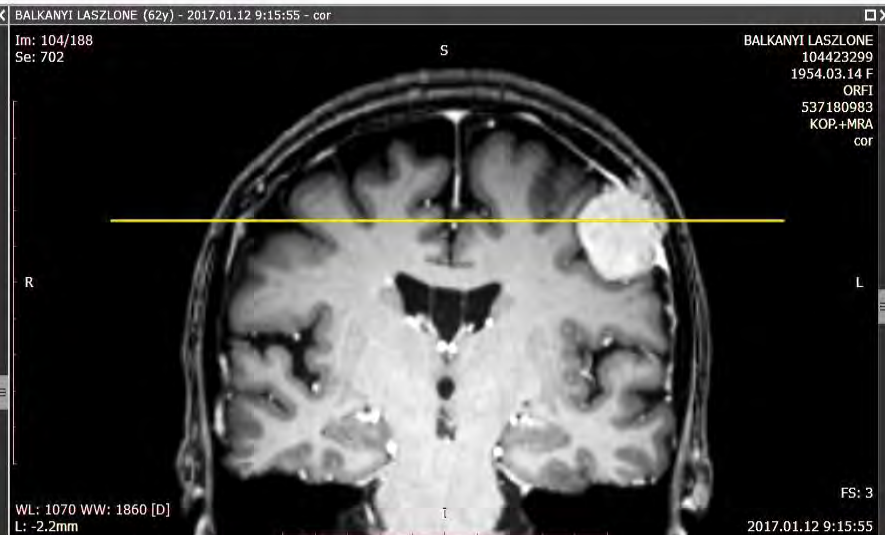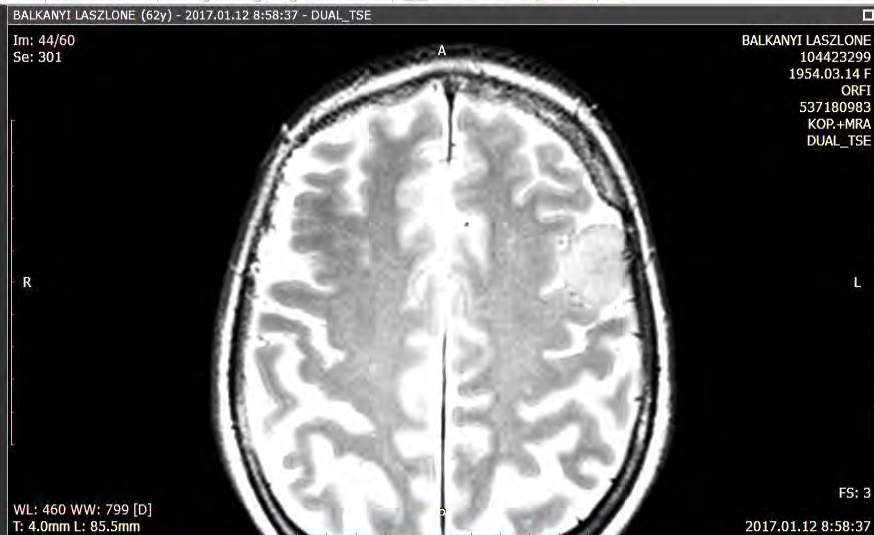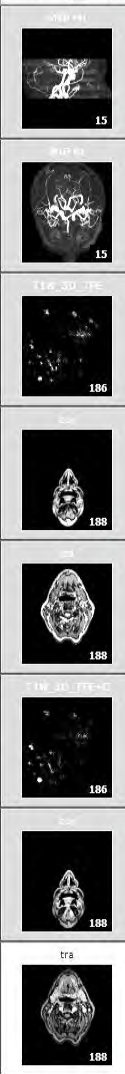c

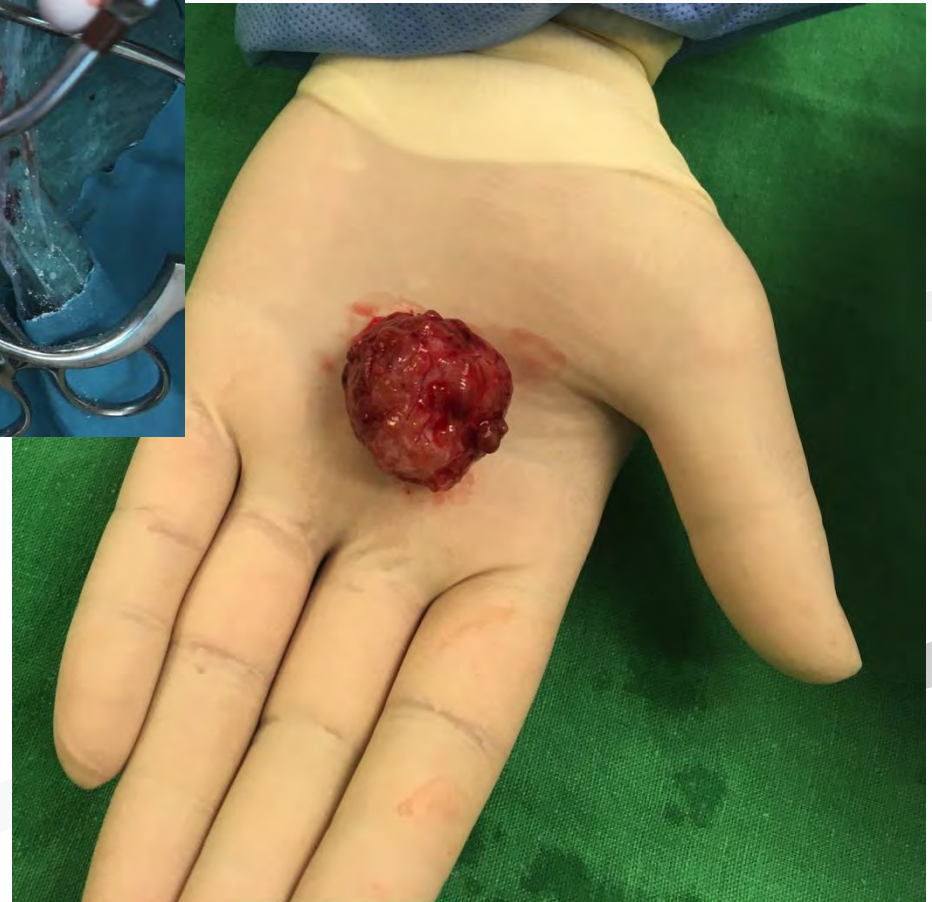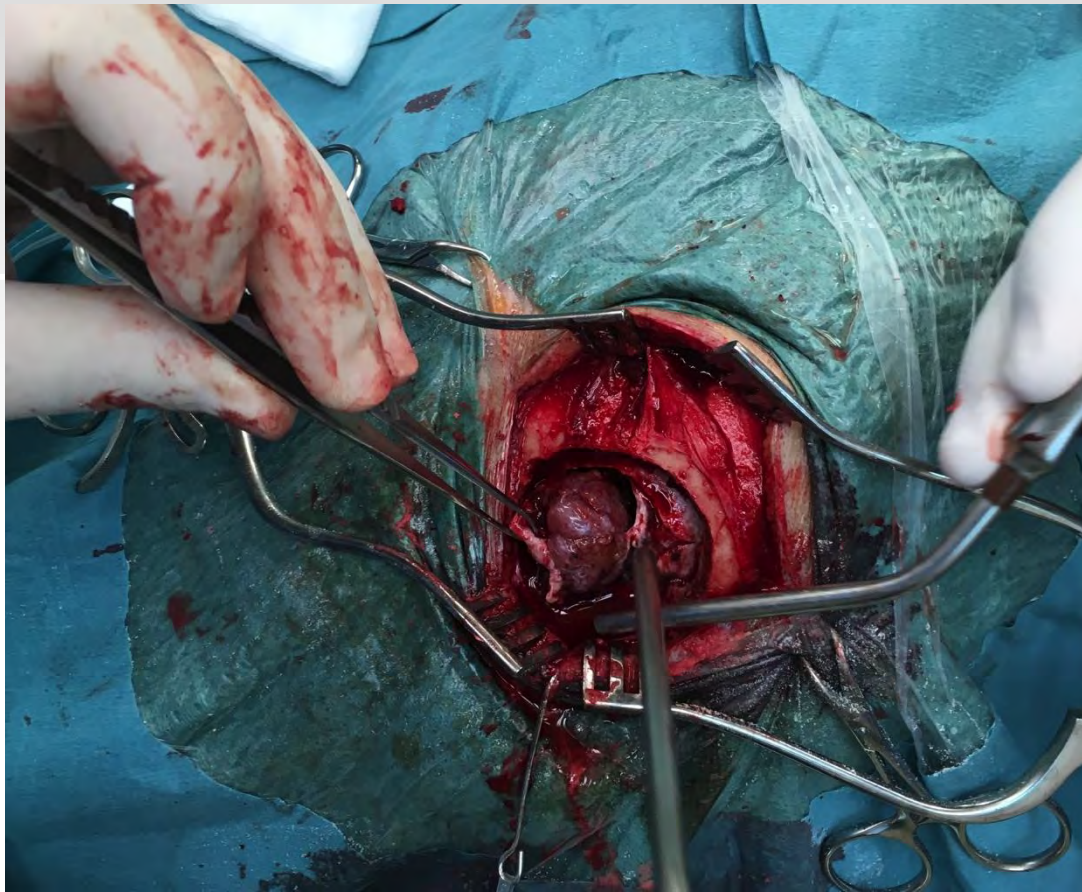


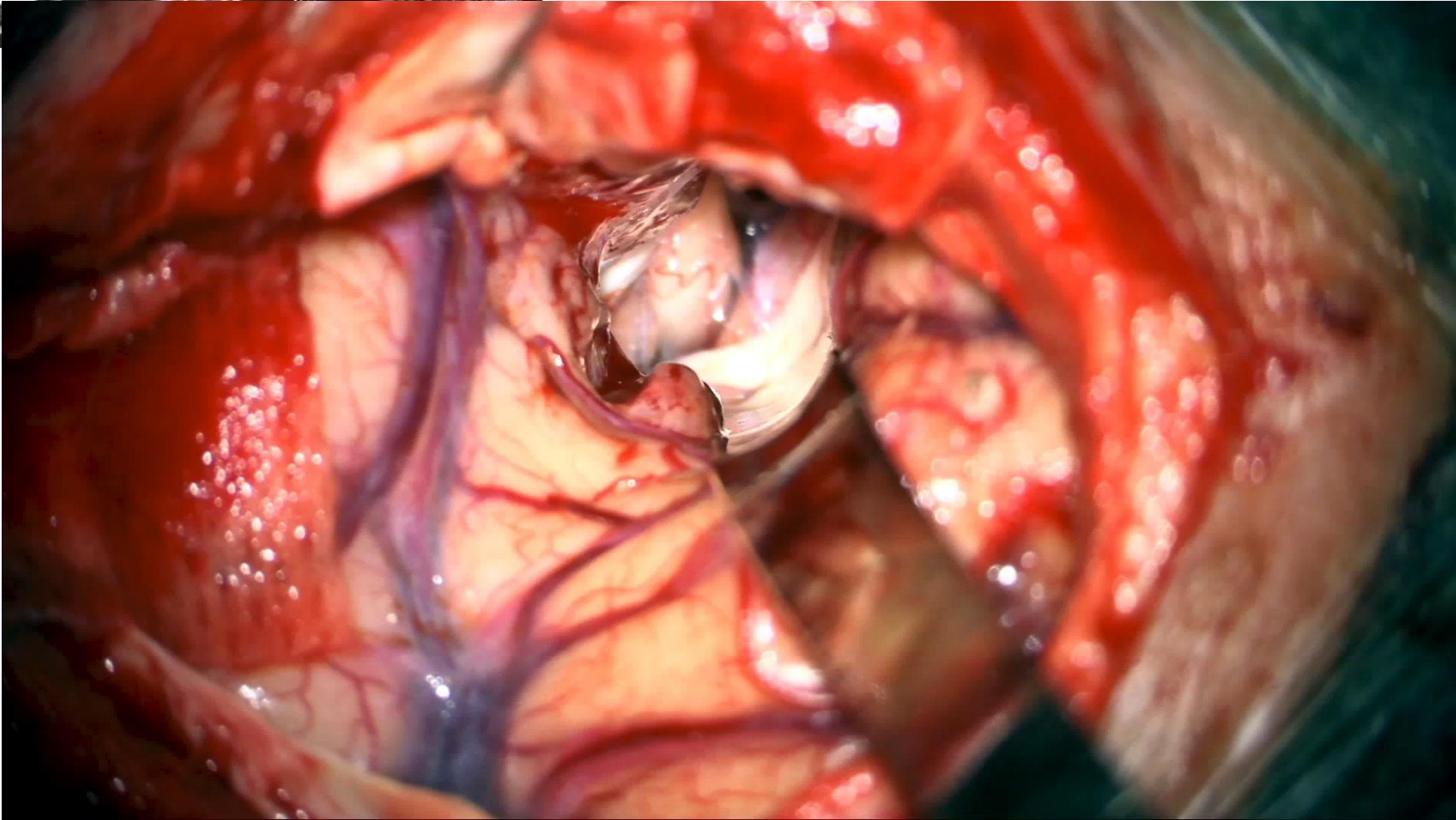
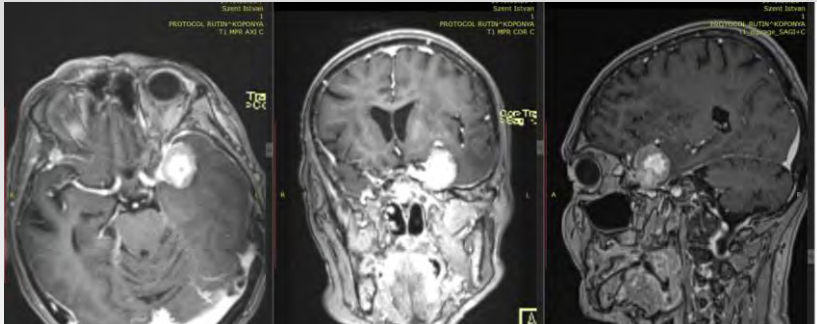


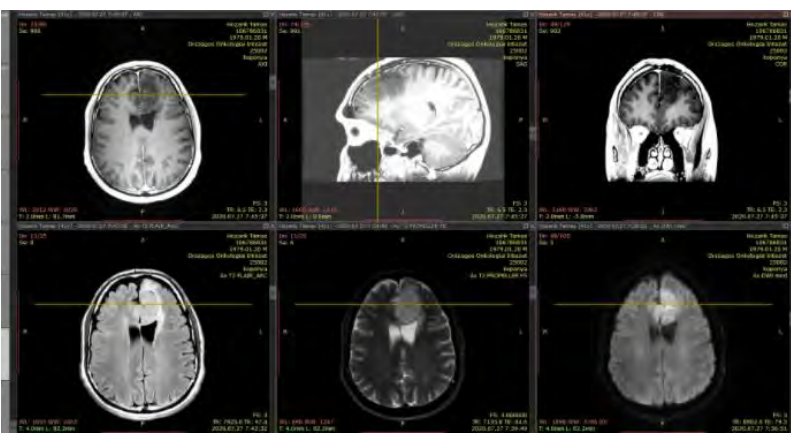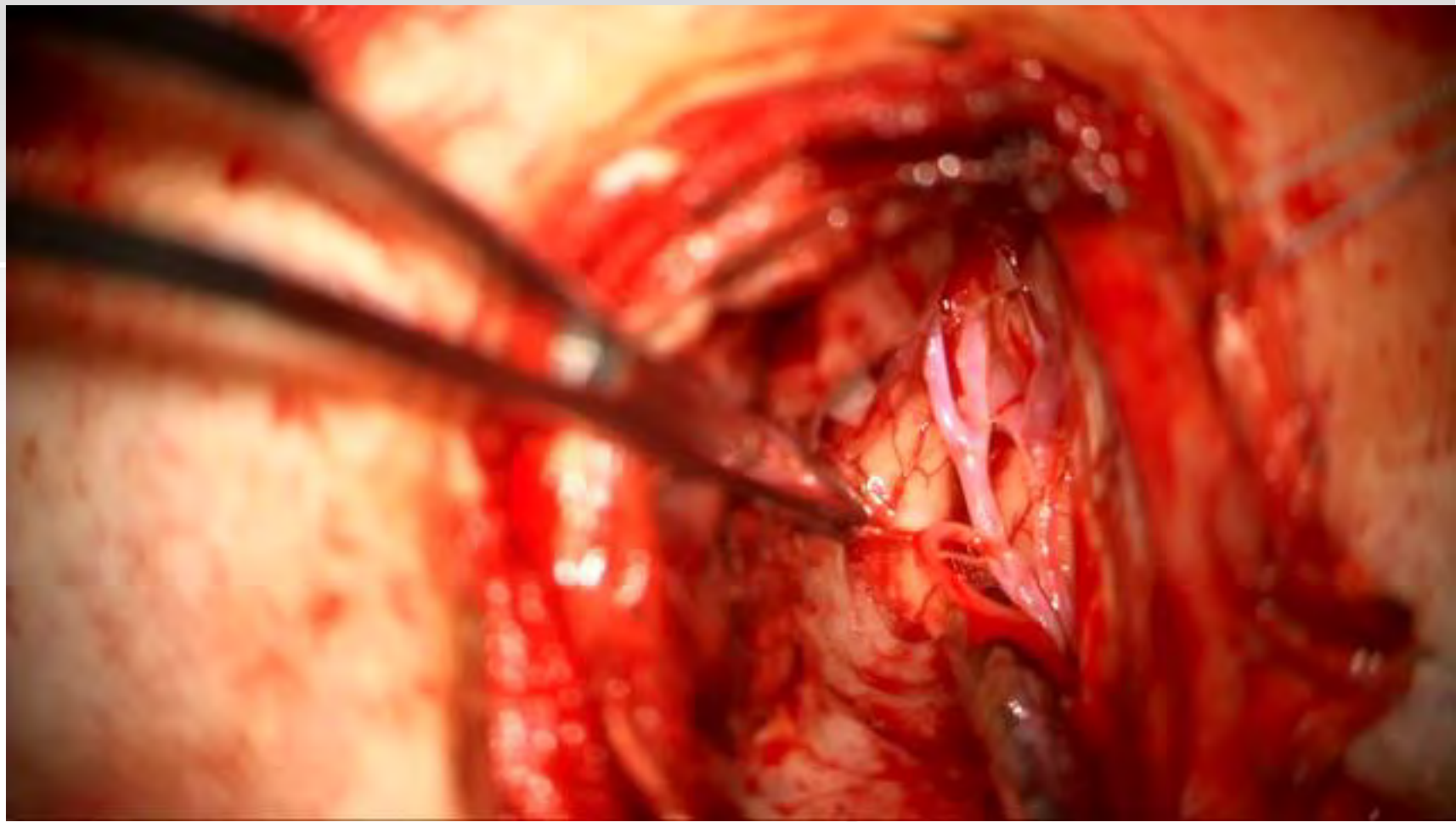








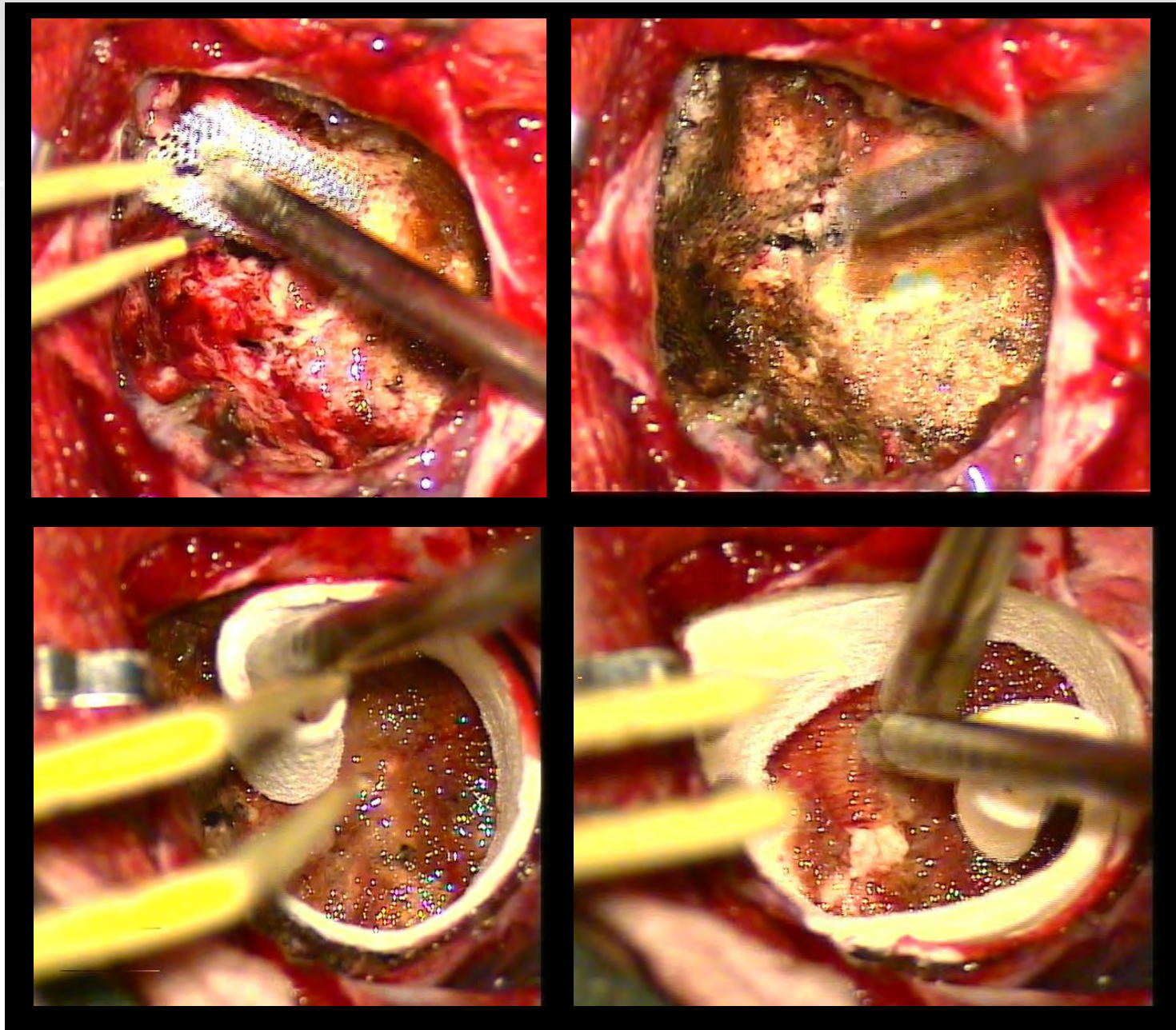




Brain tumor surgery 2.

Tumor removal

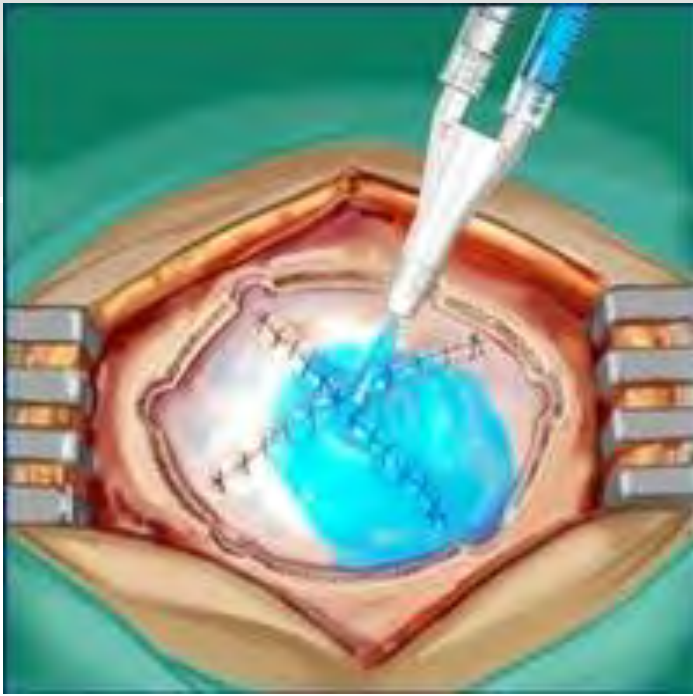
- cortical incision (deep seated tumors)
- tumor – internal decompression
- devascularization
- preparation of brain tumor – interface
- tumor removal
- hemostasis

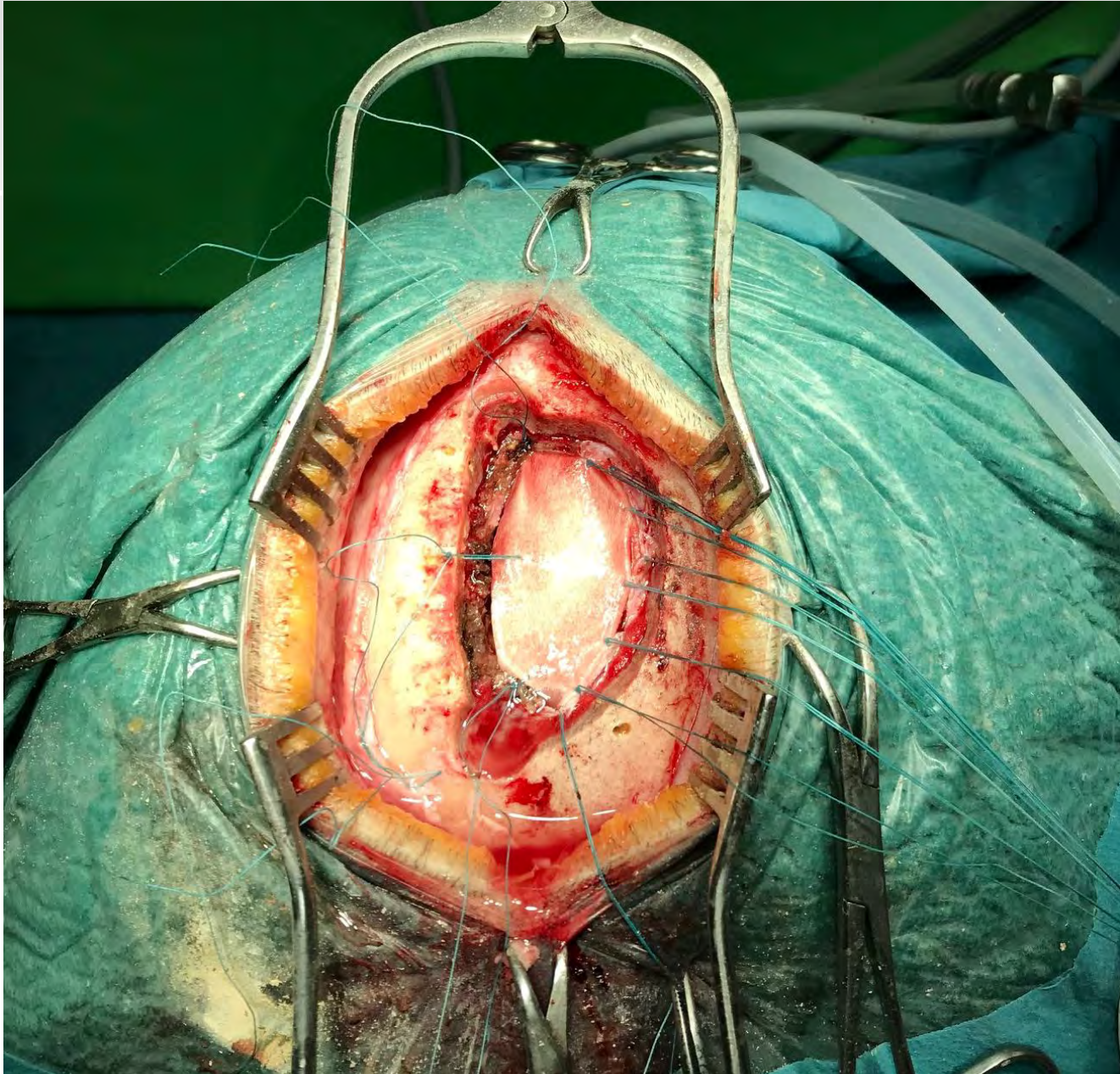


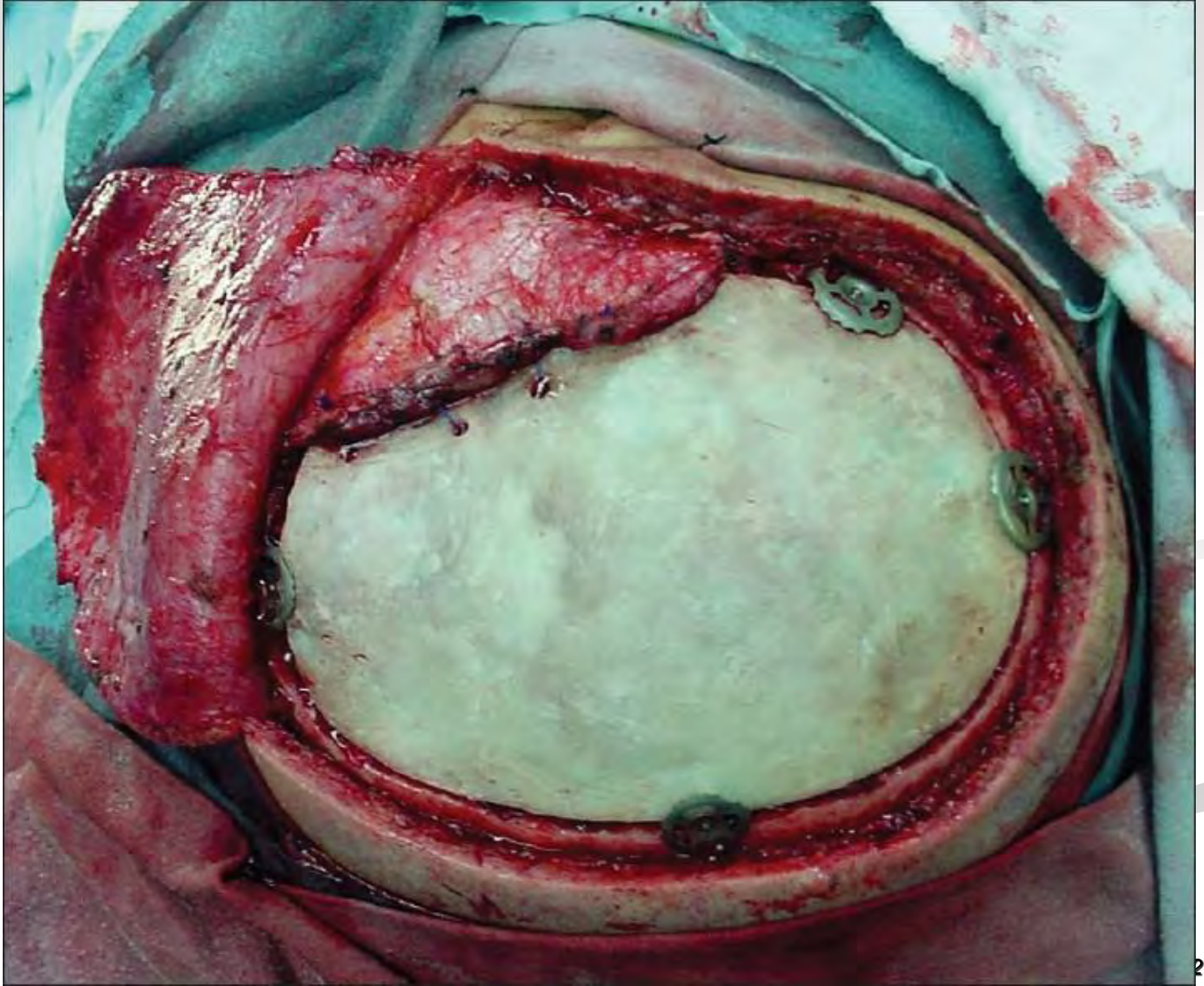
Brain tumor surgery 3.

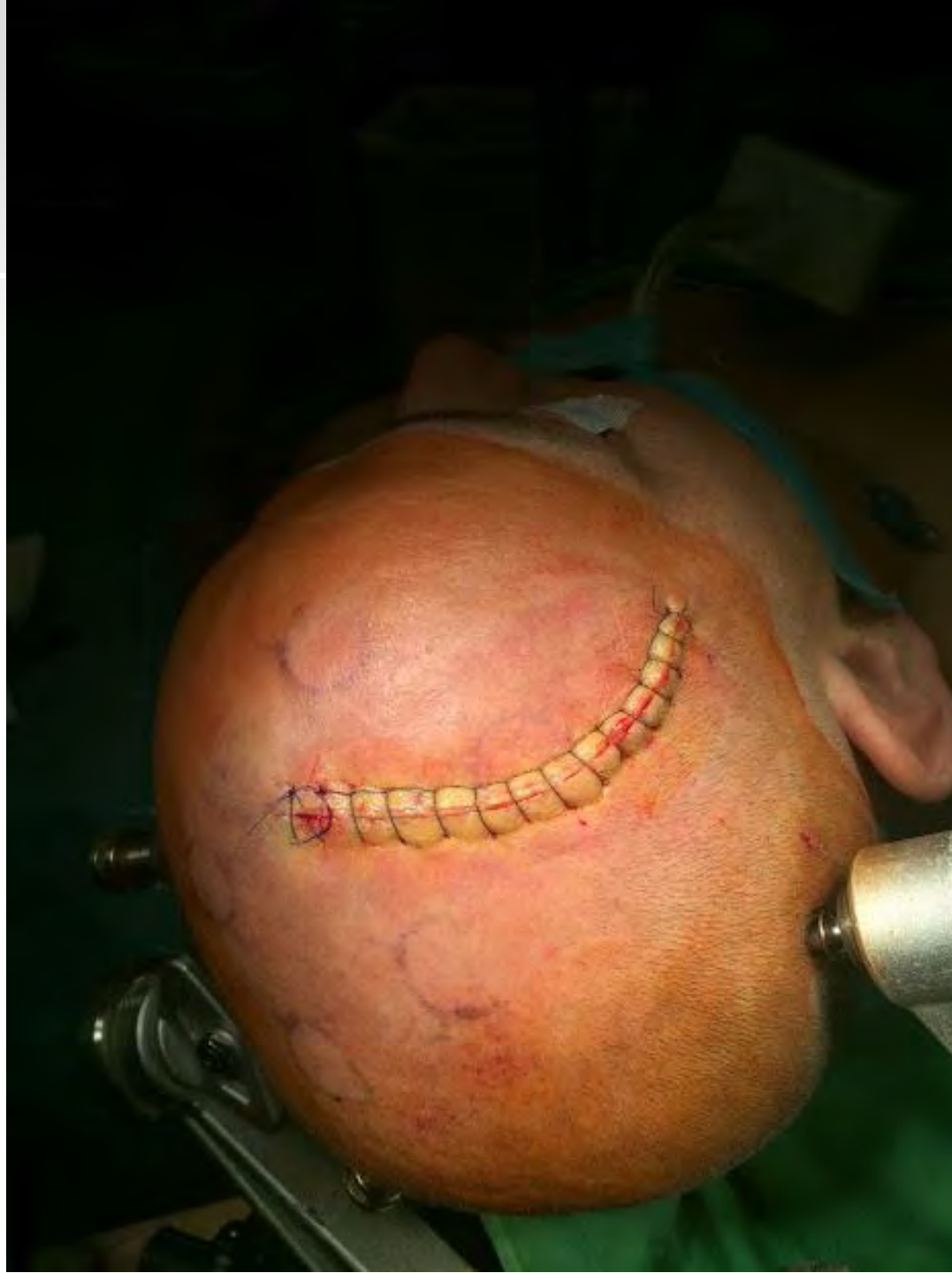Closure

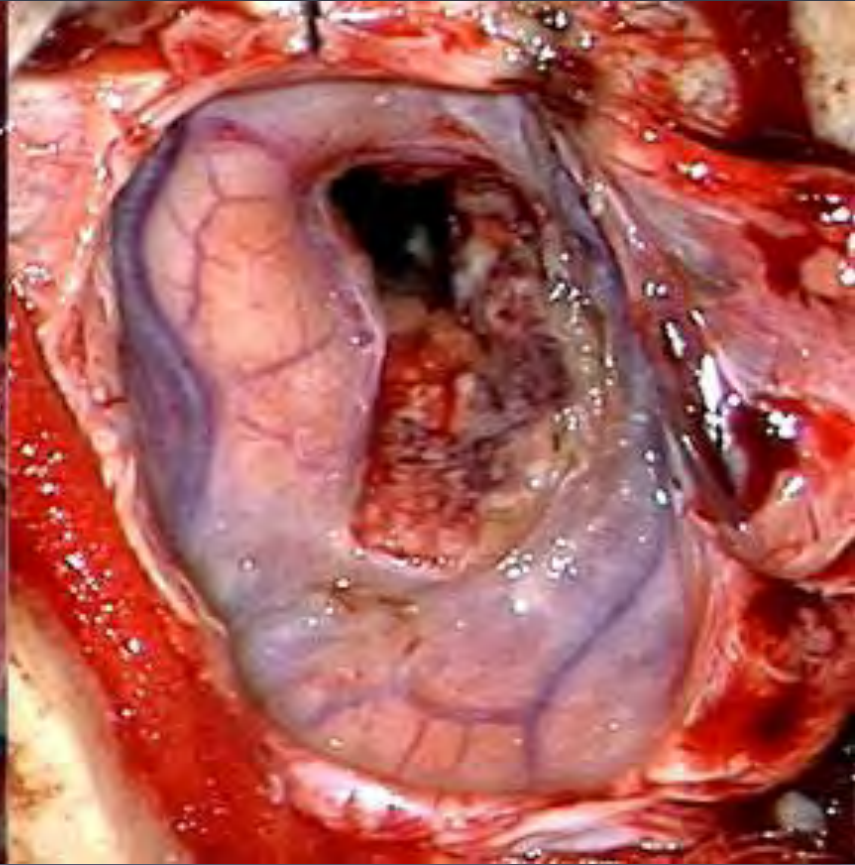
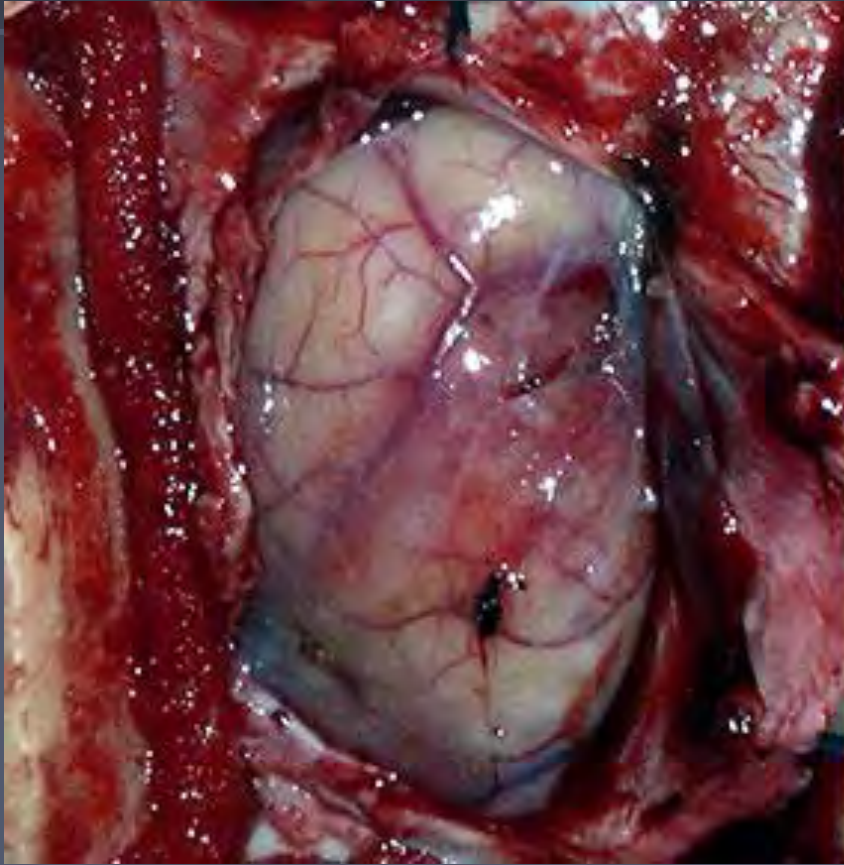
- Dural closing stitches
- Dura covering (Gelfoam, Tachosil, Durasil)
- Dural tentigt stiches – prevent epidural hematoma
- Duraplasty
- Bone flap – stitches or miniplate
- In case of craniotomy cranioplasty (Cemex)
- Perisoteal, galea and skin sutures

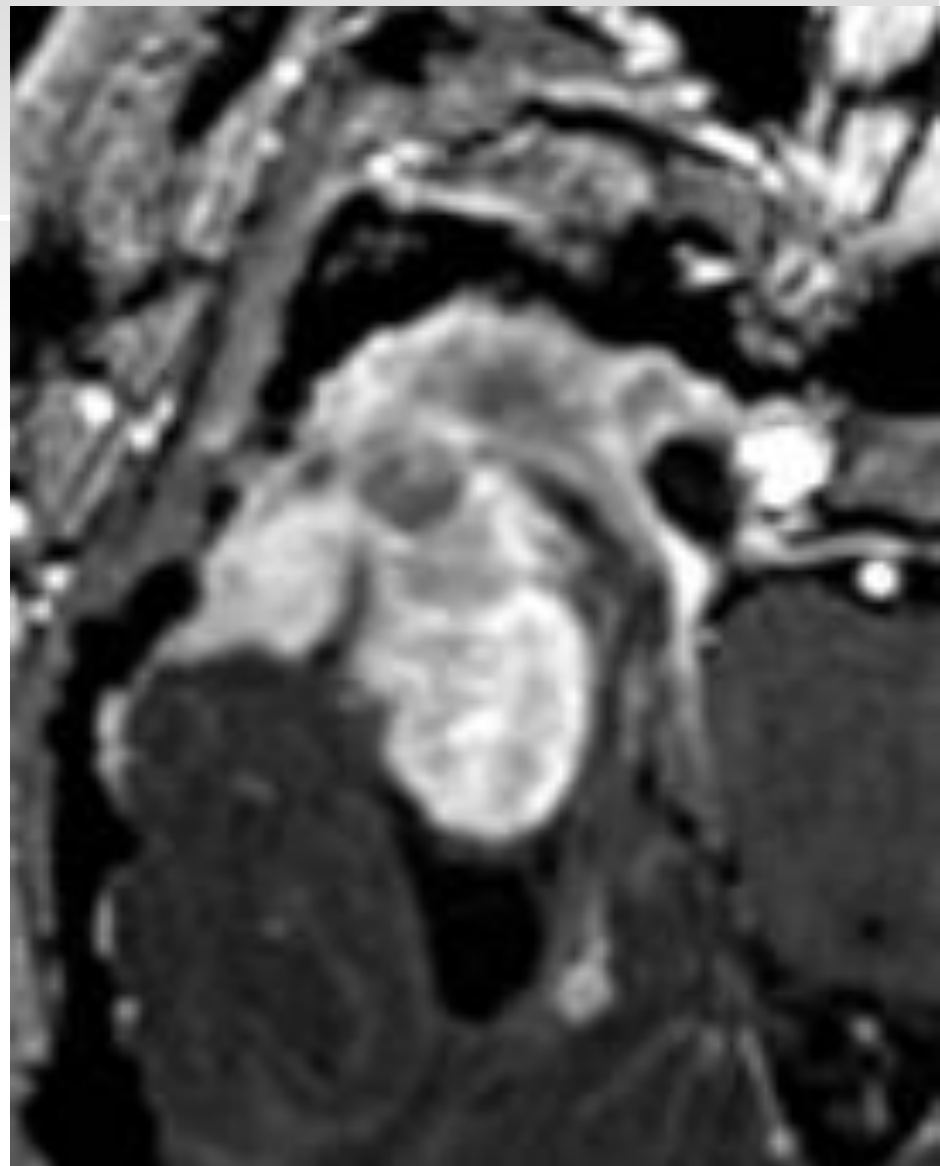
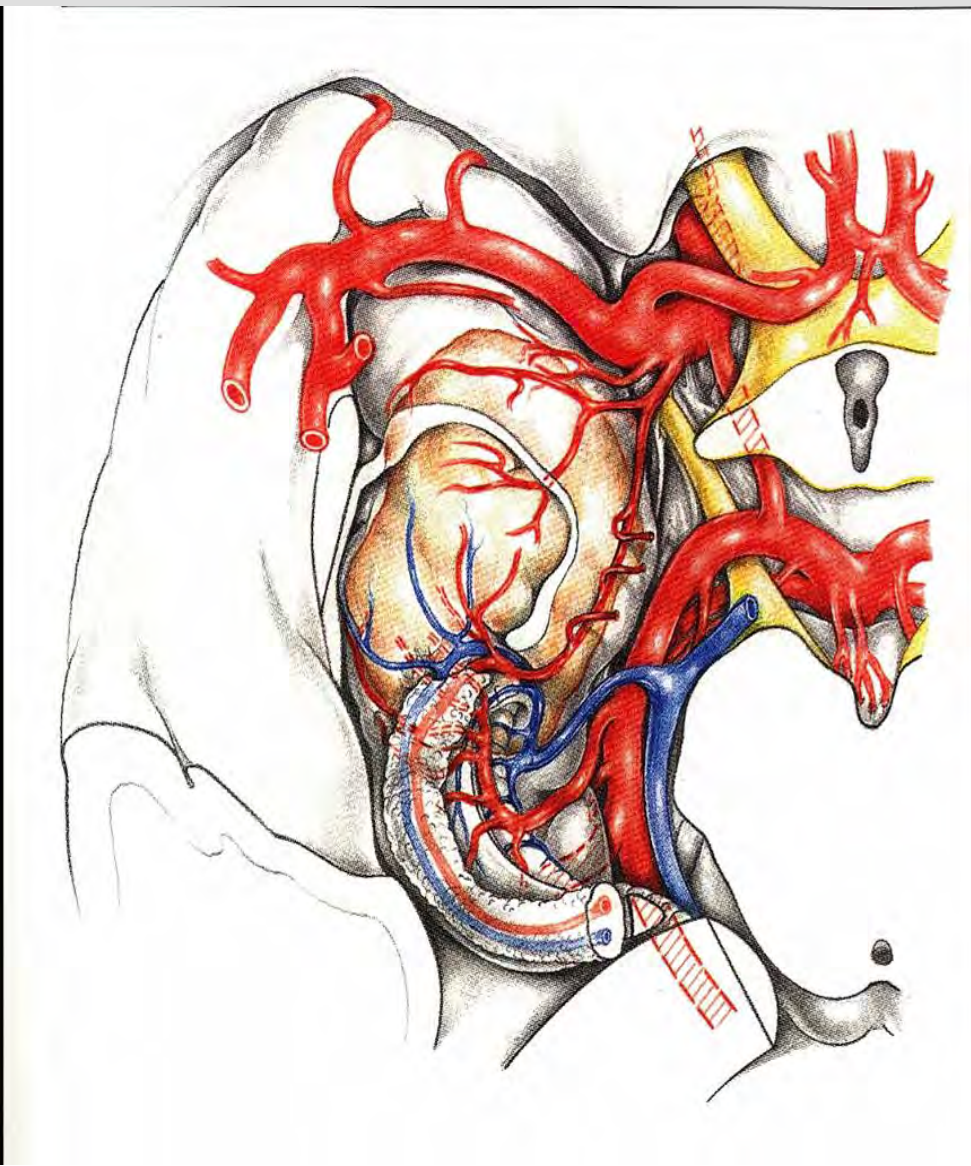




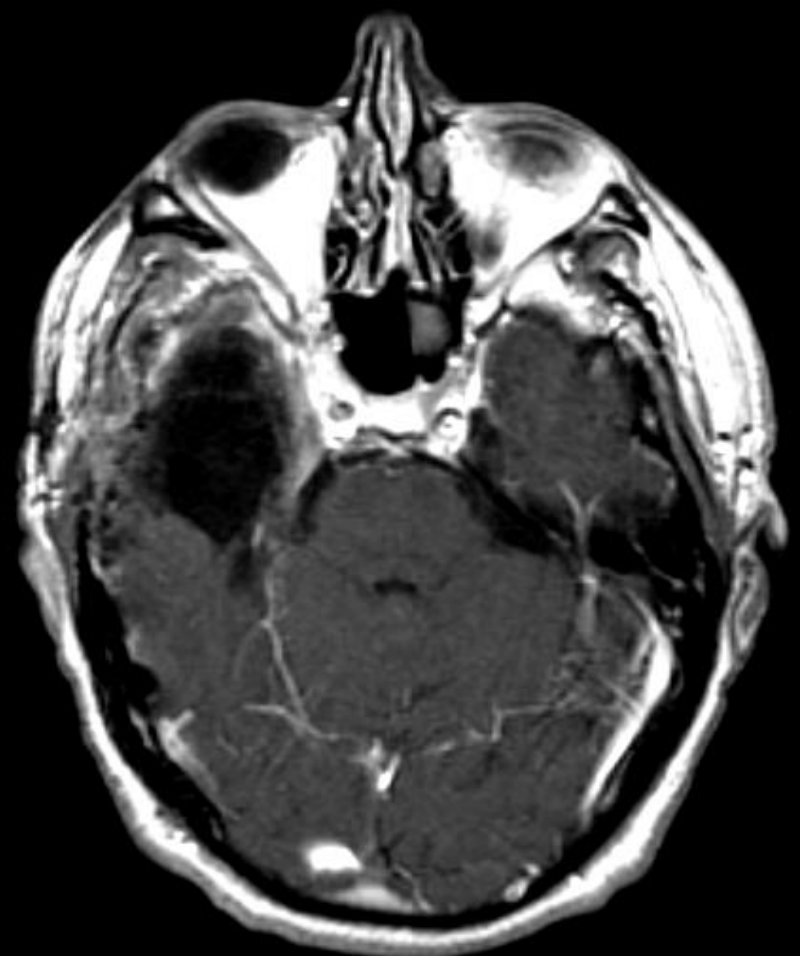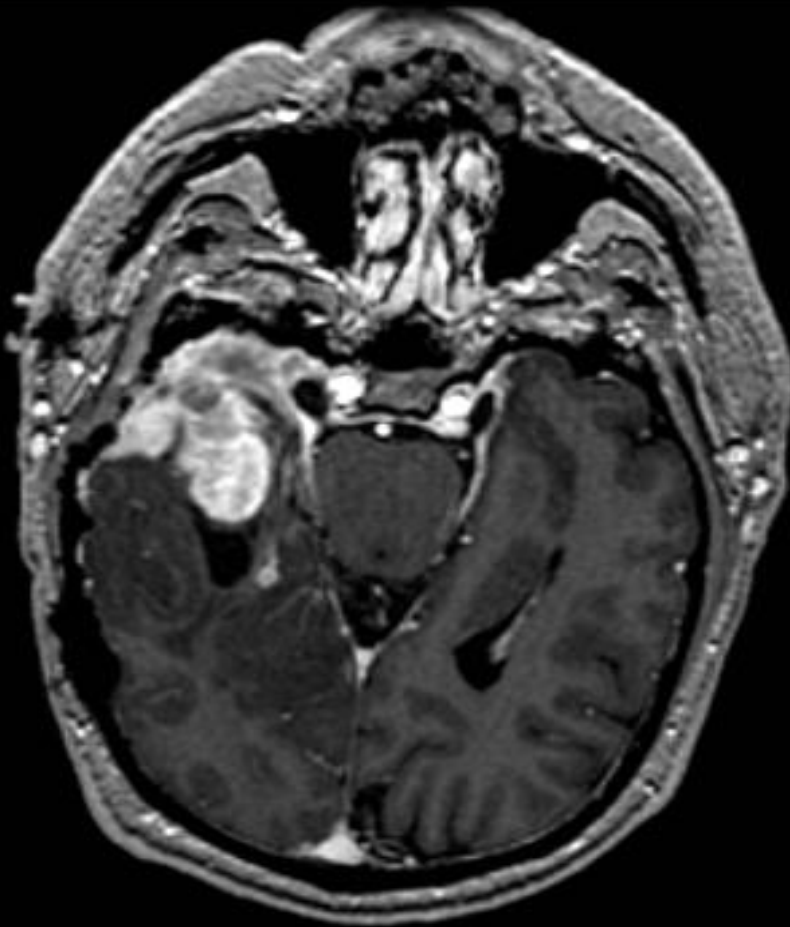




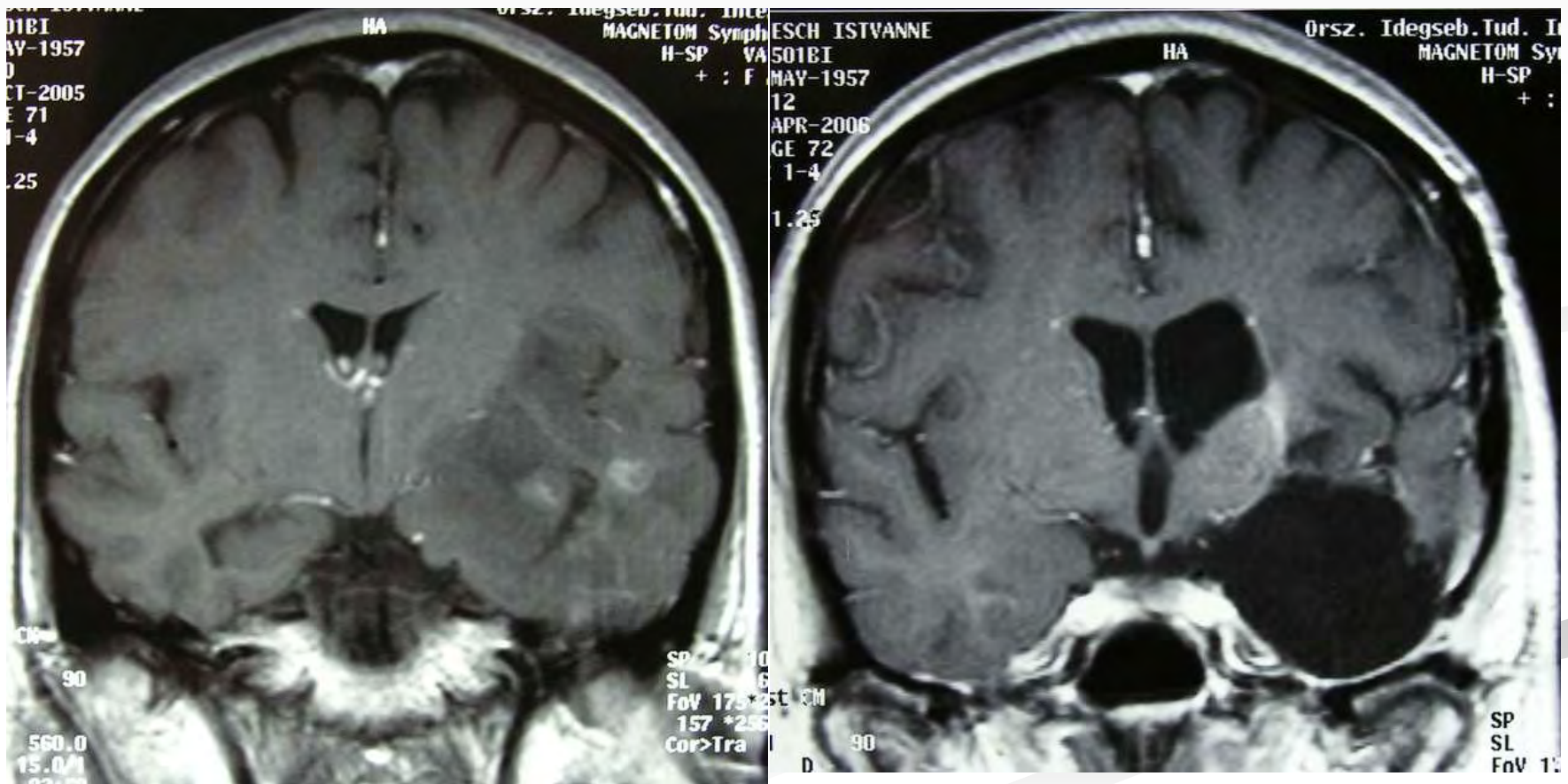




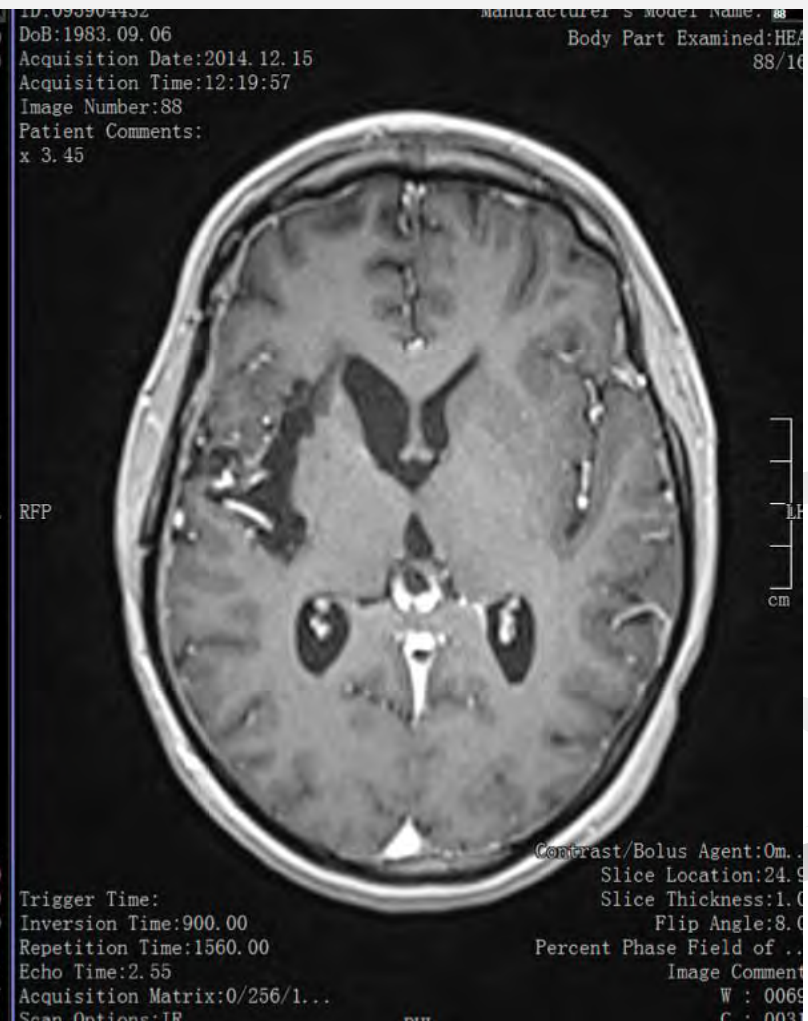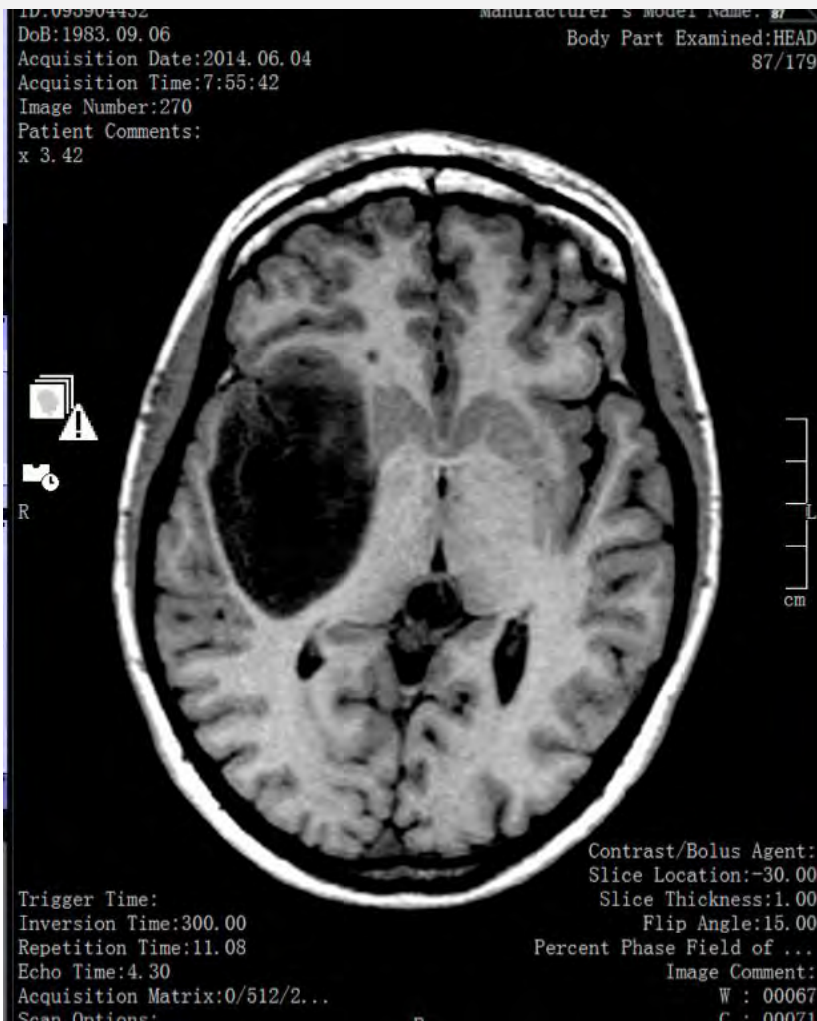glioblastoma



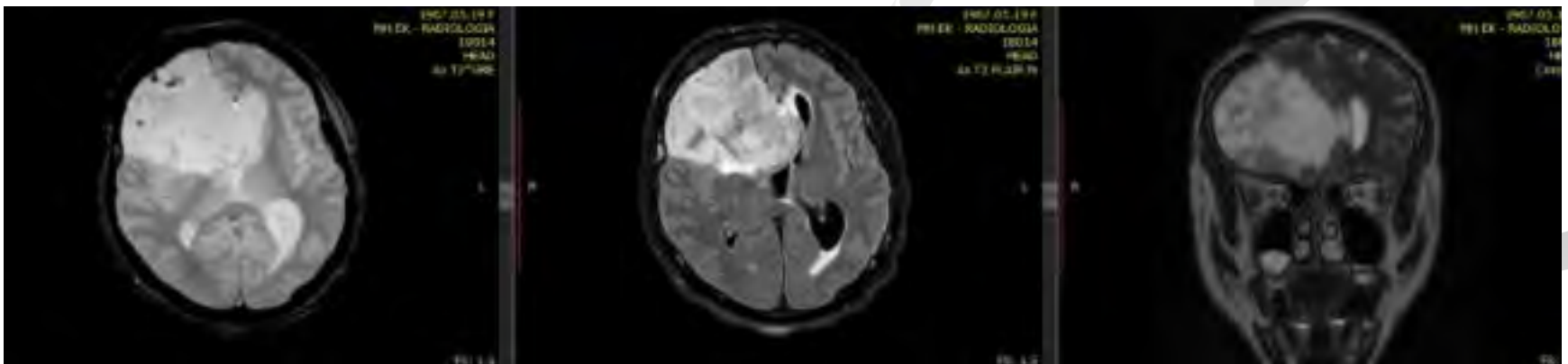
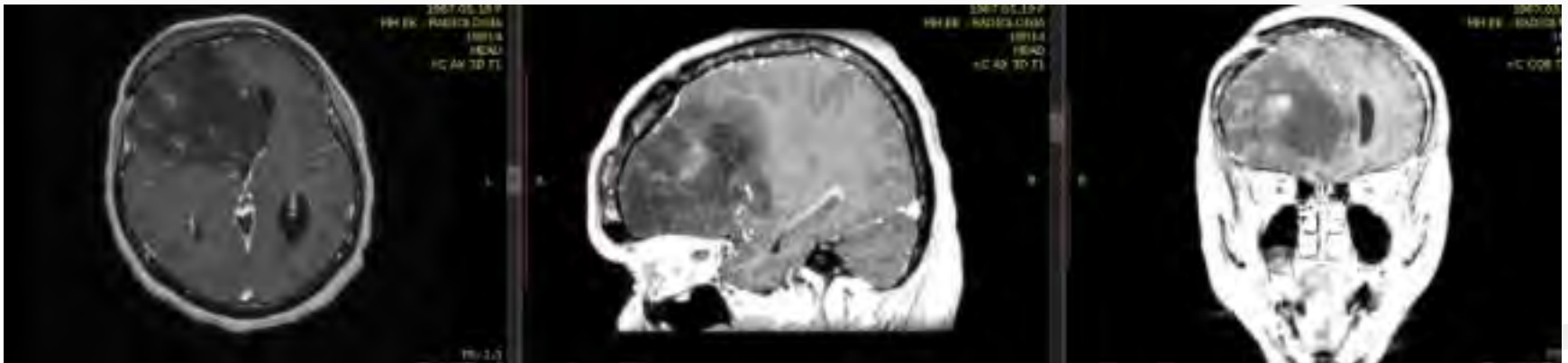
low grade glioma



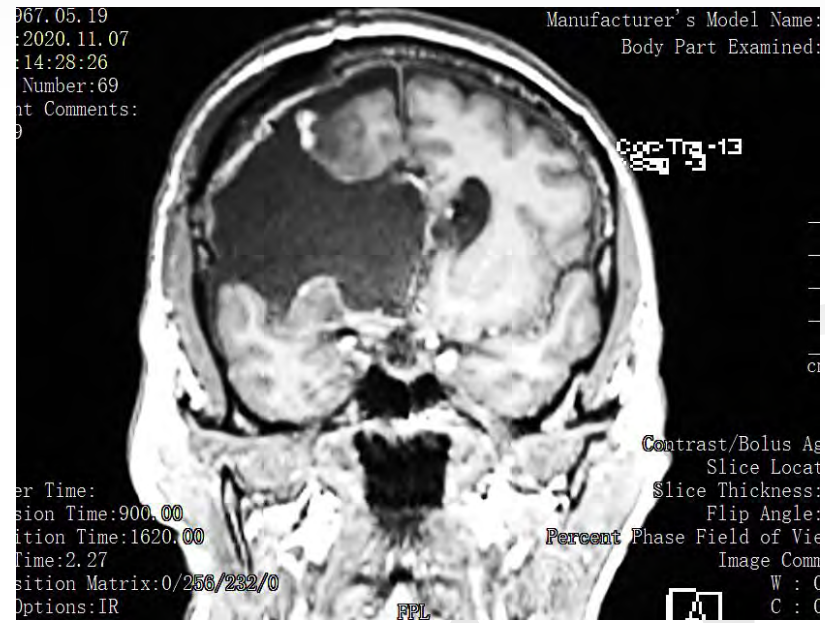
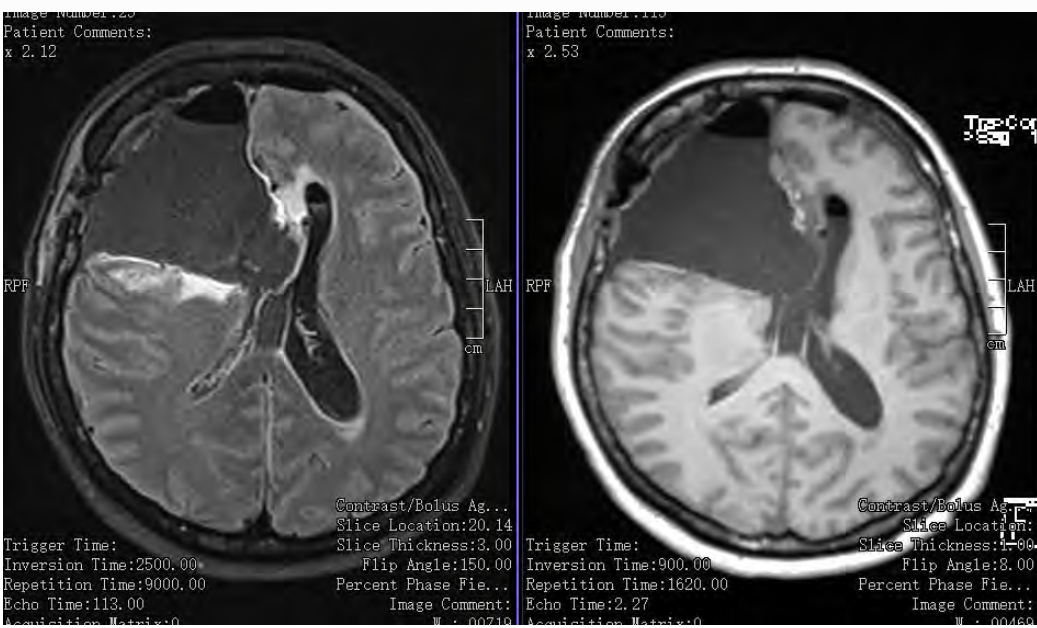
low grade glioma



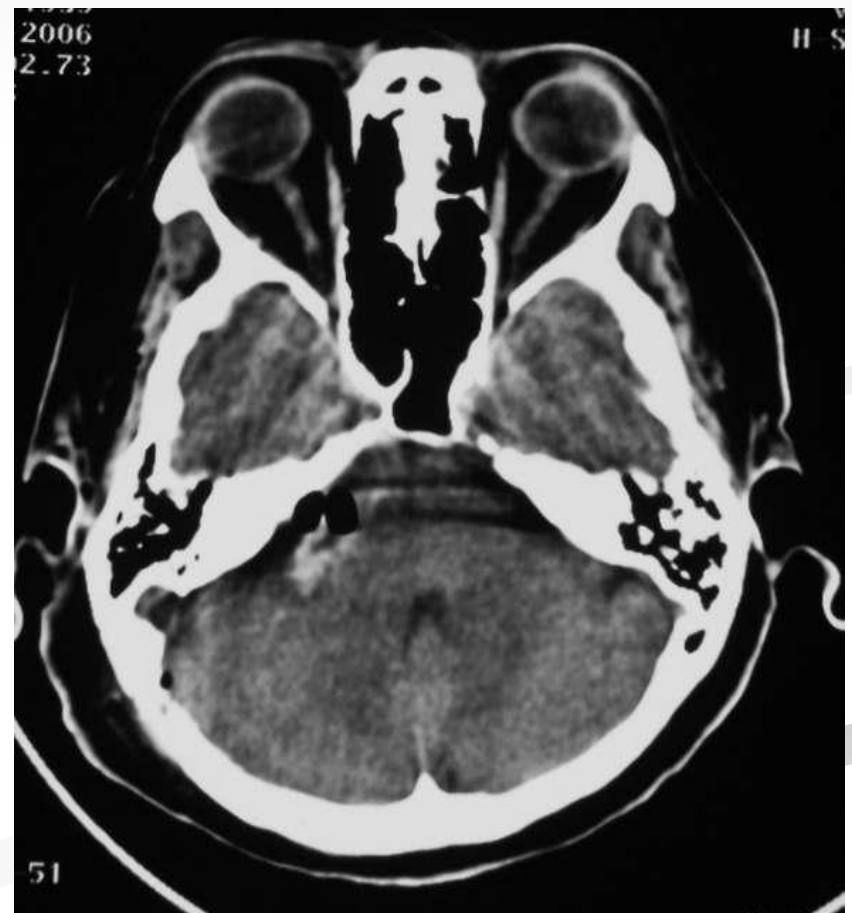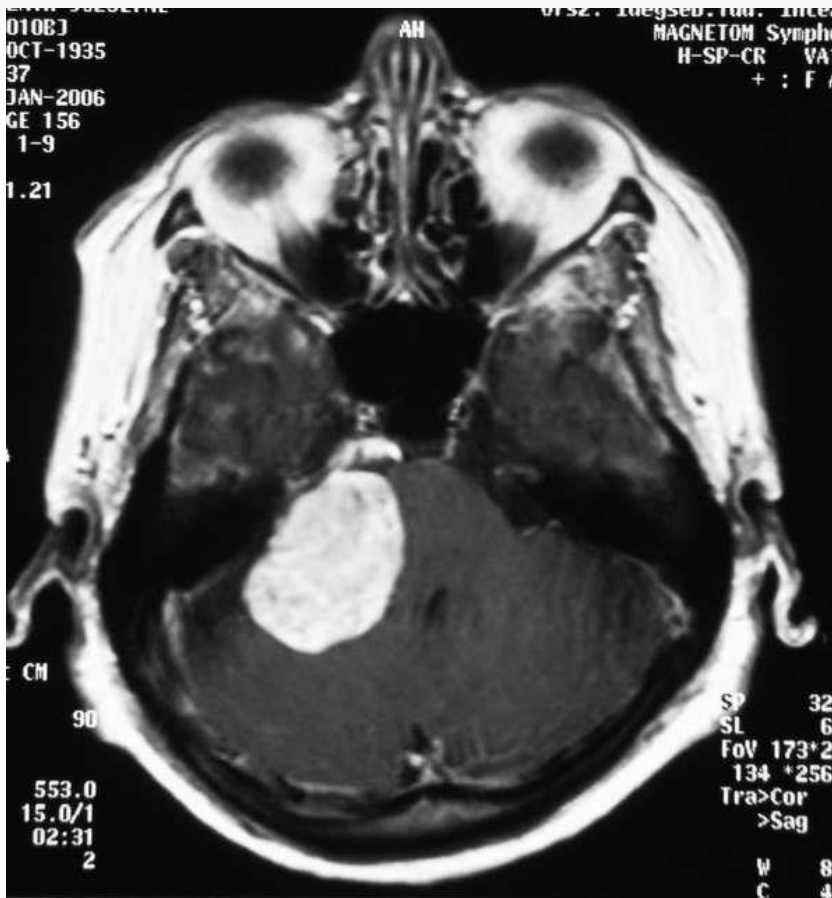Recurrent high grade glioma (A3 >> GBM)



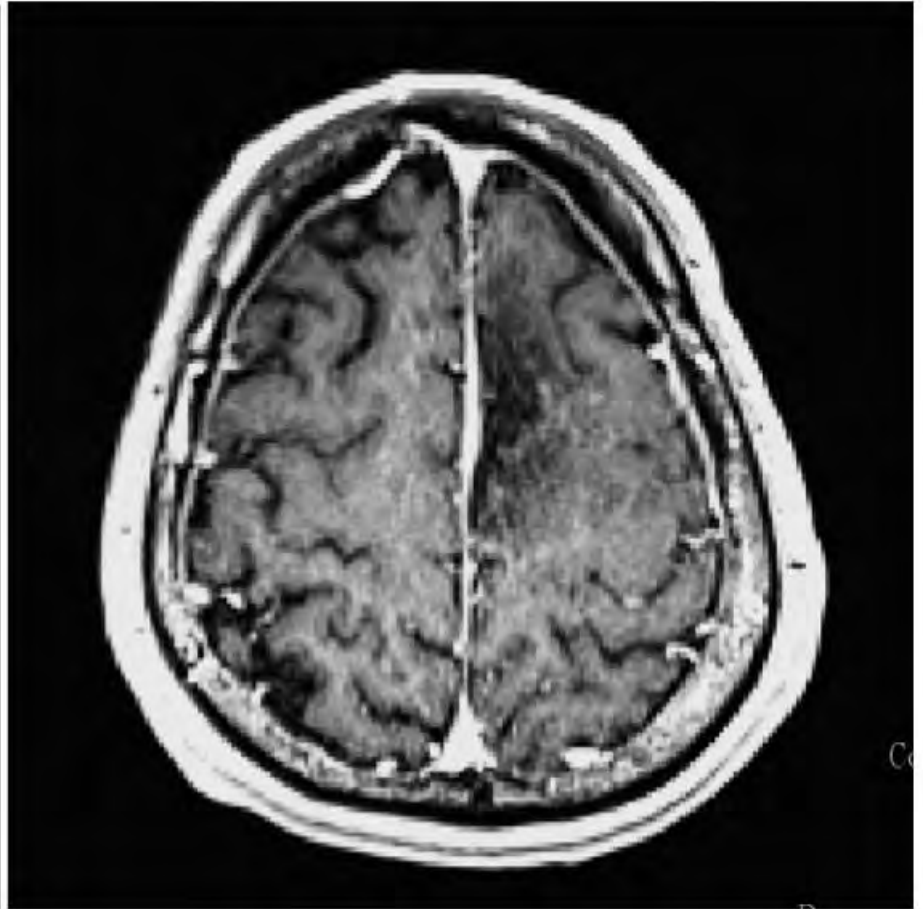
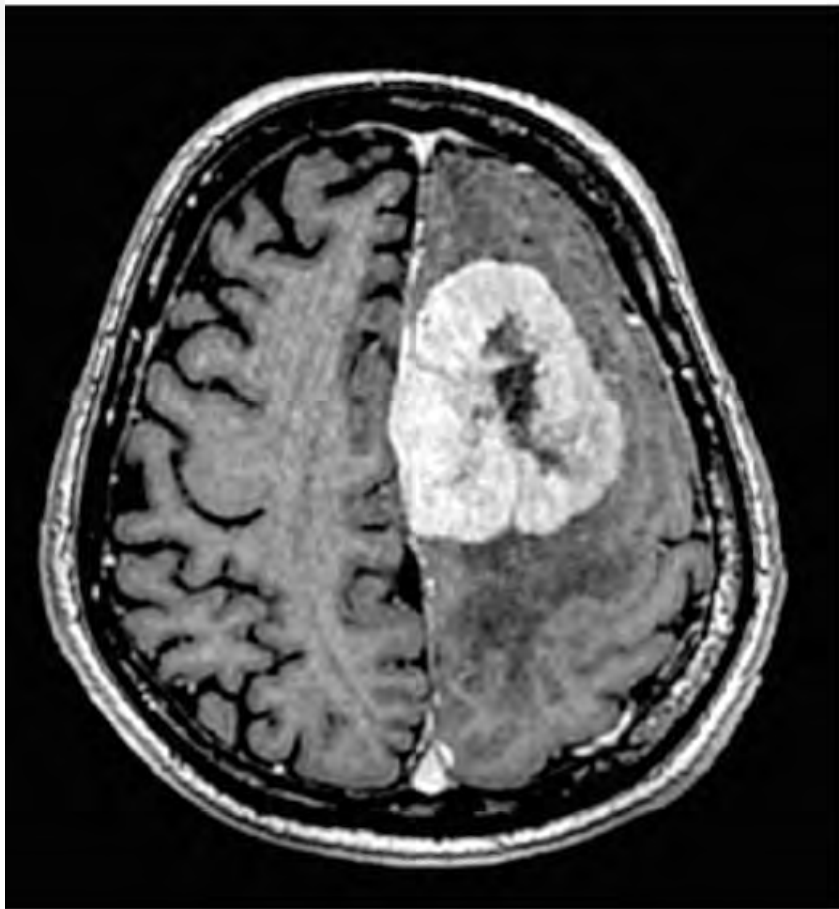
recidiv glioma (A3 >> GBM)




vestibular schwannoma

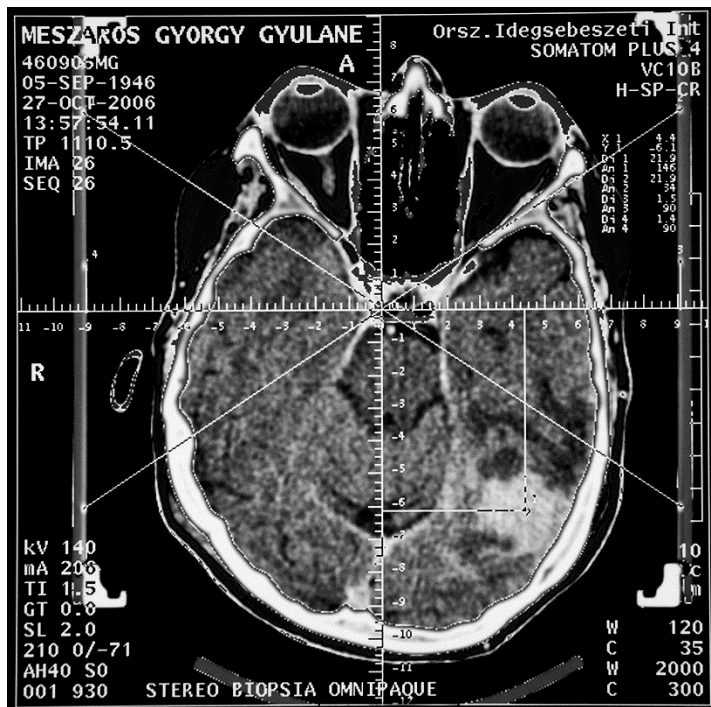
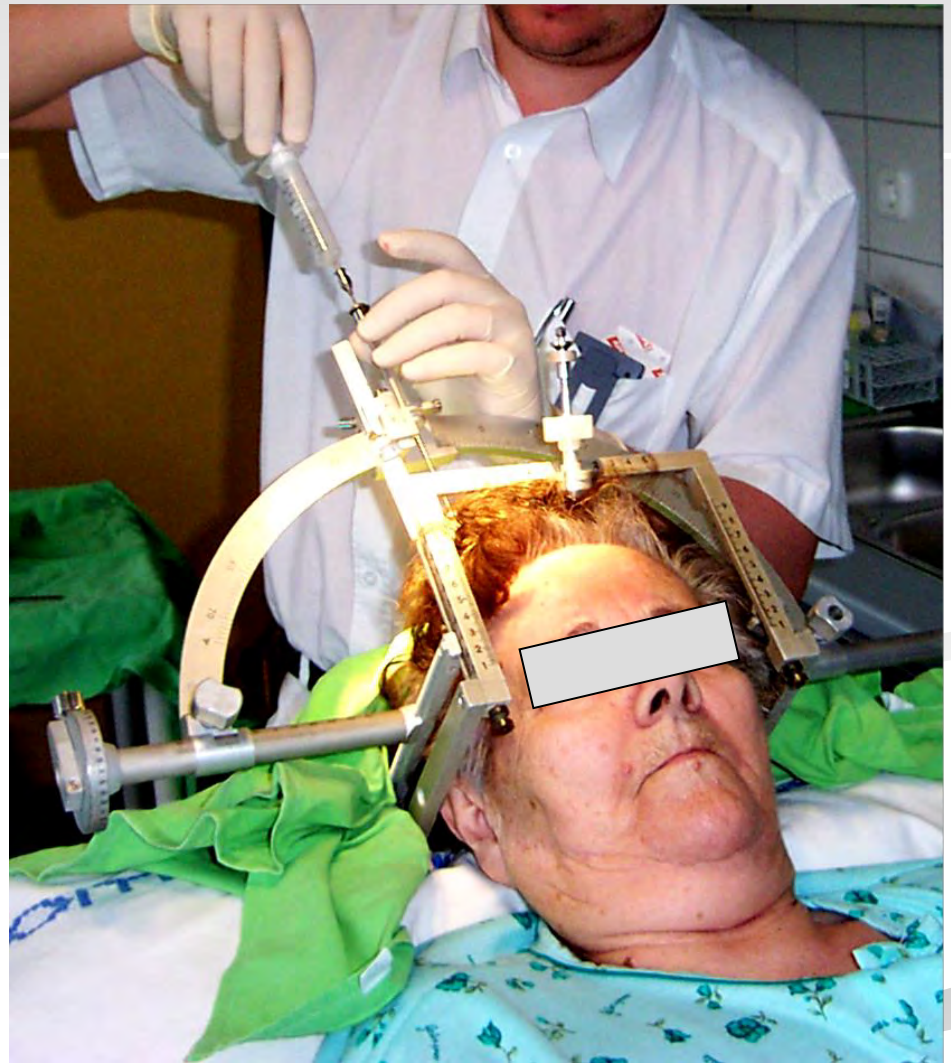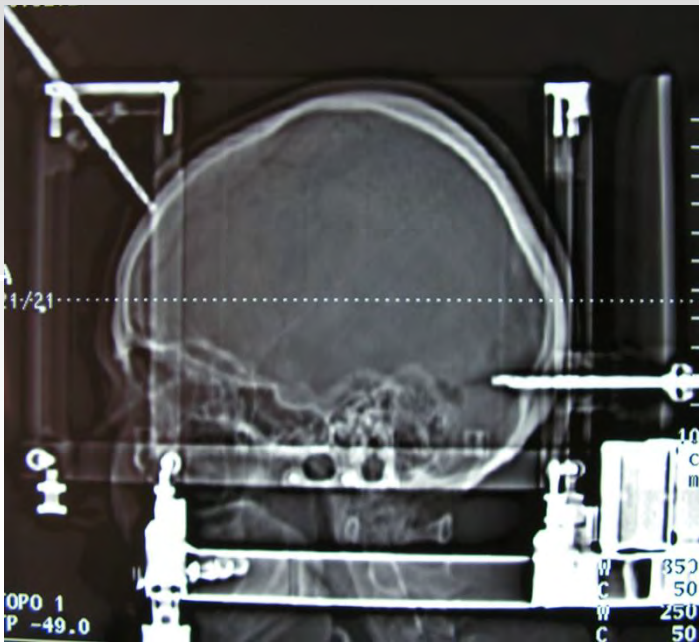


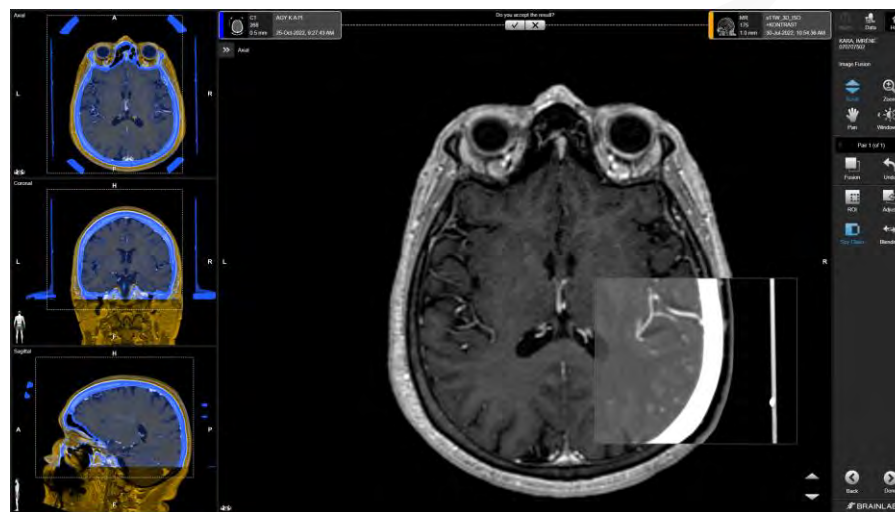
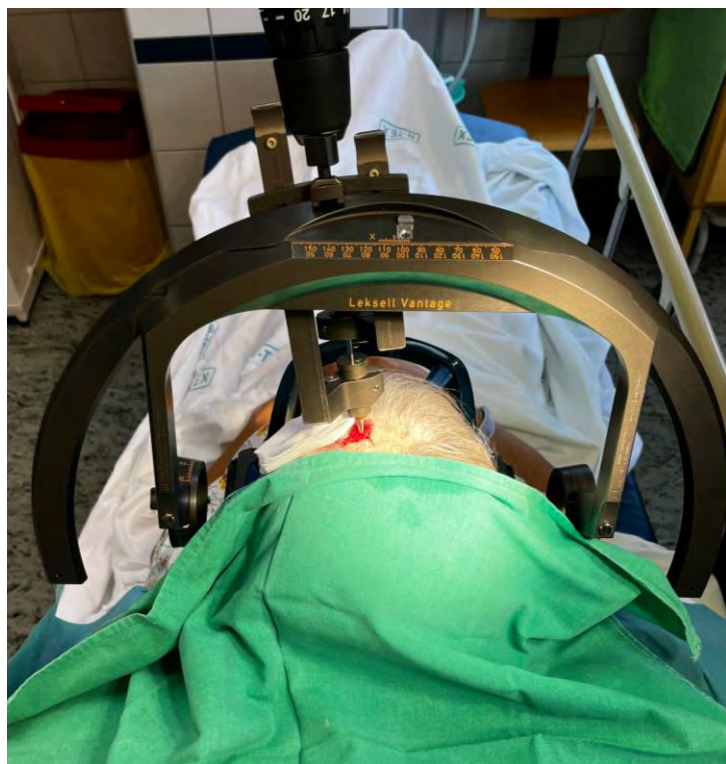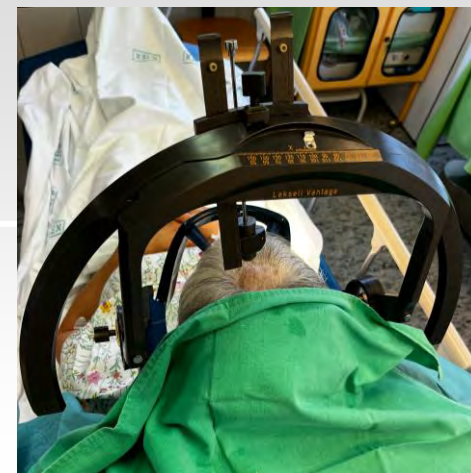
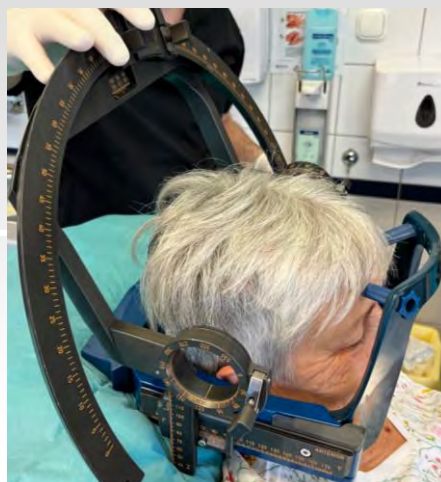meningioma

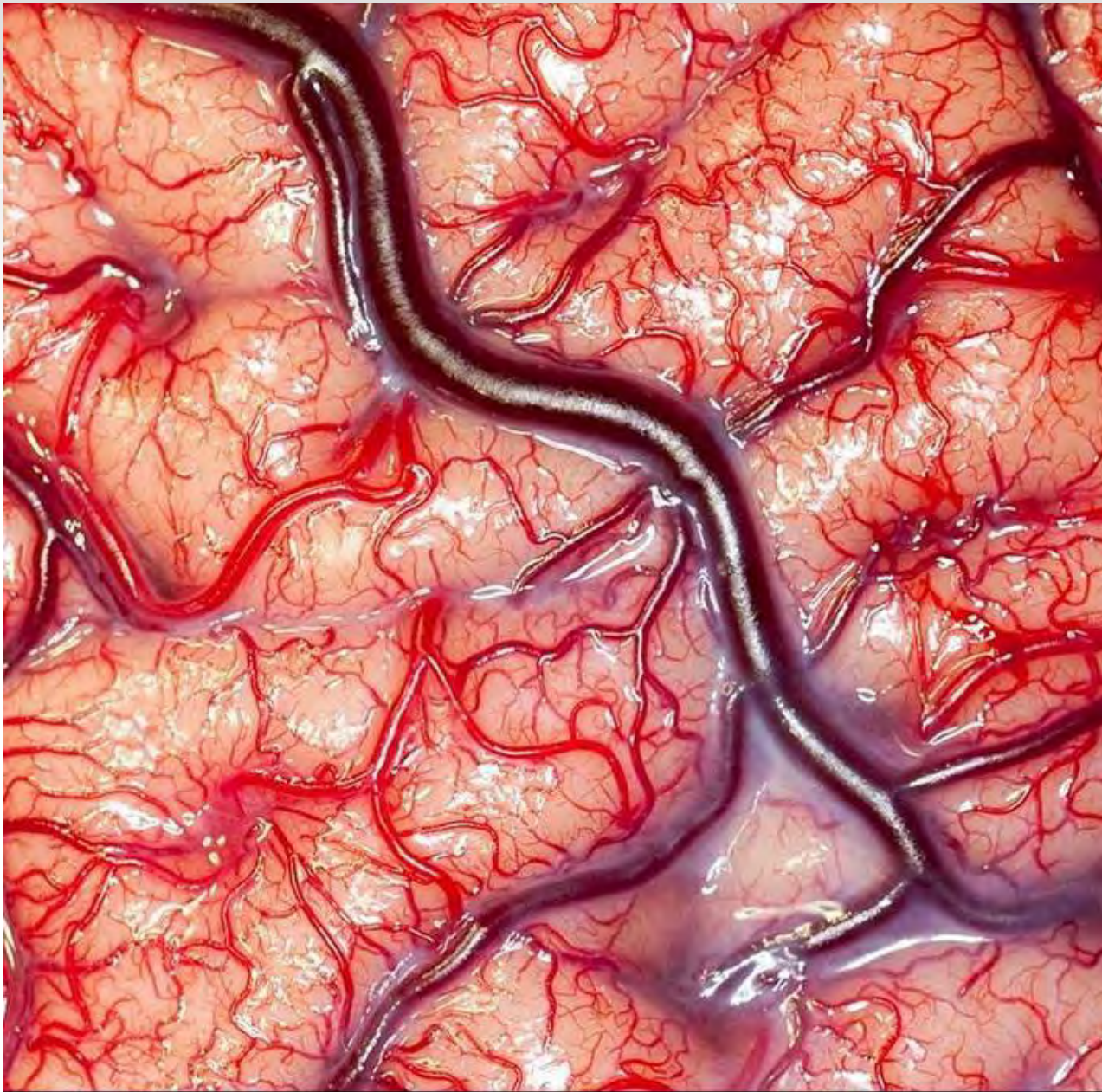


Steretactic biopsy

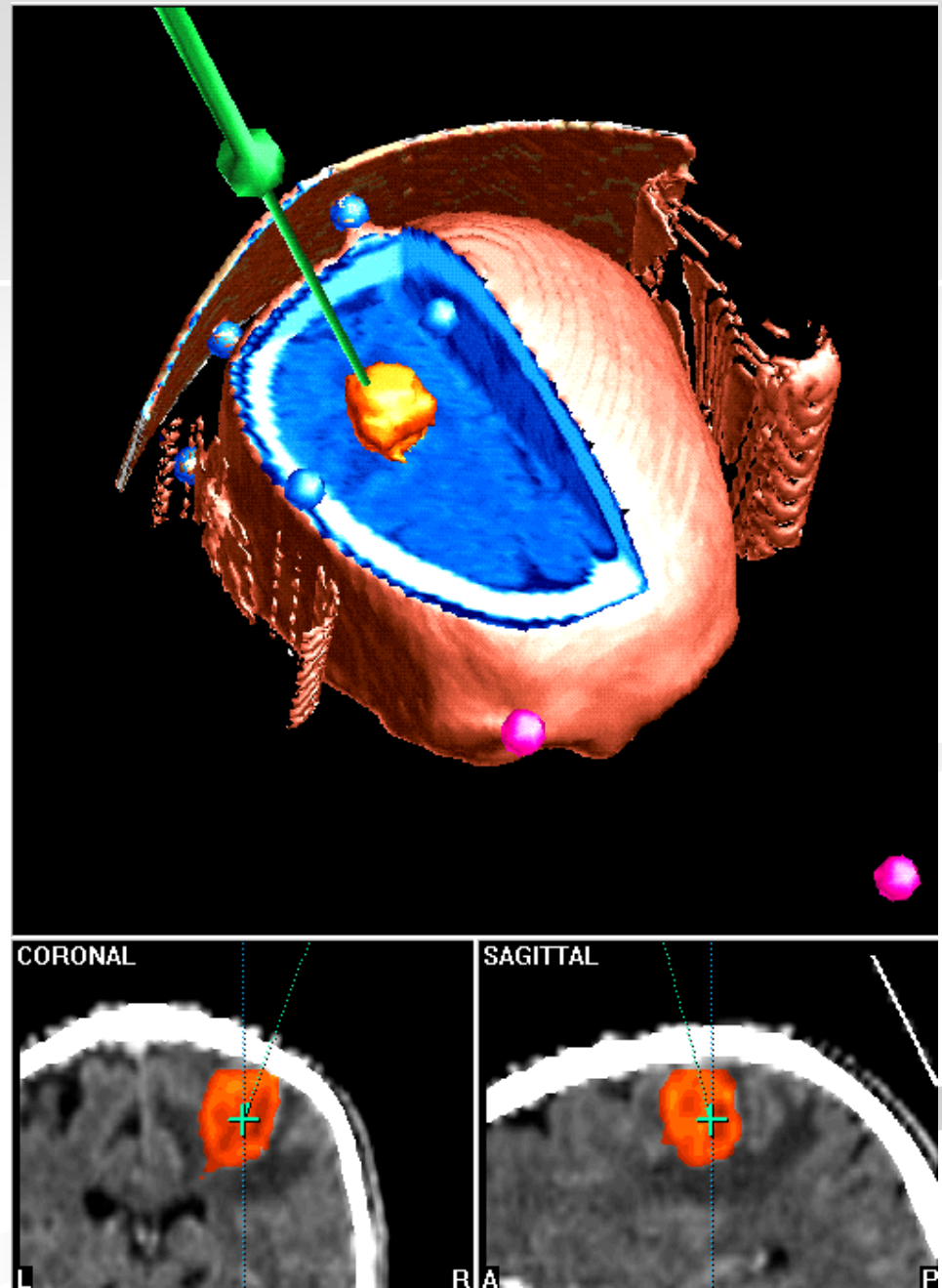
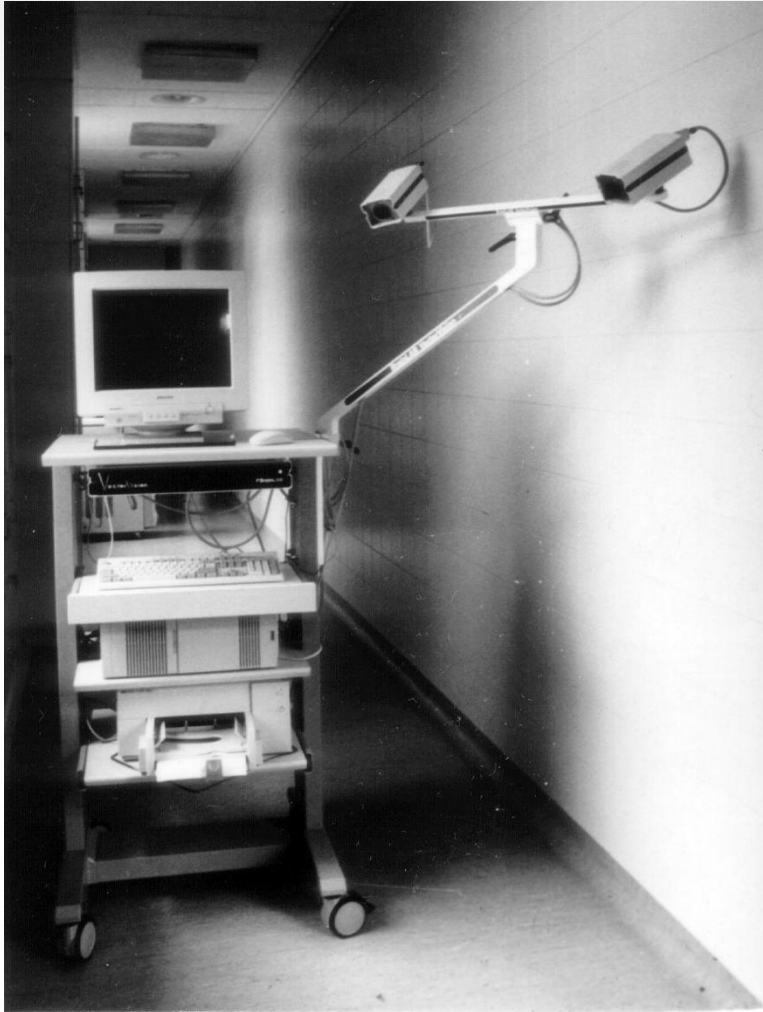


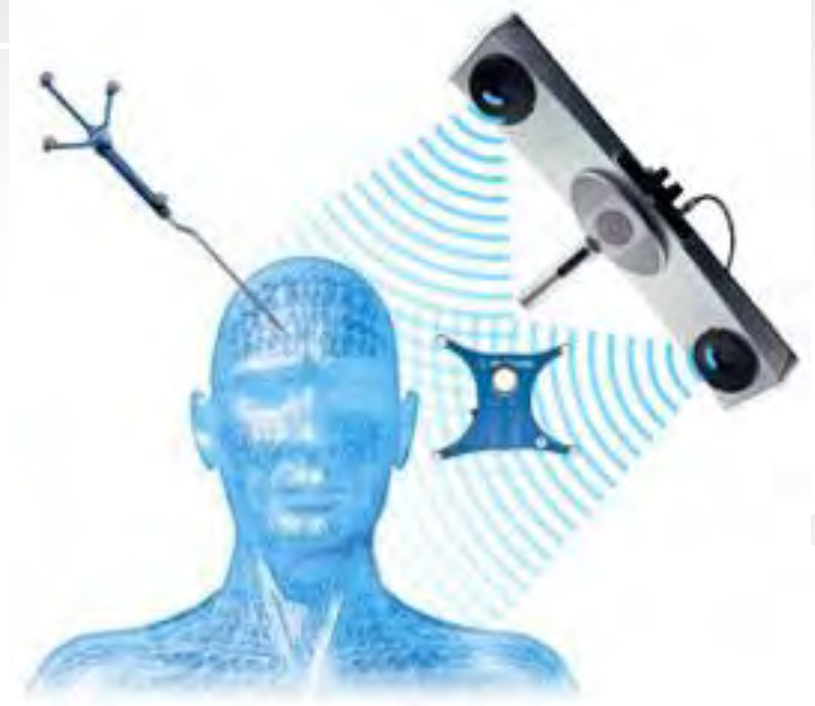




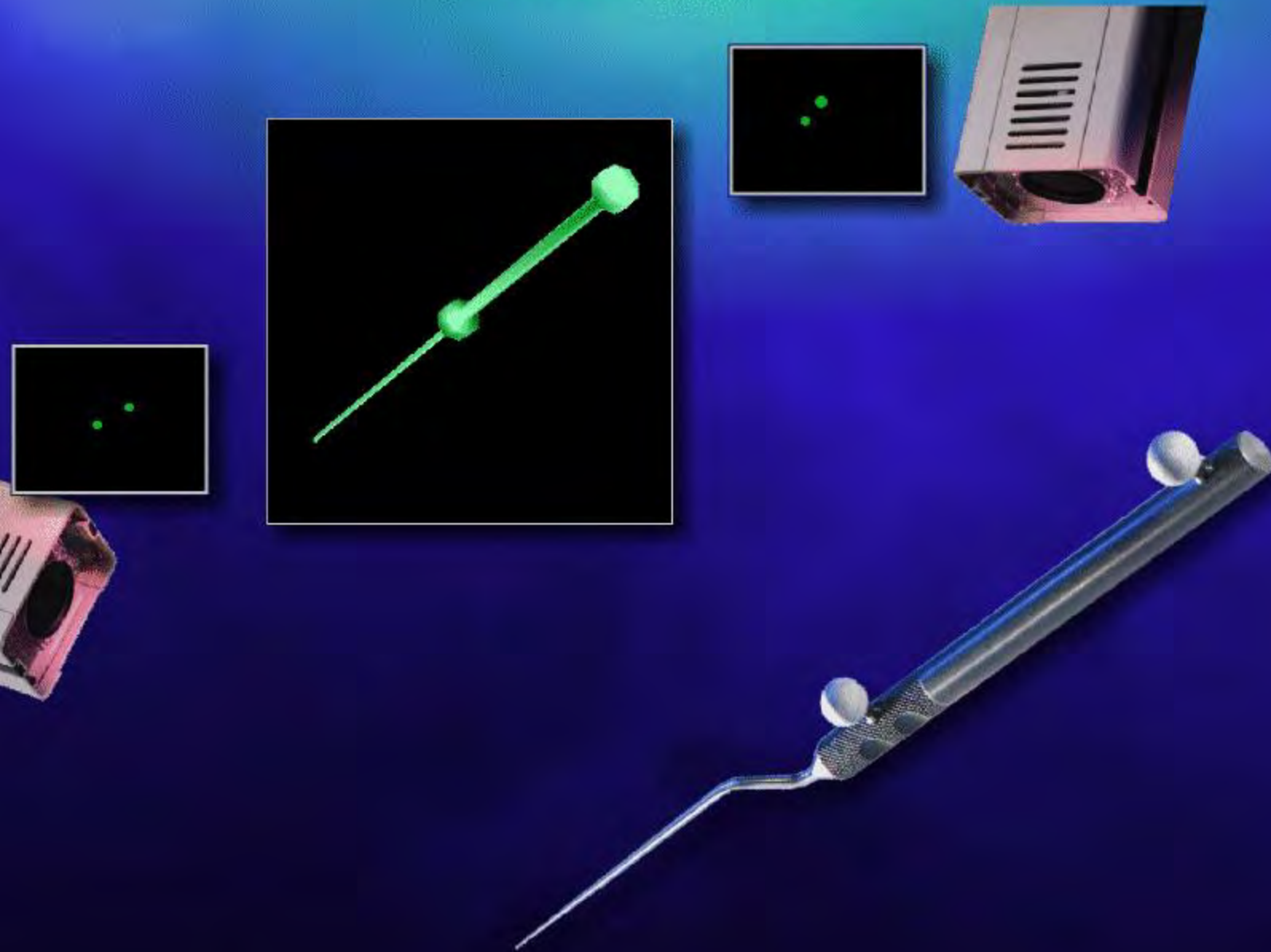
neuronavigation



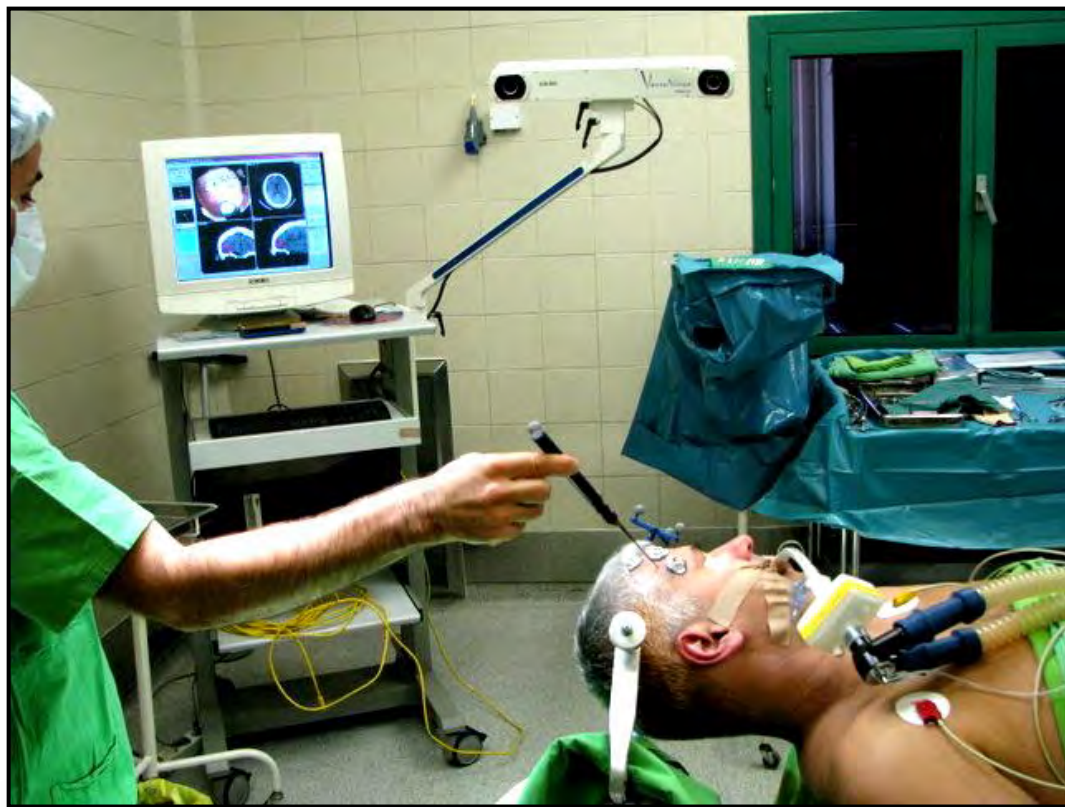
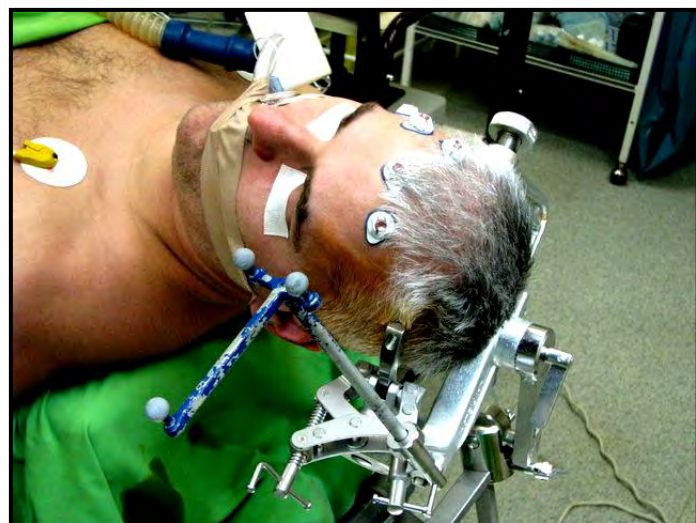
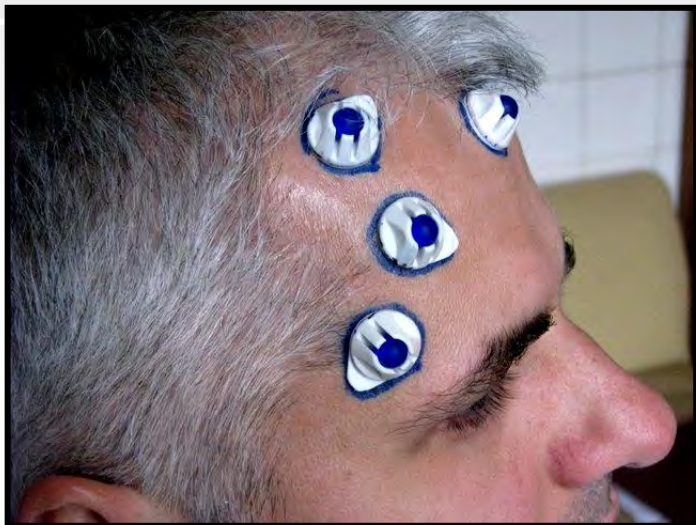
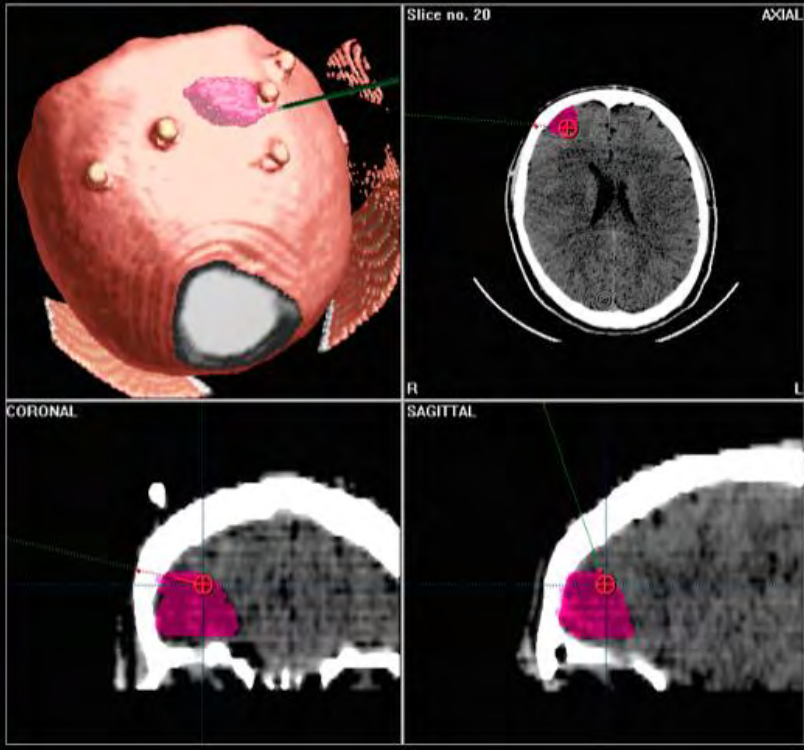
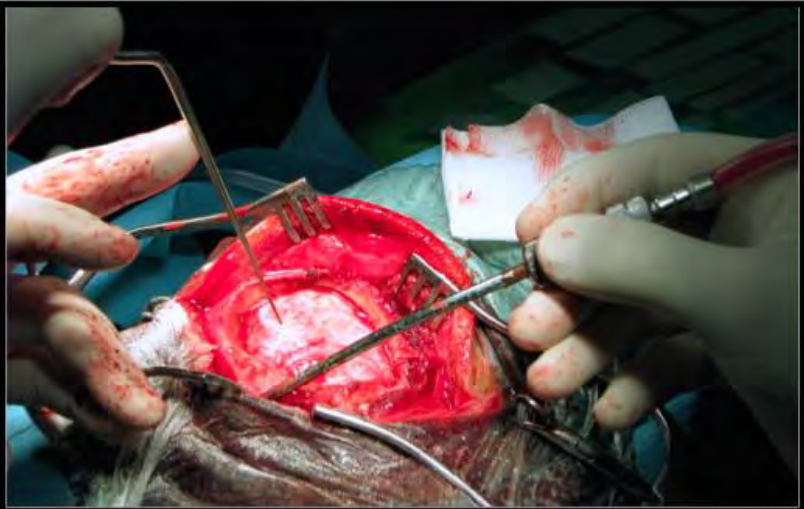
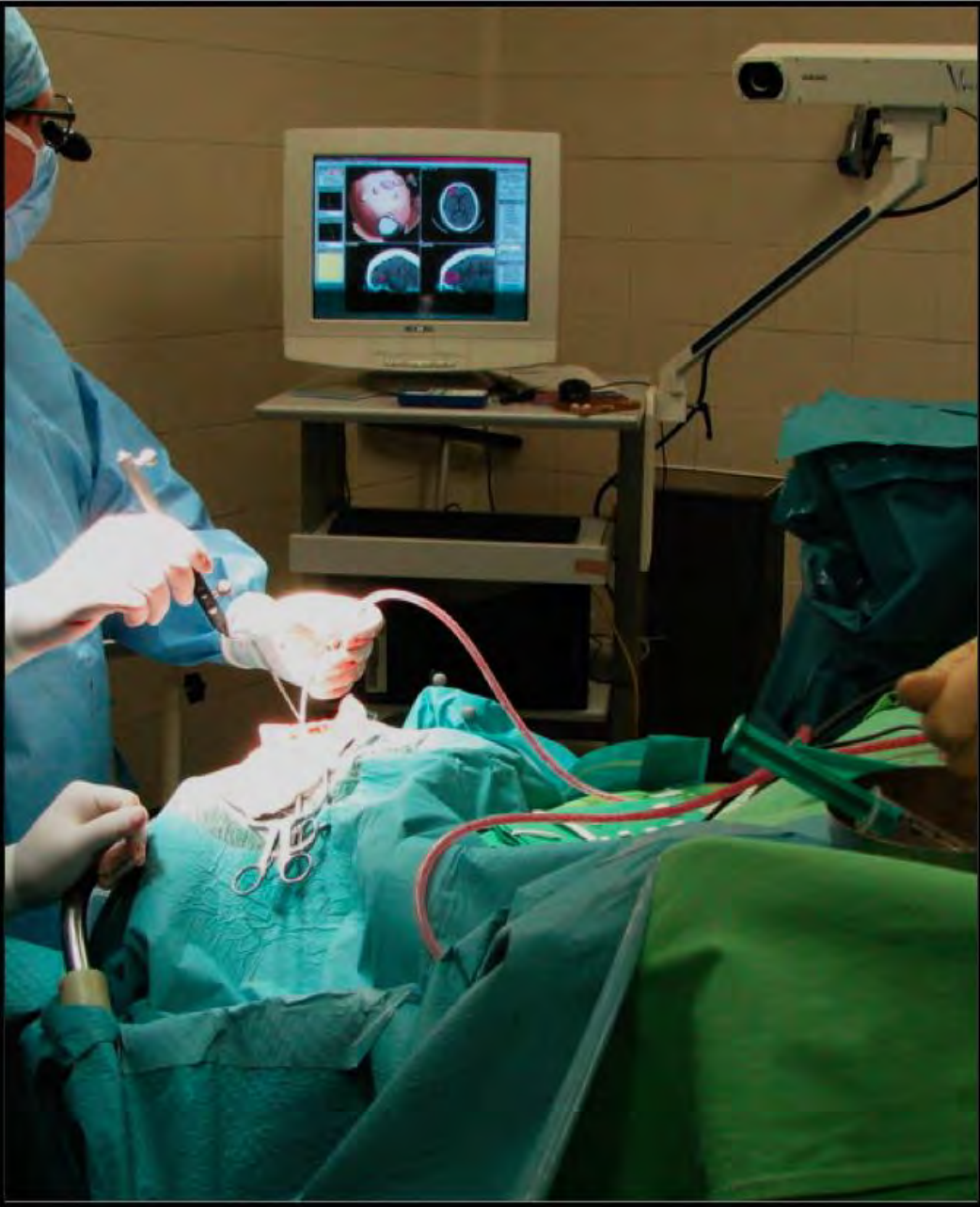Conversion to 3D-position




neuronavigation

Keret nélküli (frameless)
stereotaxia





➔  Fluorescence-guided surgery with 5-aminolevulinic acid for resection of malignant glioma: a randomised controlled multicentre phase III trial

Walter Stummer, Uwe Pichlmeier, Thomas Meinel, Otmar Dieter Wiestler, Friedhelm Zanella, Hans-Jürgen Reulen, for the ALA-Glioma Study Group*

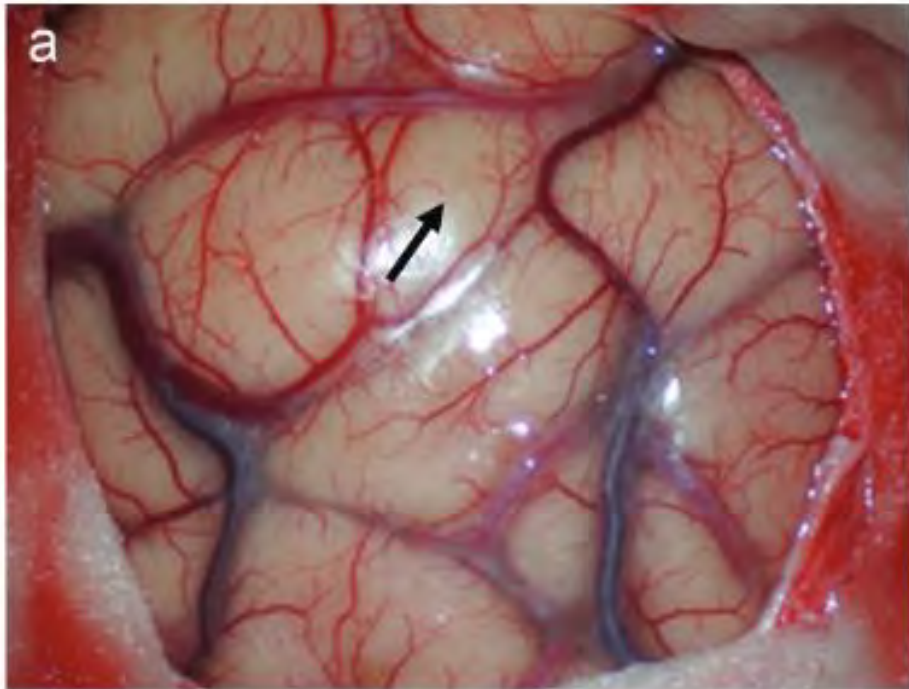
Summary

Lancet Oncol 2006;7: 392-401

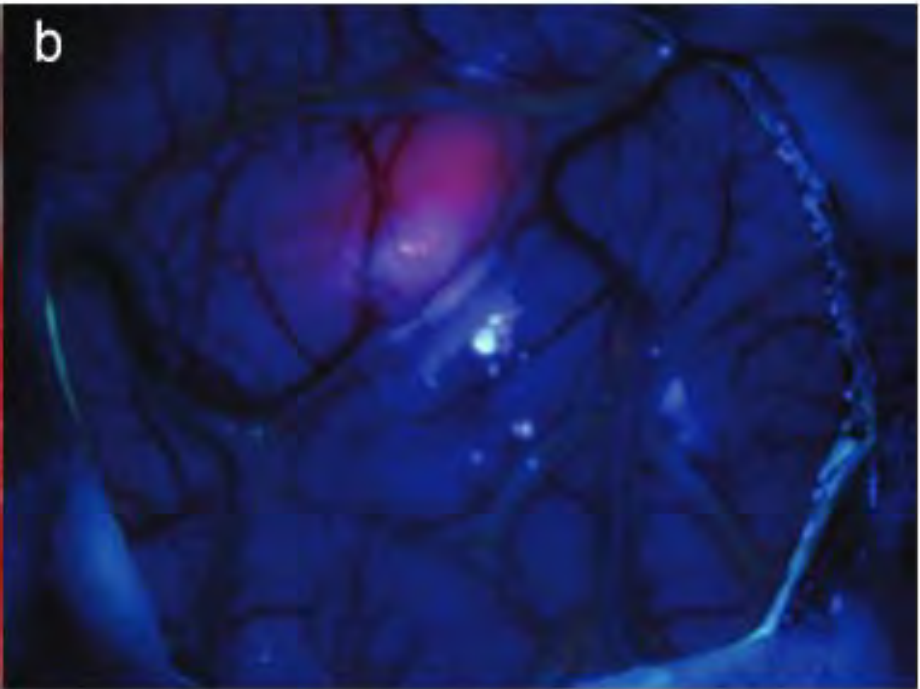
background 5-aminolevulinic acid is a non-fluorescent prodrug that leads to intracellular accumulation of

- 322 beteg, interim analízise 270 betegnél
- ALA-F vs normális mikrosebészet
- Standard postop sugárkezelés
- Teljes eltávolítás 65% vs 36%
- 6 hó PFS 41% vs 21%

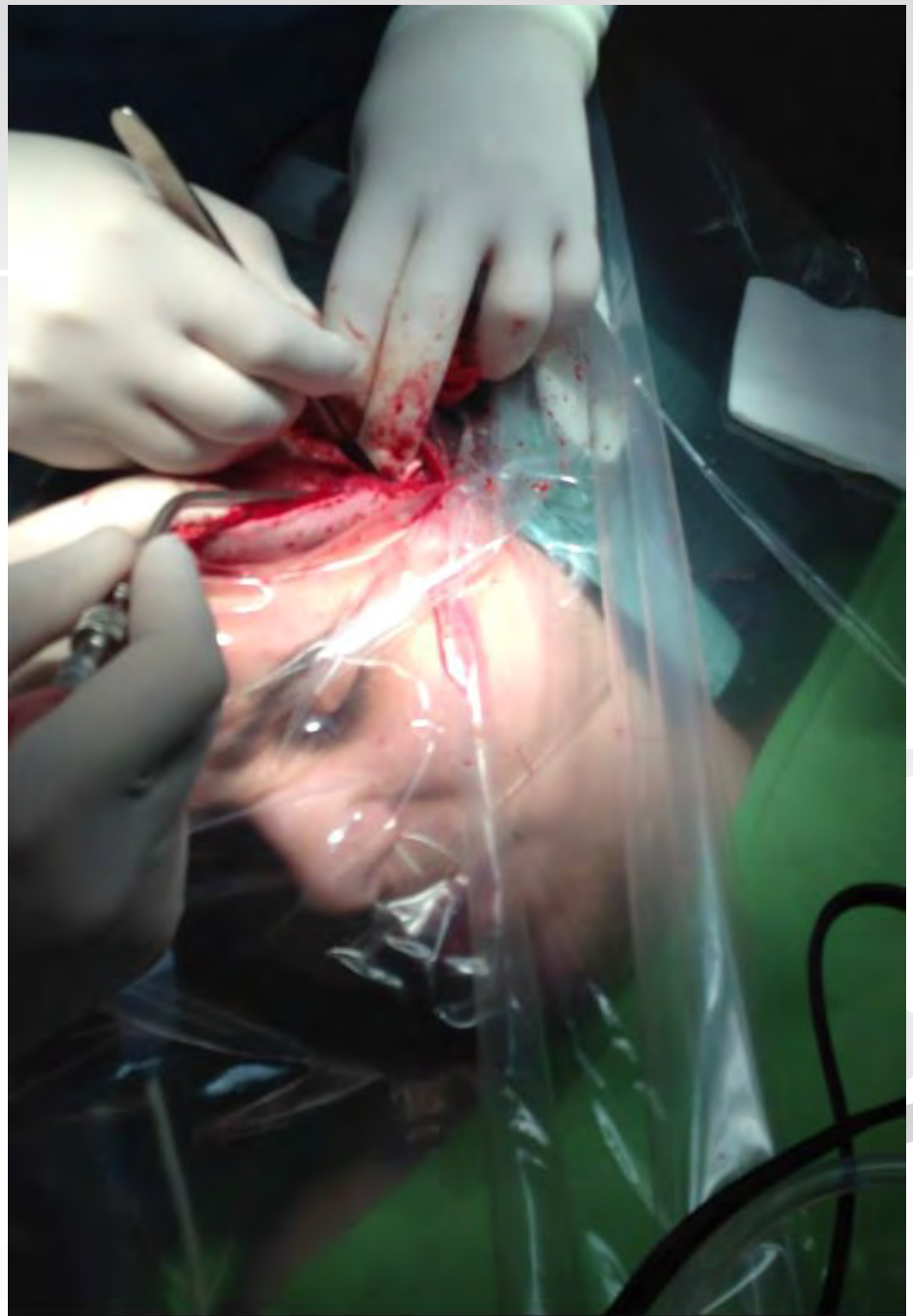
Conventional white-light surgical microscope

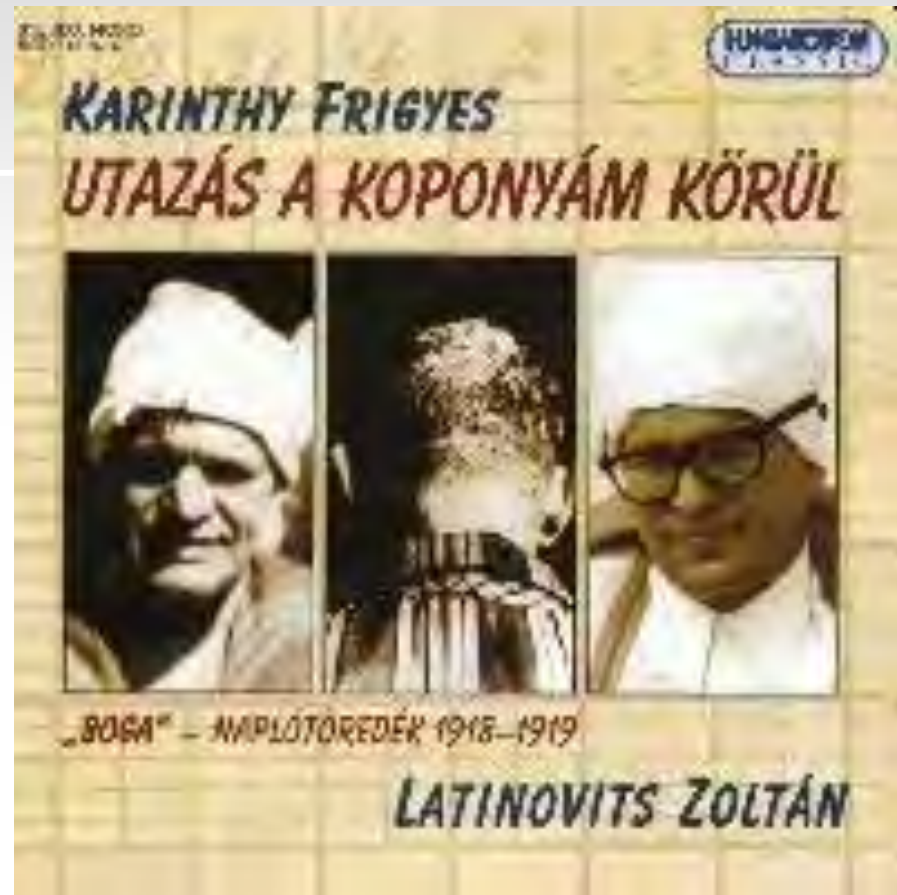

PpIX fluorescence by violet-blue excitation

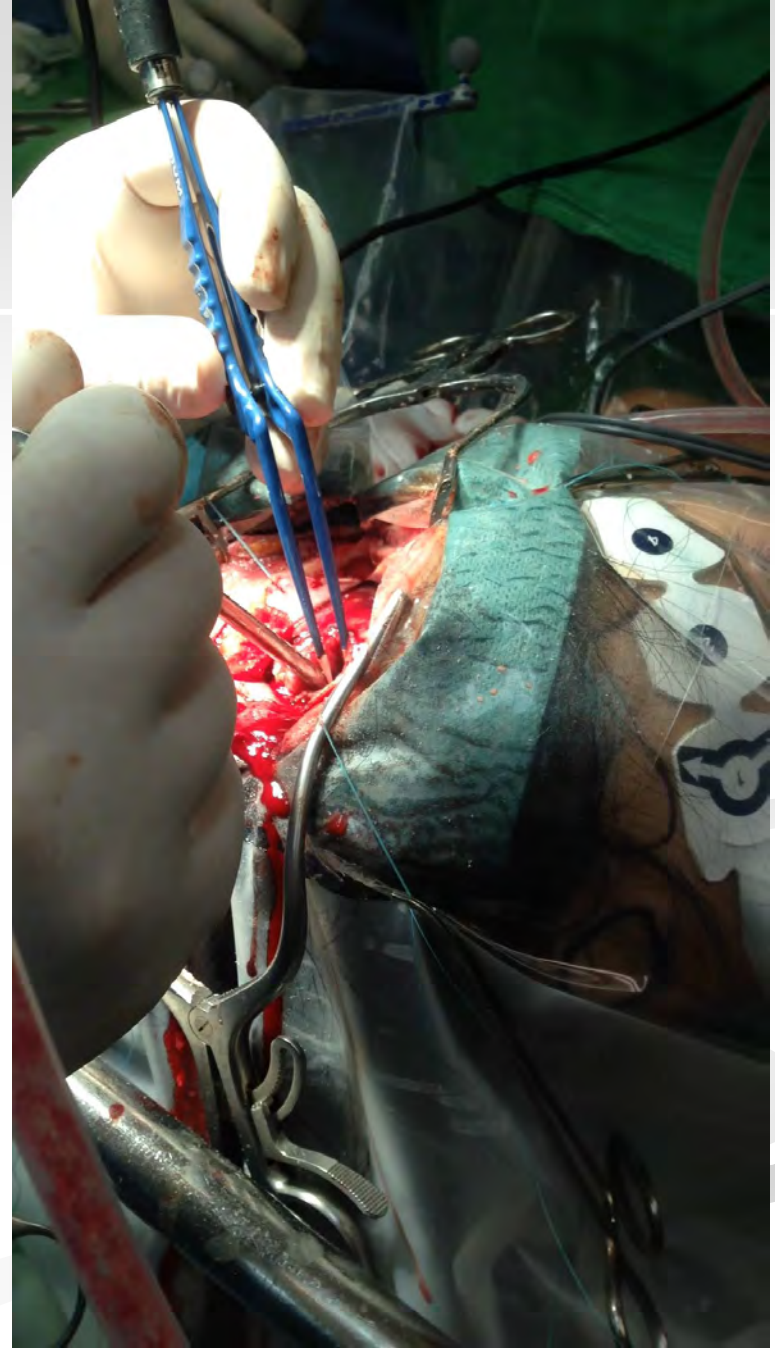
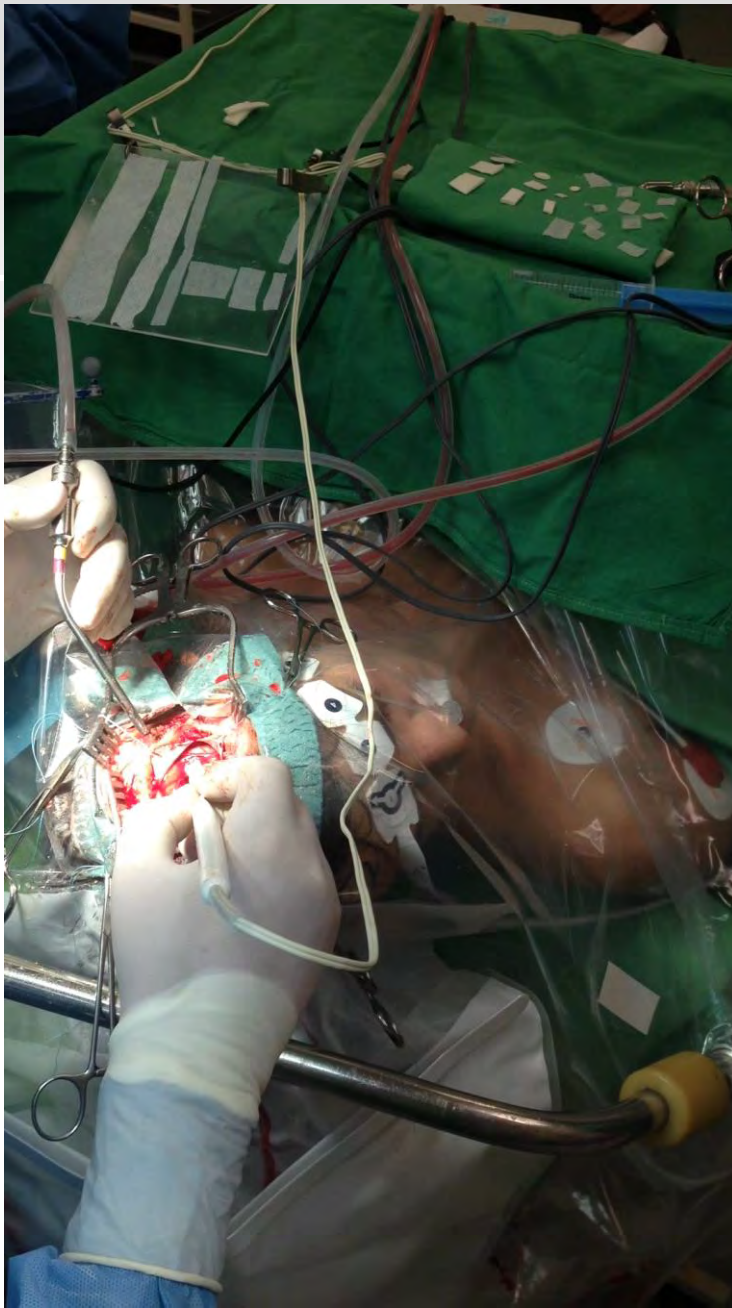

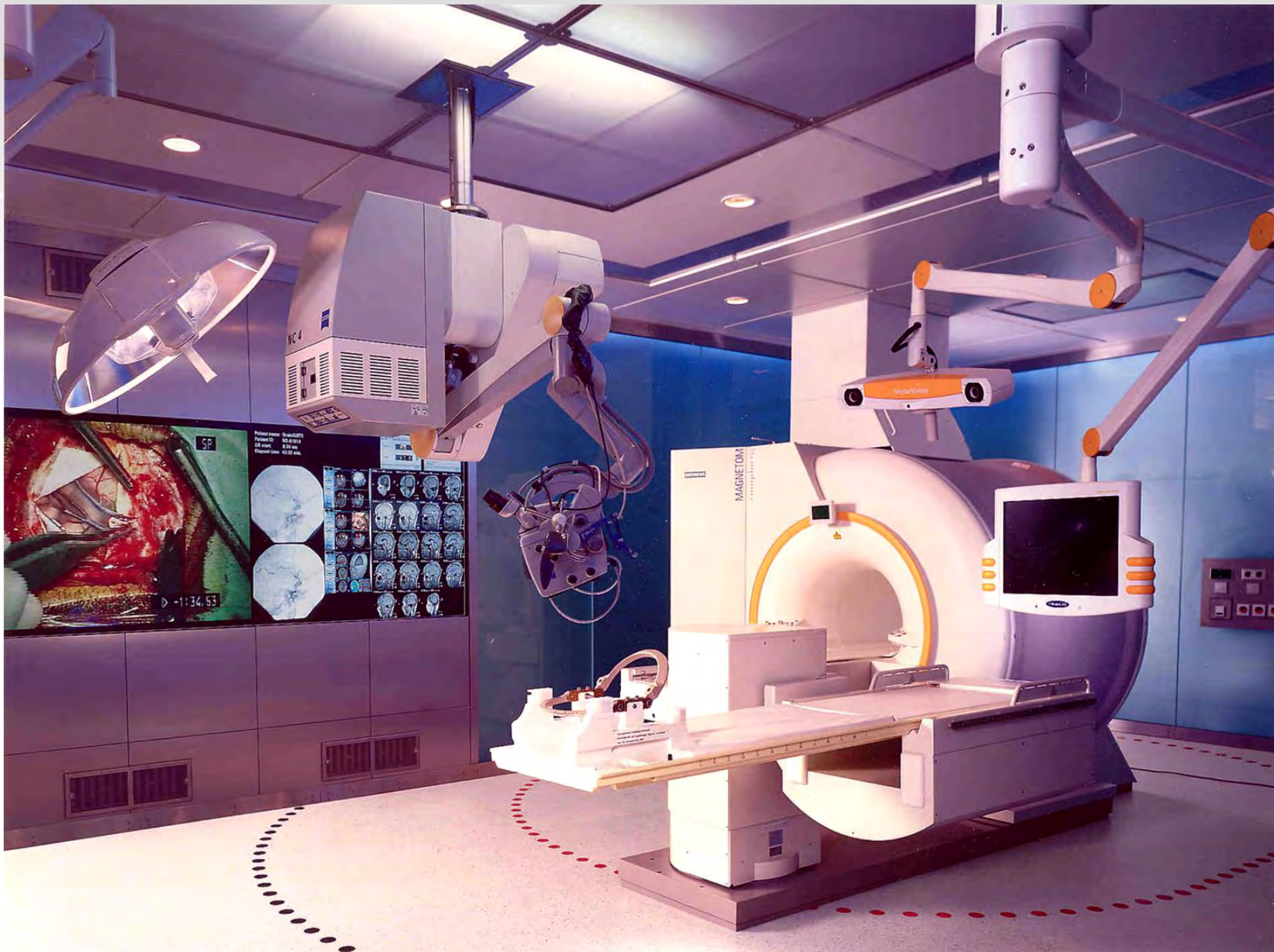
awake surgery





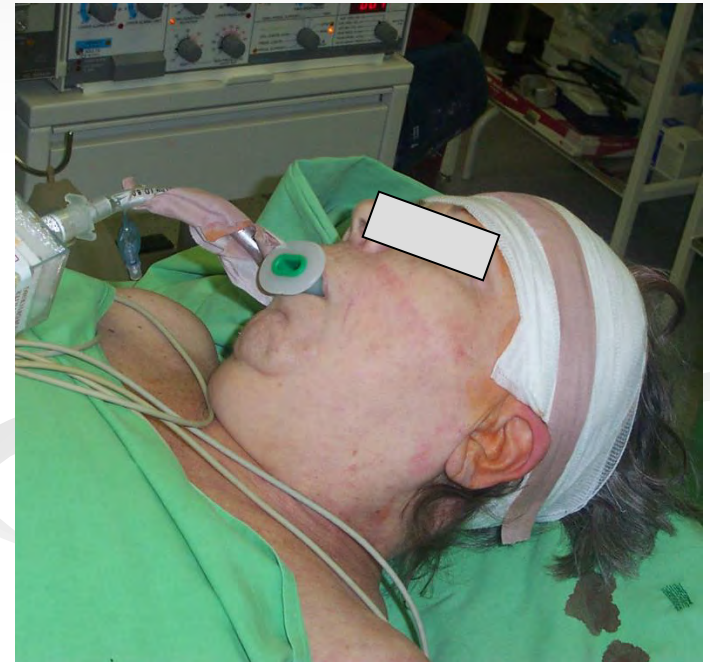H. Olivecrona (1891-1980)





postoperative therapy

- decrease oedema
 - pain controll
 - seizure profilaxis
 - ICU care
 - physiotherapy
-
- prolonged narcosis - ventillation



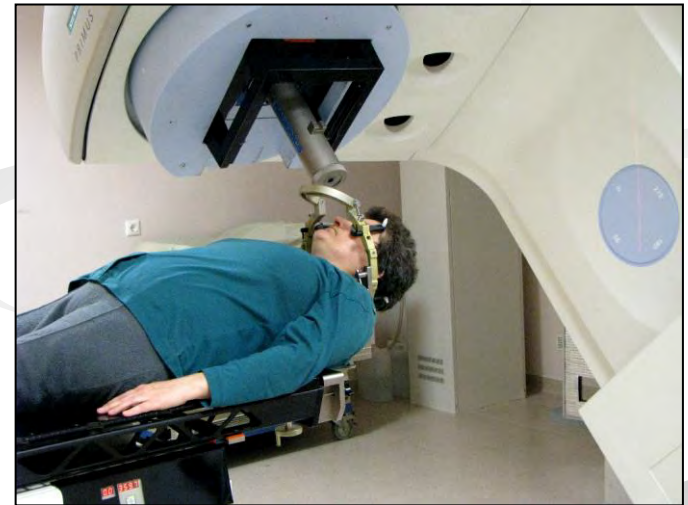
stereotactic radiosurgery

- **targeted, focus radiotherapy**
- **single, high dose (12-20 Gy)**
- stereotactic frame
- one session, outpatient based
- small sized, circumscribed tumors (<3 cm)
- Metastases or benign tumors (meningioma, neurinoma)
- no craniotomy
- LINAC / Cyber Knife or Gamma Knife

LINAC – Primus II

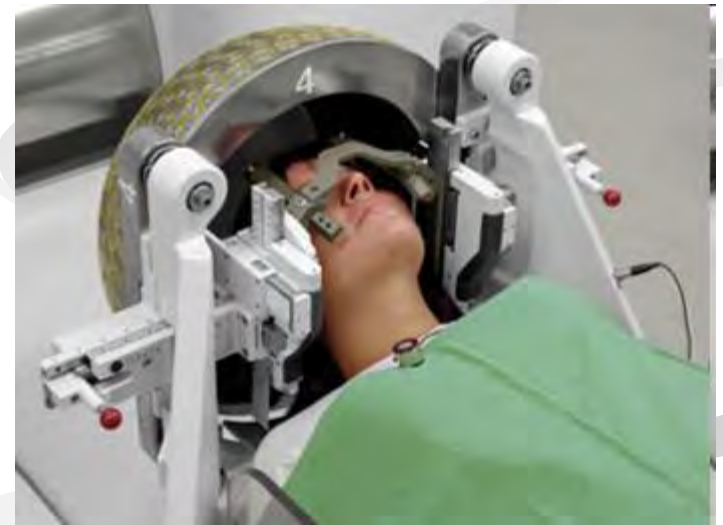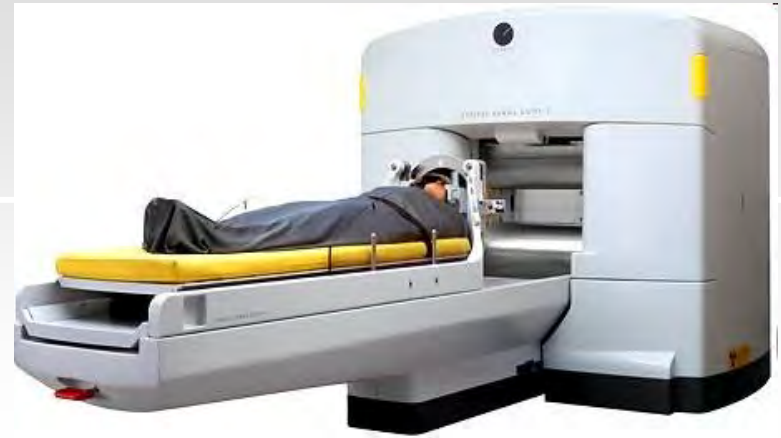- Linear accelerator
- High energy photon beam (6-18 MeV)
- Rotating radiation source
- Radiation arcs

Sine 1992 in Hungary



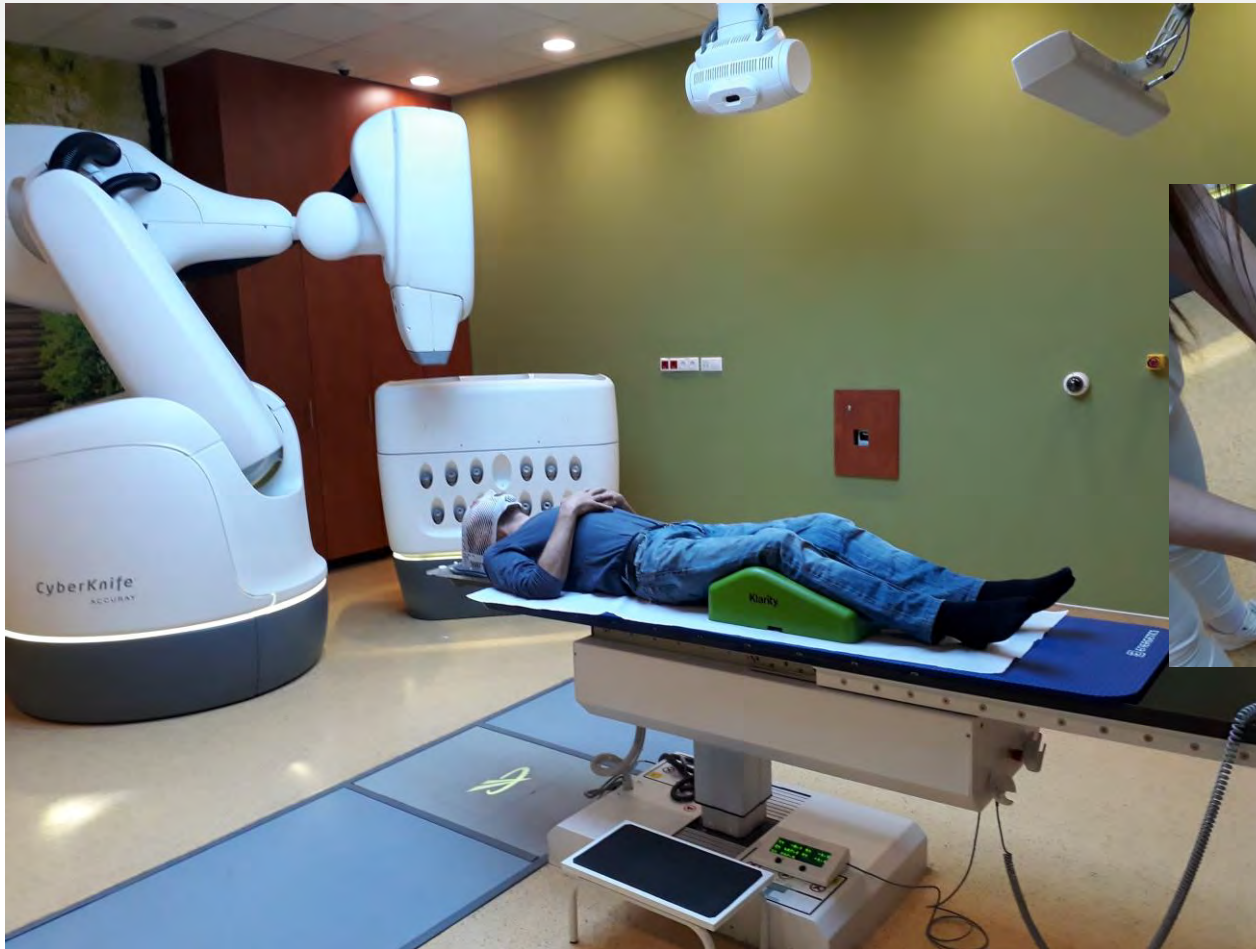Gamma Knife

- 1950's Lars Leksell
- 211 Cobalt sources
- Spheric arranged
- Target lesion in the isocenter
- Collimator helmet

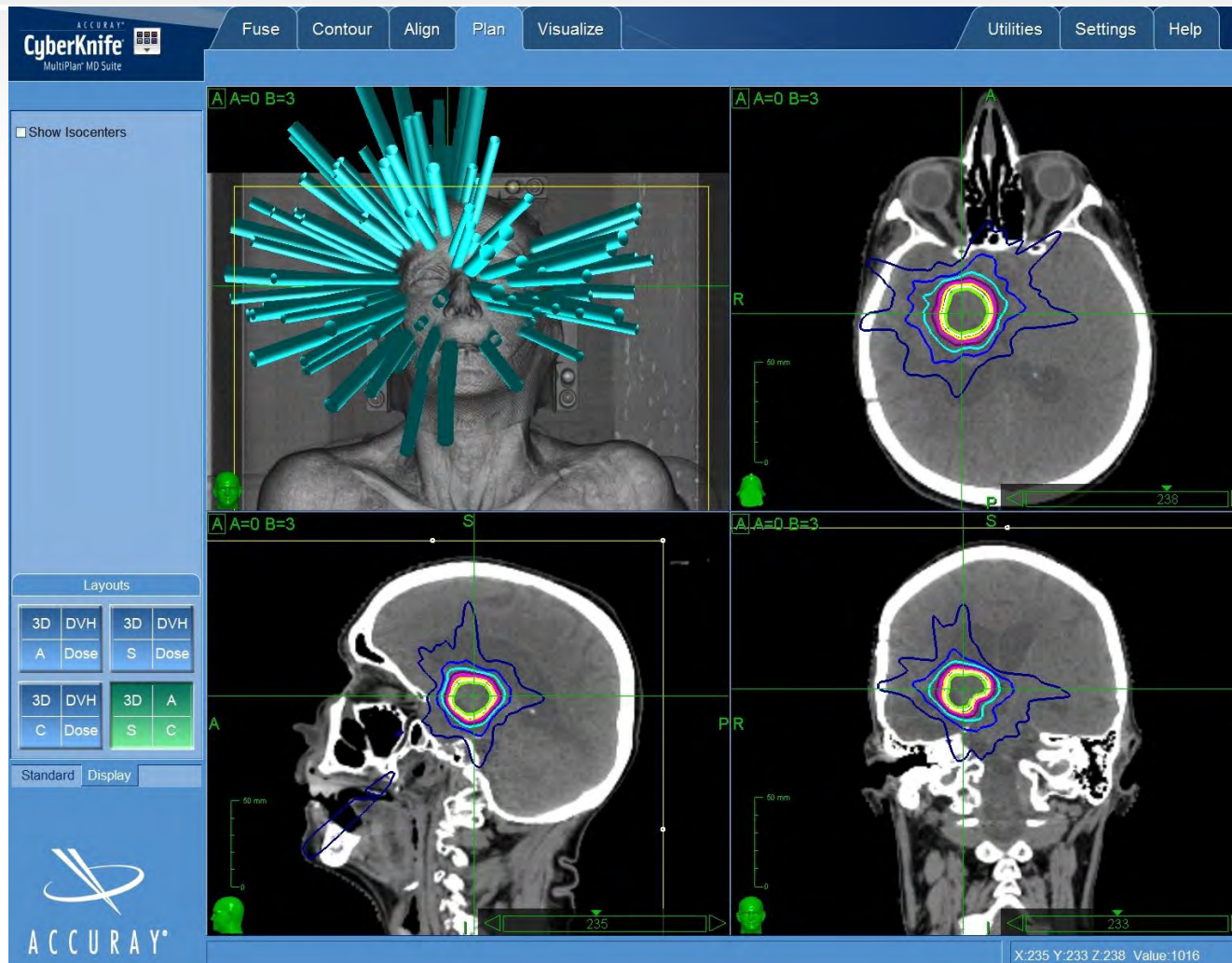


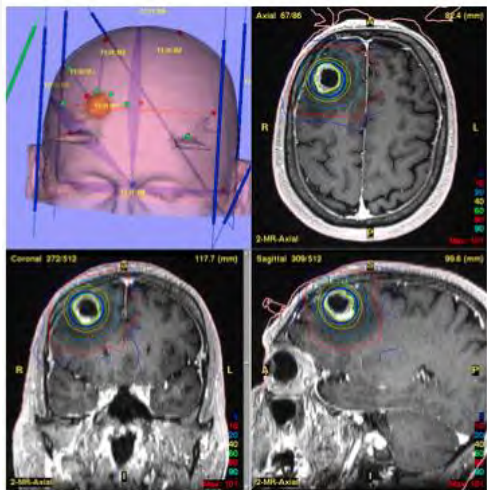
**Rotating Gamma
Debrecen University**

Cyber Knife 2018- (Natl Inst of Oncology, Budapest)

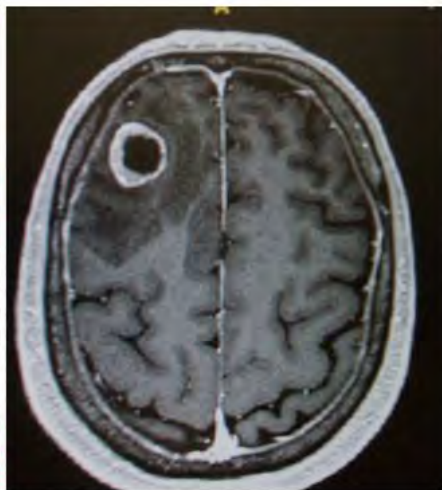


Cyber Knife

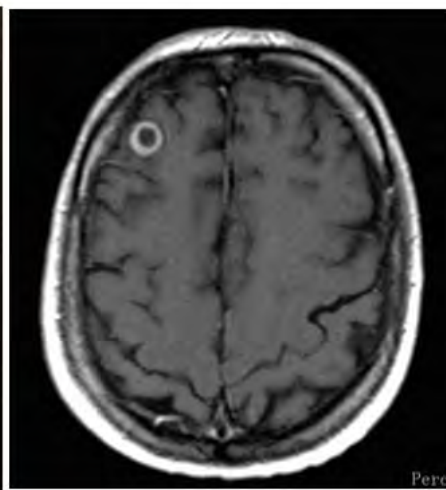




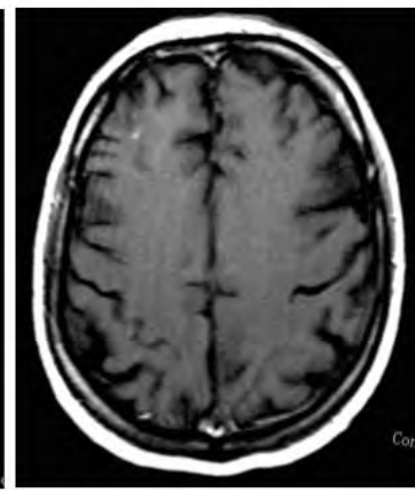
A



B

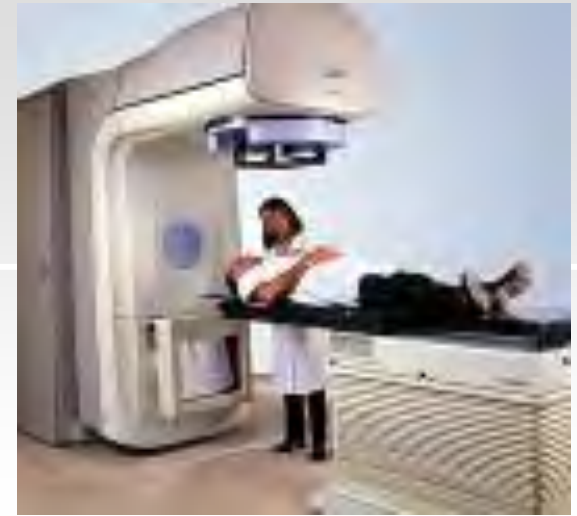

C



D

Fractionated external beam radiotherapy



- Fractionation - **small dose, multiple session**
- **Posztooperative or adjuvant setting**
- Malignant gliomas - tumorbed 25-30x2 Gy
- Metastases – whole brain WBRT 10x3 Gy
- In radiation oncology center
- LINAC based (no Cobalt anymore)

Chemotherapy

- **Blood brain barrier issue**
- Mets – according to the primary tumor
- Gliomas have **low sensitivity to Chemotx**
- Oligodendrogliomas – PCV
- CNS Lymphomas – MTX
- Now: **Temozolomide – malignant gliomas**

Temozolomide

- Methylating agent
- PO administration
- Good penetration to CNS
- less side effects
- proved efficacy
- FDA 1999 rec. high grade glioma (Yung, J Clin Oncol. 1999 Sep;17(9):2762-71)
- First in recurrent, then in adjuvant setting

Temozolomide 2

- dose 150-200mg/m²
- PO with antiemetics
- 5/28 day cycles
- BCC nadir on 21th day
- Adjuvant setting: radichemotx (6weeks) followed mothly (12-24 months)
- Recurrent setting: 12-24 months

TMZ

TMZ → methylation O⁶M-G → DNS replication ↓

MGMT status

MGMT = O⁶-metilguanin-metil-transzferáz

**MGMT promoter
methylated**



MGMT does not work

MGMT -



TMZ methylation
works



Chemosensitivity

Survival ↑

**MGMT promoter
not methylated**



MGMT works

MGMT +



TMZ methylation
does not work



Chemoresistance

Survival ↓


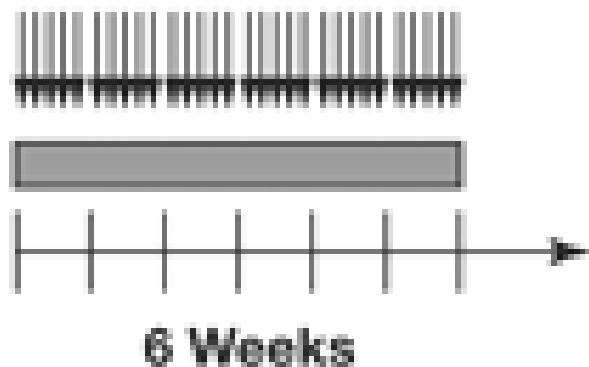
Temozolomide radiochemotherapy + prolonged TMZ monotherapy

**Stupp regimen – gold standard
in glioblastoma**

(R. Stupp et al, 2005, N Eng J Med)



Concomitant RT + TMZ



150 to 200 mg/m² days 1 to 5 every
28 days for 12 cycles maximum

 TMZ (75 mg/m²/day during concomitant phase)

 Focal RT daily: 30 × 200 cGy
Total dose: 60 Gy

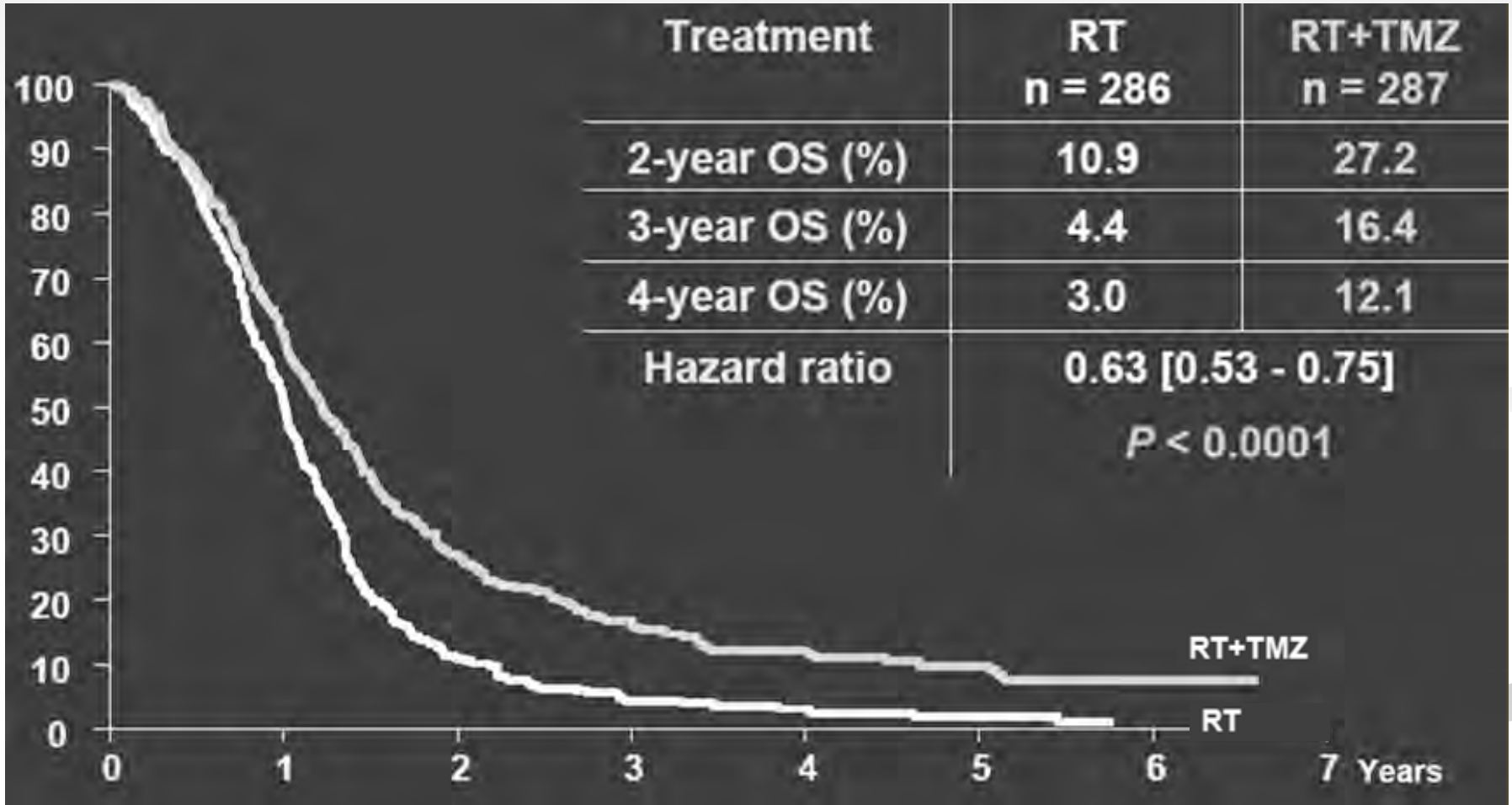
EORTC 26982/22982-NCIC-CE 3 phase III randomized study, 573 patients

Radiotherapy plus Concomitant and Adjuvant Temozolomide for Glioblastoma

Roger Stupp, M.D., Warren P. Mason, M.D., Martin J. van den Bent, M.D.,
Michael Weller, M.D., Barbara Fisher, M.D., Martin J.B. Taphoorn, M.D.,
Karl Belanger, M.D., Alba A. Brandes, M.D., Christine Marosi, M.D.,
Ulrich Bogdahn, M.D., Jürgen Curschmann, M.D., Robert C. Janzer, M.D.,
Samuel K. Ludwin, M.D., Thierry Gorlia, M.Sc., Anouk Allgeier, Ph.D.,
Denis Lacombe, M.D., J. Gregory Cairncross, M.D., Elizabeth Eisenhauer, M.D.,
and René O. Mirimanoff, M.D., for the European Organisation for Research
and Treatment of Cancer Brain Tumor and Radiotherapy Groups and the National
Cancer Institute of Canada Clinical Trials Group*

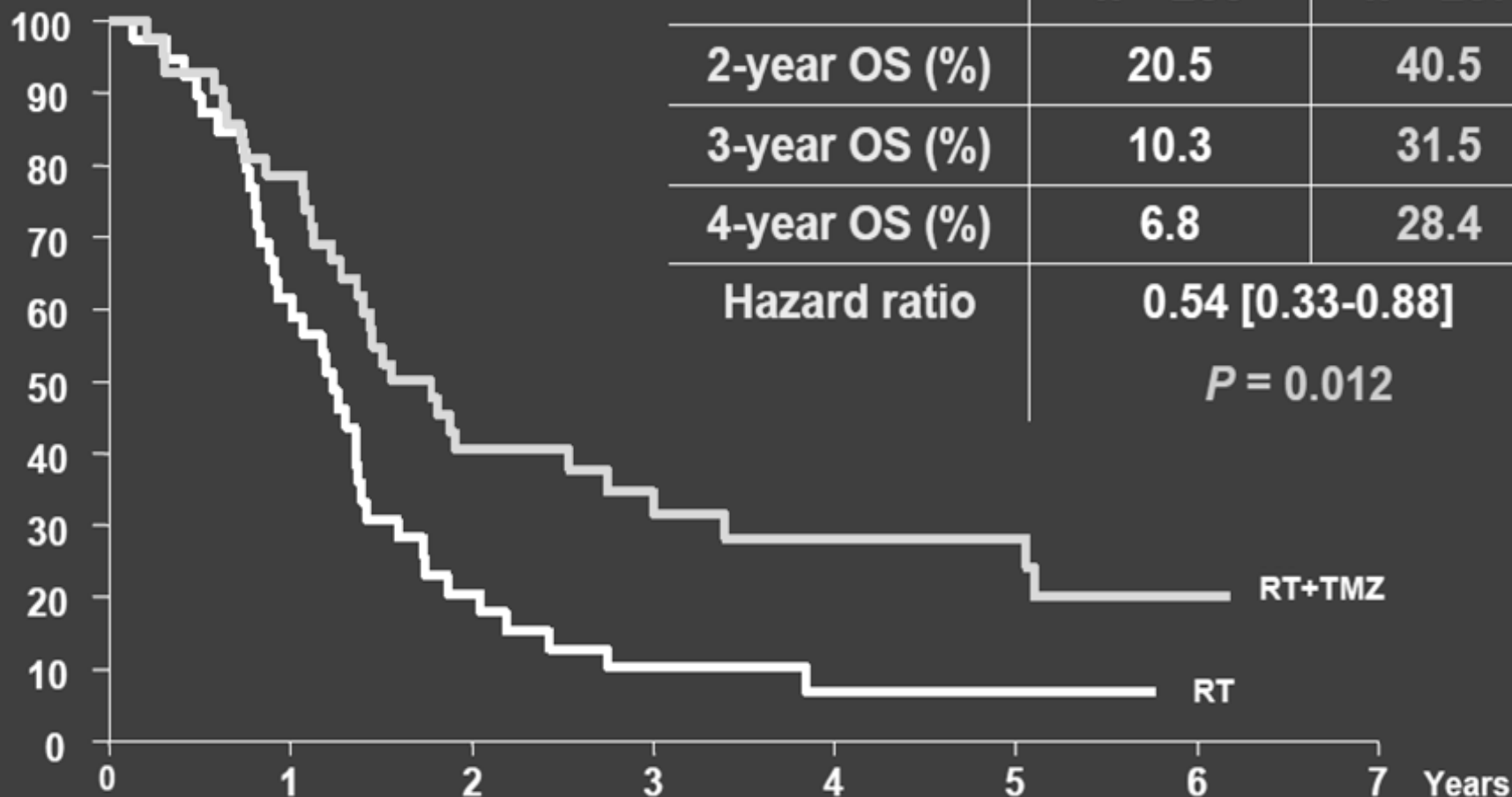
N Engl J Med 2005;352:987-96.

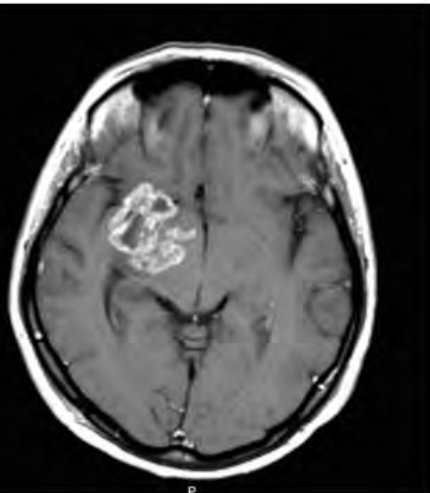
2007 update (ASTRO)



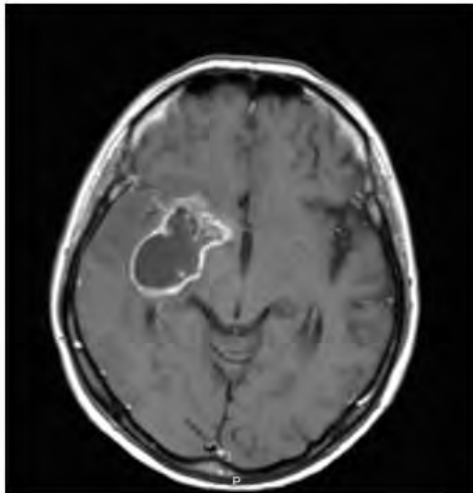
RPA III

Overall survival: Treatment in RPA class 3

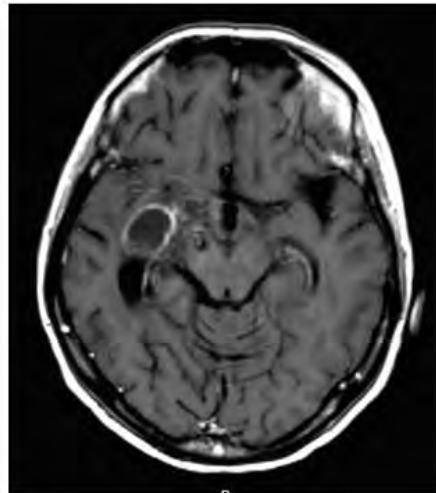




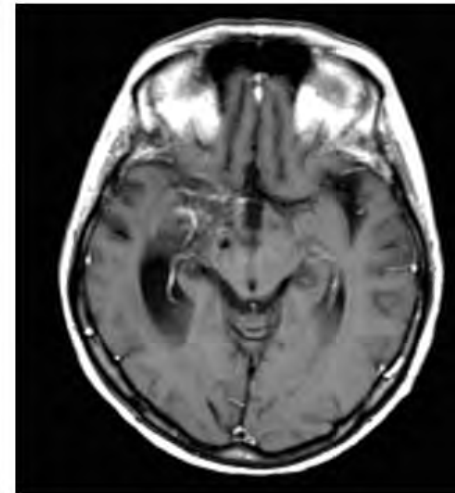
A



B



C



D

Paradigms 1

- benign tumors

- Curable/long survival with radical surgery
- Even in advanced age
- Multimodal treatment
 - – „radiosurgery tailored surgery”
- Best quality of life

Paradigms 2

- malignant gliomas

- incurable
- short time survival determined by the surgery
- long time survival determined by the response to oncotherapy
- radicality vs quality of life
- Goal of the surgery to provide the best clinical condition for the patient for the oncotherapy
- complex oncotherapy (Stupp regimen)

Paradigm 3

- brain mets

- ❑ Single / oligo met: maximal radicality
- ❑ Multimodal therapy - duplex met: craniotomy + SRS
- ❑ In case of less radiosensitive mets (melanoma of renal cell cc) surgery is preferred
- ❑ Any surgical intervention if part of the complex oncotherapy plan of the primary tumor

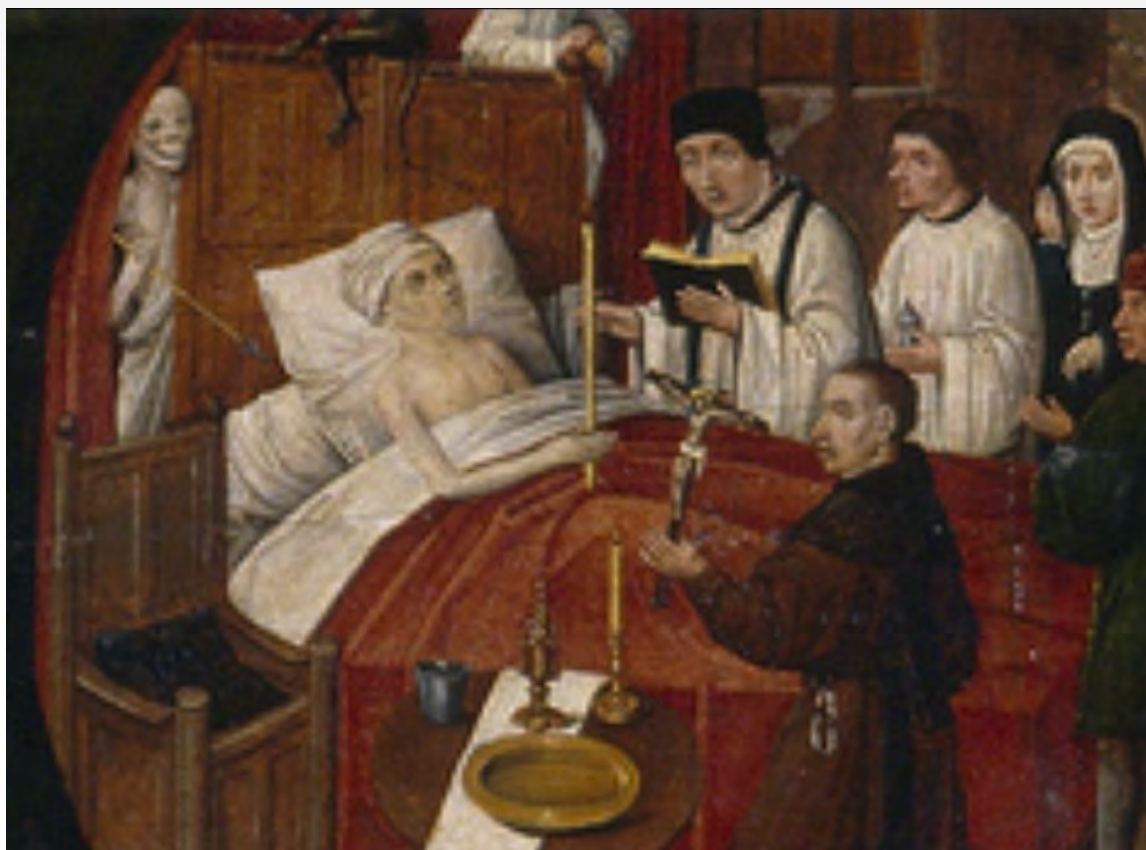Brain tumor care

- High volume neurosurgery center
- Advanced surgical technics available
- Stereotaxy onboard
- Neuropathology
- Strong collaboration with oncology centeregyüttműködés
- MDT based decisions (neuro-onco-team)

CENTER



OMIII (OITI, OKITI) Amerikai út



glioblastoma – komplex therapy



13 év



Köszönöm a figyelmet!