



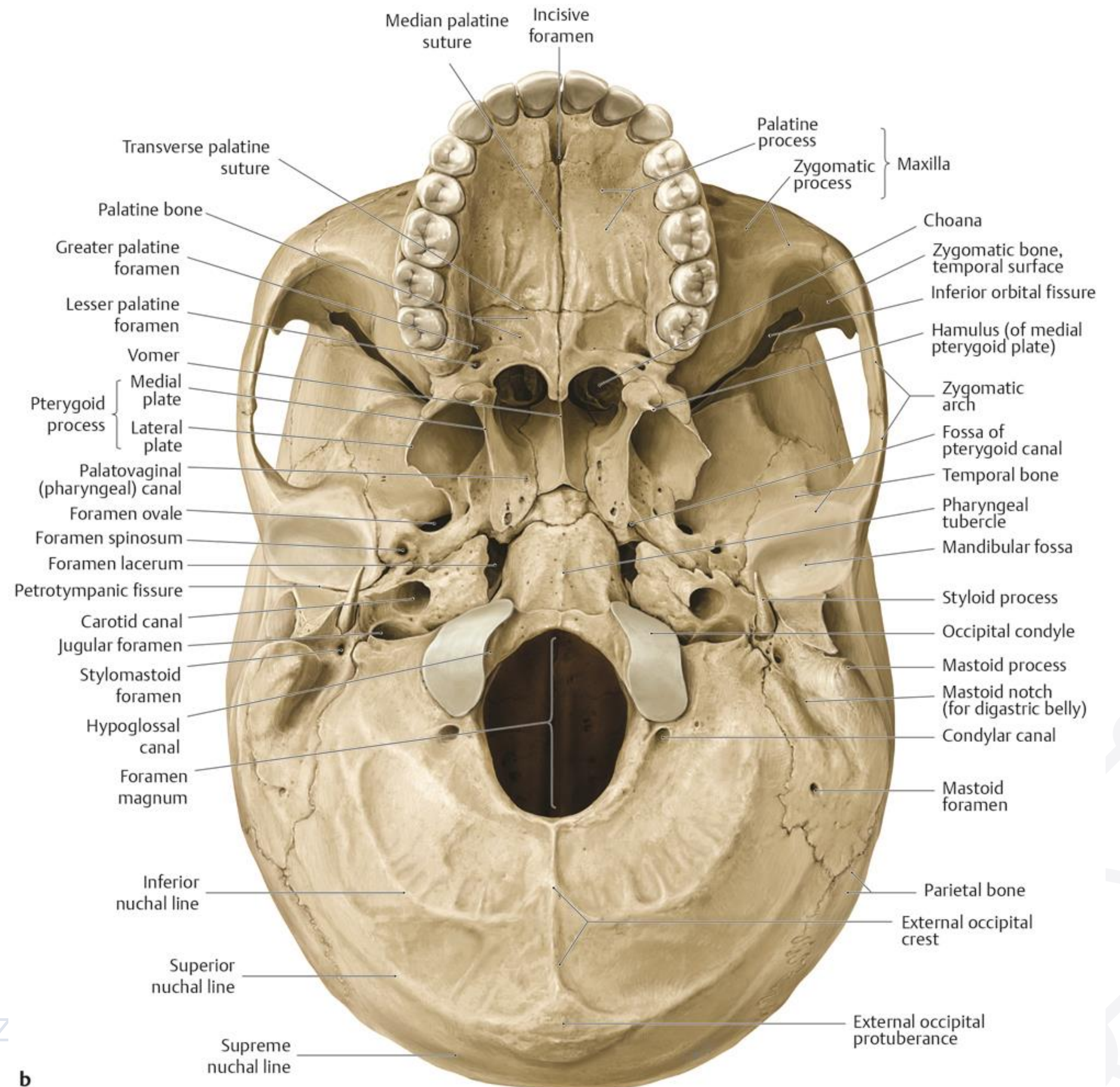
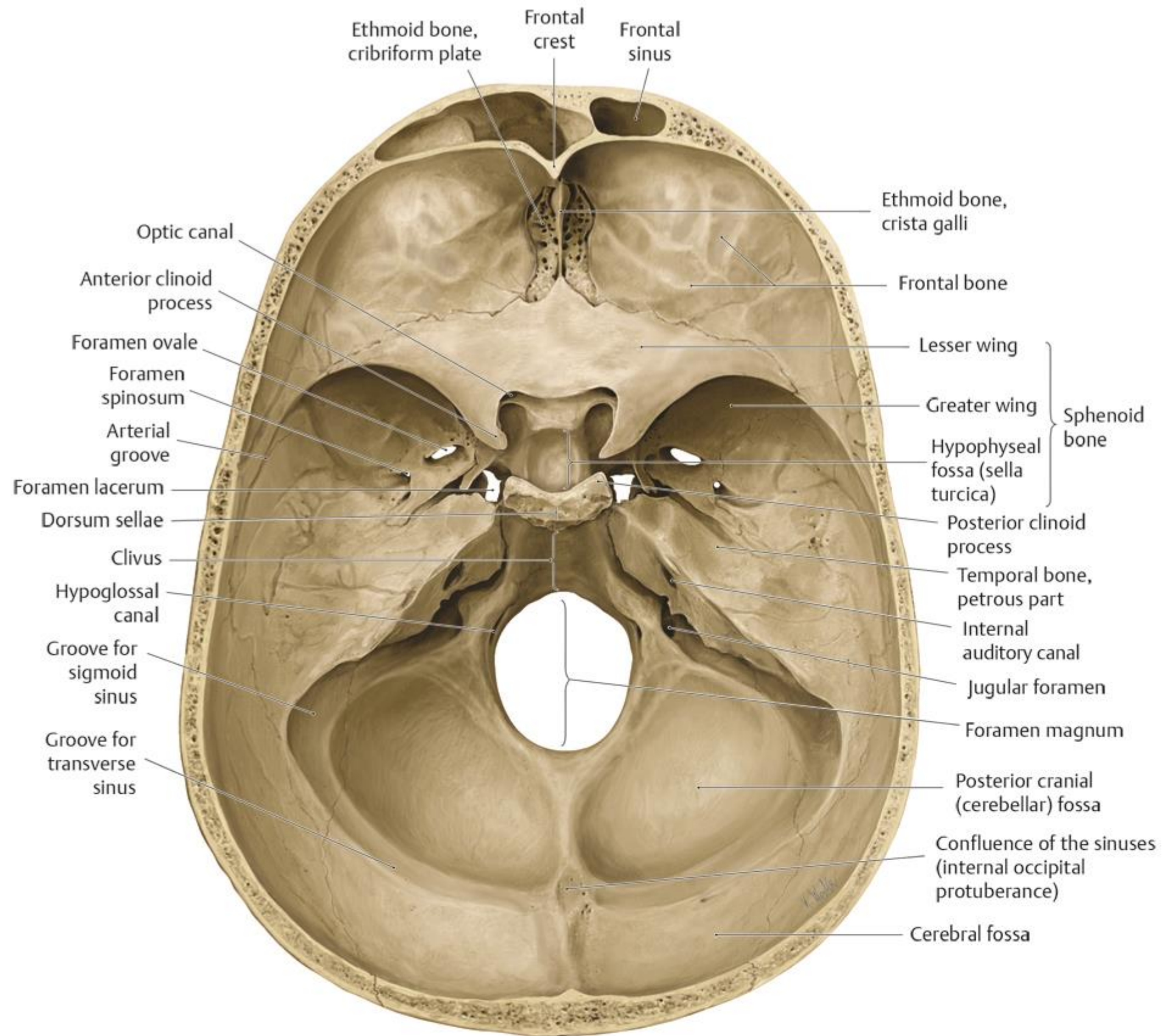
A koponyaalap sebészete

Dr. habil Nagy Gábor PhD

ORSZÁGOS MENTÁLIS, IDEGGYÓGYÁSZATI
ÉS IDEGSEBÉSZETI INTÉZET

„Ó, a formák sejtelmes varázsa!
 Kövülete istengondolta nyomnak! ...
 ... Titkos tartály, forrása jósigének,
 Méltó vagyok-e, hogy kezembe foglak?”

Goethe

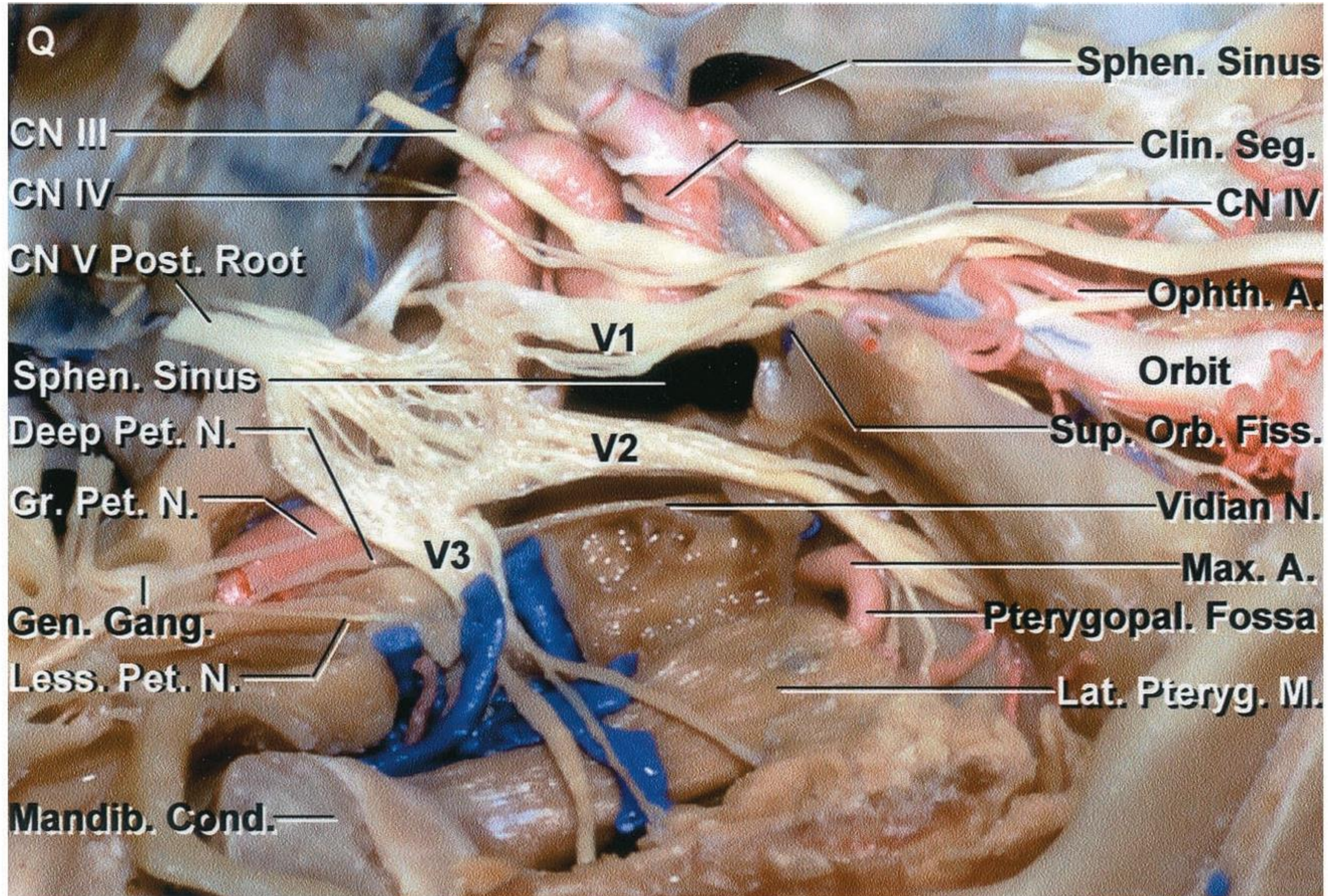


INTÉZ

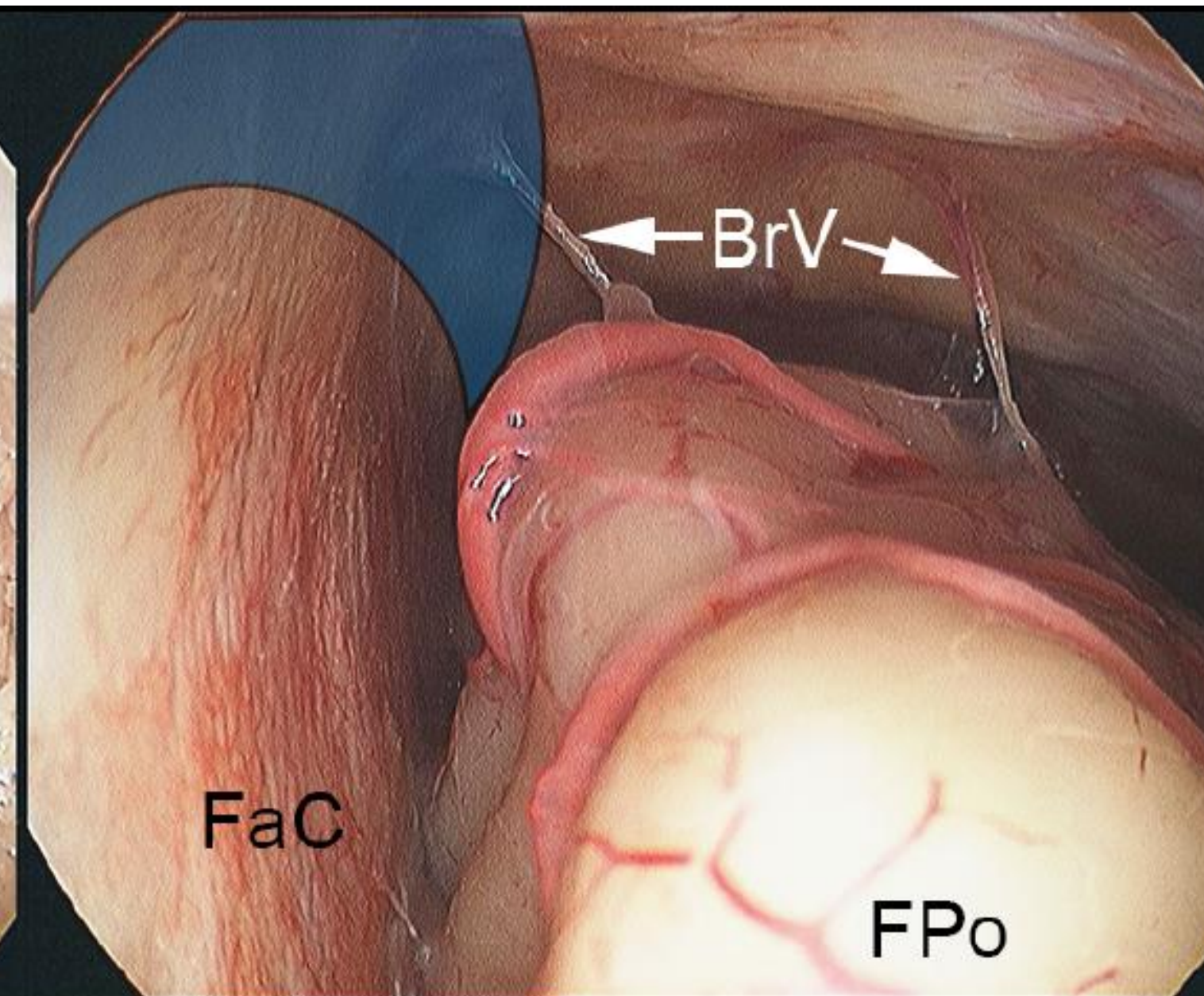
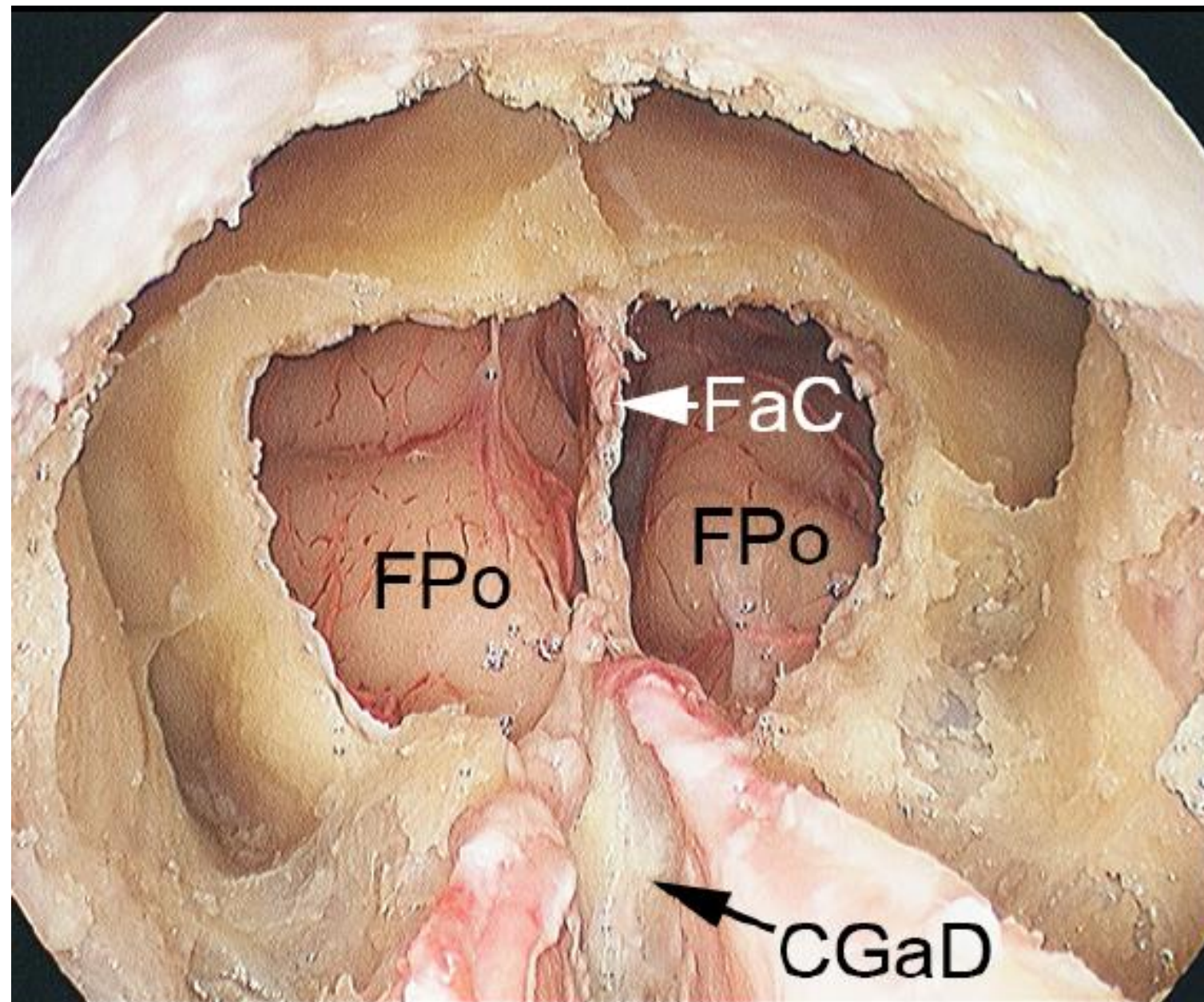
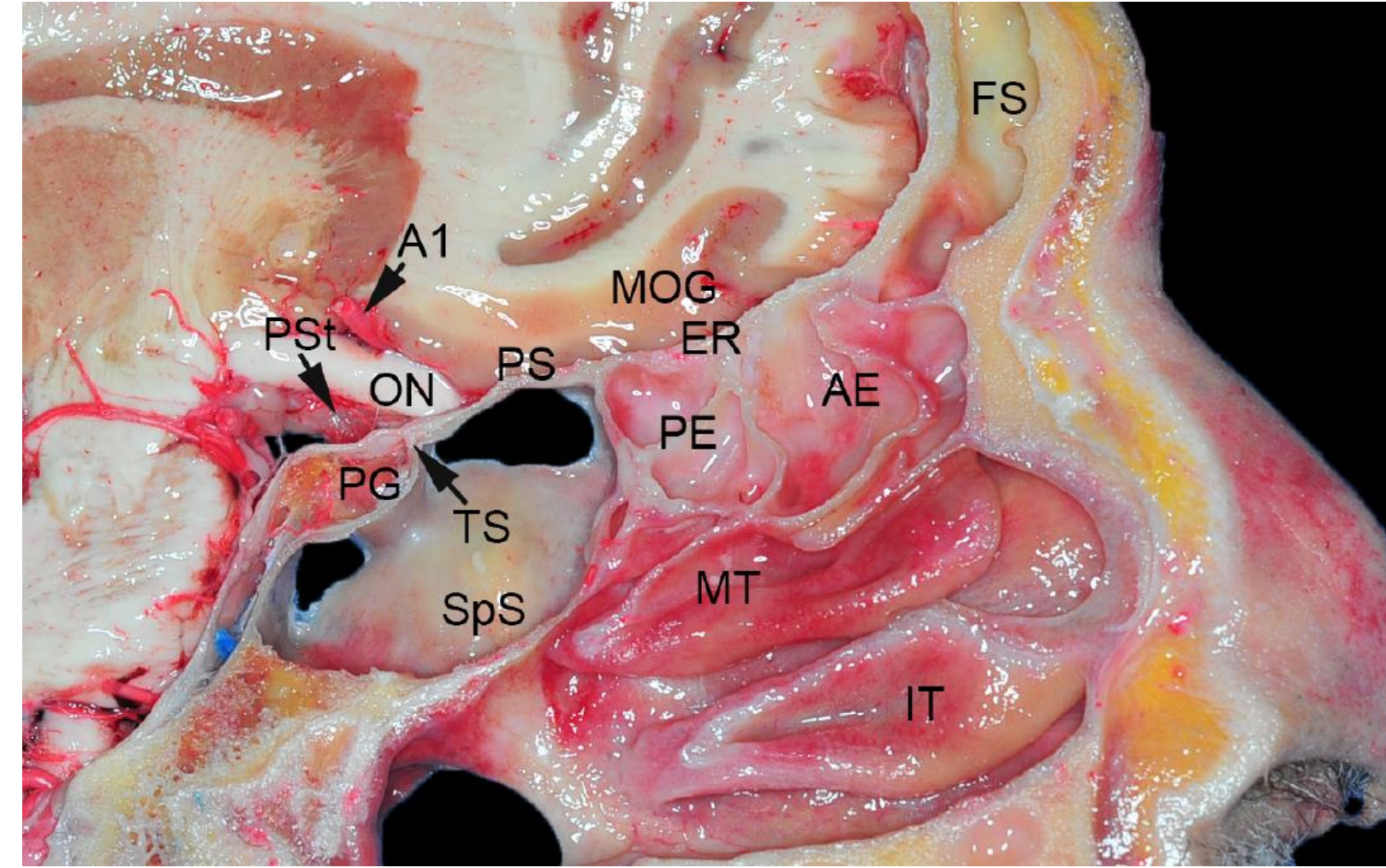
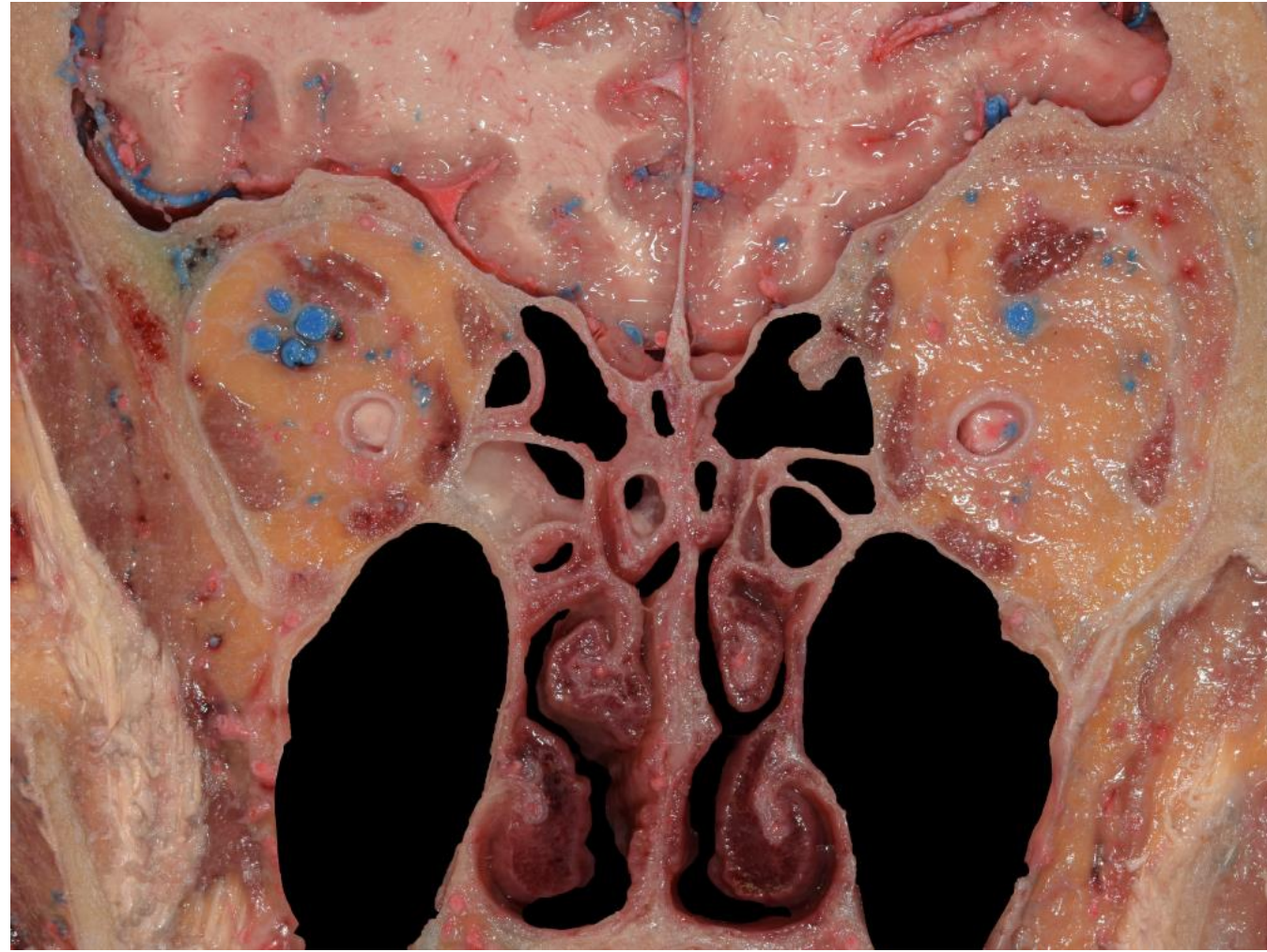b

a

Orbitacsúcs, Sinus Cavernosus és Fossa Media



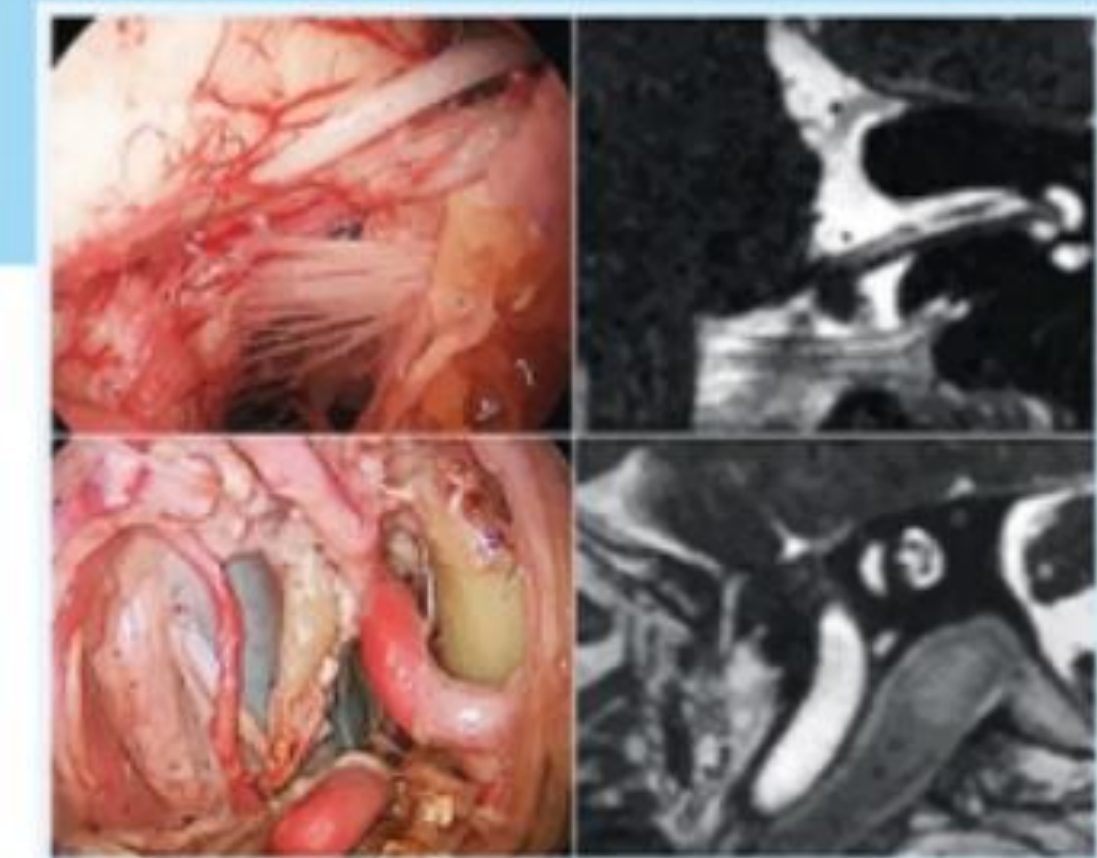
Orbita, Paranasalis Sinusok (360 fok!)



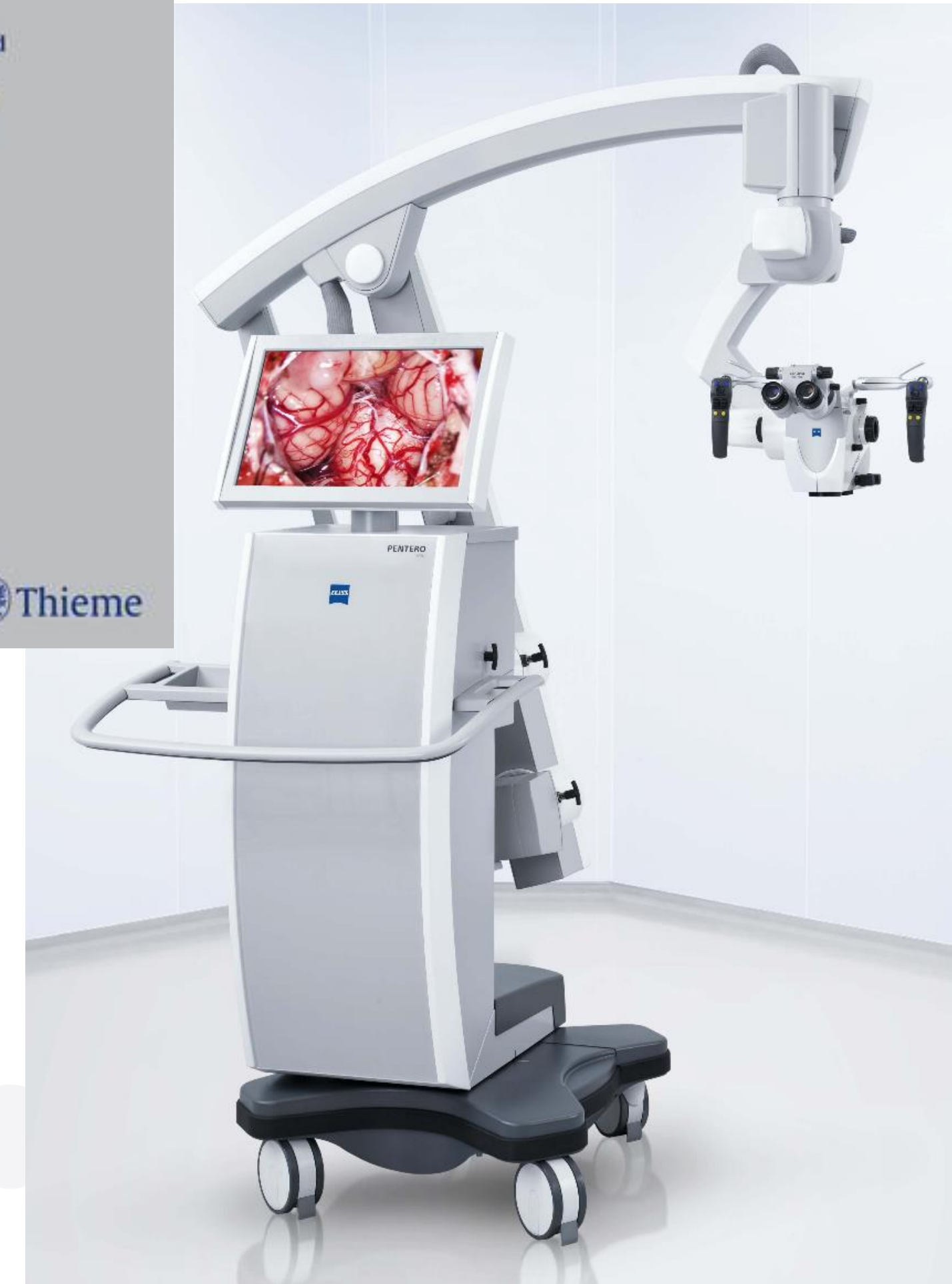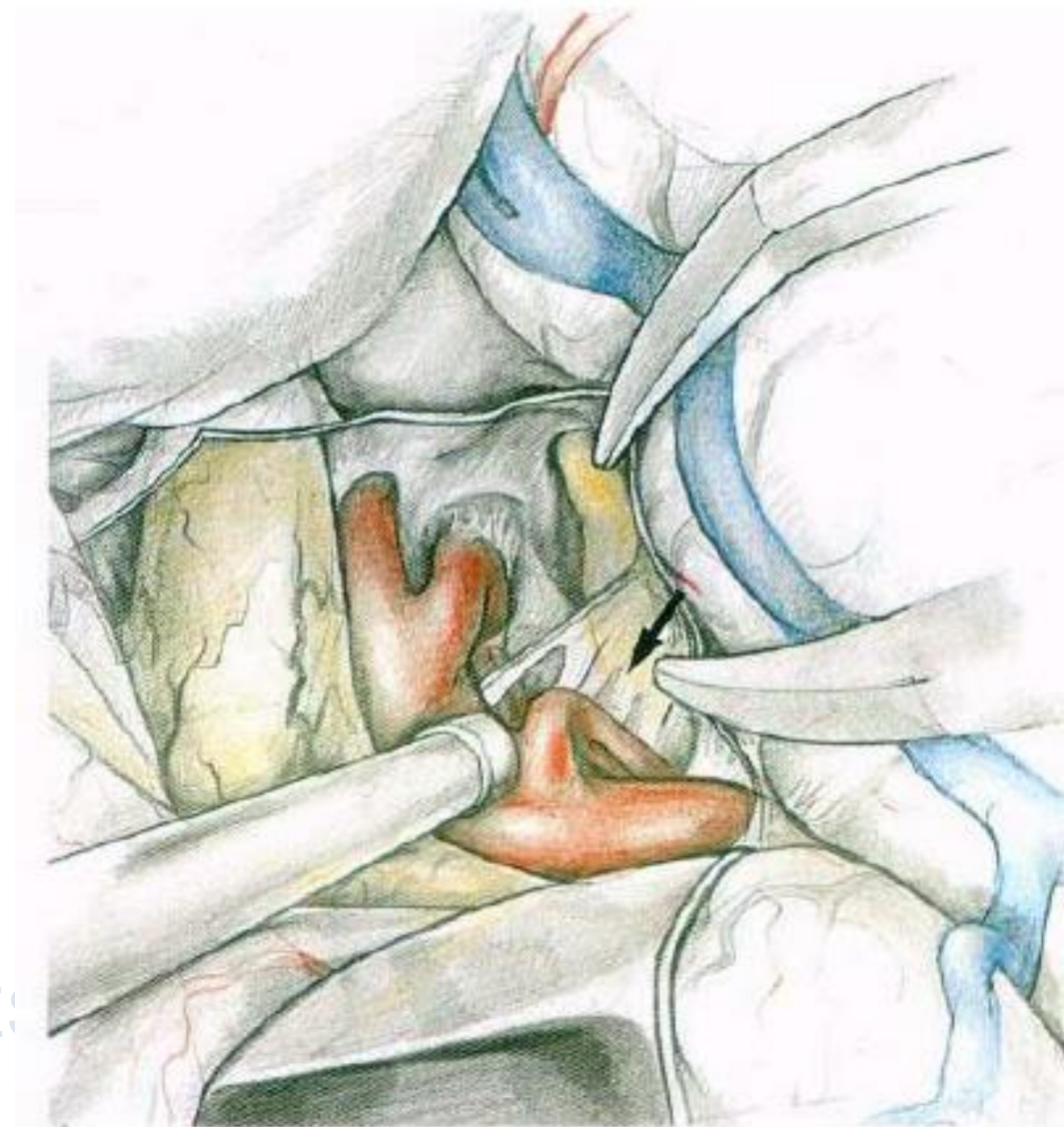
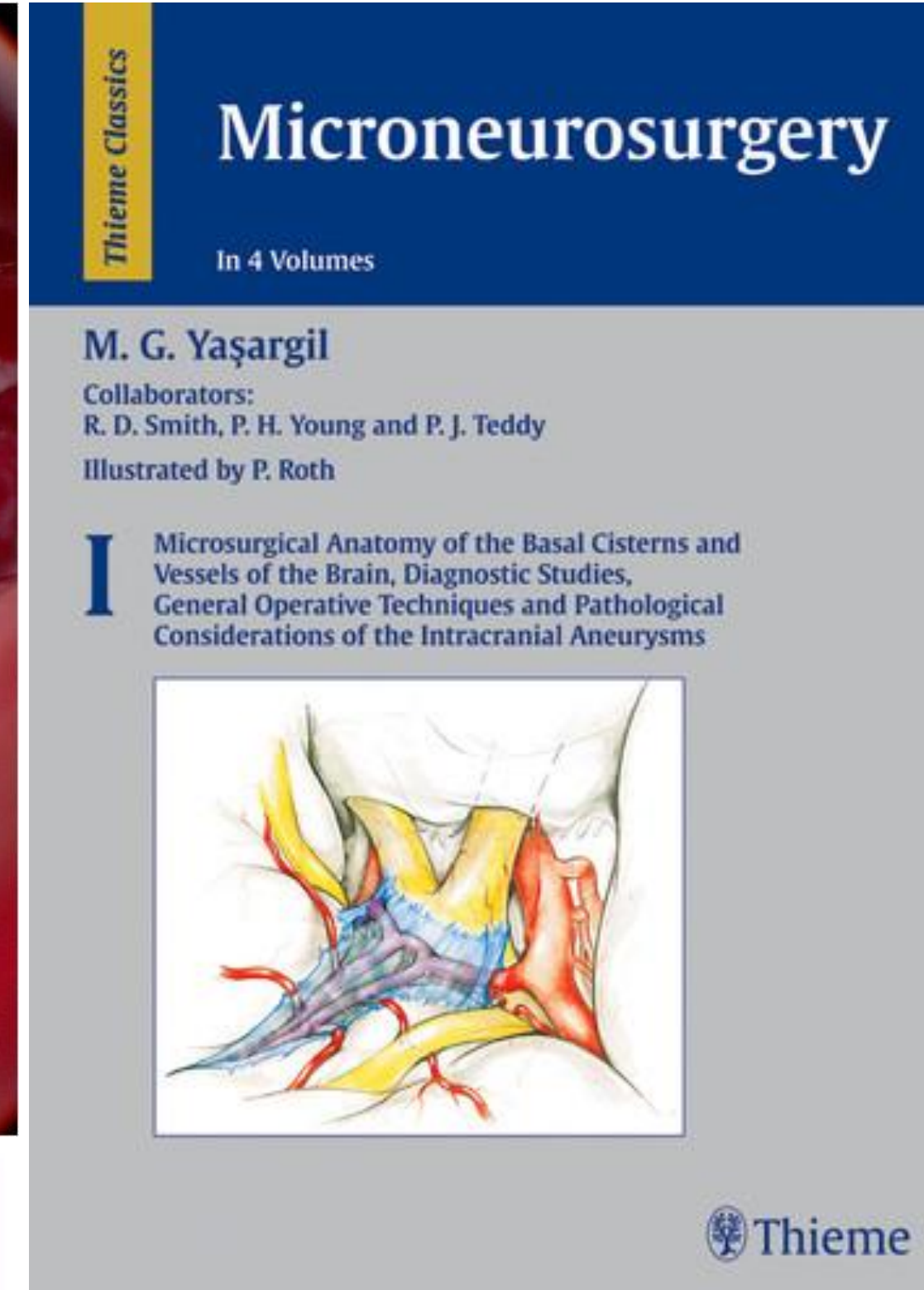
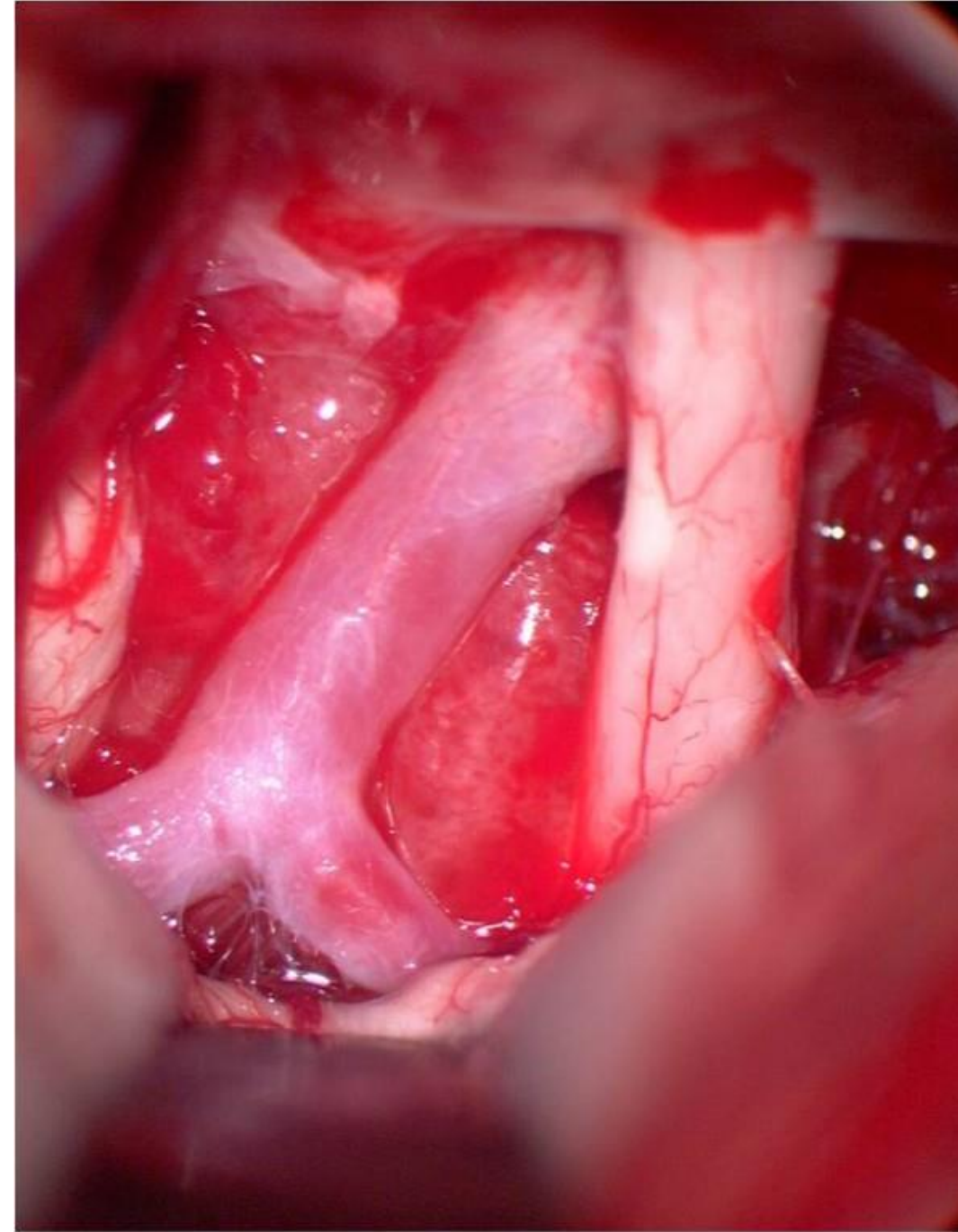

Endoscopic Transnasal Anatomy of the Skull Base and Adjacent Areas

A Lab Dissection and Radiological Atlas

Piero Nicolai
Marco Ferrari
Roberto Maroldi
Marco Maria Fontanella
Lena Hirtler
Manfred Tschabitscher
Luigi Fabrizio Rodella



A modern koponyaalapi sebészet: mikroszkóp



A modern koponyaalapi sebészet: „kulcslyuk” sebészet és neuroendoscop

LEGACY

Axel Perneczky: A Remembrance

J. André Grotenhuis, MD, PhD
Department of Neurosurgery,
Radboud University Medical Center,
Nijmegen, The Netherlands

Alan R. Cohen, MD
Division of Pediatric Neurosurgery,
The Neurological Institute,
Rainbow Babies and Children's
Hospital,
Case Western Reserve University
School of Medicine,
Cleveland, Ohio

Reprint requests:
Alan R. Cohen, MD
Division of Pediatric Neurosurgery,
Rainbow Babies and Children's
Hospital,
11100 Euclid Avenue,
Room B-501,
Cleveland, Ohio 44106.
E-mail: alan.cohen@uhhs.com

Received, September 28, 2009.
Accepted, November 22, 2009.

Copyright © 2010 by the
Congress of Neurological Surgeons

KEY WORDS: Minimally invasive neurosurgery, Keyhole surgery, Microneurosurgery, Neuroendoscopy, Perneczky

Neurosurgery 66:1036-1038, 2010

DOI: 10.1227/01.NEU.0000369185.36188.12

www.neurosurgery-online.com

*I saw the angel in the marble and carved
until I set him free.*

Michelangelo

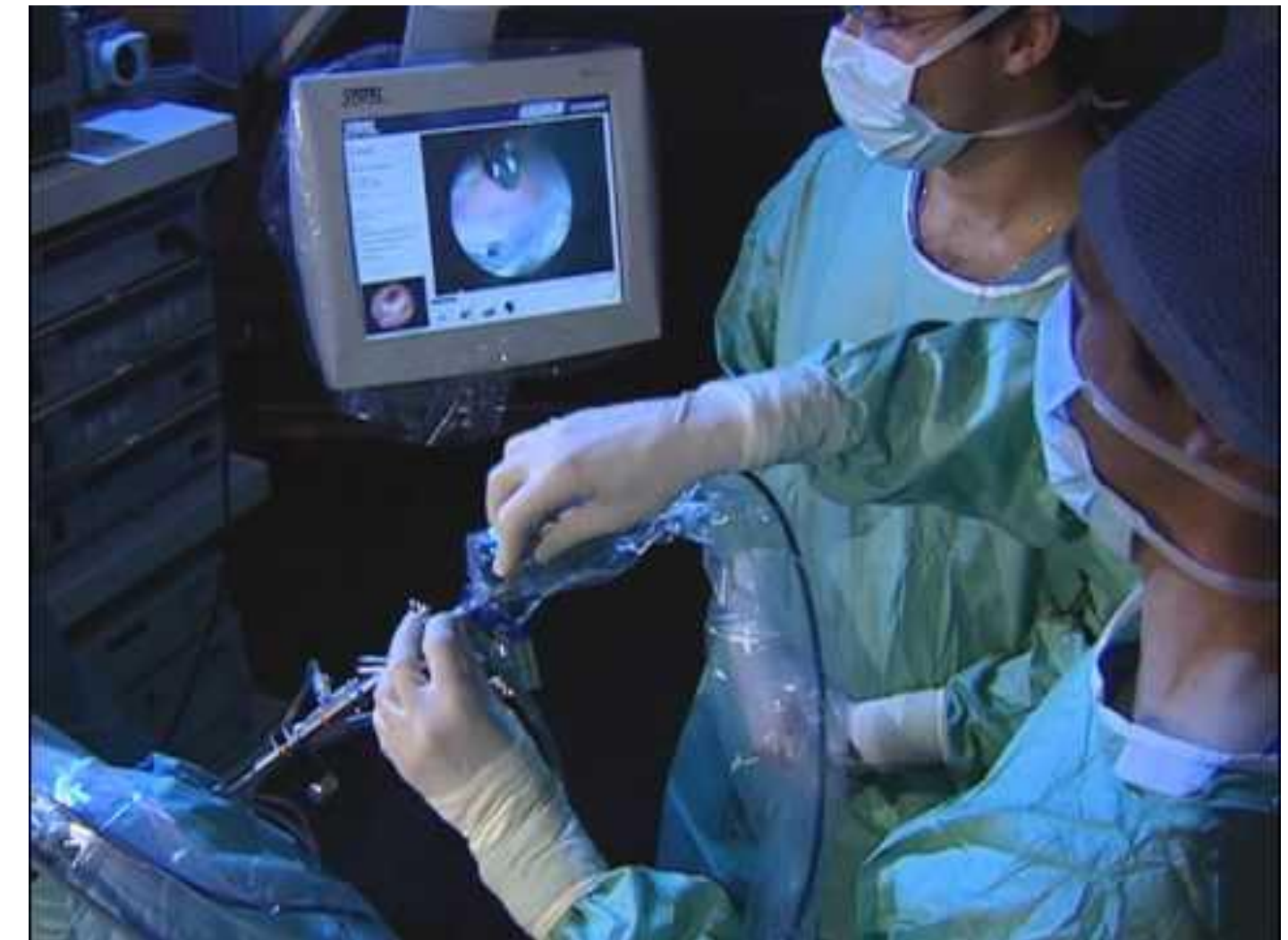Axel Perneczky died suddenly and unexpectedly on January 24, 2009, at his home near Mainz, Germany (Figure 1). He was 63 years old. With his passing, the world has lost a great man, a visionary leader, a pioneering scientist, a courageous neurosurgeon, and a kind-hearted mentor whose grateful globe. Like Michelangelo, Perity to see much that was not and to use his able mind and the future. If the tools to car not exist, he invented new on sionately and relentlessly to surgery safer and more effect His unique surgical talents enthusiasm led him to becom behind the modern era of neurosurgery.

Perneczky was born on No a prison camp near Mosco Russia. His father, an offic army in World War II, died His mother, a well-known H based in Berlin during the wa nogorsk, where she was con prison. Perneczky was extrem undernourished after his b female prisoners helped care ulously, he survived. When h they were set free, and his n him over the harsh terrain of sula along the northern coast Odessa and ultimately back

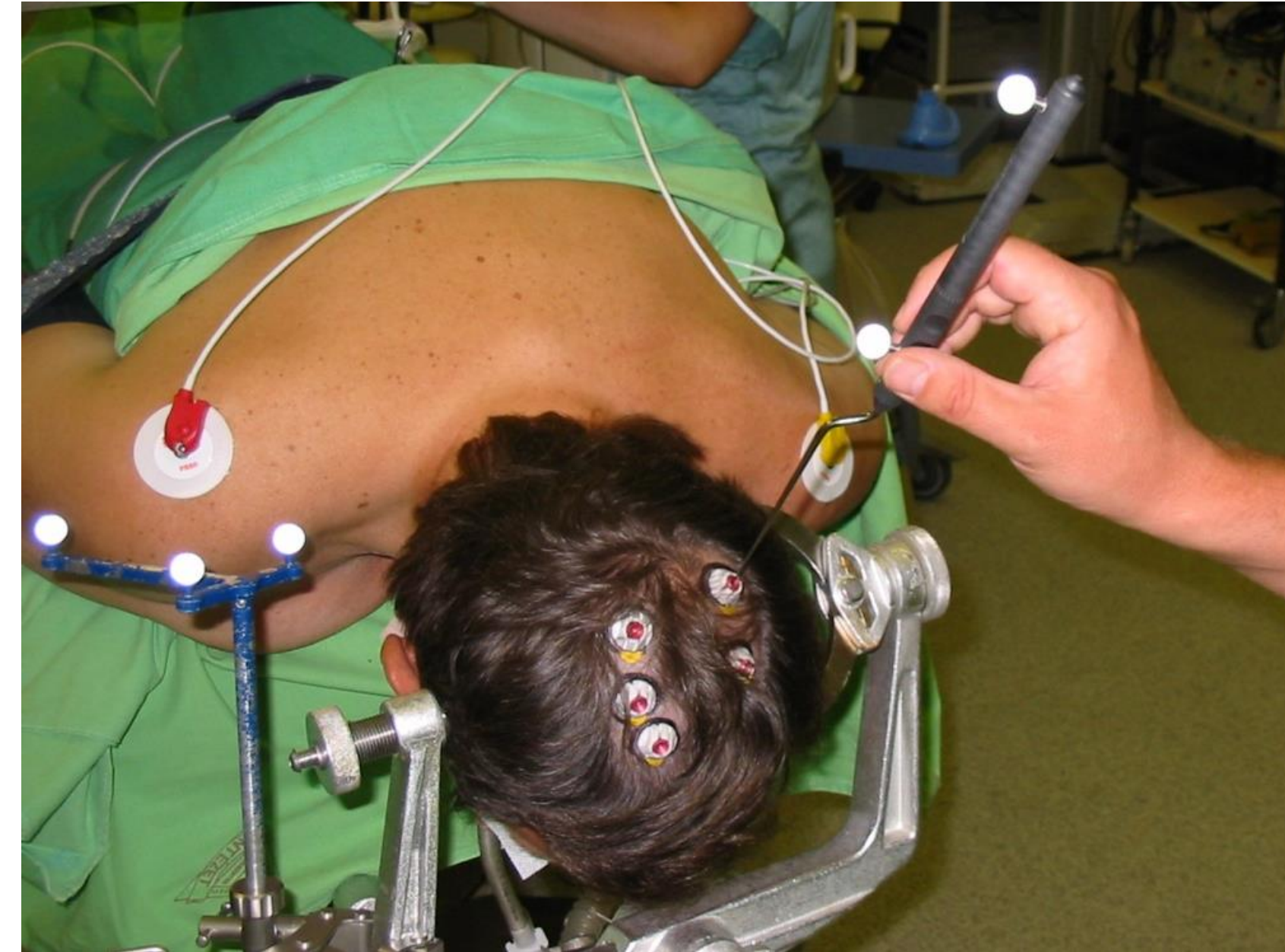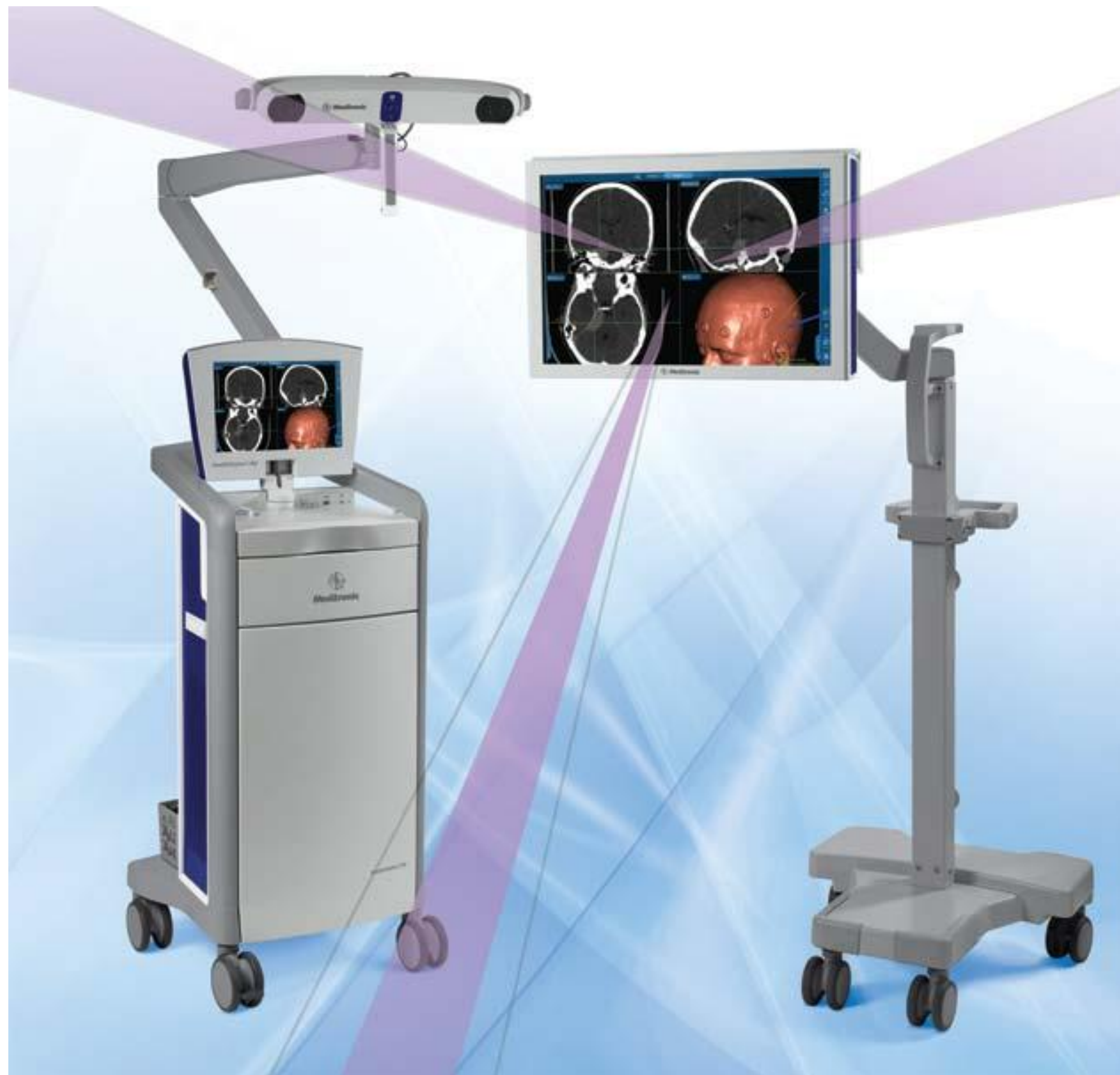Perneczky grew up under r of his mother in Budapest a young age that he would beco icine. His mother remarried son, Gideon ("Gida"), Axel who also went on to becom practicing in Vienna.


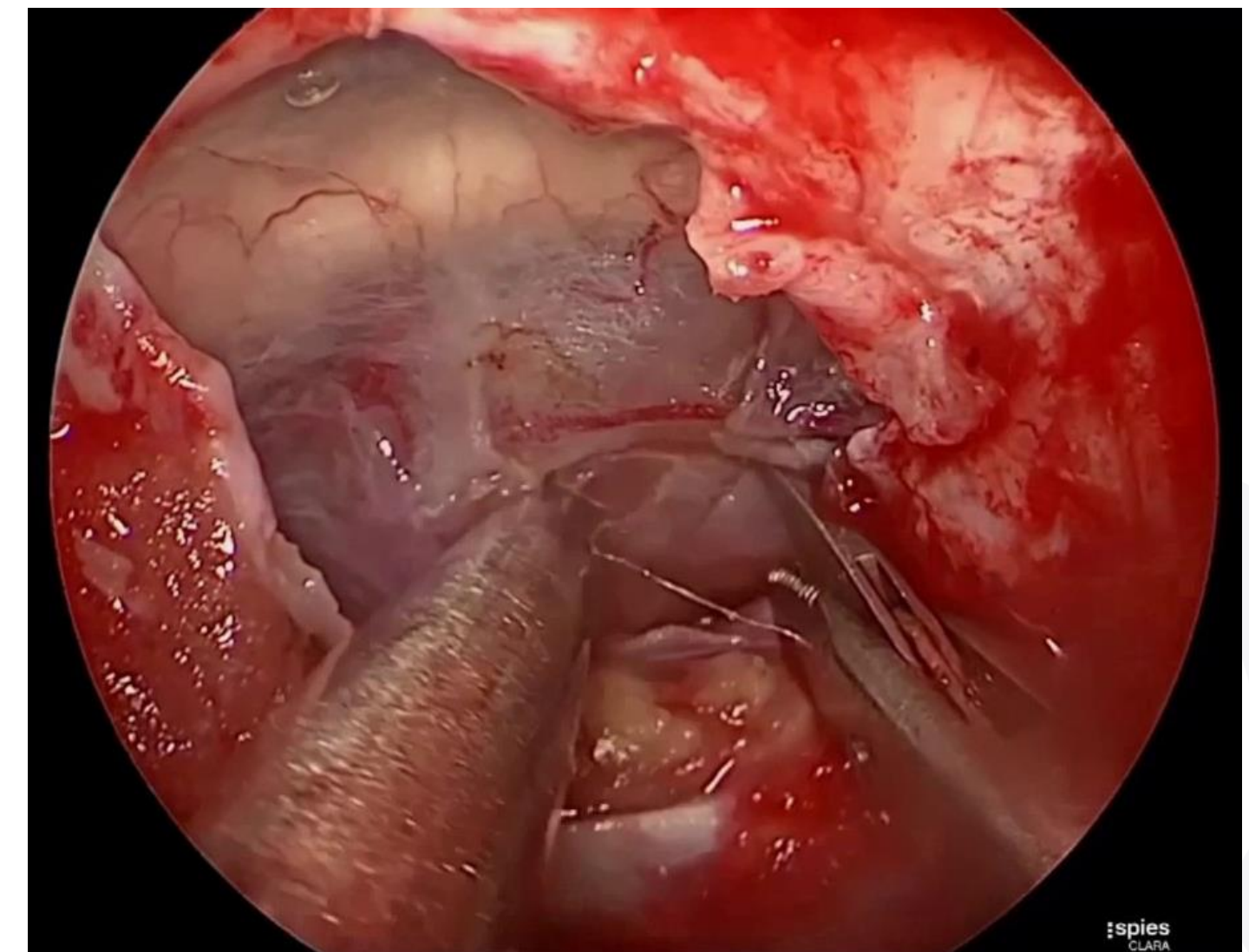
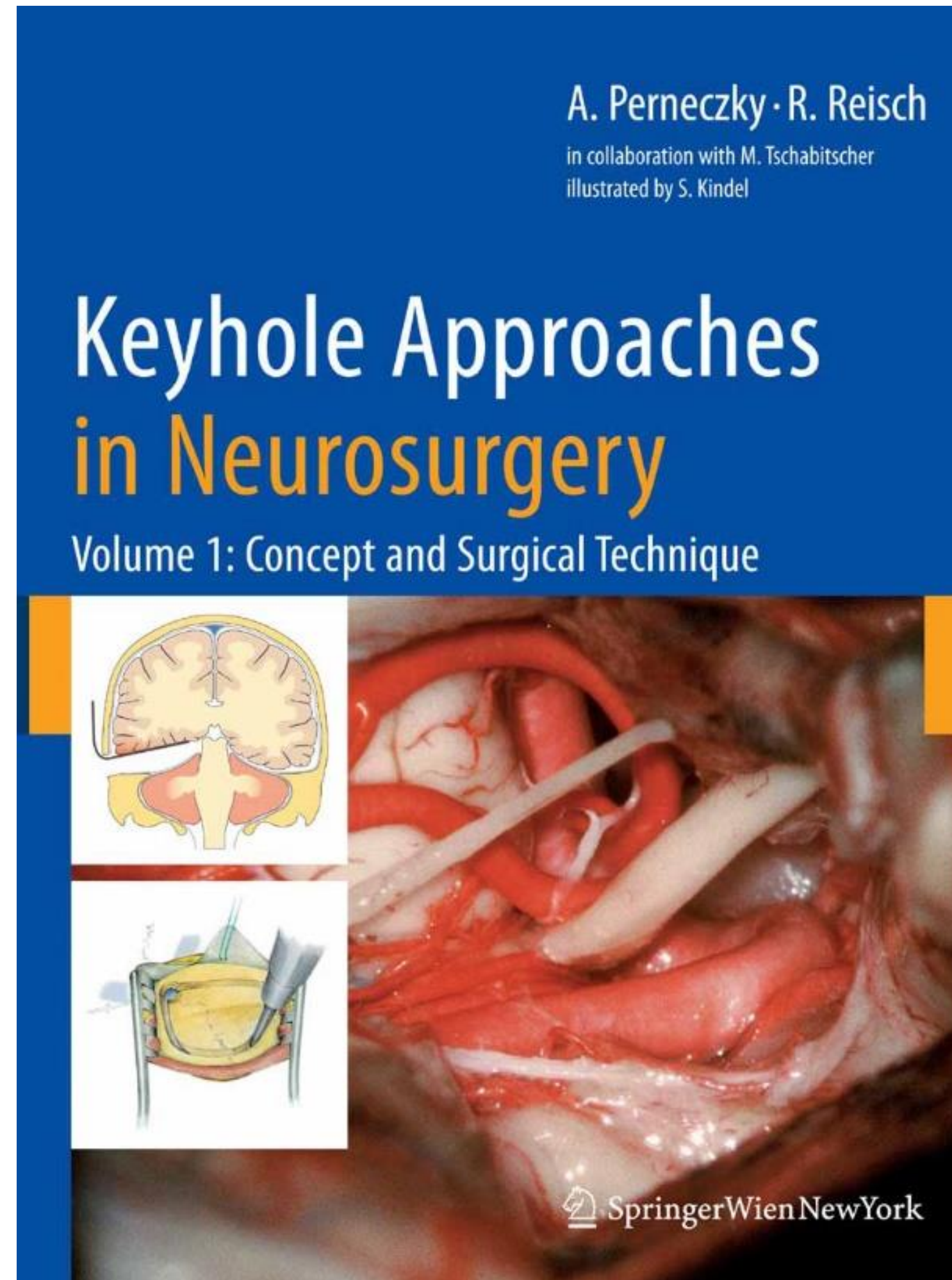
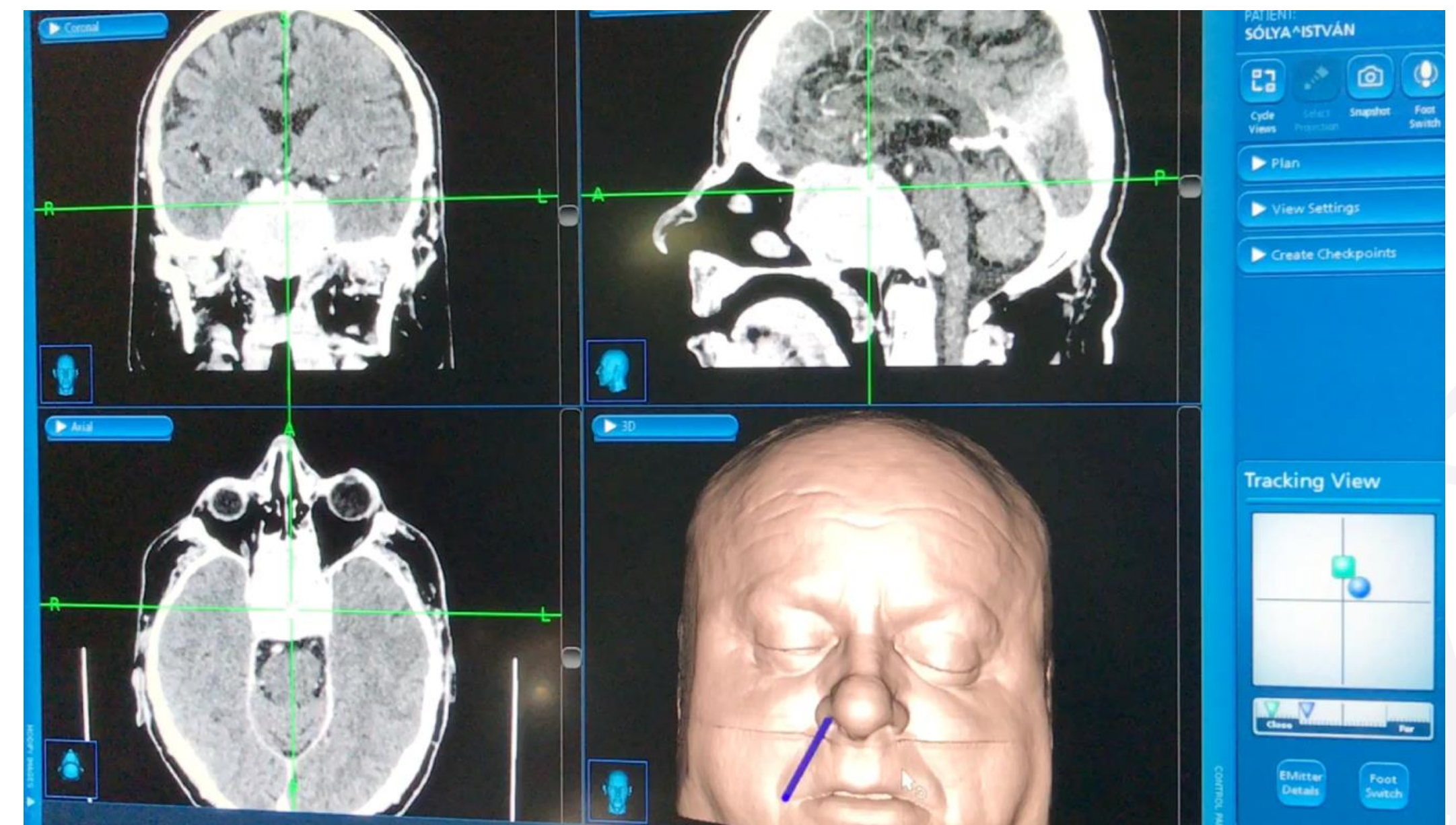


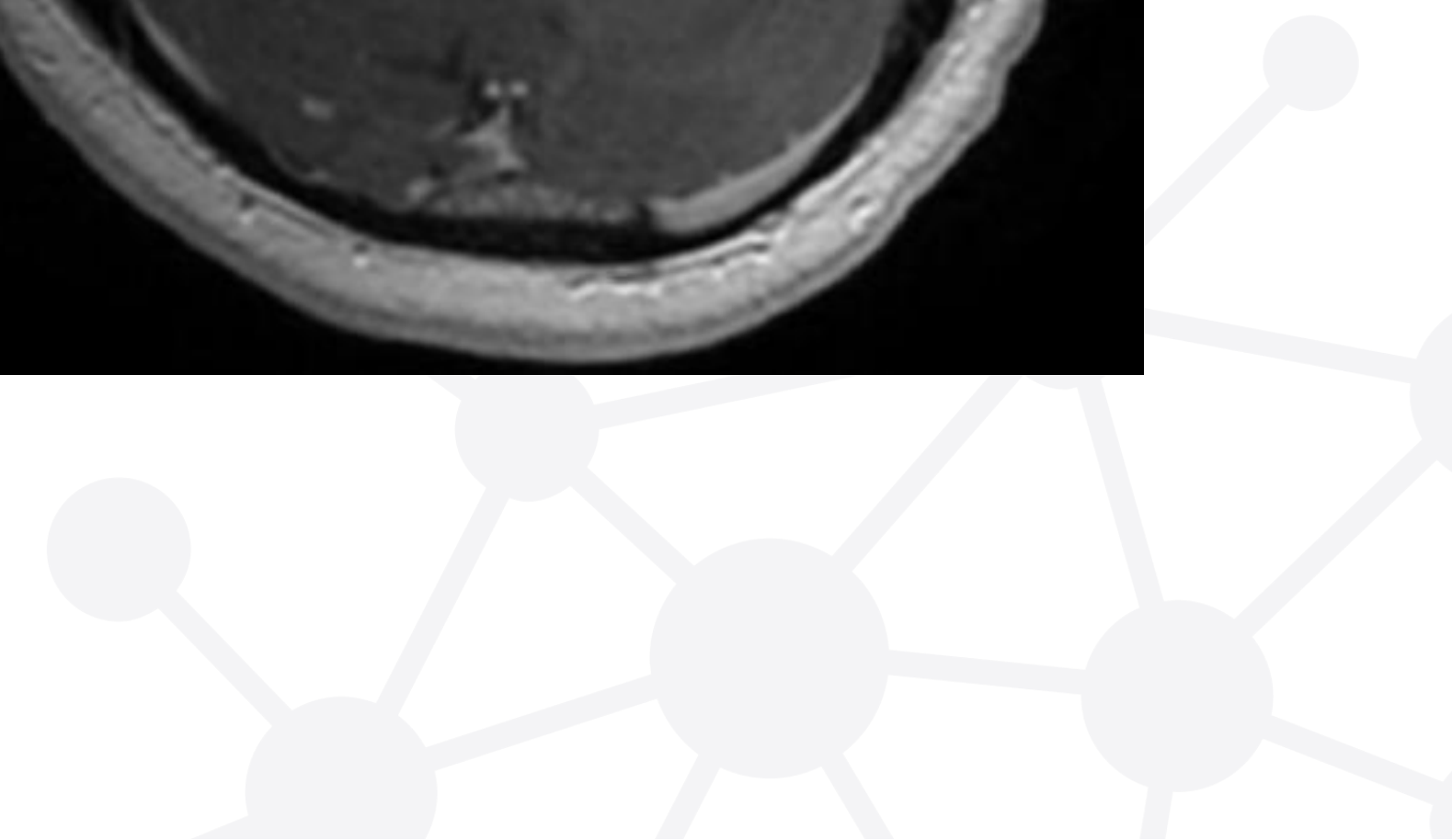
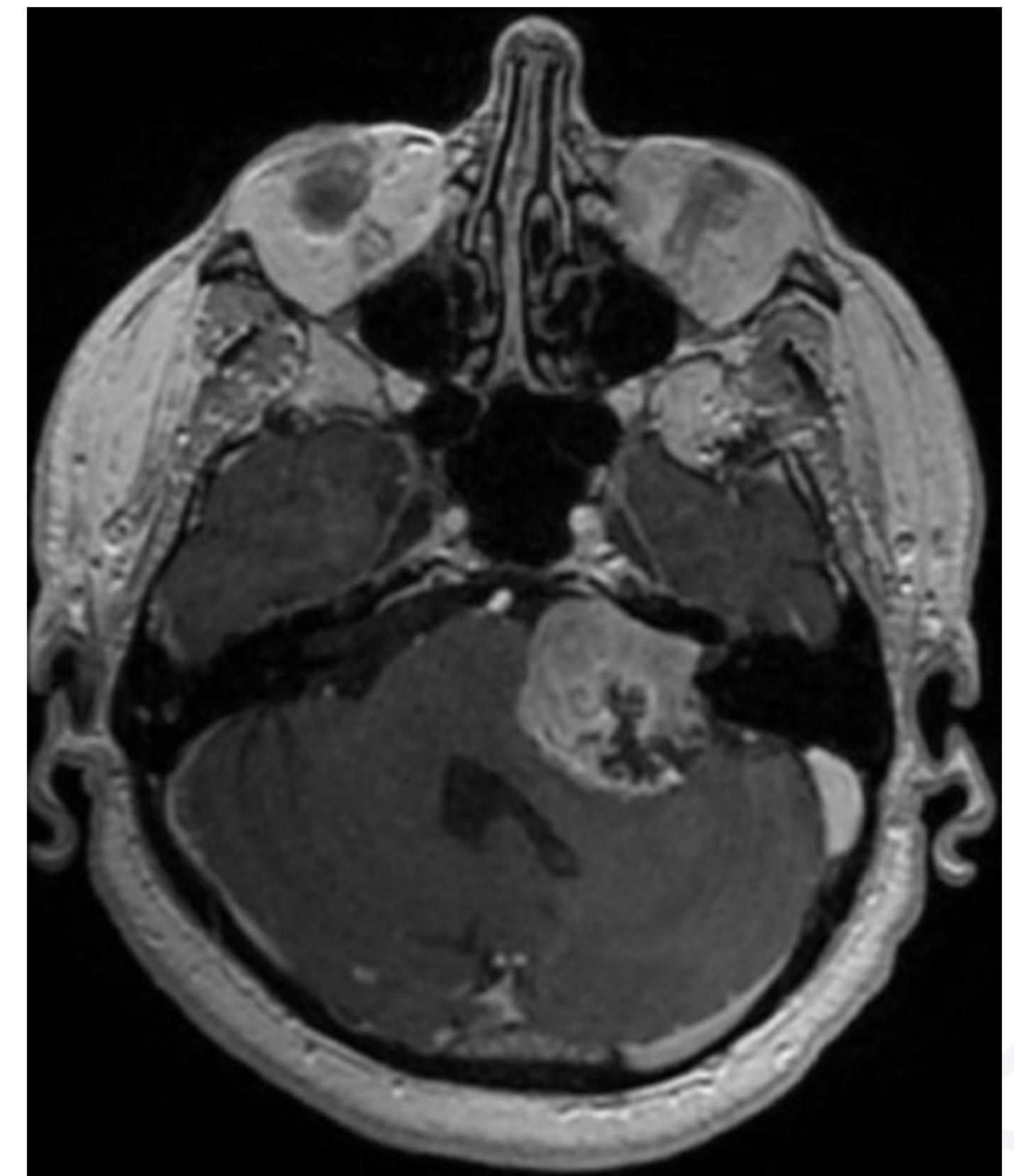
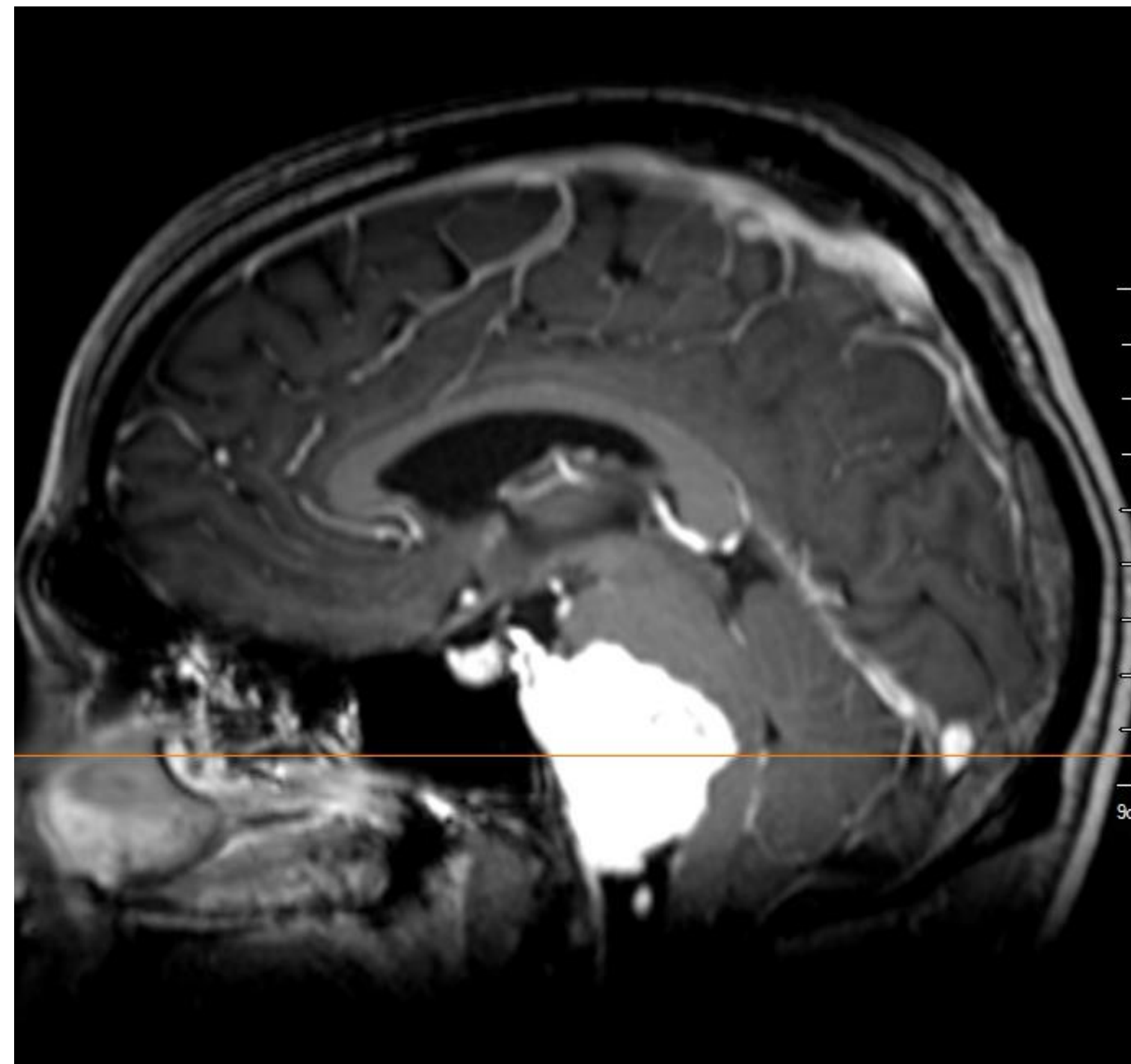
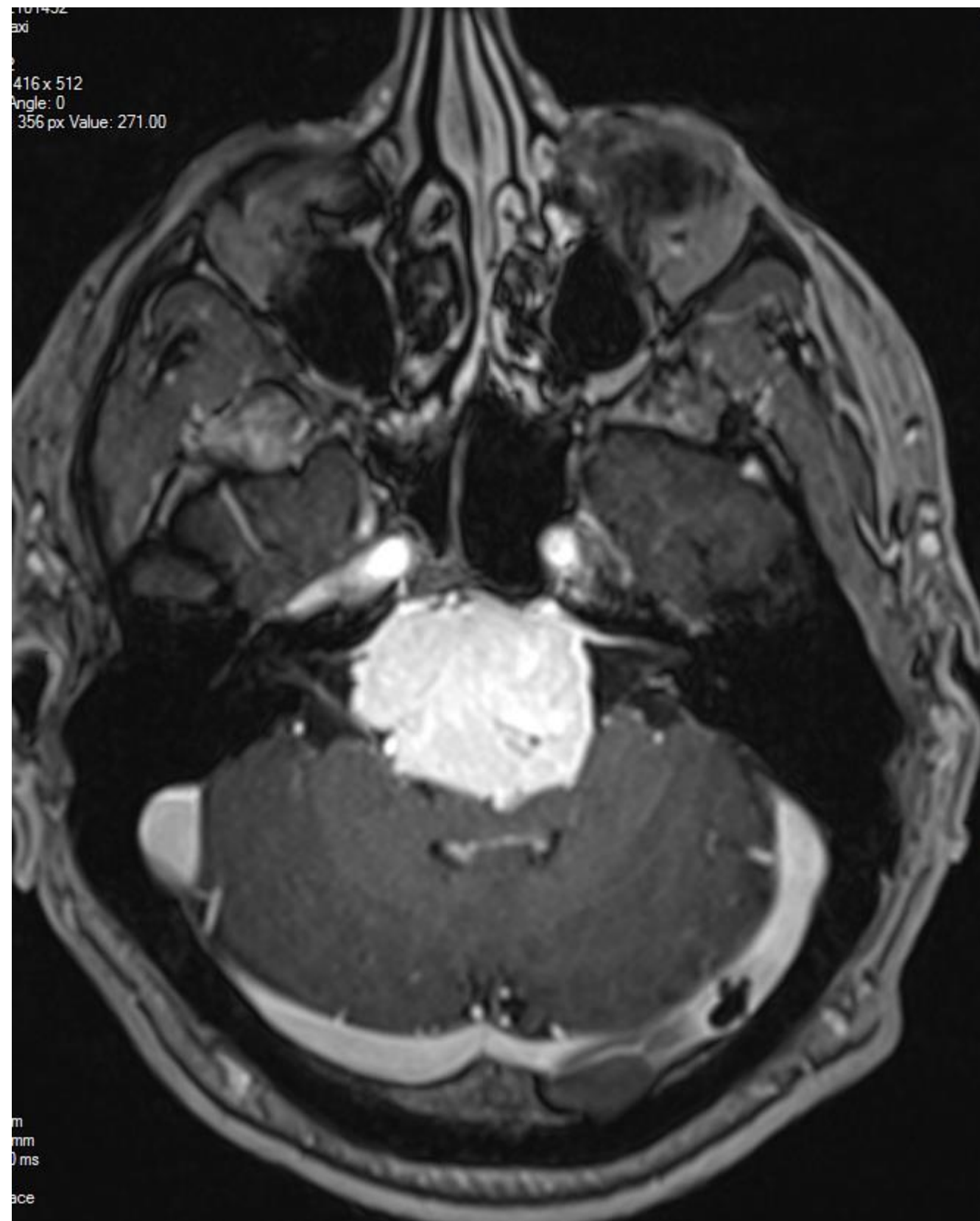
FIGURE 1. Axel Perneczky, November 1, 1945-January 24, 2009.



Neuronavigáció



Intraoperatív elektrofiziológia





Társszakmák szerepe Think Multidisciplinar!

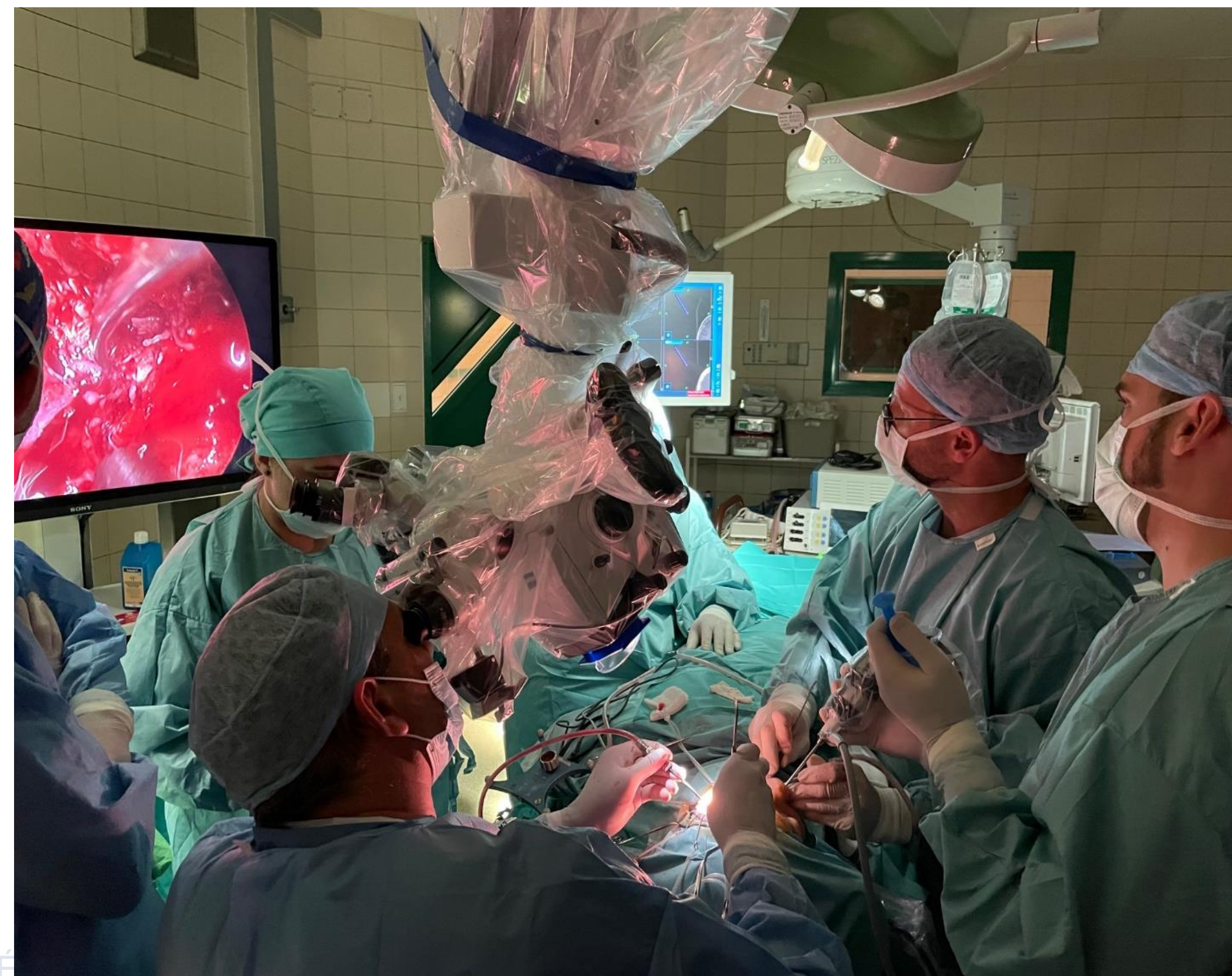

➤ A sebészi team

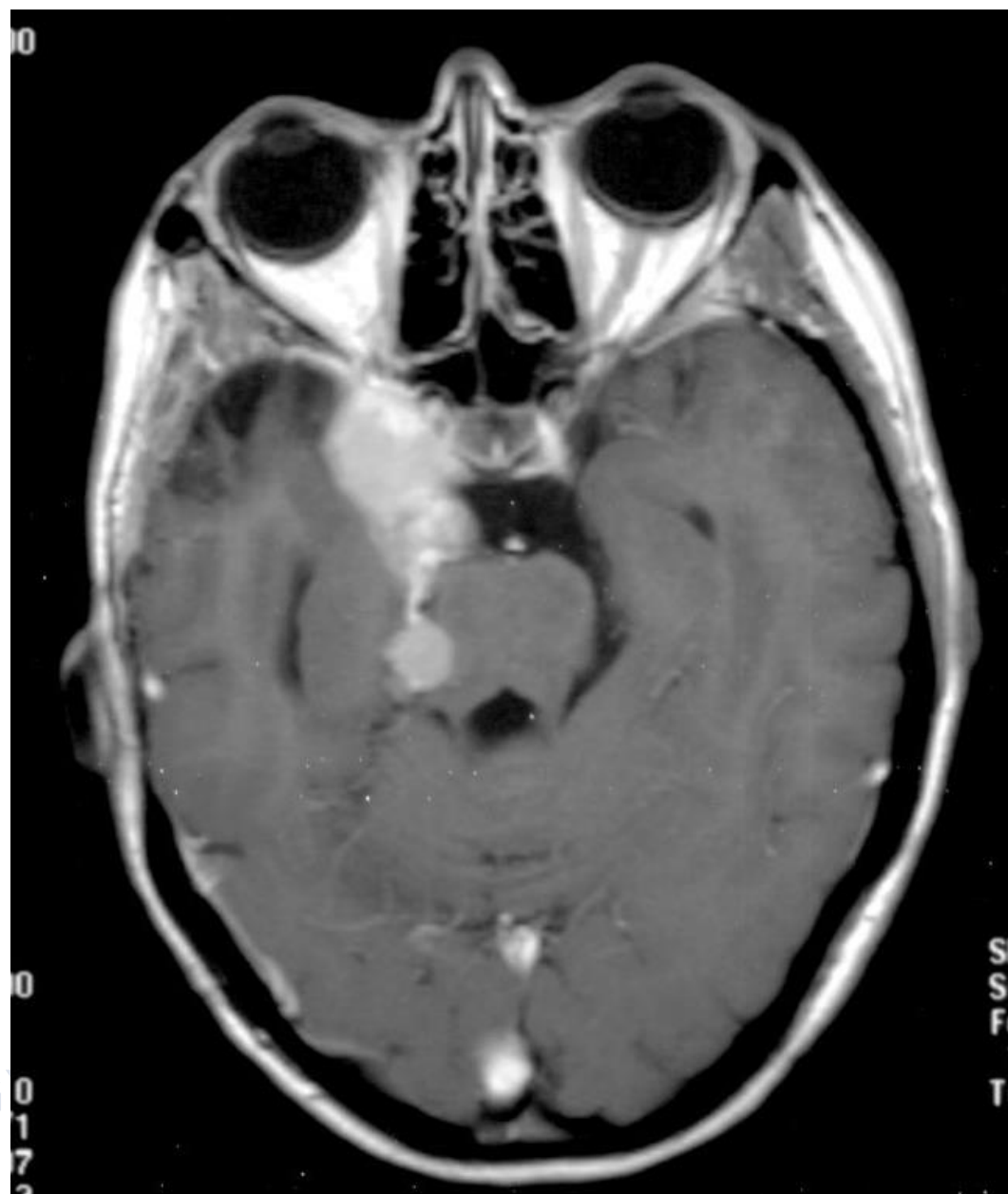
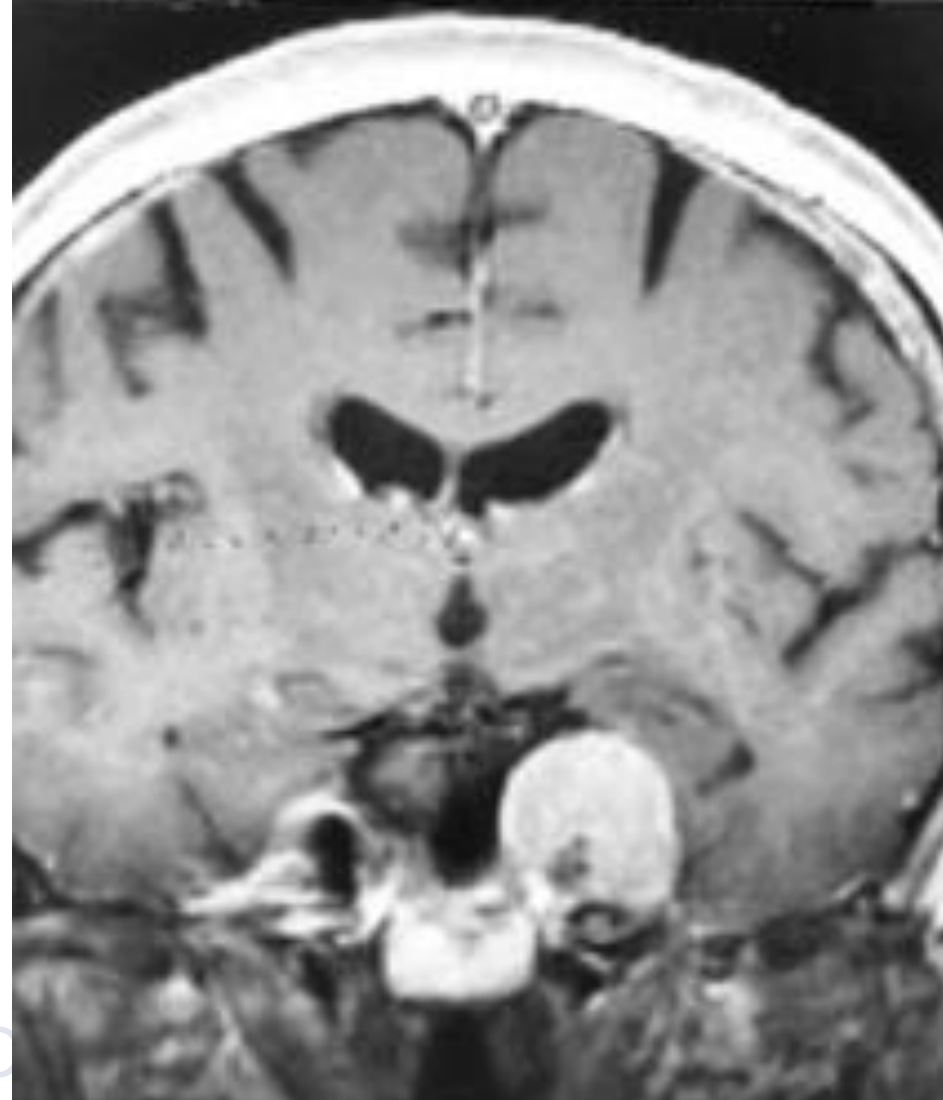
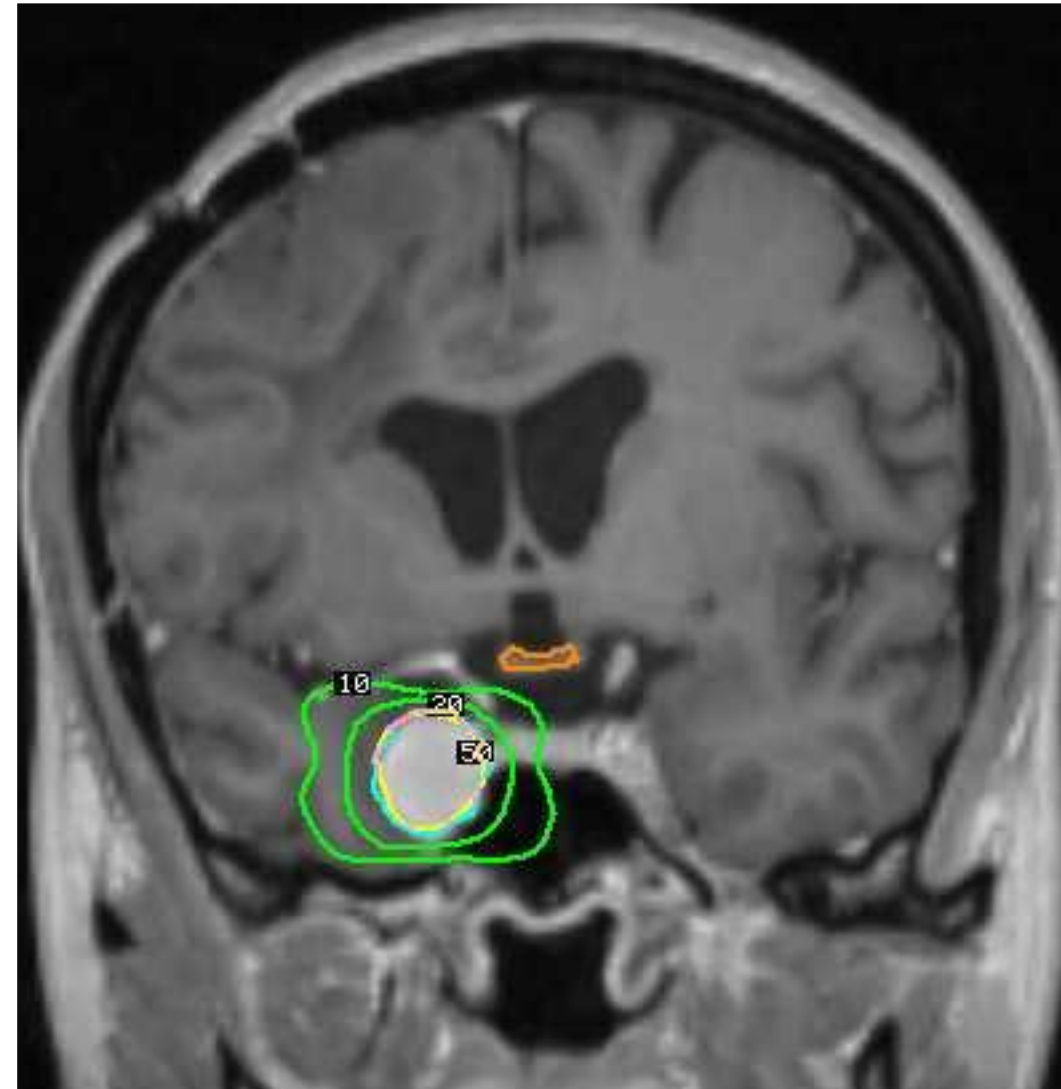
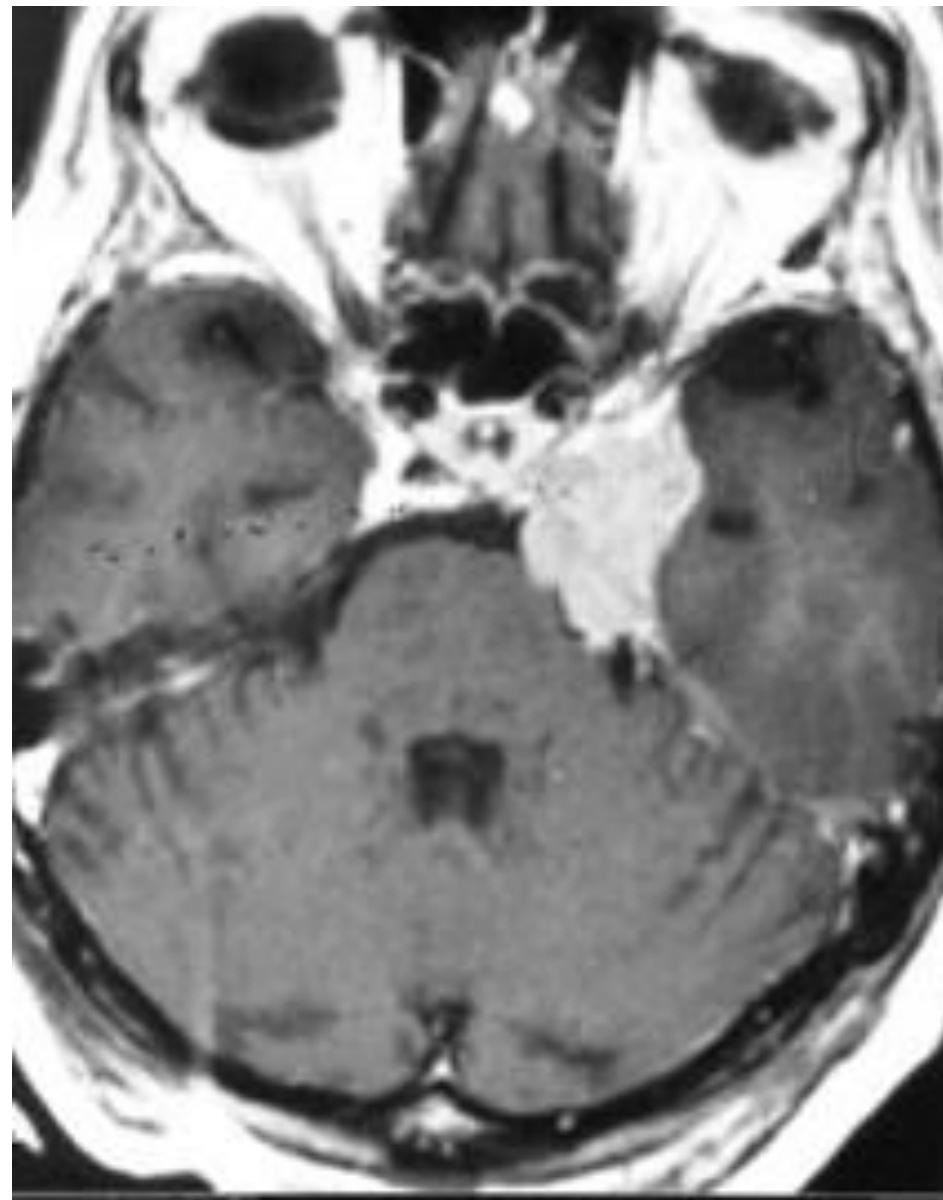- Idegsebész (mikroszkóp, endoscop)
- Fül-orr-gégész (endoscop)
- Fej-nyak sebész (rekonstrukció)
- Orbitasebész

➤ Társszakmák

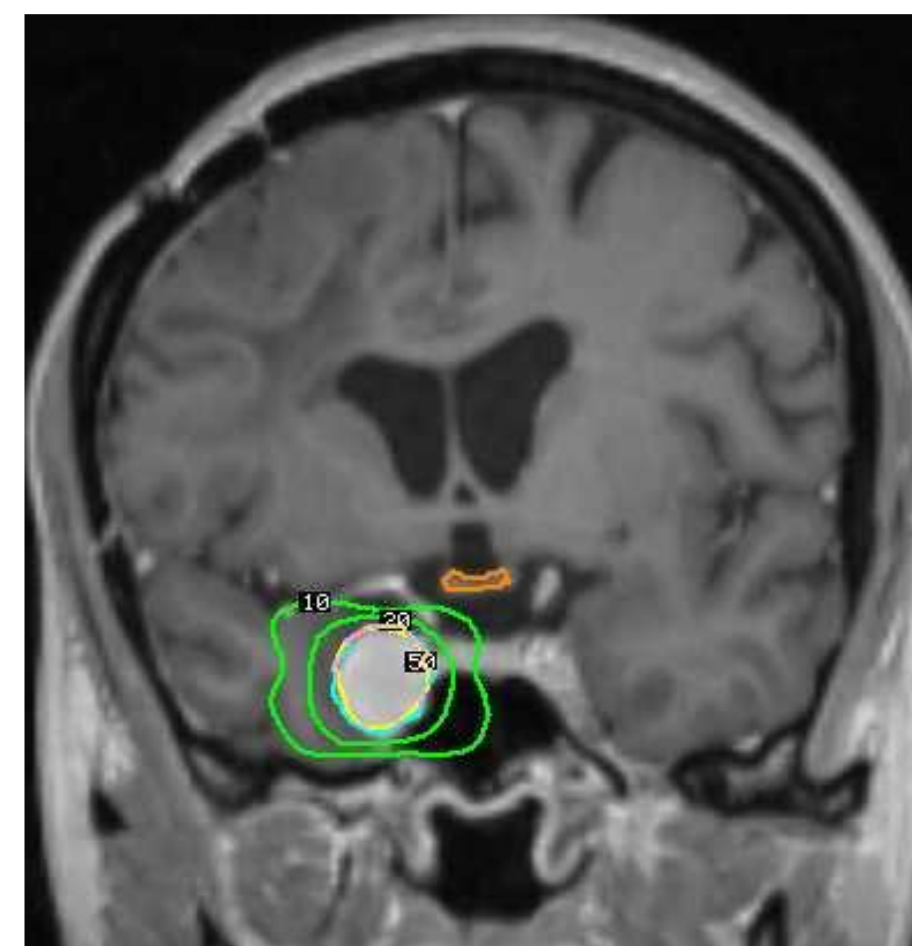
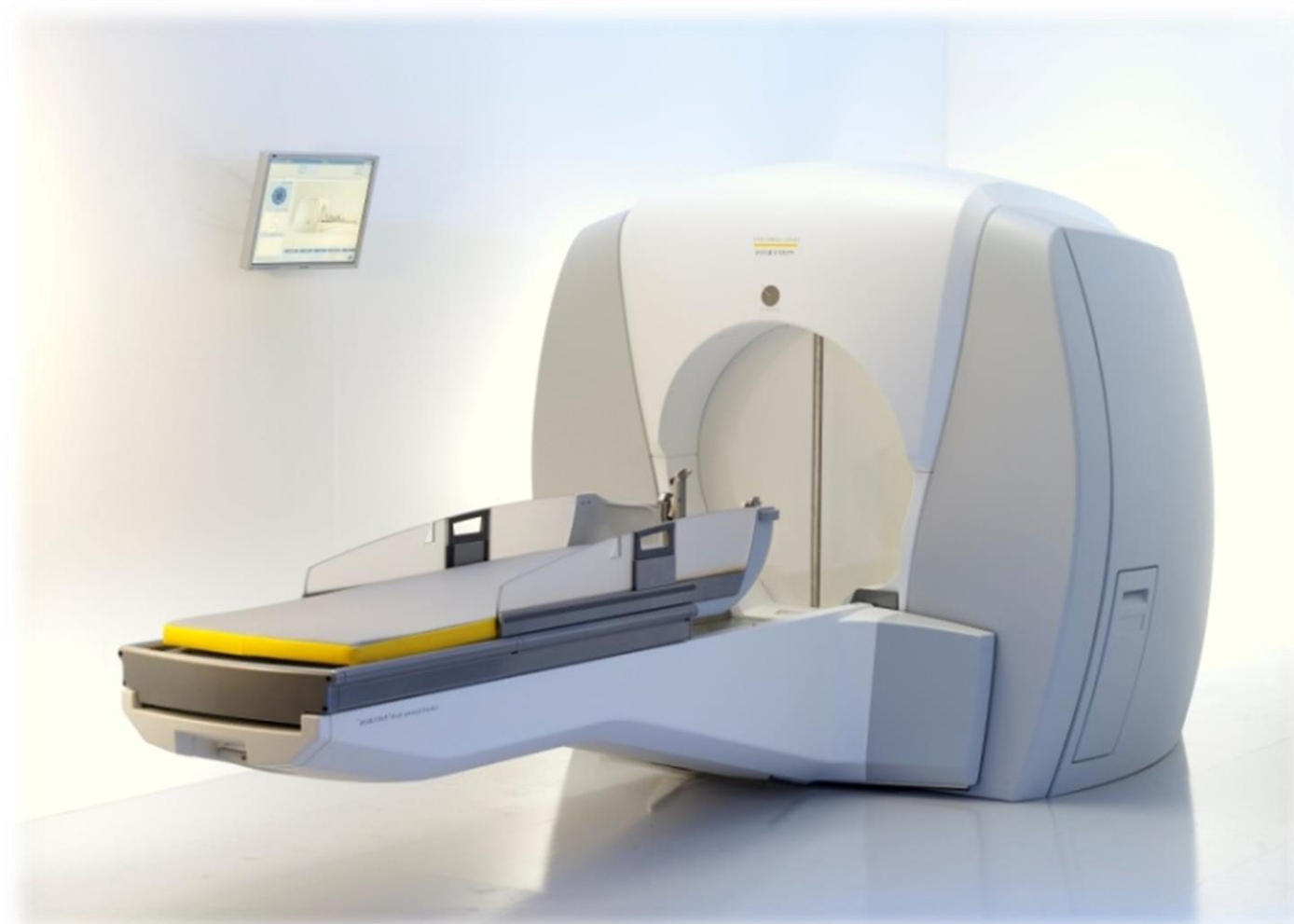
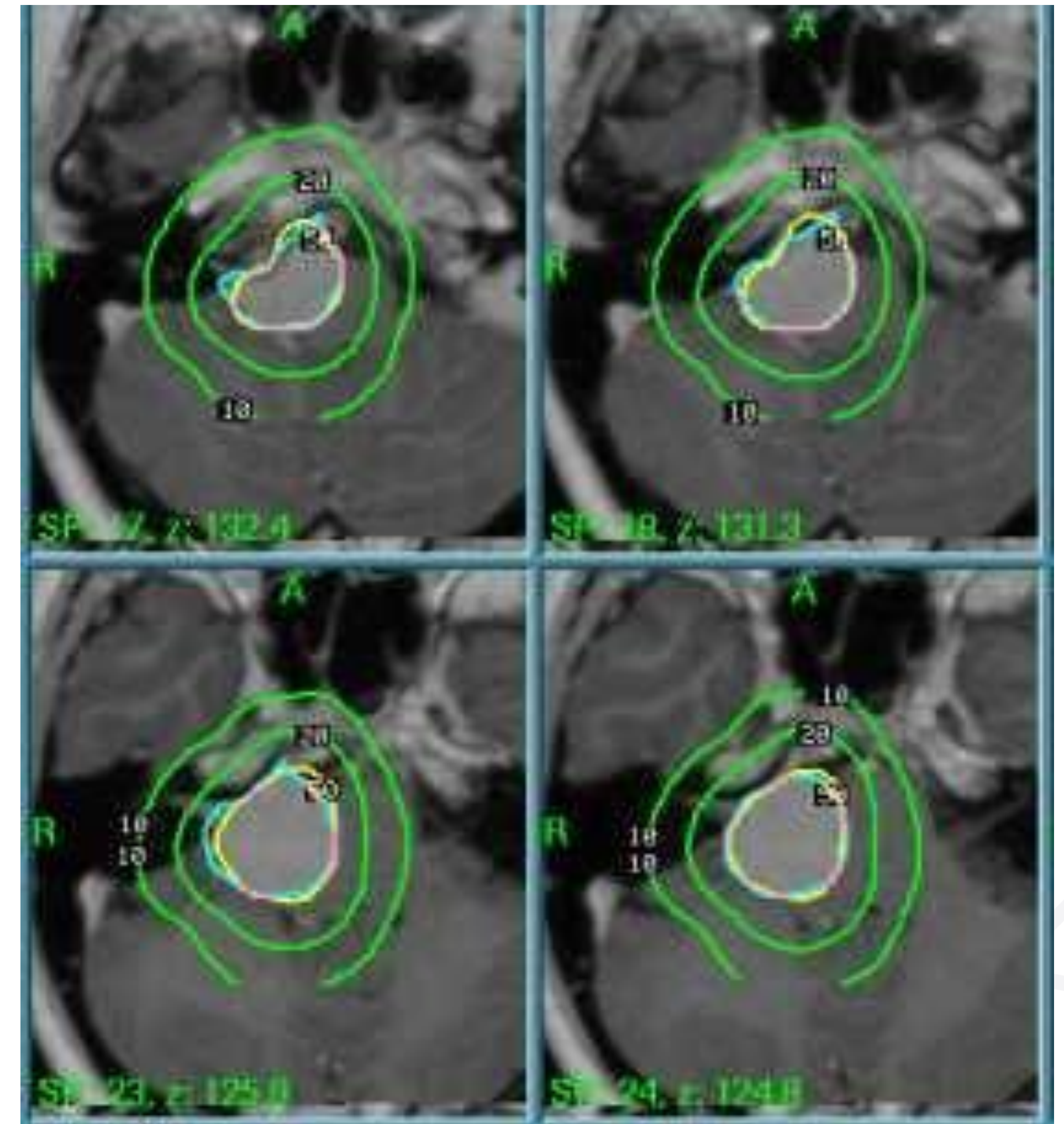
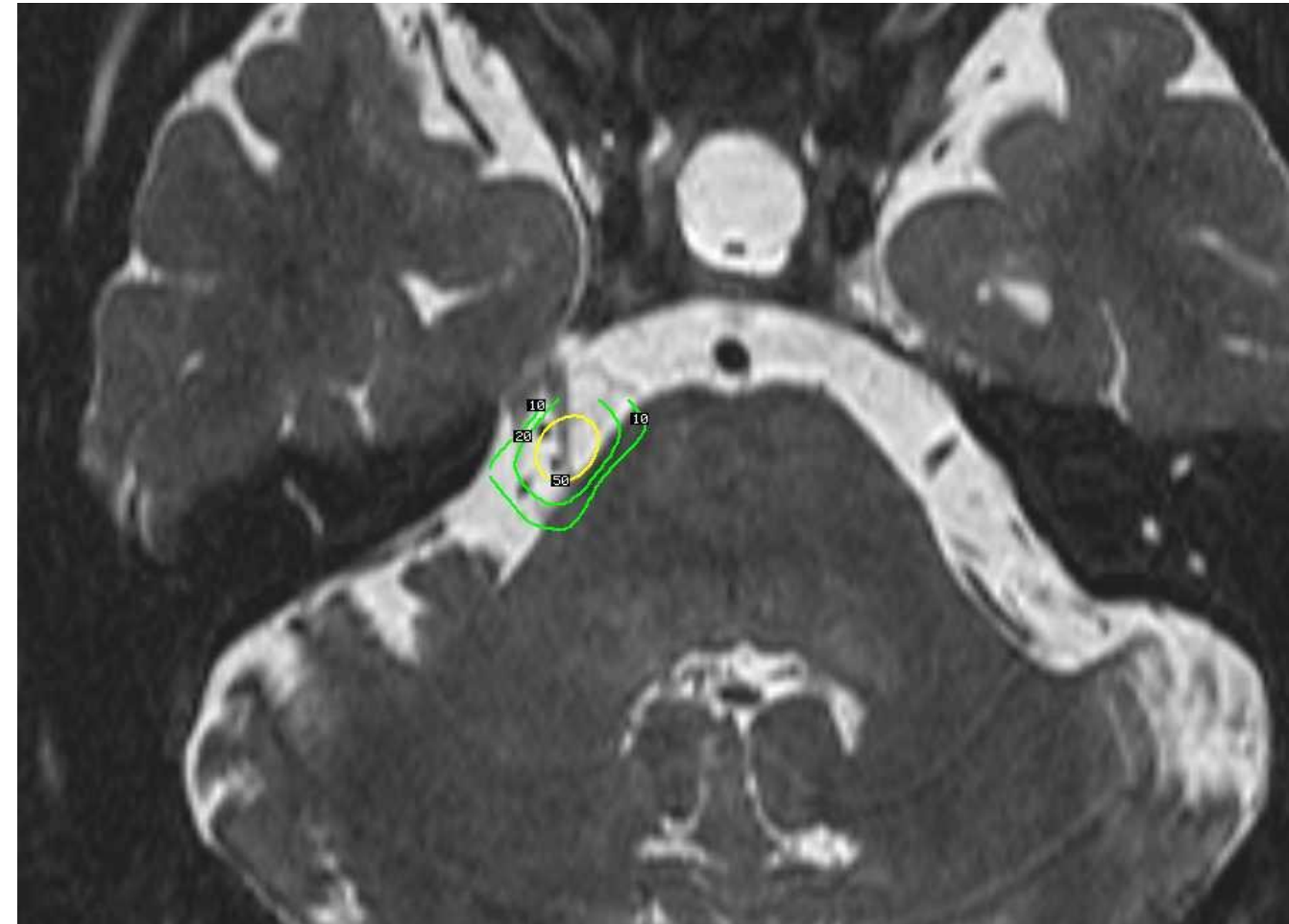
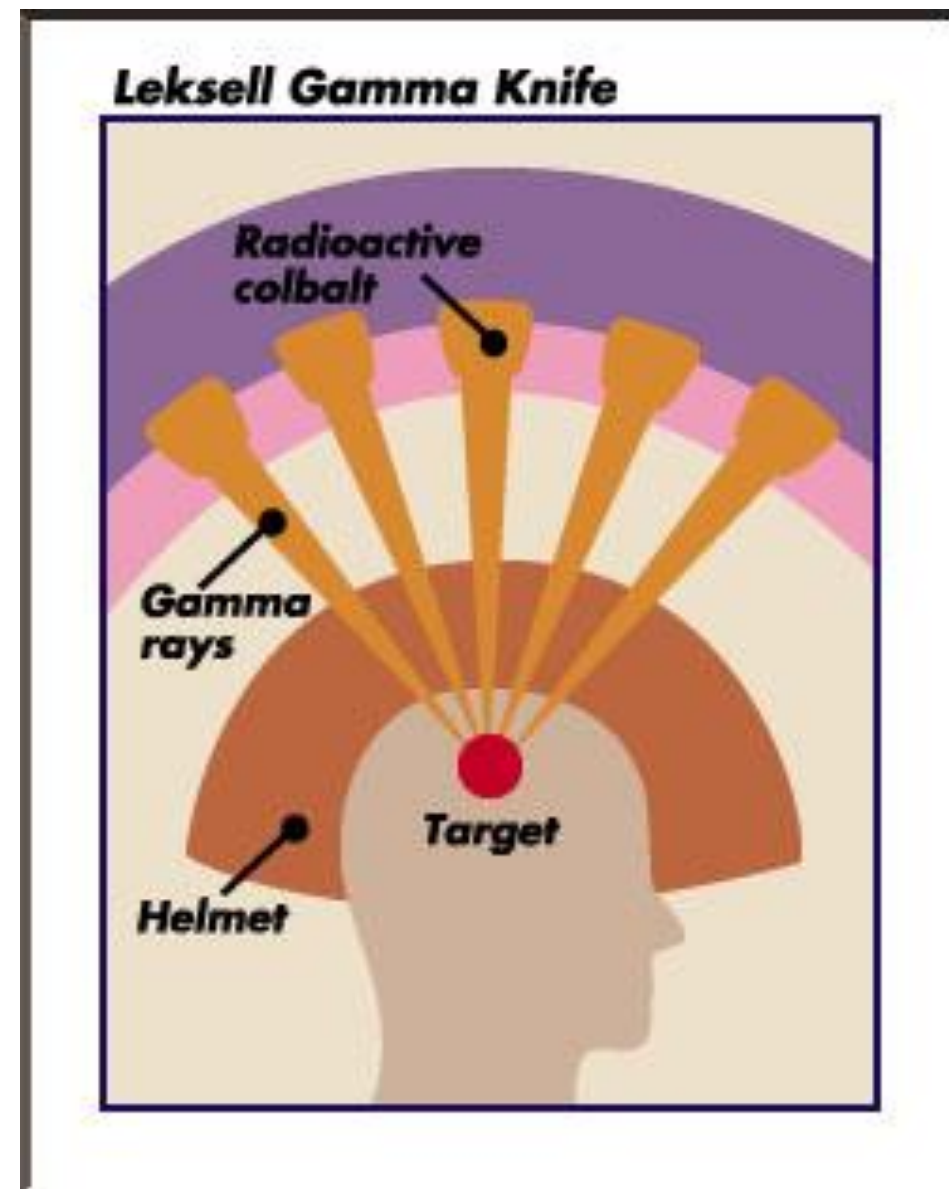
- Onkológus (kemo+radio)
- Sugársebész
- Endokrinológus
- Szemész (neuroophthalmologia)
- Neurológus



Meg tudom-e operálni? - Meg kell-e operálni?

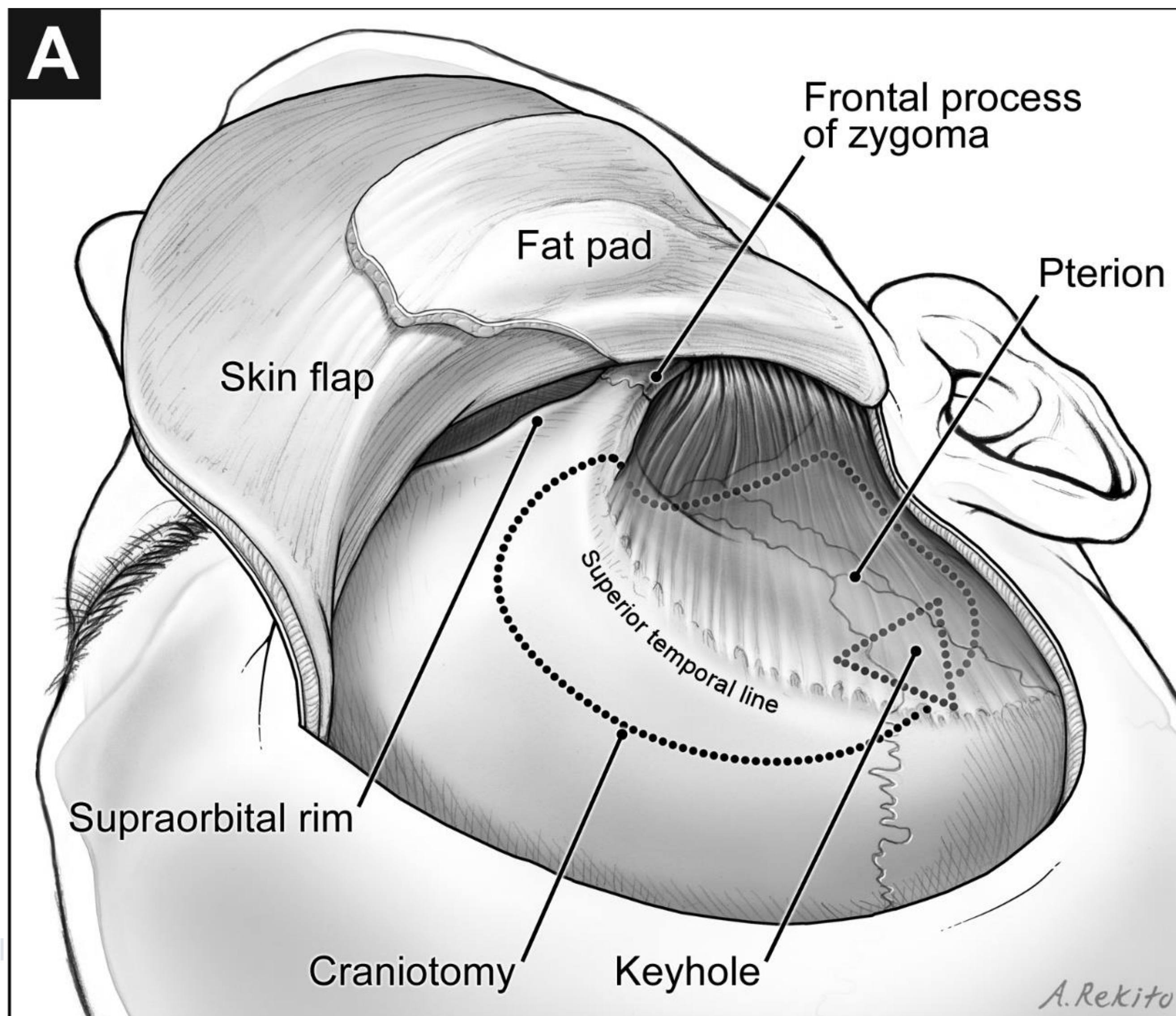
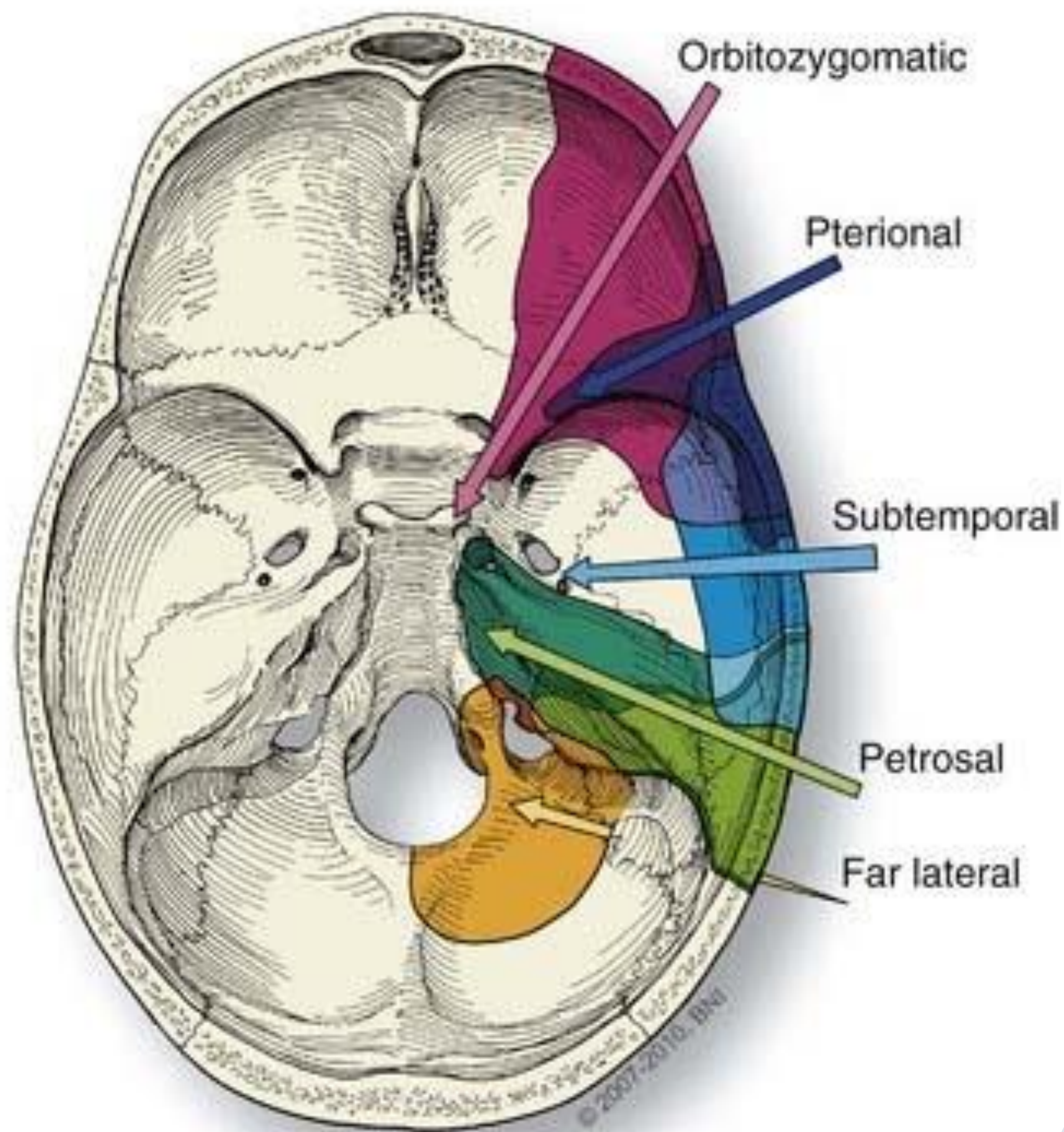


Minimálisan invazív alternatíva: Sugársebészet

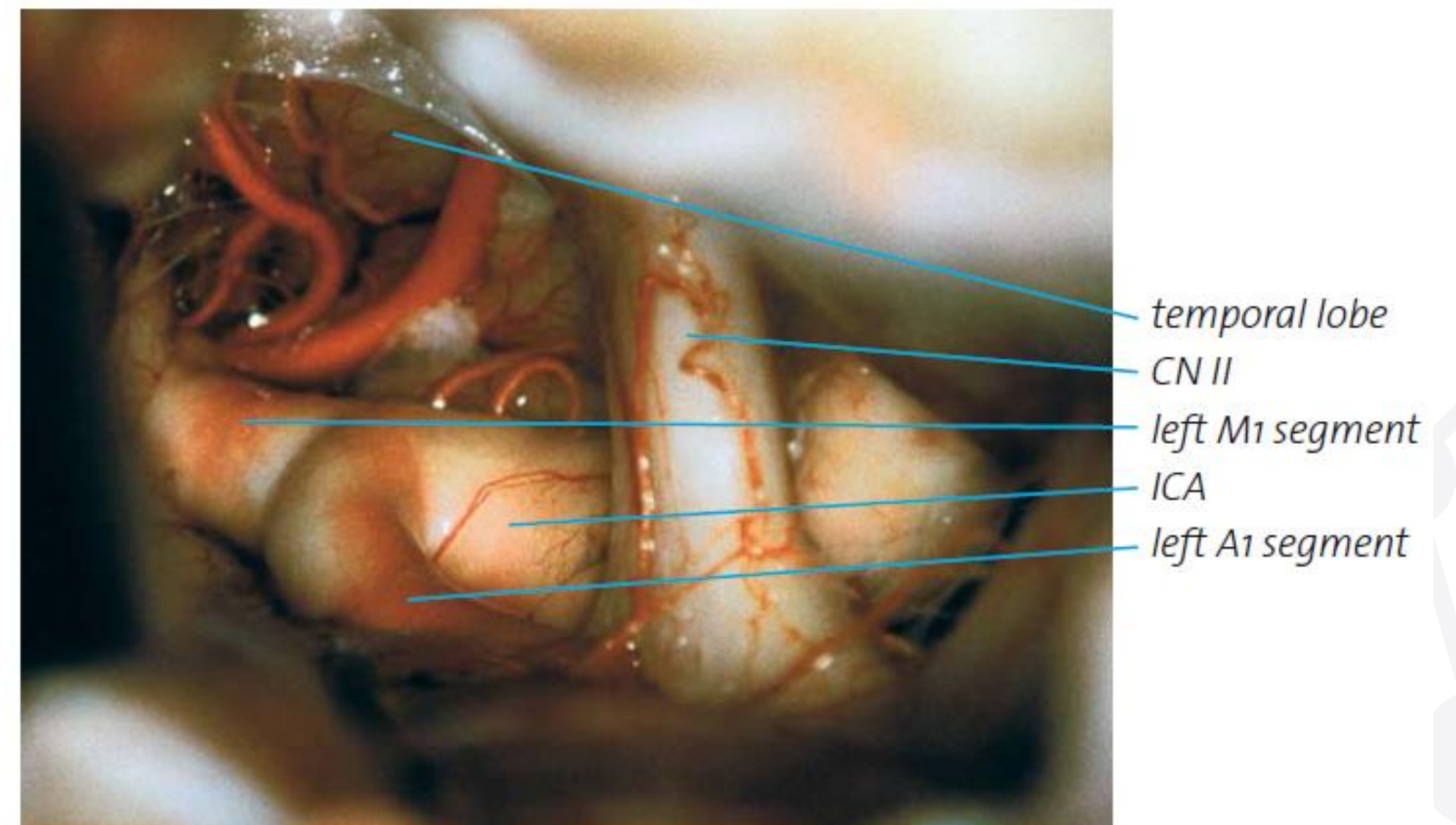
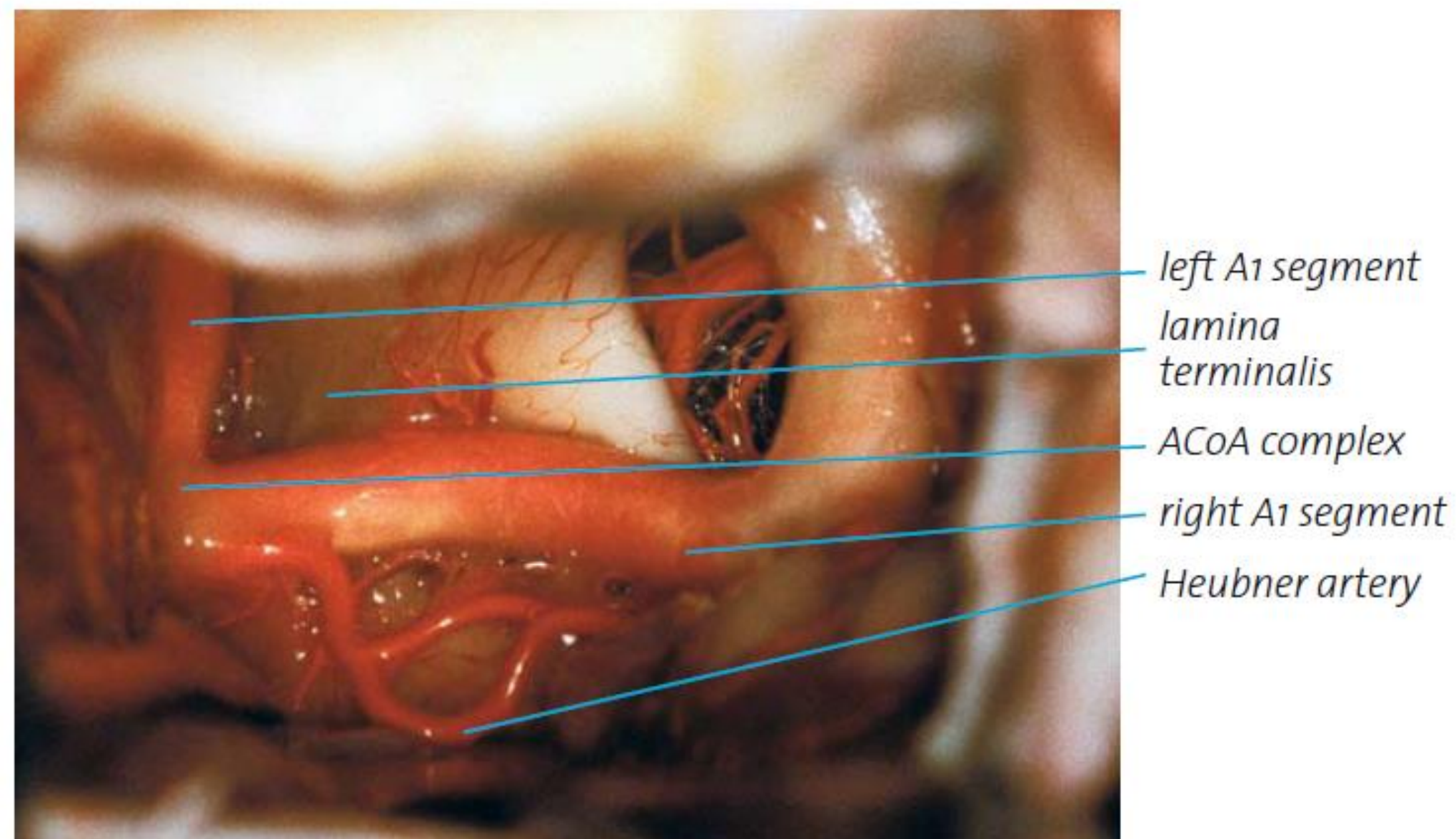
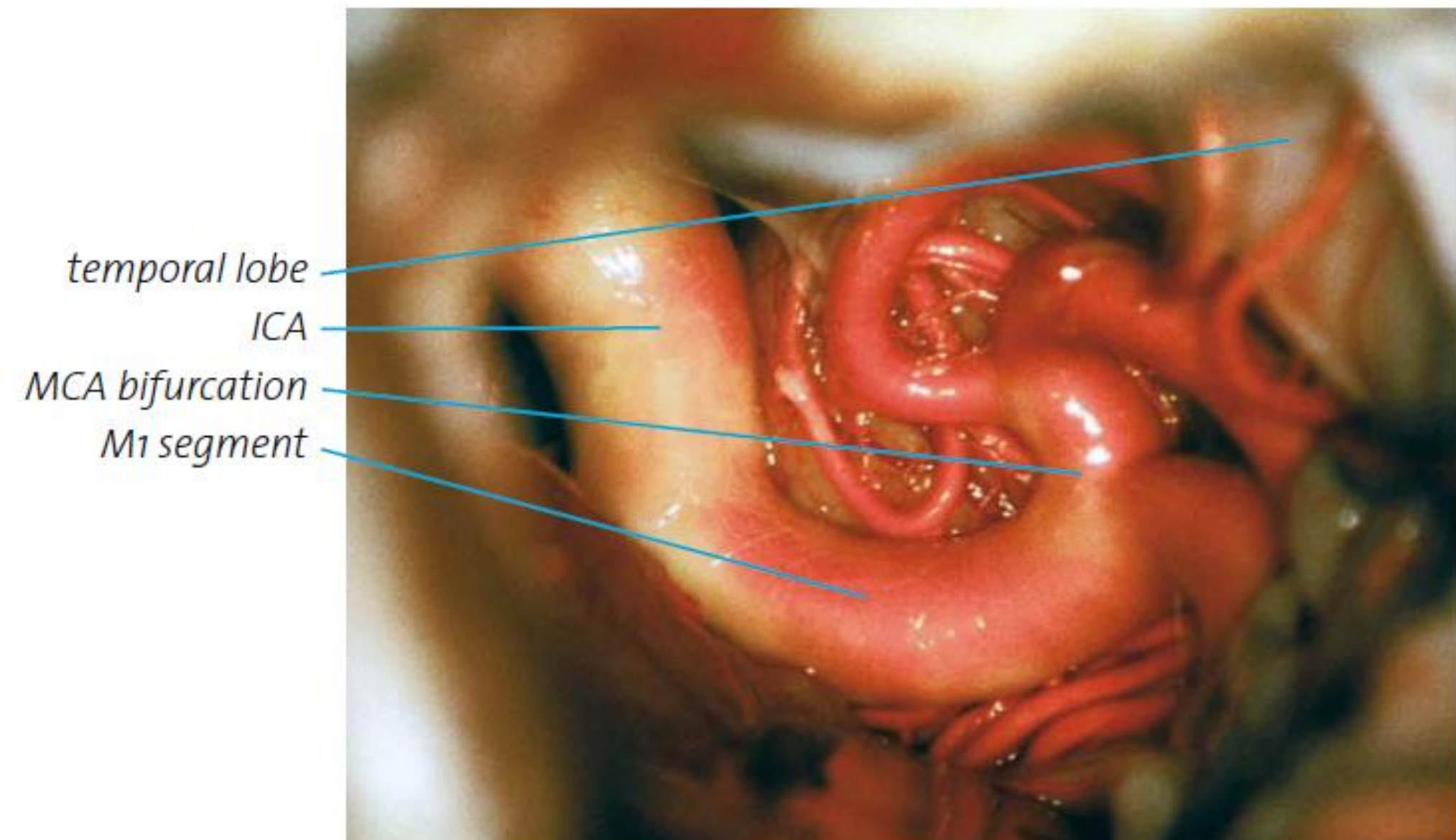
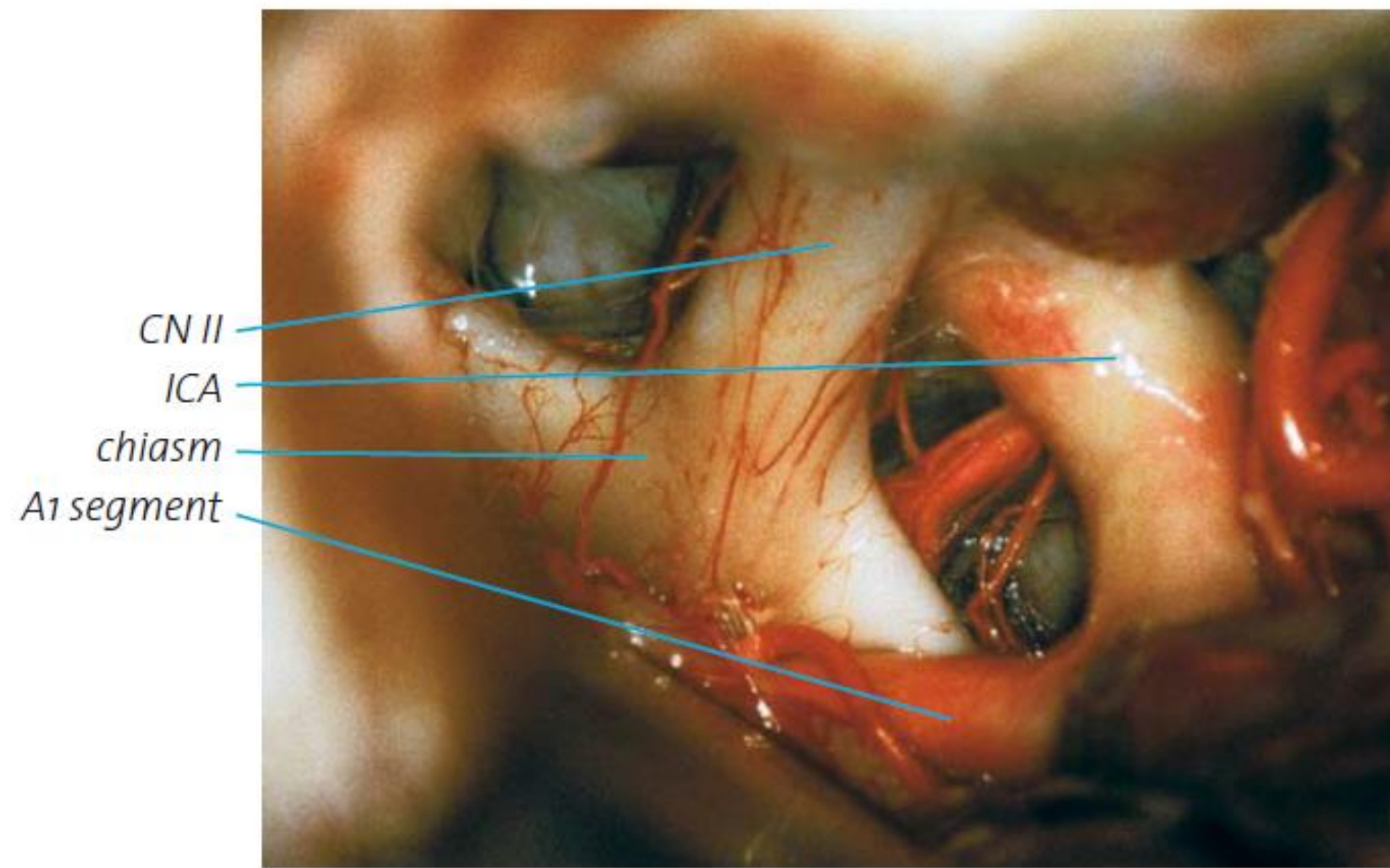


Craniotomiák a koponyaalap megközelítéséhez

Fronto-temporalis (pterionalis) craniotomia

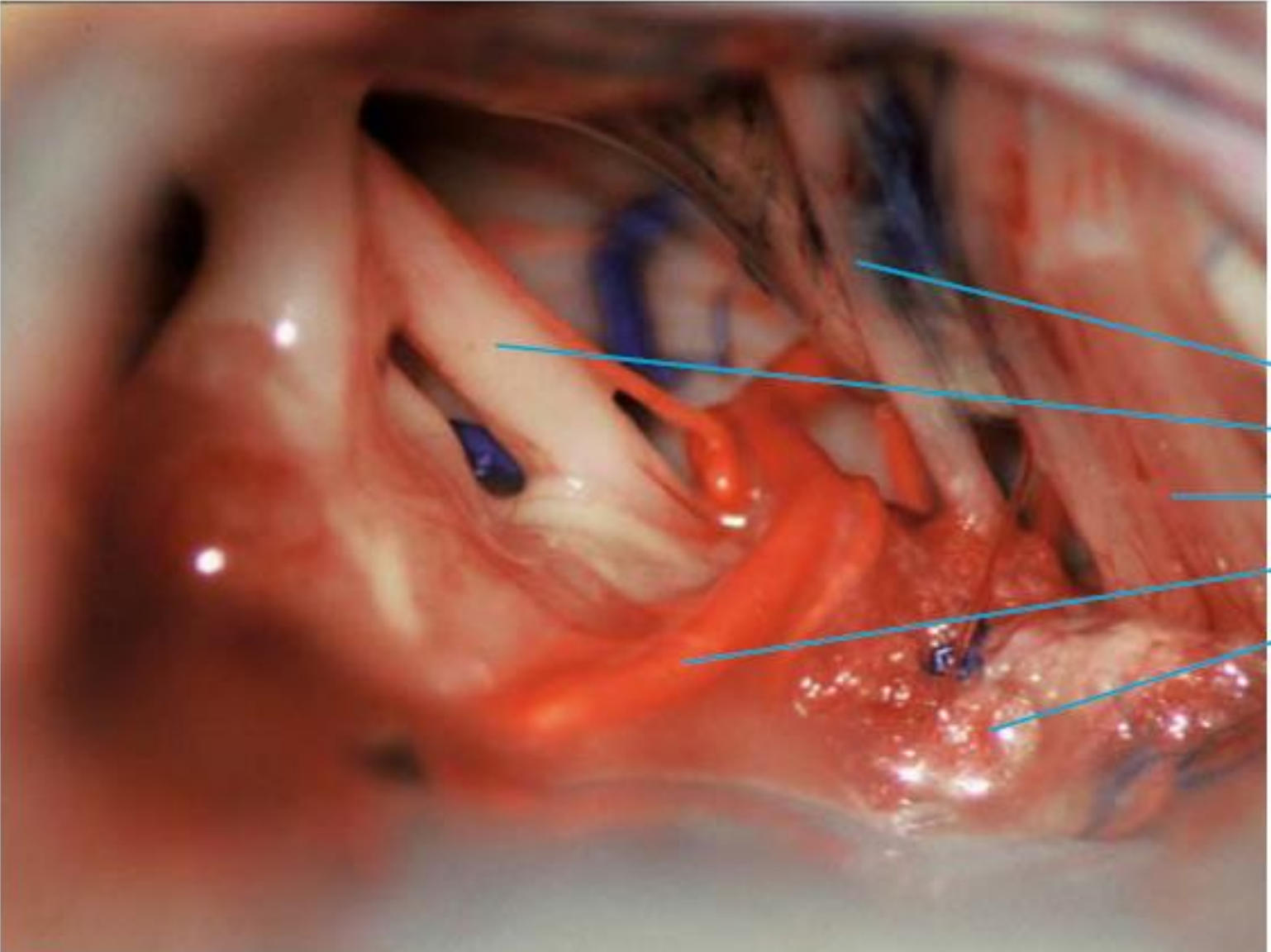
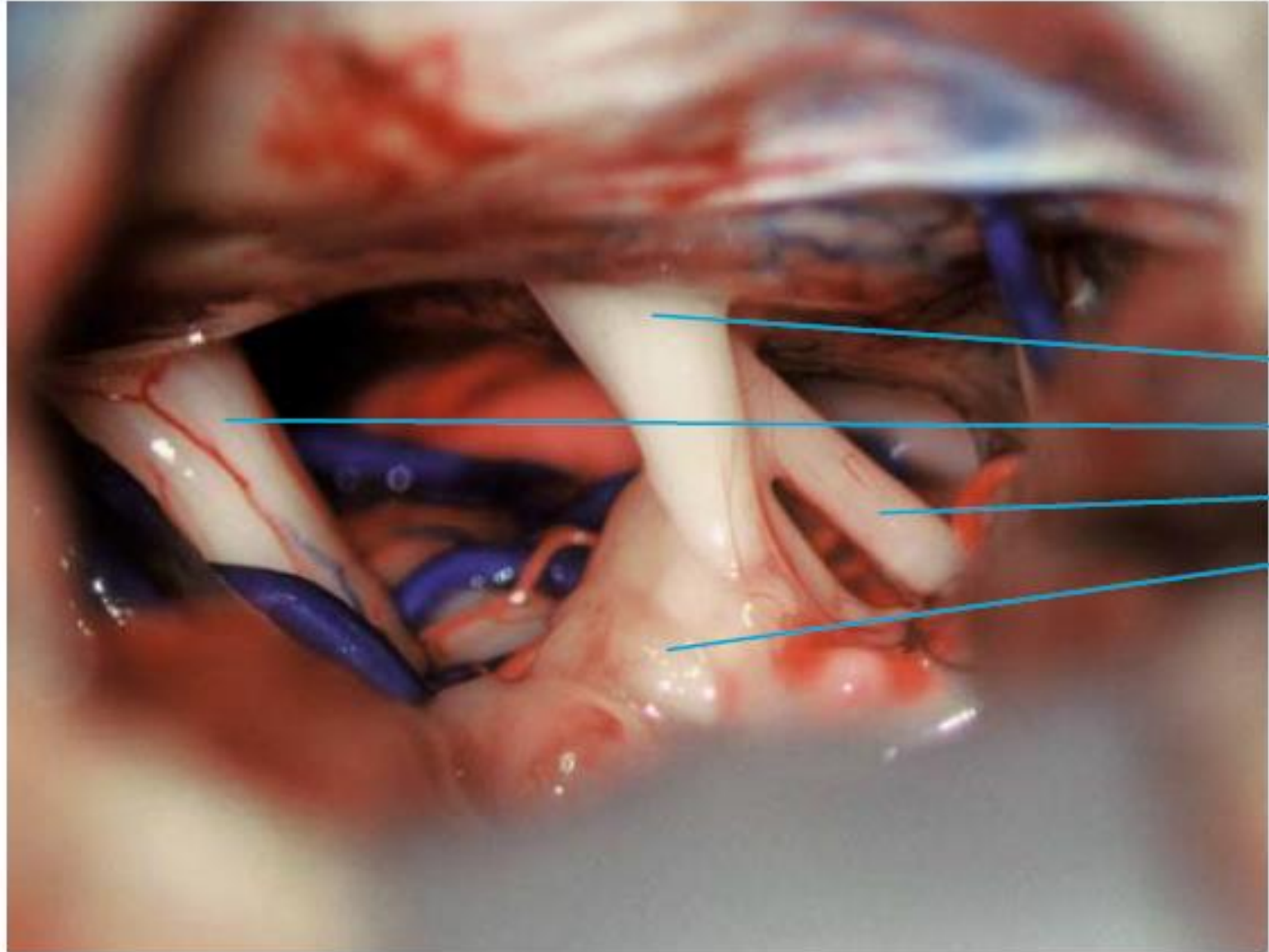
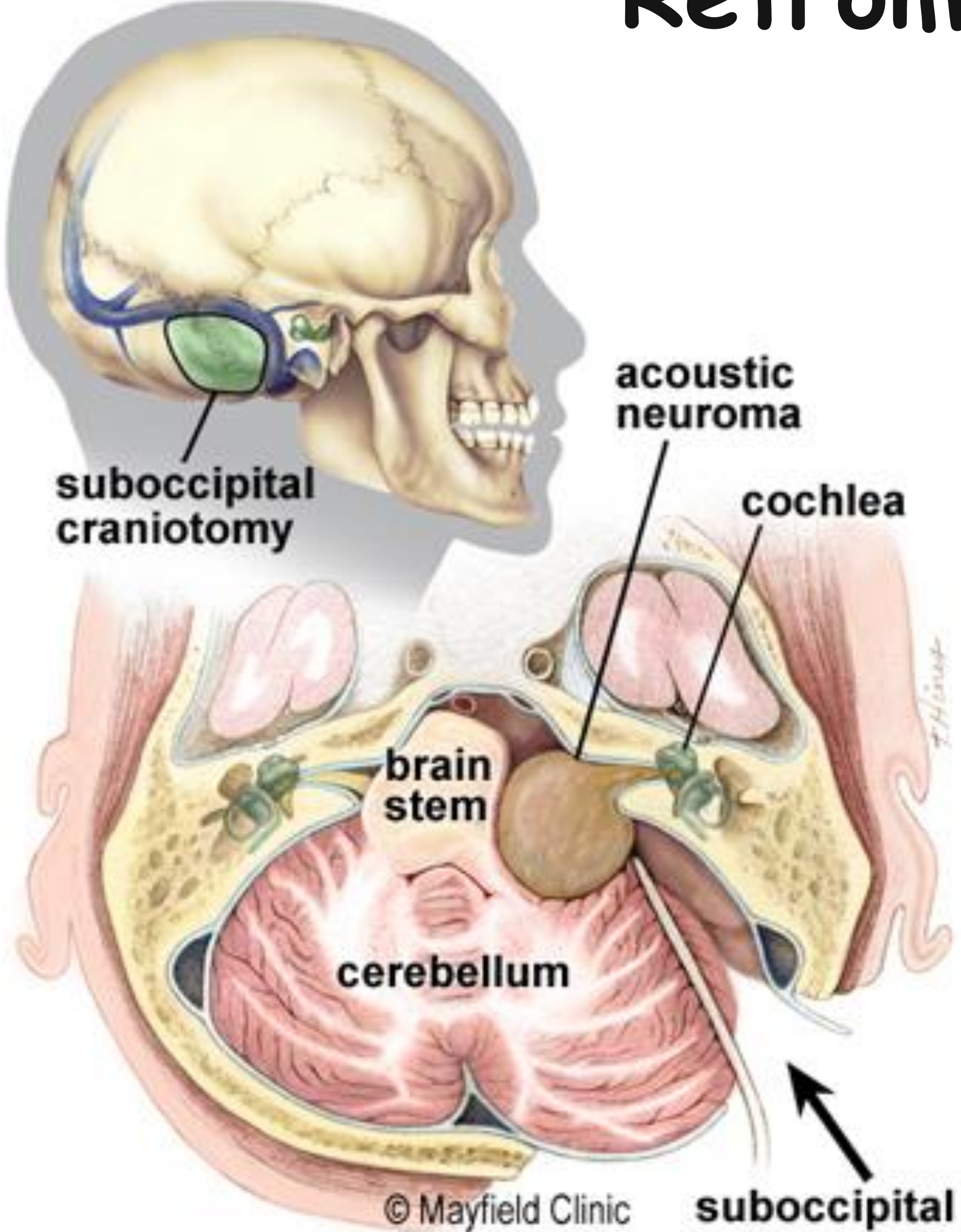


Supra- és parasellaris régió

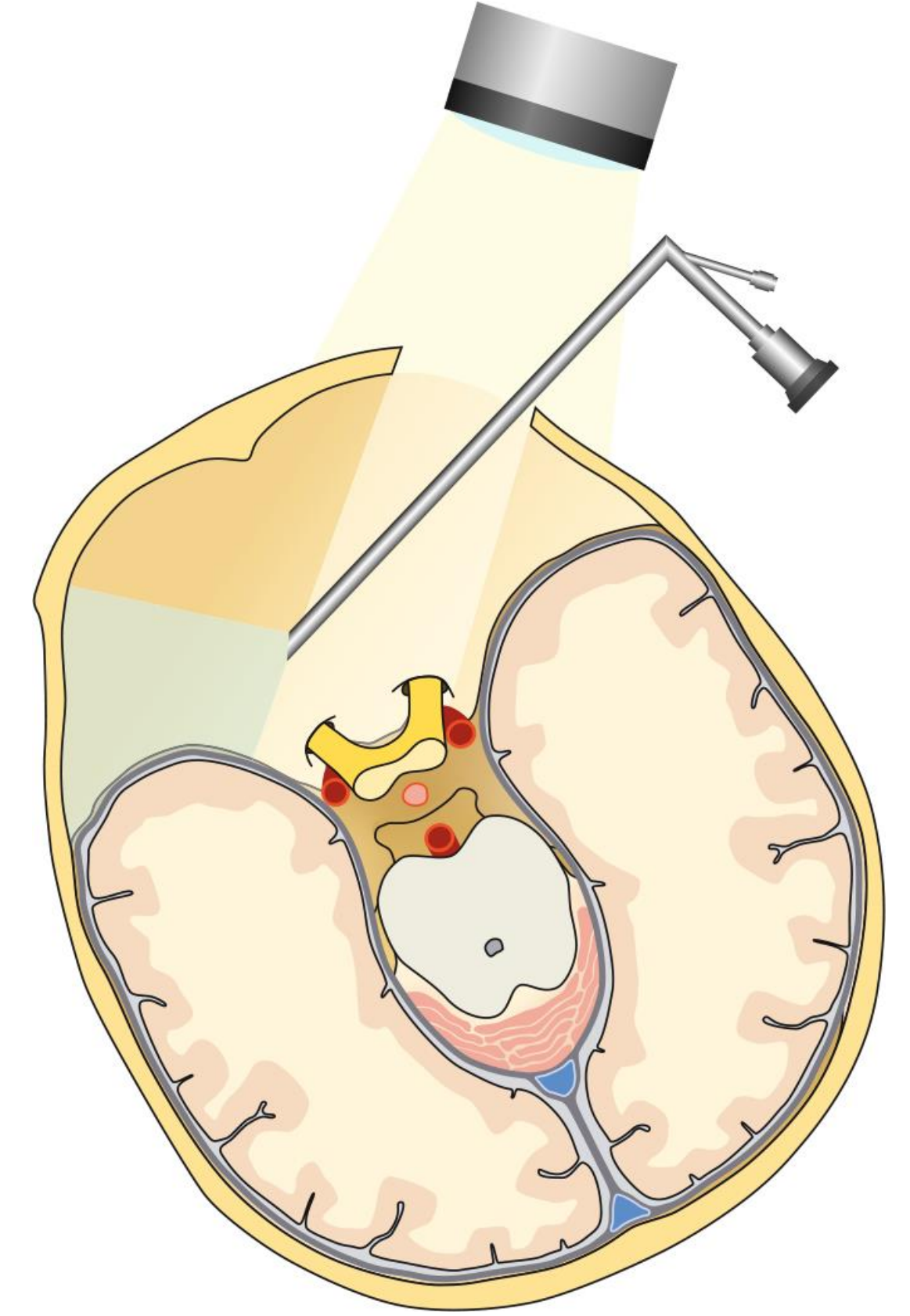
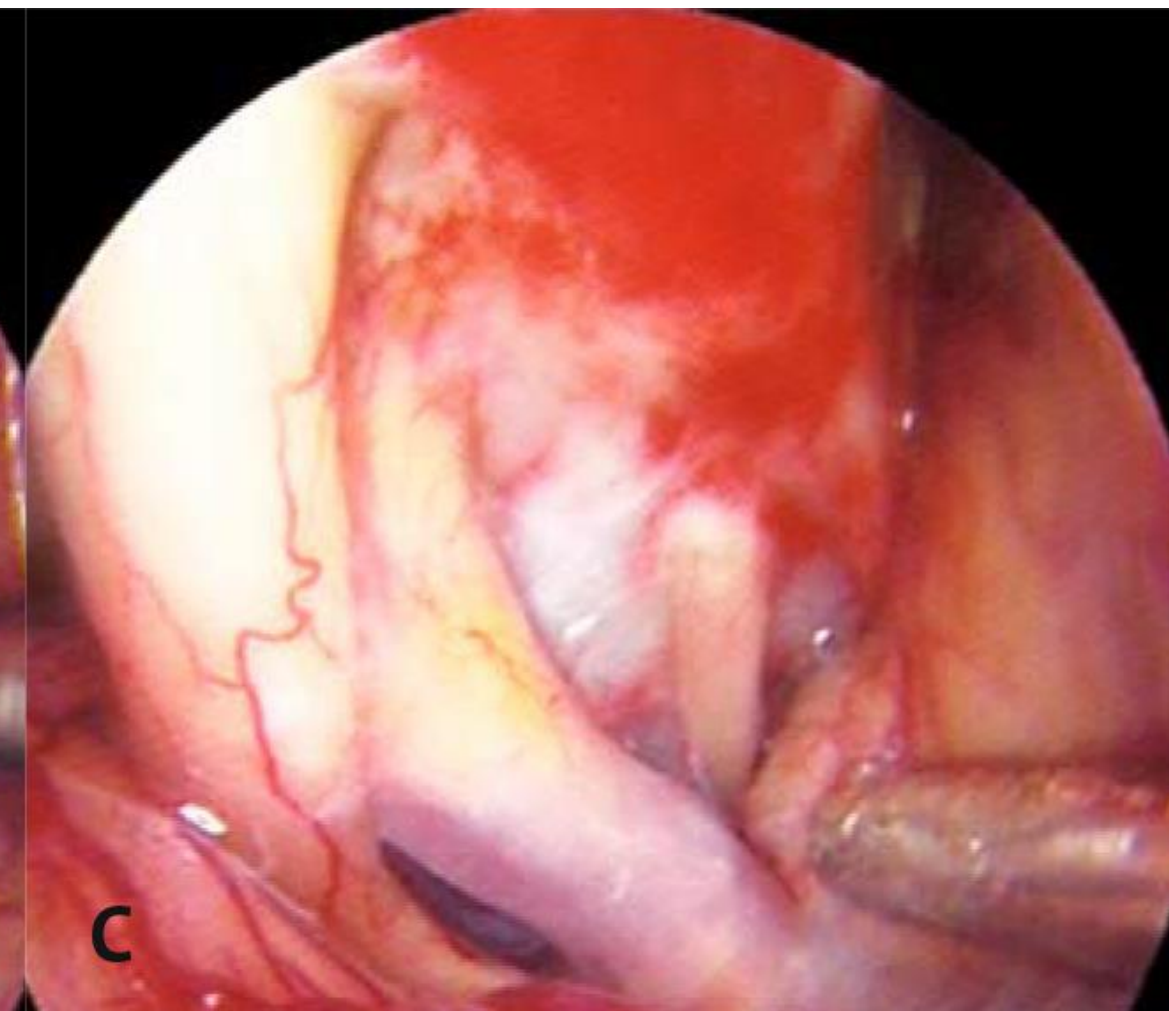
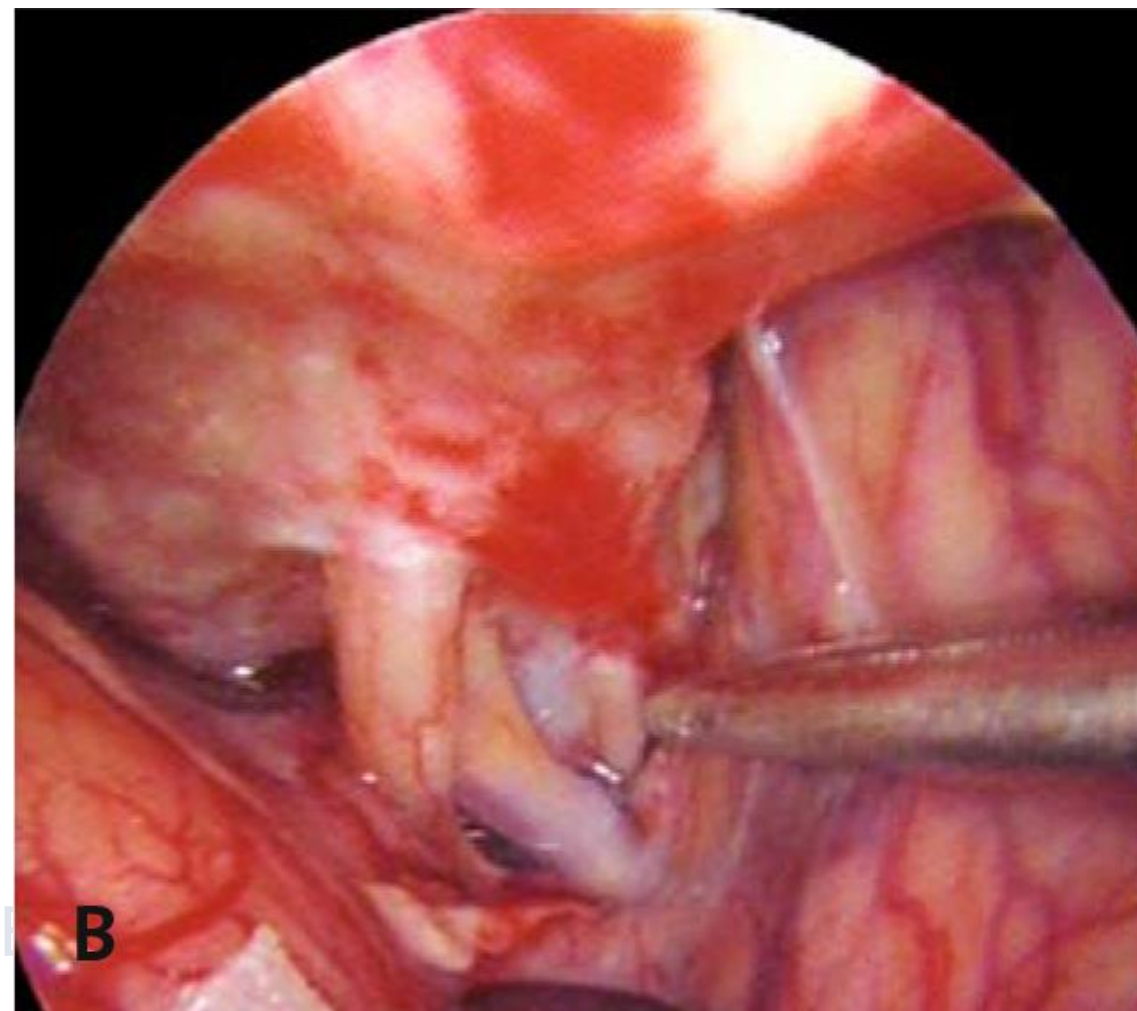
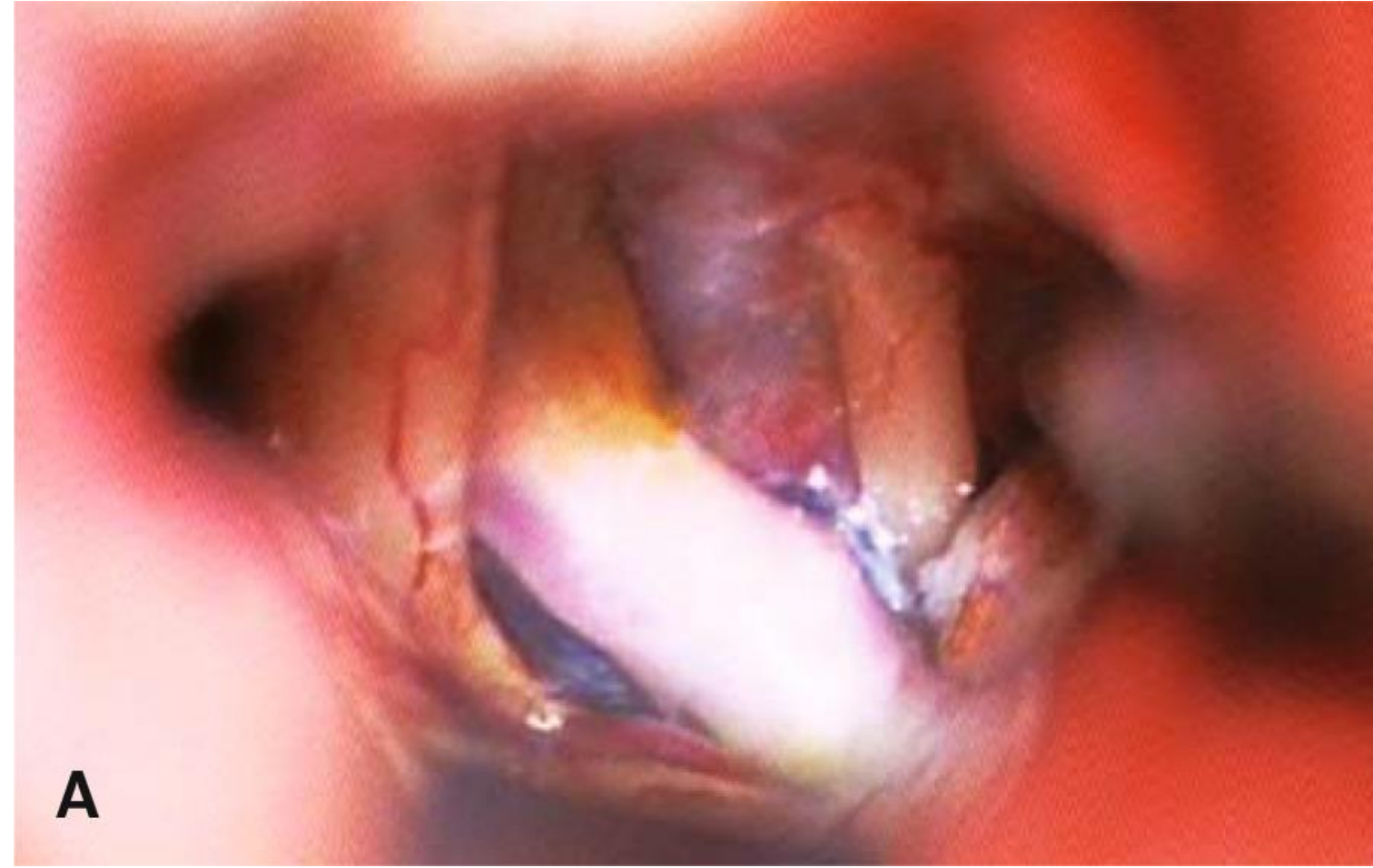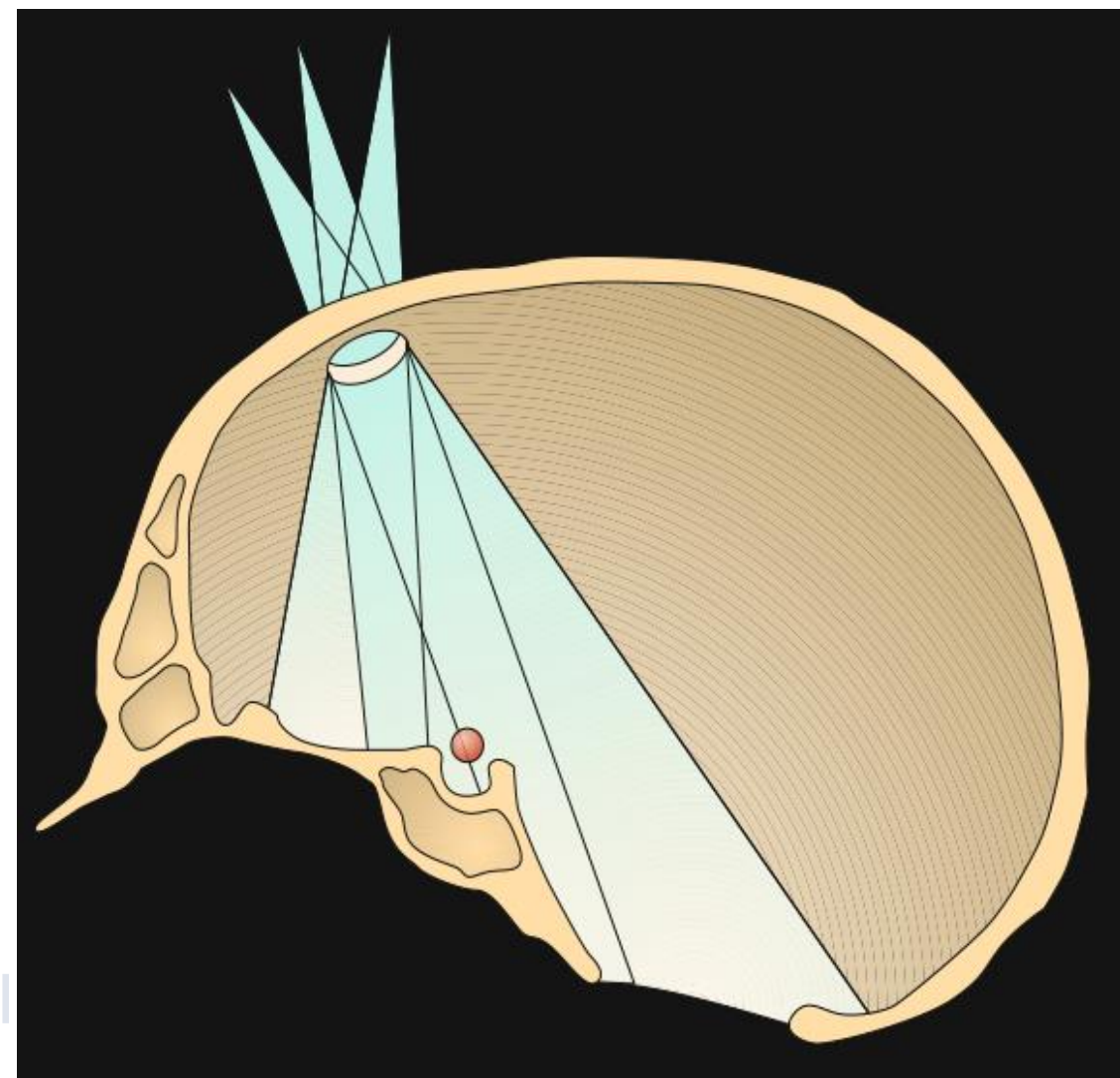
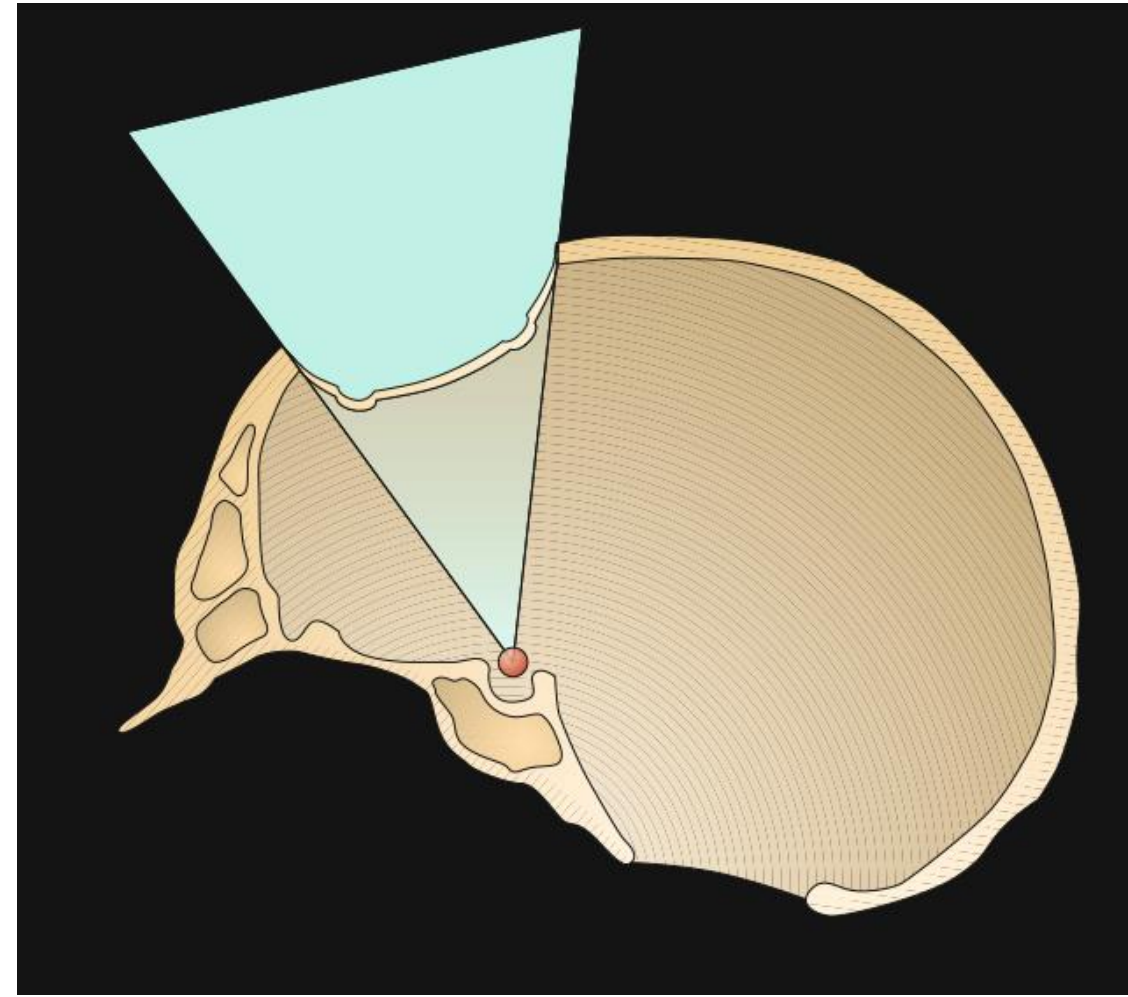
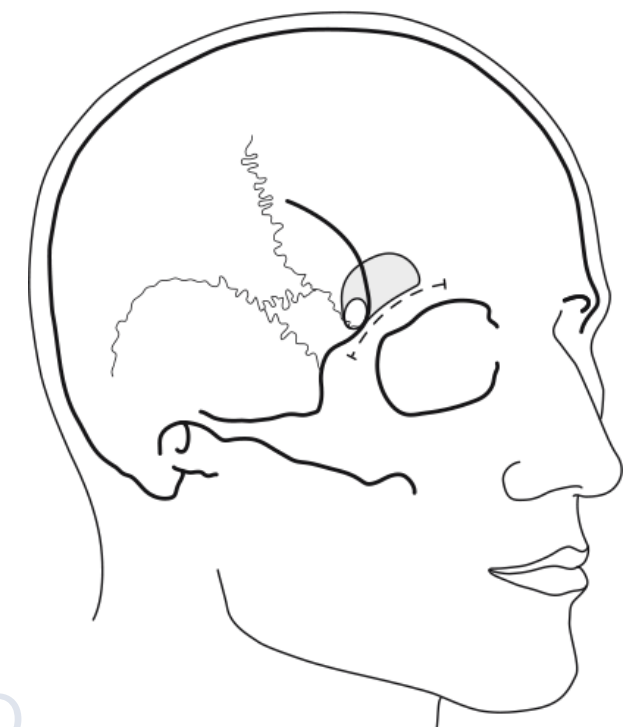
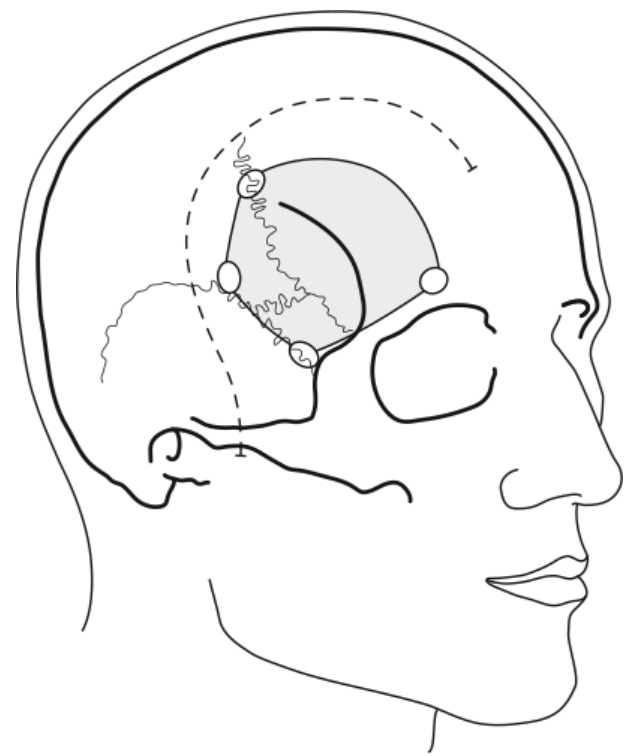
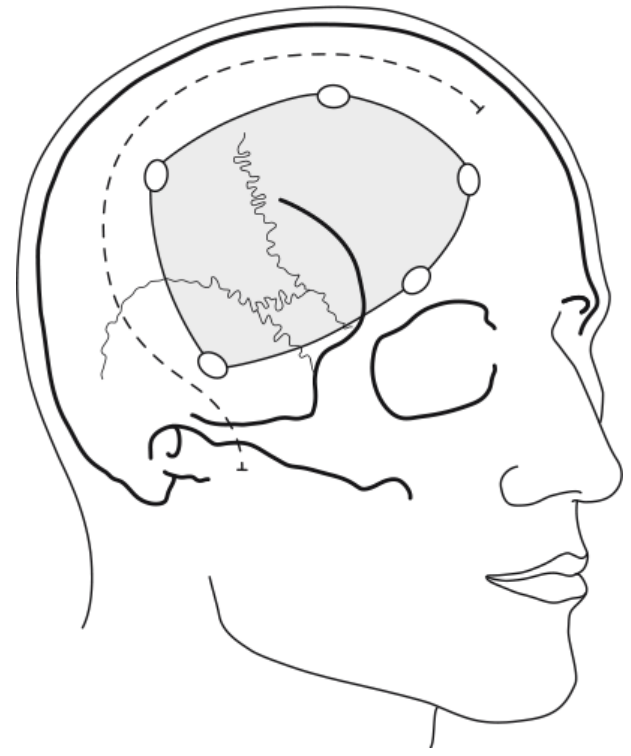


Craniotomiák a koponyaalap megközelítéséhez

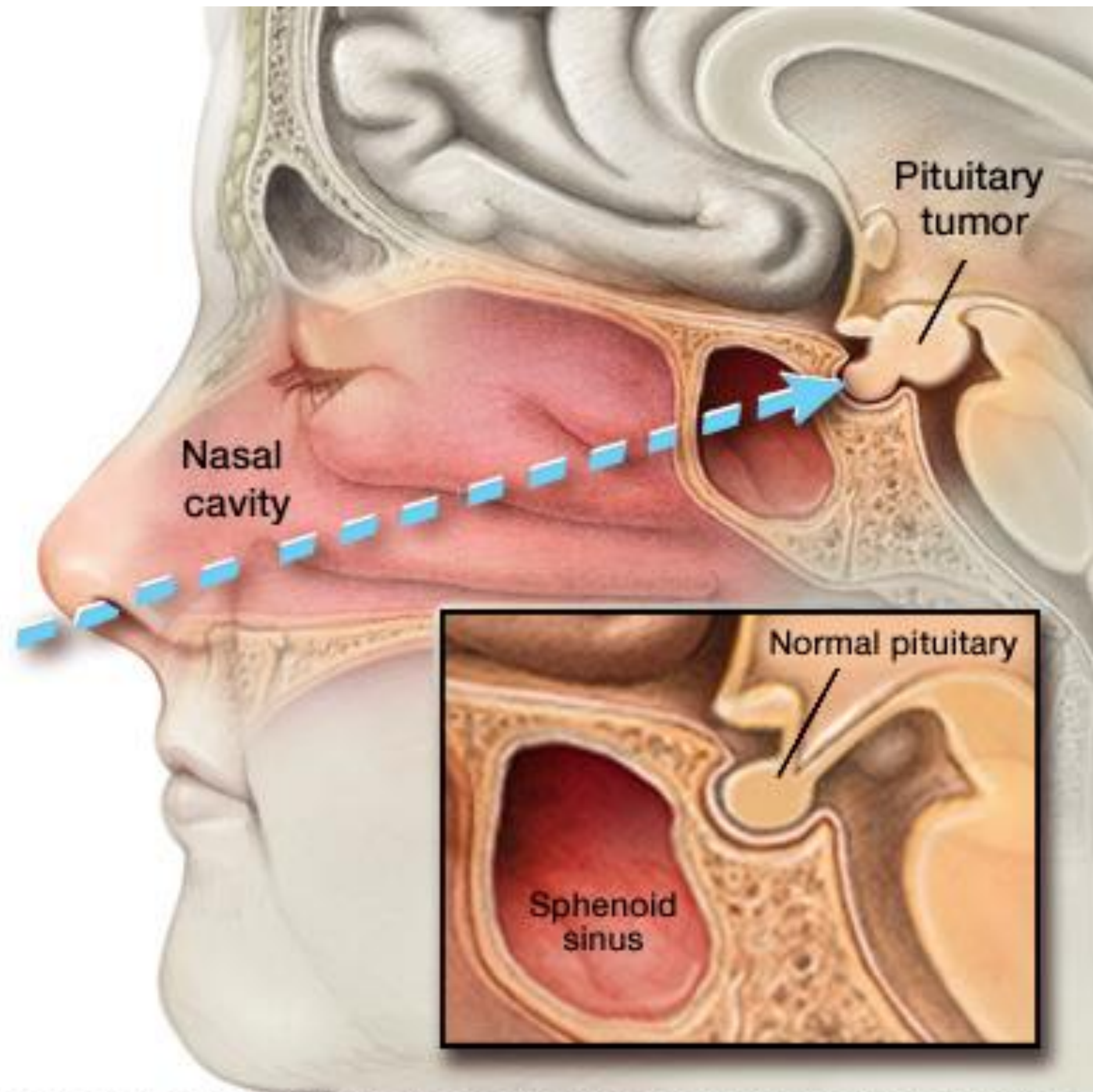
Retromastoid craniotomia



Kulcslyuk szemlélet



Endoscopos transnasalis sebészet



© MAYO FOUNDATION FOR MEDICAL EDUCATION AND RESEARCH. ALL RIGHTS RESERVED.

ORSZÁGOS MENTÁLIS, IDEGGYÓGYÁSZATI ÉS IDEGSEBÉSZETI KÖZPONT

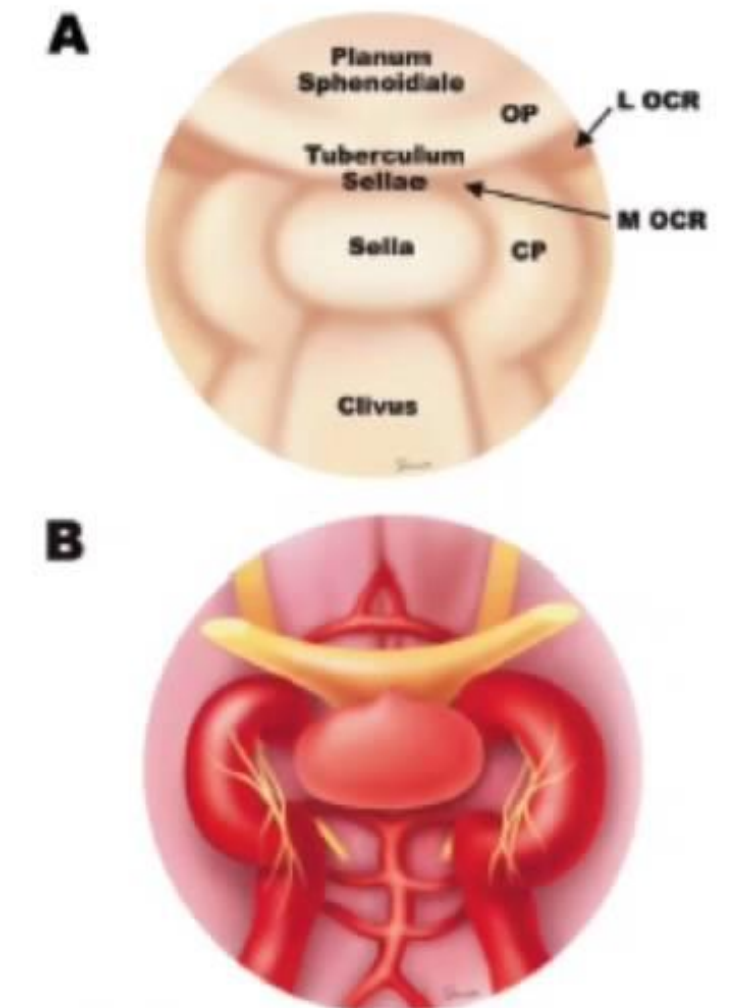
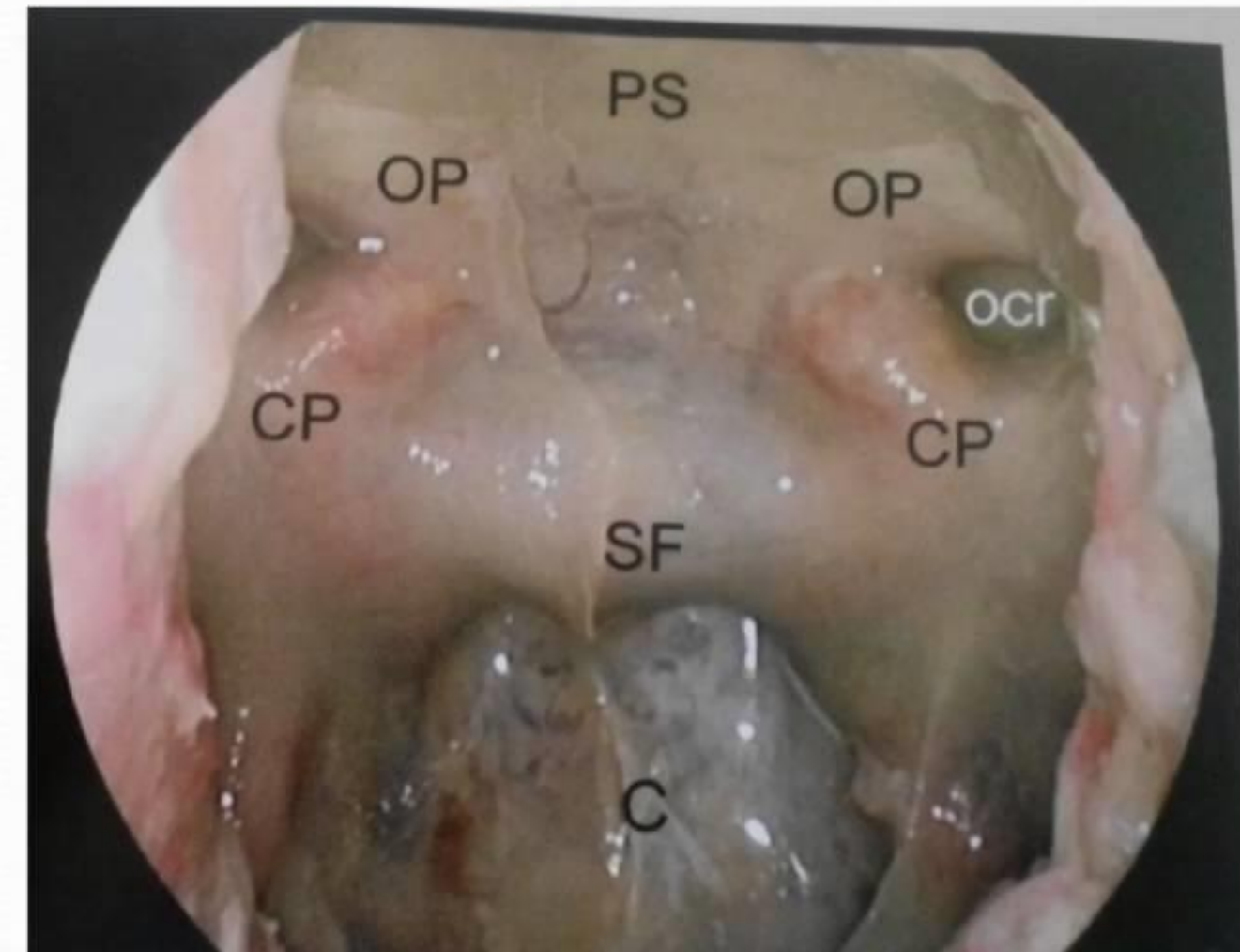
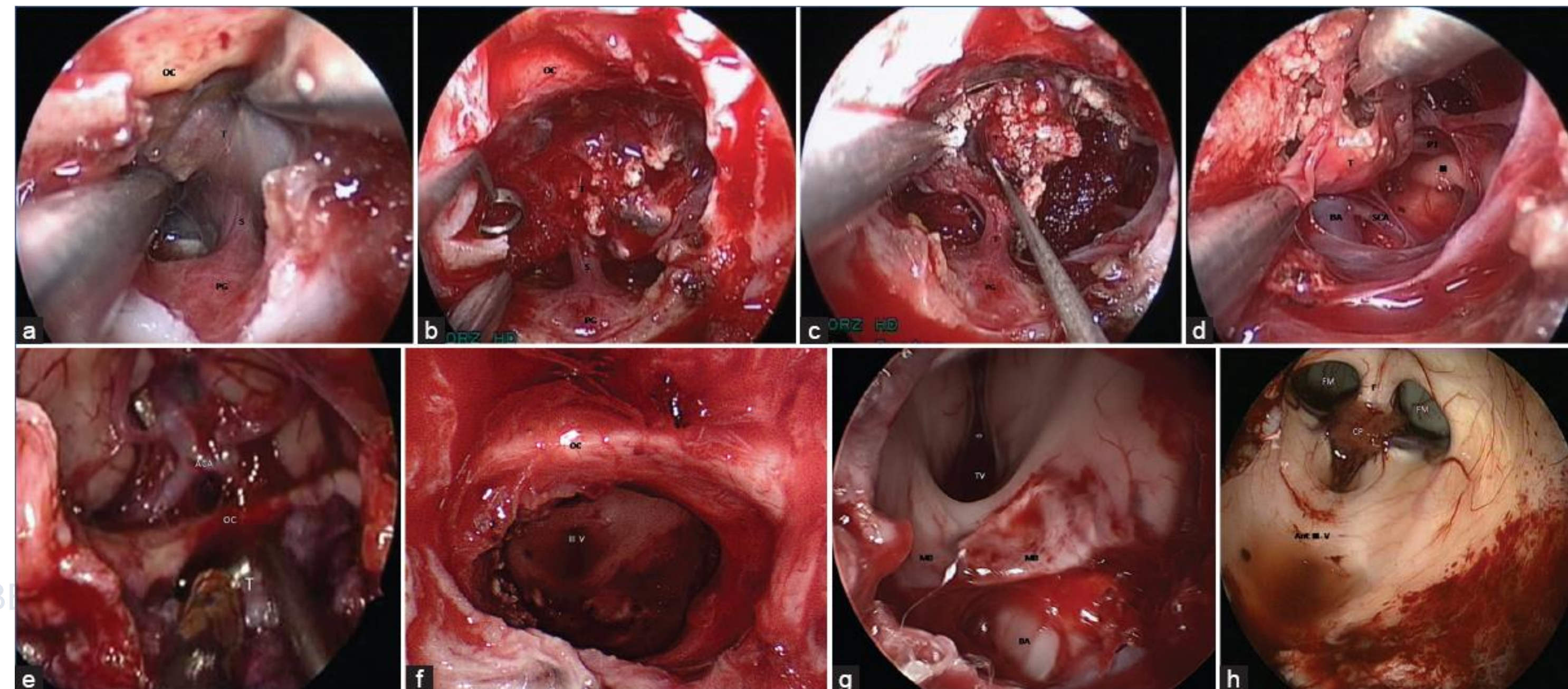


FIGURE 37.6. A, endoscopic view of the superior, posterior,



Basis rekonstrukció

➤ Erezett lebenyek

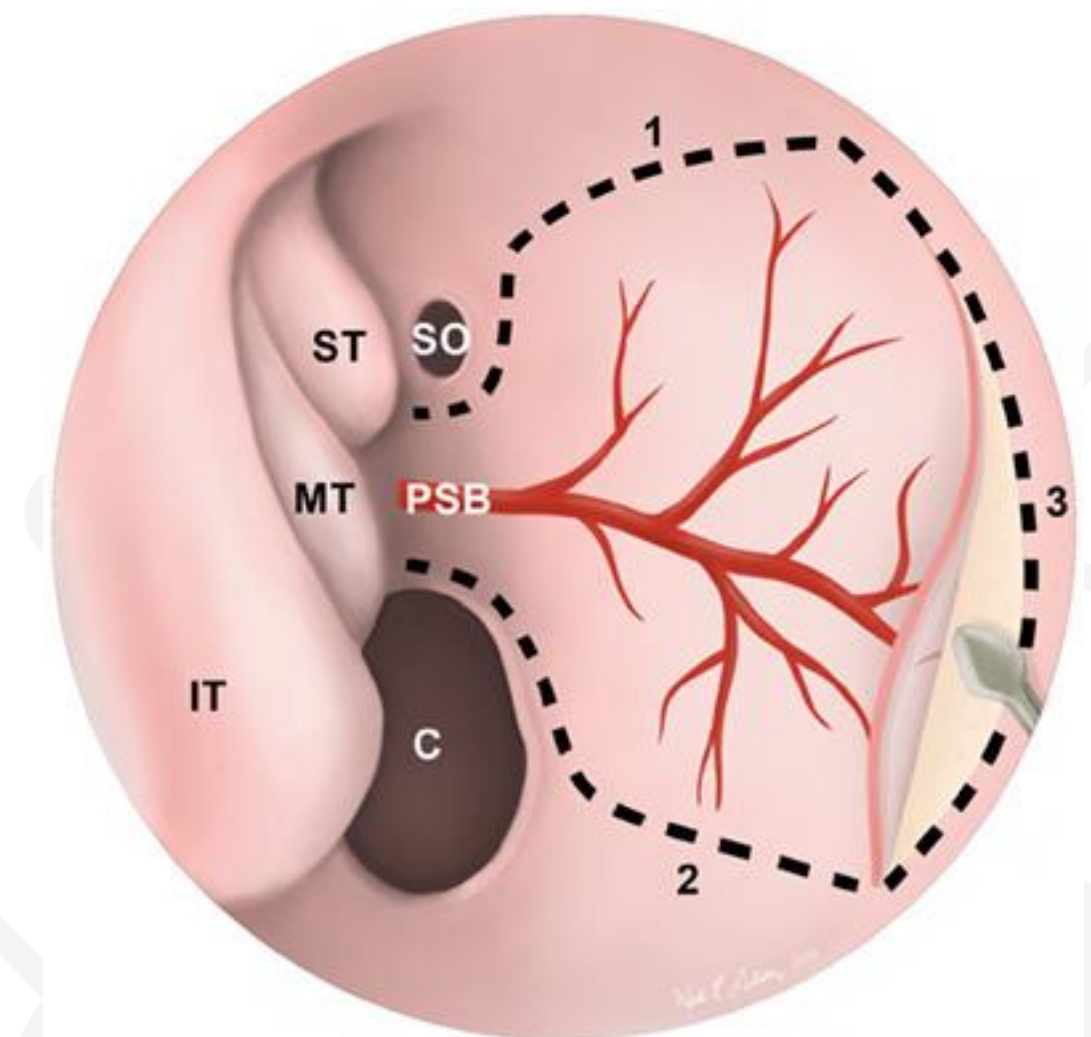
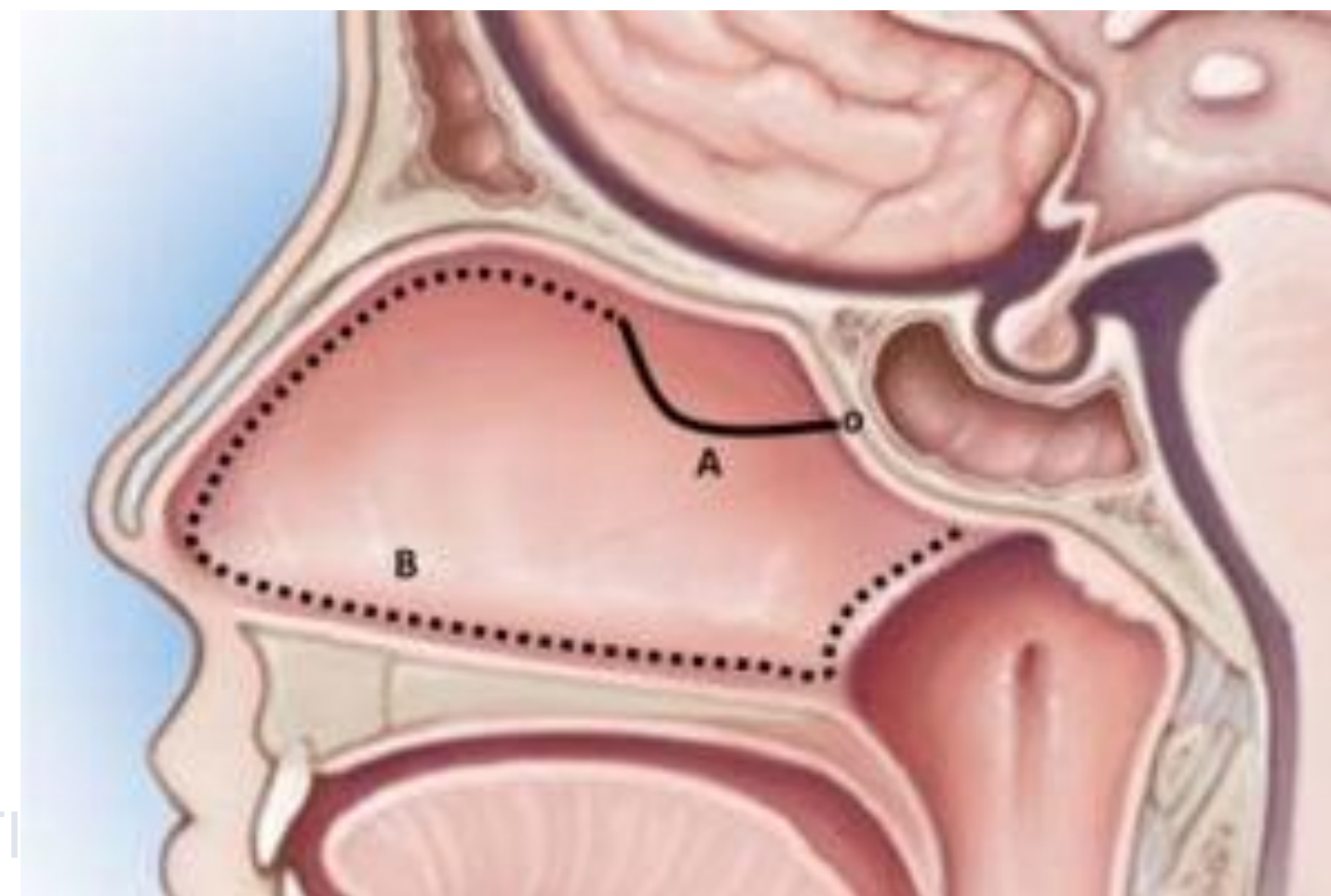
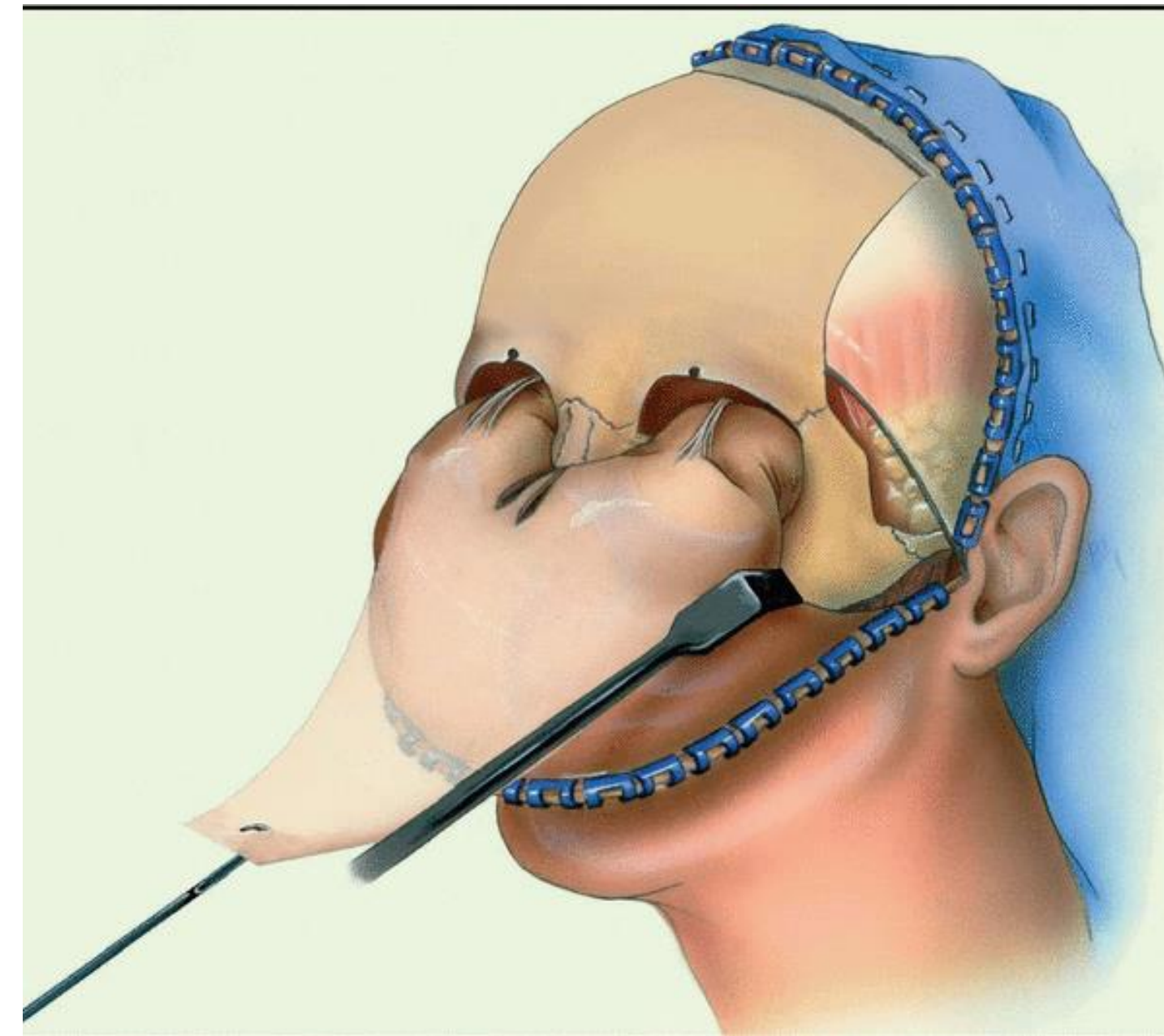
- Pericranium (frontalis - a. supraorbitalis, temporoparietalis - a. temporalis)
- Nasoseptalis (Hadad) - a. sphenopalatina

➤ Szabad sajátgraftok

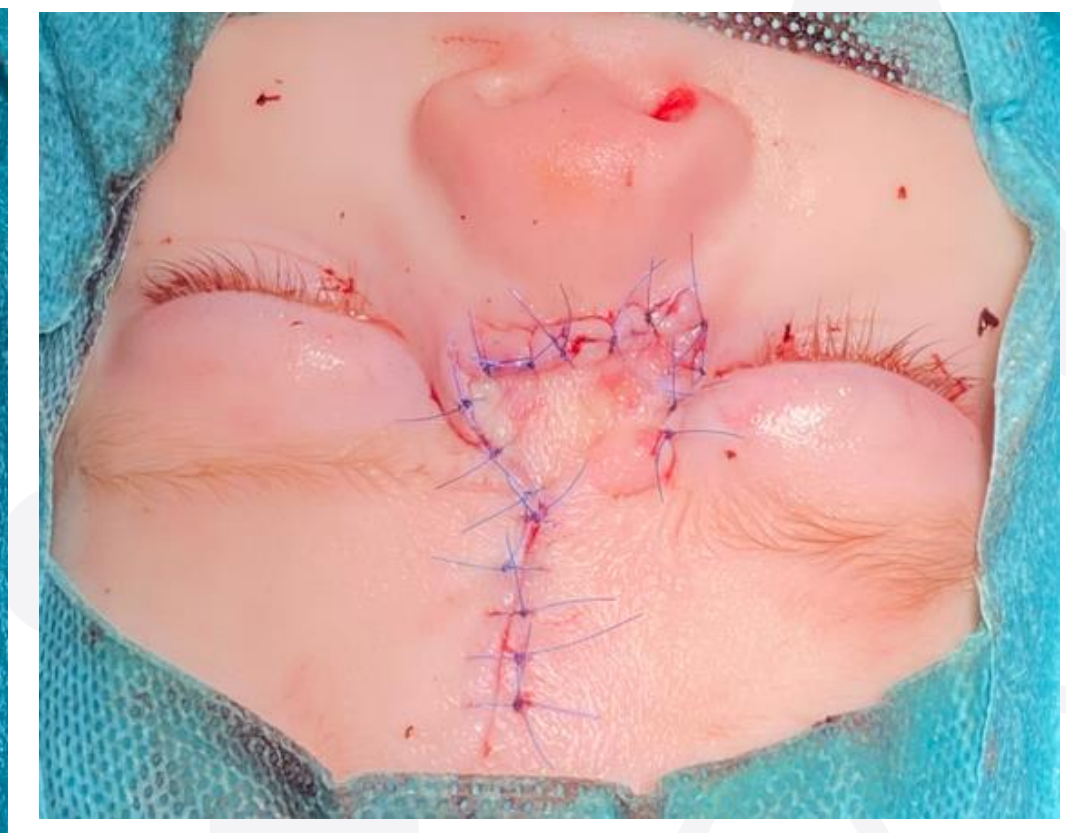
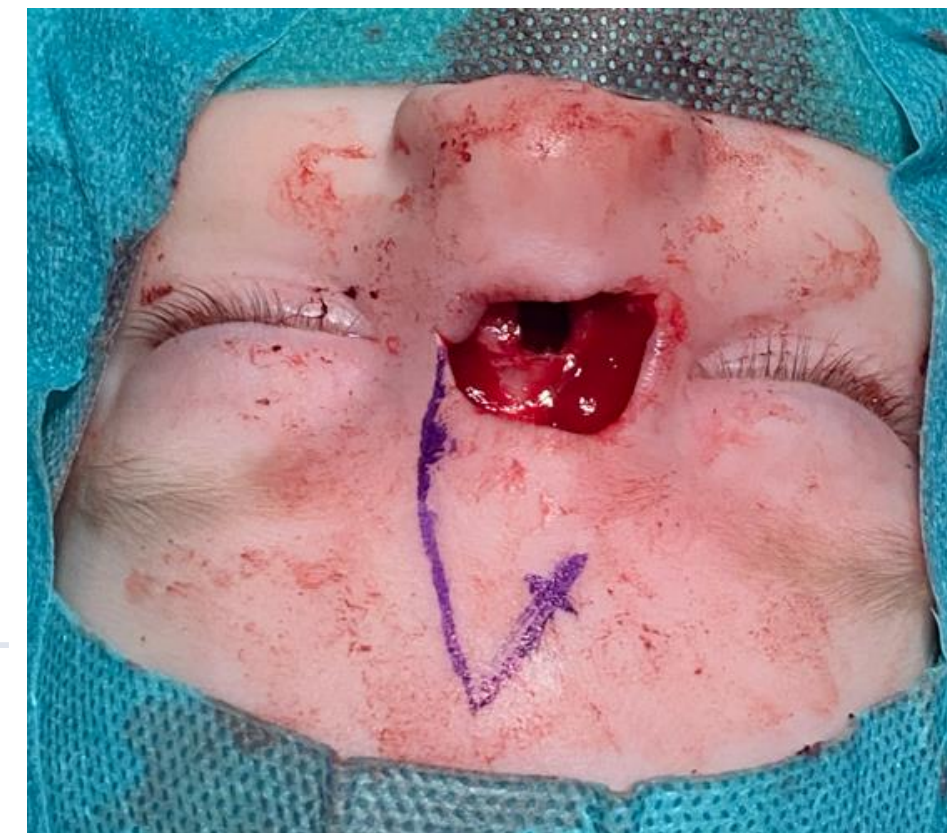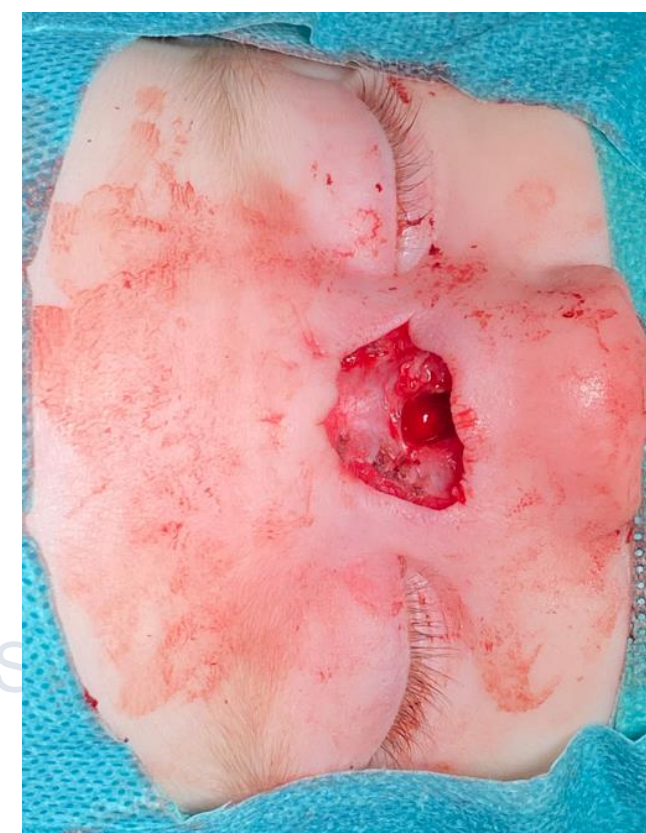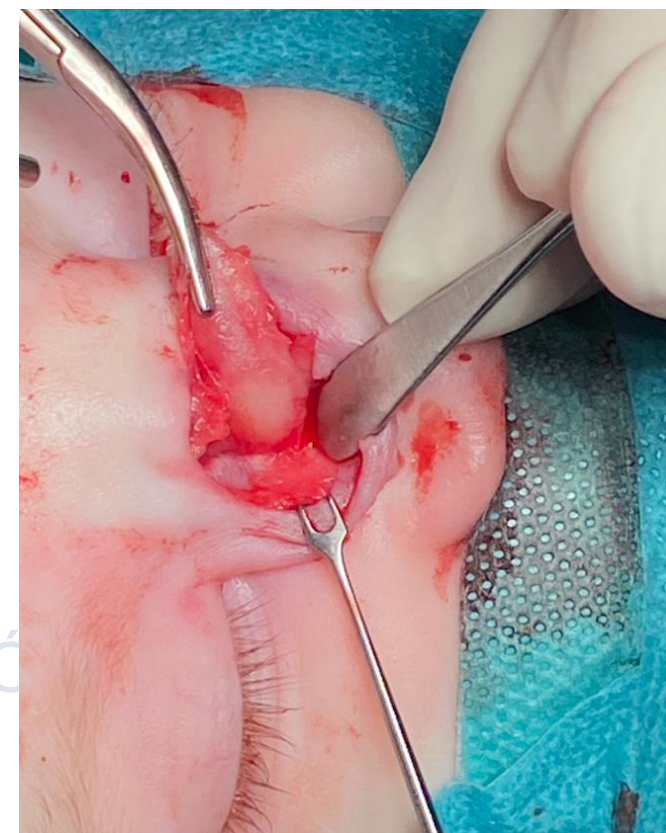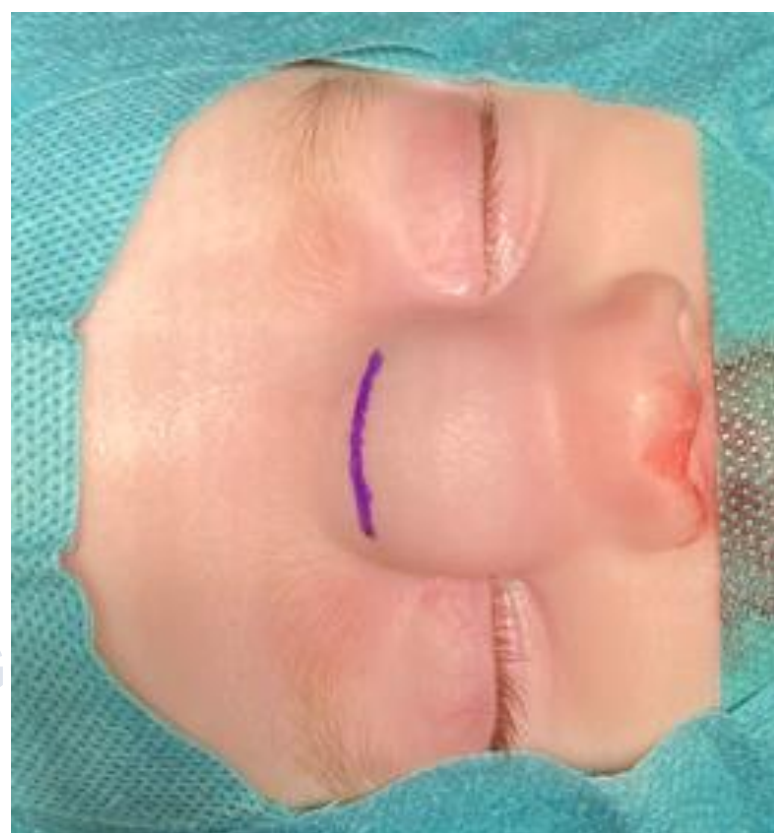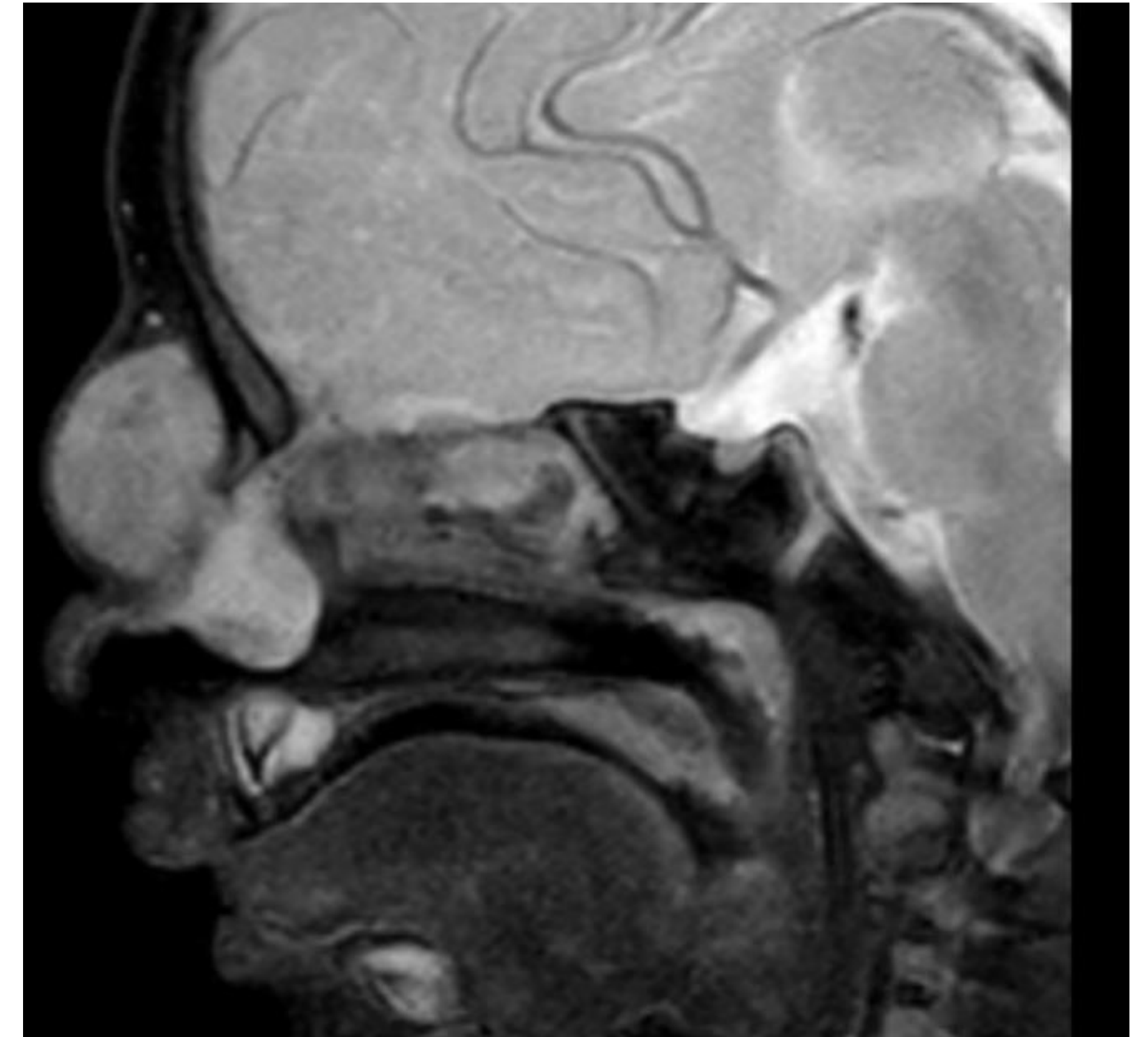
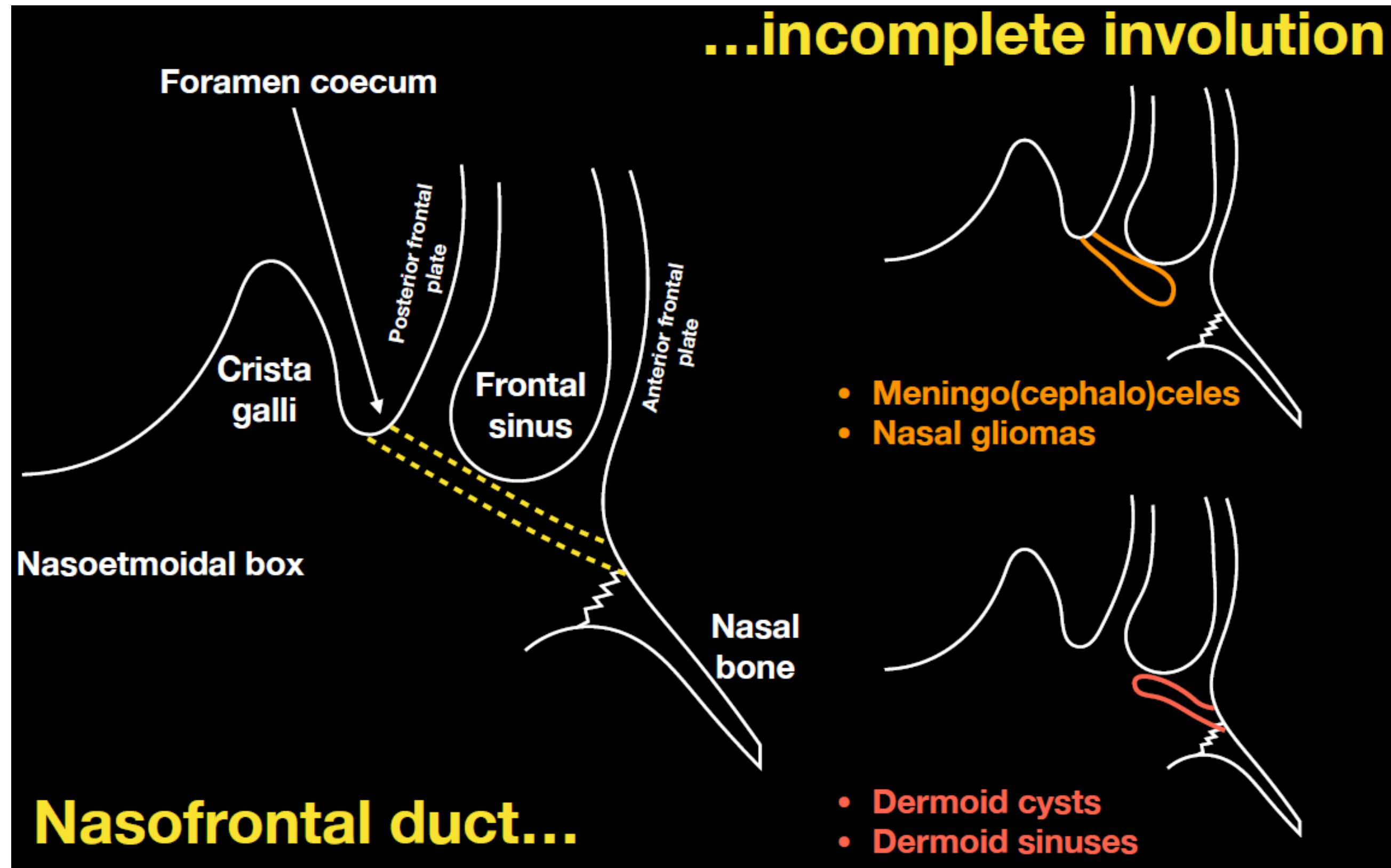
- Fascia (lata, rectus)
- Zsír

➤ Allograftok

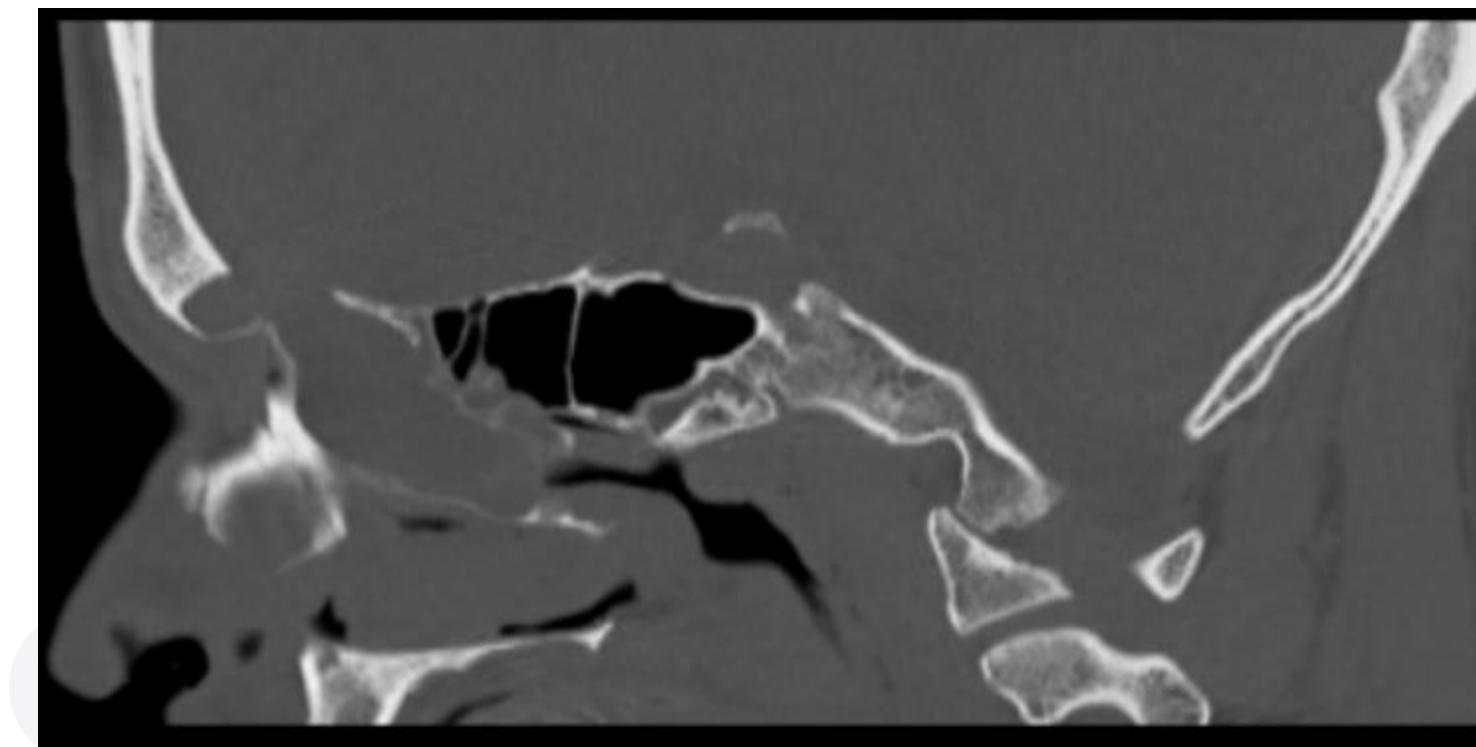
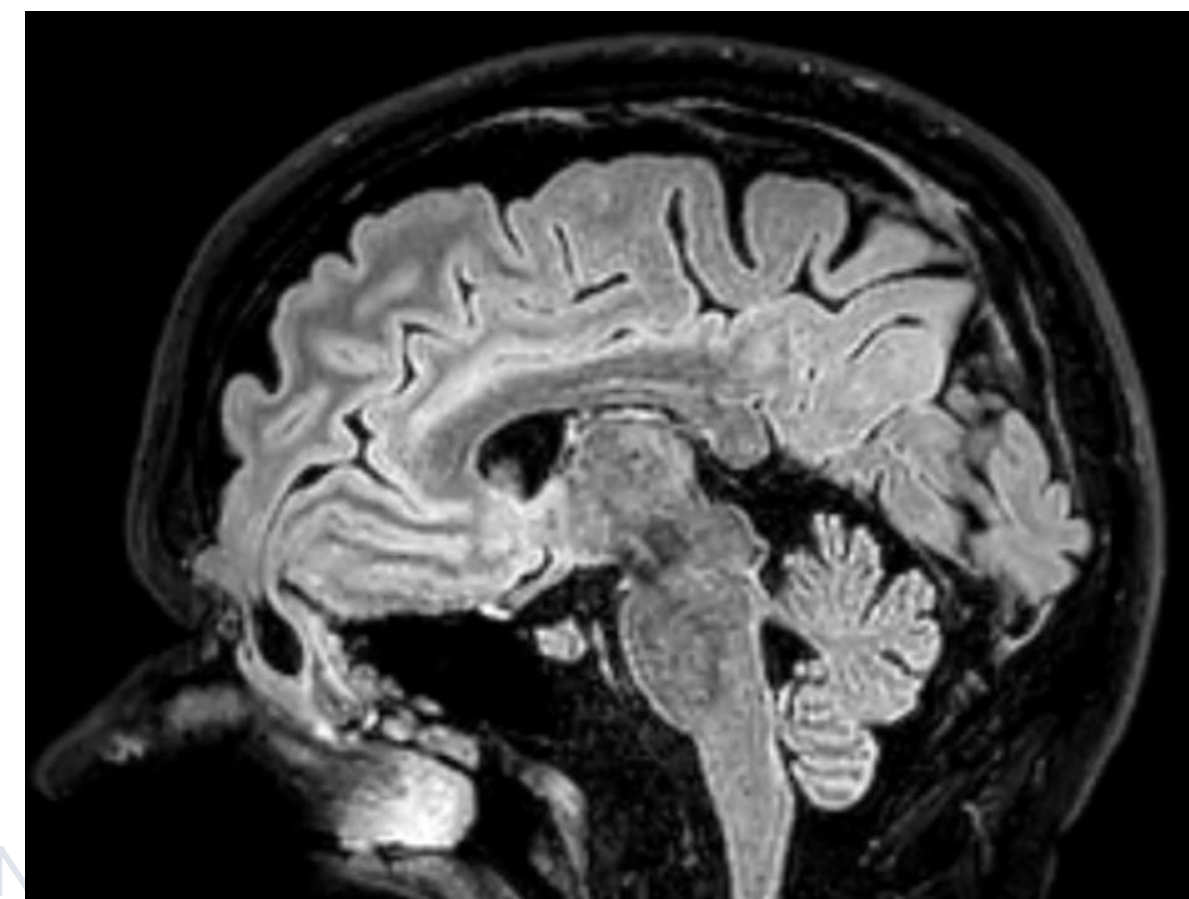
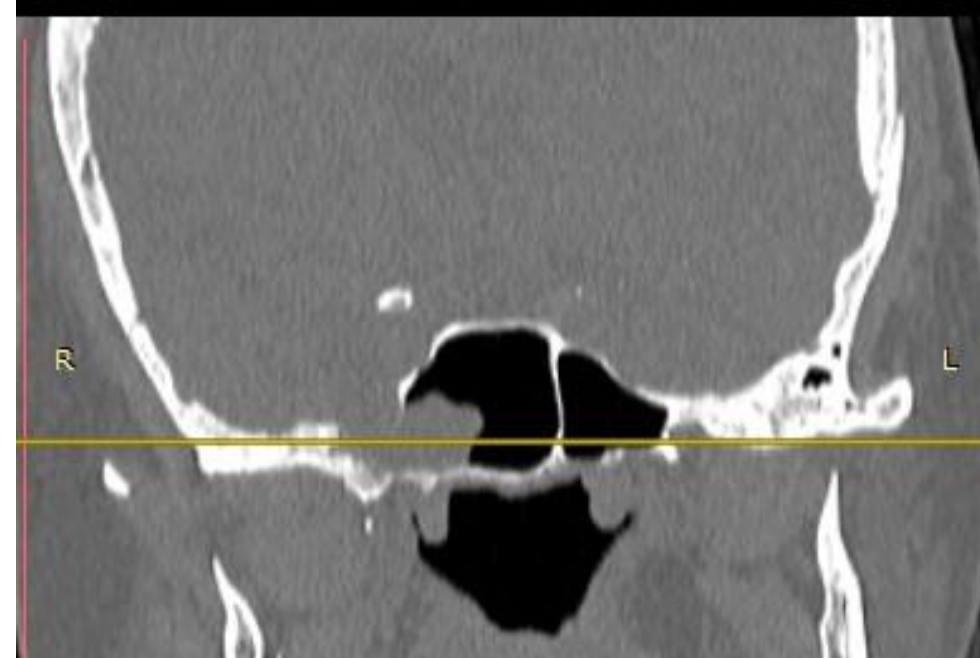
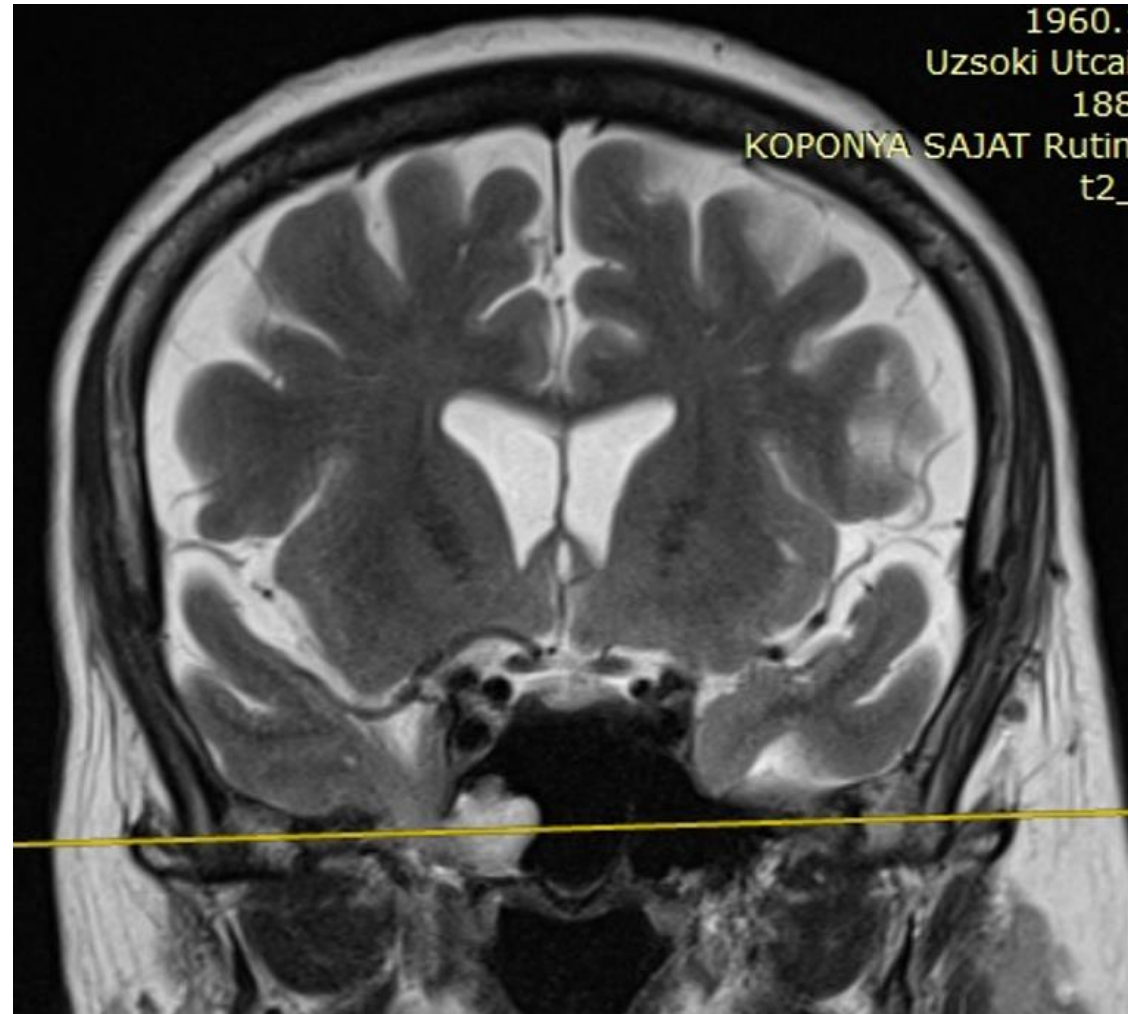
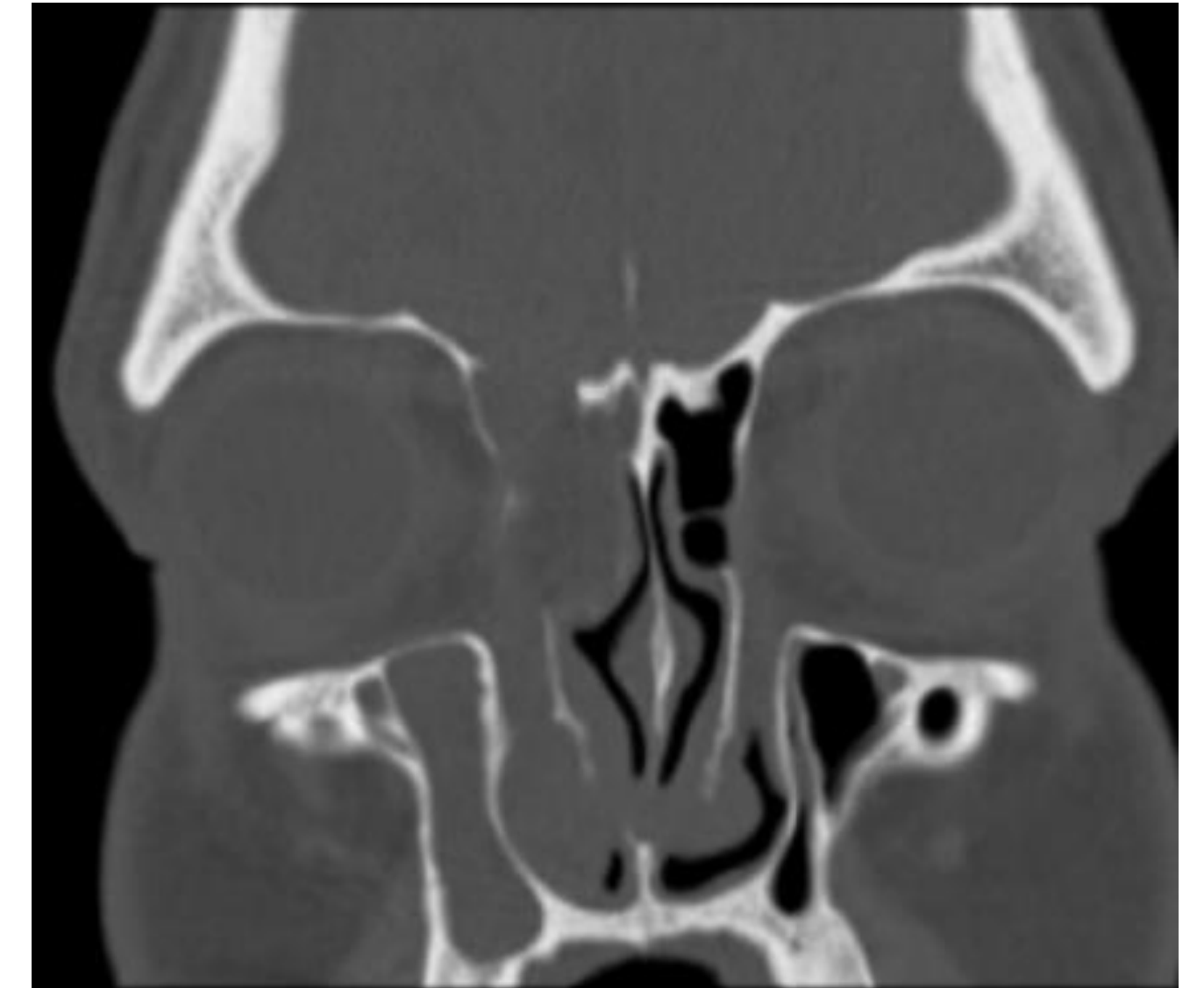
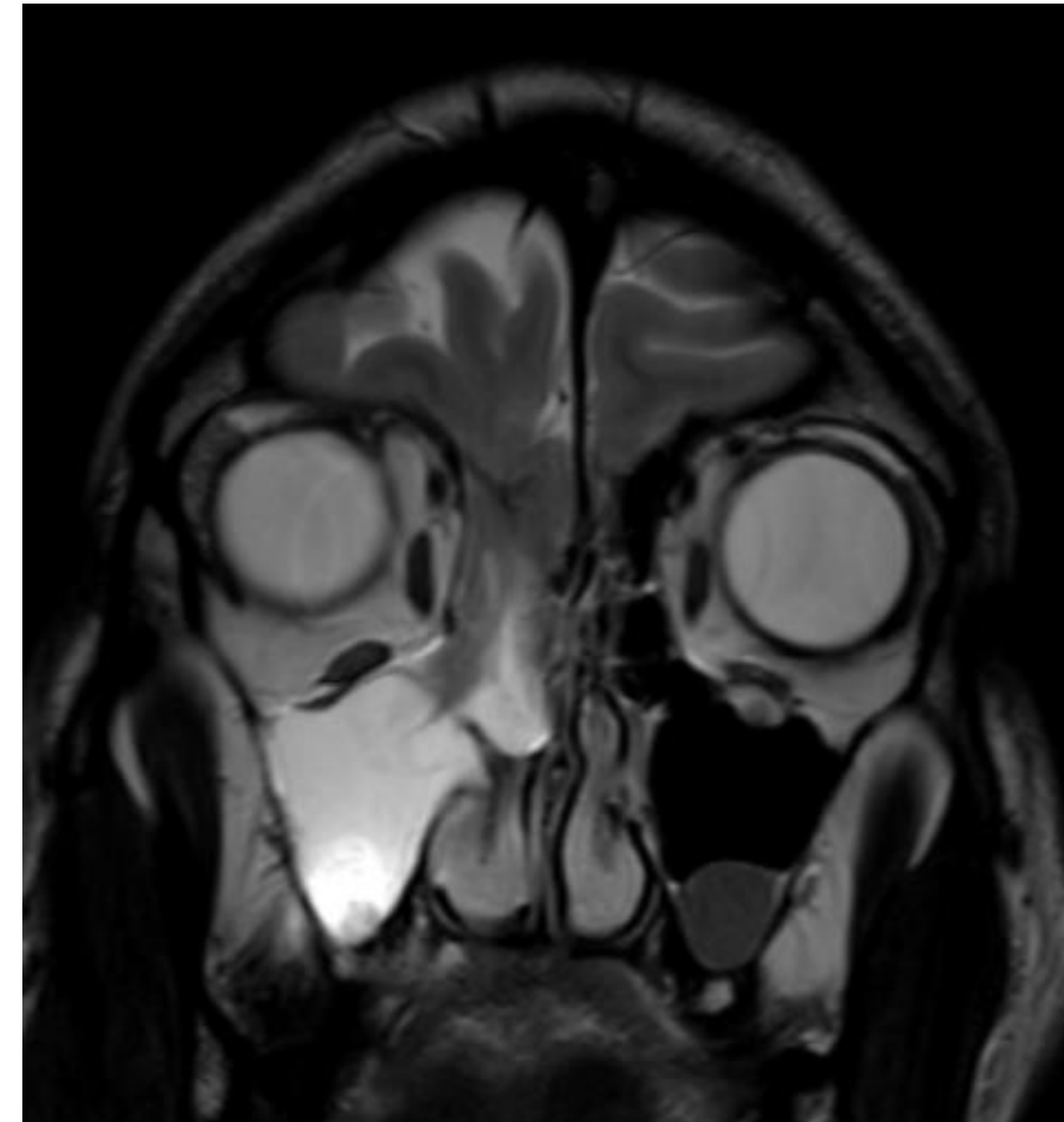
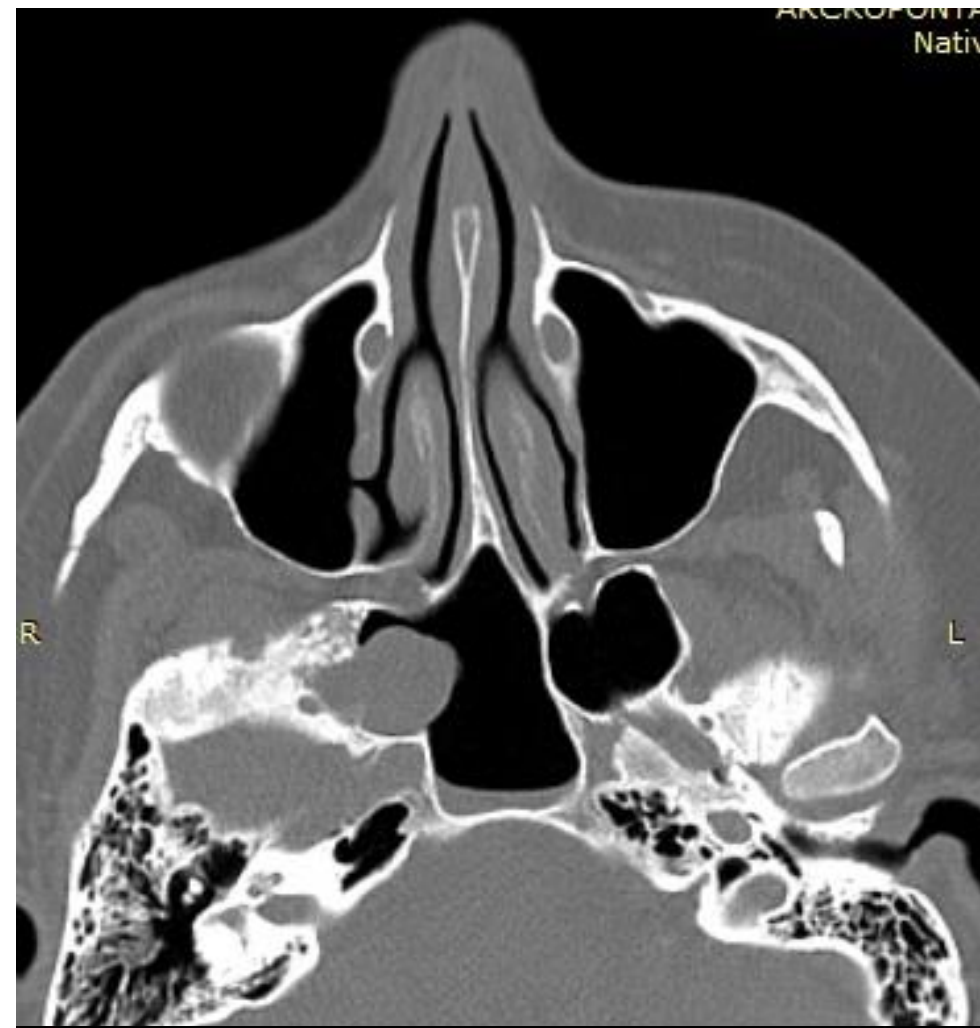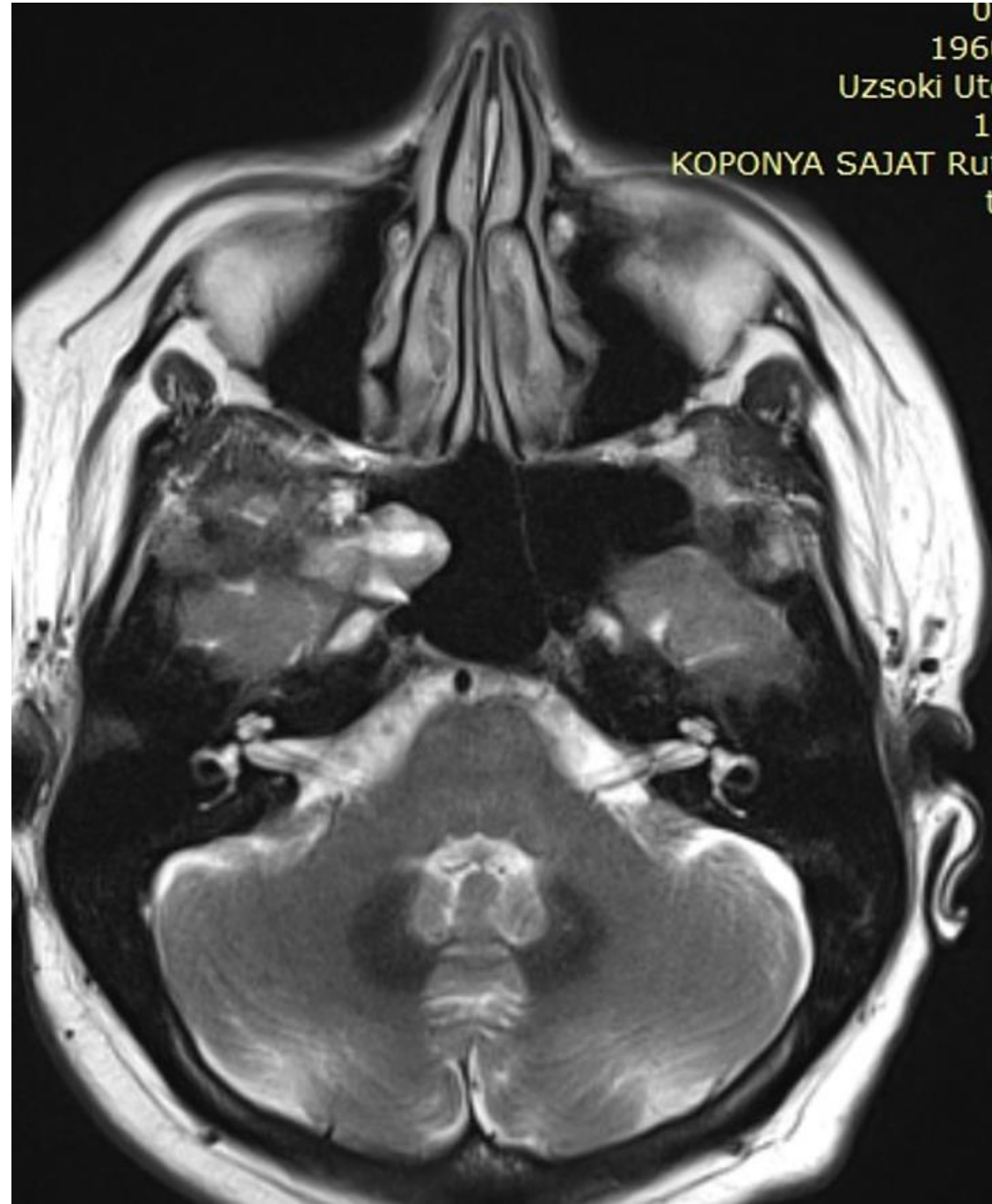
- Műdura (Neuro-patch)
- PMMA (Cemex)



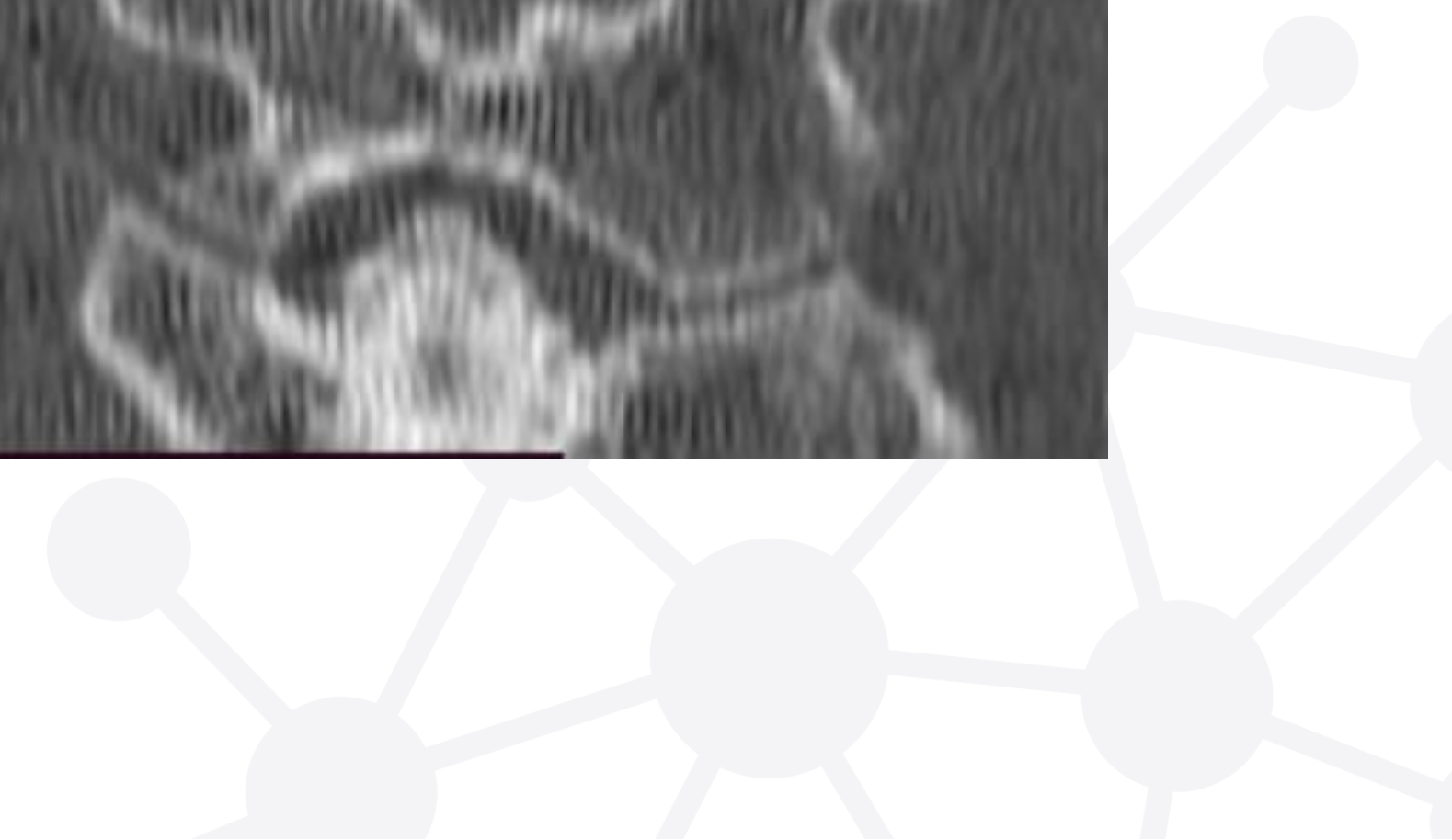
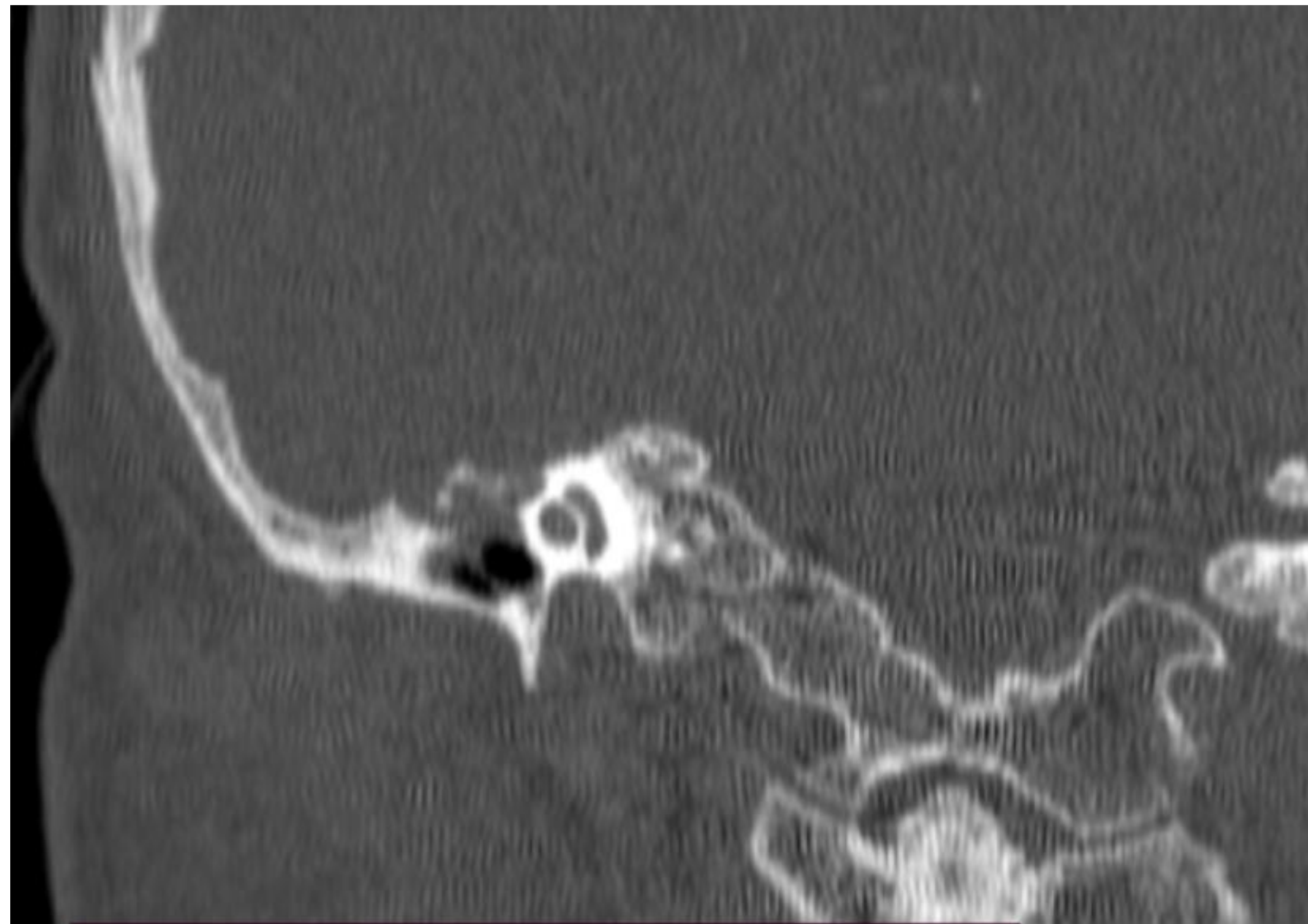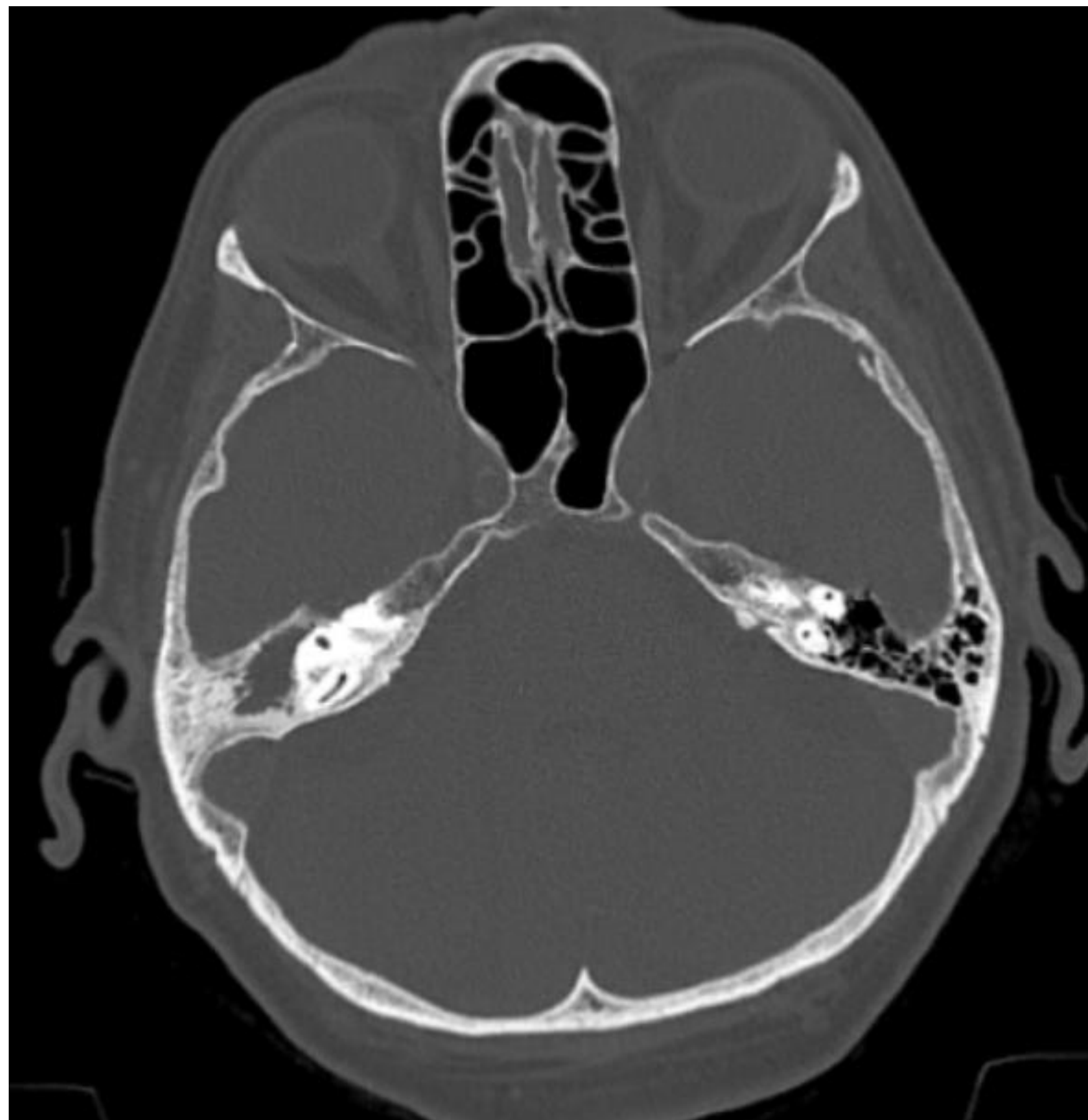
Fistulák, Encephalocelek



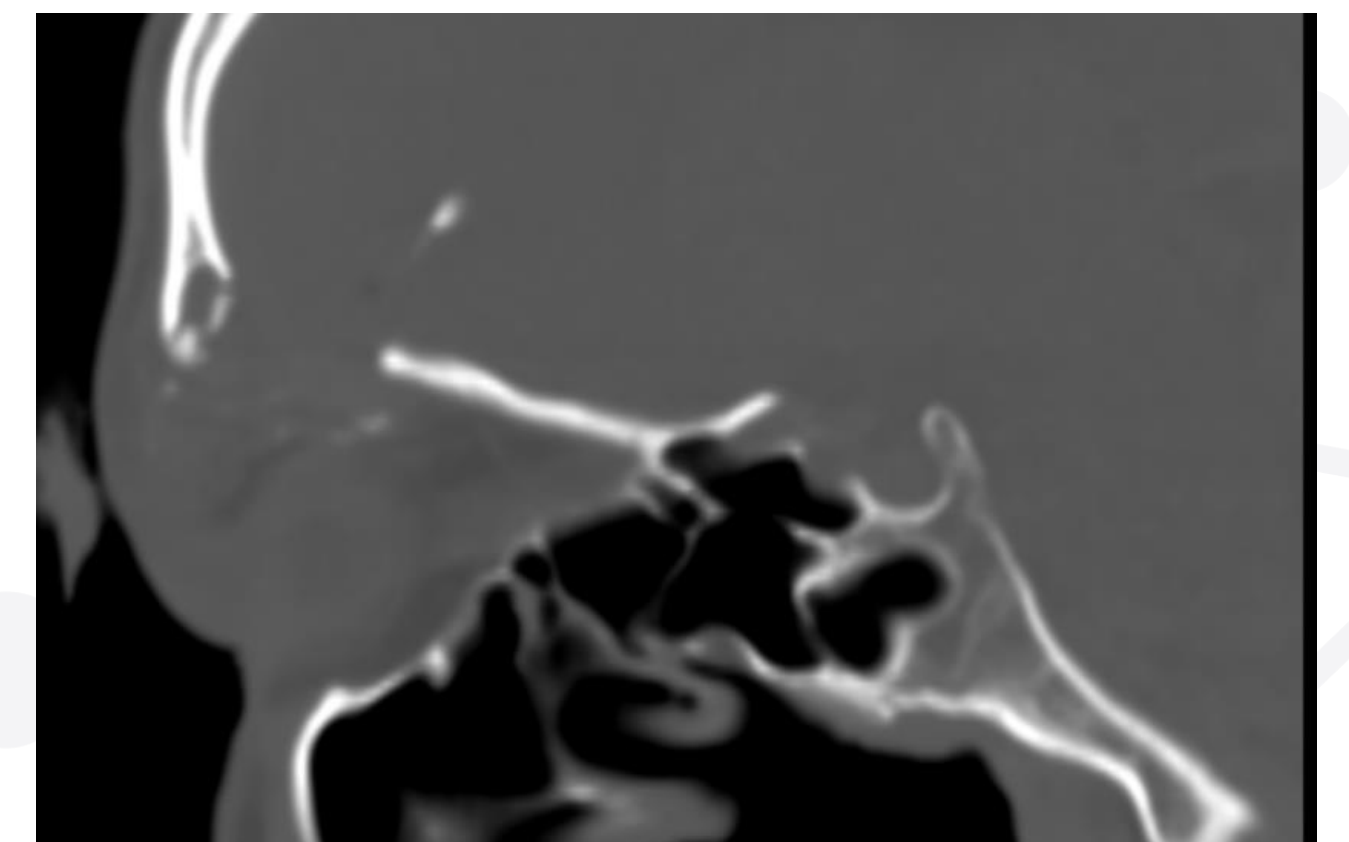
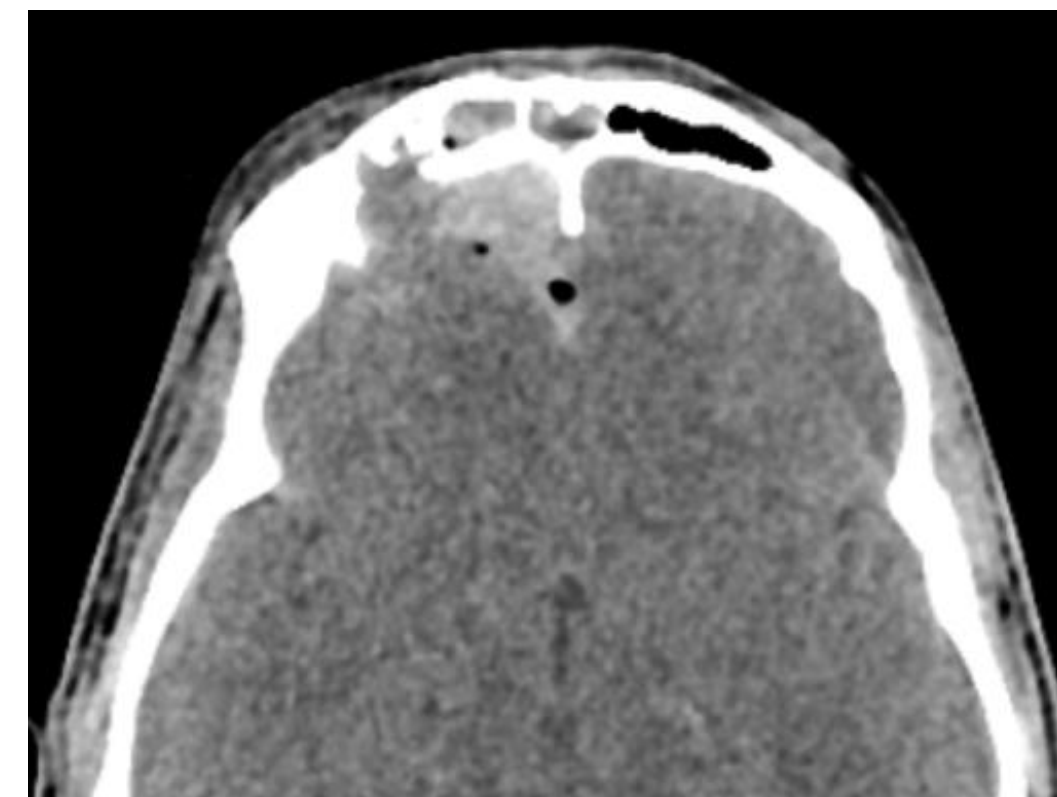
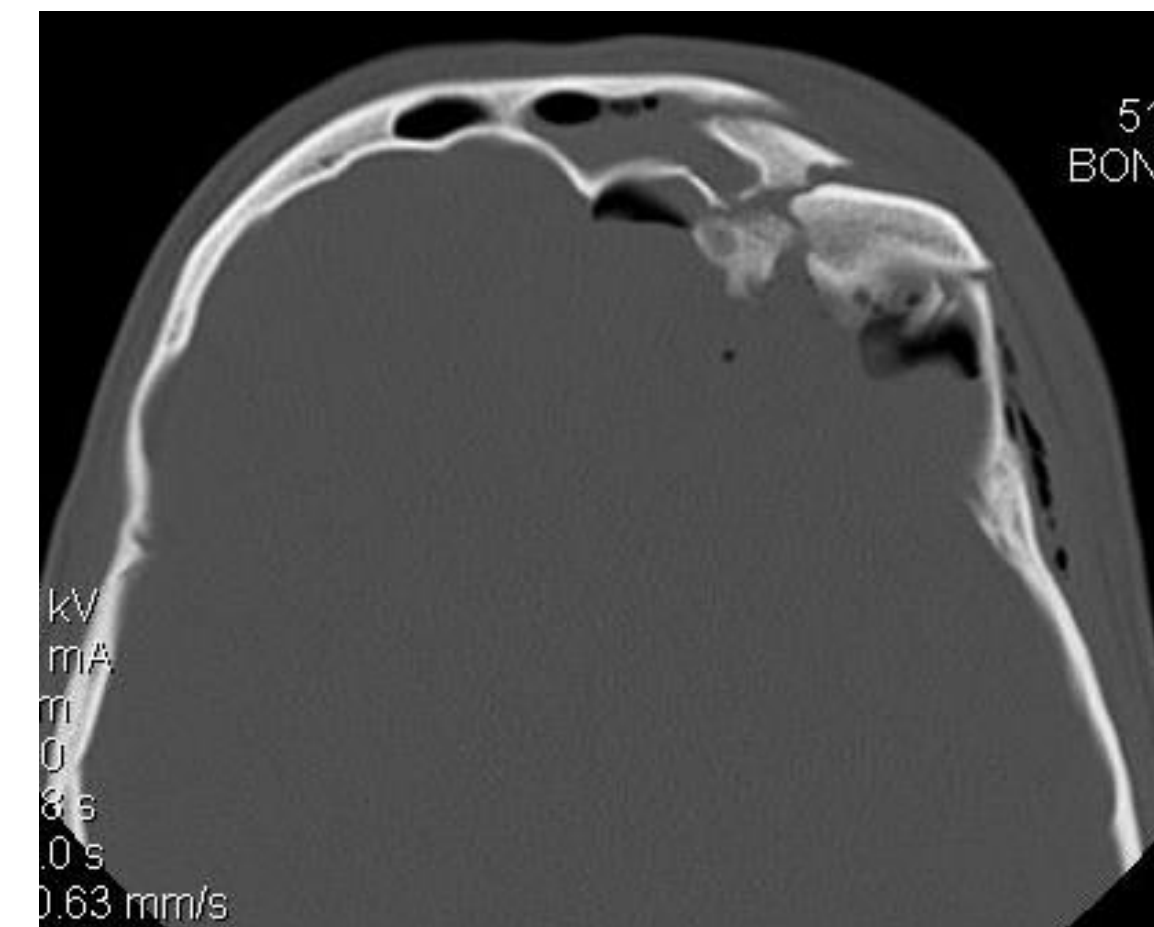
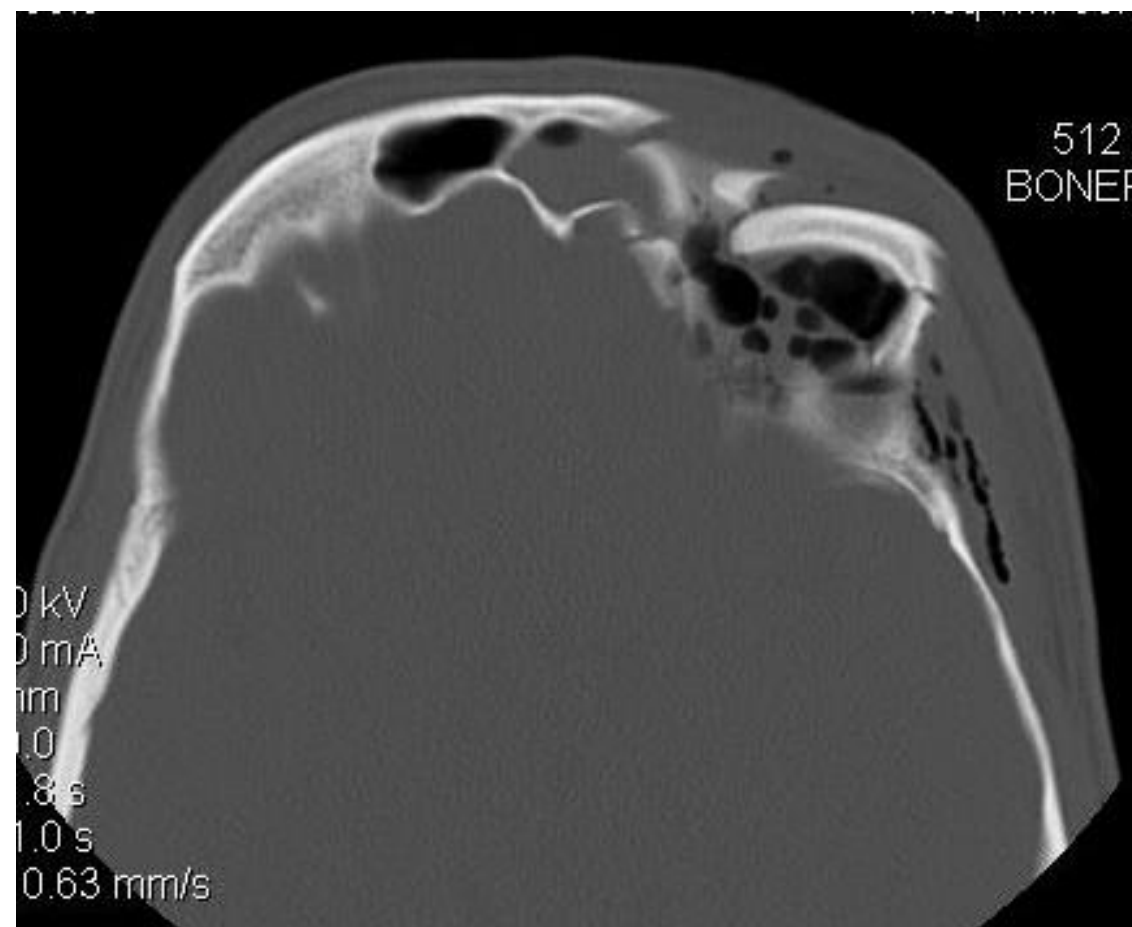
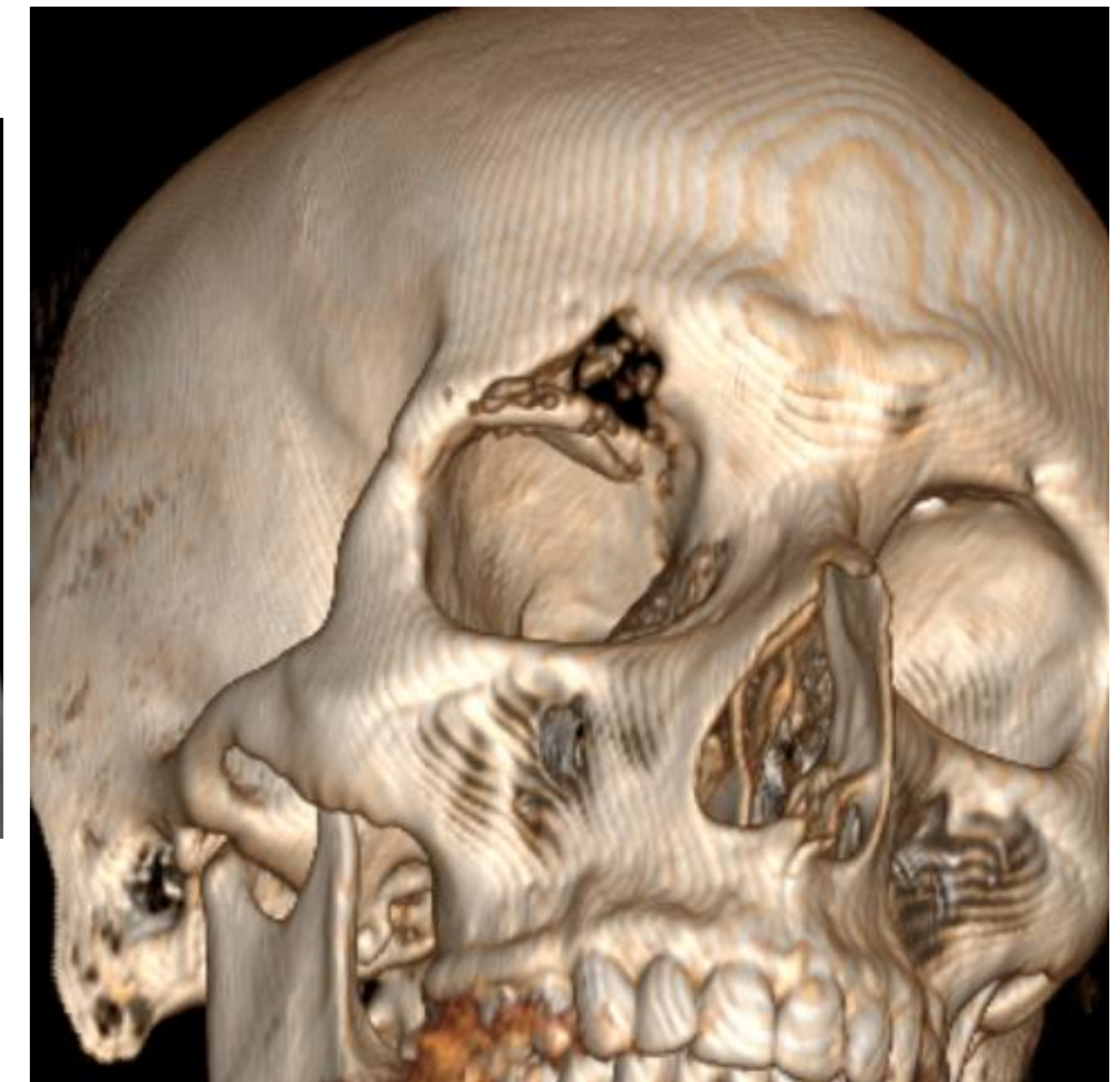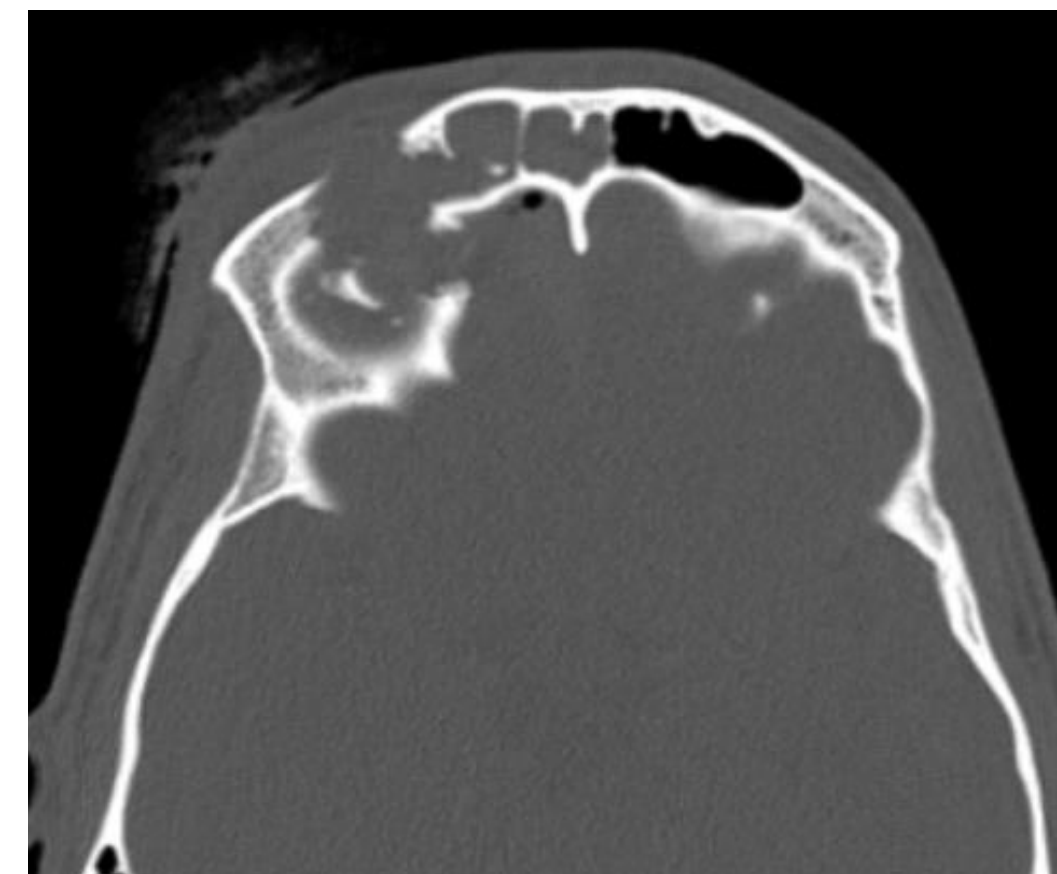
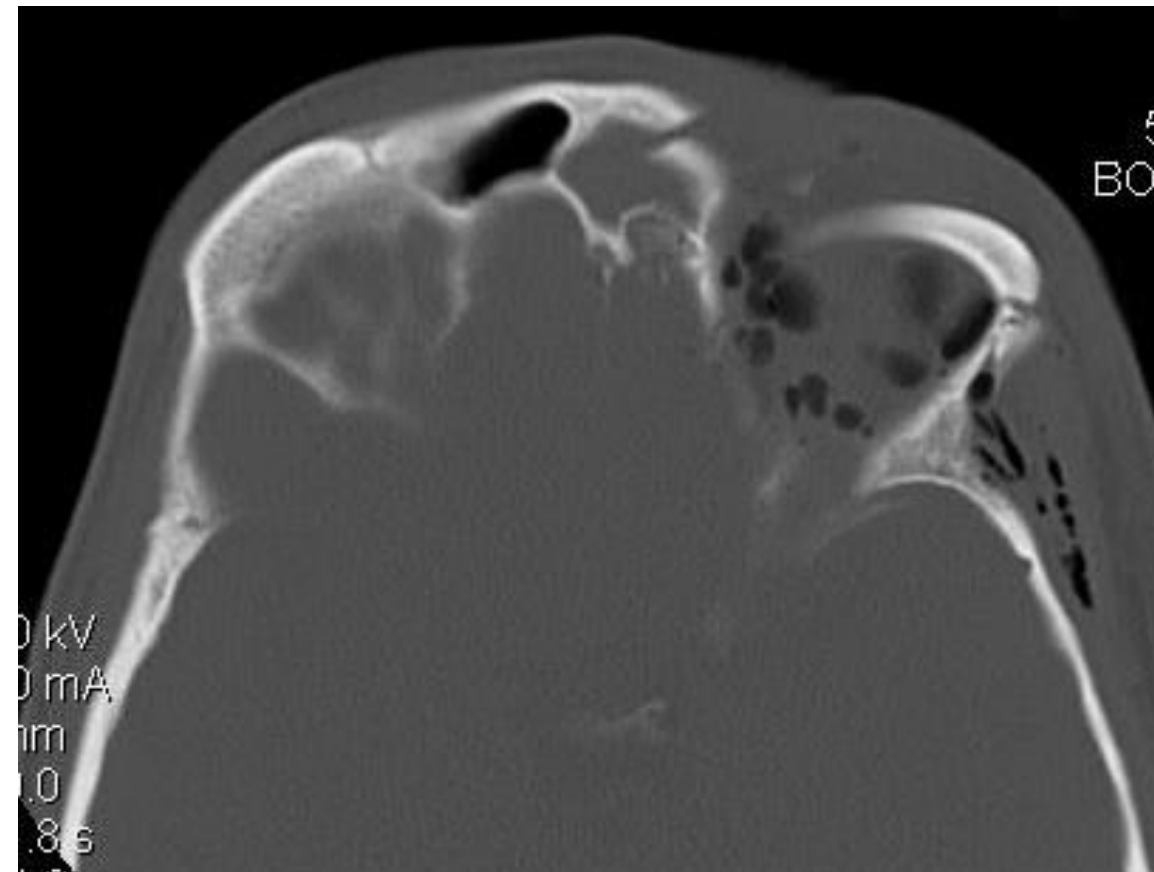
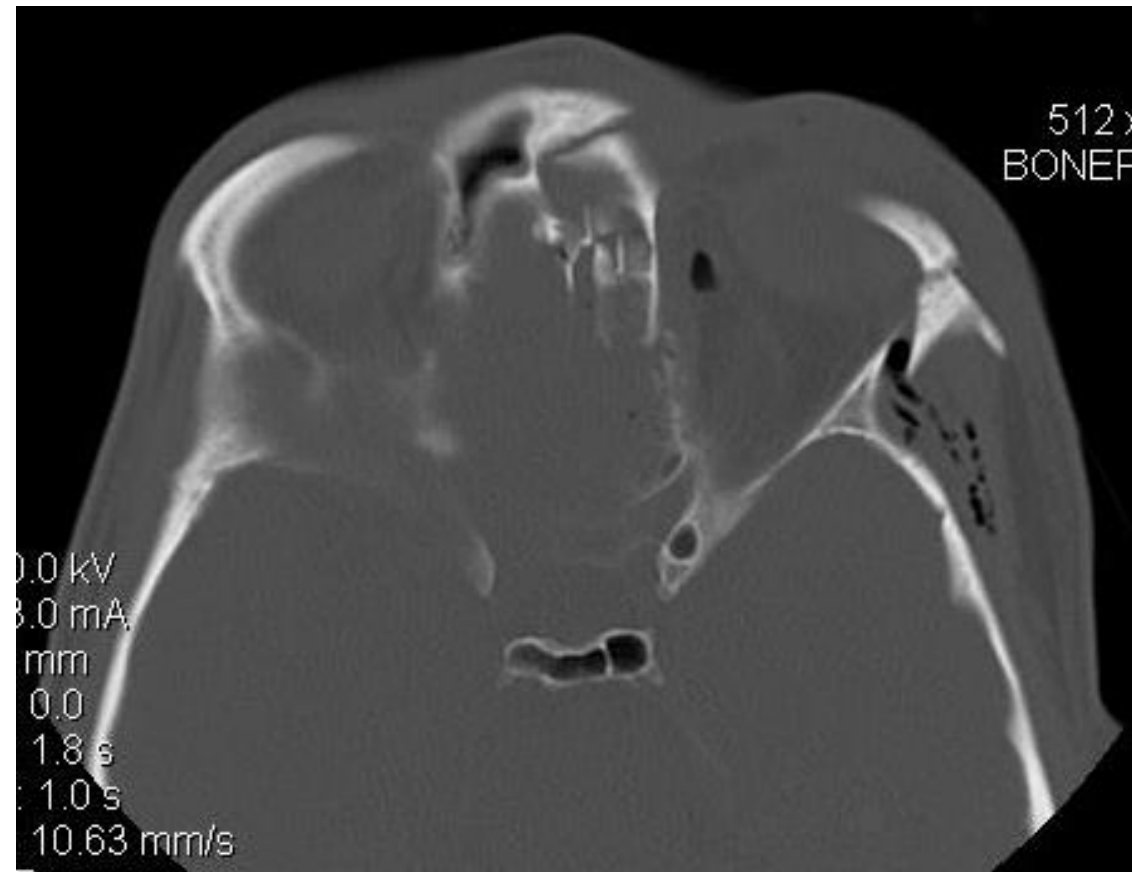
Fistulák, Encephalocelék (paranasalis sinusok)



Fistulák, Encephalocelék (pyramis)



Koponyatrauma



Daganatok

➤ Jóindulatú (intra/extraduralis)

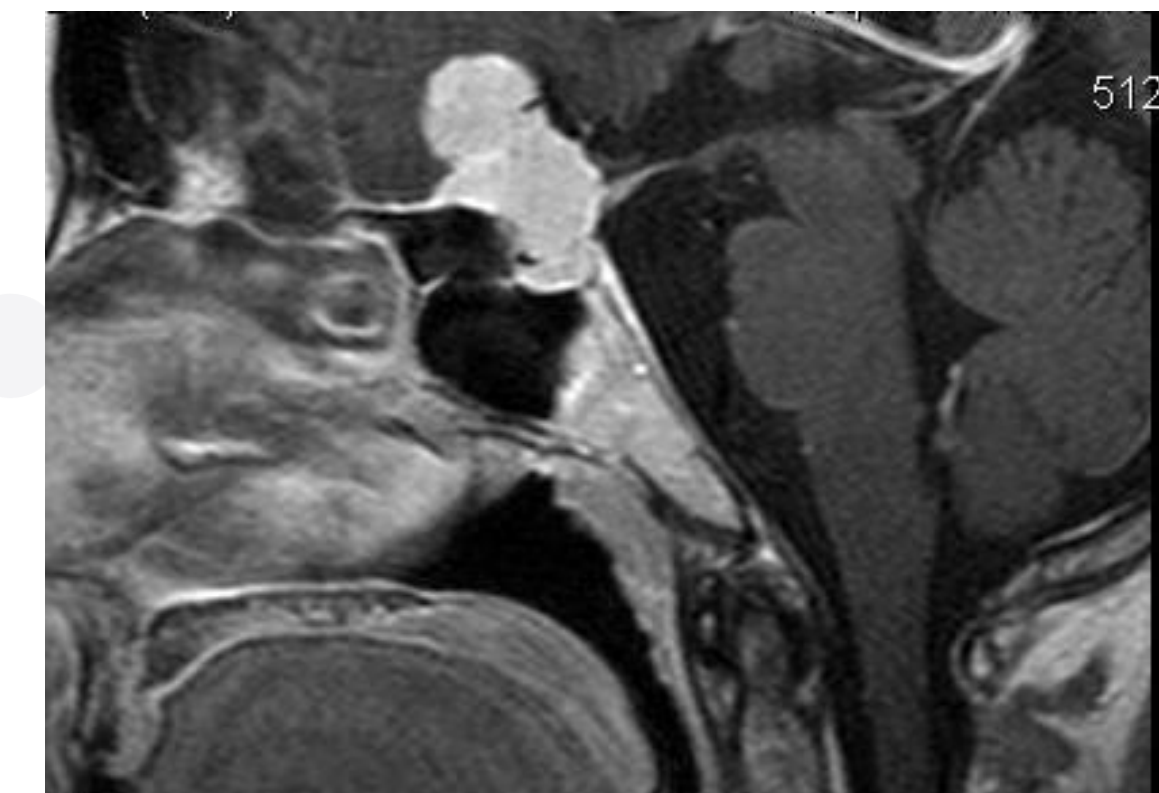
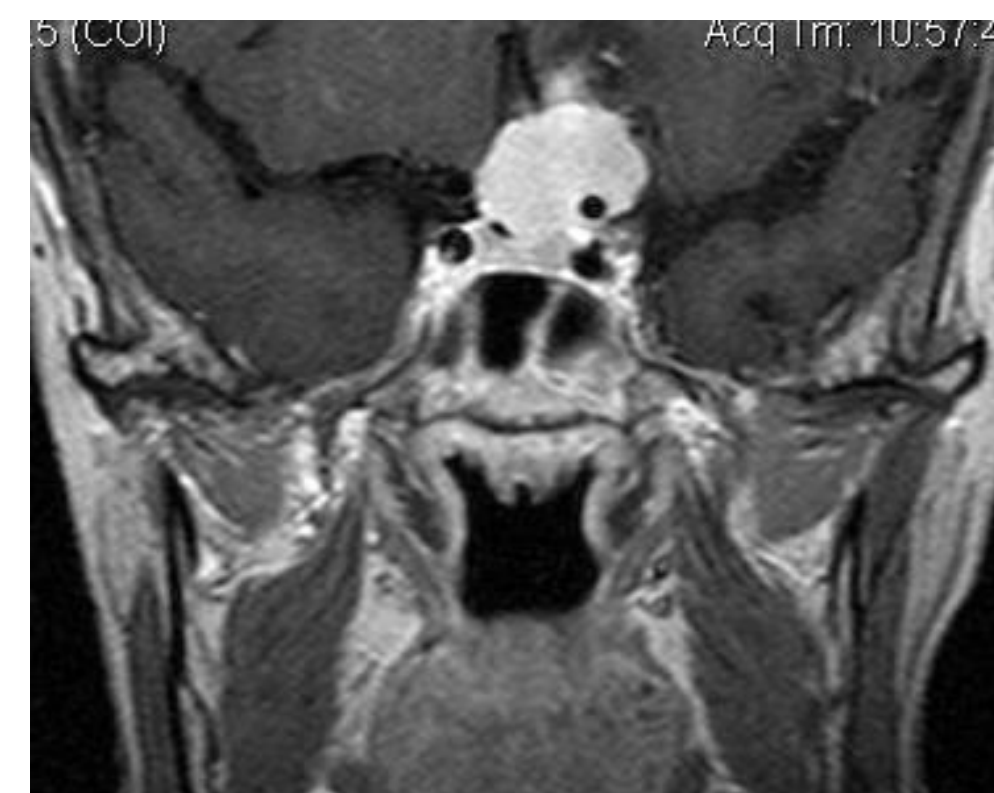
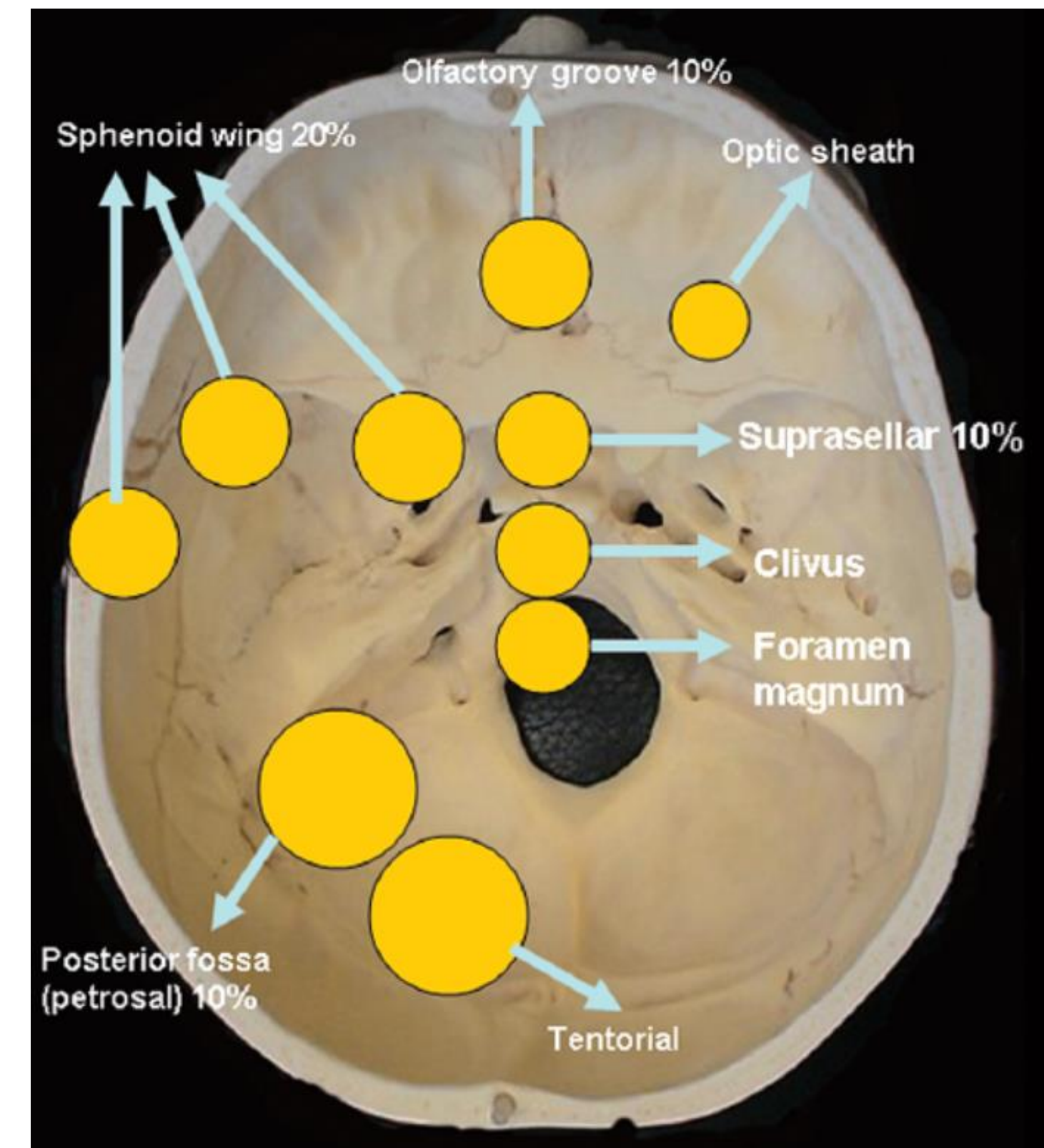
- Meningeoma
- Neurinoma (V, VII, IX)
- Hypophysis
- Chondroma, osteochondroma

➤ Malignus

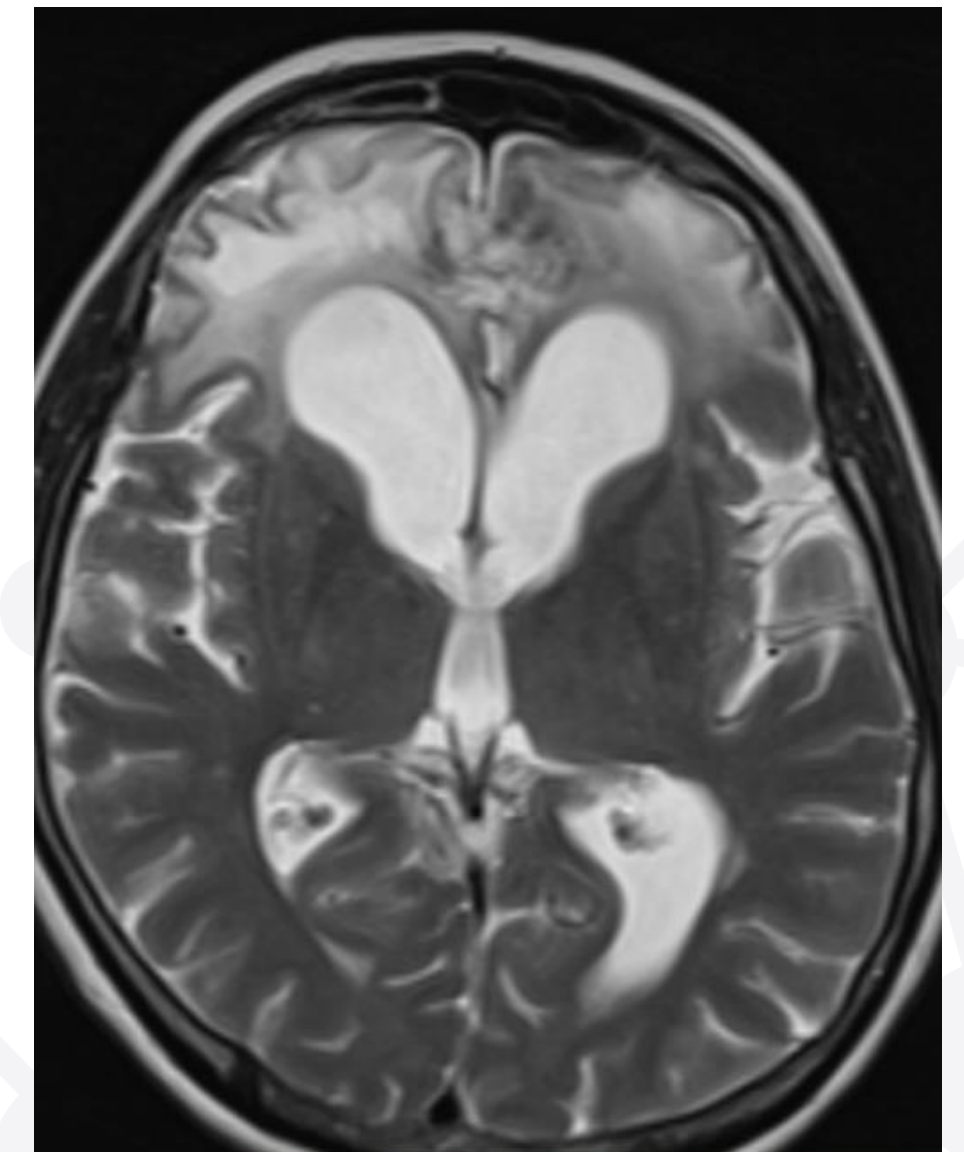
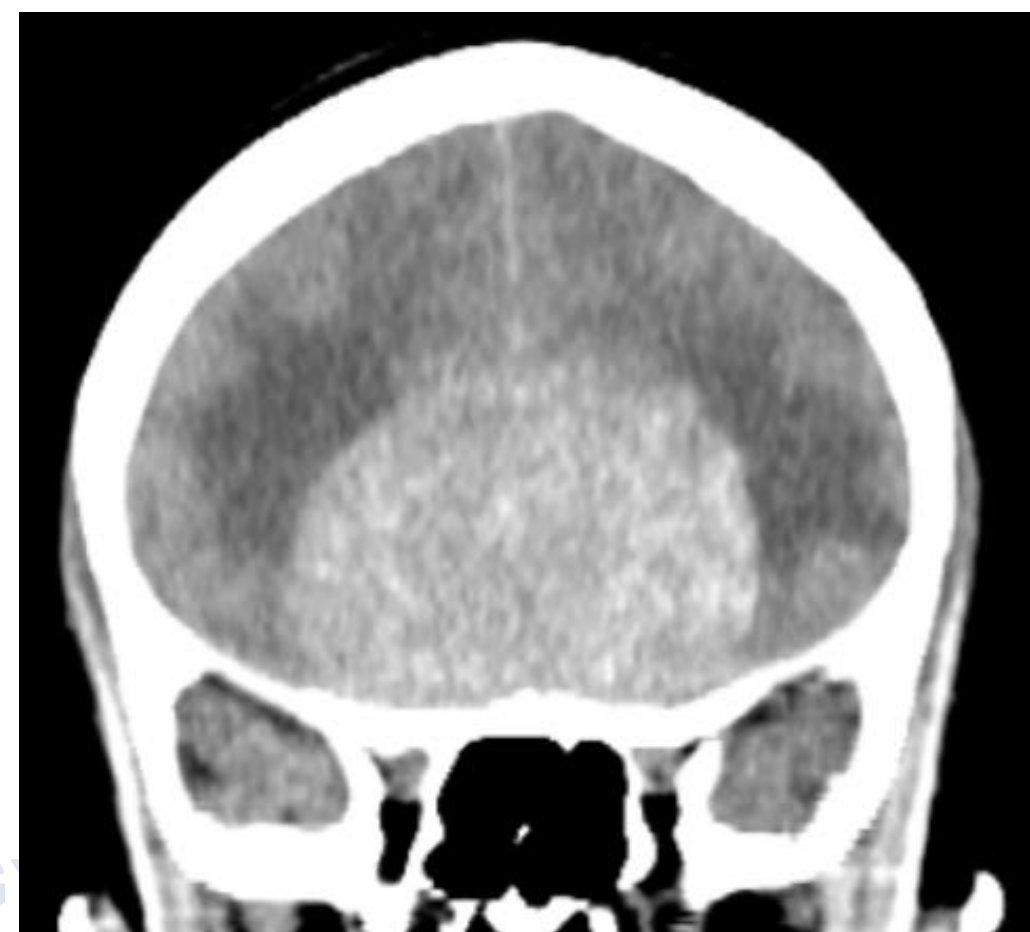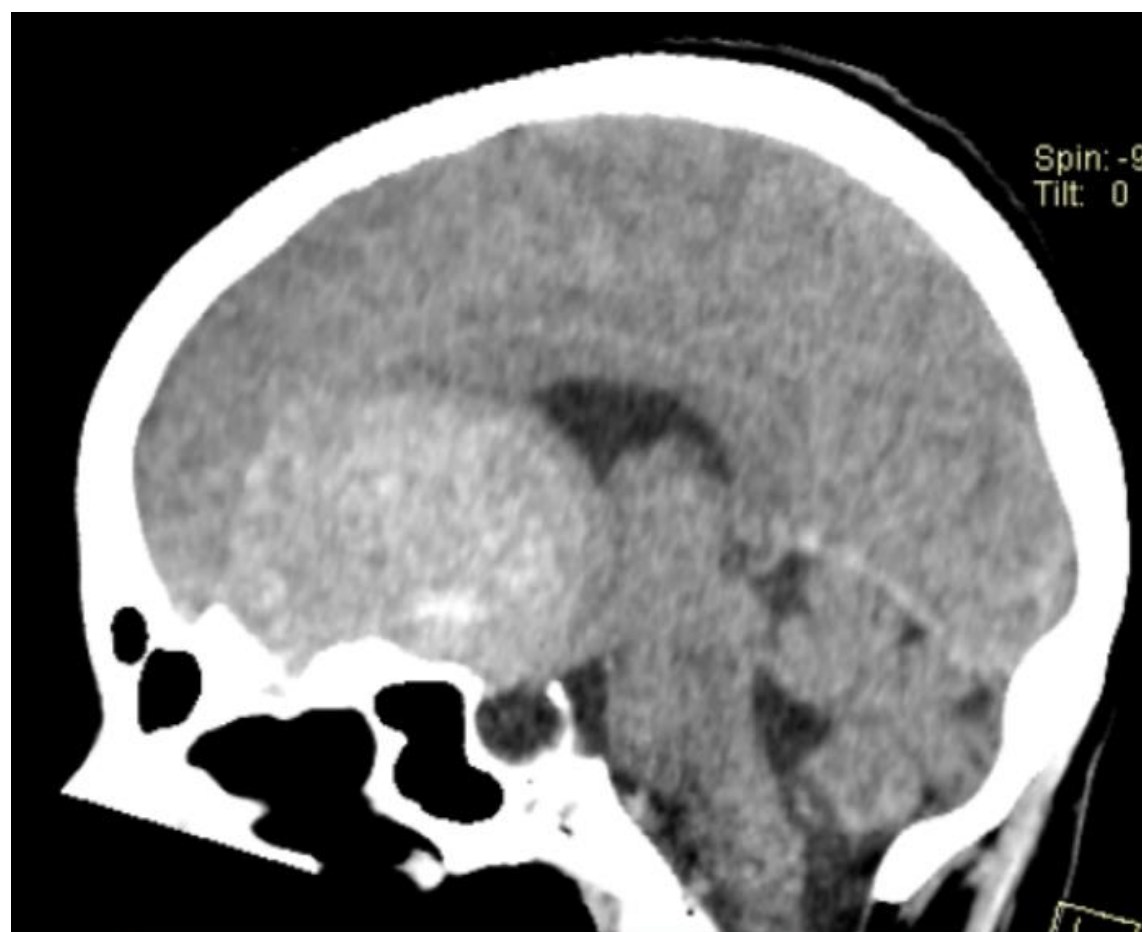
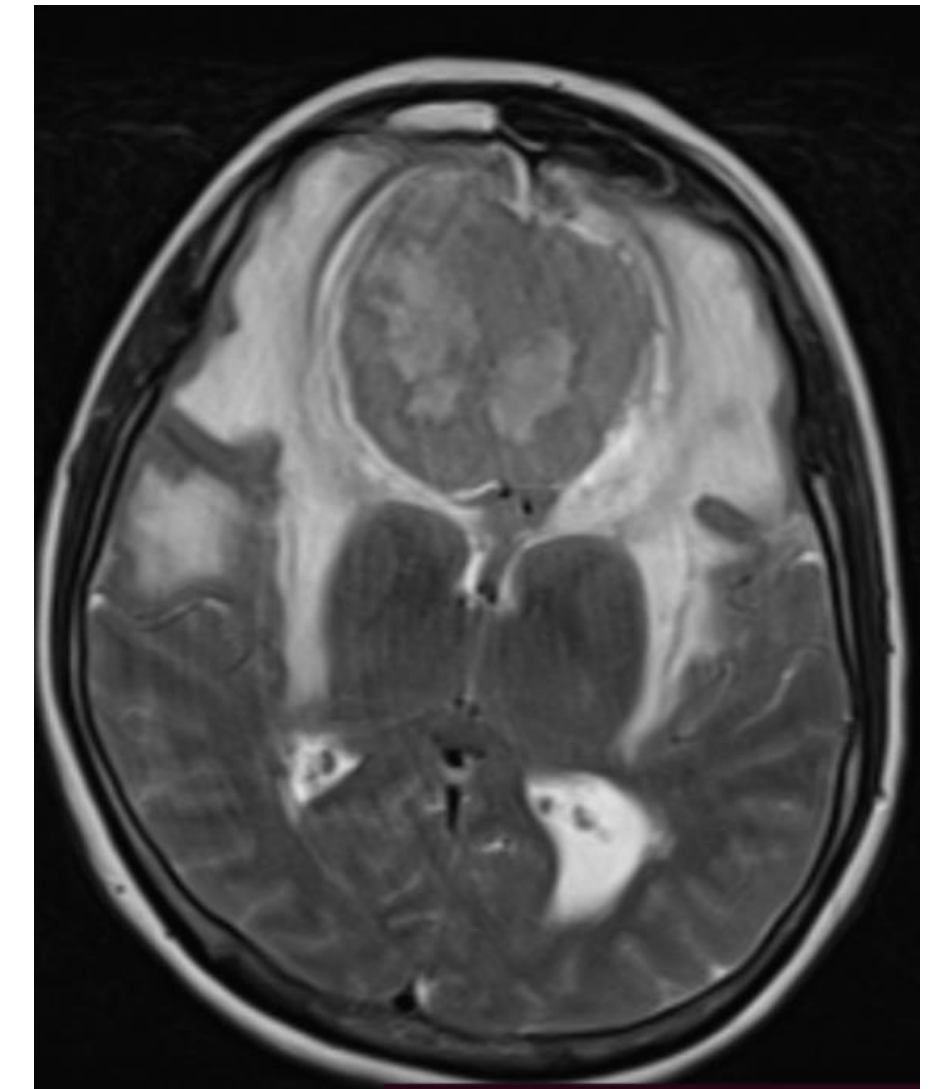
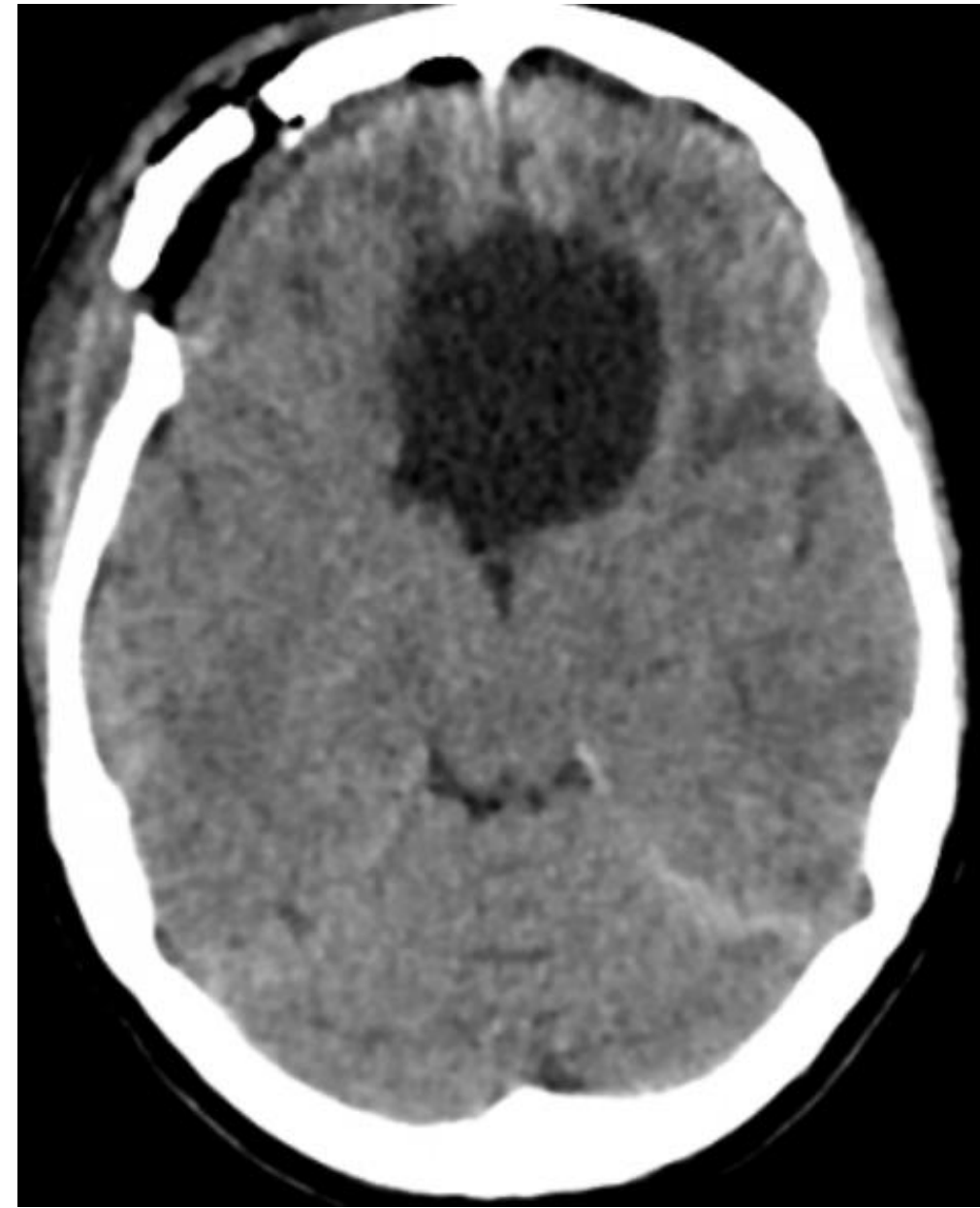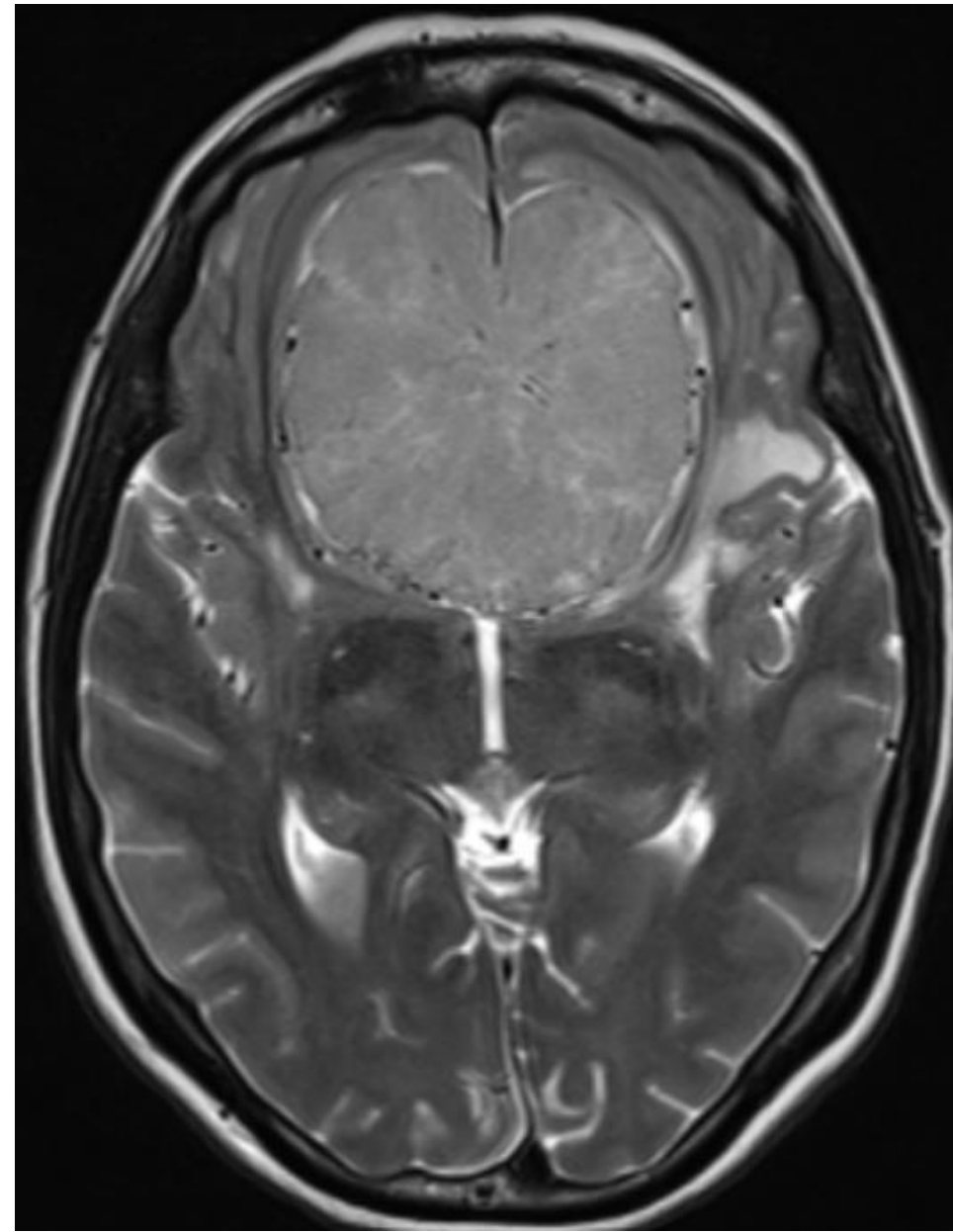
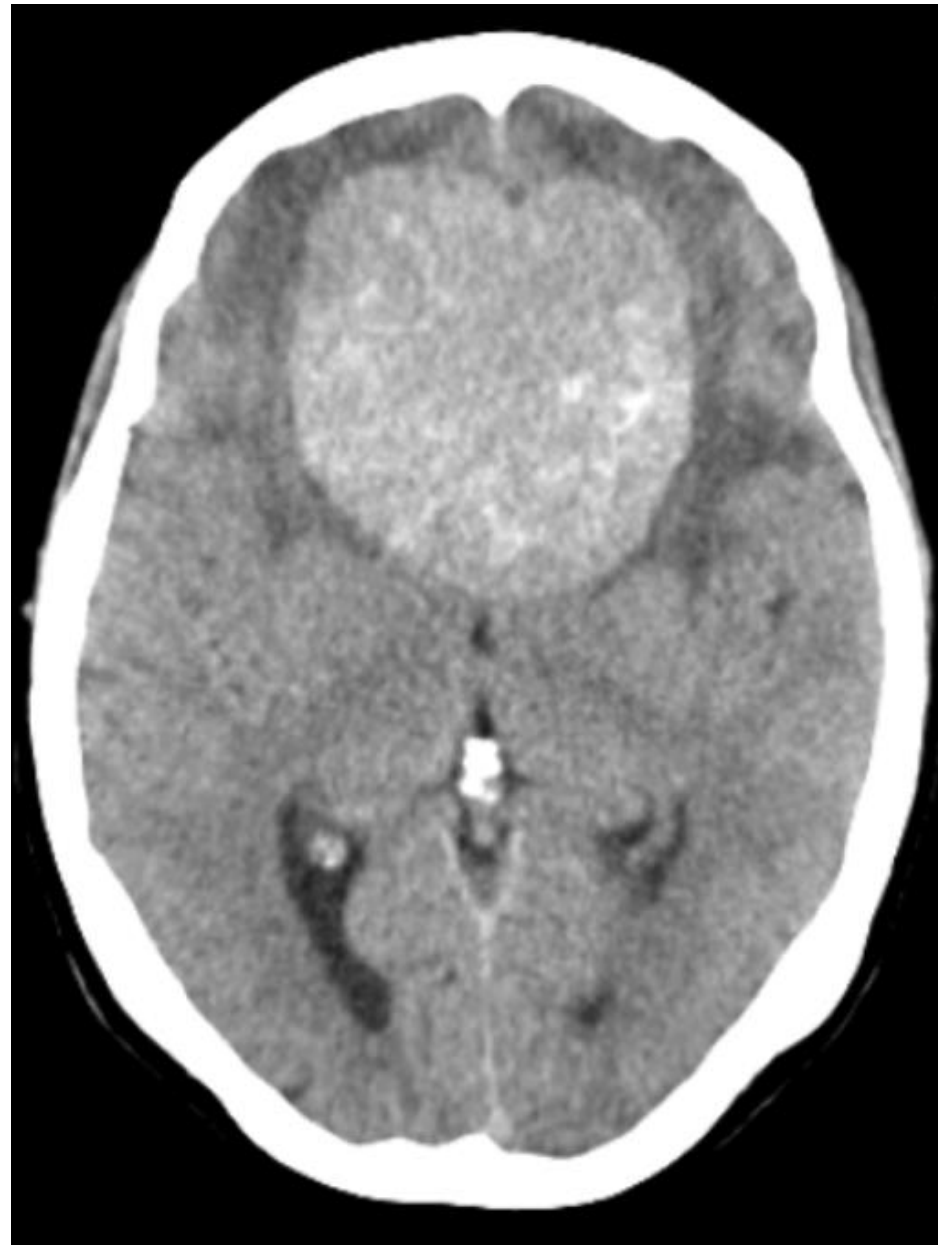- Metastasis
- Chordoma, chondrosarcoma

➤ Melléküreg

- Benignus
- Malignus

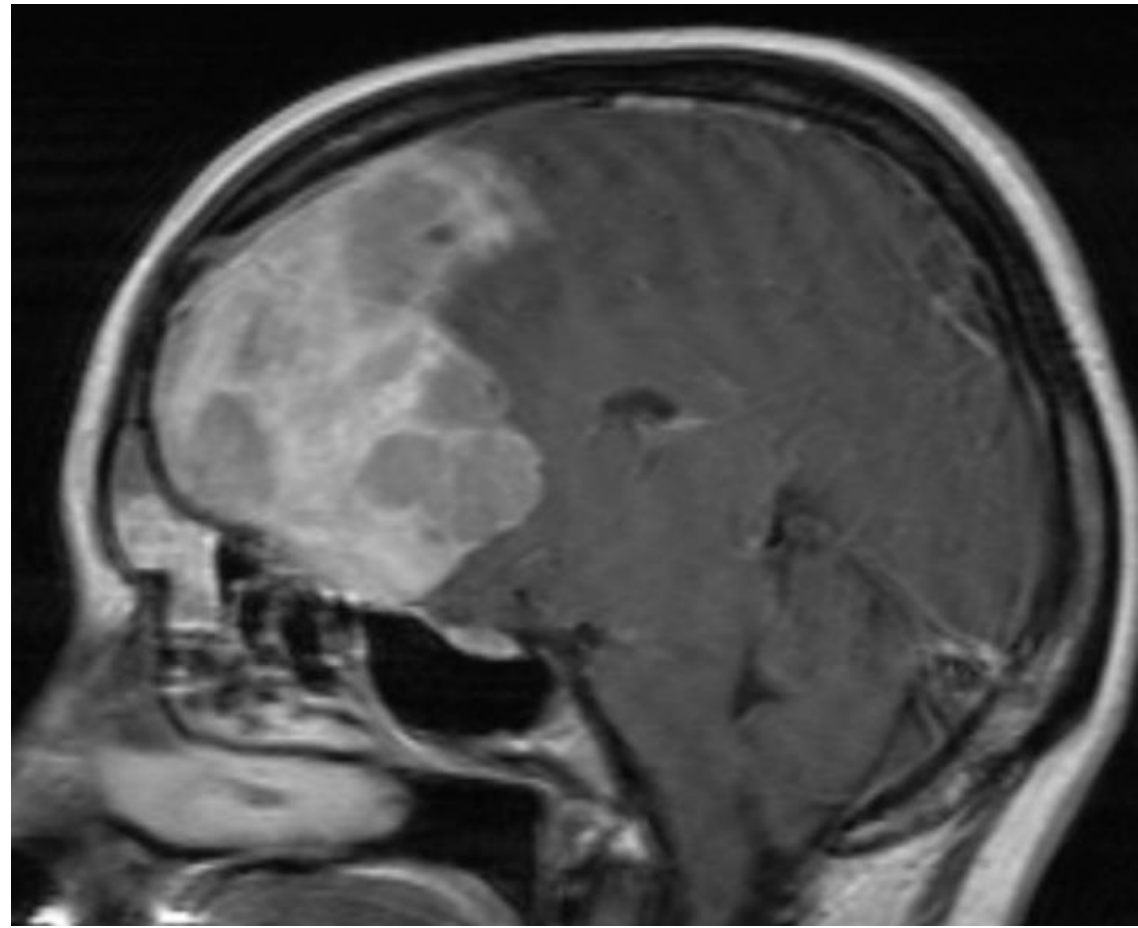


Frontobasalis (olfactorius) meningeoma

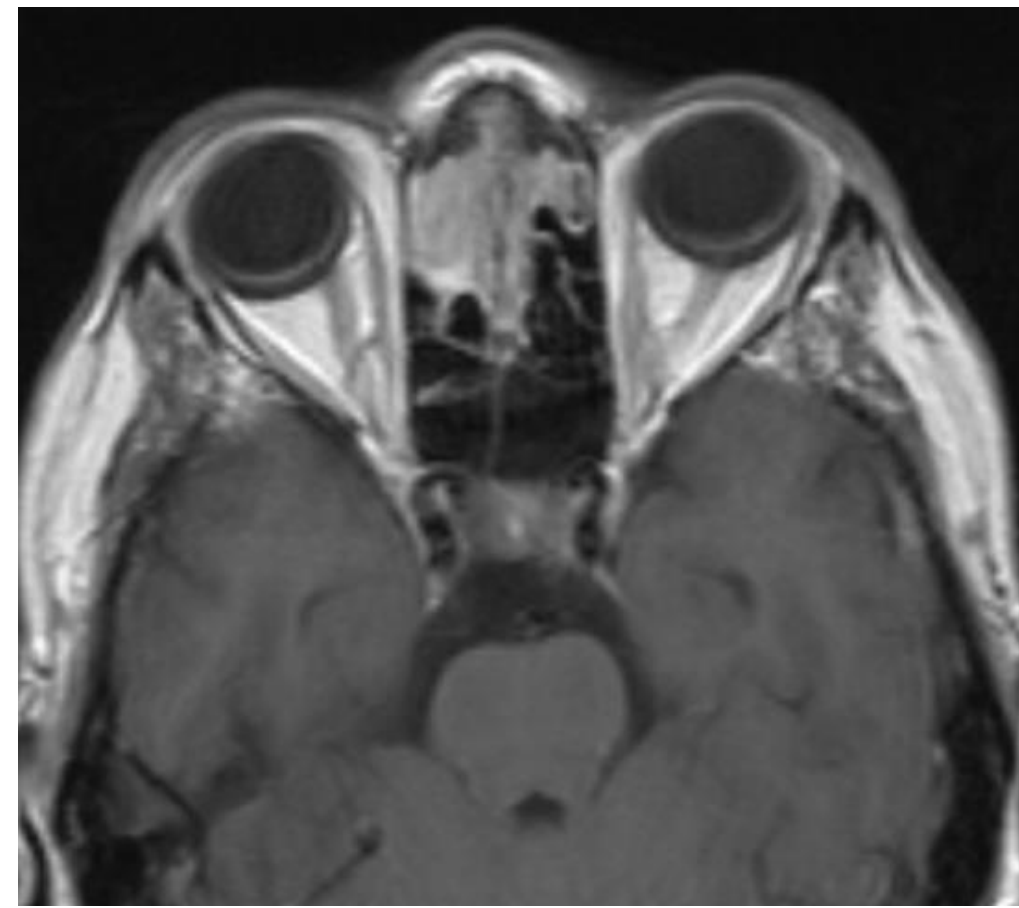


Frontobasalis meningeoma: extraduralis rész!

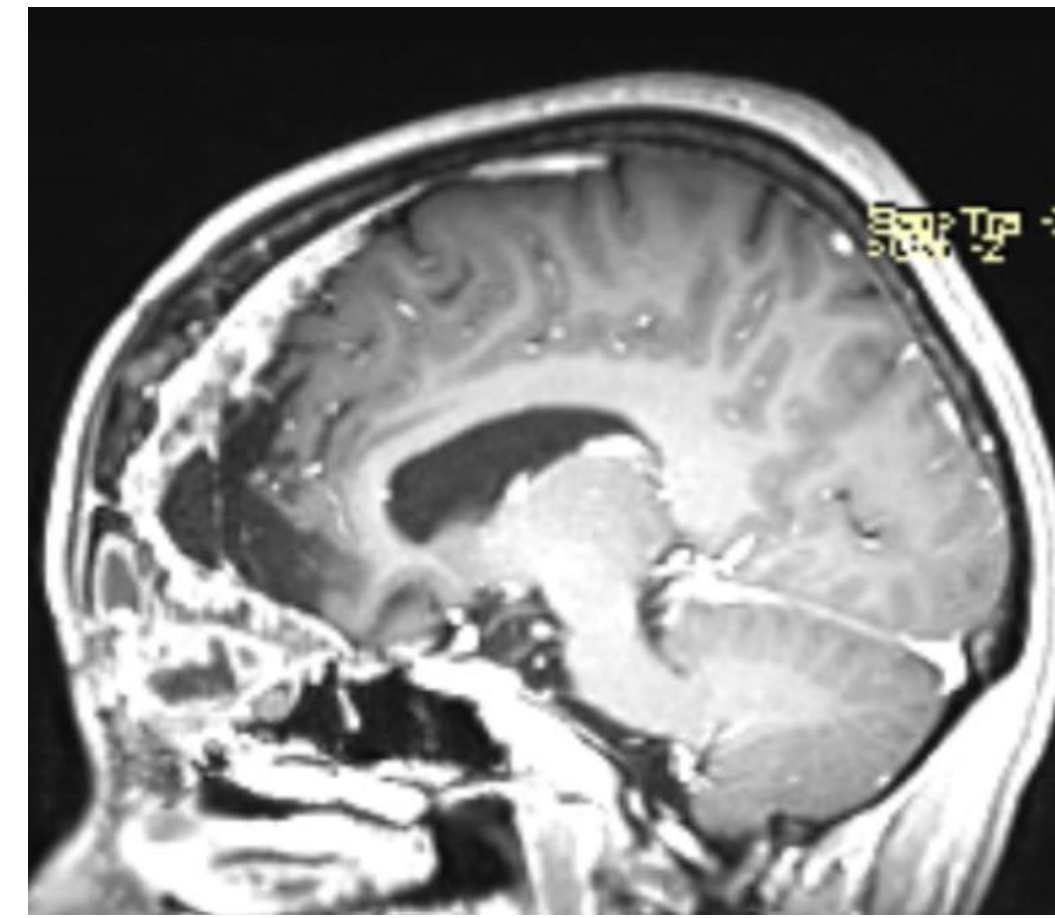
2011



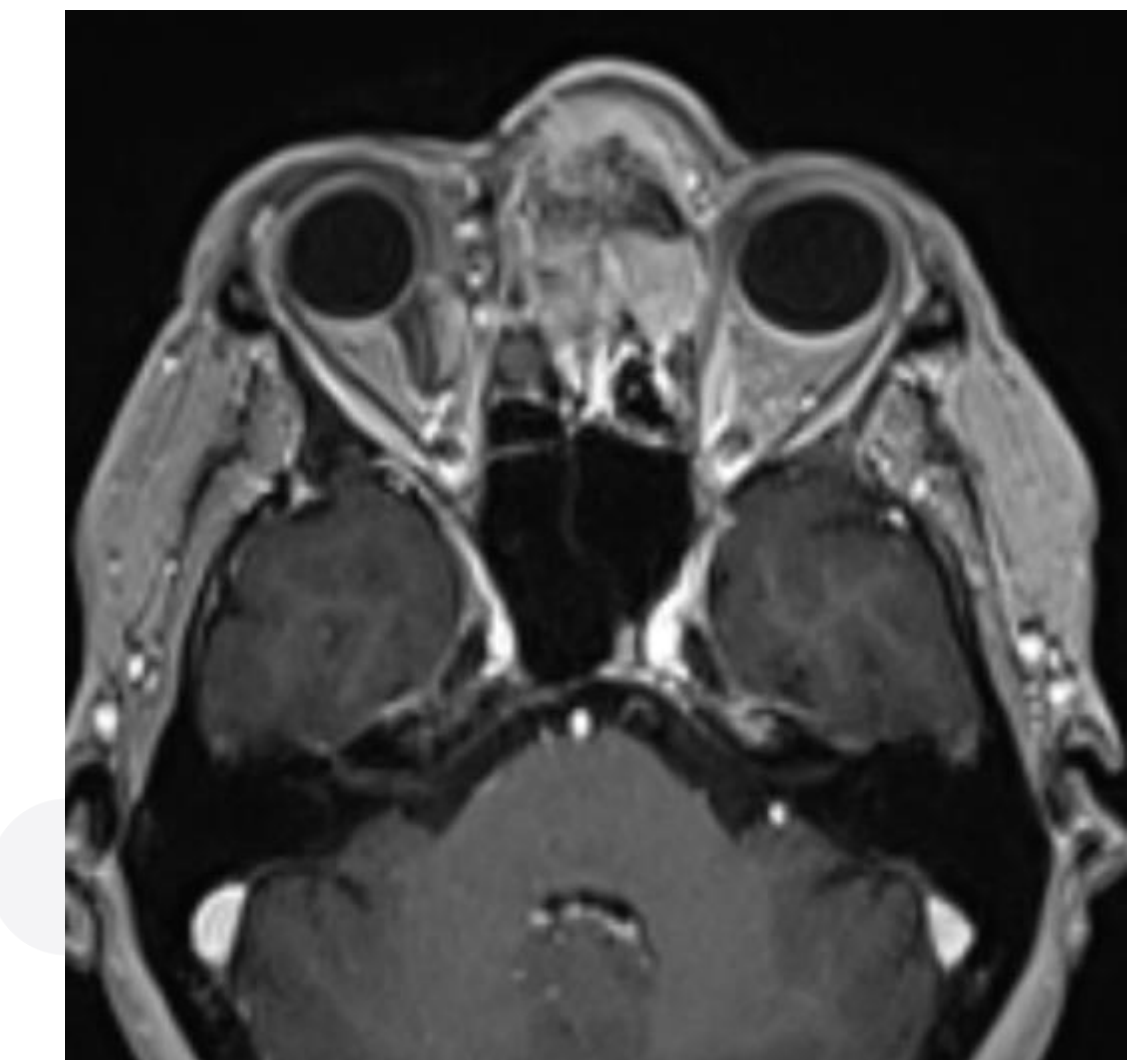
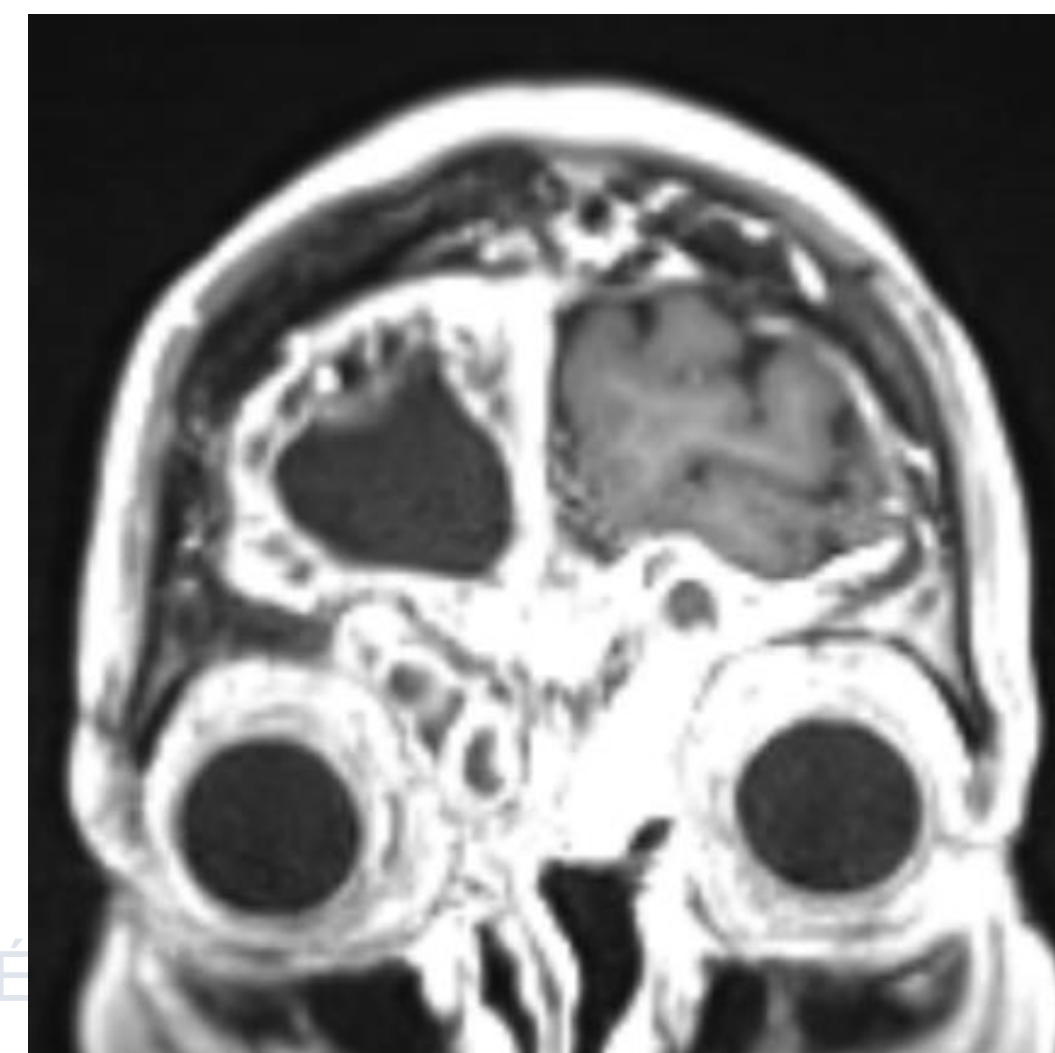
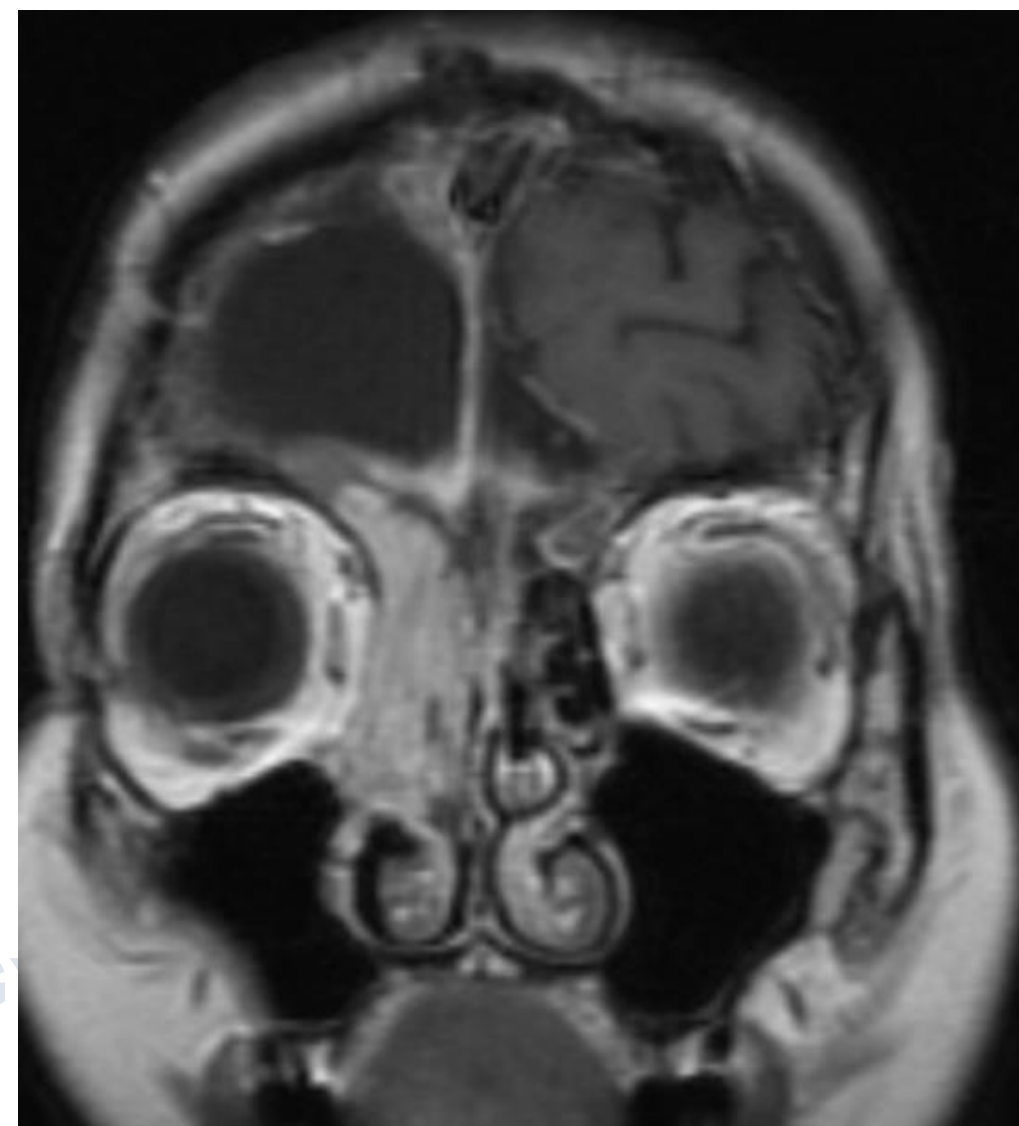
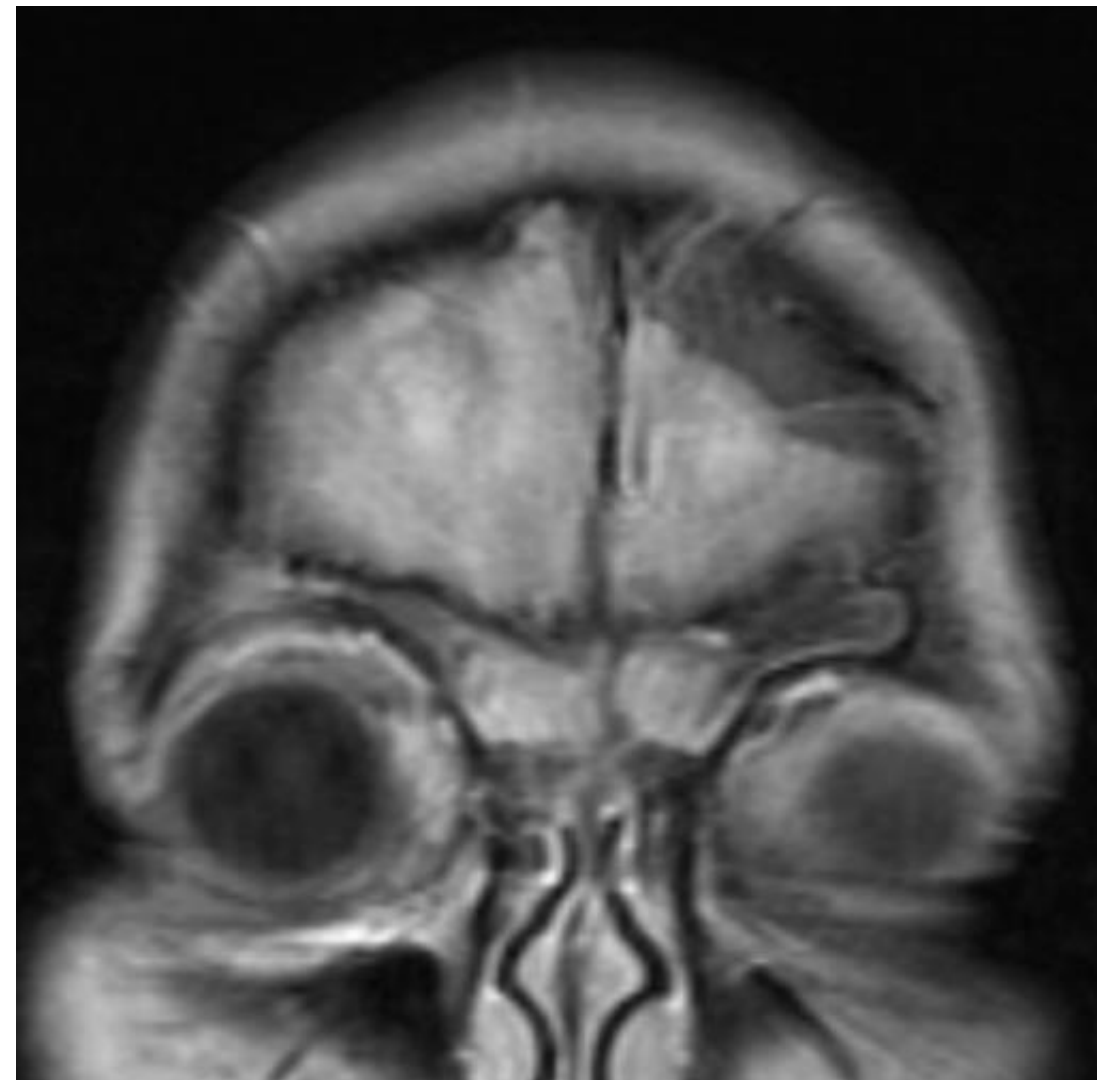
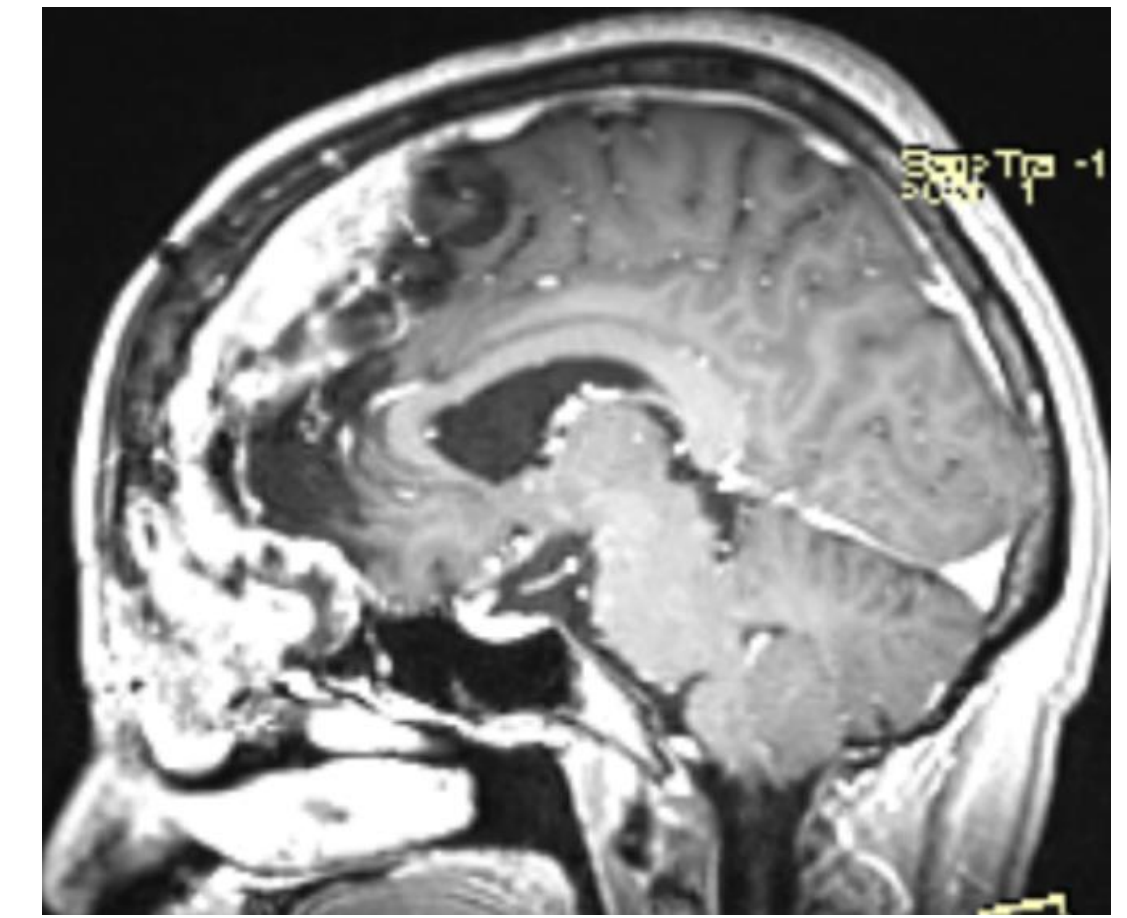
2014



2019

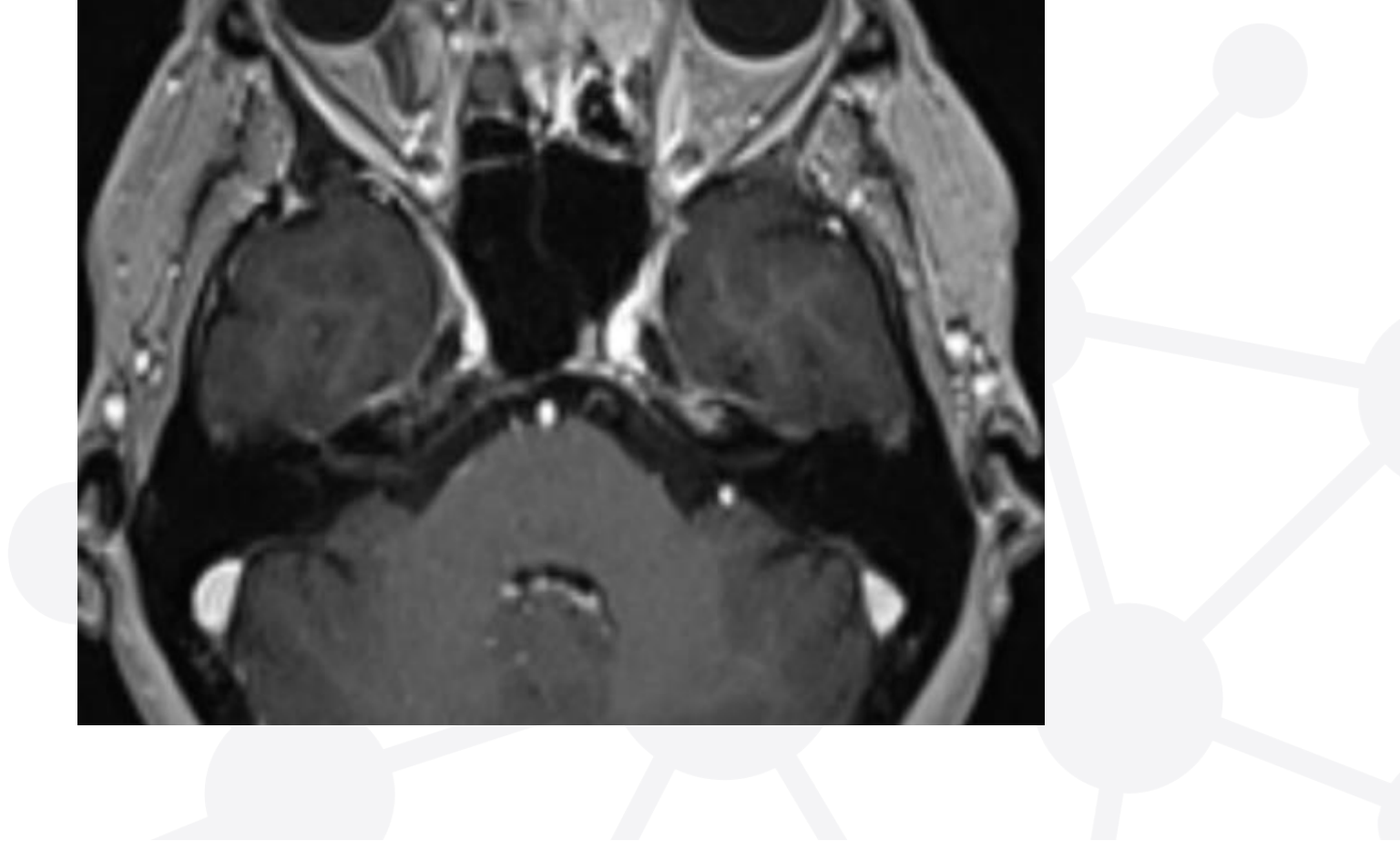


2023

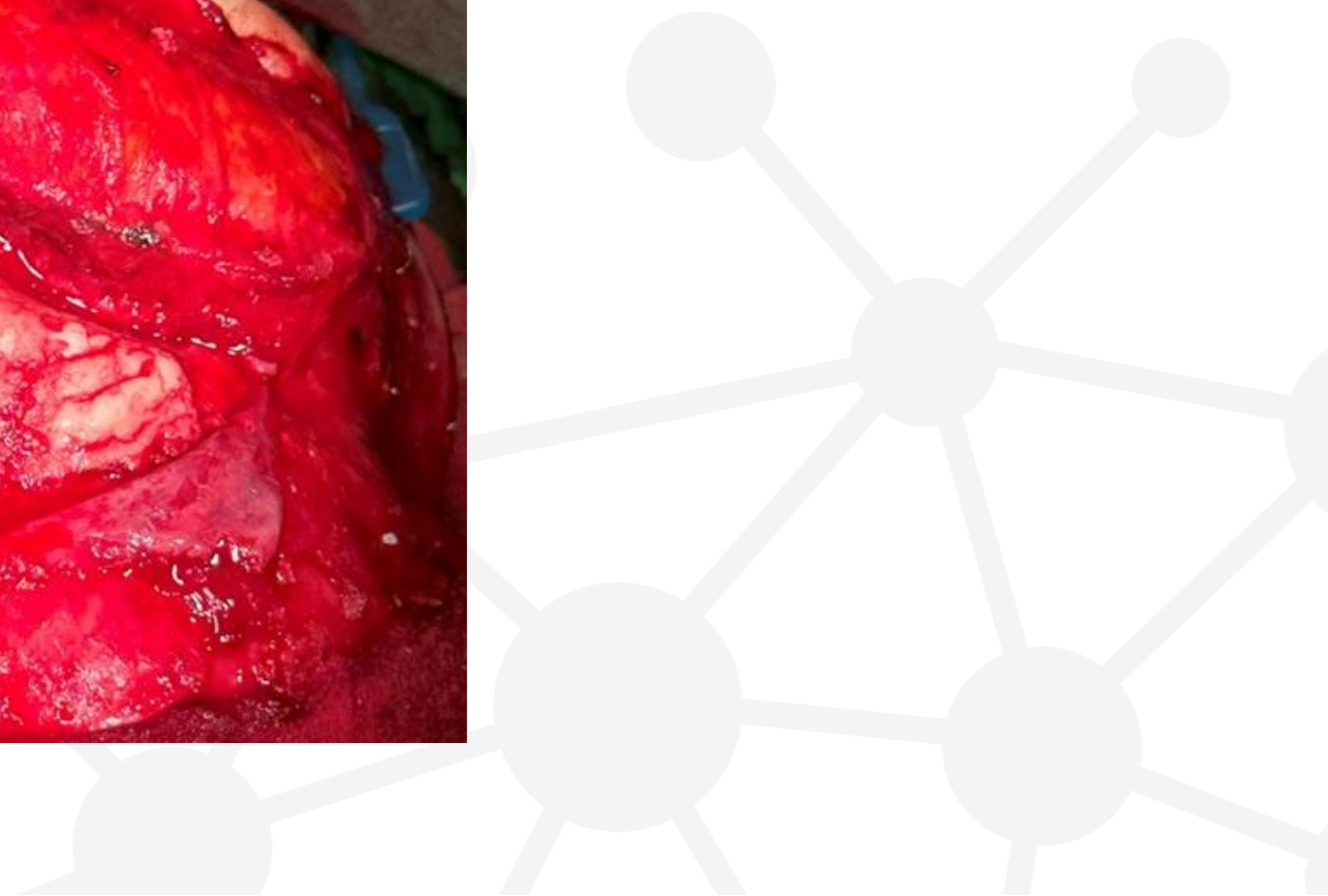
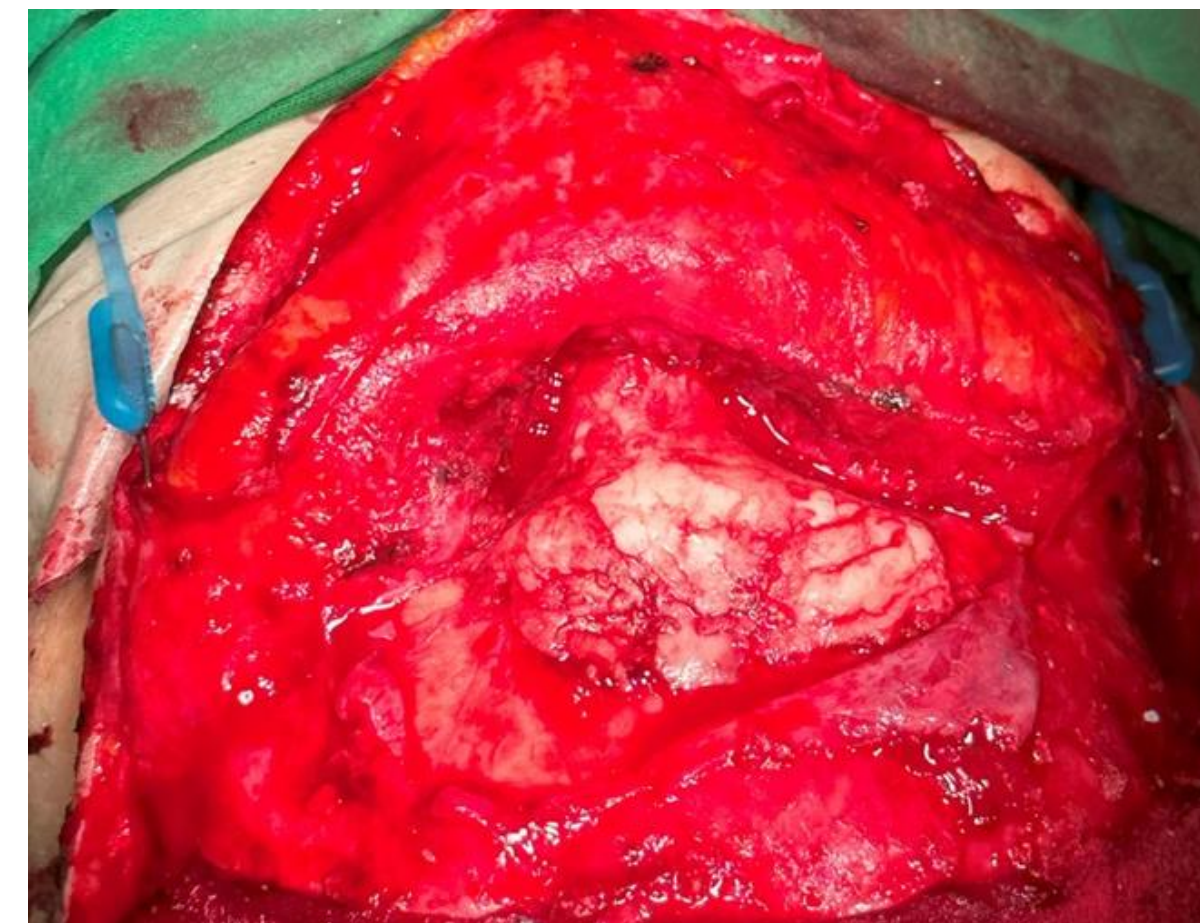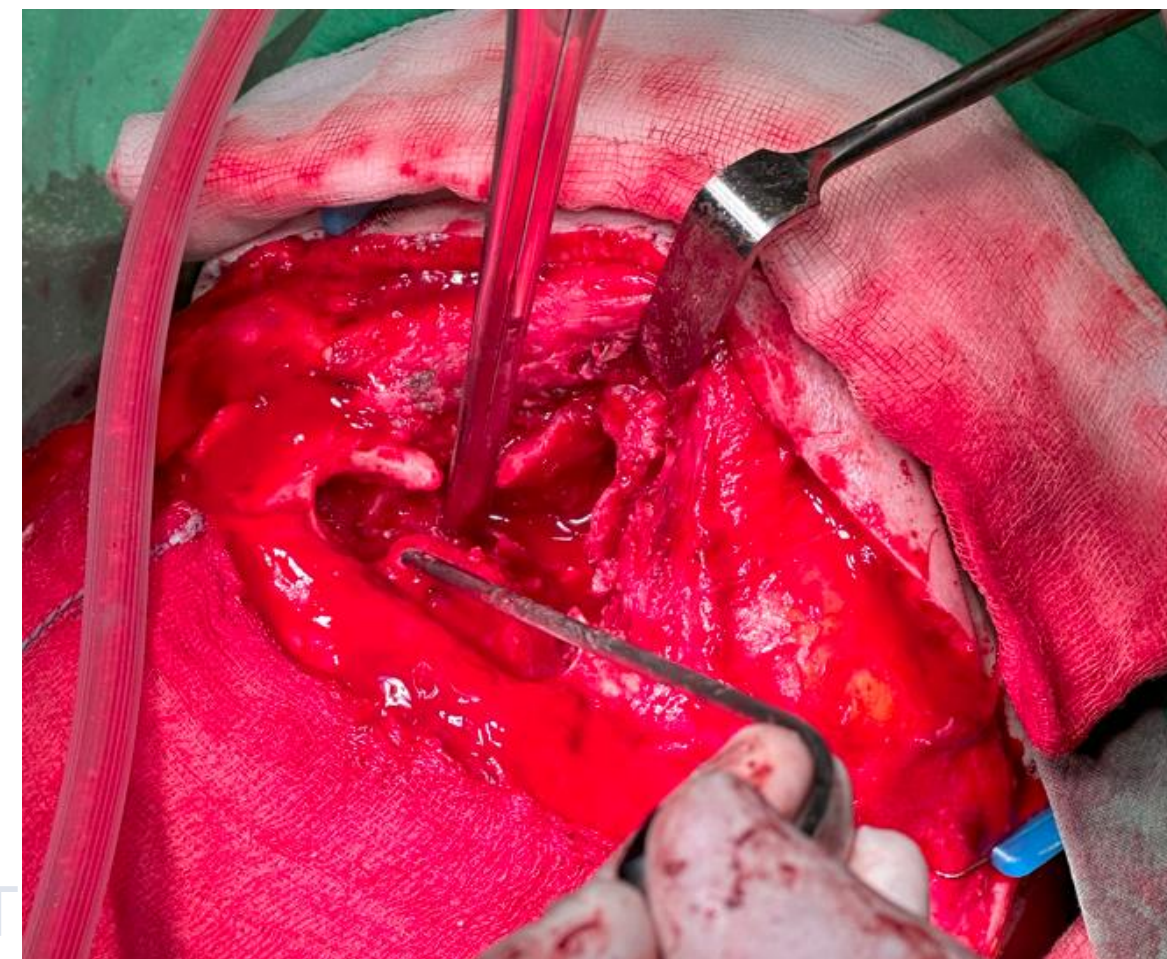
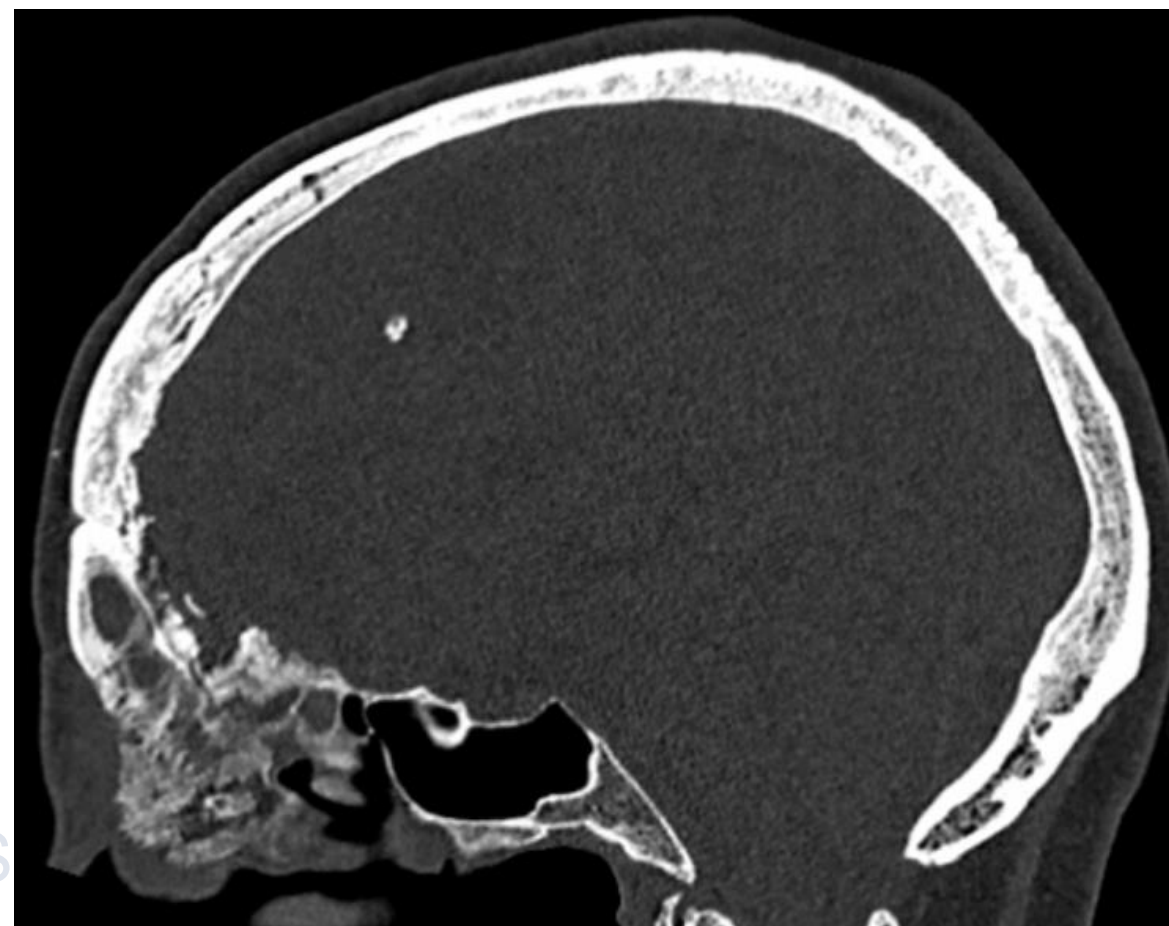
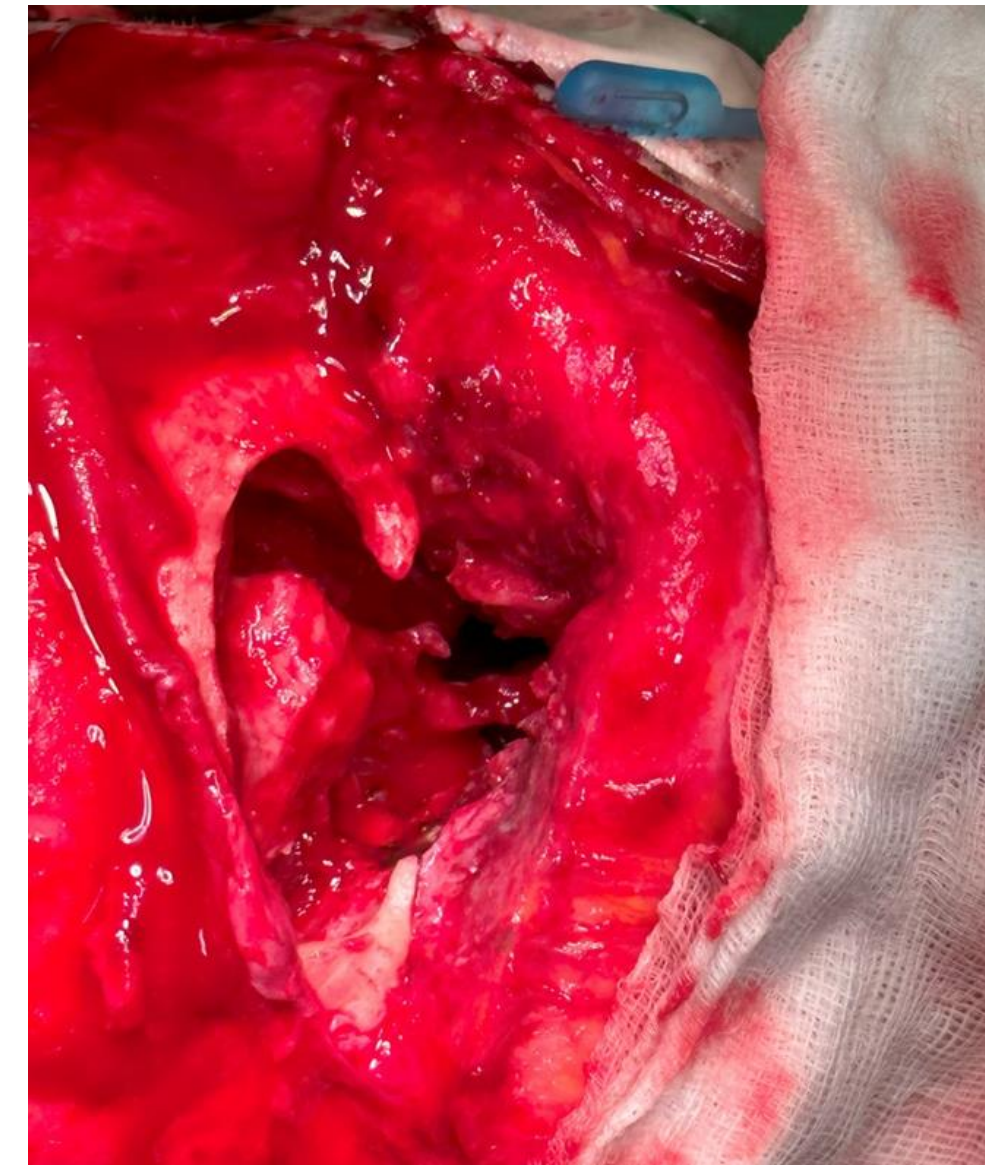
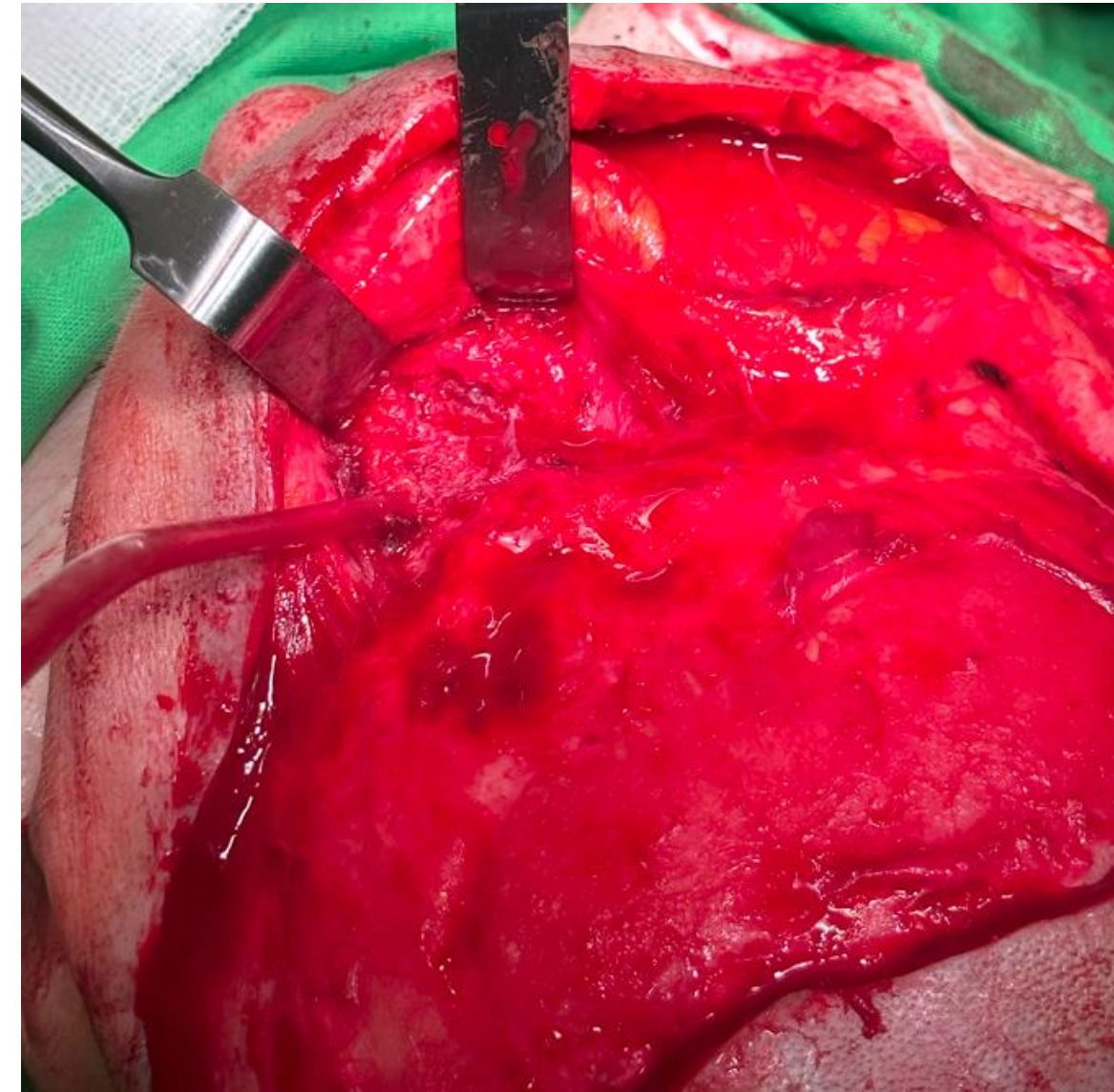

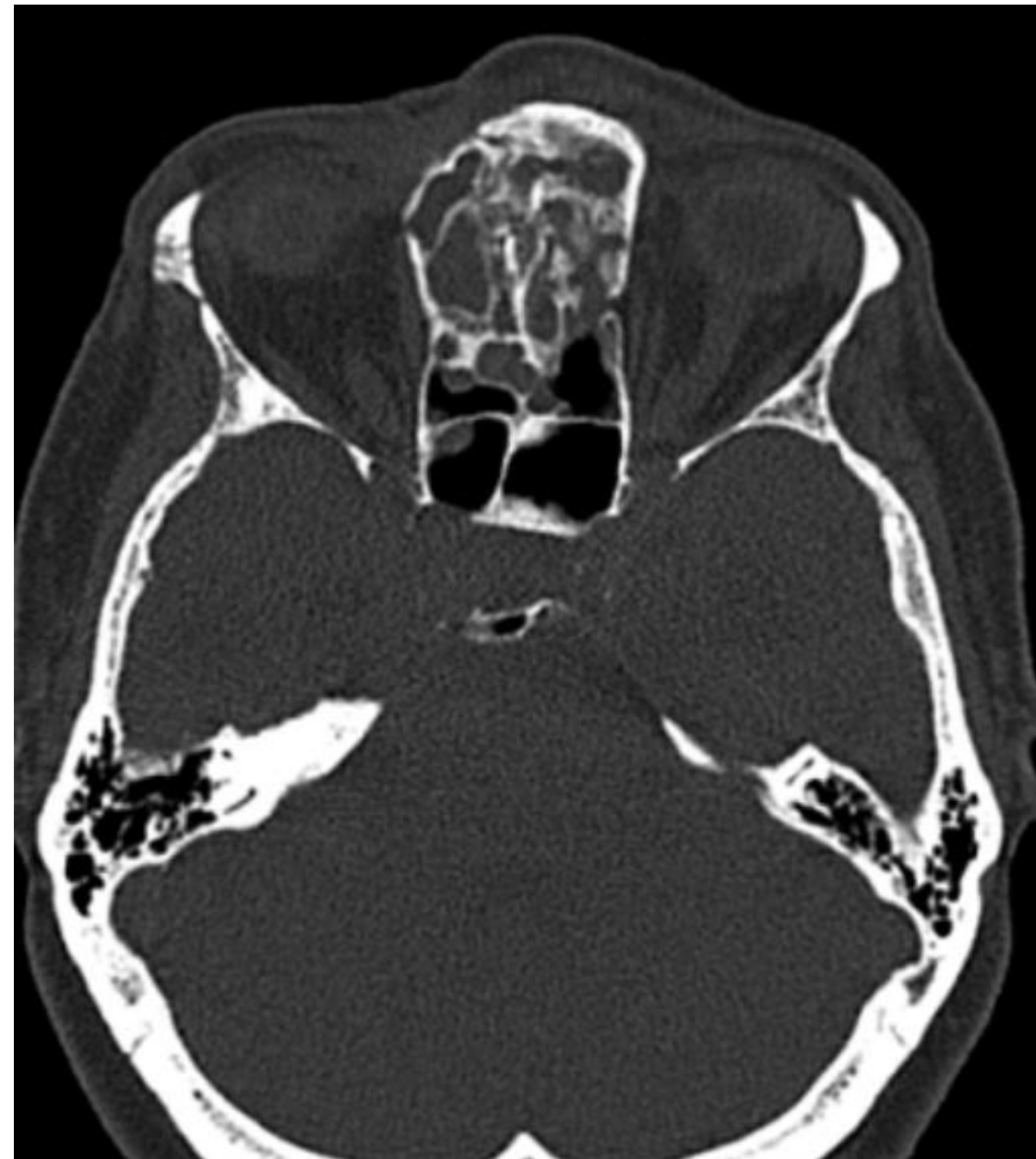
ÓG

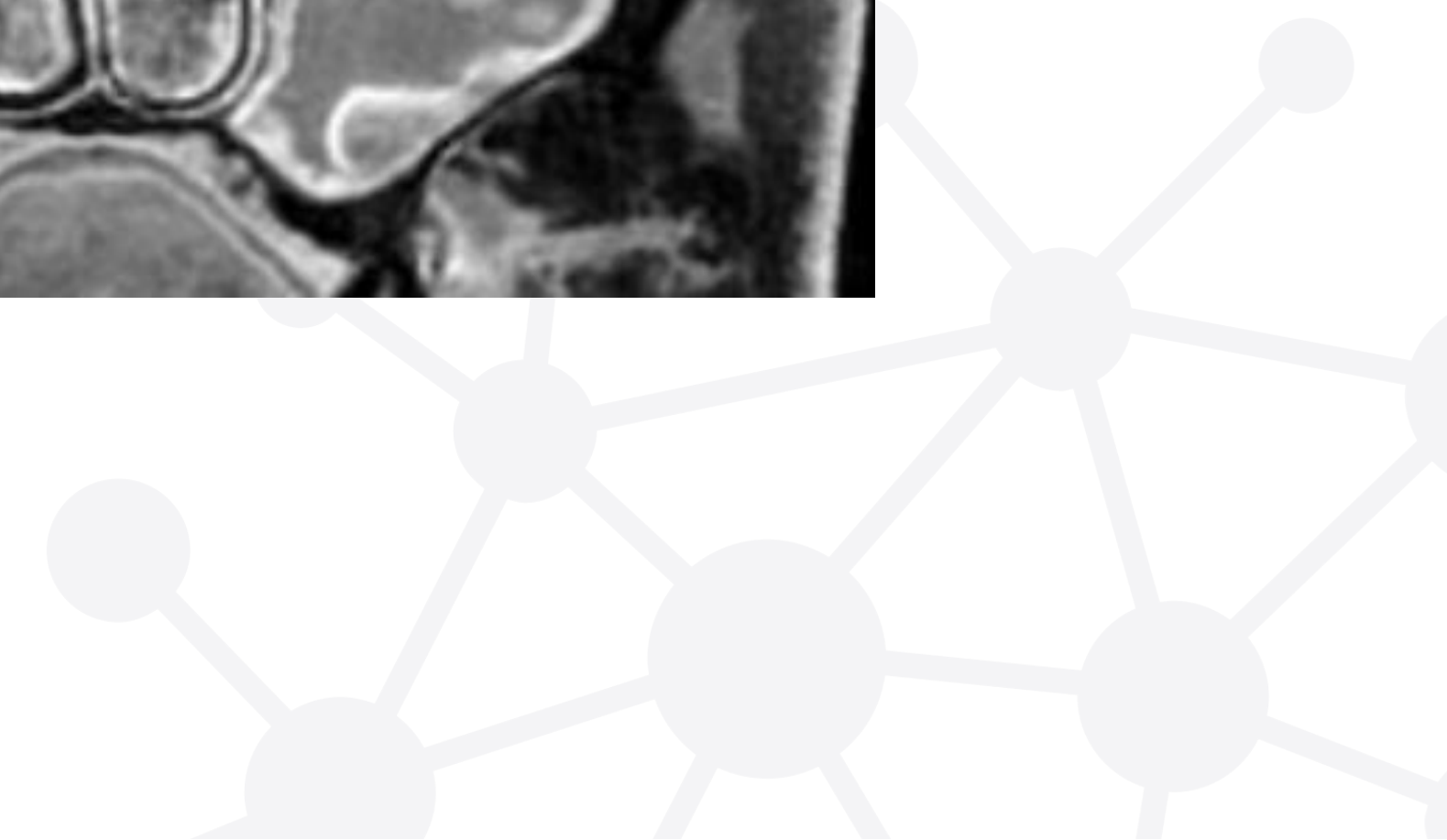
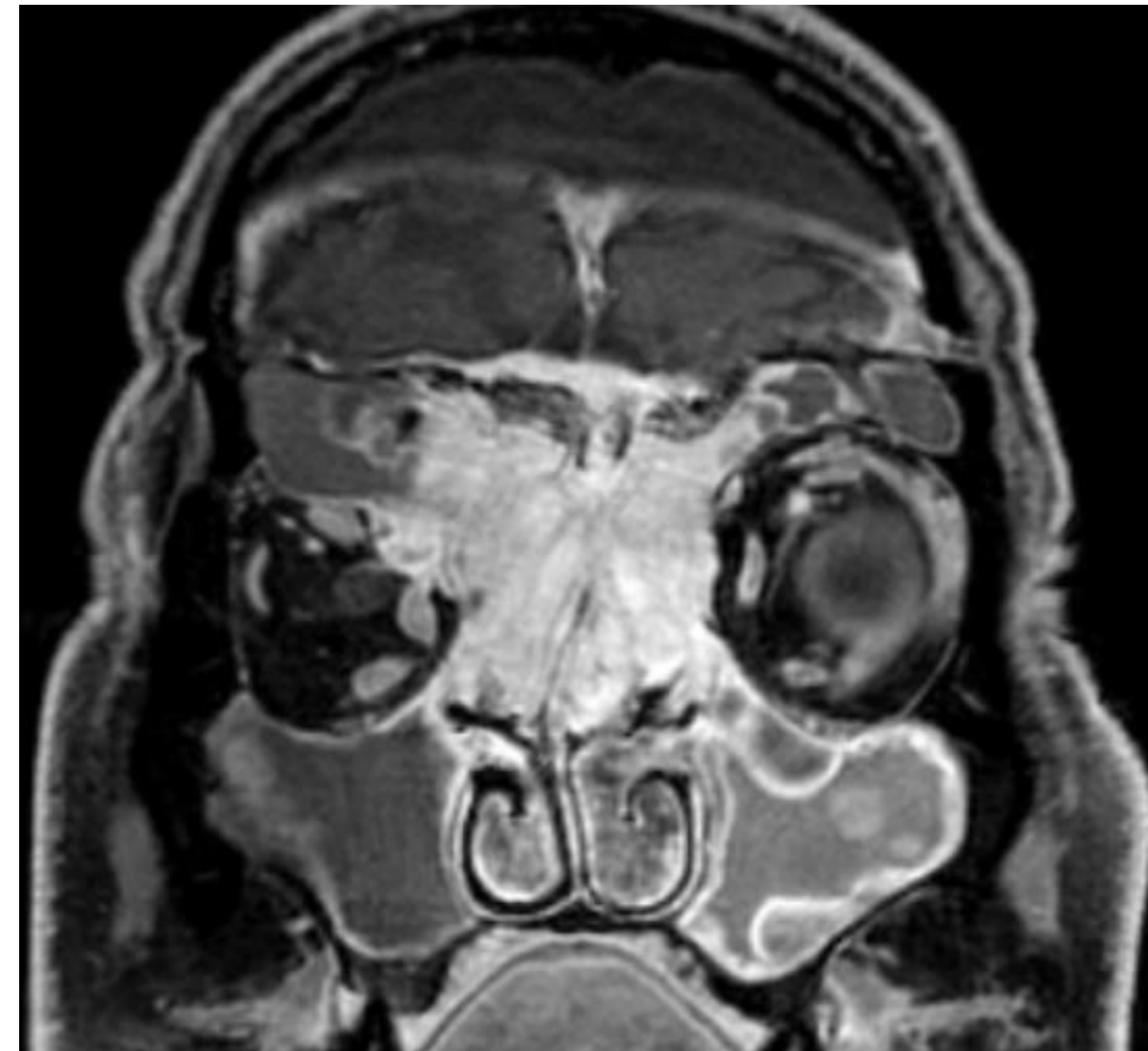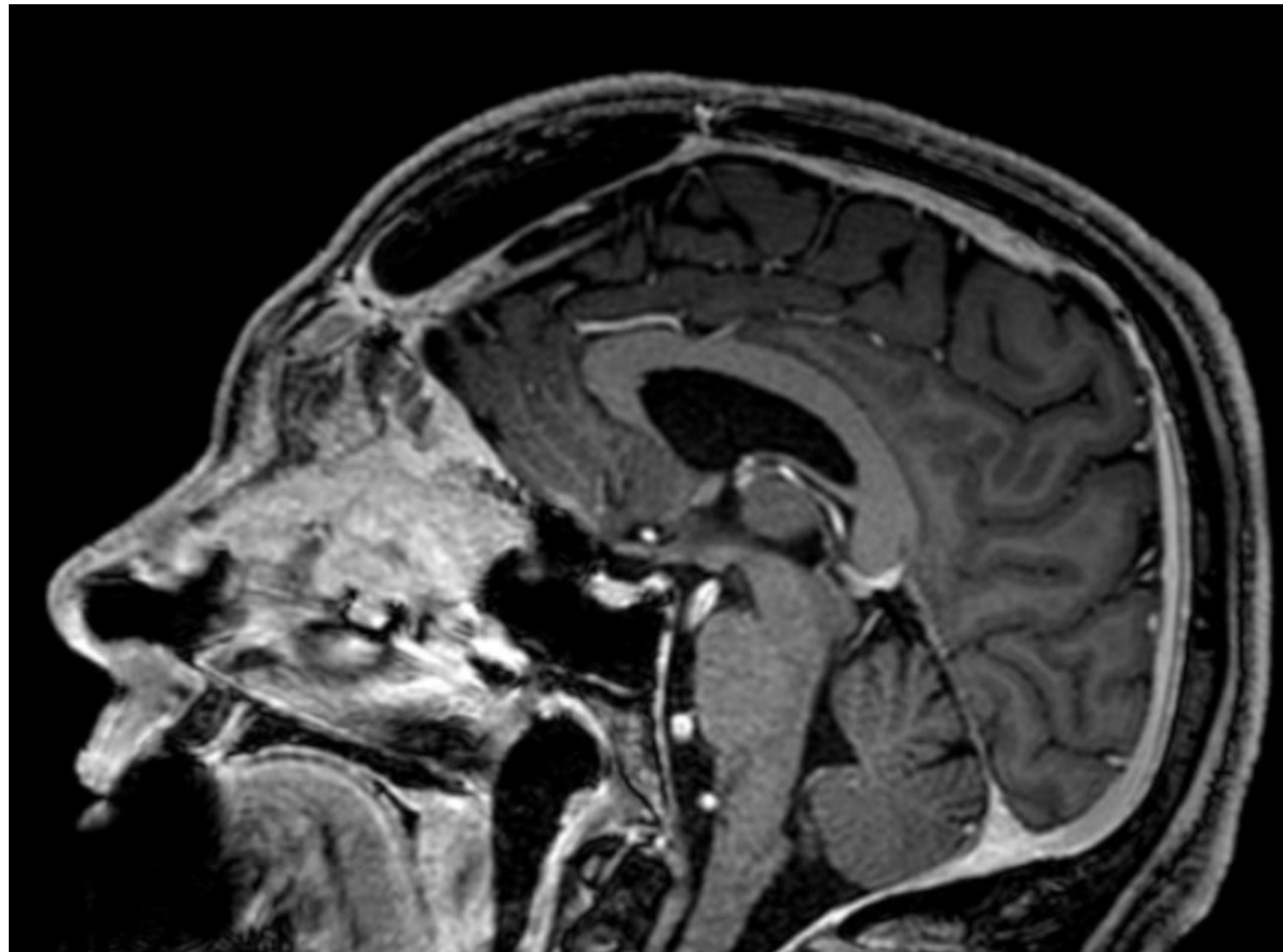
NTÉ



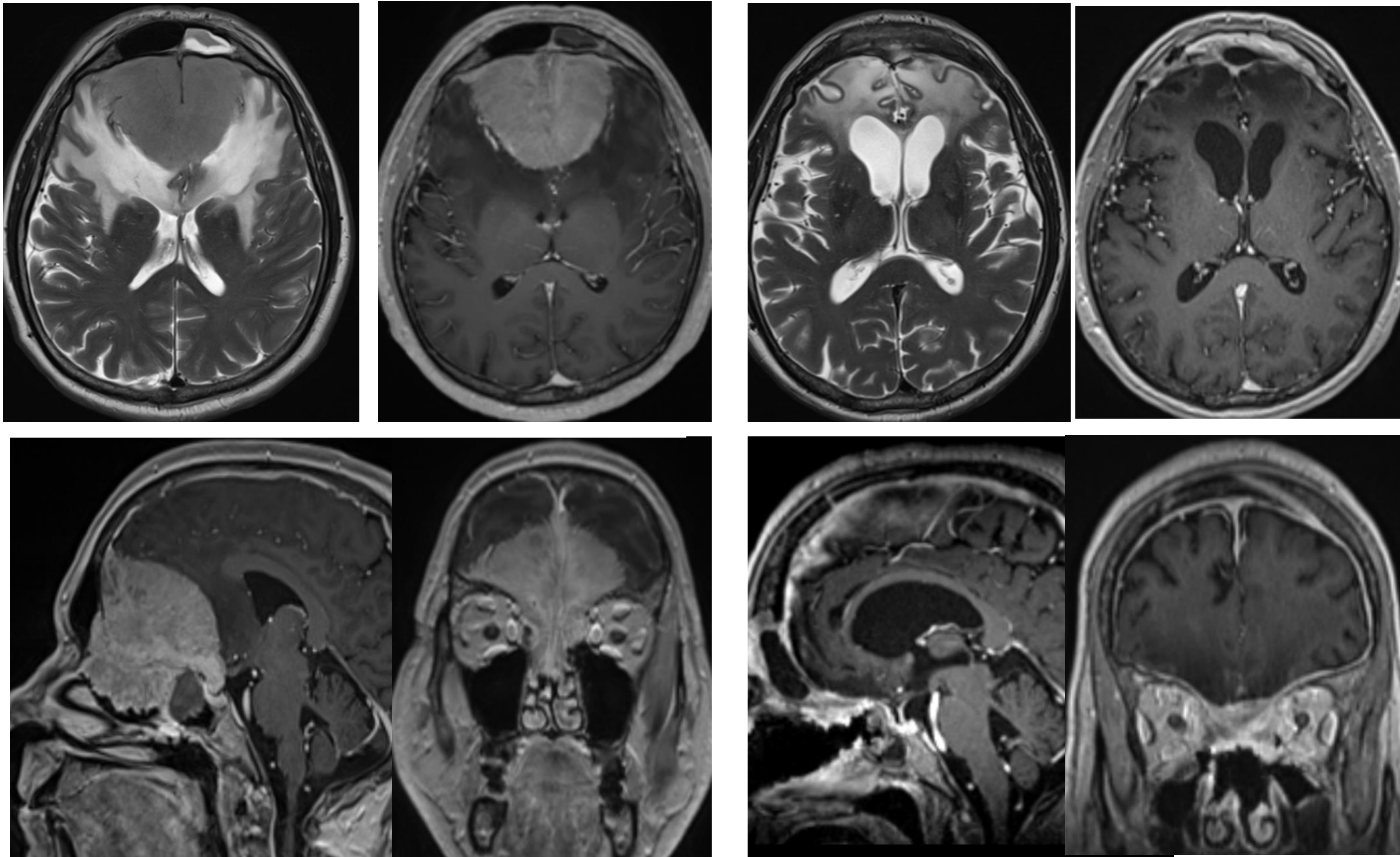
Frontobasalis meningeoma: extraduralis rész+csont!



Intranasalis-intracranialis: 2. lépés - Endoscopos transnasalis

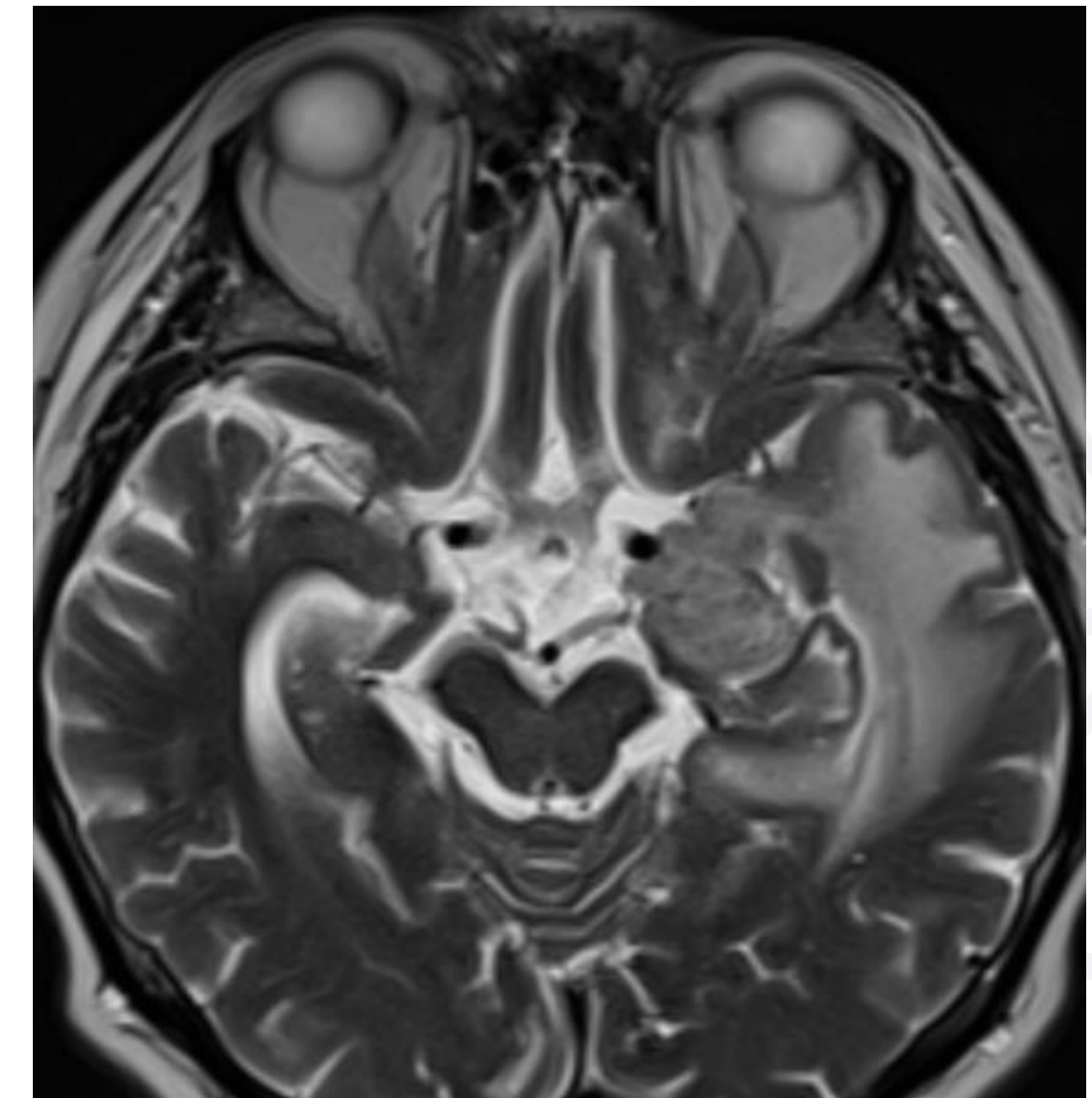
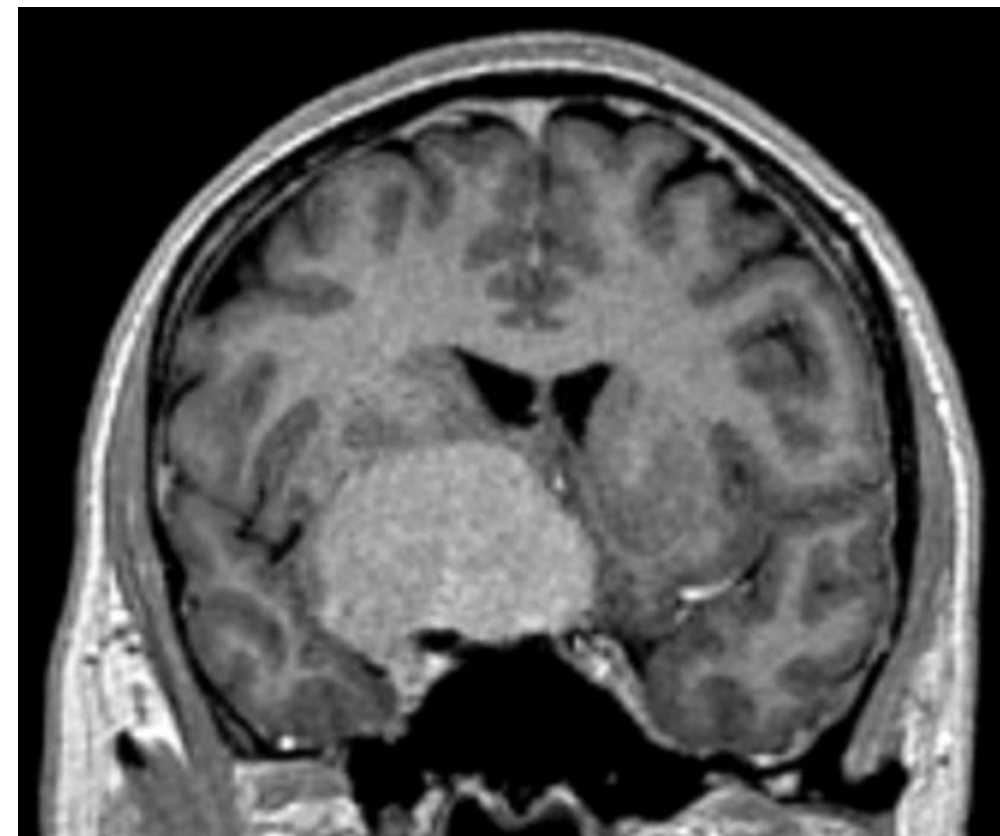
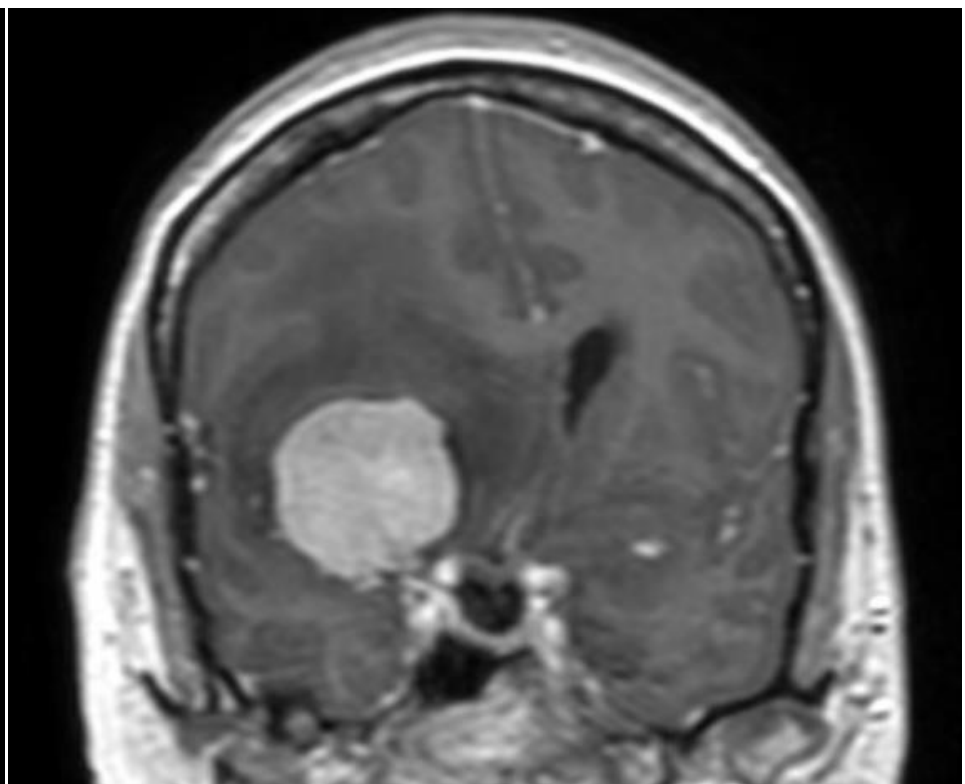
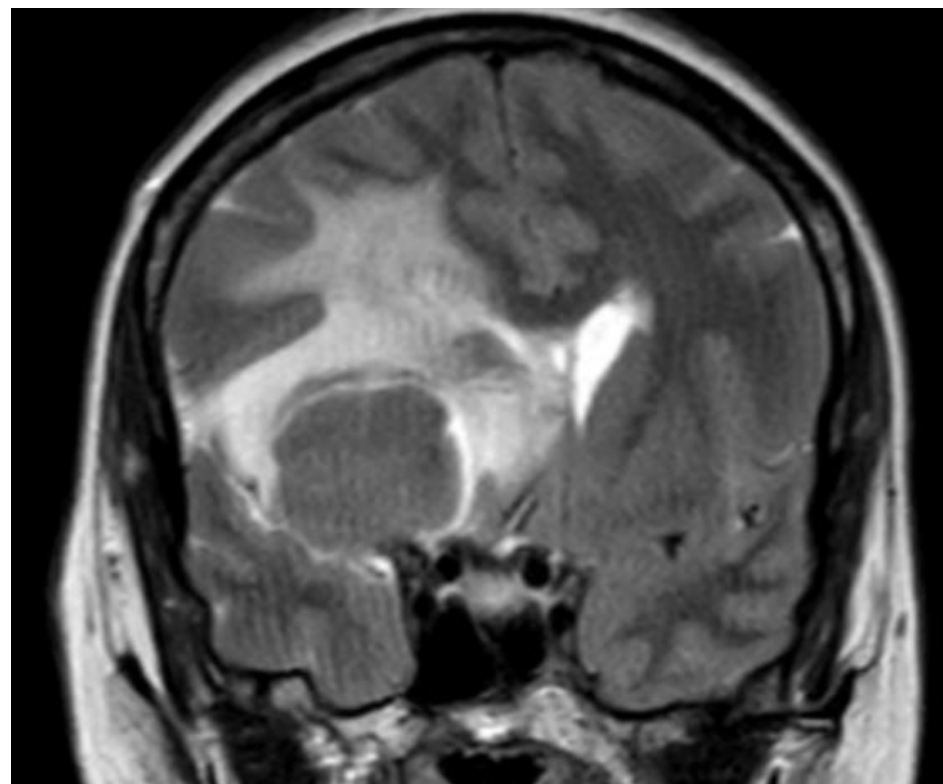
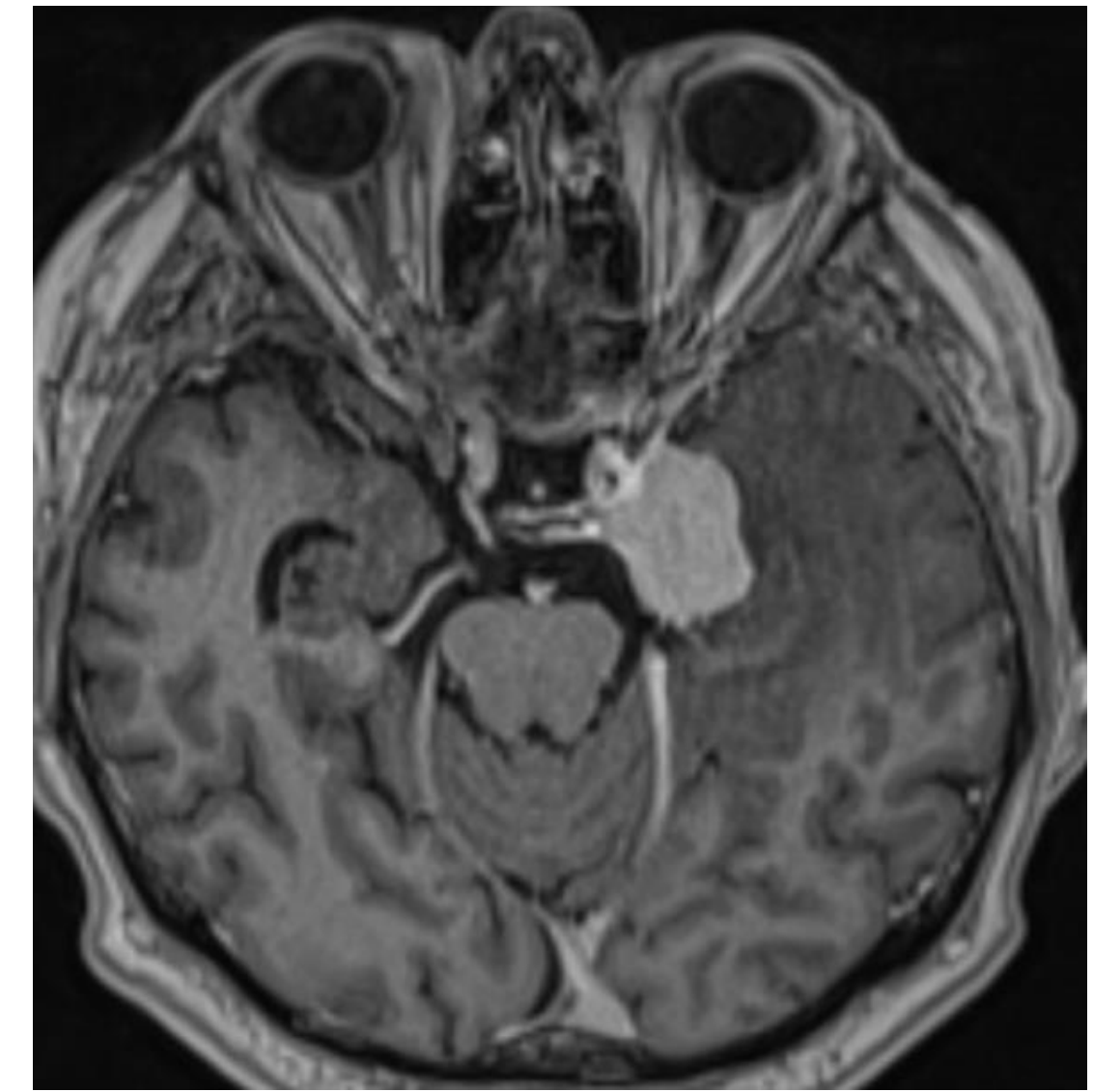
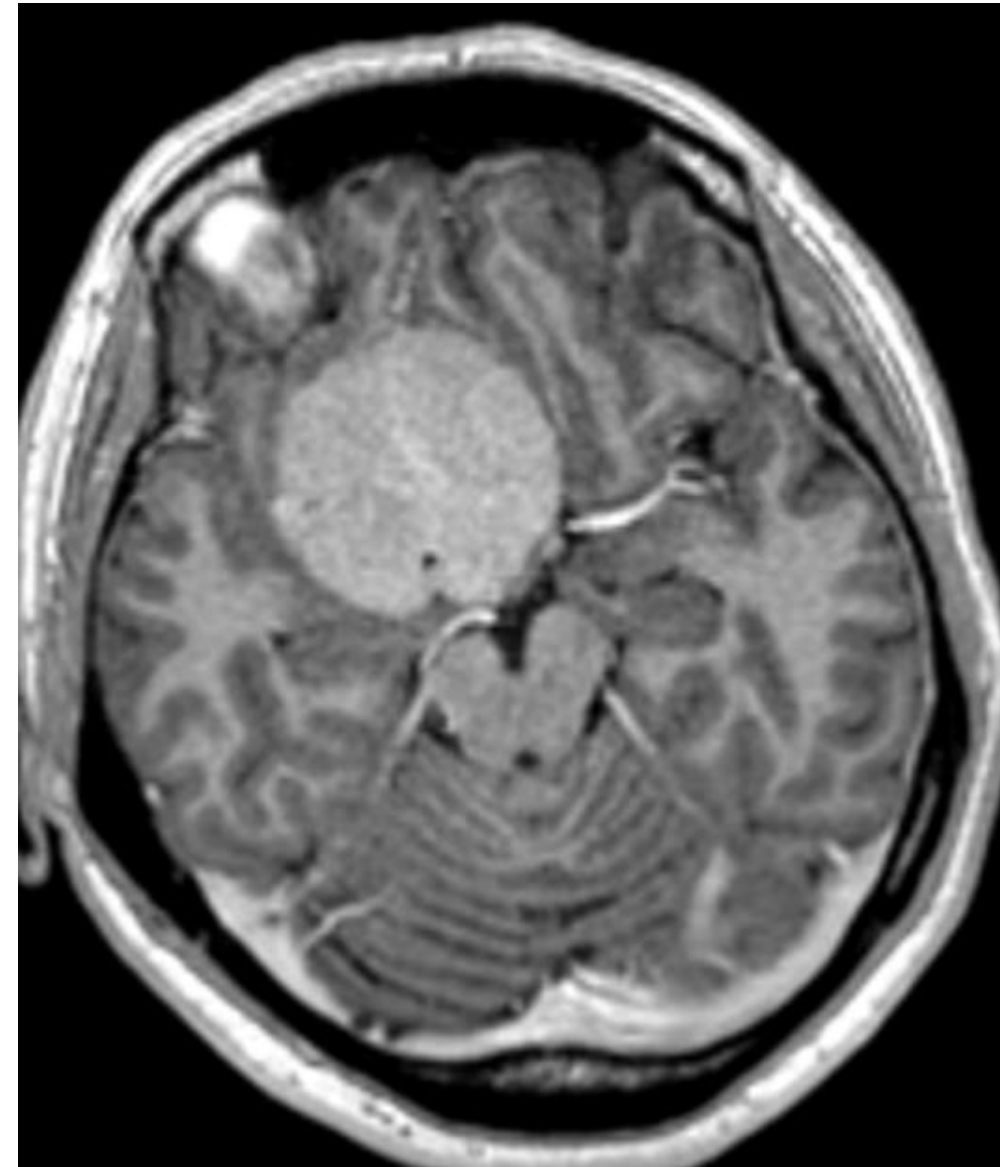
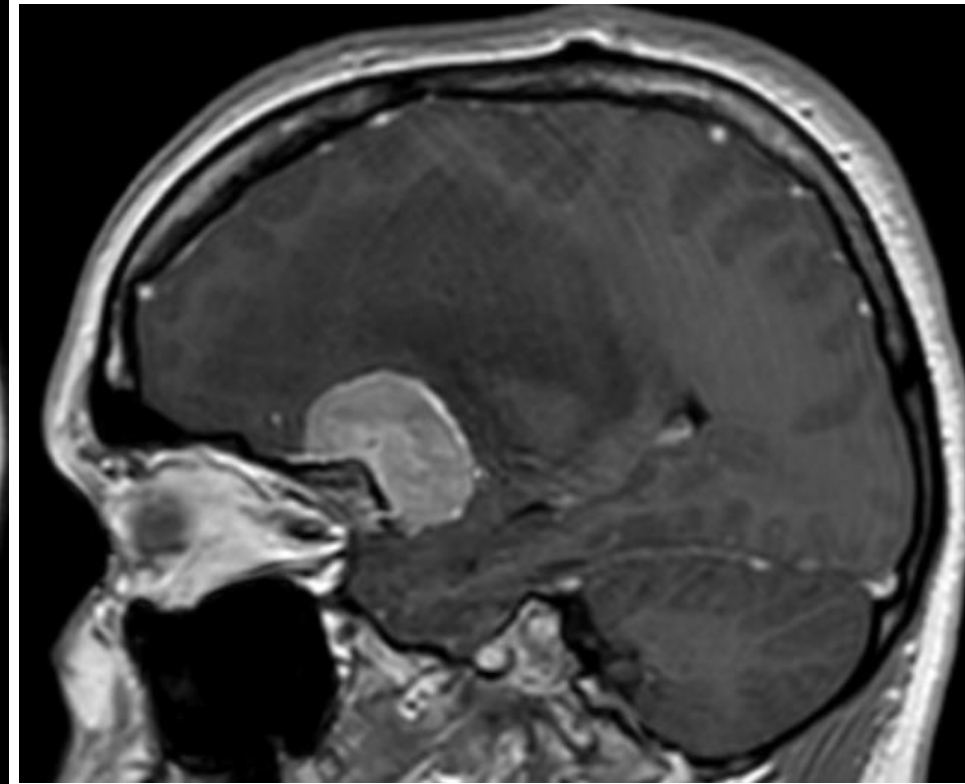
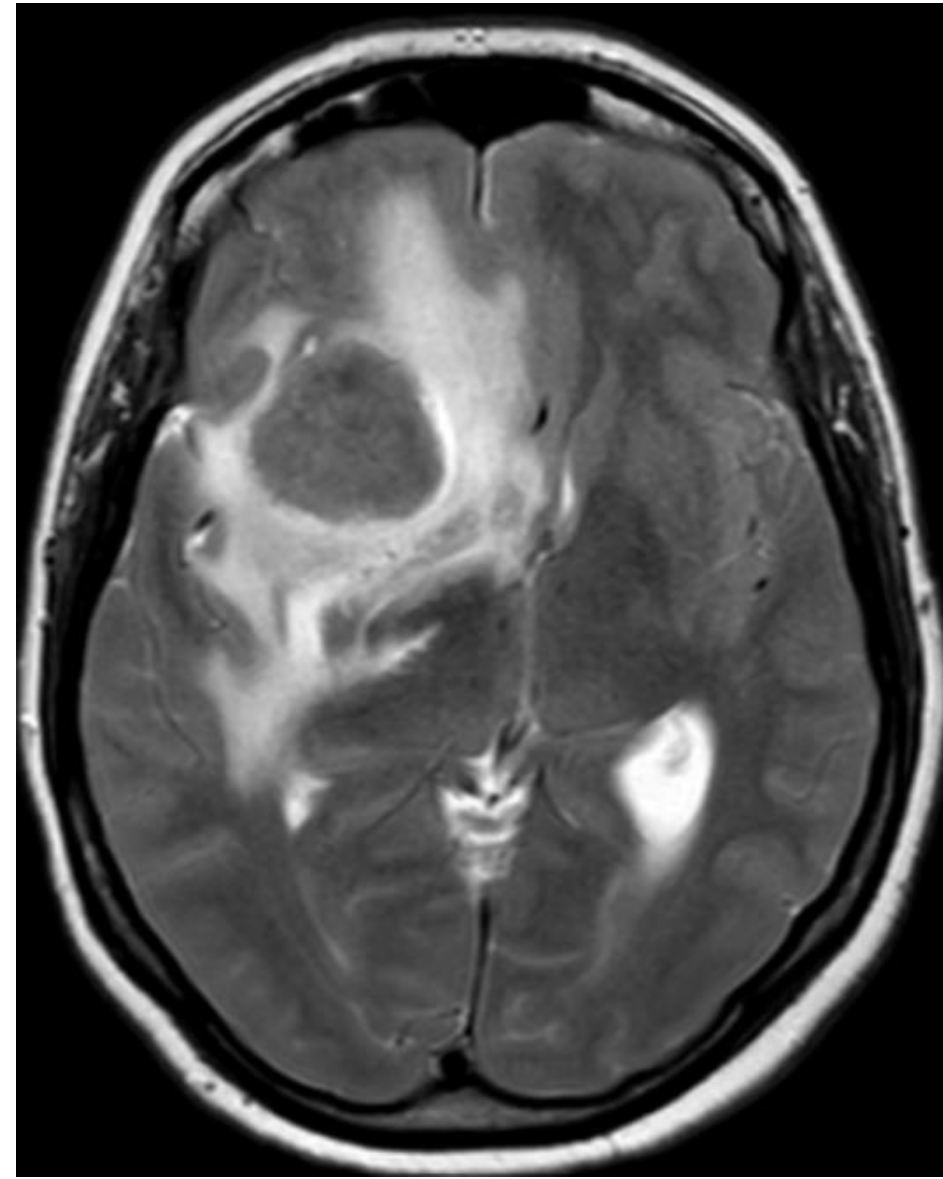


Intranasalis-intracranialis: 2 lépés

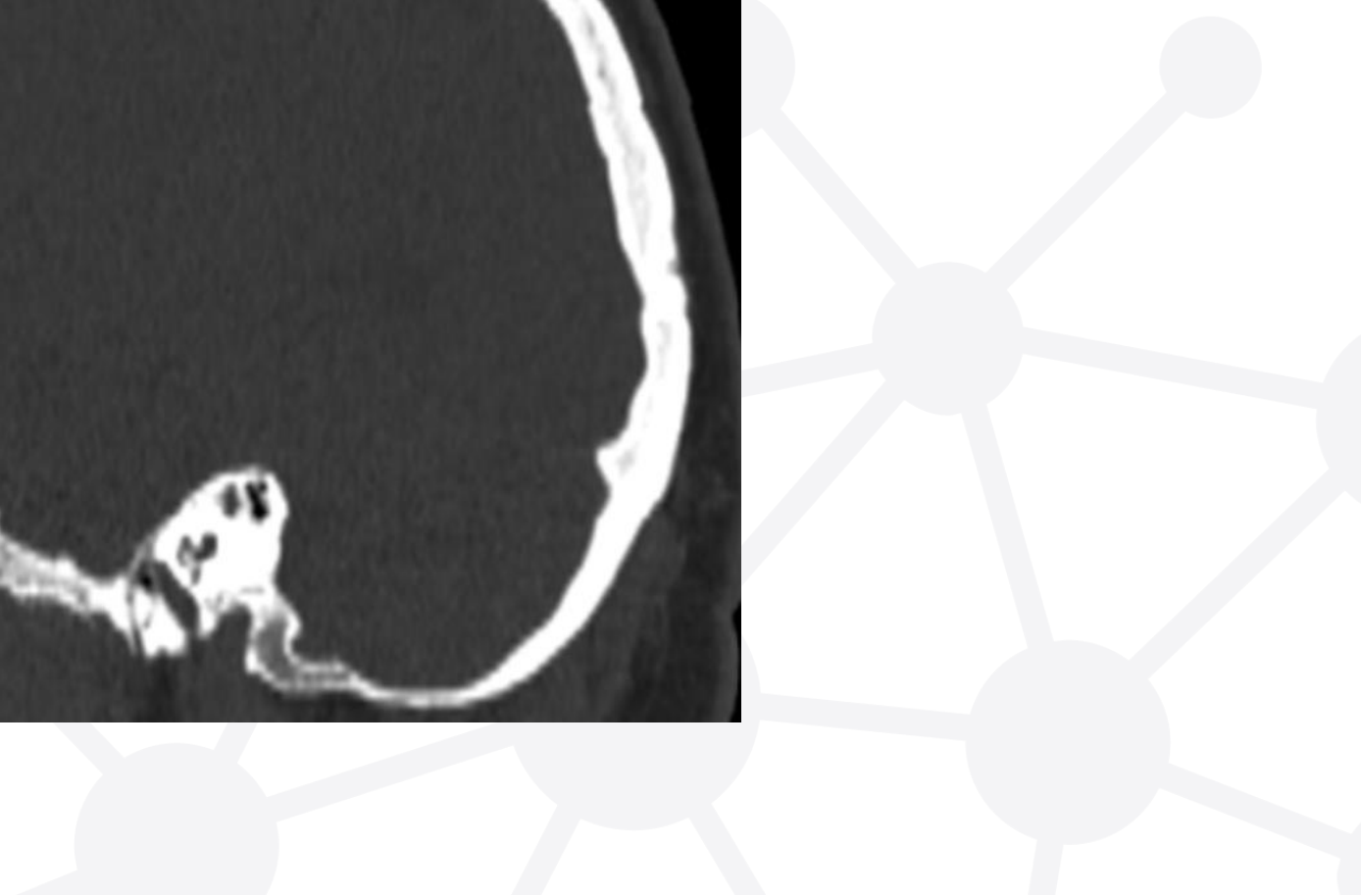
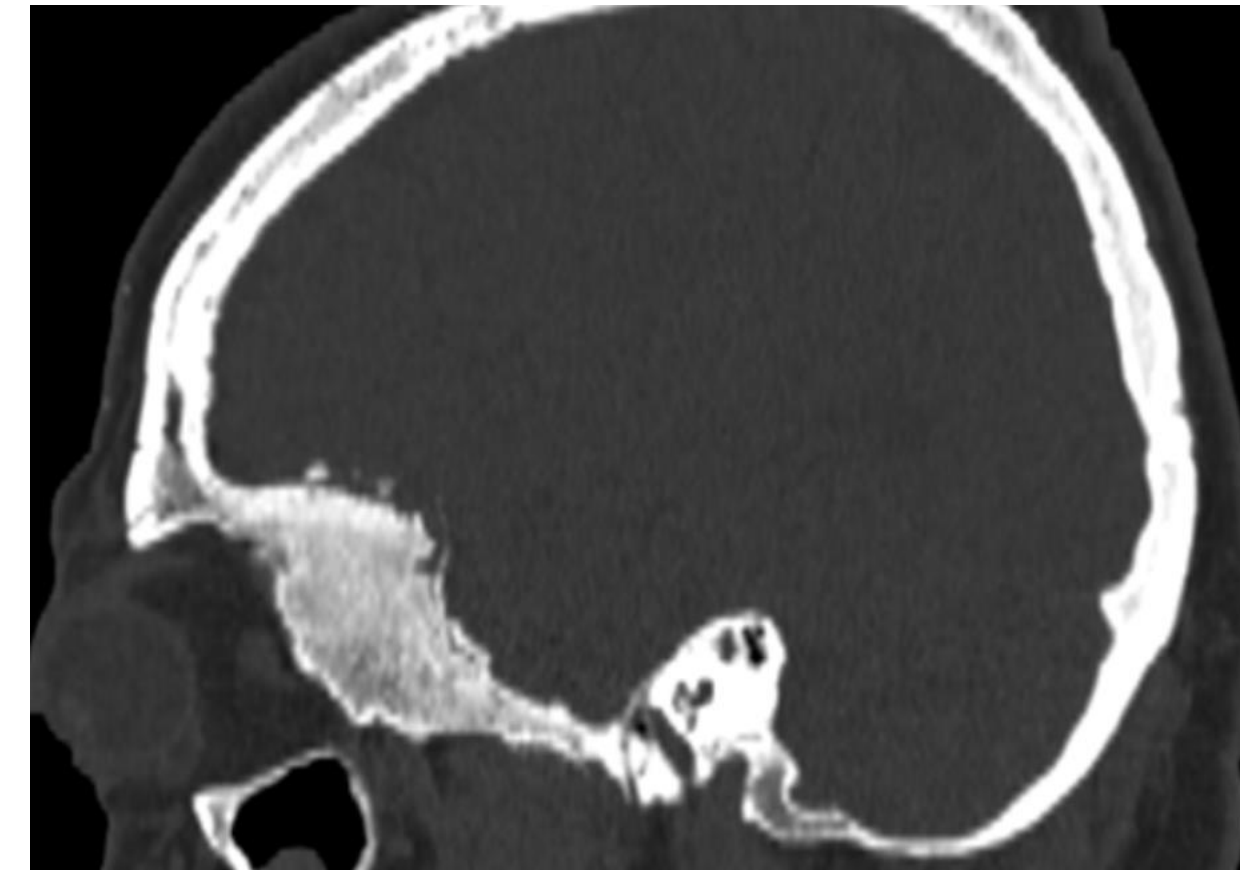
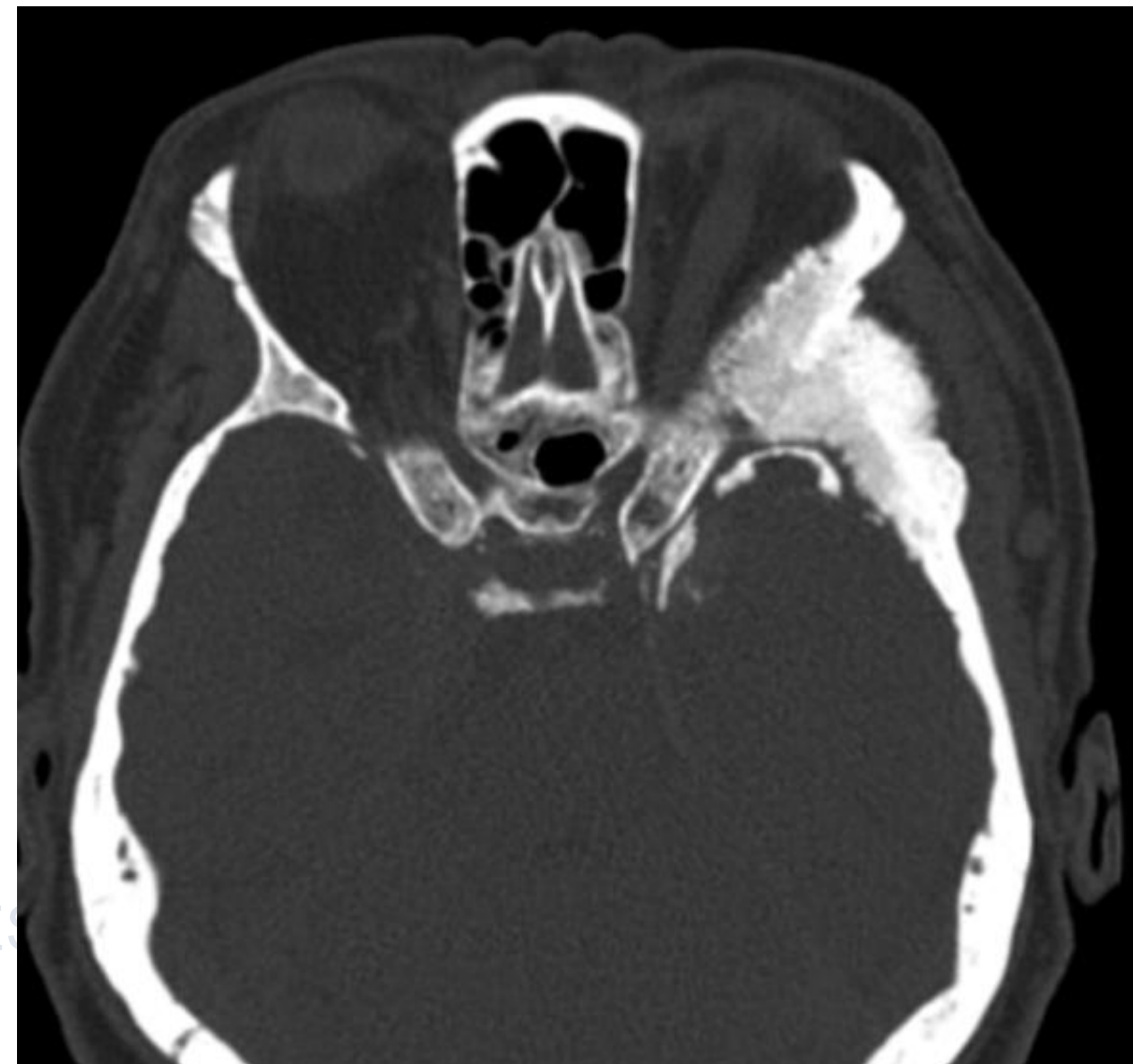
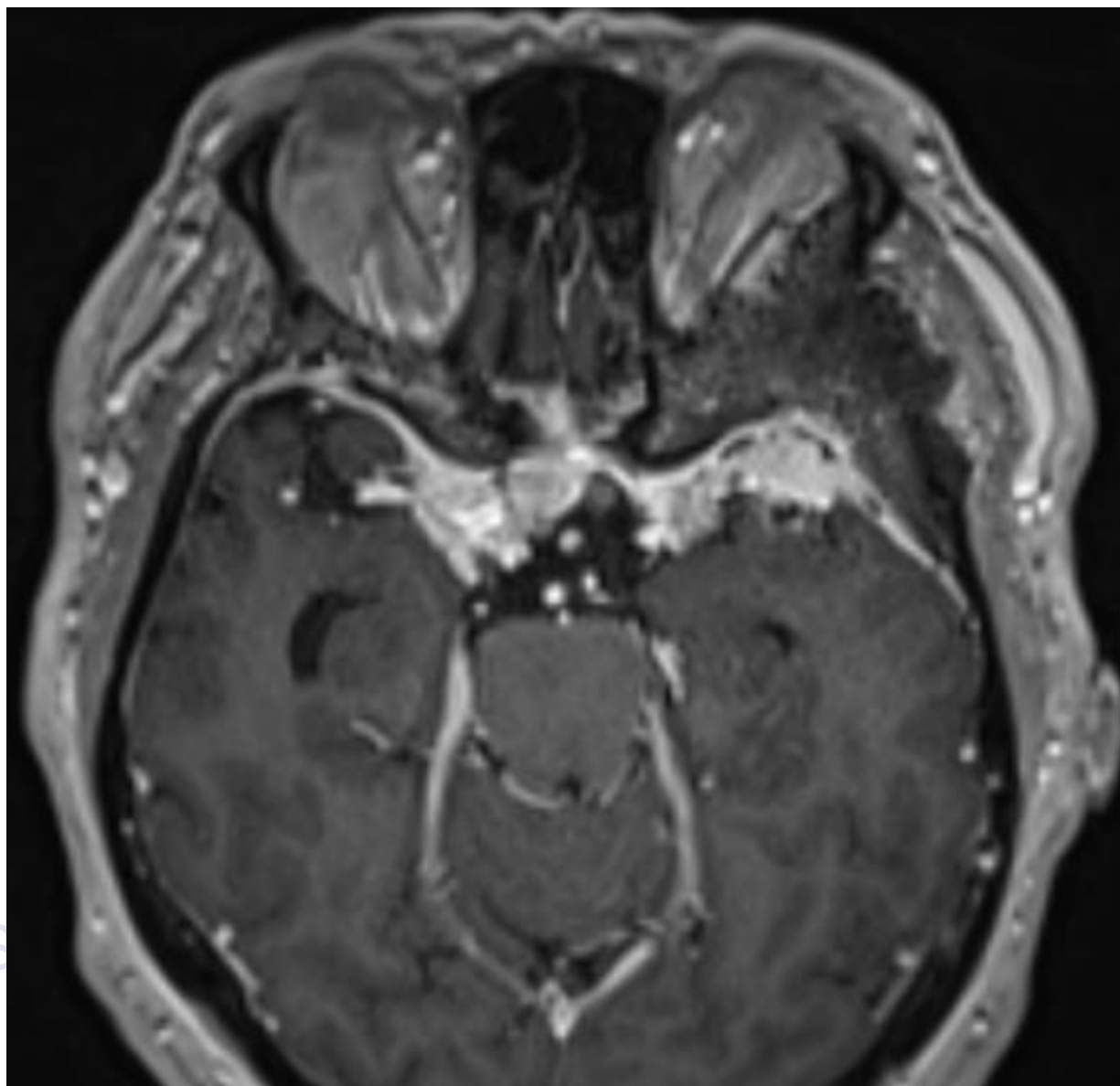
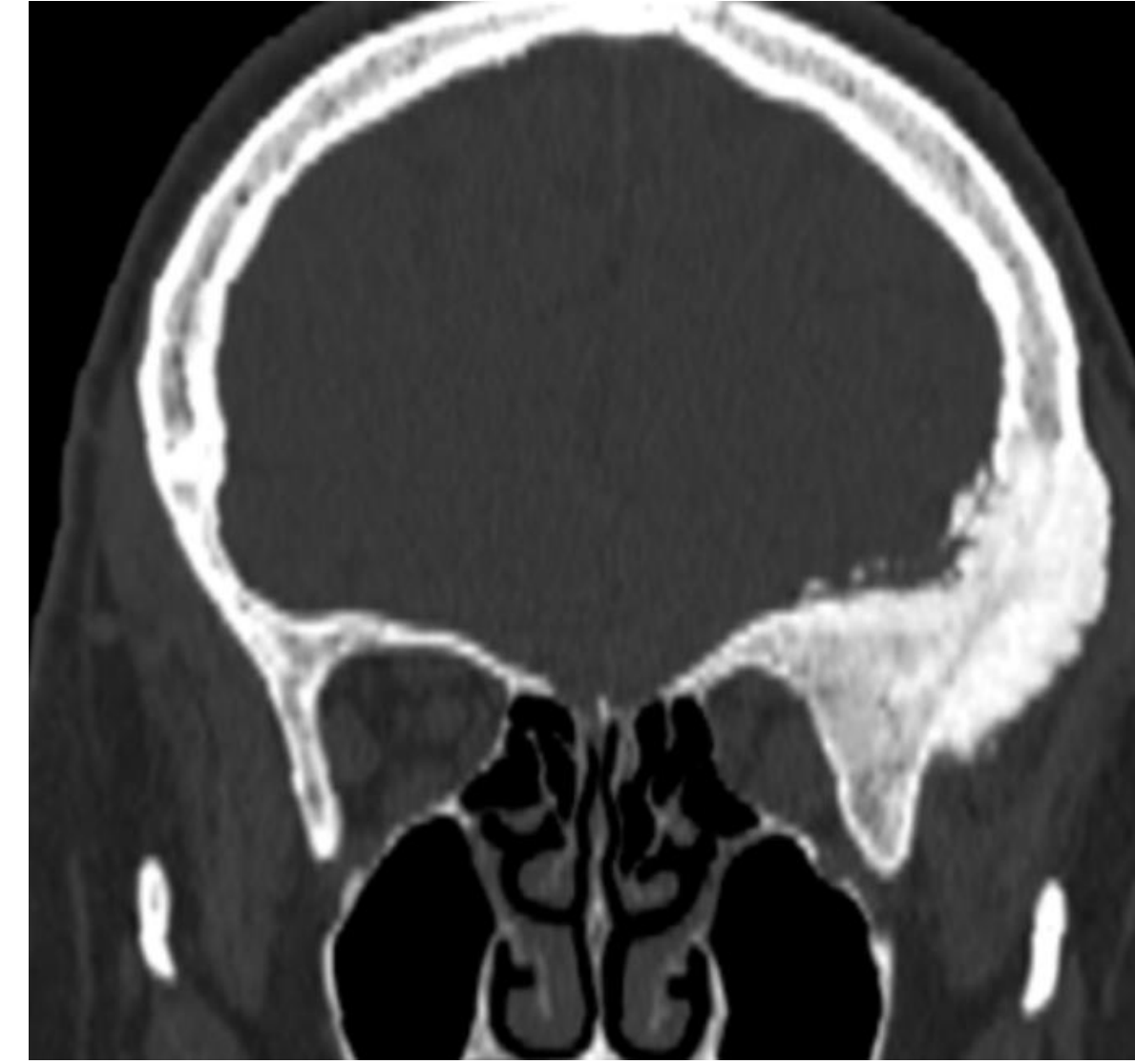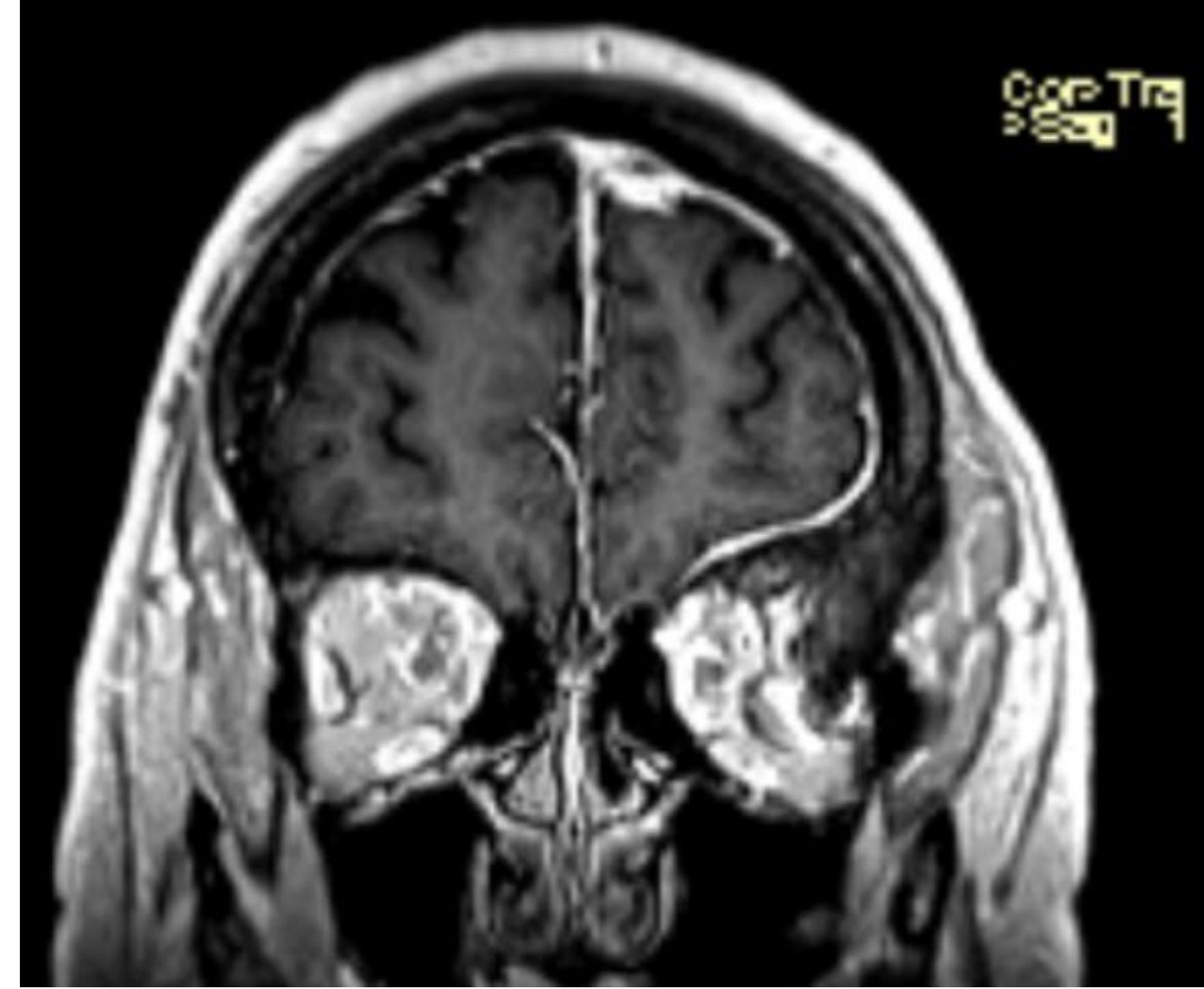
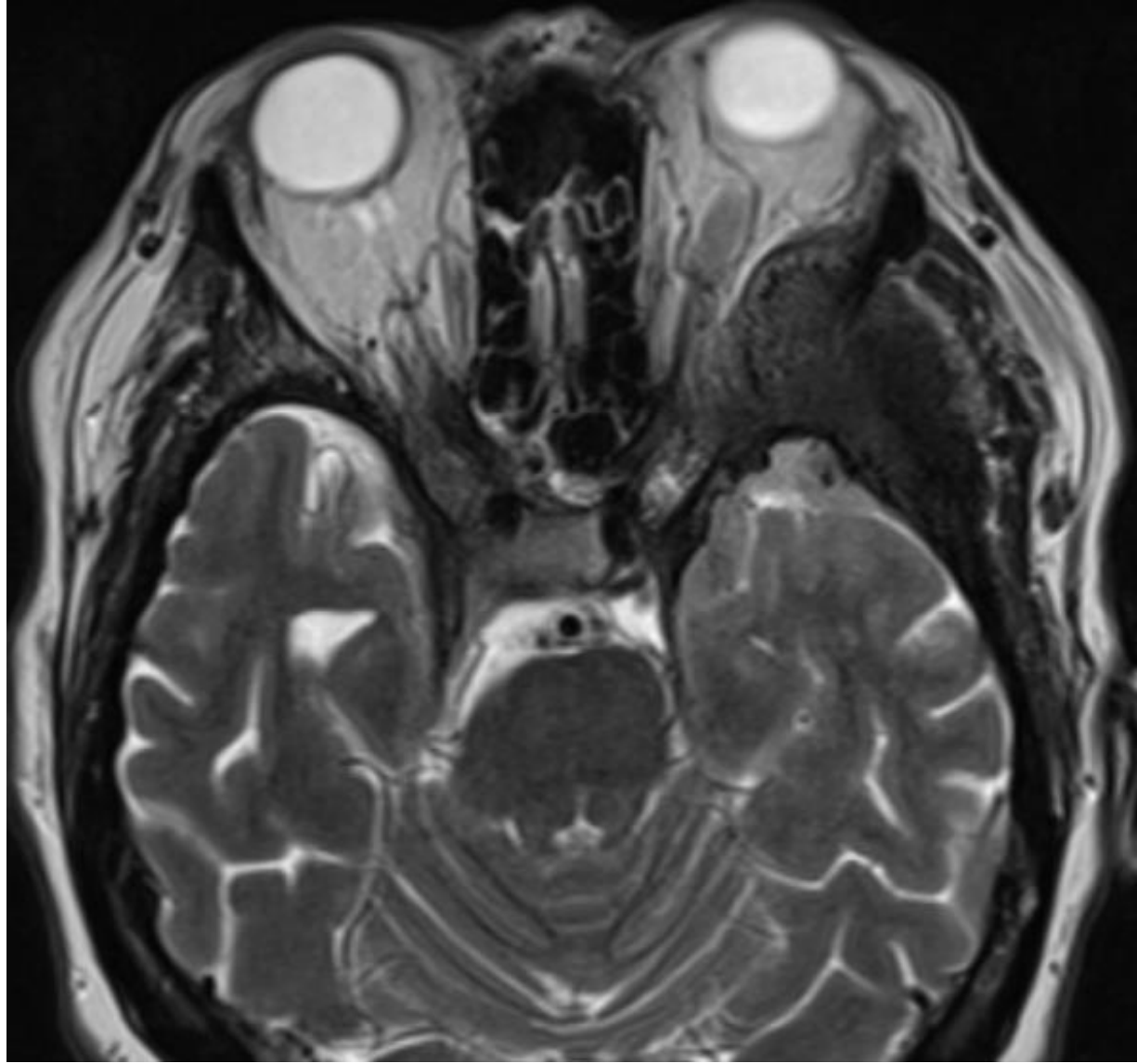


- 53 é ffi
- Évek óta anosmia, személyiségváltozás
- Progressív fejfájás
- Vakulás
- Radikális resectio
 1. Lépés: Transcranialis (bifrontalis craniotomia)
 2. Lépés: Endoscopy transnasalis (8 hét)
- Meningeoma WHO grade II

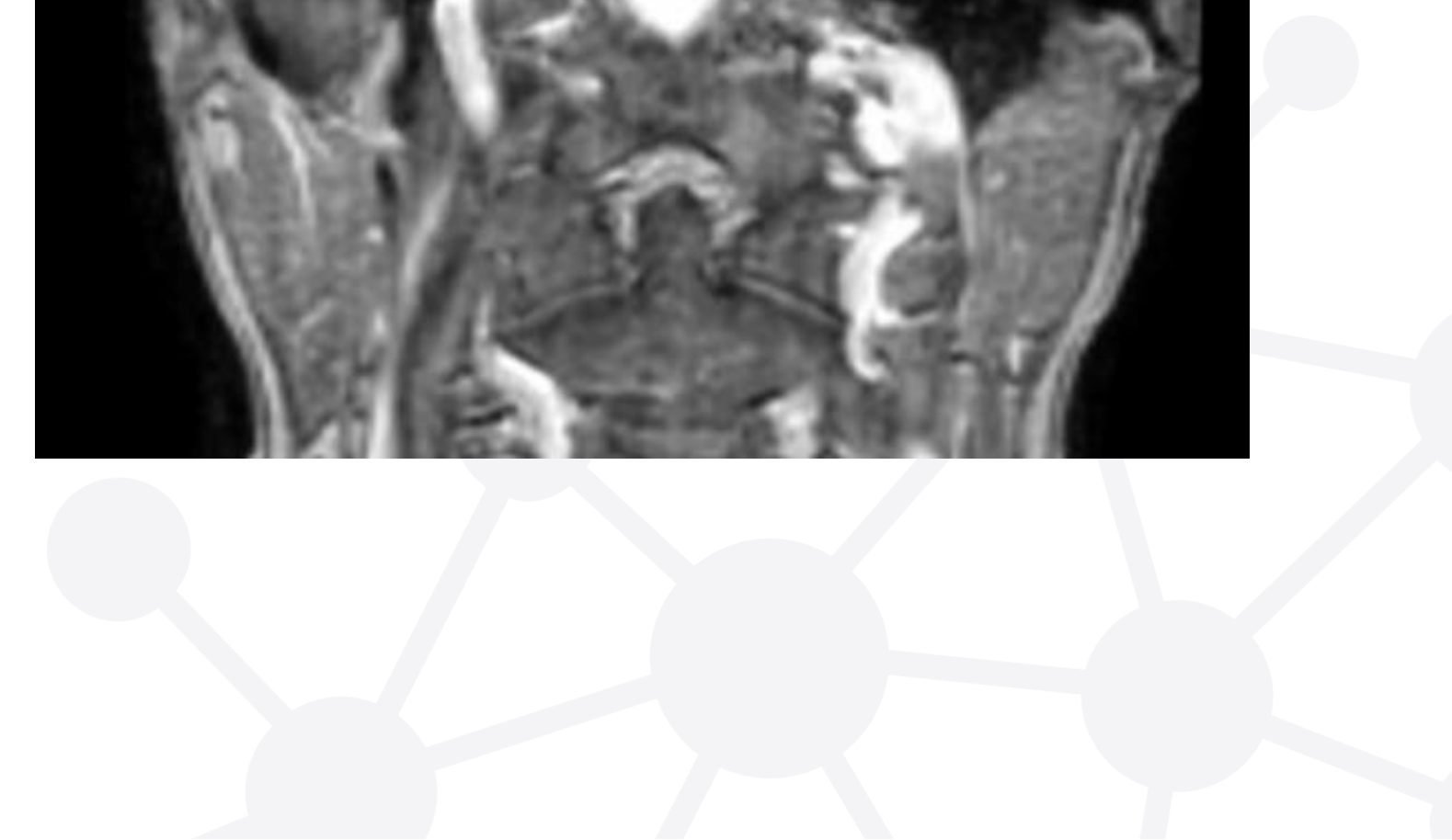
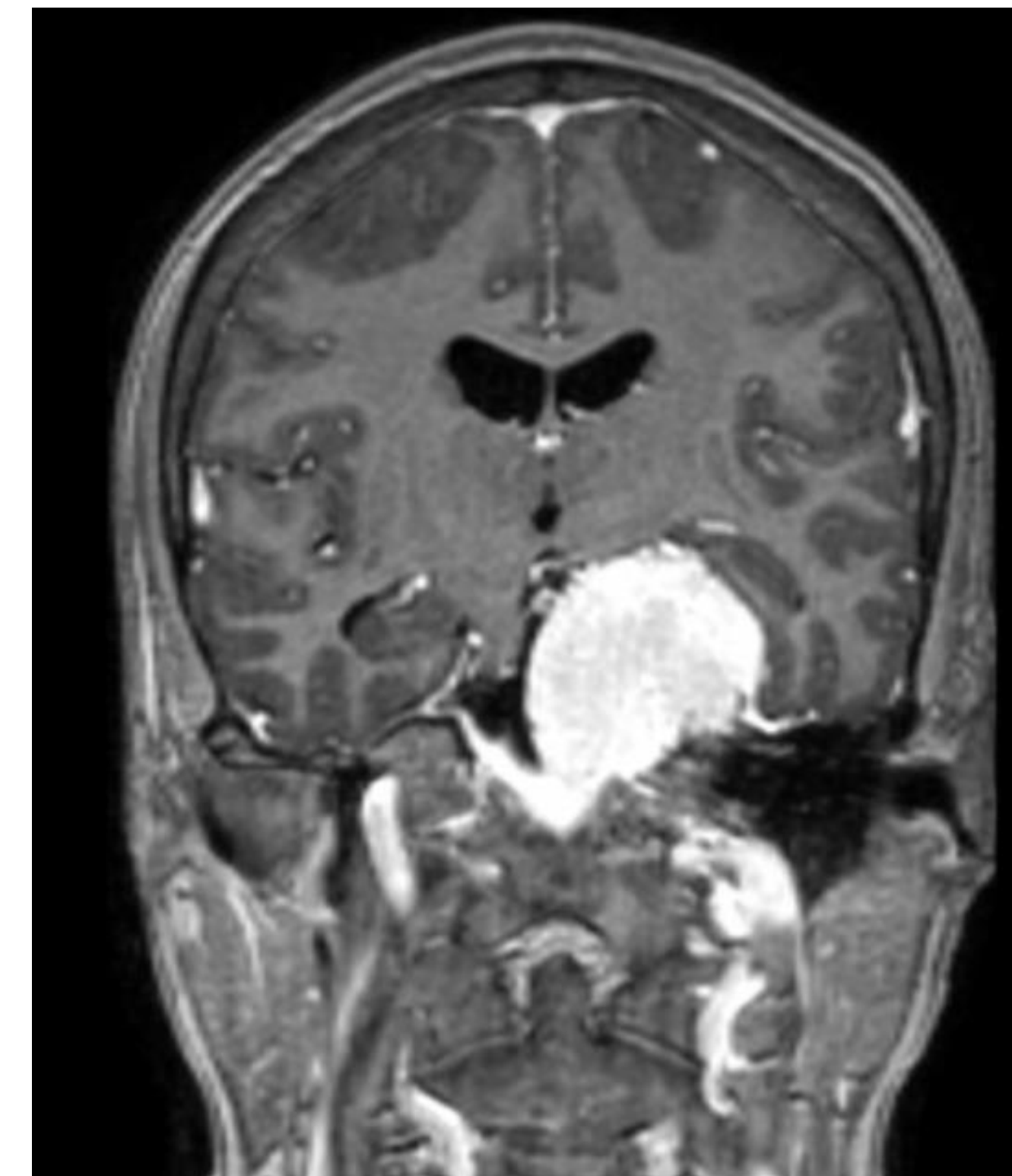
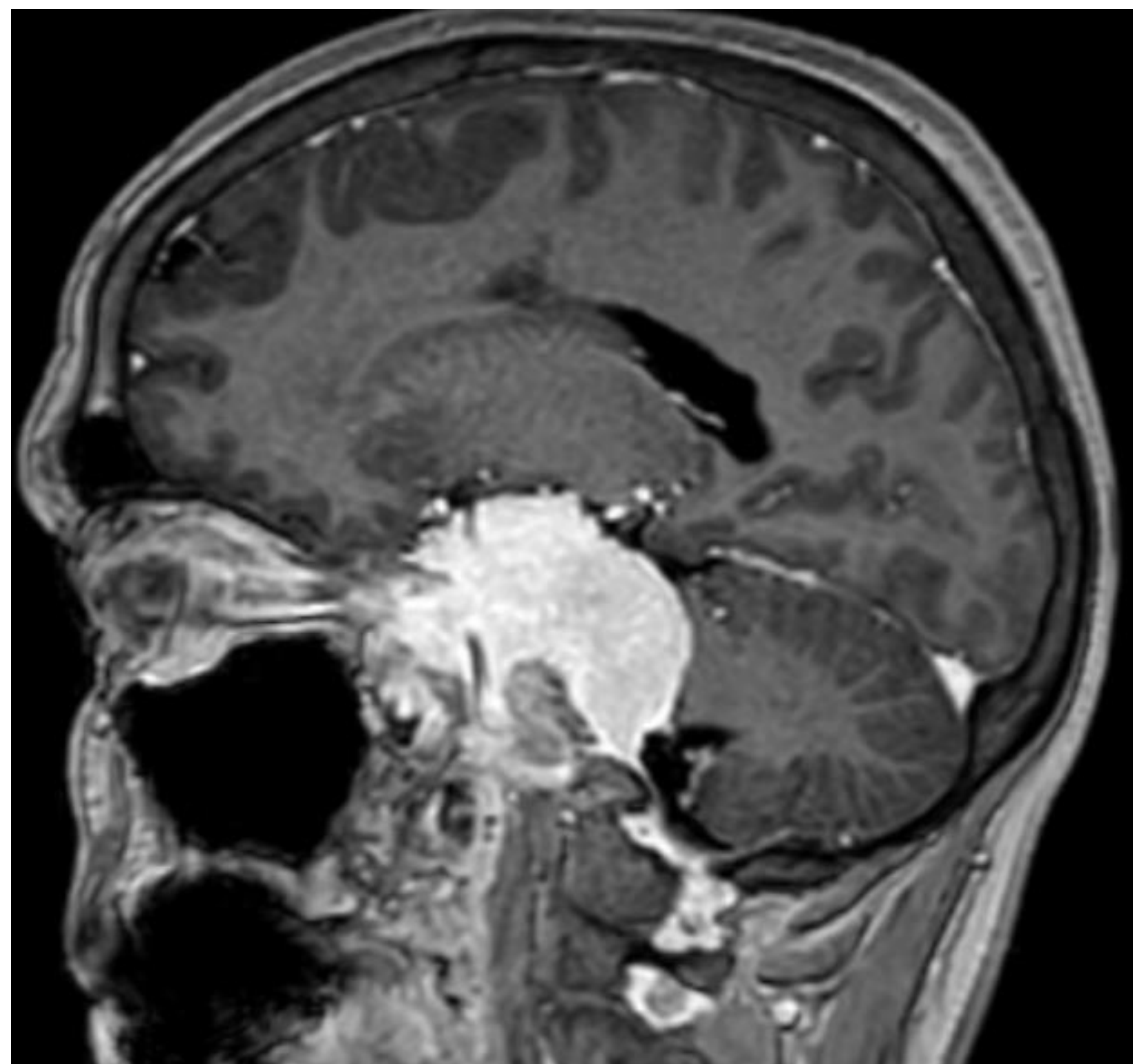
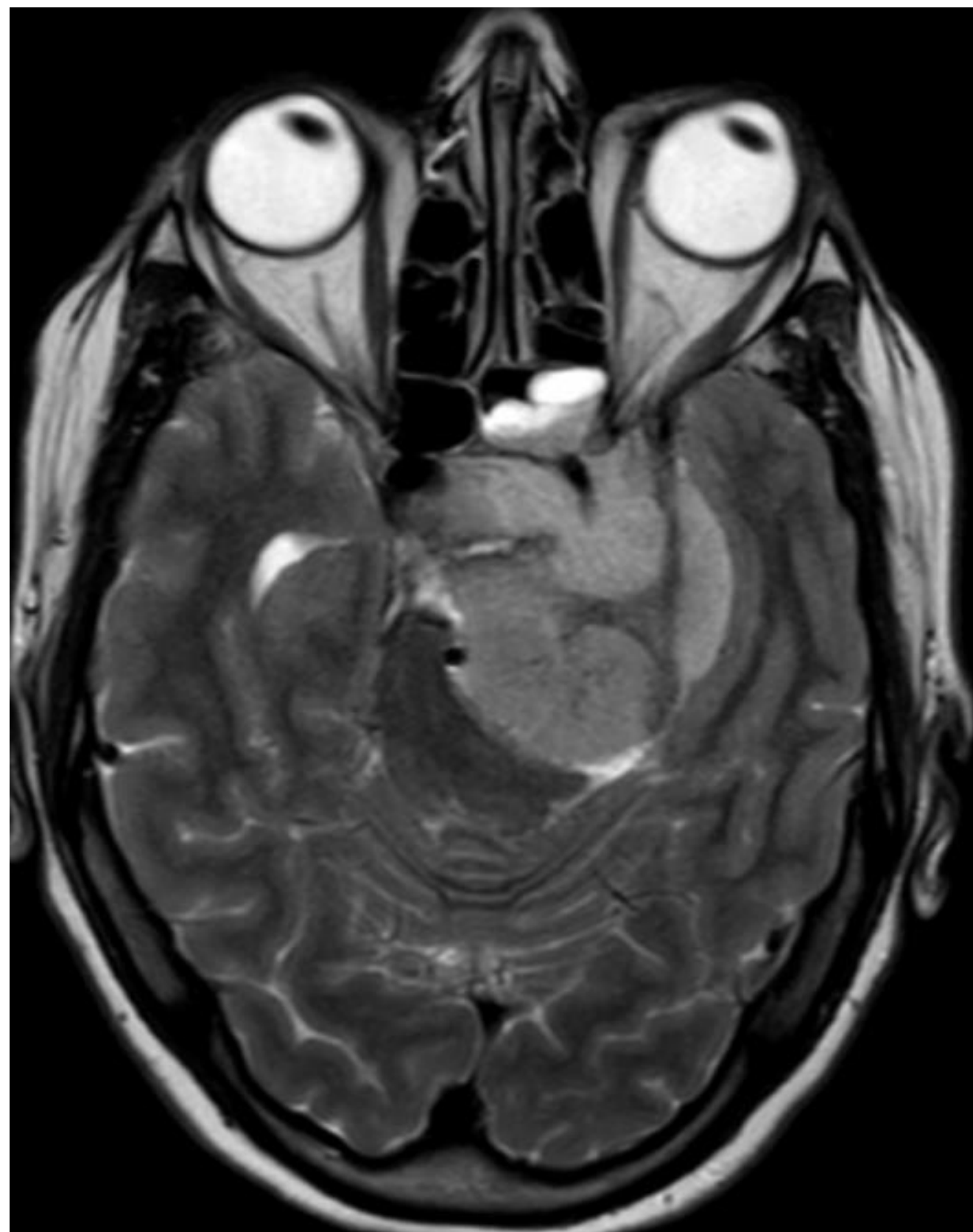Planum, Kiszárny, Nagyszárny, Parasellaris



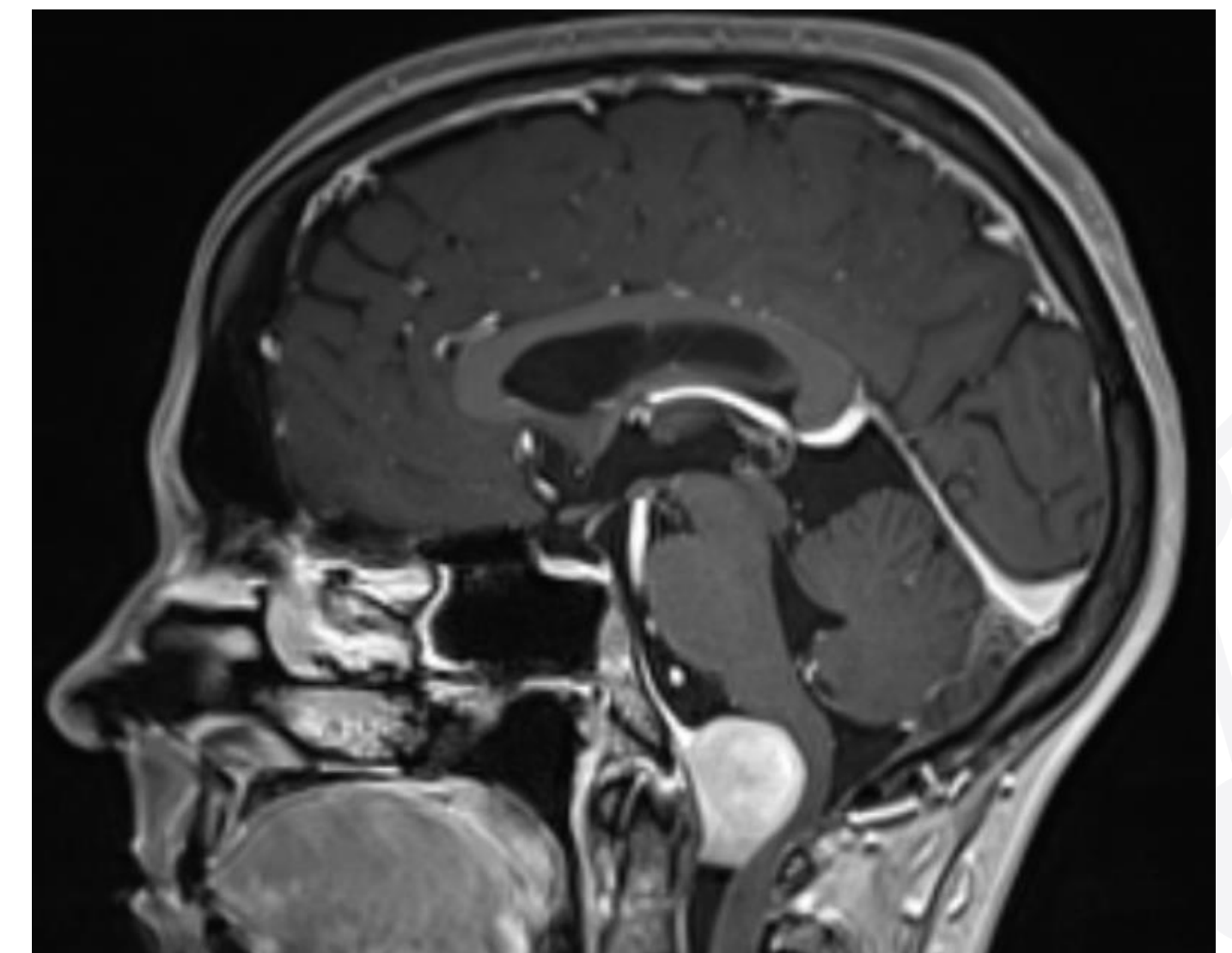
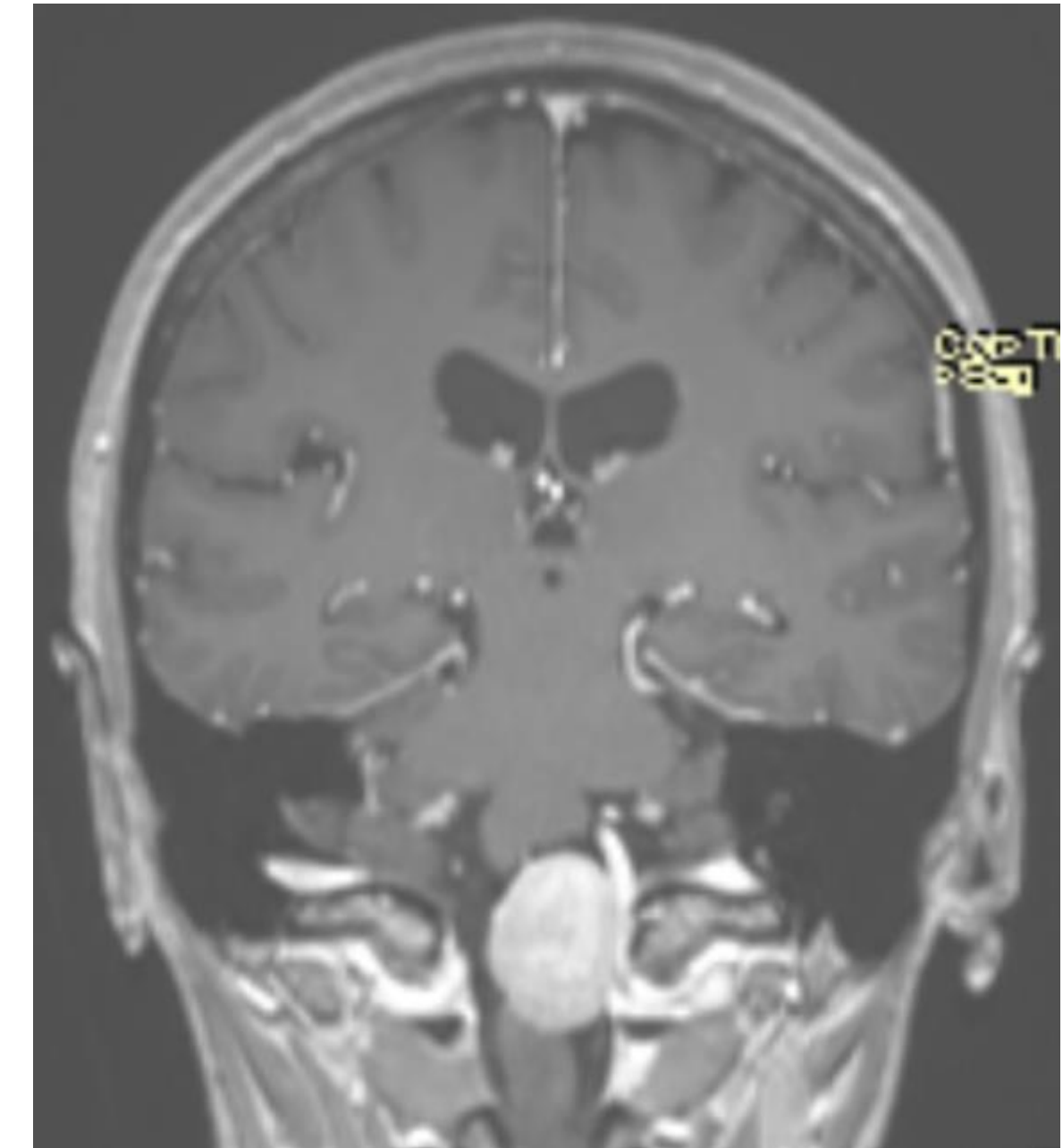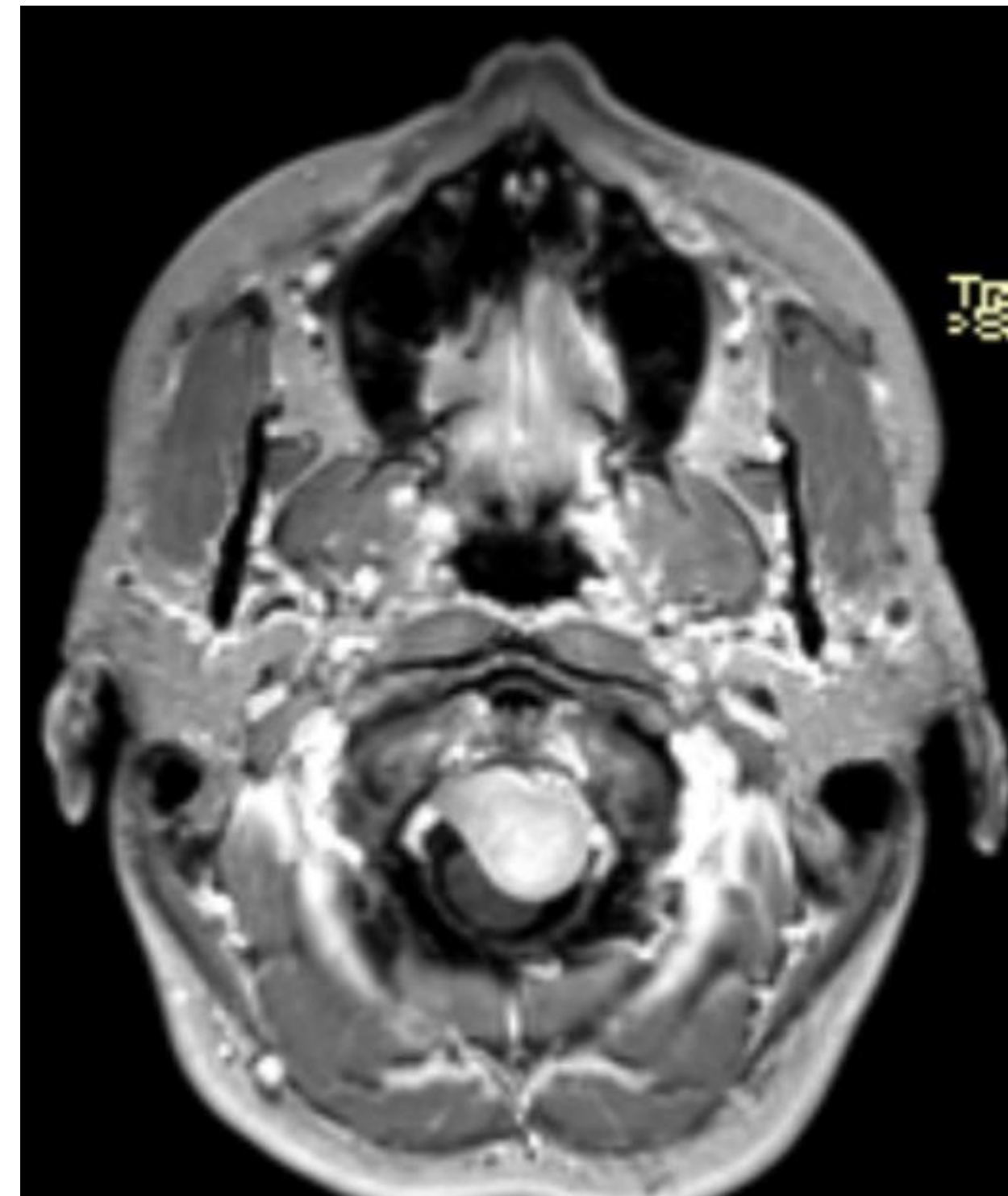
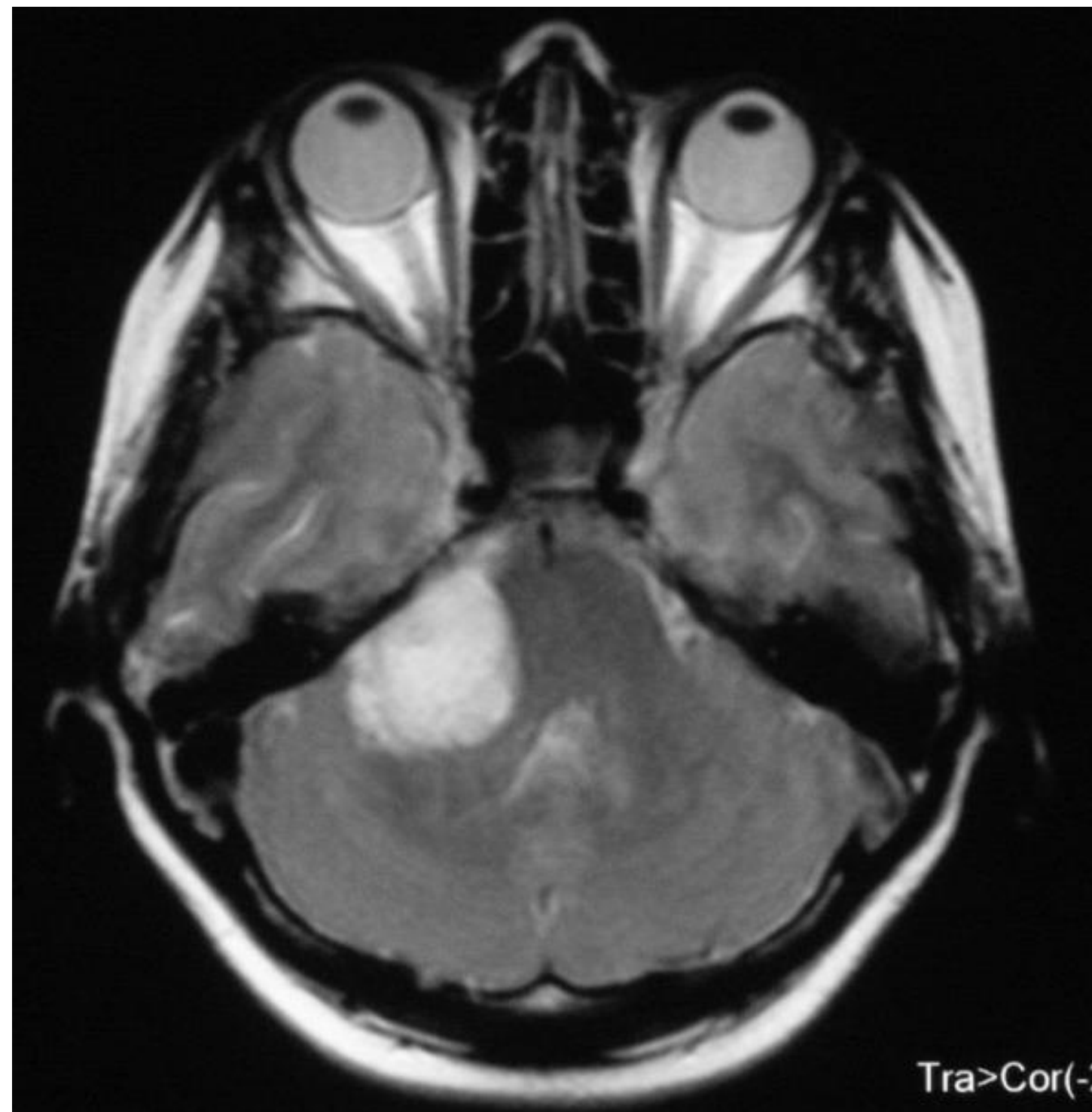
En plaque korszárny



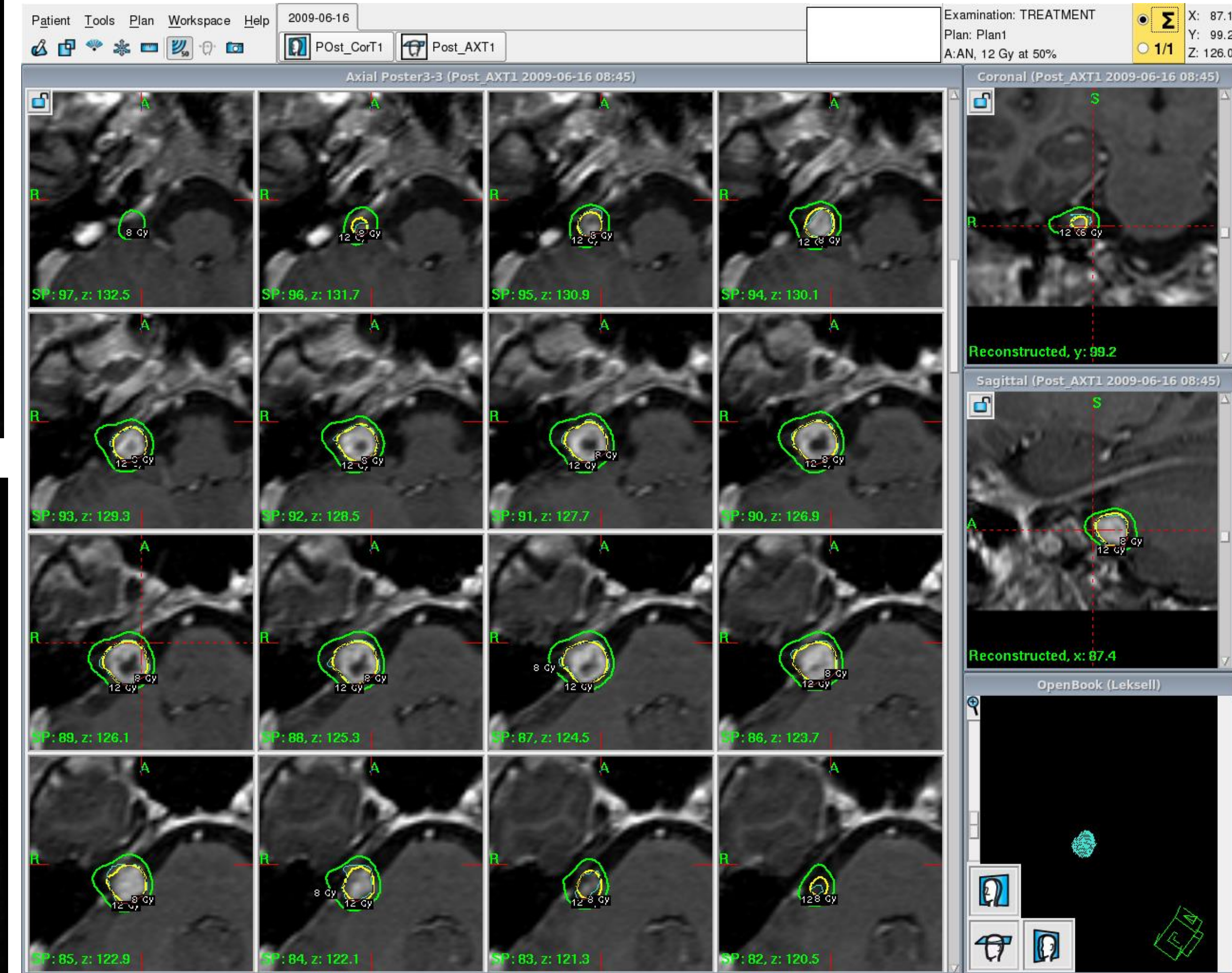
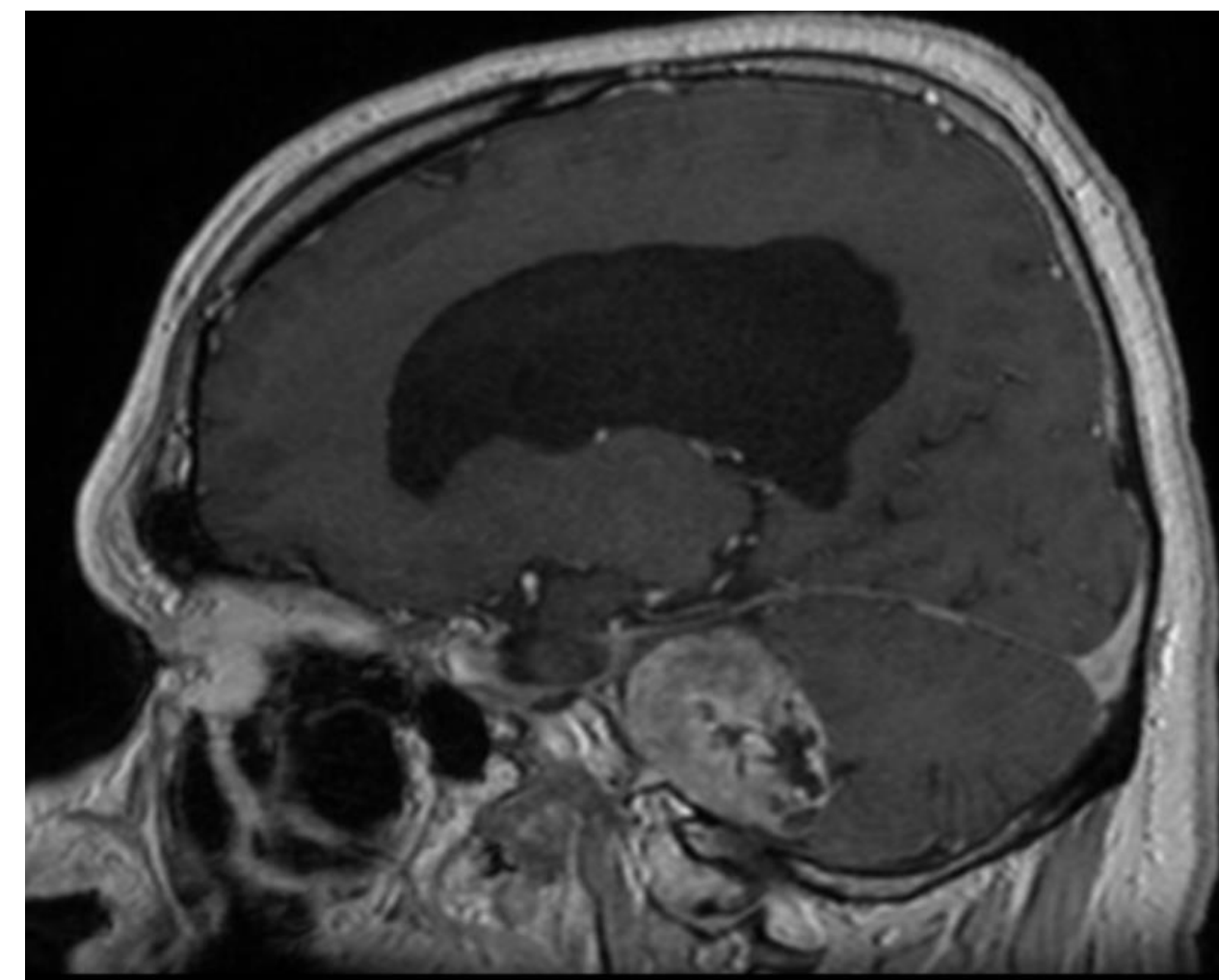
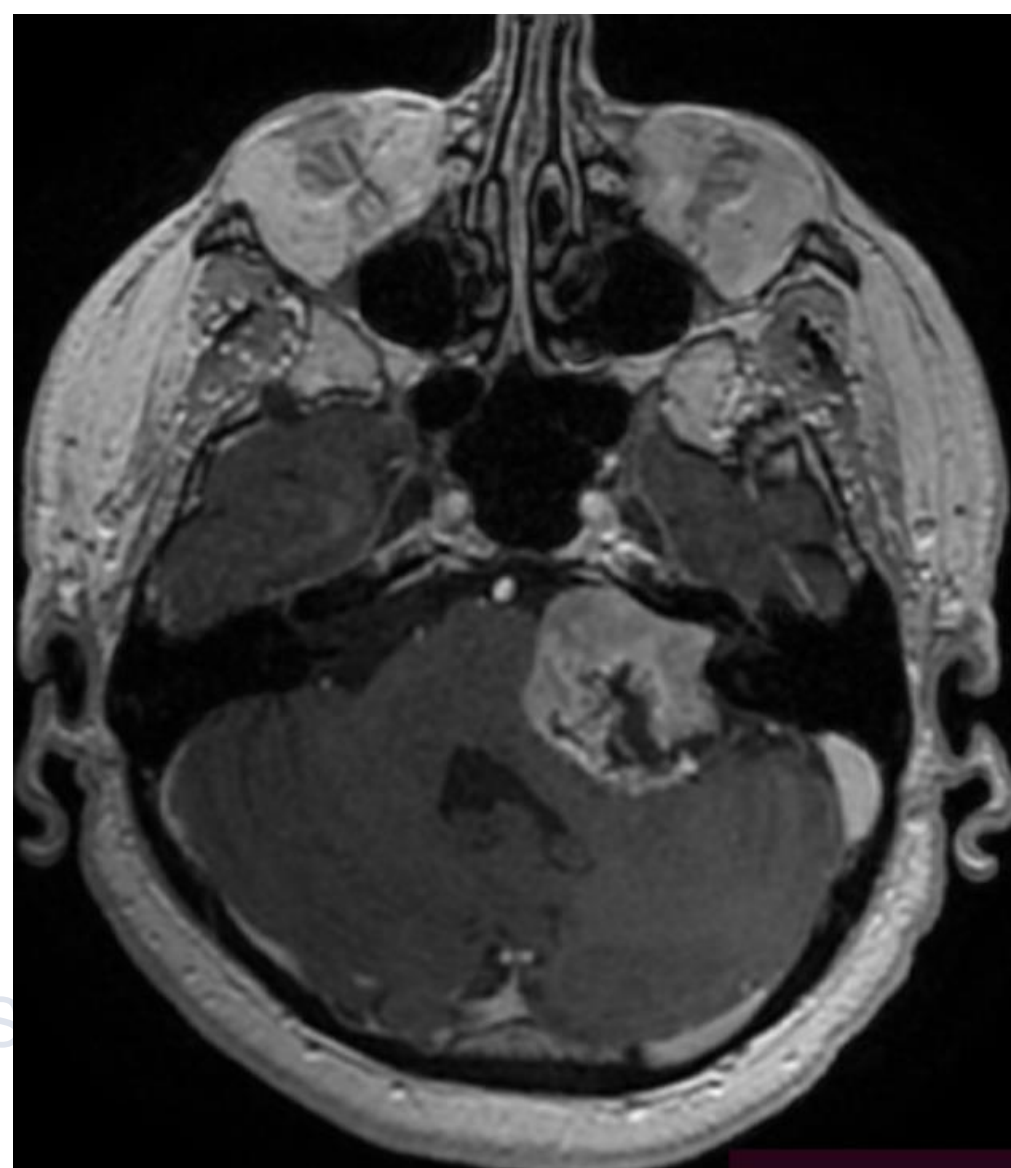
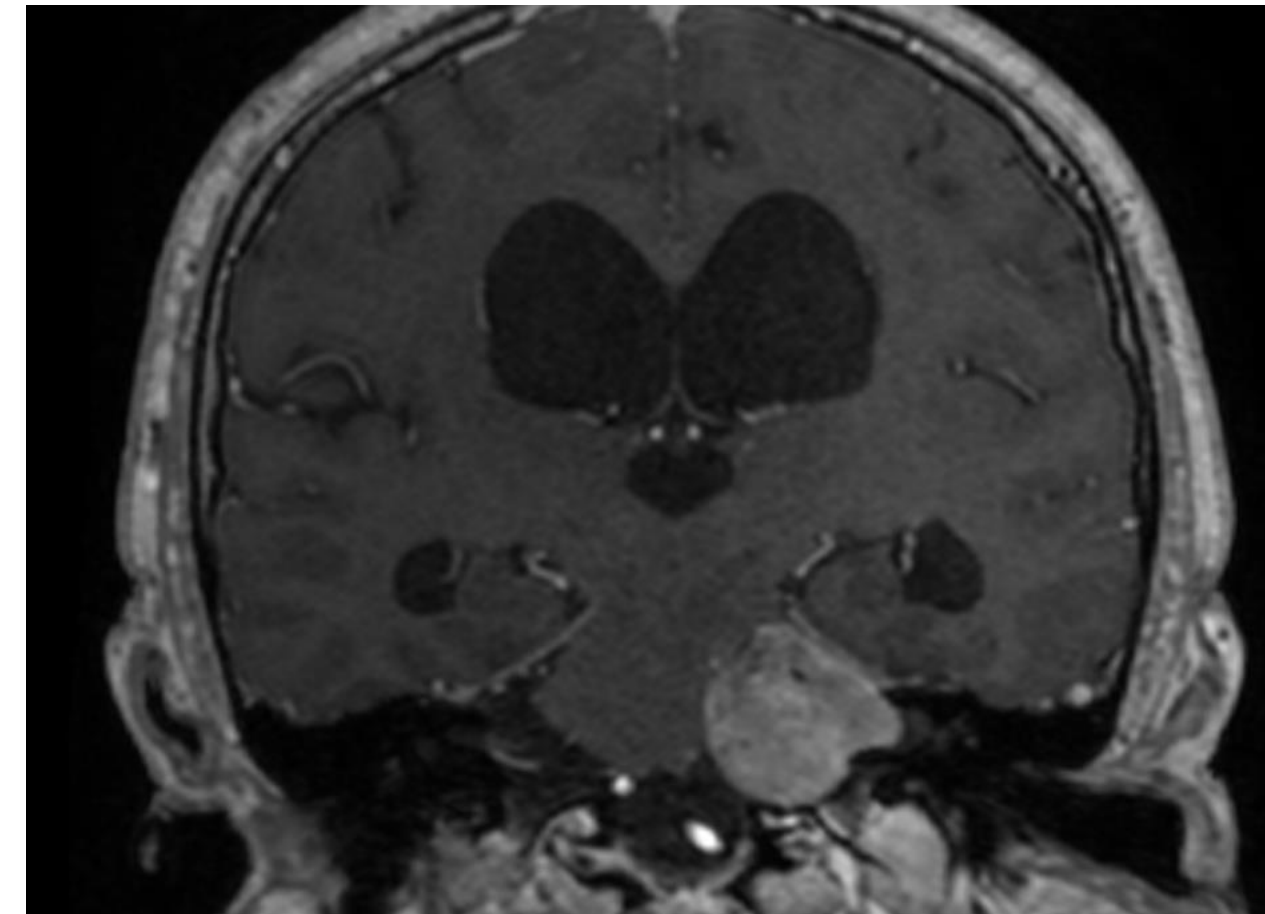
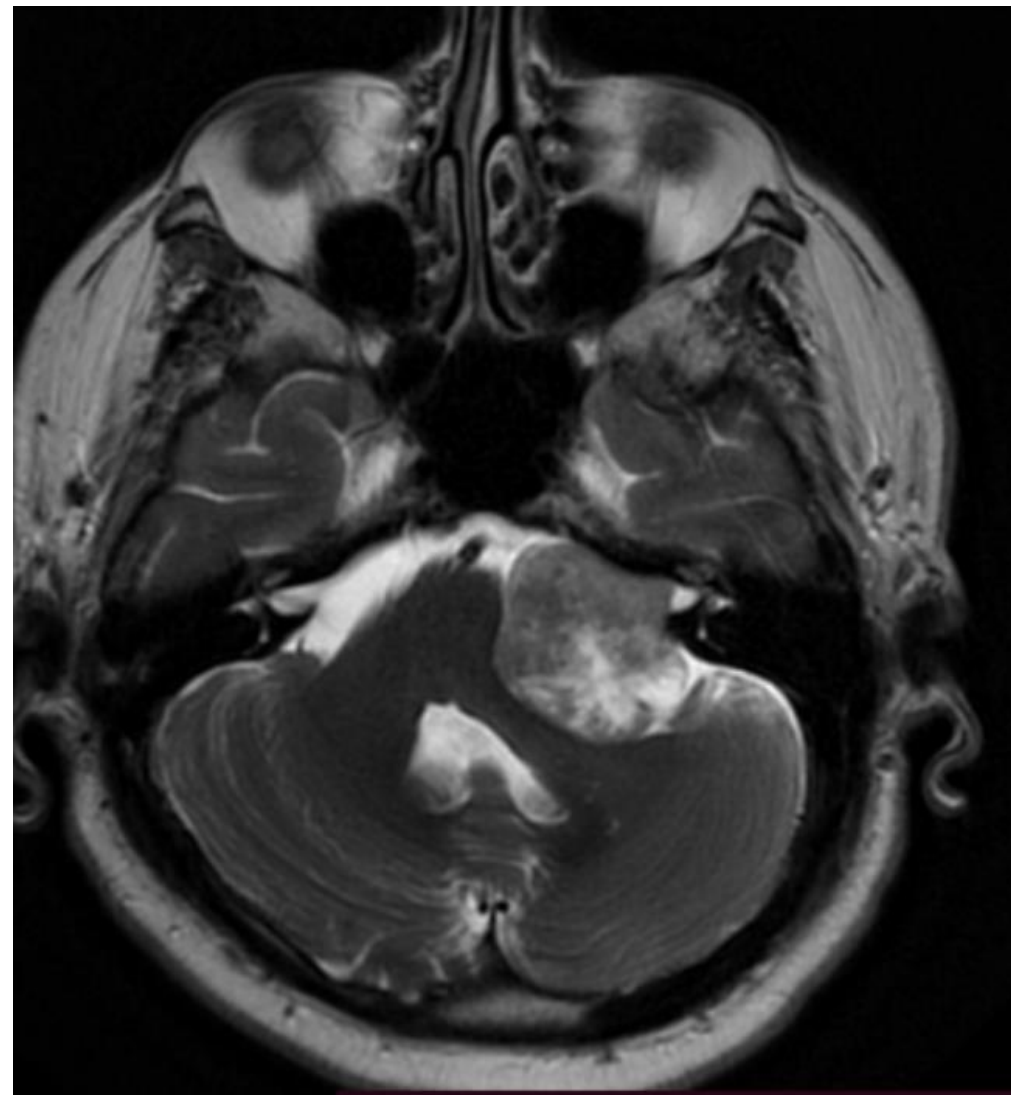
Parasellaris-petroclivalis Sebészet+sztereotaxiás sugárterápia



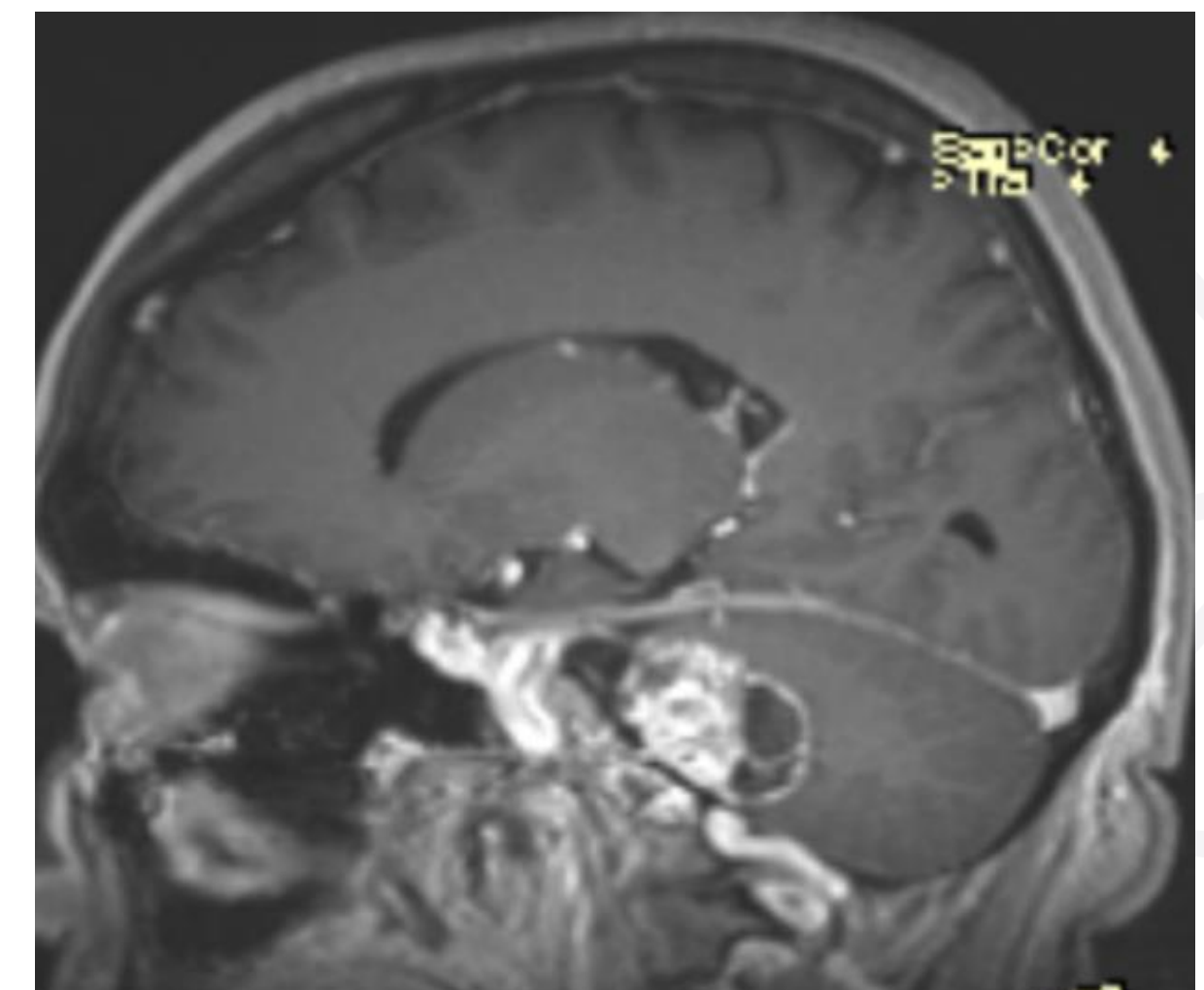
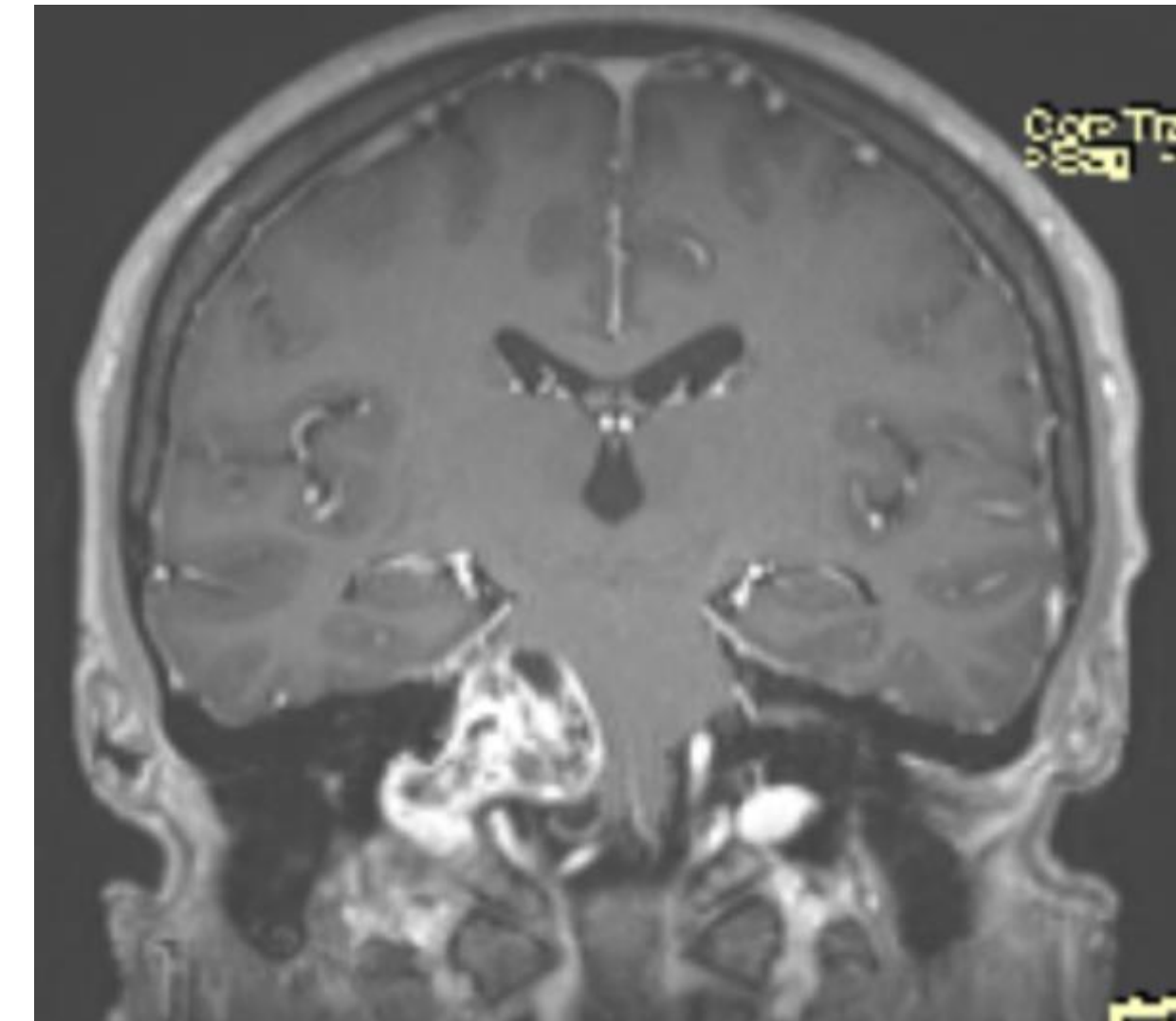
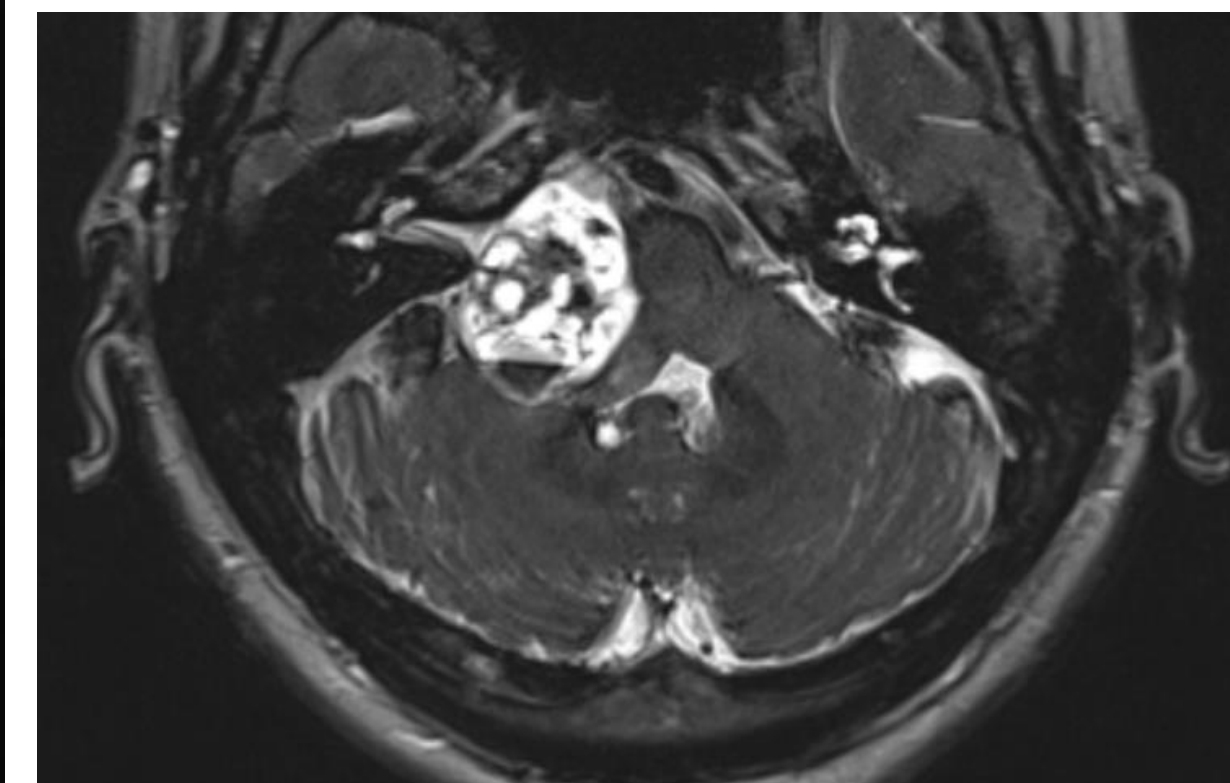
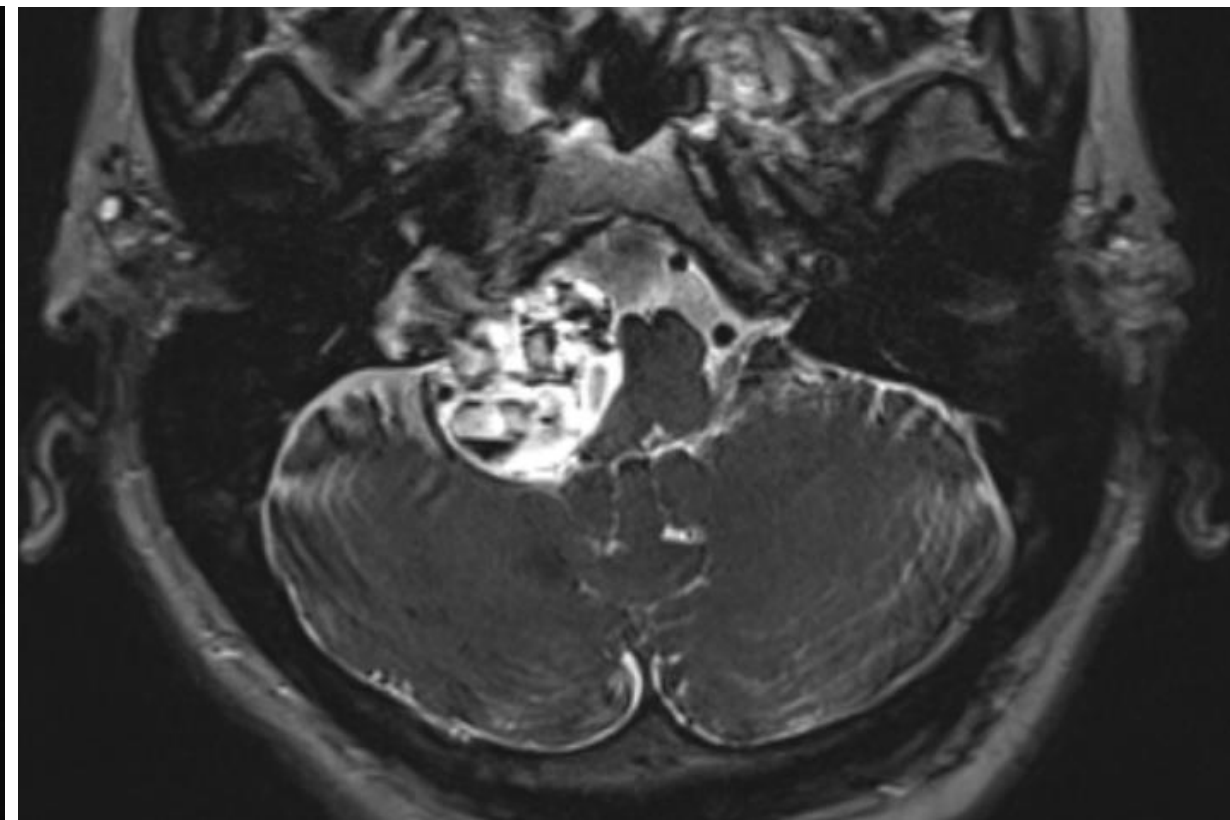
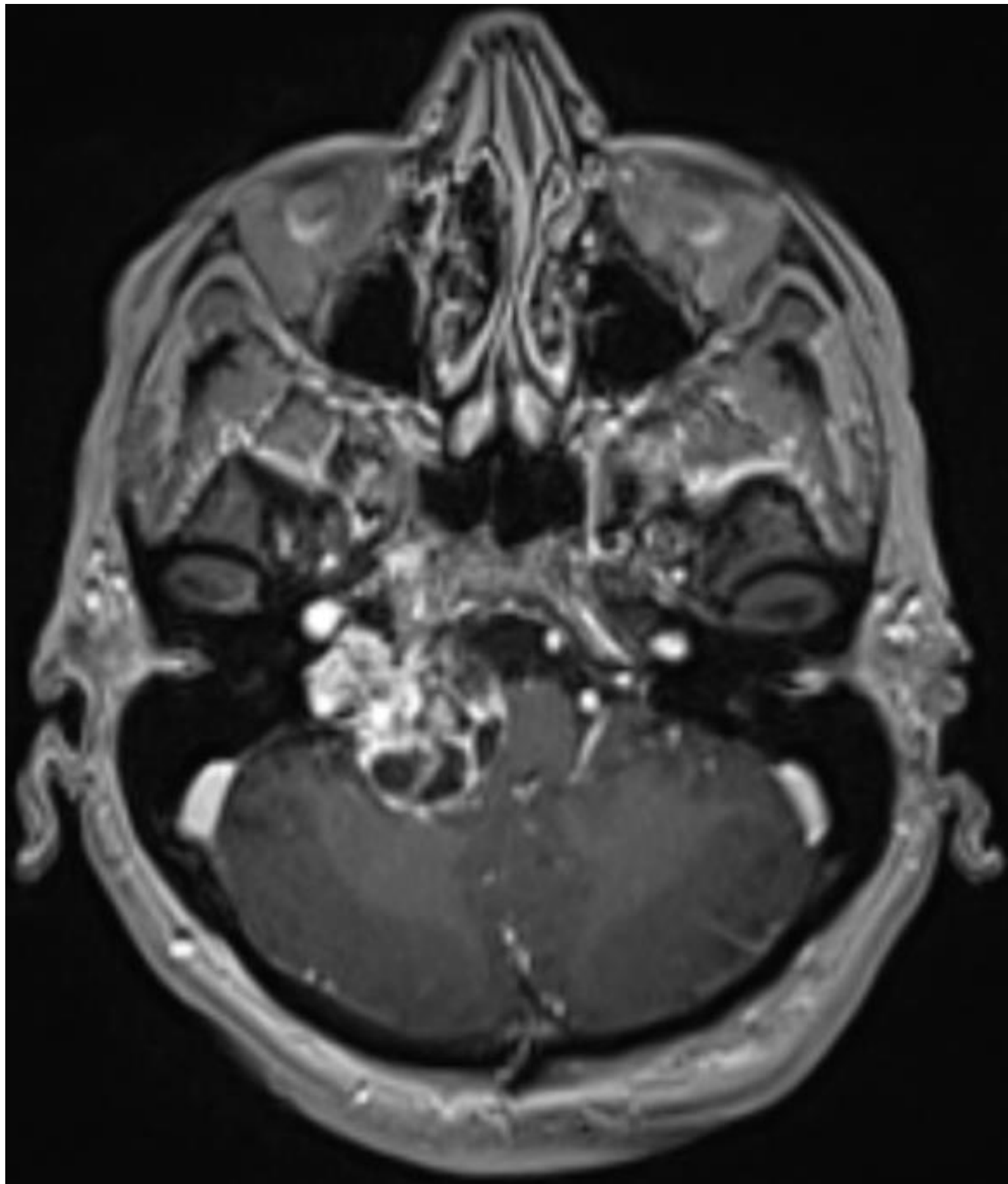
Hátsó scala: Pontocerebellaris, Petroclivalis, Foramen magnum



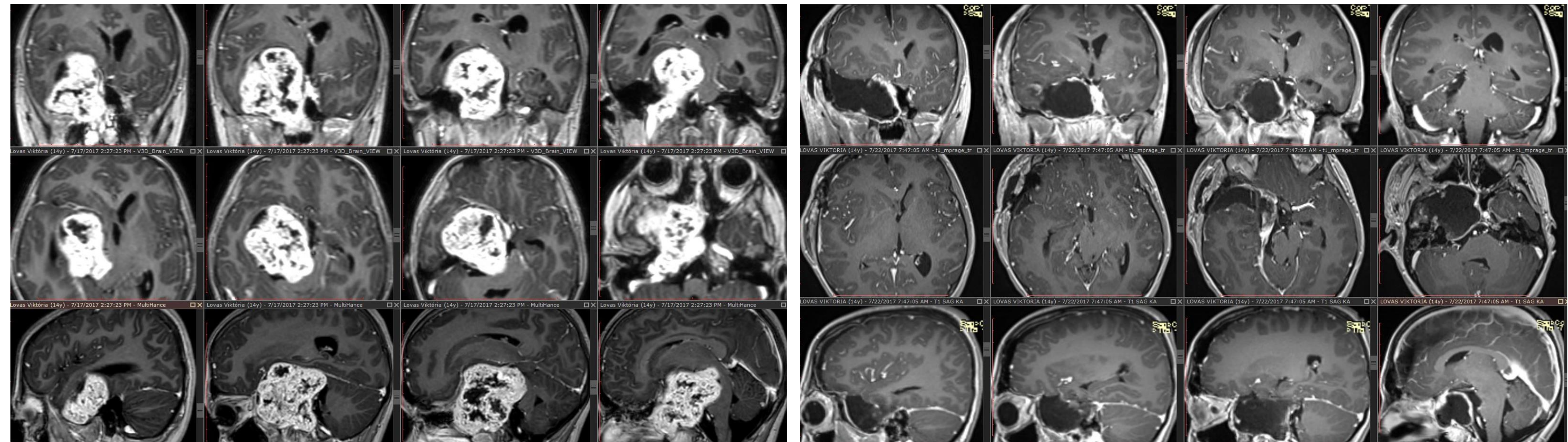
Schwannomák (neurinoma): Vestibularis



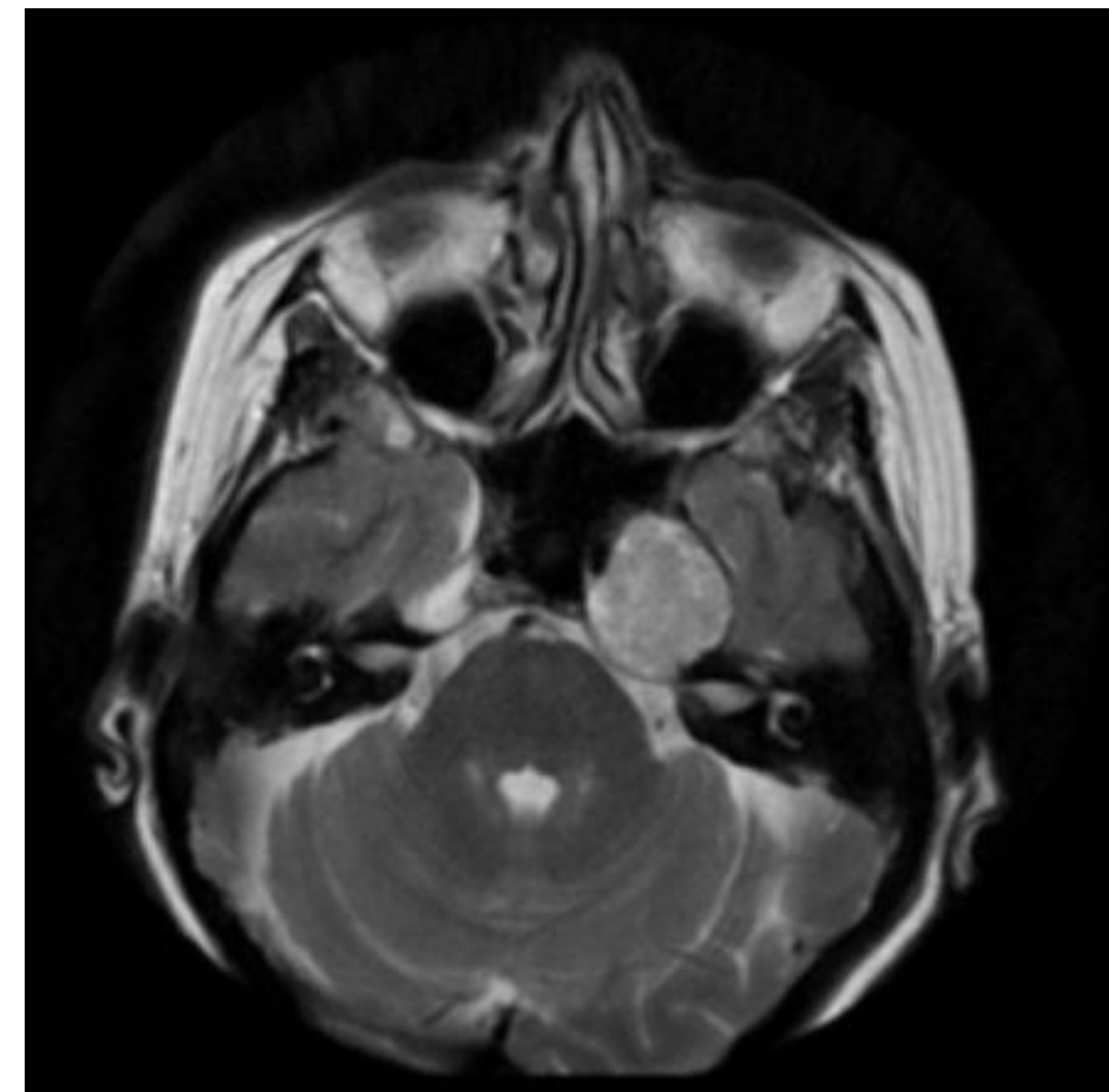
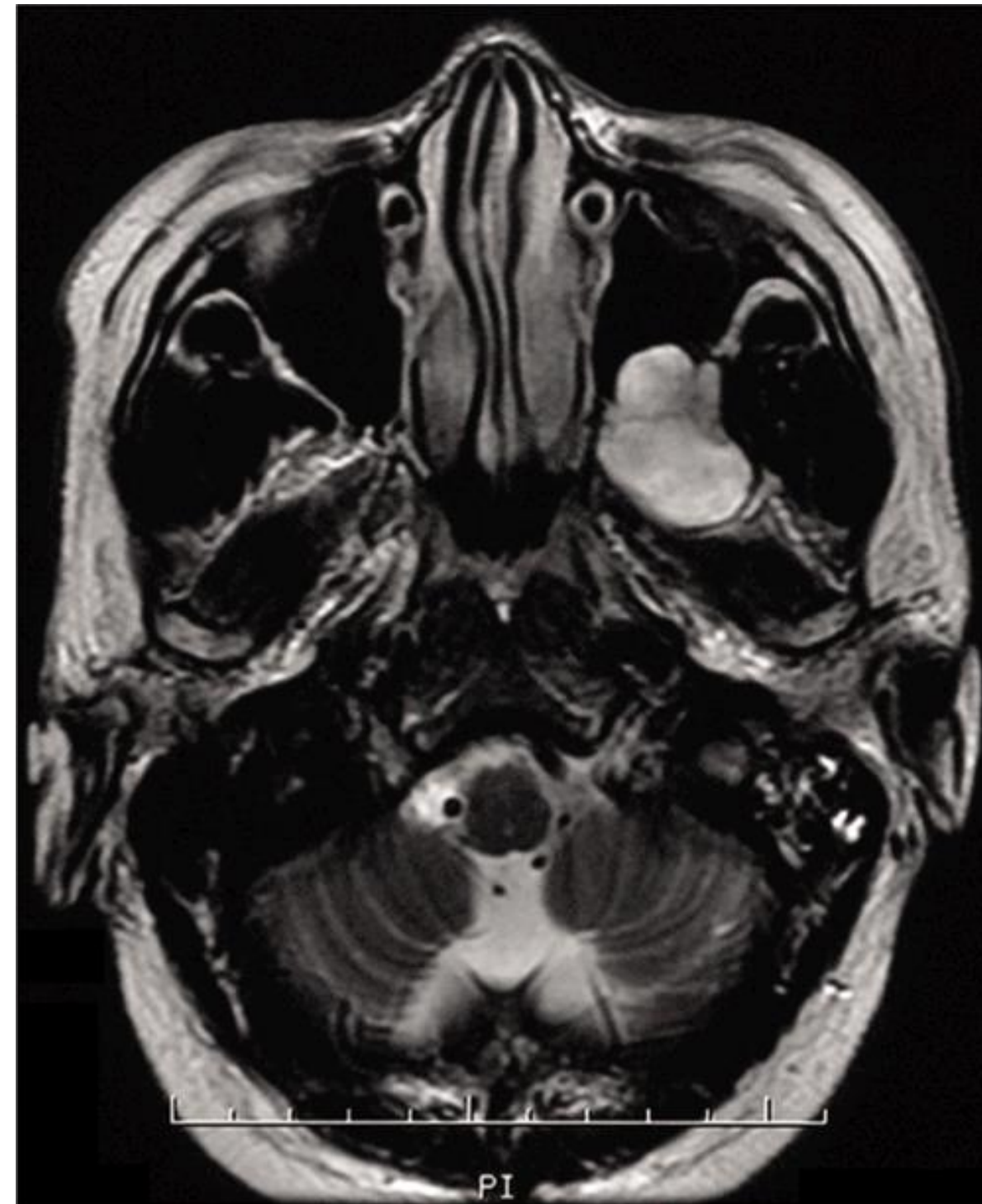
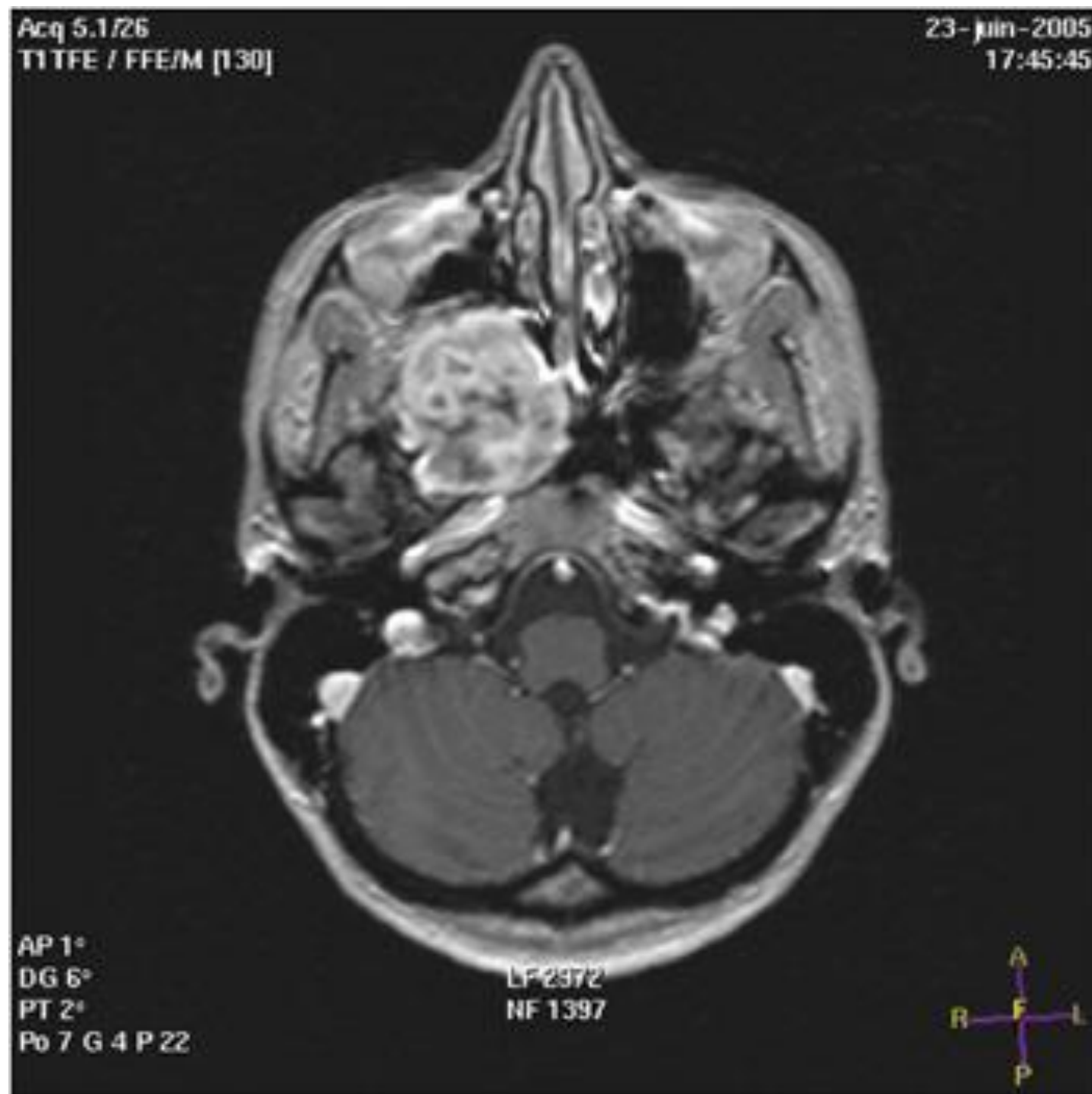
Schwannomák (neurinoma): Alsó agyidegek (IX-XI)



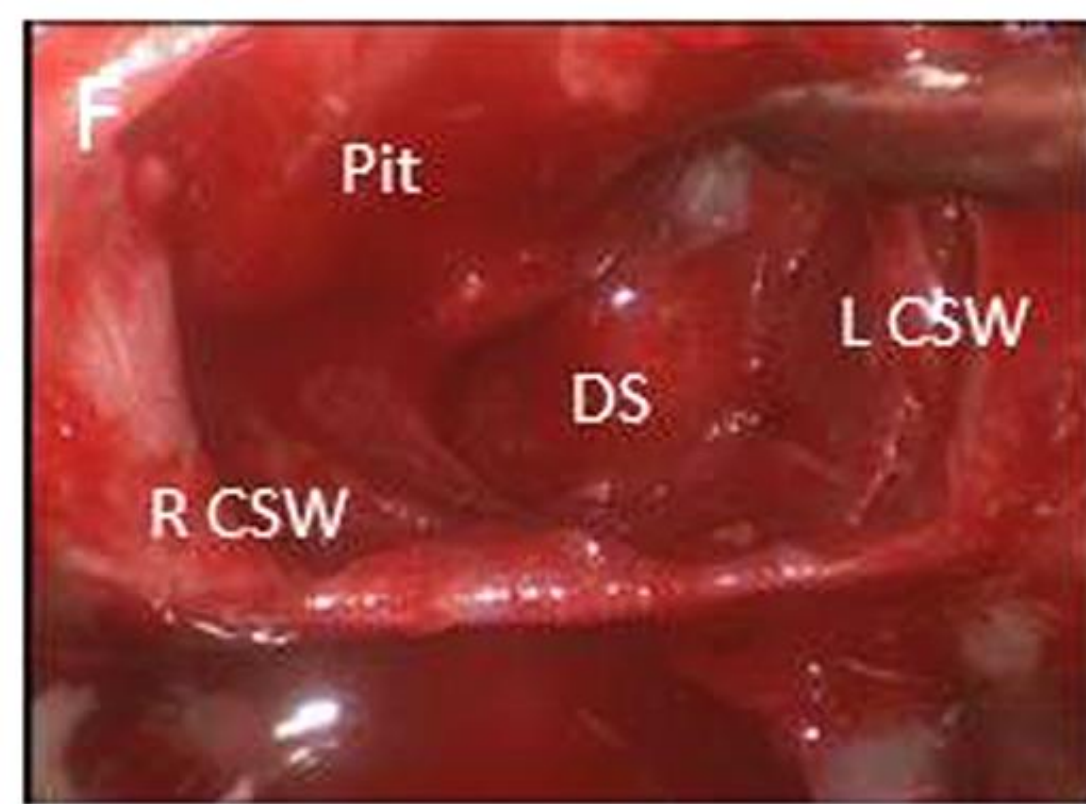
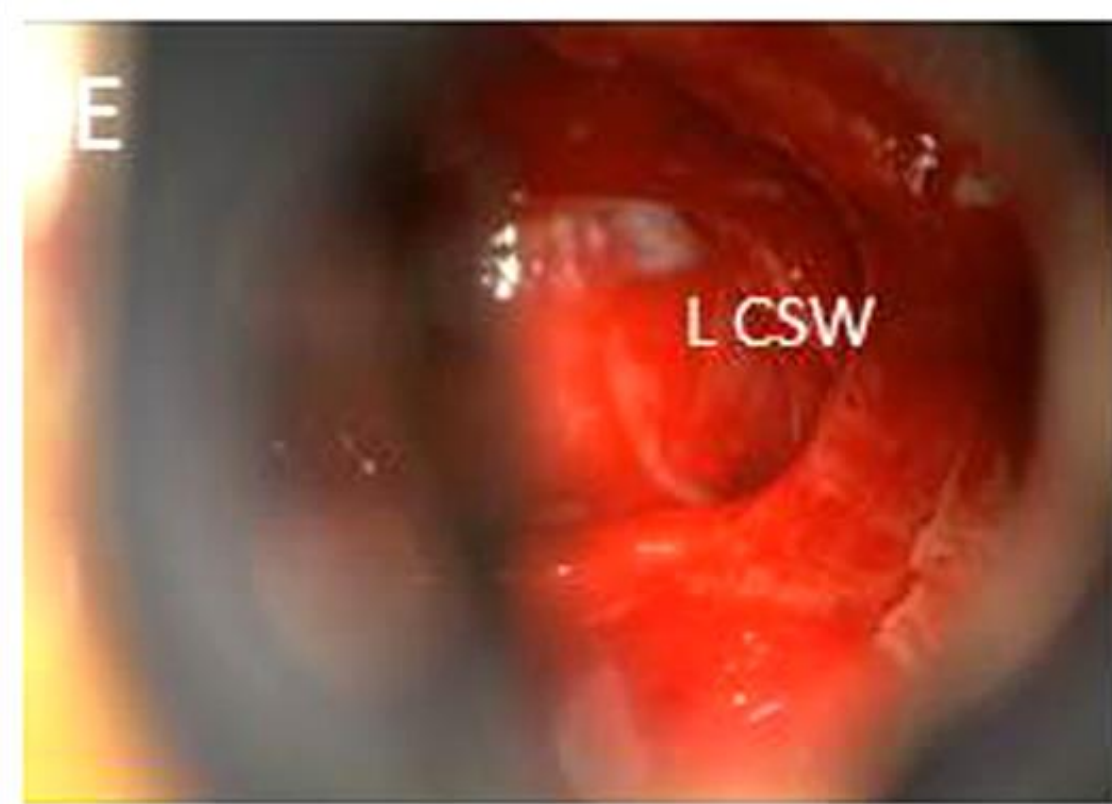
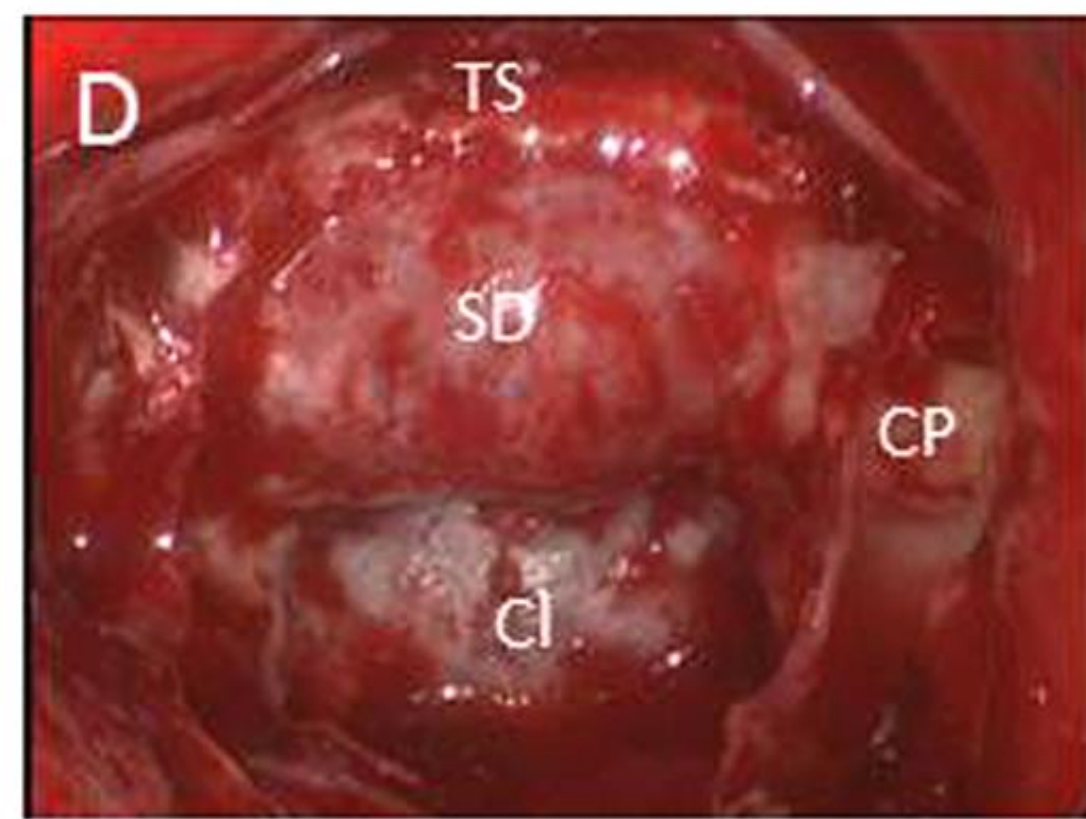
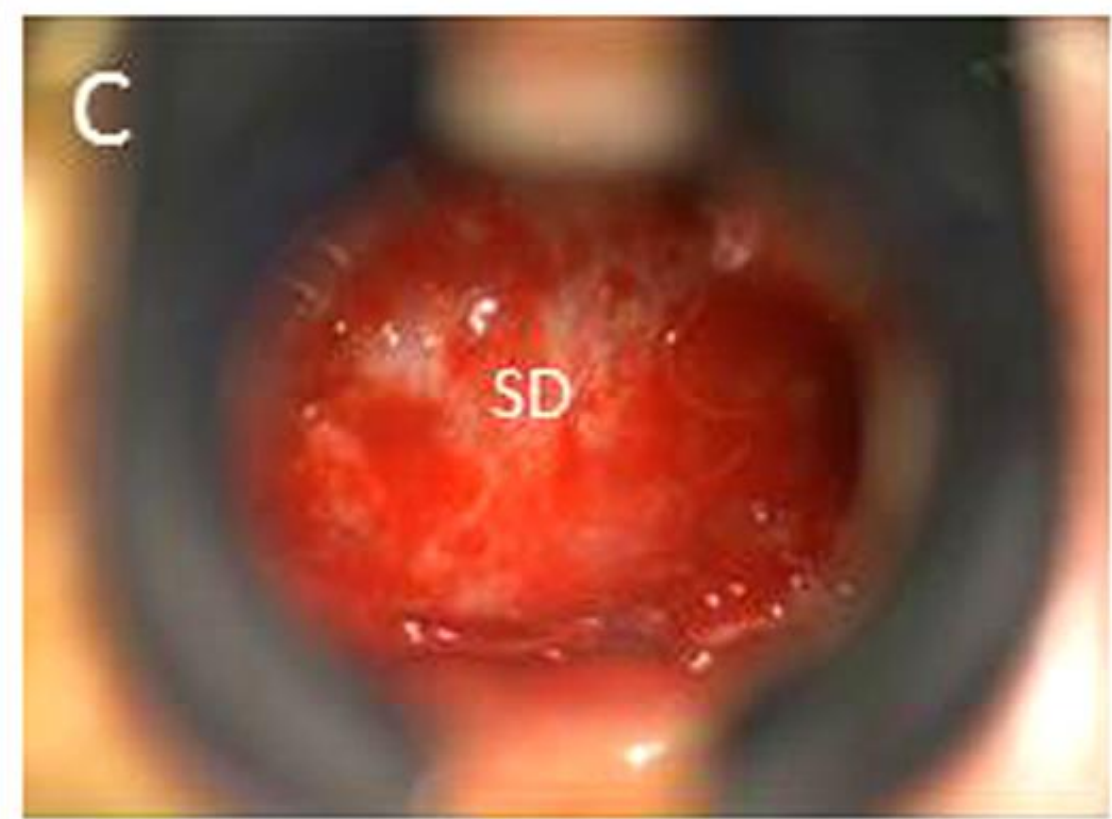
Schwannomák (neurinoma): Trigemínus



Schwannomák (neurinoma): Trigemini V/3 extracranialis (infratemporalis) > Transnasalis (transpterygoid) endoscop

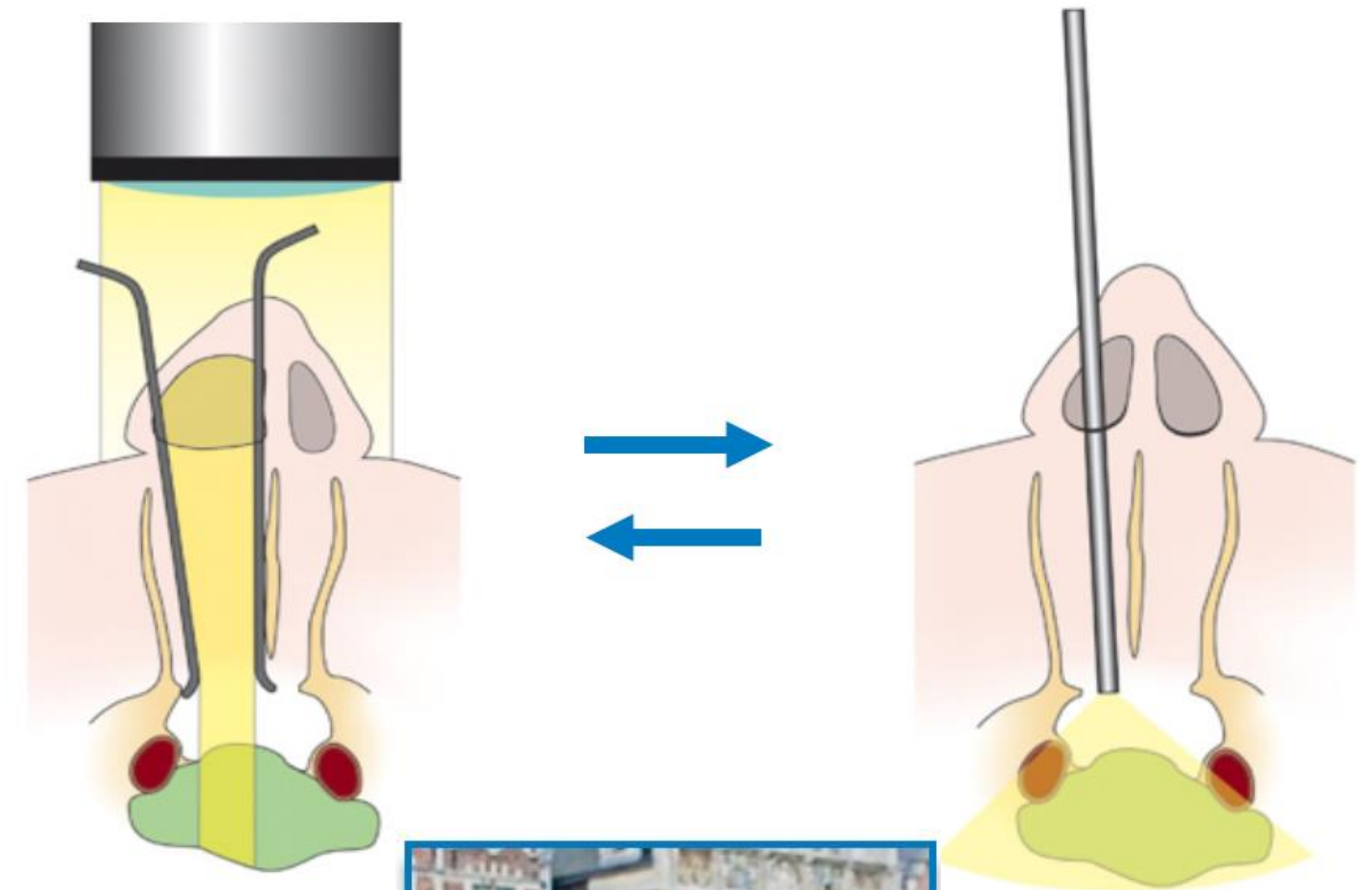


Transsphenoidal hypophysis: az endoszkóp előnye



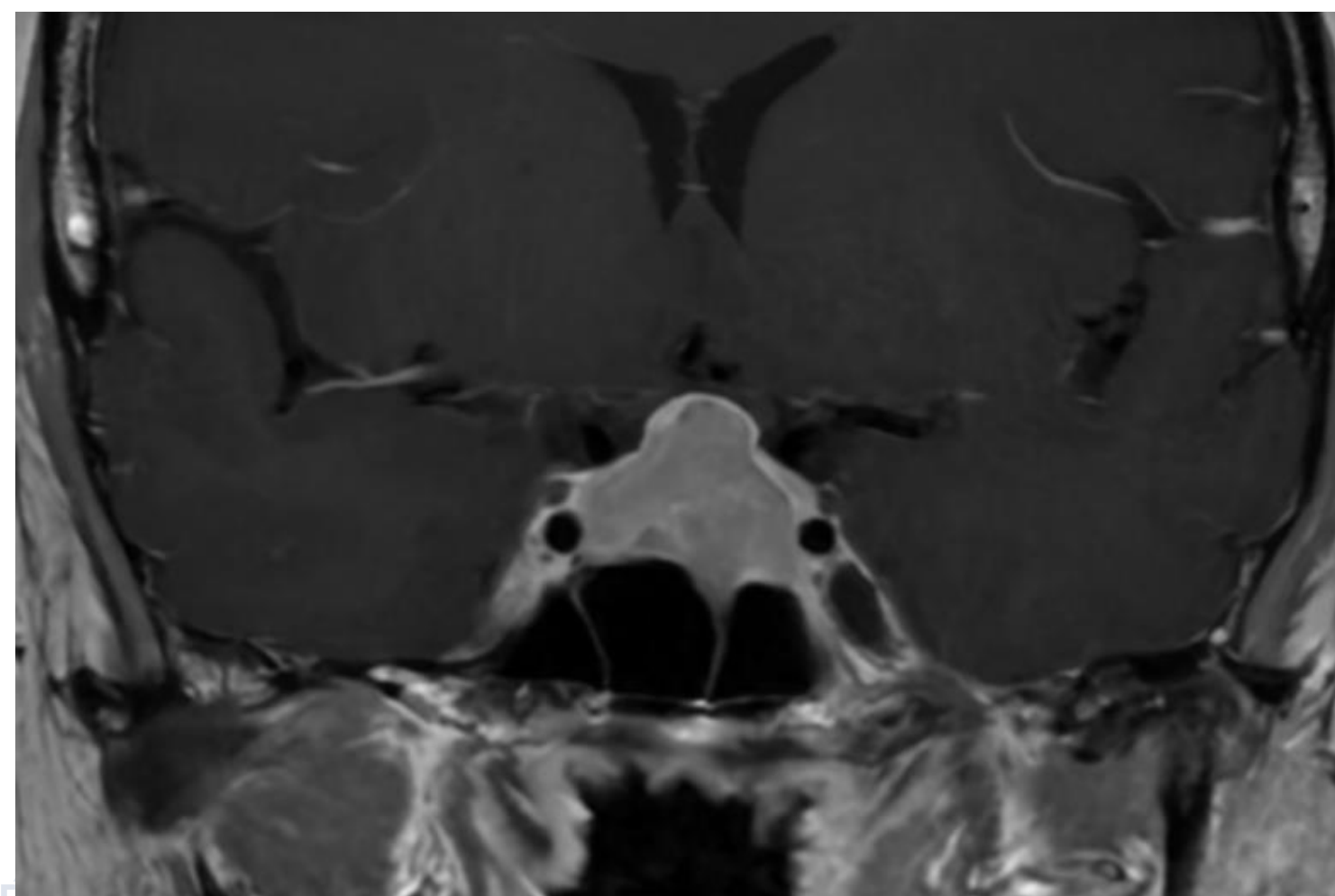
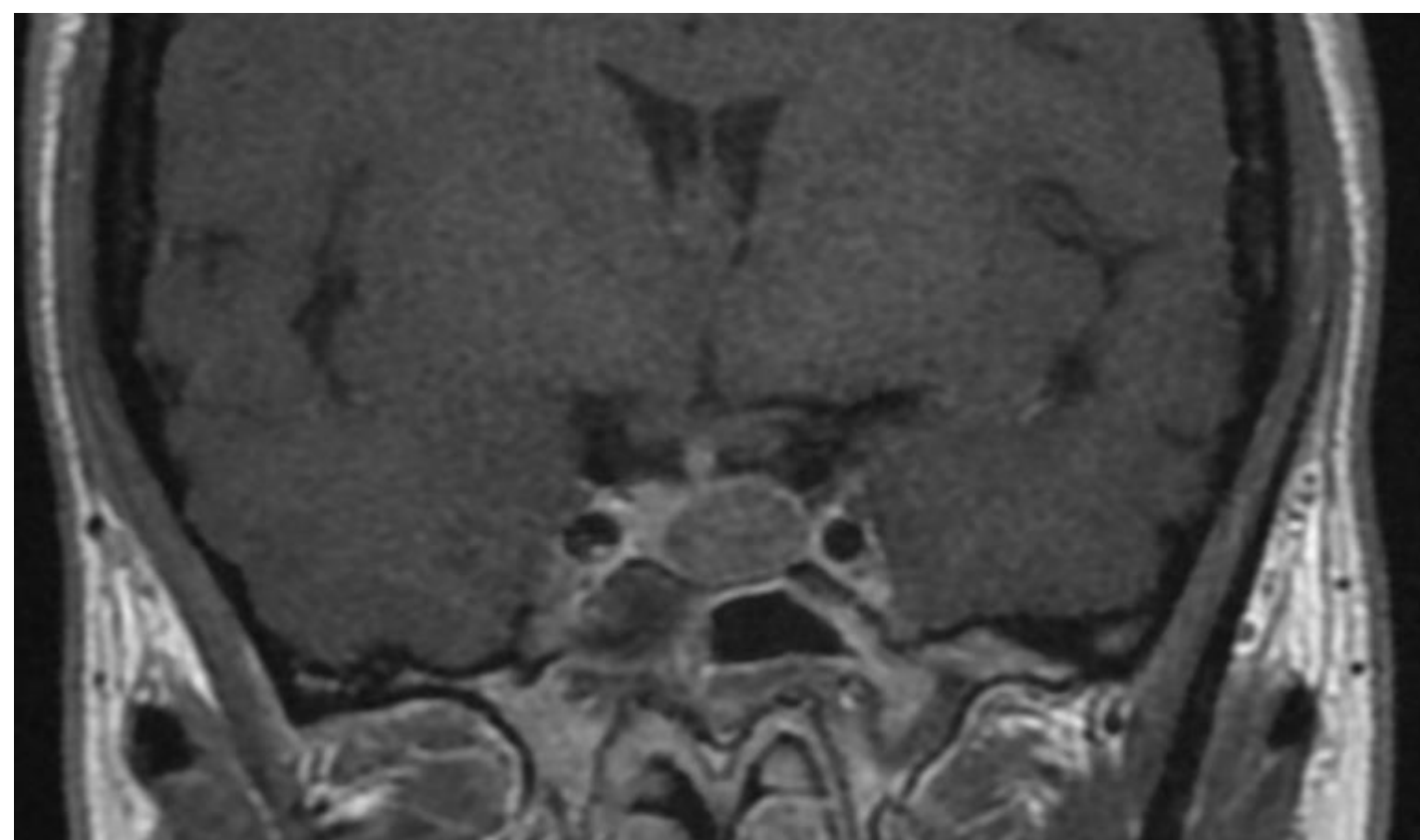
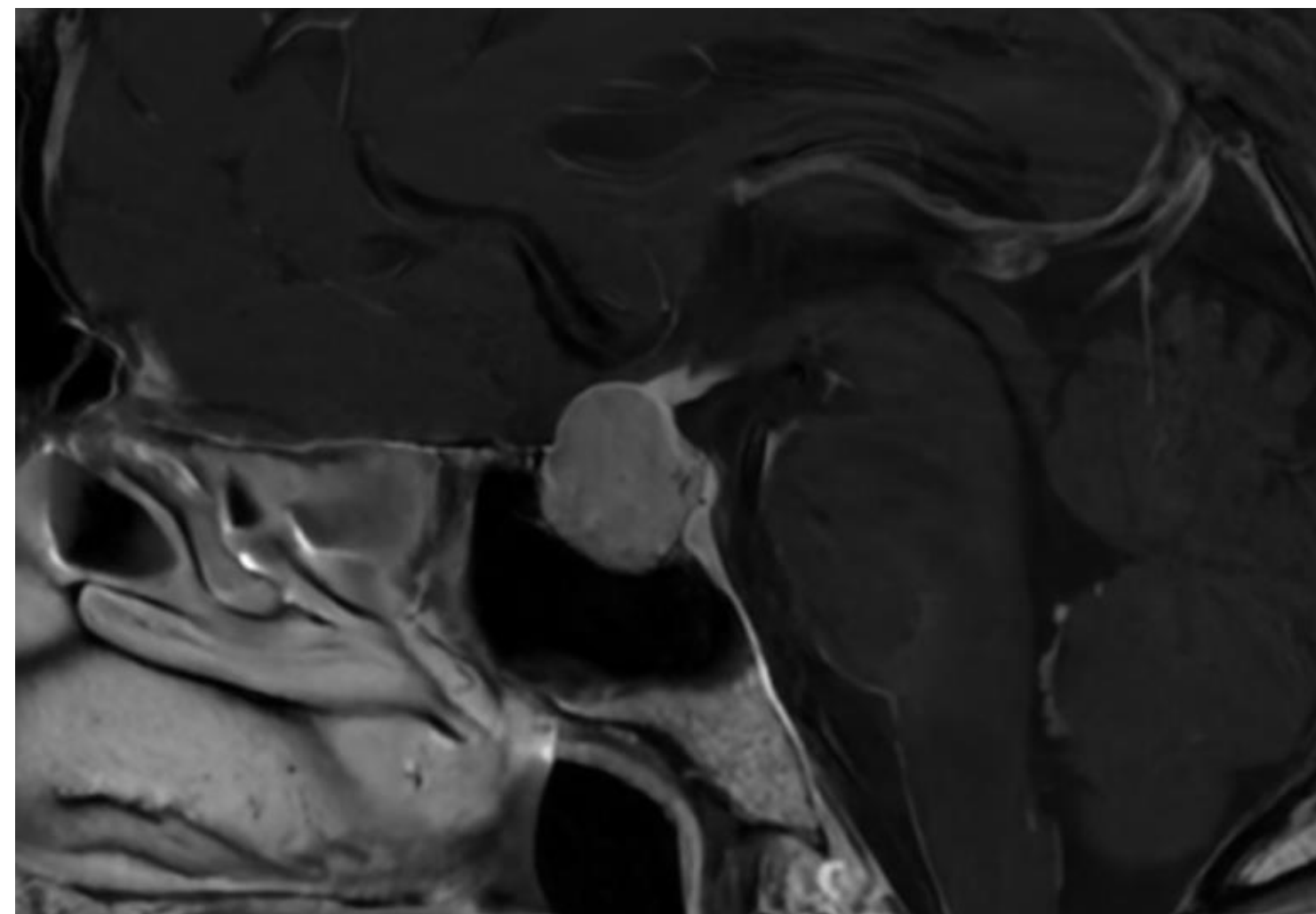
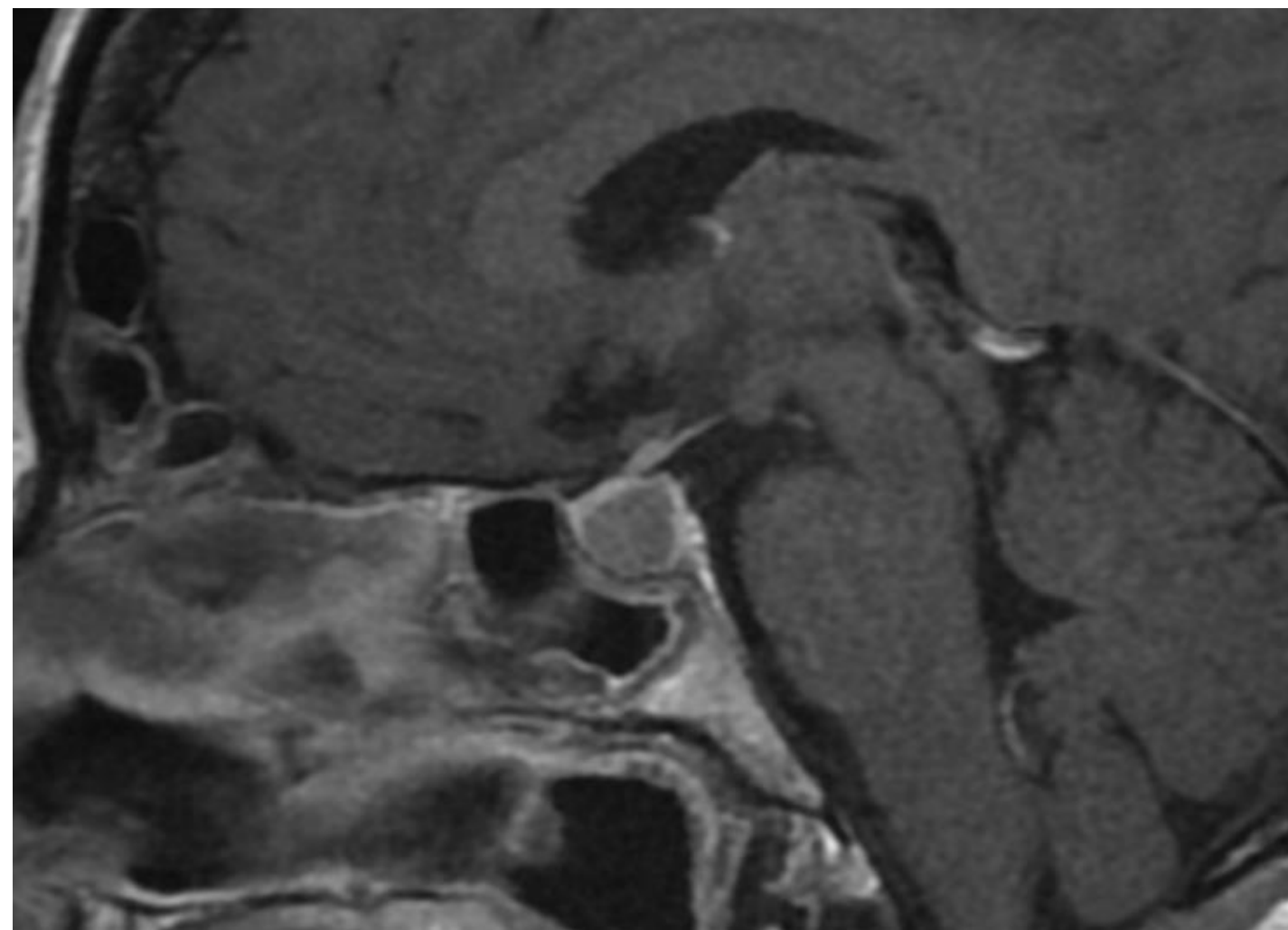
Microscope

Endoscope



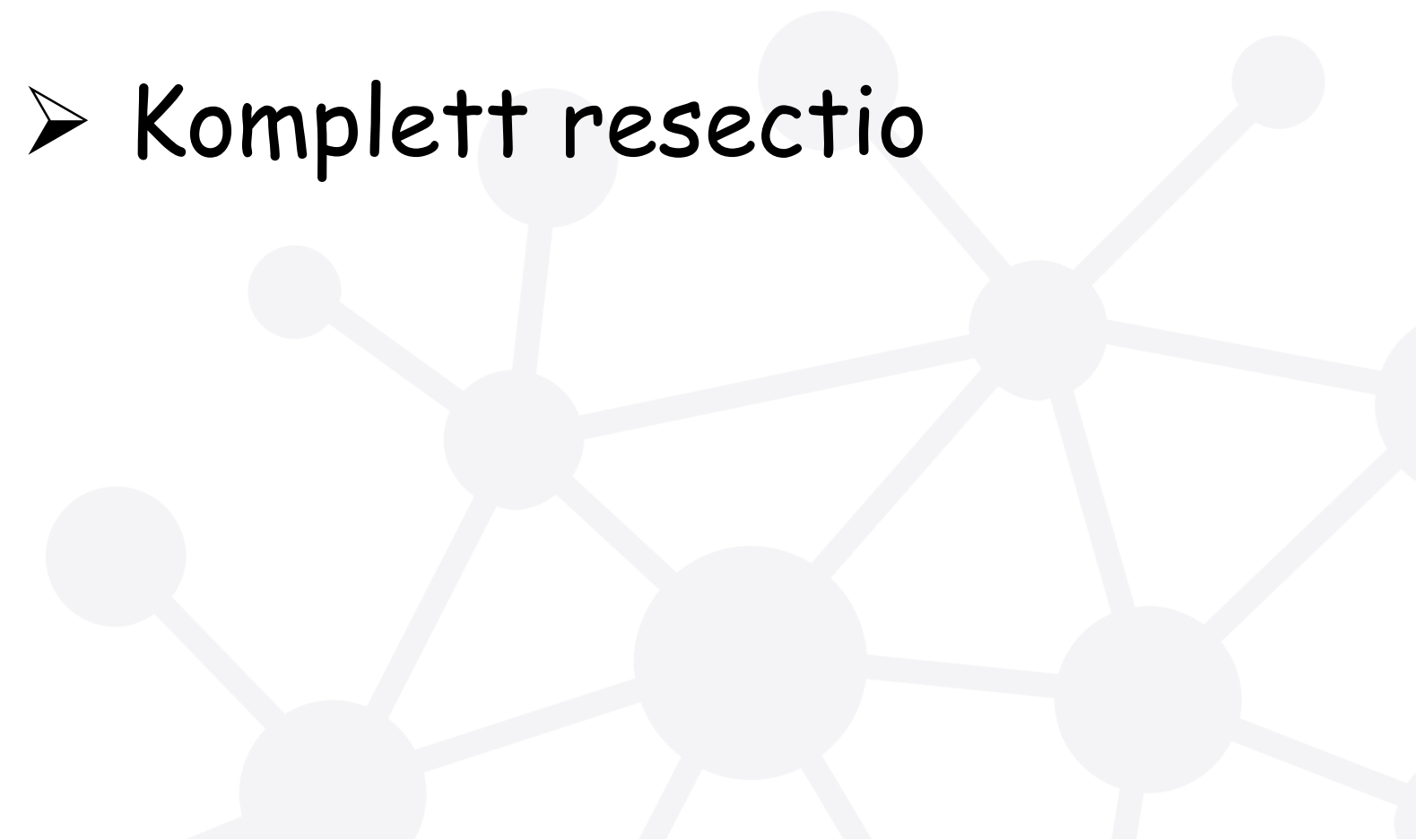Mamelak (2014) Pro: endoscopic endonasal transsphenoidal pituitary surgery is superior to microscope-based transsphenoidal surgery. Endocrine INTÉZET
DOI 10.1007/s12020-014-0294-y

Intrasellaris hypophysis adenoma

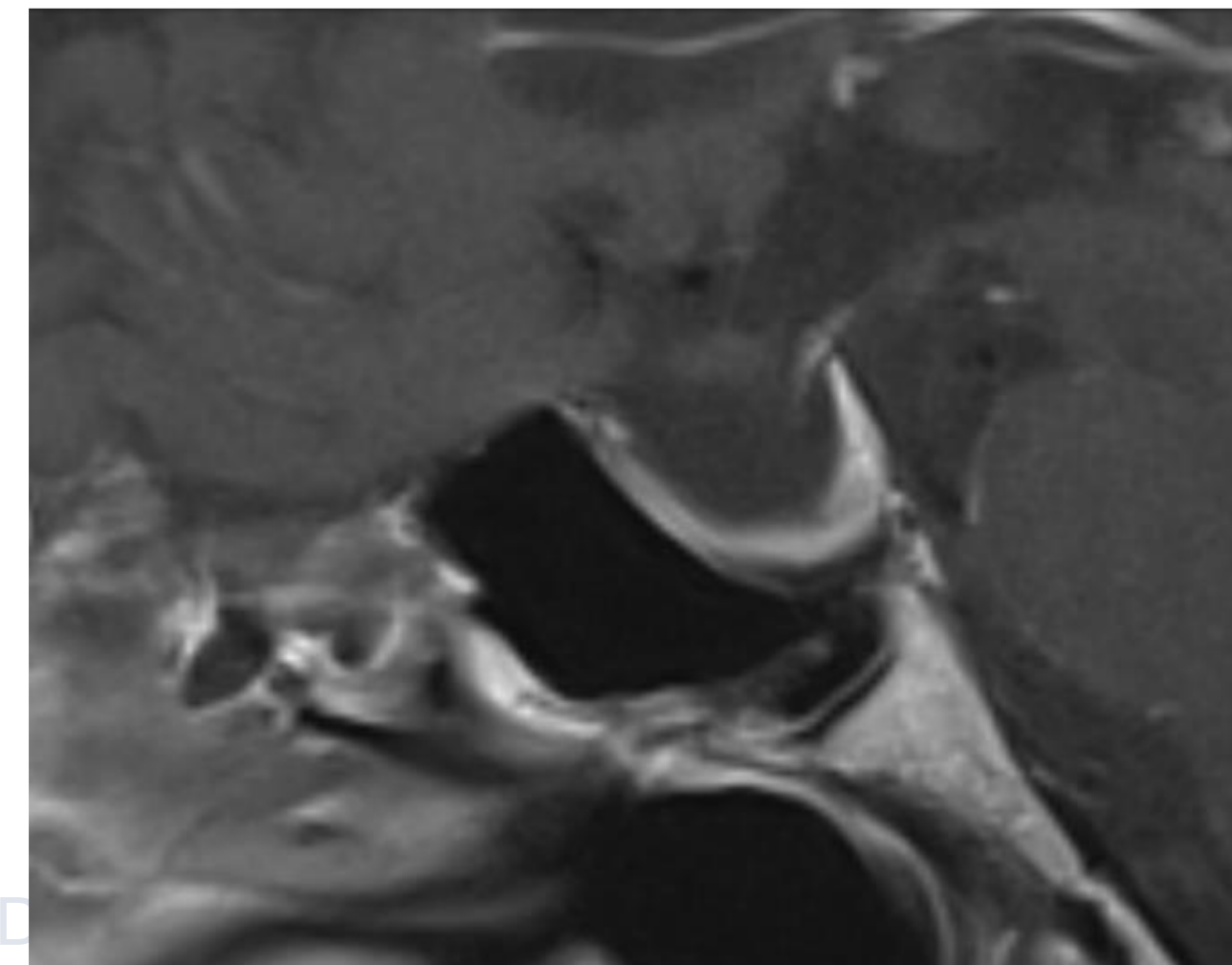
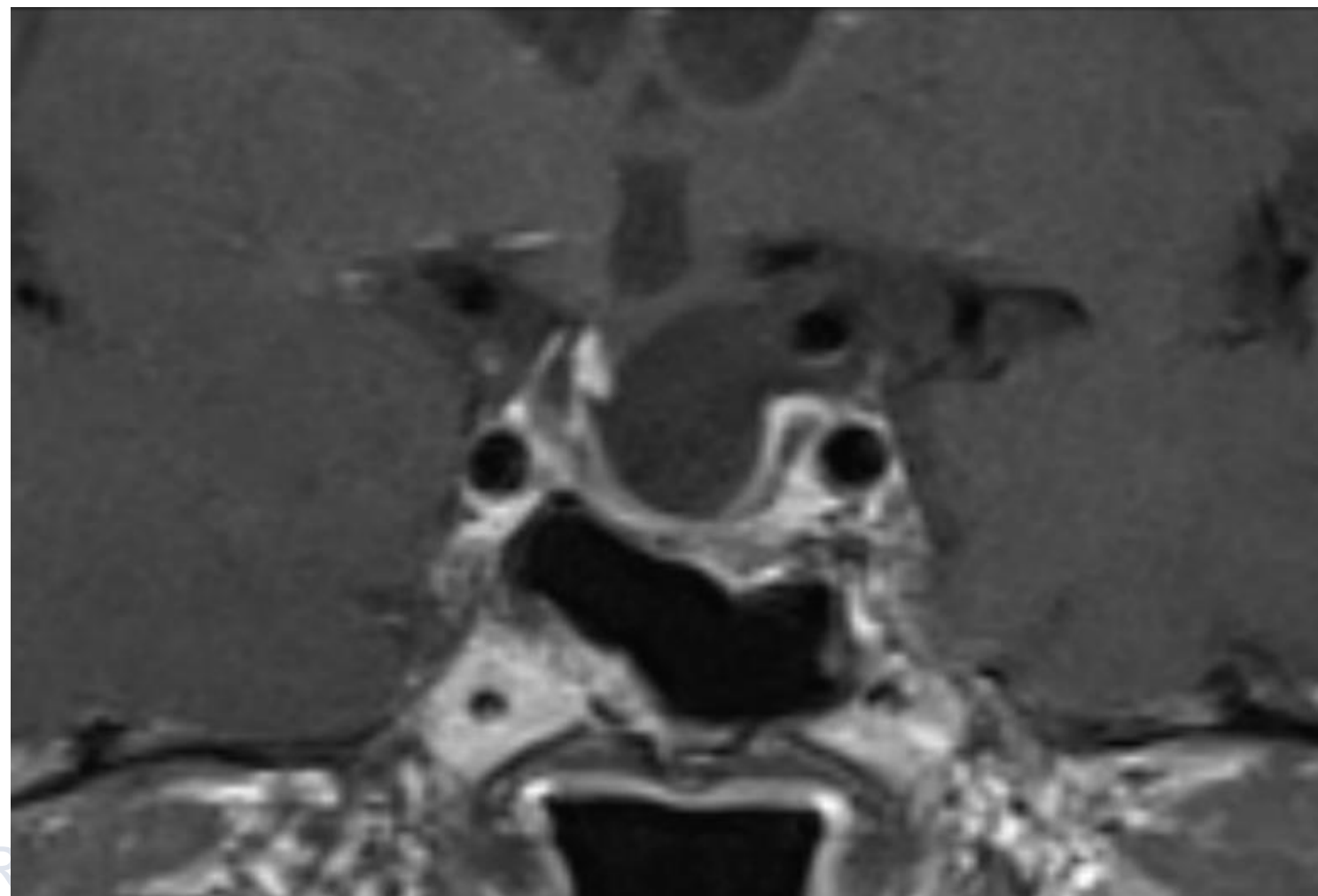
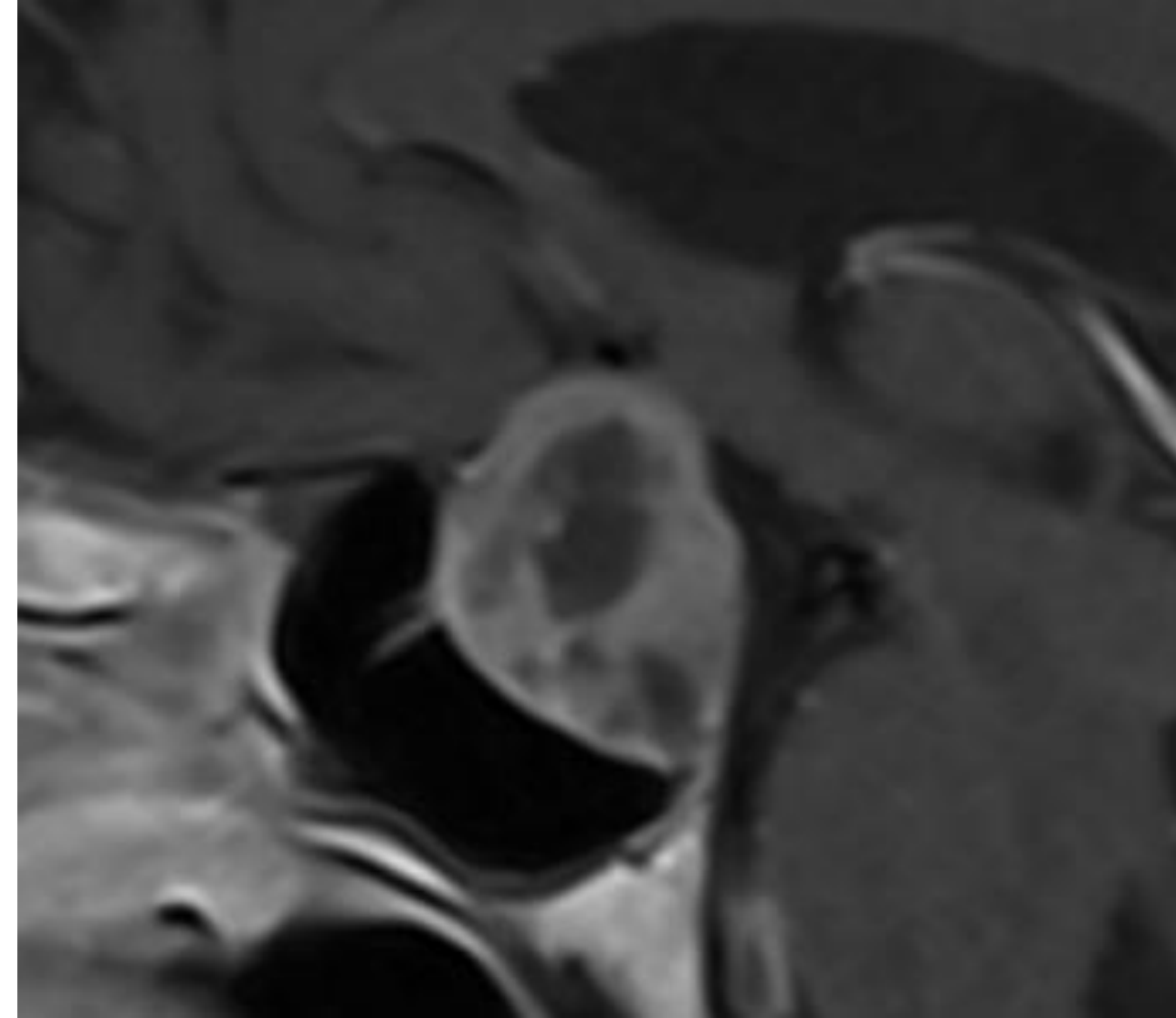
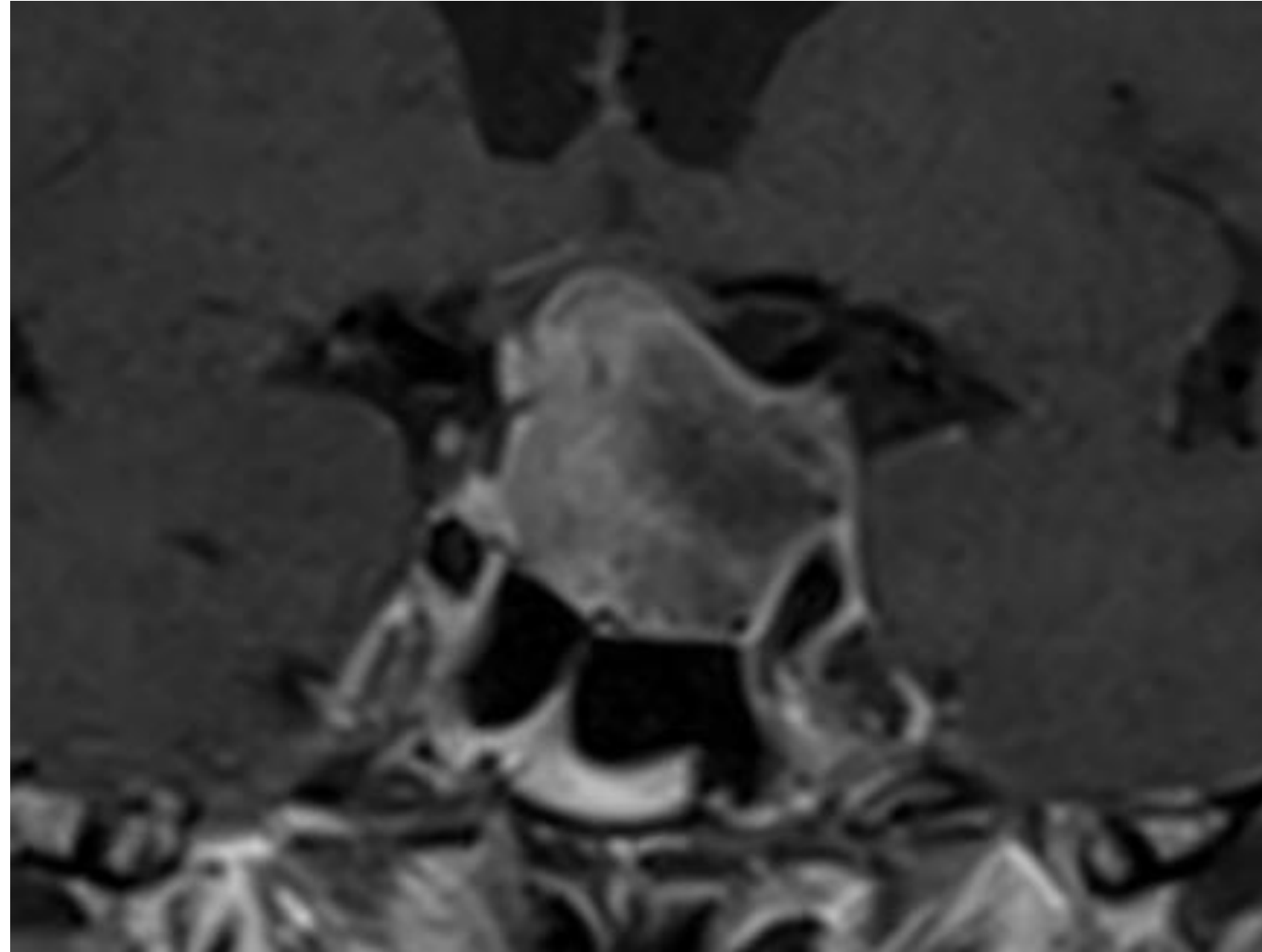


- Hormonalisan aktív: acromegalia, Cushing (micro-, macroadenoma)
- Hormonalisan inaktív: növekvő, opticus-chiasma compressio (intra>suprasellaris)

➤ Komplet resectio

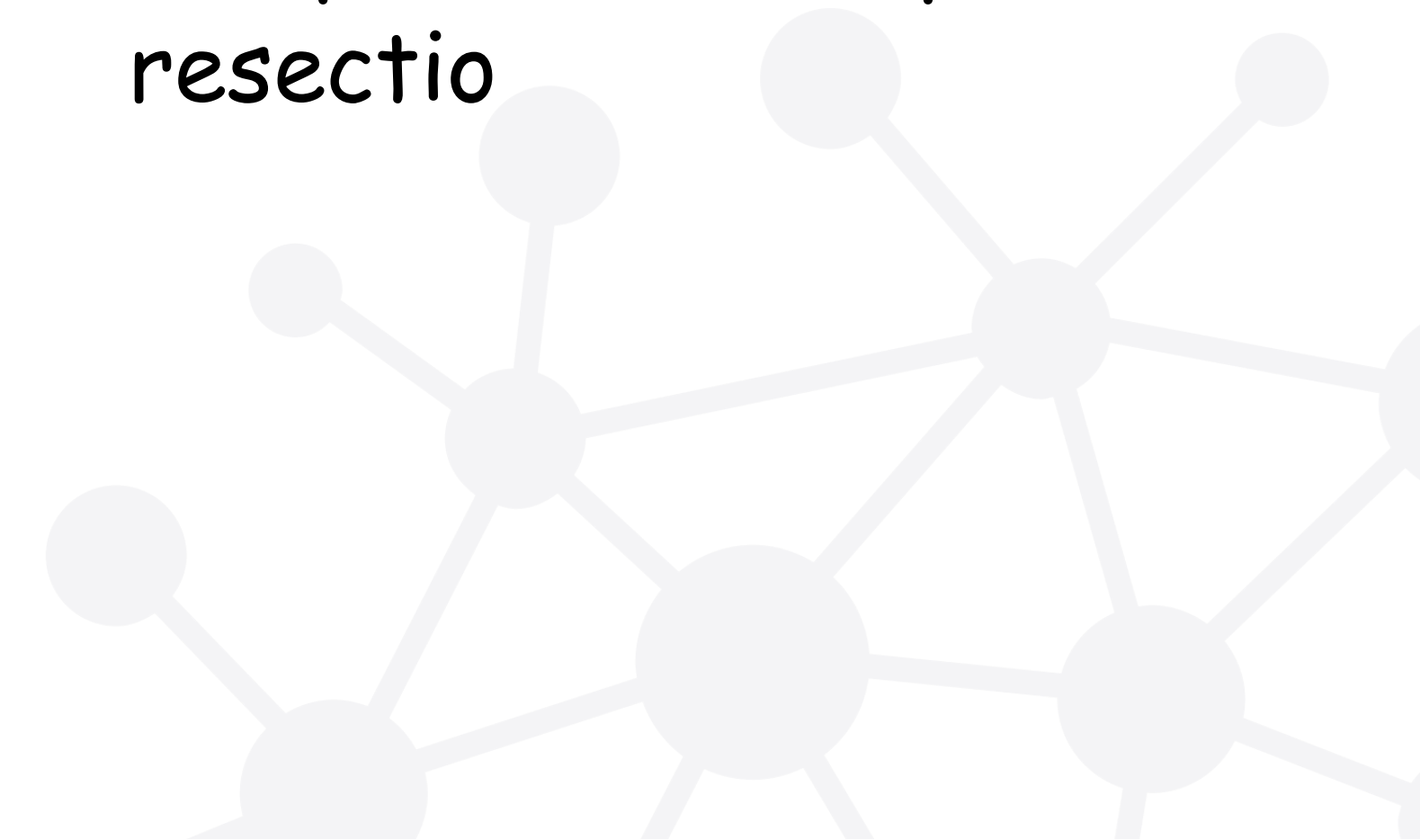

Intra-suprasellaris hypophysis adenoma

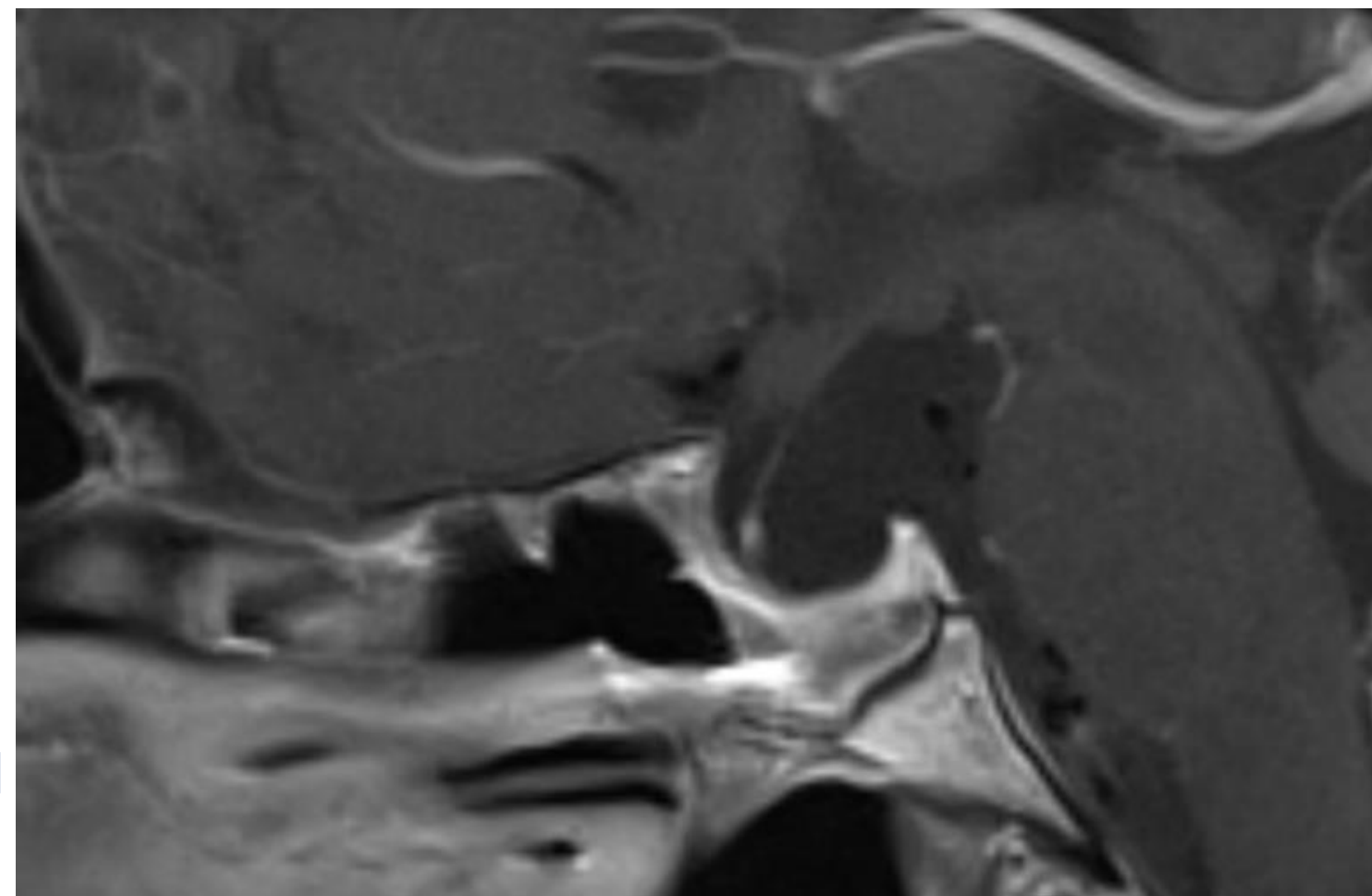
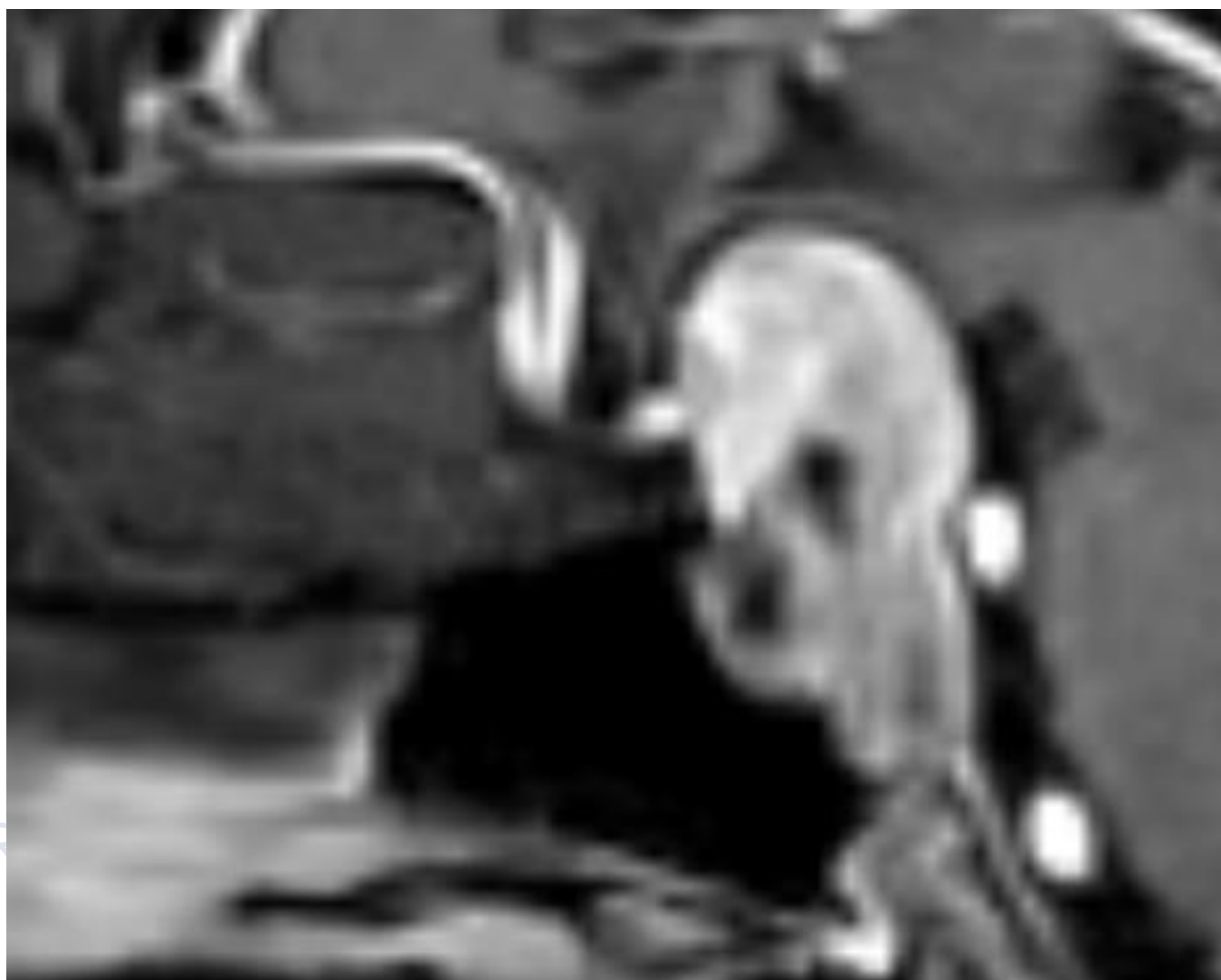
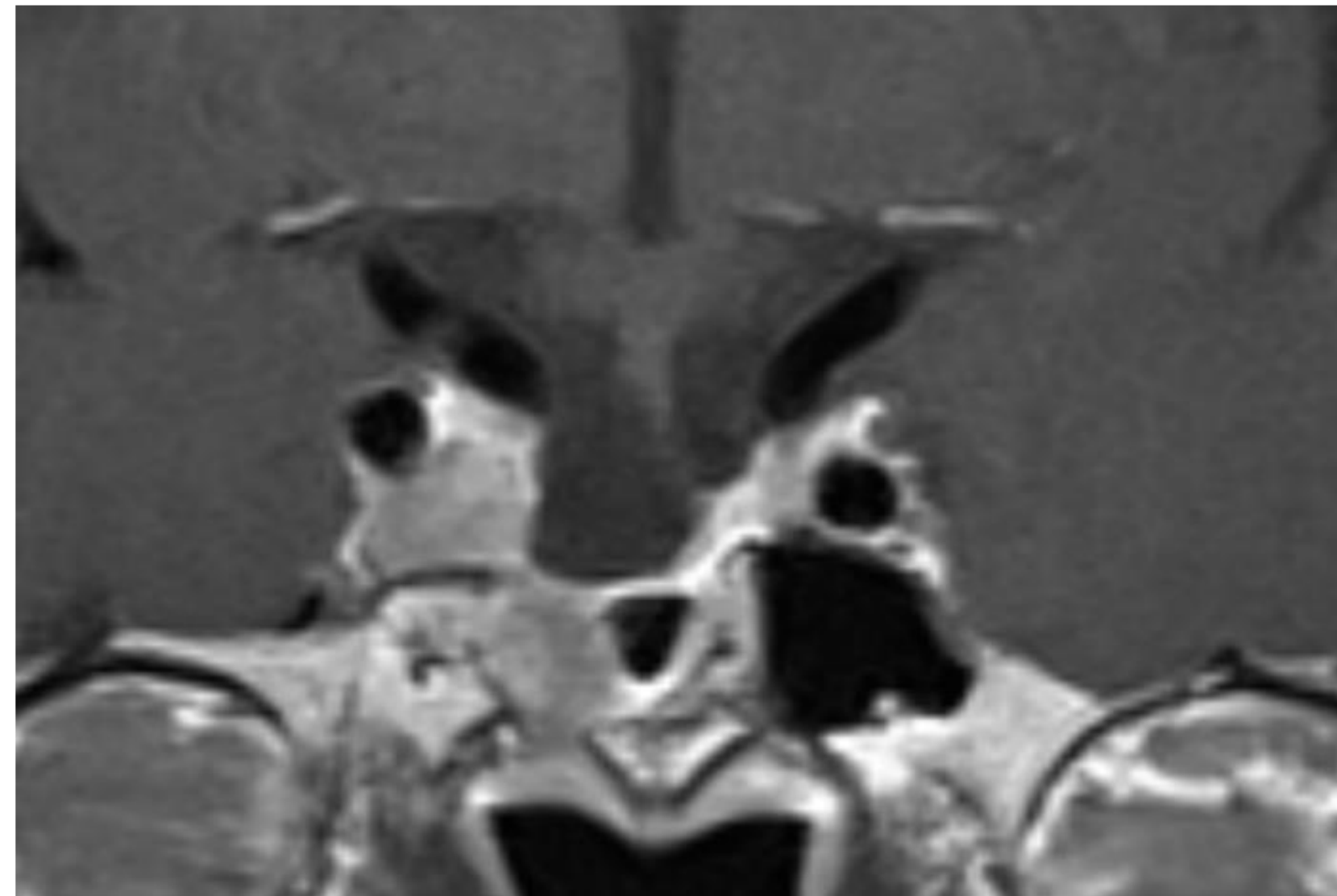
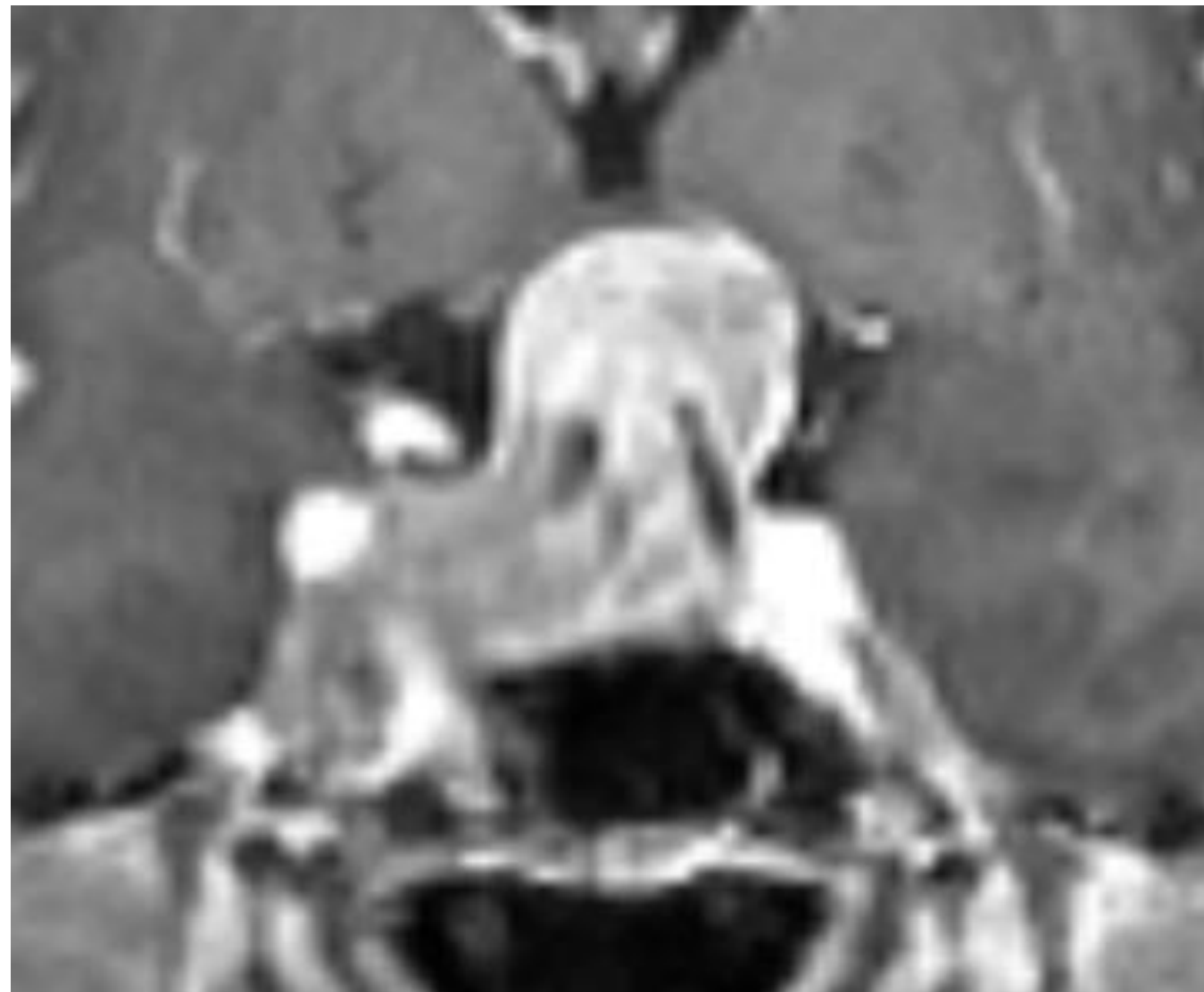


- 78 é ffi
- Visusromlás
- Preoperatív endocrinologia: hypopituiter

➤ Komplet endoscopos resectio



Intra-supra-parasellaris hypophysialis adenoma

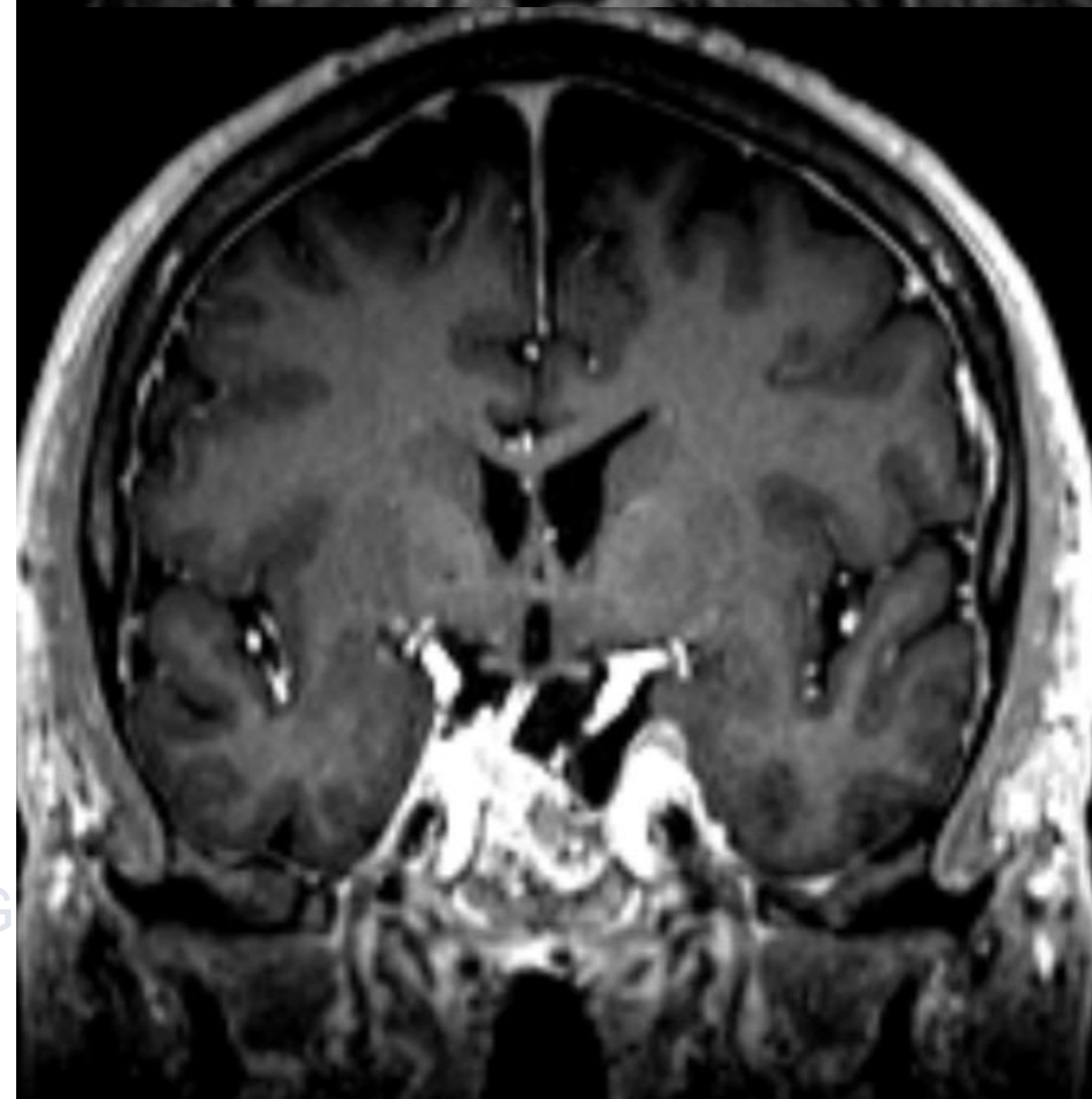
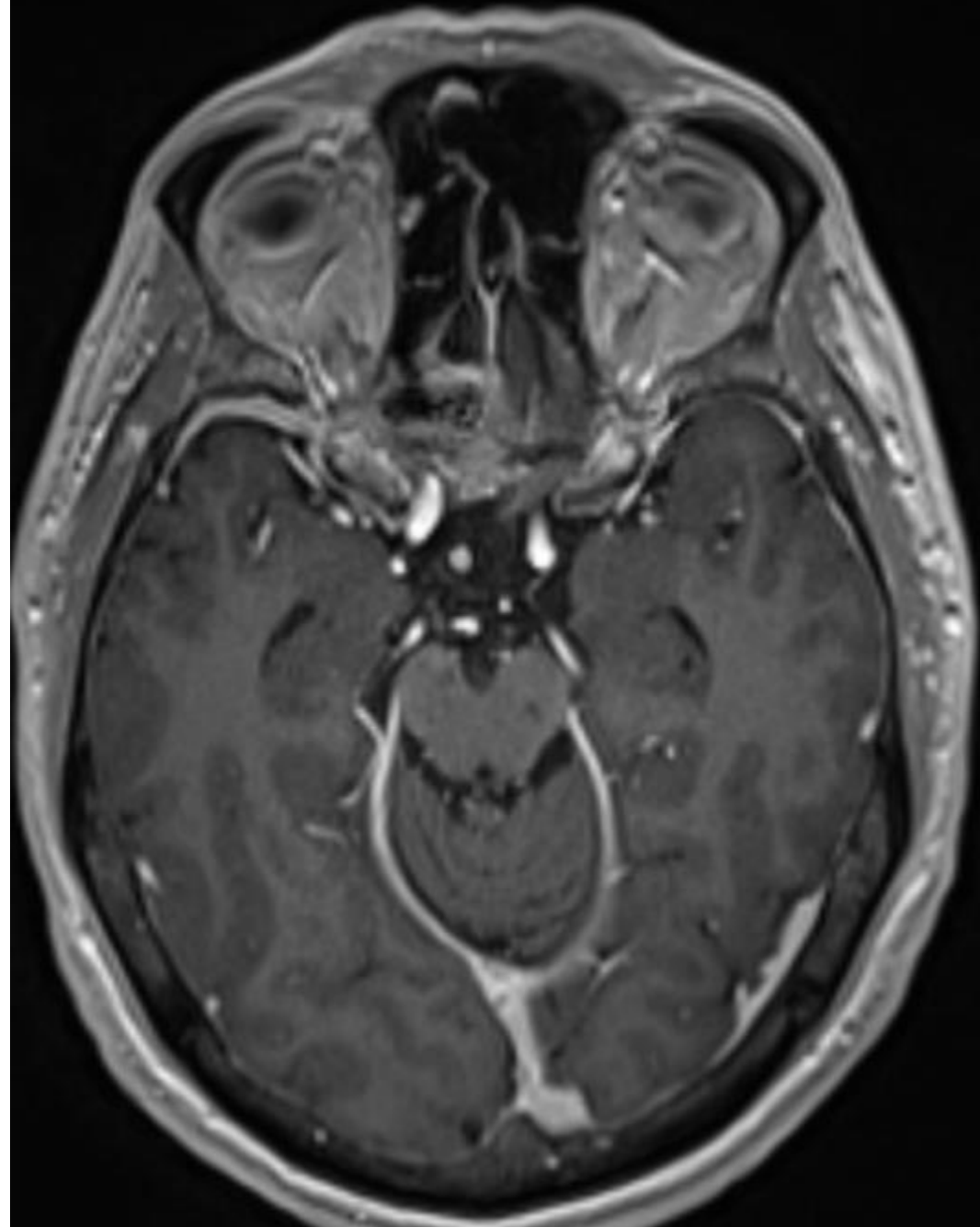
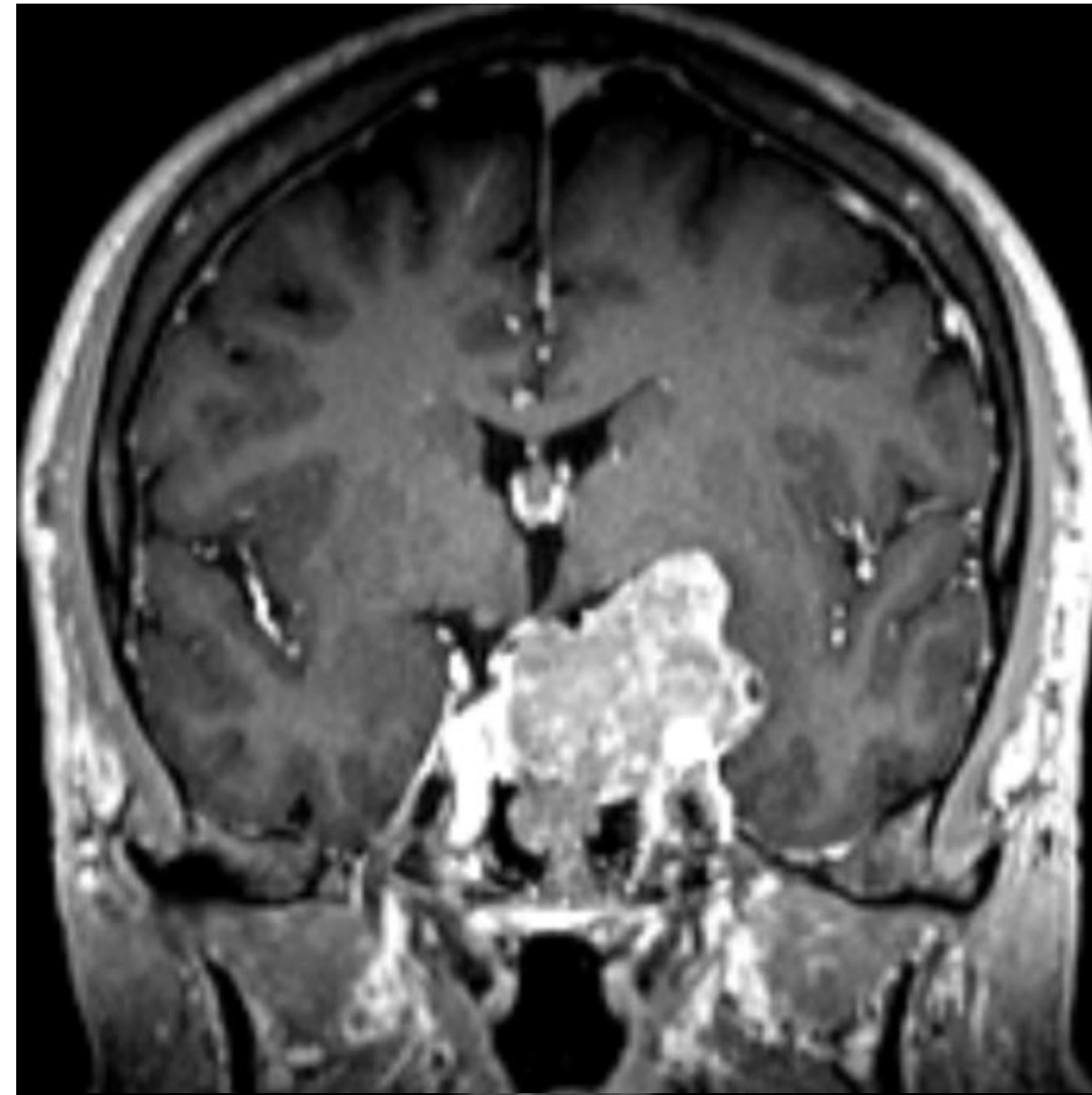
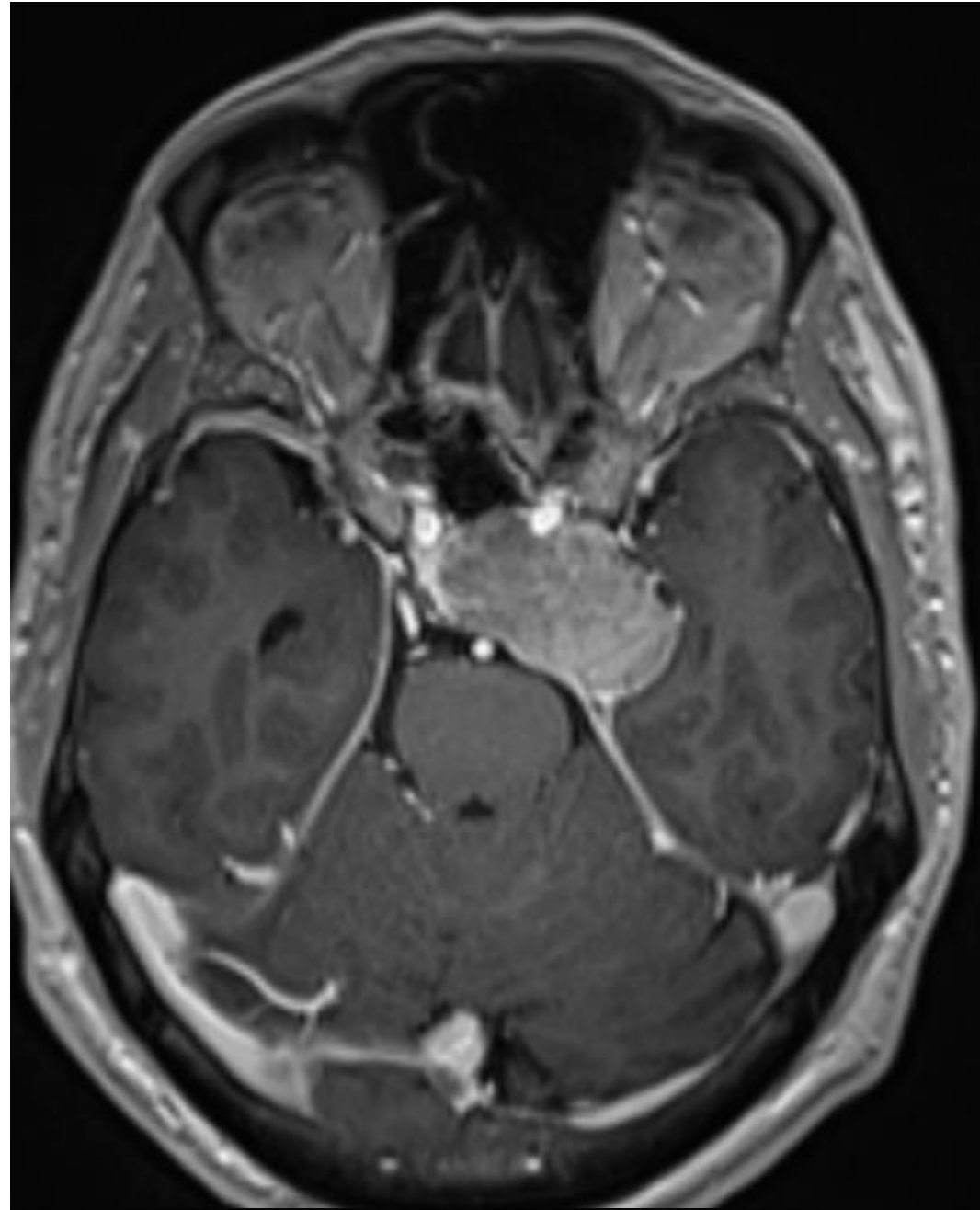


- 68 é nő
- Visusromlás
- Preoperatív endocrinologia: hypopituiter

➤ Subtotalis endoscopos resectio

- Residuum: sugársebészet

Intra-supra-parasellaris hypophysis adenoma - *Transpterygoid*

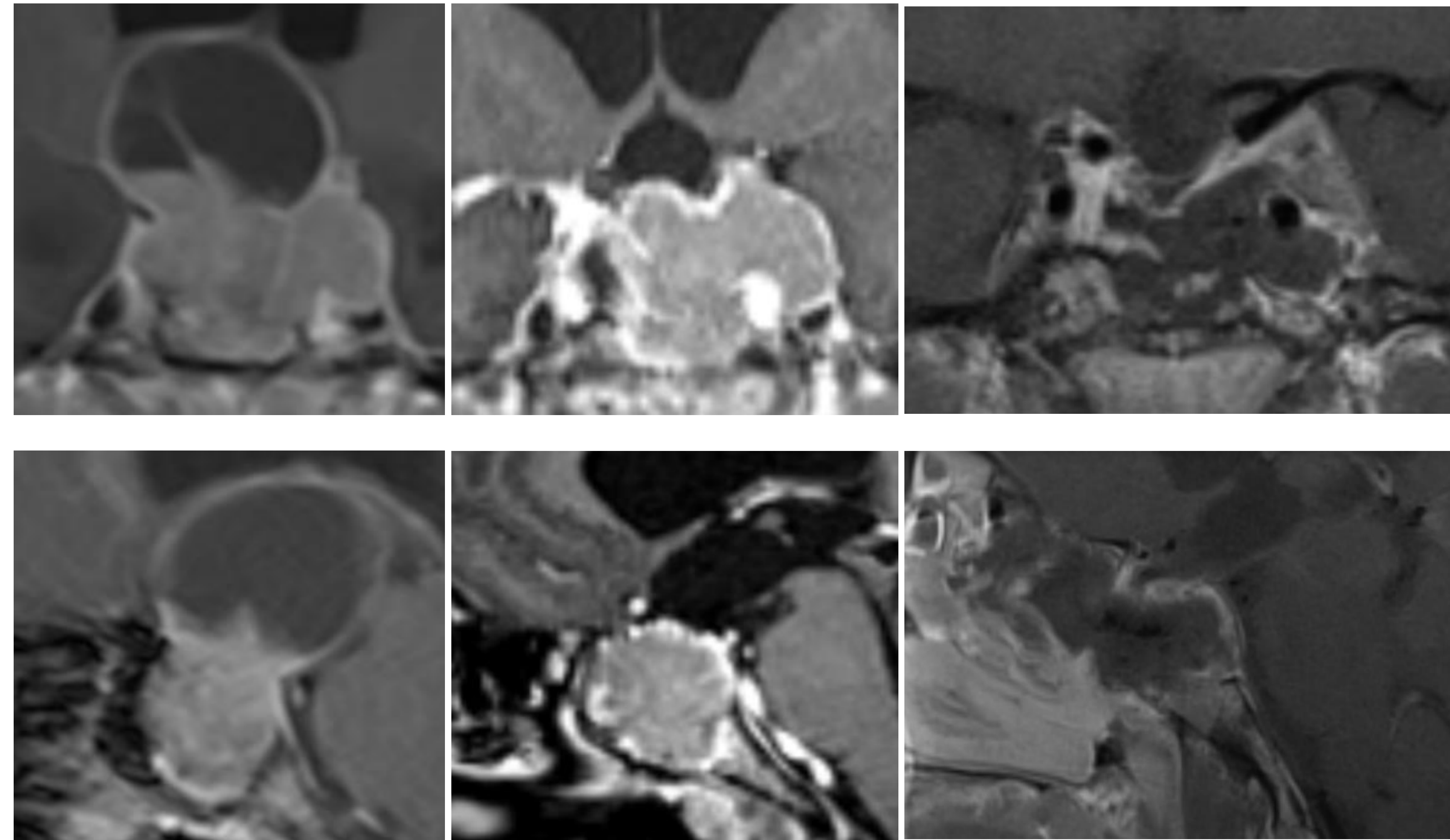


- 54 é ffi
- Melléklet > radiológiai progressio
- Preoperatív endocrinologia: hypopituiter

➤ Subtotalis resectio

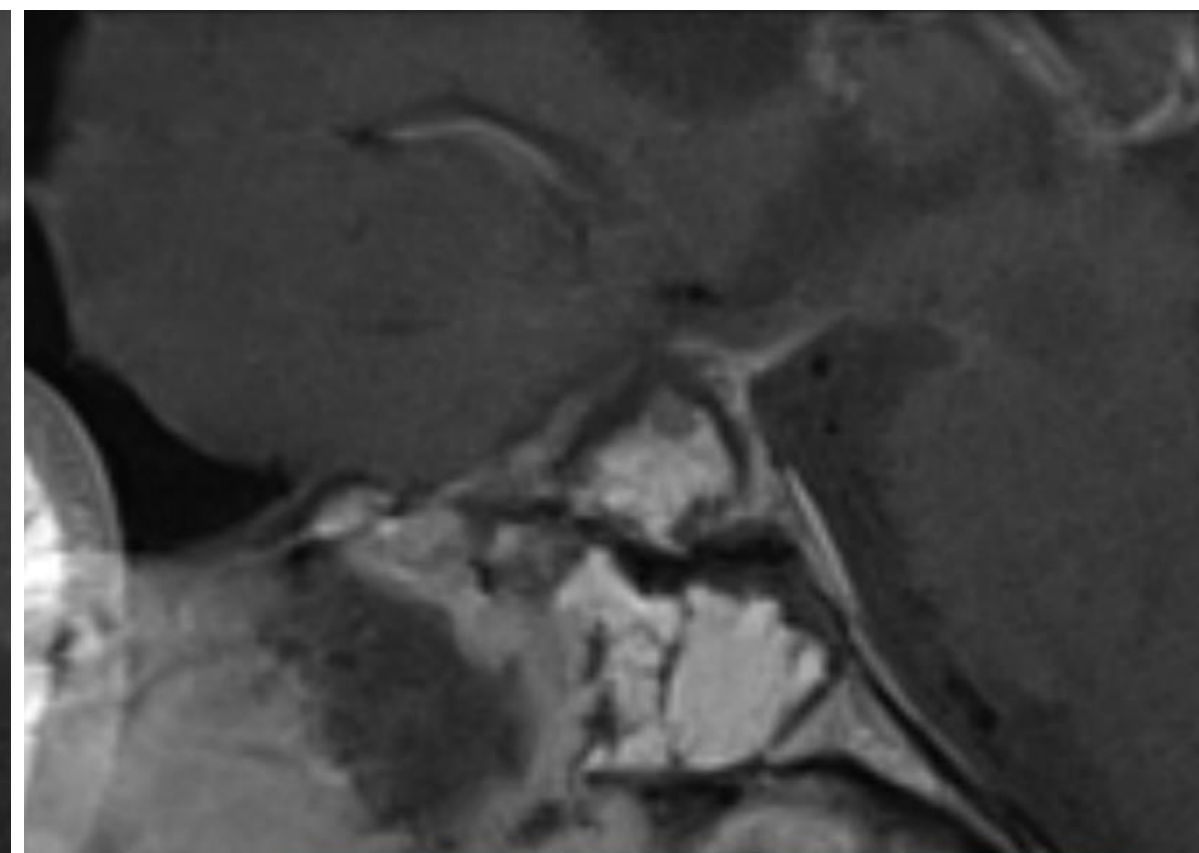
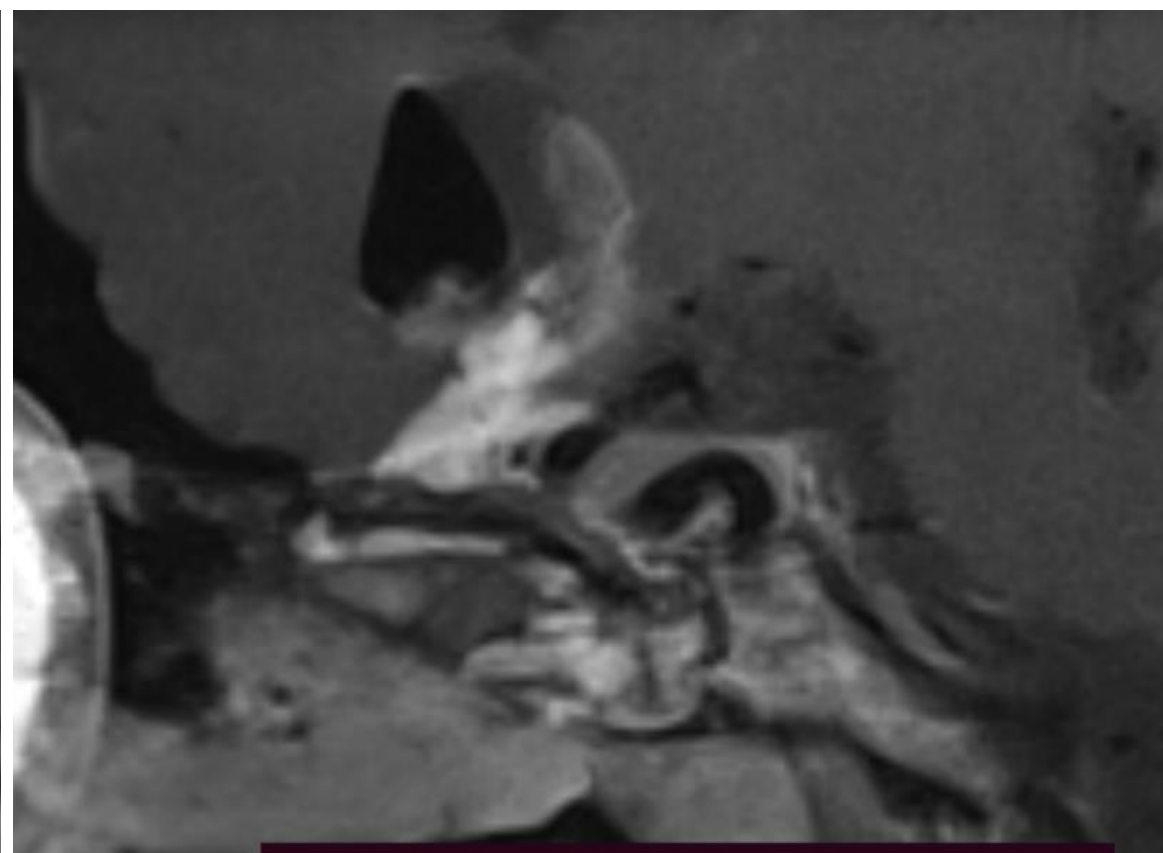

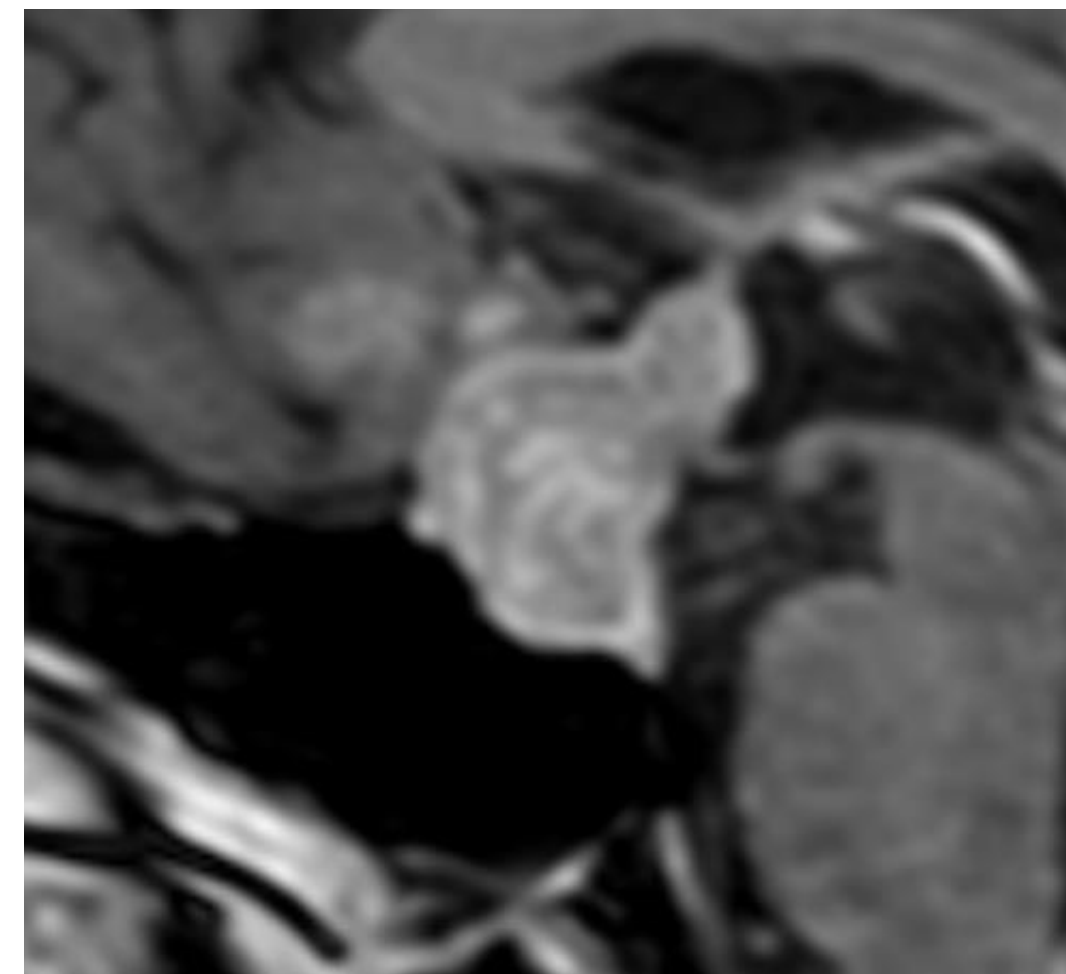
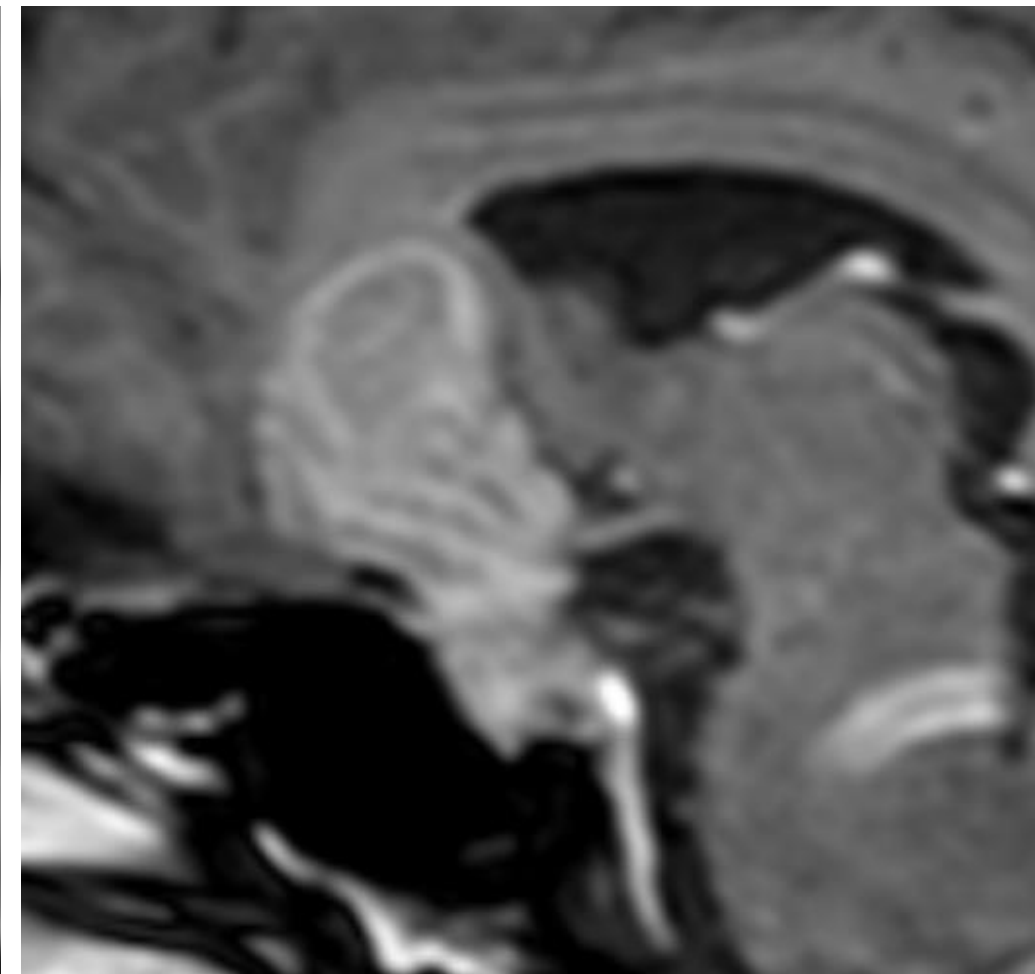
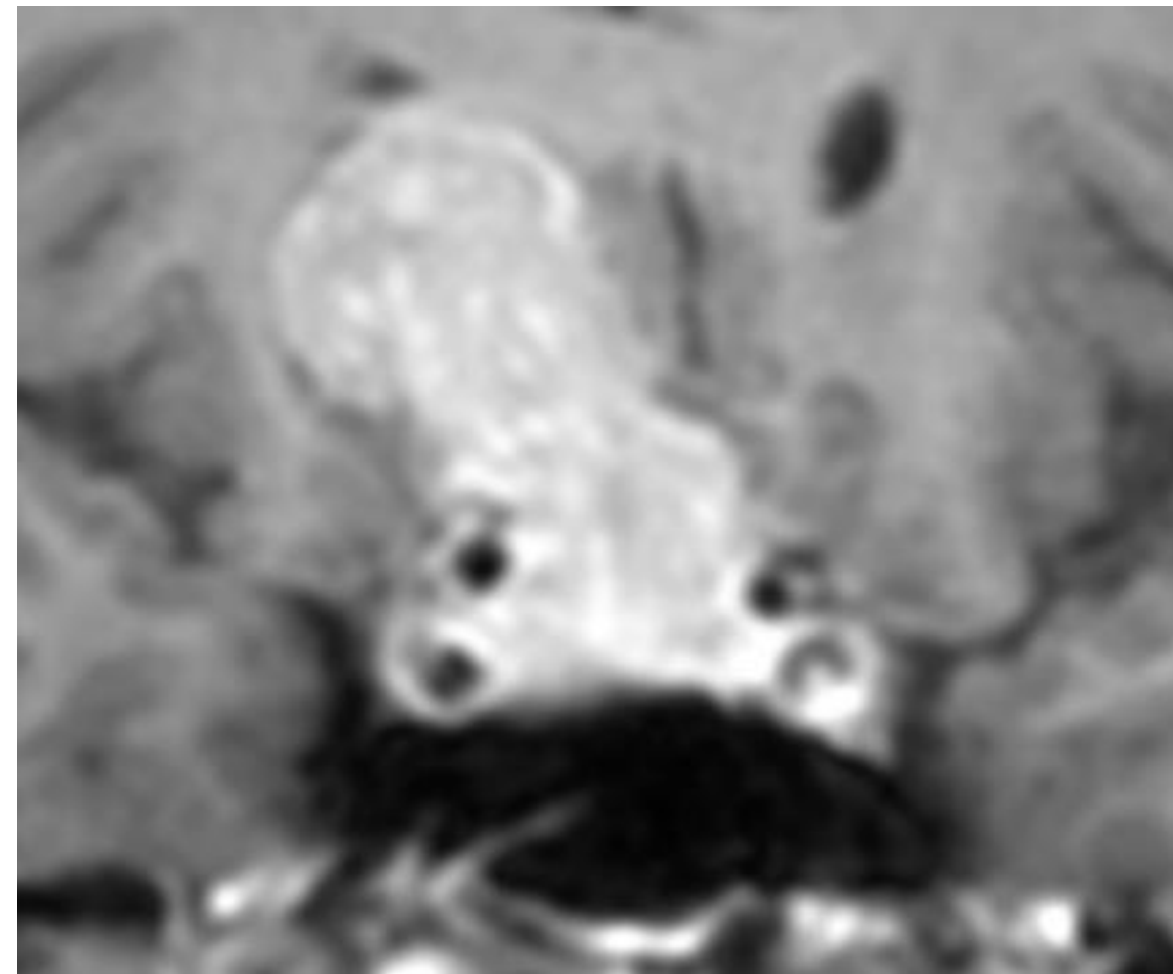
- 2. típusú plurihormonalis adenoma
- Residuum: sugársebészet

Intra-supra-parasellaris hypophysis adenoma - Reziduum: transpterygoid



- 48 é nő
- Látásromlás, tudatzavar
- Postop endocrinologia: Hormont nem termelő adenoma, hypopituiter
- 1. műtét (2021, mikroszkópos transcranialis): Partialis resectio
- Residuum: növekszik
- 2. műtét (2023, endoscopos transnasalis): Subtotalis resectio
- Residuum: sugársebészet

Intra-supra-parasellaris hypophysis adenoma - Transplanum



- 47 é ffi
- Látásromlás, 9 év követés a beteg döntése miatt
- Preoperatív endocrinologia: hypopituiter
- Komplet resectio (56 évesen, rosszabb preoperatív visus mellett)

Kiterjesztett endoszkópos műtétek: jobb láthatóság

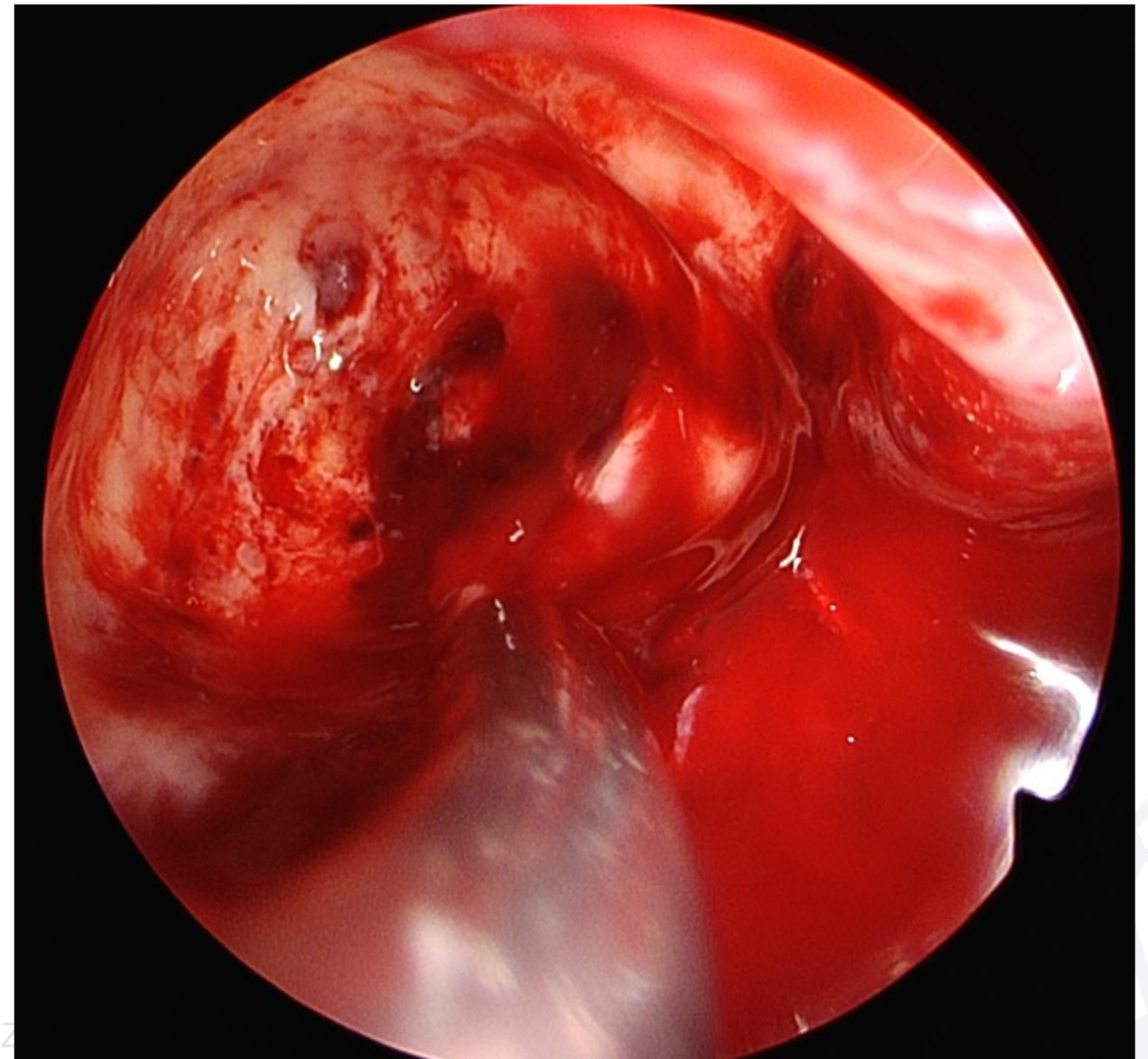
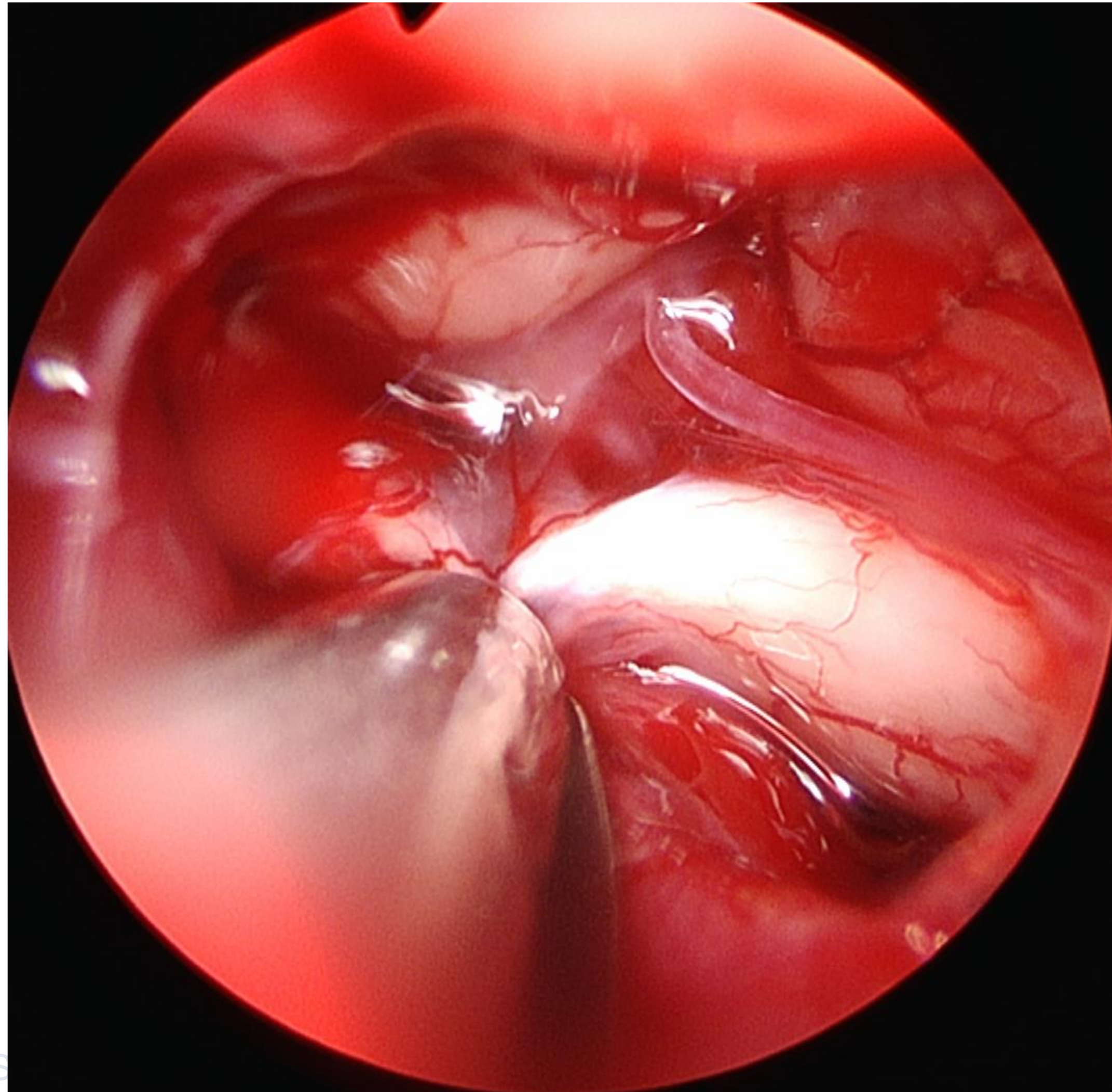


Table 4.4. Histopathology and ICD-O codes* according to WHO classifications of tumours. (* whenever available)

NASAL CAVITY AND PARANASAL SINUSES

- 1) Malignant epithelial tumours
- 2) Neuroendocrine tumours
- 3) Benign epithelial tumours
- 4) Soft tissue tumours
- 5) Tumours of bone and cartilage
- 6) Haematolymphoid tumours
- 7) Neuroectodermal tumours
- 8) Germ cell tumours
- 9) Secondary tumours

1) Malignant epithelial tumours

- Lymphoepithelial carcinoma ICD-O 8082/3
- Sinonasal undifferentiated carcinoma ICD-O 8020/3
- Neuroendocrine tumours
- Squamous cell carcinoma
 - Keratinizing squamous cell carcinoma ICD-O 8070/3
 - Non-keratinizing (cylindrical cell, transitional) carcinoma currently no separate ICD-O
 - Verrucous carcinoma ICD-O 8051/3
 - Papillary squamous cell carcinoma ICD-O 8052/3
 - Basaloid squamous cell carcinoma ICD-O 8083/3
 - Spindle cell carcinoma ICD-O 8074/3
 - Adenosquamous carcinoma ICD-O 8560/3
 - Acantholytic squamous cell carcinoma ICD-O 8075/3

Adenocarcinoma

- Intestinal-type adenocarcinomas ICD-O 8144/3 (Subclassification according to Barnes 1986)
 - Papillary - type
 - Colonic - type
 - Solid - type
 - Mucinous - type
 - Mixed

Sinonasal non-intestinal-type adenocarcinomas ICD-O 8140/3

- Low-grade adenocarcinoma
- High-grade adenocarcinoma

Salivary gland-type carcinoma

- Adenoid cystic carcinoma ICD-O 8200/3
- Acinic cell carcinoma ICD-O 8550/3
- Mucoepidermoid carcinoma ICD-O 8430/3
- Epithelial-myoeplithelial carcinoma ICD-O 8562/3
- Clear cell carcinoma ICD-O 8310/3

2) Neuroendocrine tumours

- Typical carcinoid ICD-O 8240/3
- Atypical carcinoid ICD-O 8249/3
- Small cell carcinoma, neuroendocrine type ICD-O 8041/3

3) Benign epithelial tumours

Sinonasal (Schneiderian) papillomas

- Inverted papilloma (Schneiderian papilloma, inverted type) ICD-O 8121/1
- Oncocytic papilloma (Schneiderian papilloma, oncocytic type) ICD-O 8121/1
- Exophytic papilloma (Schneiderian papilloma, exophytic type, everted type) ICD-O 8121/1

Respiratory epithelial adenomatoid hamartoma; no ICD-O

Salivary gland-type adenomas (Main types)

- Pleomorphic adenoma ICD-O 8940/0
- Myoepithelioma ICD-O 8982/0
- Oncocytoma ICD-O 8290/0

4) Malignant soft tissue tumours

- Fibrosarcoma ICD-O 8810/3
- Undifferentiated high grade pleomorphic Sarcoma („MFH“) ICD-O 8830/3
- Leiomyosarcoma ICD-O 8890/3
- Embryonal rhabdomyosarcoma ICD-O 8910/3
- Alveolar rhabdomyosarcoma ICD-O 8920/3
- Angiosarcoma ICD-O 9120/3
- Malignant peripheral nerve sheath tumour ICD-O 9540/3

5) Borderline and low malignant potential tumours of soft tissue

- Desmoid-type fibromatosis ICD-O 8821/1
- Inflammatory myofibroblastic tumour ICD-O 8825/1
- Glomangiopericytoma (Sinonasal-type haemangiopericytoma) ICD-O 9150/1
- Extrapleural solitary fibrous tumour ICD-O 8815/1

6) Benign soft tissue tumours

- Myxoma ICD-O 8840/0
- Leiomyoma ICD-O 8890/0
- Haemangioma ICD-O 9120/0
- Schwannoma ICD-O 9560/0
- Neurofibroma ICD-O 9540/0
- Meningioma ICD-O 9530/0

7) Malignant tumours of bone and cartilage

- Chondrosarcoma ICD-O 9220/3
- Mesenchymal chondrosarcoma ICD-O 9240/3
- Osteosarcoma ICD-O 9180/3
- Chordoma ICD-O 9370/3

8) Benign tumours of bone and cartilage

- Fibrous dysplasia; no ICD-O Code
- Osteoma ICD-O 9180
- Osteoid osteoma ICD-O 9191/0
- Osteoblastoma ICD-O 9200/0

- Osteochondroma (exostosis) ICD-O 9210/0
- Chondroma ICD-O 9220/0
- Chondroblastoma ICD-O 9230/0
- Chondromyxoid fibroma ICD-O 9241/0
- Giant cell lesion ICD-O None
- Giant cell tumour of bone ICD-O 9250/1
- Ameloblastoma ICD-O 9310/0
- Nasal chondromesenchymal hamartoma; no ICD-O Code

9) Haematolymphoid tumours

- Extranodal NK/T cell lymphoma ICD-O 9719/3
- Diffuse large B-cell lymphoma ICD-O 9680/3
- Extramedullary plasmacytoma ICD-O 9734/3
- Extramedullary myeloid sarcoma ICD-O 9930/3
- Histiocytic sarcoma ICD-O 9755/3
- Langerhans cell histiocytosis ICD-O 9751/1
- Juvenile xanthogranuloma; no ICD-O Code
- Rosai - Dorfman disease (Sinus histiocytosis with massive lymphadenopathy); no ICD-O Code

10) Neuroectodermal tumours

- Ewing sarcoma ICD-O 9260/3
- Primitive neuroectodermal tumour (PNET) ICD-O 9364/3
- Olfactory neuroblastoma (esthesioneuroblastoma) ICD-O 9522/3
- Grading (Grade 1 - 4) according to Hyams 1988 based on:
 - Architecture
 - Pleomorphism
 - Neurofibrillary matrix
 - Rosettes
 - Mitosis
 - Necrosis
- Glands
 - Calcification
- Melanotic neuroectodermal tumour of infancy ICD-O 9363/0
- Mucosal malignant melanoma ICD-O 8720/3
- Heterotopic central nervous system tissue(nasal glioma) ICD-O None

11) Germ cell tumours

- Immature teratoma ICD-O 9080/3
- Teratoma with malignant transformation ICD-O 9084/3
- Sinonasal yolk sac tumour (endodermal sinus tumour) ICD-O 9071/3
- Sinonasal teratocarcinosarcoma ICD-O None
- Mature teratoma ICD-O 9080/0
- Dermoid cyst ICD-O 9084/0

11) Germ cell tumours

- Immature teratoma ICD-O 9080/3
- Teratoma with malignant transformation ICD-O 9084/3
- Sinonasal yolk sac tumour (endodermal sinus tumour) ICD-O 9071/3
- Sinonasal teratocarcinosarcoma ICD-O None
- Mature teratoma ICD-O 9080/0
- Dermoid cyst ICD-O 9084/0

12) Secondary tumours (Mainly metastases from primary tumours of...)

- Kidney
- Lung
- Breast
- Thyroid
- Prostate
- Others

NASOPHARYNX

- 1) Malignant epithelial tumours
- 2) Benign epithelial tumours
- 3) Soft tissue neoplasms

Nasopharyngeal angiofibroma* ICD-O 9160/0

*Although juvenile angiofibroma is known to arise from the posterior nasal cavity and not the nasopharynx, the WHO classification includes this lesion here

- 4) Haematolymphoid tumours
- 5) Tumours of bone and cartilage
- 6) Secondary tumours

TUMOURS OF THE SELLA REGION

- 1) Tumours of the pituitary gland proper
- 2) Craniopharyngioma
- 3) Chordoma
- 4) Meningioma
- 5) Secondary tumours

1) Tumours of the pituitary gland proper

Pituitary adenoma

- Typical adenoma ICD-O 8272/0
- Atypical adenoma ICD-O 8272/1
 - Growth hormone producing adenoma ICD-O 8272
 - Prolactin producing adenoma ICD-O 8271/0
 - TSH producing adenoma ICD-O 8272/0
 - ACTH producing adenoma ICD-O 8272/0
 - Gonadotropin producing adenoma ICD-O 8272/0
 - Null cell adenoma ICD-O 8272
 - Plurihormonal adenoma ICD-O 8272/0
- Pituitary carcinoma ICD-O 8272/3
- Gangliocytoma ICD-O 9492/0
- Granular cell tumour ICD-O 9580/0

- Pituitary carcinoma
- Gangliocytoma
- Granular cell tumour

2) Craniopharyngioma

3) Chordoma

4) Meningioma

- 5) Secondary tumours (Metastases from primary tumours from...)
 - Breast
 - Lung
 - Gastrointestinal tract

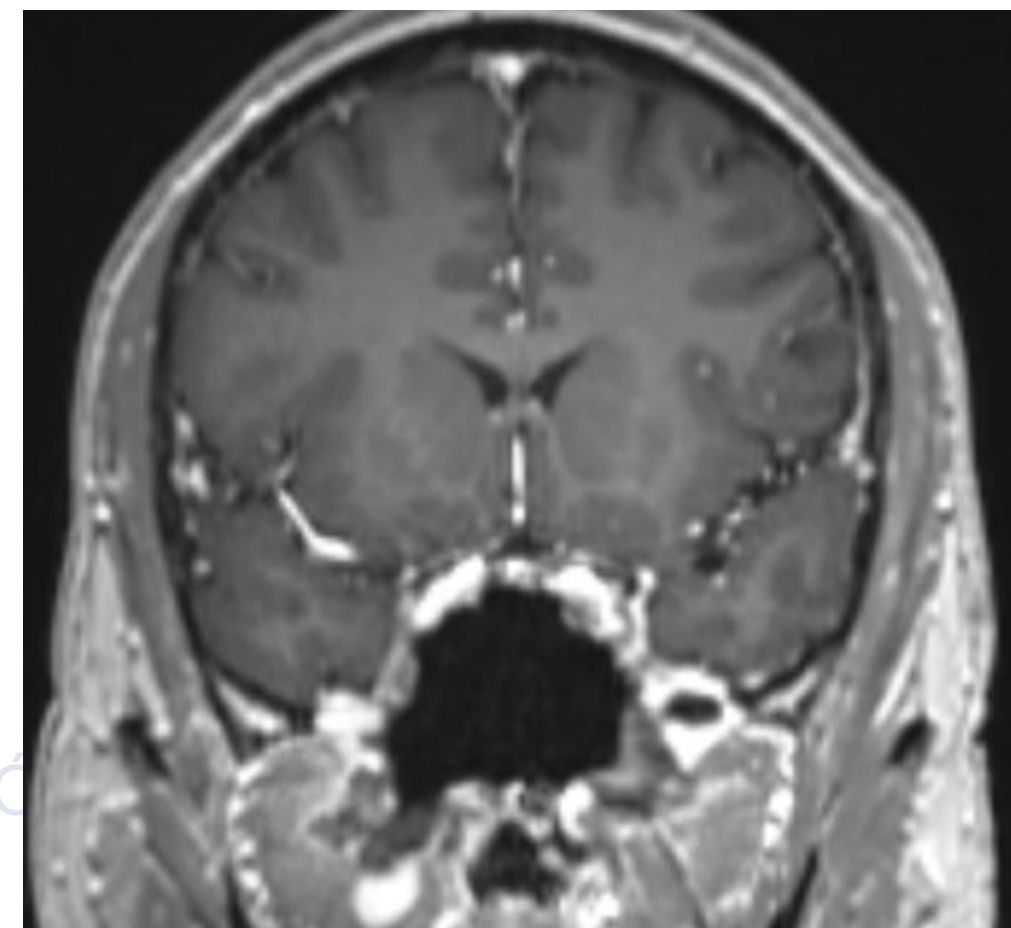
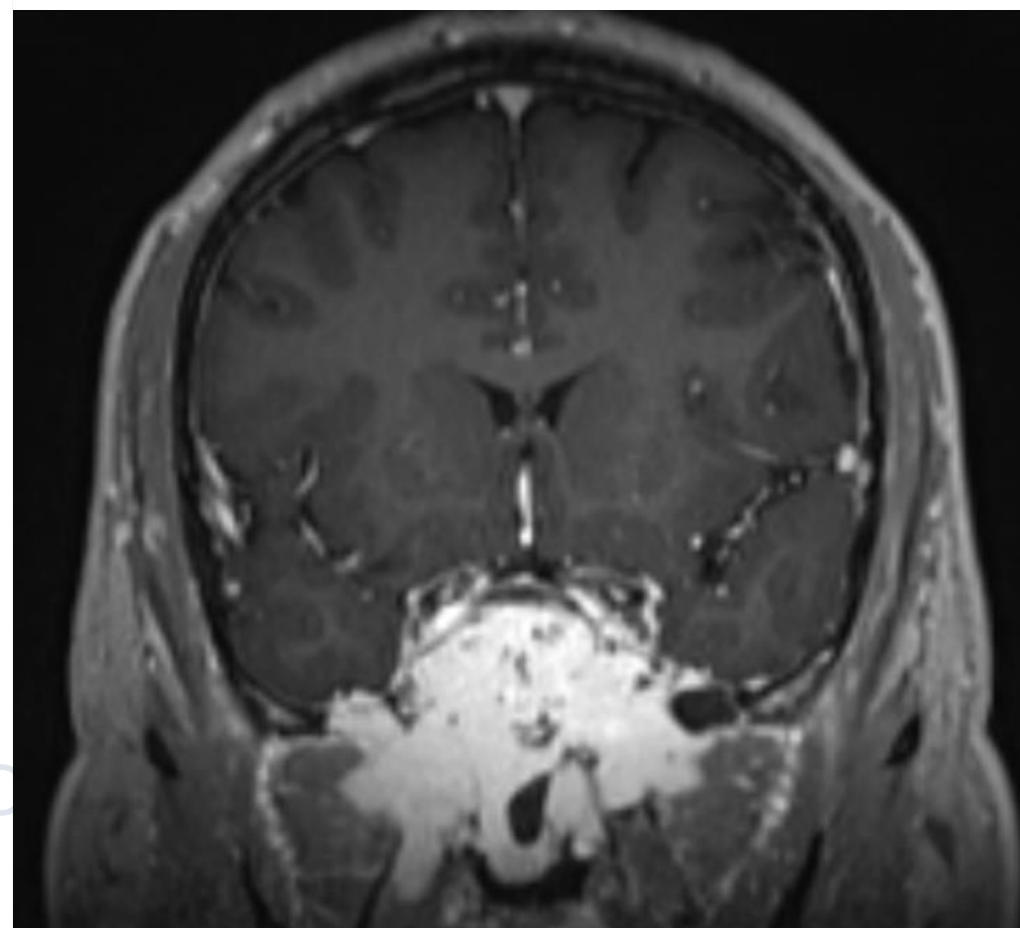
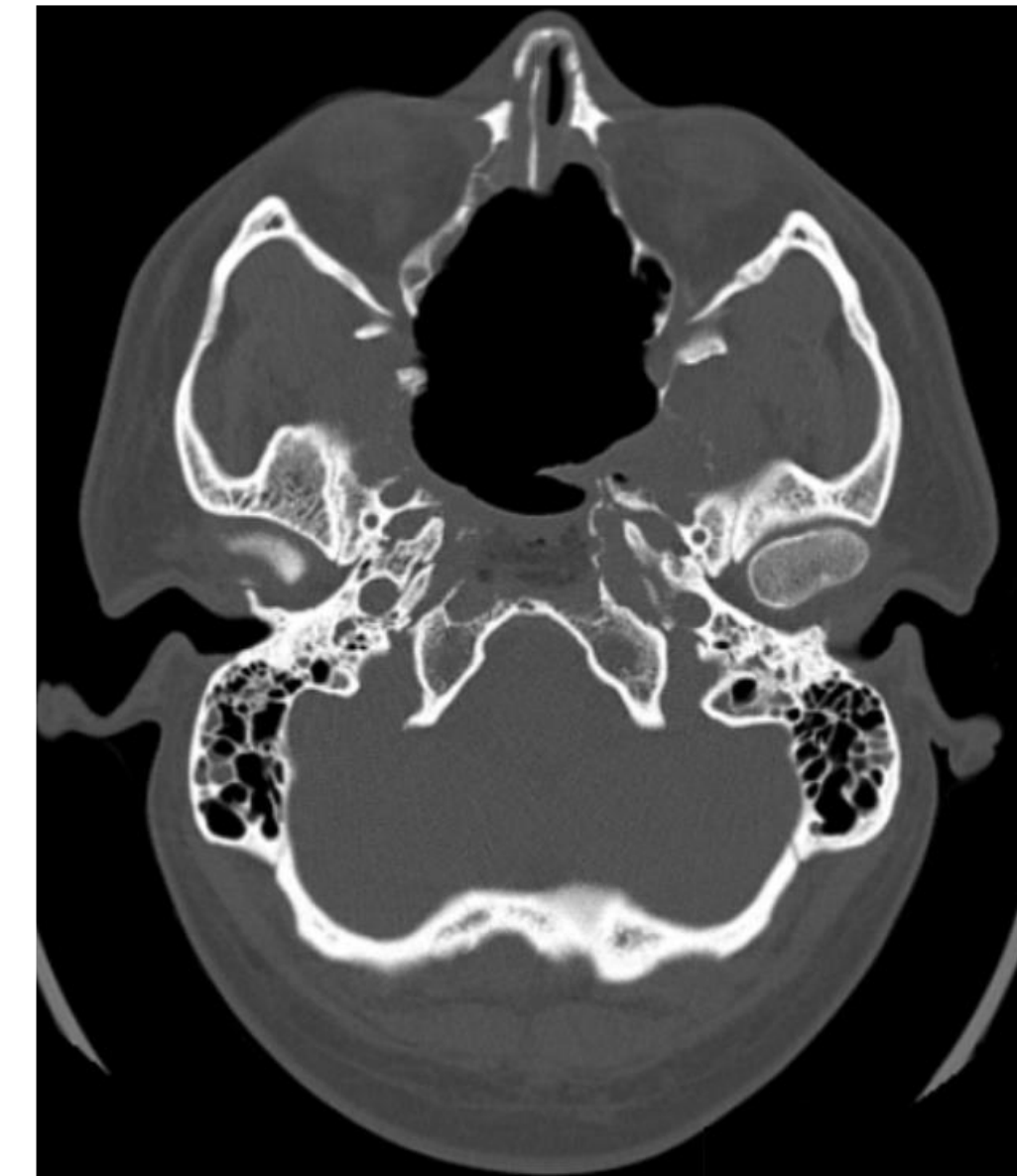
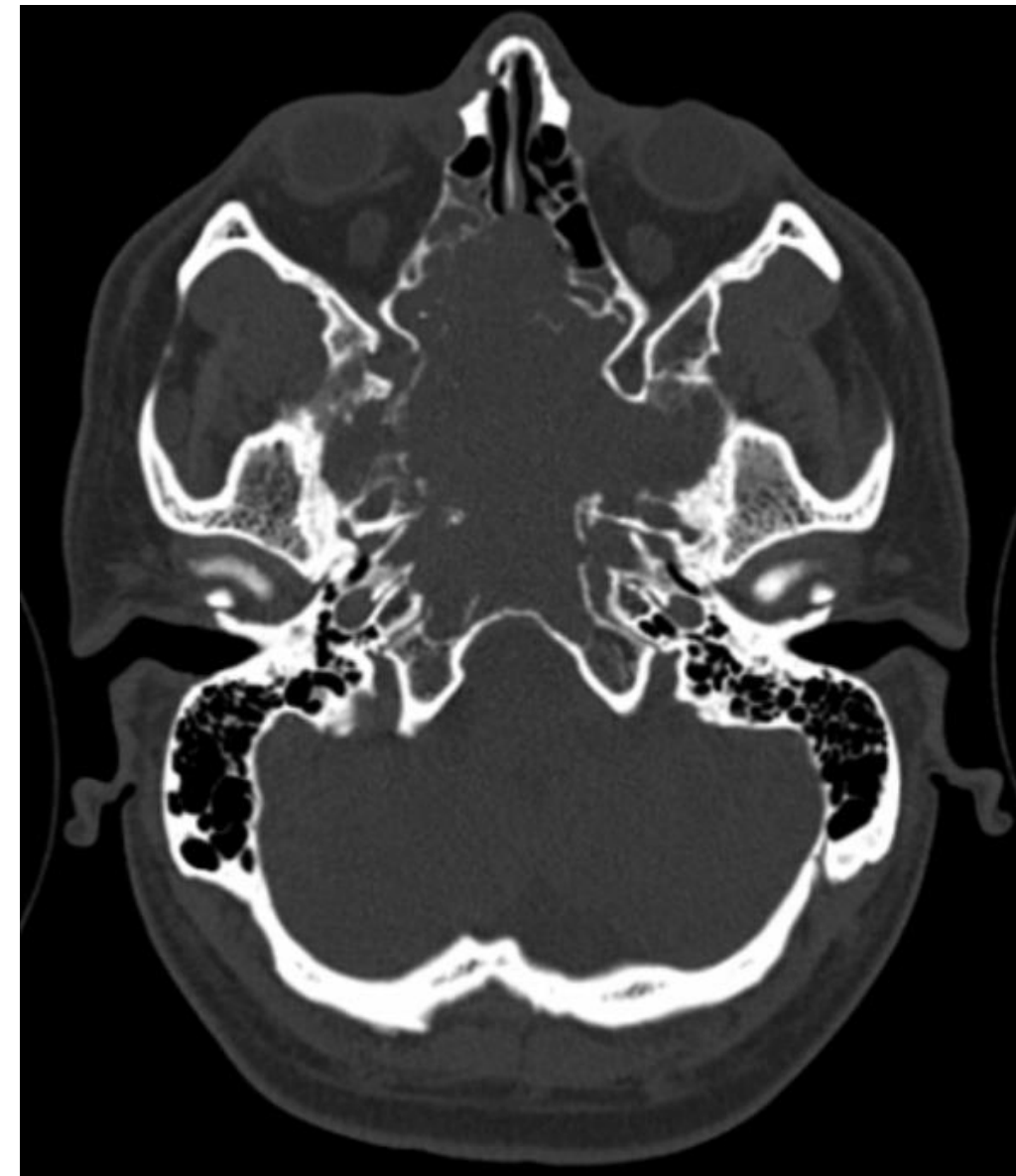
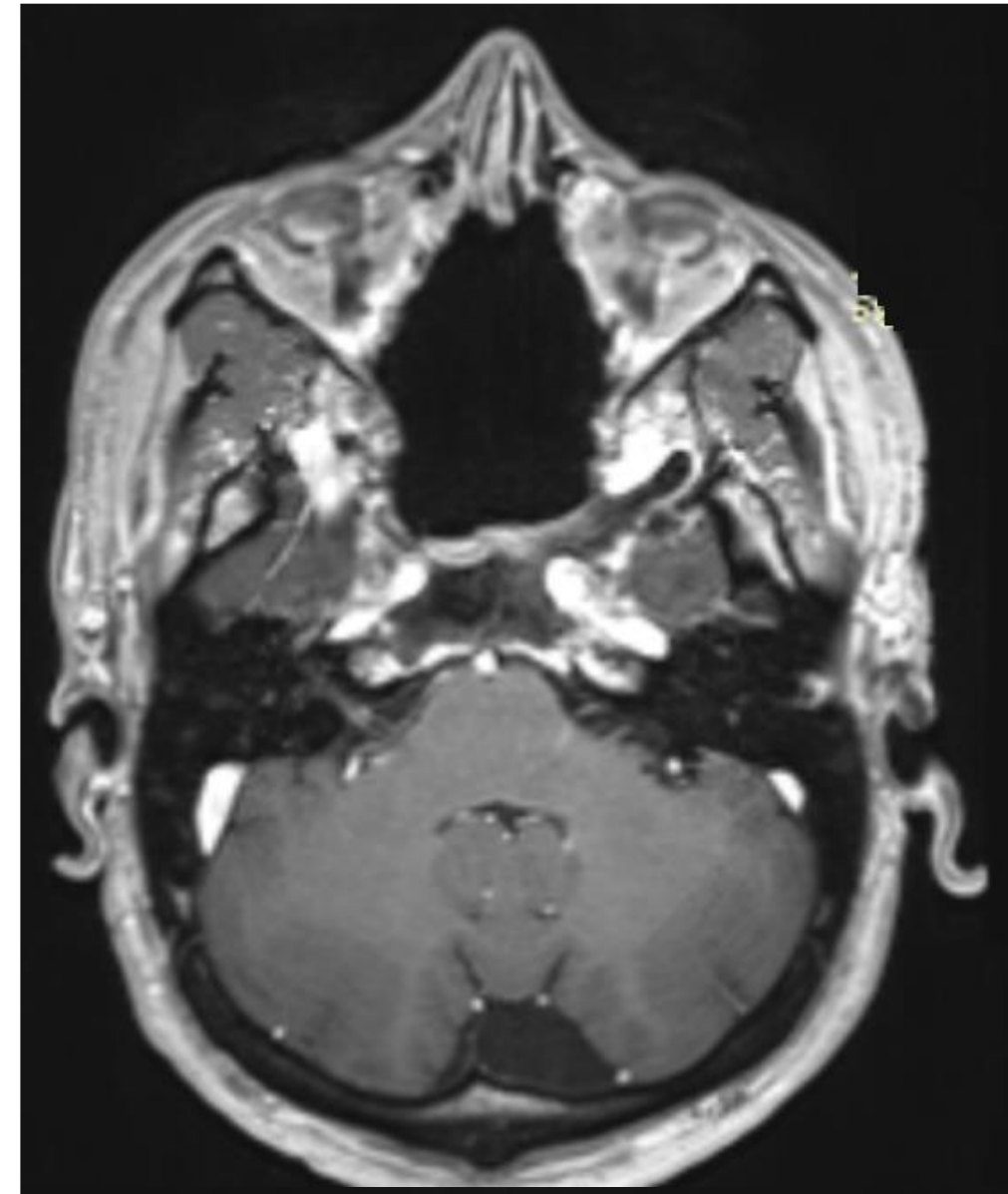
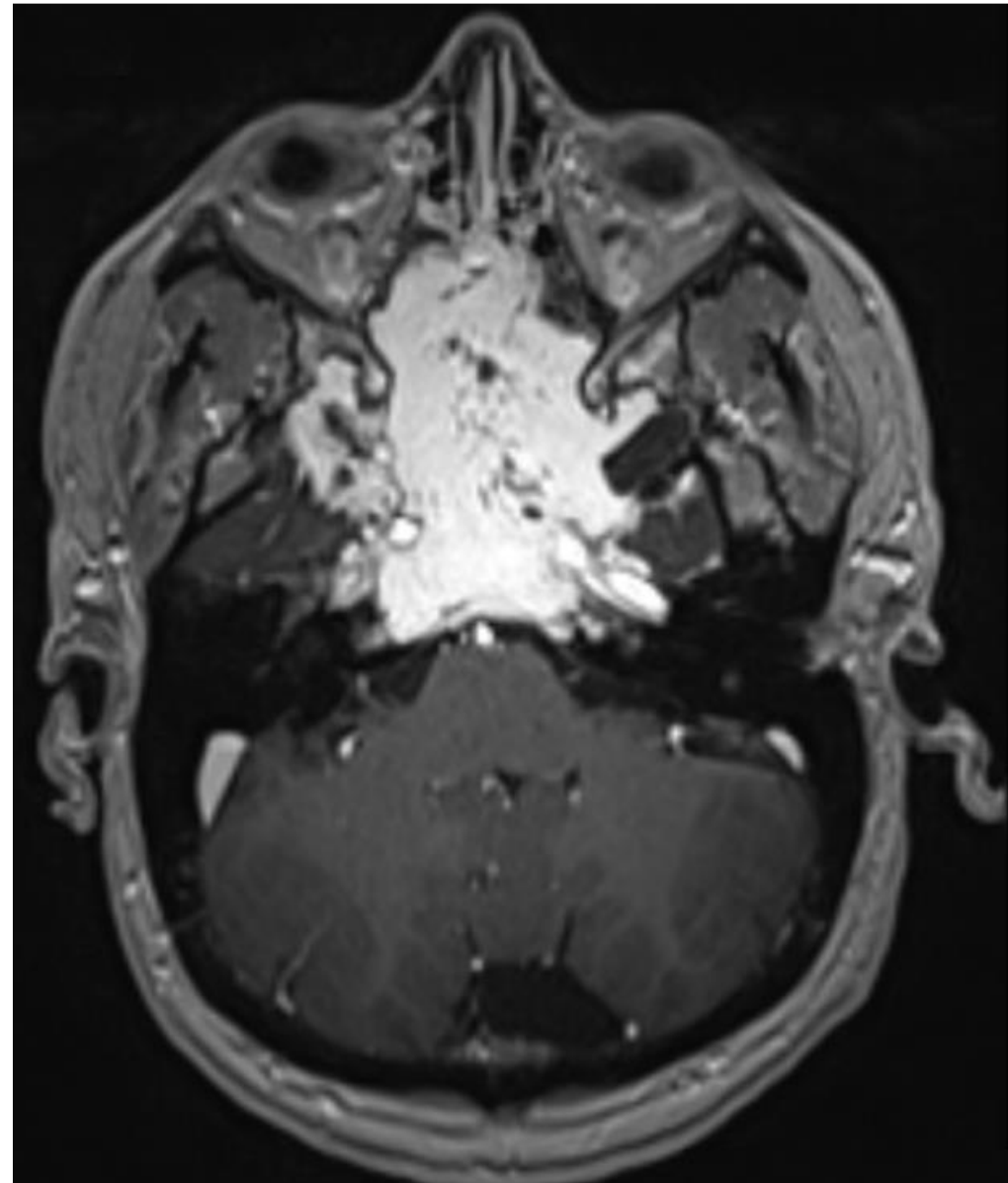
4) Meningioma

- 5) Secondary tumours (Metastases from primary tumours from...)
 - Breast
 - Lung
 - Gastrointestinal tract

Melléküreg daganatok



Benignus melléküregi tumor (juvenilis angiofibroma)



- 30 é ffi
- 2020: partialis resectio módosított Moore-ból
- 2021: partialis resectio embolizáció után mikroszkópos transnasalis feltárásból
- 2022: radikális resectio endoscoppal embolizáció után

Malignus melléküregdaganatok

TNM

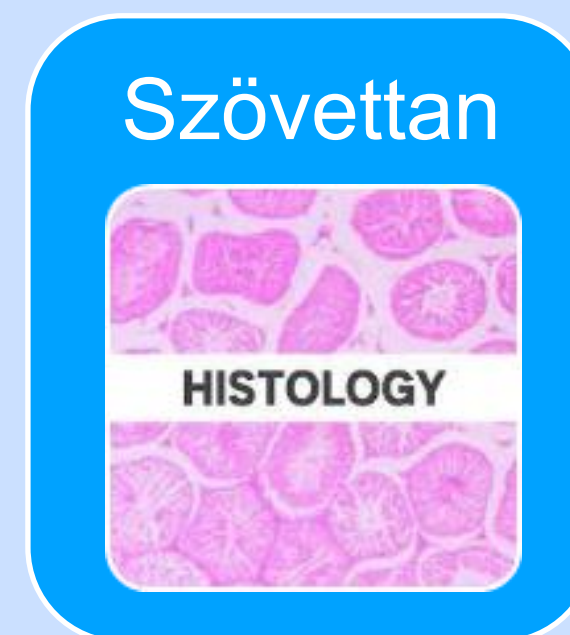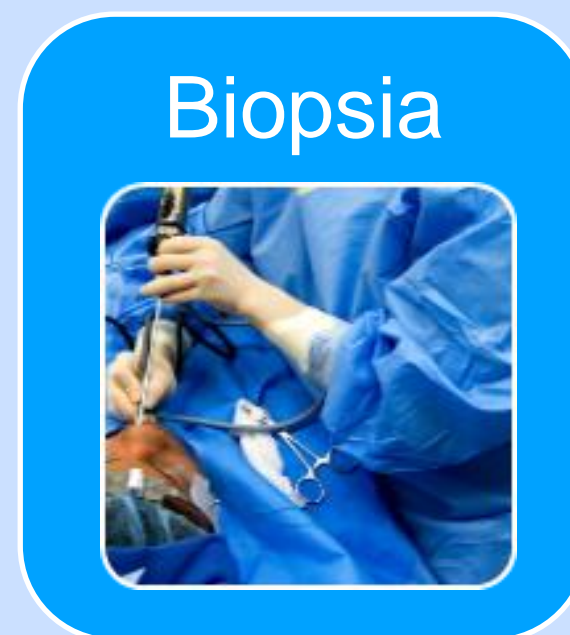
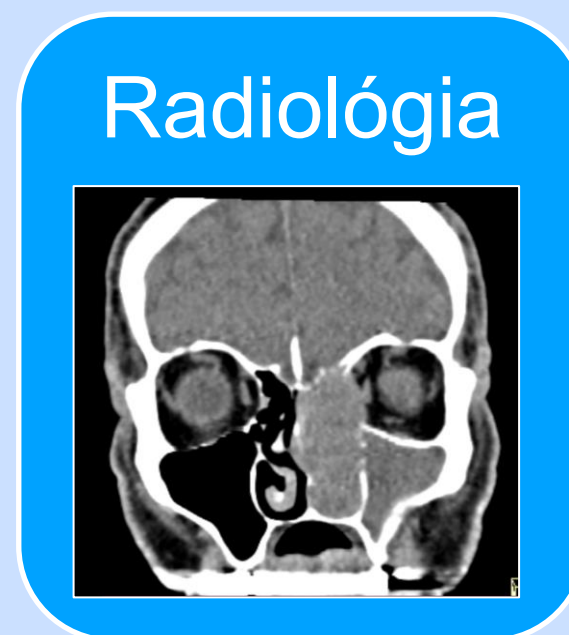
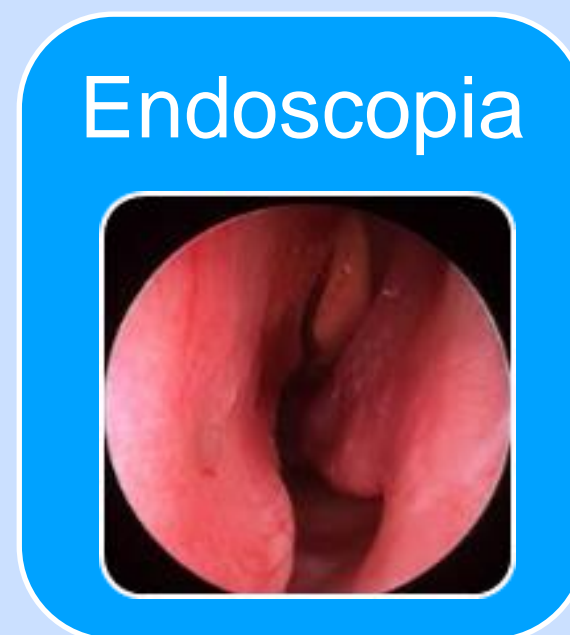
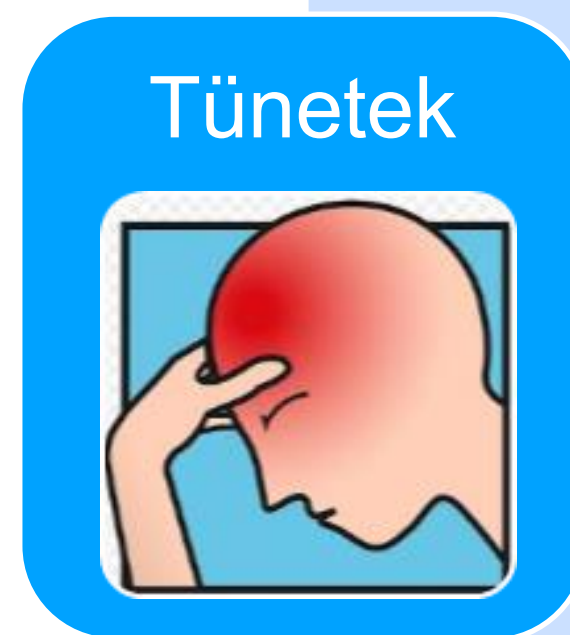
Maxillary Sinus

T Category	T Criteria
TX	Primary tumor cannot be assessed
Tis	Carcinoma <i>in situ</i>
T1	Tumor limited to maxillary sinus mucosa with no erosion or destruction of bone
T2	Tumor causing bone erosion or destruction including extension into the hard palate and/or middle nasal meatus, except extension to posterior wall of maxillary sinus and pterygoid plates
T3	Tumor invades any of the following: bone of the posterior wall of maxillary sinus, subcutaneous tissues, floor or medial wall of orbit, pterygoid fossa, ethmoid sinuses
T4	Moderately advanced or very advanced local disease
T4a	Moderately advanced local disease Tumor invades anterior orbital contents, skin of cheek, pterygoid plates, infratemporal fossa, cribriform plate, sphenoid or frontal sinuses
T4b	Very advanced local disease Tumor invades any of the following: orbital apex, dura, brain, middle cranial fossa, cranial nerves other than maxillary division of trigeminal nerve (V2), nasopharynx, or clivus

Nasal Cavity and Ethmoid Sinus

T Category	T Criteria
TX	Primary tumor cannot be assessed
Tis	Carcinoma <i>in situ</i>
T1	Tumor restricted to any one subsite, with or without bony invasion
T2	Tumor invading two subsites in a single region or extending to involve an adjacent region within the nasoethmoidal complex, with or without bony invasion
T3	Tumor extends to invade the medial wall or floor of the orbit, maxillary sinus, palate, or cribriform plate
T4	Moderately advanced or very advanced local disease
T4a	Moderately advanced local disease Tumor invades any of the following: anterior orbital contents, skin of nose or cheek, minimal extension to anterior cranial fossa, pterygoid plates, sphenoid or frontal sinuses
T4b	Very advanced local disease Tumor invades any of the following: orbital apex, dura, brain, middle cranial fossa, cranial nerves other than (V2), nasopharynx, or clivus

Koponyaalapot érintő melléküregdaganatok



Nancy McLaughlin et al. Teamwork in skull base surgery: An avenue for improvement in patient care (2013)

Malignus melléküregdaganatok: Szövettan vezérelt terápia

Histology-driven treatment strategies in sinonasal cancer

Sinonasal Malignancies of Anterior Skull Base

Histology-driven Treatment Strategies

Castelnuovo, et al. Otolaryngol Clin N Am, 2016

The Impact of Histologic Phenotype in the Treatment of Sinonasal Cancer

Lopez, et al. Adv Ther, 2017

Sinonasal cancers treatments: state of the art

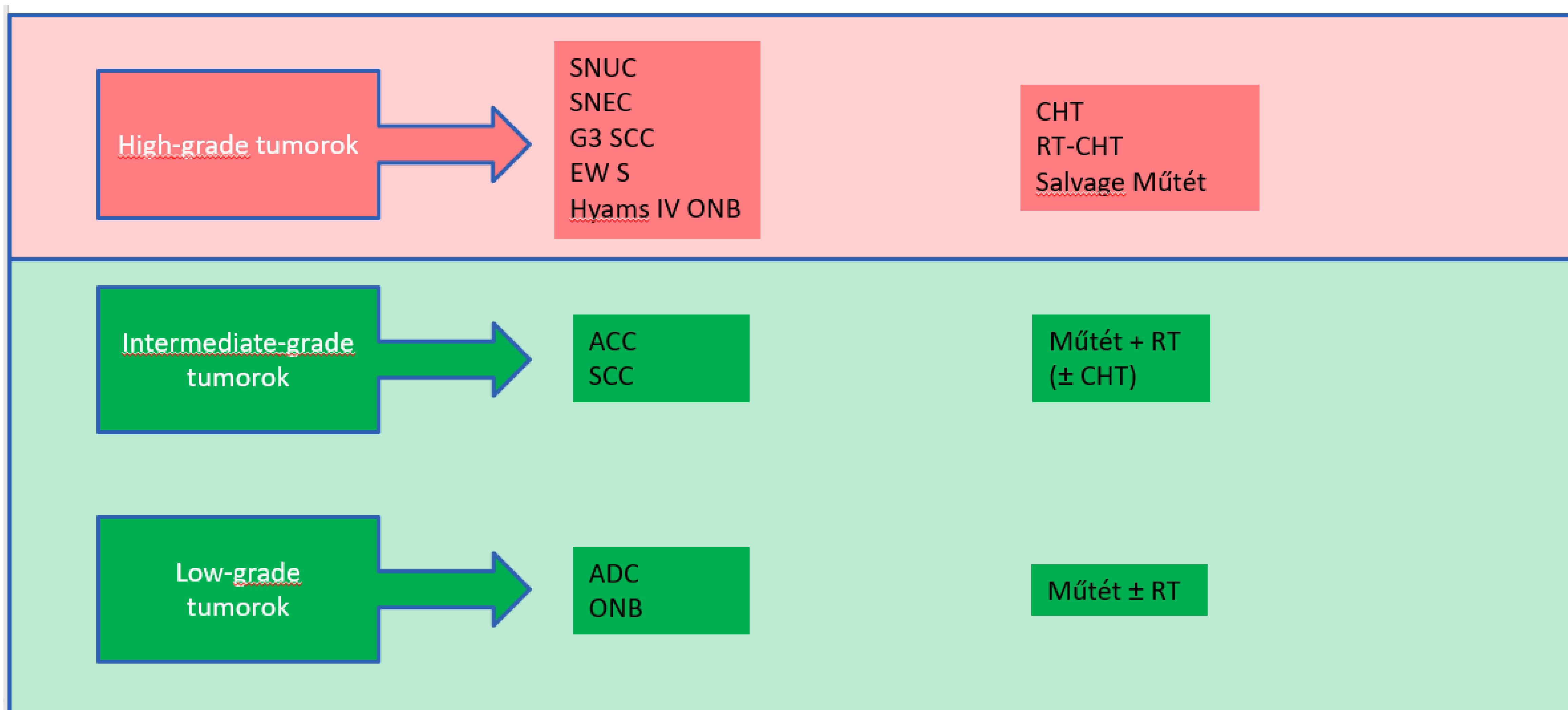
Marco Ferrari^a, Ester Orlandi^b, and Paolo Bossi^c

Curr Opin Oncol, 2021

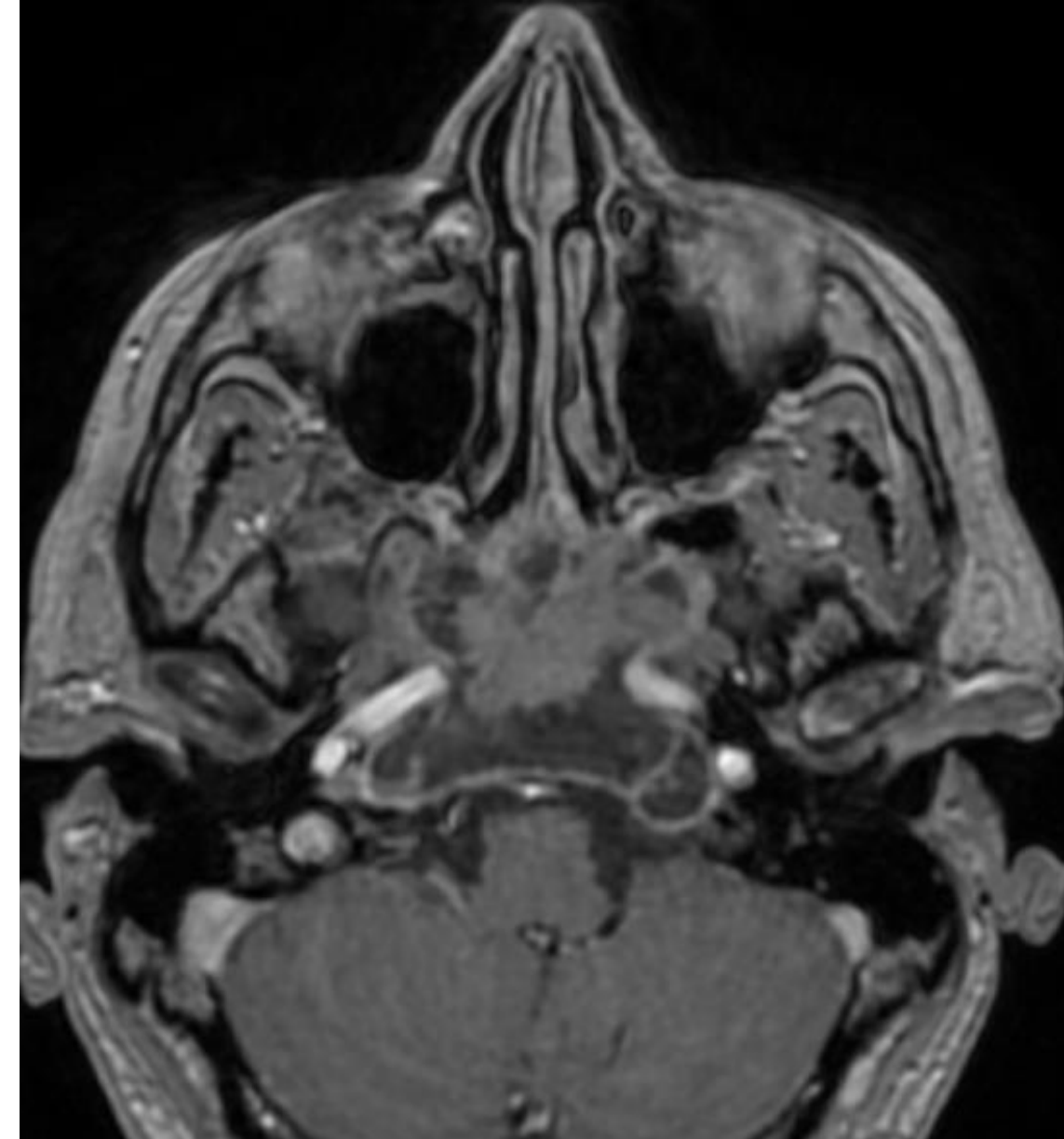
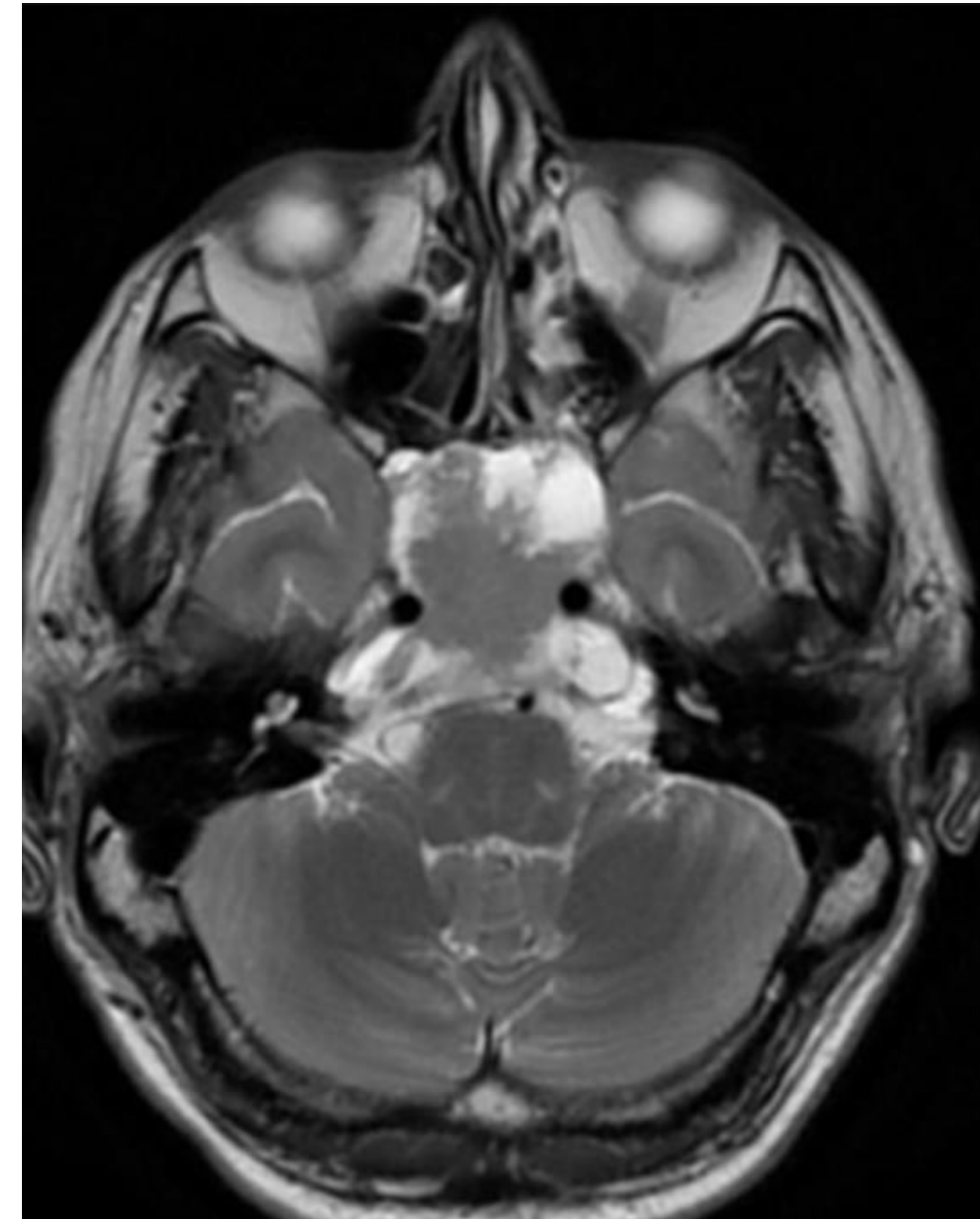
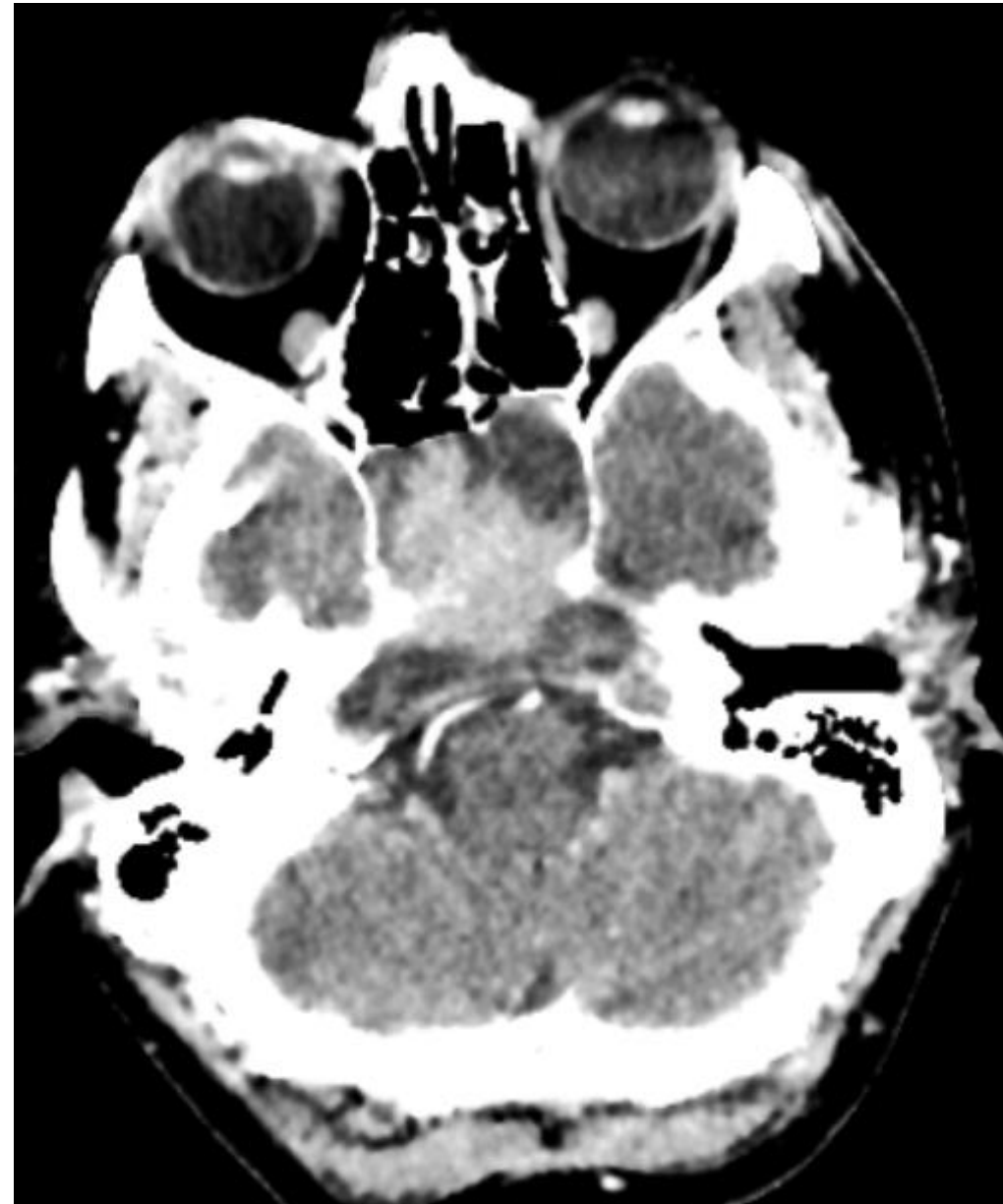
Histology	Highlights	5-year OS ^b	Treatment
Squamous cell carcinoma	Frequently located in the maxillary sinus Can arise de novo or ex inverted papilloma HPV-related multiphenotypic and nonkeratinizing variant might have pronounced radiosensitivity Low-to-moderate risk of nodal metastasis ^a	Intermediate	S + (C)RT nCT + CRT nCT + S + (C)RT
Intestinal-type adenocarcinoma	Frequently located in the nasoethmoidal complex Associated with wood-, leather-, or cork-working Heterogeneous geographical distribution Grade-dependent behavior Low risk of nodal metastasis ^a	Intermediate-to-high	S S + RT nCT + S + RT
Nonintestinal-type adenocarcinoma	Very rare 'Wastebasket' entity grouping diverse tumors Grade-dependent behavior	Intermediate	S S + RT
Olfactory neuroblastoma	Most often centered in the olfactory cleft Grade-dependent behavior Moderate-to-high risk of nodal metastasis ^a Slow kinetic, nonnegligible rate of late relapse	High-to-very high	S S + (C)RT nCT + (C)RT nCT + S + (C)RT
Mucosal melanoma	Very aggressive tumor Noncontiguous mucosal extension (i.e. melanosis, satellites) Low-to-moderate risk of nodal metastasis ^a High risk of distant metastasis ^a	Low-to-very-low	S + RT ^c RT ^c
Adenoid cystic carcinoma	Tendency to submucosal, perineural, and lymphovascular spread Grade-dependent behavior High-grade transformation variant Slow kinetic, remarkable rate of late relapse Low-to-moderate risk of nodal metastasis ^a High risk of distant metastasis ^a High long-term disease-specific mortality	Intermediate-to-high	S + RT ^c RT ^c
Sinonasal undifferentiated carcinoma – variant not associated with molecular identifiers, IDH2-mutated variant, HPV-related variant	'Wastebasket' entity grouping diverse tumors; includes variants with molecular identifiers (see also next row) Quick kinetic Knowledge, treatment, and prognosis have been changing over the last 3 decades Moderate-to-high risk of nodal metastasis ^a	Intermediate-to-high	nCT + (C)RT nCT + S + (C)RT

Sinonasal undifferentiated carcinoma – SMARCB1/INI1-deficient variant, SMARCA4-deficient variant	Very aggressive tumor Extremely quick kinetic High risk of nodal metastasis ^a High risk of distant metastasis ^a	Very low	S + (C)RT nCT + (C)RT nCT + S + (C)RT
NUT carcinoma	Considered by some authors as the most dedifferentiated type of squamous cell carcinoma Very aggressive tumor Extremely quick kinetic High risk of nodal metastasis ^a High risk of distant metastasis ^a	Very low	S + (C)RT nCT + (C)RT nCT + S + (C)RT
Sinonasal neuroendocrine carcinoma	Group of diverse carcinomas Might be found in combination with squamous cell carcinomatous or adenocarcinomatous tumor cells Generally, very aggressive tumor Quick kinetic High risk of nodal metastasis ^a High risk of distant metastasis ^a	Low-to-very-low	S + (C)RT nCT + (C)RT nCT + S + (C)RT
Soft tissue sarcomas and borderline mesenchymal tumors – Rhabdomyosarcoma	Aggressive tumor Quick kinetic Subtype- and age-dependent behavior High risk of nodal metastasis ^a High risk of distant metastasis ^a	Intermediate-to-low	S + (C)RT CRT + S nCT + S + (C)RT nCT + (C)RT + S
Soft tissue sarcomas and borderline mesenchymal tumors – Nonangiosarcoma, nonrhabdomyosarcoma	Group of diverse tumors Low risk of nodal metastasis ^a Intermediate risk of distant metastasis ^a	Intermediate-to-high	S S + RT
Chondrosarcoma	Locally aggressive tumor Grade-dependent behavior Low risk of nodal metastasis ^a Low risk of distant metastasis ^a	High-to-very high	S S + RT ^c RT ^c
Osteosarcoma	Locally aggressive tumor Grade-dependent behavior Low risk of nodal metastasis ^a Intermediate-to-high risk of distant metastasis ^a	Intermediate-to-high	S S + RT ^c nCT + S + aCT nCT + S + RT nCT + S + RT + aCT RT ^c

Malignus melléküregdaganatok: Szövettan vezérelt terápia

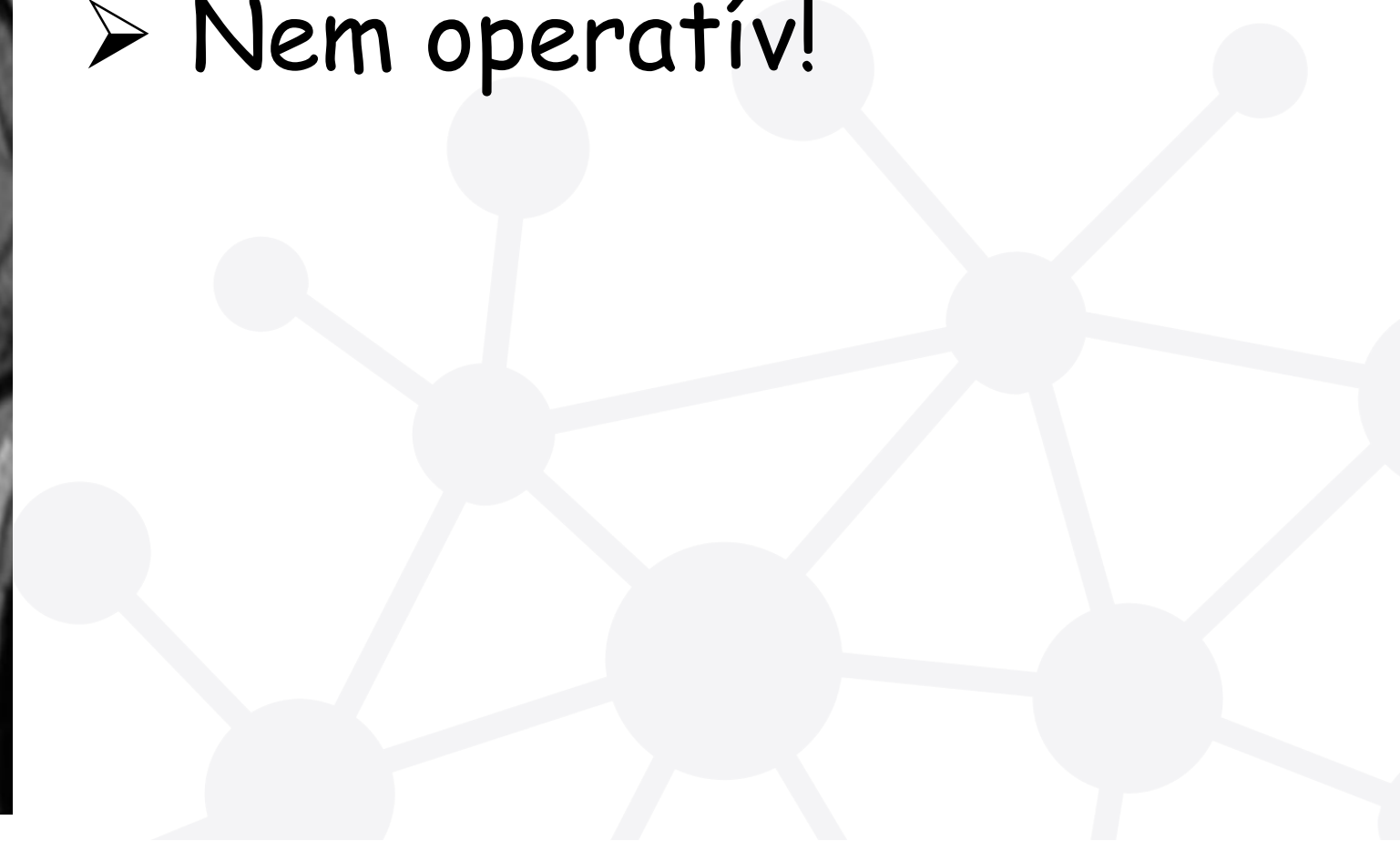

Próbaexcísió és preoperatív endocrinológia

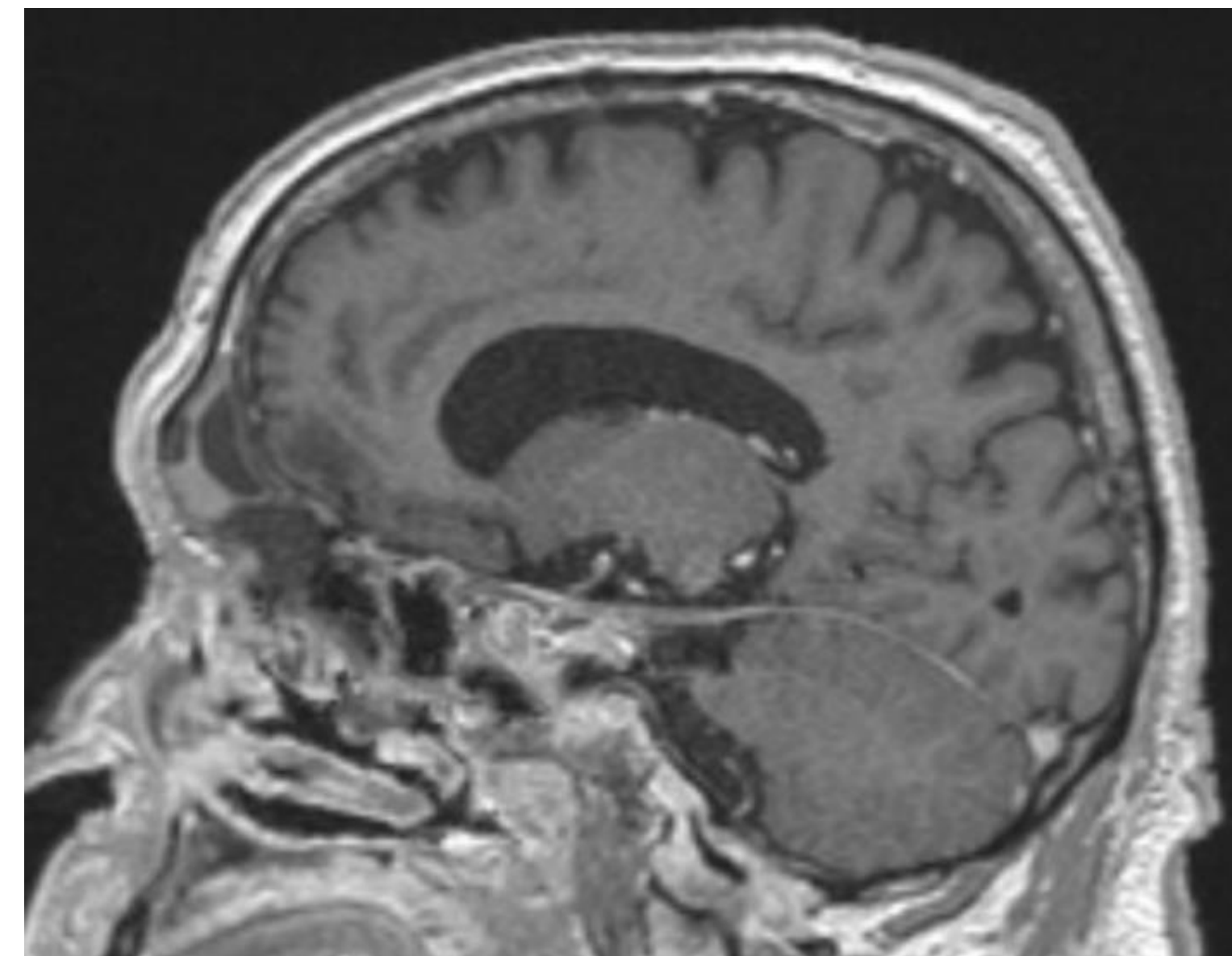
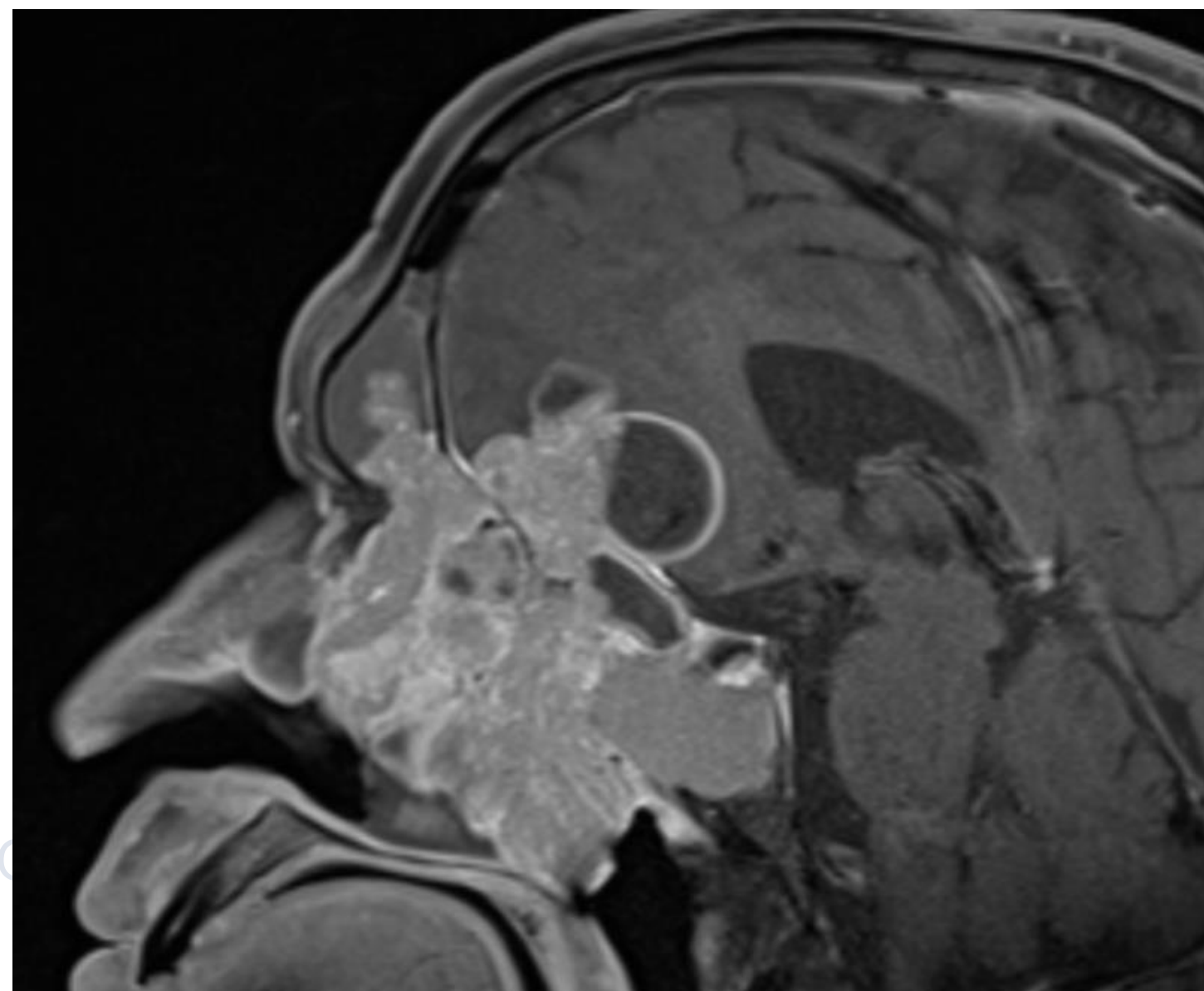
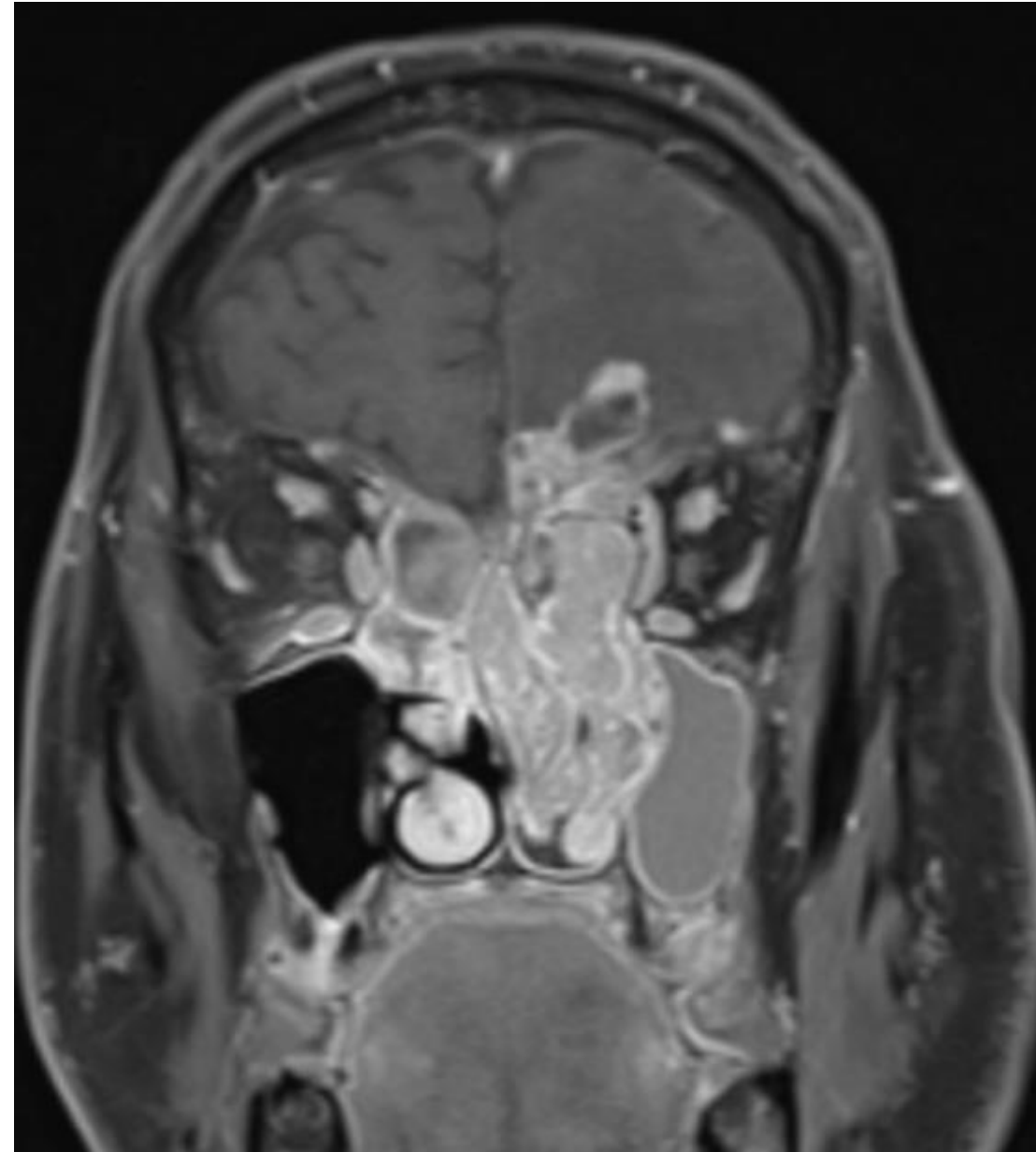
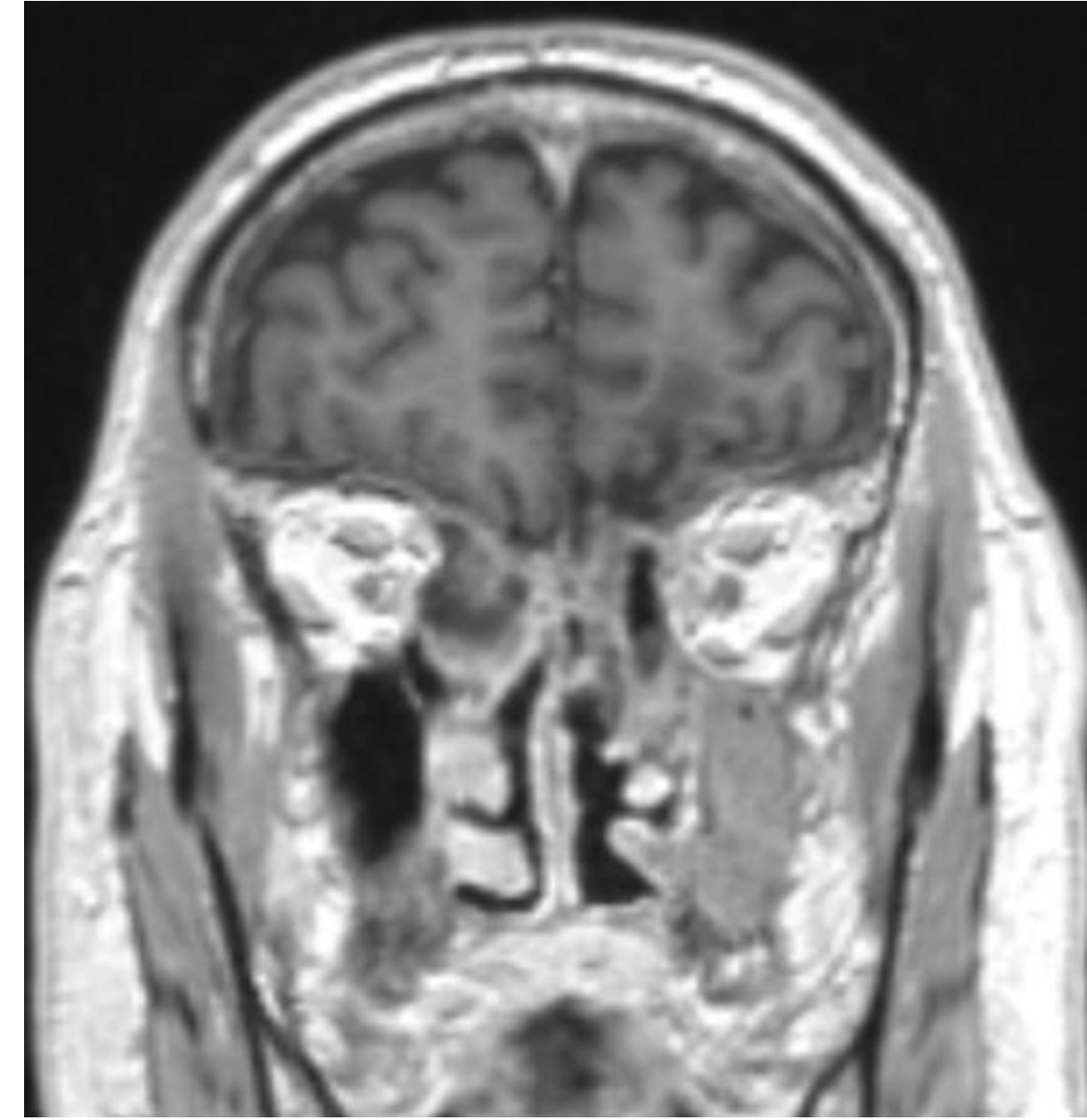
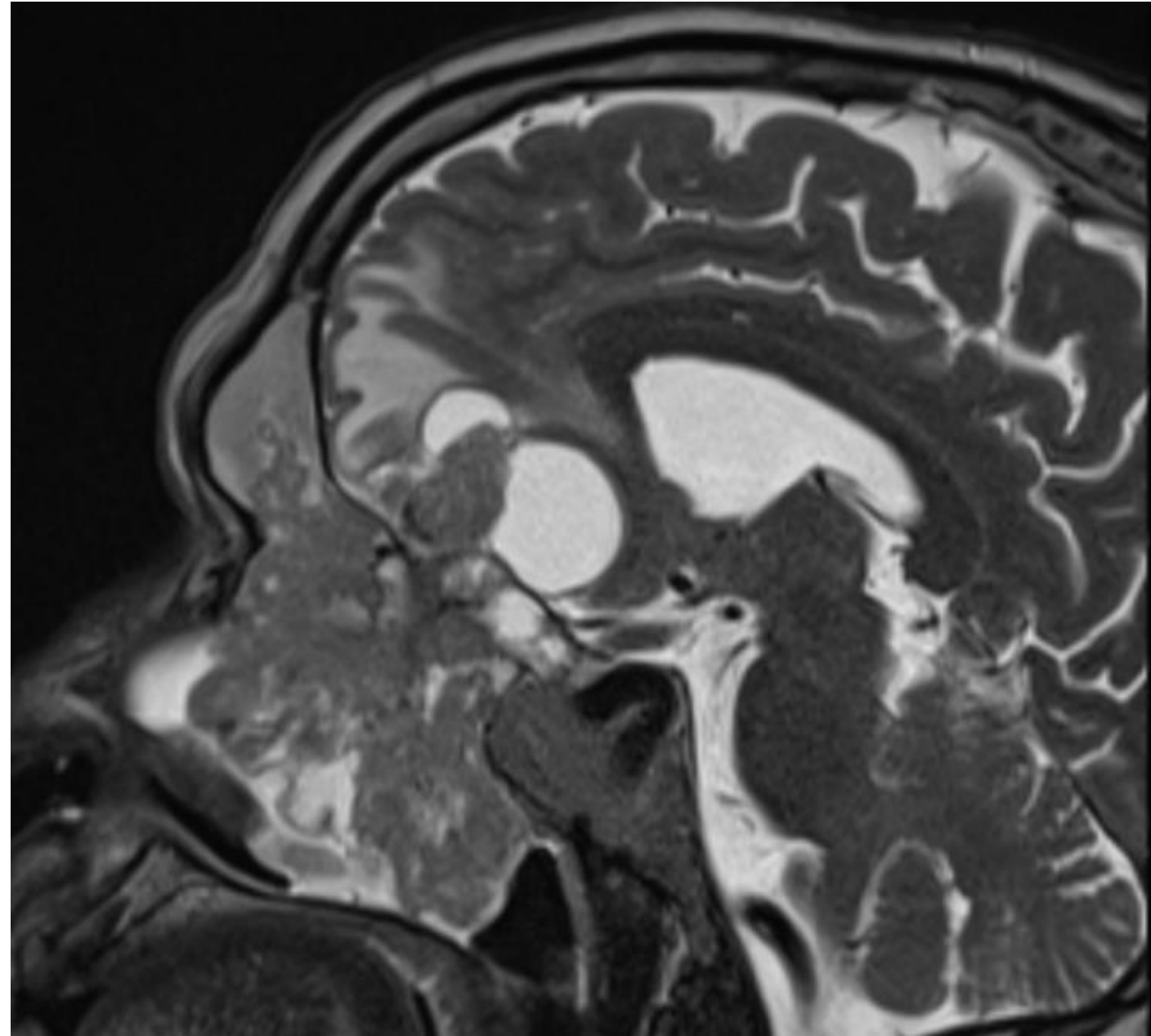
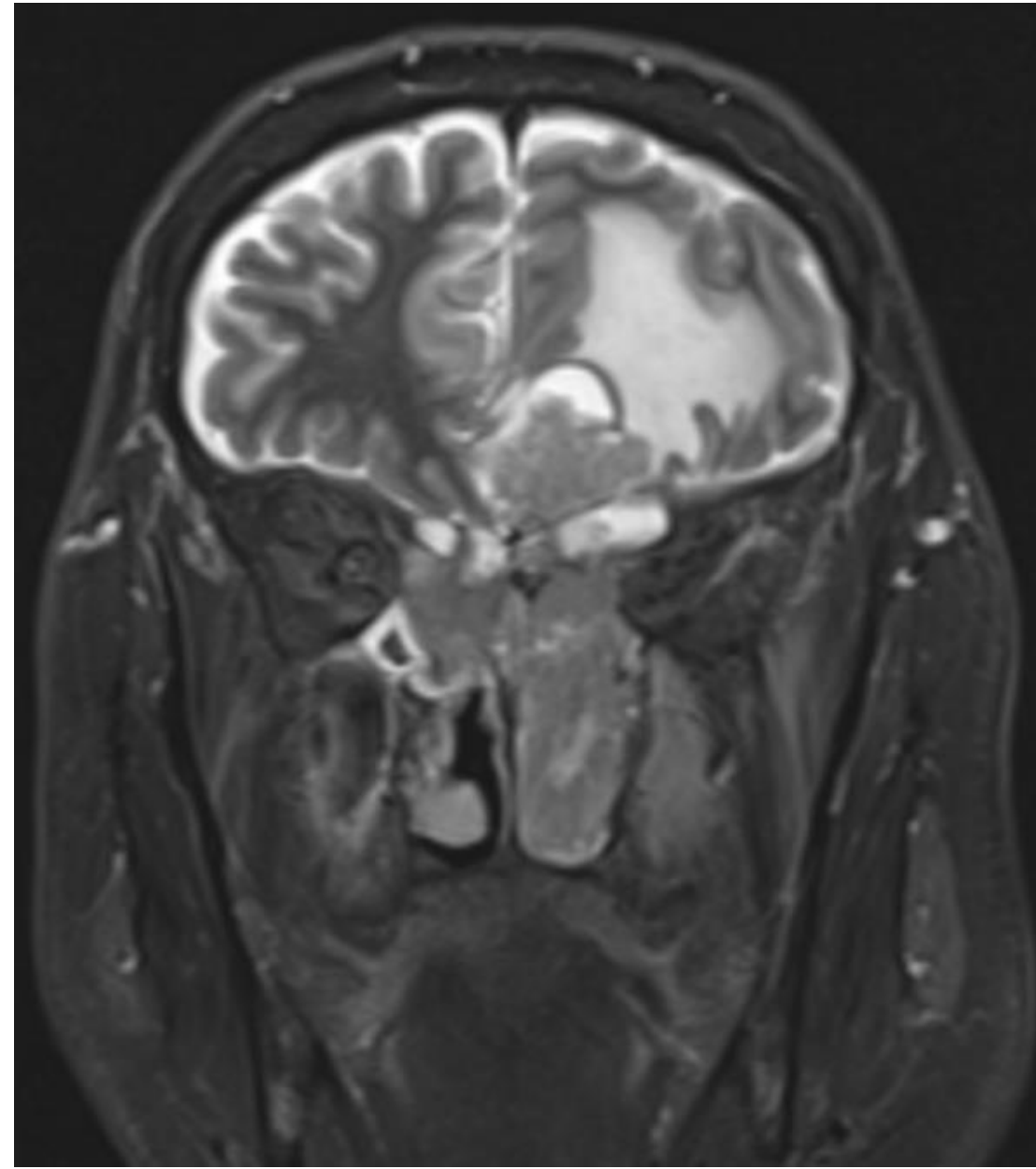


- 42 é ffi
- Fejfájás
- Prex: hypophysis adenoma
- Endocrinologia: prolactinoma

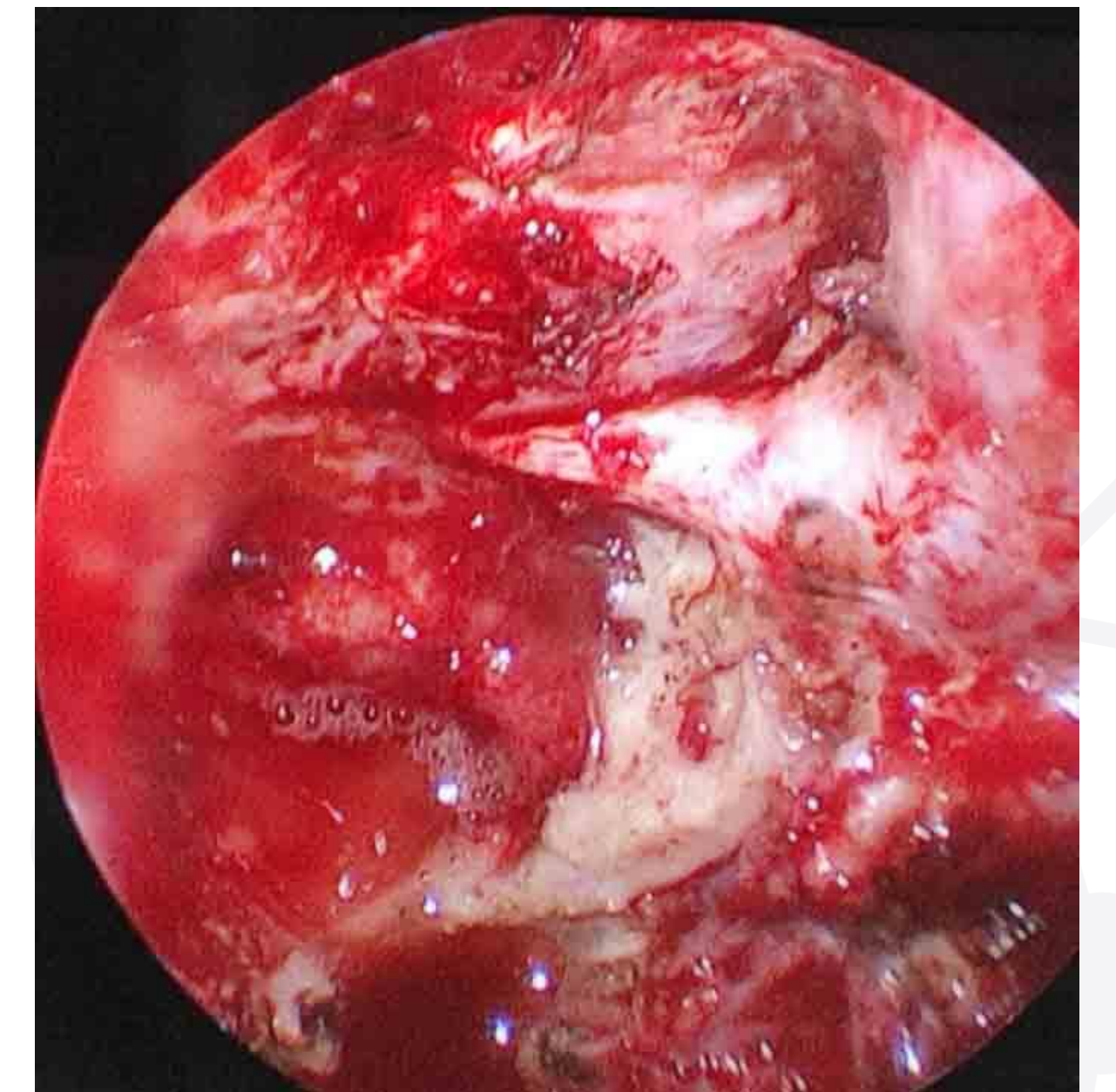
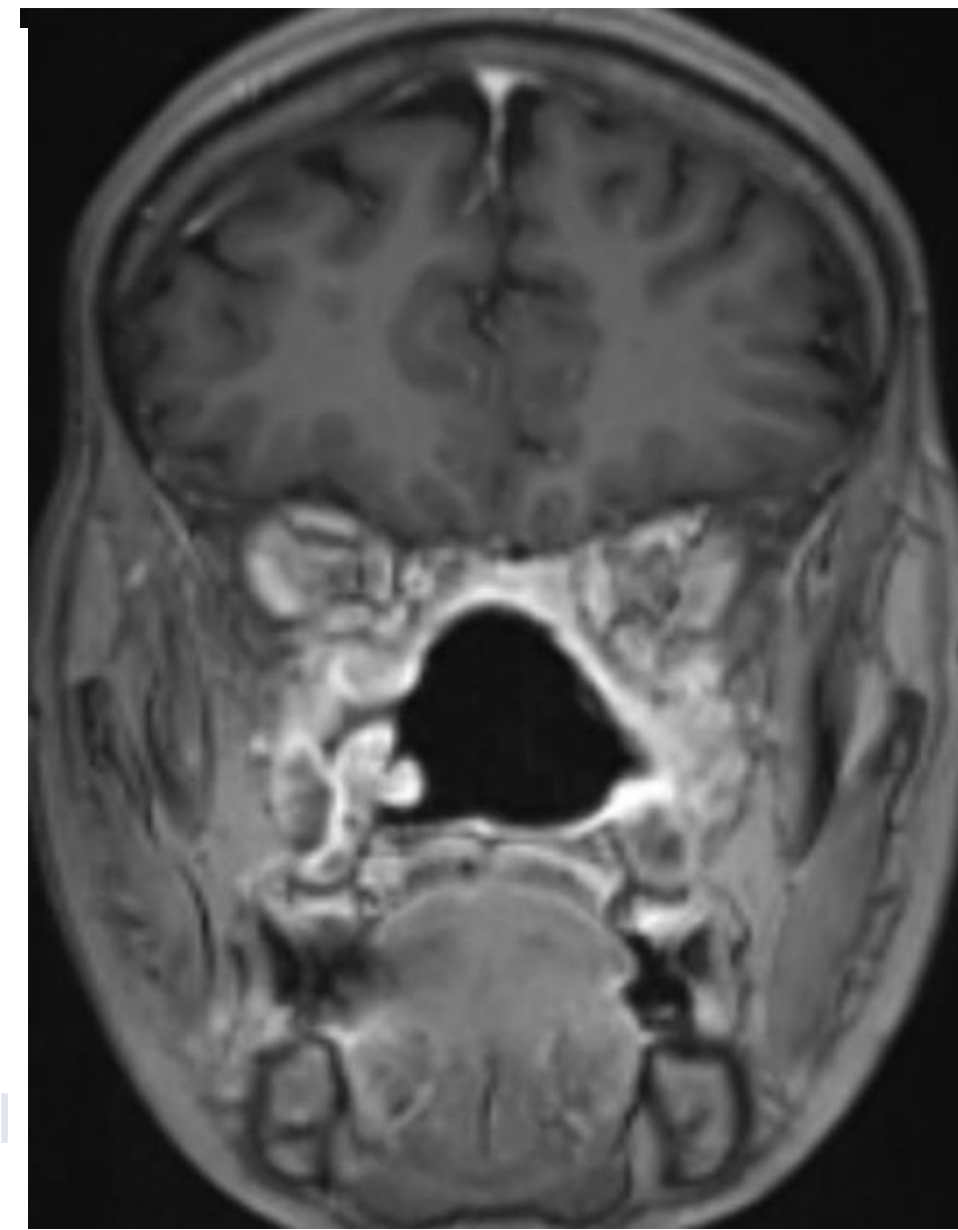
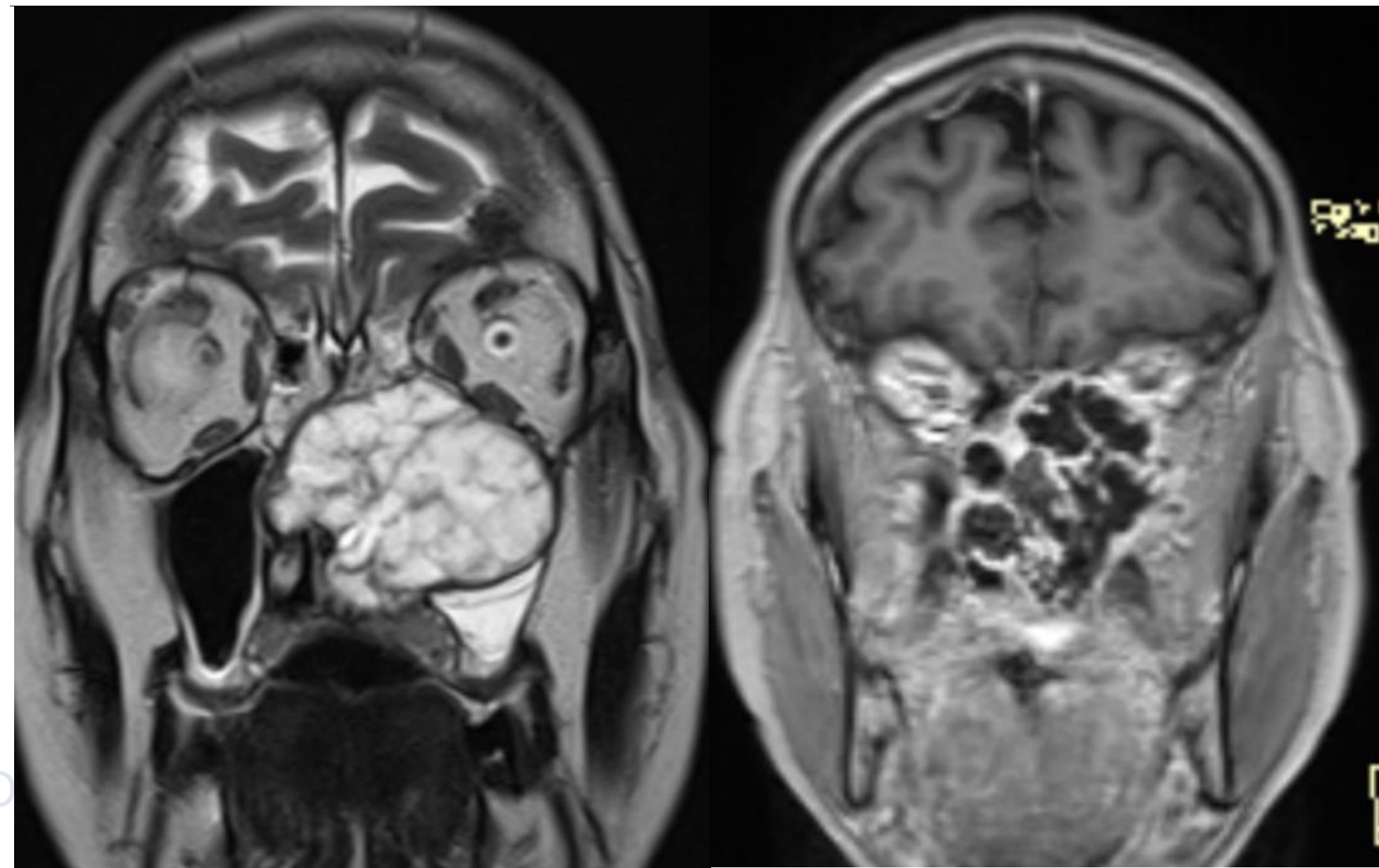
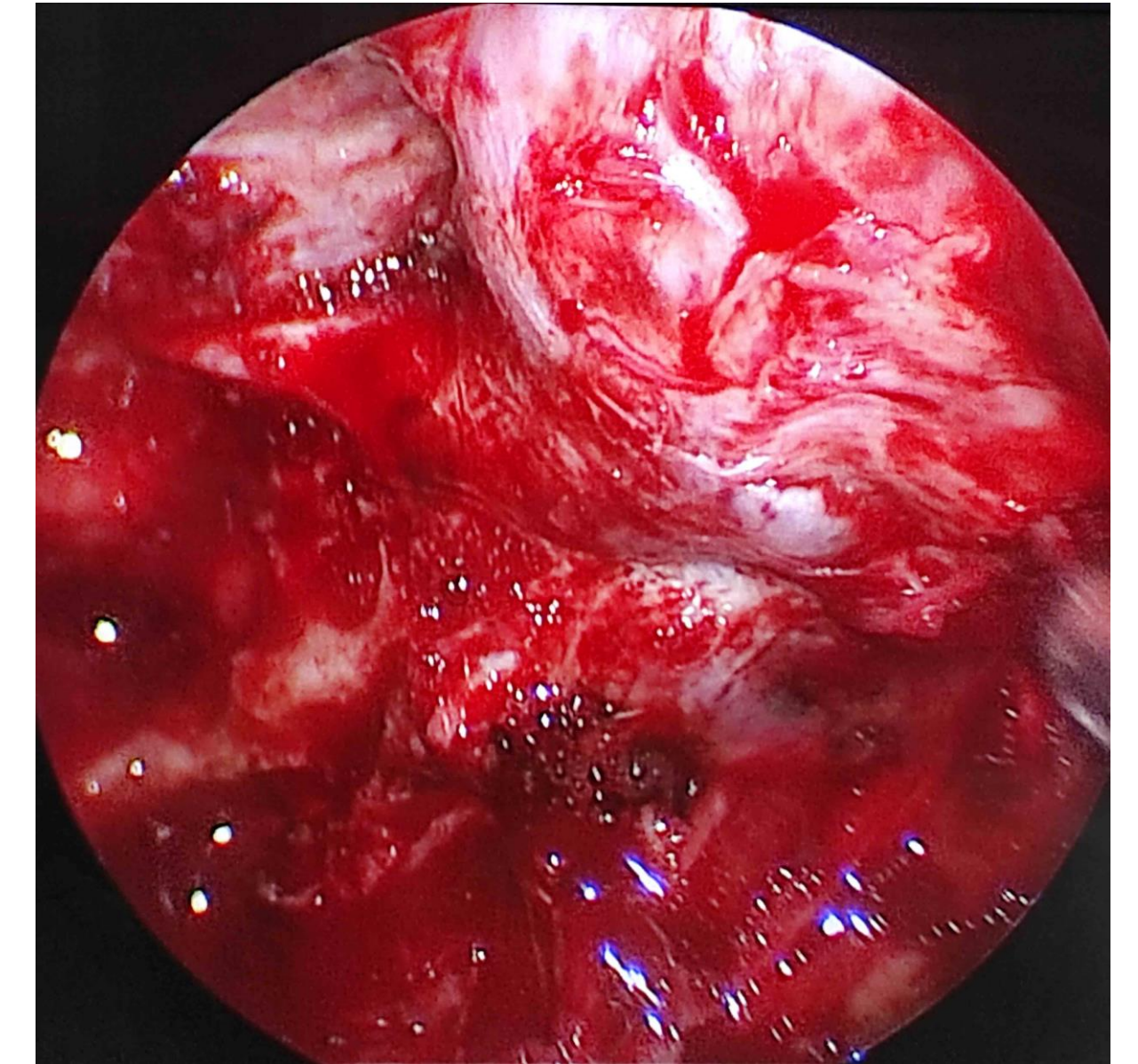
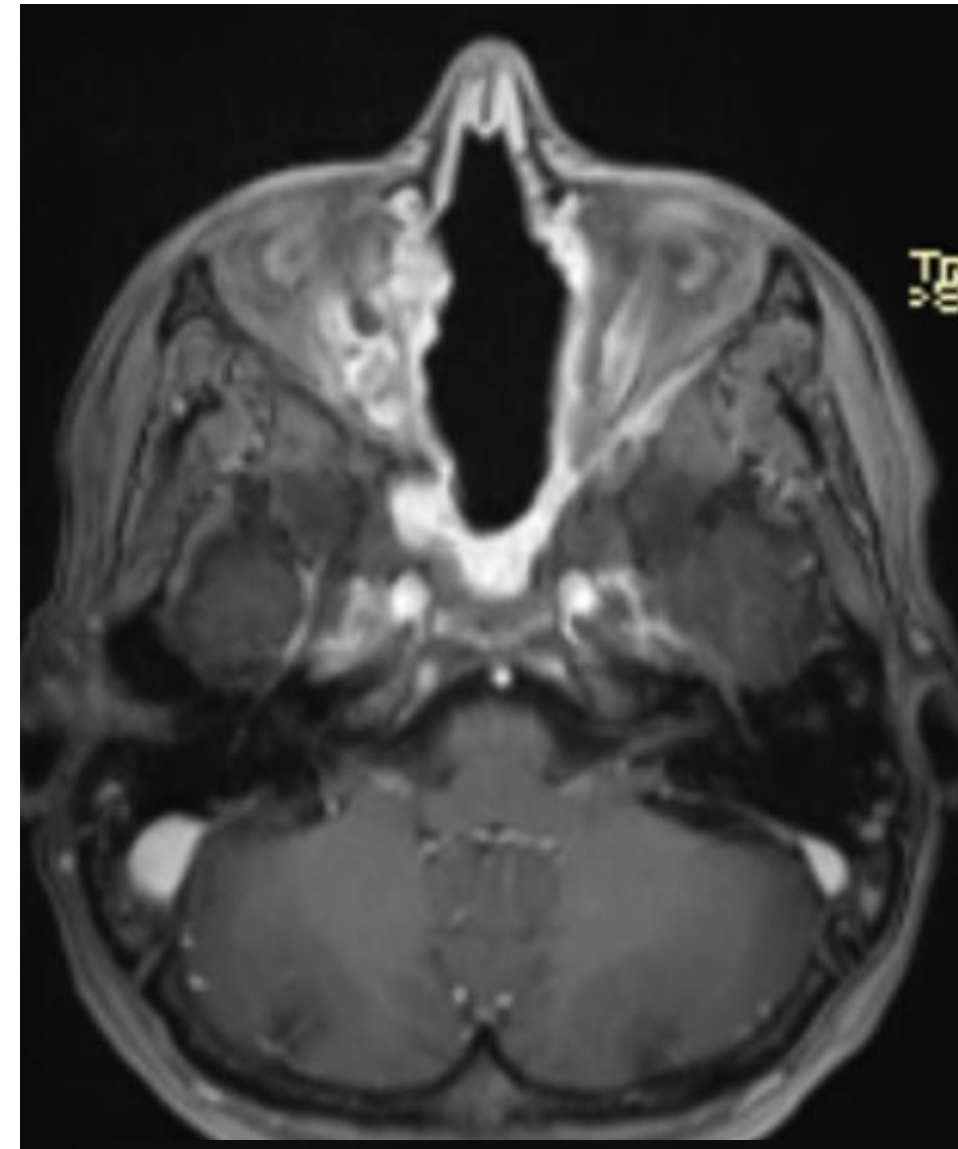
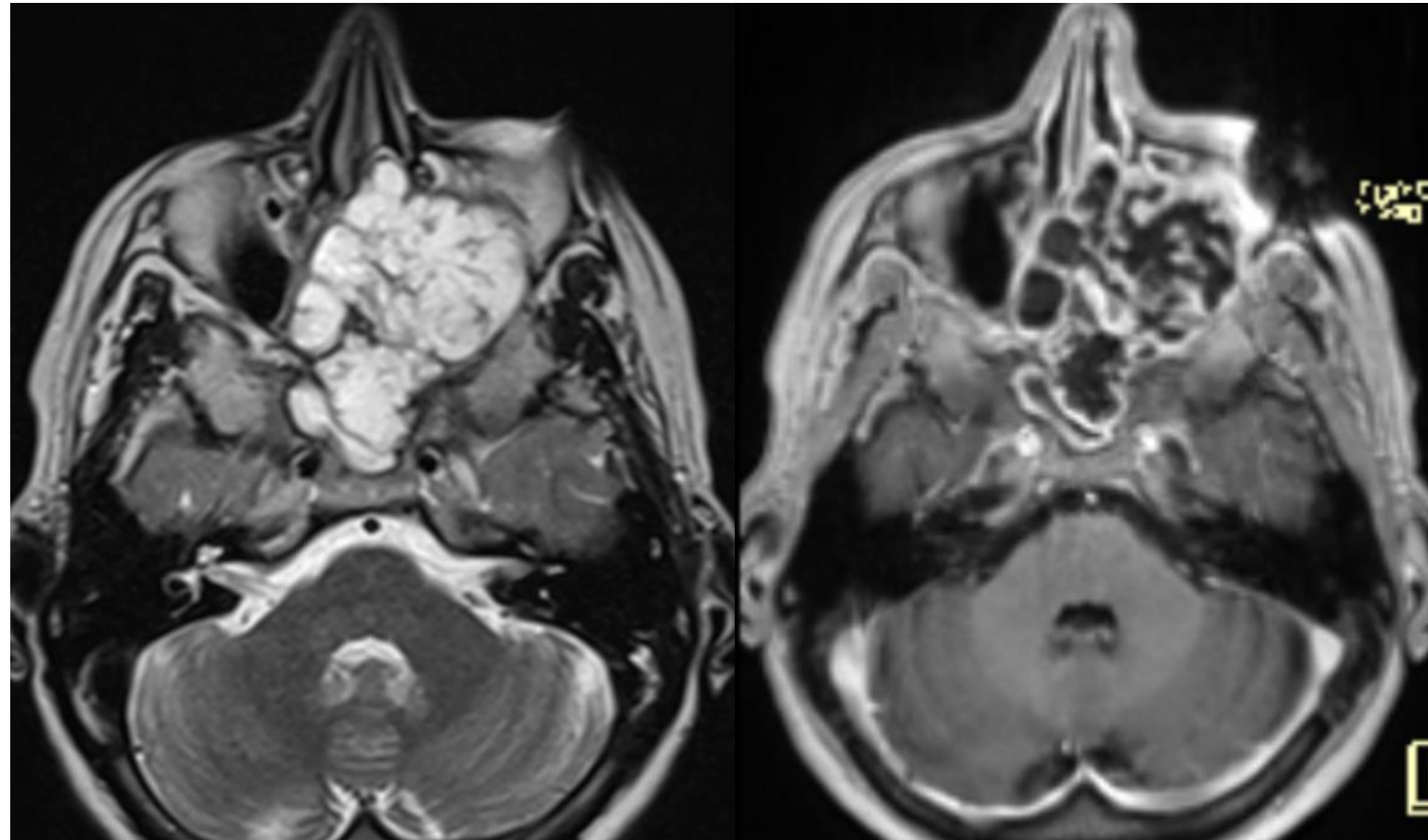
➤ Nem operatív!



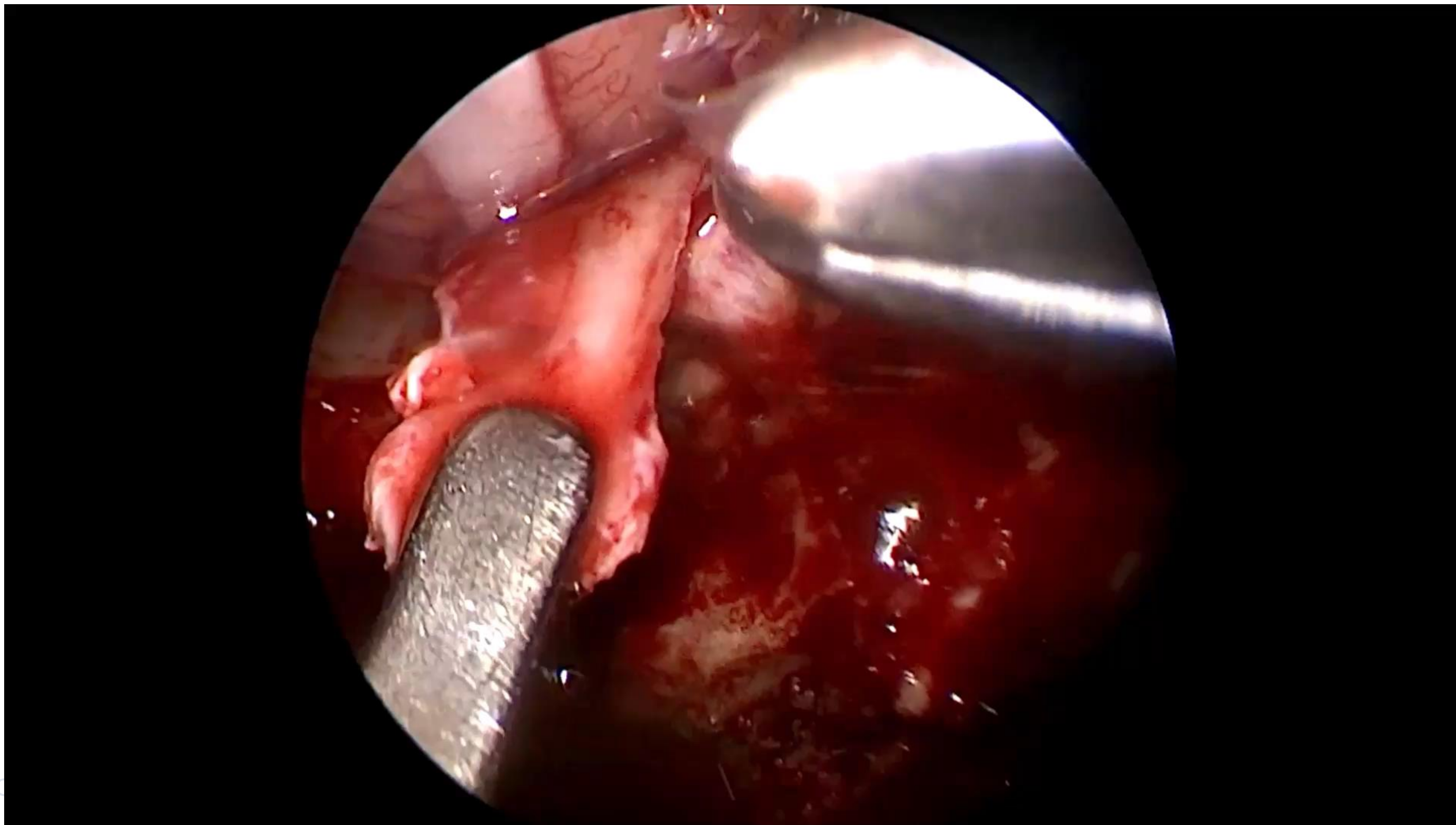
Neoadjuváns onkoterápia hatása



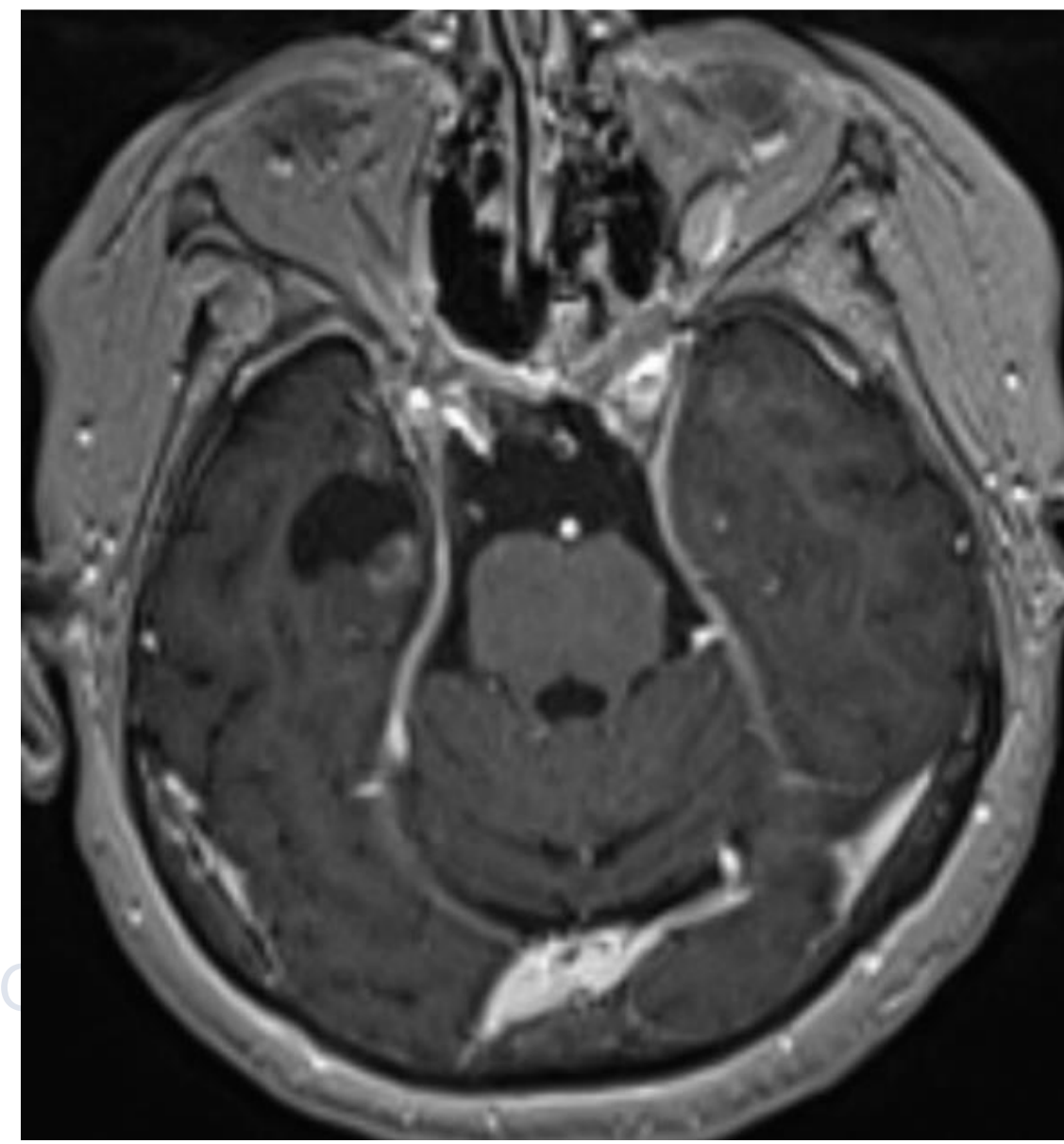
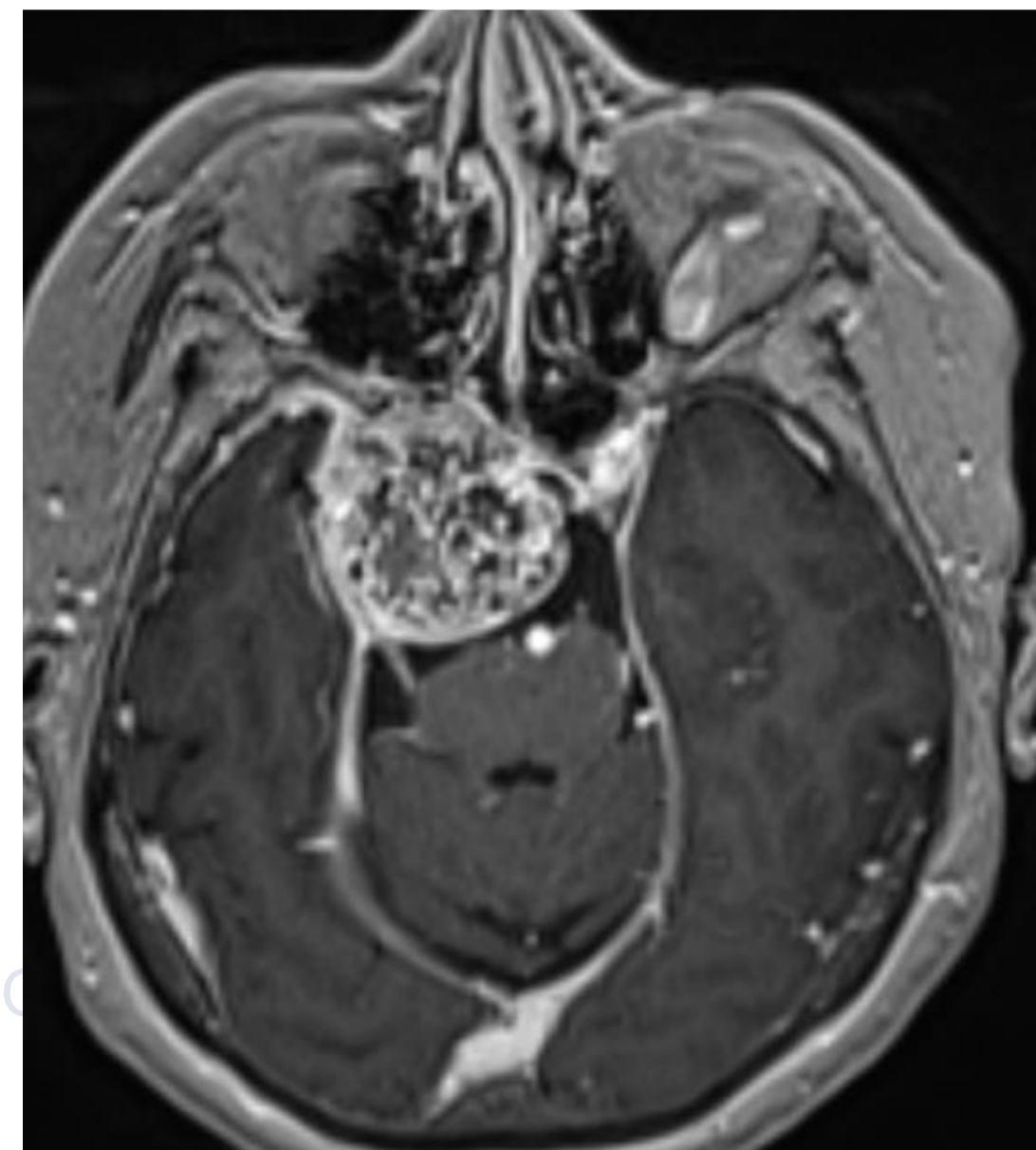
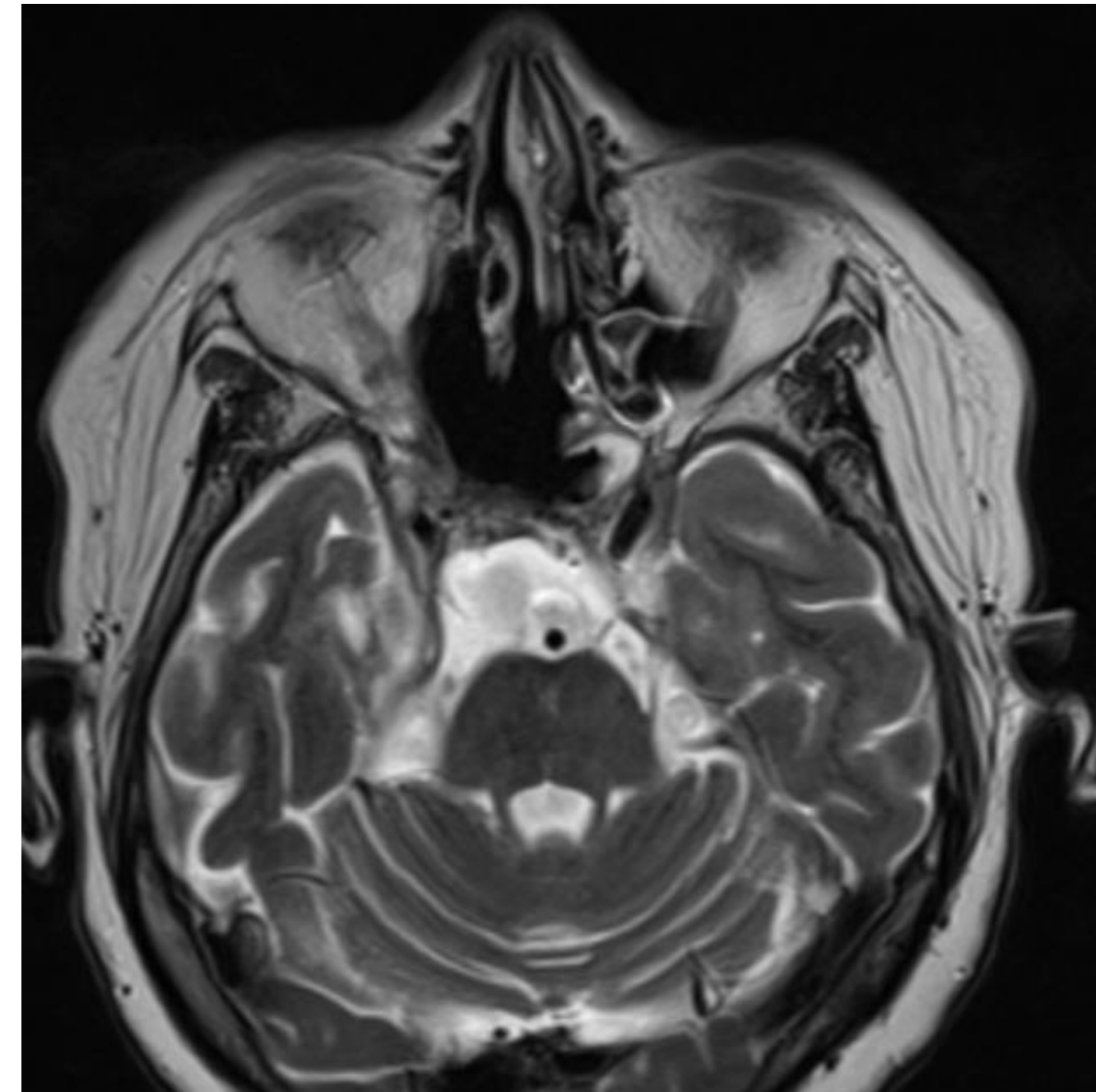
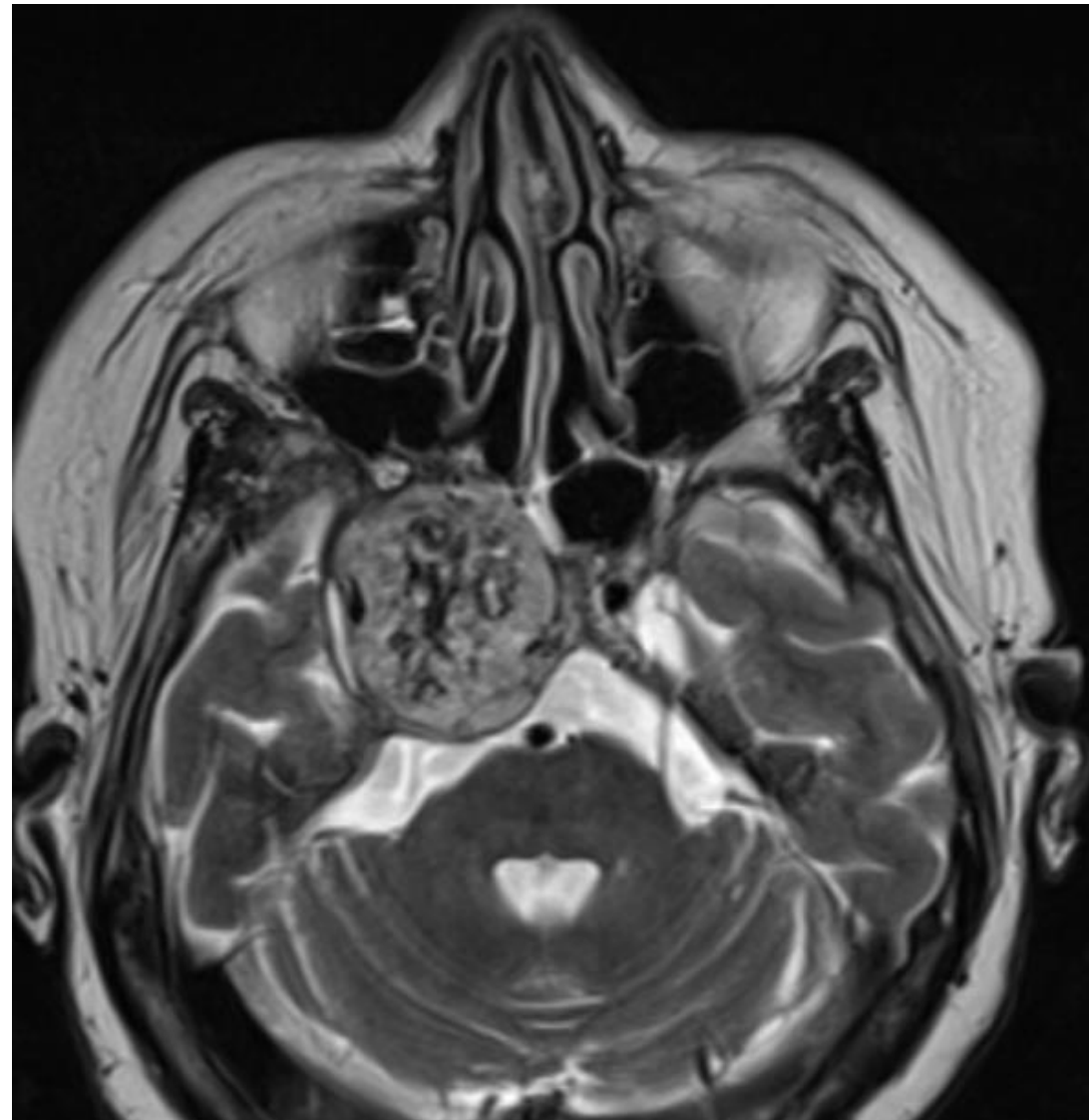
Semimalignus melléküregi tumor



Semimalignus melléküregi tumor - duraresectio

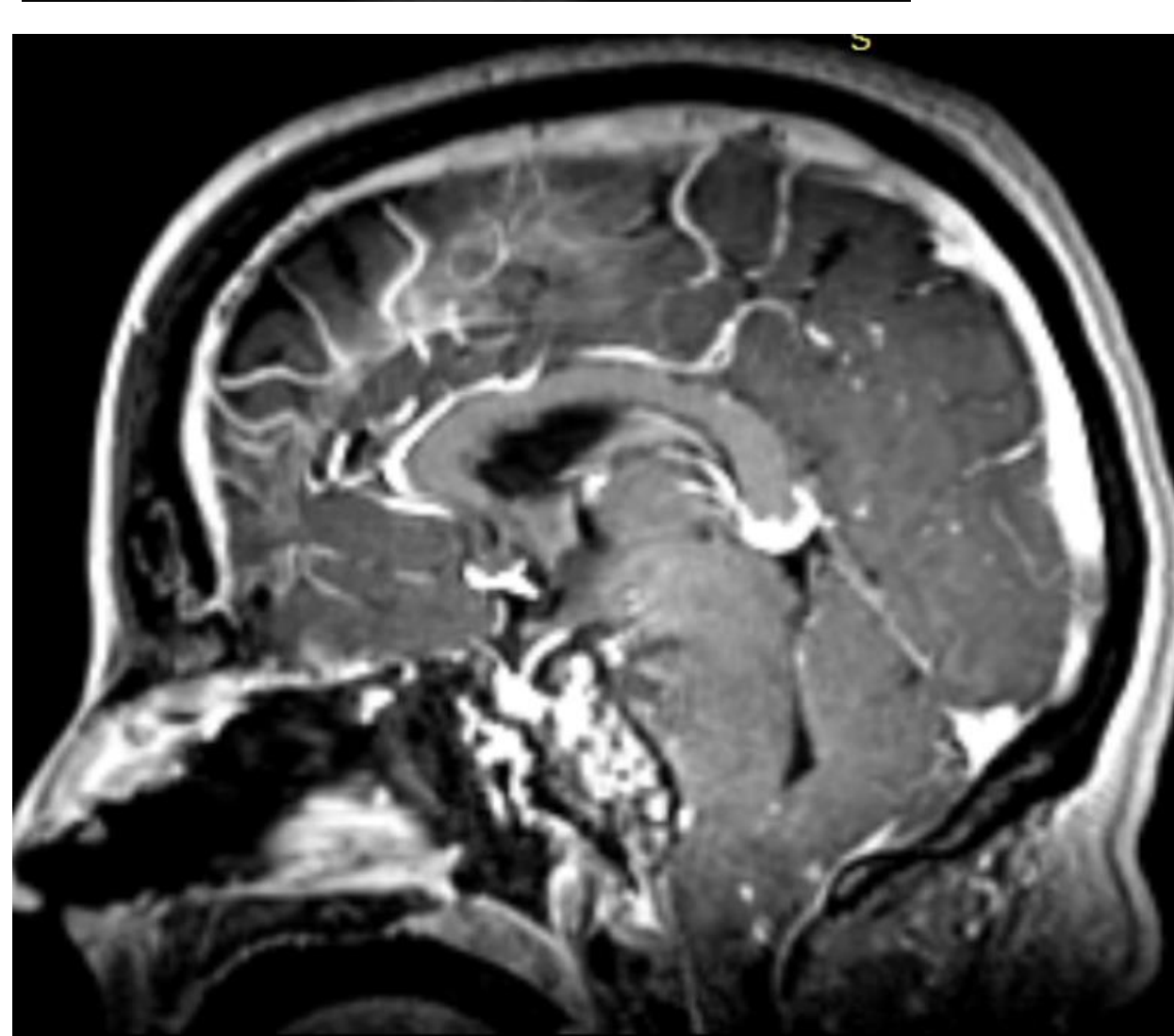
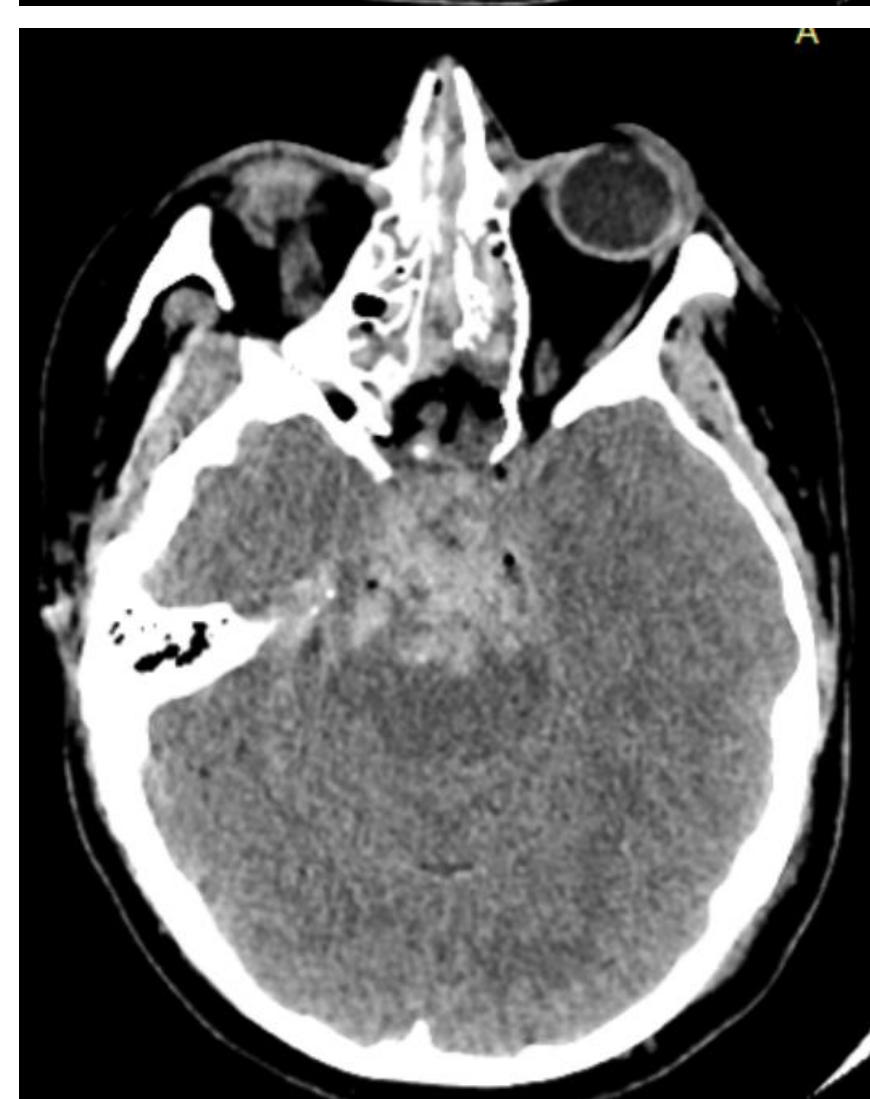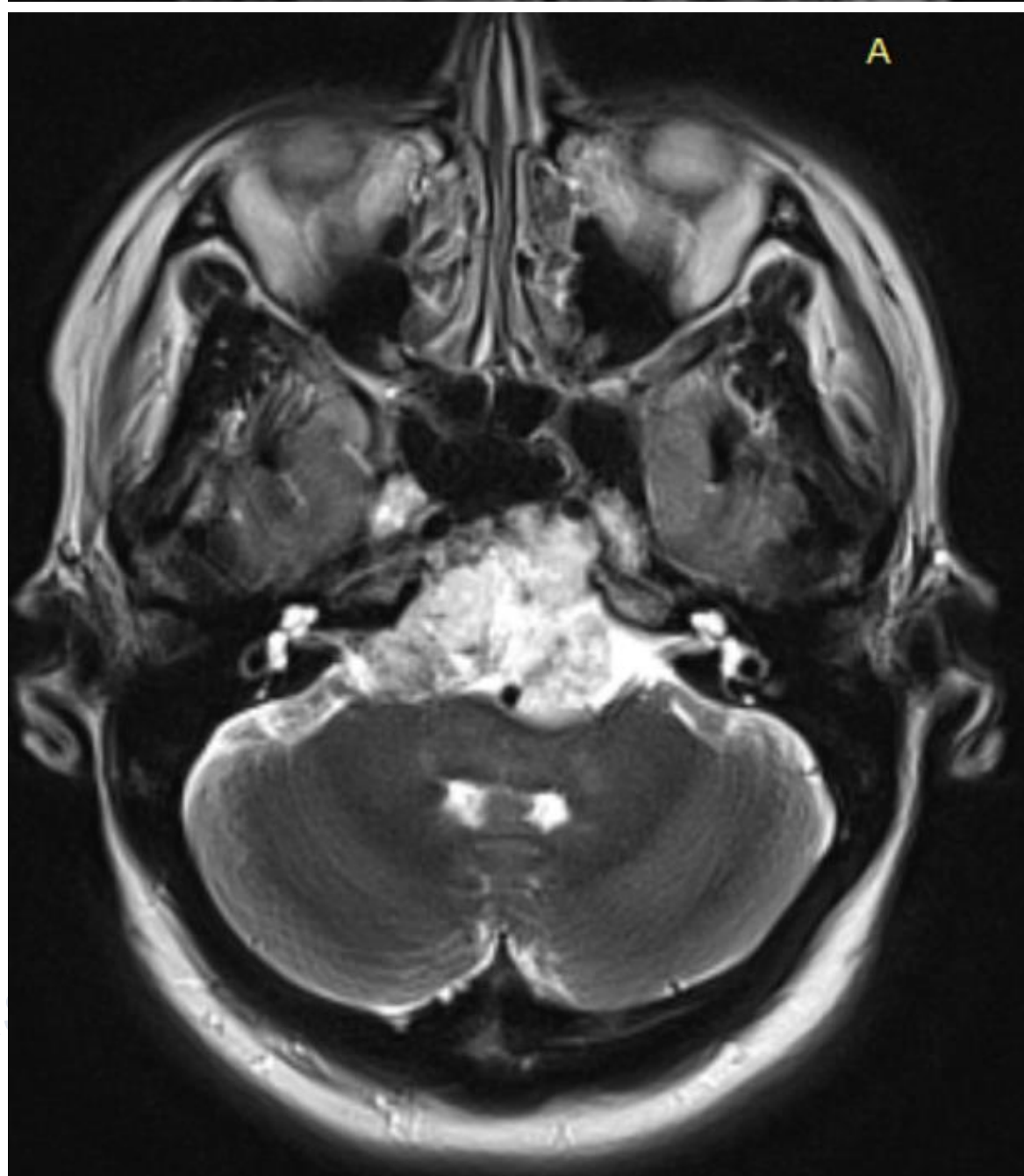
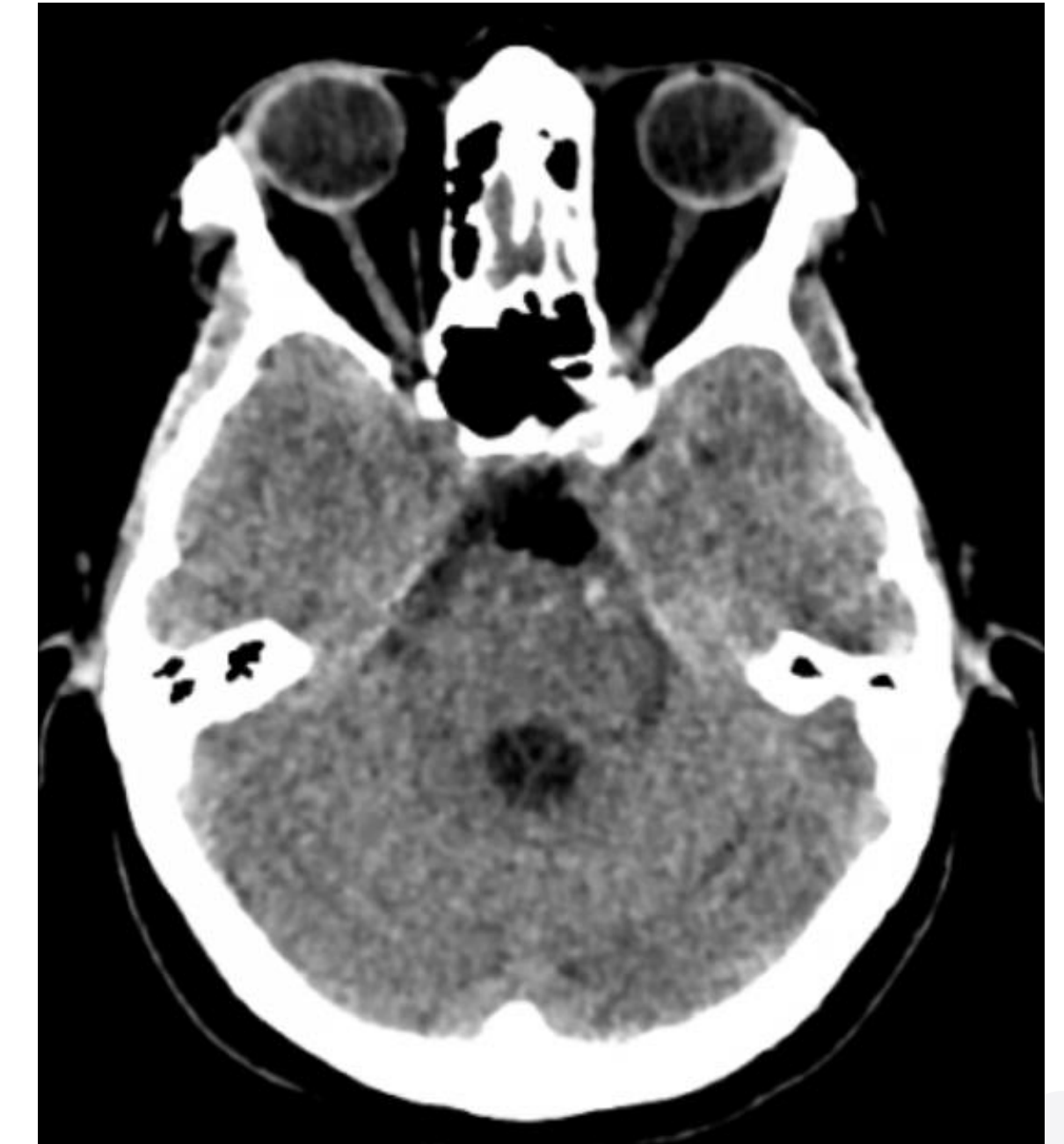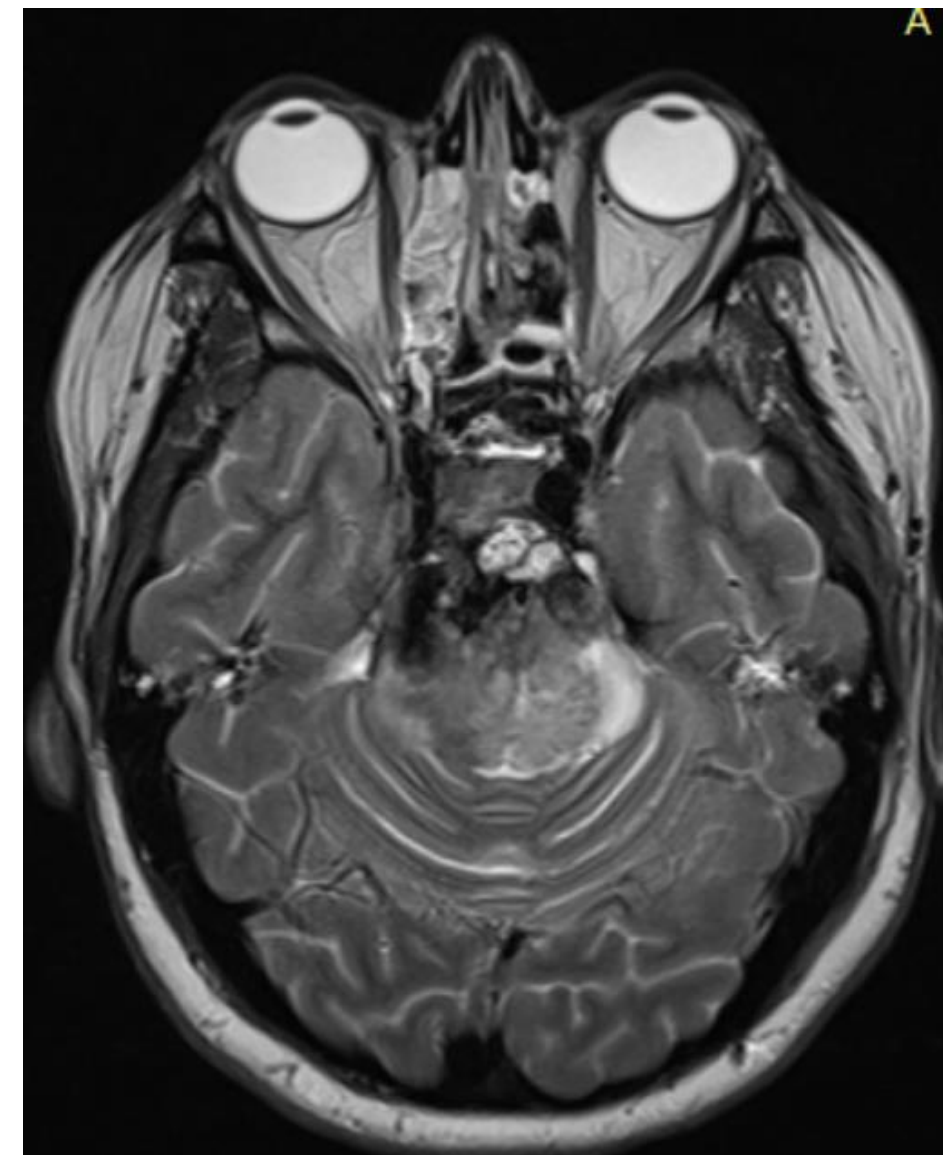
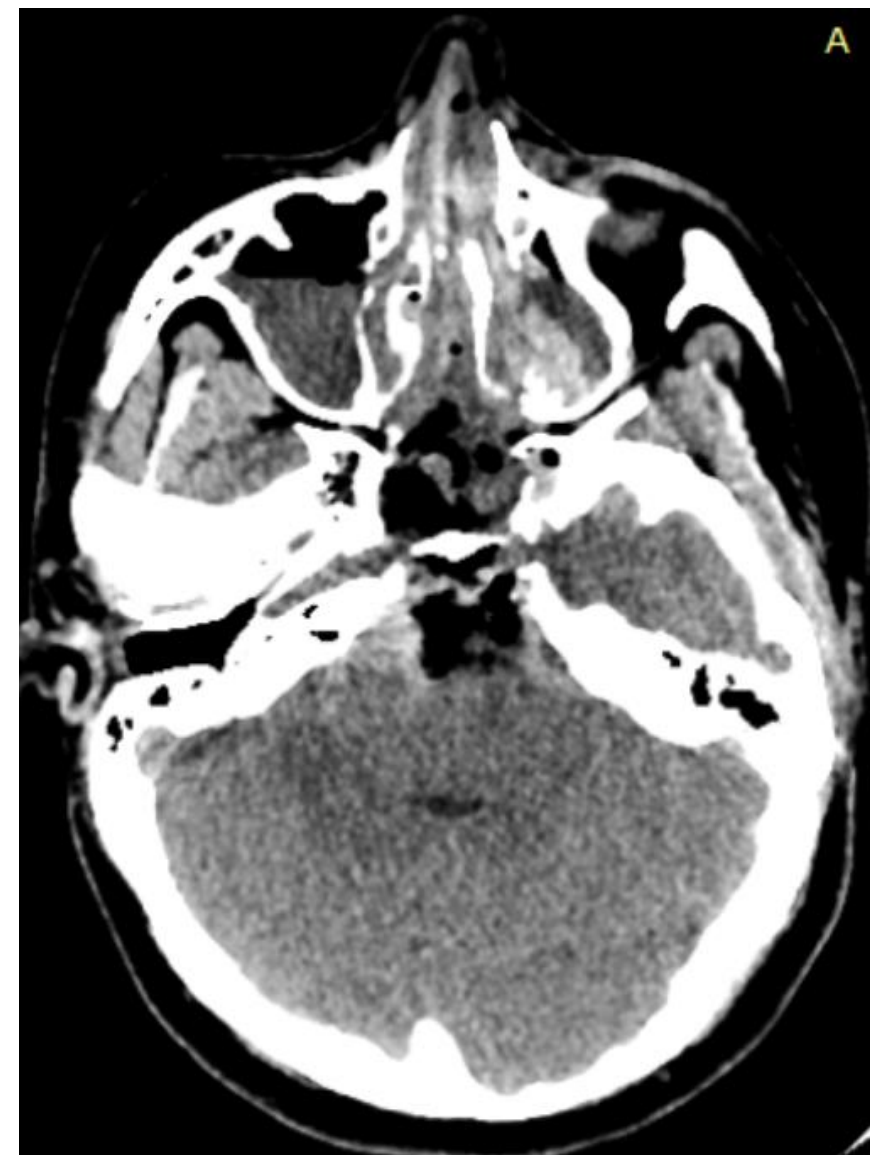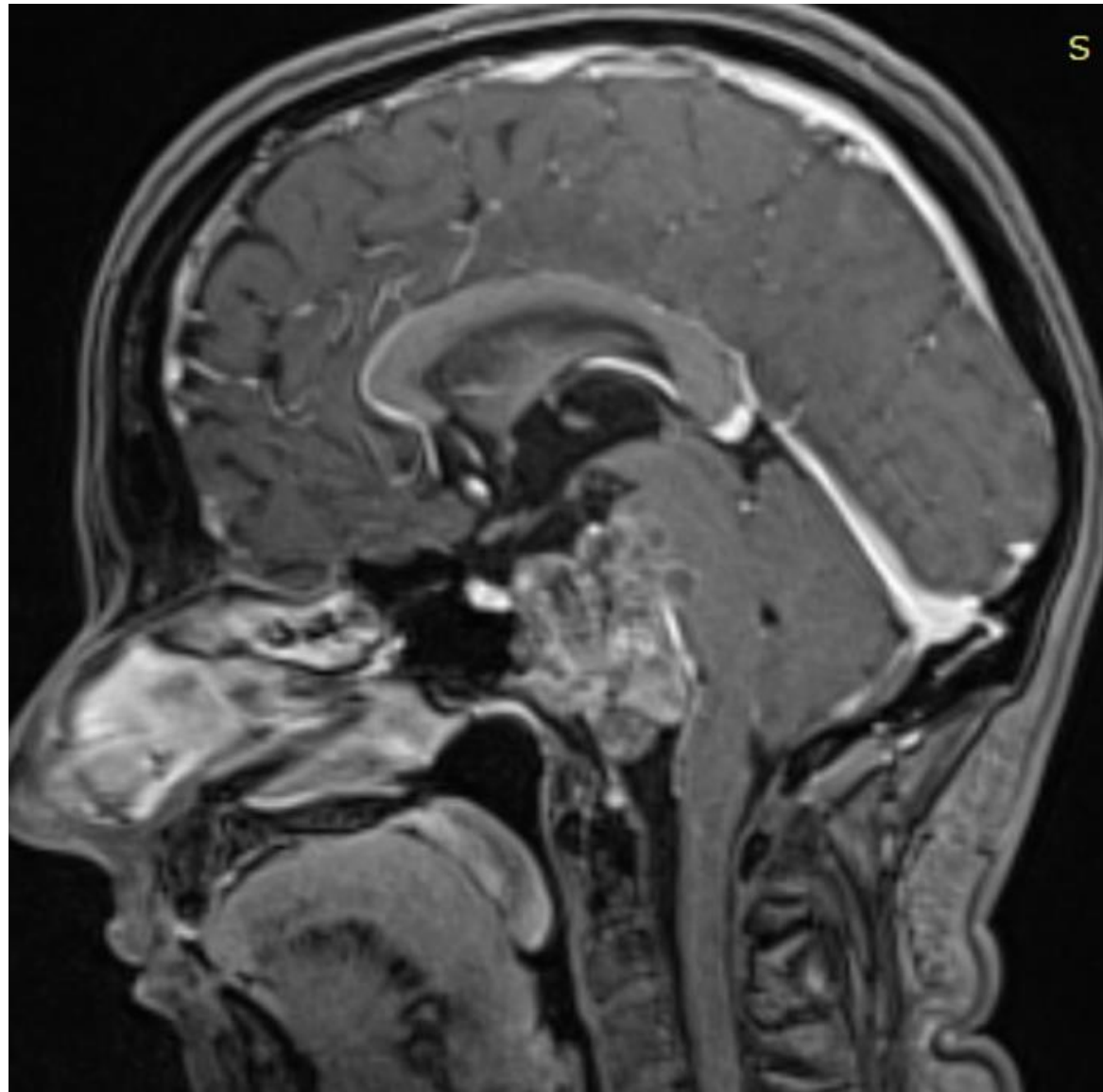


Recidiv clivus chordoma- *Transpterygoid*



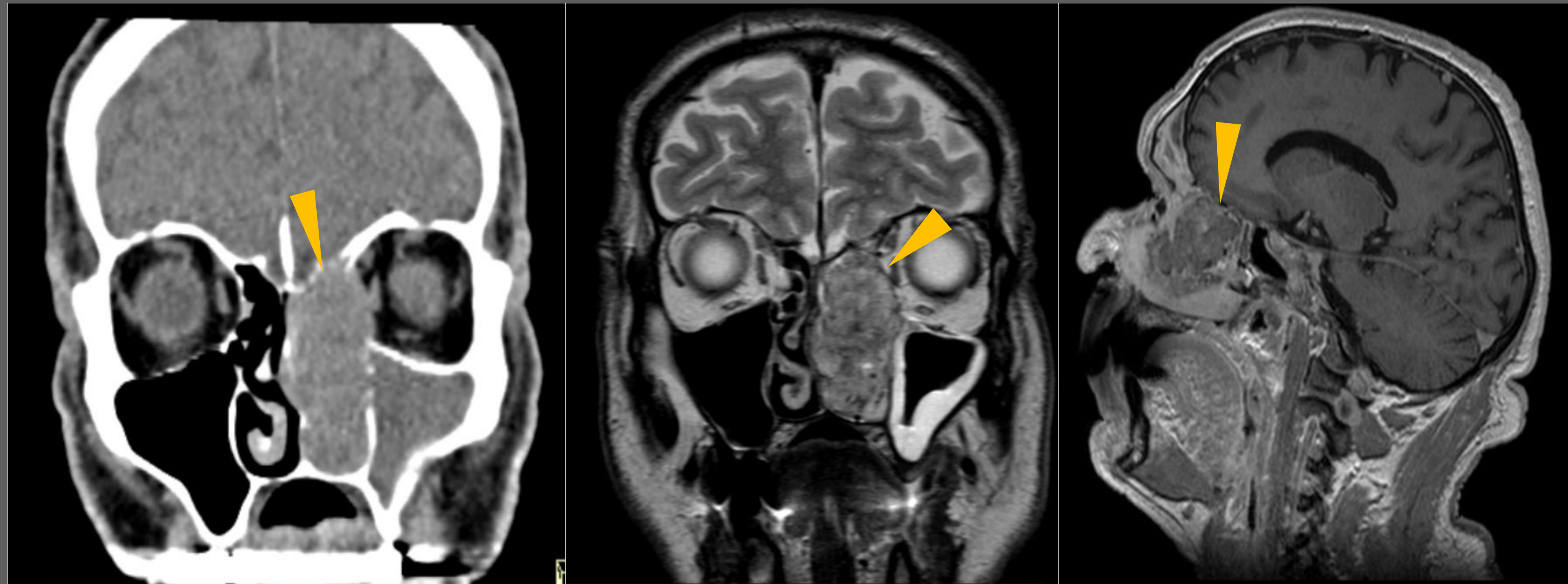
- 56 é nő
 - 1. superciliaris craniotomia: partialis resectio
 - 2. transnasalis mikroszkóp: partialis resectio
 - 3. Proton sugárterápia
 - 4. Convexitas drop metastasis eltávolítás
 - Residuum progressio: oculomotorius plegia
- Radikális endoscopos transnasalis resectio

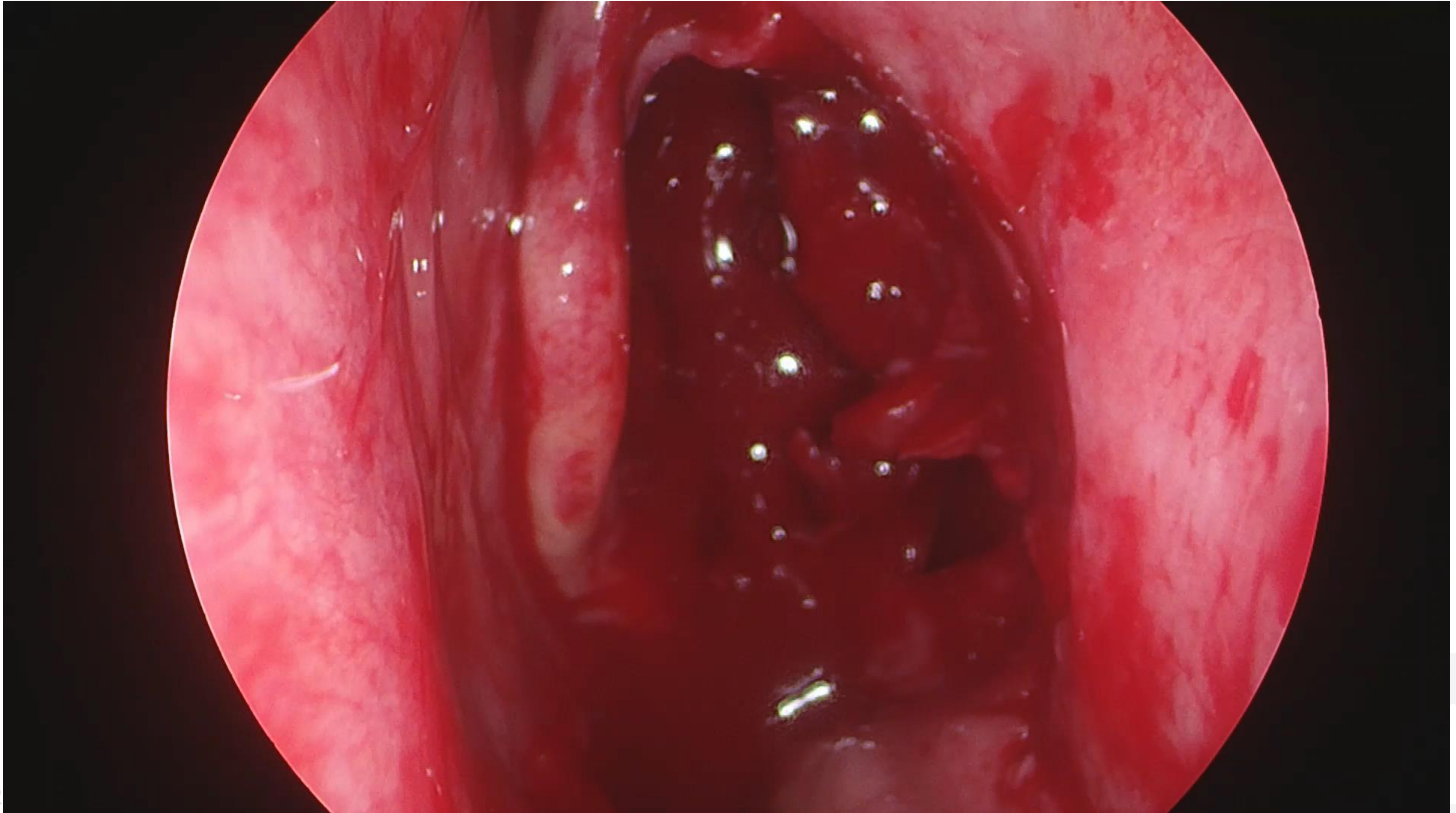
Invasiv clivus chordoma



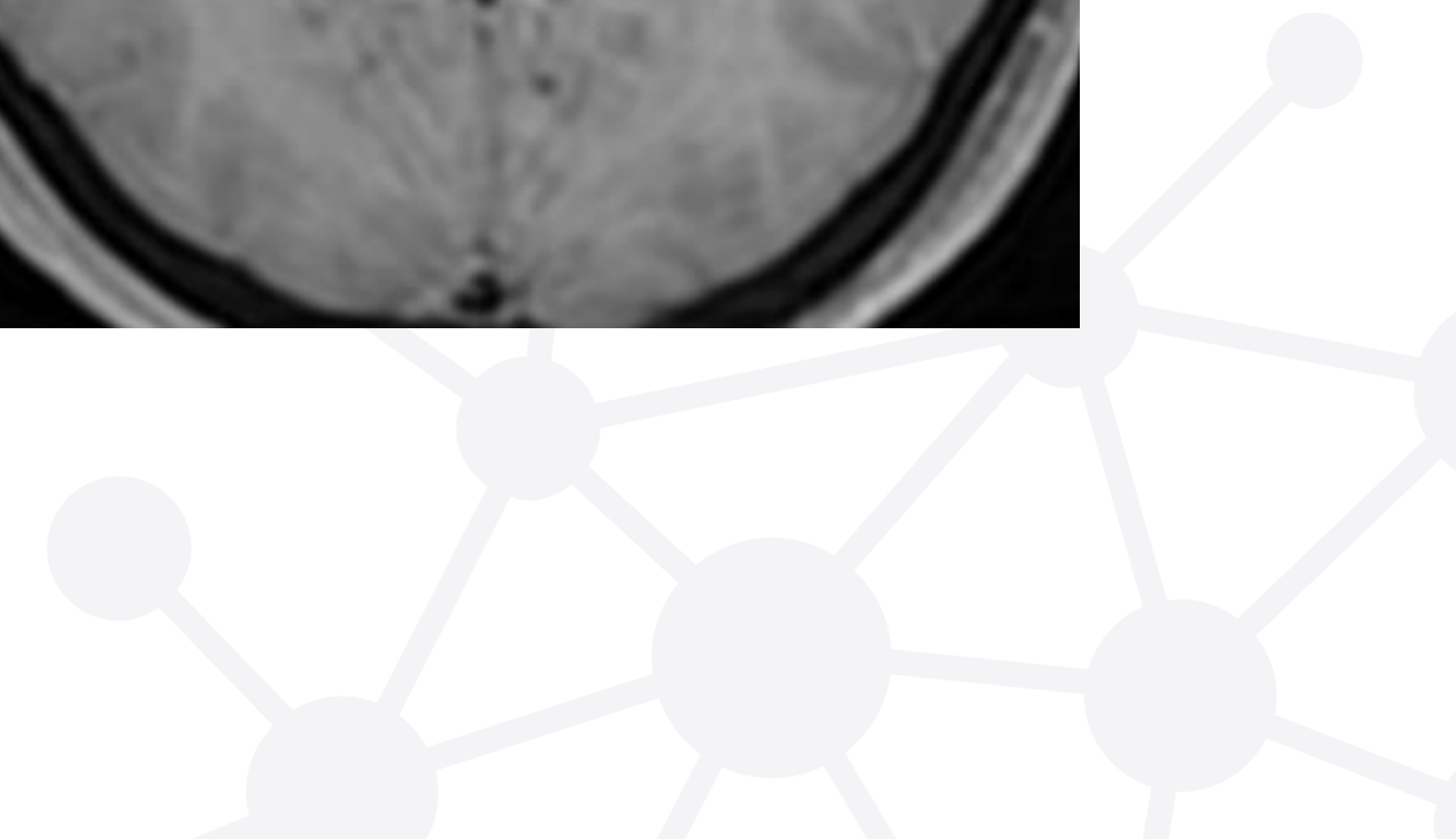
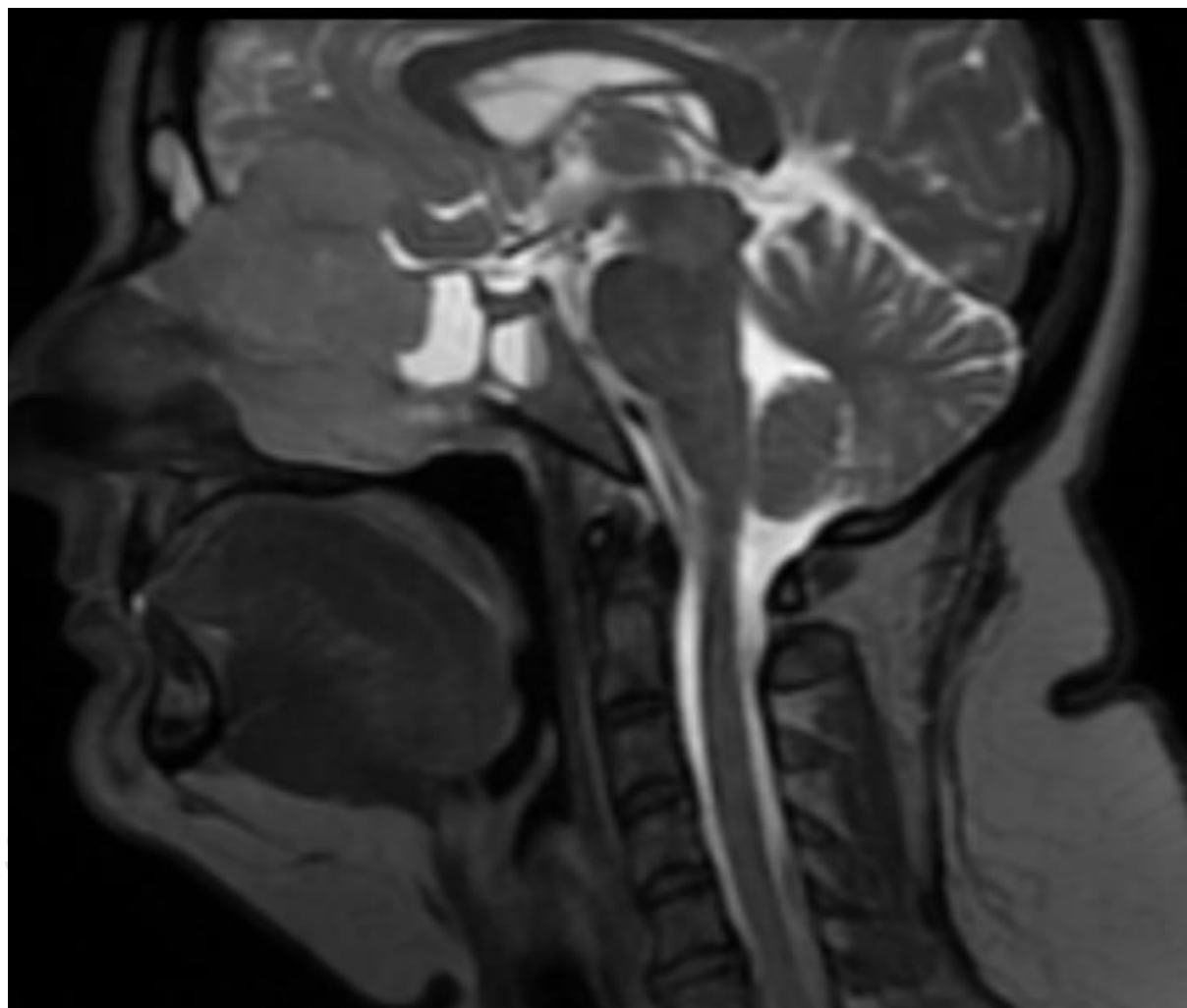
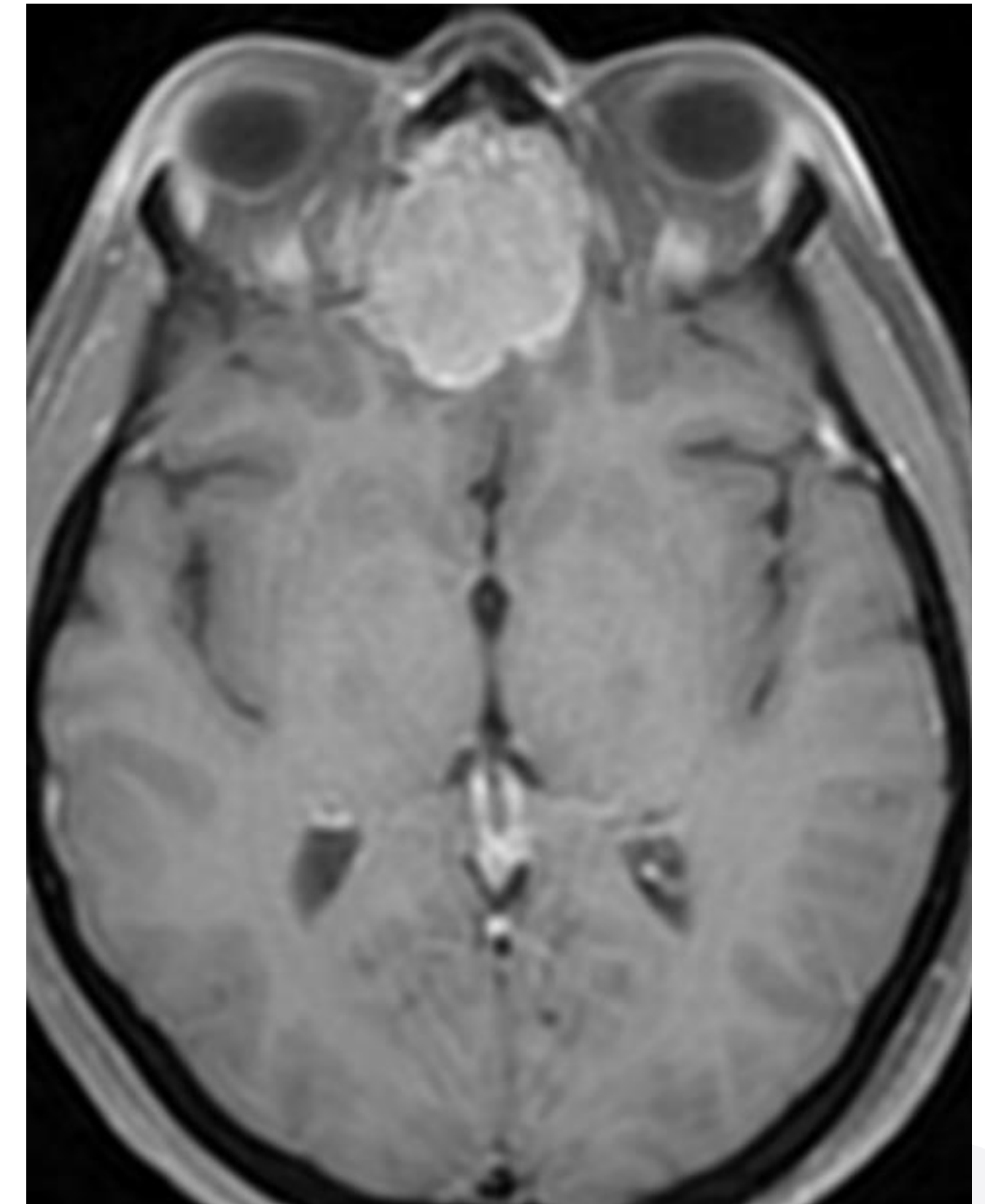
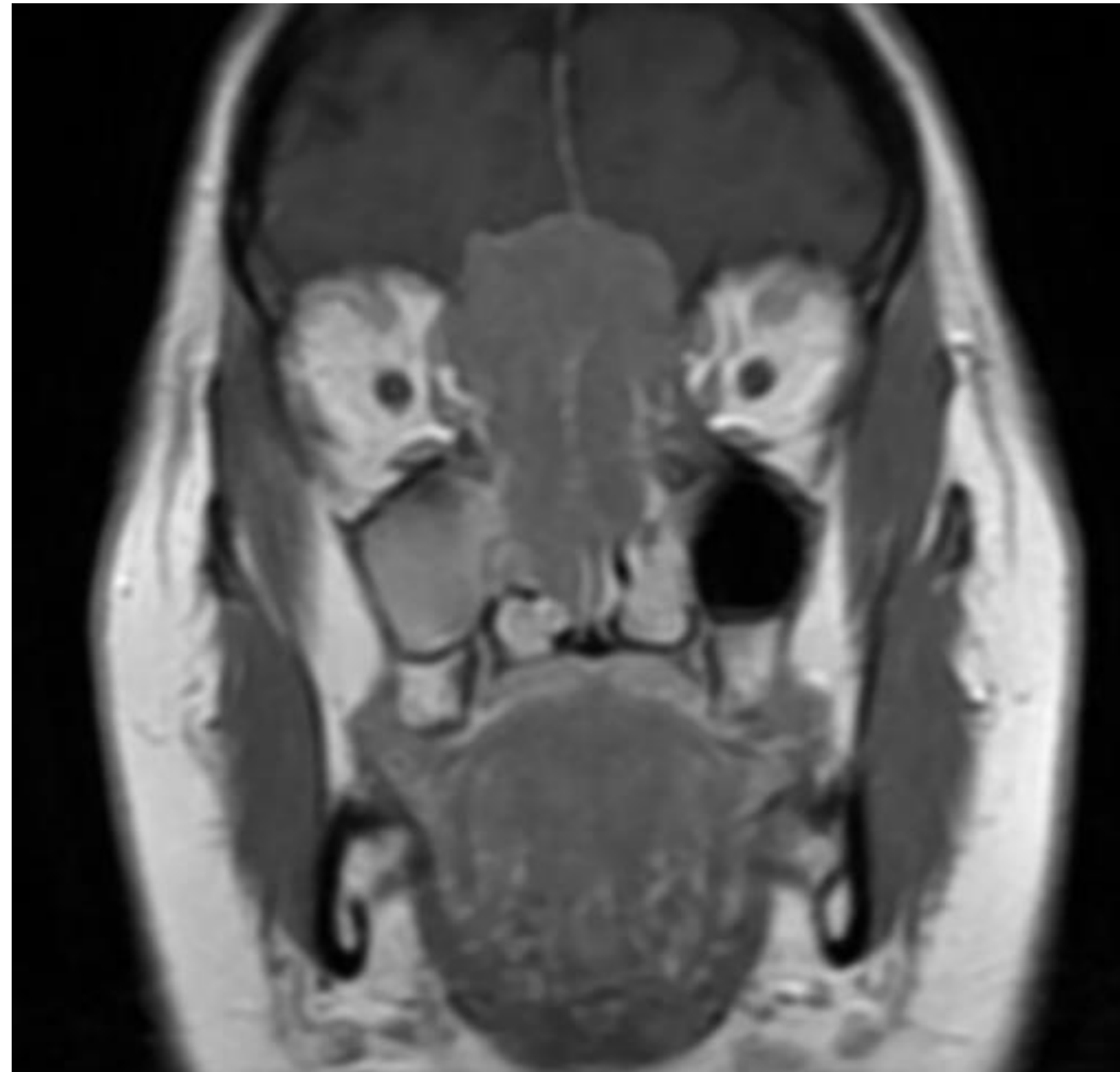
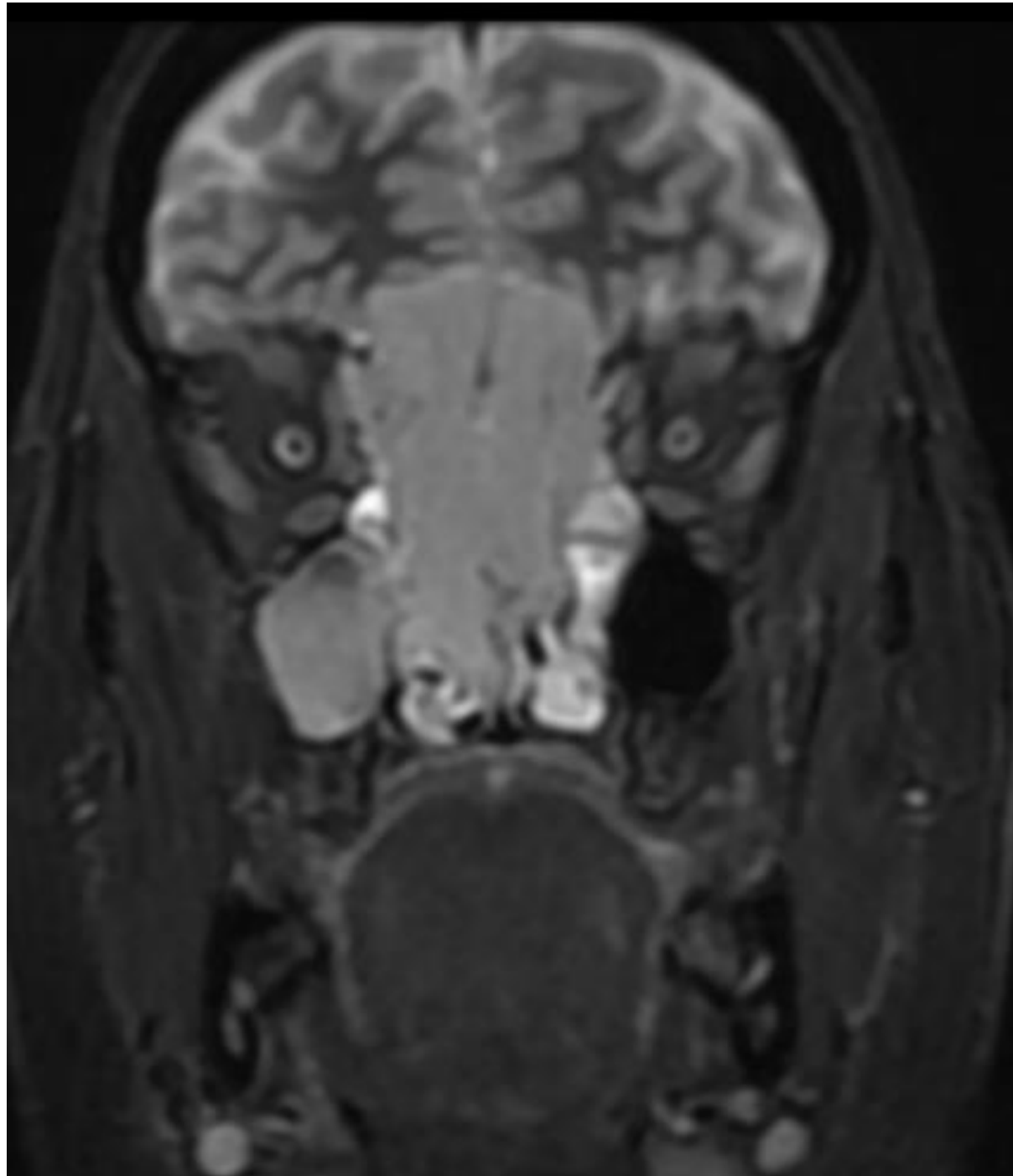
Szövettan megbízhatósága

- 68 éves ff, SNUC hozott lelet
- ICHT 3x, SD
- Műtét (Transcribriform feltárás), histologia: ITAC
- Adjuváns RT

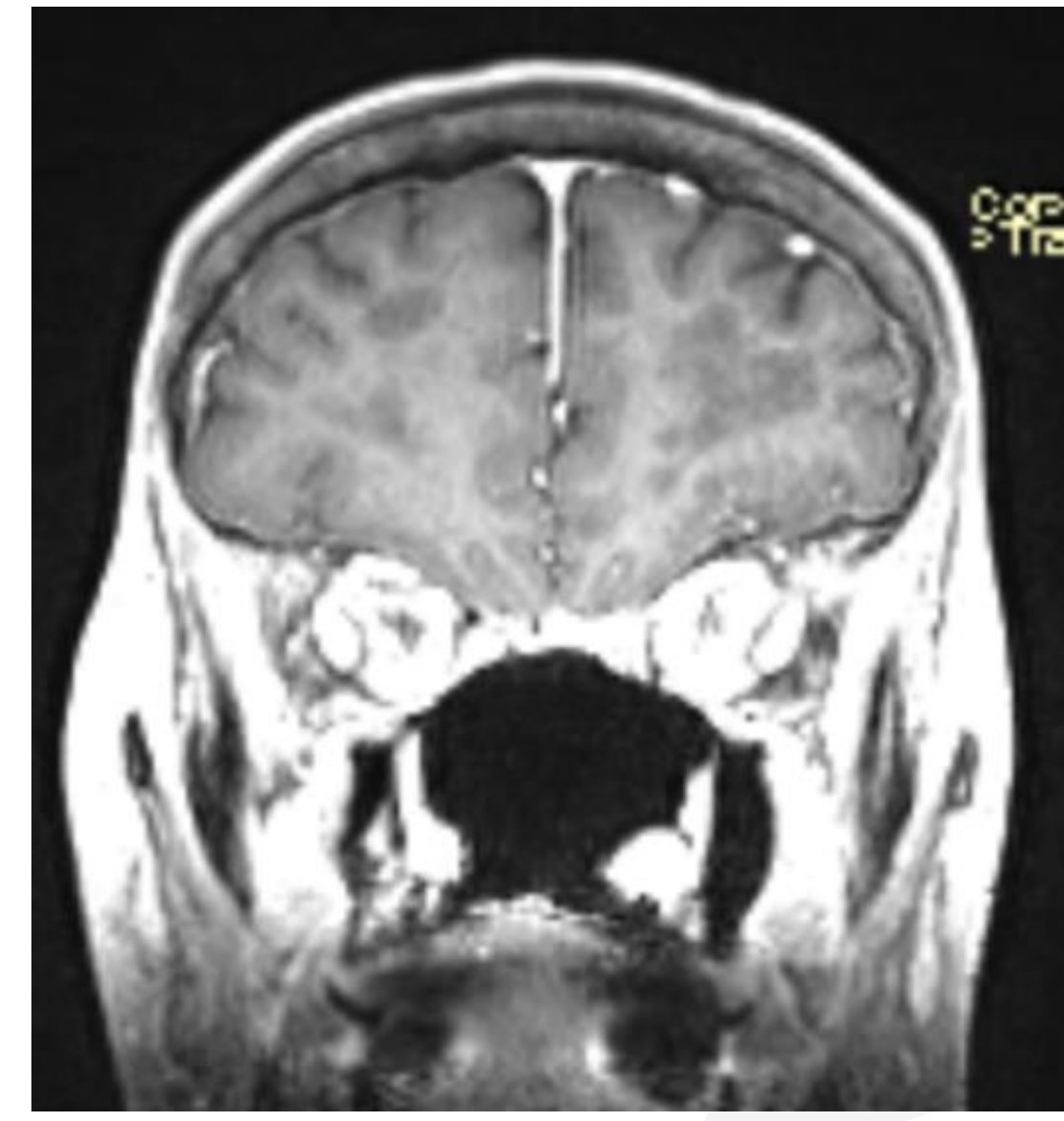
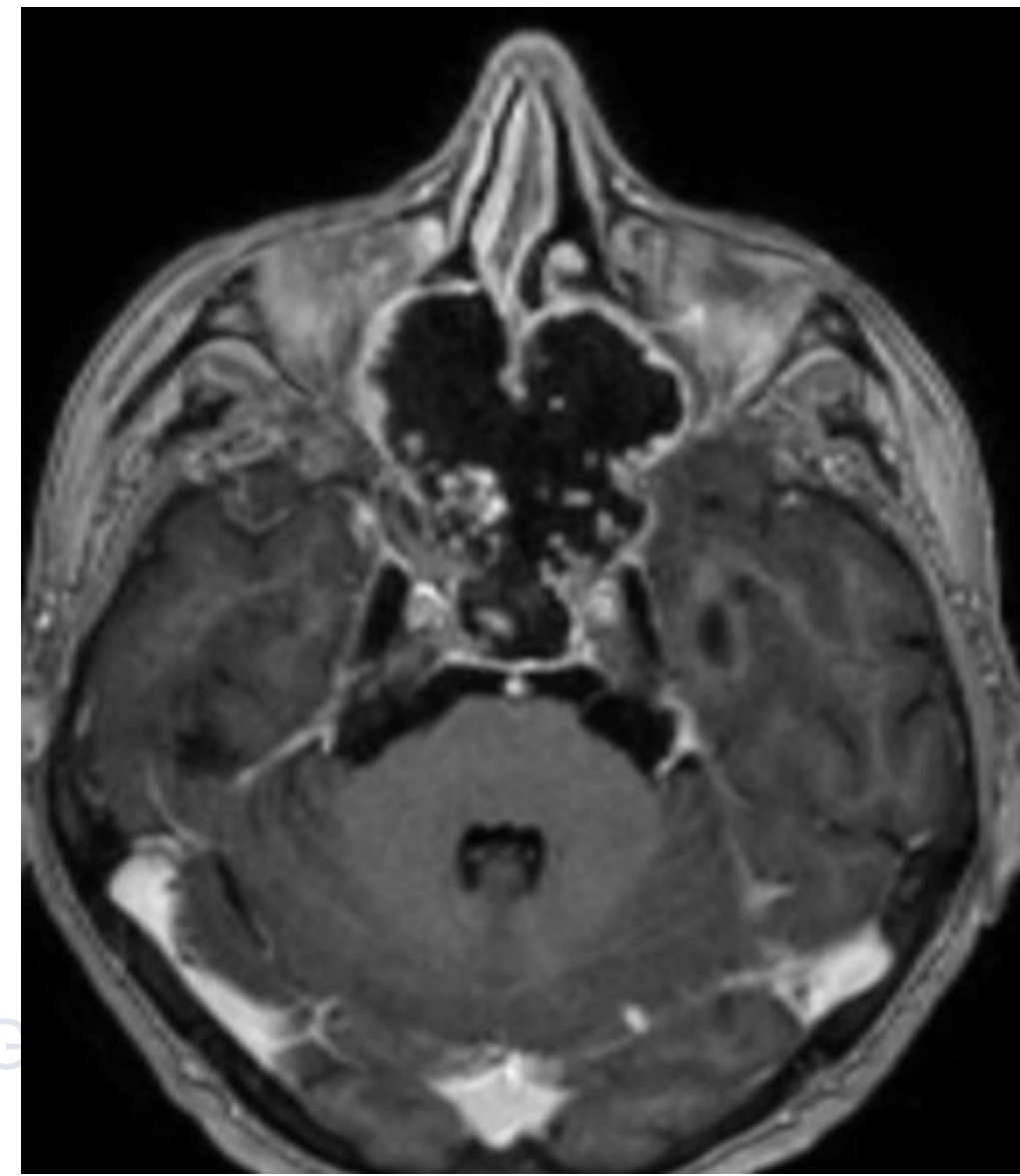
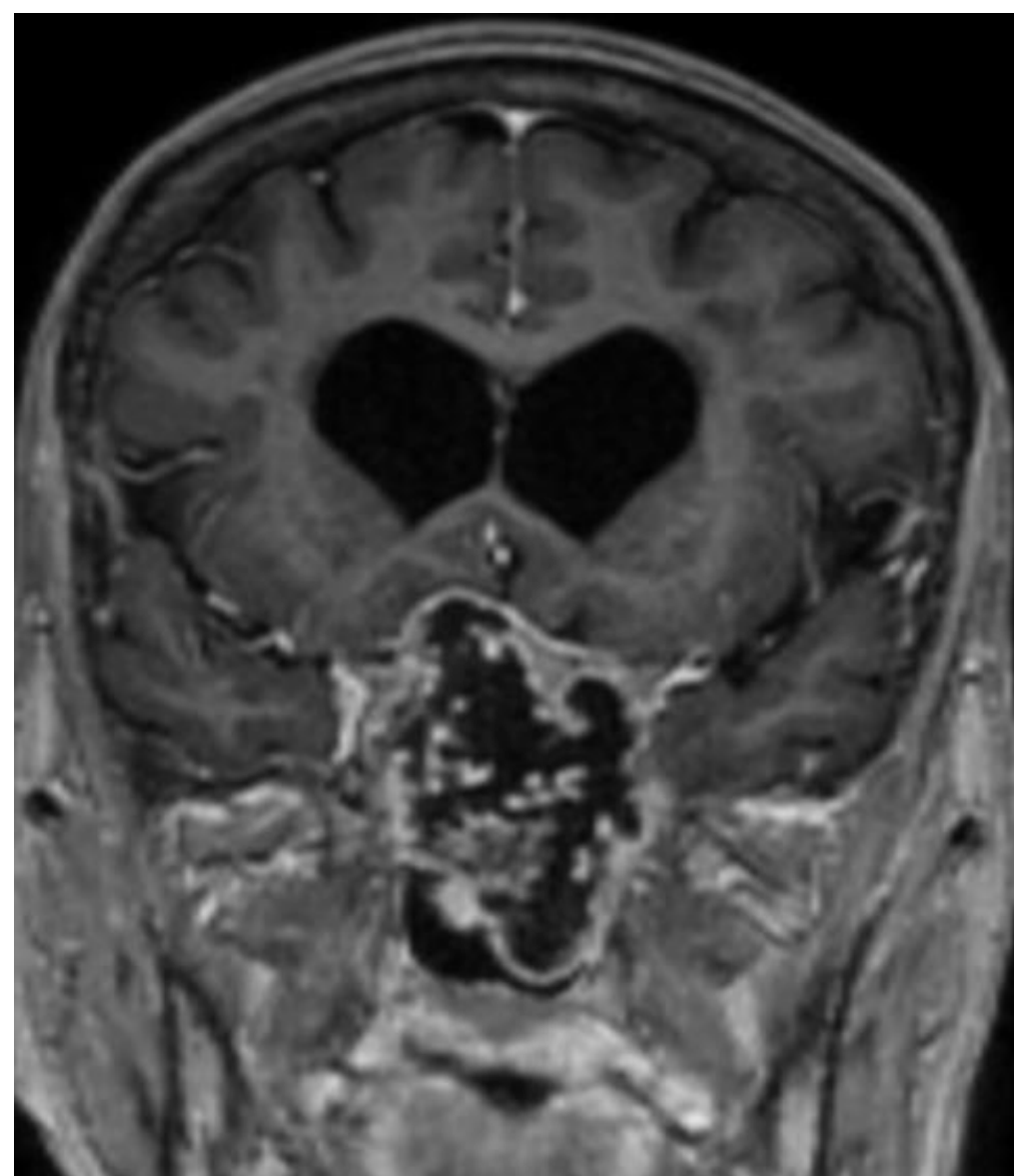
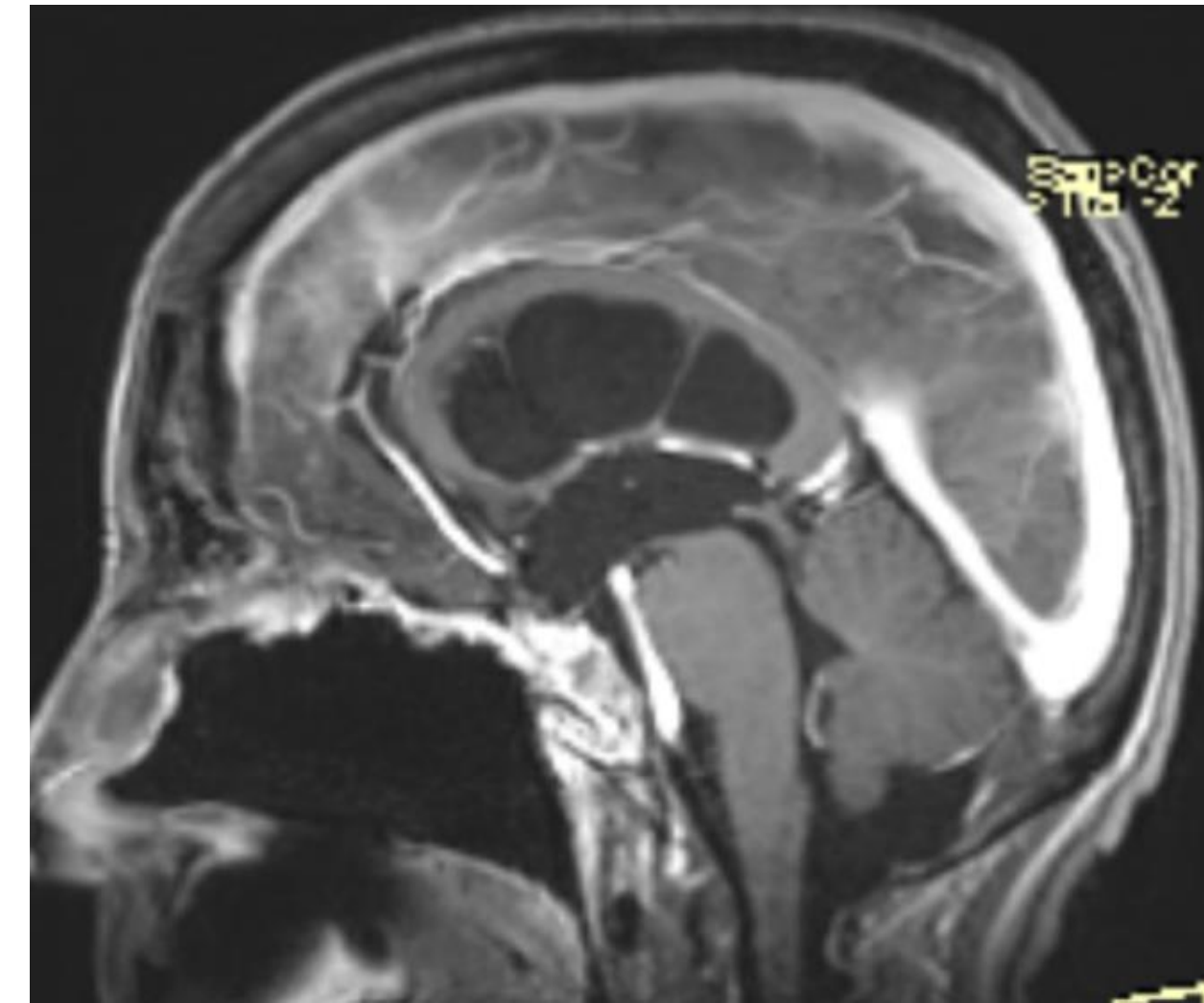
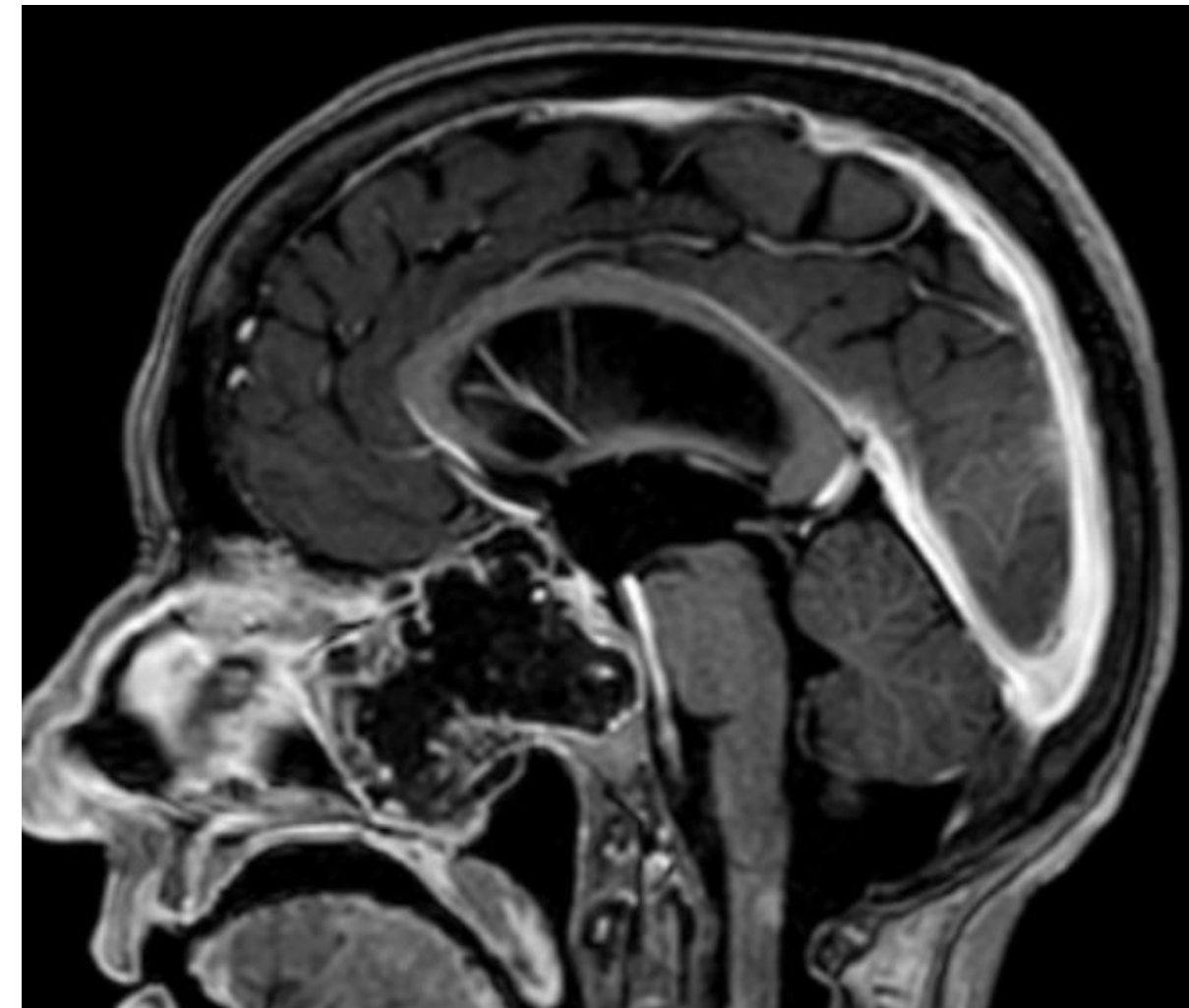
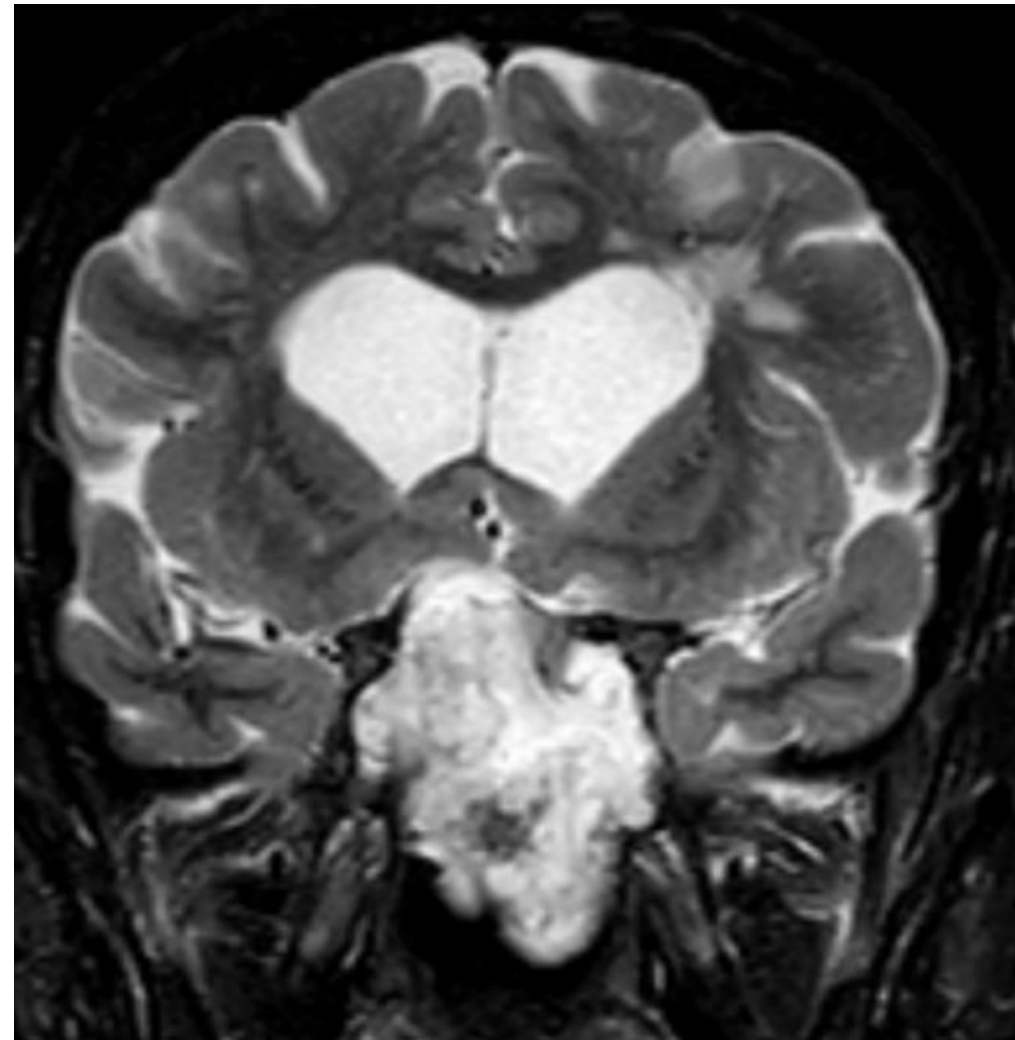




Endoscopos transnasalis határai



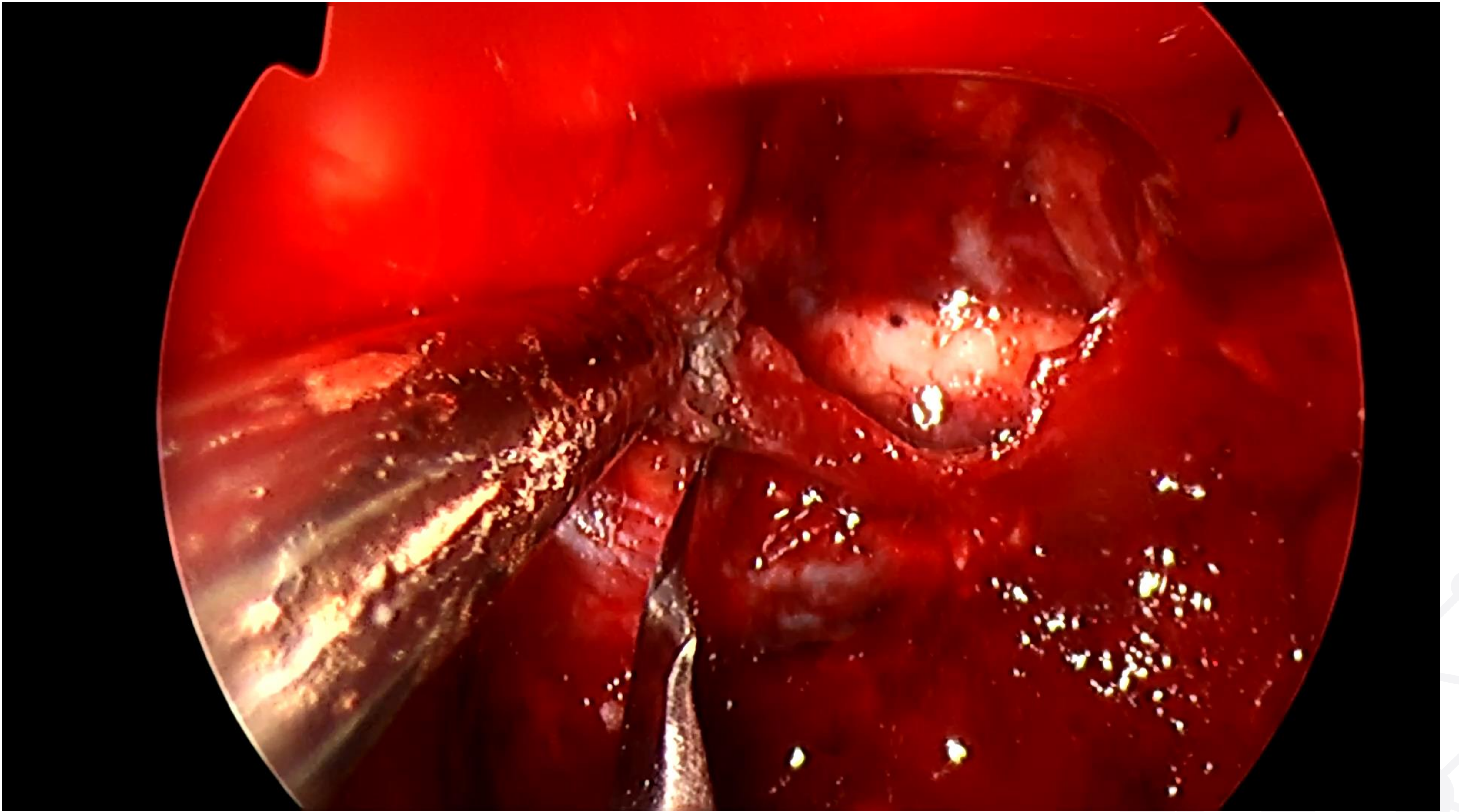
Endoscopos transnasalis határai



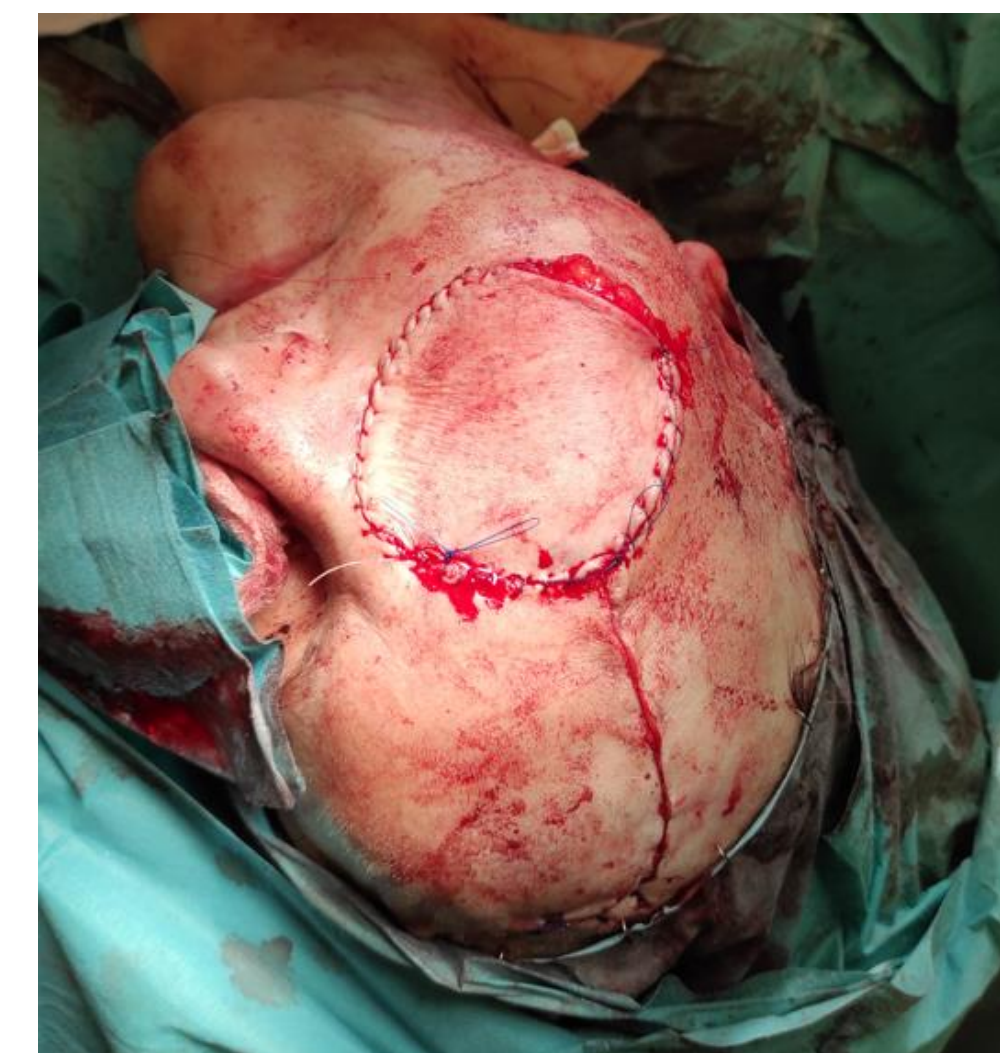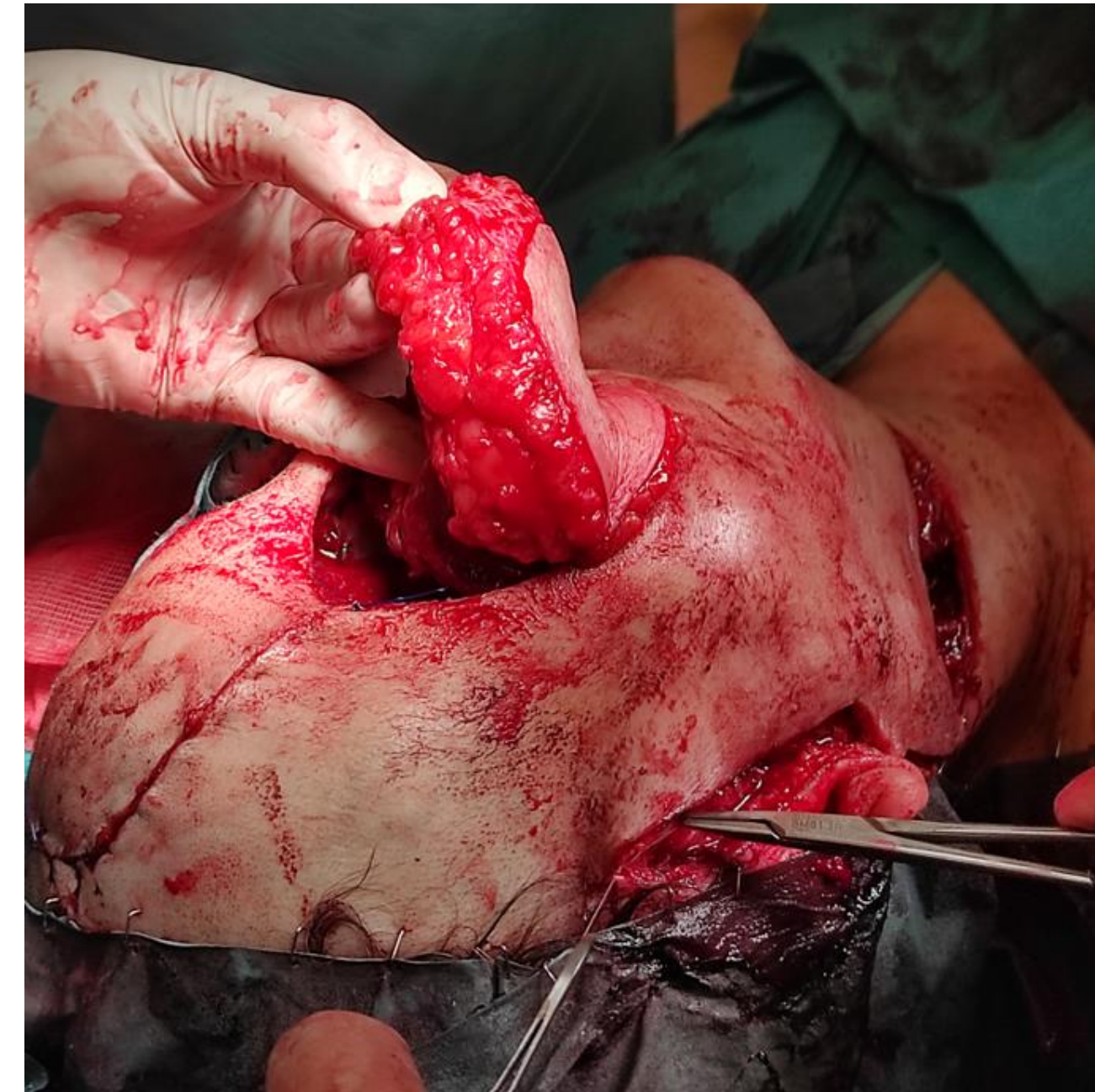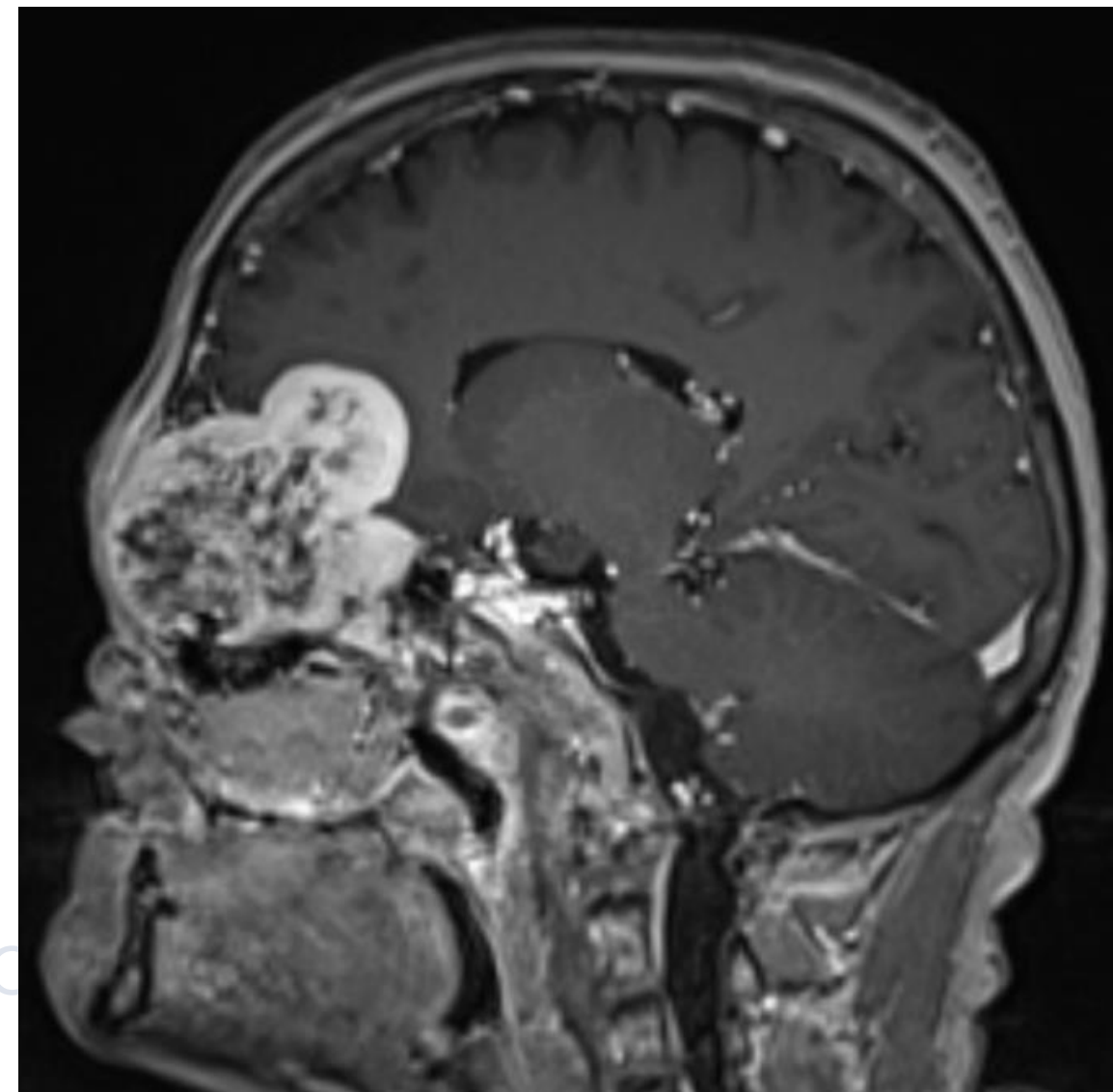
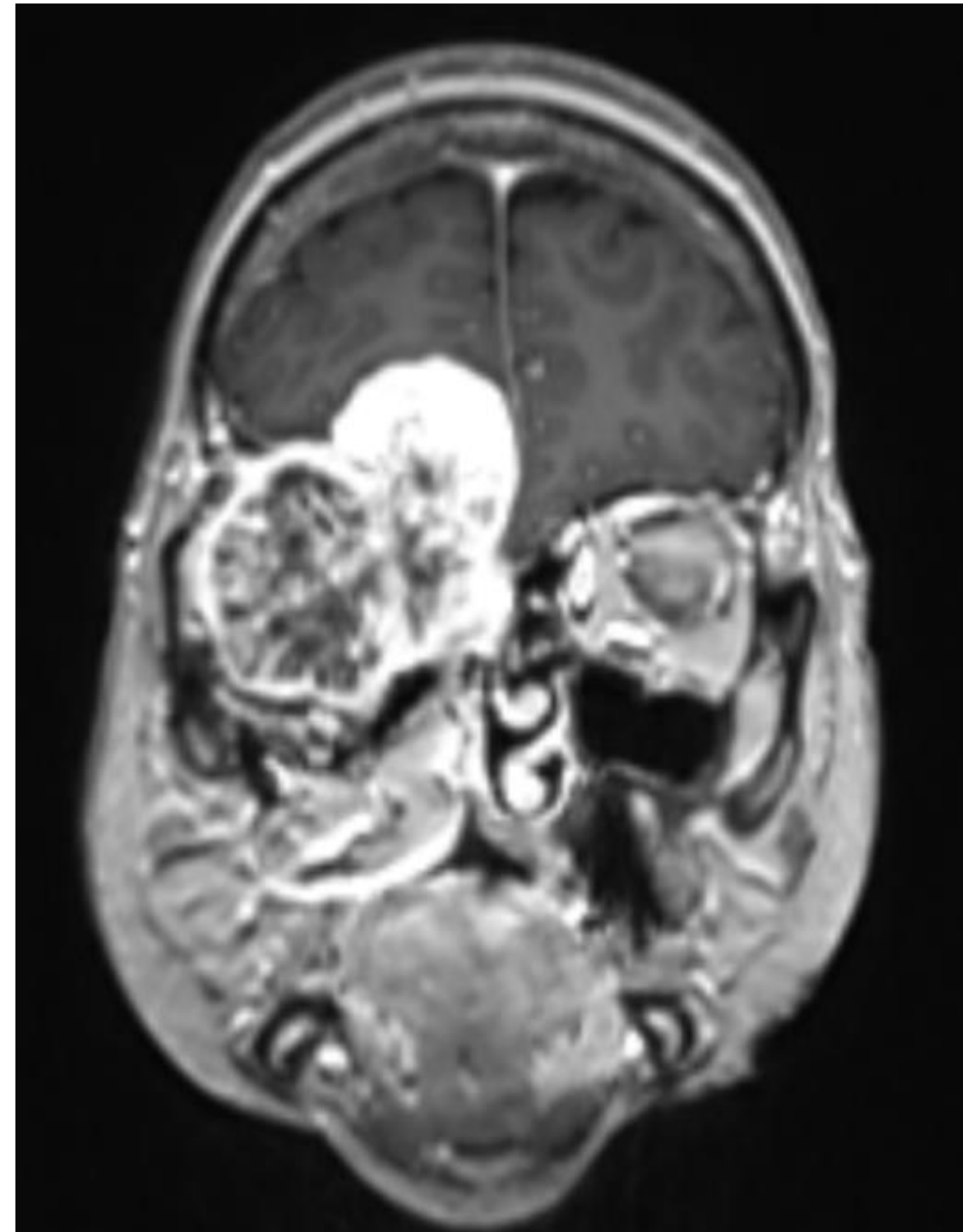
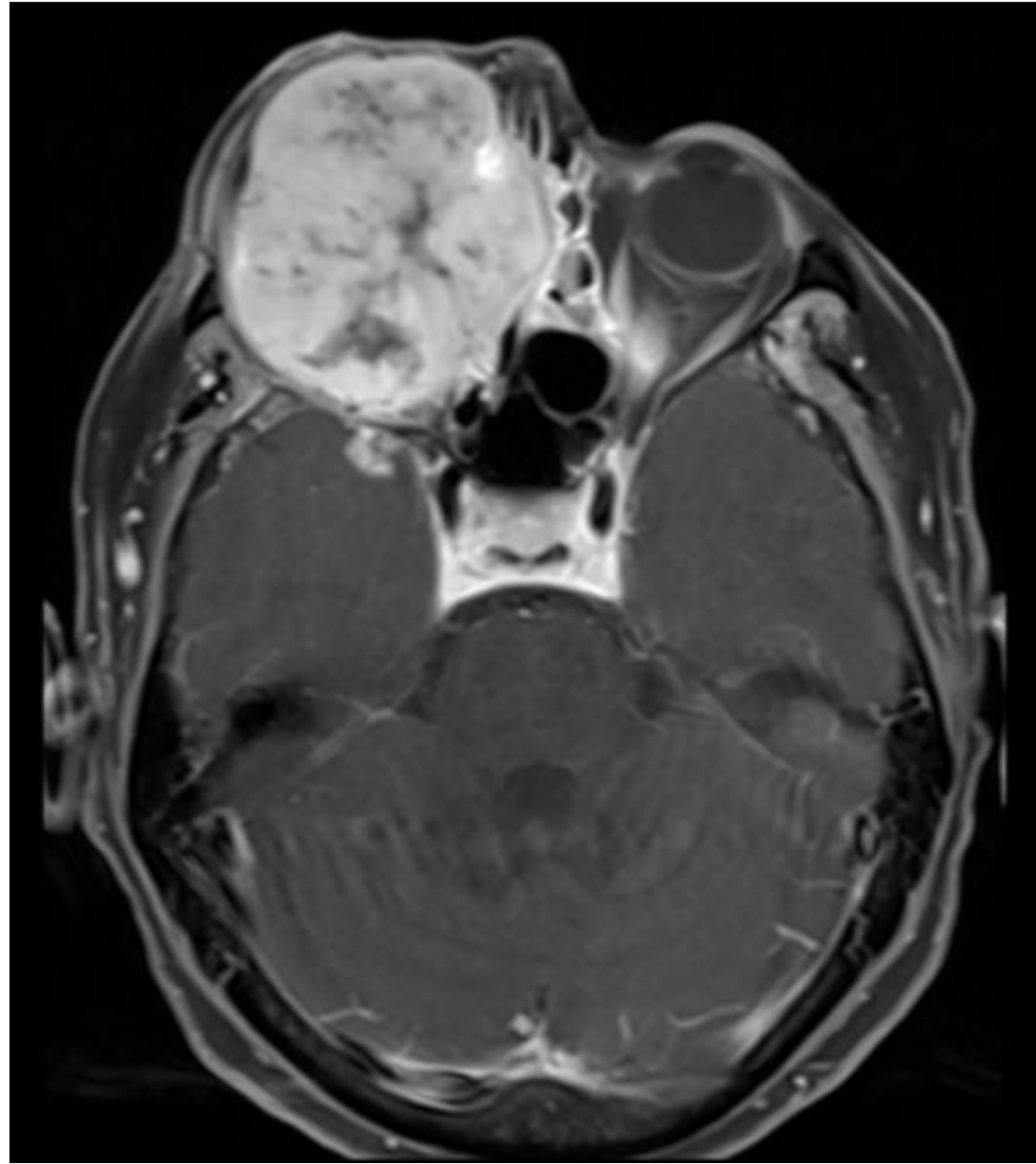
YÓC

NTÉZET

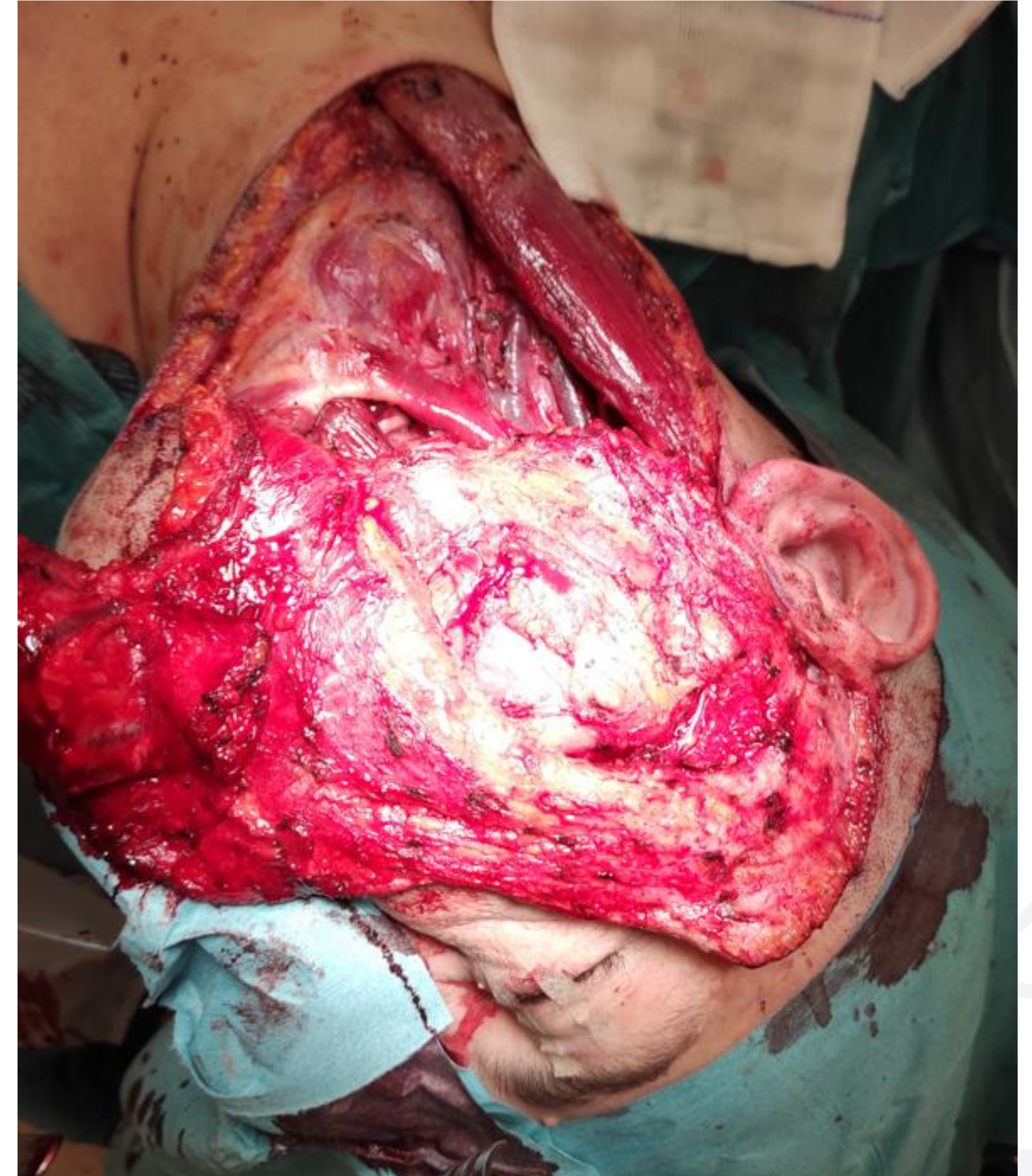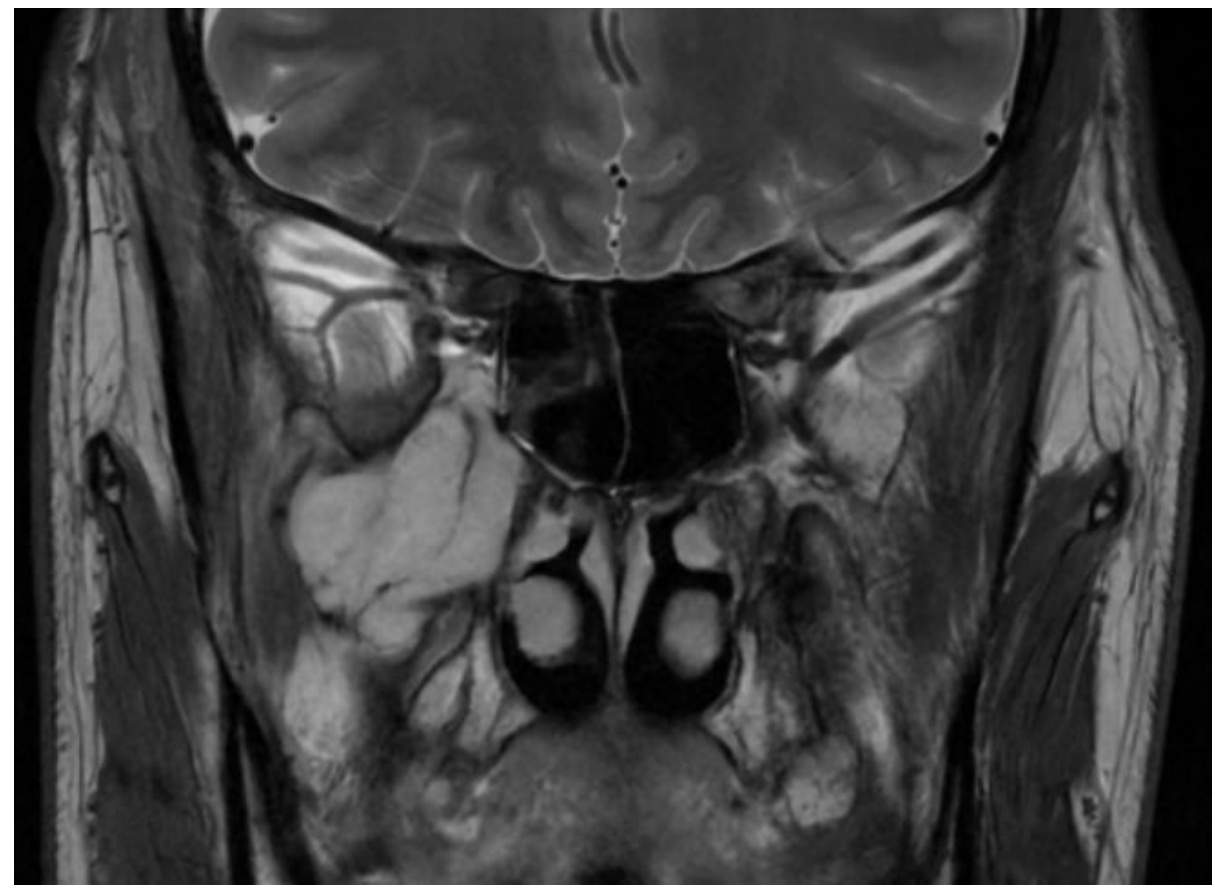
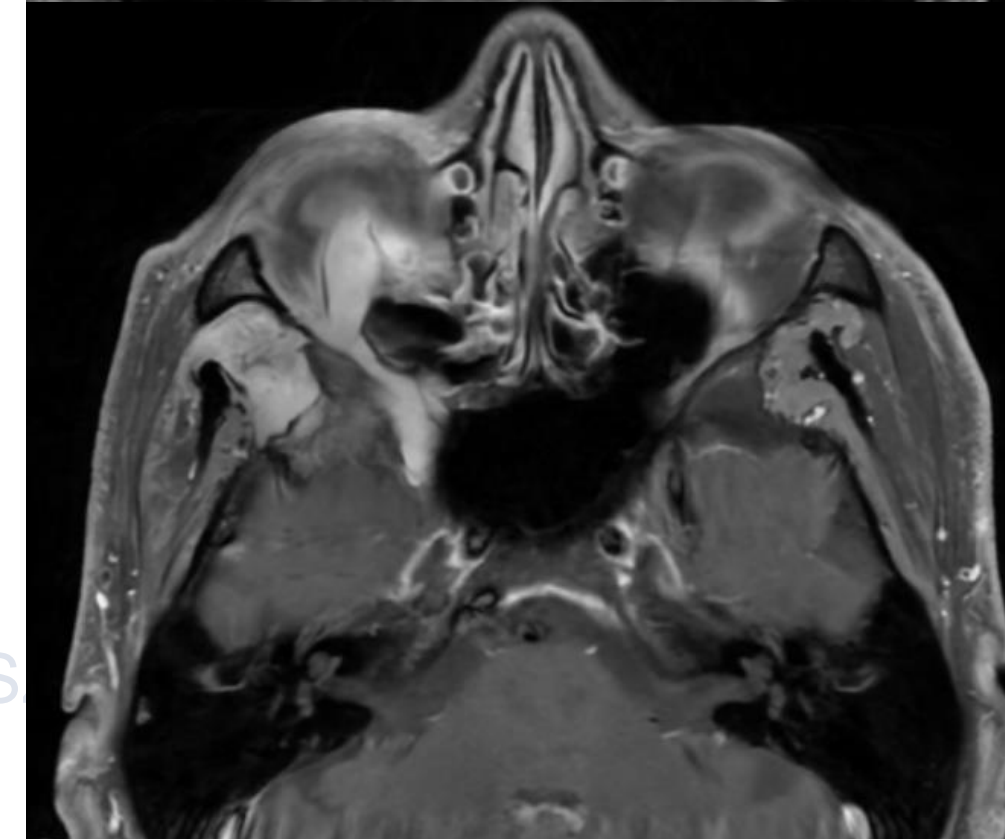
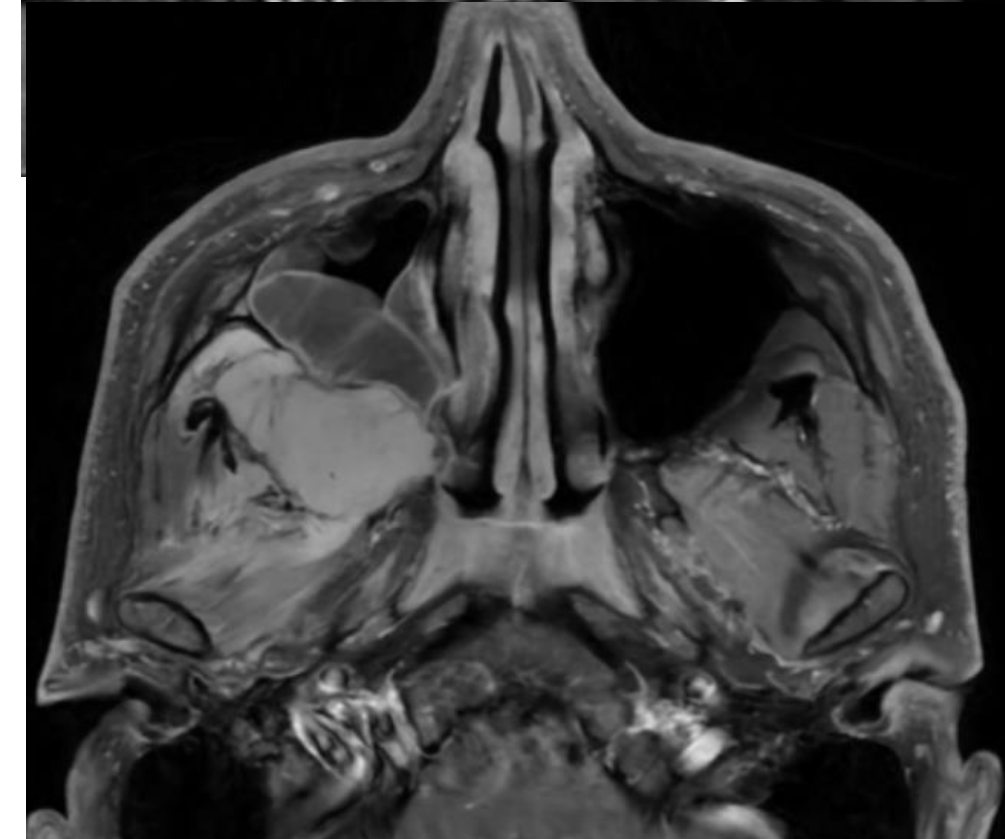
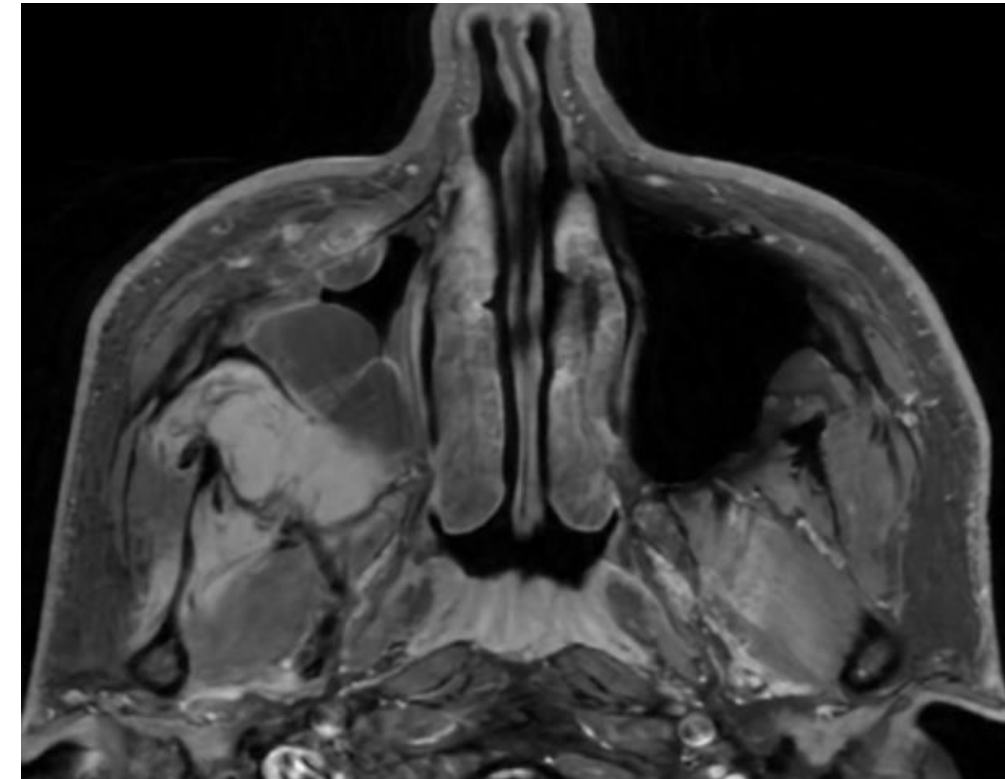
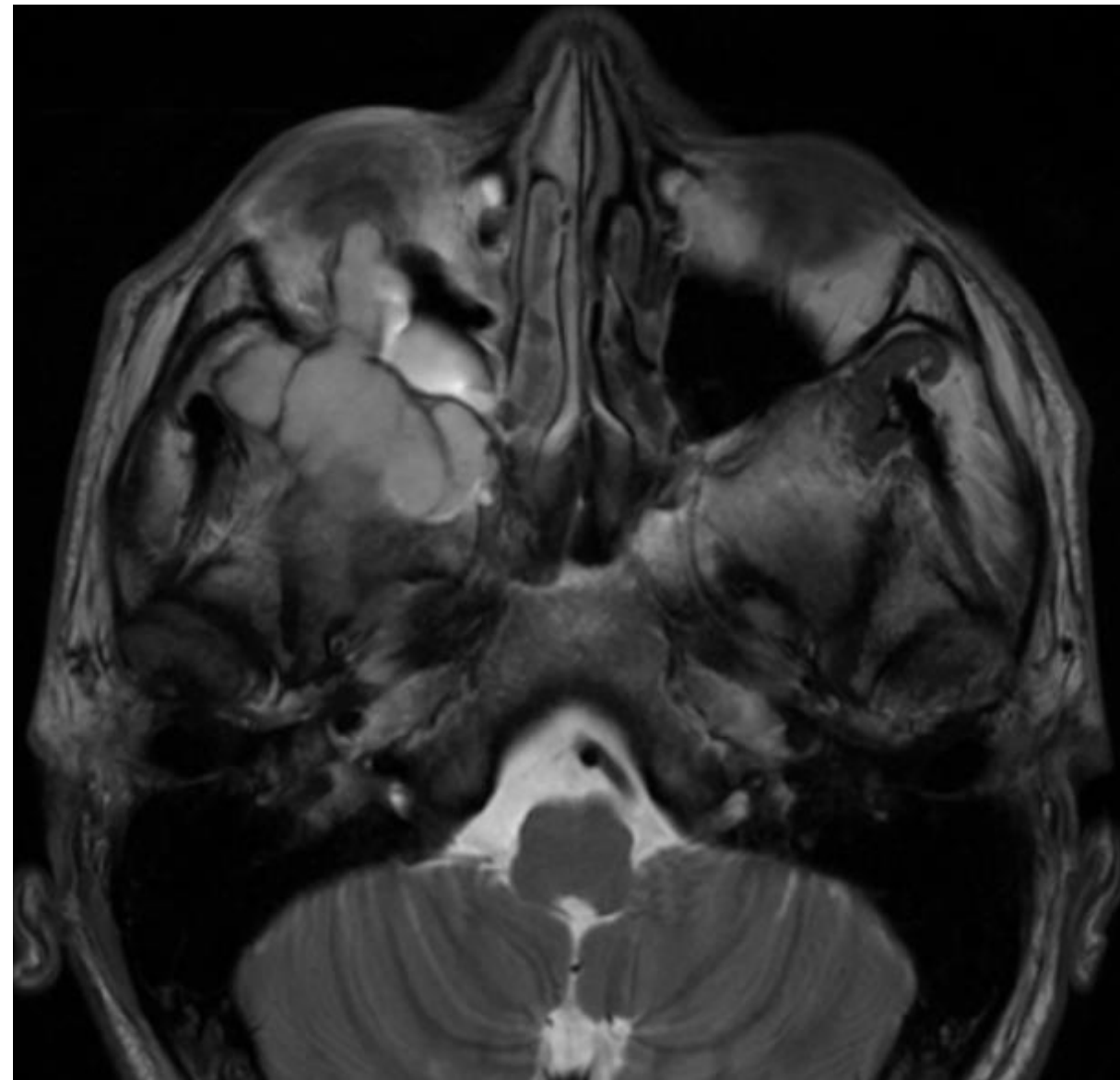




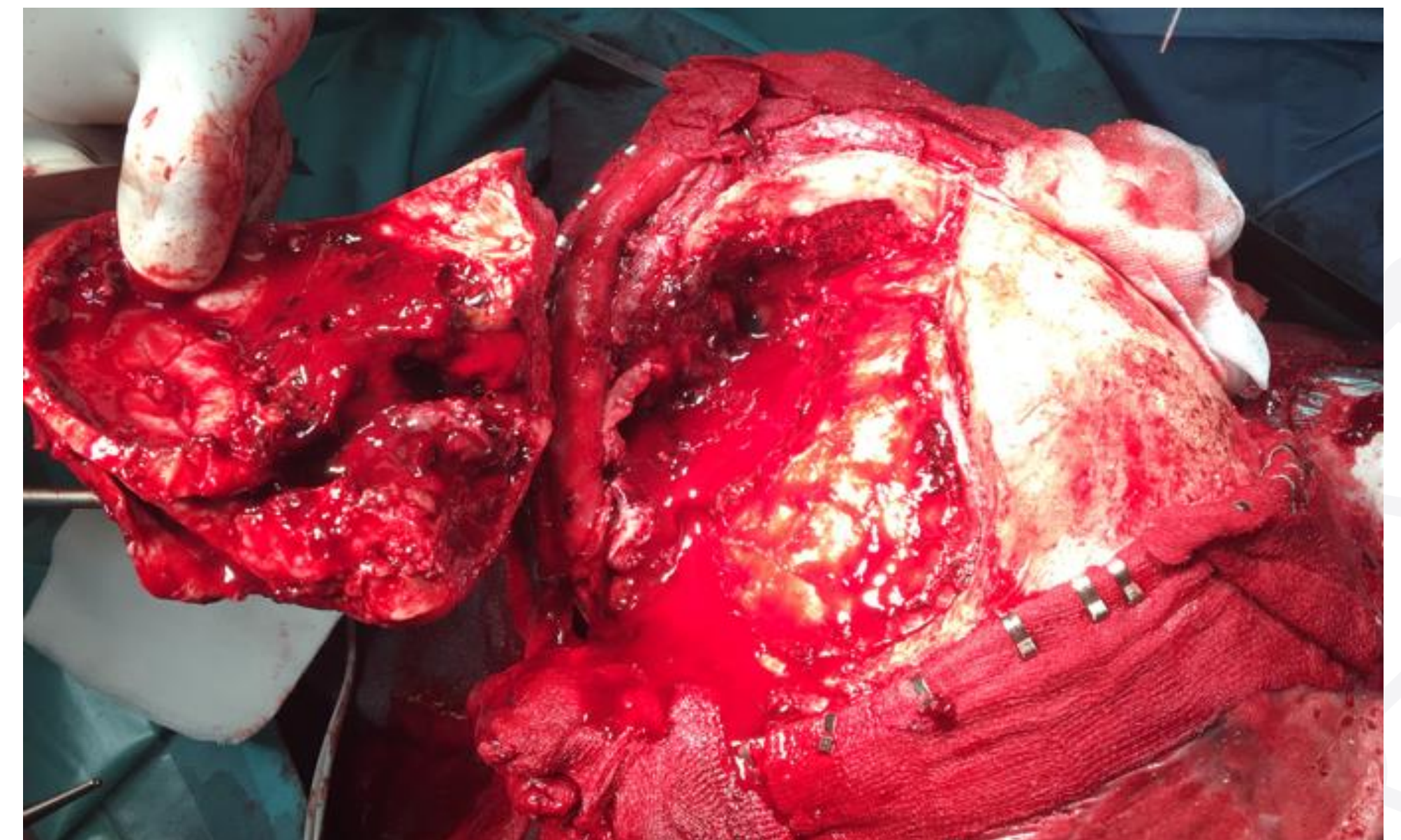
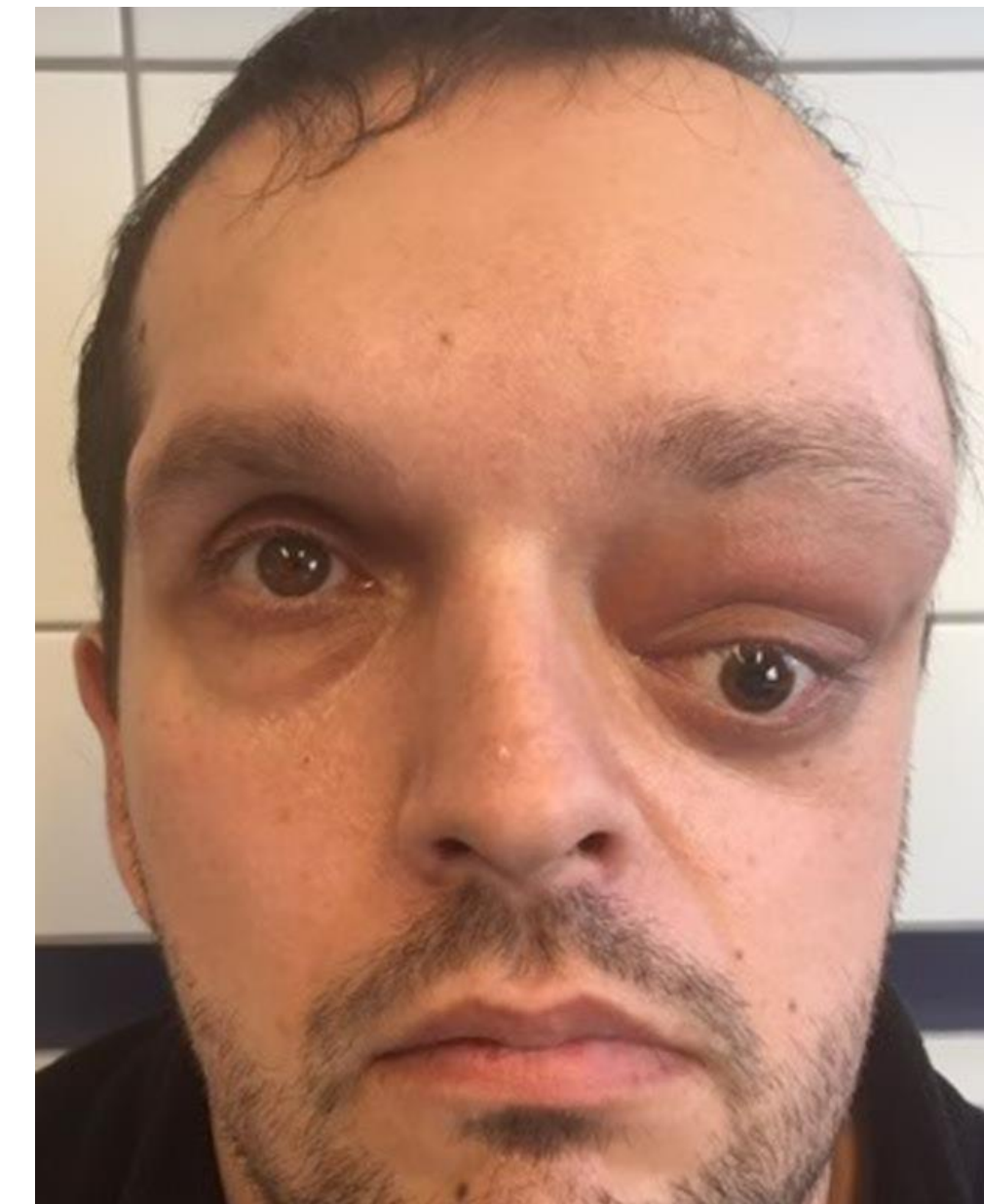
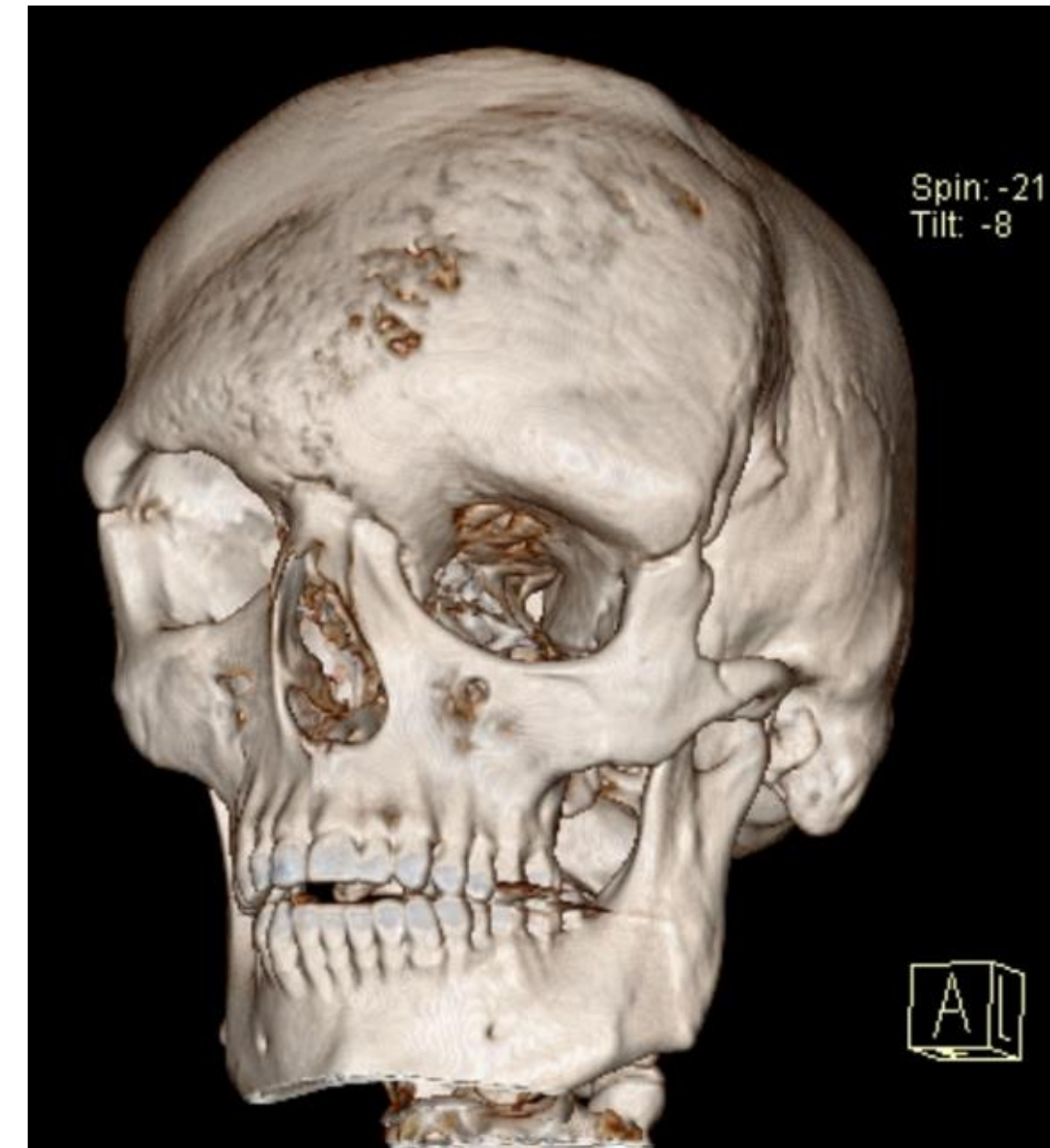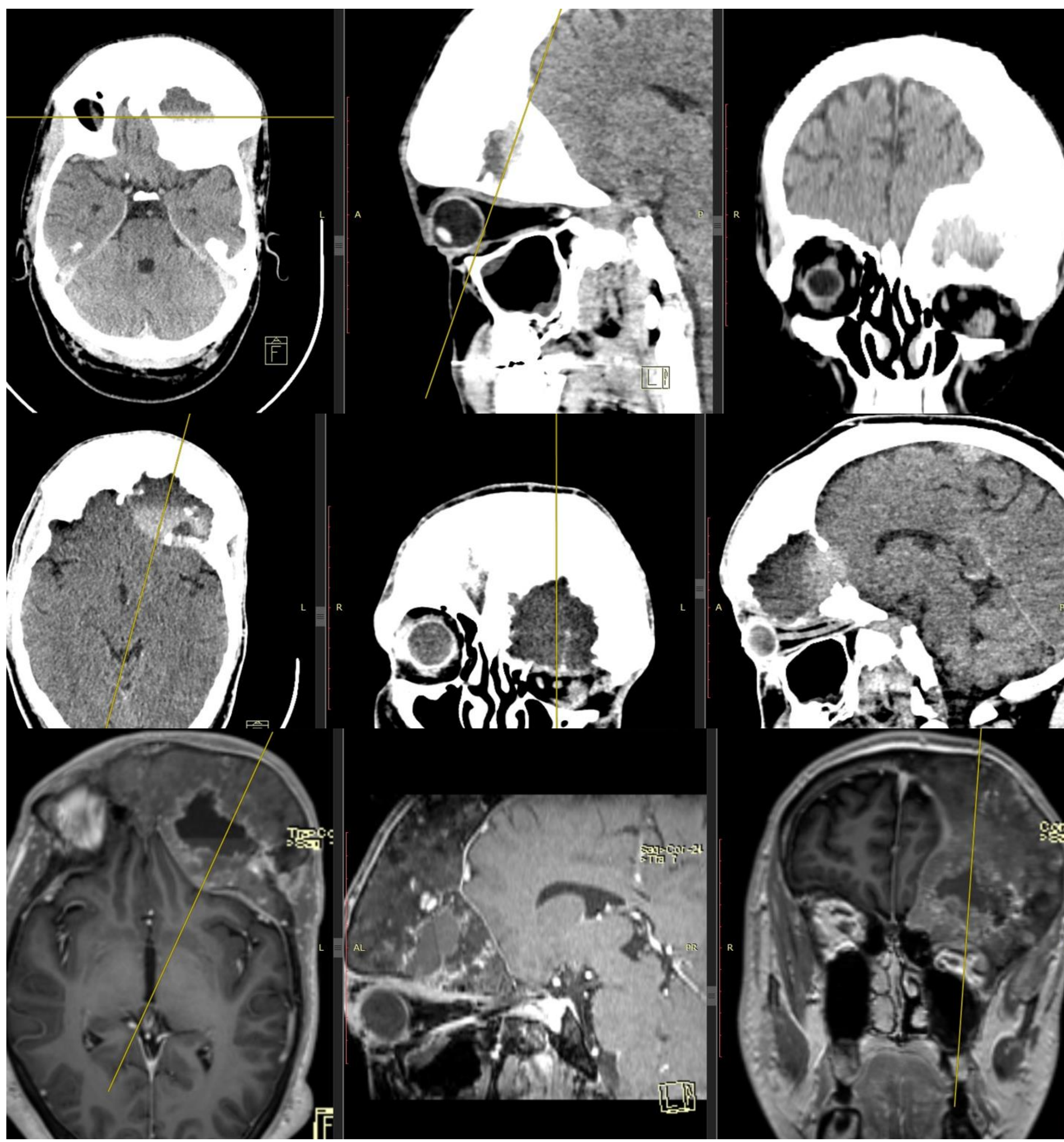
Kombinált maxillo-facialis műtét



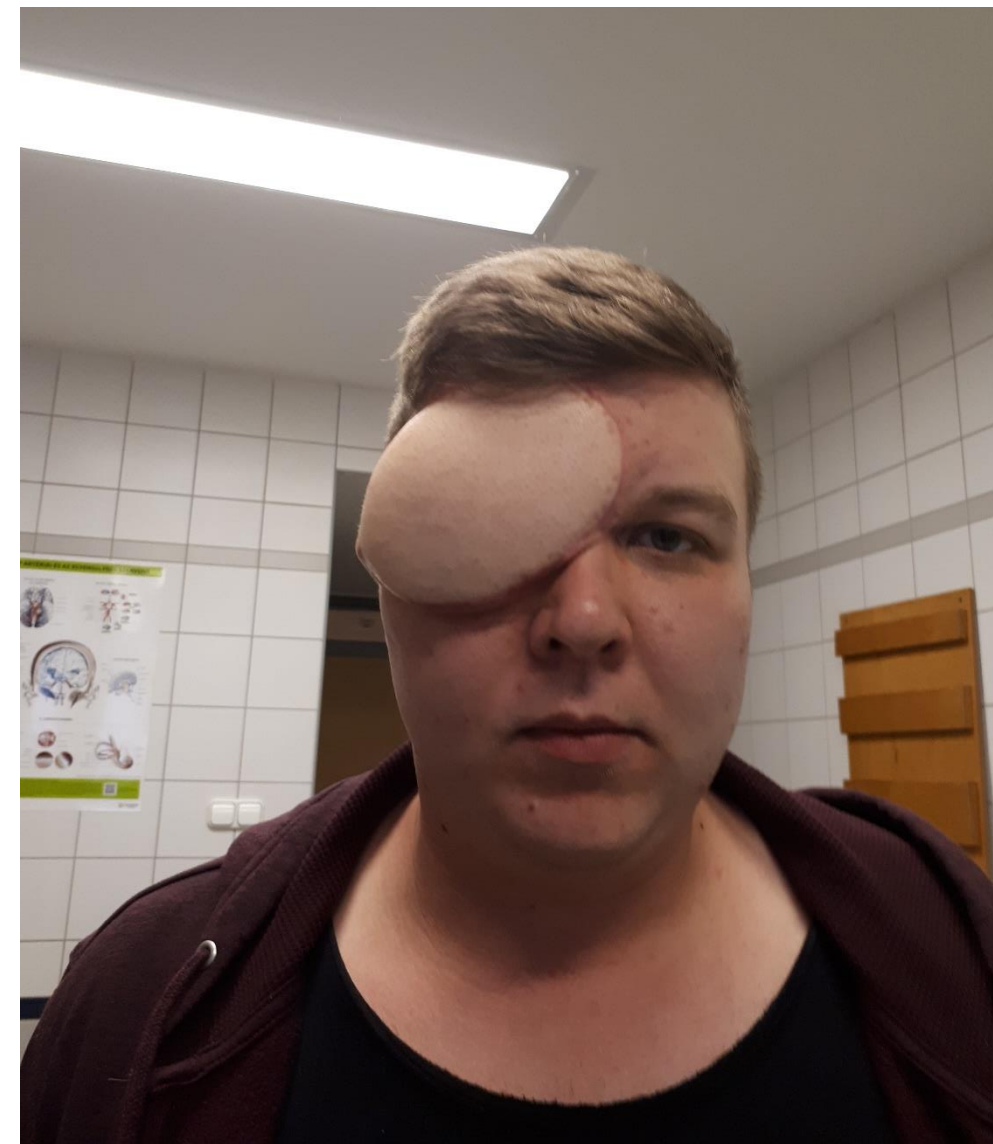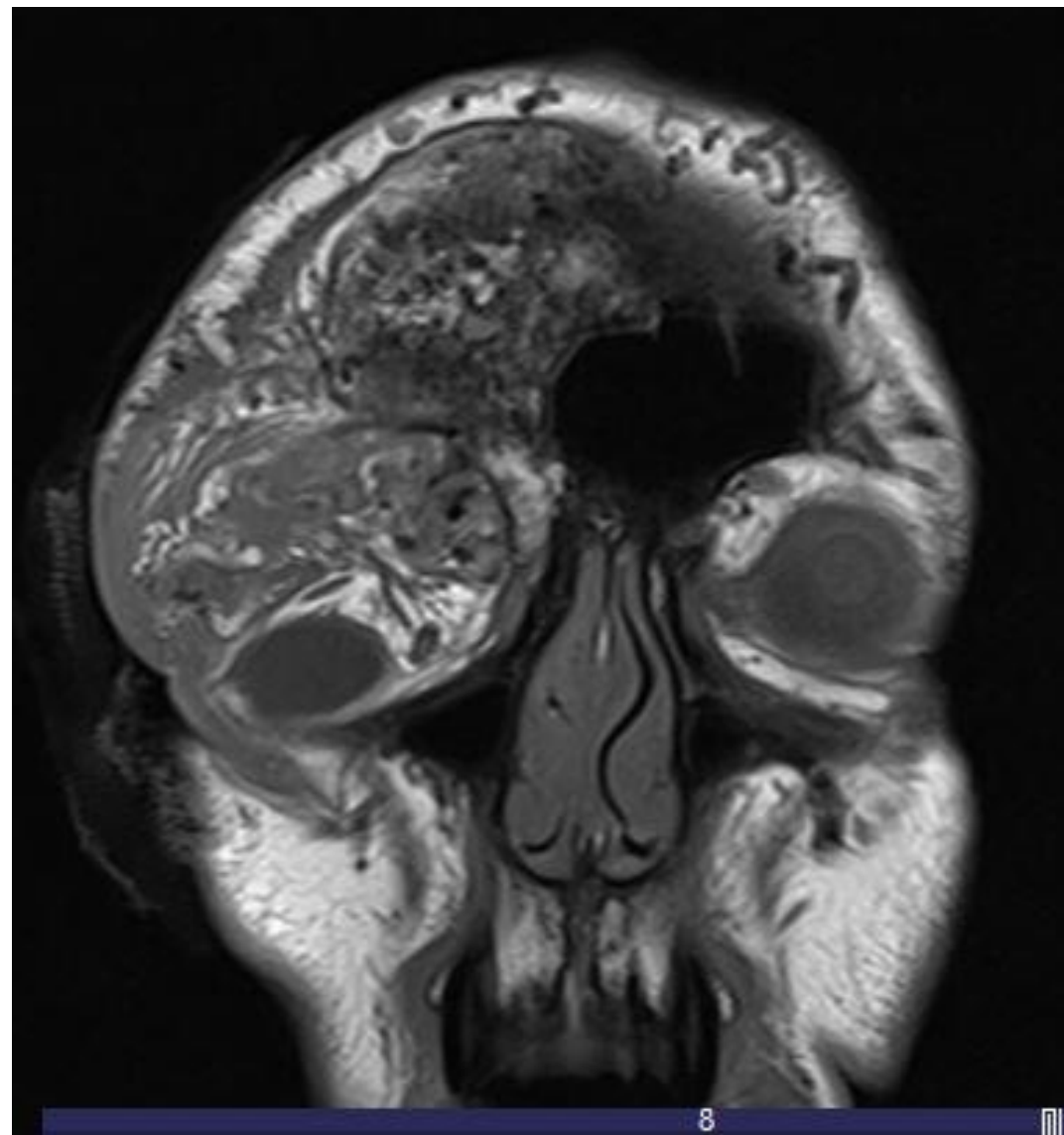
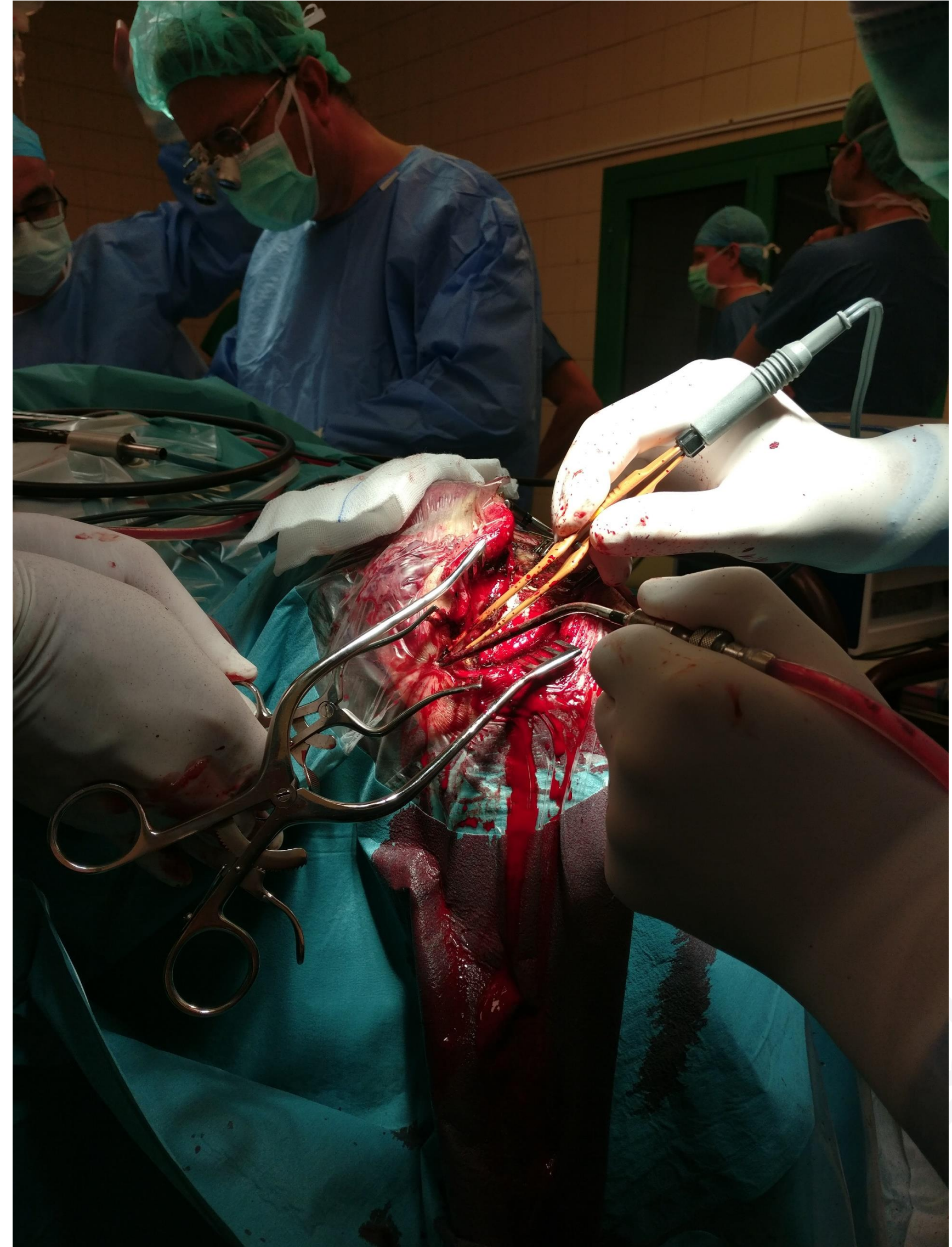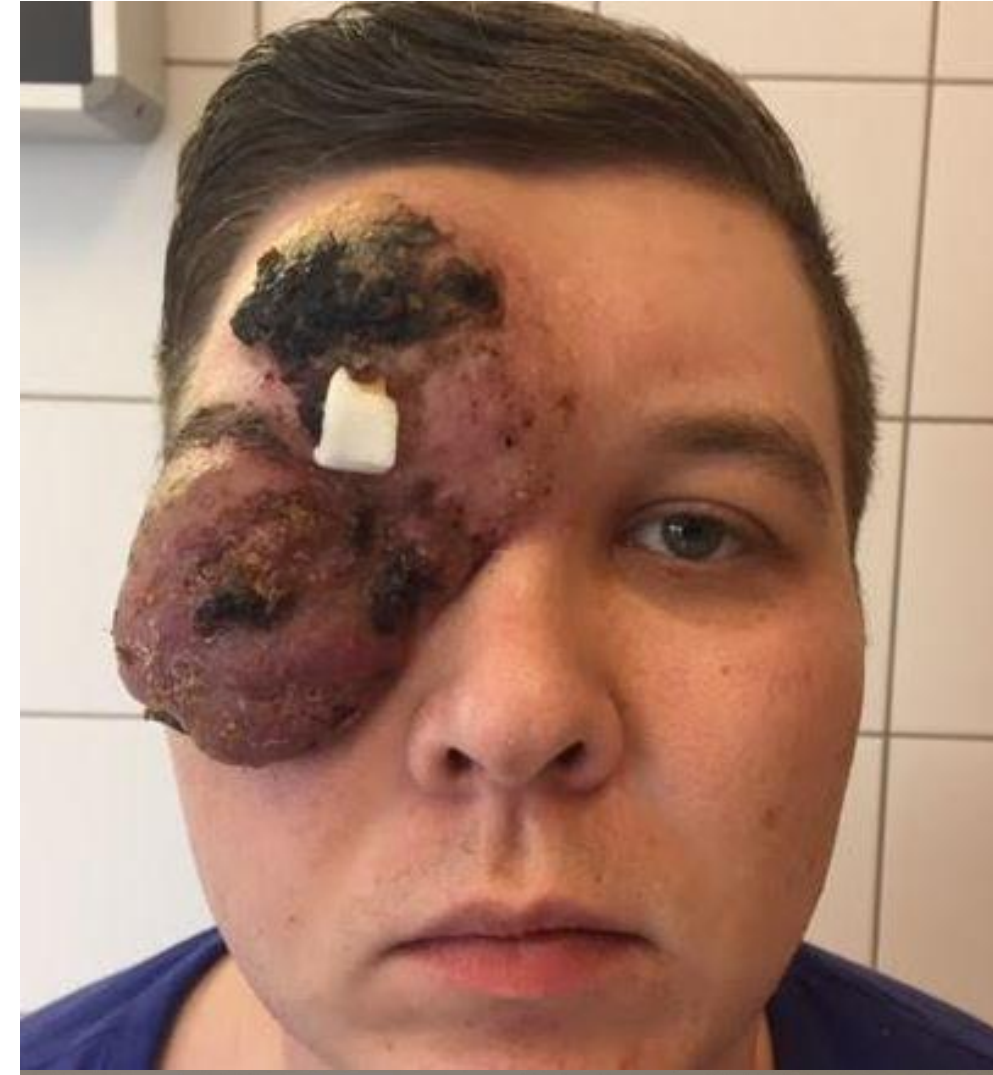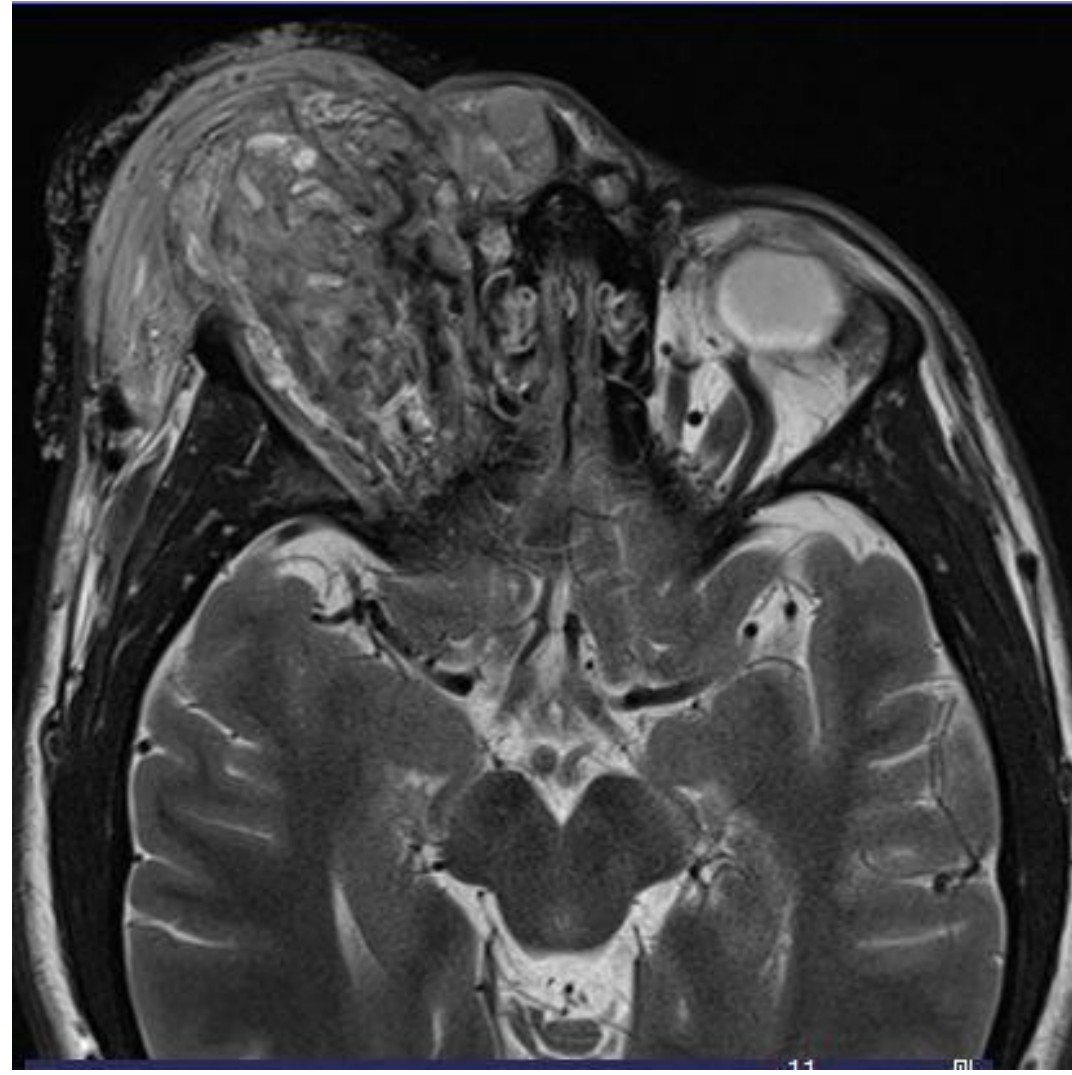
Kombinált maxillo-facialis műtét



Fibrosus dysplasia



Arterio-venosus malformatio- Társszakmák szerepe



Köszönöm a figyelmet!

