

Orthognatic Surgery


Dr. Bálint Nemes

Semmelweis University,
Department of Paediatric Dentistry and Orthodontics



SEMMELWEIS
UNIVERSITY 1769

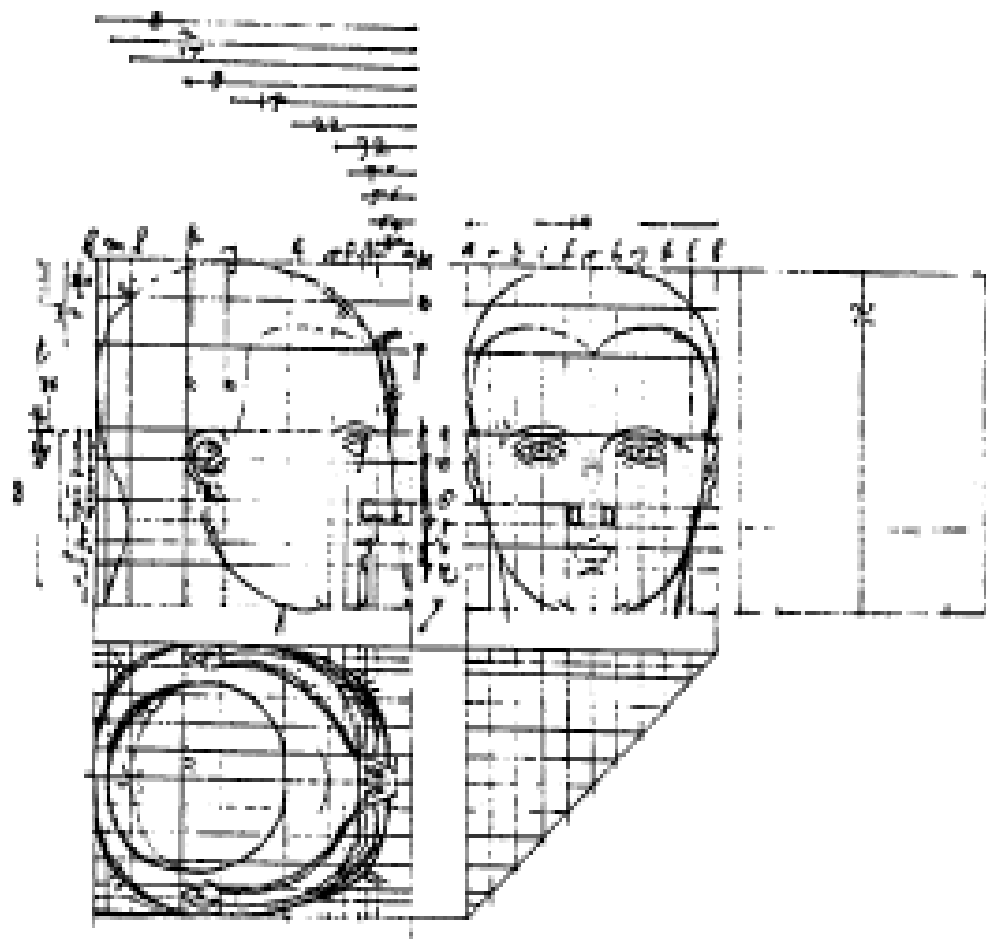
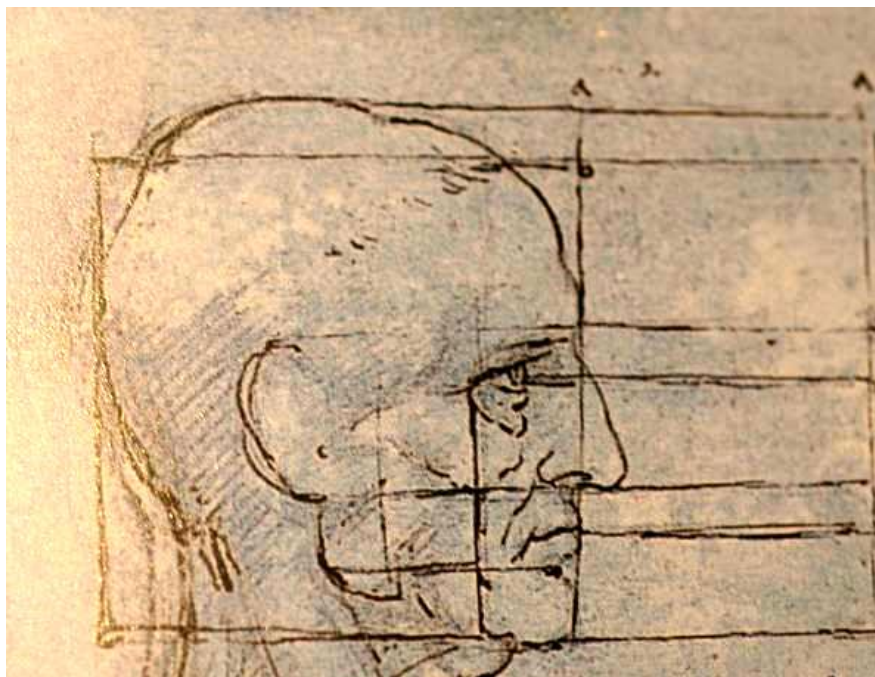
Facial deformities?



- 20% of population
- Europe/USA - Angle II

Genetic background – The „Habsburg jaw”

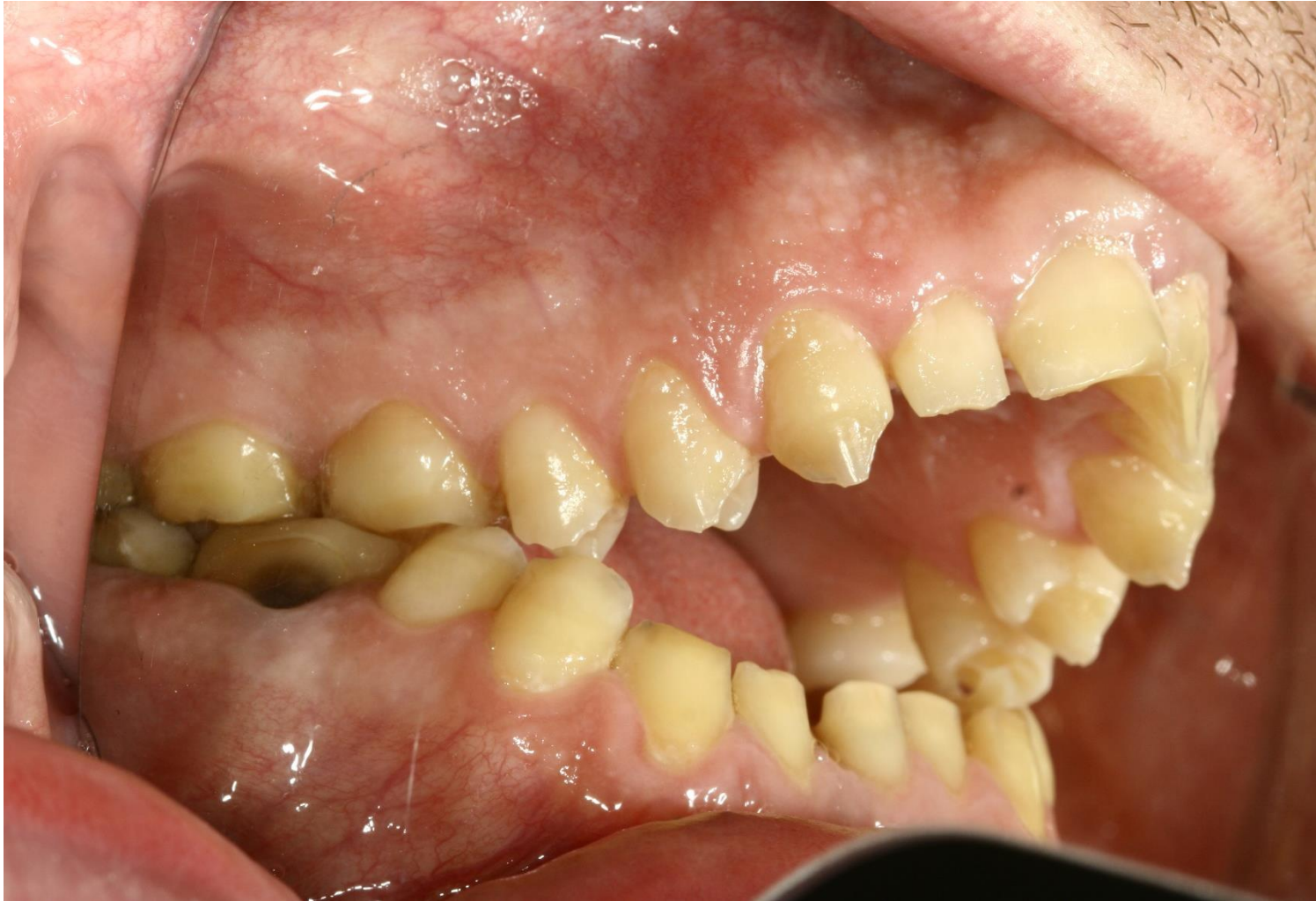



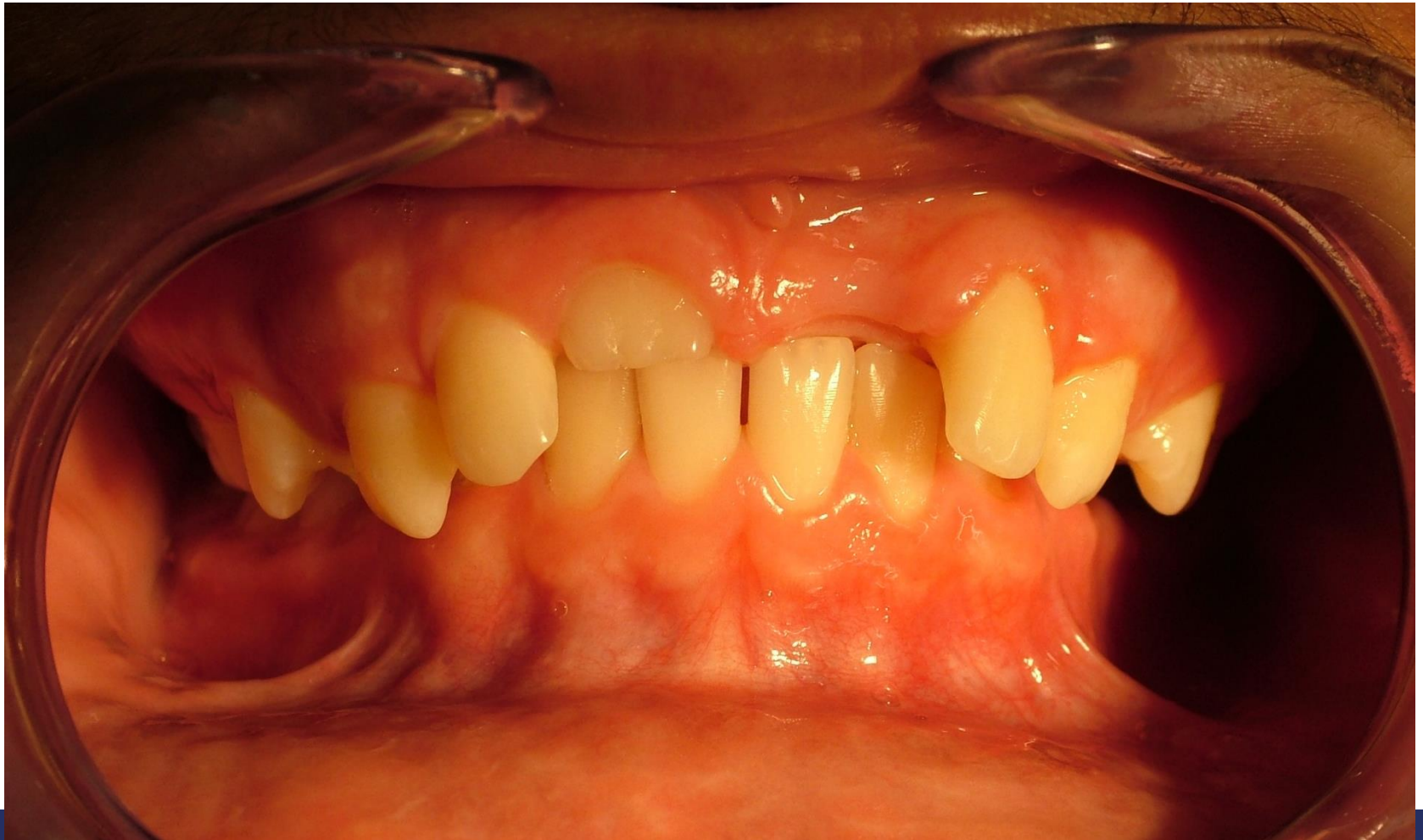Goals of orthognatic surgery

- 1. Restoration of masticatory function in cases of maxillary and/or mandibular base discrepancy ORTHO IS NOT ENOUGH!!**
- 2. Prevention of functional problems**
- 3. Oral hygieny, healthy periodontal tissues**
- 4. Harmonious face proportions**
- 5. Airway management**

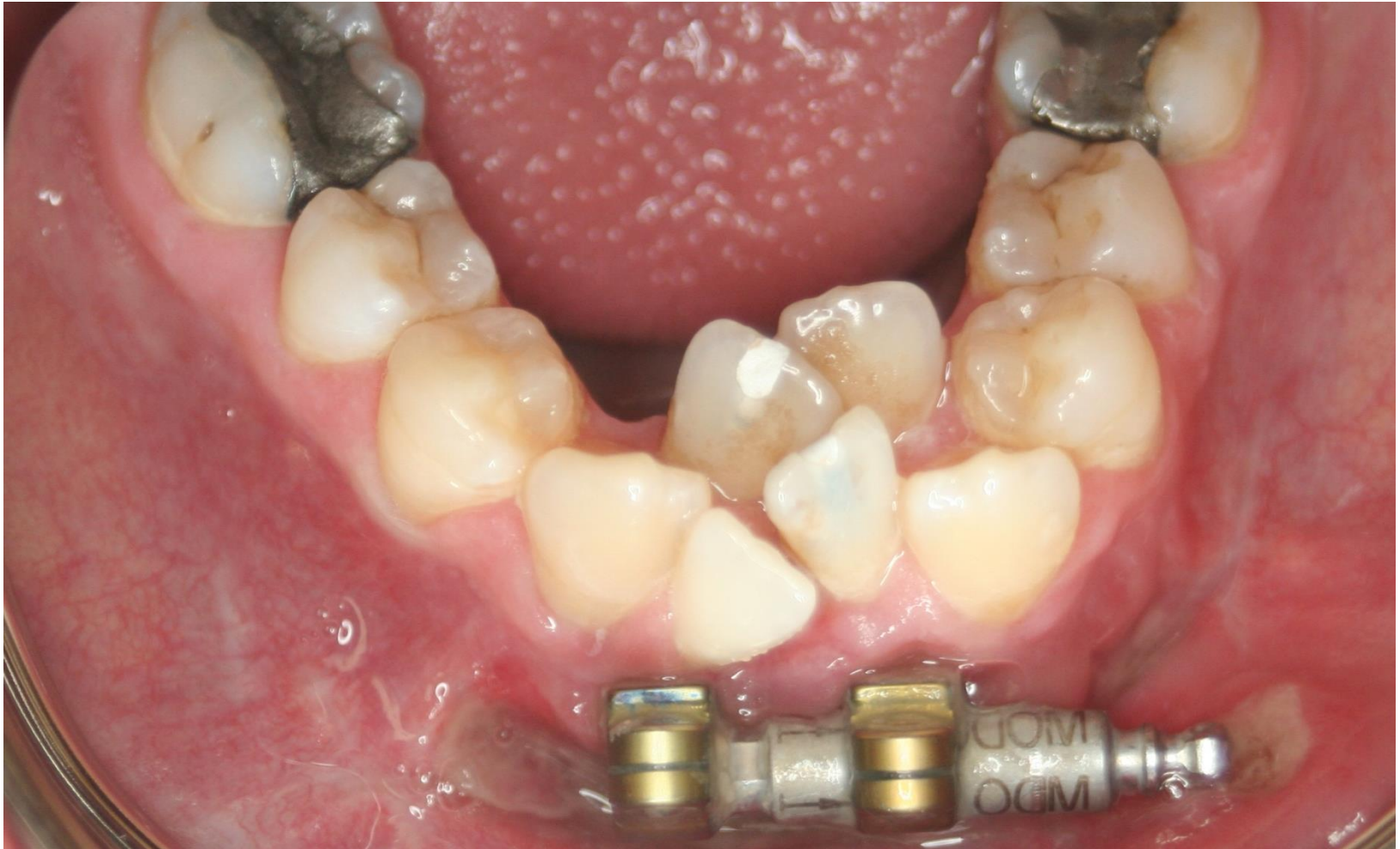
1. Masticatory function



2. Functional problems



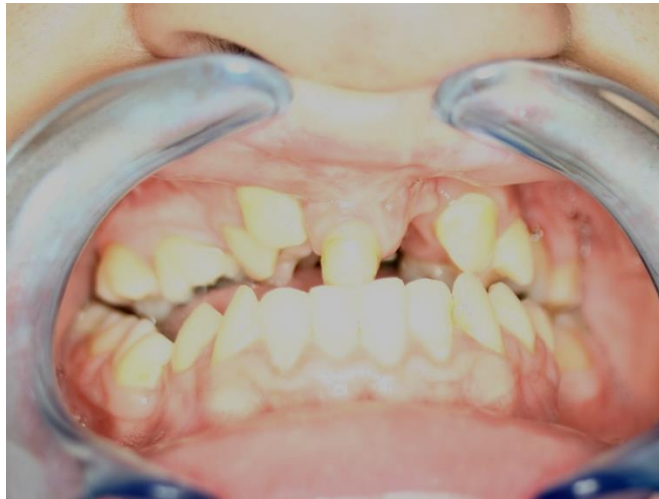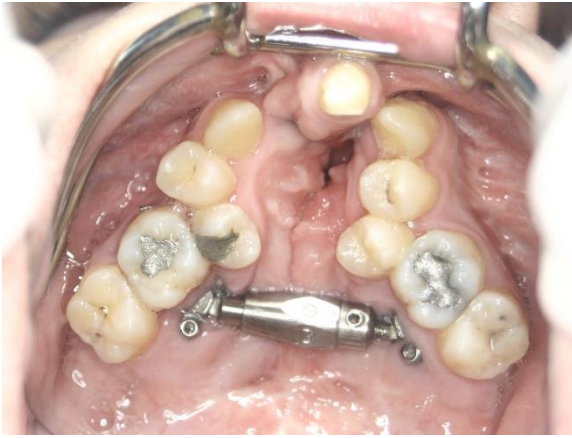
3. Oral hygiene



4. Harmonious face



Cleft lip palate patients



Documentations needed

1. Anthropometry - history taking -demographic data
2. Models (digital) + Face bow registration
3. Intra and extraoral photos, videos
4. (X-ray), CT

Types of orthognatic surgeries

1. Transversal discrepancies

Subtotal Le Fort I - surgically assisted maxillary expansion SARME

Transmandibular distraction

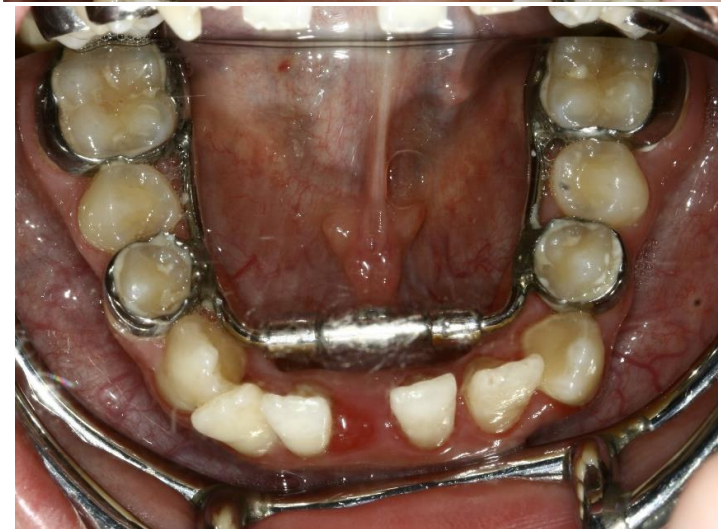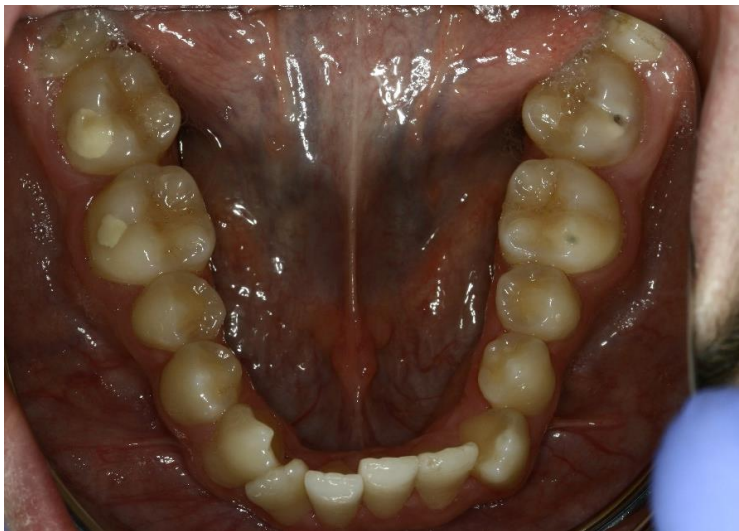
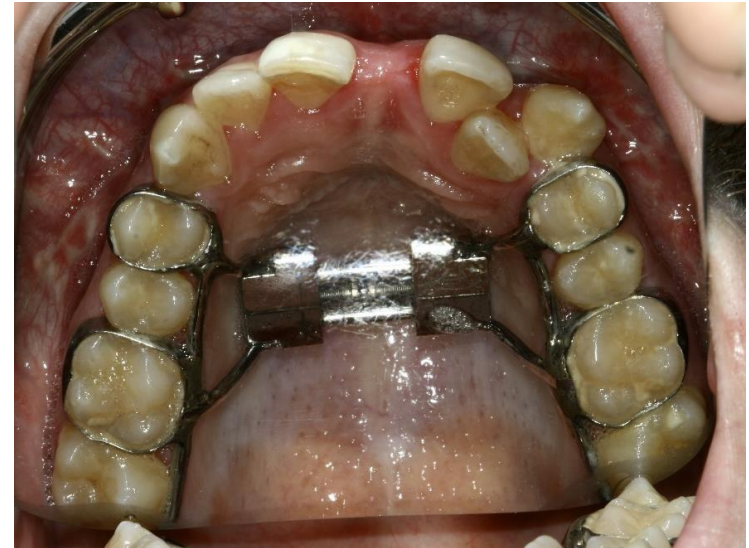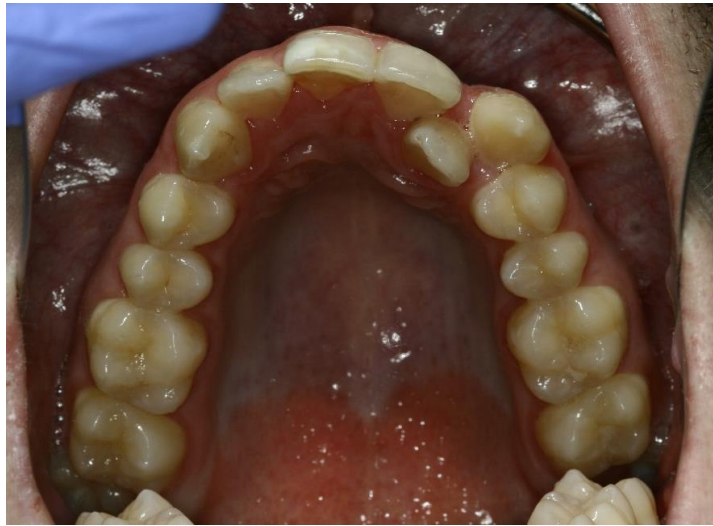2. Le Fort I osteotomy

3. Bilateral Saggital Split Osteotomy (BSSO = Obwegeser-Dal Pont surgery)

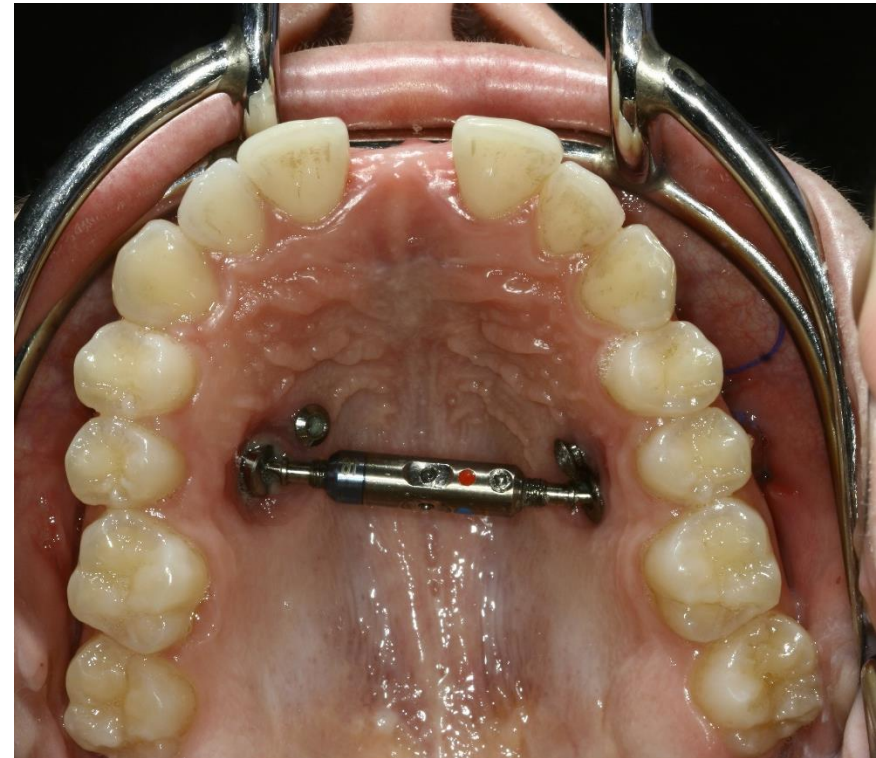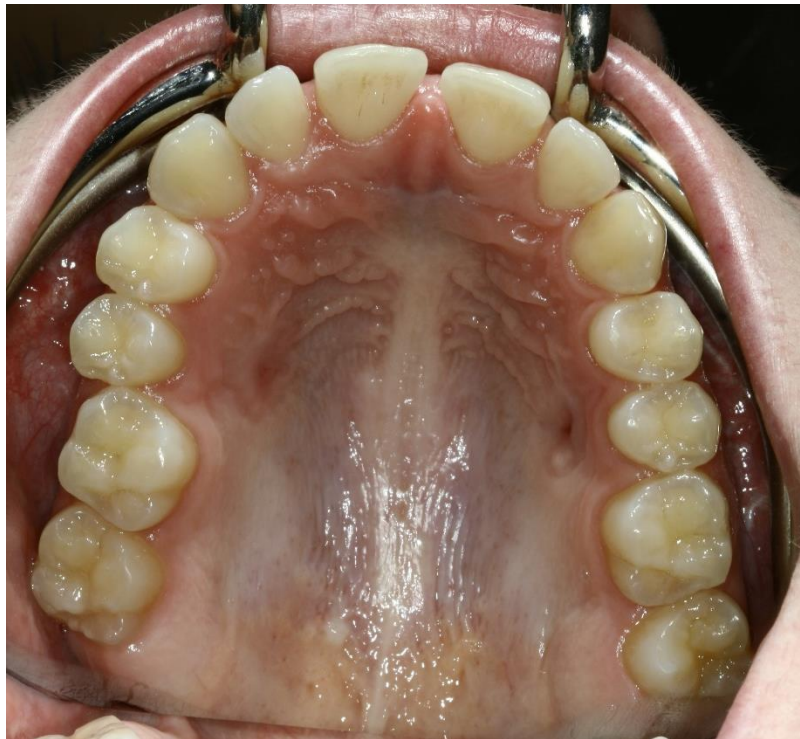4. Genioplasty

Transversal discrepancies

Transversal Problems - distraction osteogenesis - SARME



Transpalatal Distraction TPD with bone borne anchors

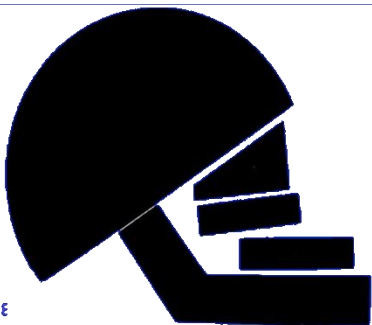
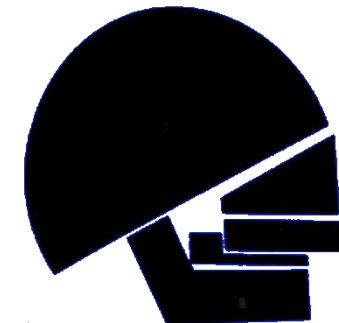
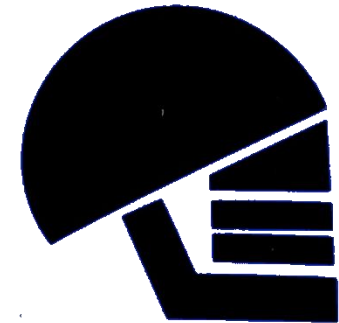


Sagittal discrepancies

• **Class I** : normocclusion

• **Class II**: distocclusion

• **Class III**: mesiocclusion



Saggital discrepancies

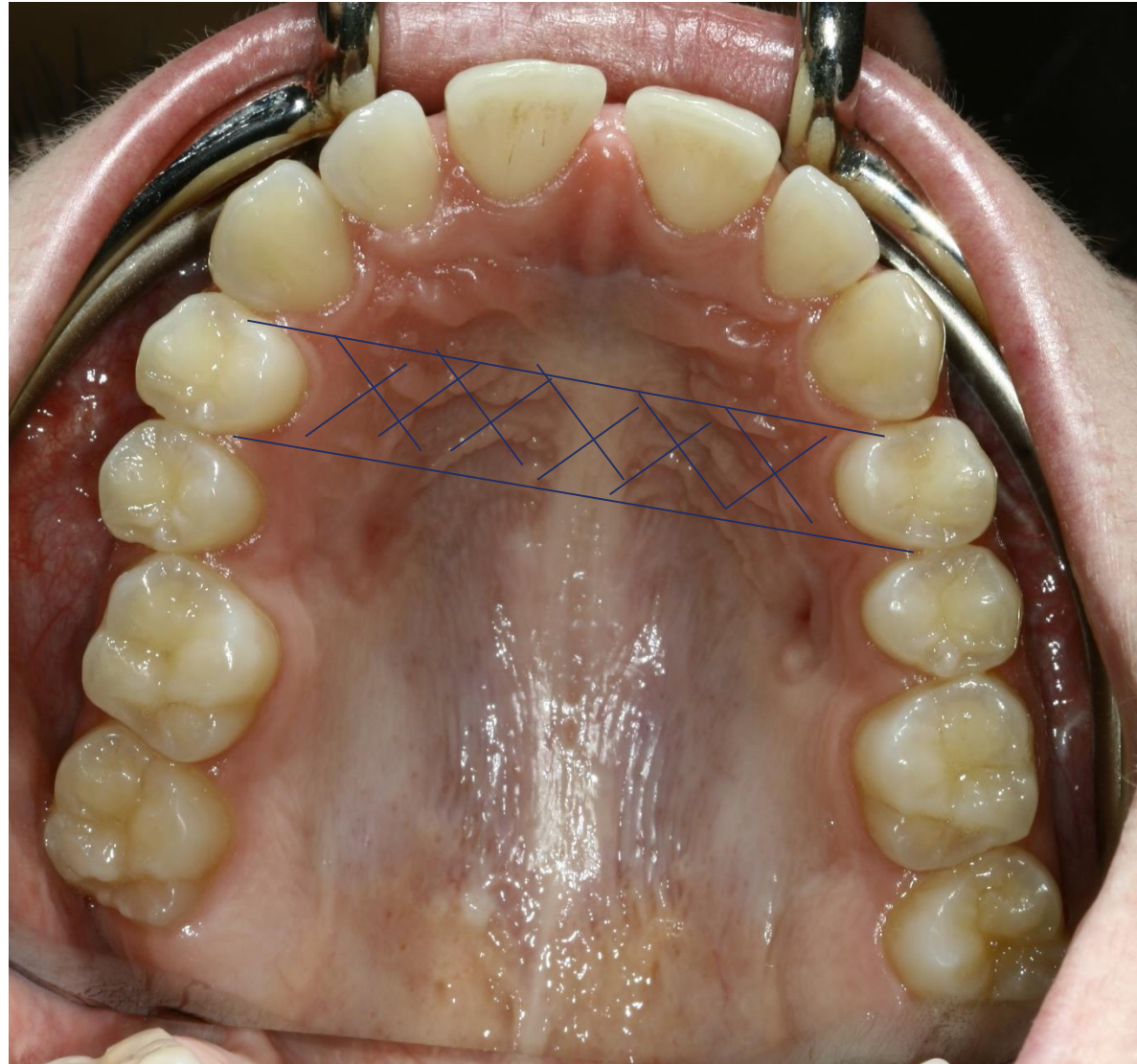
Le Fort I -Maxillary advancement

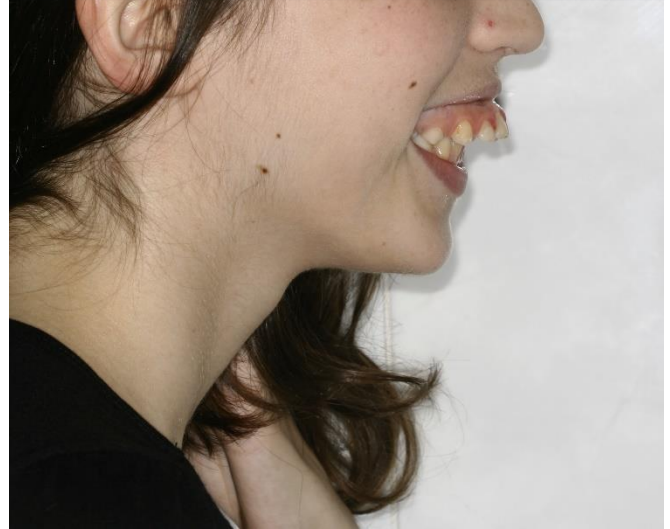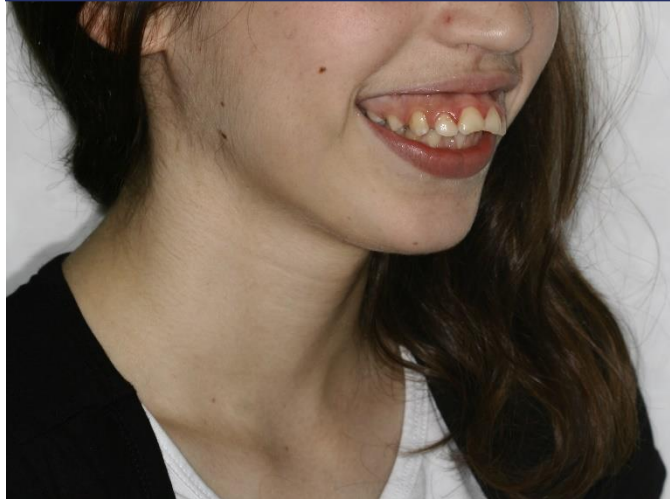Köle Surgery

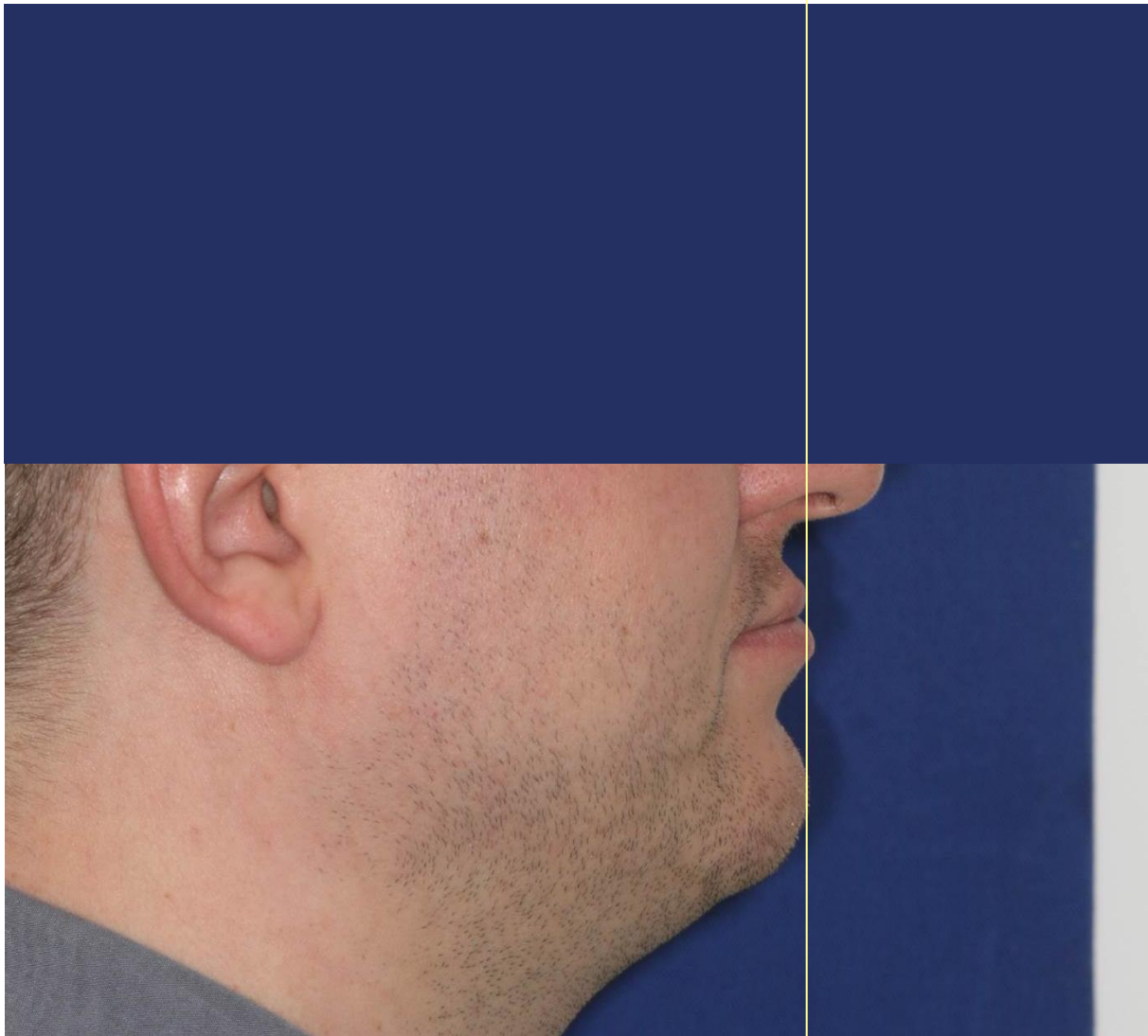BSSO - Mandibular advancement or setback

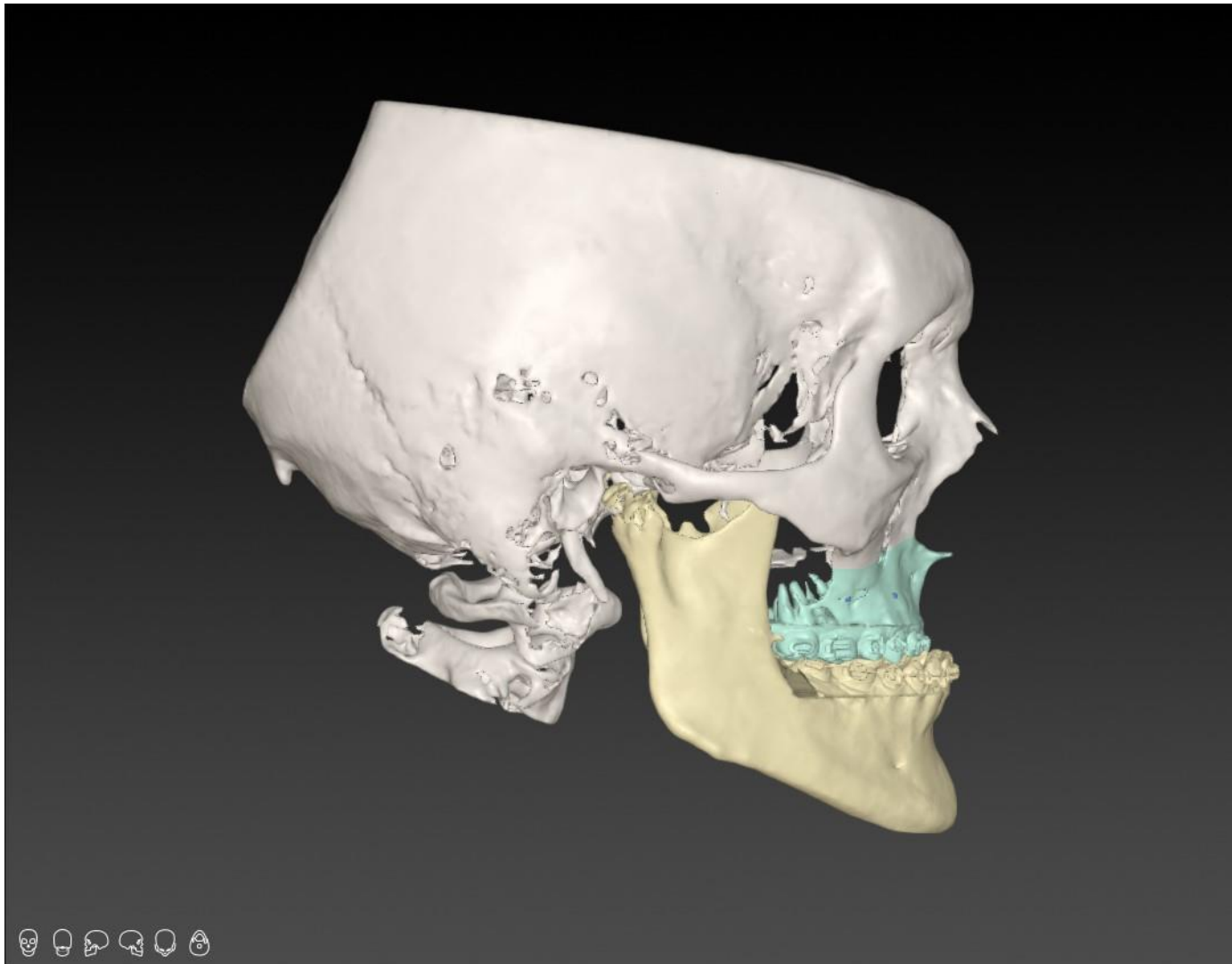
Genioplasty - advancement or setback

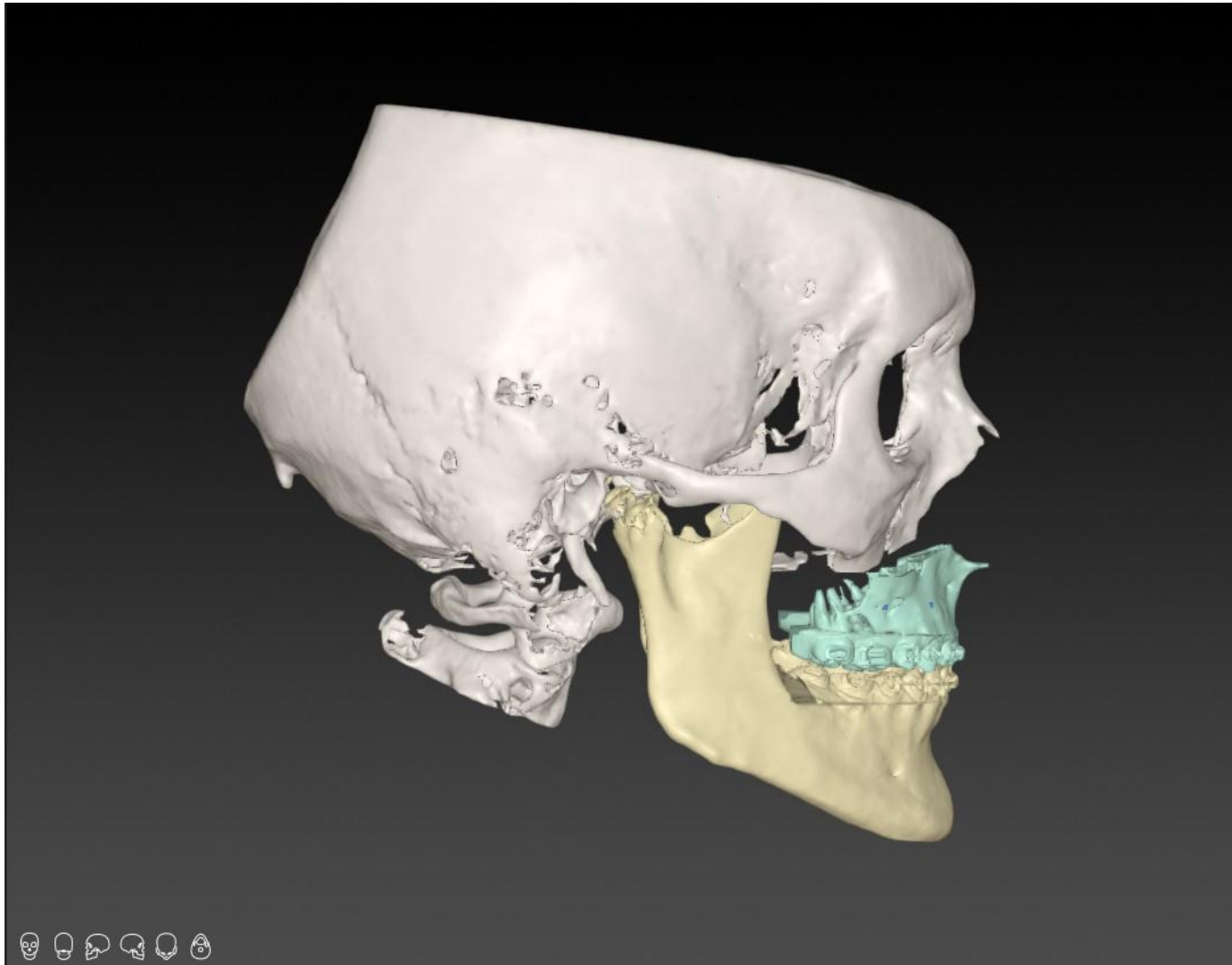
Köle Surgery

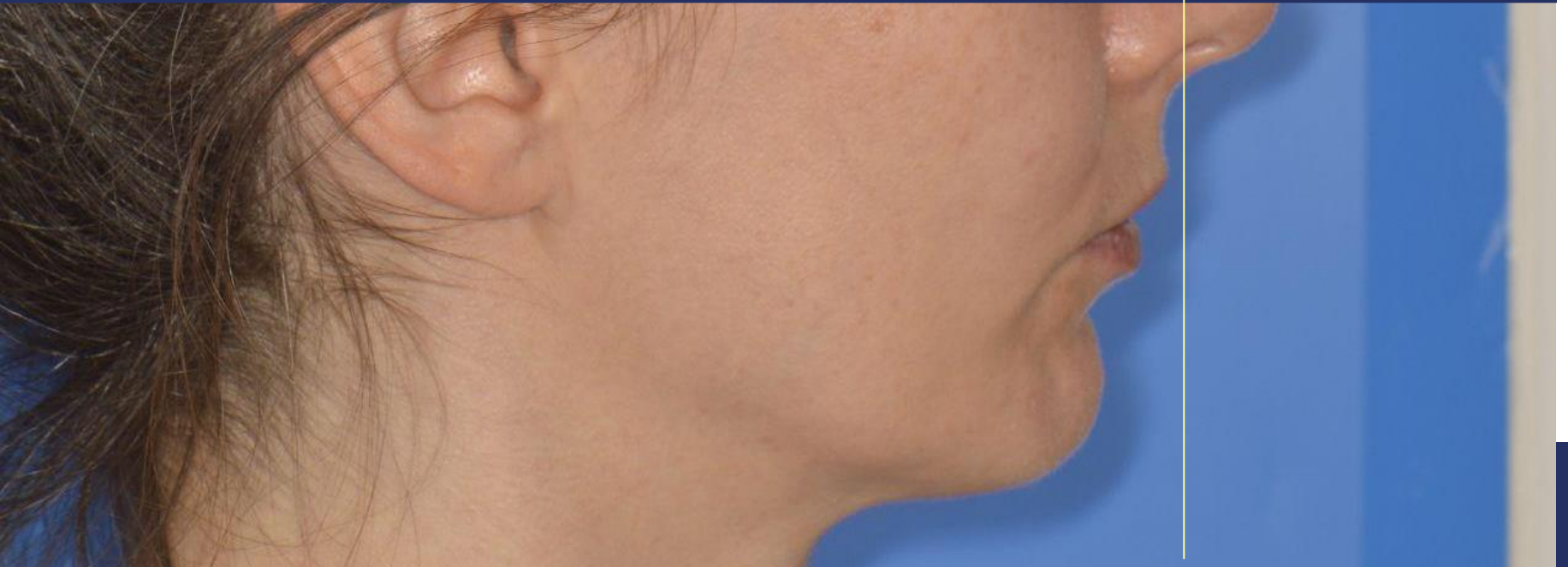

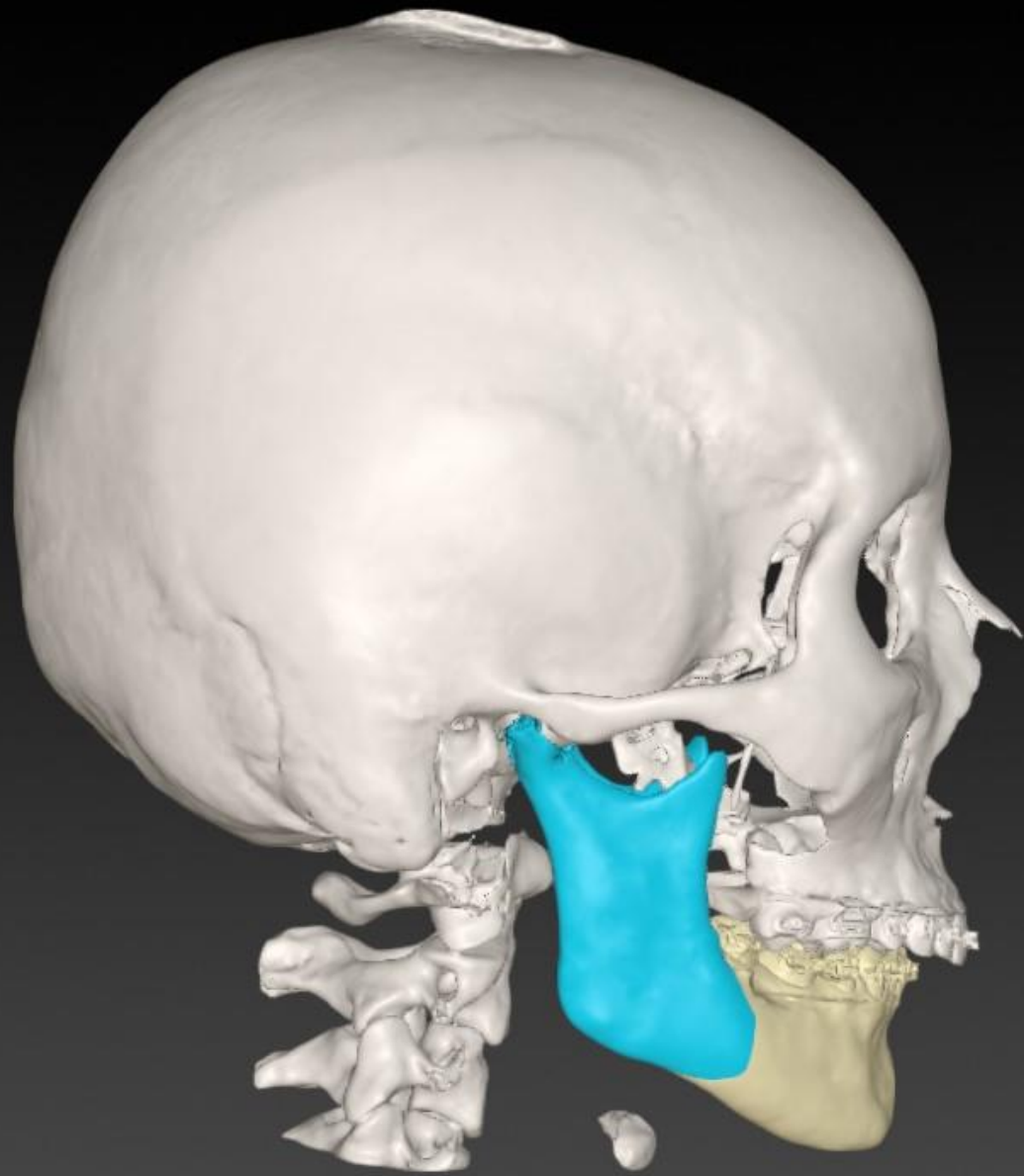


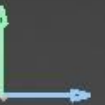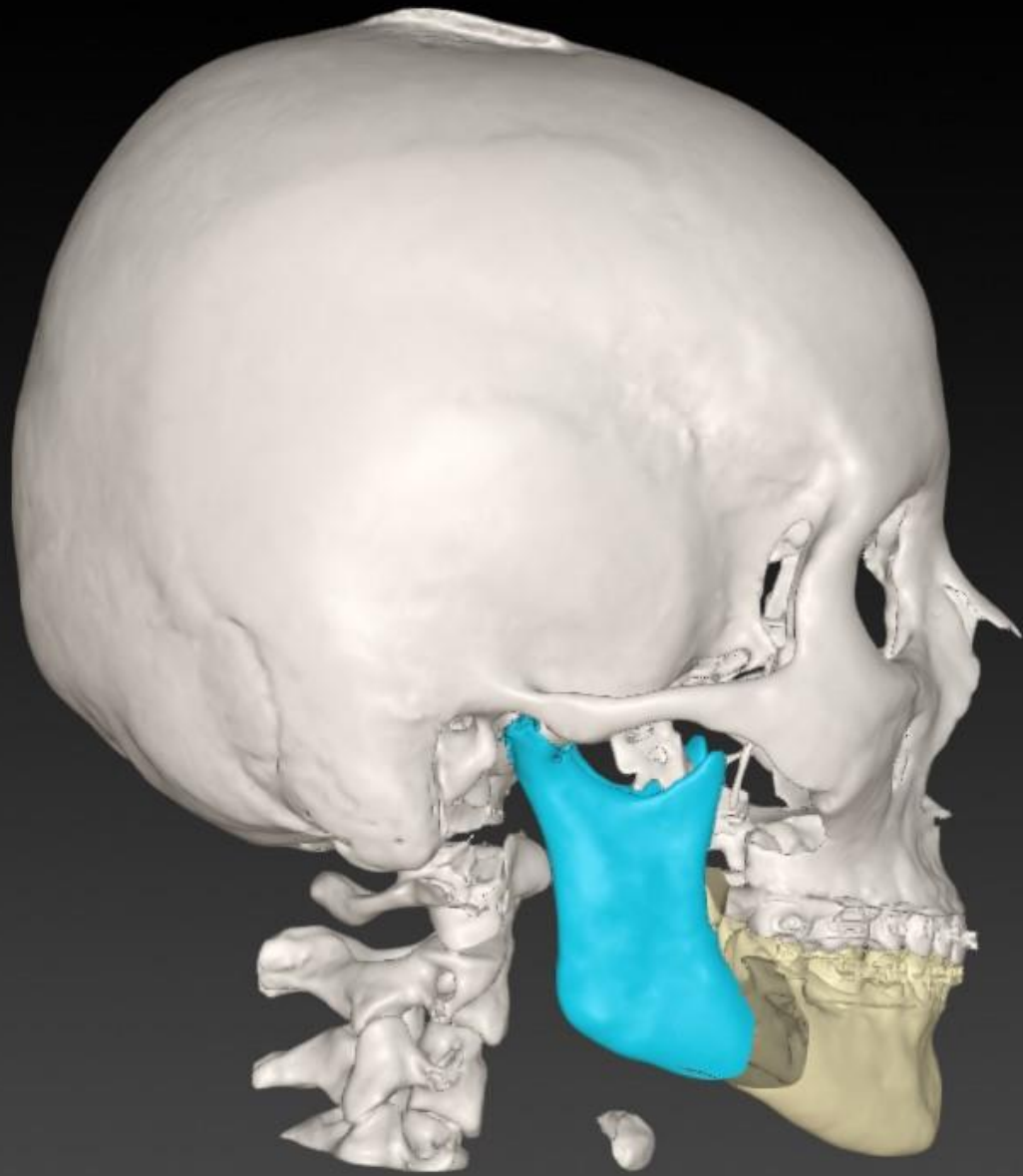








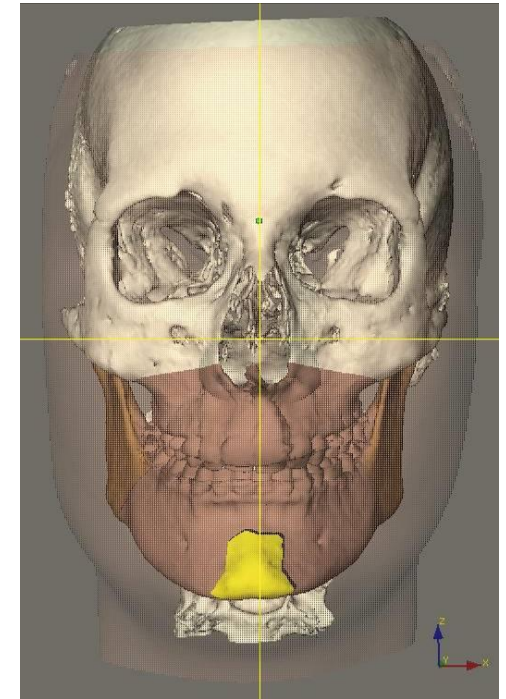
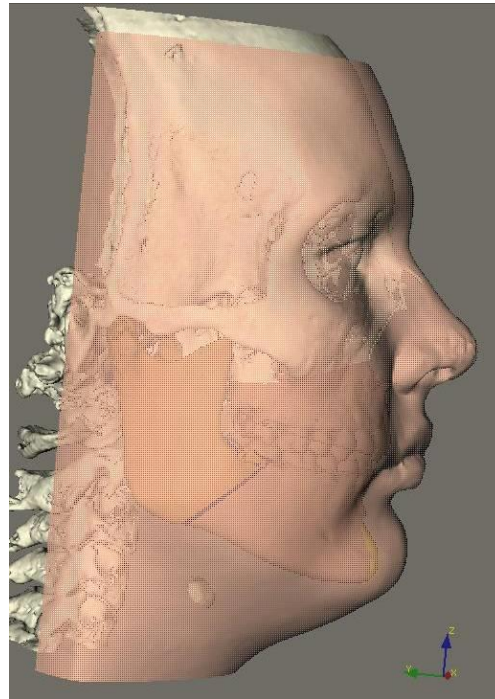




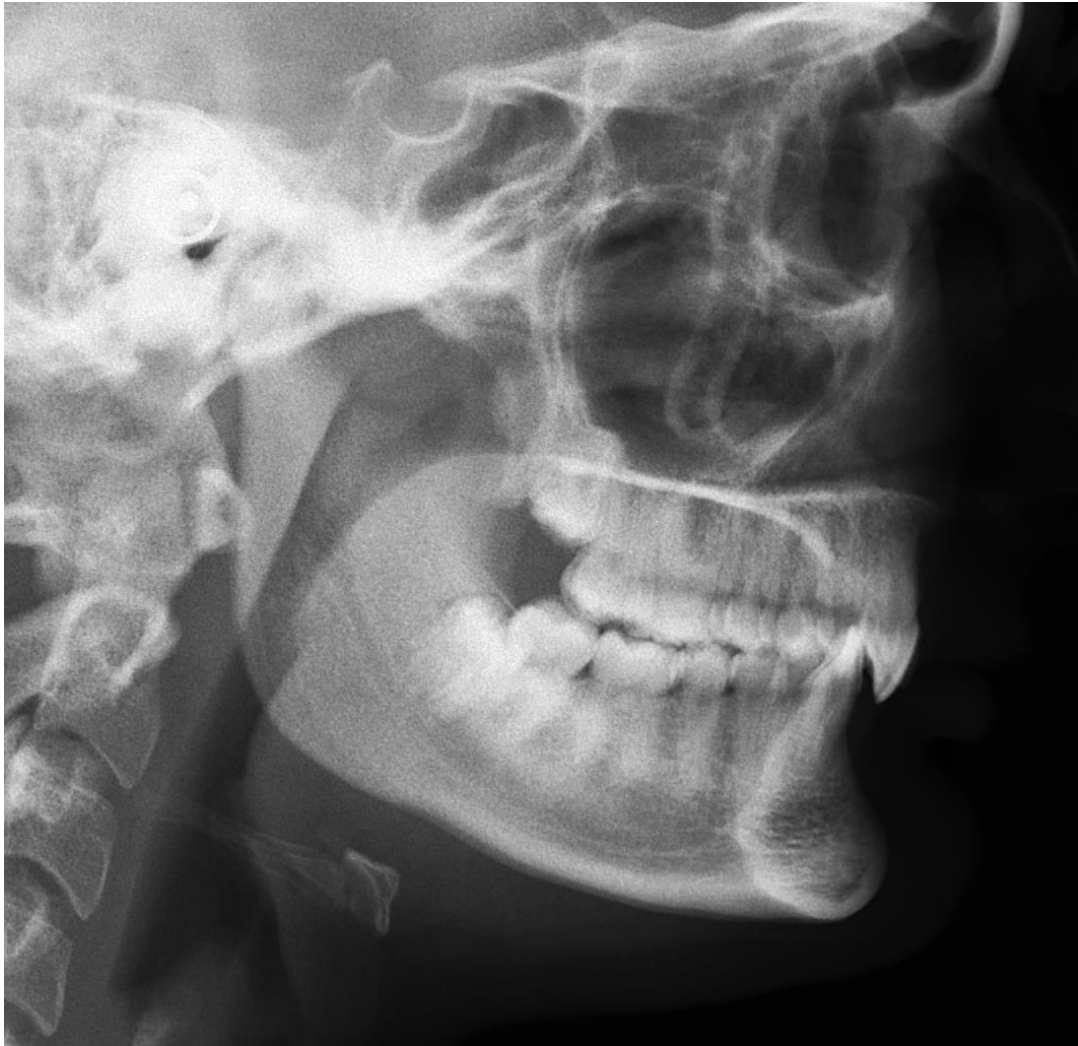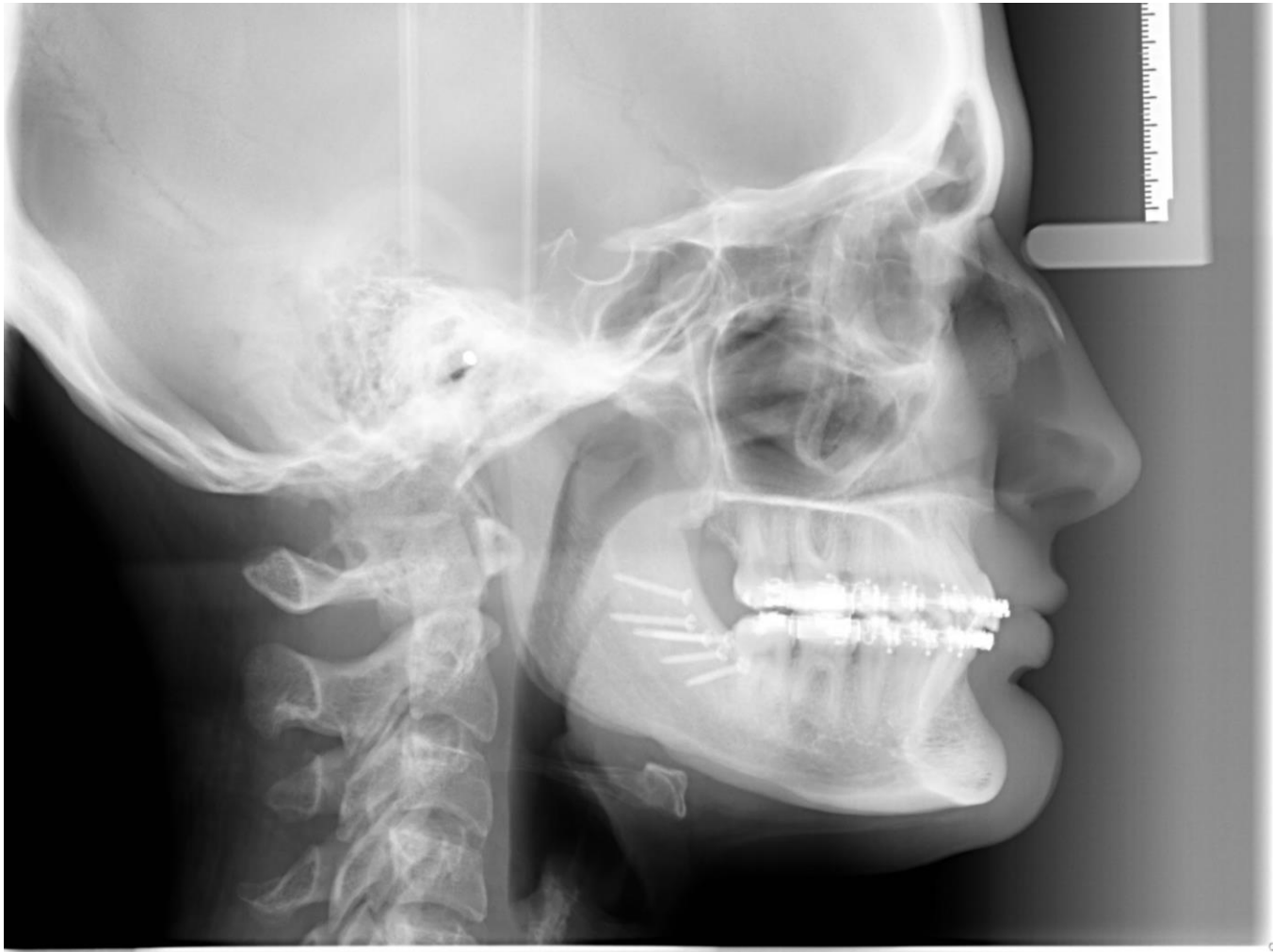Vertical discrepancies

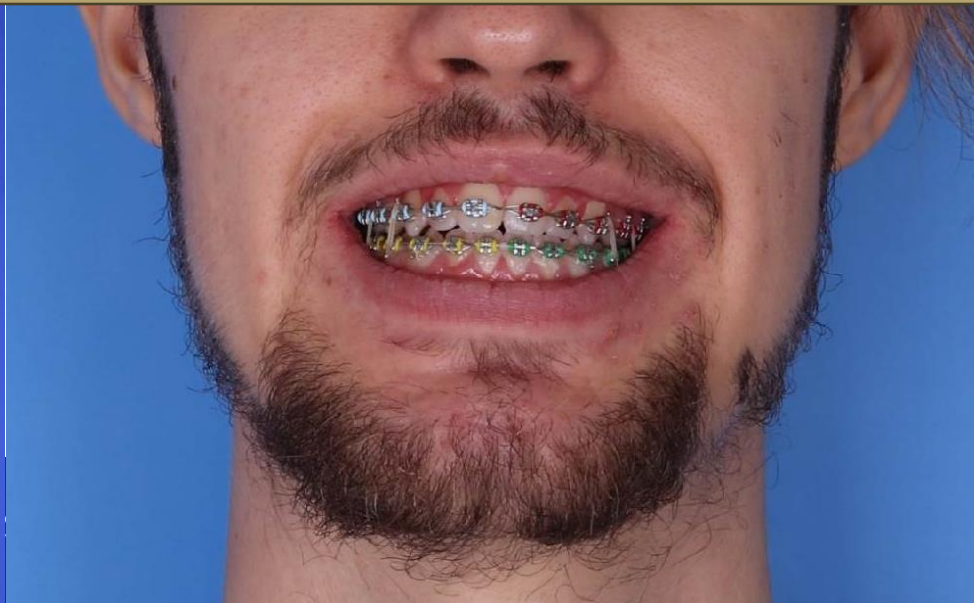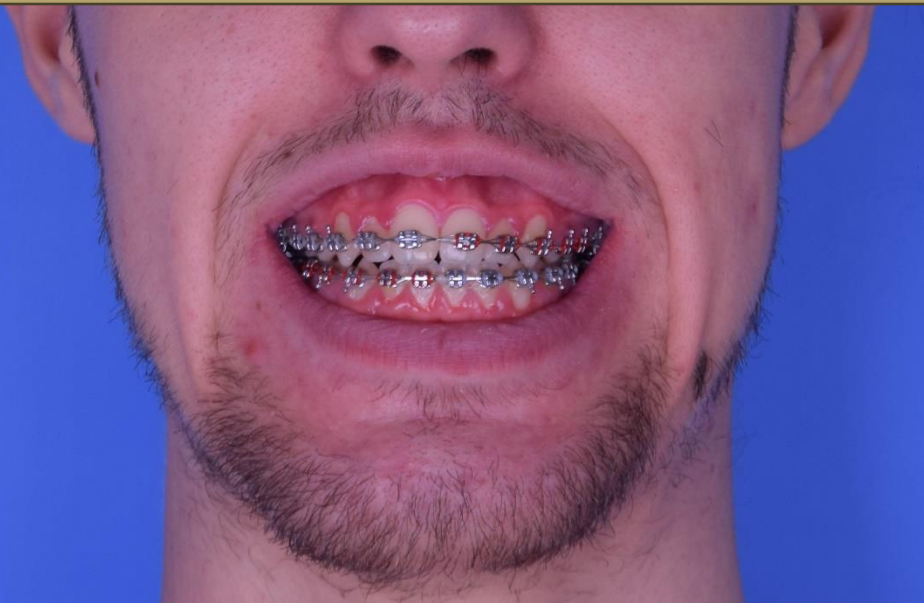Vertical discrepancies

- BSSO vertical pitch movement
- Le Fort I Maxillary impaction or downgraft
- Genioplasty







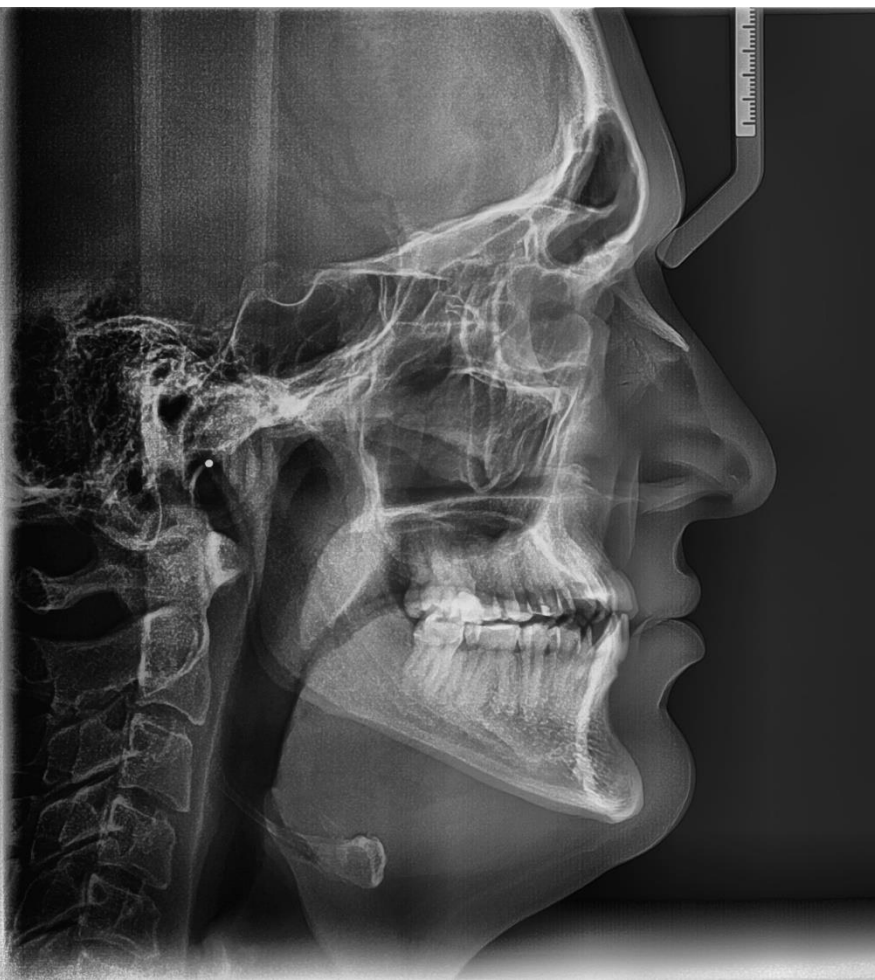

Orthodontic decompensation

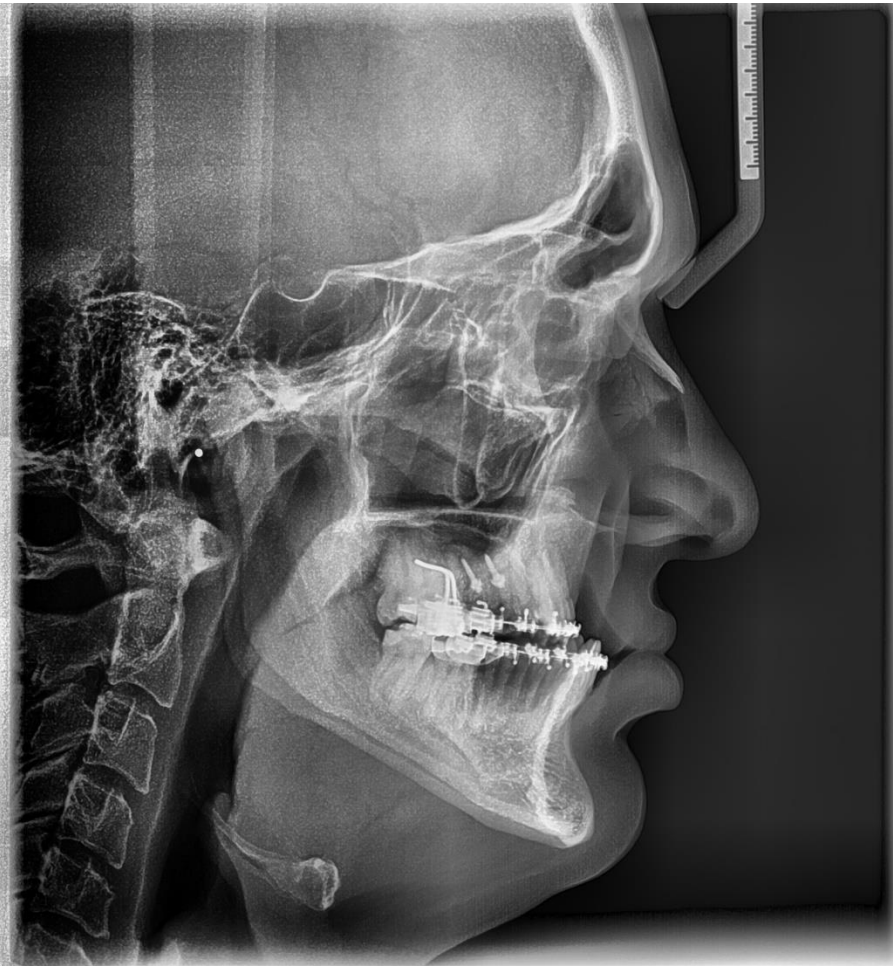The essence of orthodontic surgical preparation:

Align the incisors and occlusal plane according to bony base of the jaw

Radiodental Extra

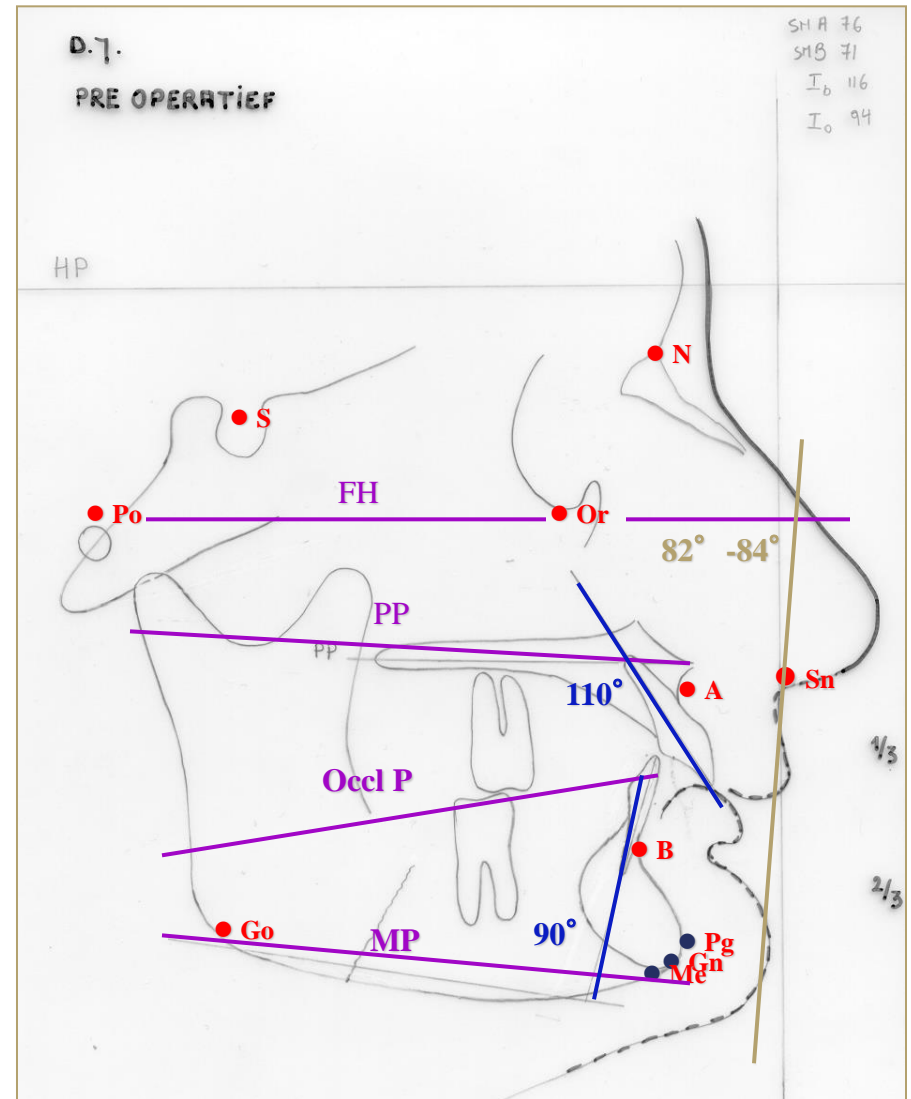
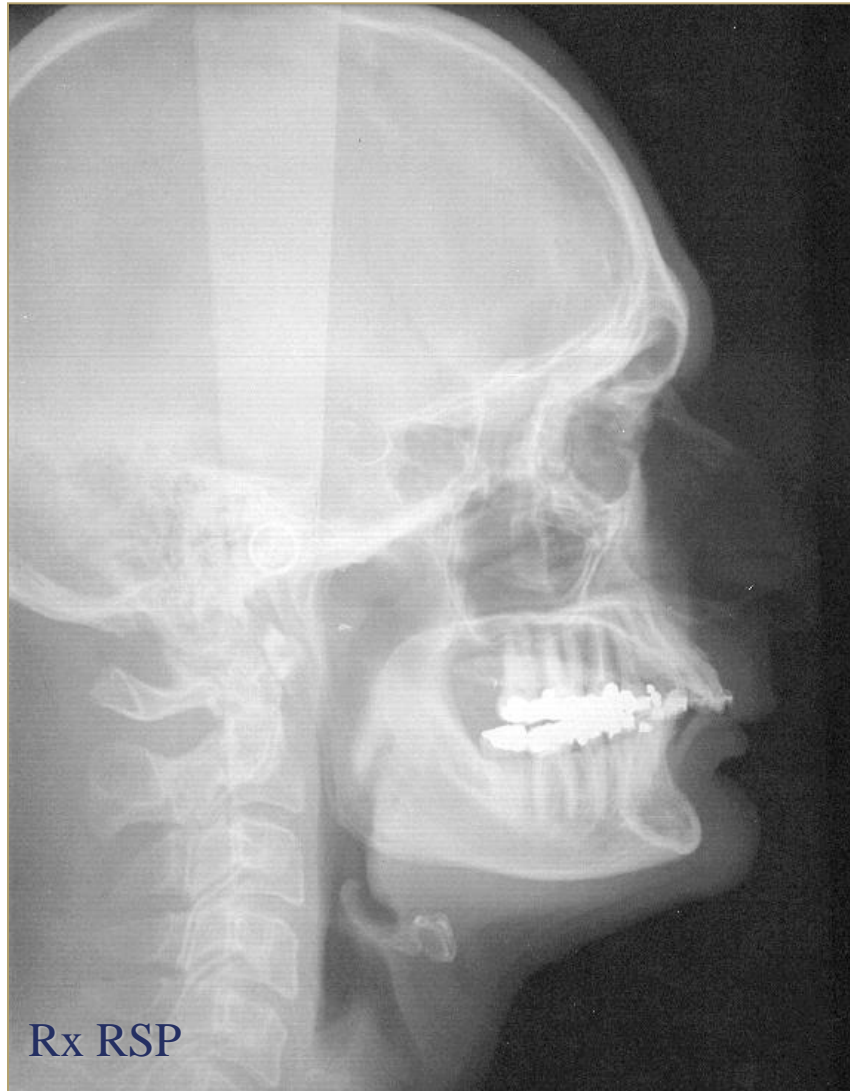


Óbuda Fogklinikai Vatech Pax-I



Surgical planning

Cephalometry - paper surgery

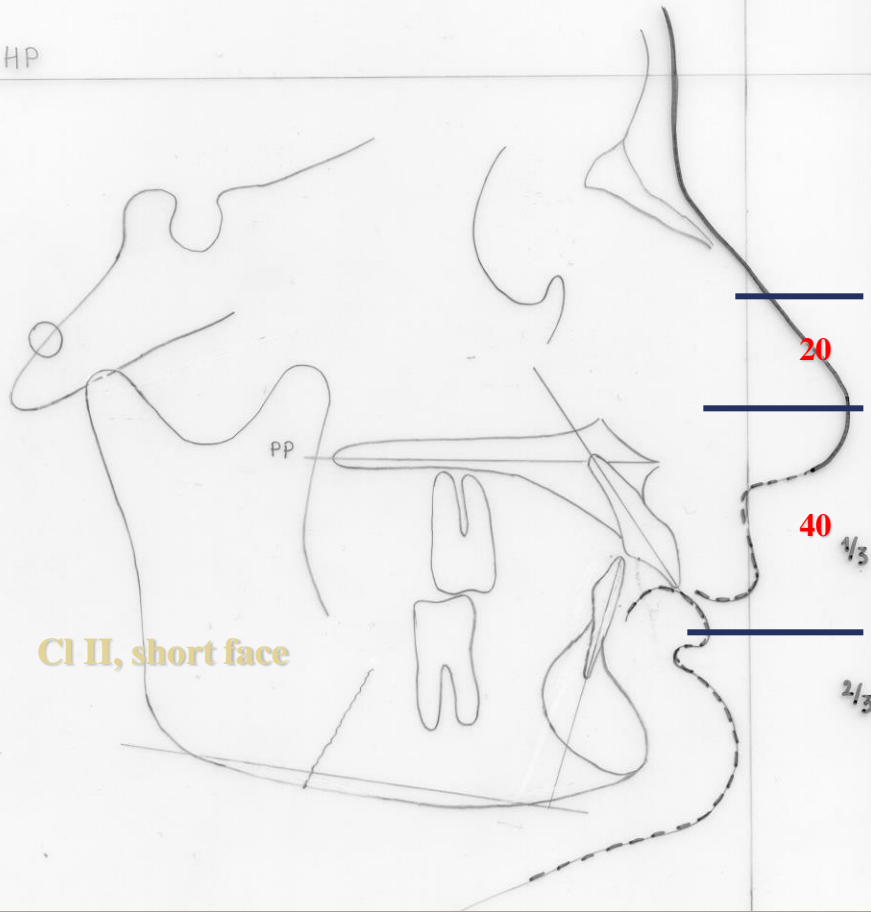


D.7.

PRE OPERATIEF

SHA 76
SIB 71
I_b 116
I_o 94

HP



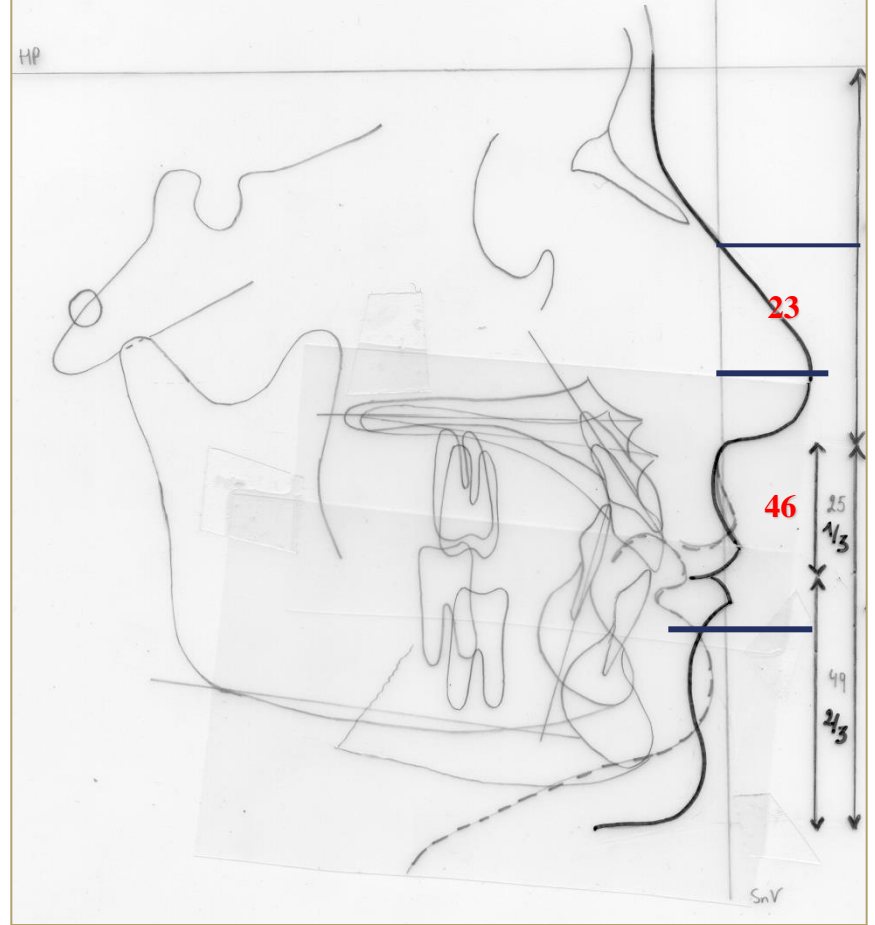
Cl II, short face



D.7.

BK ↓ F5 D0
OK → R2 L3

SHA 79
SIB 71
I_b 116
I_o 94


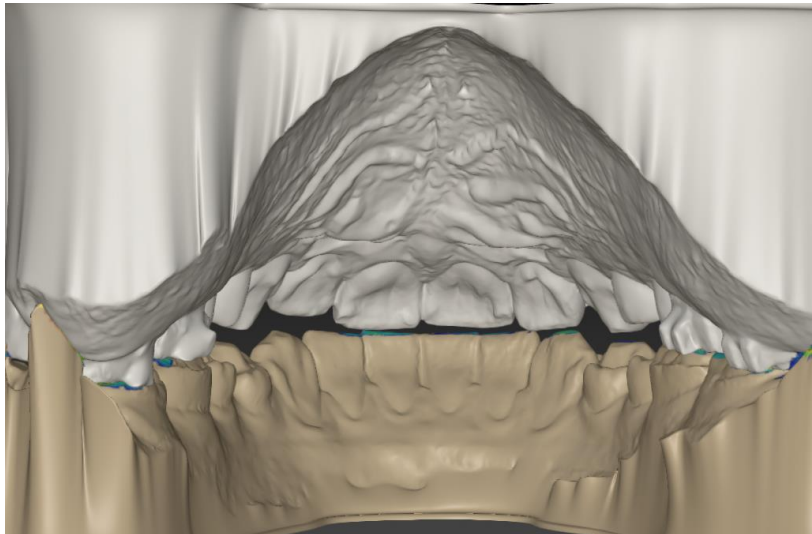
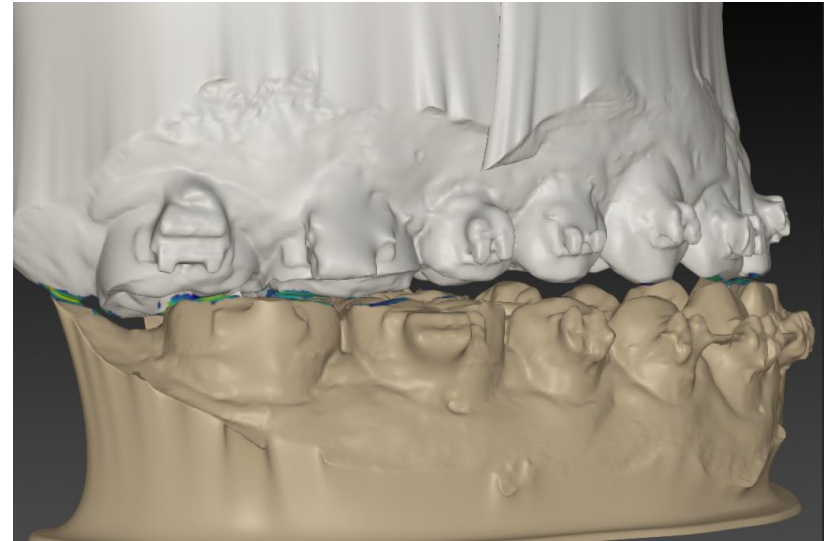
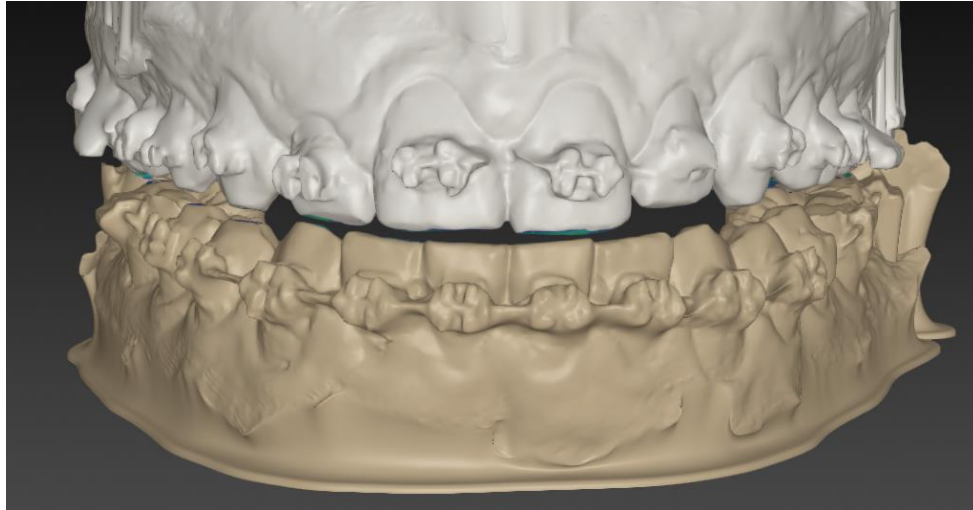
HP



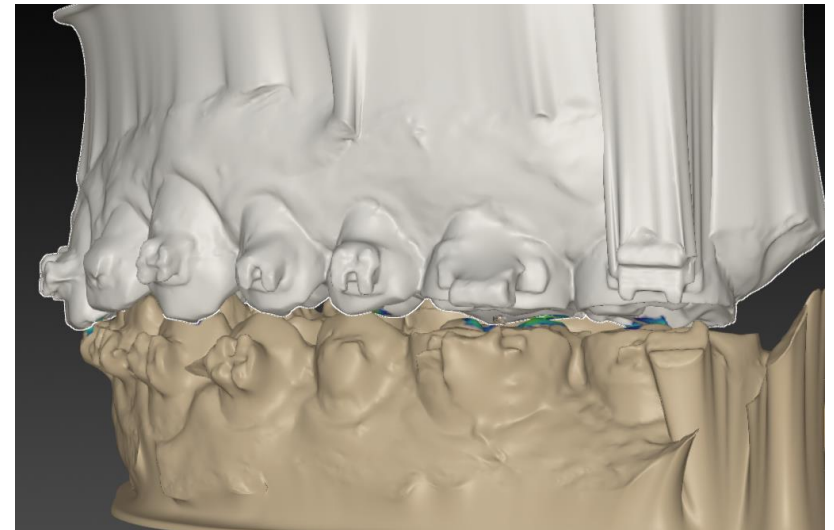
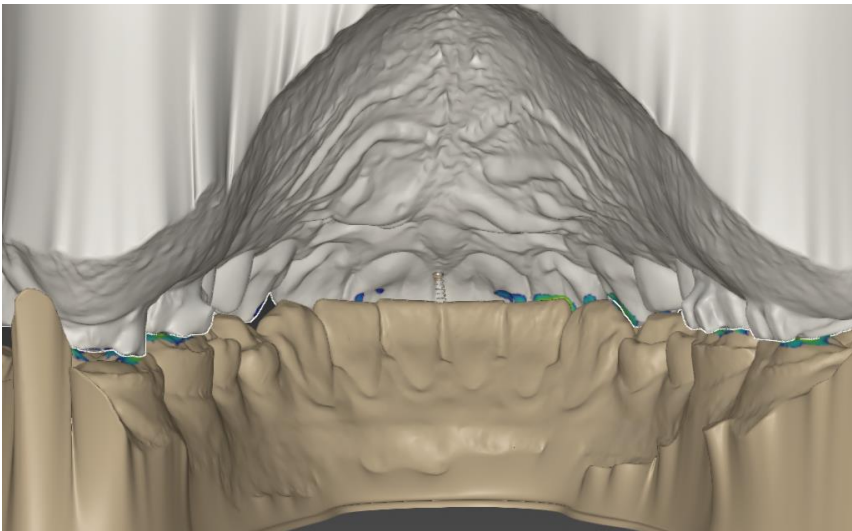
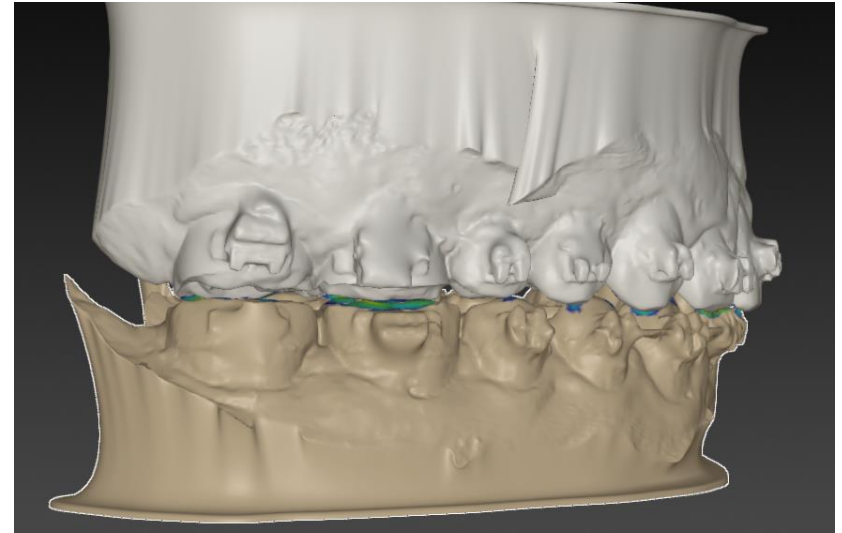
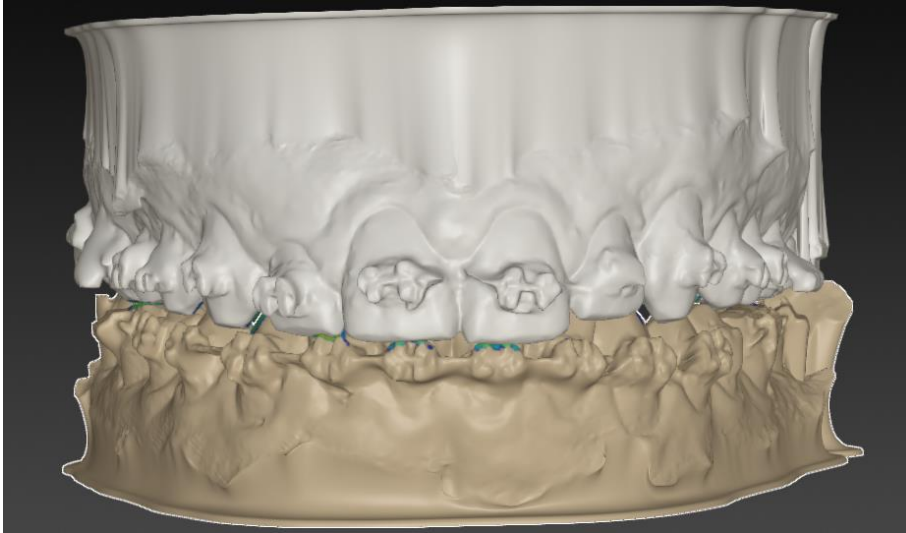


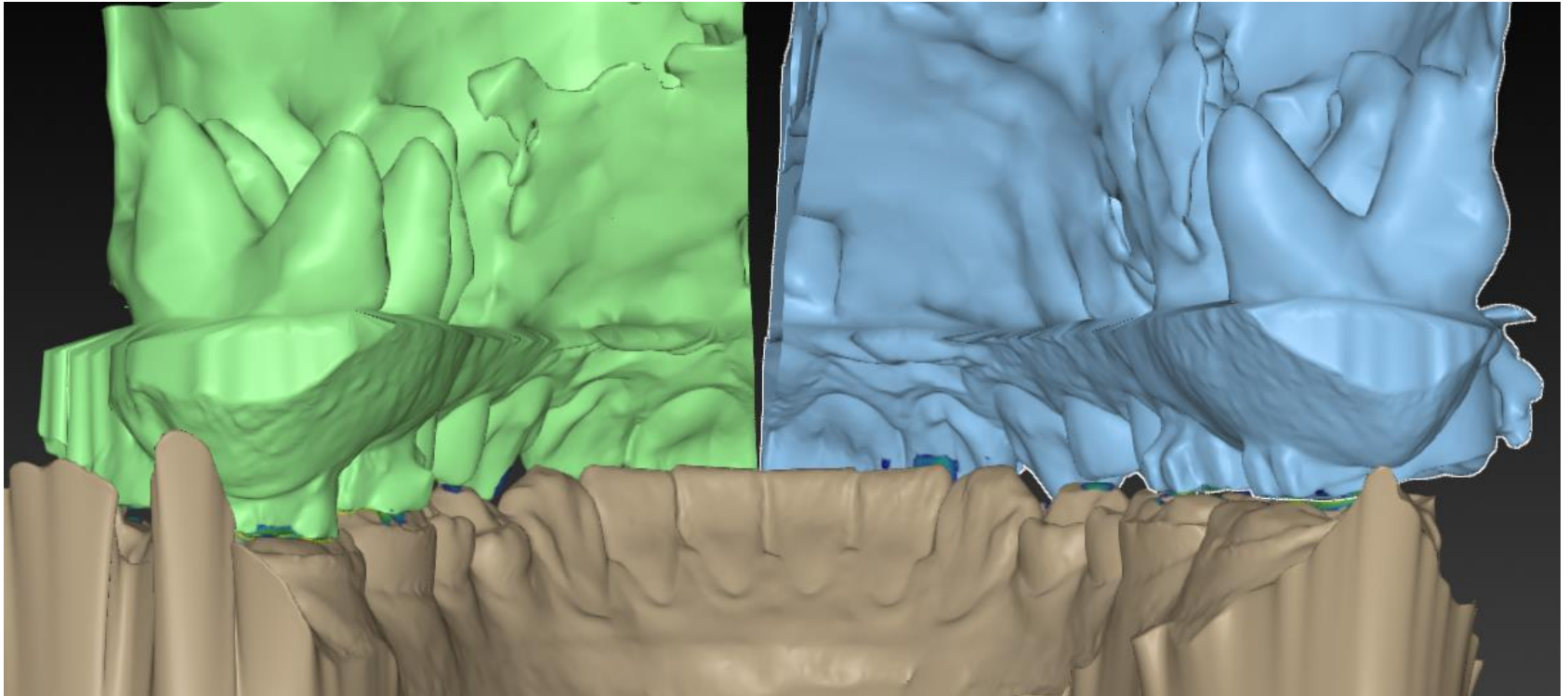




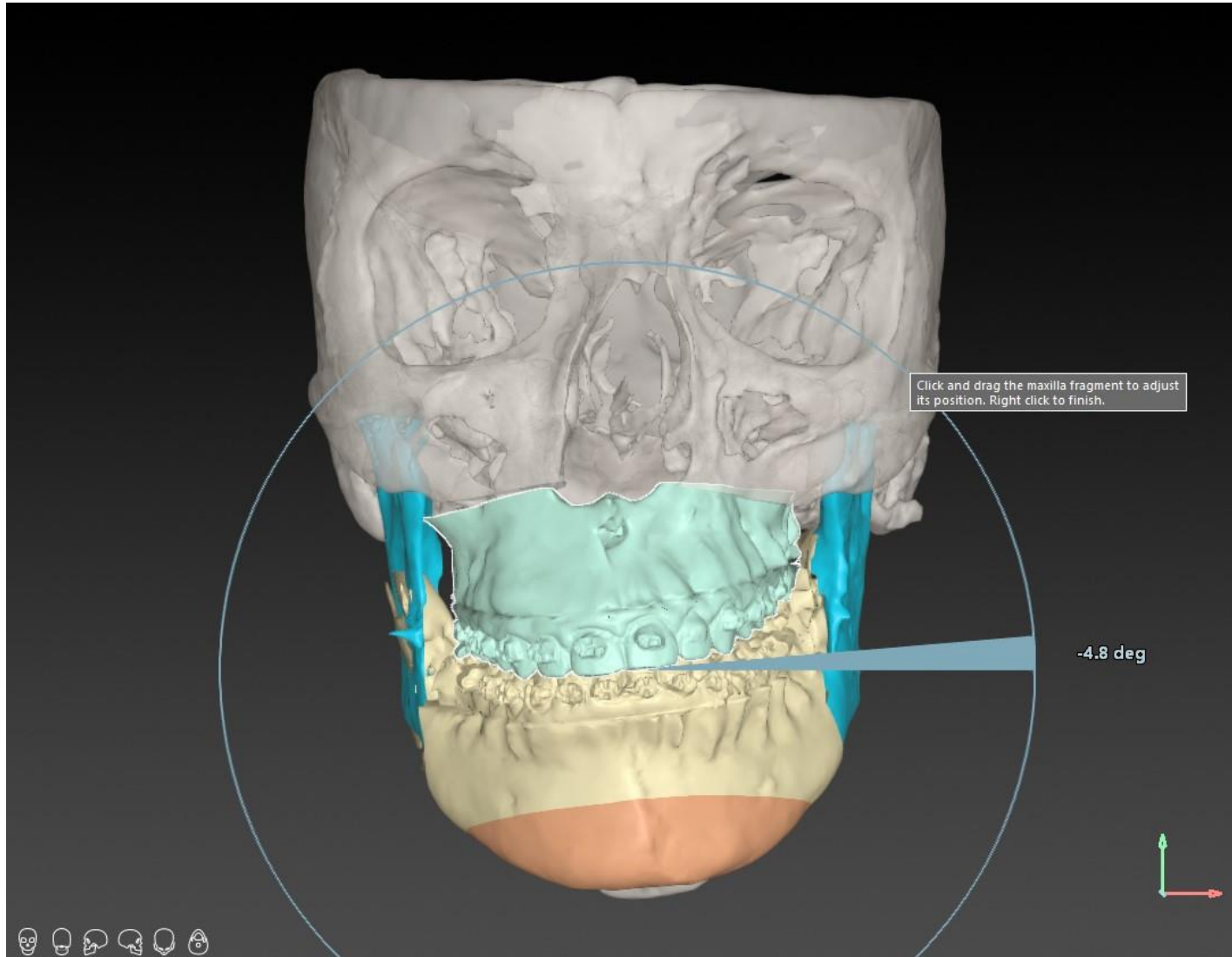


Setting the wish-occlusion

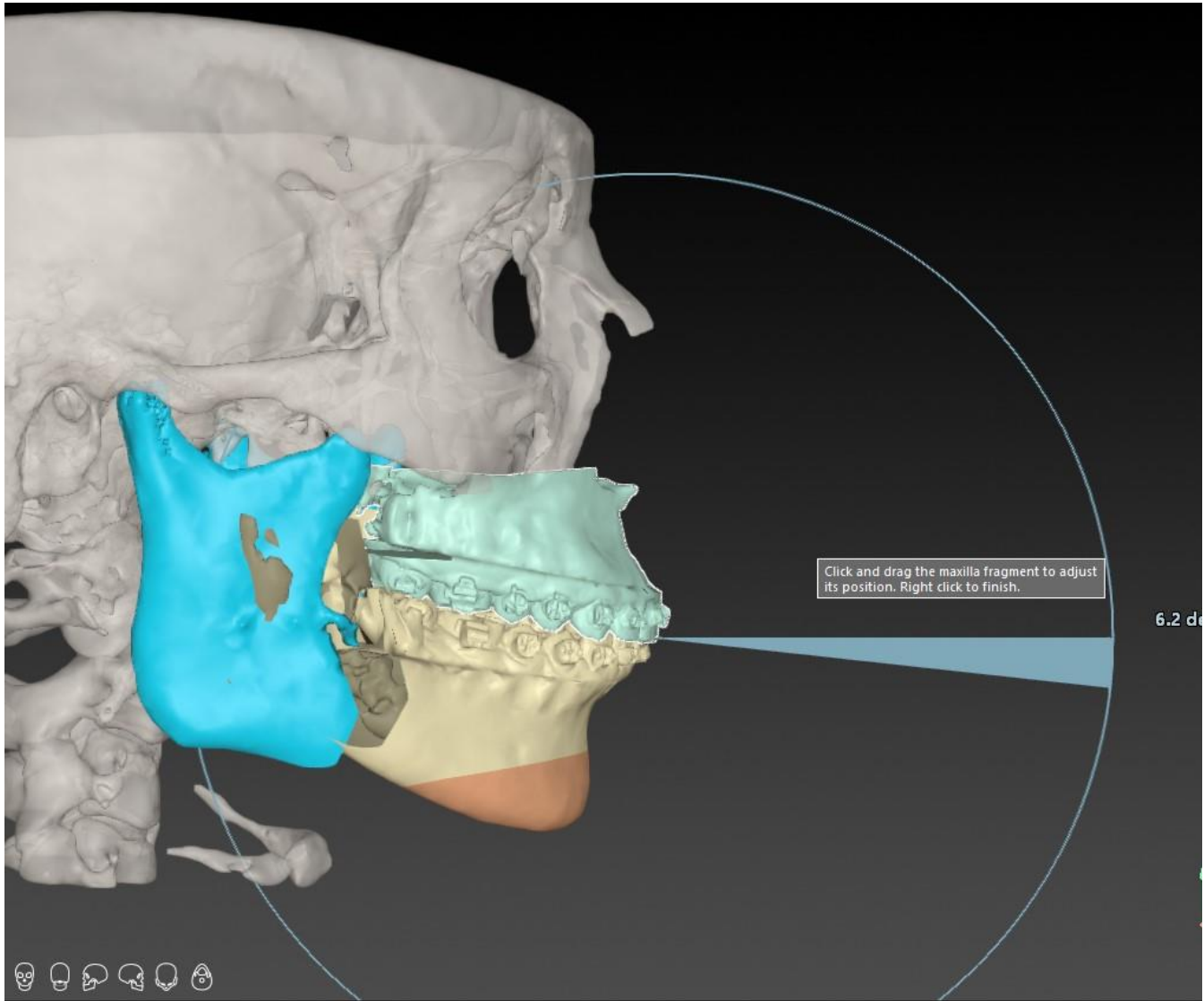




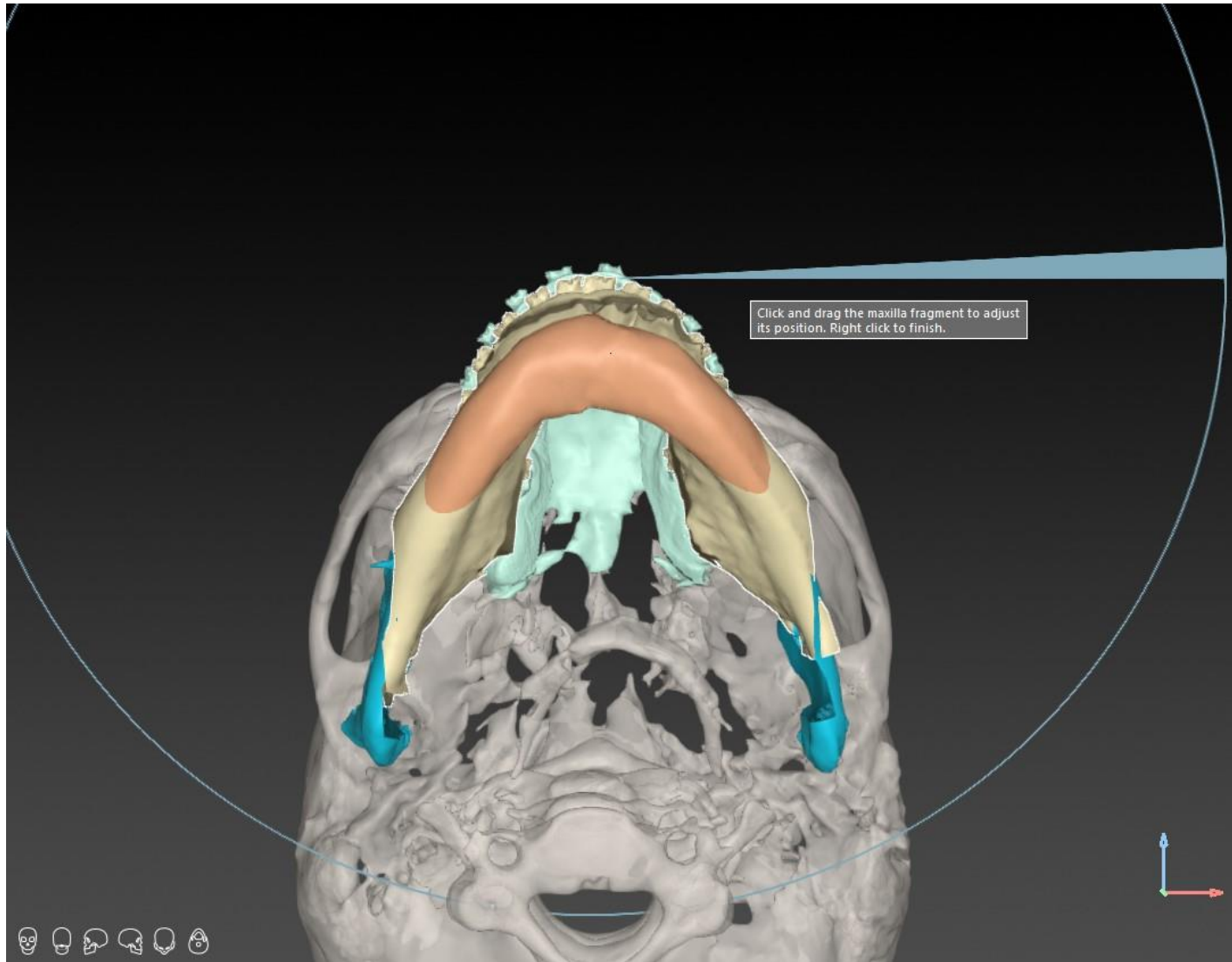
Surgical movements - ROLL

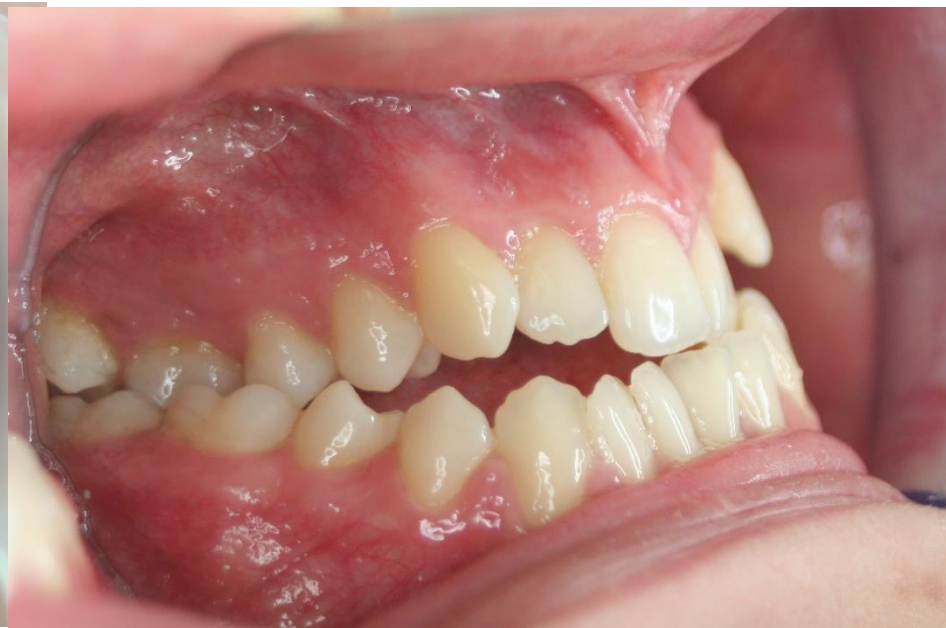
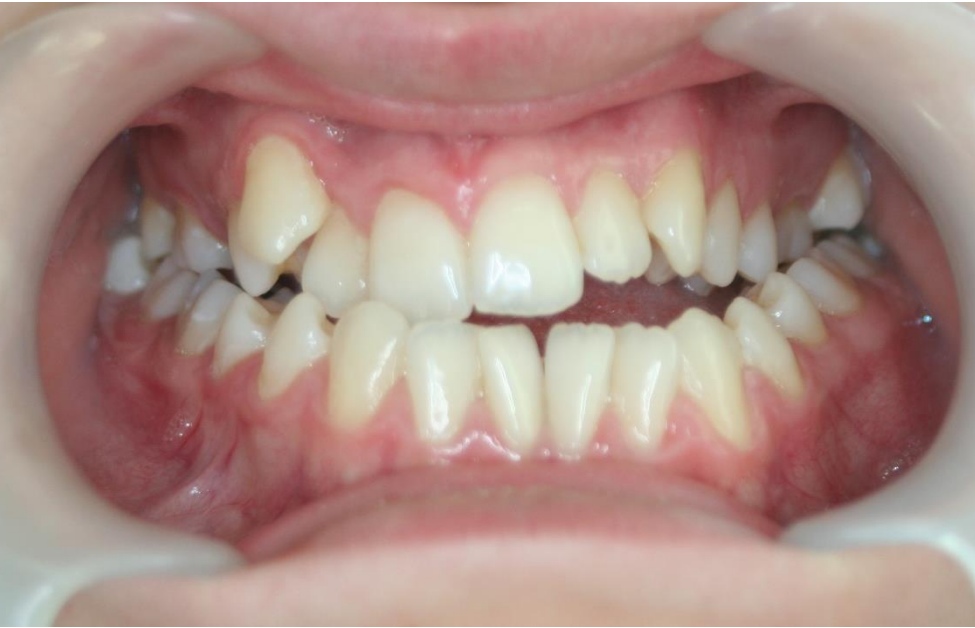
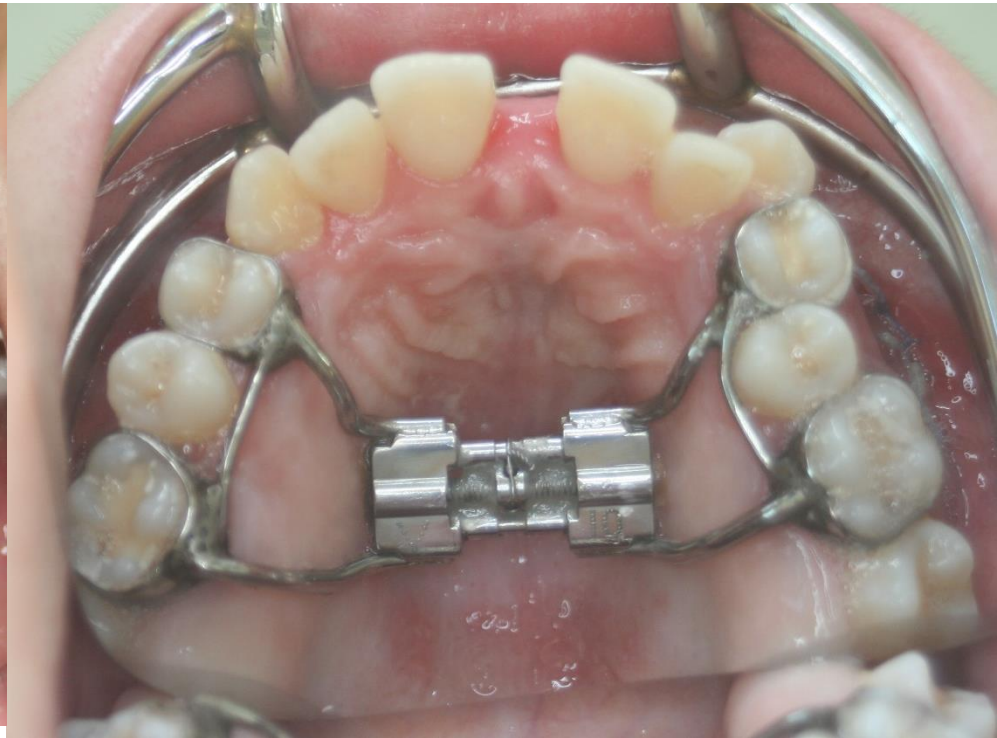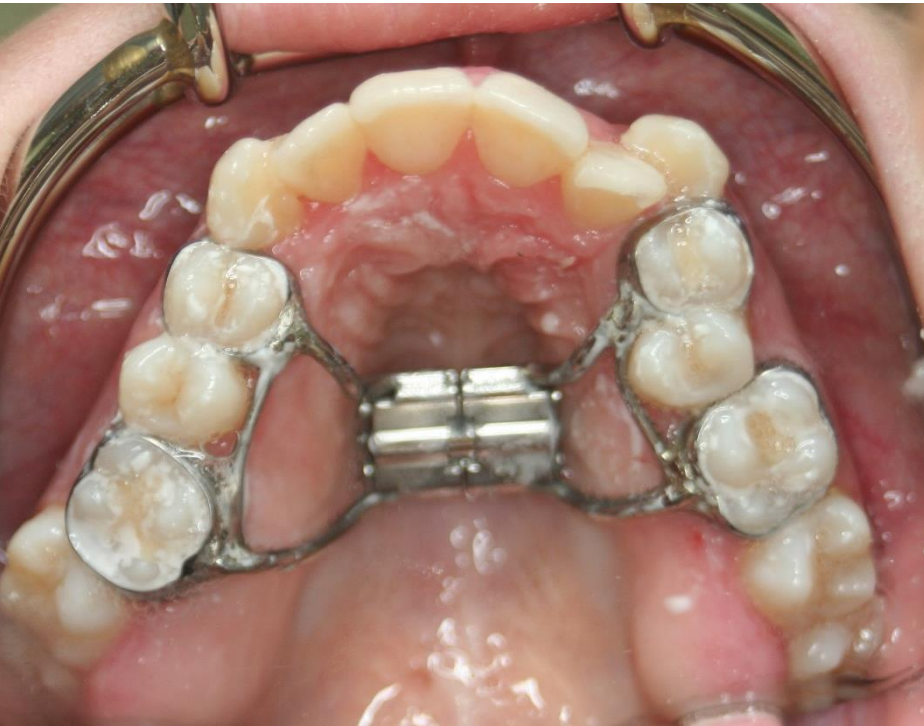Surgical movements - PITCH

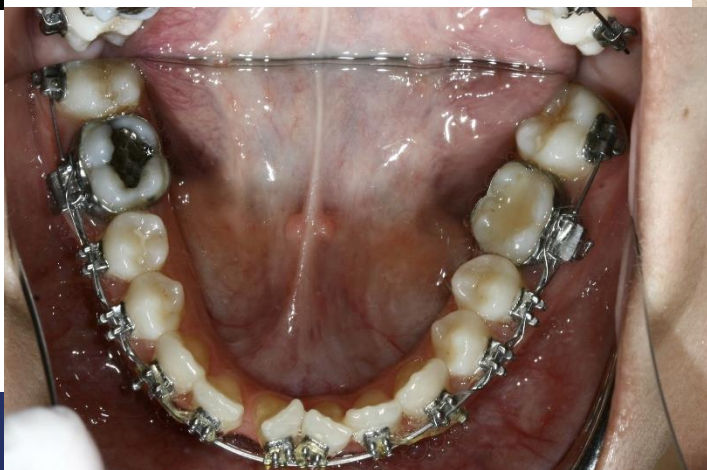
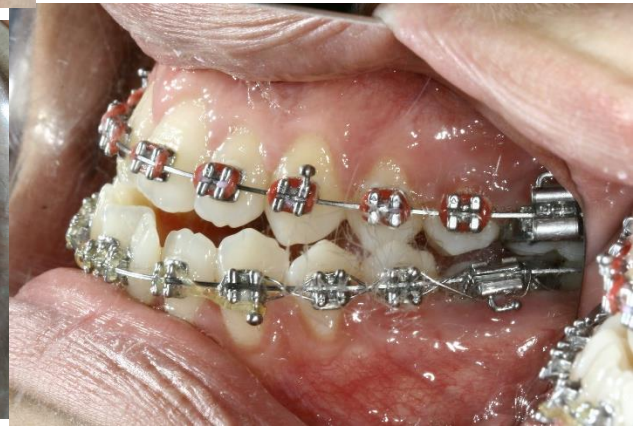
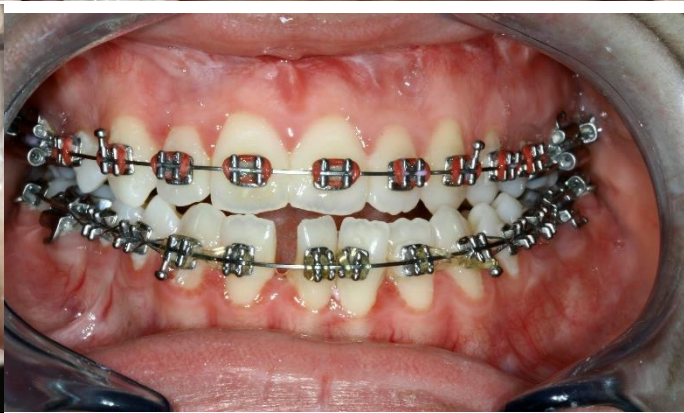
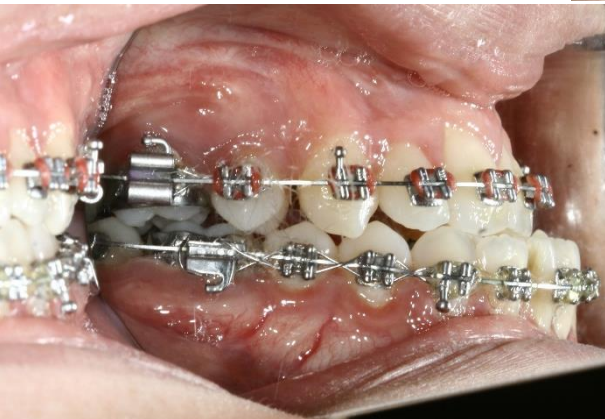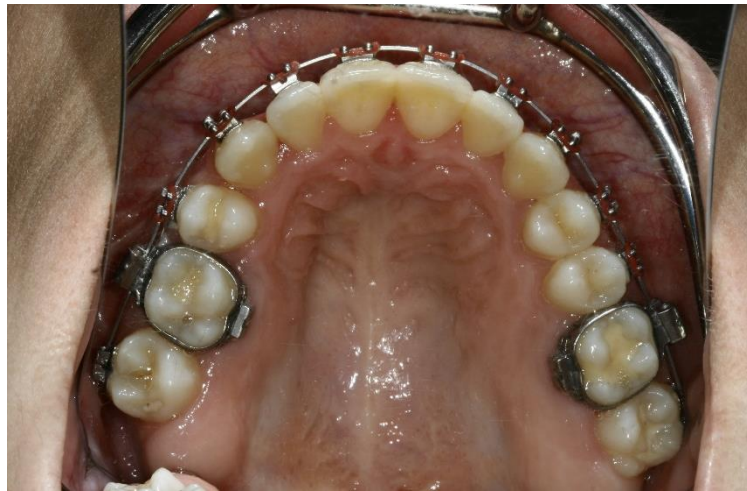Surgical movements - YAW









Name

Dr.Nemes Bálint

Phone

SE Fogszab Klinika

Surgeryt: Bimax osteotomy

Maxilla:

Impaktion

R6: 5mm R3: 3mm

L6: 3mm L3: 1mm

RL1: 0mm

Advancement:

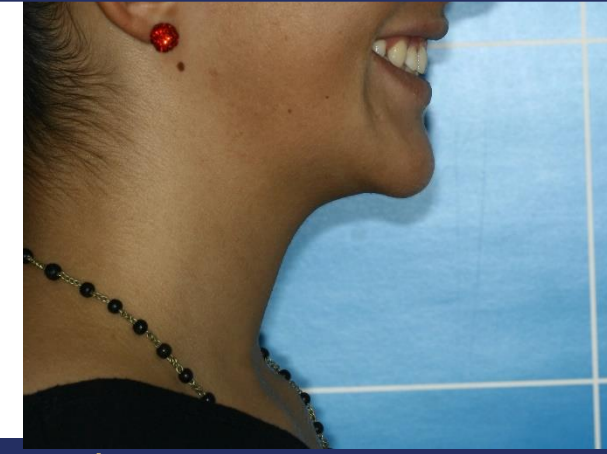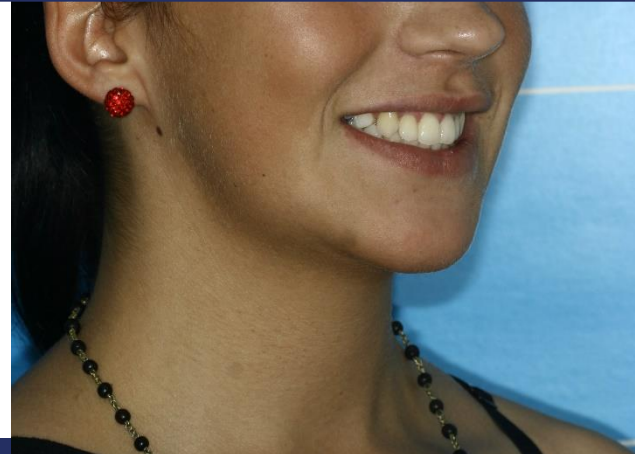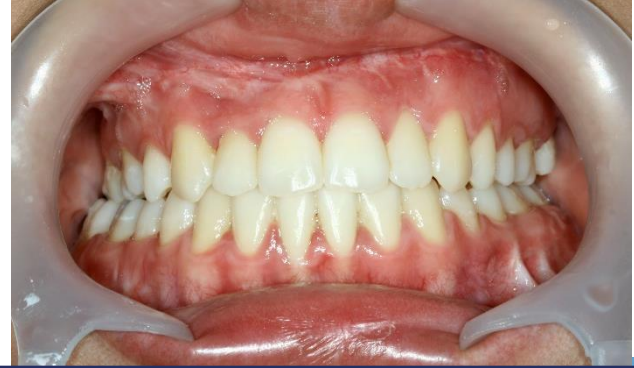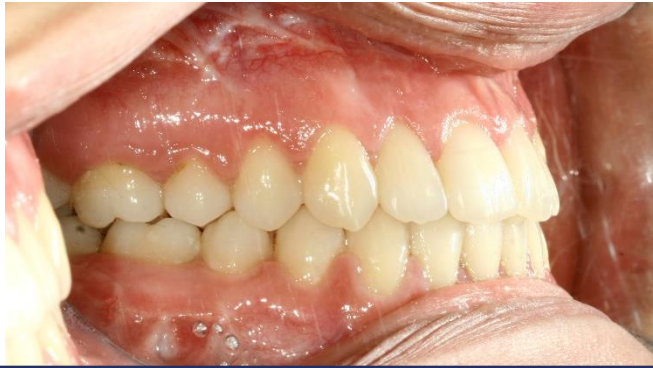R: 4mm L: 1mm

Mandible:

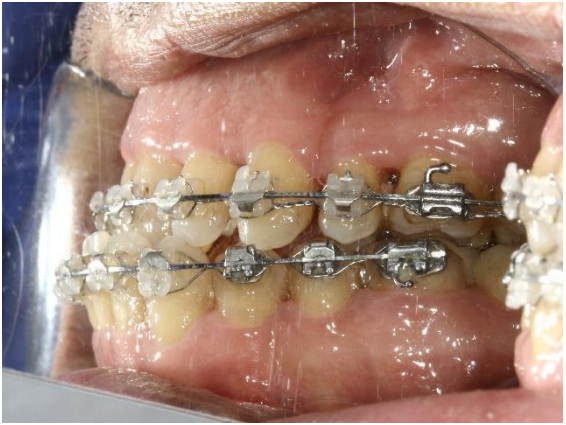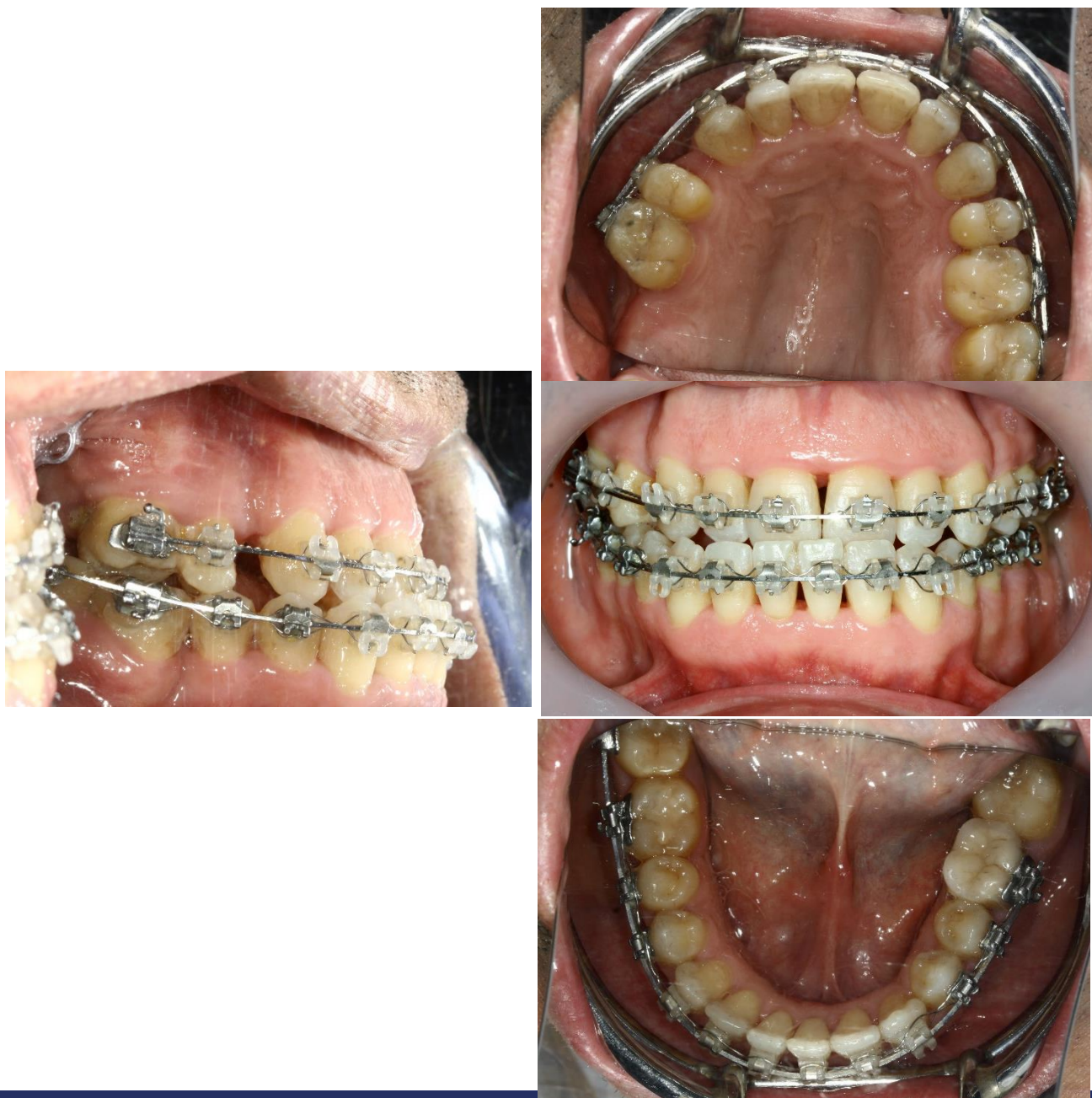Setback:

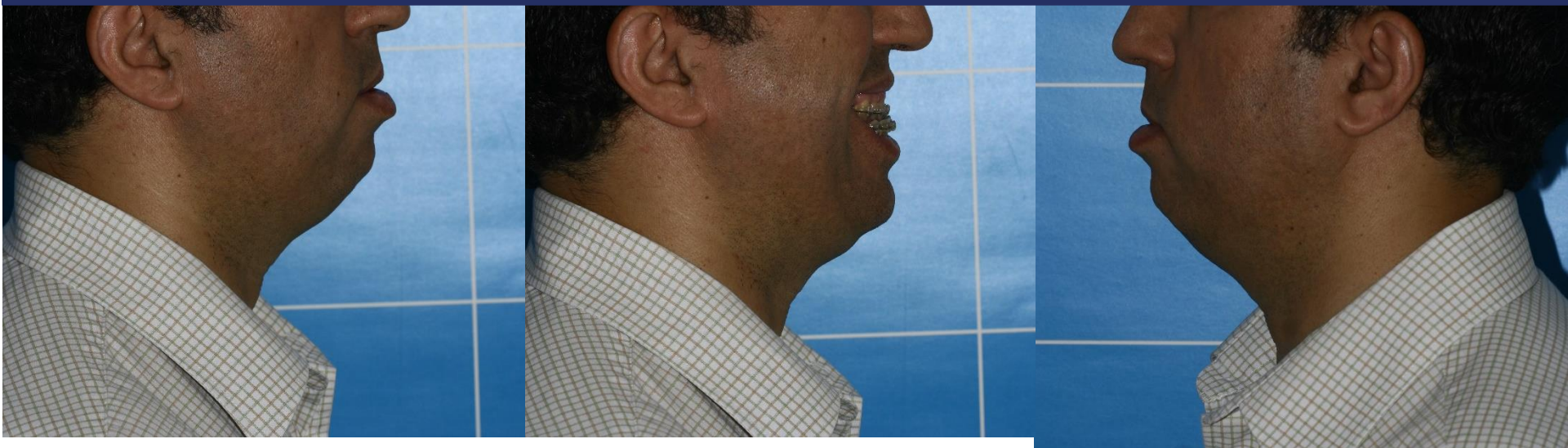
R.: 9mm

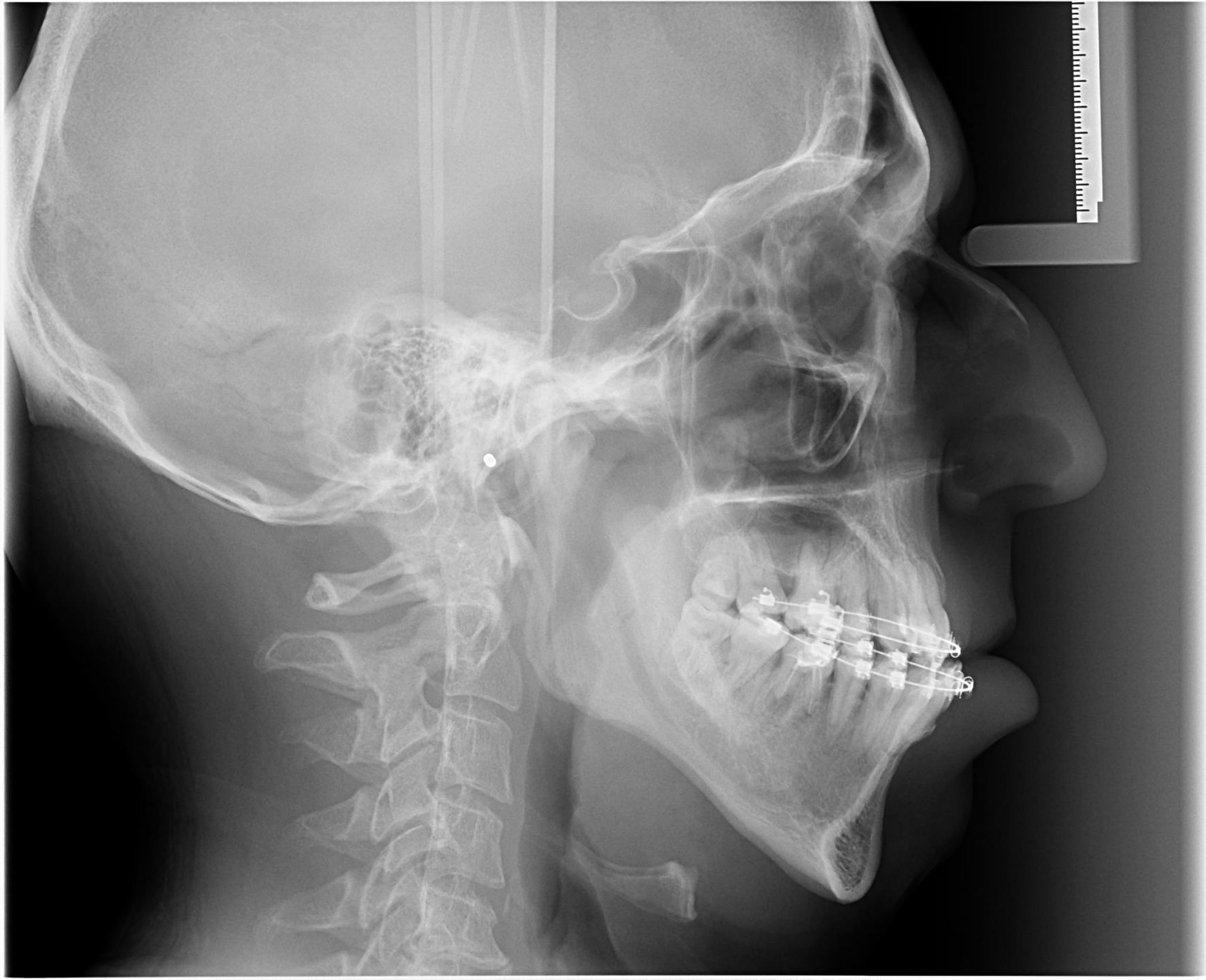
L.: 4mm

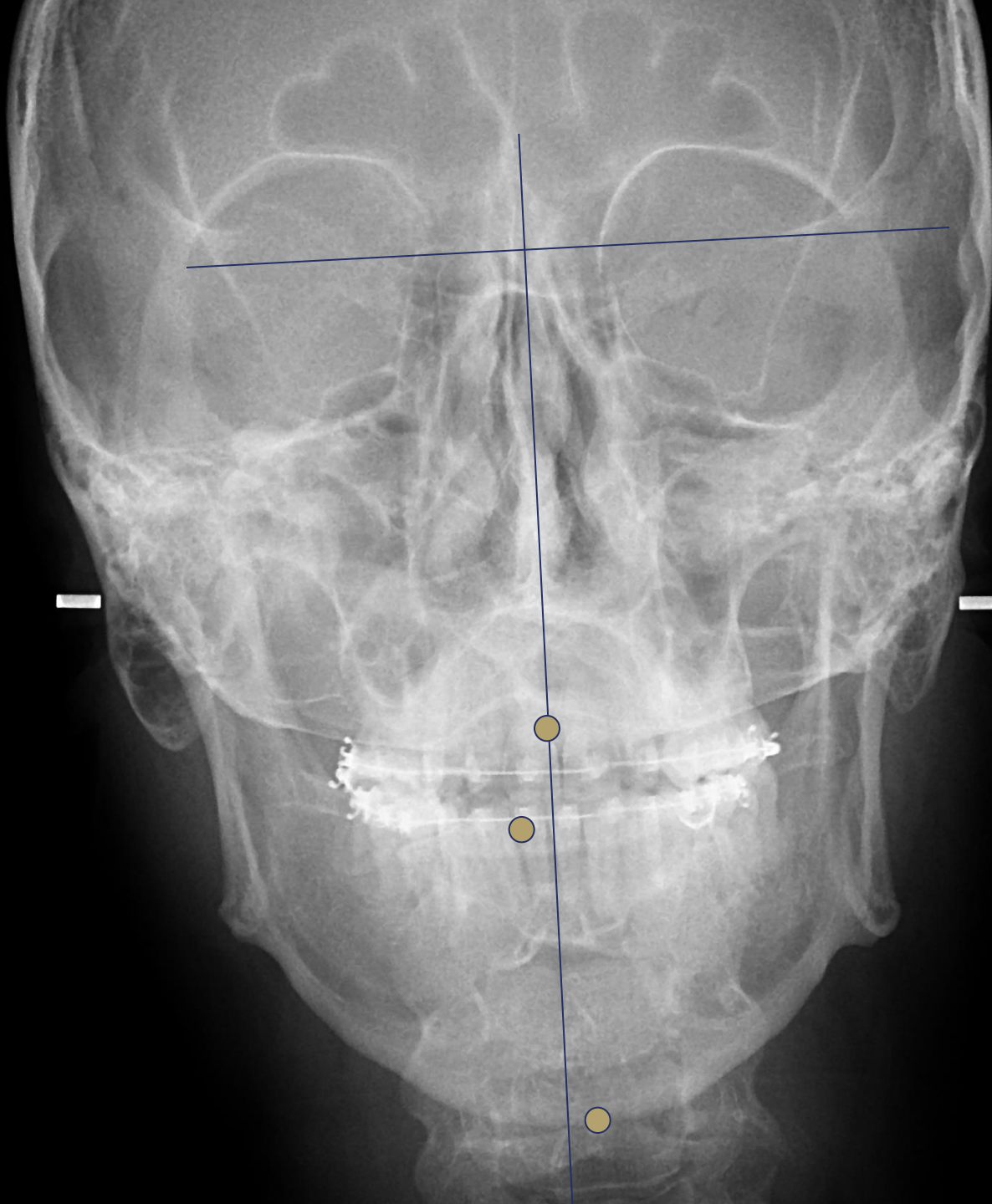


SURGERY: DR. BOGDÁN S









Pacients neve:

Fogszabályozó orvos:

Surgery

Le Fort I advancement

R: 6.5 mm L: 6.5 mm:

BSSO

R: 2.5 mm advancement

L: 2.5 mm setback

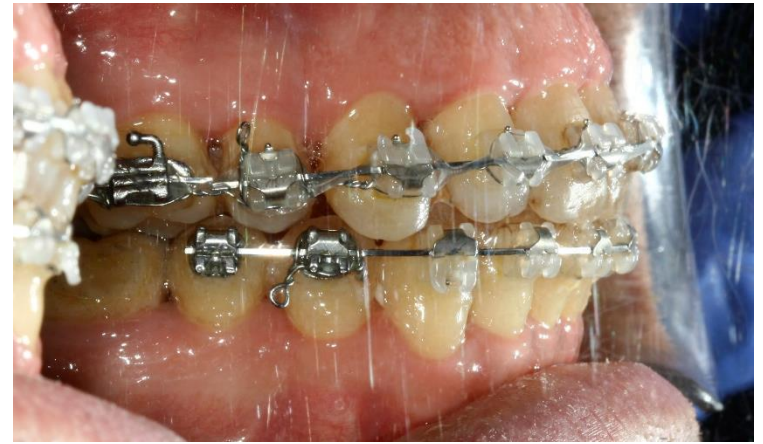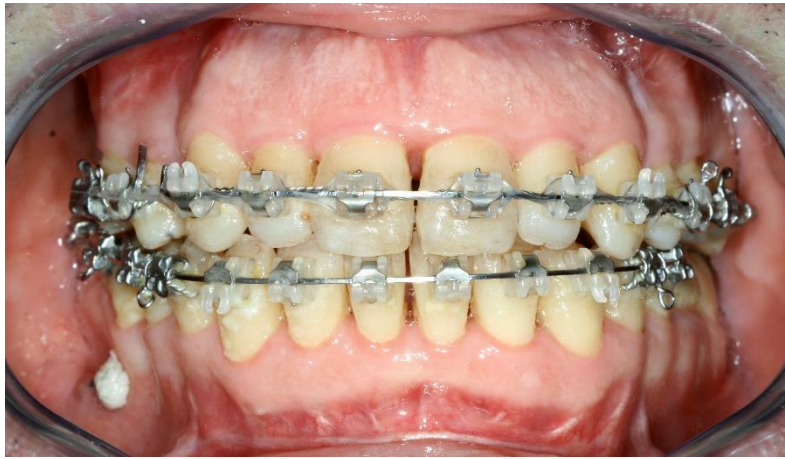ML: 2.5 mm to the left

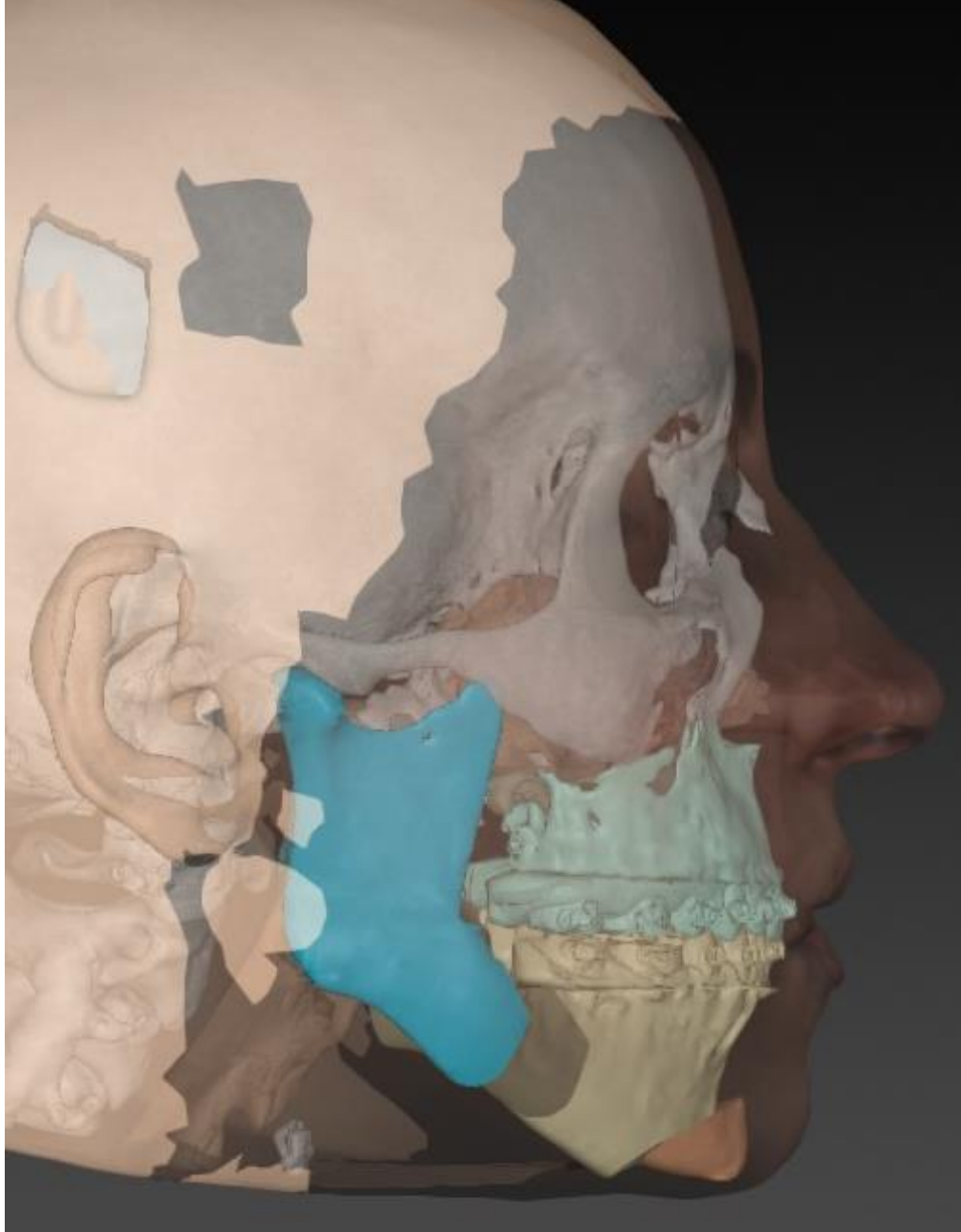
Genioplasty:

Vertikal 4 mm slice out

Saggitally 5mm advancement

Transversal 7mm to the right





Thank you for your
attention!