

Orthodontics

subject

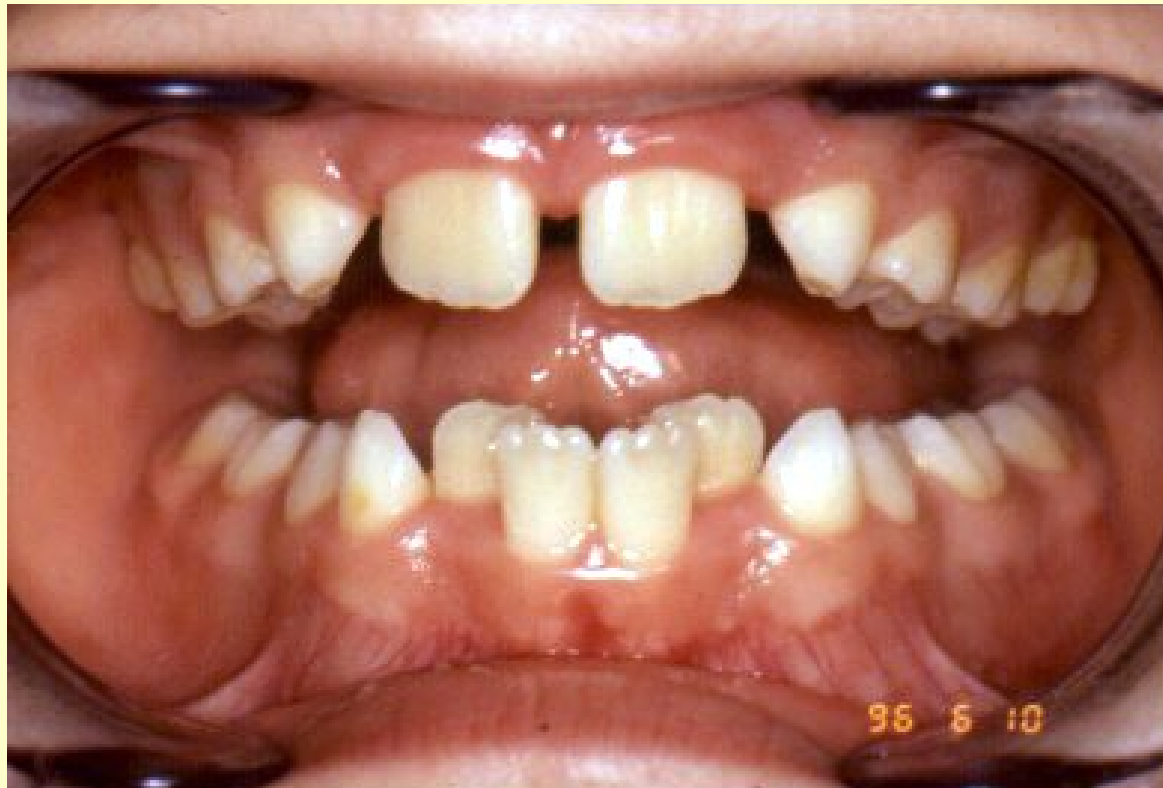significans

relations

Subject of orthodontics

diagnosis, treatment, prevention of the anomalies of the dentition

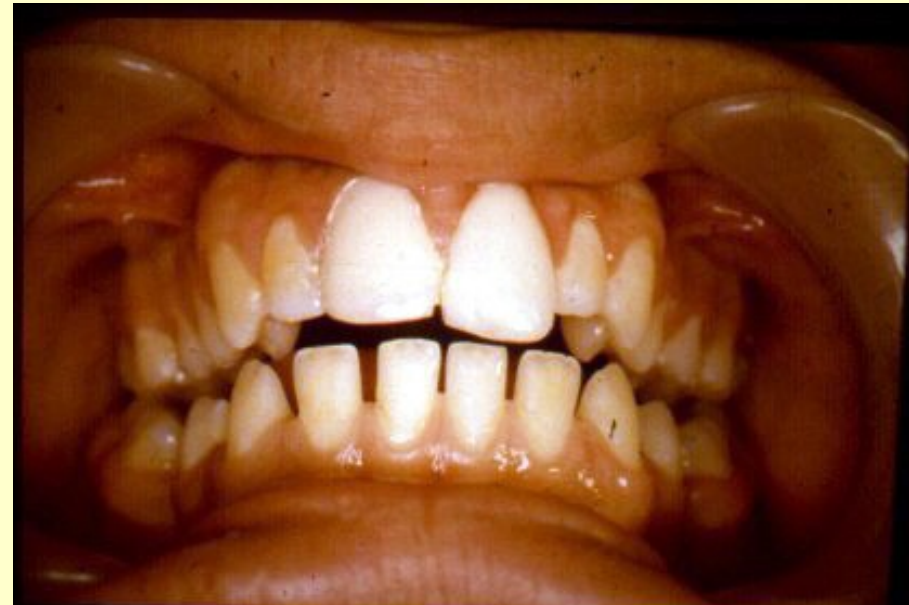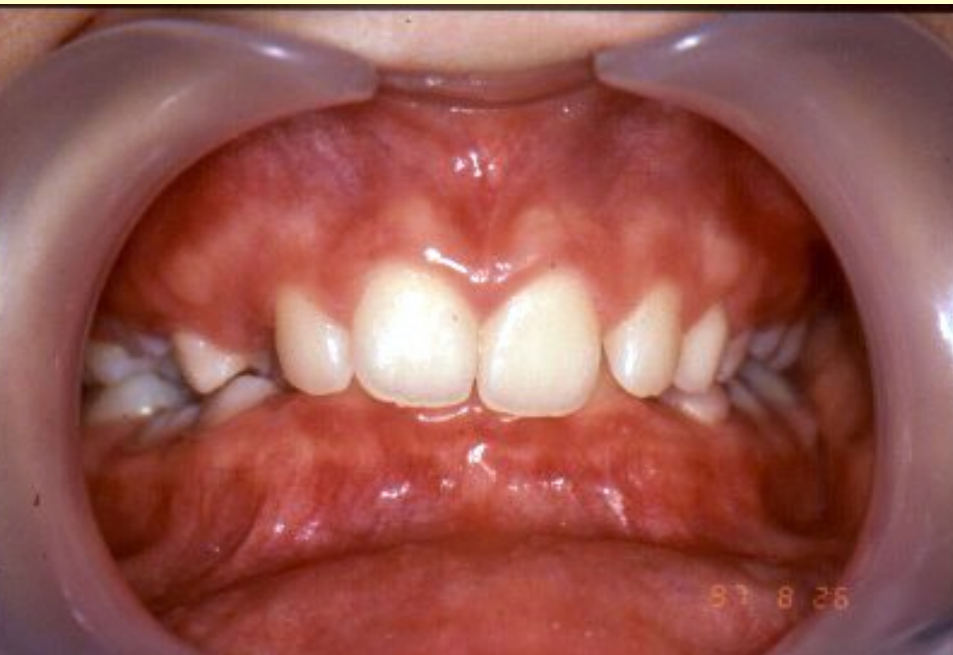form and position of teeth, dental arch, jaws



Subject of orthodontics

diagnosis, treatment, prevention of the anomalies of the dentition

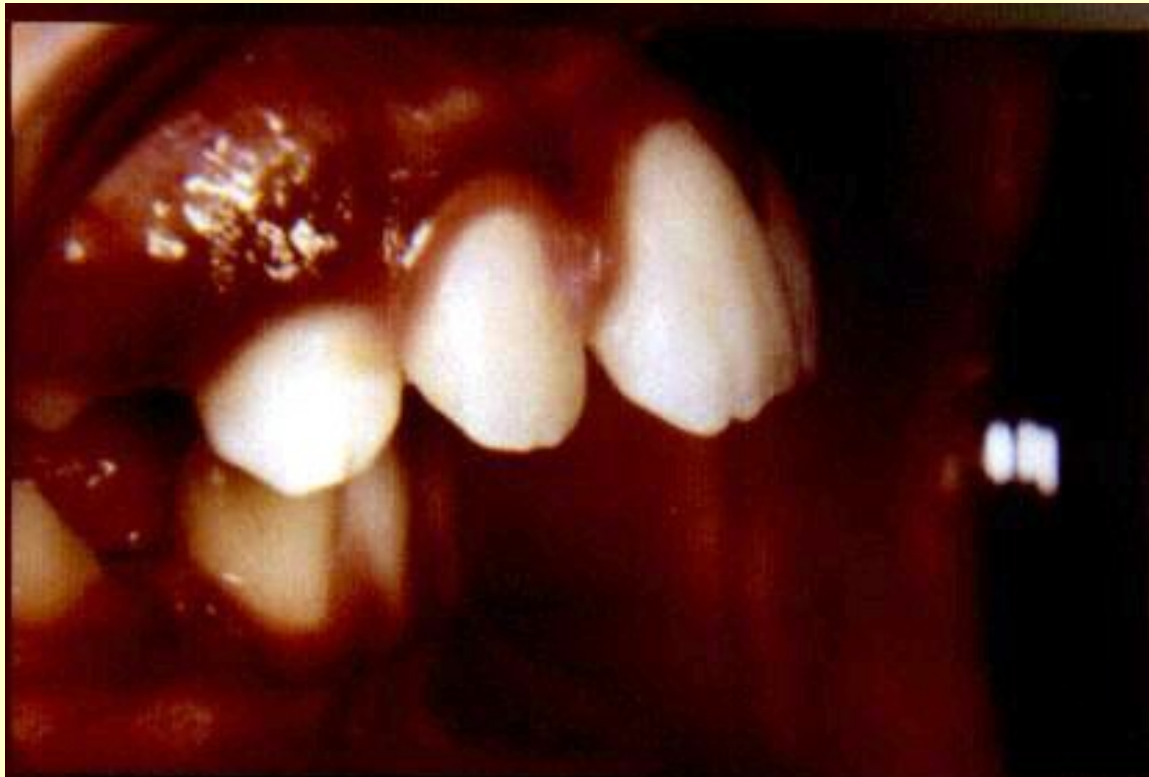form and position of teeth, dental arch, jaws



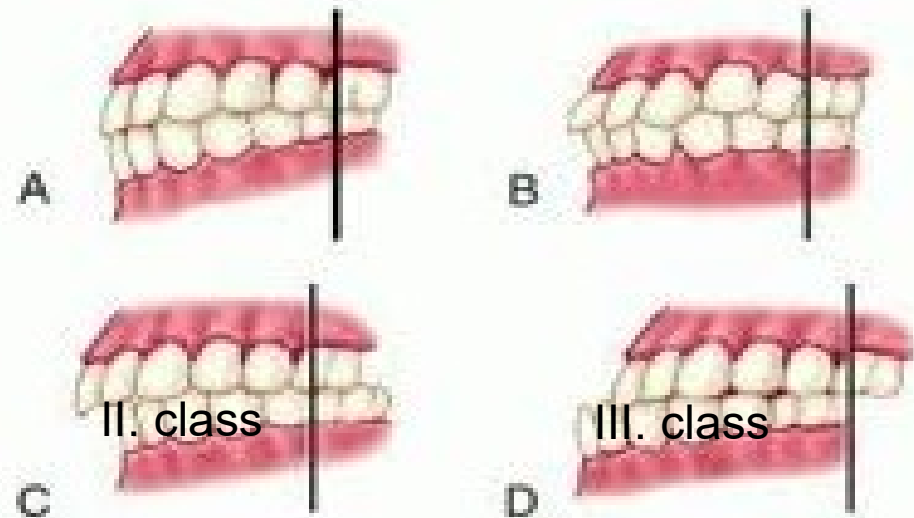

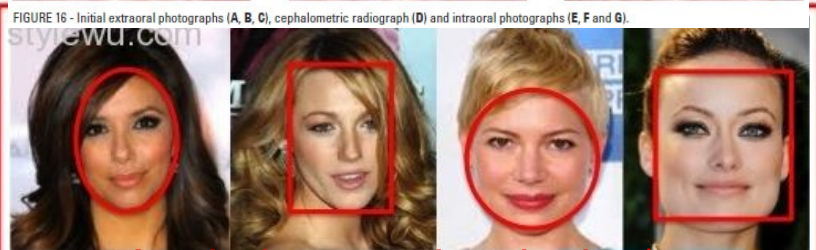
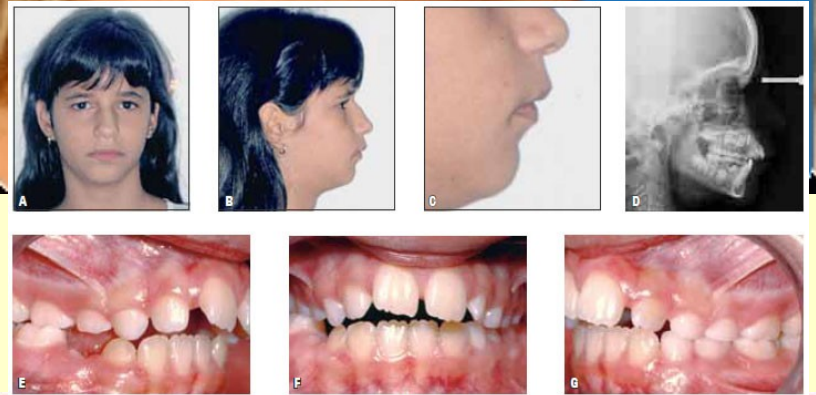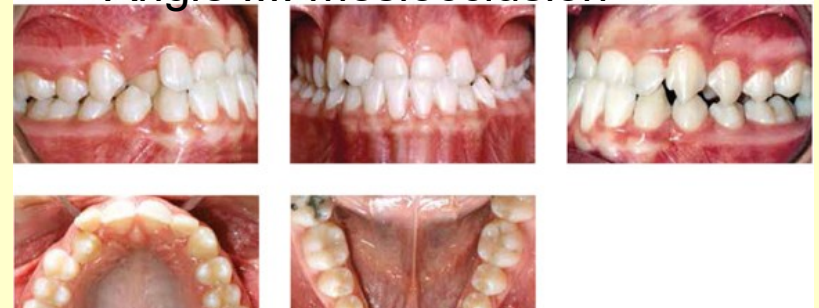
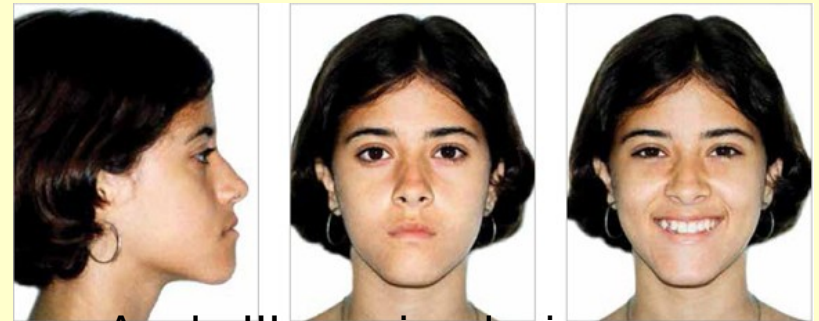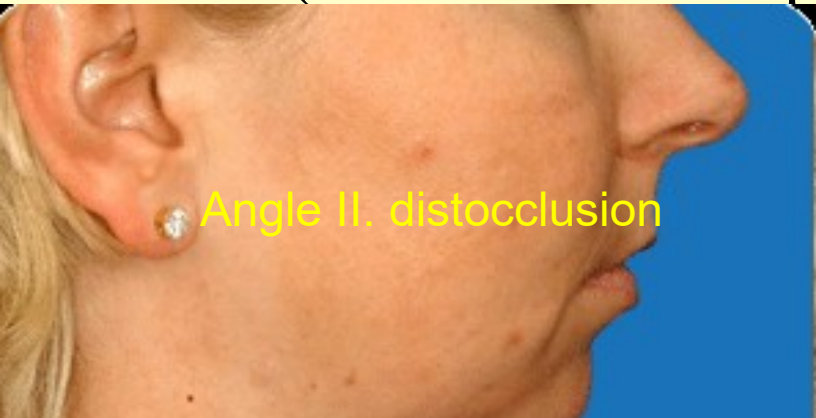Subject of orthodontics

diagnosis, treatment, prevention of the anomalies of the
dentition

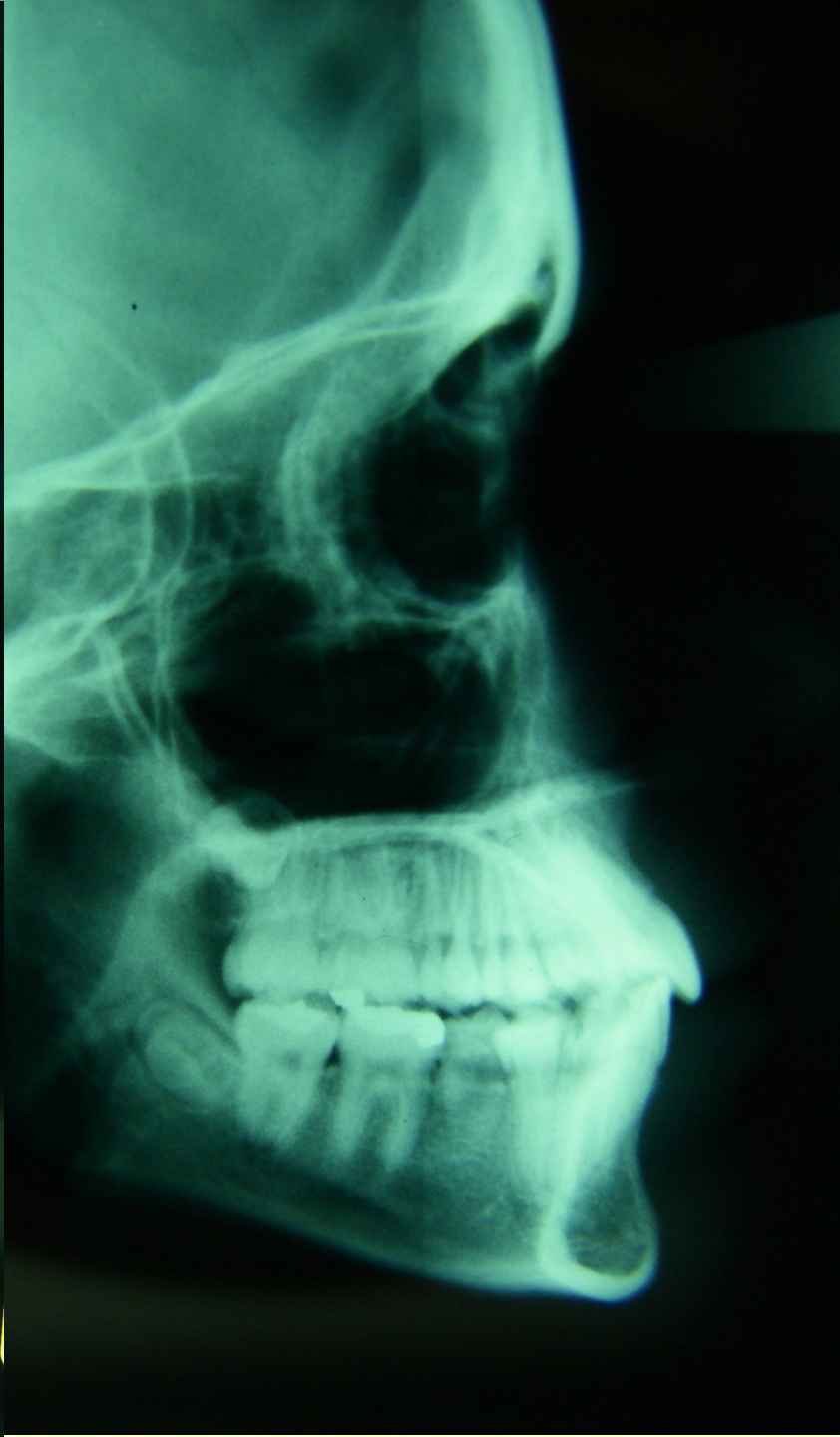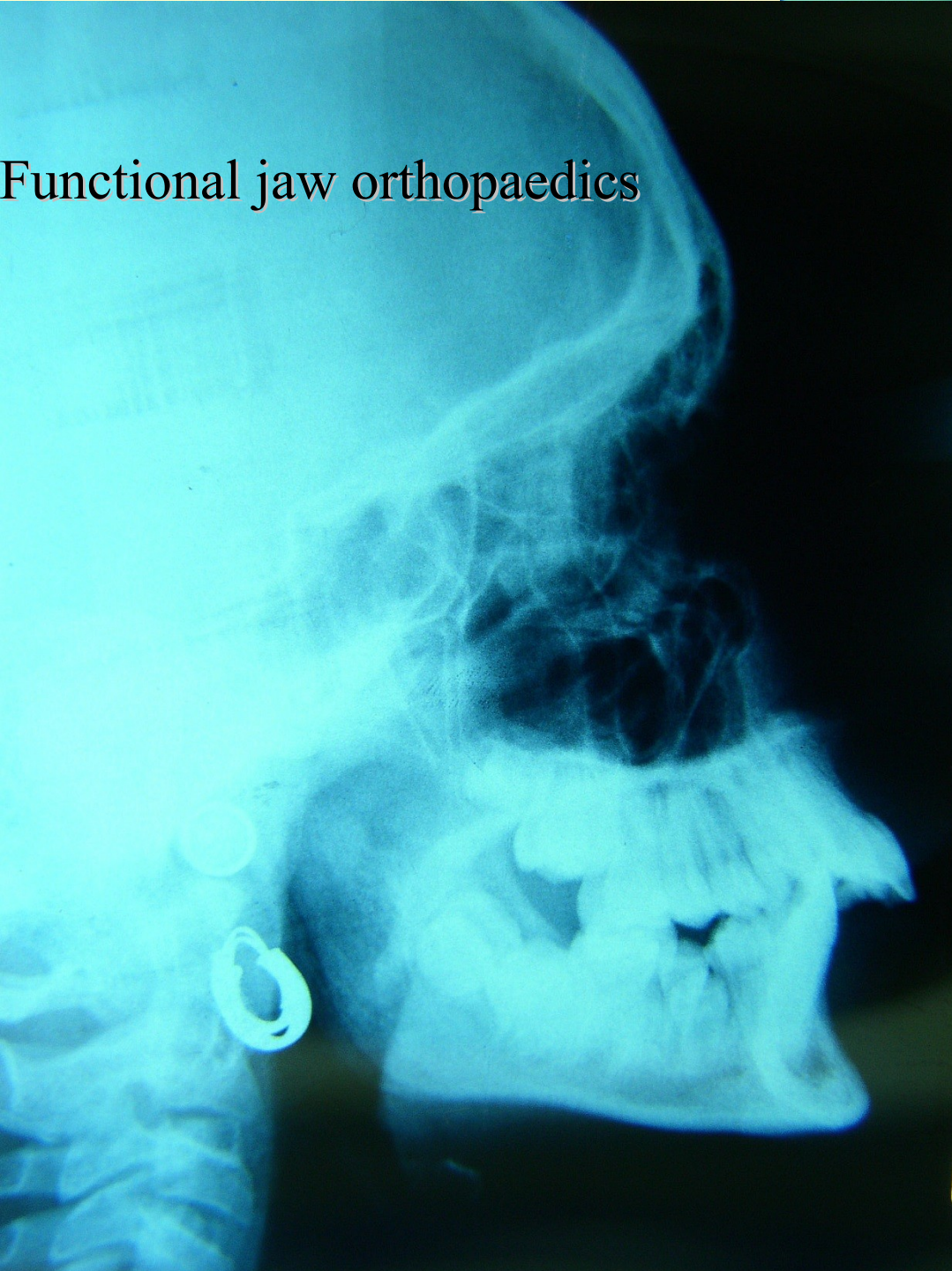
form and position of teeth, dental arch, jaws



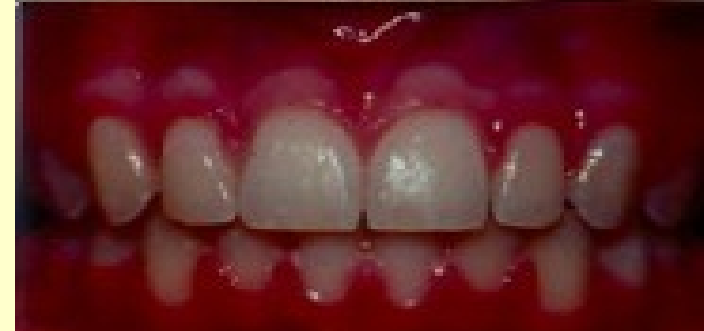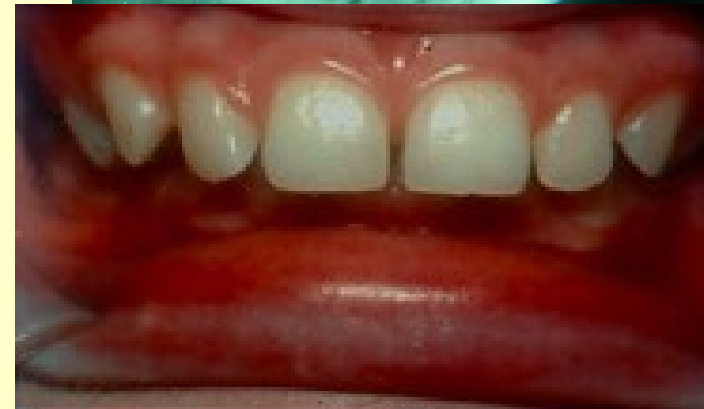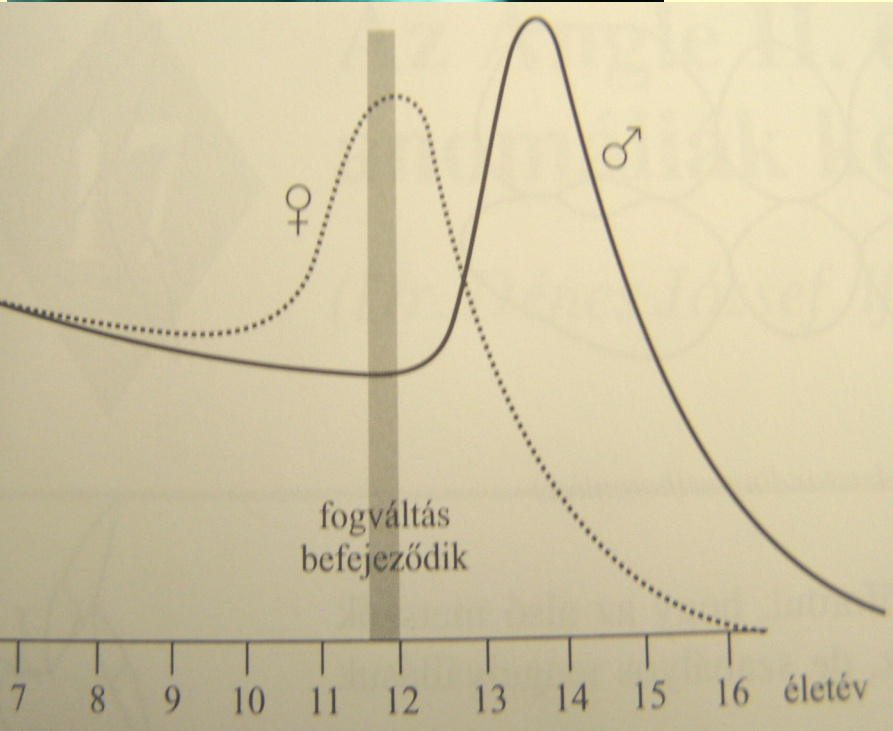
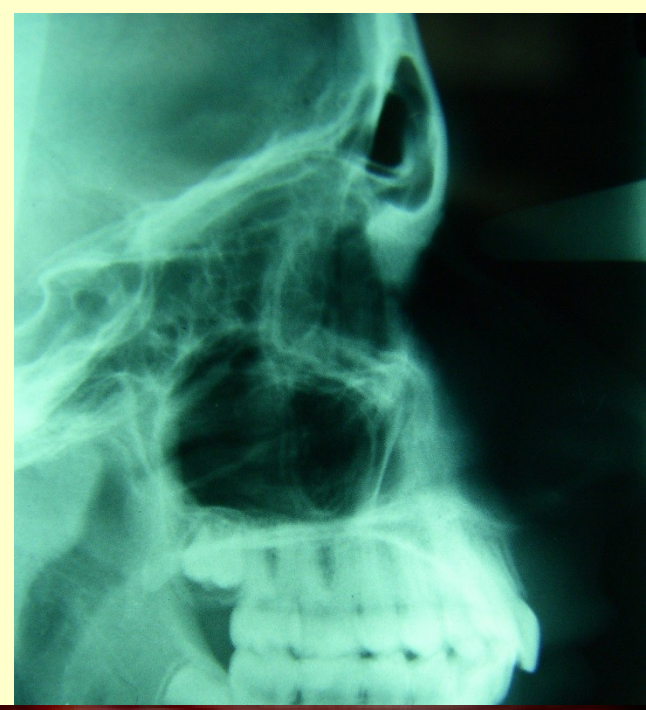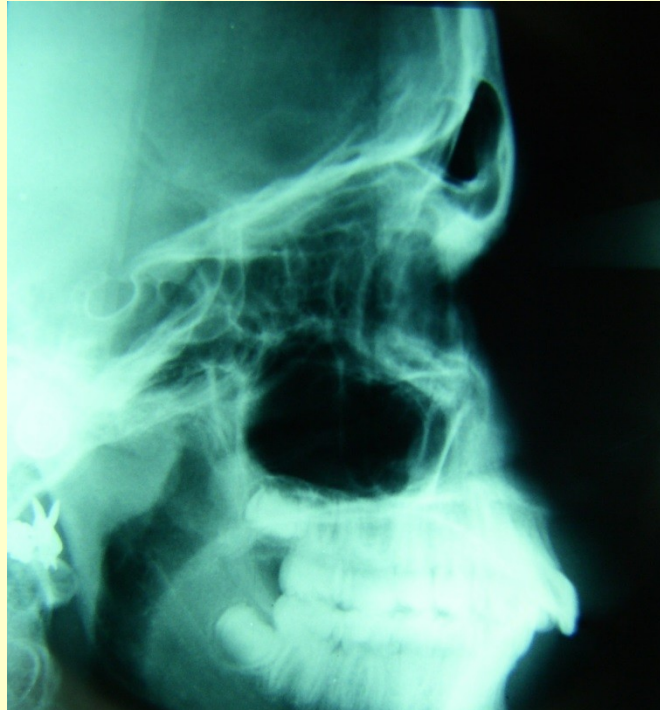Sagittal anomalies - Angle classification (based on: anteroposterior relationship of the jaws)



Functional jaw orthopaedics

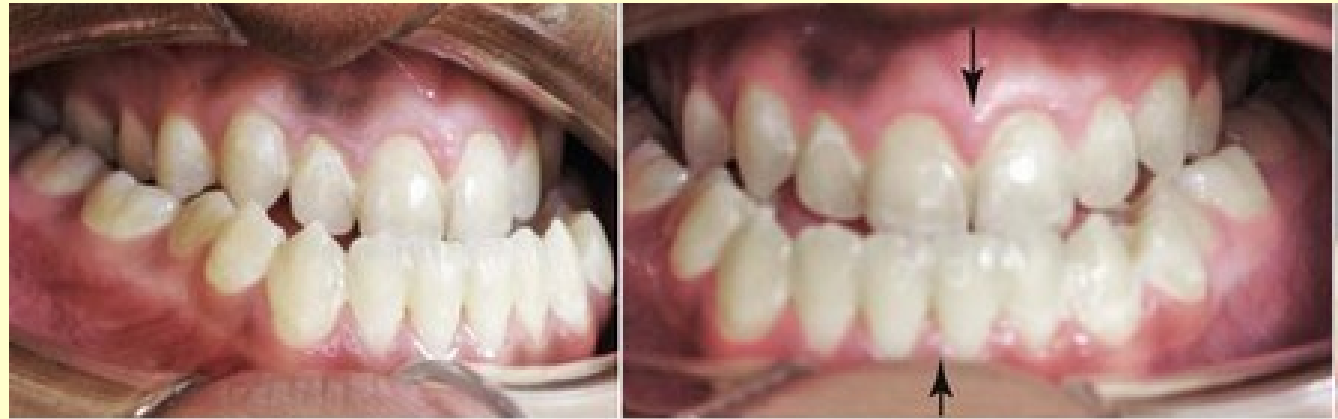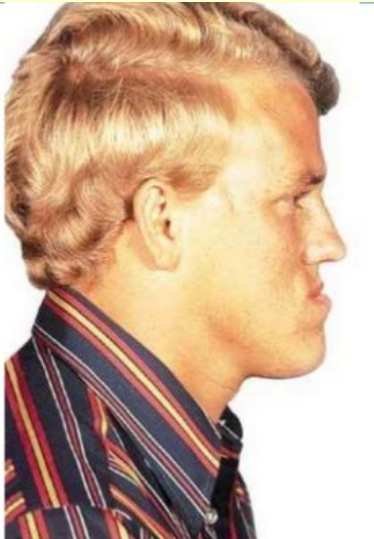


Class II



Class III cases

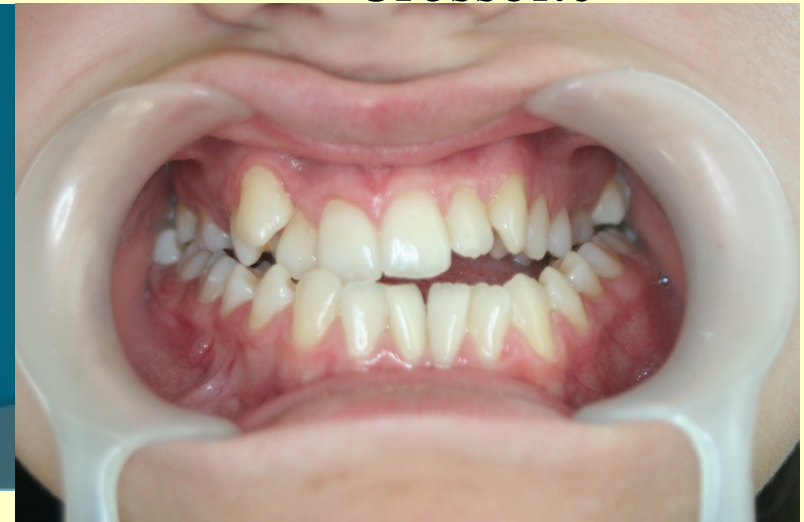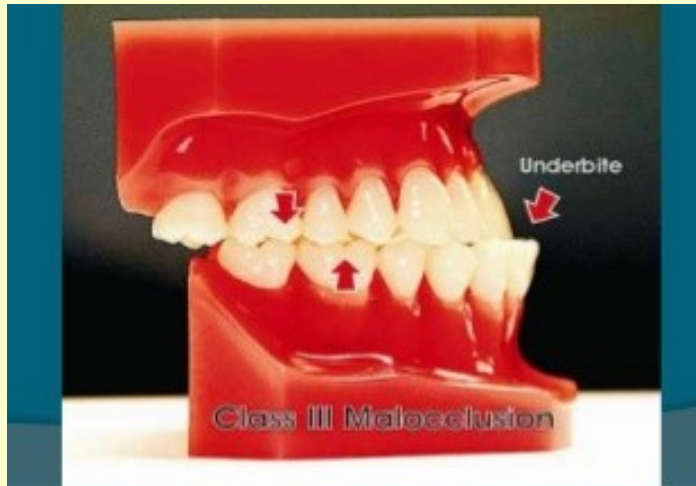
- The lower jaw is too large or placed forward
- Progenie
- Bulldog bite
- Mesialocclusion
- Class III.



Class III

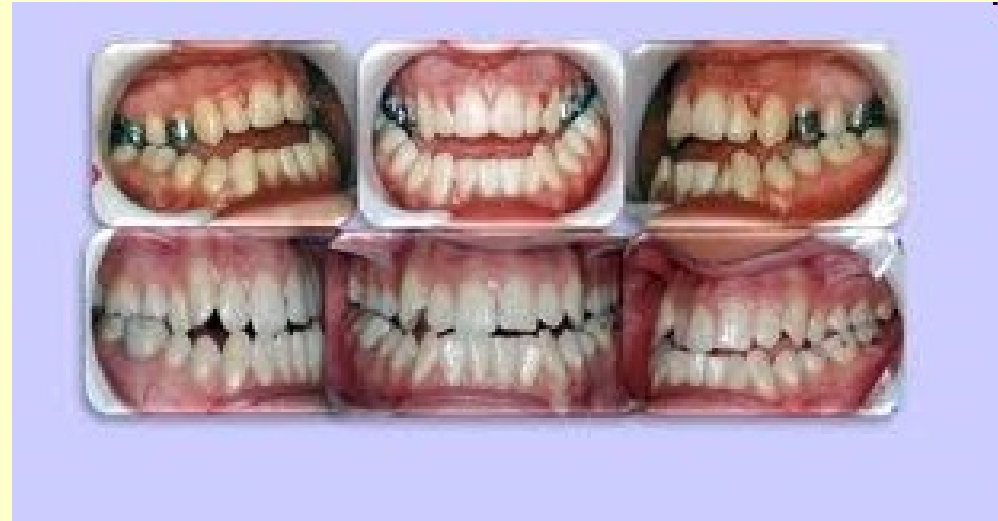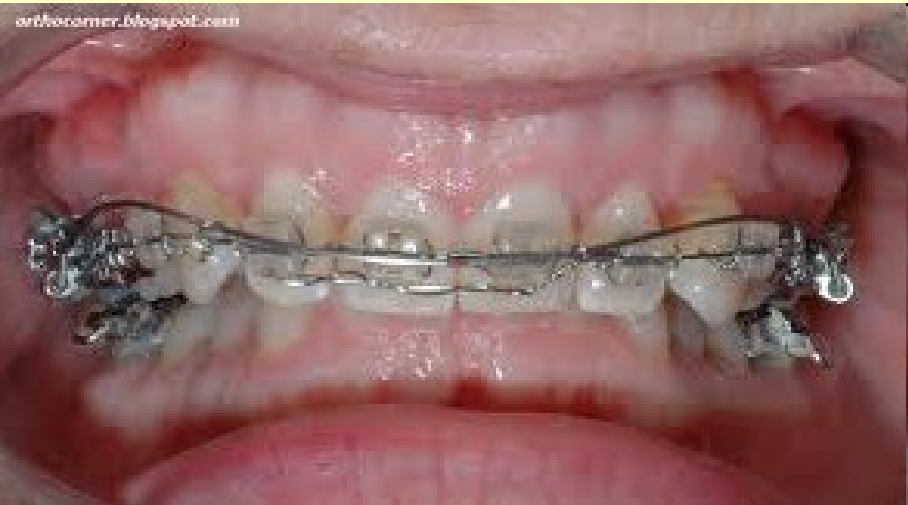- The relationship of the first molars
- Crossbite
- Concave profile)
- With vertical anomalies (deepbite or open bite)

Crossbite

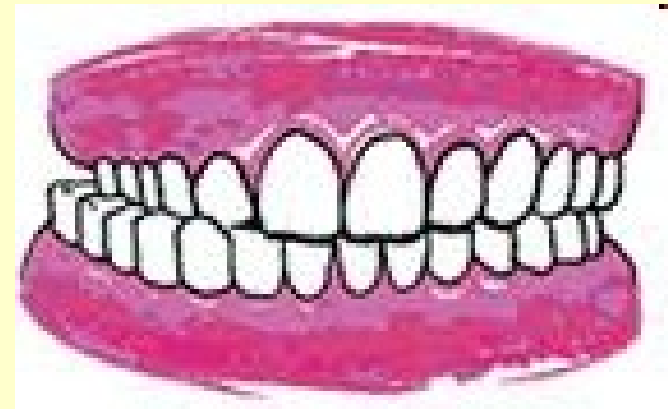
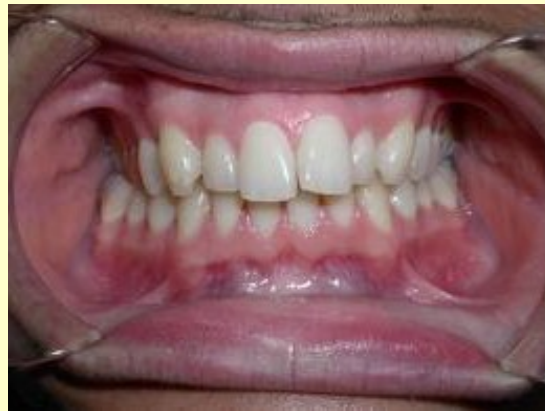

Transversal and vertical anomalies – they can be skeletal or dentoalveolar

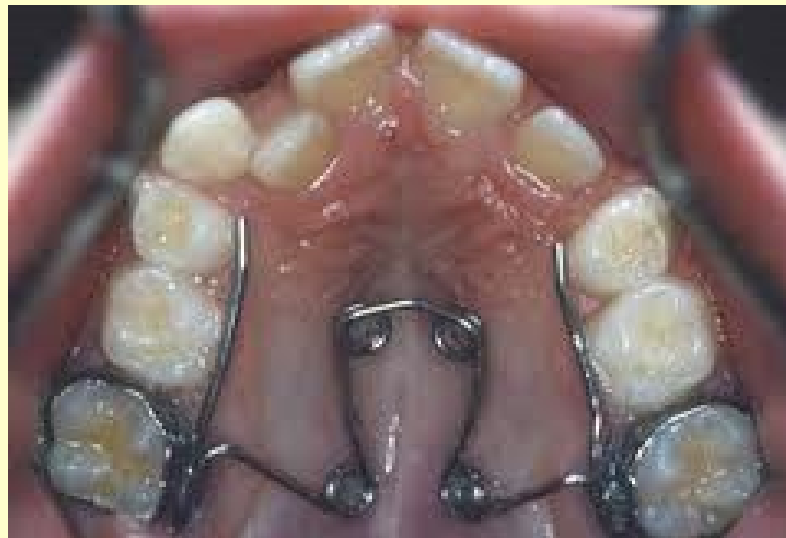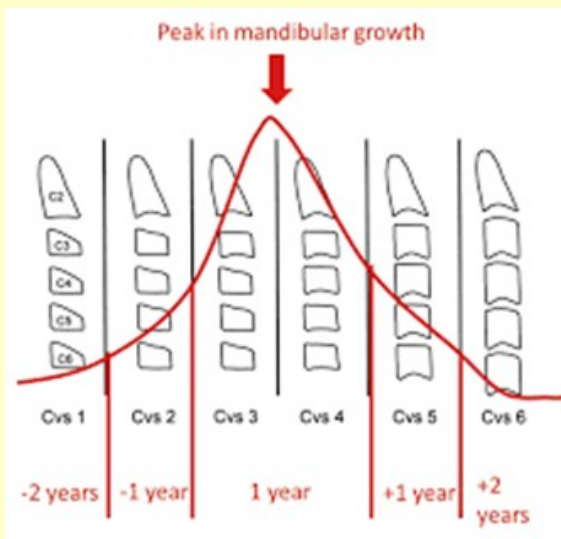
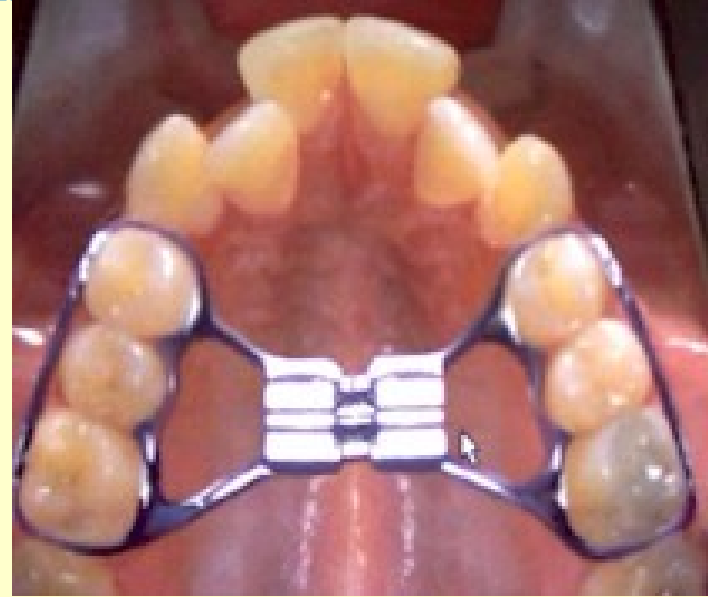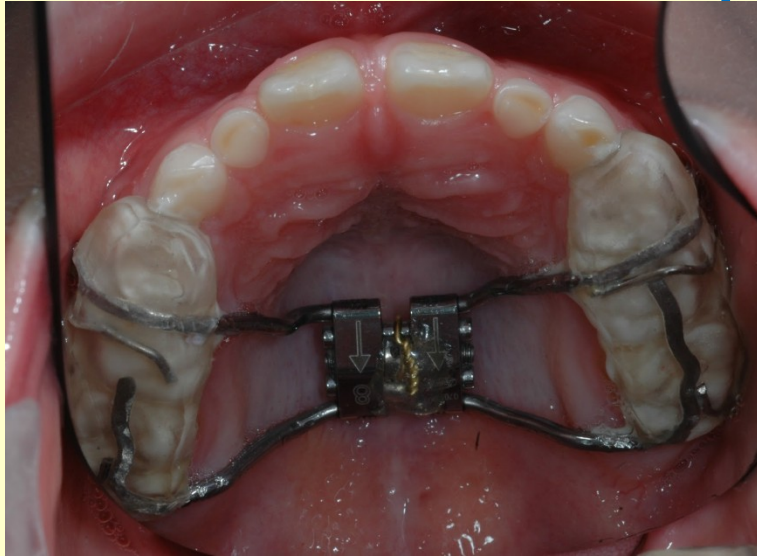
Vertical problems



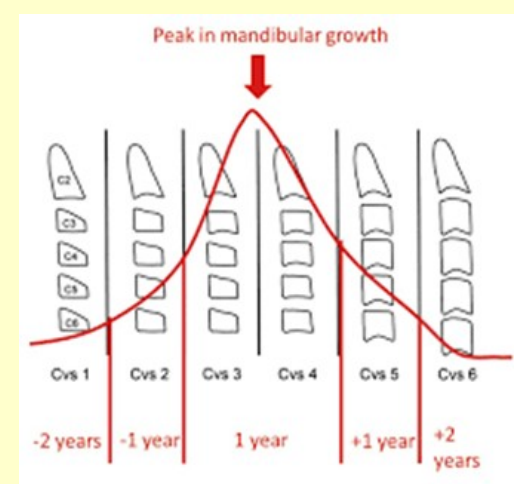
Transversal problems



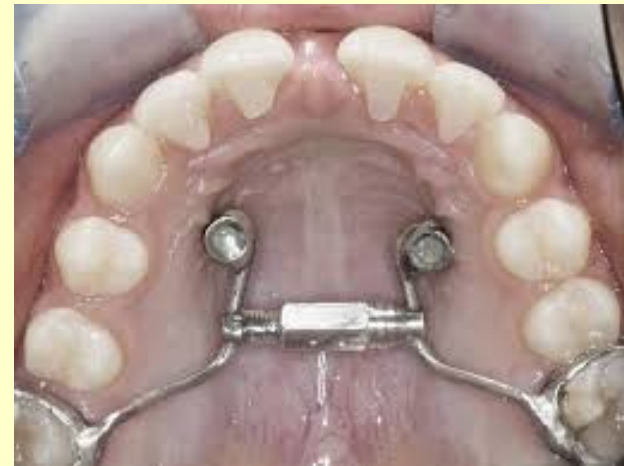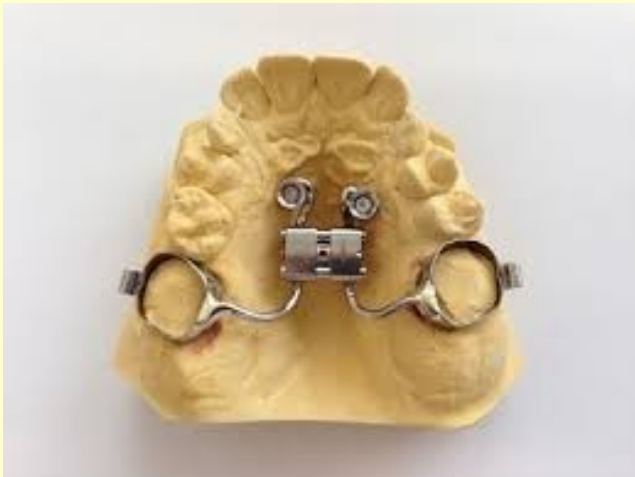Hyrax !! (ripping of the midpalatal suture), quad-helix



Hibrid hyrax



CVMS 4-5 is it possible to expand the maxilla ?

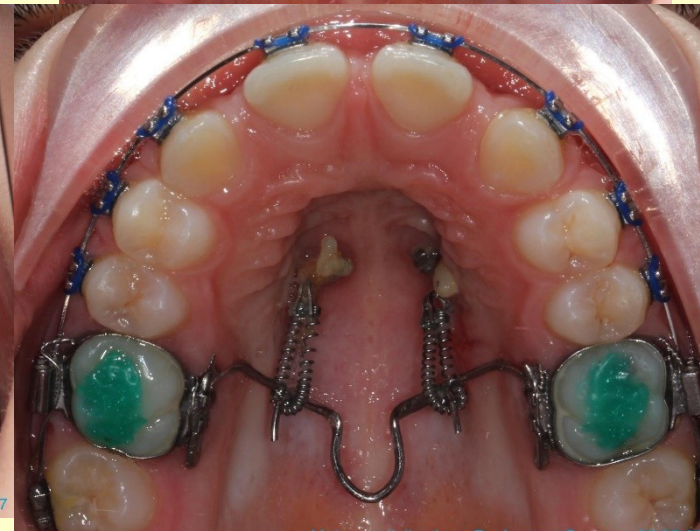
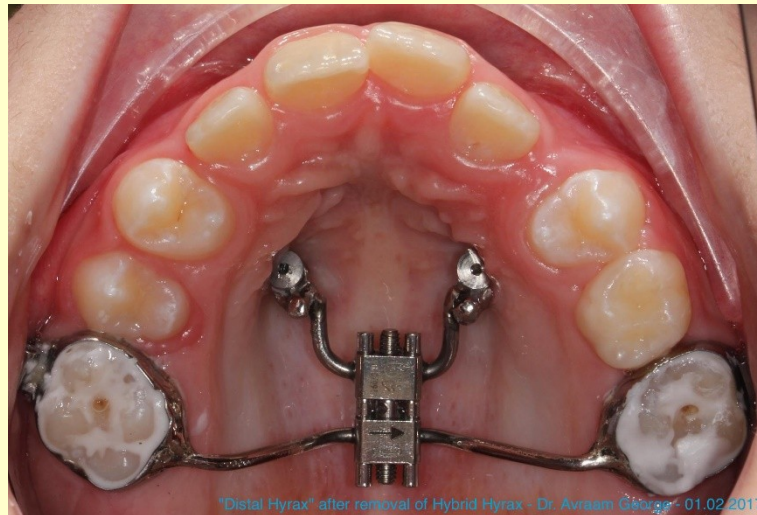
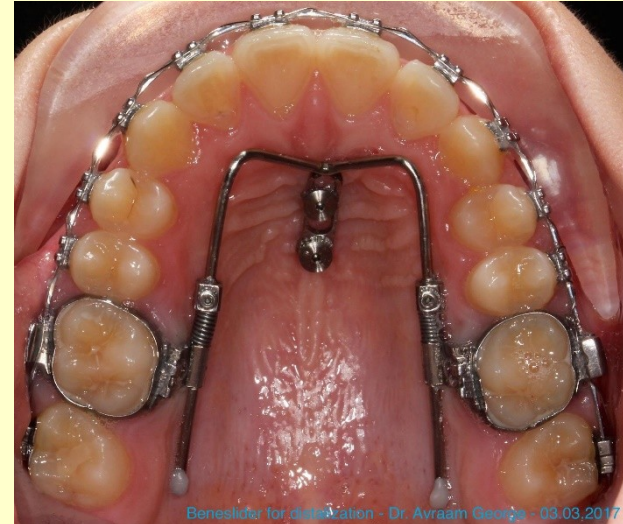
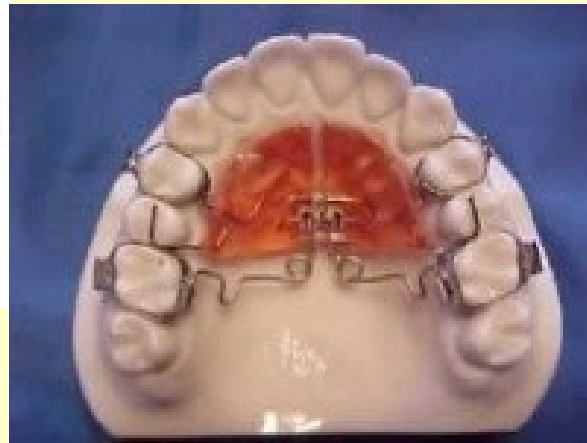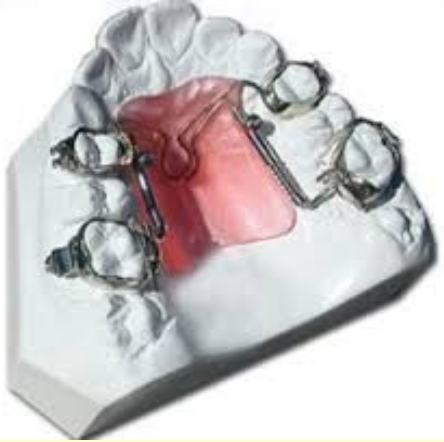Dr Juhász Fanni és Dr. Szegedi Levente vizsgálata

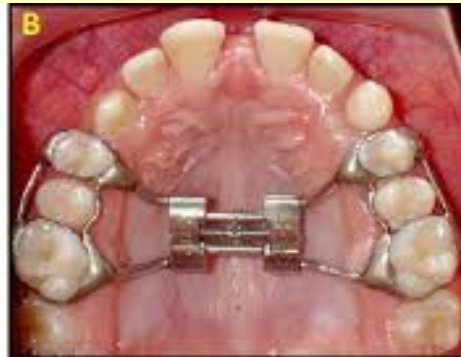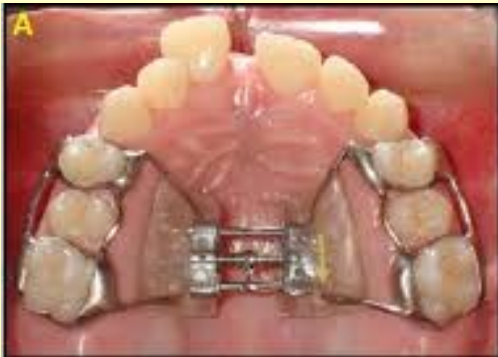24.10.09.

12

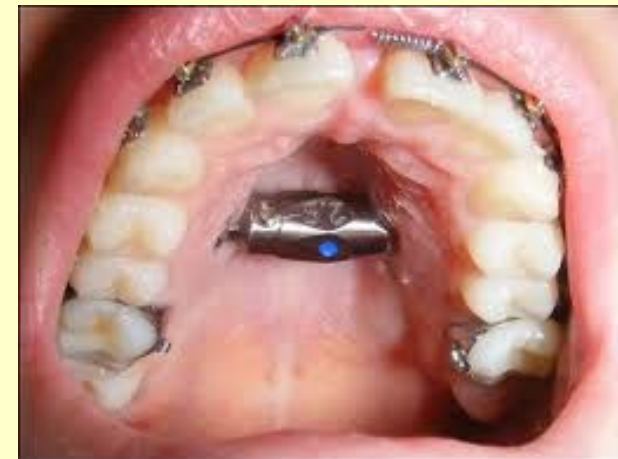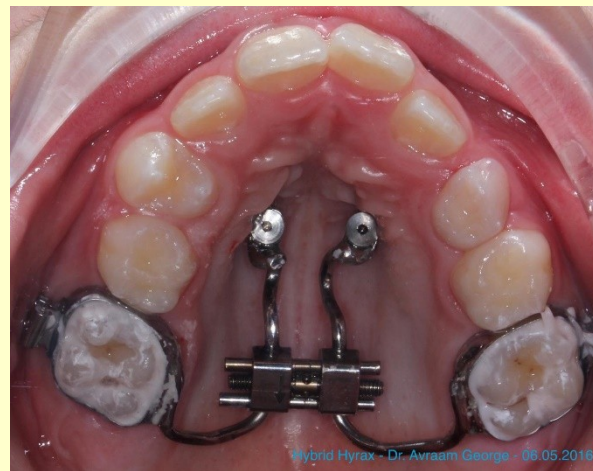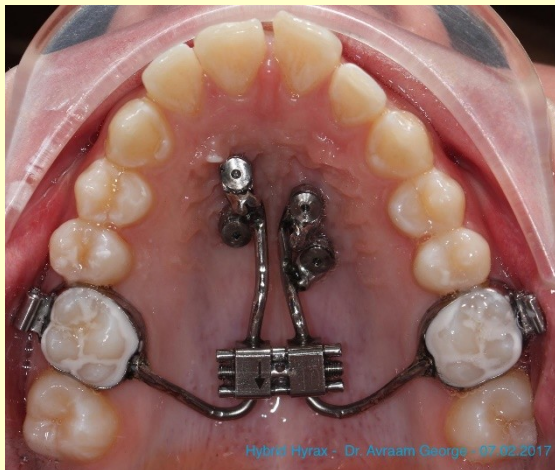Fixed appliances for the distalisation of the upper molars



Fixed expanders

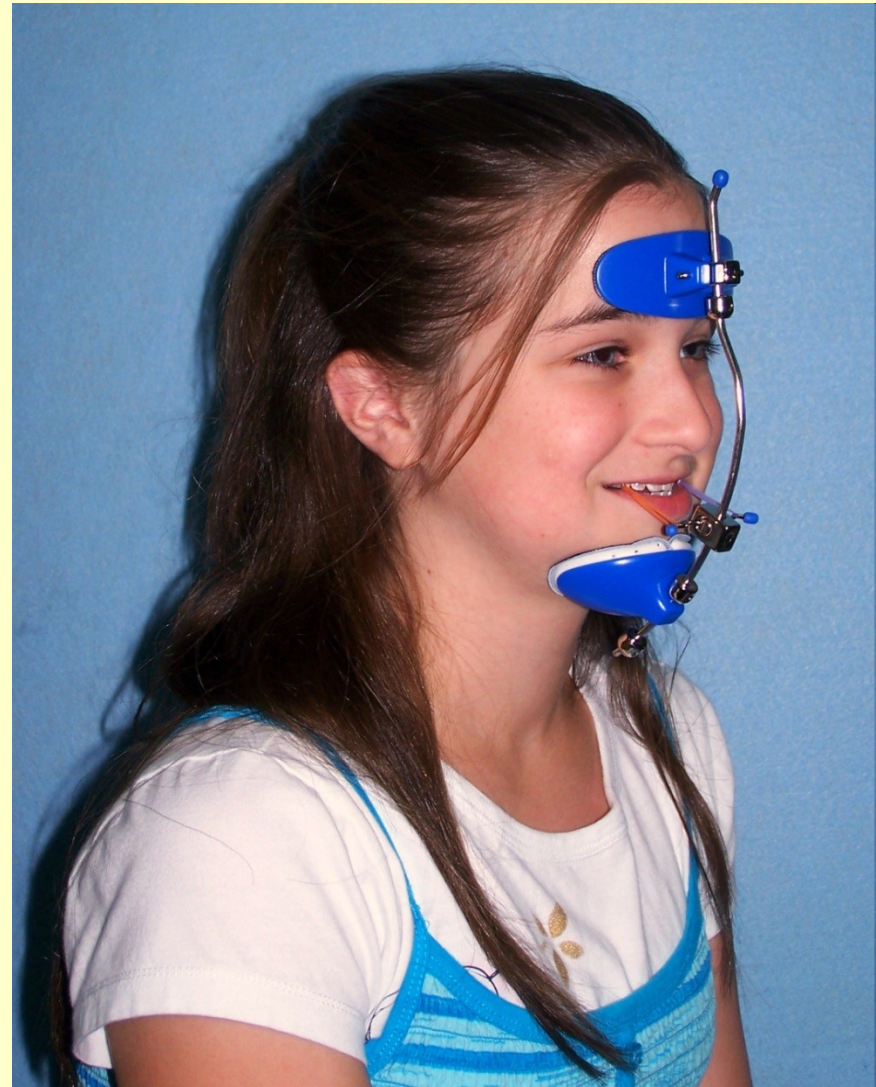
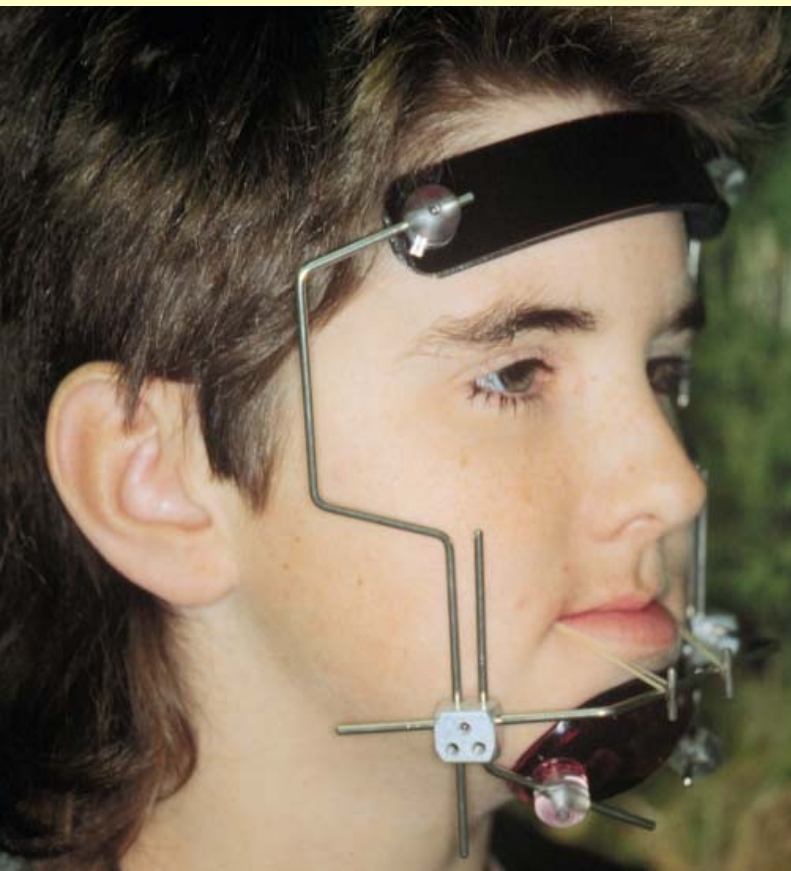
Hyrax →
skeletal expansion!!
hibrid-hyrax
dystractors

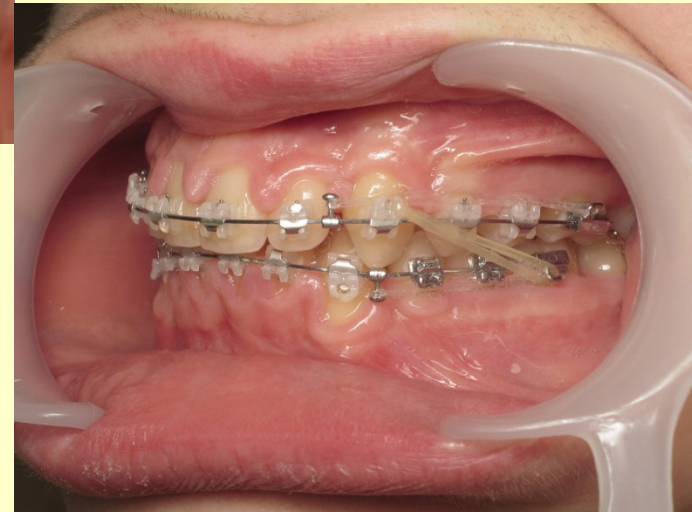
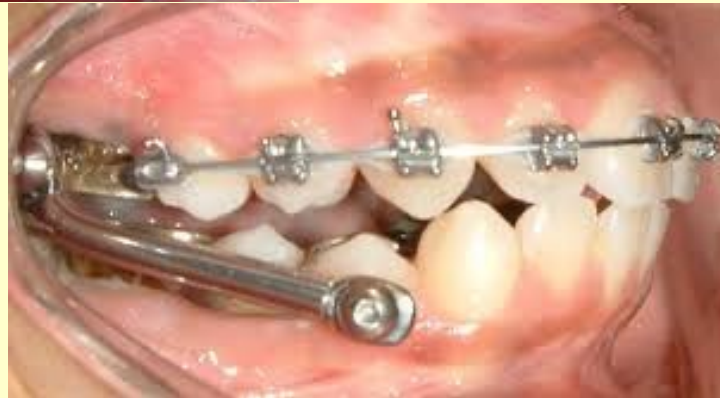
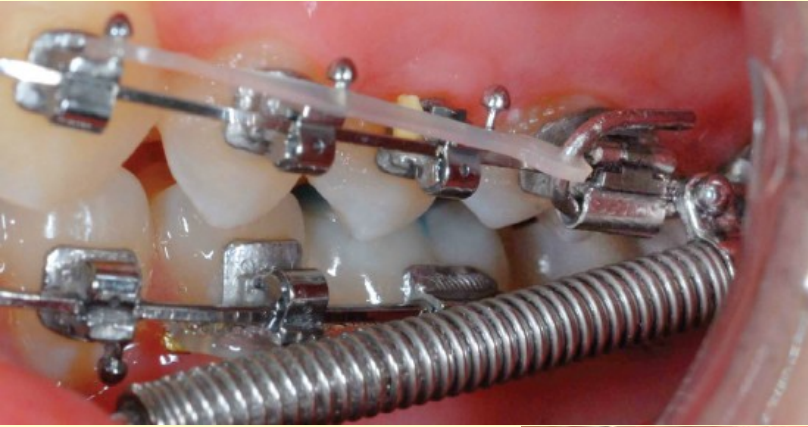Intra-, extraoral appliance: Reverse Headgear Facemask

sagittális expansion of the maxilla



Fixed appliances for the correction of the sagittal (antero-posterior) anomalies



Phases of orthodontic treatments

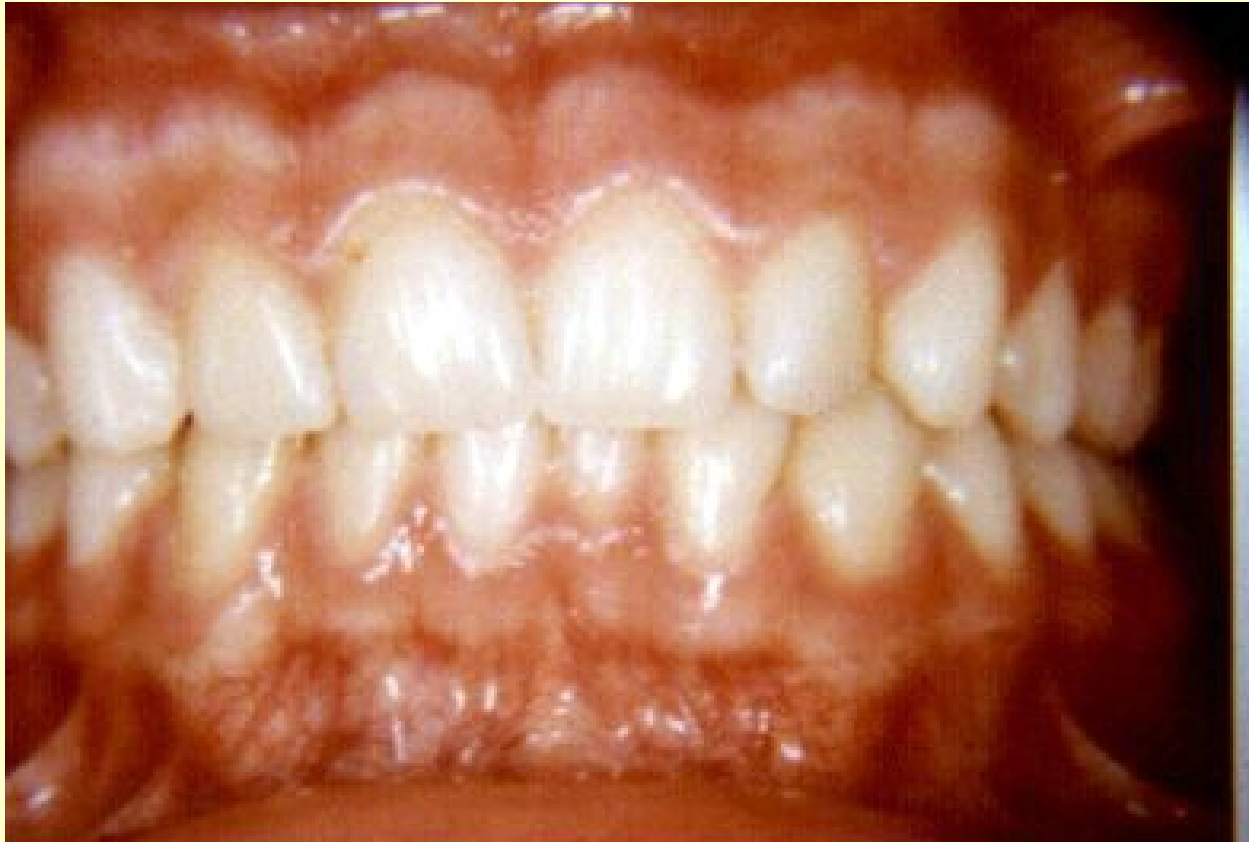Early (preventive and interceptive) orthodontics

- Preventive and **interceptive (early) orthodontics** simply means diagnosing and treating malocclusions as soon as they are detected. Mainly the skeletal anomalies have to be treated in early ages (mixed dentition). It is phase 1.
- In early ages it is easier to influence the growth and the development.
- Phase 2 will begin when all the permanent teeth are in place. (with multiband-multibond appliances). Alignment of the denture and improvement of the occlusion.
- Going through phases allows for the second phase to be shorter in duration, since the major (skeletal) corrections happened in the interceptive orthodontics phase (in mixed dentition).

Goal of the treatment:

functionally normal dentition

aesthetically ideal dentition



Treatment methods:

appliances

surgical interventions and appliances

myotherapy

prevention

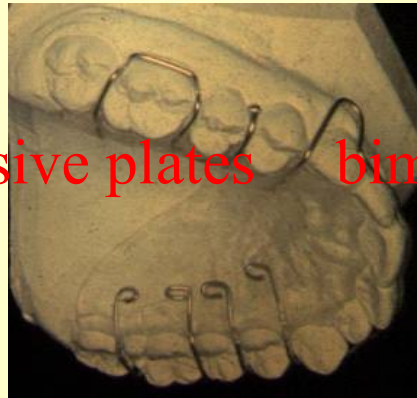


A fogszabályozó készülékek csoportosítása

Removable appliances



Active plates

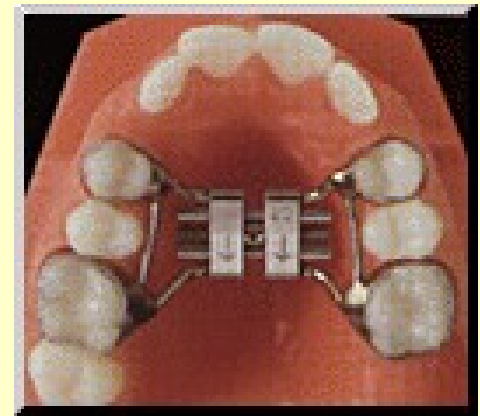
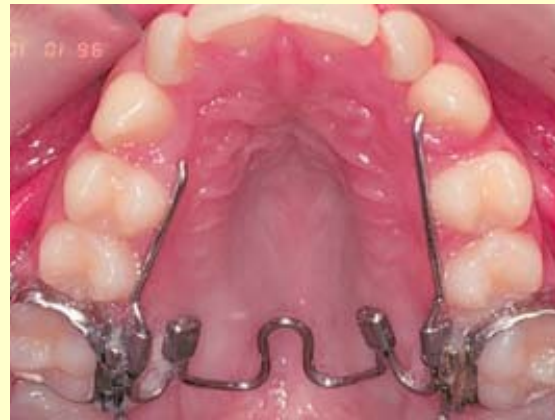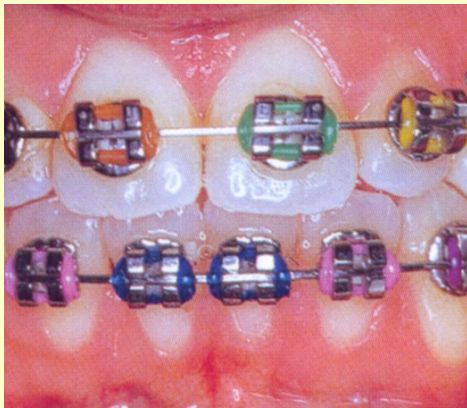


Passive plates

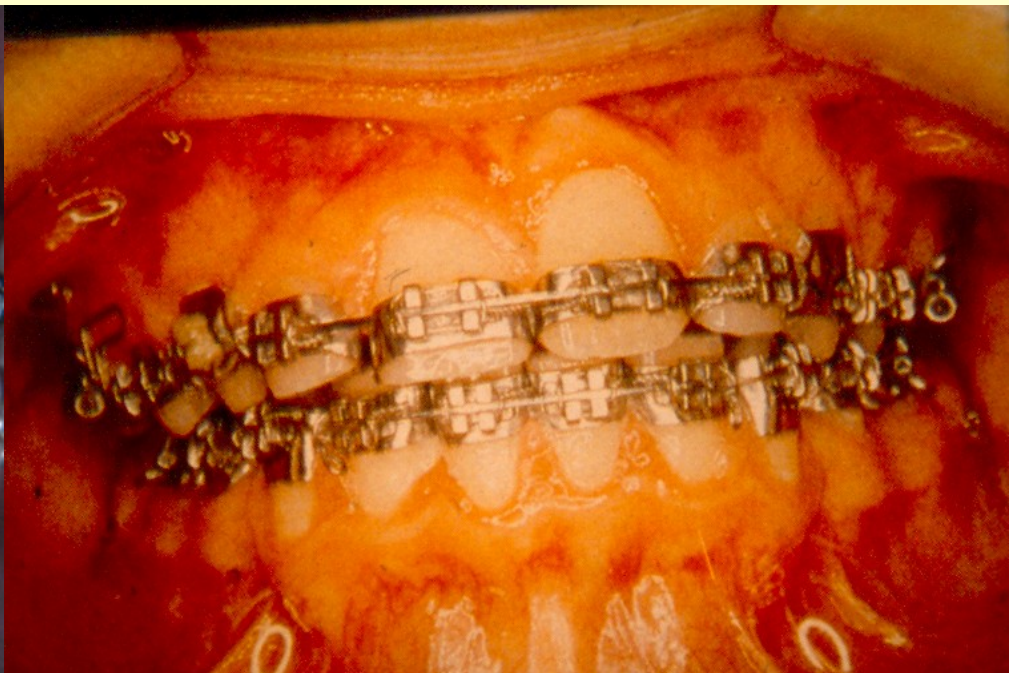
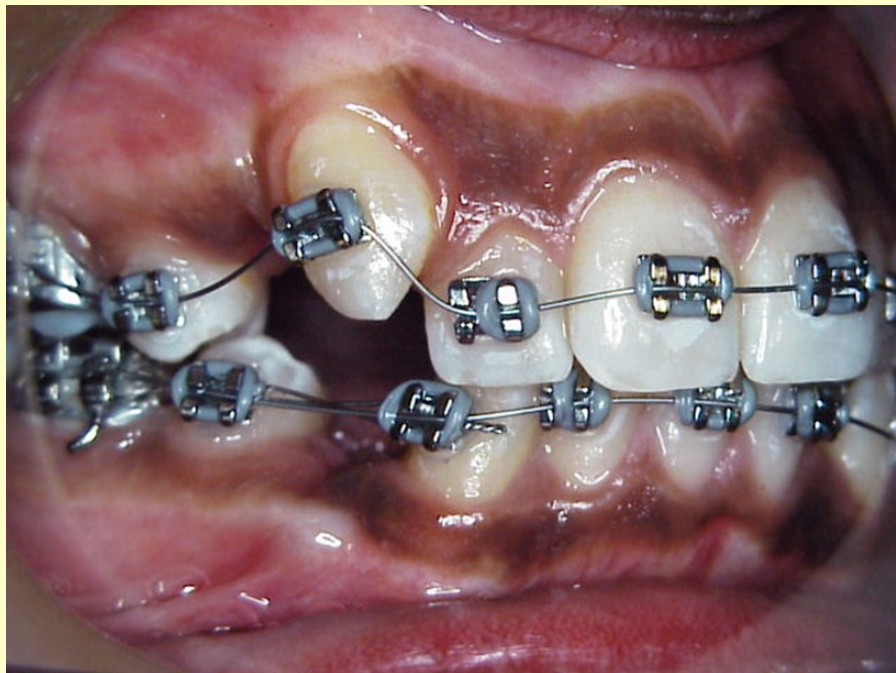

bimaxillary functional appliances

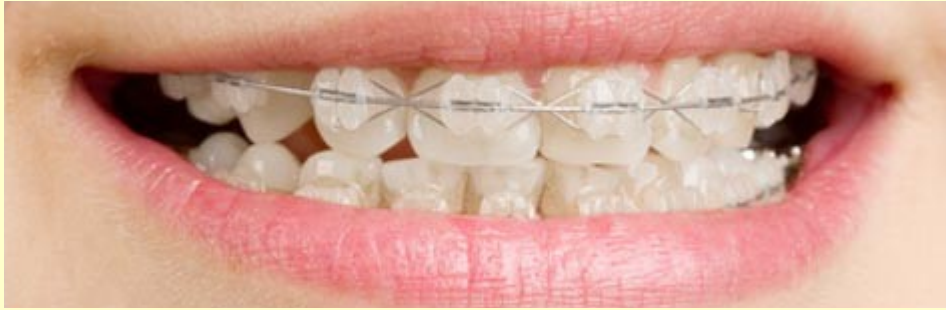Fixed appliances



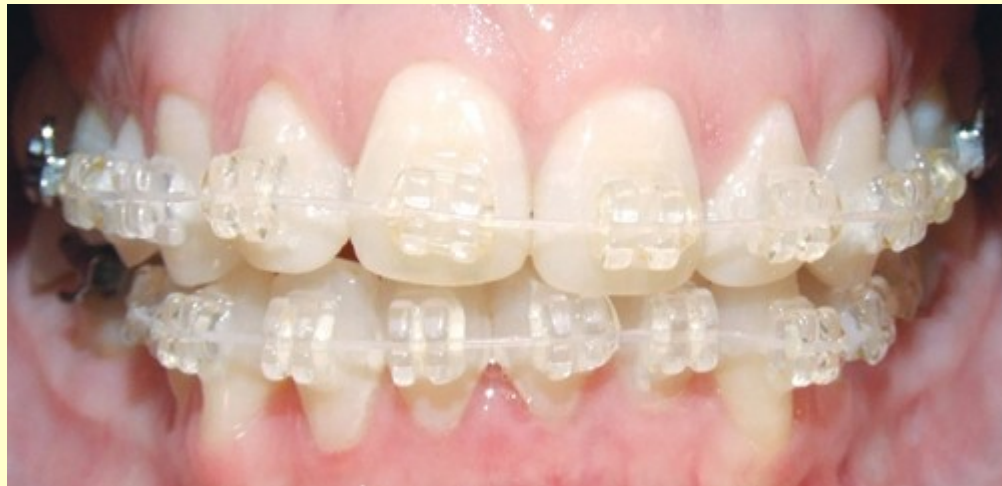Multiband-multibond appliances



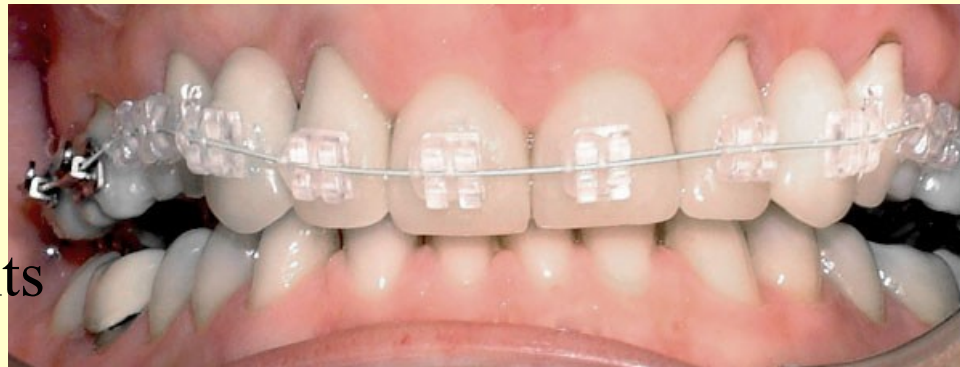Esthetic brackets, white archwires



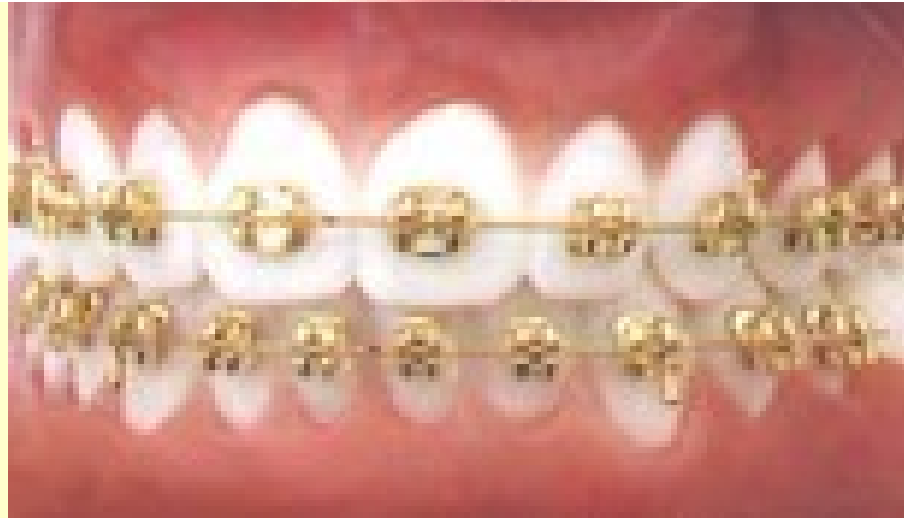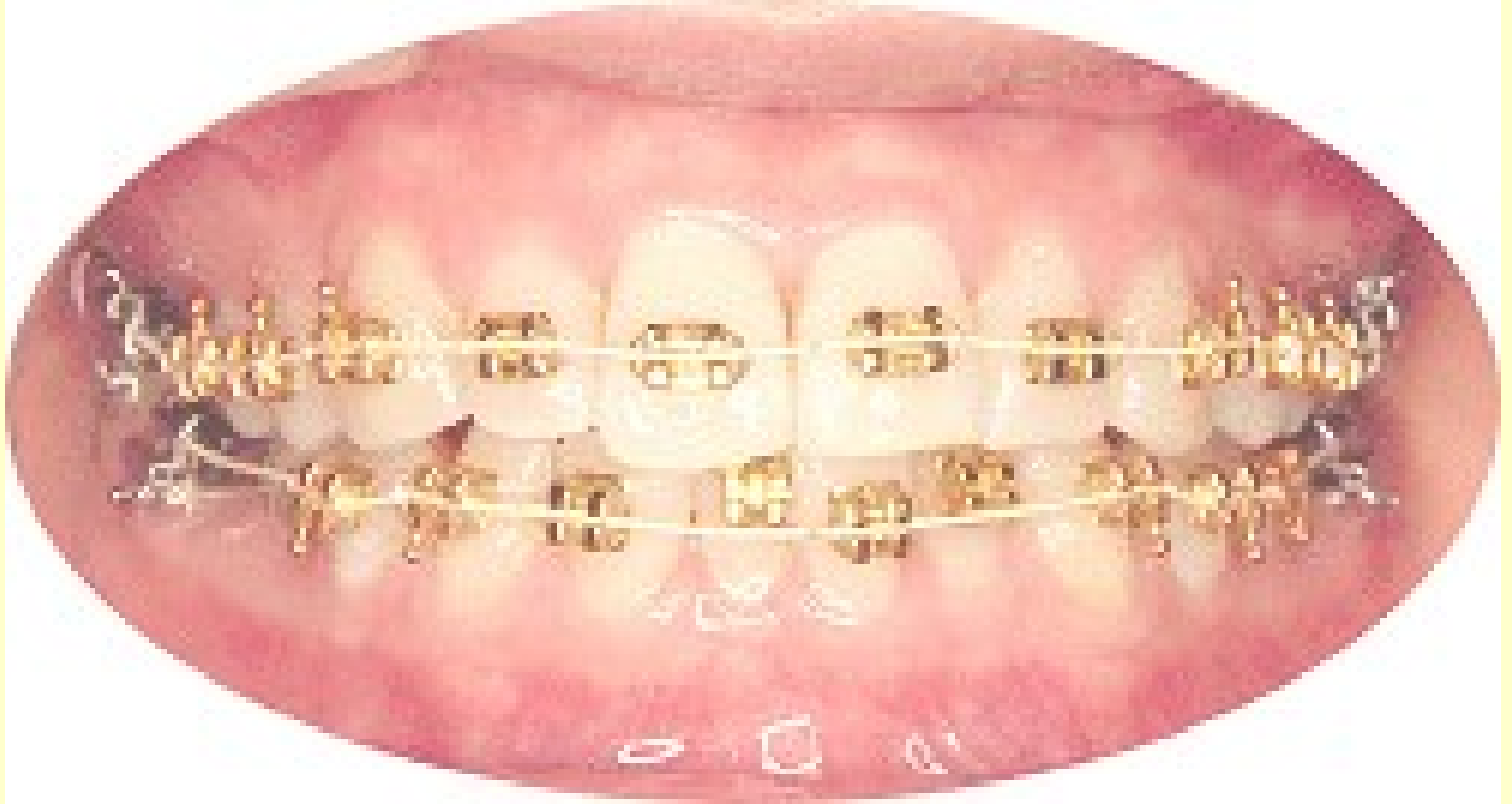Ceramic and plastic brackets



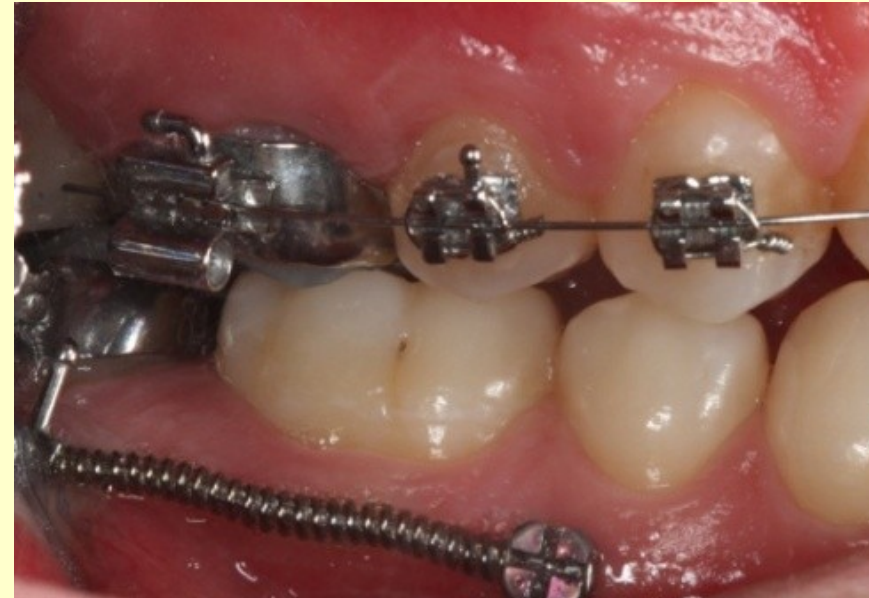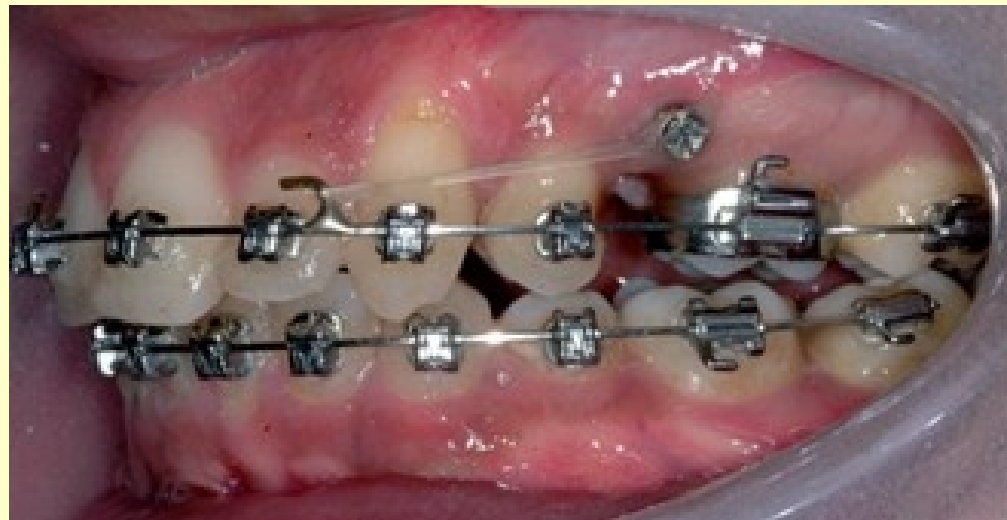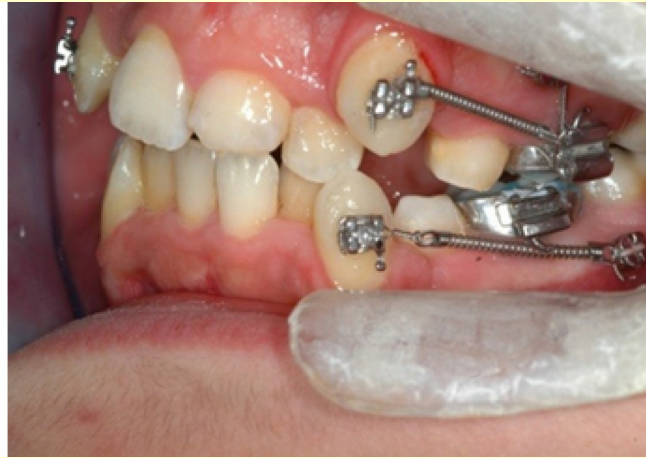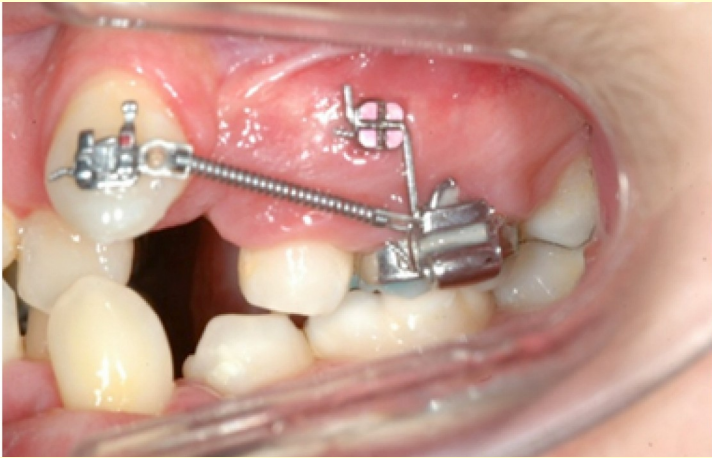Metal wires covered with plastic
(teflon)



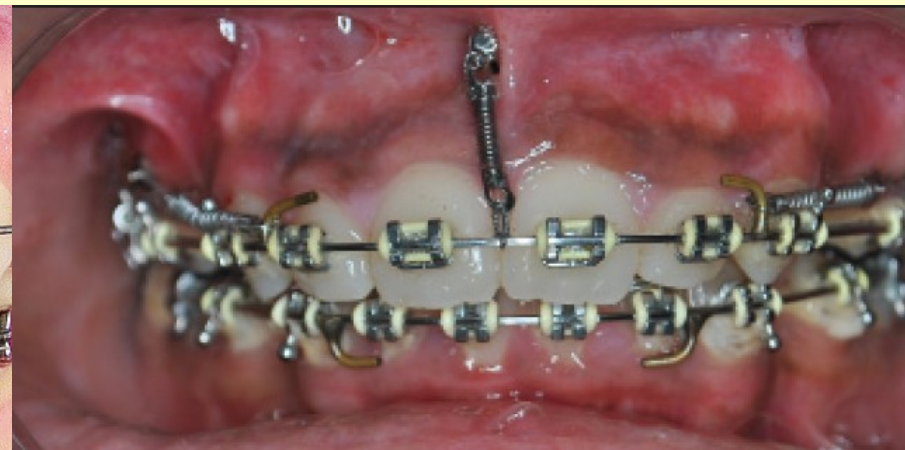
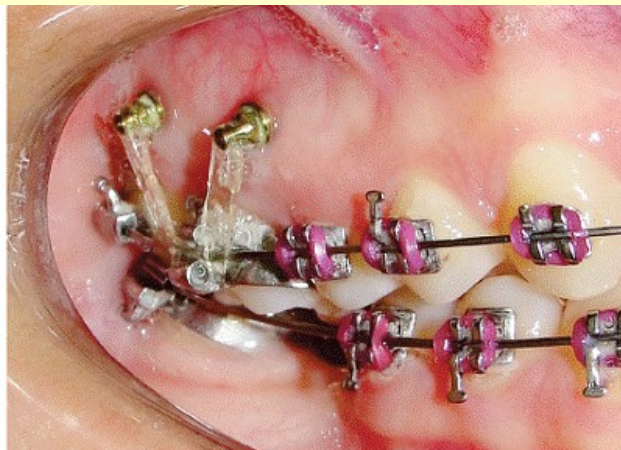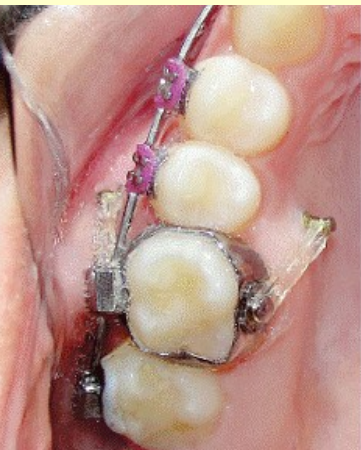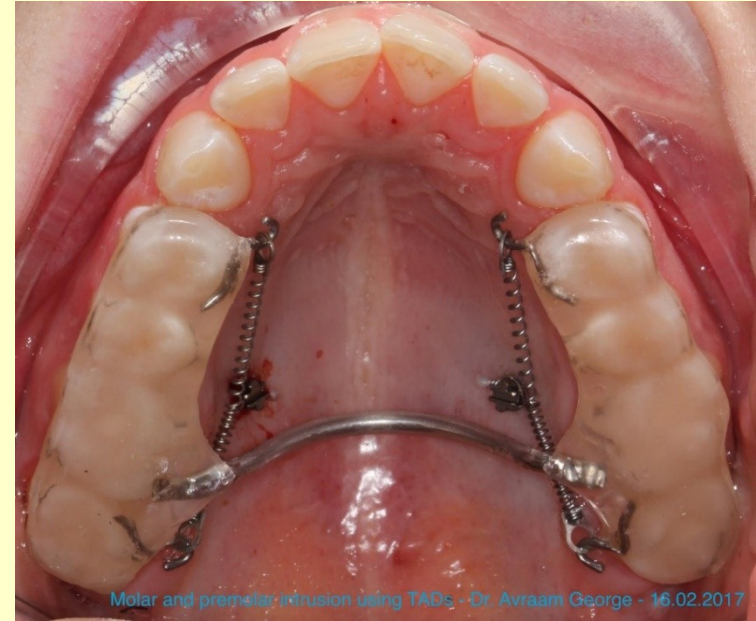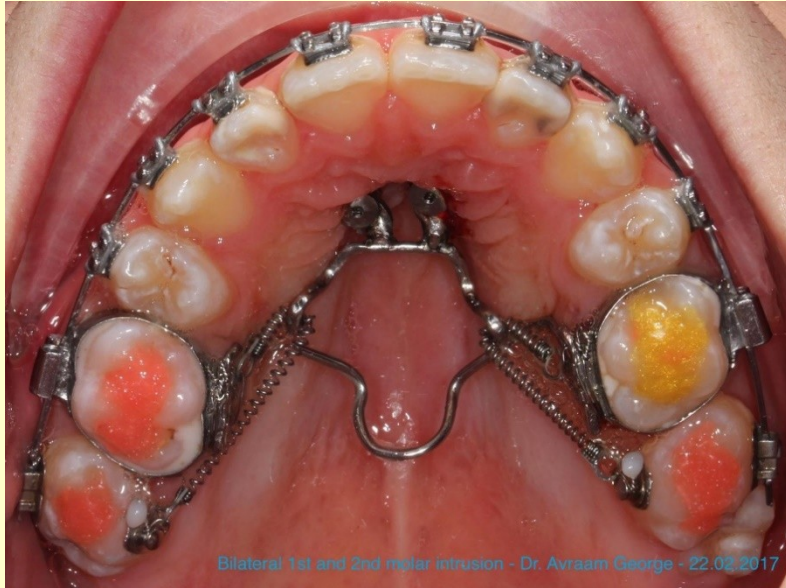according to the wishes of the patients



Orthodontic mini-implants used as anchorage



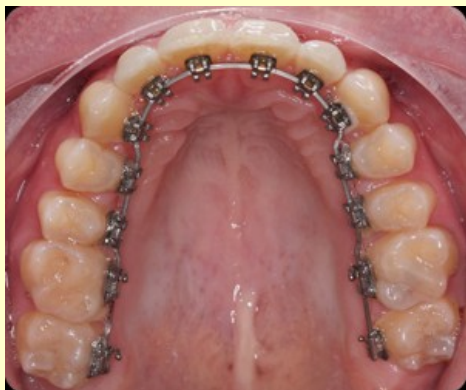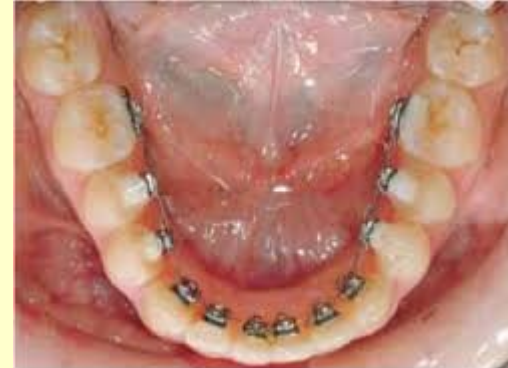Rögzített készülékek vertikális problémák kezelésére





damon.jpg

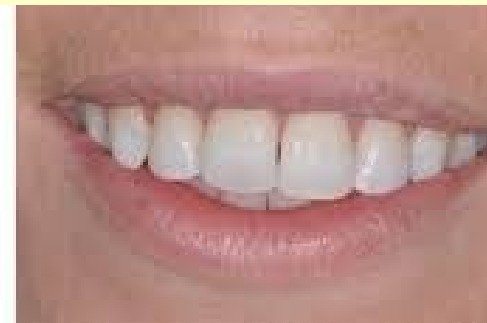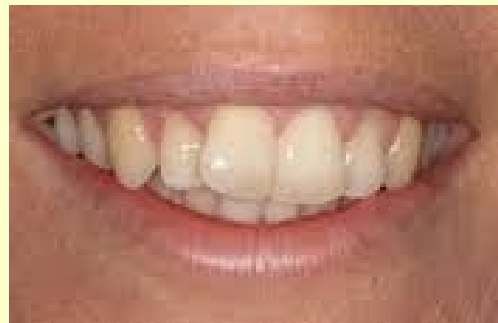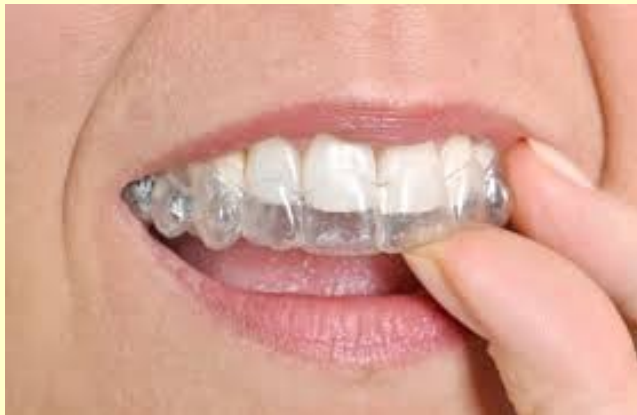Lingual technic (is not visible)



- It appeared in 1976
- Occlusal problems
- Speech problems
- These appliances disturb the movement of the tongue → the form of the brackets was changed
- All the elements of the appliance is made individually
- It's more difficult to work with lingual brackets

Invisalign and other aligners

- It is the future
- Expensive
- These appliances are not suitable for all kind of anomalies
- They change the denture step by step




Treatment methods:

appliances

surgical interventions and appliances

myotherapy

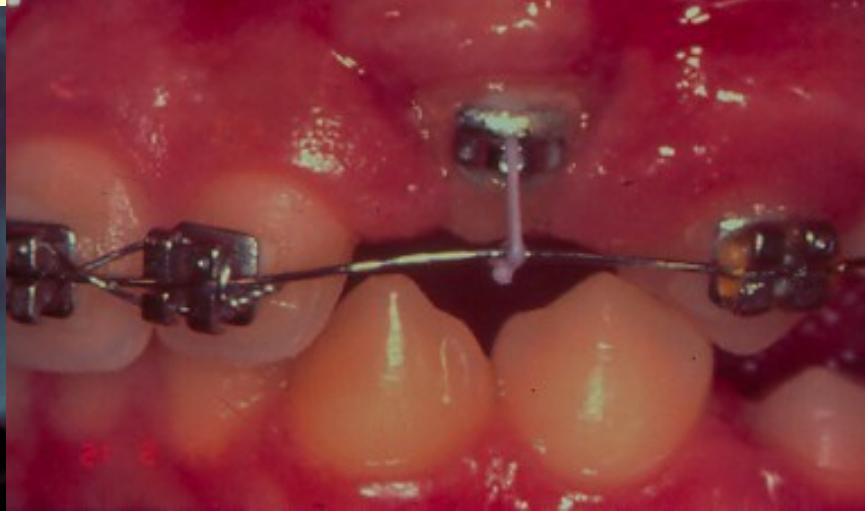
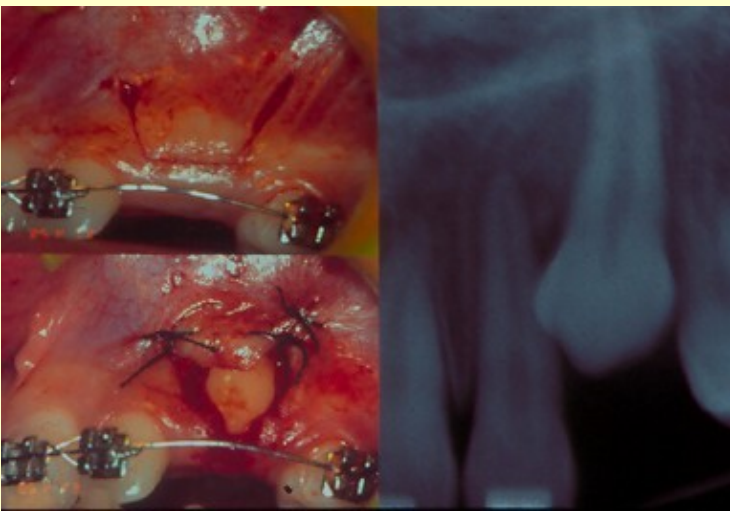
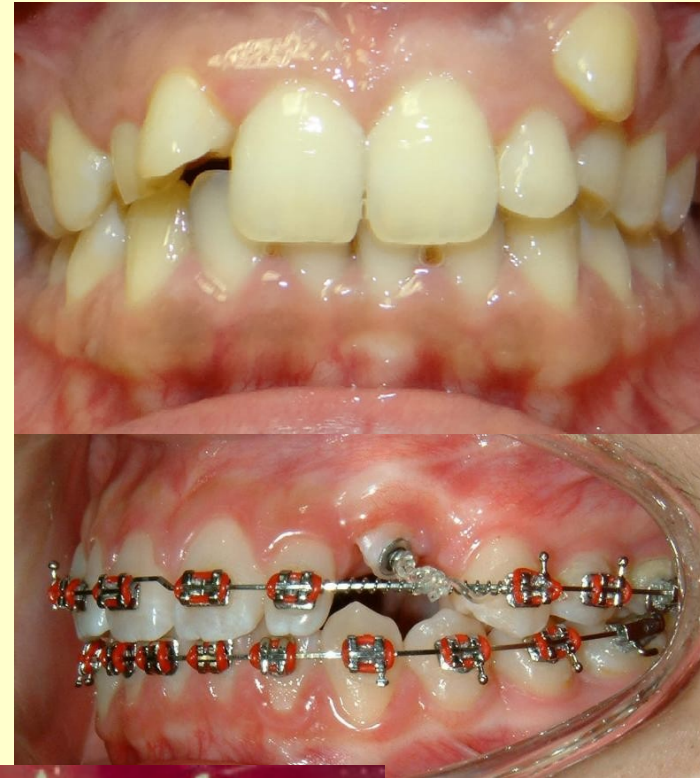prevention



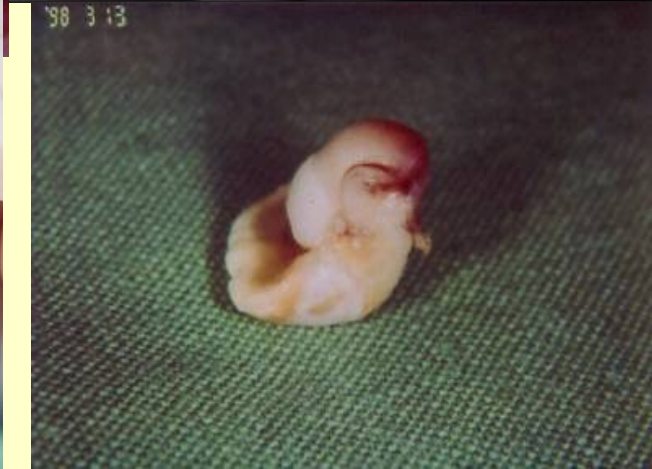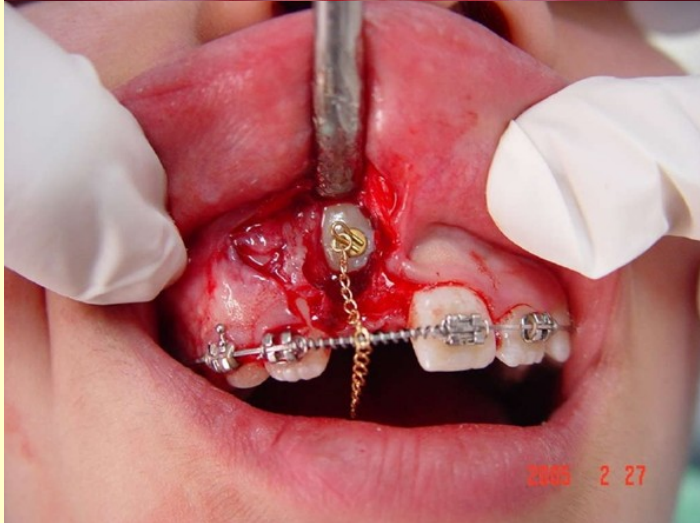
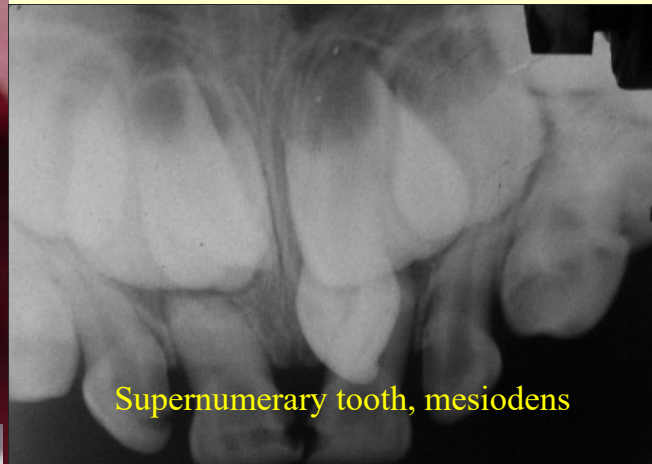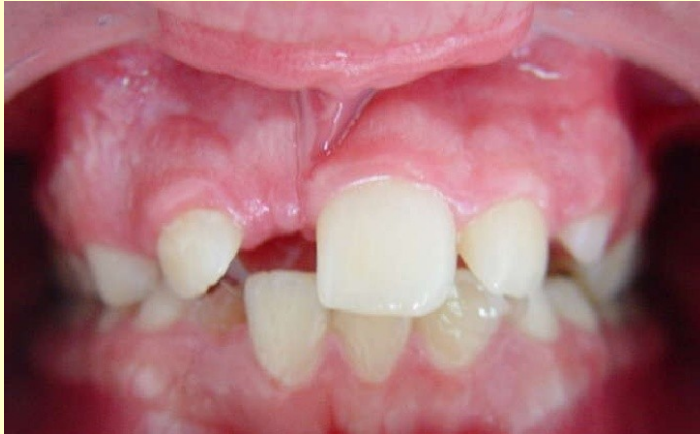Impaction, retention

Retention: teeth in the bone without the eruption tendency

Impaction: the eruption of the tooth is prohibited (f.e: there's no enough place)

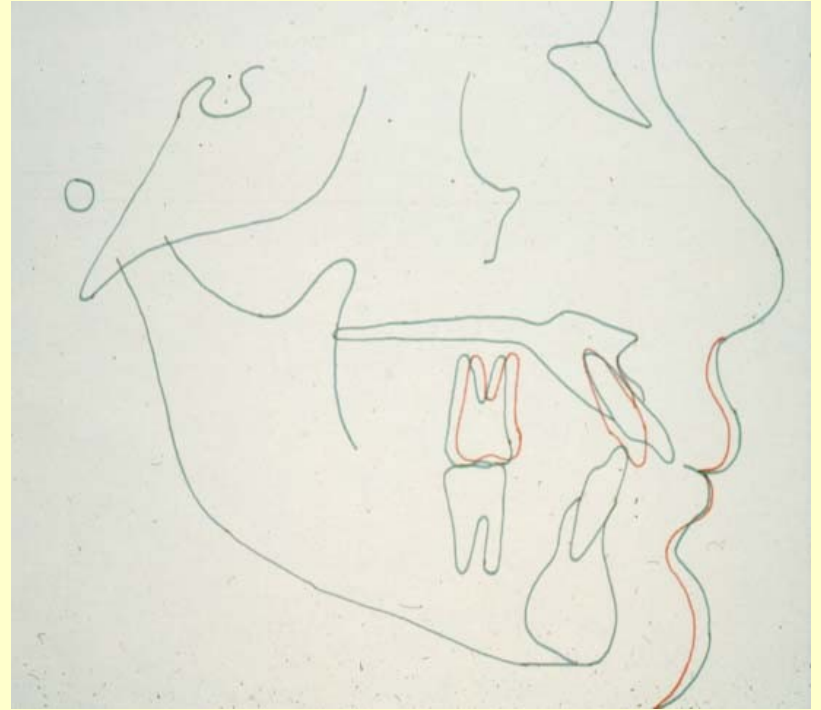
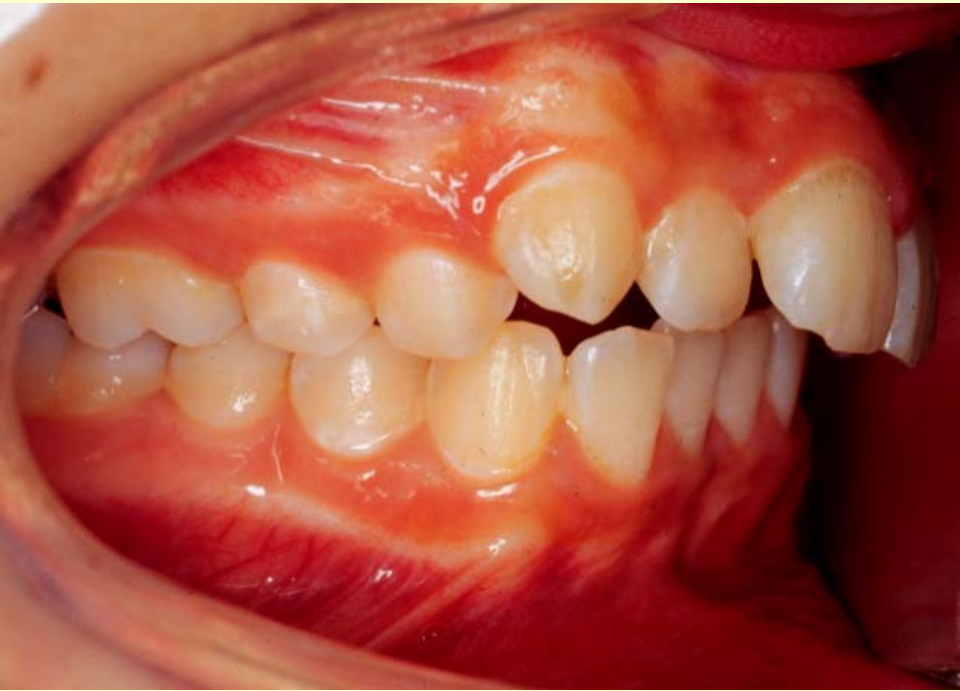

IMPACTION OF THE UPPER FIRST INCISOR




CLASS II

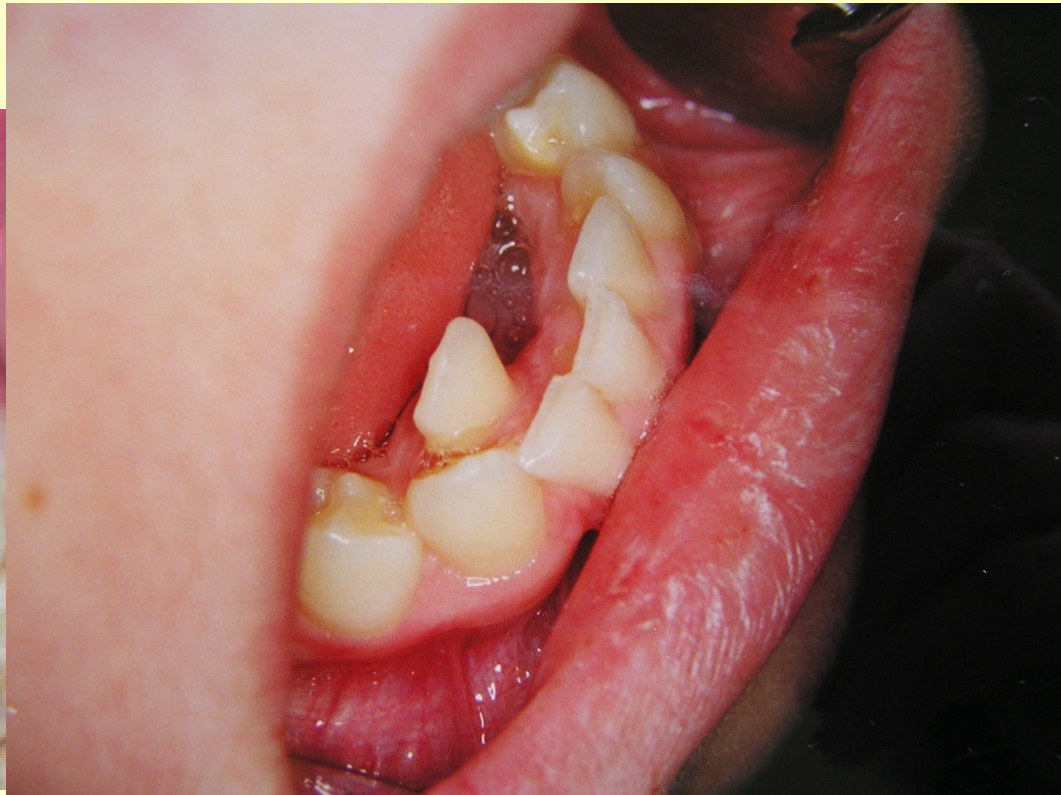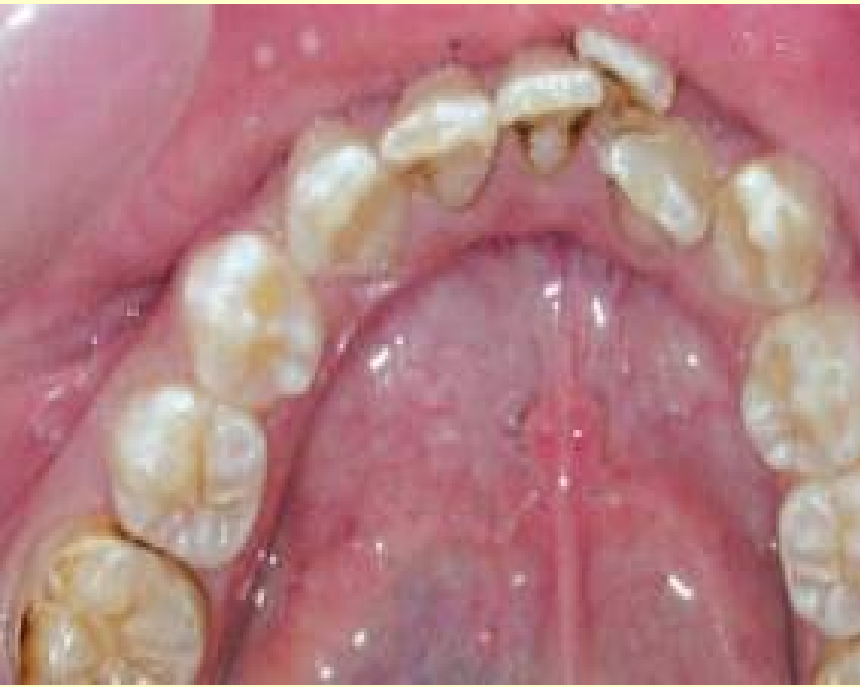Extraction of upper first premolars



ADULT (THE DEVELOPMENT HAS ALREADY FINISHED)
CLASS II DIVISION 1
OVERJET
PROGNATHISM
OPEN BITE

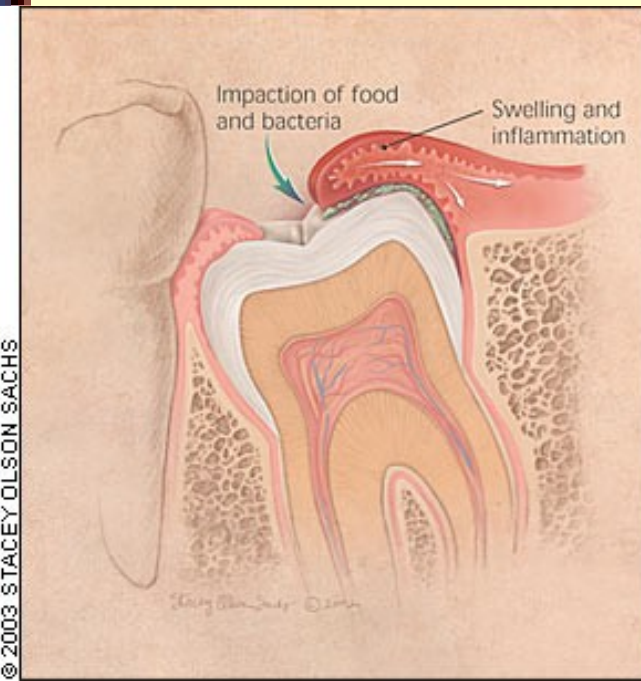
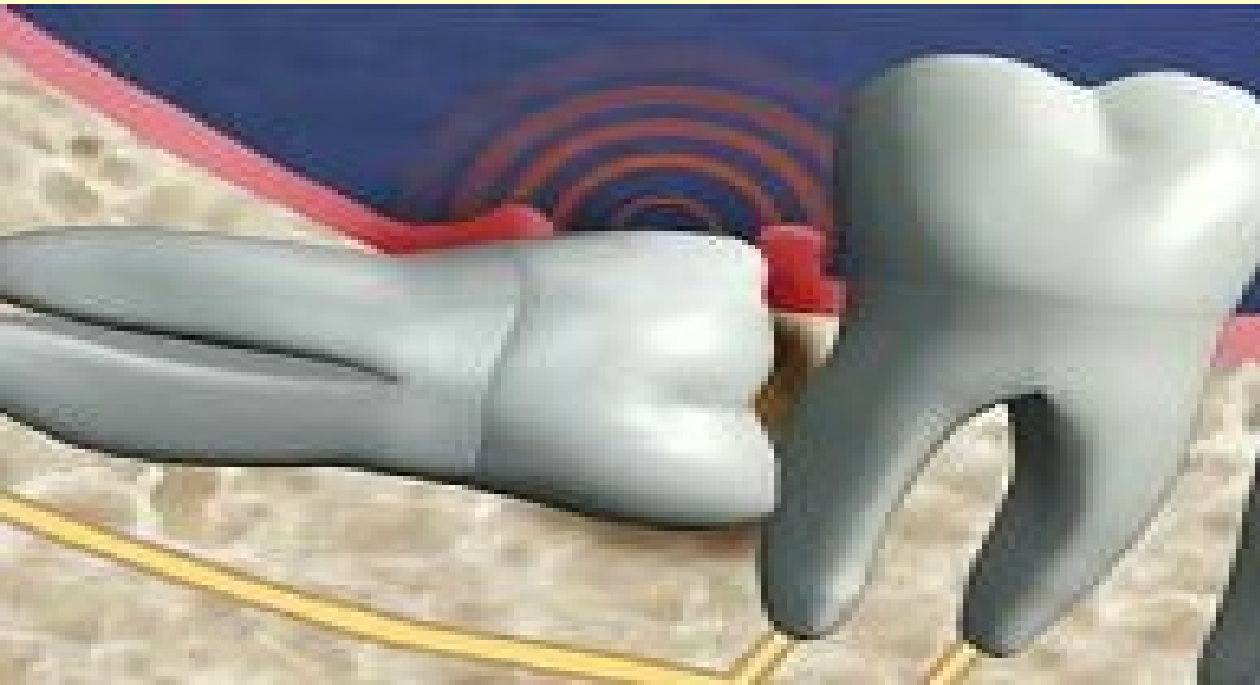

Extraction of the lower incisors



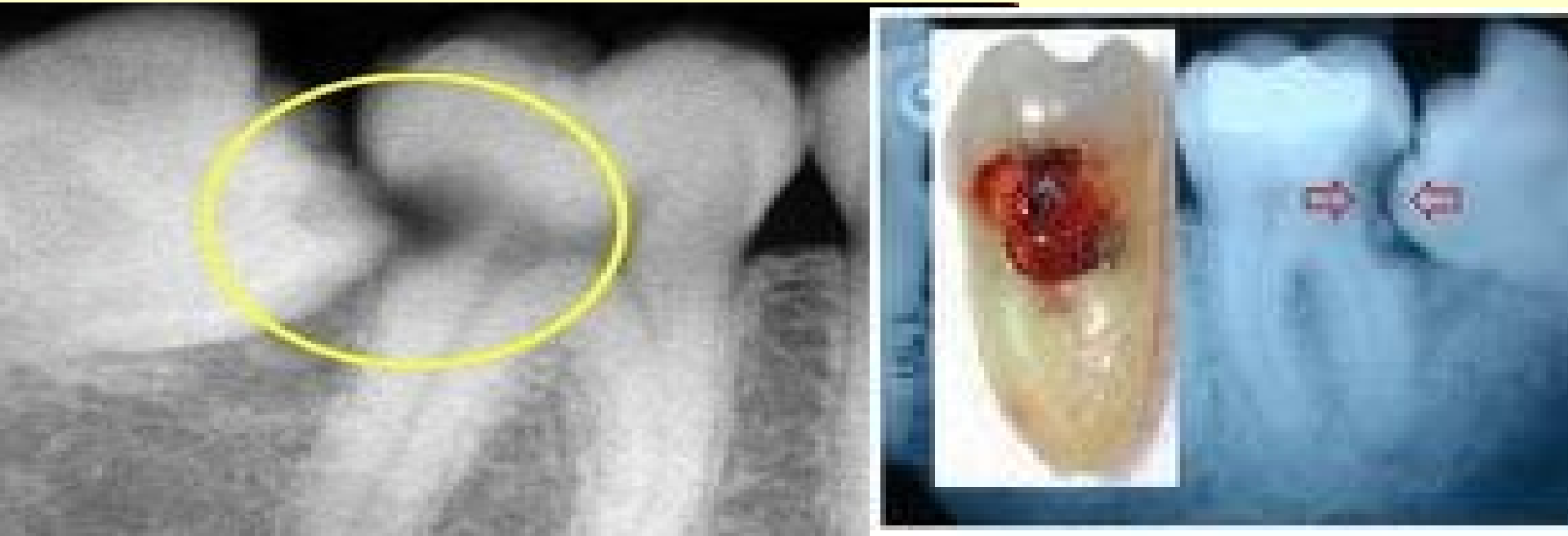
Removing of the wisdom tooth

Pericoronitis



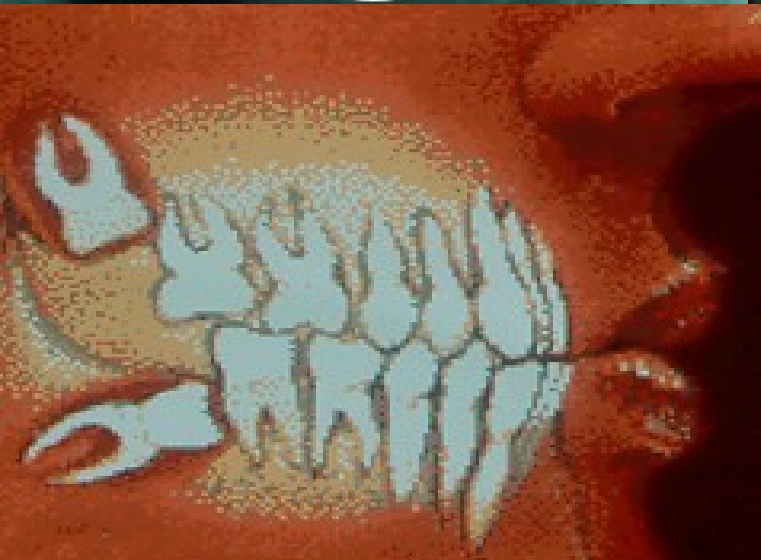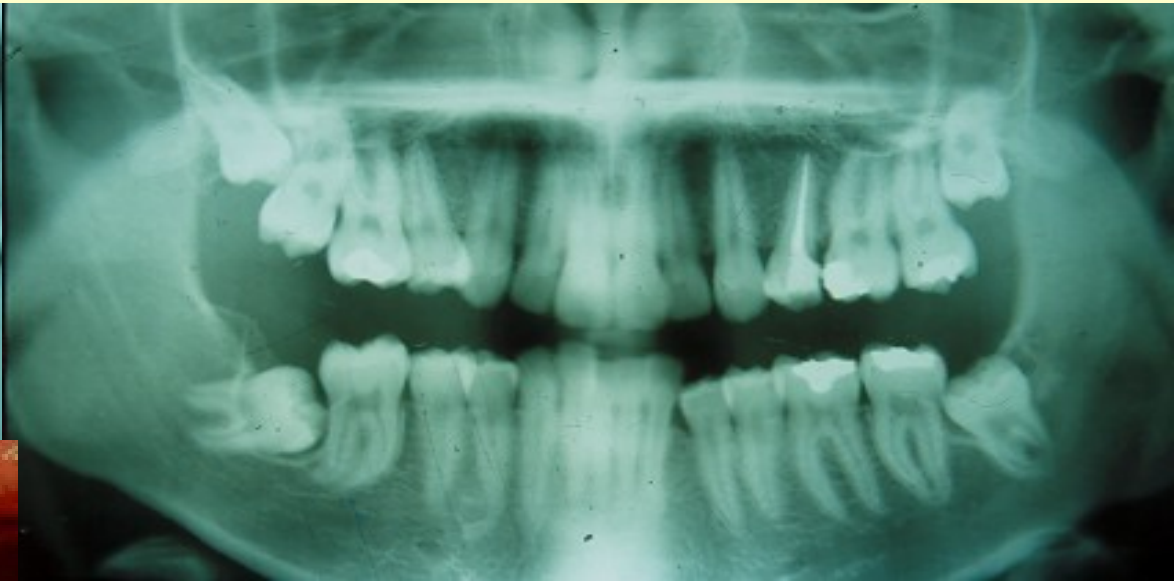
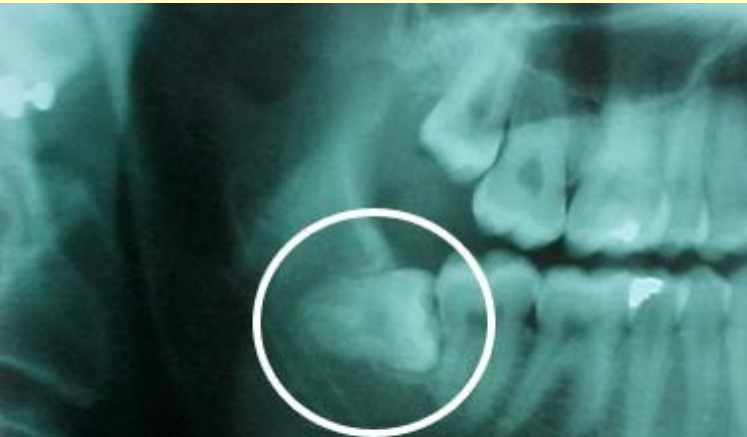Removing of the wisdom tooth

Caries of the 47 tooth
A második őrlő károsodása



Removing of the wisdom tooth

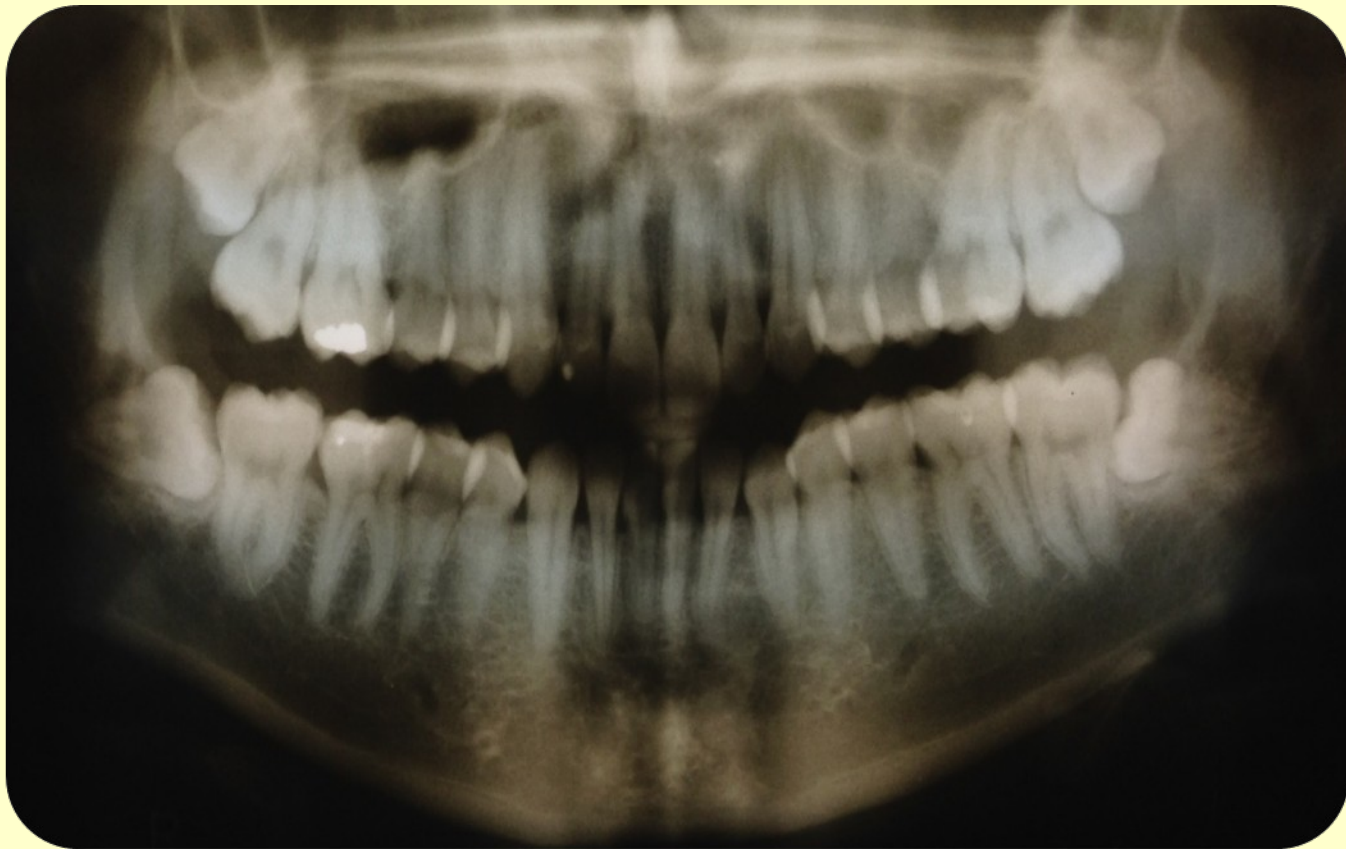
Orthodontiai indikáció

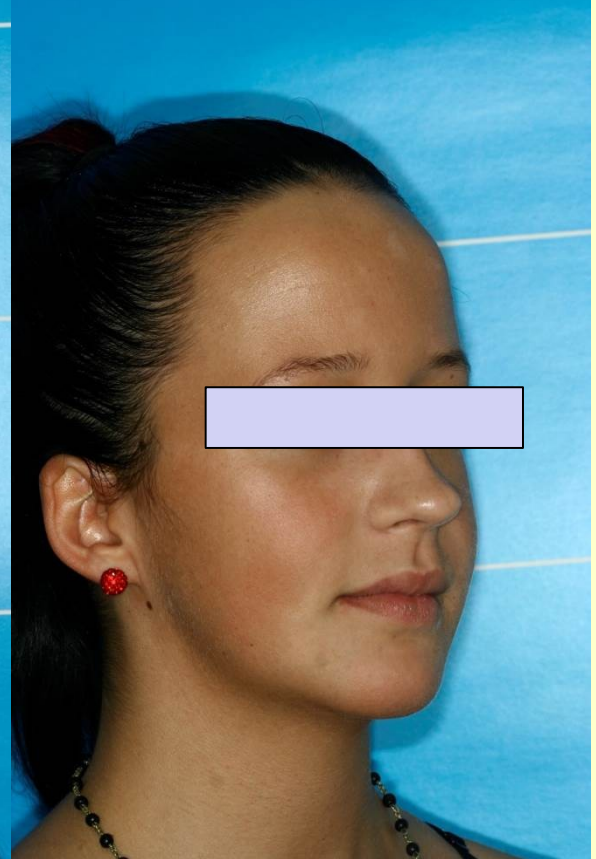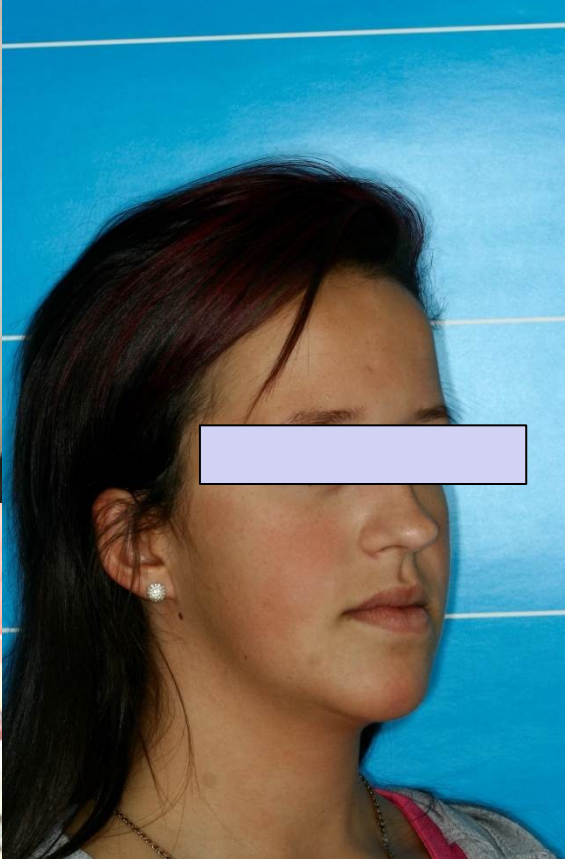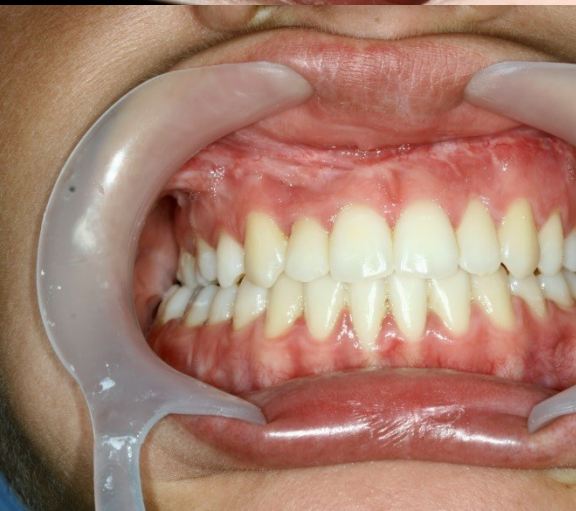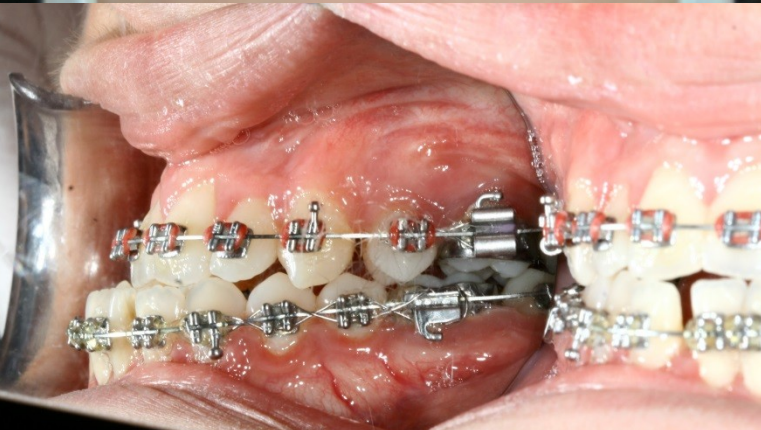


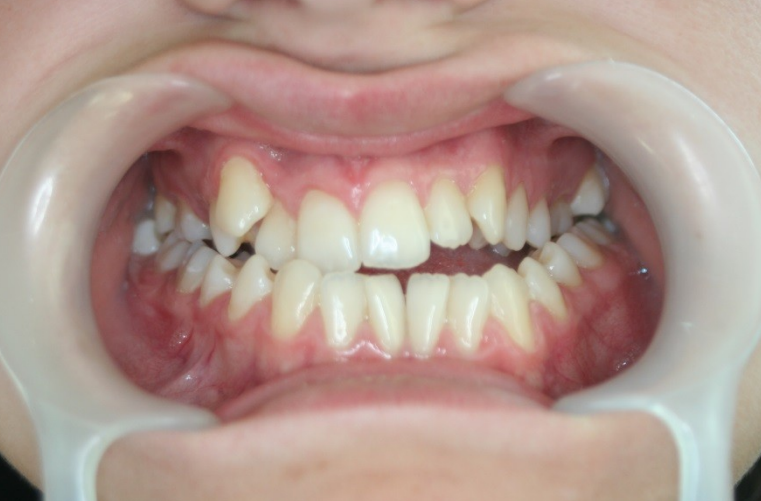Relapse, tertier crowding

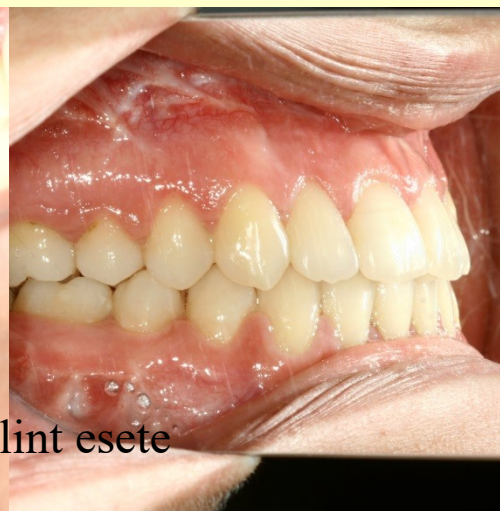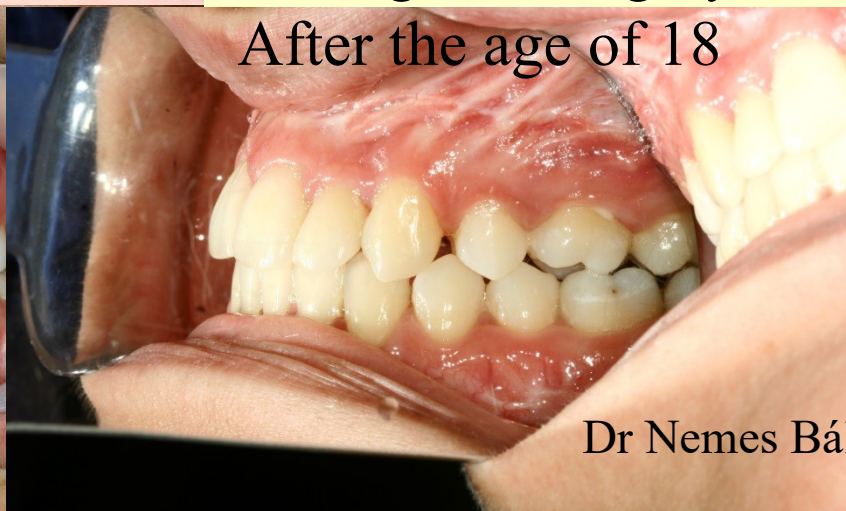
OP CBCT

-








Orthognath surgery – „real” III. class,
After the age of 18



Dr Nemes Bálint esete



Bimaxillary surgical interventions
Le-Fort I. – Obwegeser, Dalpont



Another grouping of orthodontic appliances

Intraoral

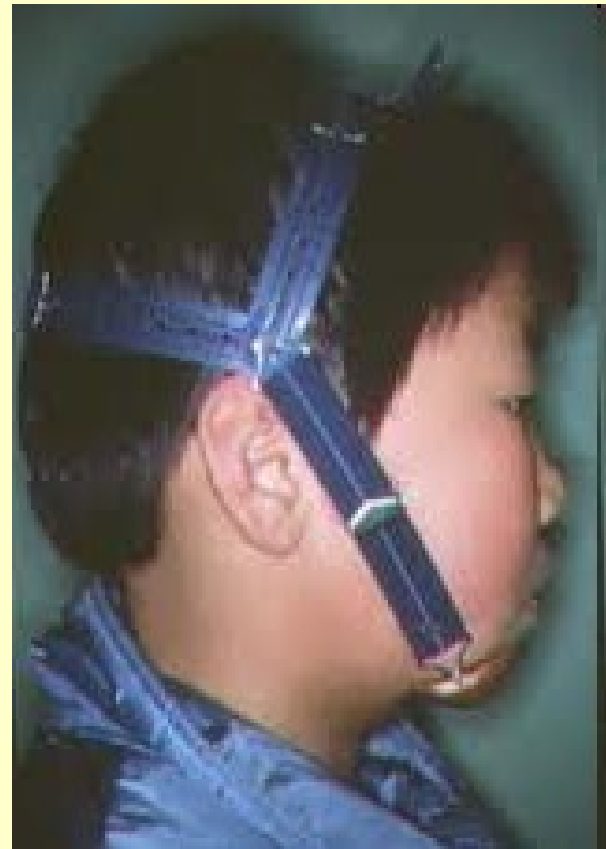Extraoral

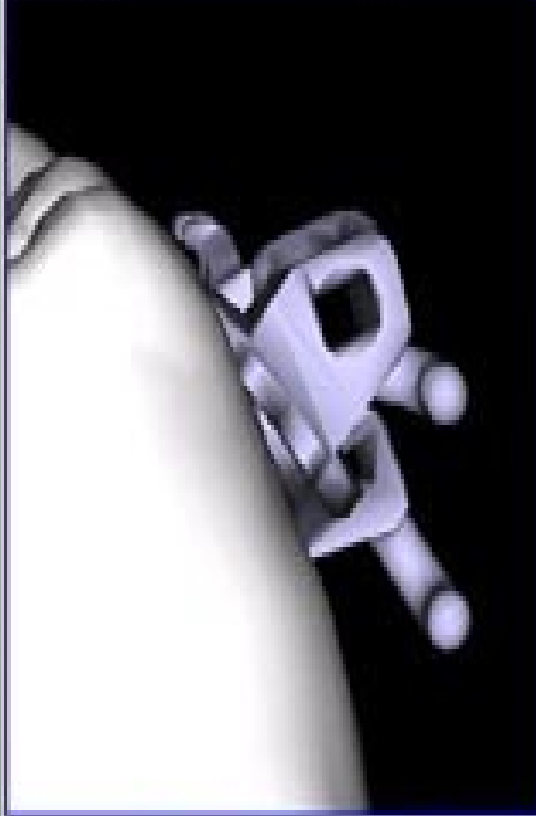
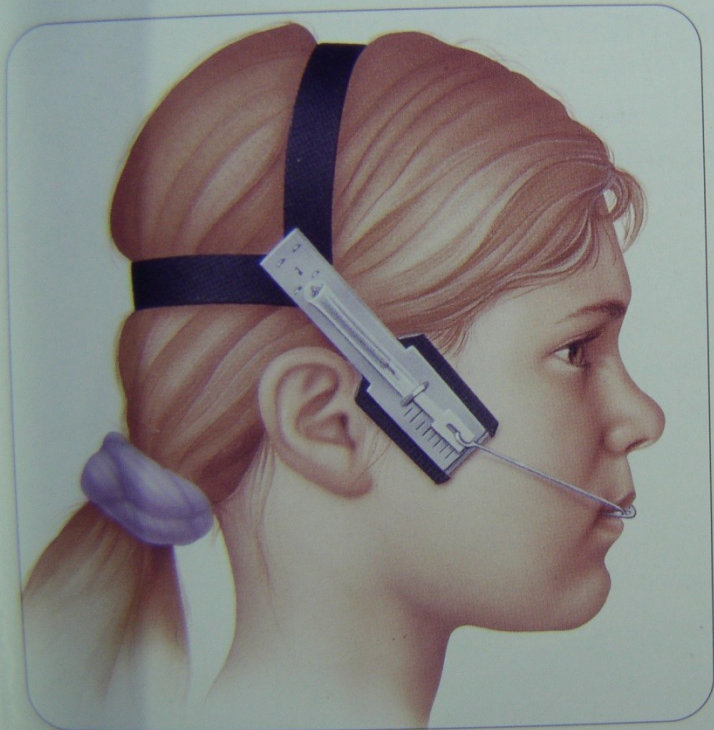Intra-, extraoral appliances

Extraorális készülék:

Chin cap (III.o, mesialocclusion)

Used from early ages





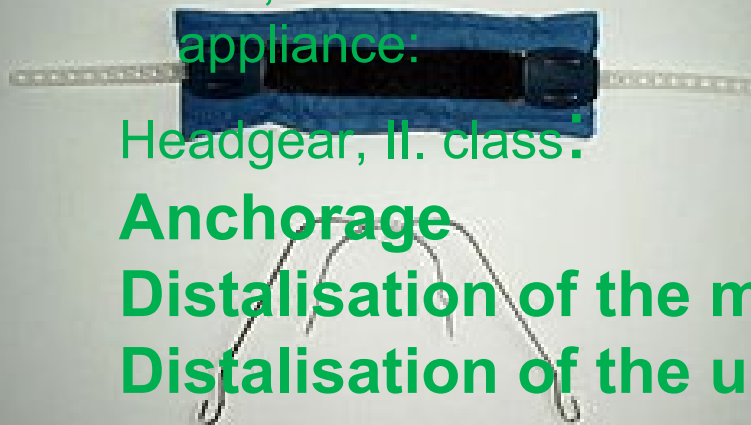Extra-,Intraoral
appliance:

Headgear, II. class:

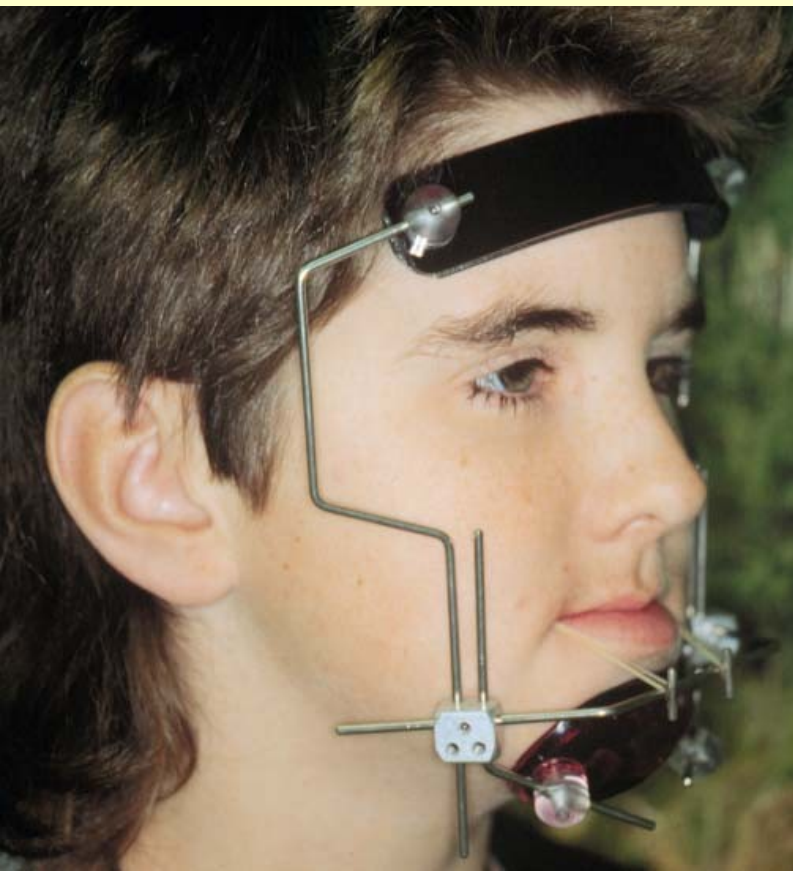Anchorage

Distalisation of the maxilla

Distalisation of the upper molars



Extra-,intraoral appliance: Reversed headger facemask



Sagittal expansion of teh upper jaw



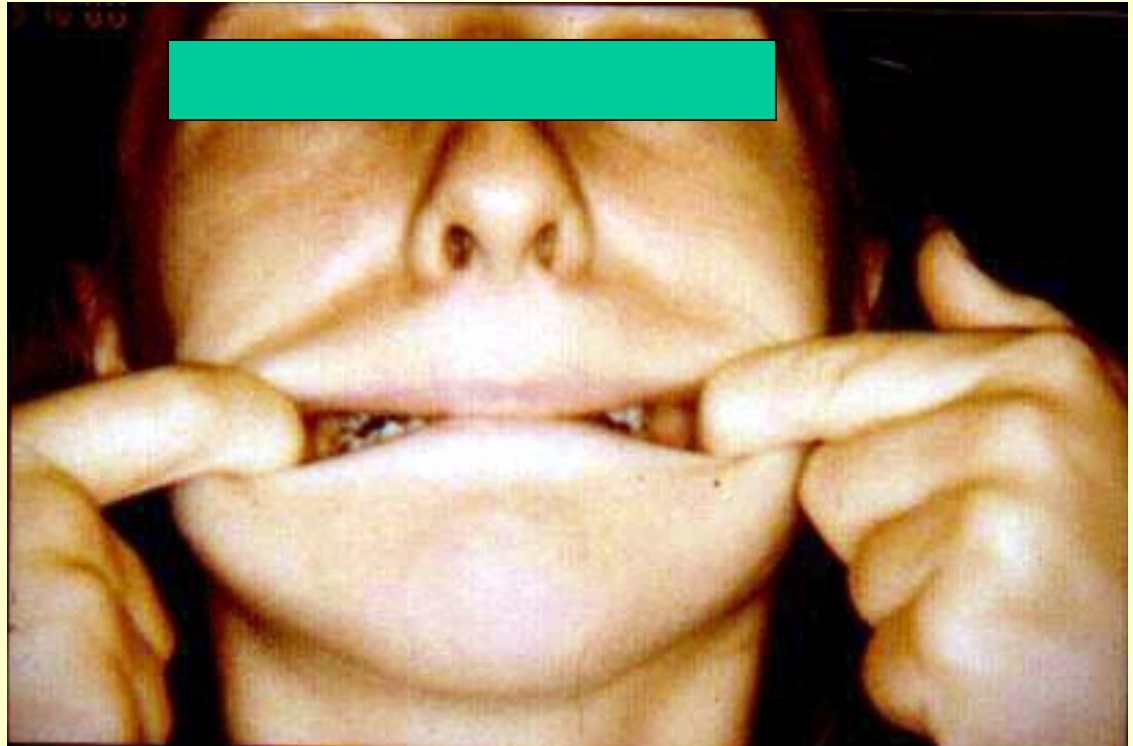
Treatment methods:

appliances

surgical interventions and appliances

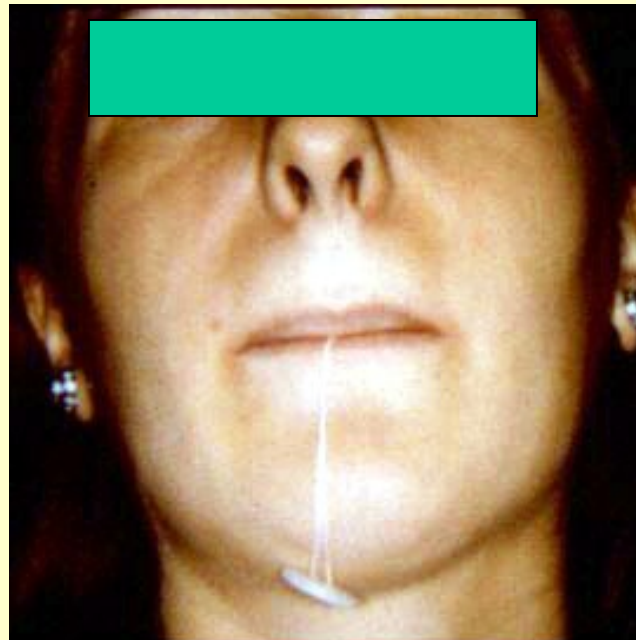
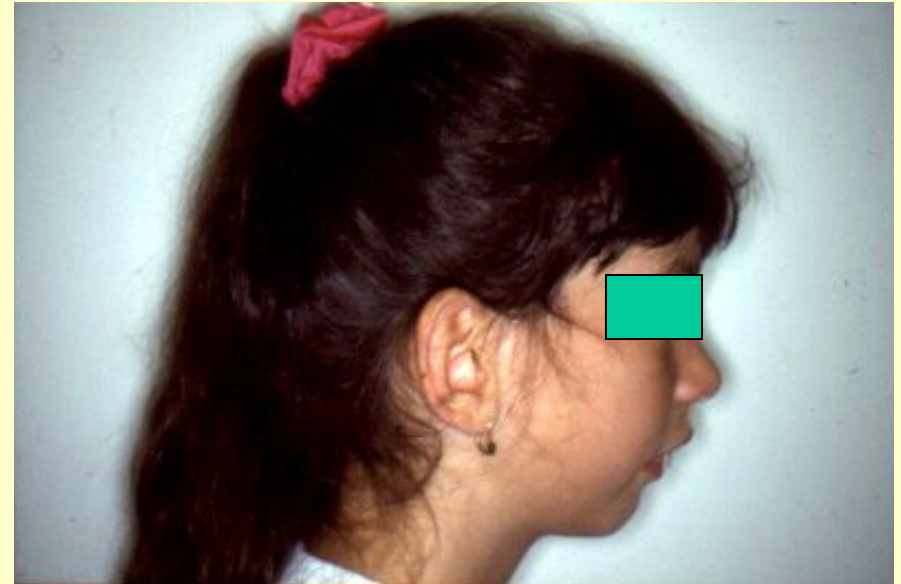
myotherapy

prevention



•Early treatment /interceptive orthodontics/

- appliances in primary and mixed dentition
- **myotherapy**
- surgical interventions
- prevention



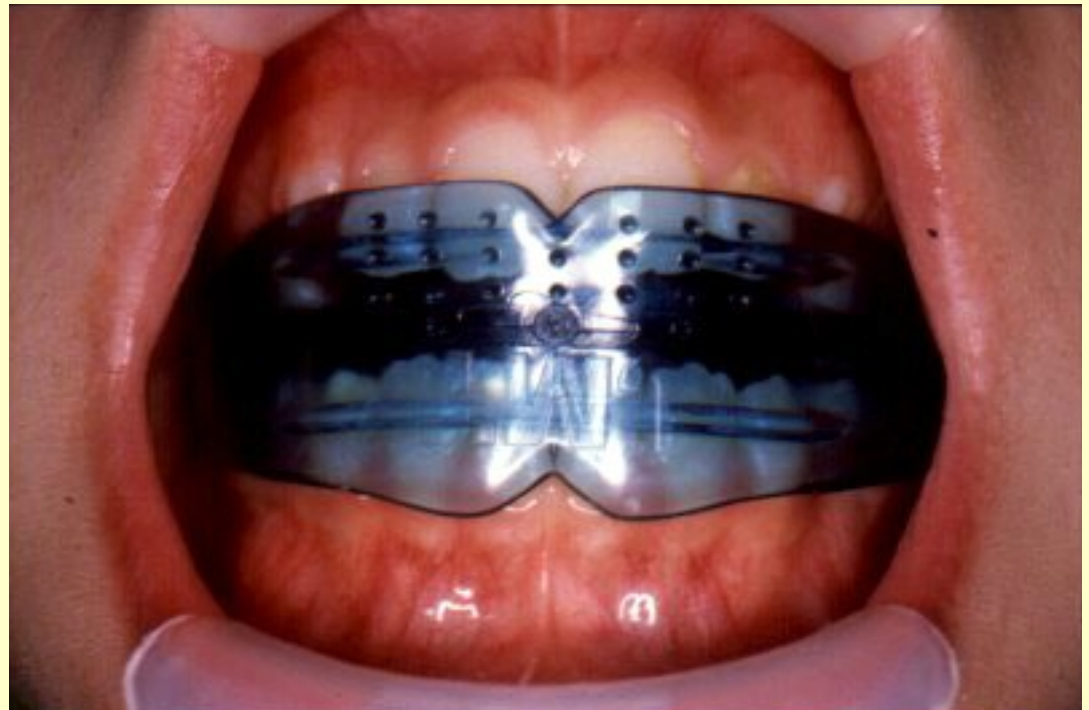Treatment methods:

appliances

surgical interventions and appliances

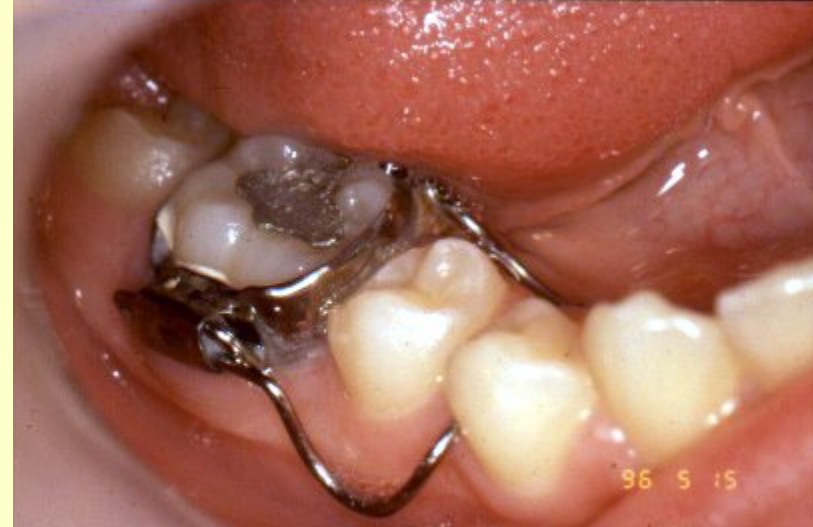myotherapy

prevention



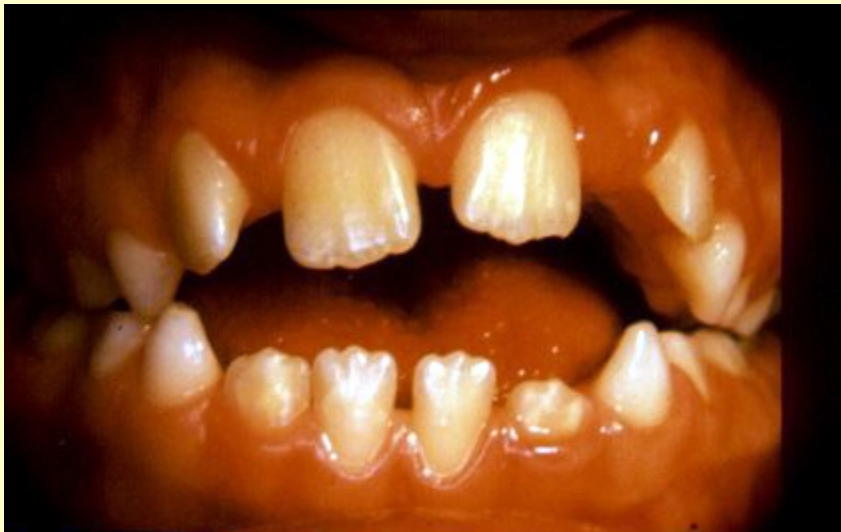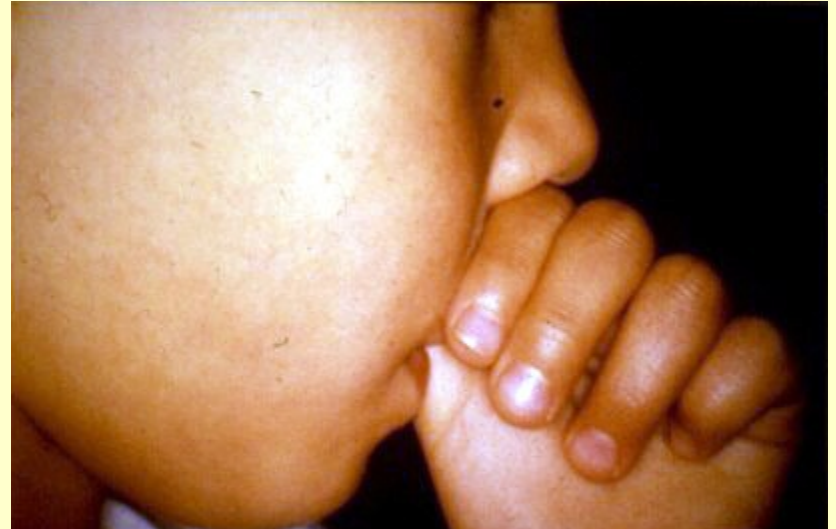Possibilities of prevention

- **General preventive practice**
 - prevention of prenatal injuries
 - treatment of general diseases
 - assurance of normal development
- **Space maintainers**
- **Early treatment /interceptive orthodontics/**
 - inhibit deleterious oral habits
 - appliances in primary and mixed dentition
 - myotherapy
 - serial extraction /Hotz/



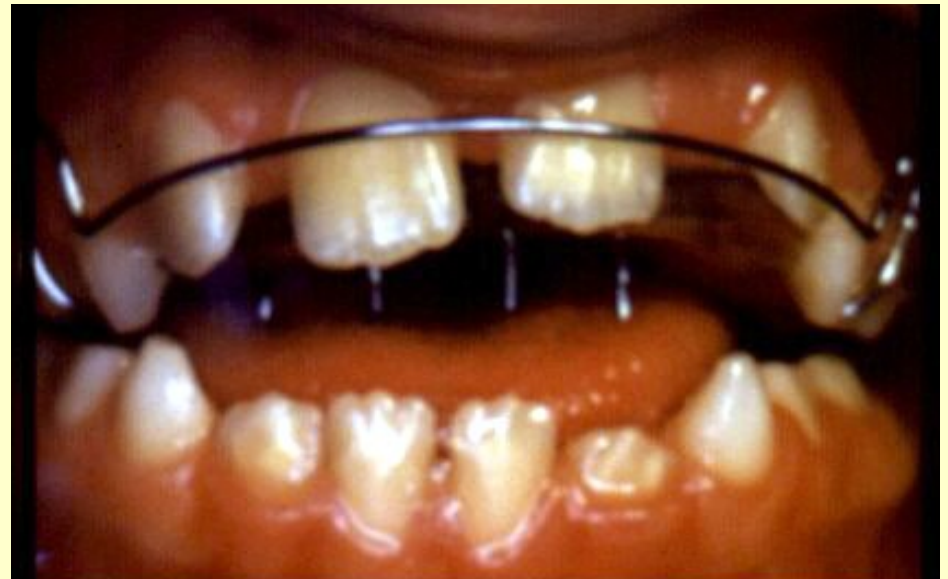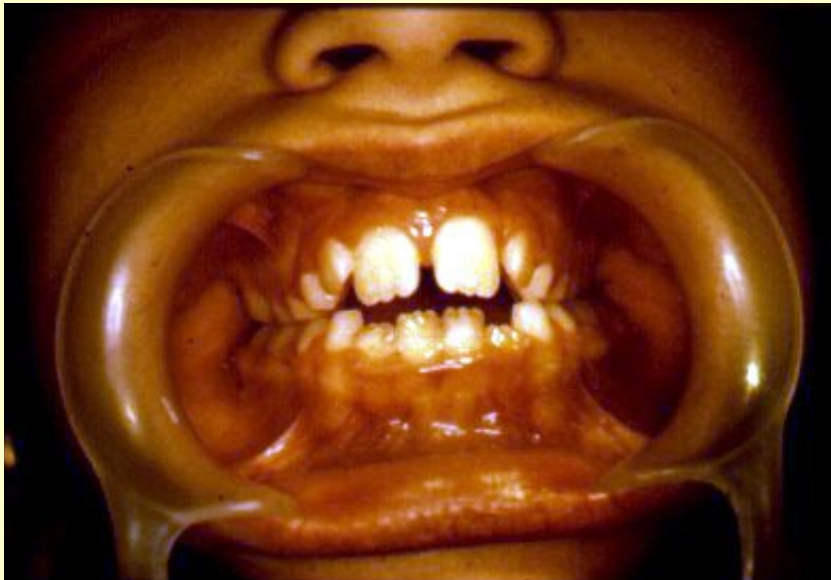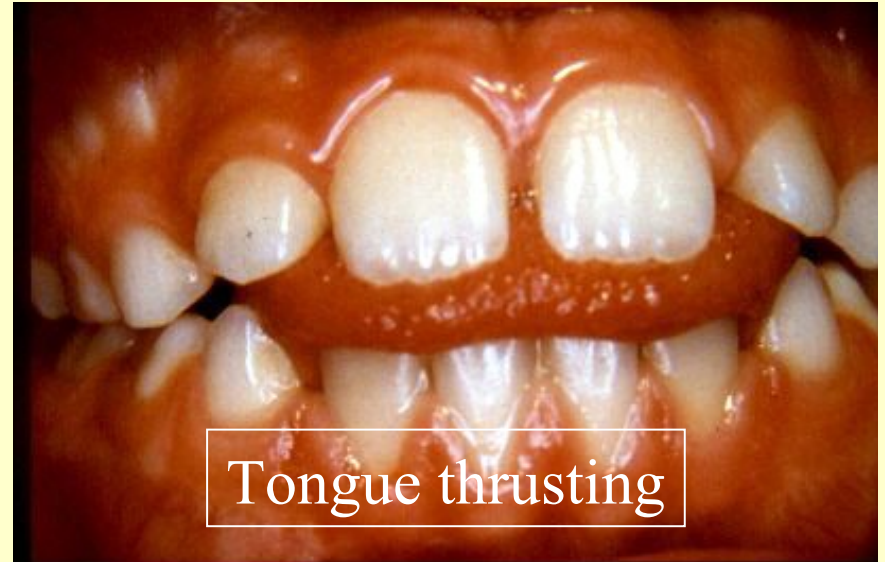
•Early treatment /interceptive orthodontics/

- inhibit deleterious oral habits
- appliances in primary and mixed dentition
- myotherapy
- serial extraction /Hotz/

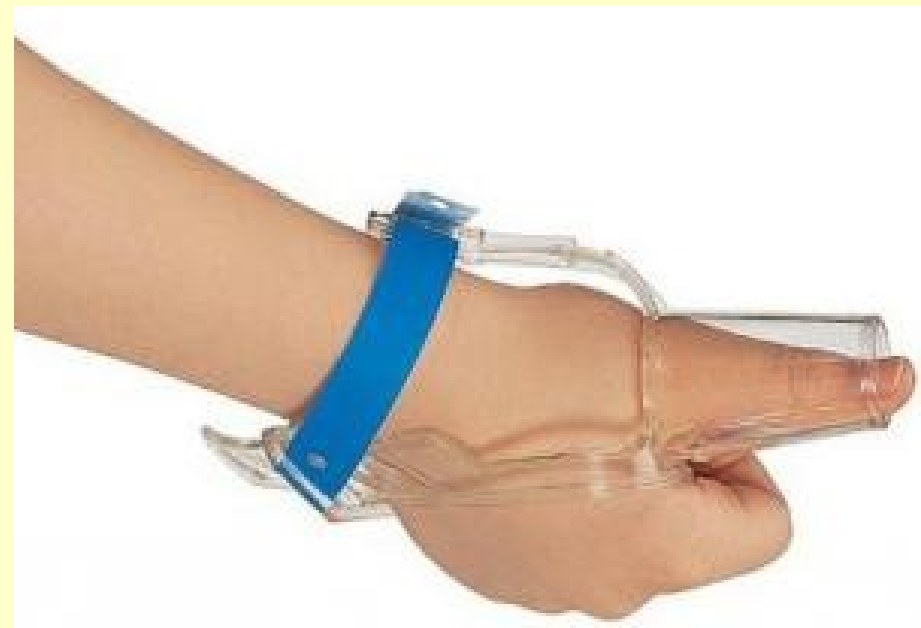
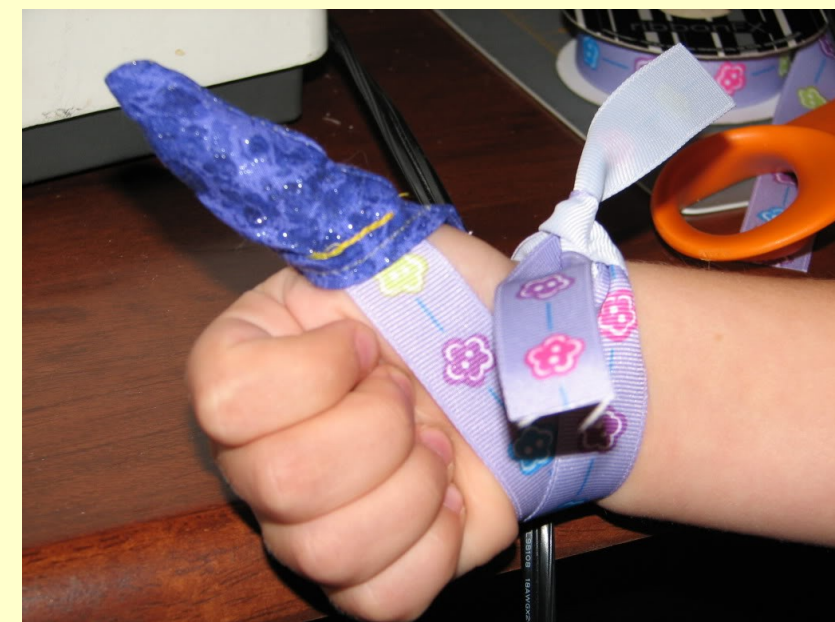
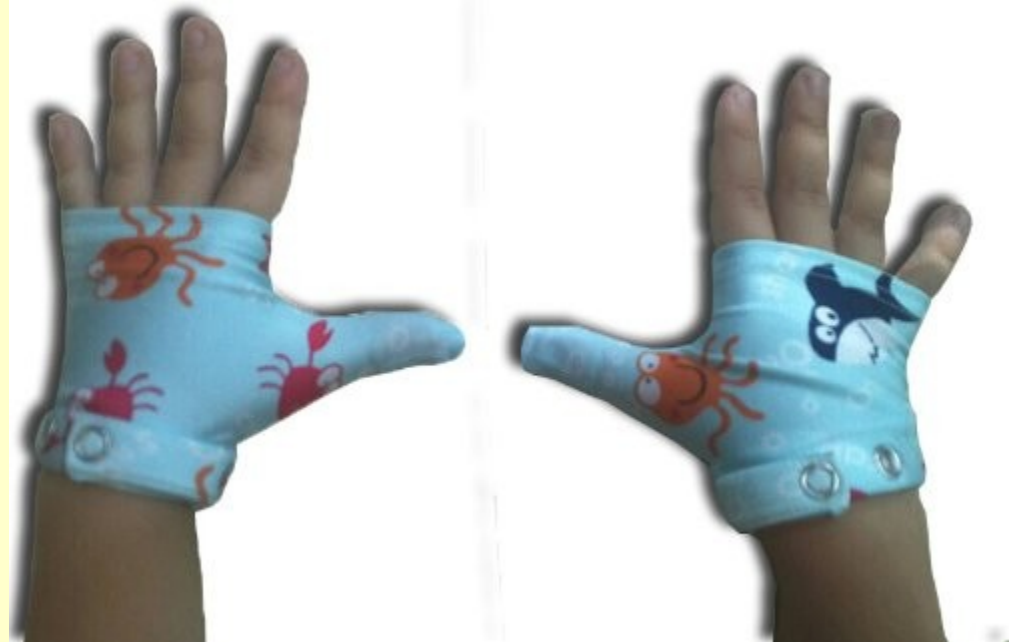• **Early treatment /interceptive orthodontics/**

- **inhibit deleterious oral habits**
- **appliances in primary and mixed dentition**
- **myotherapy**
- **serial extraction /Hotz/**



Habit breakers



MAVALA

SWITZERLAND
USA



THUM

THUMB SUCKING
NAIL BITING

Help Break The Habit

Just paint
on fingertips

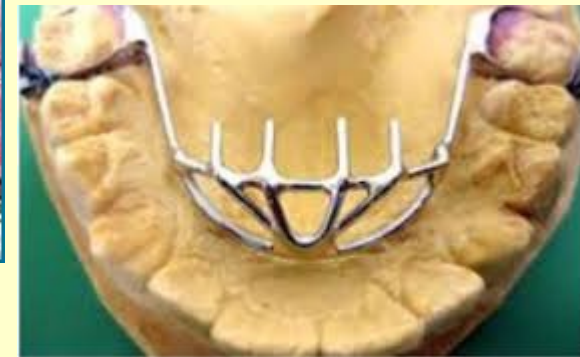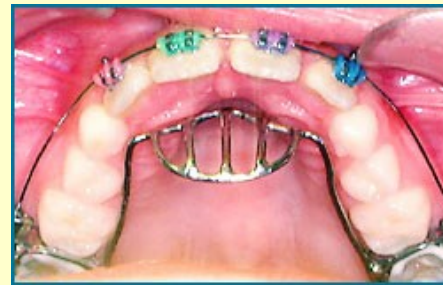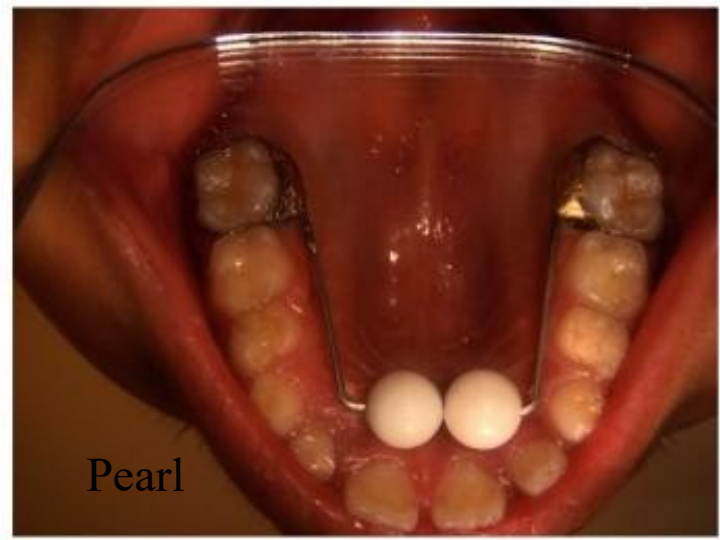No nausea or
stomach upset

NET .20 FL. OZ.

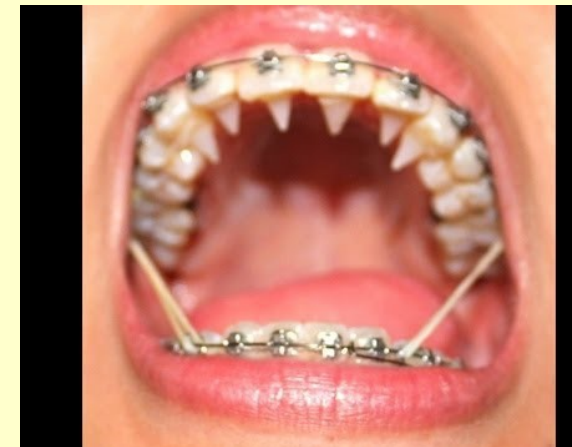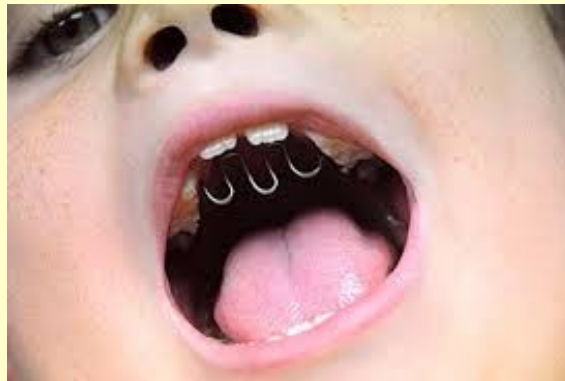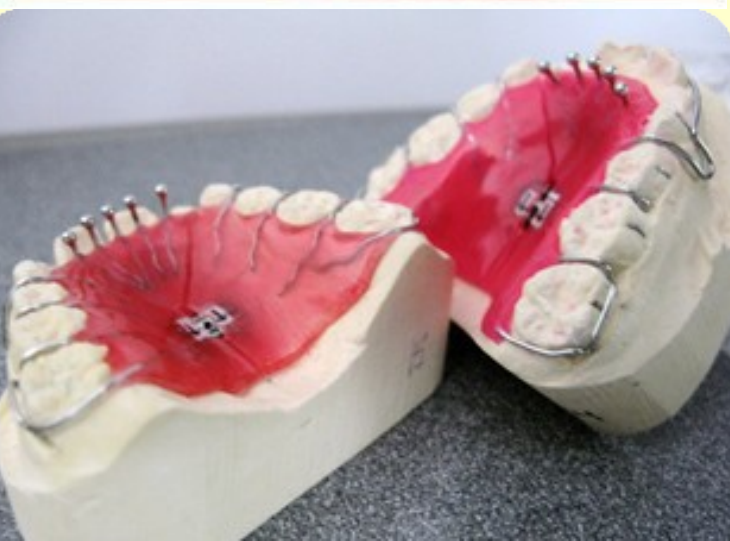24.10.09.

50

Orthodontic appliances against thumb sucking or tongue thrusting



Speech therapist !!



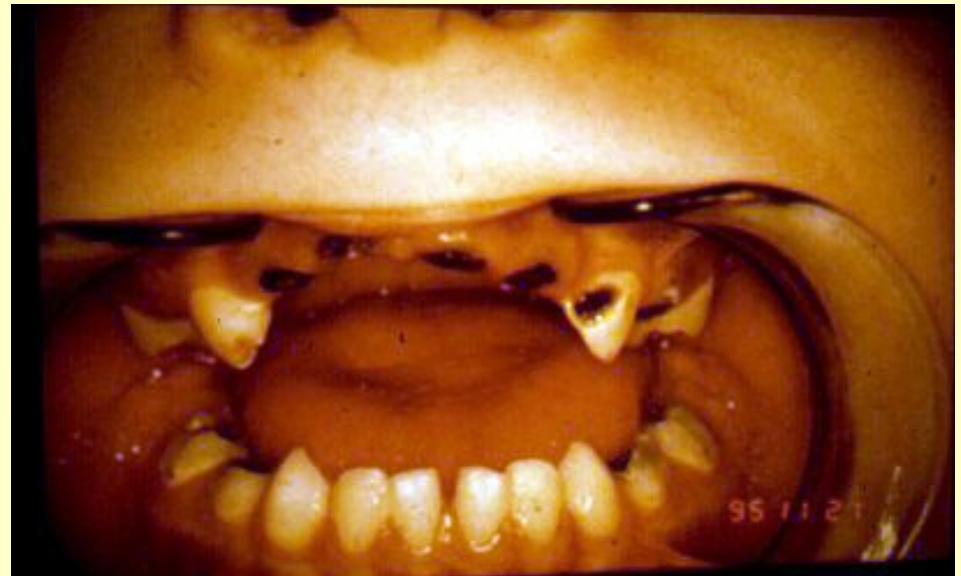
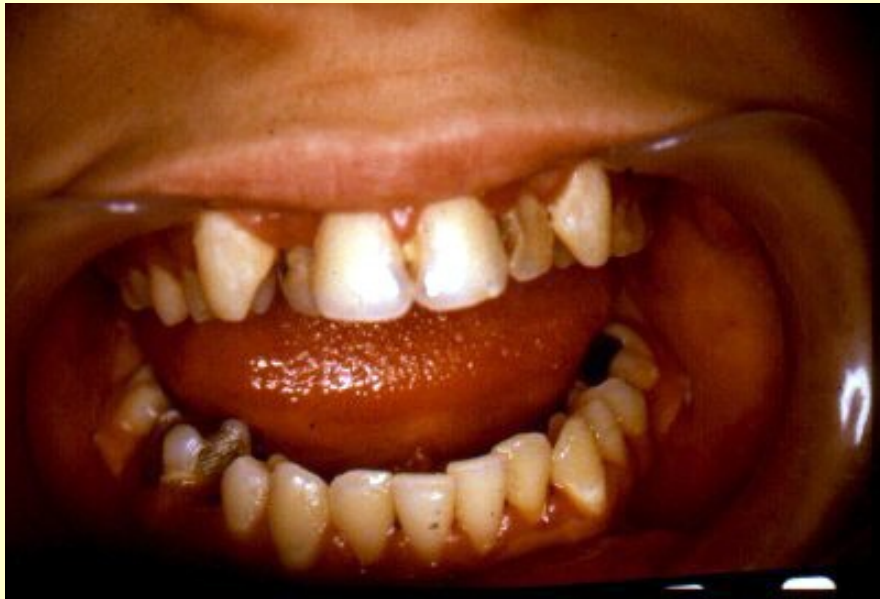Connection between orthodontic and other dental anomalies

Malocclusion ↔ **caries (crowding)**

Malocclusion ↔ **parodontitis (plaque, incorrect occlusion)**

Malocclusion → **speech defects**

Malocclusion ↔ **psychological problems**



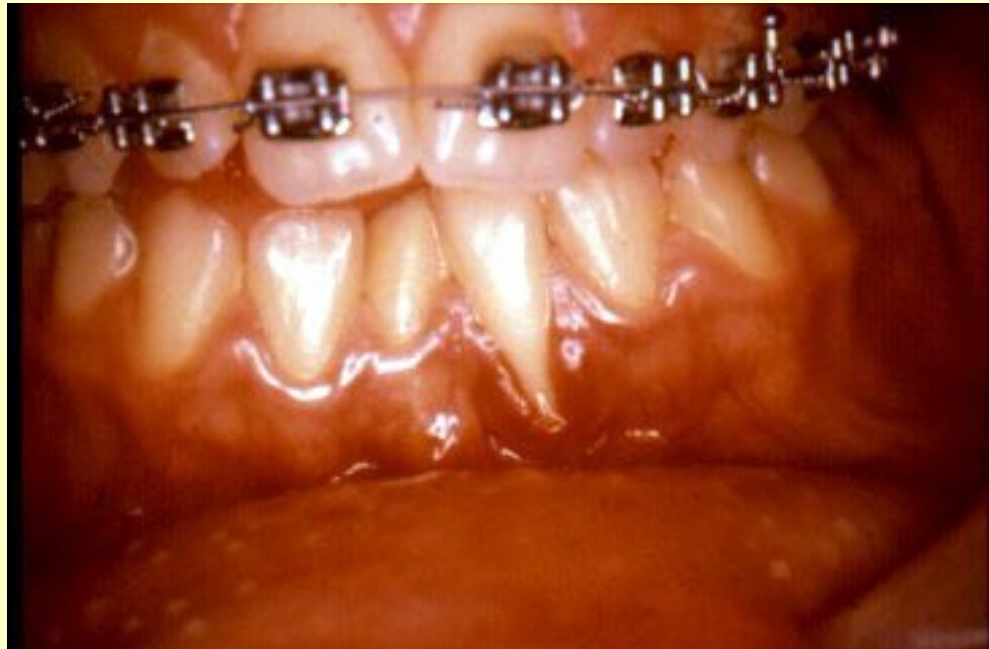
Connection between orthodontic and other anomalies

Malocclusion ↔ **caries**

Malocclusion ↔ **parodontitis, (caries, bad occlusion)**

Malocclusion → **speech defects**

Malocclusion ↔ **psychological problems**



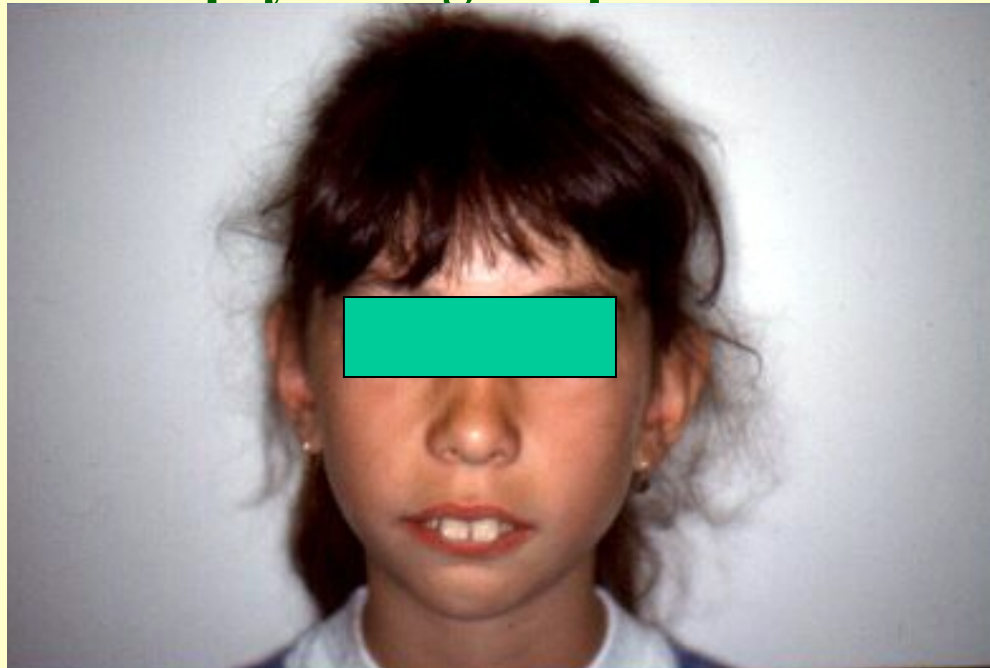Connection between orthodontic and other anomalies

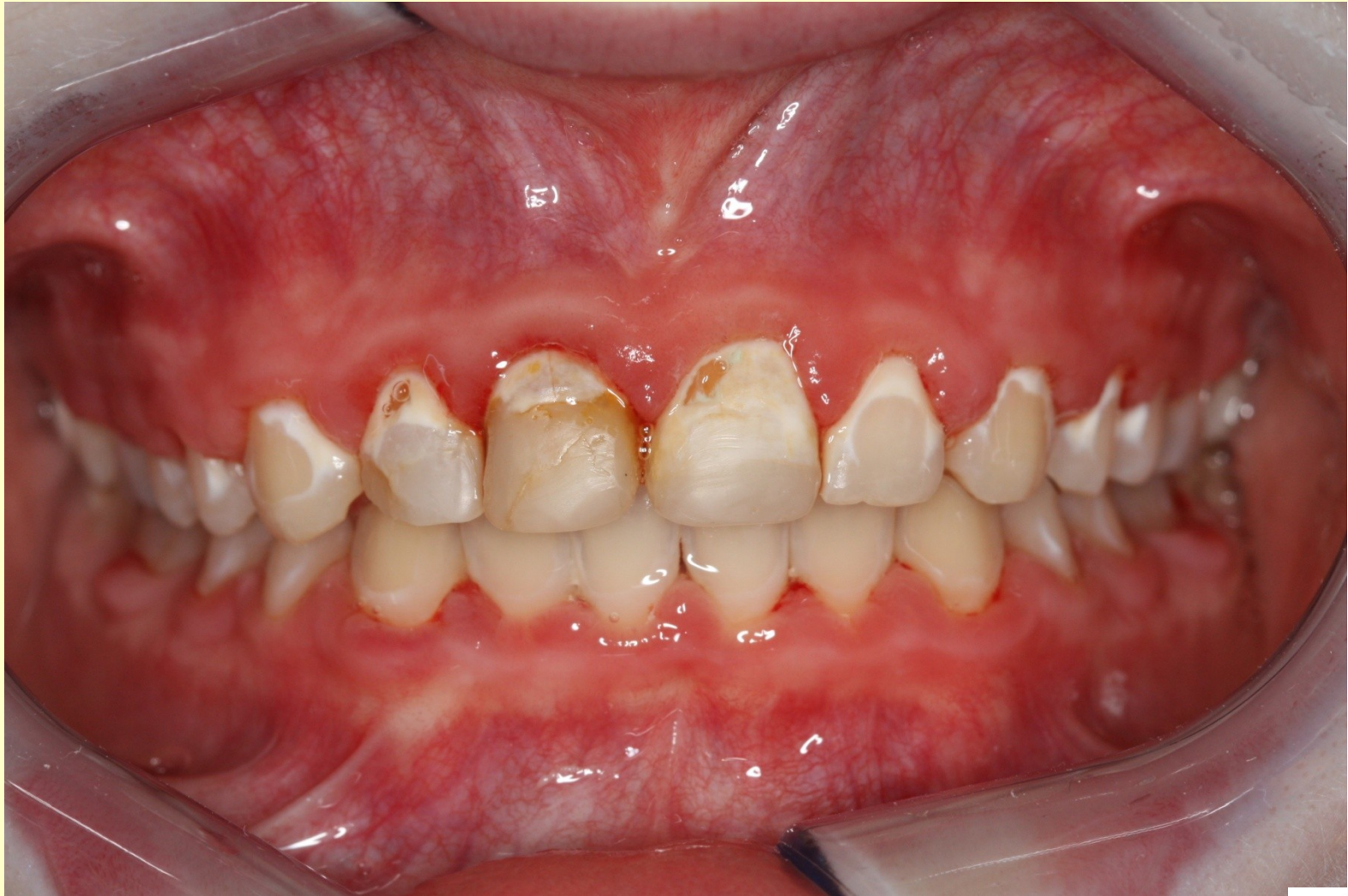Malocclusion ↔ **caries**

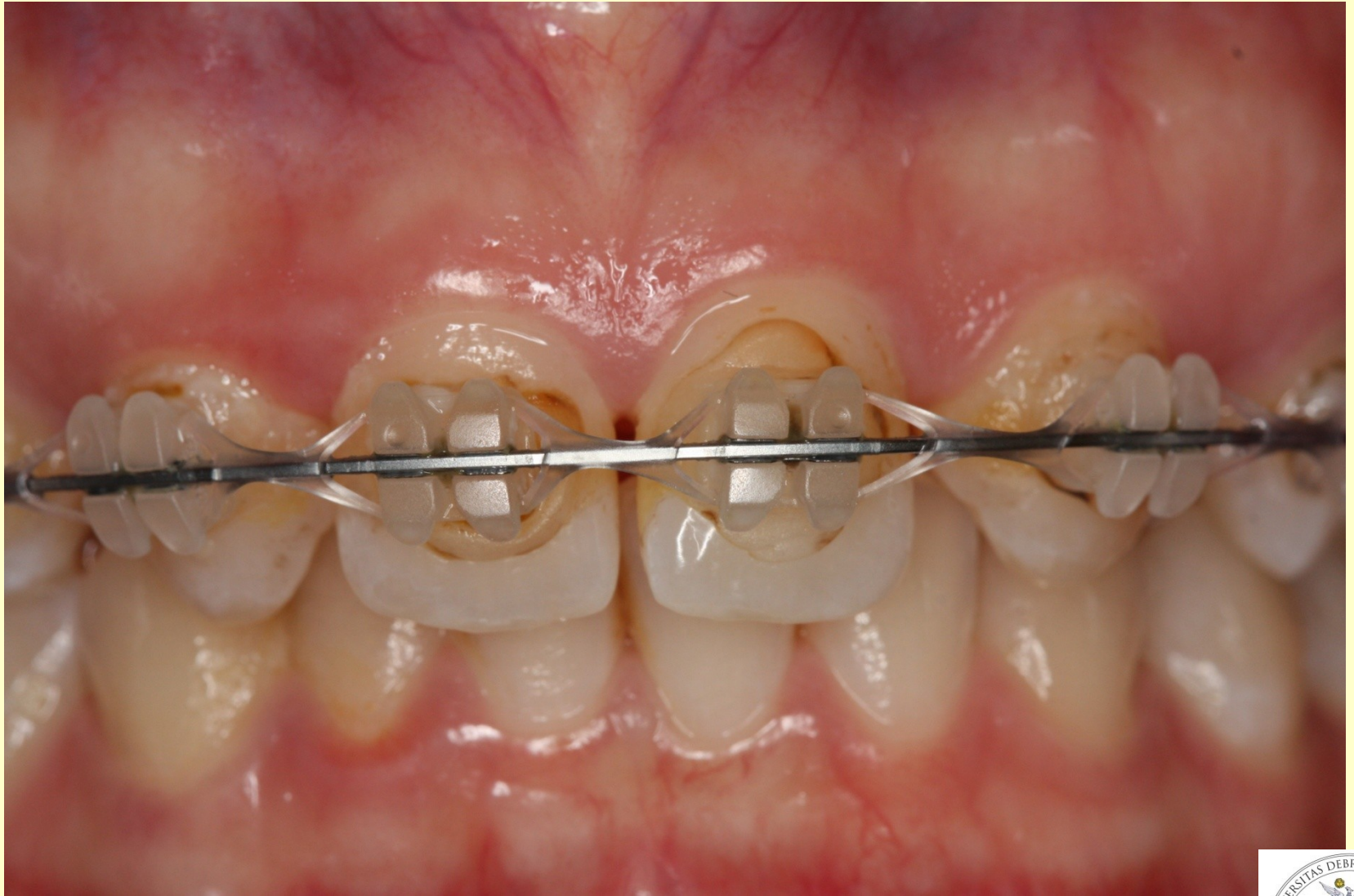
Malocclusion ↔ **parodontopathie**

Malocclusion → **speech defects (open bite, protrusion of the incisors, diasthema)**

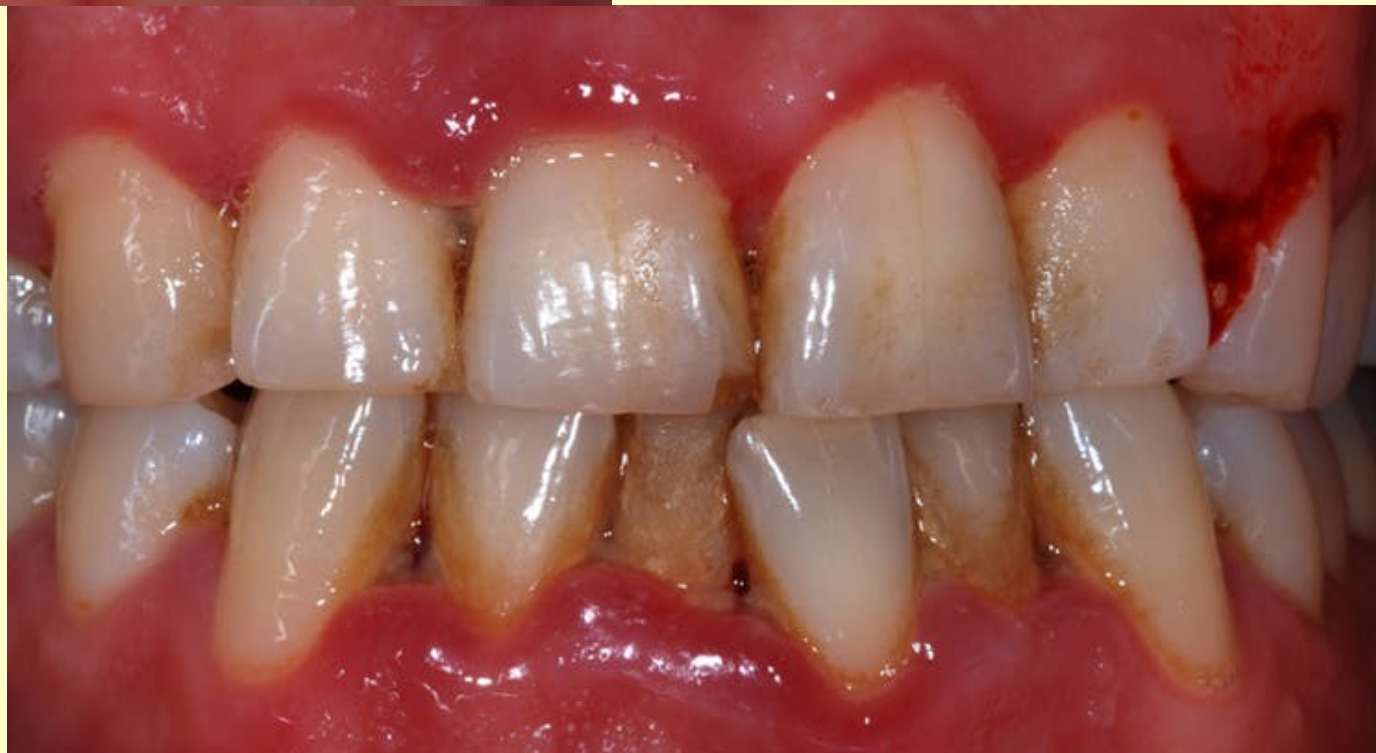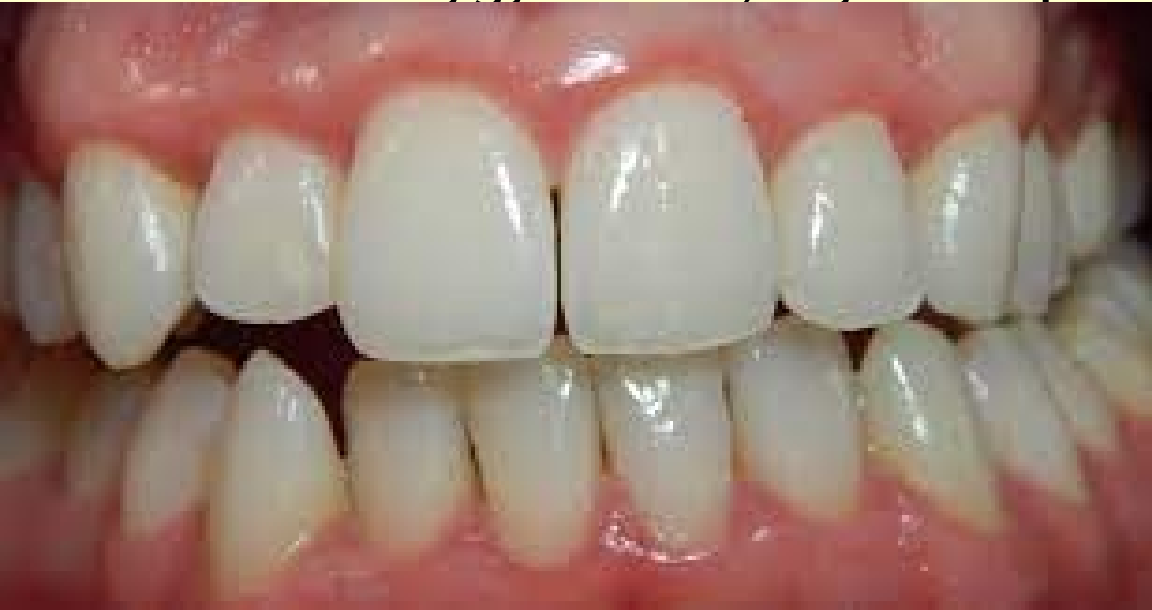Malocclusion ↔ **psychological problems**

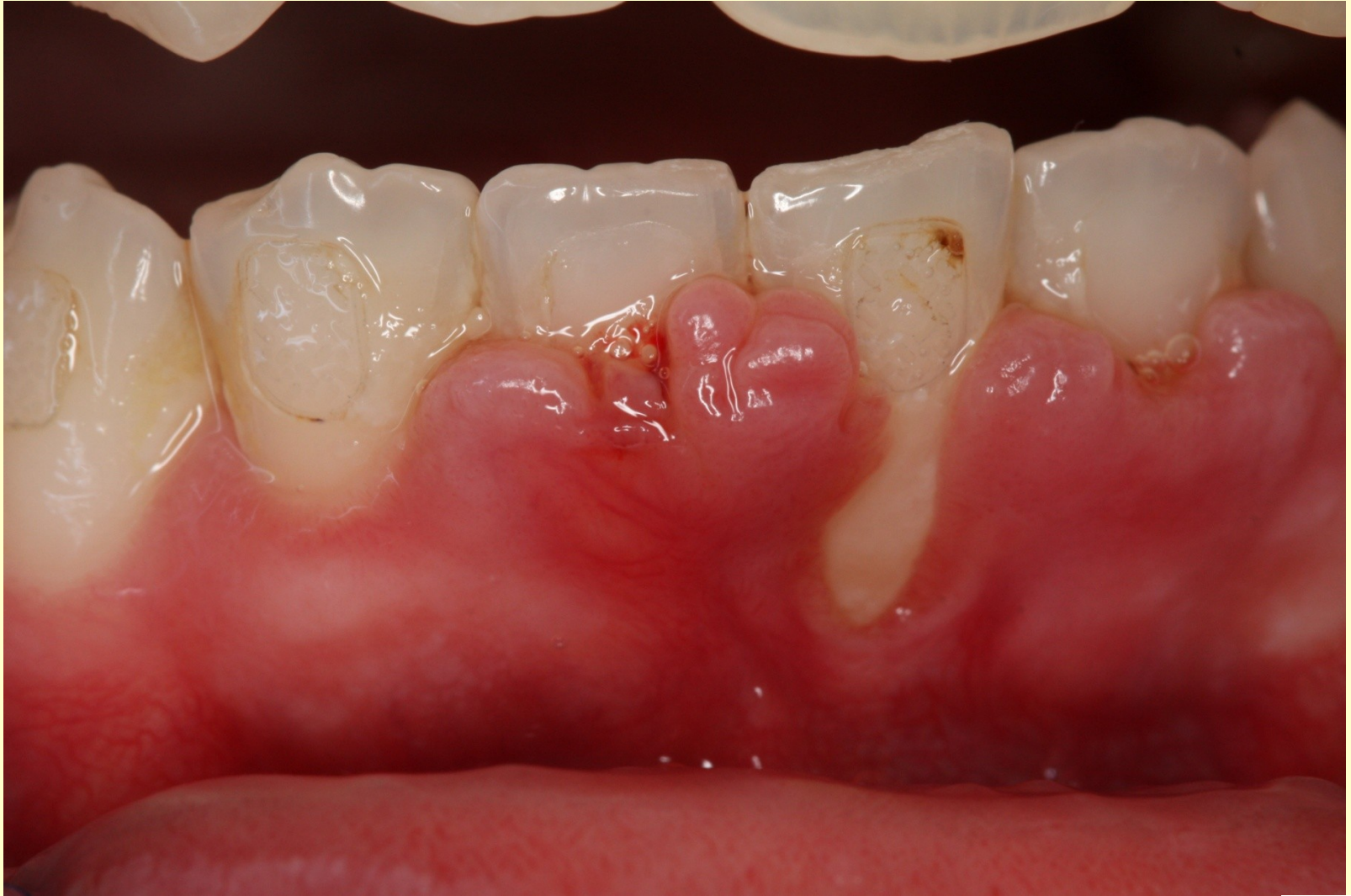



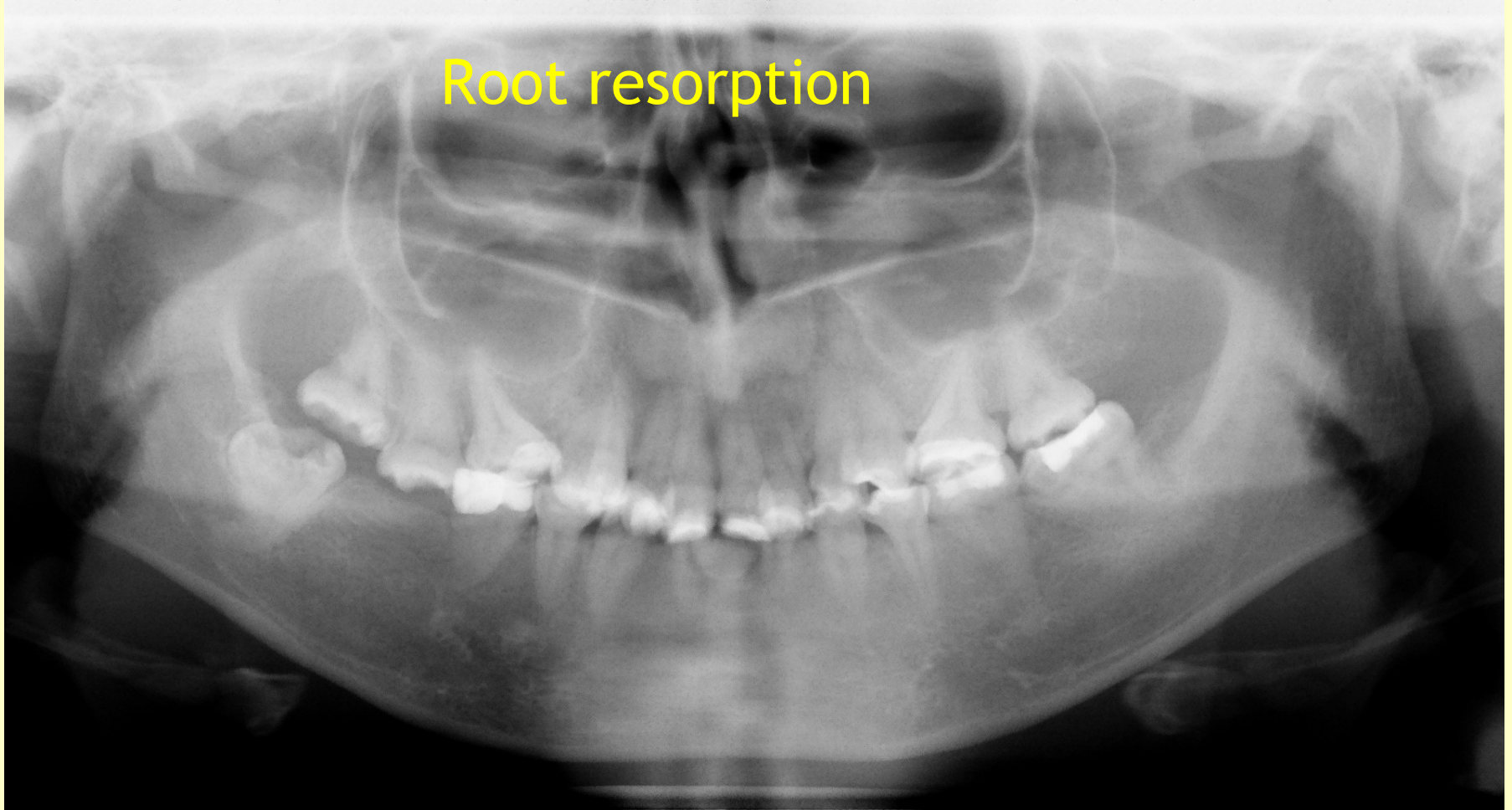


Ínygyulladás, ínyreszorpció

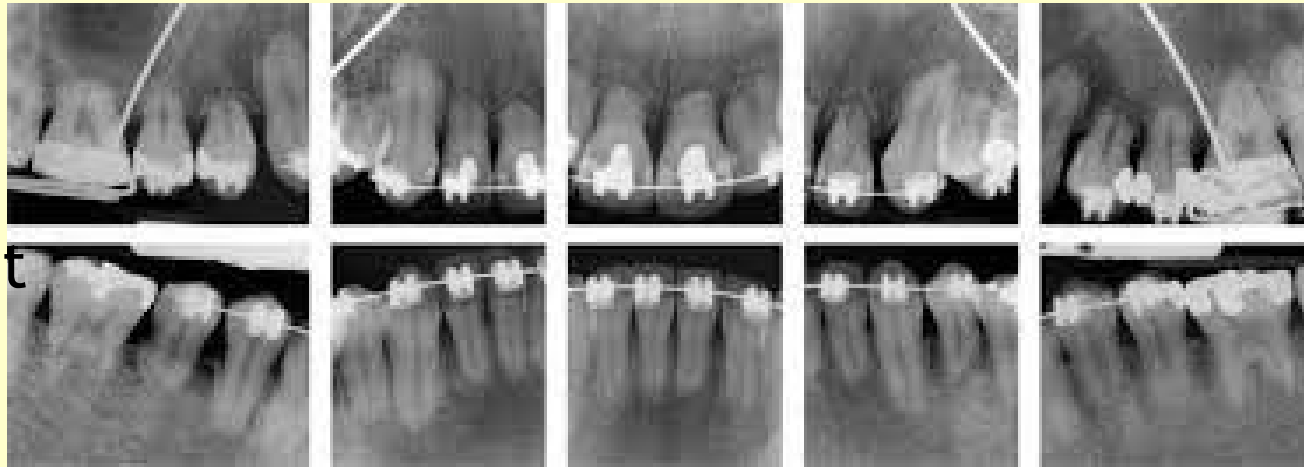

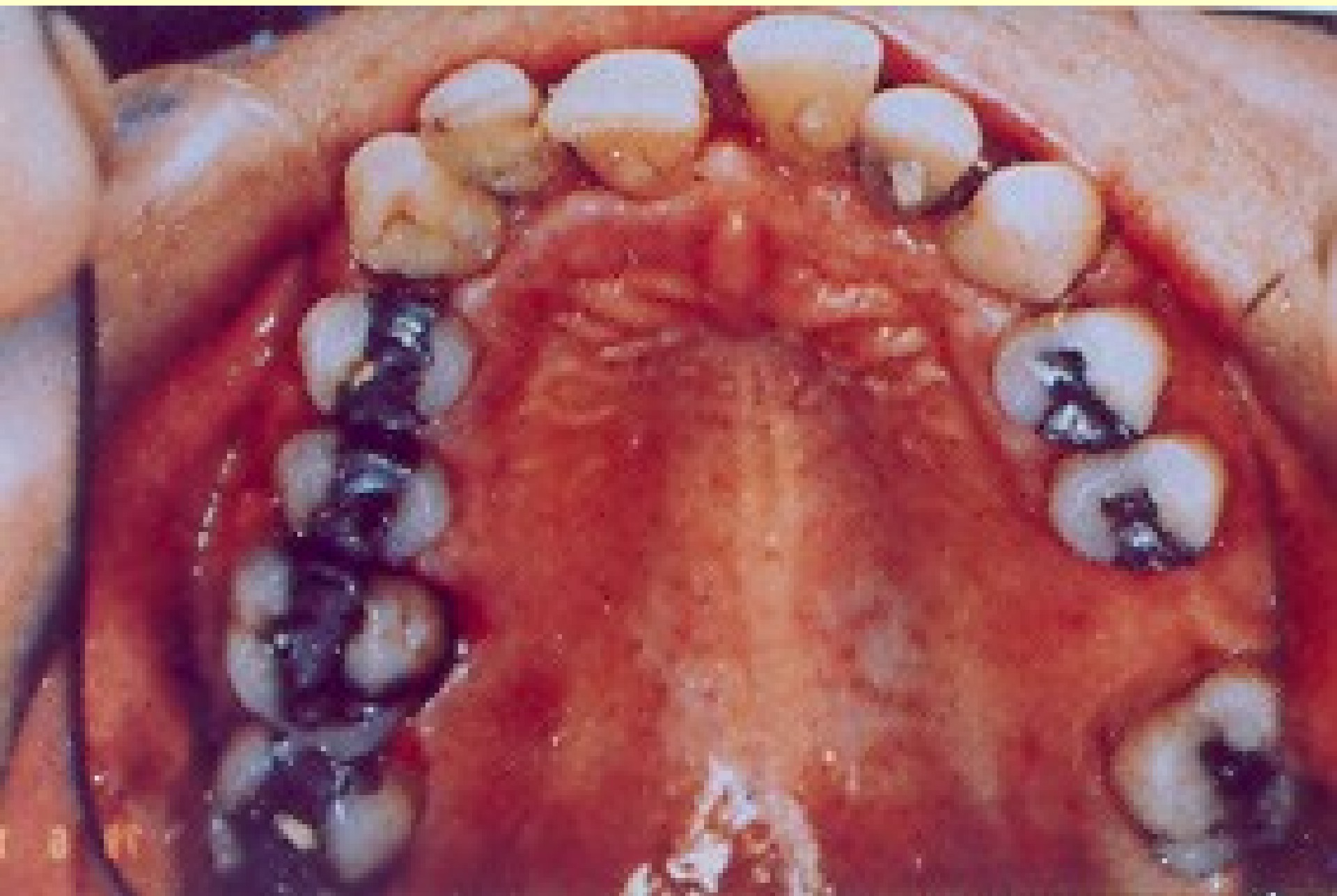


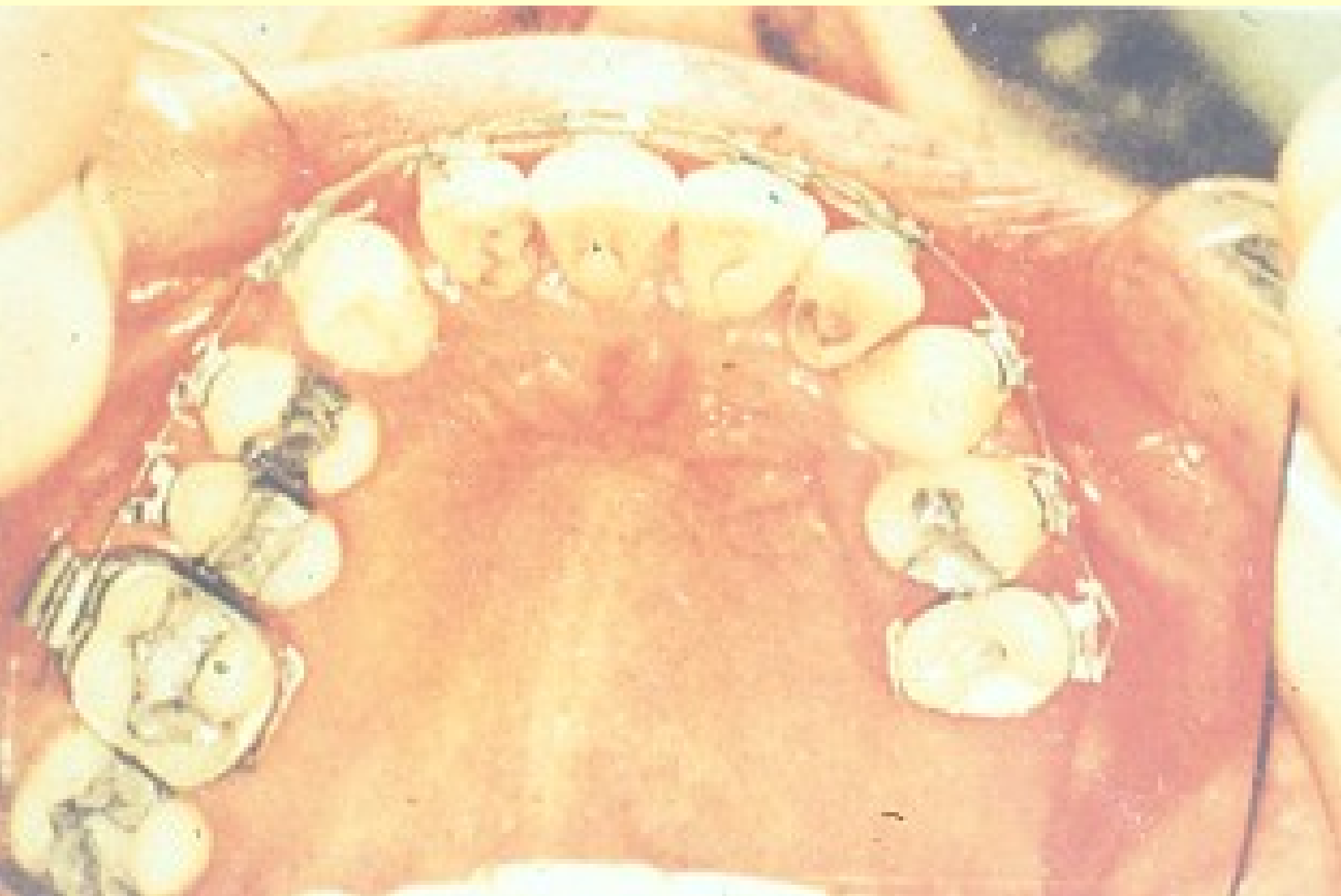Root resorption



Heavy forces
Long treatment
Jiggling
The age of the patient





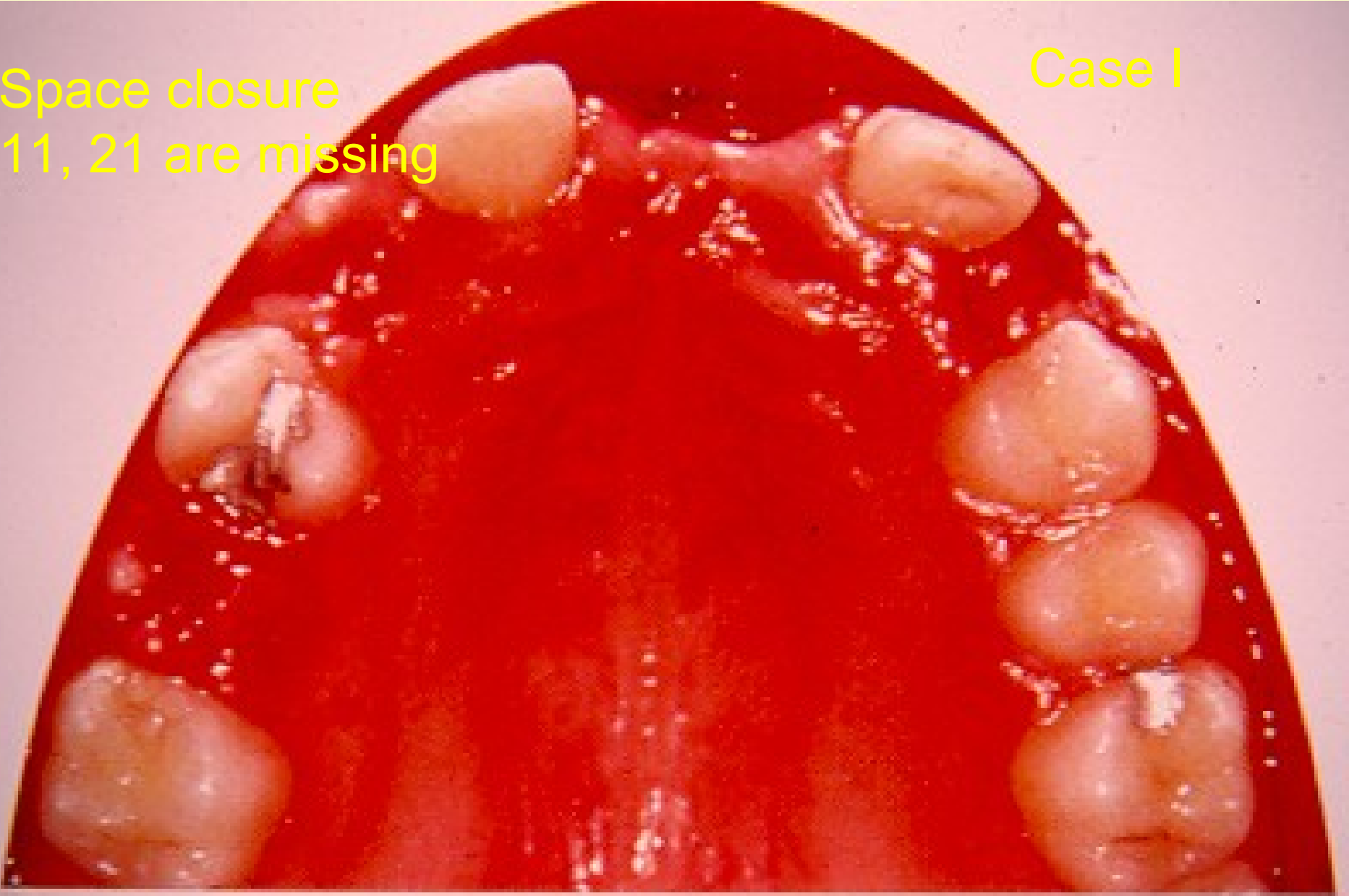


Treatment possibilities by missing teeth

- Reimplantation (after accidents)
- Bridge
- Implantation
- Space closure with fixed orthodontic appliance
- Preprosthetic orthodontic treatment +prosthetic solution – space maintaining, space gaining

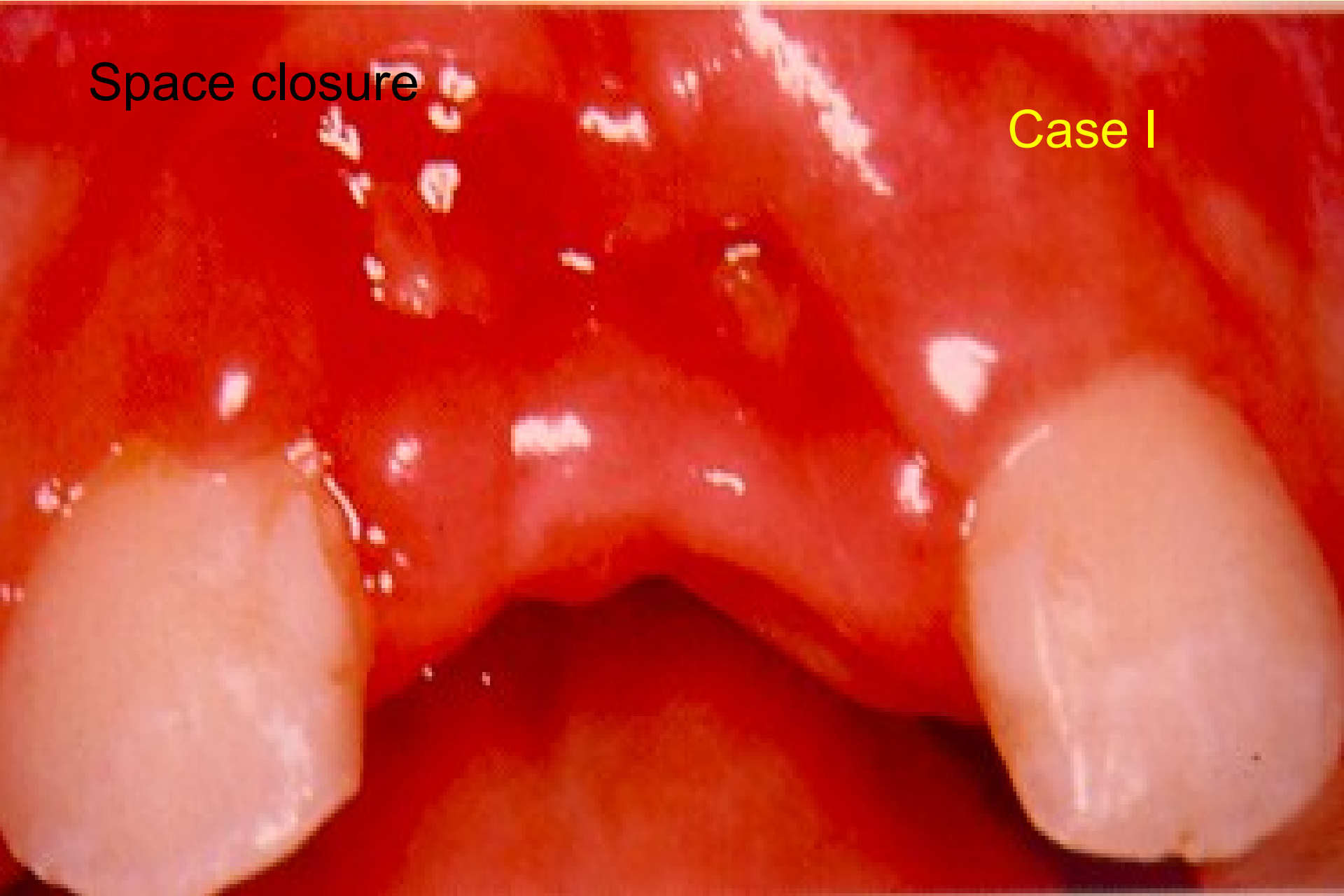Space closure
11, 21 are missing

Case I



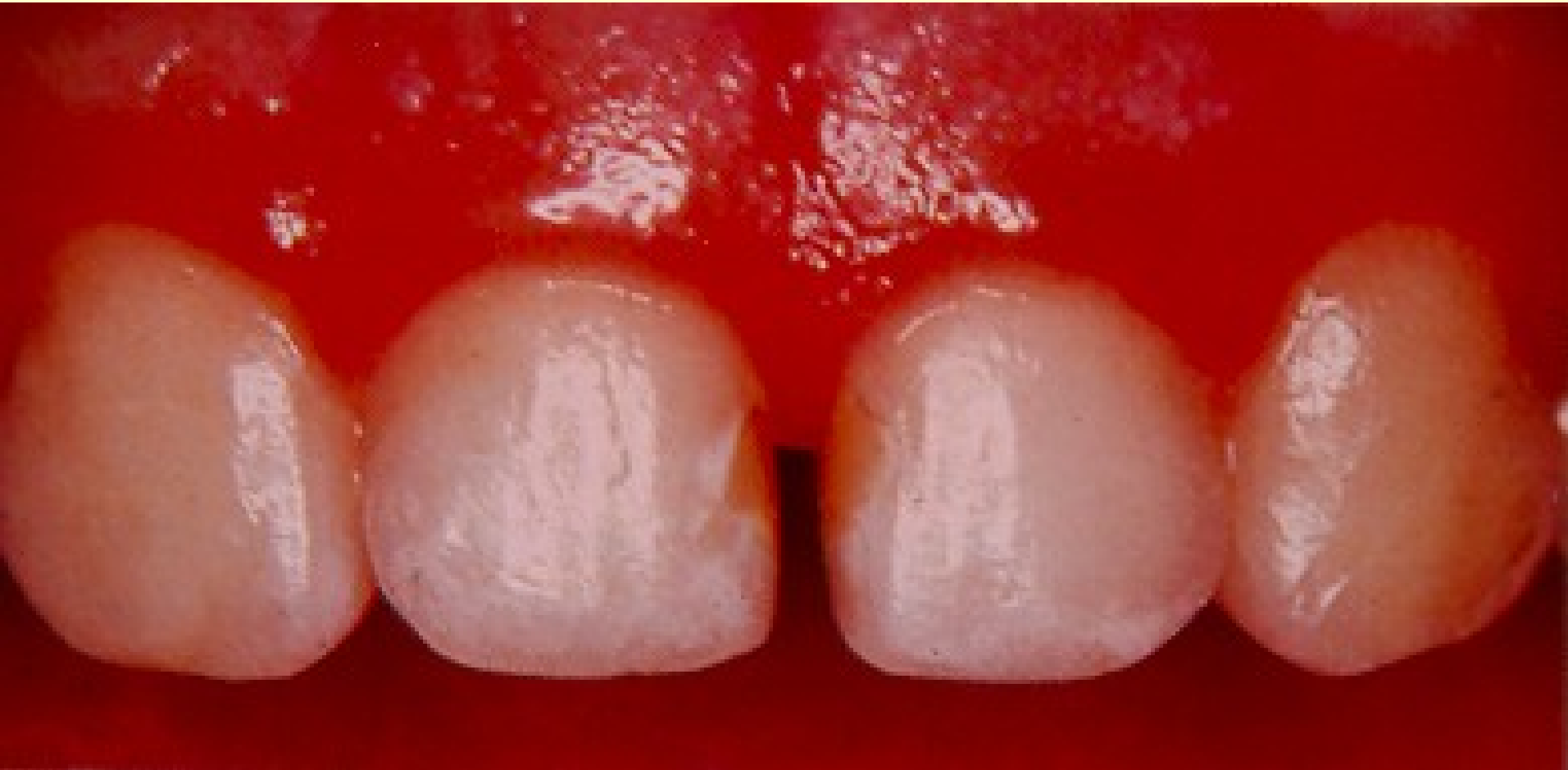Space closure

Case I



Space closure

Case I

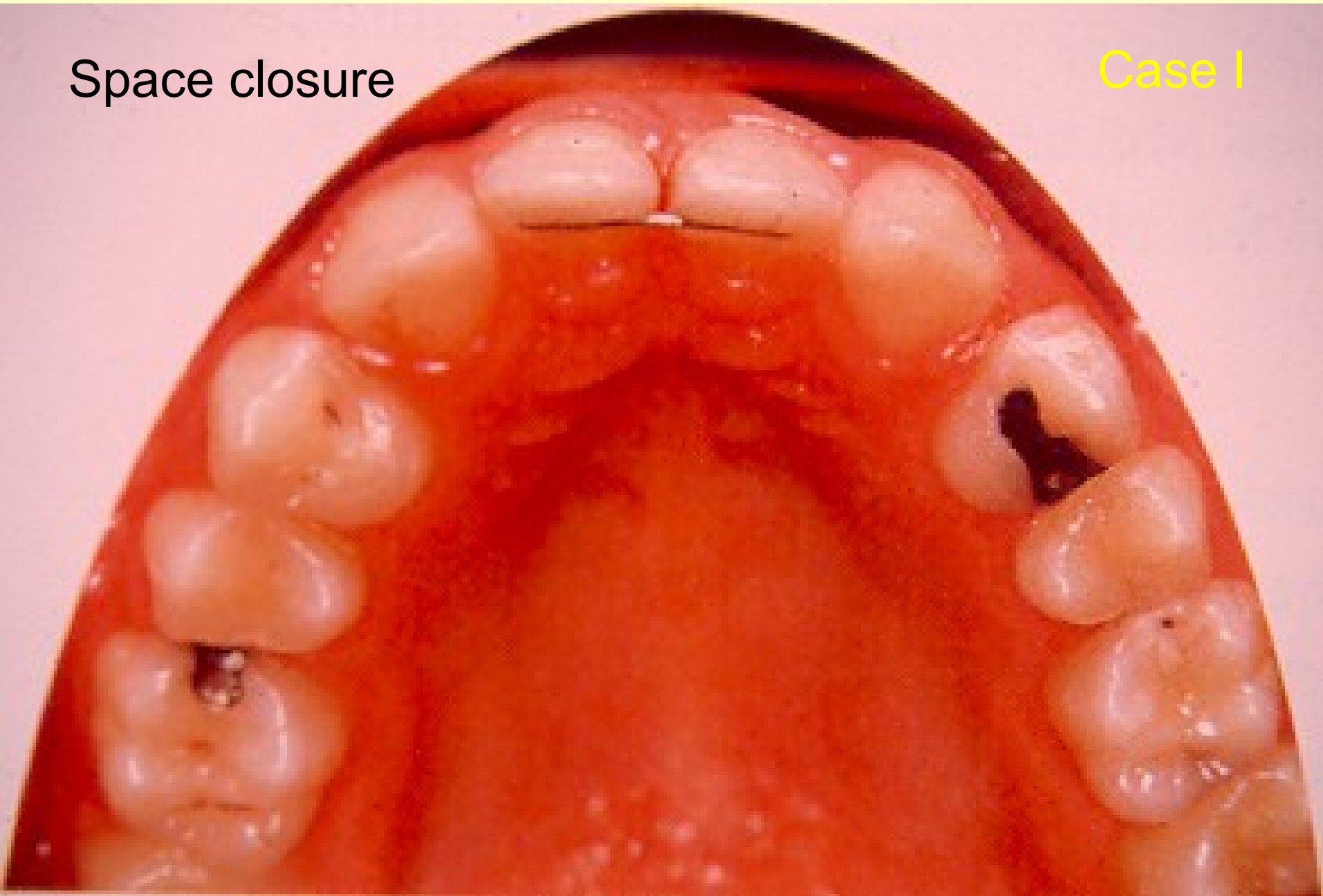


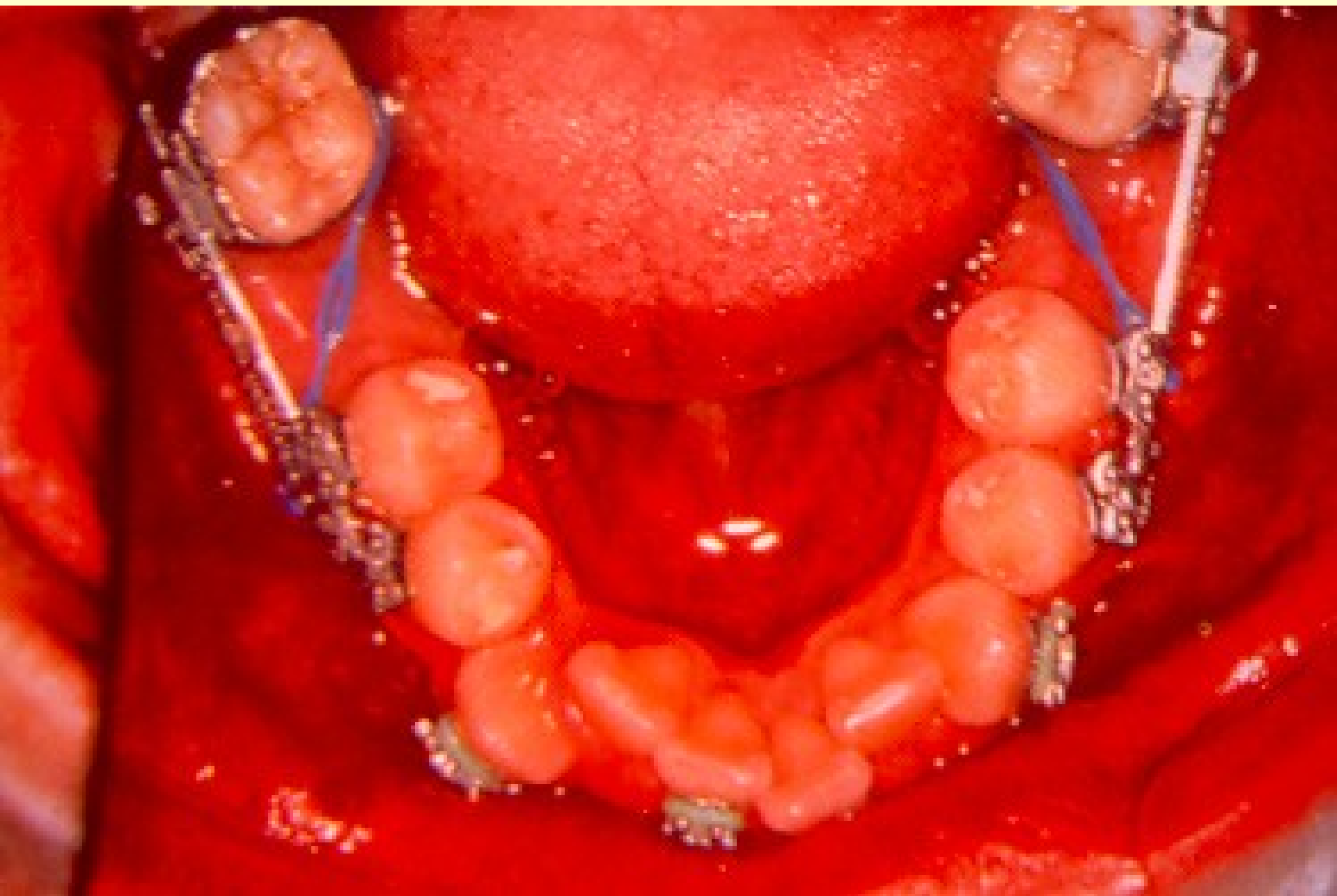
Indication of preprosthetic orthodontic treatment

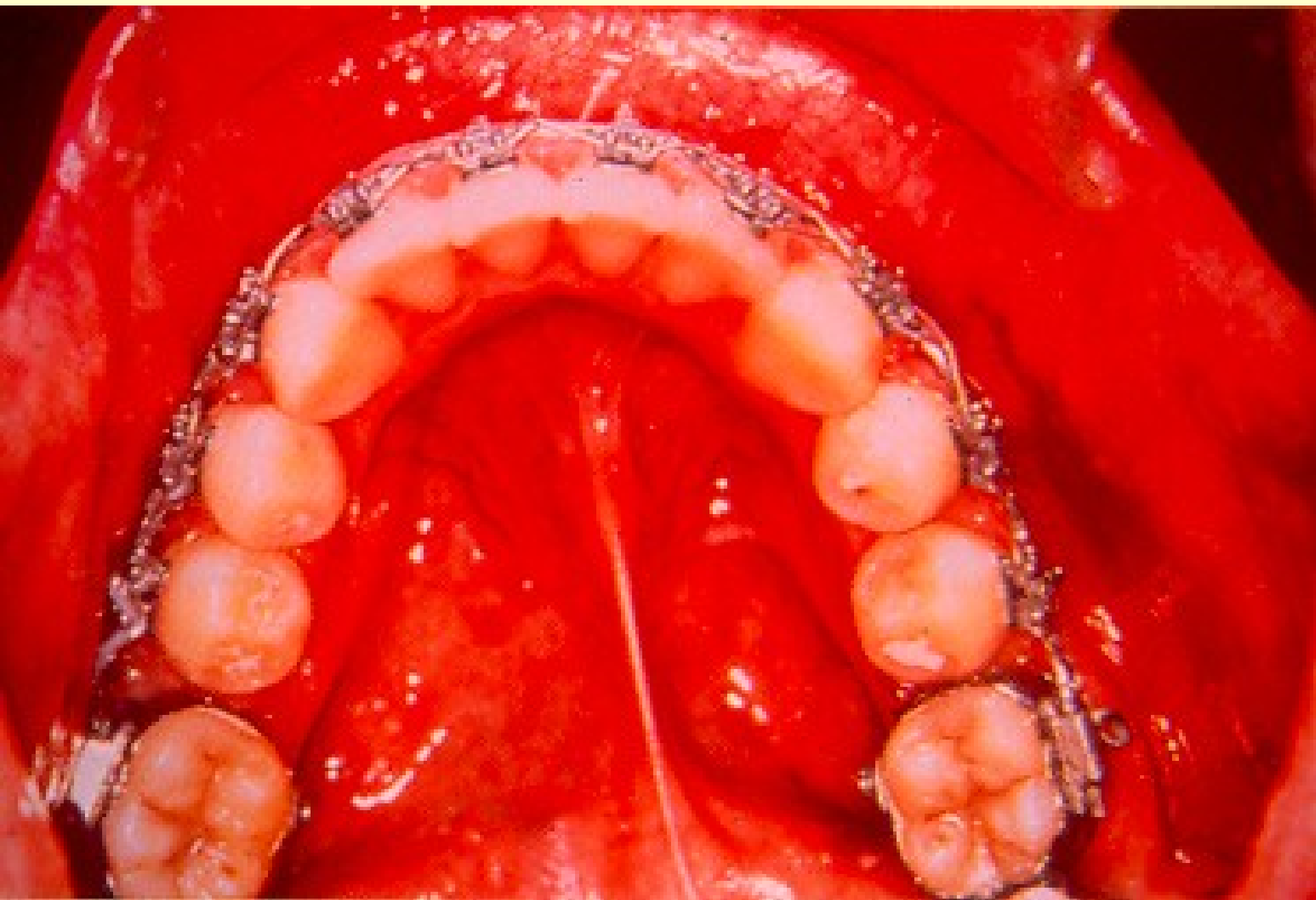
- Space opening (or space maintaining) for bridge or implantatum
- Correction of the tooth axis
- Treatment of crossbite of abutment teeth
- Alignment of impacted teeth
- Forced lengthening of the clinical crown (e. after accidents)
- Treatment of the consequences of parodontitis

Space closure

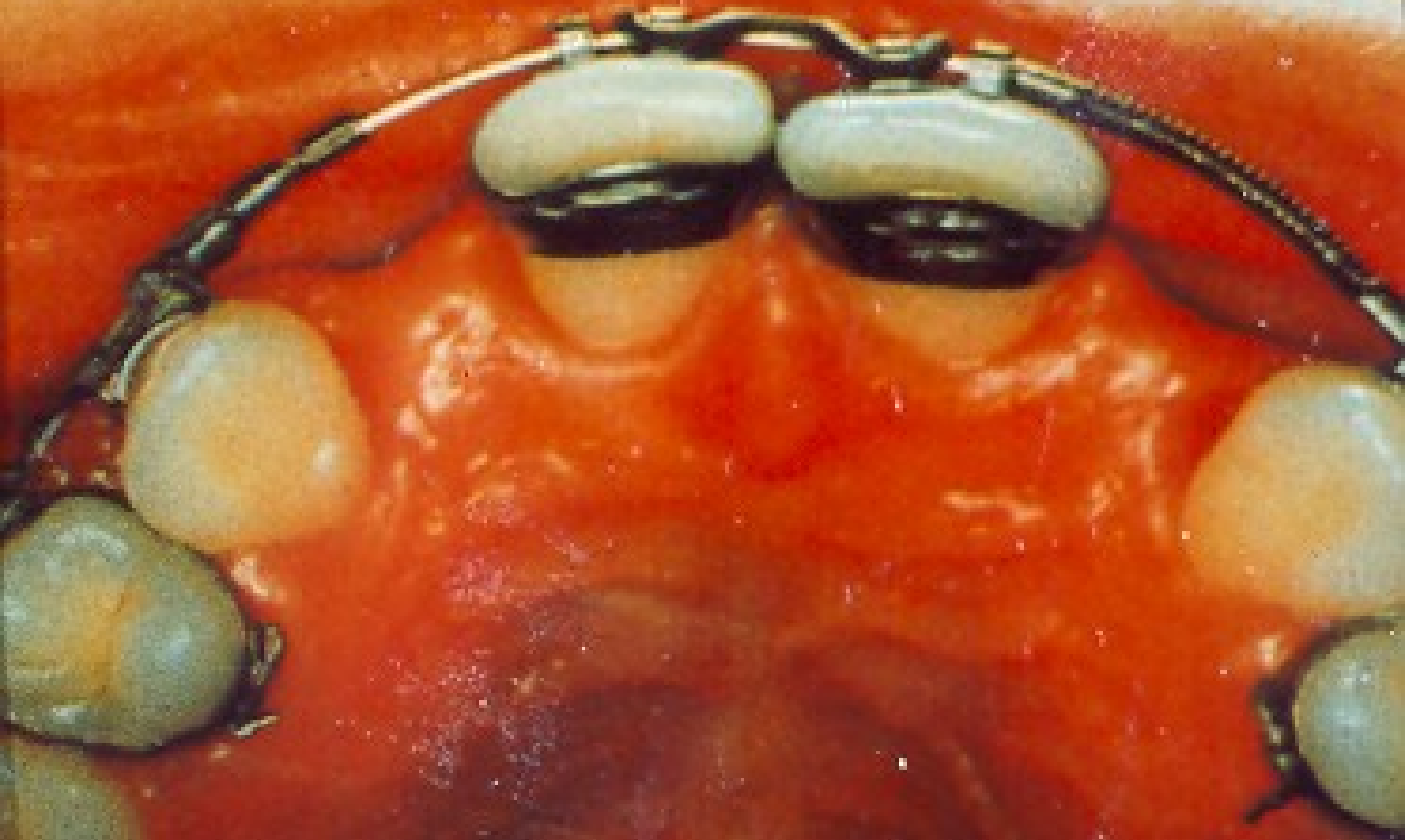
Case I

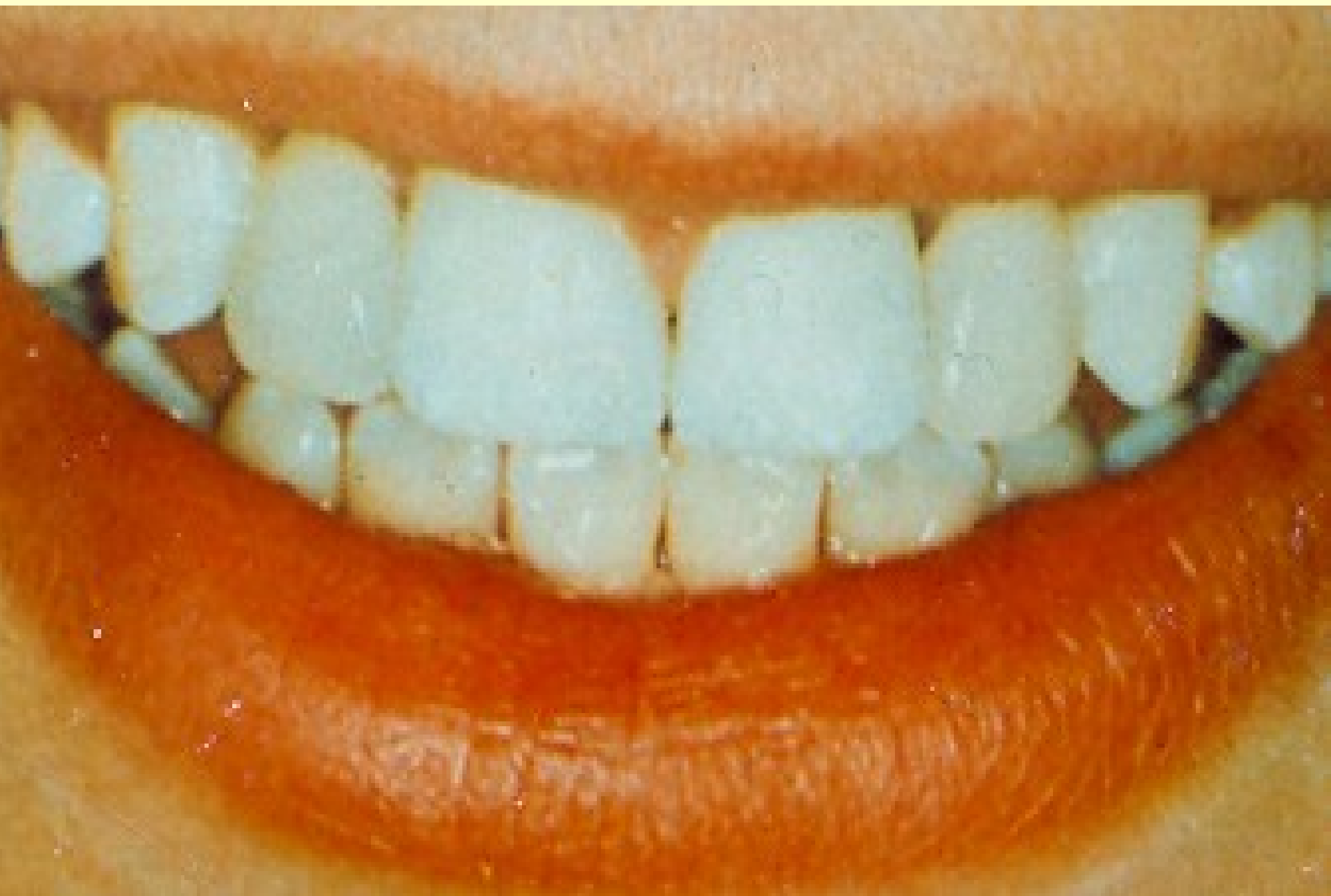

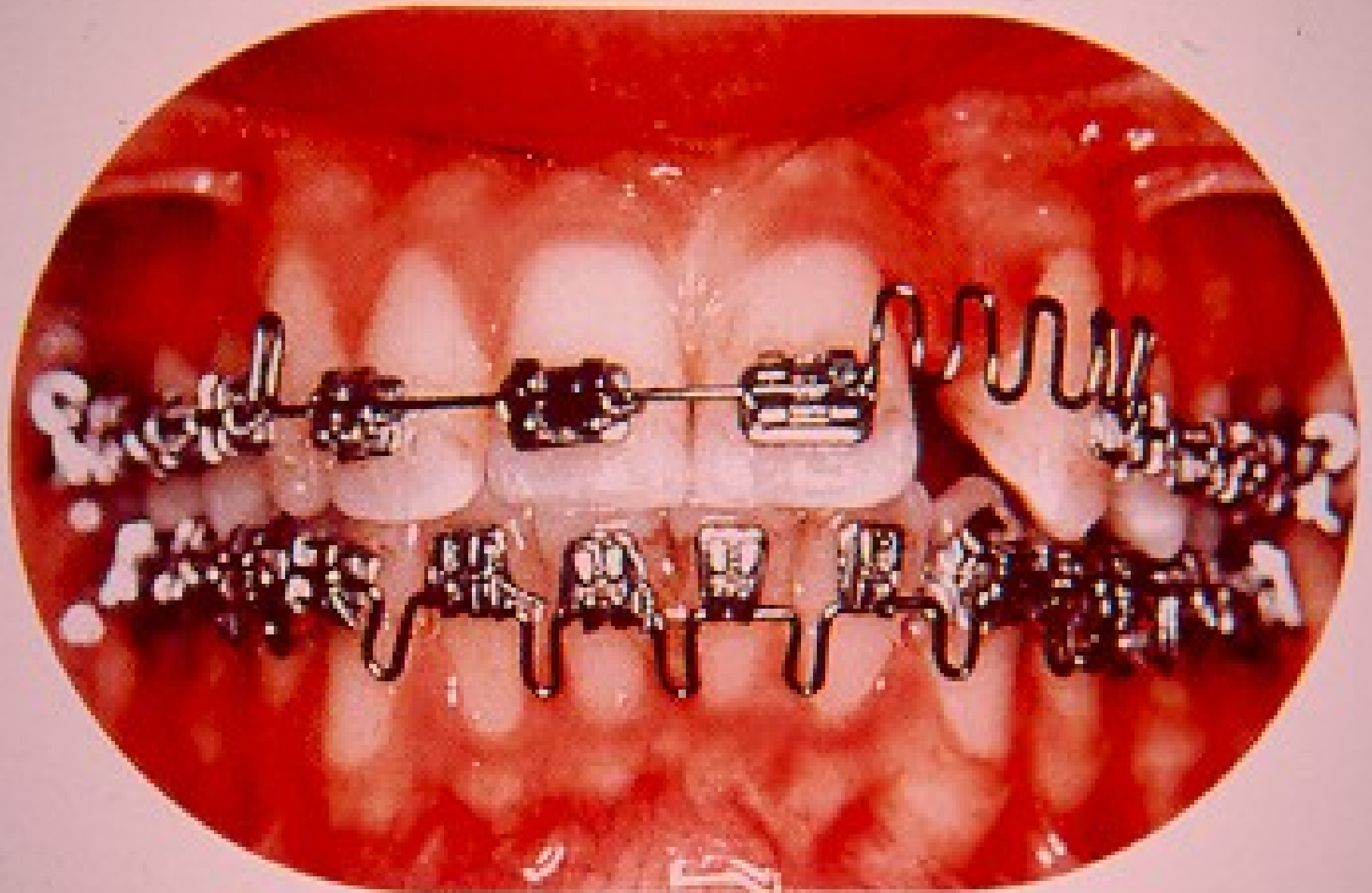



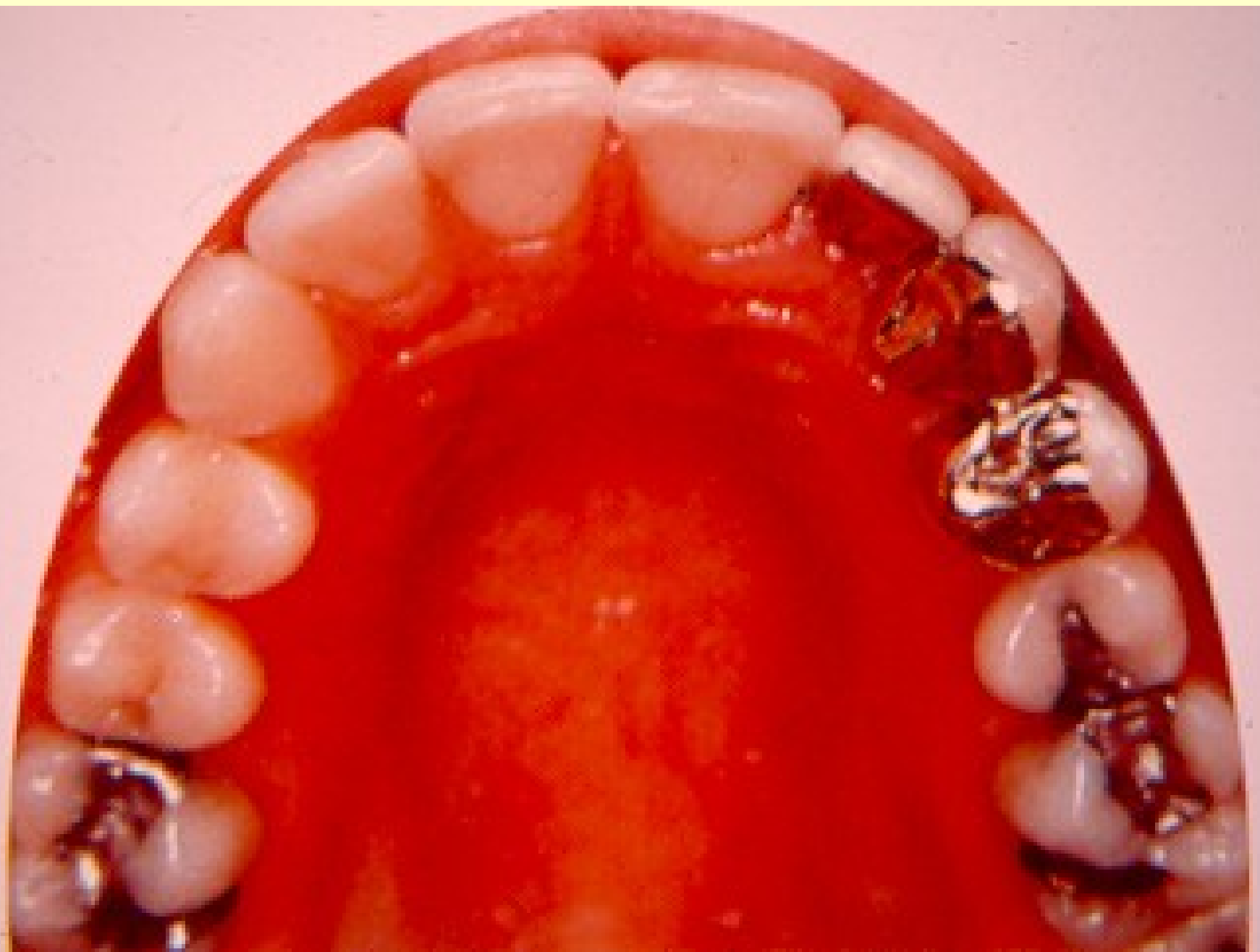
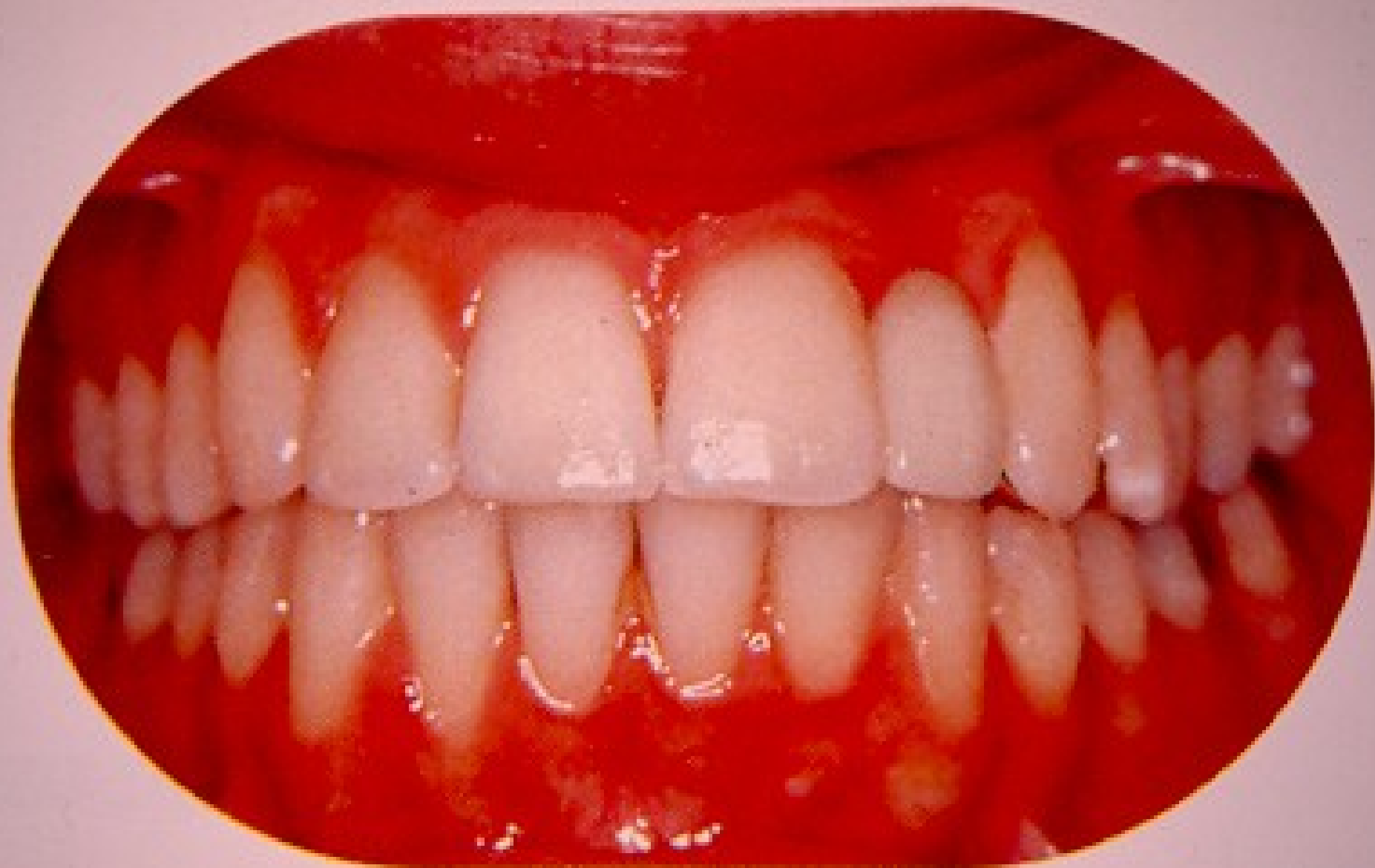Orthodontics and Prosthetic dentistry



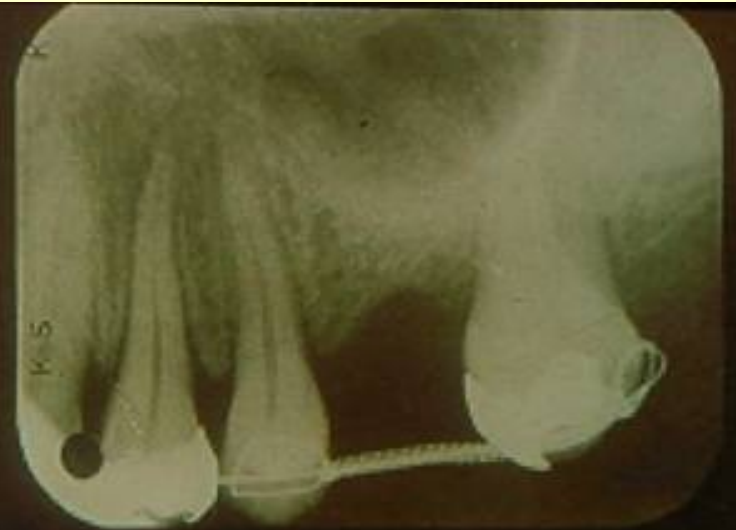
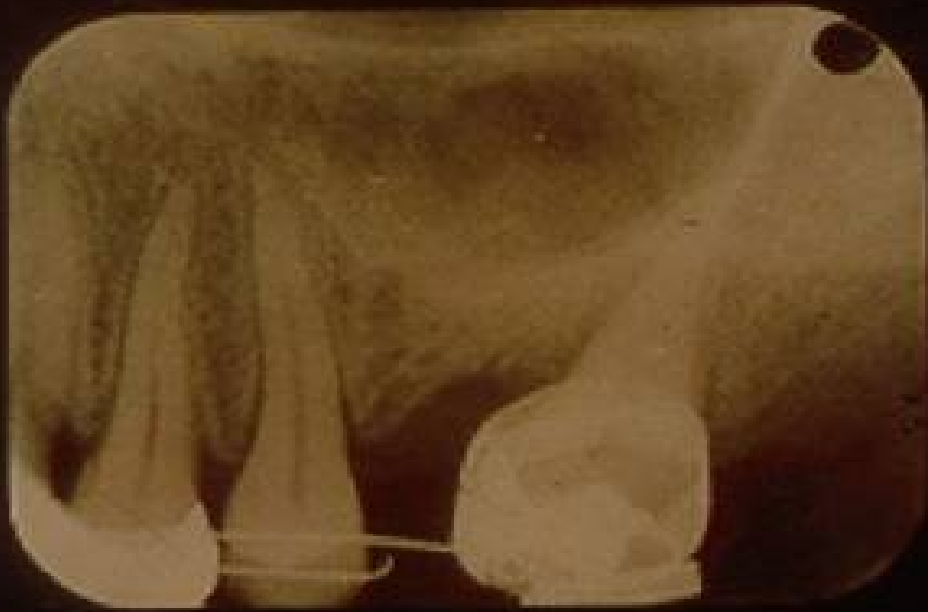


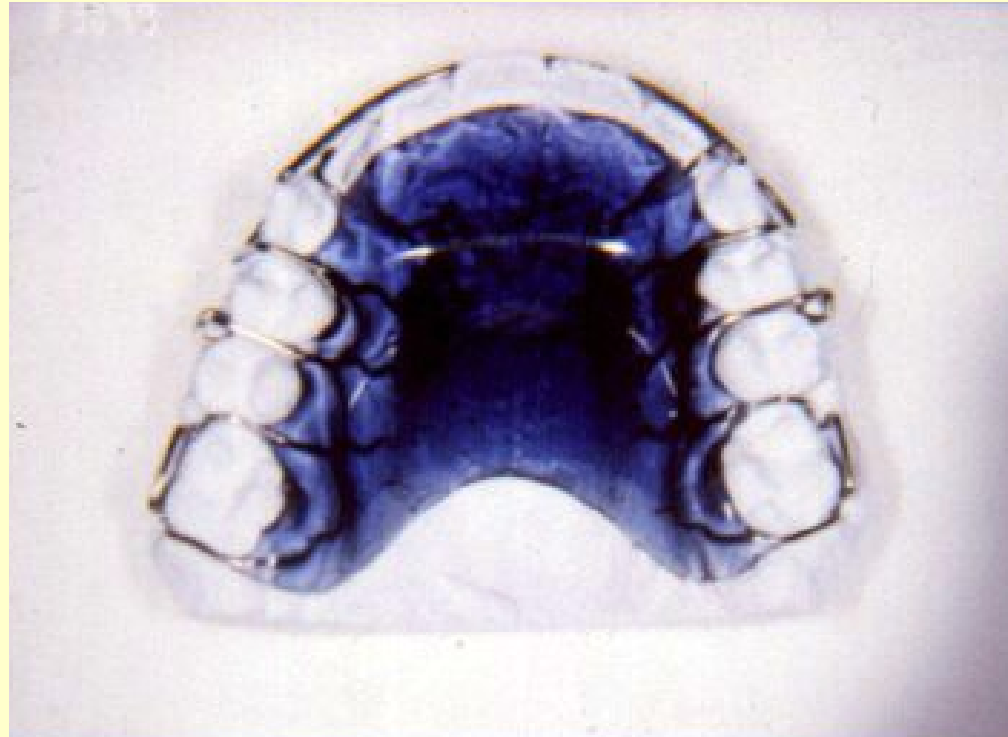




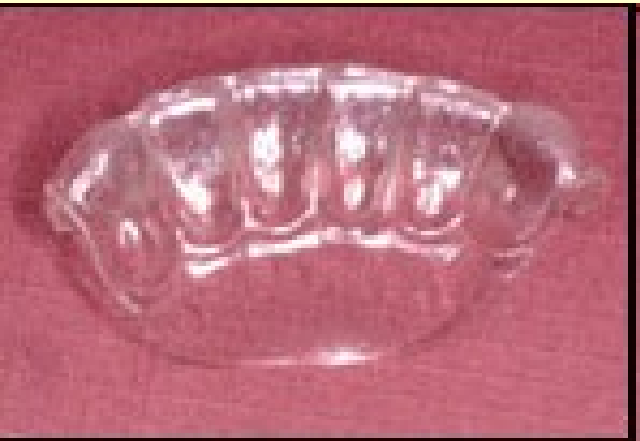Pillérfogak tengelykorrekciója



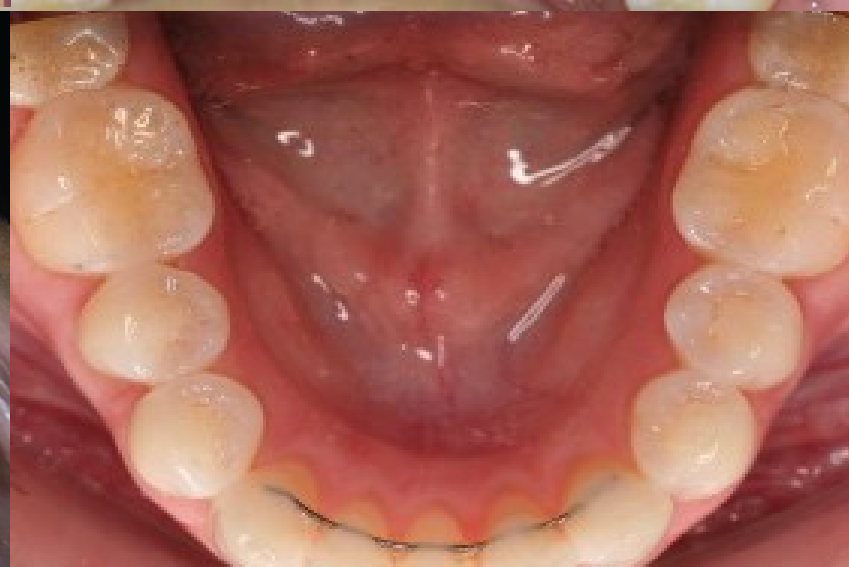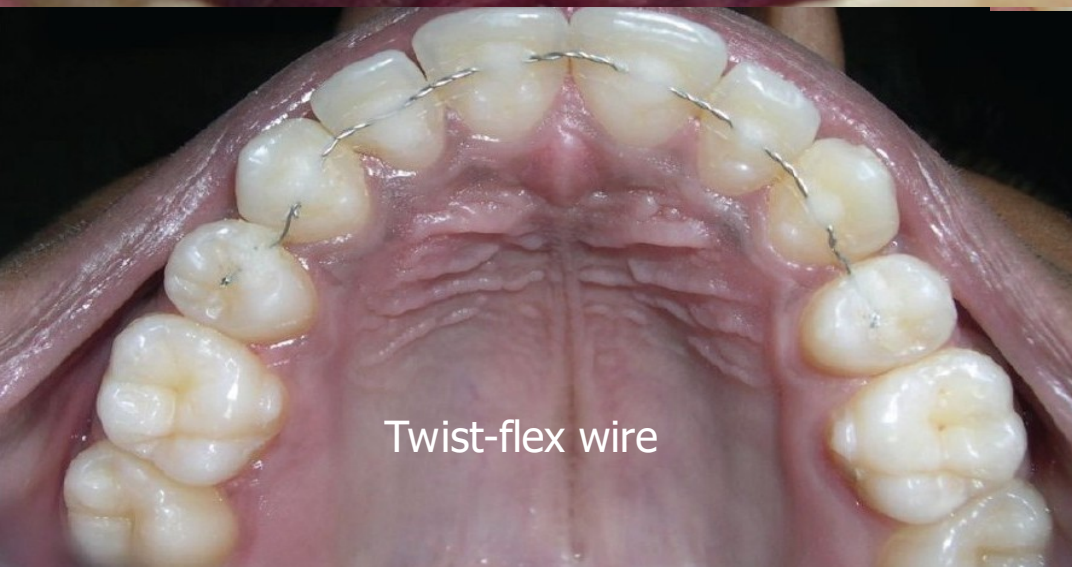
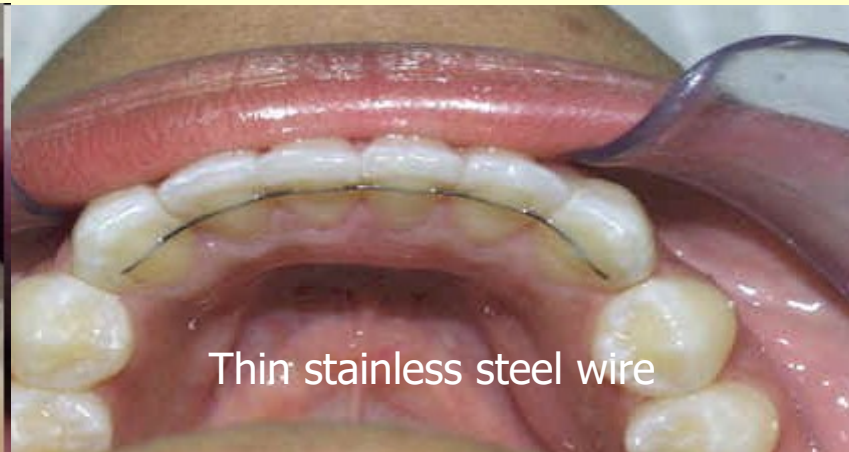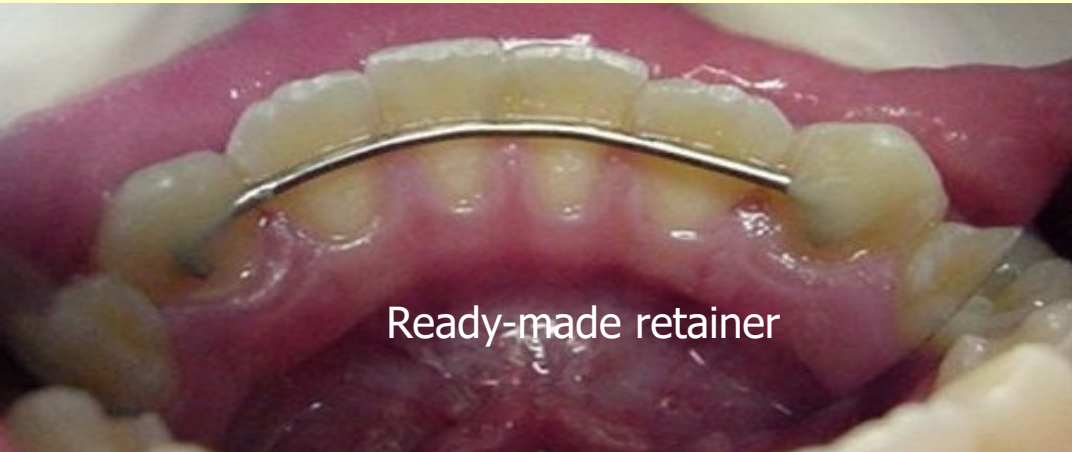Retention and relapse



Essix retainer



Fixed retainer



Thank you for your attention!

