

# PERIODONTOLOGY AND ORAL DISEASES IN CHILDHOOD

dr. Radó Zsuzsanna Stefánia, dr. Löchli Heike



SEMMELWEIS UNIVERSITY

Department of Paediatric Dentistry and Orthodontics

# Overview

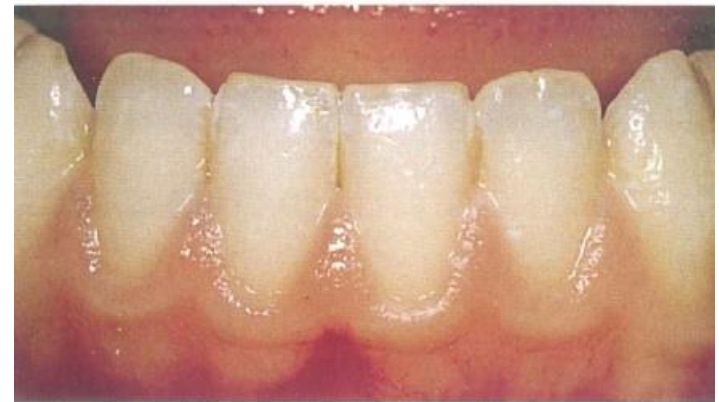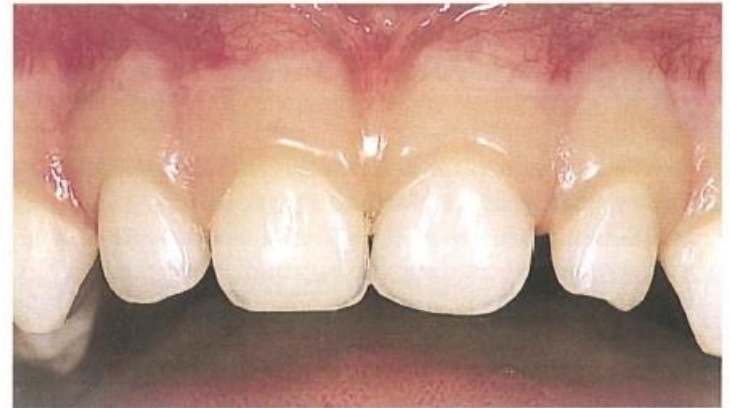- Normal periodontal conditions
- Gingivitis
- Periodontitis
- Prevention
- Gingival recession
- Traumatic ulcerative gingival lesions
- Developmental disturbances
  - Cleft patients
  - Ankyloglossia
- Anomalies of the tongue
  - Lingua geographica
  - Acute and chronic inflammation of the tongue
- Diseases of the lip (Cheilitis exfoliativa, granulomatosa, angularis)
- Diseases of viral origin (HSV, EBV, HIV, HPV)
- Fungal infections
- Recurring ulcerative lesions (RAU, RAS, Mikulicz, Sutton, Cooke)

Goran Koch , Sven Poulsen: Pediatric Dentistry: A Clinical Approach

Fábián G., Gábris K., Tarján I.: Gyermekfogászat, fogsabályozás és állcsont-ortopédia

# Normal periodontal conditions

- Primary dentition
  - Bulkier
  - Stippling develops gradually after the age of 2-3
  - Connective tissue is similar to permanent teeth but thicker junctional epithelium → more resistant to inflammation bc it is less permeable
- Permanent dentition
  - Healthy marginal gingiva becomes thinner and pinkish
  - Length of the junctional epithelium can be considerably longer → no need to probe routinely

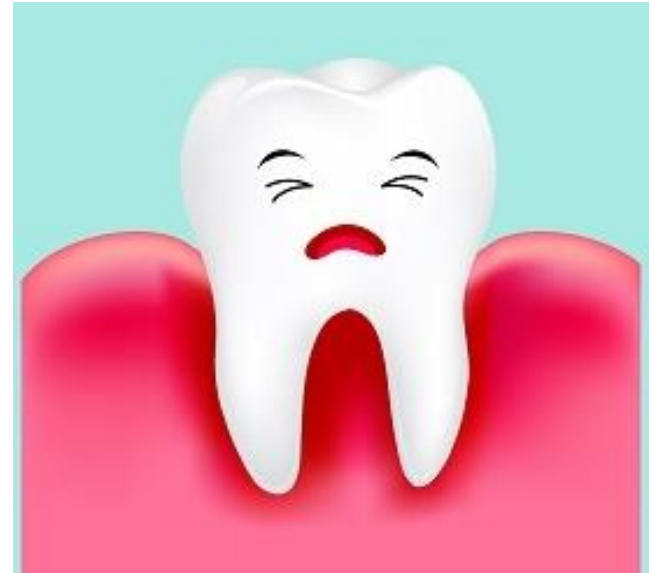

Goran Koch , Sven Poulsen: Pediatric Dentistry: A Clinical Approach

# GINGIVITIS

# Clinical appearance

- Hard to distinguish between normal and pathologic reactions
- If plaque accumulation is minimal and the defense mechanisms work well, there will be no clinical symptoms
- More pronounced plaque accumulation or defects in defense reactions will result in clinical symptoms
- Diagnosis based on clinical symptoms (GBI)
- In healthy children gingival infections remain superficial
- If a child has long standing generalized gingivitis general health should be checked



Vascular response and accumulation of inflammatory cells

- Reddish gingiva
- Swollen appearance
- Papillae protruding from the interproximal spaces
- Increased volume, shiny surface
- Crevicular exudation
- Increased tendency of bleeding on probing

# Age dependent tendency to develop gingivitis

- Preschool children are less susceptible than adolescents and adults
- Possible causes:
  - Spirochetes and black-pigmented bacteroides are less frequently found in children
  - Lower proportions of Fusobacterii, Eubacterii and Lactobacilli
  - Increased cell proliferation and turnover of collagene
  - Cellular infiltration is predominantly of T-lymphocytes (in adults it's B-s)
  - Lower permeability
  - Pubertal hormonal changes increase the risk



“I can't believe you'd accuse us of age discrimination. At your age, you ought to know better.”

# Etiology of gingivitis

- Unanimous agreement: **microbial plaque**

→ Quantity of bacteria and bacterial products

- BUT must be regarded as **multifactorial** disease with intrinsic and extrinsic factors

- Disturbances in enamel mineralization  
→ rough surface

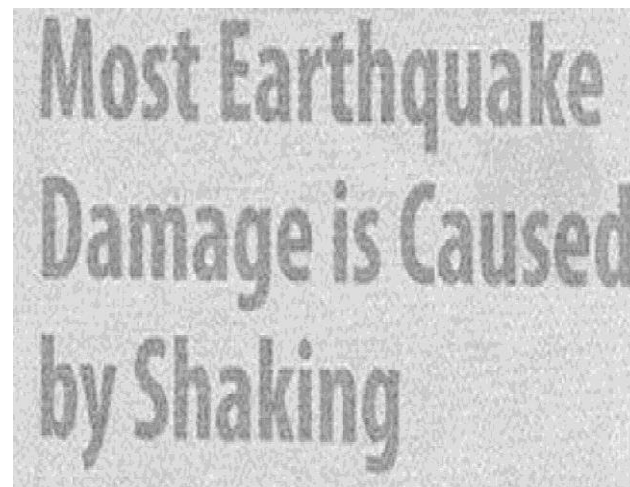
- Manifest carious lesions

- Cervical carious lesions are almost always accompanied with chronic gingivitis

- Restoration with defective margins/rough surfaces; braces

- MALOCCLUSIONS are not dominant → depends on oral hygiene

- Systematic factors



# Factors modifying gingivitis I.

- Mouth breathing
- Hormonal changes  
(puberty gingivitis)
- Eruption gingivitis
  - Gingival response is often out of proportion to the degree of bacterial irritation
  - Epithelium displays degenerative changes
  - Cleaning is unpleasant



# Diabetes mellitus

(Factors modifying gingivitis II.)

- More susceptible to develop periodontal diseases
- Tendency to develop chronic forms is higher
- Specially poorly controlled DM

# Leukemia

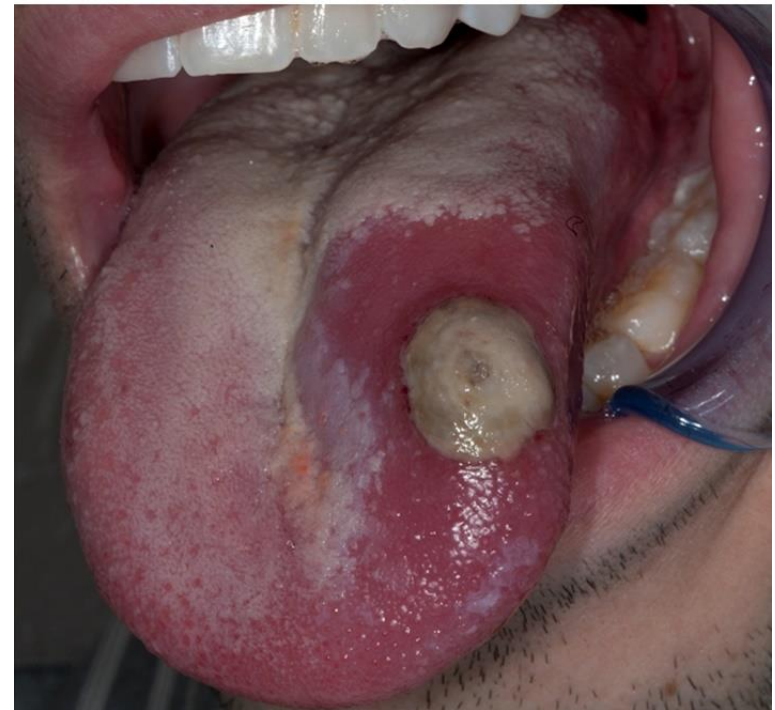(Factors modifying gingivitis III.)

- Most common form during childhood: acute lymphoblastic leukemia
- Often accompanied by severe oral symptoms
- Gingival margins are soft and swollen from the infiltration
- Cytotoxic treatments
- Drug interference with the replication of epithelial cells
- Plaque control before the start of cytotoxic treatment!

# Agranulocytosis

(Factors modifying gingivitis IV.)

- Malignant type of neutropenia
- Acute and very severe condition
- Etiology: drug induced or autoimmune
- Oral ulcerations and peridontal manifestations are common
- In chronic cases the gingiva becomes hyperplastic with granulomatous changes



Kurago, Z B et al. "Clinical pathologic conference case 5: agranulocytosis" *Head and neck pathology* vol. 5,3 (2011): 286-91.

# Heart conditions

(Factors modifying gingivitis V.)

- Severity of oral manifestations is directly proportional to the cyanosis
- Bluish-red gingiva
- Sometimes antibiotic prophylaxis is indicated

# Drug-induced gingival overgrowth

- Calcium channel blockers (nifedipine)
- Immunosuppressives (cyclosporinA)
- Anticonvulsants (phenytoin)
  - Overgrowth occurs more frequently in children than in adults
  - Plaquecontrol program before start of therapy!!!!
- Pseudopockets (over 4mm)
- Altered tissue composition: more glycosaminoglycans

# Non-plaque-induced gingival lesions

- Specific bacterial origin:

*Neisseria gonorrhoea*, *Treponema pallidum*, *Actinomyces israelii*,  
*Mycobacterium tuberculosis*, *Streptococcus*

- Viral origin:

Herpes simplex 1-2 (primary herpetic gingivostomatitis, recurrent oral herpes,  
Varicella-zoster, HPV)

- Fungal origin

- Gingival manifestation of systematic conditions – desquamative gingivitis:

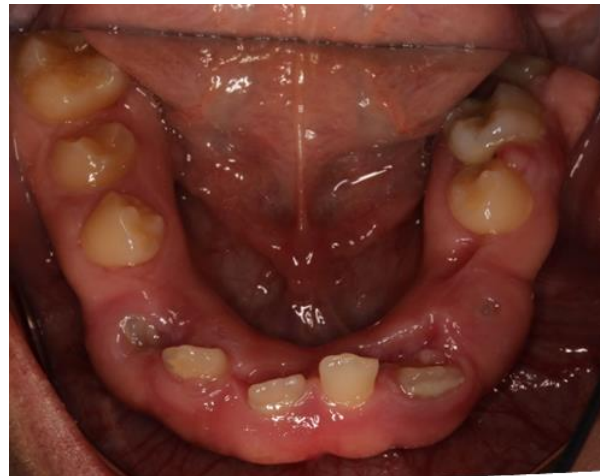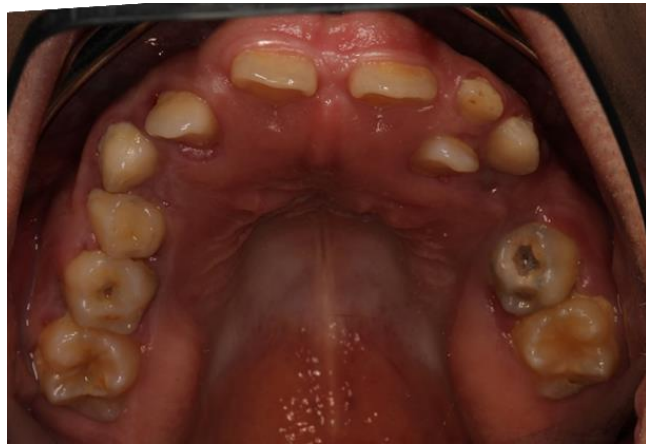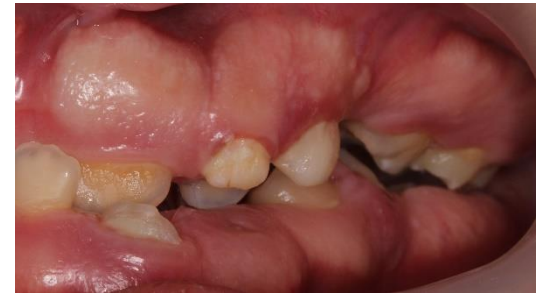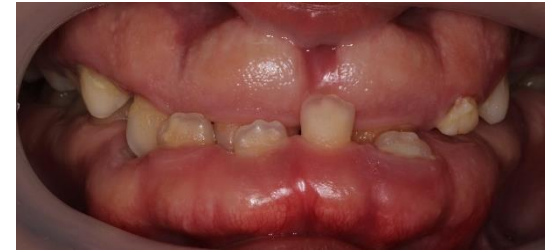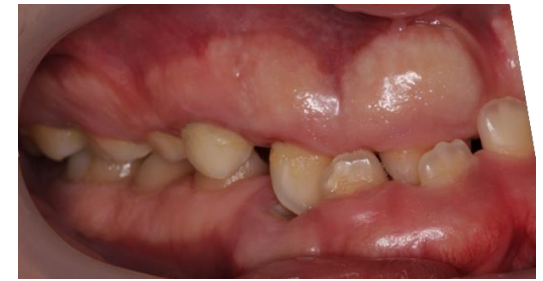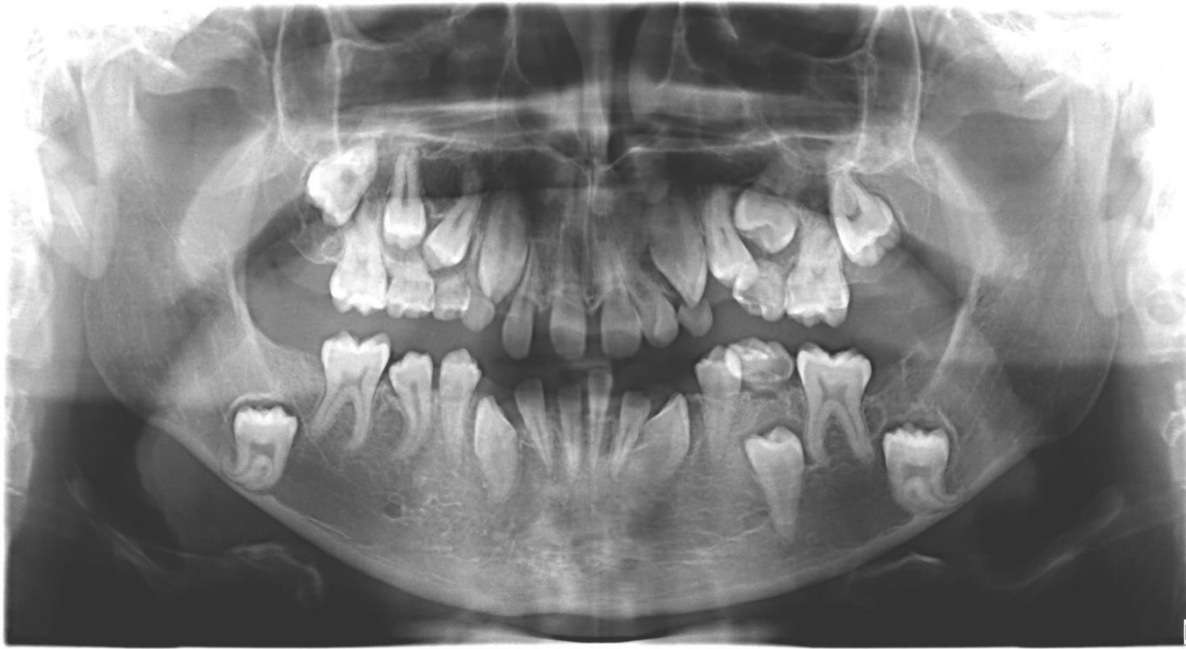
lichen planus, pemphigoid, pemphigus vulgaris, erythema multiforme...

- Genetic origin: hereditary gingival fibromatosis

# Gingival fibromatosis

=diffuse, non inflammatory  
gingival enlargement

- Autosomally inherited
- Generalized/localized
- Retarded eruption
- Enlargement is pale and very firm



Patient of Semmelweis University Dept of  
Pediatric Dentistry and Orthodontics  
Documented by dr Szilvia Baksa



# Gingivitis treatment

- Marginal gingivitis
  - Plaque control  
(parents in preschool children,  
modified Bass technique with  
soft brush)
- Severe forms of gingivitis
  - Professional tooth cleaning  
(potentially in local anesthesia)
  - Chemical plaque control
  - Education

# PERIODONTITIS

# Clinical picture

- Ongoing inflammatory process involving deeper parts of the periodontium with loss of tooth support
- Histological appearance of inflammation is different
  - Larger proportion of plasma cells and B-lymphocytes (↔gingiv.)
- Few subjective symptoms

→ Clinical diagnosis based on

- probing depth
- attachment loss
- marginal bone assessed on radiographs

→ evaluation of the inflammatory status

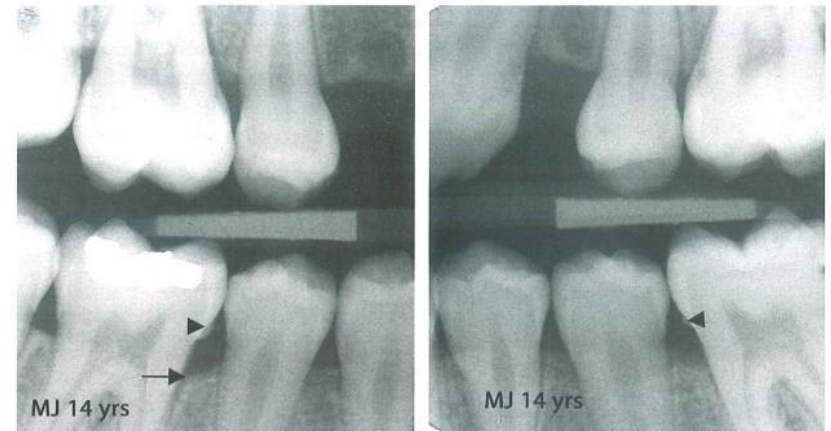- Bleeding on probing
- Subgingival calculus

# Classification

1. Early, chronic periodontitis with minimal attachment loss (stage I, grade A)
2. Localized, rapid (stage I, grade C)
3. Generalized, rapid (stage III-IV, grade C)
4. Juvenile necrotizing periodontitis
5. Periodontitis associated with systematic diseases and genetic factors

# Early, chronic periodontitis with minimal attachment loss (stage I, grade A)

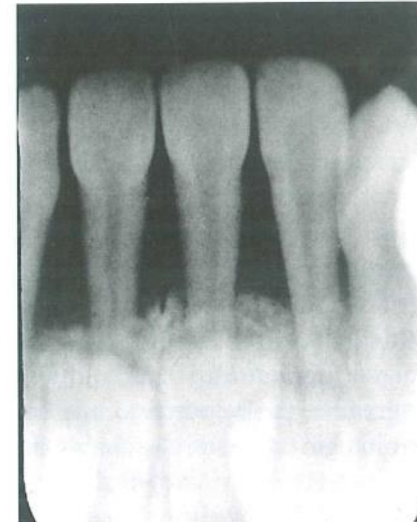- Minor loss of periodontal support
- Slow progression rate
- Considerable plaque accumulation
- Can be of local origin (trauma, development)
- Mostly in late adolescent patients
- May represent initial stage of progressive periodontal disease



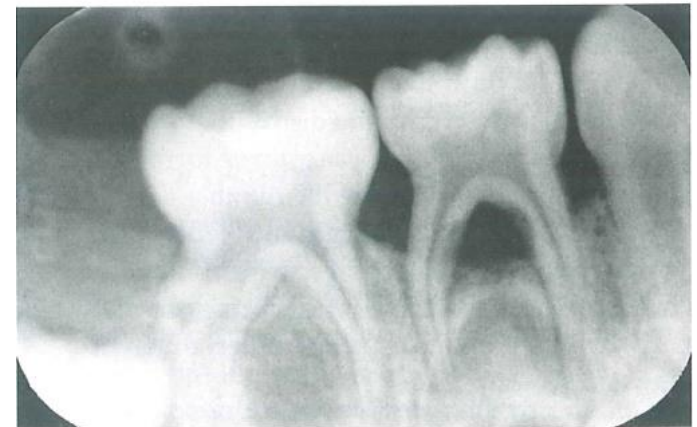Goran Koch , Sven Poulsen: Pediatric Dentistry: A Clinical Approach

# Localized (stage I-II, grade C) and generalized (stage III-IV, grade C) rapid periodontitis

- No strict definition on level of attachment loss or number of teeth involved
- Prevalence less than 0,5%
- Most cases show localized lesions with moderate signs of inflammation
- Generalized forms are often associated with systemic diseases
  - underlying cause examination by pediatrician
  - destruction starts early after eruption and may lead to premature loss of teeth

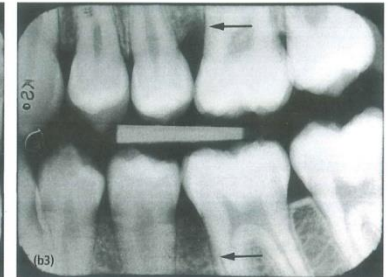
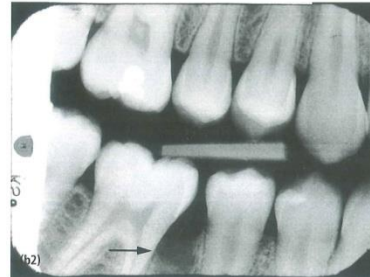
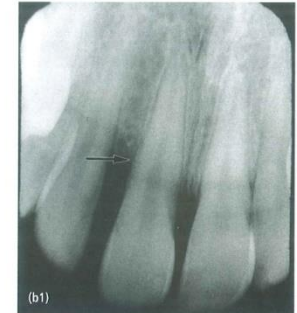
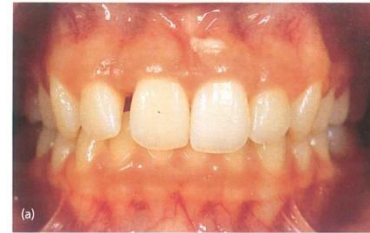
Goran Koch , Sven Poulsen: Pediatric Dentistry: A Clinical Approach



# Localized (stage I-II, grade C) and generalized (stage III-IV, grade C) rapid periodontitis

- Onset in early permanent dentition
- Amount of plaque is not in accordance with the severity attachment loss
- Often preceded by bone loss in primary dentition
- Localized: first molars and incisors
  - Radiographs show vertical or arch-shaped pattern of bone loss
- Generalized form
  - At least 3 teeth that are not molars or incisors
  - Severe inflammation
  - Usually in association with systematic diseases/ genetic disorders



Goran Koch , Sven Poulsen: Pediatric Dentistry: A Clinical Approach

Systematic use of bitewing radiographs (caries diagnosis) may help identify patients → early treatment

# Etiology and risk factors-Microbiology

- Localized: *Aggregatibacter actinomycetemcomitans*
  - Leukotoxin
  - Cytolethal-distending toxin reduces the content of collagen in tissues
  - Capacity to invade periodontal tissue
  - Variation of virulence between different clones
- Generalized:
  - *A.actinomycetemcomitans*
  - *Porohyromonas gingivalis*
  - *Prevotella intermedia*

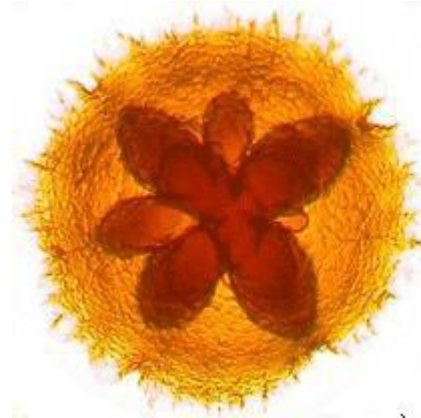



Image of *Aggregatibacter actinomycetemcomitans* colony grown on selective agar from UCL Eastman Dental Institute

*P. gingivalis* colonies grown on blood agar. Heme from the media is oxidized by the bacteria to produce hemin which accumulates on the cell surface producing a characteristic black pigment after about 7 days of anaerobic incubation.



→ Periodontitis is a polyinfection with varying efficiency of the host response



# Etiology and risk factors

## – Host-defense factors

- Polymorphonuclear neutrophil cells (PMNcells)
  - Abnormalities of adherence, chemotaxis, phagocytosis, bactericidal activity
  - Defect chemotaxis mainly in African-Americans
- Serum Immunoglobulin G levels high (particularly to AA)

# Genetic factors and ethnicity

- Markedly increased incidence within families
- AD, AR, X-linked
- 8-63% of near relatives have severe periodontitis too
- Black or Hispanic adolescents 5-15x compared to caucasians



**"Your weight problem is partly genetic and partly Boston Cream pie."**

# Etiology and risks-Modifying factors

- Restorations, manifest caries
- Ectopic eruption
- Obesity (inflammatory molecules)
- Smoking
  - Vasoconstrictor effect → anaerob colonization
  - Substances affect fibroblasts and inflammatory cells
  - Passive smoking decreases protective LL37-protein

# Necrotizing periodontal diseases (NG)

Acute necrotizing ulcerative gingivitis (ANUG) → ANUP

- Rapid onset
- Painful necrotic ulcerative gingival lesions
- Affected interdental papillae
- Foetor ex ore
- Mostly seen in children suffering malnutrition/ immunodeficiency/ stress factors/ smoking
- Professional plaque removal
- Mouthrinsing with 0,5% hydrogenperoxid or 0,1%chlorhexidine
- Antibiotics in cases of non-response to the above

# Systemic diseases and syndromes connected to periodontal disease

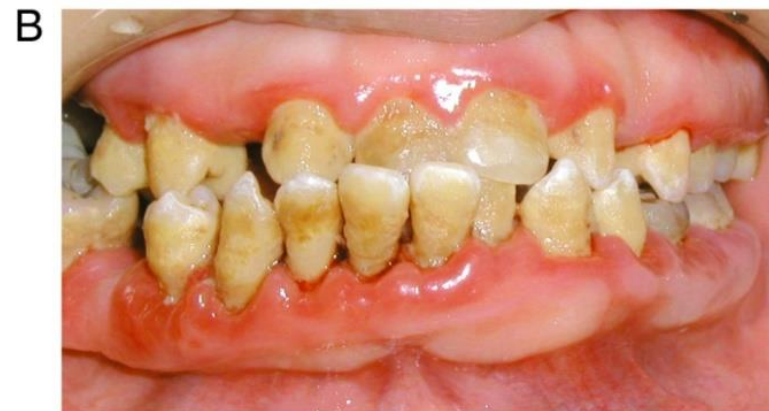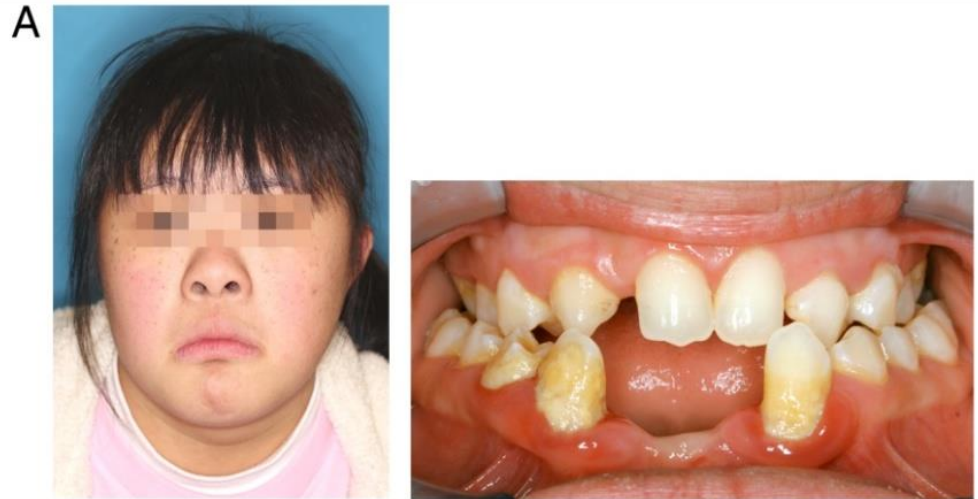- Diseases influencing the periodontal inflammation (immune response, tissue development): agranulocytosis, leukaemia, congenital diseases (neutropenia, lazy leukocyte syndrome, PLS, Down, hypophosphatasia, EDS)
- Systemic diseases/factors modifying the pathogenesis of periodontitis: DM, obesity, smoking
- Diseases causing direct tissue destruction: Langerhans cell histiocytosis

# Down syndrome

- Marginal bone loss
- Severe in the anterior segment, especially mandible
- Impaired phagocytic function, quantity
- Increased MMP-8
- Poor oral hygiene

Picture source:

<https://www.intechopen.com/books/prenatal-diagnosis-and-screening-for-down-syndrome/oral-health-in-individuals-with-down-syndrome>



# Hypophosphatasia

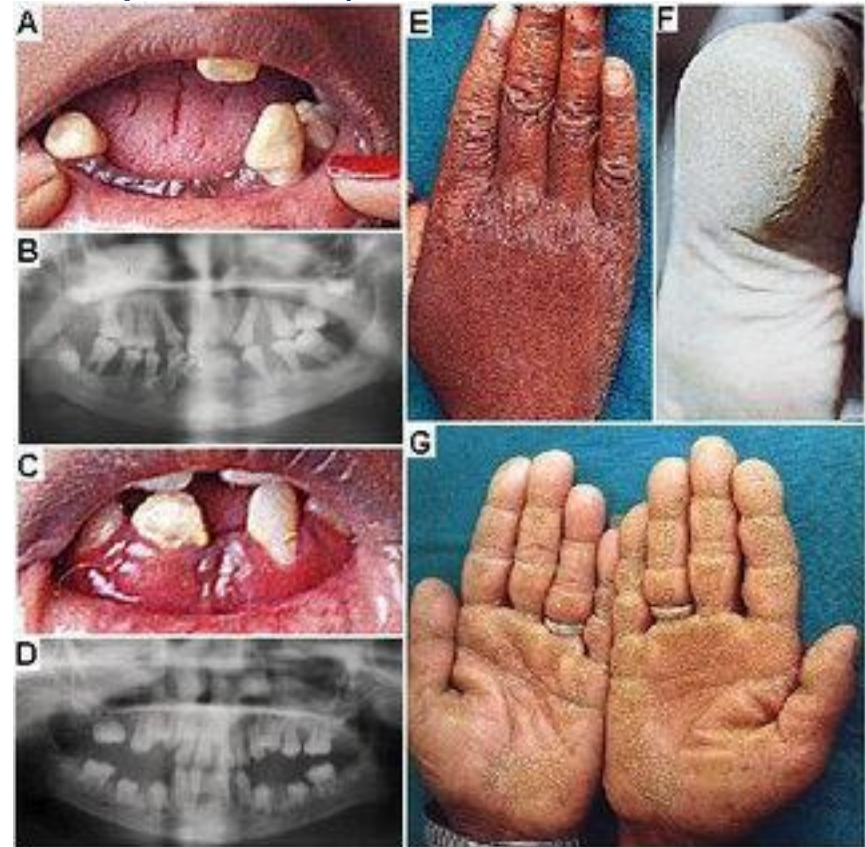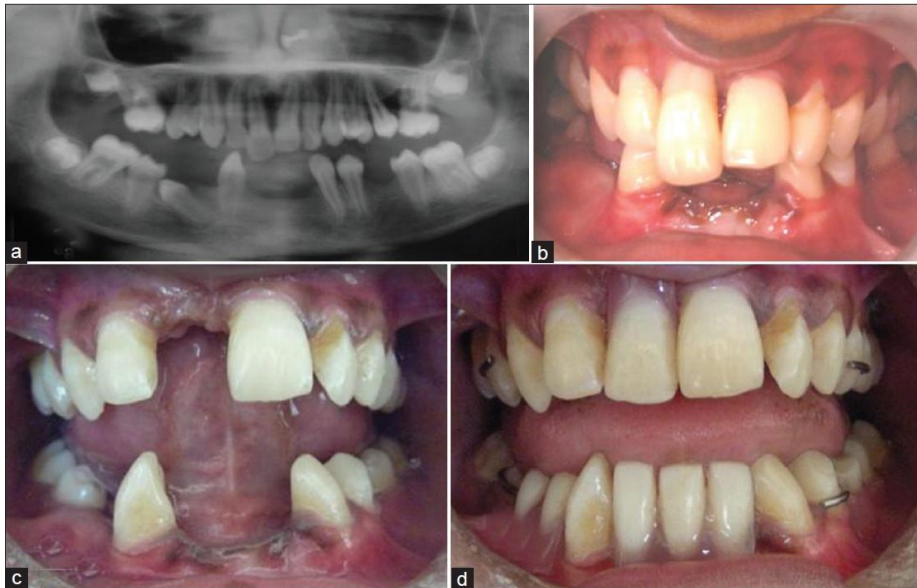
- Low serum alkaline phosphatase
- Ricket-like skeletal changes
- Loss of alveolar bone, early tooth loss
- Anterior primary teeth
  - Aplasia and hypoplasia of root cementum
  - Large pulp chambers



# Papillon-Lefevre syndrome

(keratosis palmaris et plantaris)

- Fulminant types of periodontitis with rapid bone destruction (cathepsin C nonfunction)



<http://www.jidonline.com/article.asp?issn=2229-5194;year=2012;volume=2;issue=2;page=122;epage=127;aulast=Anehosur>  
CASE REPORT Year : 2012 | Volume : 2 | Issue : 2 | Page : 122-127/Rehabilitation of three siblings with Papillon-Lefevre syndrome

Gouri V Anehosur<sup>1</sup>, Harikishore Bhat<sup>2</sup>, Ramesh K Nadiger<sup>3</sup>, Venkatesh S Anehosur<sup>4</sup>

<sup>1</sup> Department of Prosthodontics and Geriatric Dentistry, SDM College of Dental Sciences & Hospital, Sattur, Dharwad, India

<sup>2</sup> Department of Oral and Maxillofacial Surgery, Sri Sai College of Dental Surgery, Opp. Shiv Sagar, Kothrepally, Vikarabad, India

<sup>3</sup> Department of Prosthodontics, SDM College of Dental Sciences & Hospital, Sattur, Dharwad, India

<sup>4</sup> Department of Oral and Maxillofacial Surgery, SDM College of Dental Sciences & Hospital, Sattur, Dharwad, India

Date of Web Publication-4-Sep-2012



# Histiocytosis-X (reticuloendotheliosis)

- Eosinophilic granuloma in bone → more frequent in mandible than maxilla
- Hand-Schüller-Christian disease (→ disseminated form)
- Treatment of the disease (steroids, irradiation, cytostatics) produce secondary negative effects

# Screening

- Organized dental health care helps a lot
- Full mouth probing is debated  
→ partial periodontal probing → first molars
- Radiographic analysis of marginal bone level
- More thorough examination in risk groups



# Treatment

## Initial therapy

- Plaque control
- Professional scaling
- Root planning
- Systemically administered antibiotics (aggressive P)  
→ successful outcome has been reported without it

## Reevaluation

- 4-6 weeks after scaling and root planning

## Regular maintenance

- Subgingival sampling
- Extraction of severely affected primary teeth
- Surgery in adolescents

# Prevention

## Mechanical plaque control

- Parents have to brush their children's teeth
- Modified Bass technique
- Toothbrush: small, soft, big handle
- Quality is more important than quantity

(Chemical plaque control)

# Gingival recessions

- Localized GR in 10-15% of teenagers
- Labial and irregular position of teeth, traumatic brushing
- History of orthodontic therapy
- Poor plaque control
- Therapy: underlying cause

# Traumatic ulcerative gingival lesions

- Bacterial superinfection of traumatized gingival tissue
- Morsicatio buccae
- Infection is caused by the normal mixed flora of the oral cavity
- Ddg: HSV infection and ANUG
  - no affection of the papillae
  - localisation

2nd part 😊

# ORAL DISEASES IN CHILDHOOD

# Developmental problems



# Cleft lips and palate

# Ankyloglossia

- Impairment of speech
- Different levels of restriction
- Surgical treatment

# Anomalies of the tongue

# Lingua geographica (glossitis migrans)

- Smooth redish areas without papillae
- Borders are white and curly – hence the name
- Often hereditary
- Depapillated areas can be painful

# Acute and chronic inflammation of the tongue

Acute inflammation usually accompanies some general infectious disease

- scarlet fever  
(strawberry tongue)
- Herpetiform stomatitis

Chronic inflammation

Anaemia perniciosa

Candidiasis

- Tongue becomes red and smooth “mirrortongue”

# Diseases of the lip

# Cheilitis exfoliativa

## Cheilitis exfoliativa

- Due to exsiccation of the lip (fever) or to chewing on lip
- The lip is bright red, exfoliates, cracks and bleeds
- Possible superinfection

## Cheilitis acuta

- Sunburn, wind, allergy etc

Treatment: coating and moisturizing

# Cheilitis granulomatosa

- Isolated symptom or part of Melkersson-Rosenthal syndrome
- Painless granulomatous enlargement of lips
- Can be regressing and recurring



# Cheilitis angularis/angulus infectiosus

- Usually starts with a sense of dryness, then exfoliation, then cracking of the corners of the mouth
- Very painful
- Etiology: SLS allergy, fungal infections + vitamin B deficiency

# Diseases of viral origin

# Herpes simplex virus (HSV)

- Herpetic gingivostomatitis
- Gingivostomatitis herpetica et ulcerosa → bacterial superinfections
- Herpes simplex

# Herpangina

- CoxsackievirusA
- Sudden fever with sore throat
- 1-2 mm diameter grayish lumps form and develop into vesicles with red surrounding
- Over 24 hours they become shallow ulcers
- Vesicles typically found on the posterior oropharynx

# Mononucleosis infectiosa

Aka. Glandular fever

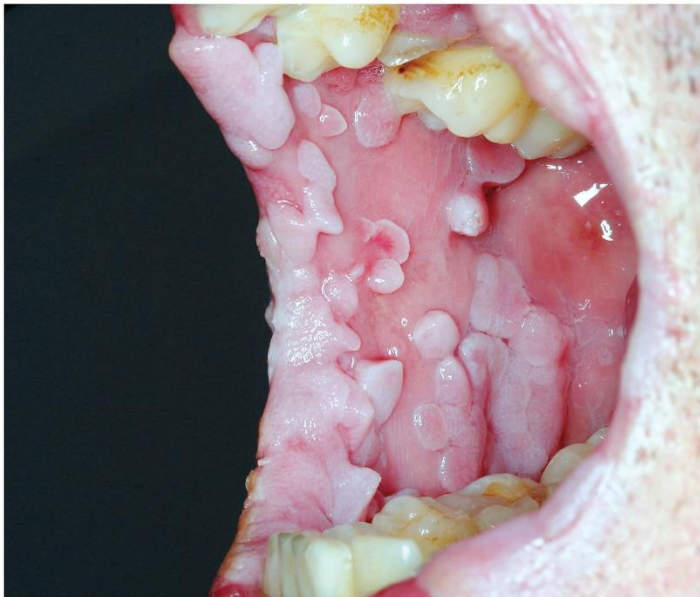
Epstein-Barr virus

- Infection in childhood produces milder symptoms
- In young adults it causes fever, sore throat, enlarged lymph nodes
- Spontaneous recovery within 2-4 weeks

# HIV

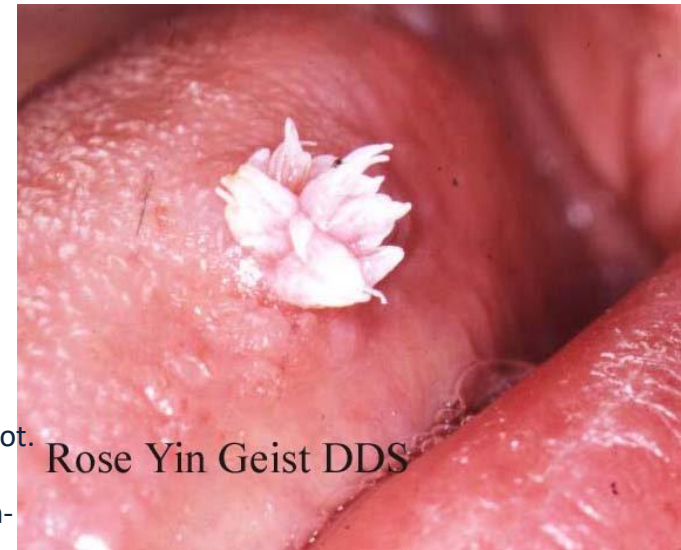
- Infection from mother during birth or through breastfeeding
- Well controlled HIV doesn't produce symptoms
- Known HIV+ doesn't pose risks since medicated individuals have low virus count and are not contagious
- Unknow disease represents the real threat
- Virus has a low virulence

# HPV

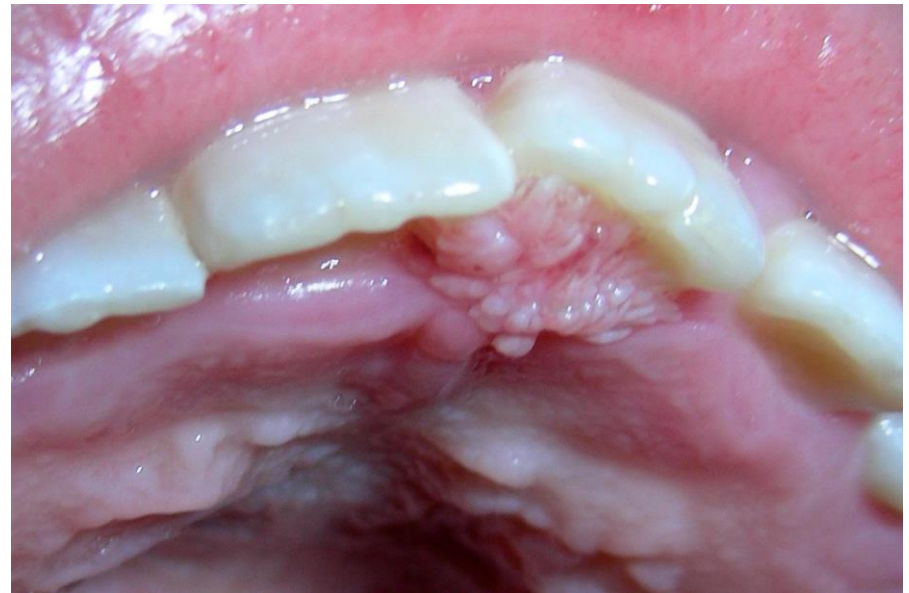

Limeres Posse J, Scully C. IMAGES IN CLINICAL MEDICINE. Oral HPV-Associated Papillomatosis in AIDS. N Engl J Med. 2016 Jun 30;374(26):2585. doi: 10.1056/NEJMicm1512047. PubMed PMID: 27355537.

Source:  
<http://oralmaxillofacialsurgery.blogspot.com/2010/05/viral-infections-of-mouth-cont-2.html>



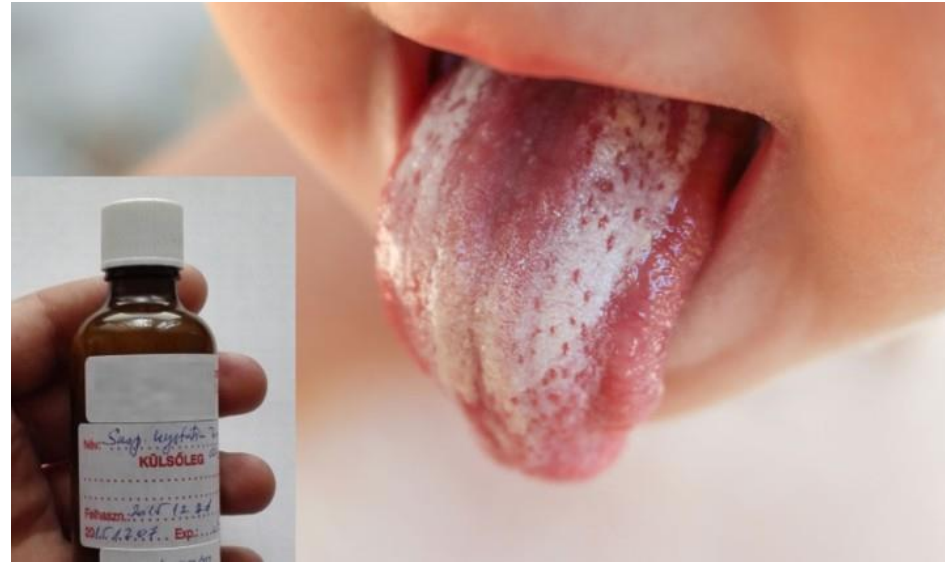Rose Yin Geist DDS



# Fungal infections

## Candida albicans

- Is part of normal oral flora and only invades mucosa if there is some change in the immunological or humoral environment (antibiotics or immunosuppressives)
  - Pseudomembranous candidiasis (thrush)
    - Common disease in newborns and children with chronic disease
    - Raised pearly white patches that can be rubbed off, leaving an erythematous or bleeding mucosa surface
    - Treatment: antifungal medication (nystatin, miconazole) systemically or topically applied



<https://www.novakhunor.hu/betegsegek/szajpenesz-kezelese-zacher-gabor-szerint-sem-ajanlott-a-borax-glicerin-eletveszelyes-is-lehet>



# Recurring ulcerative lesions

Benign and non-contagious ulcers in otherwise healthy individuals

→ multiple, erythematous, recurrent, small, round or ovoid ulcers with circumscribed margins, typically presenting first in childhood or adolescence

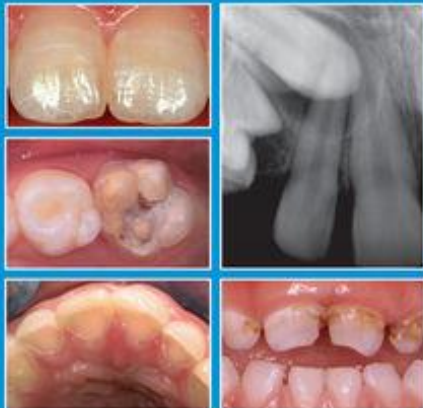- Mikulicz aphta – most common
  - Separate multiple ulcers 1-2 mm diameter
- Recurrent aphthous ulcer major (Sutton)
  - Typically single and 2-3 cm, may cause scarring
- Cook aphta
  - Multiple small lesions in groups, very similar to herpes

Thank you for your kind attention!

# Literature

SECOND EDITION  
**Pediatric Dentistry**  
A Clinical Approach

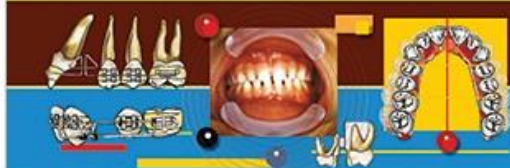GÖRAN KOCH • SVEN POULSEN



WILEY-BLACKWELL

Szerkesztette:  
Dr. Fábián Gábor,  
Dr. Gábris Katalin,  
Dr. Tarján Ildikó

## GYERMEKFOGÁSZAT, FOGSZABÁLYOZÁS ÉS ÁLLCSONT-ORTOPÉDIA



Semmelweis Kiadó

## GYERMEK- ÉS IFJÚSÁGI FOGÁSZAT

Szerkesztette:

Dr. Ábrányi Zoltán, Dr. Gábris Katalin, Dr. Tarján Ildikó



Semmelweis Kiadó