



Semmelweis University Faculty of Dentistry Department of Community Dentistry


Head of Department: Dr. Peter Kivovics associate professor

<http://semmelweis-egyetem.hu/fszoi/>

<https://www.facebook.com/fszoi>



Oral surgical aspects of Emergency dentistry

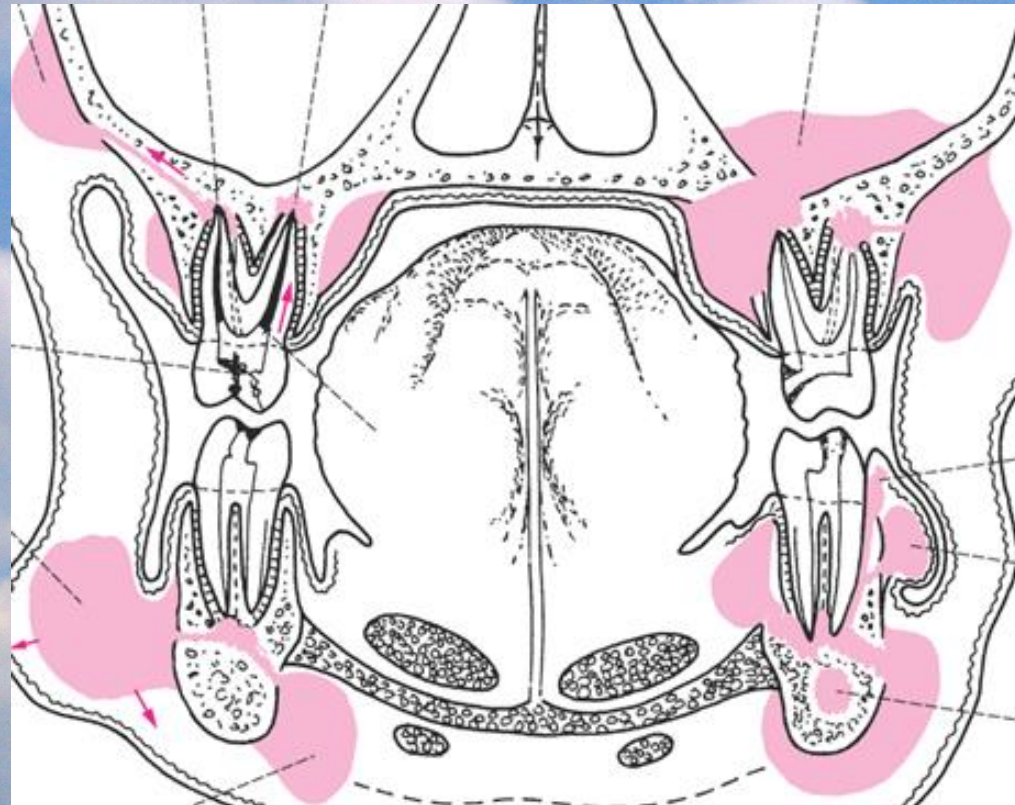


Dr. Mercédesz Orsós
MsC and PhD student

Odontogenic inflammations

Consecutive illnesses of caries

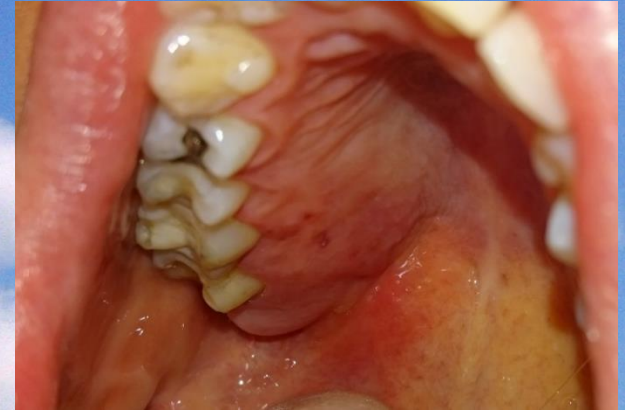- Pulp chamber, root canal - pulpitis, gangraena pulpae
- Periapical area - periodontitis apicalis
- Get through the cortical - periostitis
- Spread in soft tissues - abscessus, phlegmone
- Spread in the medulla - osteomyelitis



Periostitis

2 types:

- Serosus periostitis – diffuse swelling
- Periostitis purulenta absecendens – fluctuates



Symptoms: fever, bad general condition, swollen lymph nodes, severe pulsing pain

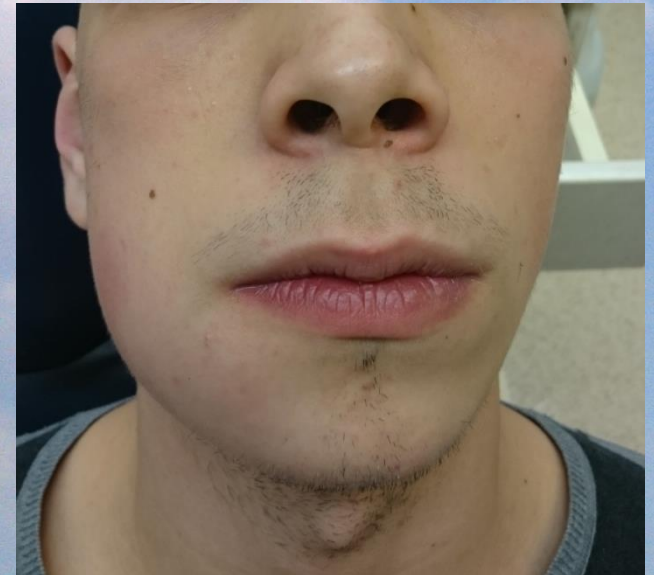Therapy: different in the 2 types!

AB

Trepanation, extraction

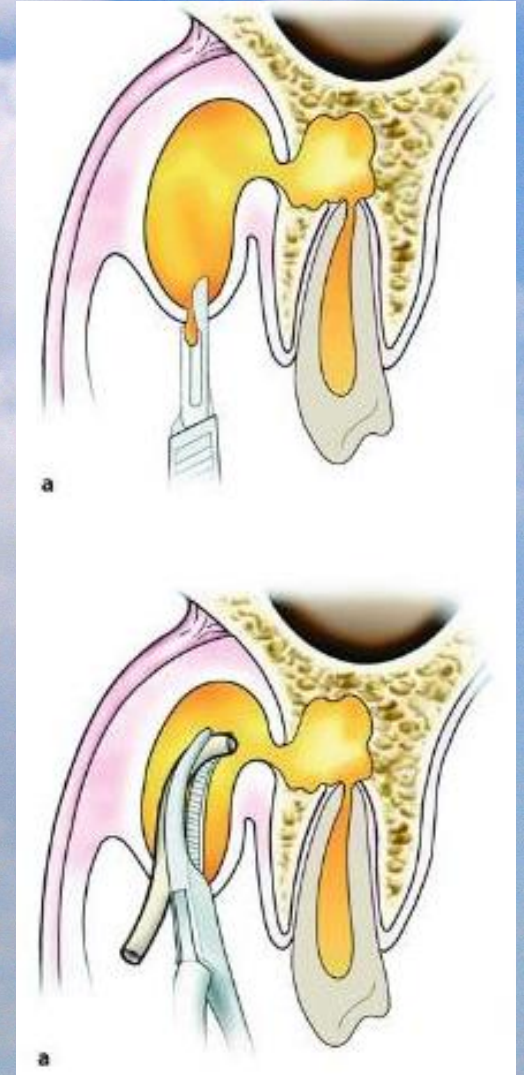
Incision and drainage

Wet compression

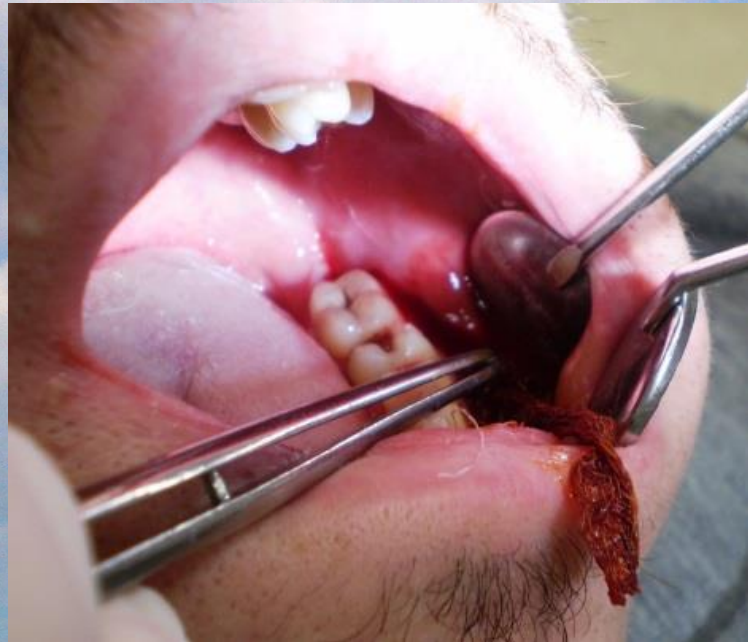
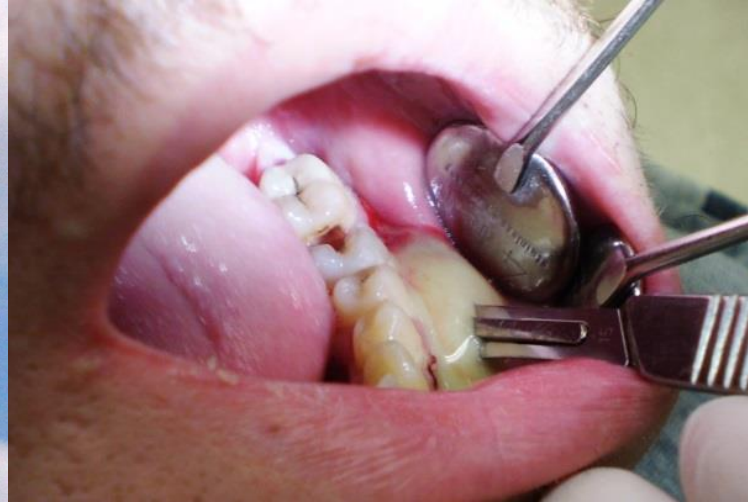
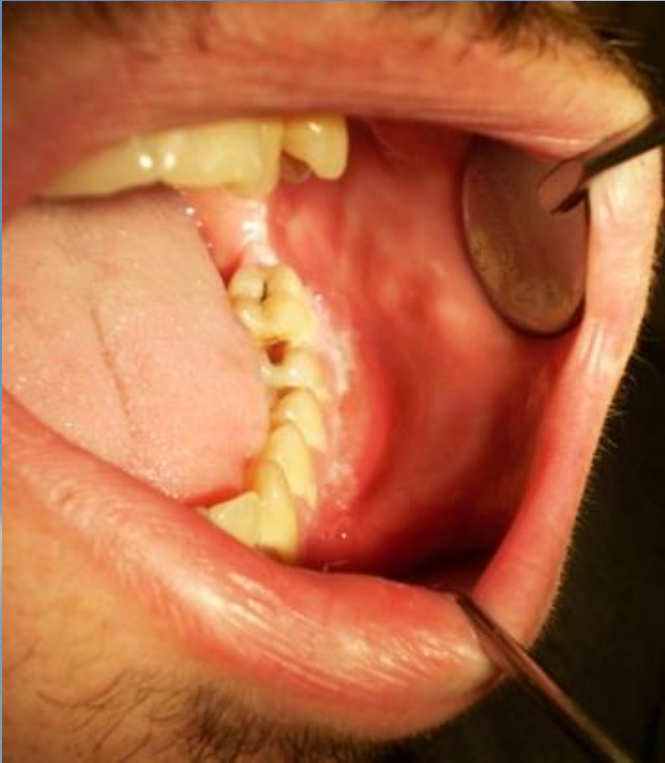Incision, drainage

- Intraoral or extraoral
- Local anaesthesia
- Avoid the anatomical structures
- Definite cut to reach the bone
- Drainage: gauze with iodine, Betadin (allergy?) or silicone drainage
- Change it daily

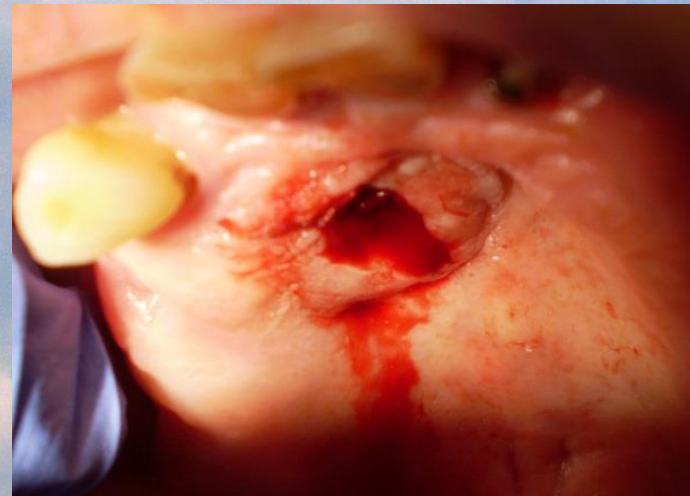
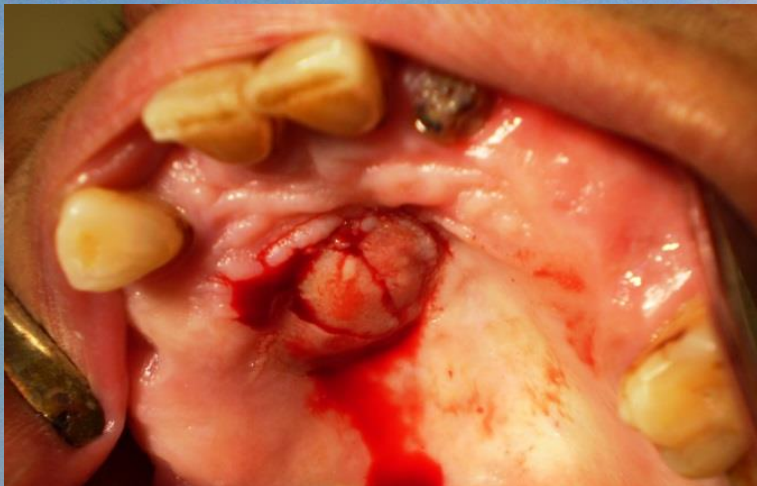
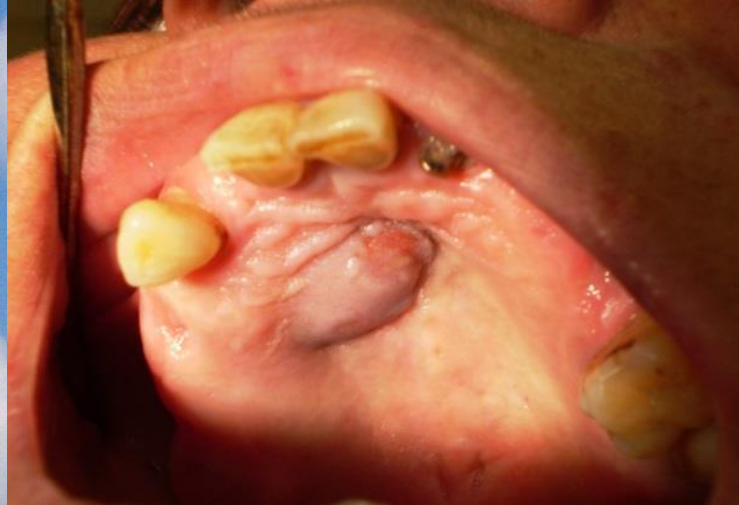
Intraoral incision, drainage



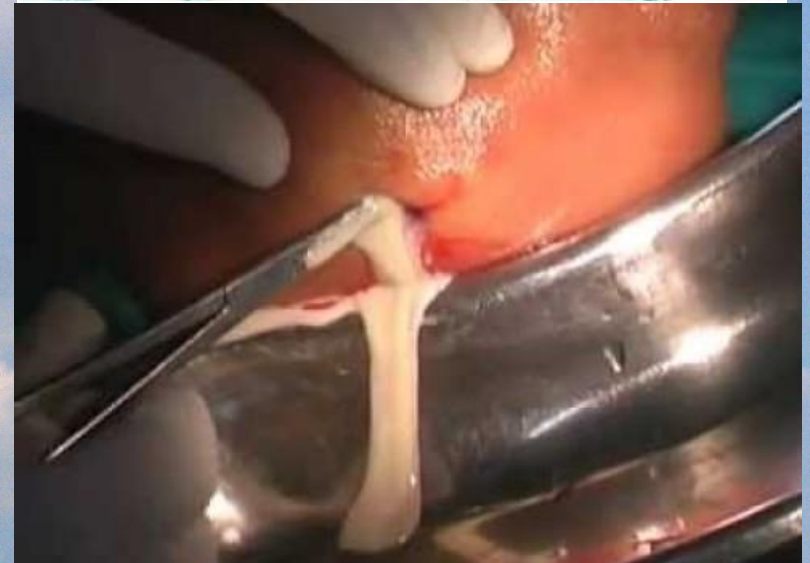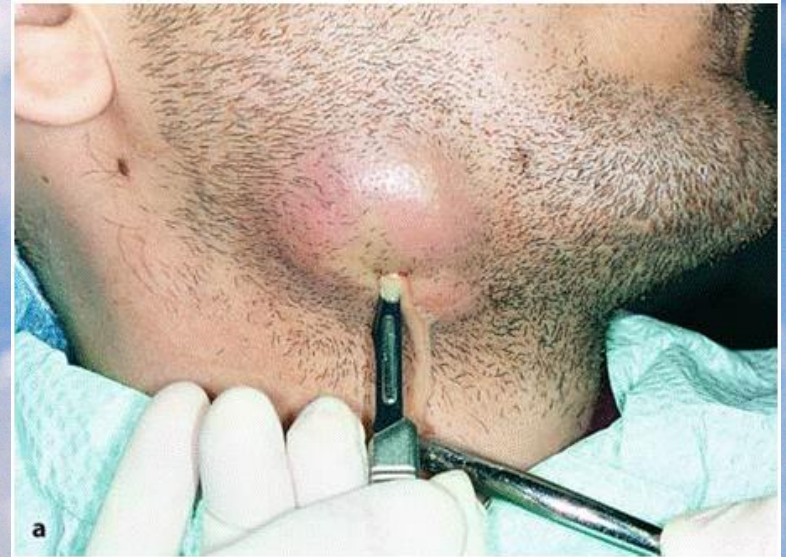Intraoral incision, drainage

a. palatina!!!



Extraoral incision, drainage

- Apply iodine
- Find the punctum maximum (possibly test puncture)
- Cut
- Widen with Hegar-Mayo
- Silicone drain
- Scab remains!



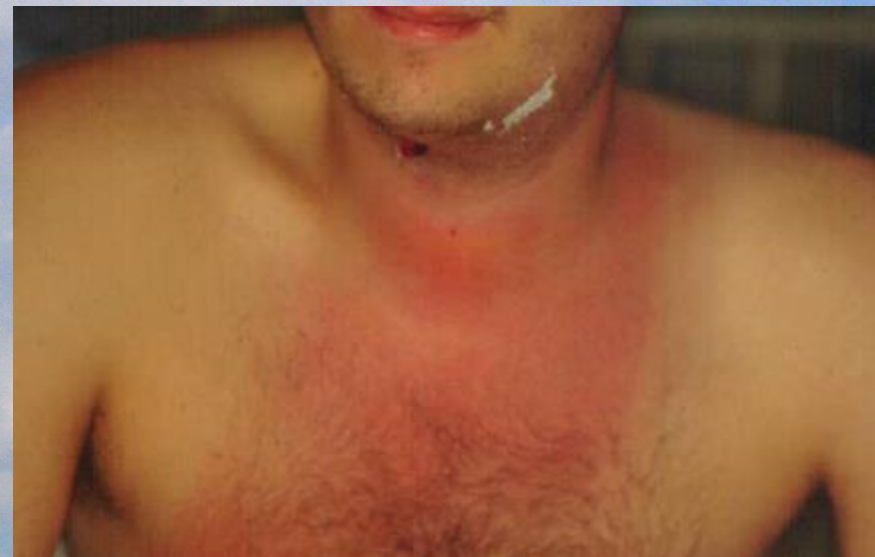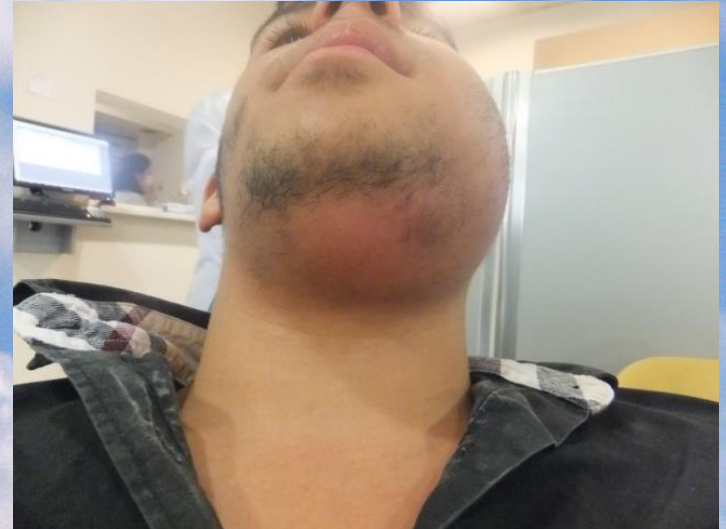Phlegmone

Symptoms:

- Spread in head and neck connective tissue spaces
- It has no inclination to blend in
- „Hard as a wooden board”
- Very high septic fever
- Very poor general condition
- Mostly caused by anaerobs

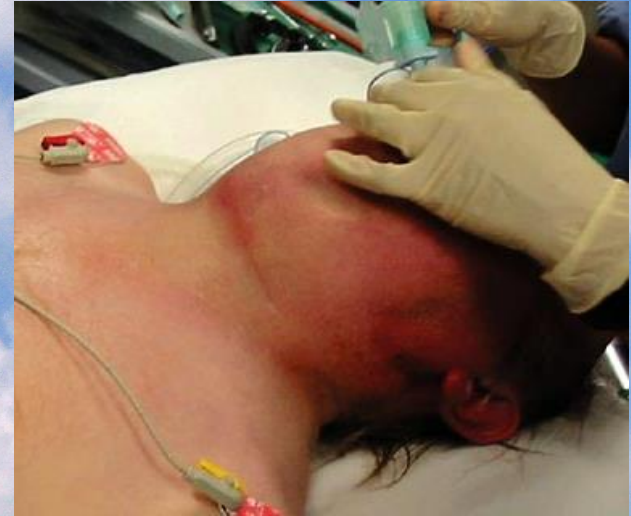Therapy:

- Hospital treatment
- Targeted AB IV
- Cut it on wide base, drainage

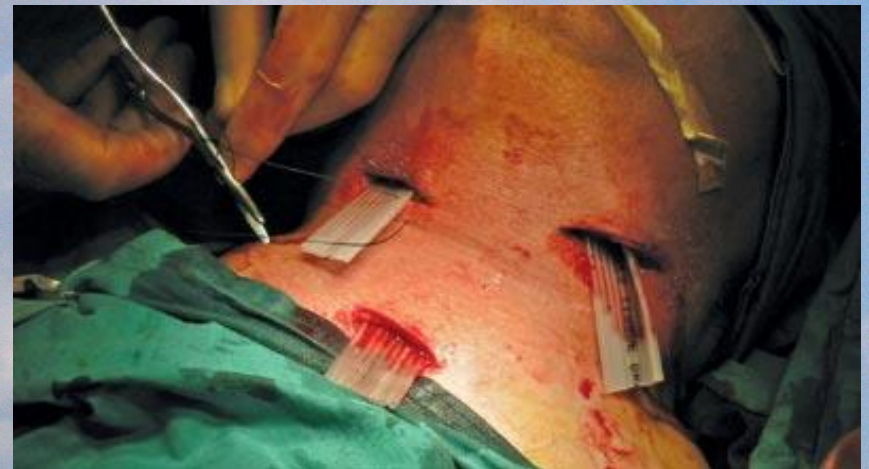

Phlegmone

Early surgical intervention,
aggressive intravenous
antimicrobial therapy and
supportive care is
imperative!

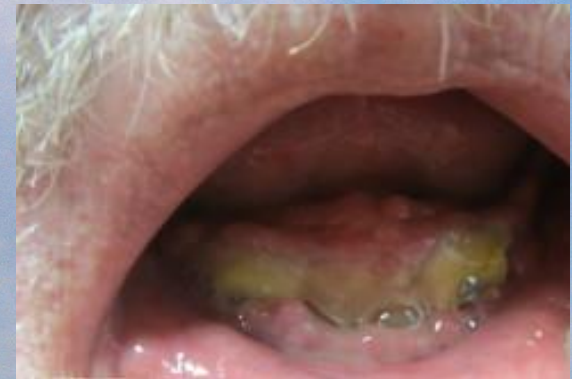
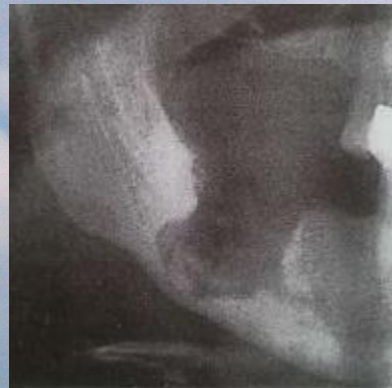
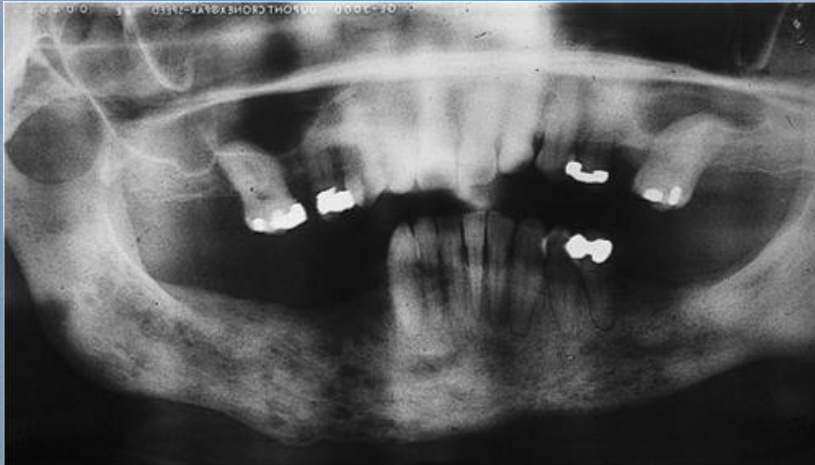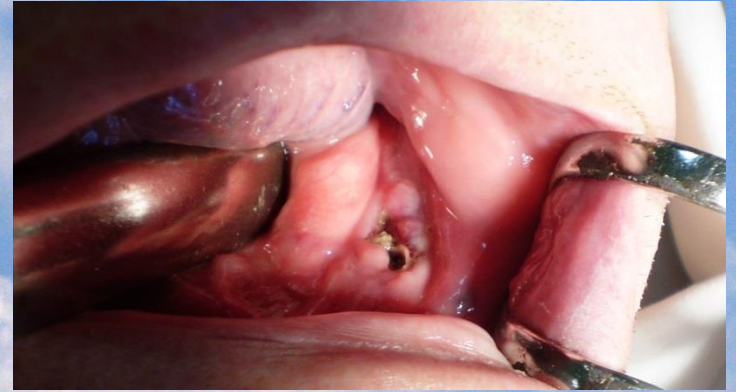Mortality rate is still very high



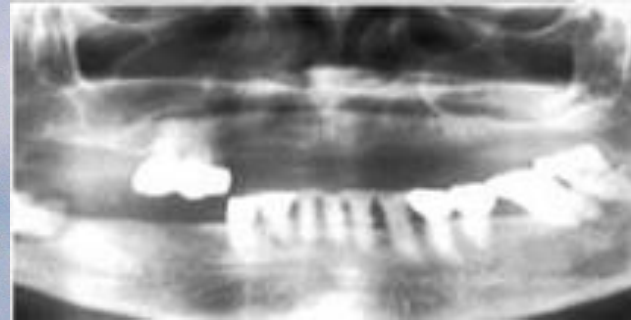
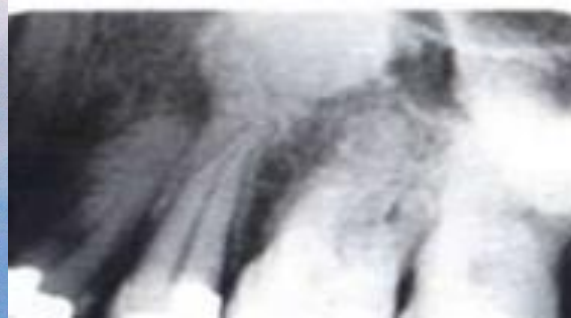Osteomyelitis

- Mostly in the lower jaw
- In immune suppressed conditions
- Odontogenic or traumatic causes



Osteomyelitis

- Focal sclerosing osteomyelitis
- Diffuse sclerosing osteomyelitis
- Garré's osteomyelitis
- **Osteoradionecrosis**
- **Medication related osteonecrosis of the Jaw (MRONJ)**



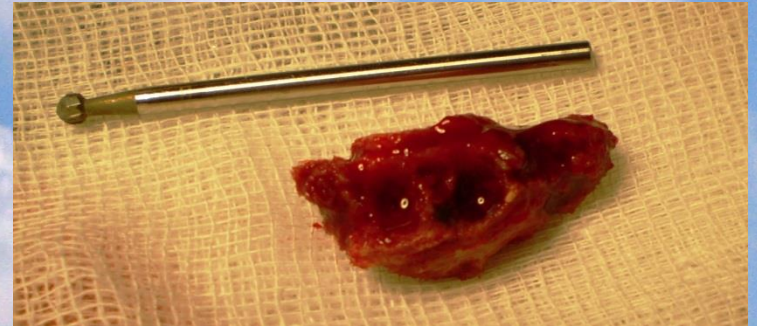
Bisphosphonates, antiresorptive (denosumab) and antiangiogenic therapies.

Osteomyelitis

- Acute osteomyelitis

Symptomes: fever, pain, loose teeth

Treatment: AB, extraction



- Chronic osteomyelitis

Symptomes: develops from acute condition,
mild symptoms

Treatment: AB, remove bone sequestrs,
splinting

Pericoronitis

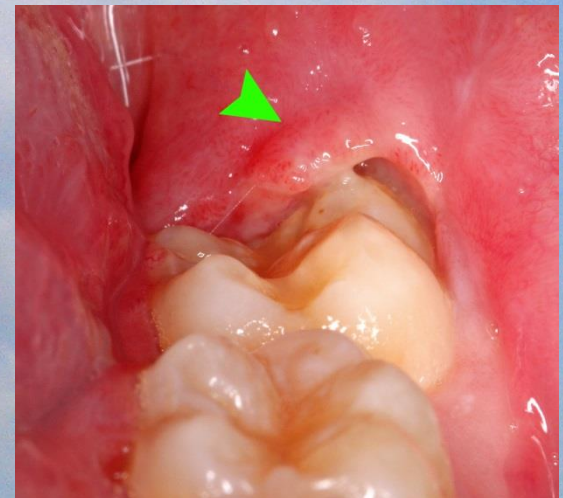
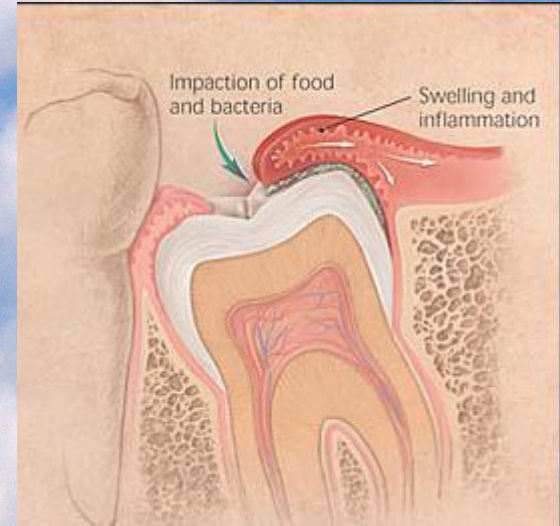
- Inflammation around the wisdom tooth

Symptomes:

- Pain
- Trismus
- Swollen lymph nodes

Treatment:

- Cleaning around
- Insert stripe (Chlumsky)
- AB
- Extraction



Dry socket syndrome

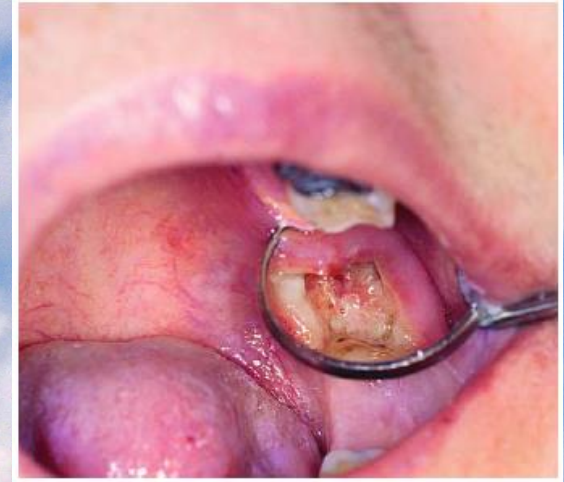- After the extraction (in 3 days)

Symptomes:

- Pain
- Foetor ex ore
- Swollen lymph nodes
- Fever

Risk factors:

- Bone injury
- Sex
- Age
- Contraceptive pill
- Smoking
- Bad hygiene



Treatment:

Surgical

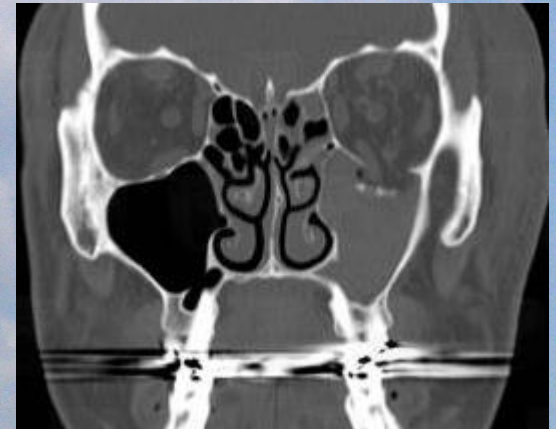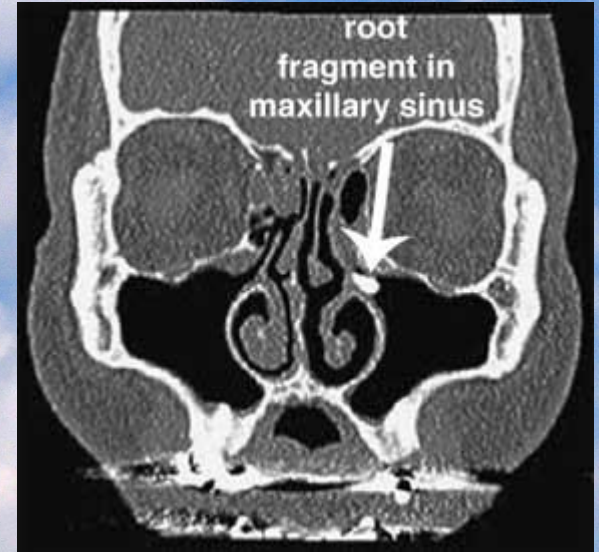
Loc.anaest. remove the debris

Conservative

put a stripe in Iodine, Chlumsky, „Alvogyl”

Sinus Maxillaris

- Inflammation
- Iatrogenic problems
- Radix in antro
- Sinus apertus
- Foreign body
- Fracture



Sinusitis

Sinusitis maxillaris acuta

Sudden onset

Mostly bilateral

Pulsing pain

Lot of mucus flows

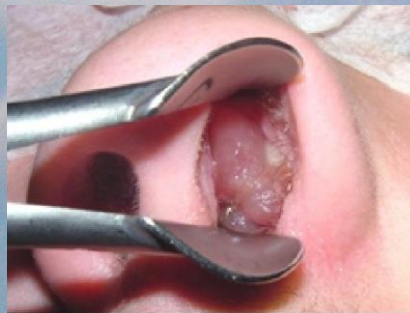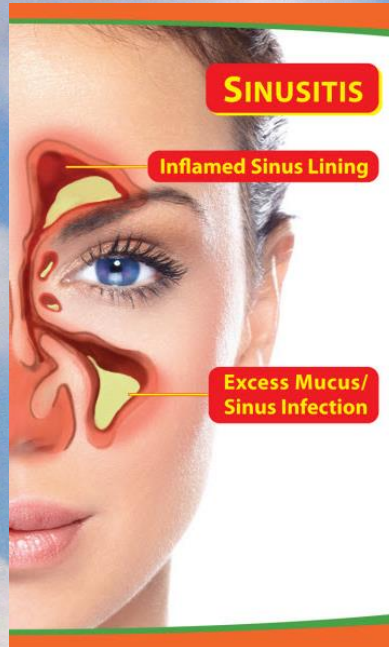
Treatment

Diff. Diag.

Find causes

AB

Infralamp



Sinusitis maxillaris chronica

Mostly unilateral

Few symptoms

Reduced nasal air flow

Foreign body feeling

Headache

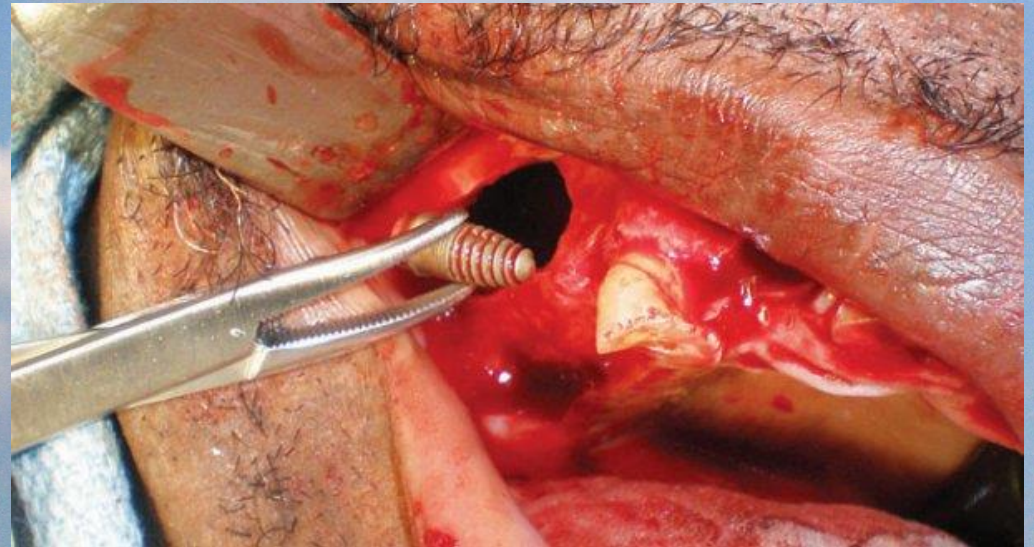
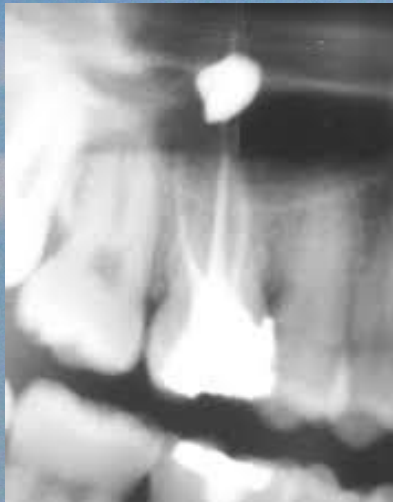
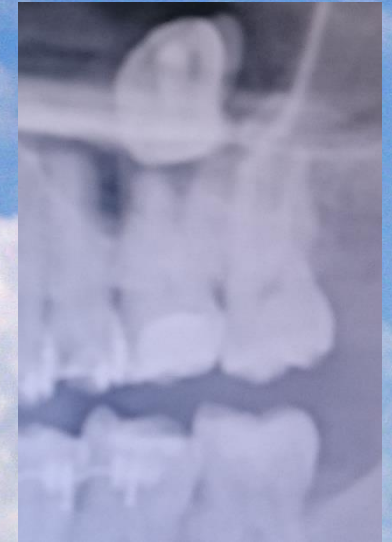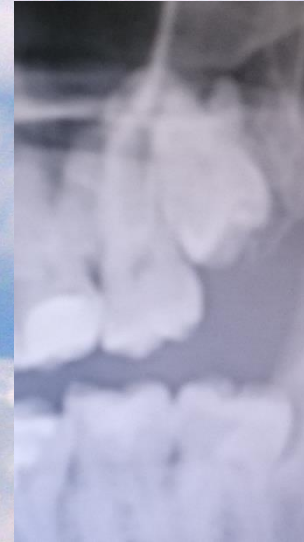
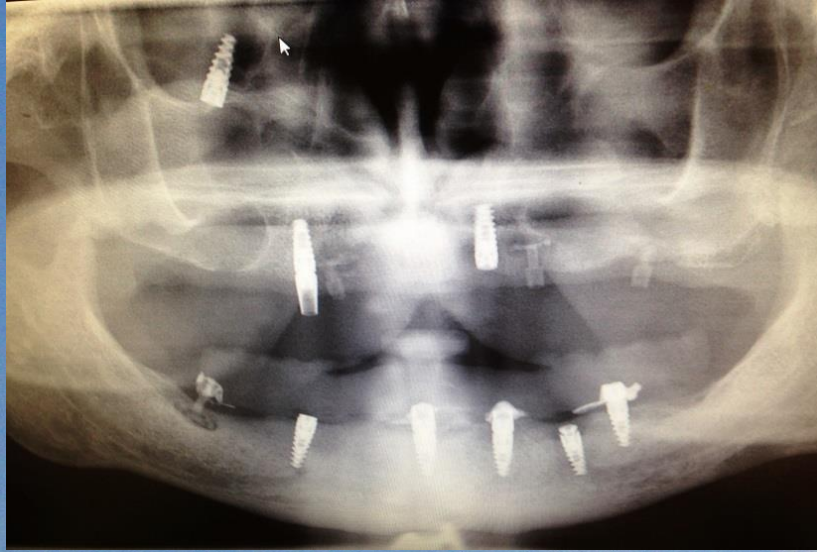
Treatment

Rinsing

Steroid spray

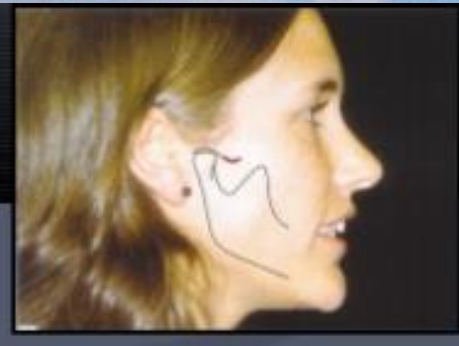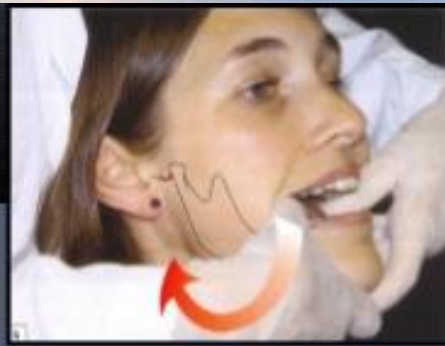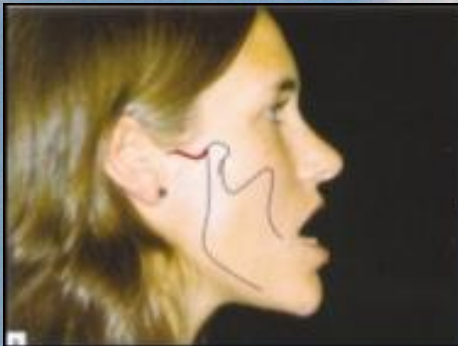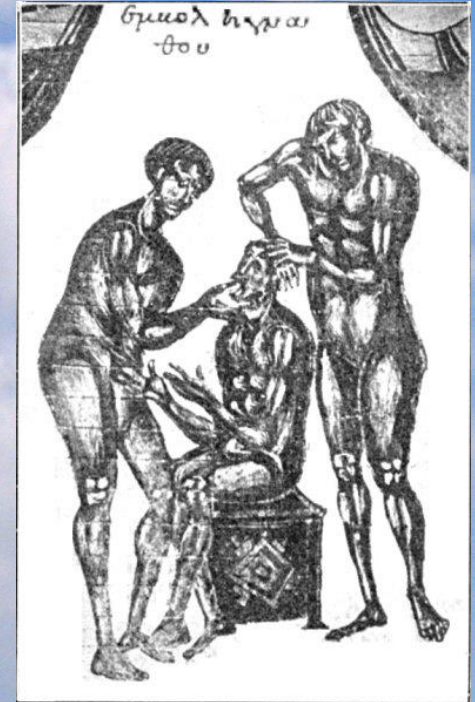
FESS

Foreign body



Emergency TM joint problems

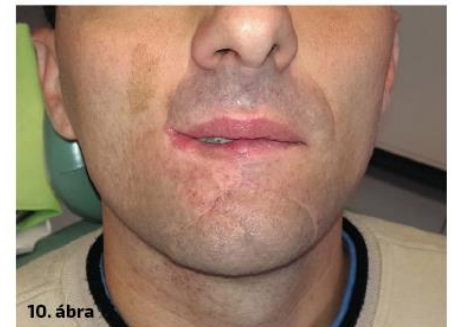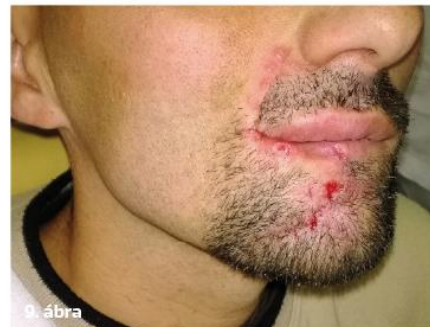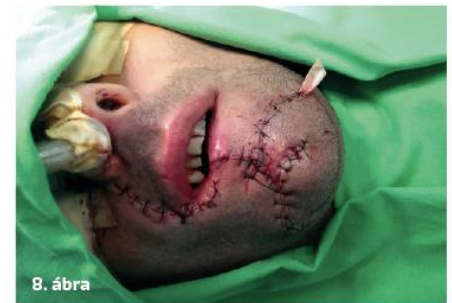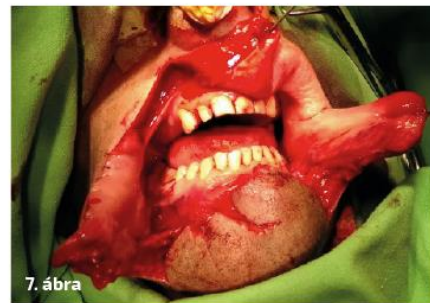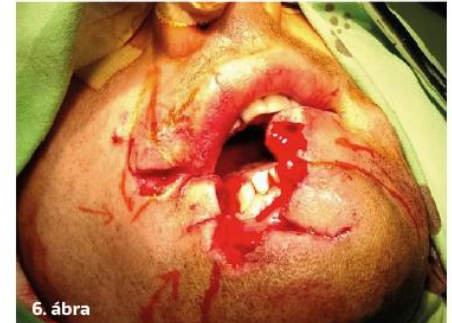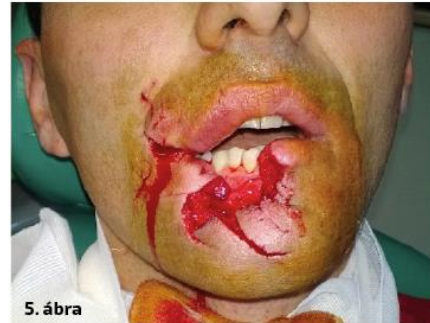- Luxation
(anterior, posterior, lateral)
- Reponation
- Muscle relaxant
- Pain killer



Injuries

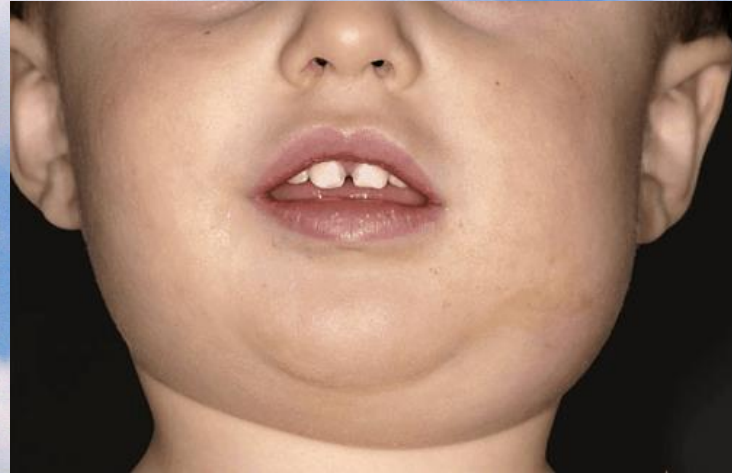Treatment of traumatic injuries

- Local/general anesthesia
- Rinsing the wound with iodine
- Remove the necrotised parts
- Sew up
- Tetanus

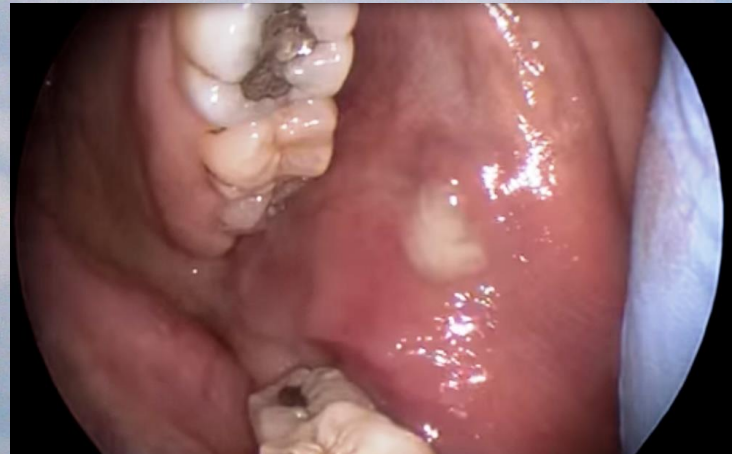

Salivary glands

- Parotitis epidemica



- Parotitis acuta suppurativa

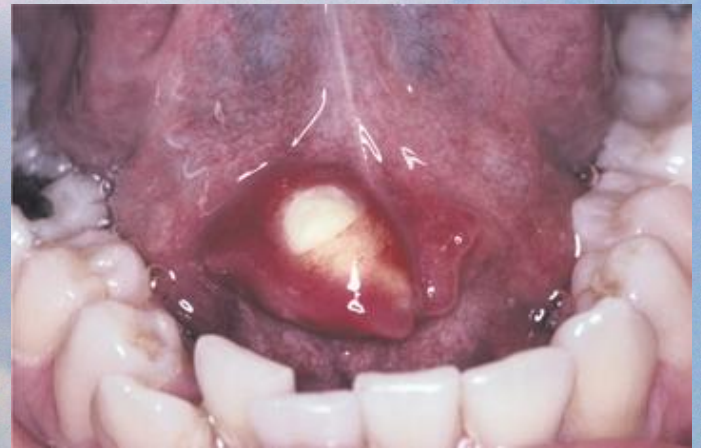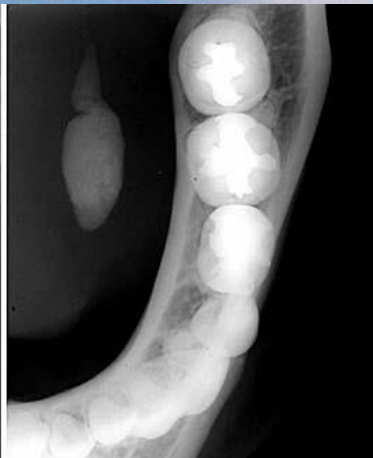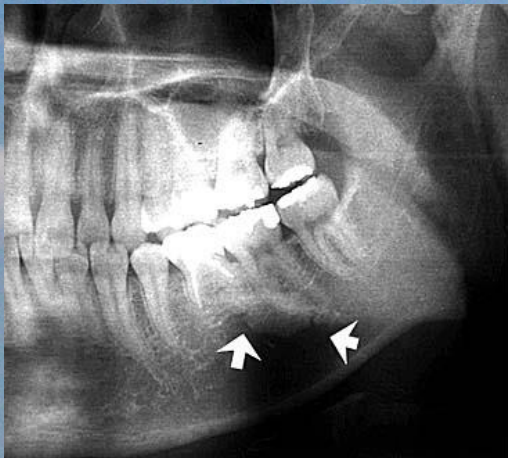


Sialolithiasis

83% of salivary stones in gl. Submand.

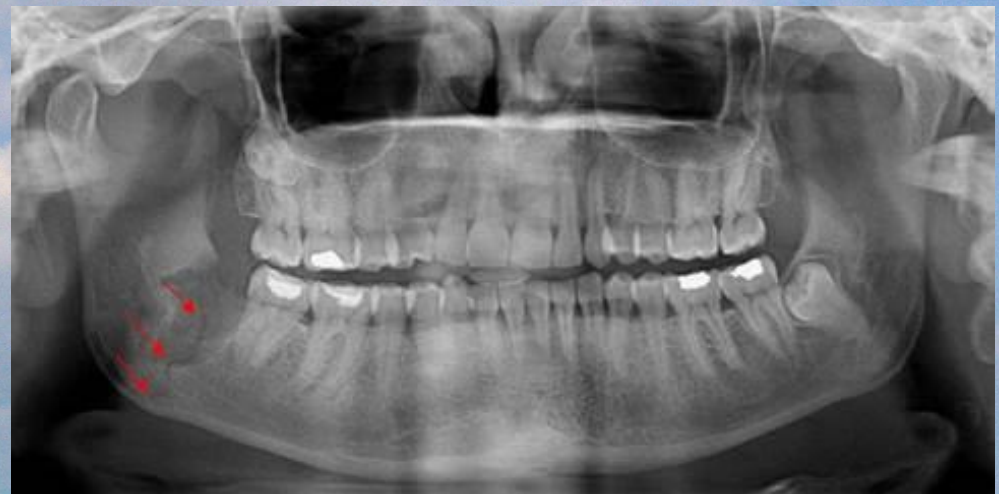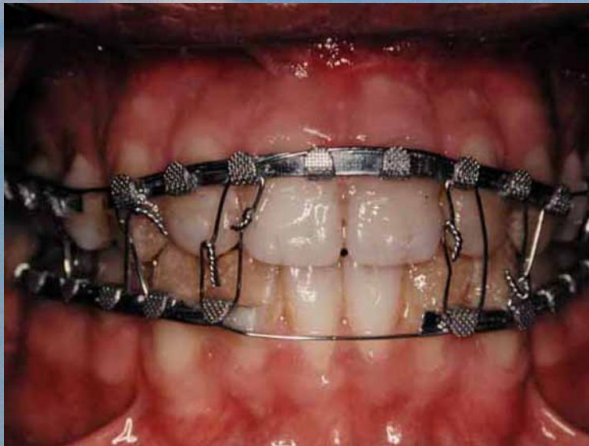Conservative treatment: „Tarivid“ (ofloxacin)

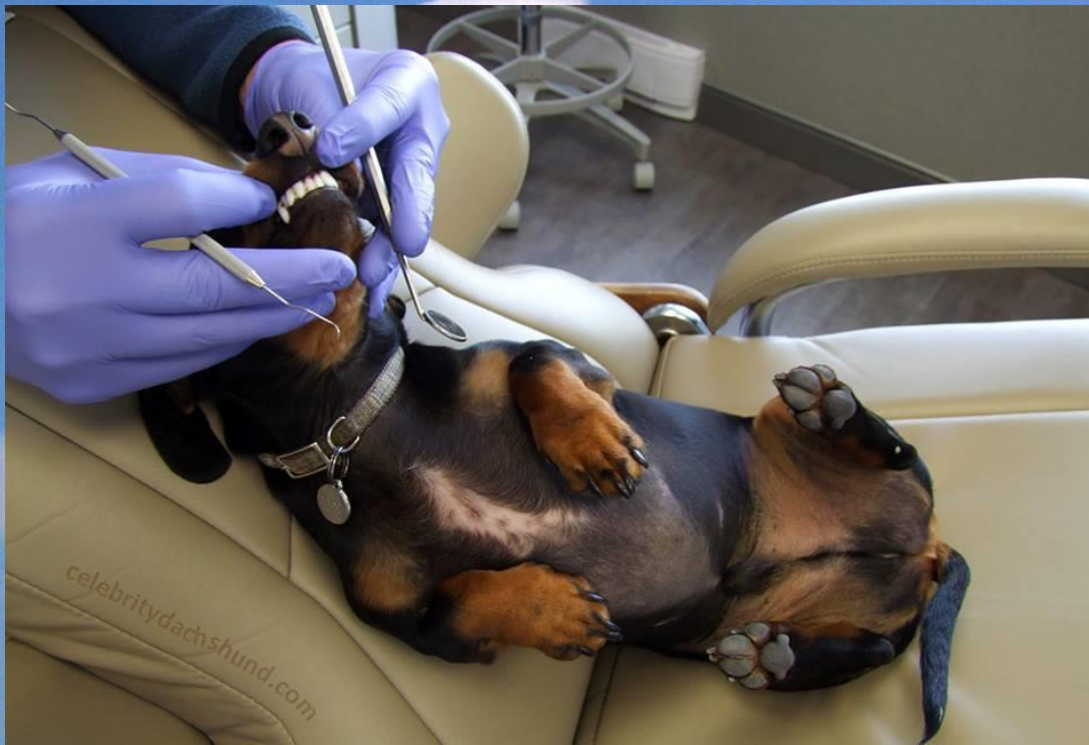Surgical treatment: if necessary



Broken jaws

- Uncertain symptoms: pain, swelling, wounds
- Certain symptoms: deformation, crepitation, X-ray





**Thank you for your kind
attention!**