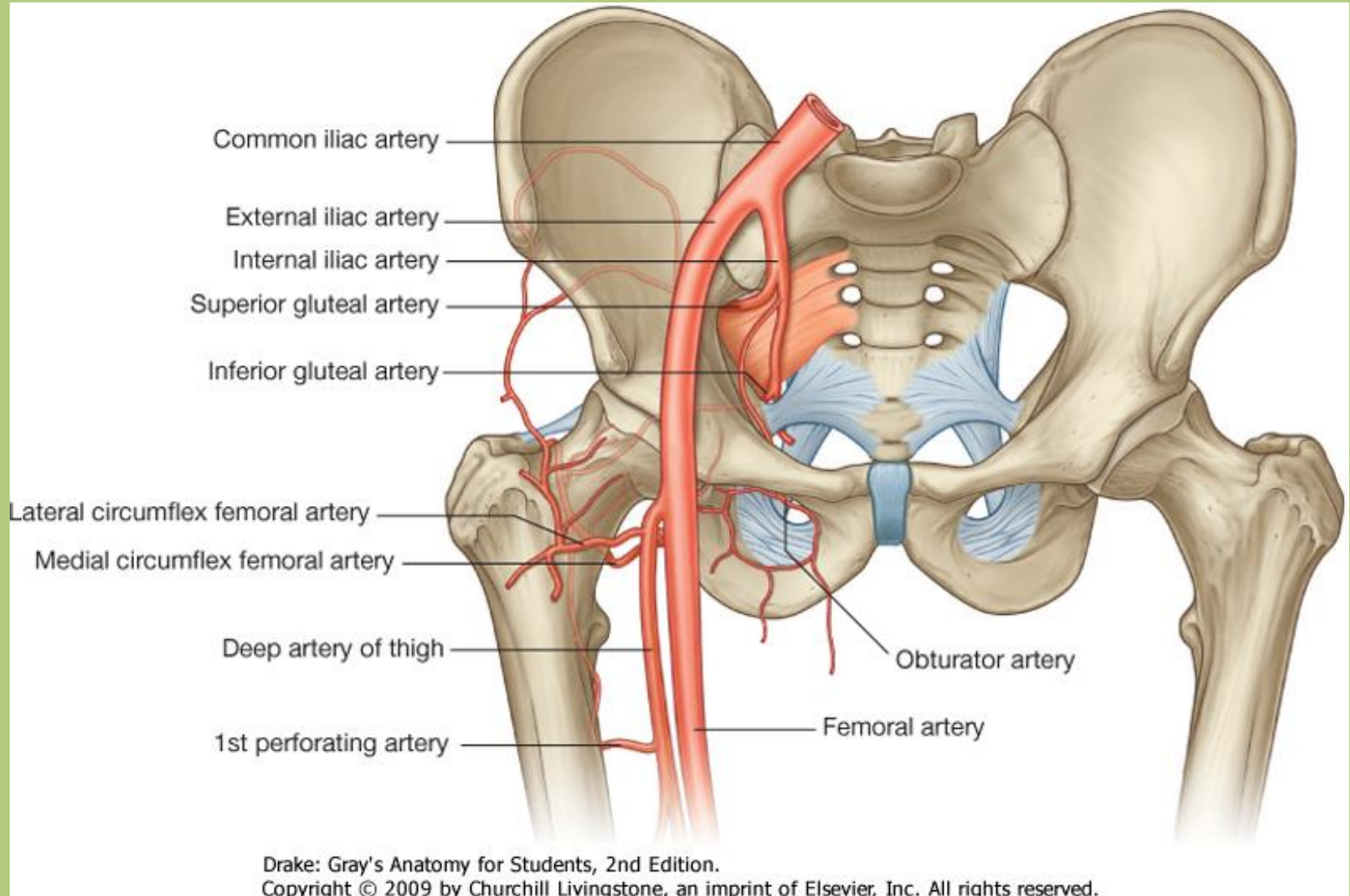


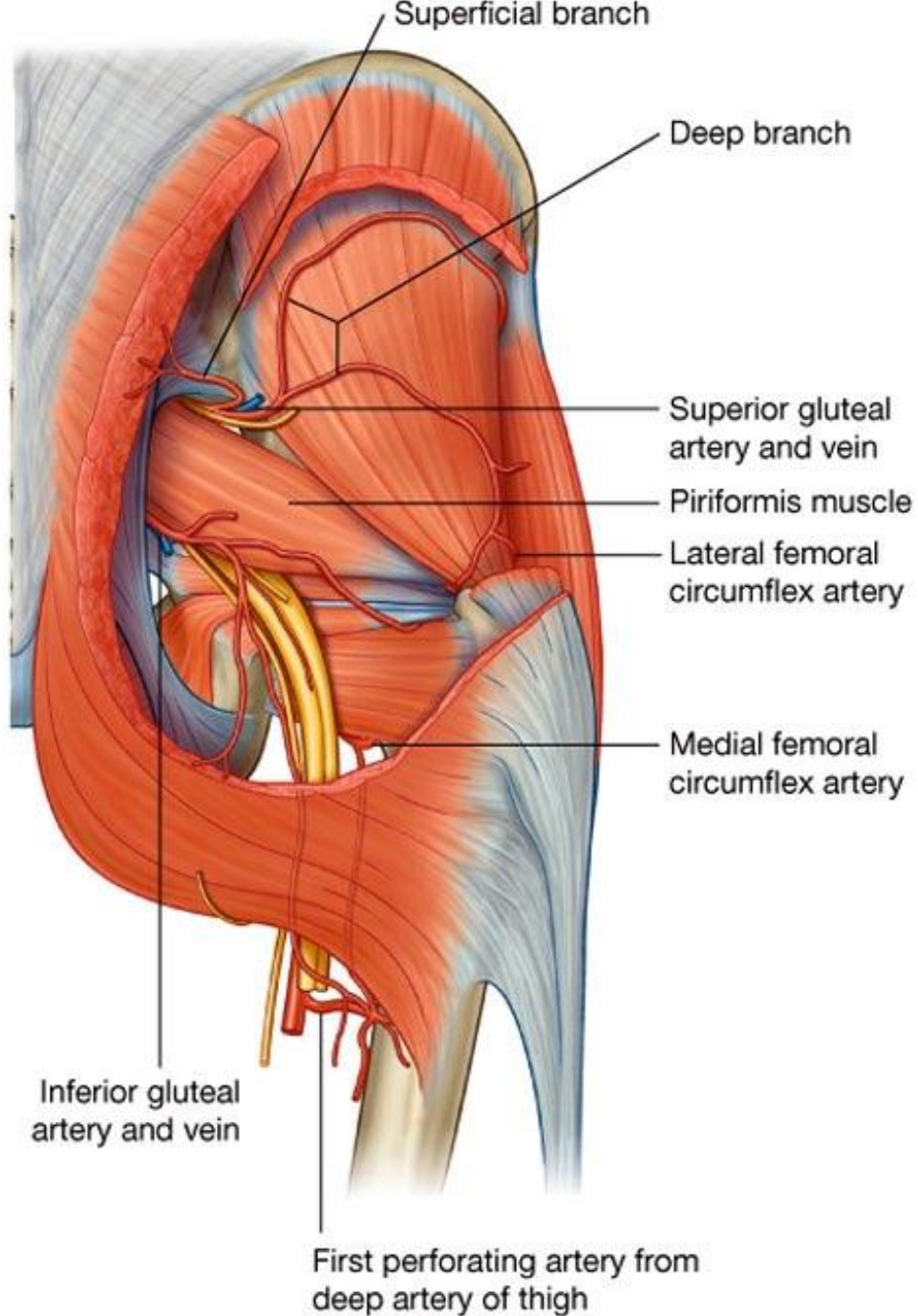


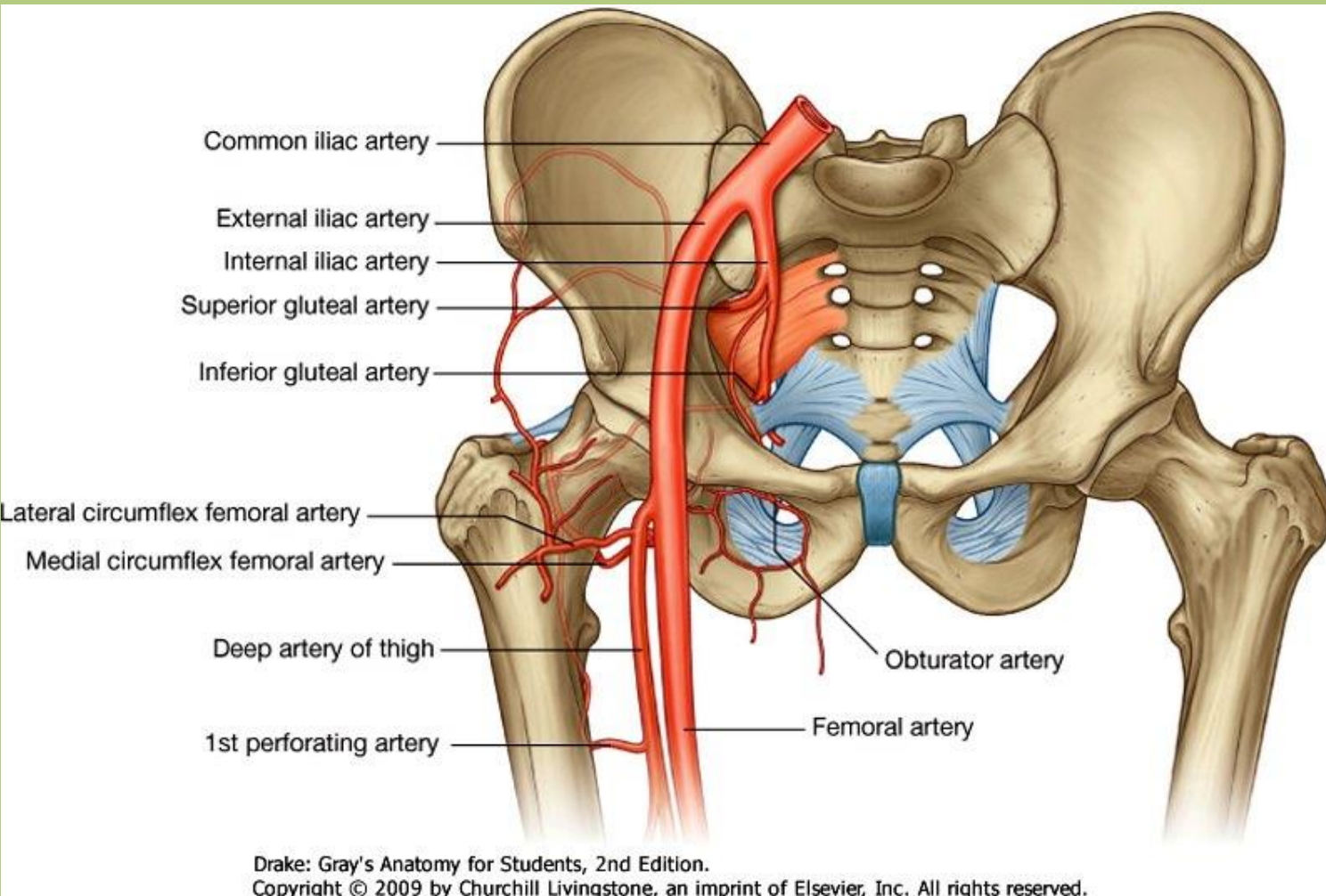
# Neurovascular system of the lower limb

Sándor Katz M.D.,Ph.D.



internal iliac artery: superior and inferior gluteal arteries

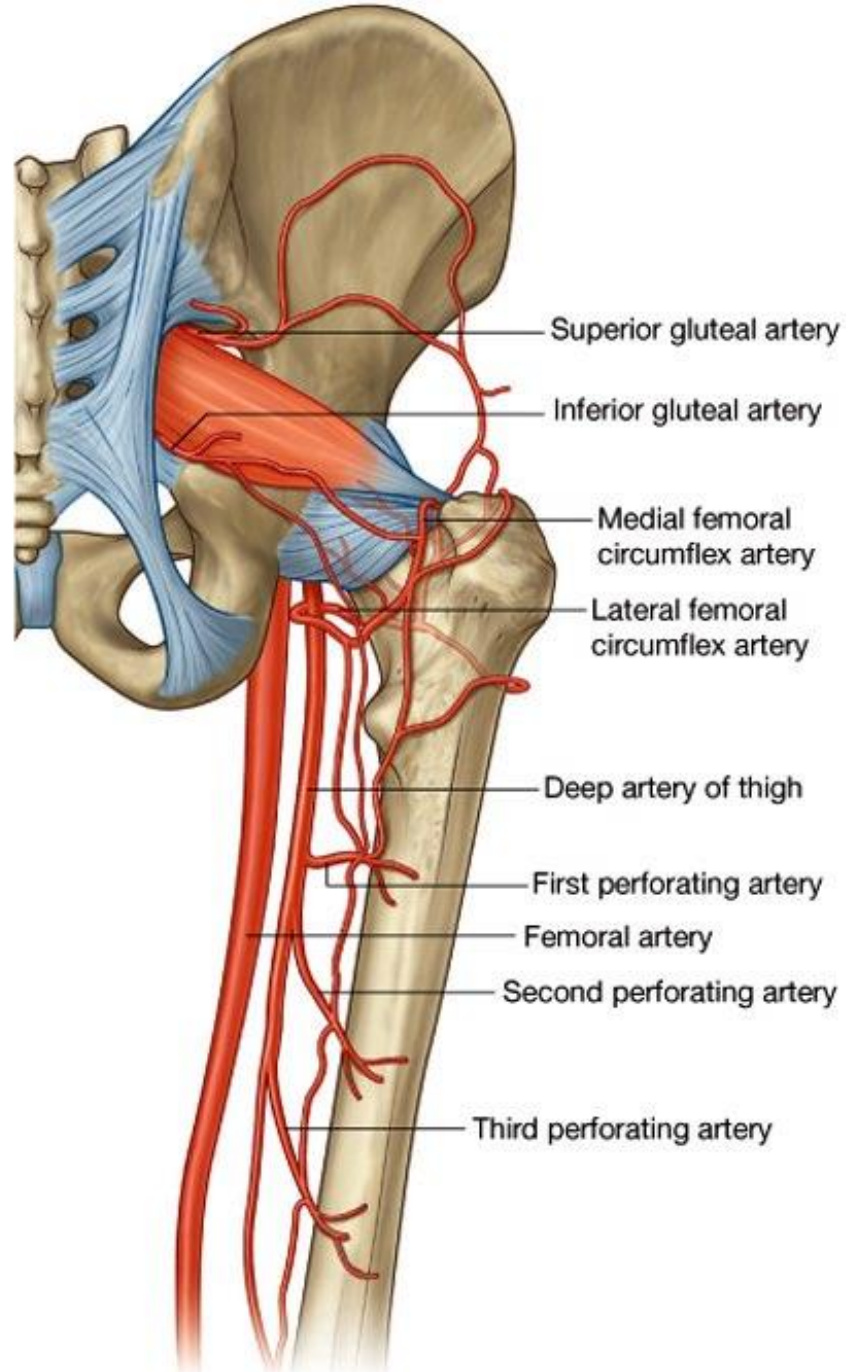


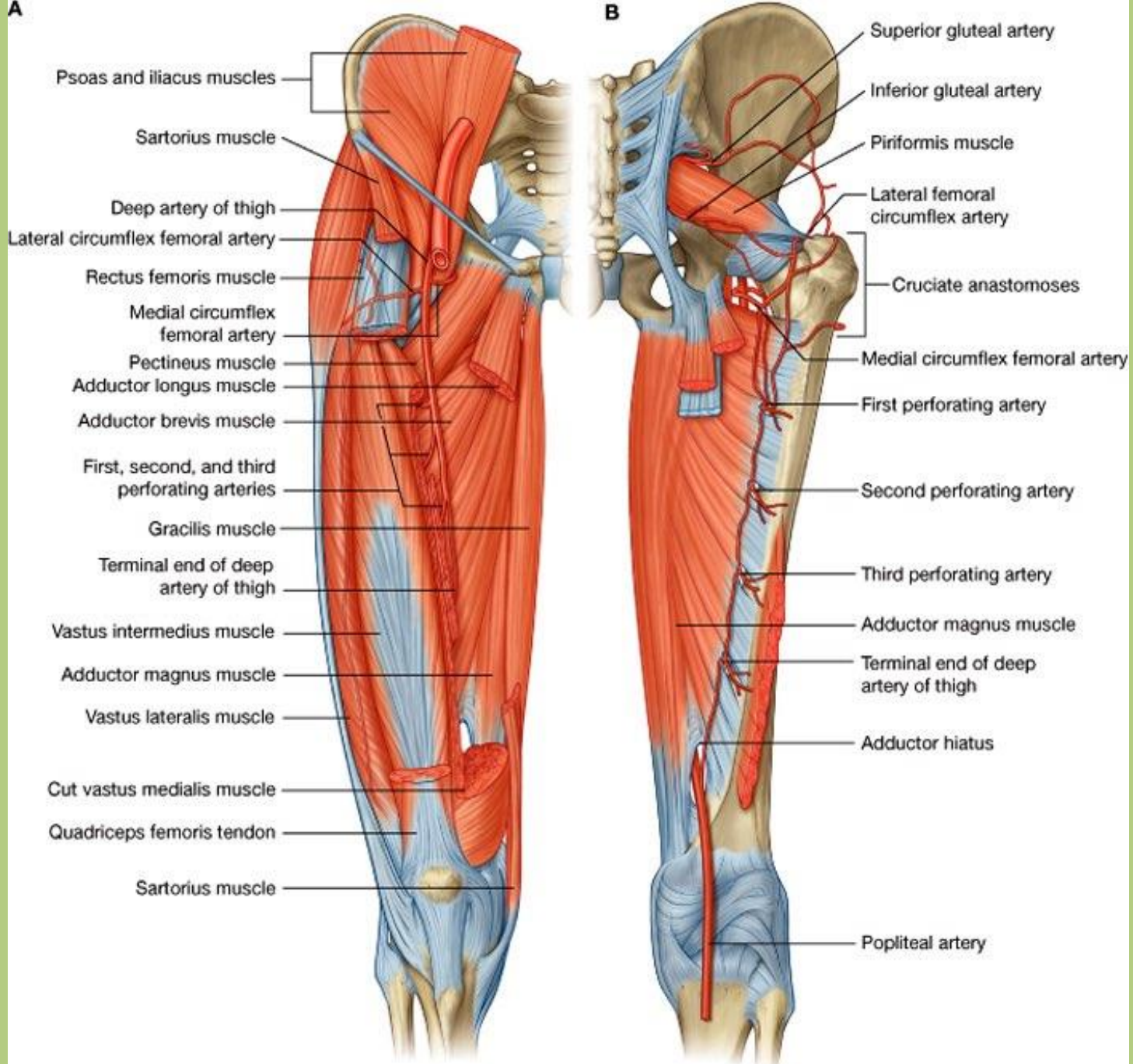


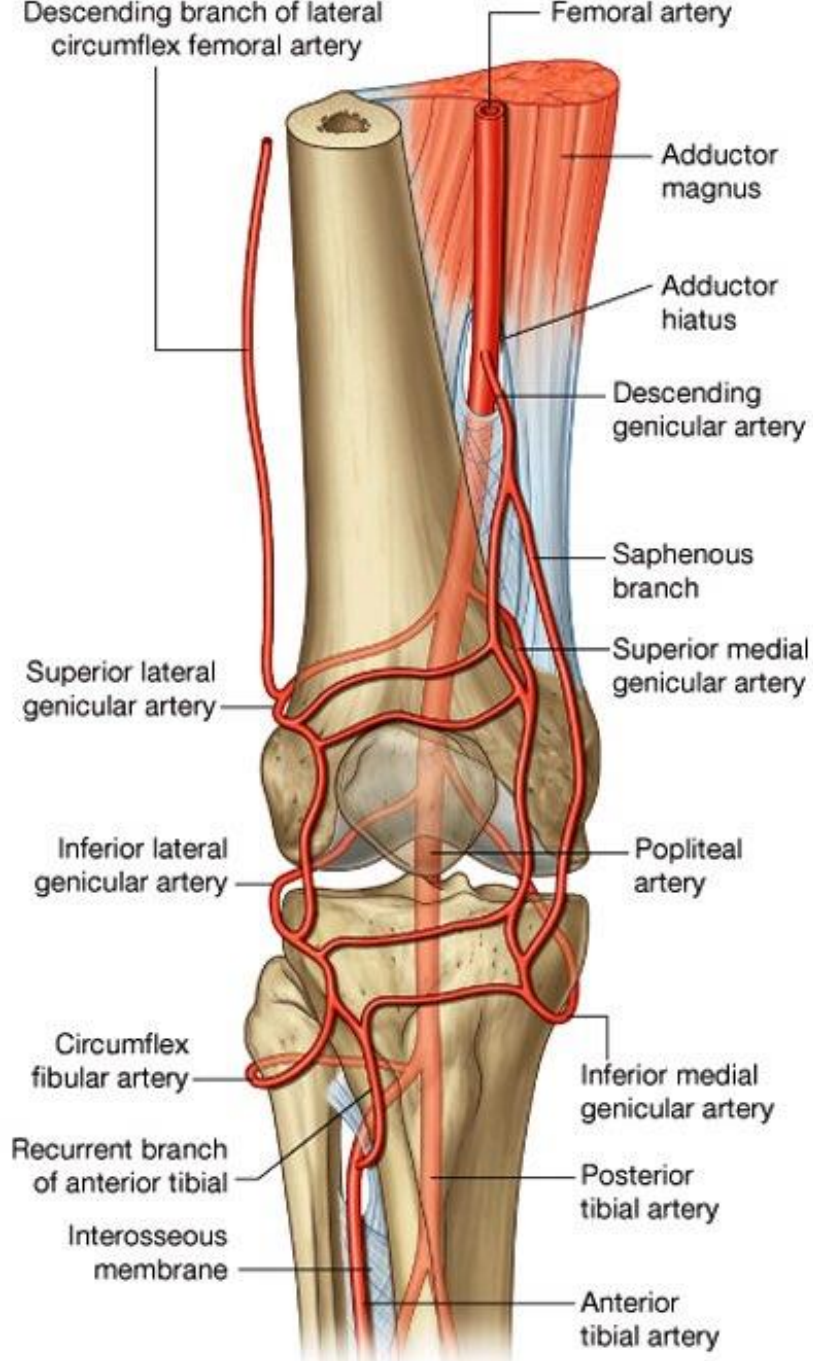
femoral artery:

profunda femoris  
 artery (*deep  
 artery of thigh*)

- lateral and medial circumflex femoral arteries
- perforating branches





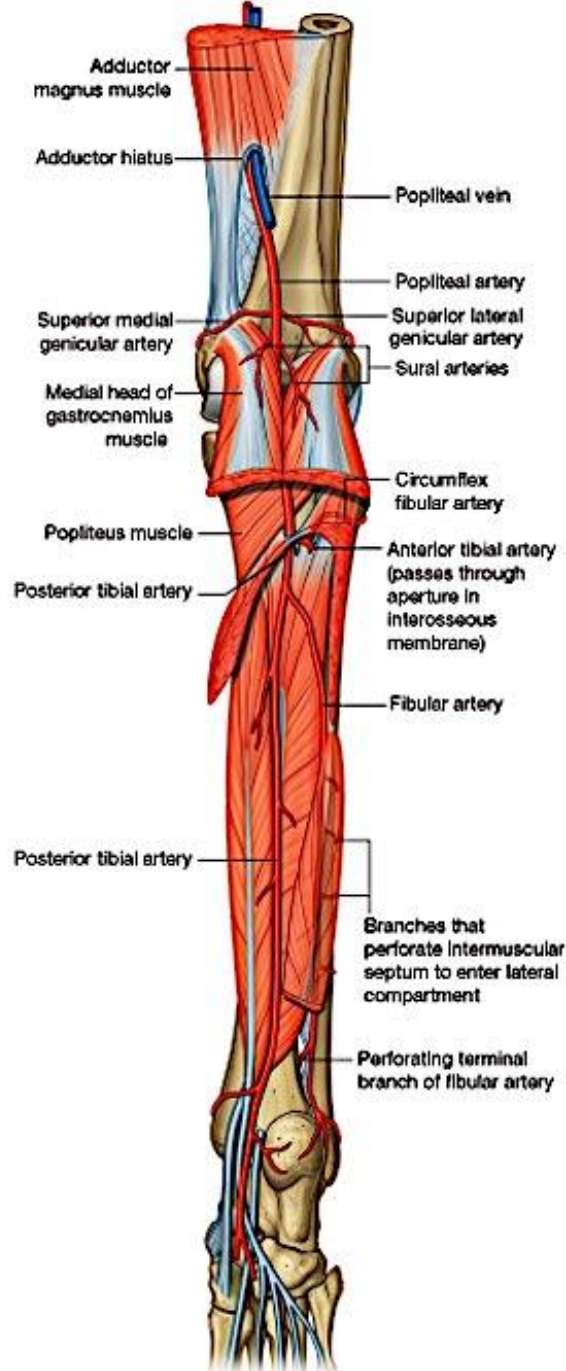


## femoral artery:

- descending genicular artery

## popliteal artery:

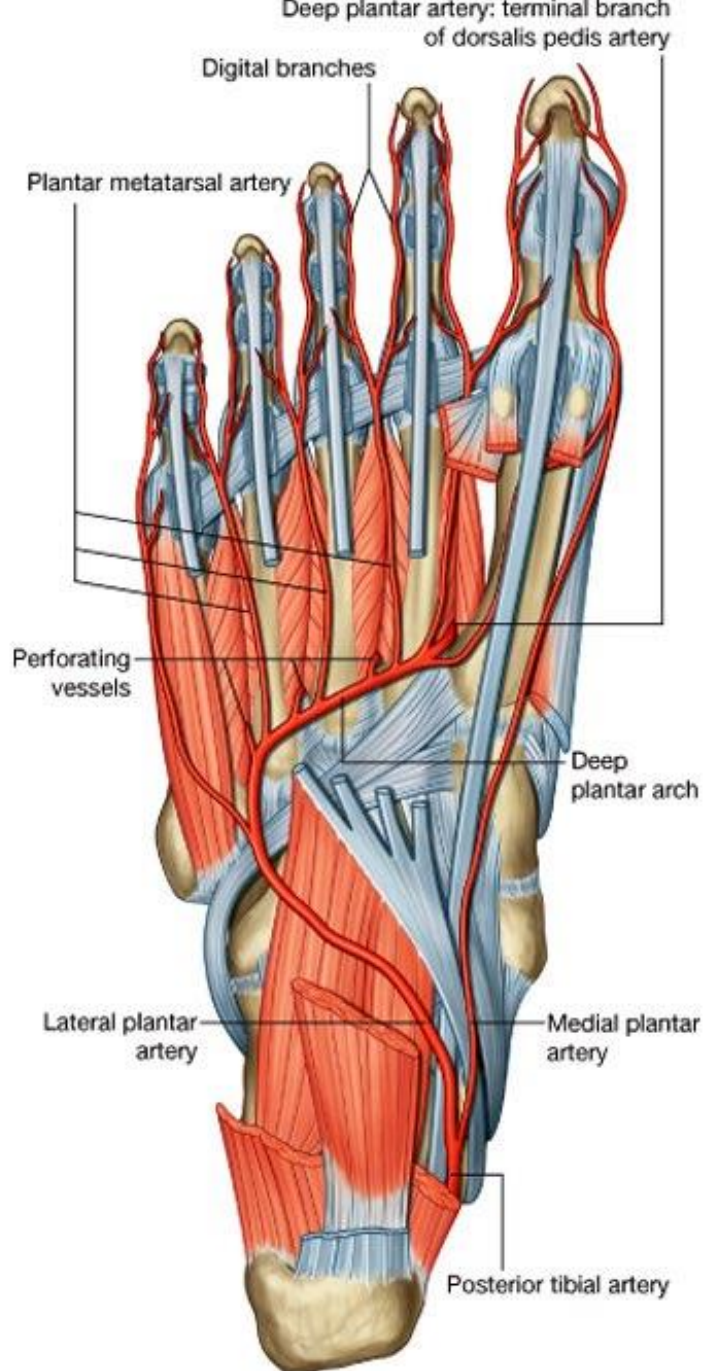
- lateral superior and medial superior genicular arteries
- middle genicular artery
- lateral inferior and medial inferior genicular arteries
- anterior tibial artery
  - *anterior tibial recurrent artery*
- posterior tibial artery
  - *posterior tibial recurrent artery*



## posterior tibial artery:

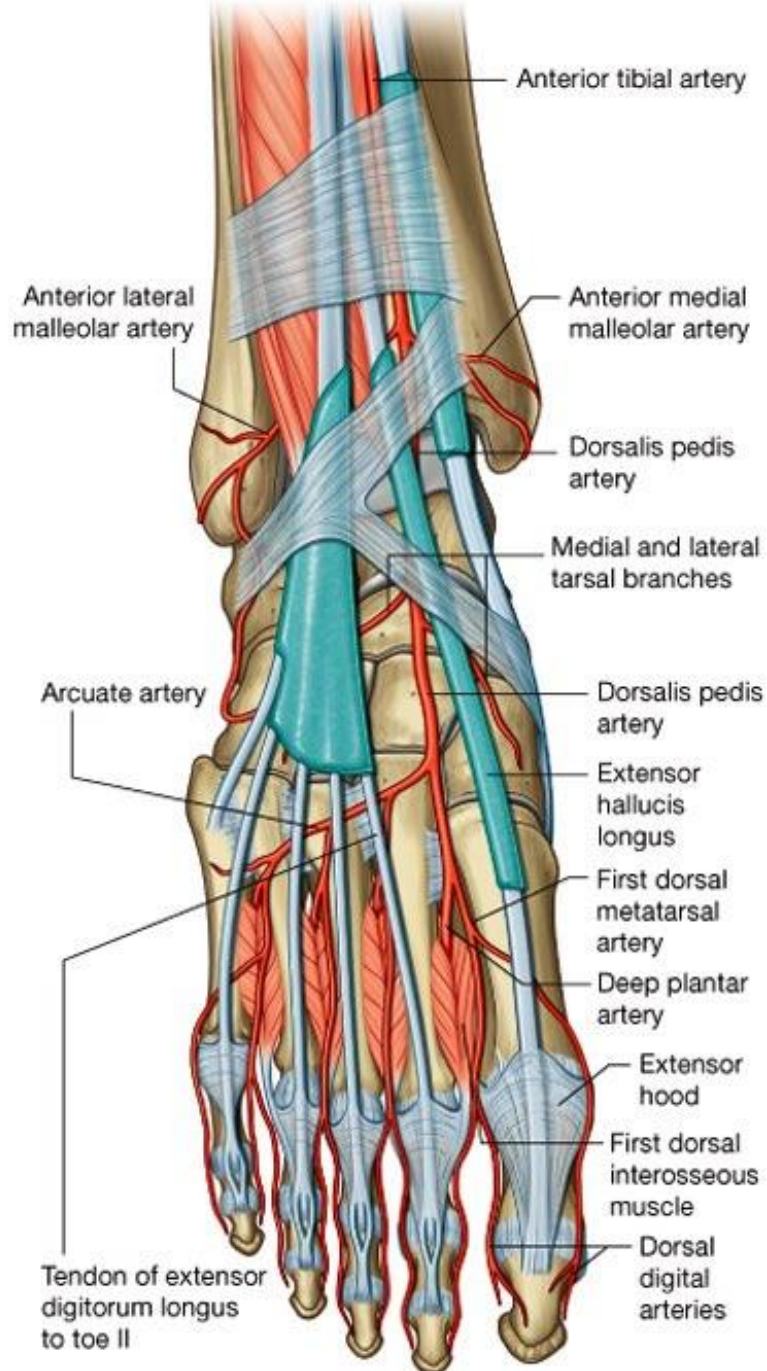
- fibular artery
  - *lateral malleolar branch*
- medial malleolar branch
- lateral and medial plantar arteries





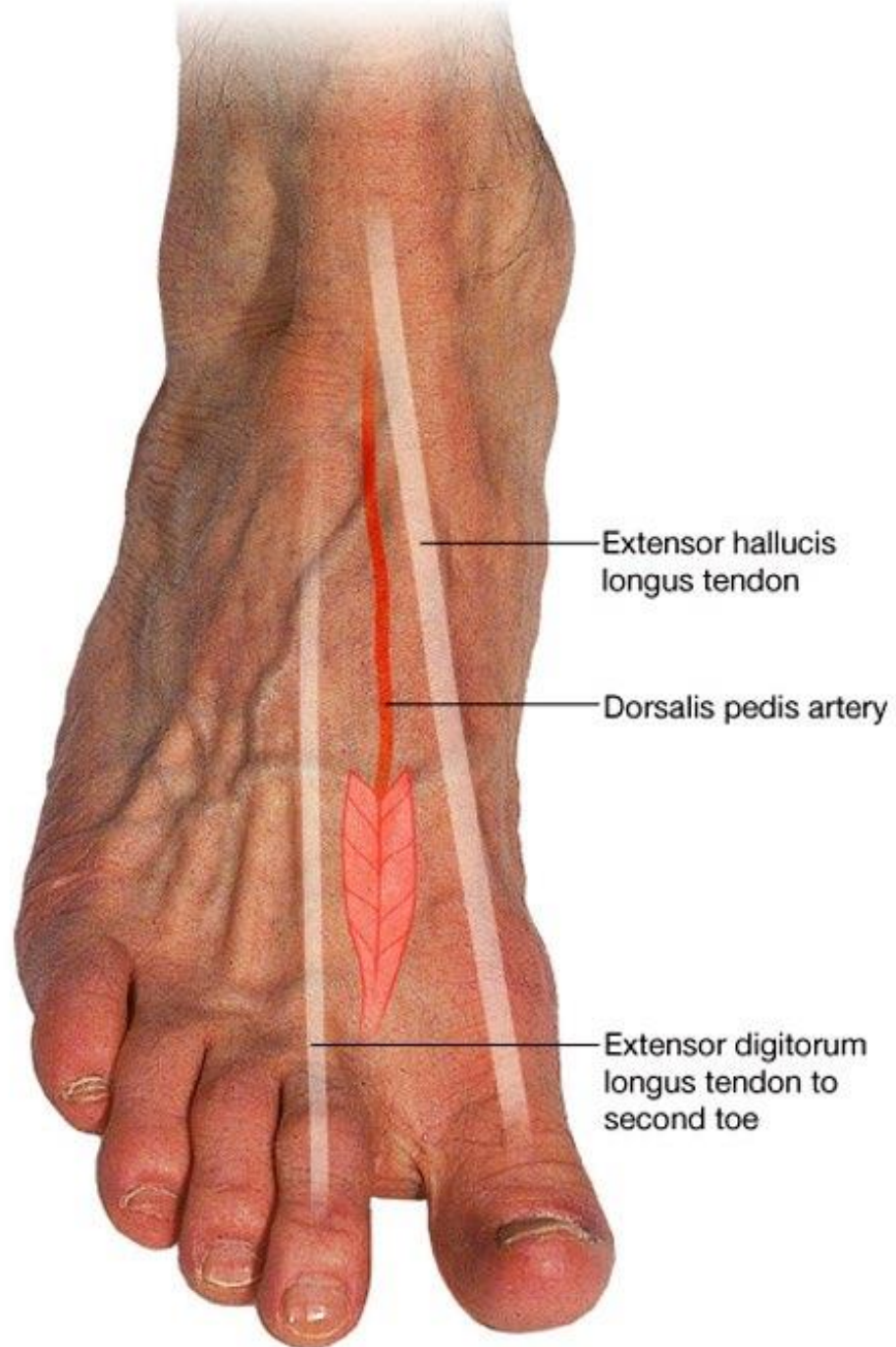
posterior tibial artery:

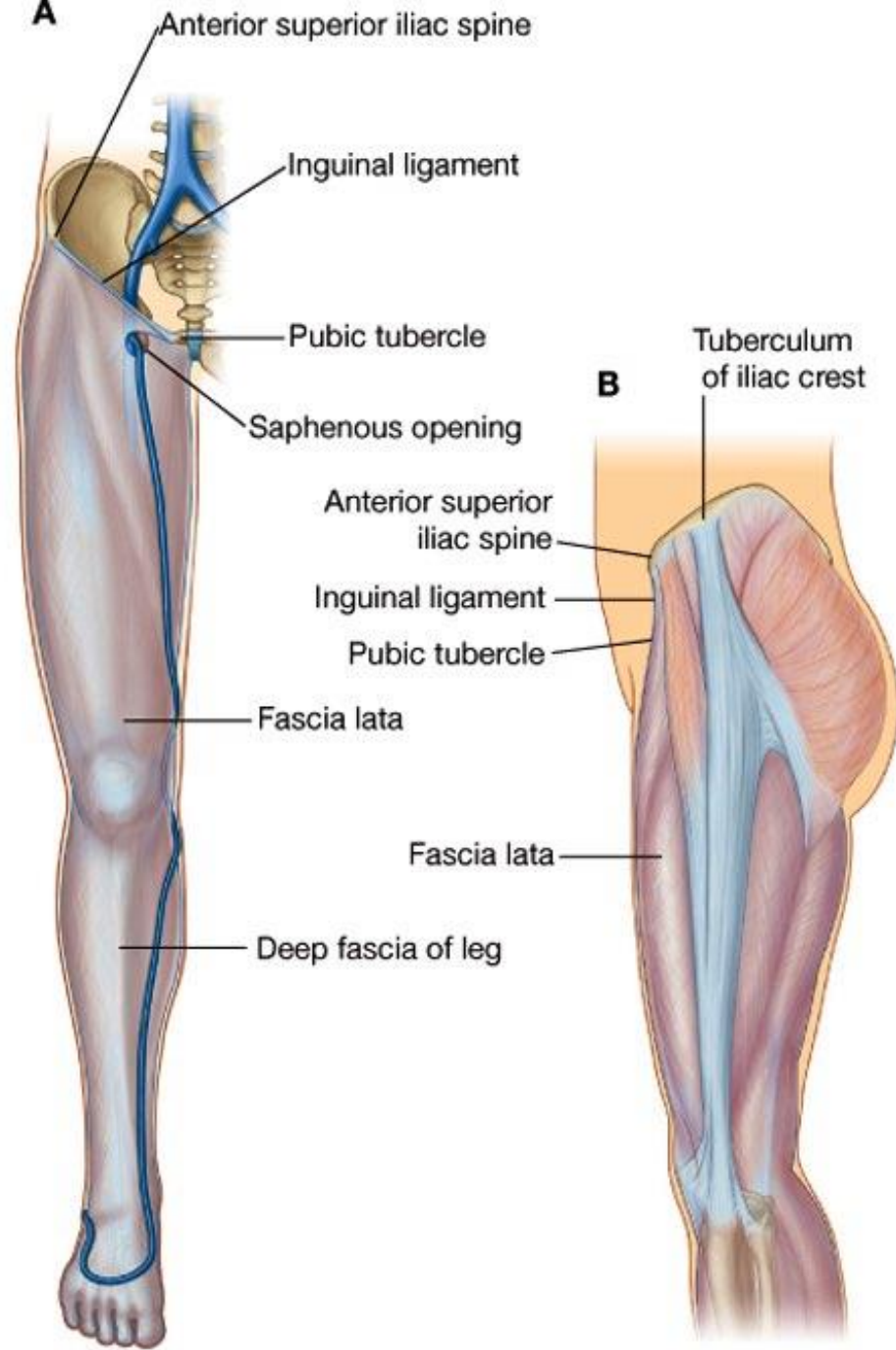
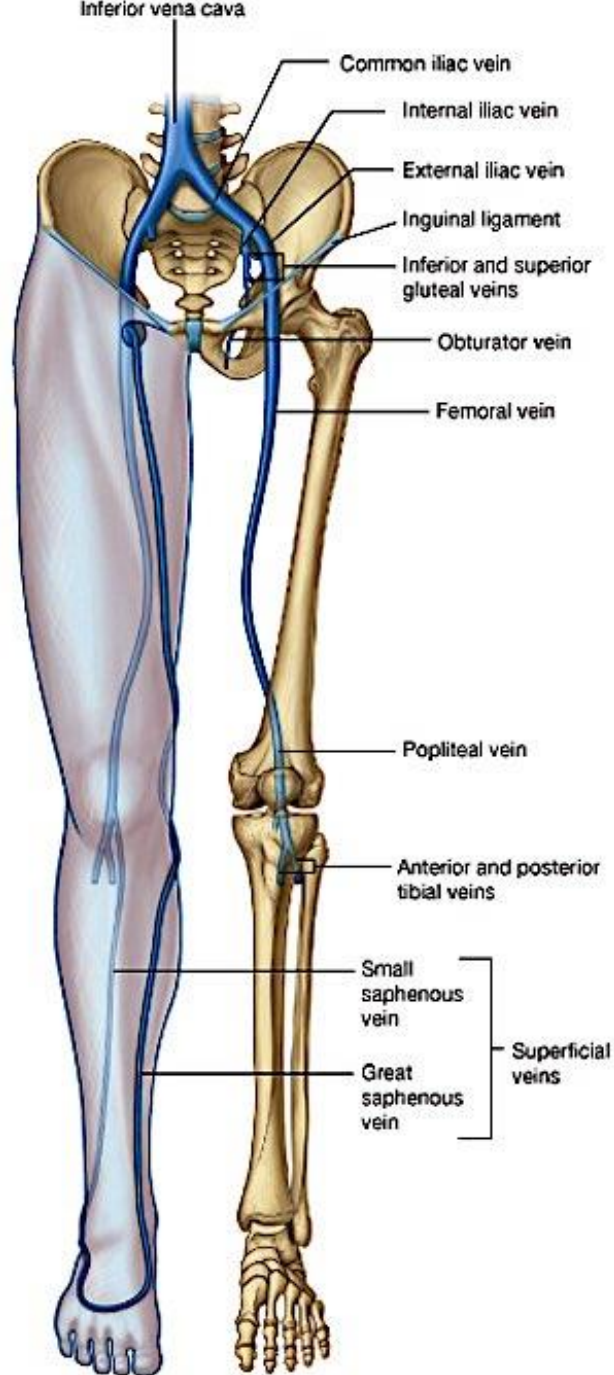
- fibular artery
- *lateral malleolar branch*
- medial malleolar branch
- lateral and medial plantar arteries
- *plantar metatarsal arteries*

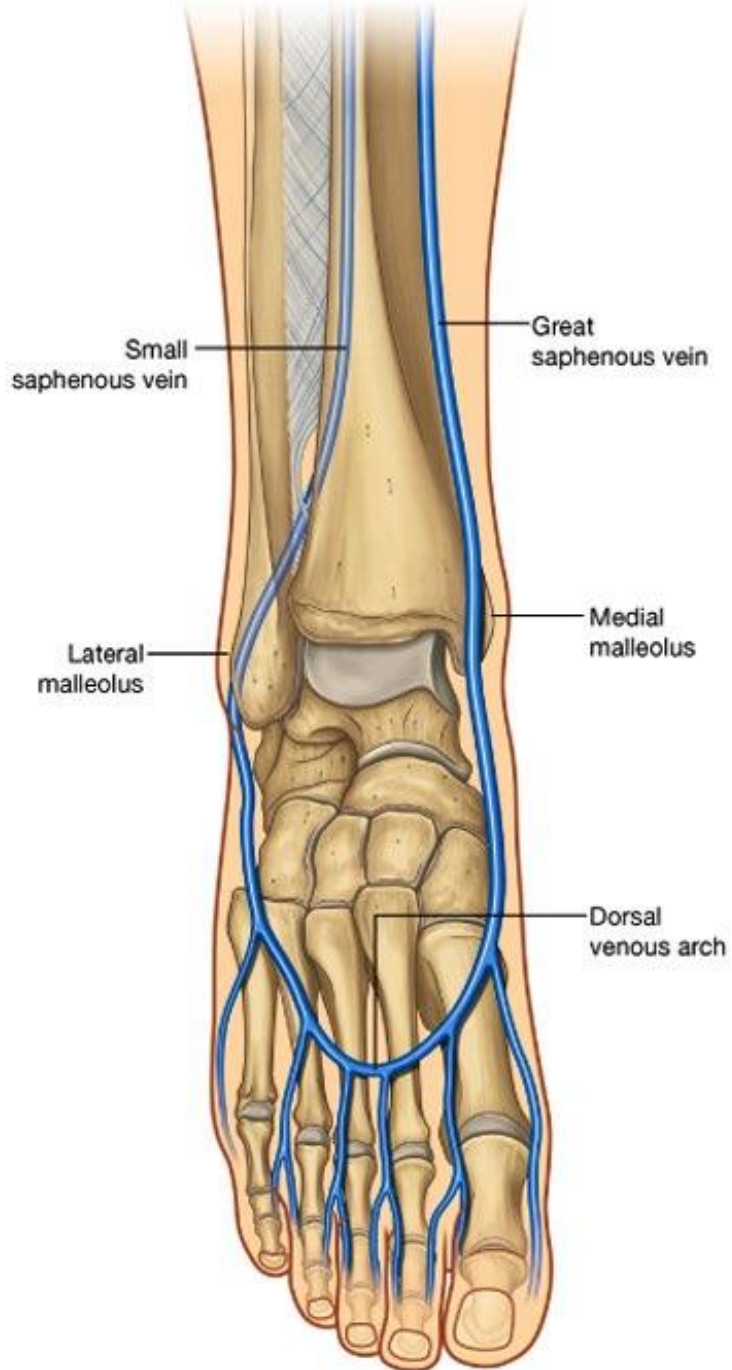


### anterior tibial artery:

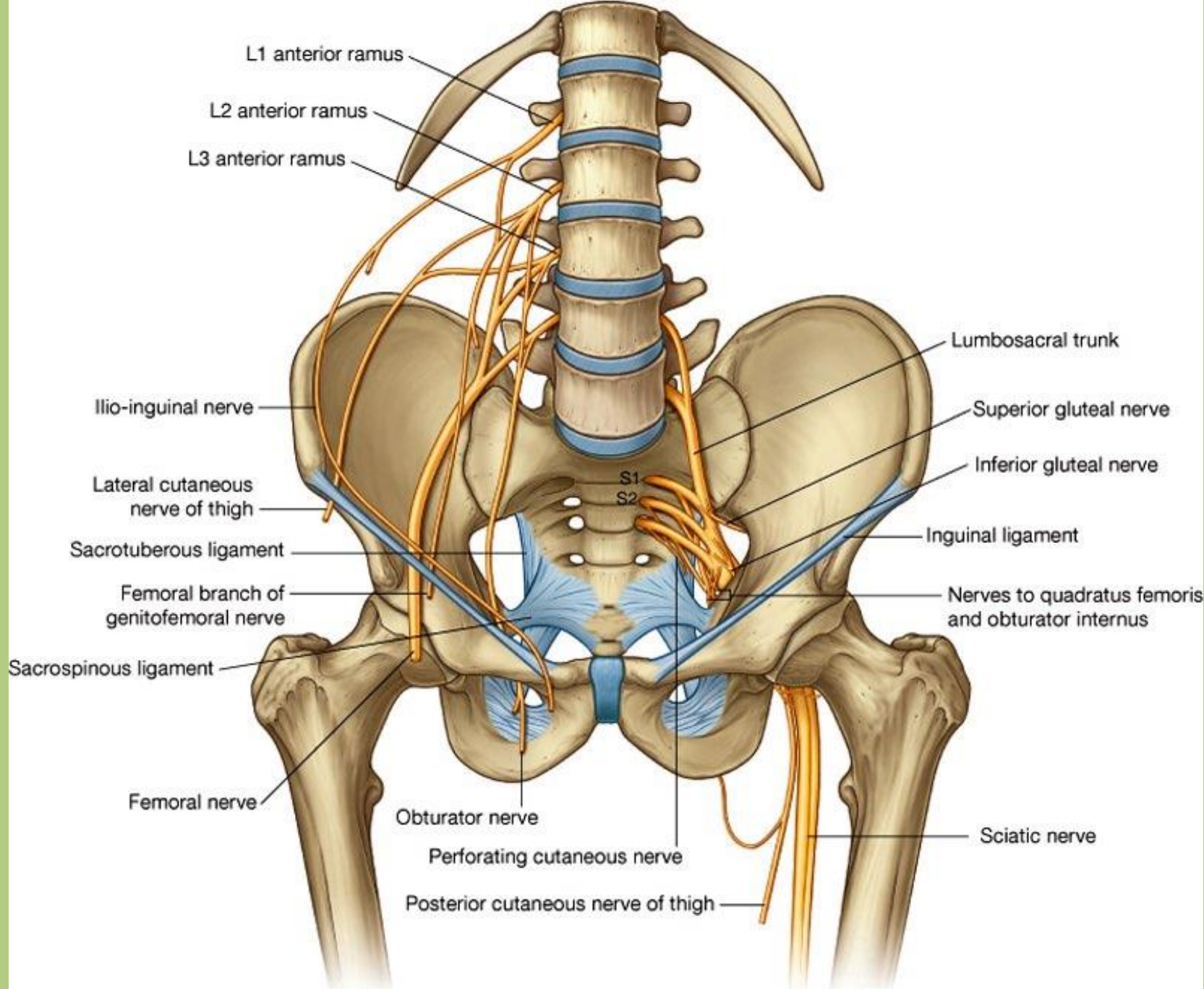
- anterior medial and anterior lateral malleolar arteries
  - dorsal pedal (dorsalis pedis) artery
- lateral and medial tarsal arteries, forming the arcuate artery with dorsal metatarsal arteries*



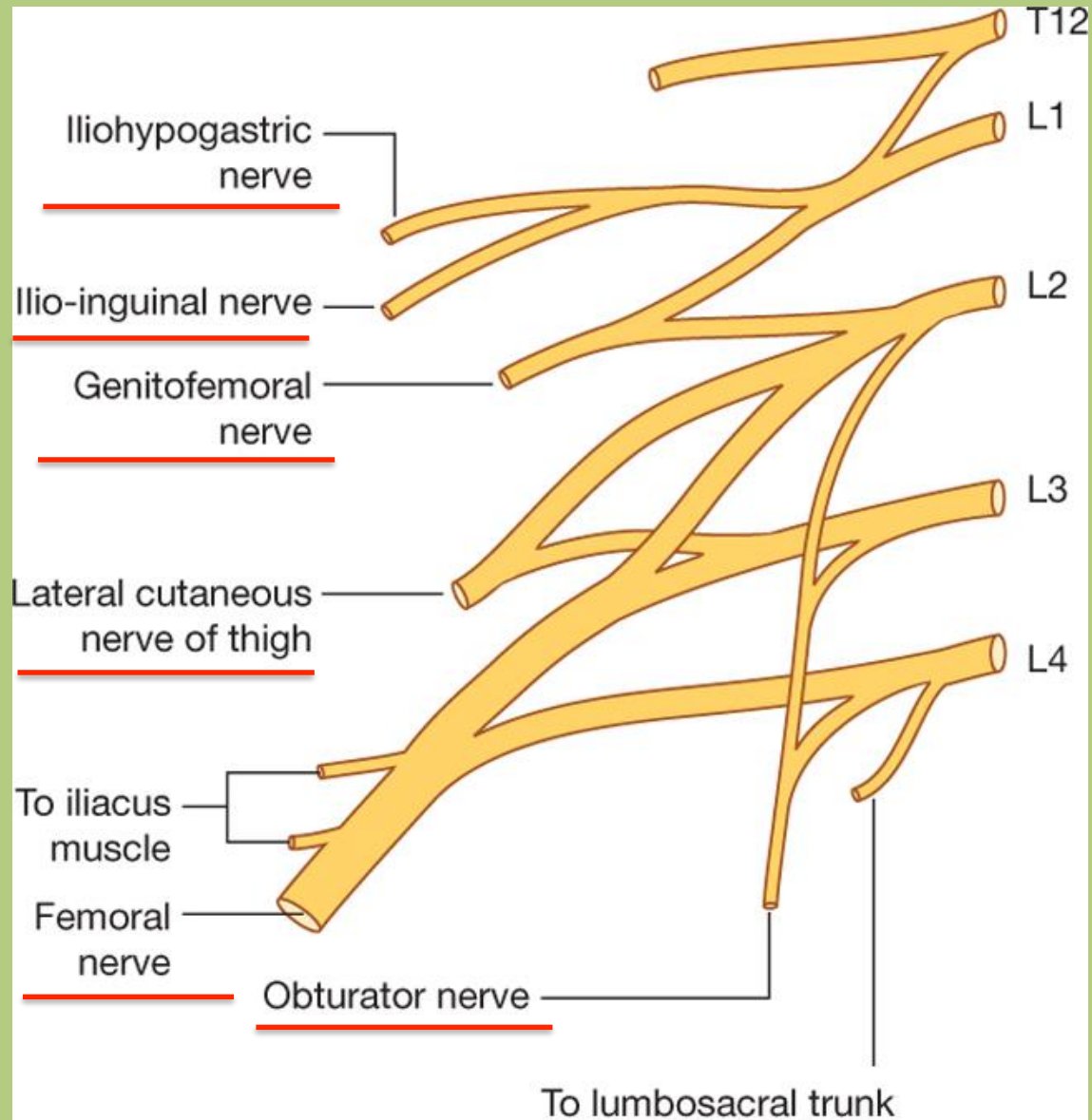




# Nerves of the lower limb



# Plexus lumbalis

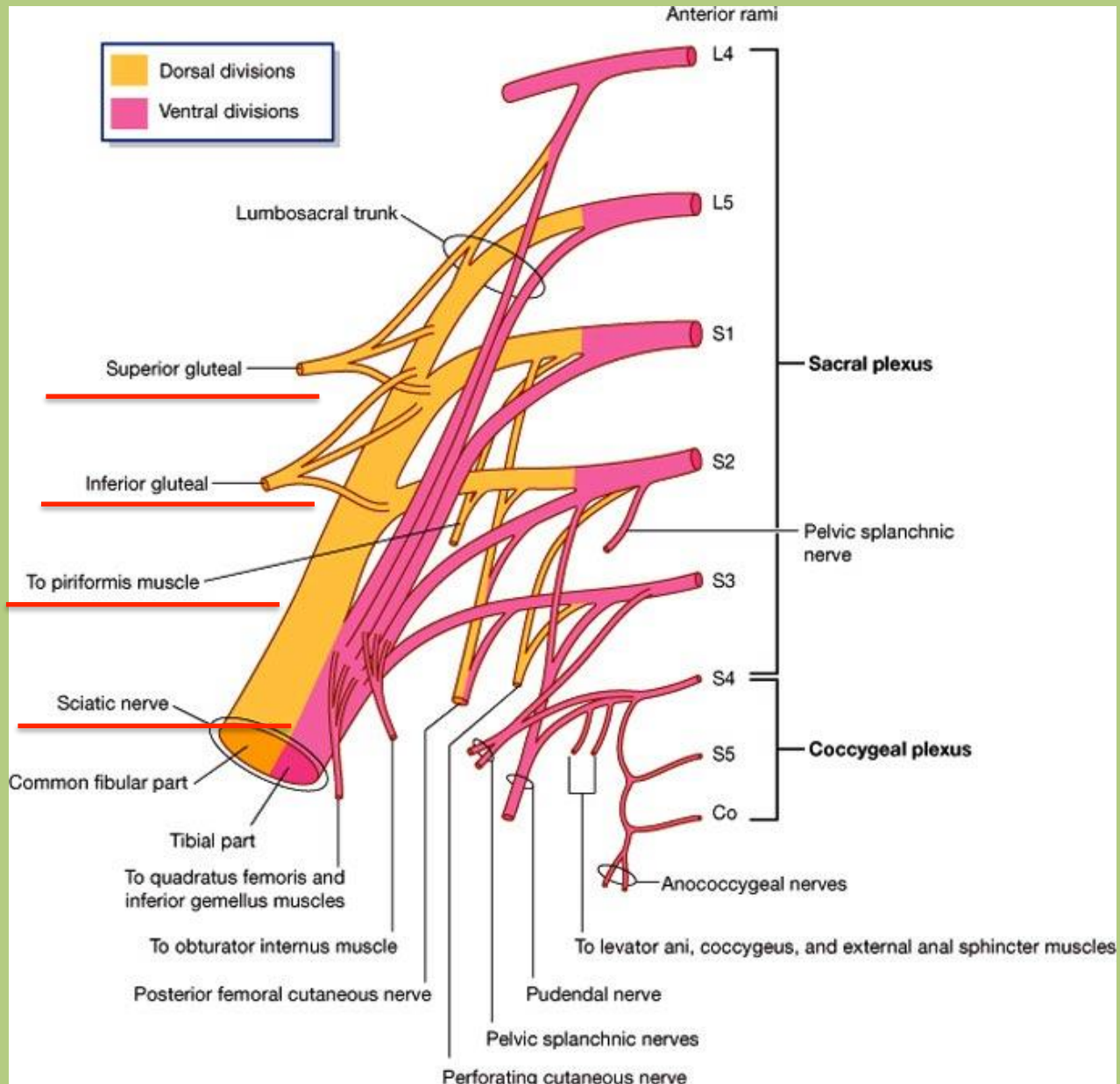


Drake: Gray's Anatomy for Students, 2nd Edition.

Copyright © 2009 by Churchill Livingstone, an imprint of Elsevier, Inc. All rights reserved.

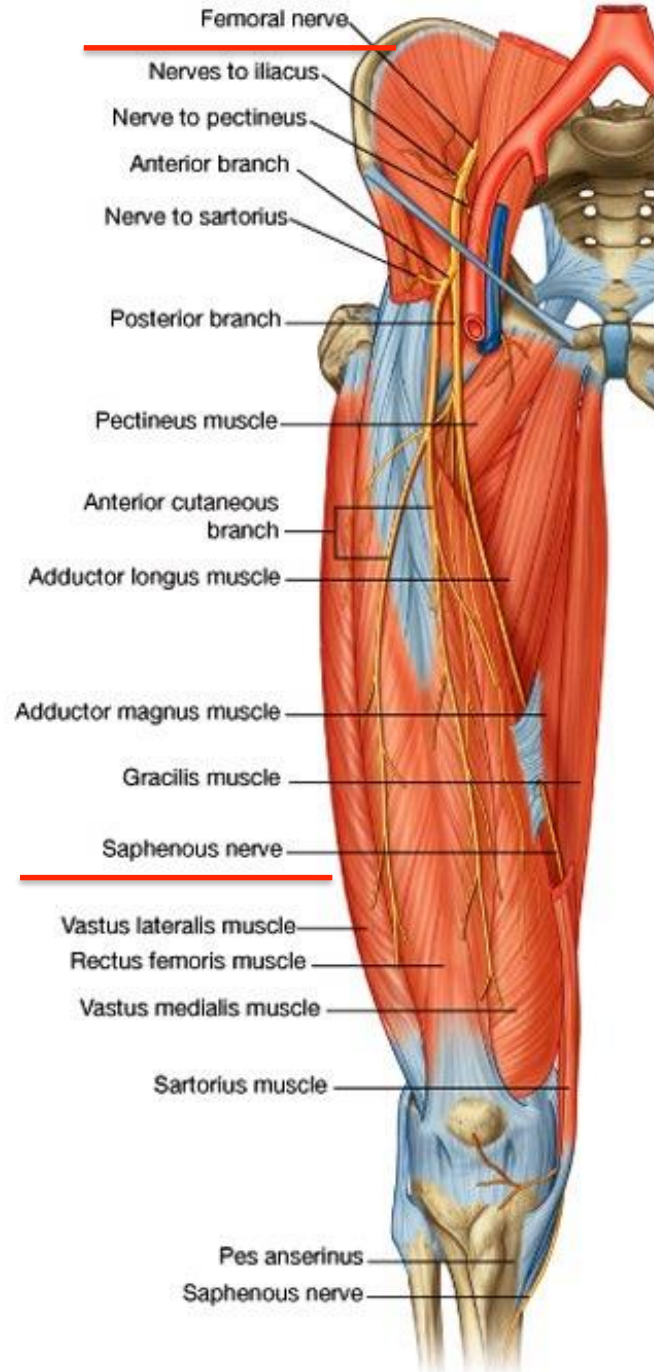


# Sacral plexus

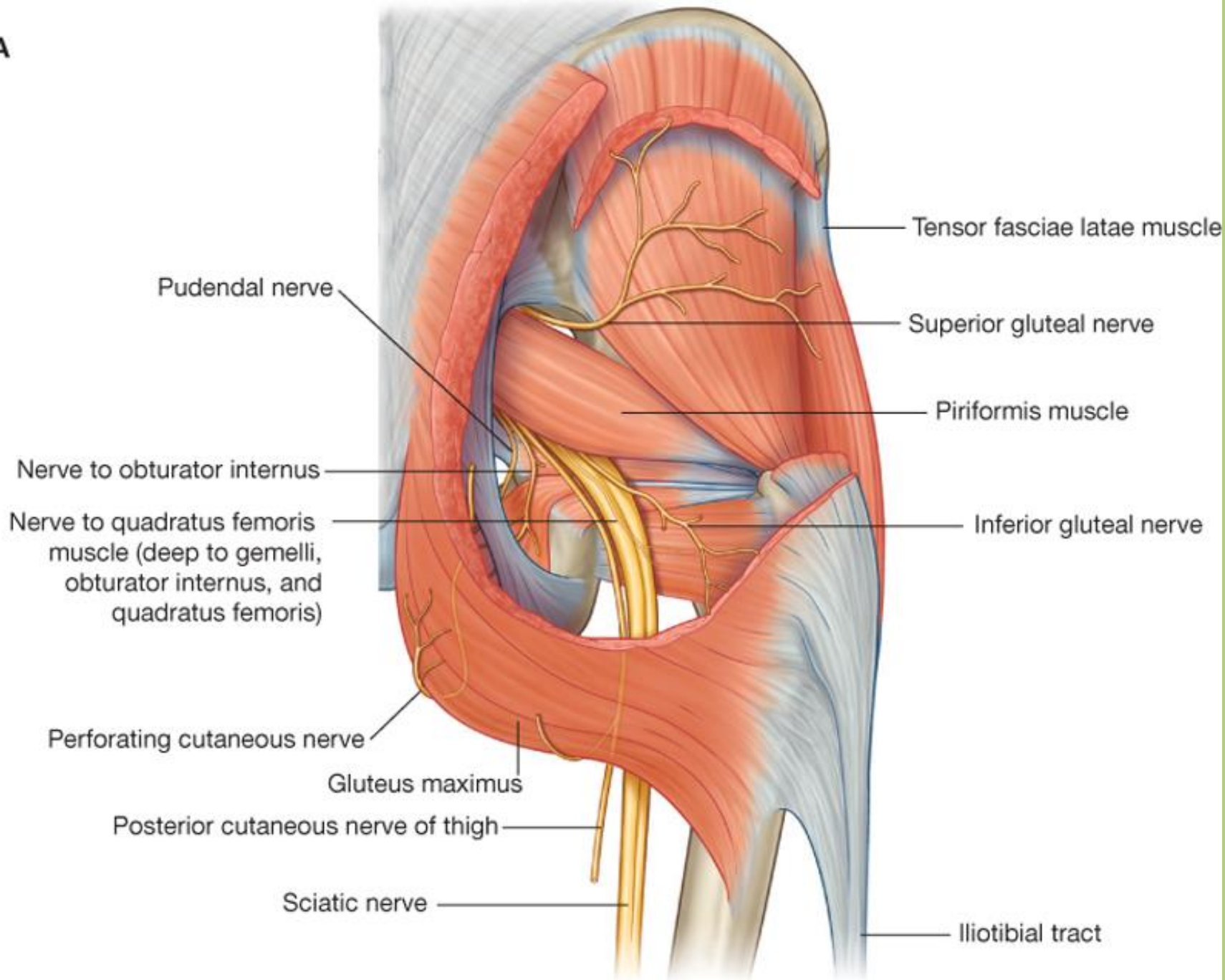


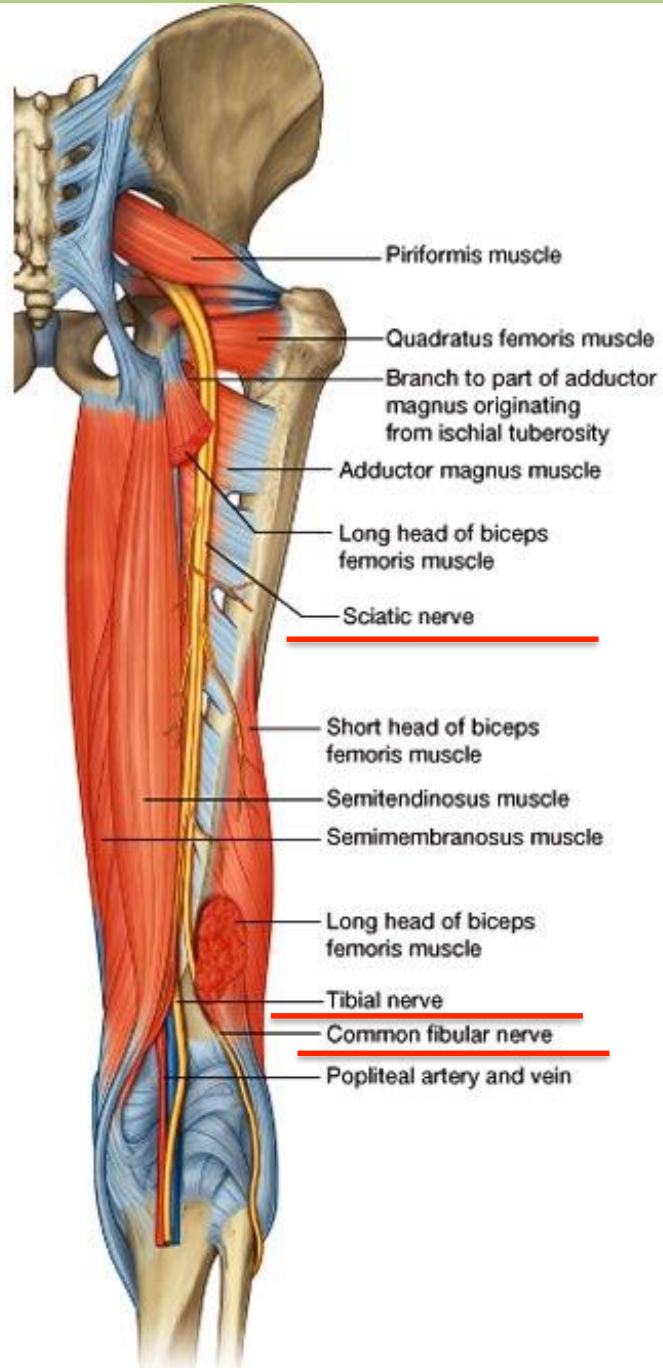
Drake: Gray's Anatomy for Students, 2nd Edition.

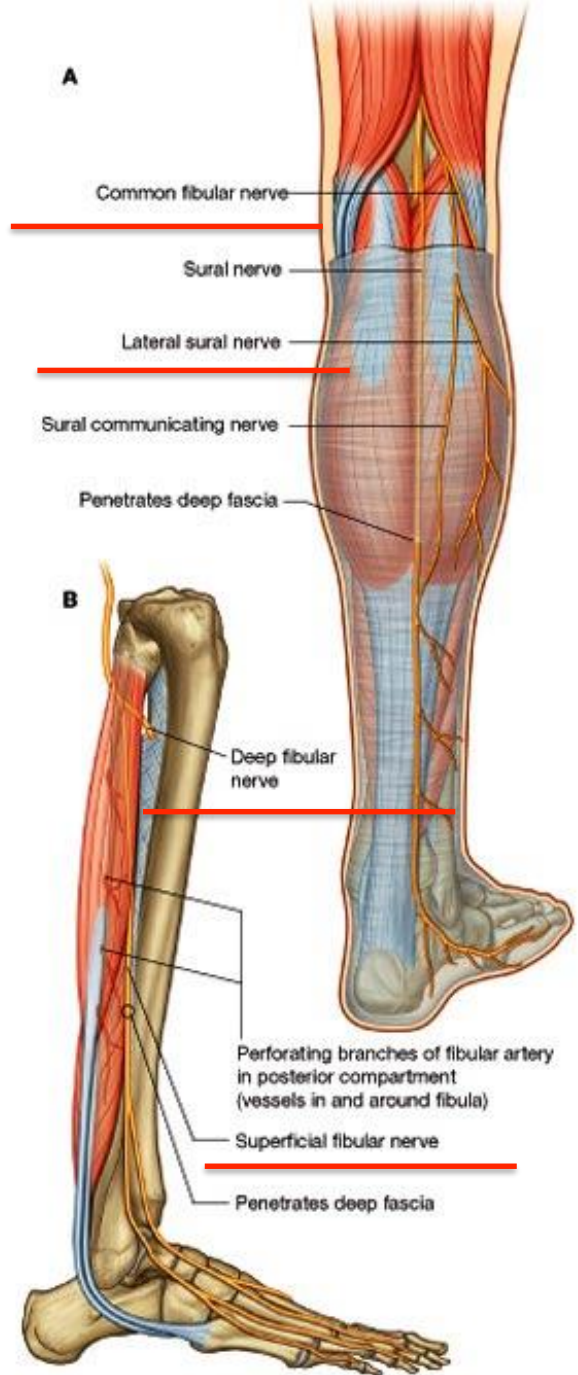
Copyright © 2009 by Churchill Livingstone, an imprint of Elsevier, Inc. All rights reserved.

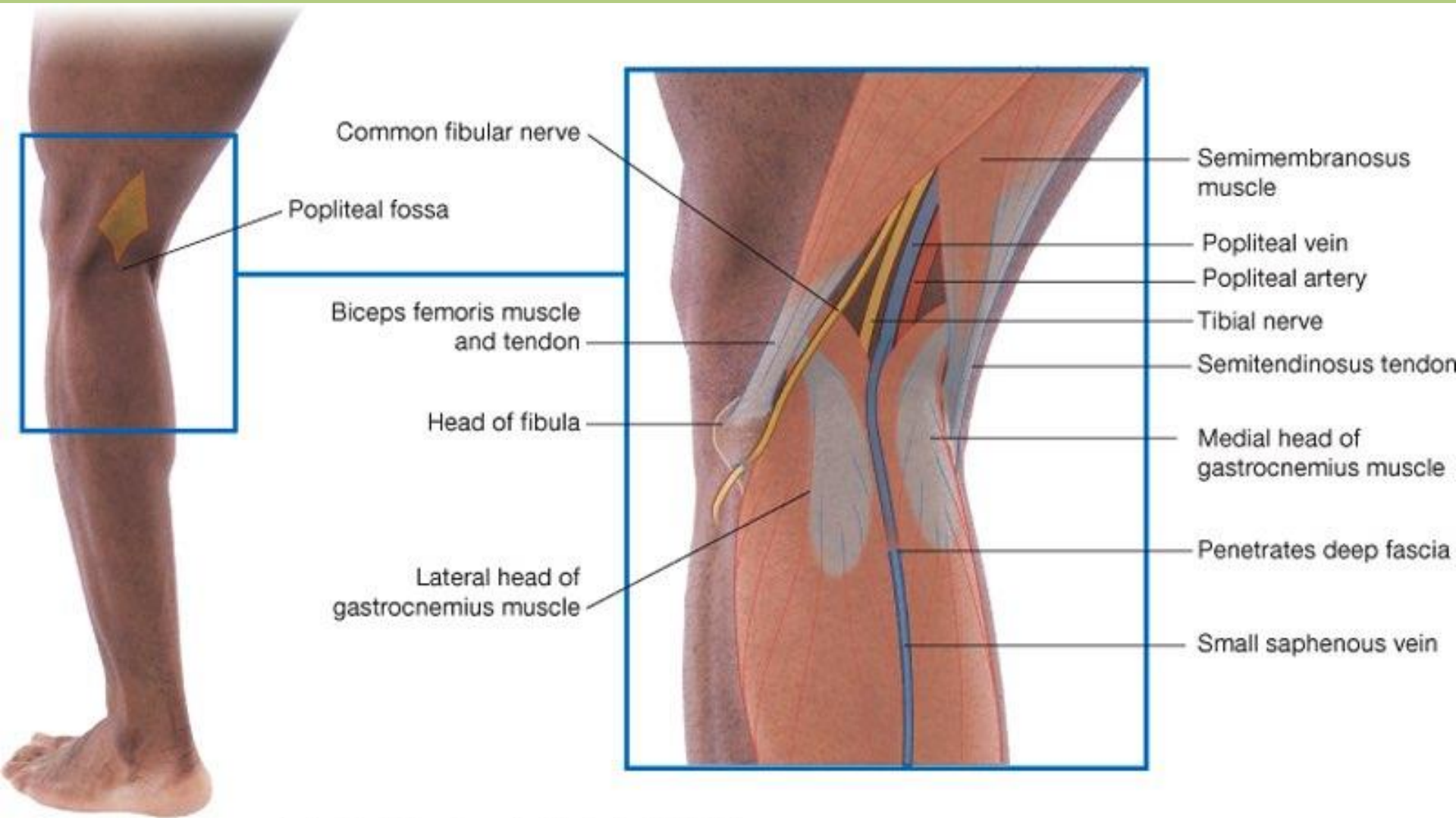


A





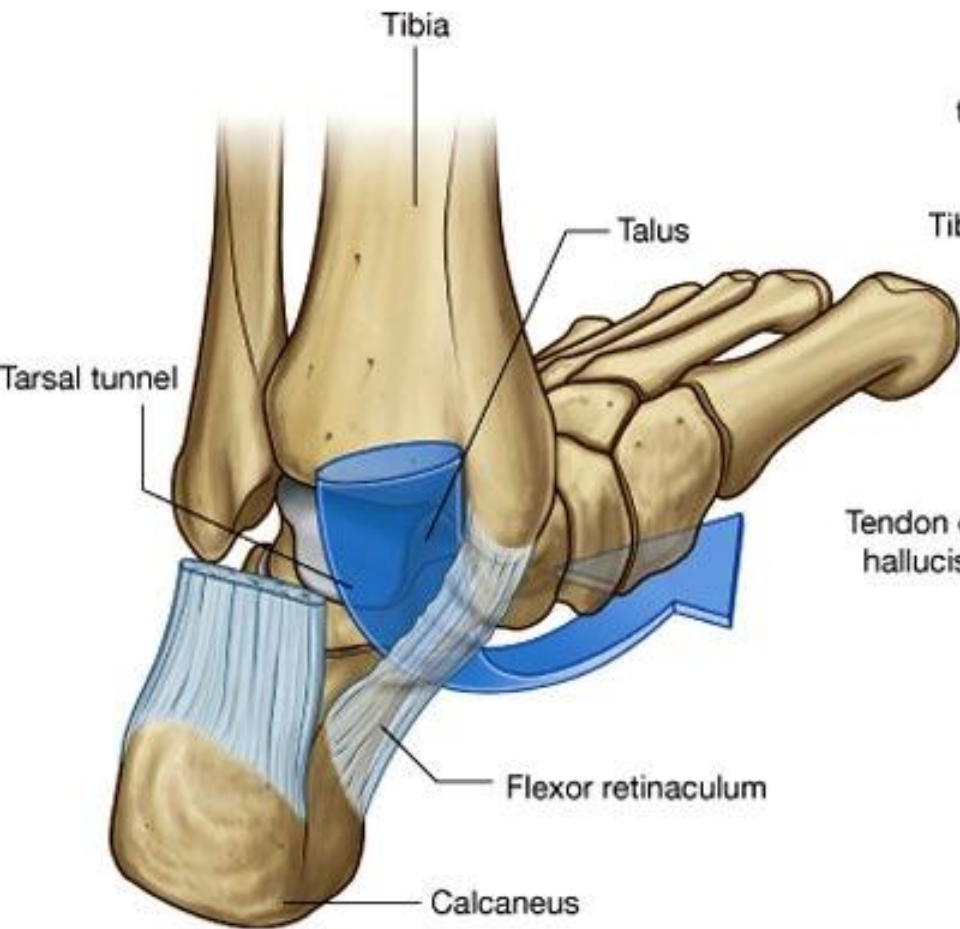




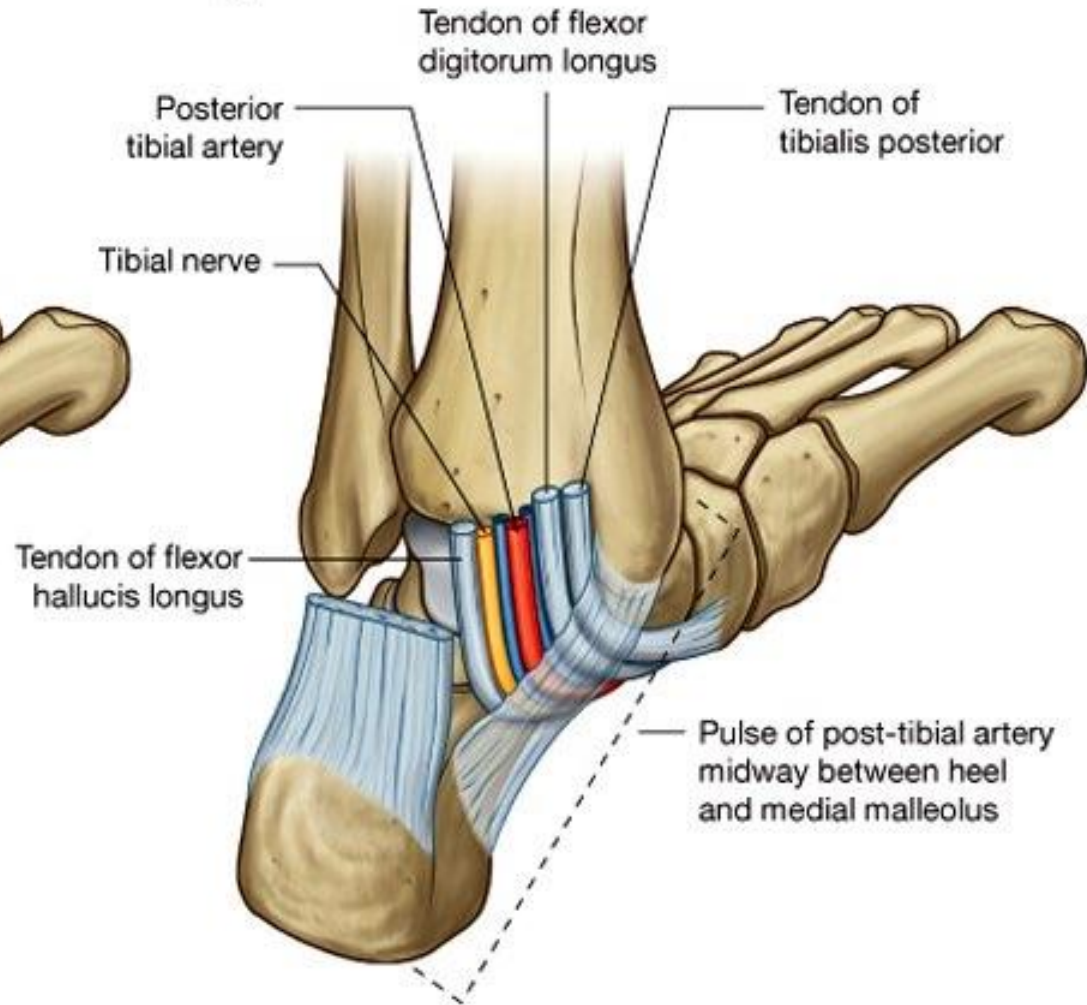
Drake: Gray's Anatomy for Students, 2nd Edition.

Copyright © 2009 by Churchill Livingstone, an imprint of Elsevier, Inc. All rights reserved.

**A**

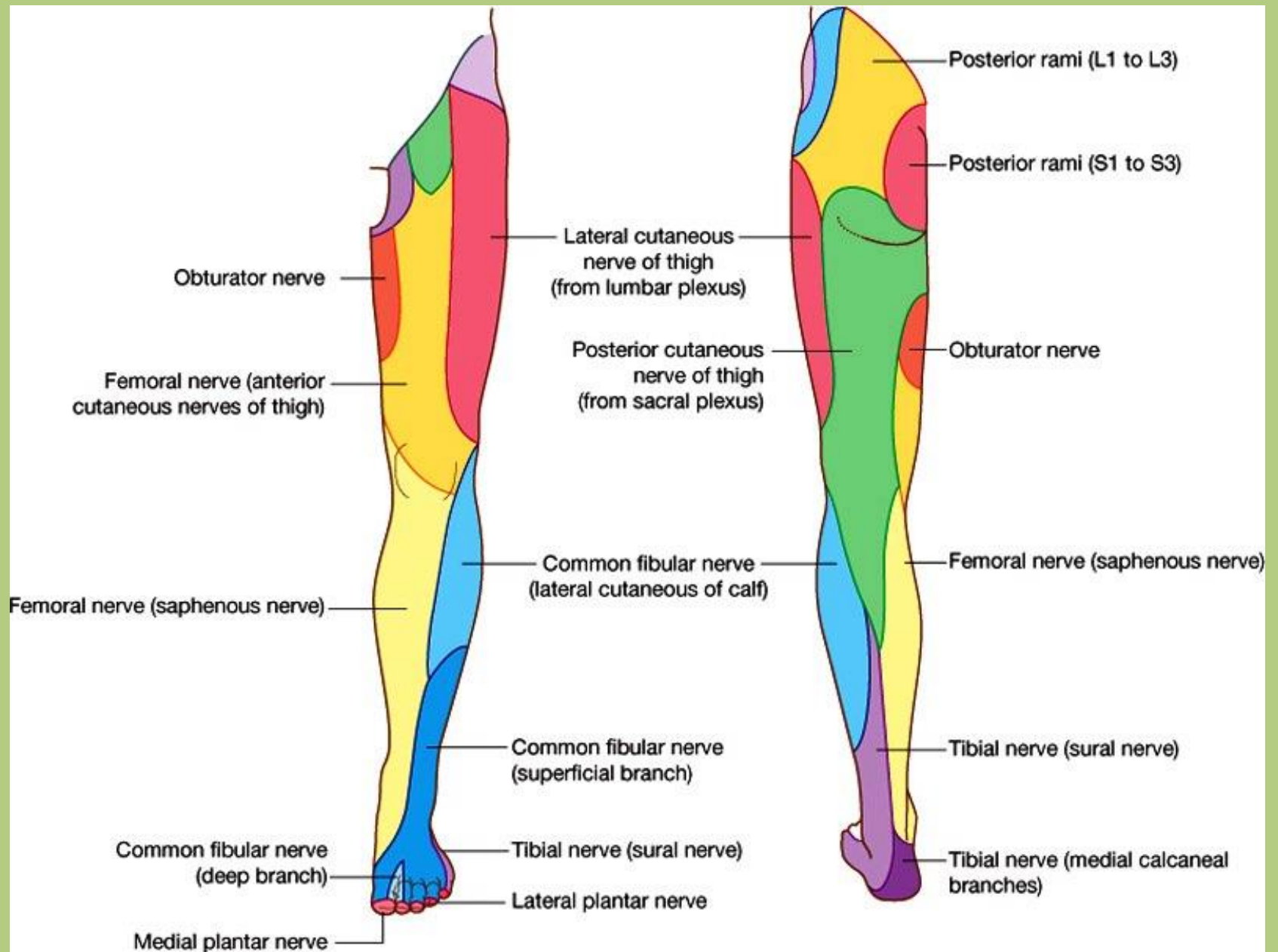


**B**



Drake: Gray's Anatomy for Students, 2nd Edition.

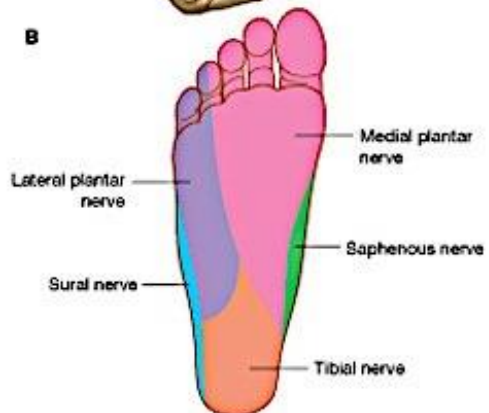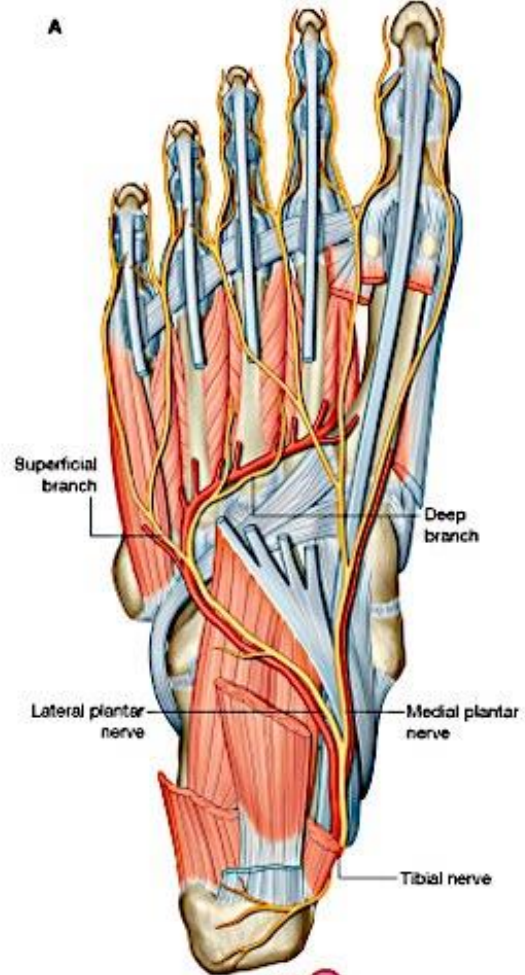
Copyright © 2009 by Churchill Livingstone, an imprint of Elsevier, Inc. All rights reserved.

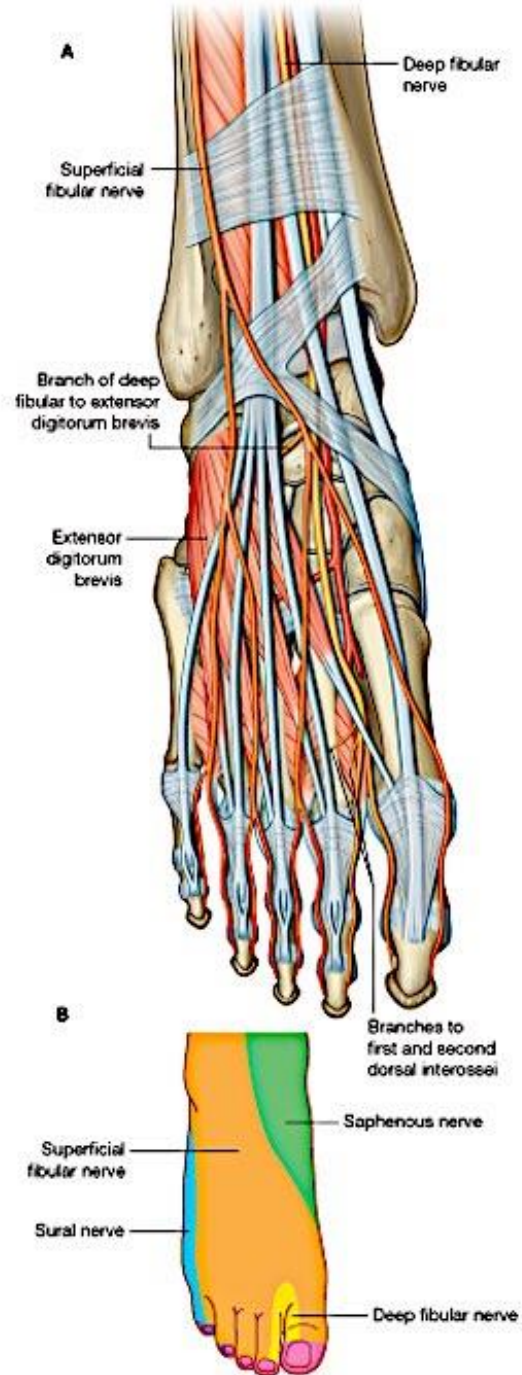


Drake: Gray's Anatomy for Students, 2nd Edition.

Copyright © 2009 by Churchill Livingstone, an imprint of Elsevier, Inc. All rights reserved.







Thank you for your attention.



References:

Drake: Gray's Anatomy for Students, 2nd ed.

Standring: Gray's Anatomy, 39th ed.