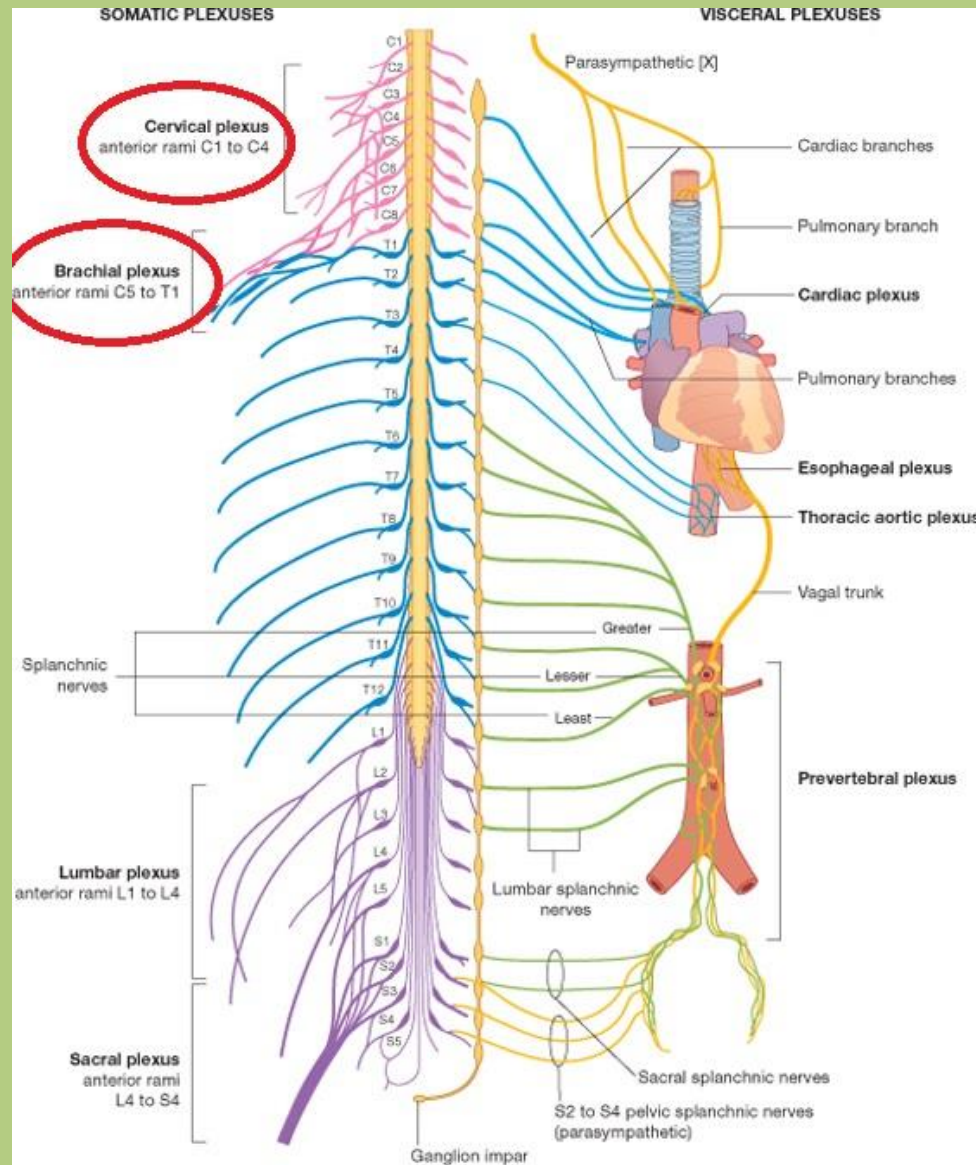




# Innervation and blood supply of the upper limb. Carpal tunnel.

Sándor Katz M.D., Ph.D.

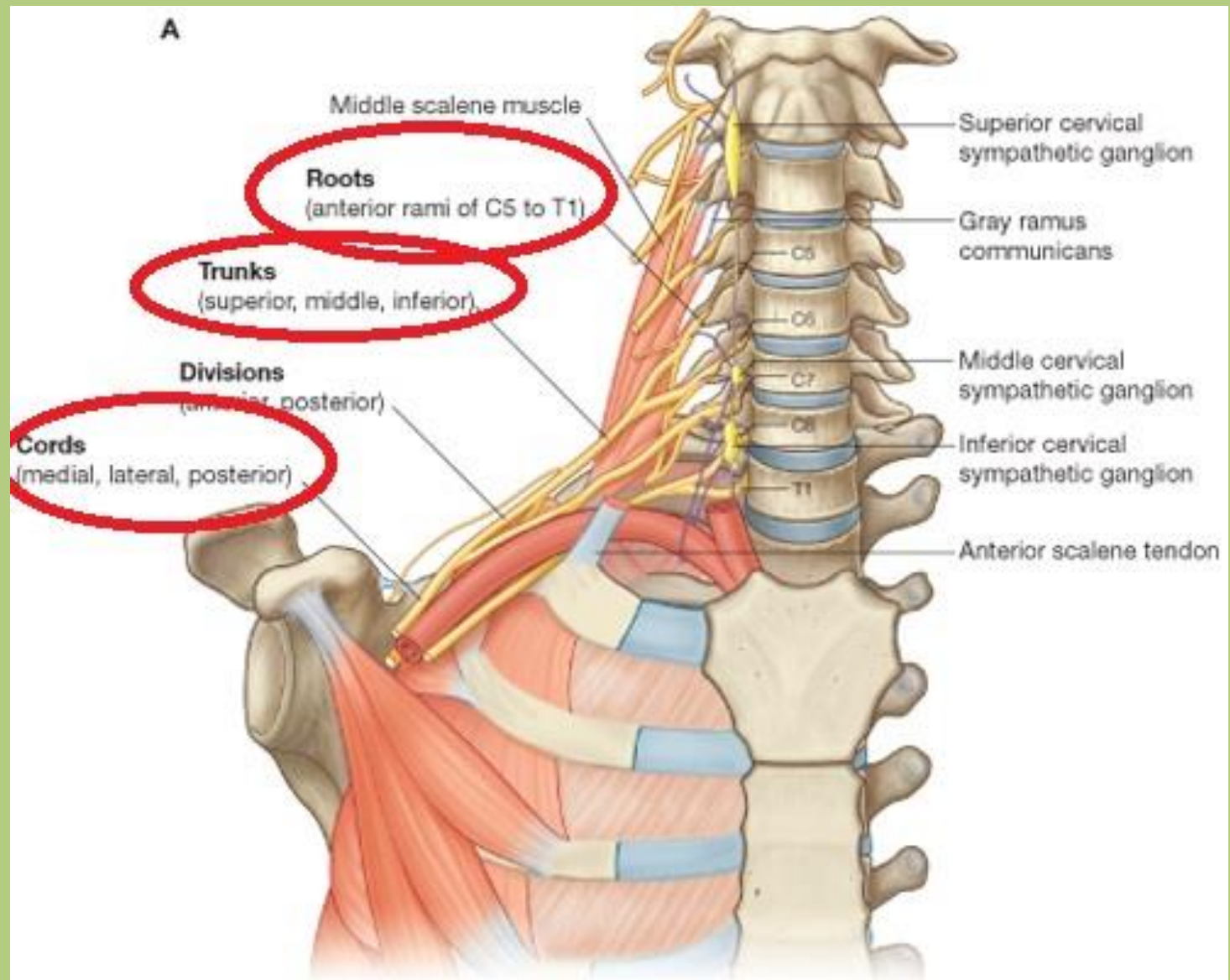
# Spinal nerves



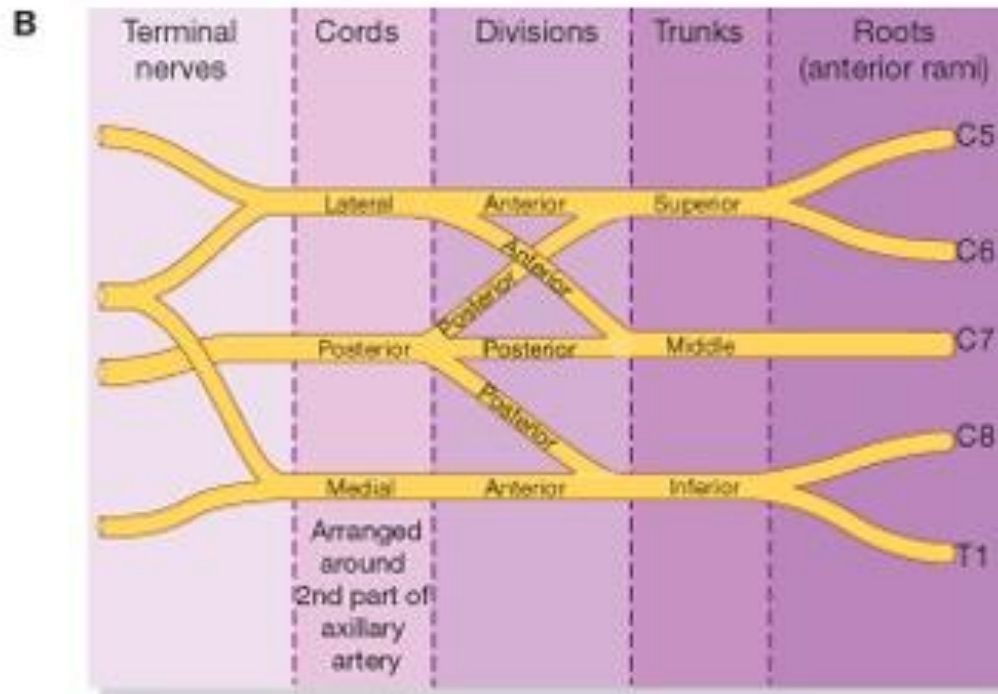
Drake: Gray's Anatomy for Students, 2nd Edition.

Copyright © 2009 by Churchill Livingstone, an imprint of Elsevier, Inc. All rights reserved.

# Brachial plexus

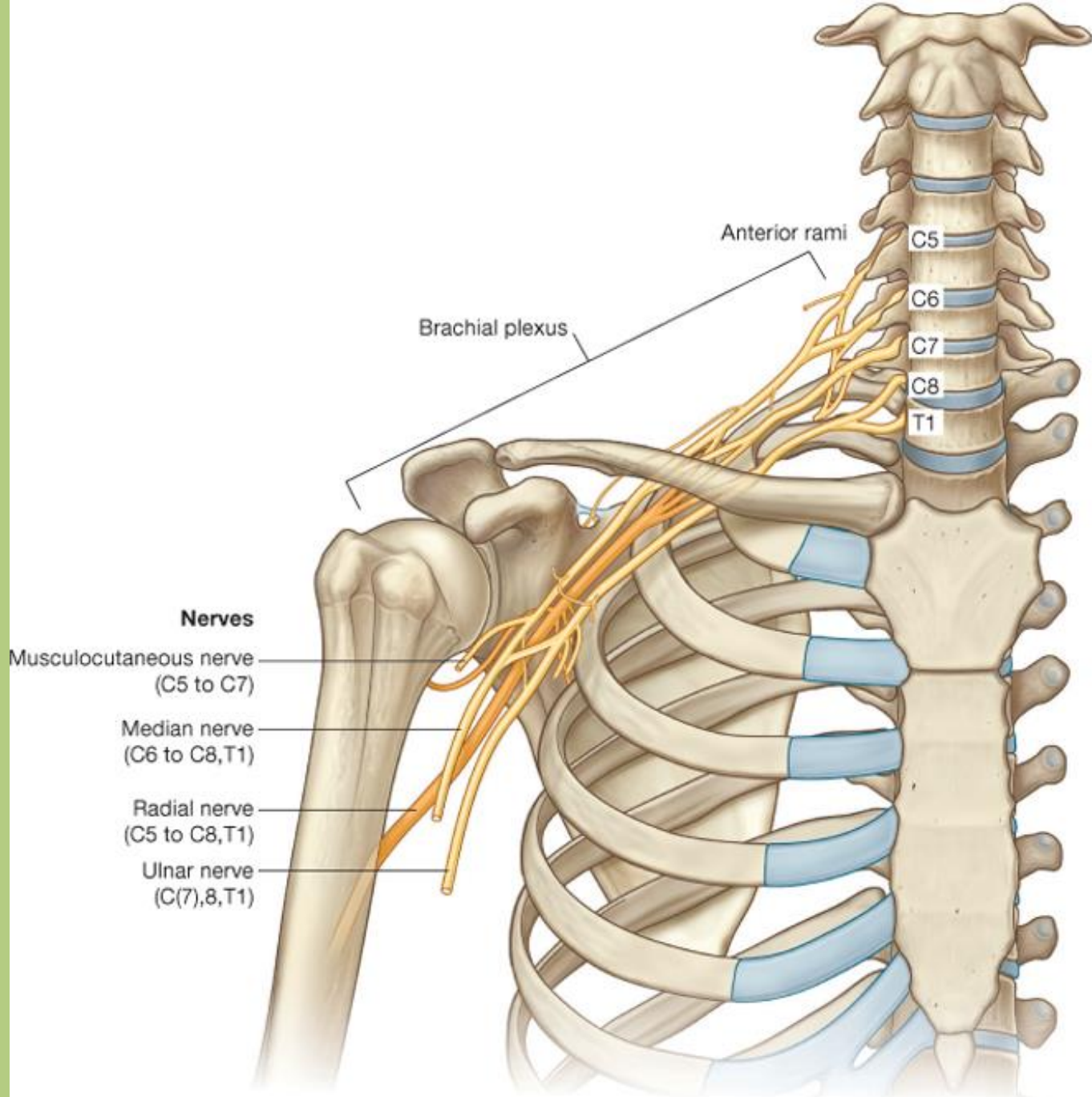


# Brachial plexus



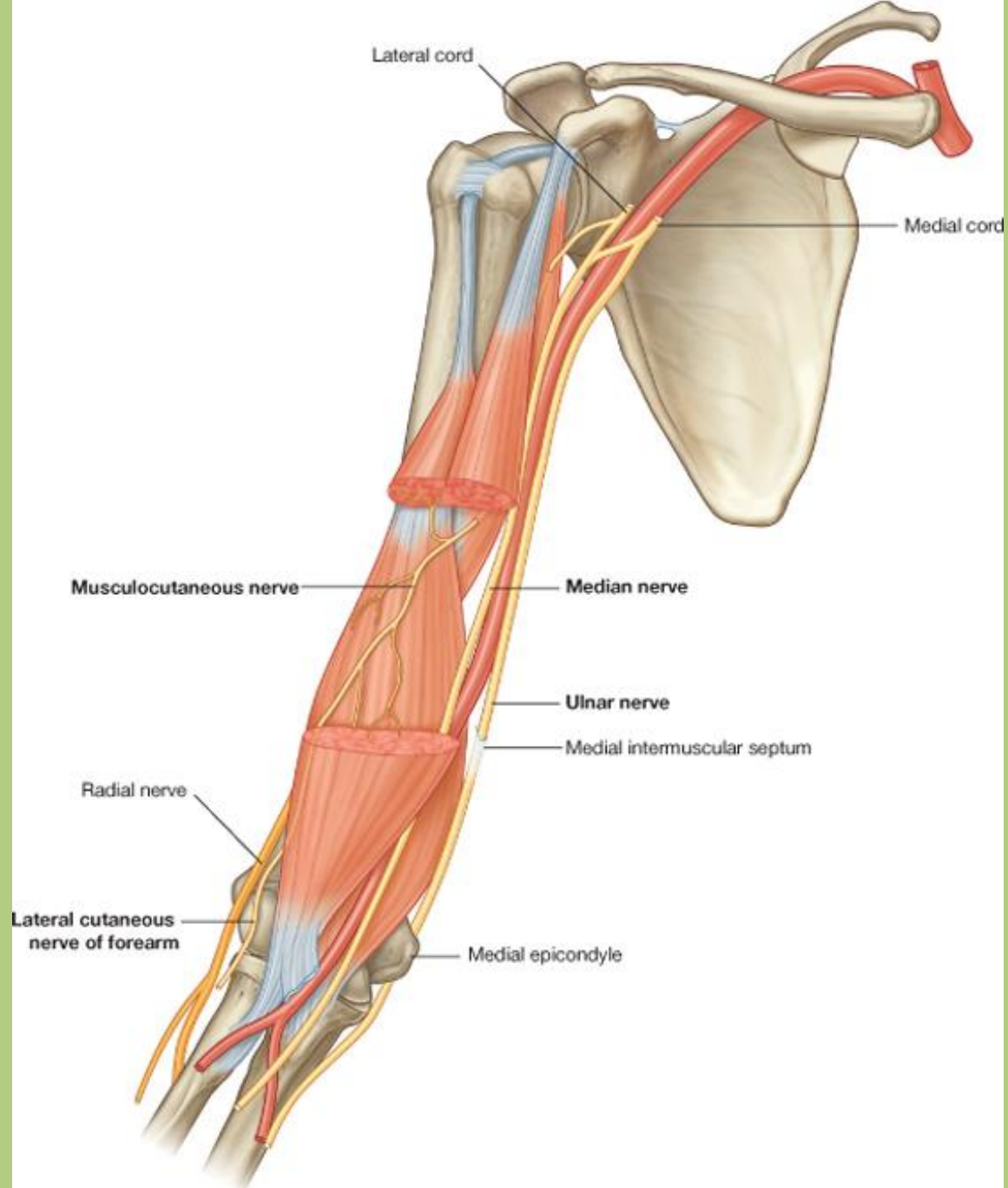
Drake: Gray's Anatomy for Students, 2nd Edition.

Copyright © 2009 by Churchill Livingstone, an imprint of Elsevier, Inc. All rights reserved.



# Lateral cord

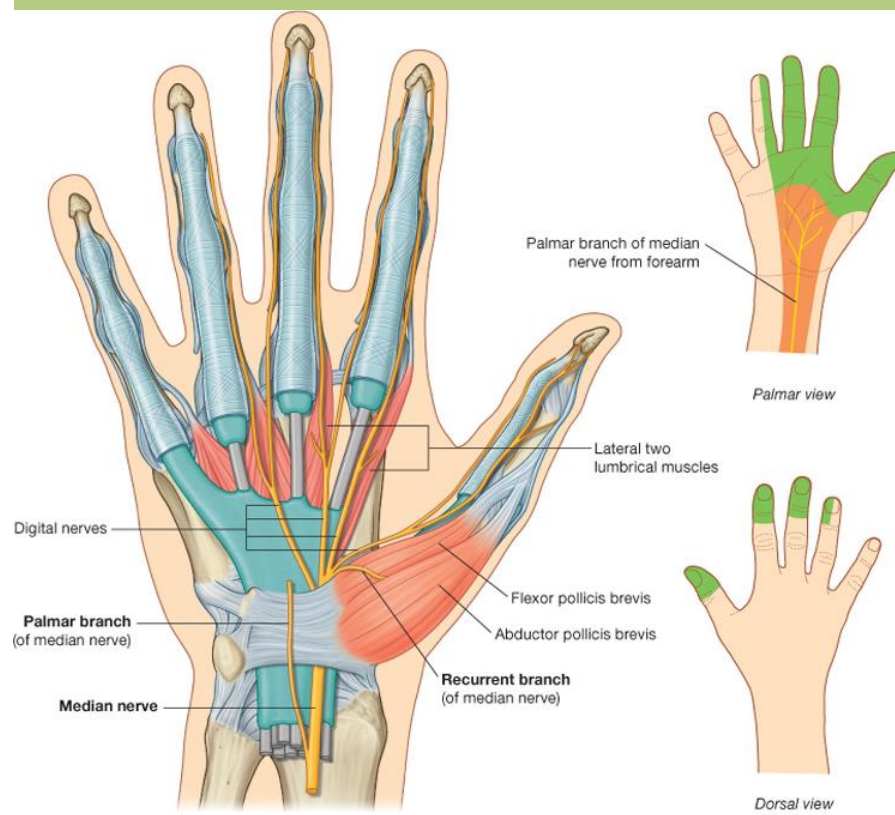
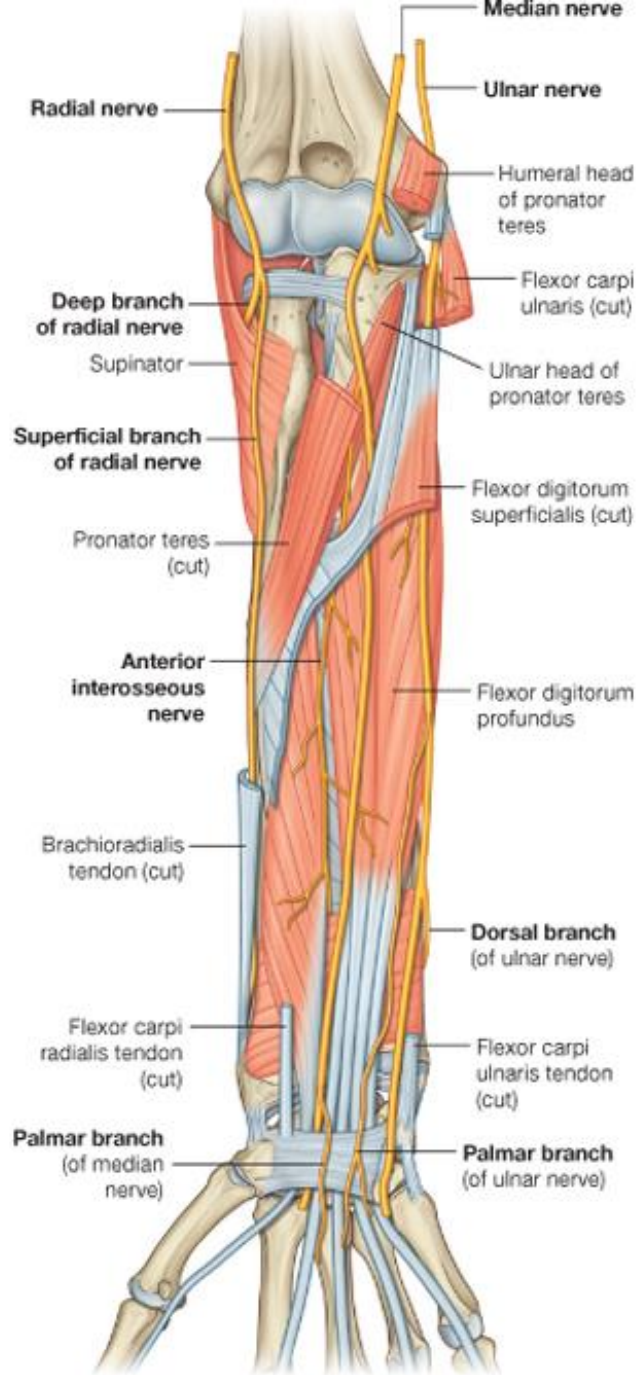
- **Musculocutaneous nerve:**
- perforates the coracobrachialis muscle
- runs between the biceps brachii and brachialis muscles
- its sensory end-branch is the *lateral antebrachial cutaneous nerve*
  
- *Motor innervation:* flexors muscles of the arm
- *Skin innervation:* (lateral antebrachial cutaneous nerve)  
lateral part of the forearm



# Lateral cord

- **Median nerve (lateral part):**
- runs in the *medial bicipital groove lateral to the brachial artery*
- passes between the two heads of the pronator teres
- in the forearm it runs between the flexor digitorum superficialis and profundus
- *it passes through the carpal tunnel*
  
- ***Motor innervation:*** majority of the flexor muscles of forearm
- ***Skin innervation:*** radial part of the palm

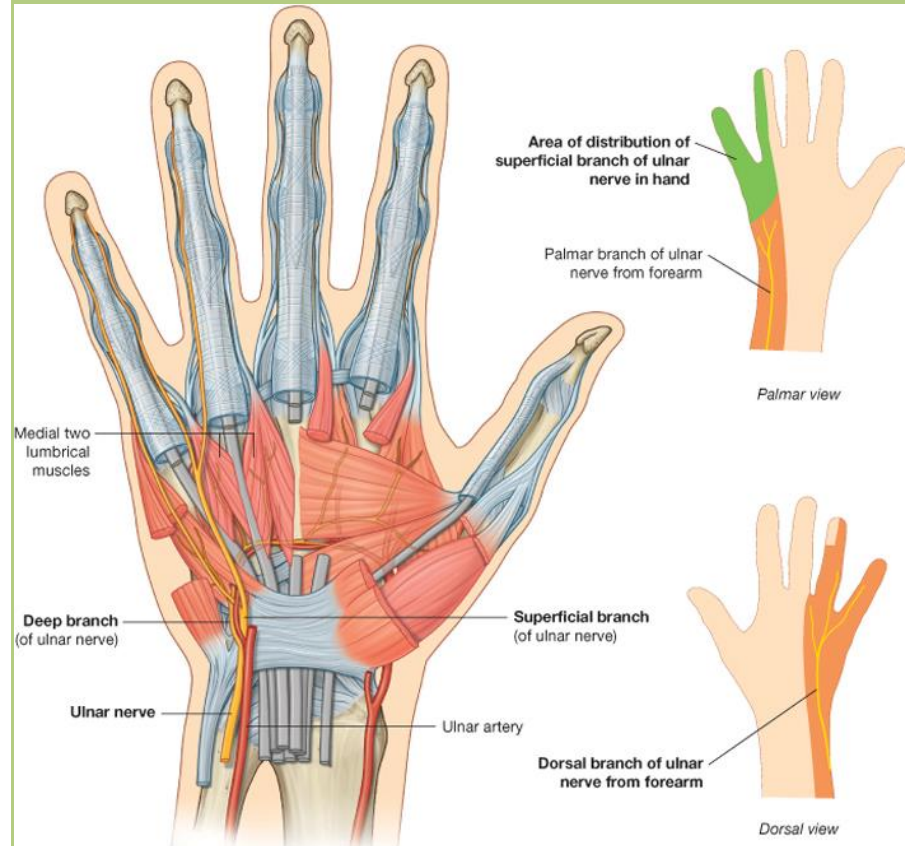
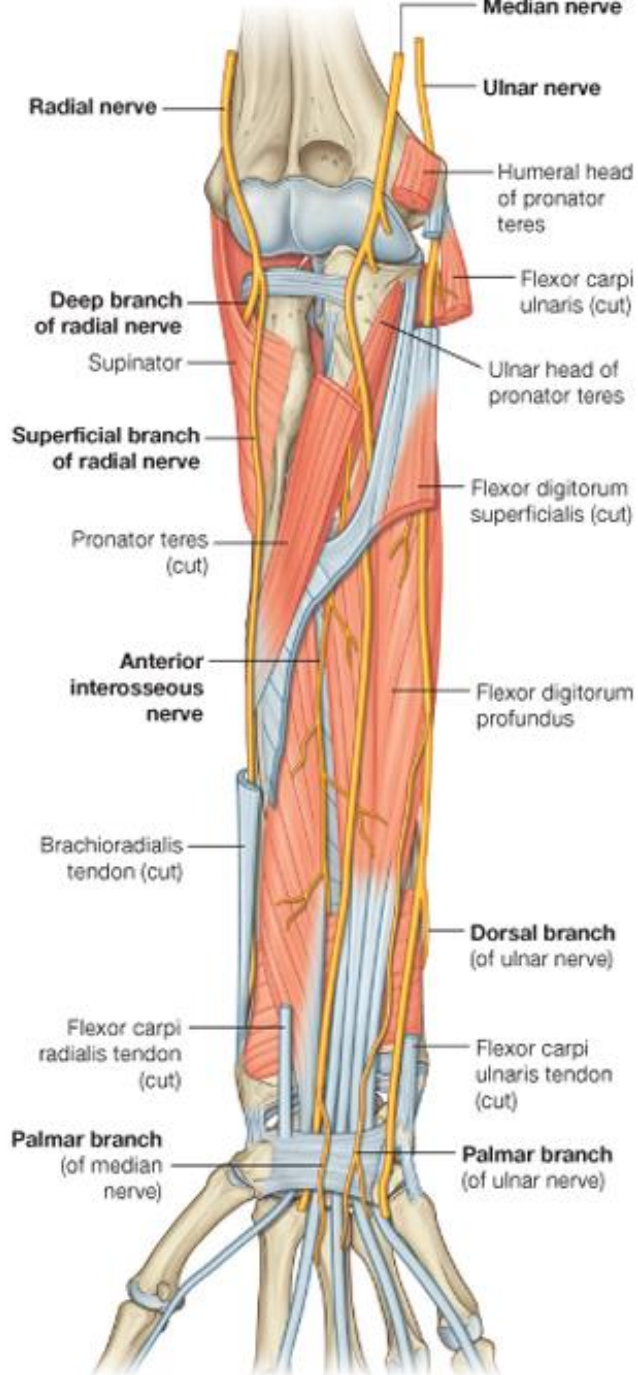




Drake: Gray's Anatomy for Students, 2nd Edition.  
 Copyright © 2009 by Churchill Livingstone, an imprint of Elsevier, Inc. All rights reserved.

# Medial cord

- **Median nerve (medial part)**
- **Ulnar nerve:**
  - in the middle part of the arm it pierces the medial intermuscular septum and enters into the 'extensor muscle compartment'
  - in the elbow region it goes around the medial epicondyle (*groove for ulnar nerve*)
  - passes between the two heads of the flexor carpi ulnaris
  - runs through the *Guyon's canal* above the flexor retinaculum with the ulnar vessels
- ***Motor innervation:*** minority of the flexor muscles of forearm and majority of hand muscles
- ***Skin innervation:*** ulnar side of the hand



Drake: Gray's Anatomy for Students, 2nd Edition.  
 Copyright © 2009 by Churchill Livingstone, an imprint of Elsevier, Inc. All rights reserved.

# Medial cord

- **Medial brachial cutaneous nerve:**
  - only sensory innervation
  - medial surface of the arm
  
- **Medial antebrachial cutaneous nerve:**
  - only sensory innervation
  - medial surface of the forearm

# Posterior cord

- **Axillary nerve:**
- passes through the quadrangular space and surrounds the surgical neck of the humerus
- its sensory branch is the ***superior lateral brachial cutaneous nerve***
  
- ***Motor innervation:*** deltoid and teres minor
- ***Skin innervation:*** (superior lateral brachial cutaneous nerve) superior lateral part of the arm

# Posterior cord

- **Radial nerve:**
- locates behind the axillary and brachial arteries
- enters to the *groove for radial nerve* of humerus with the profunda (deep) brachii artery
- brachial branches:
  - posterior brachial cutaneous nerve*
  - inferior lateral brachial cutaneous nerve*
  - posterior antebrachial cutaneous nerve*

# Posterior cord

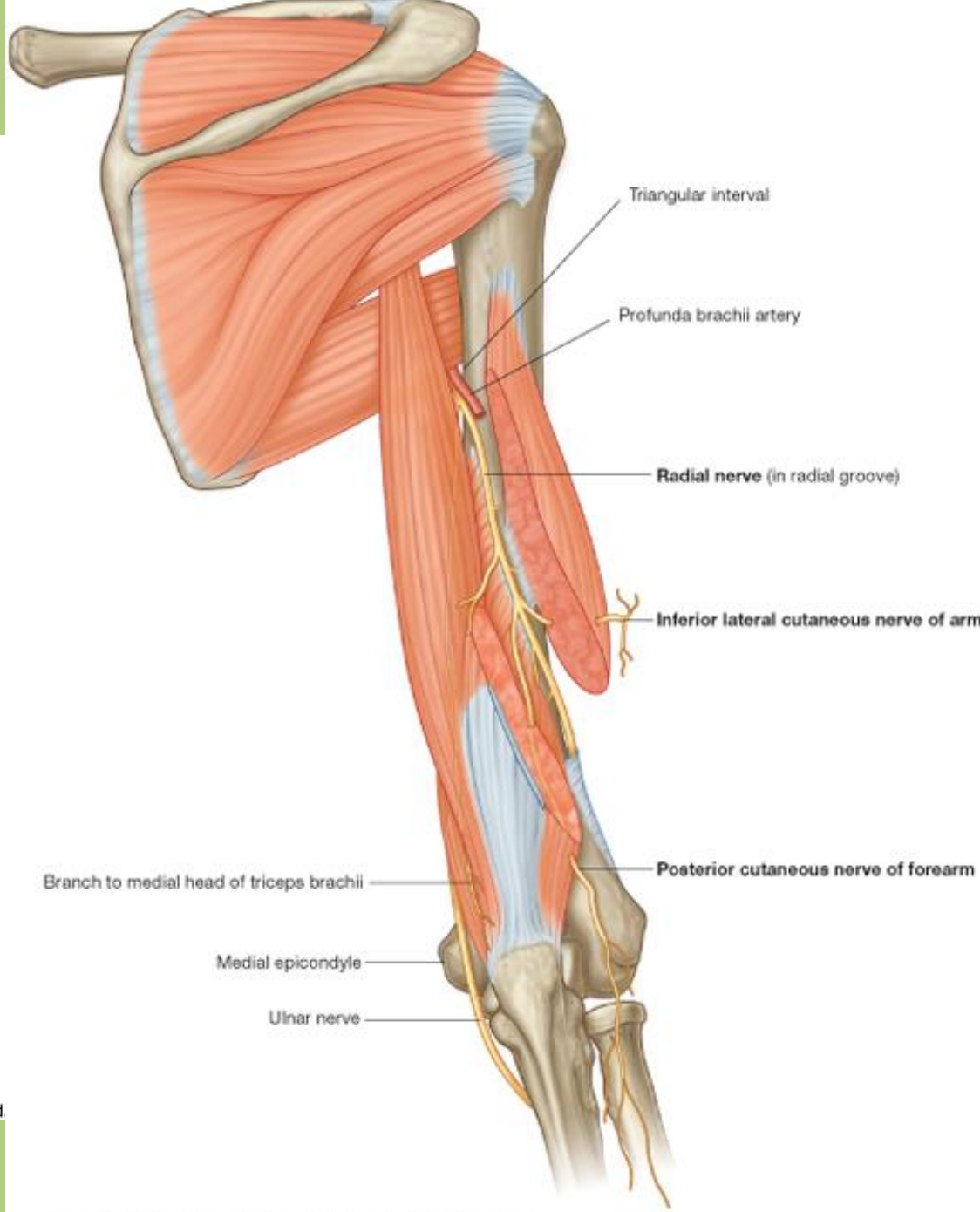
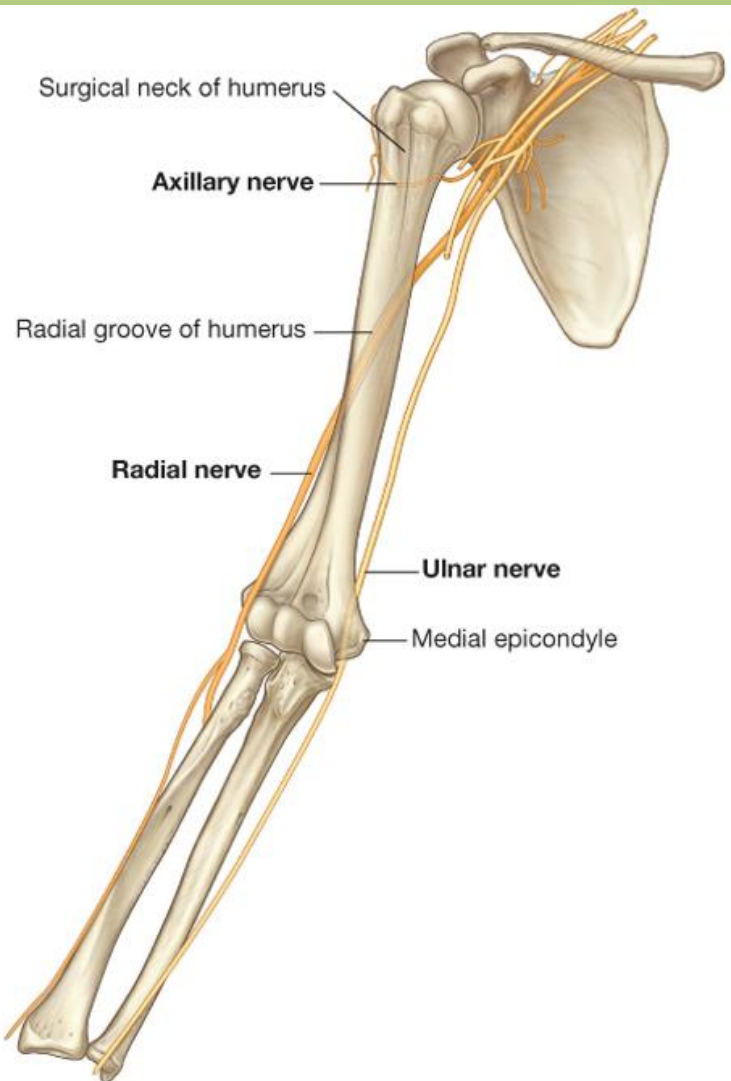
- **Radial nerve:**

- runs between the brachioradialis and brachialis muscles at the lateral part of the cubital (elbow) region and here it divides into two main branches:

*Deep branch:* motor branch, it is presented among the extensor muscles of the forearm

*Superficial branch:* only sensory innervation

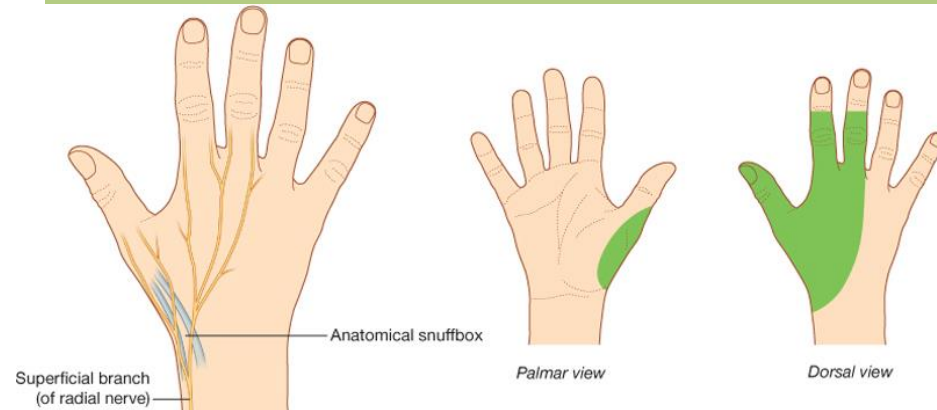
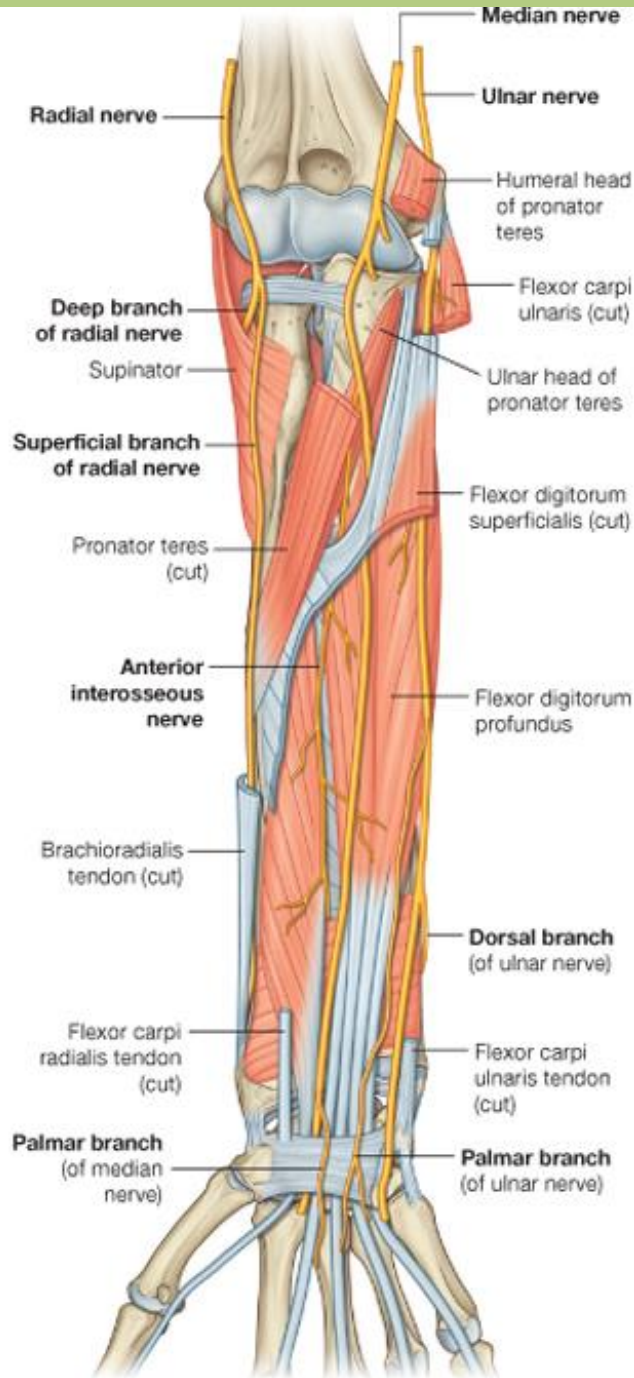
- ***Motor innervation:*** extensor muscles of the arm and forearm
- ***Skin innervation:*** posterior surfaces of the arm and forearm, lower lateral surface of the arm, dorsal radial side of the hand



Drake: Gray's Anatomy for Students, 2nd Edition.  
 Copyright © 2009 by Churchill Livingstone, an imprint of Elsevier, Inc. All rights reserved.

Drake: Gray's Anatomy for Students, 2nd Edition.  
 Copyright © 2009 by Churchill Livingstone, an imprint of Elsevier, Inc. All rights reserved.

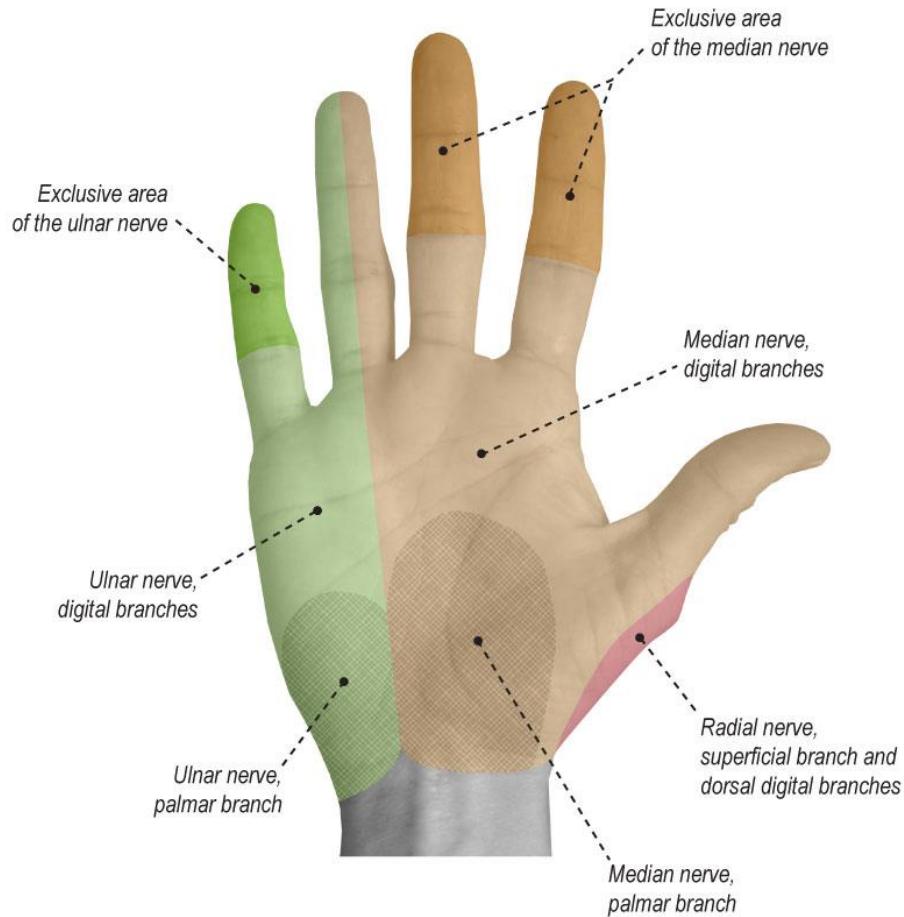




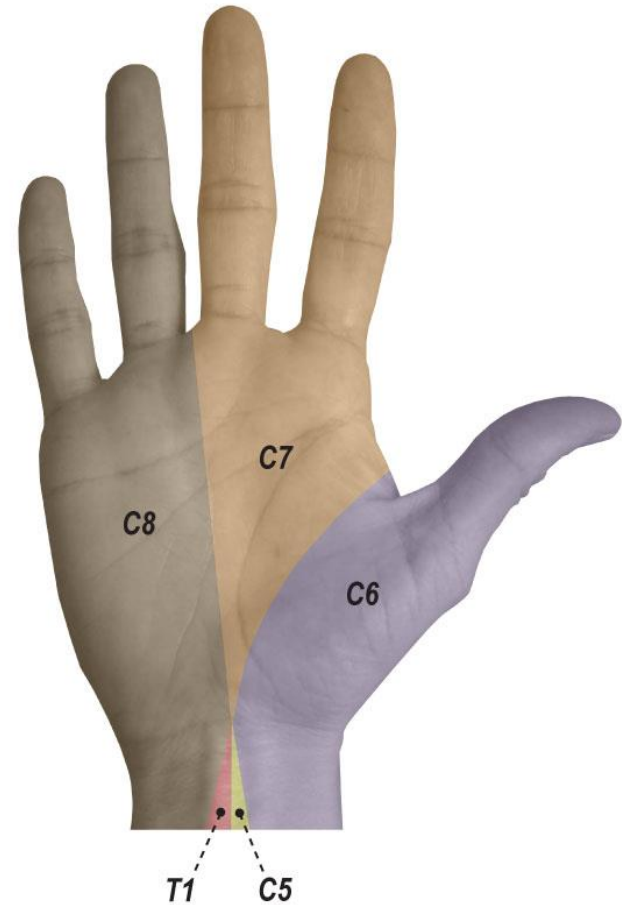
Drake: Gray's Anatomy for Students, 2nd Edition.  
 Copyright © 2009 by Churchill Livingstone, an imprint of Elsevier, Inc. All rights reserved.

# Skin innervation of the hand

**Sensory Territories and Innervations  
(Volar View)**

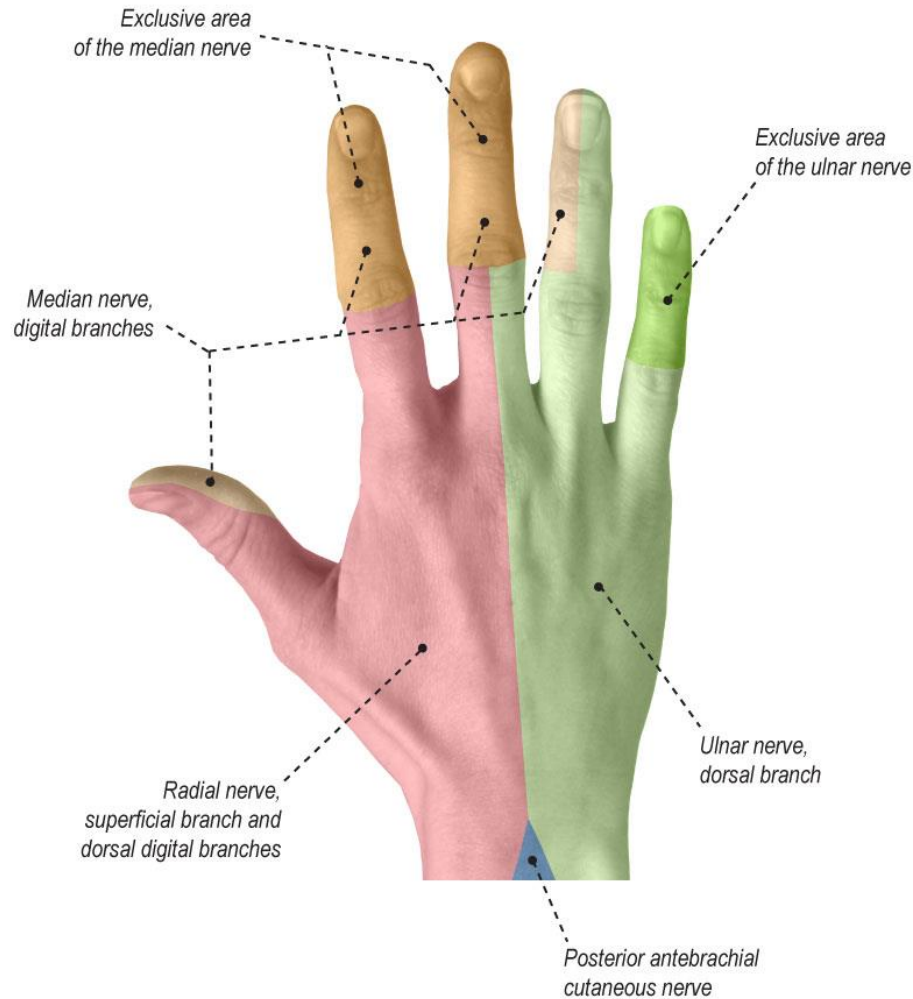


**Dermatomes  
(Volar View)**

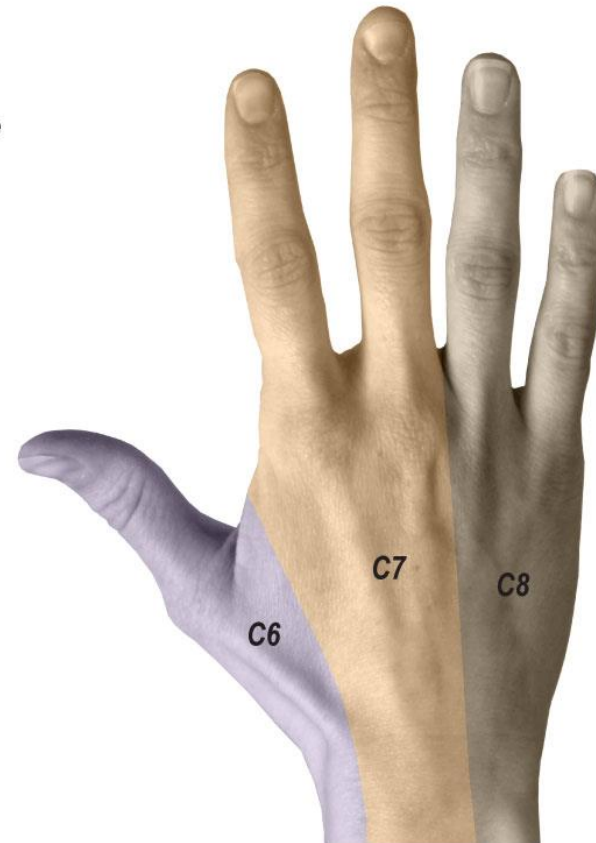


# Skin innervation of the hand

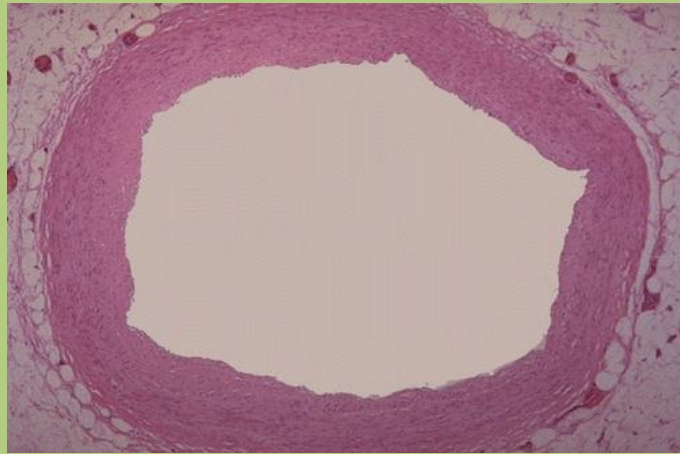
**Sensory Territories and Innervations  
(Dorsal View)**

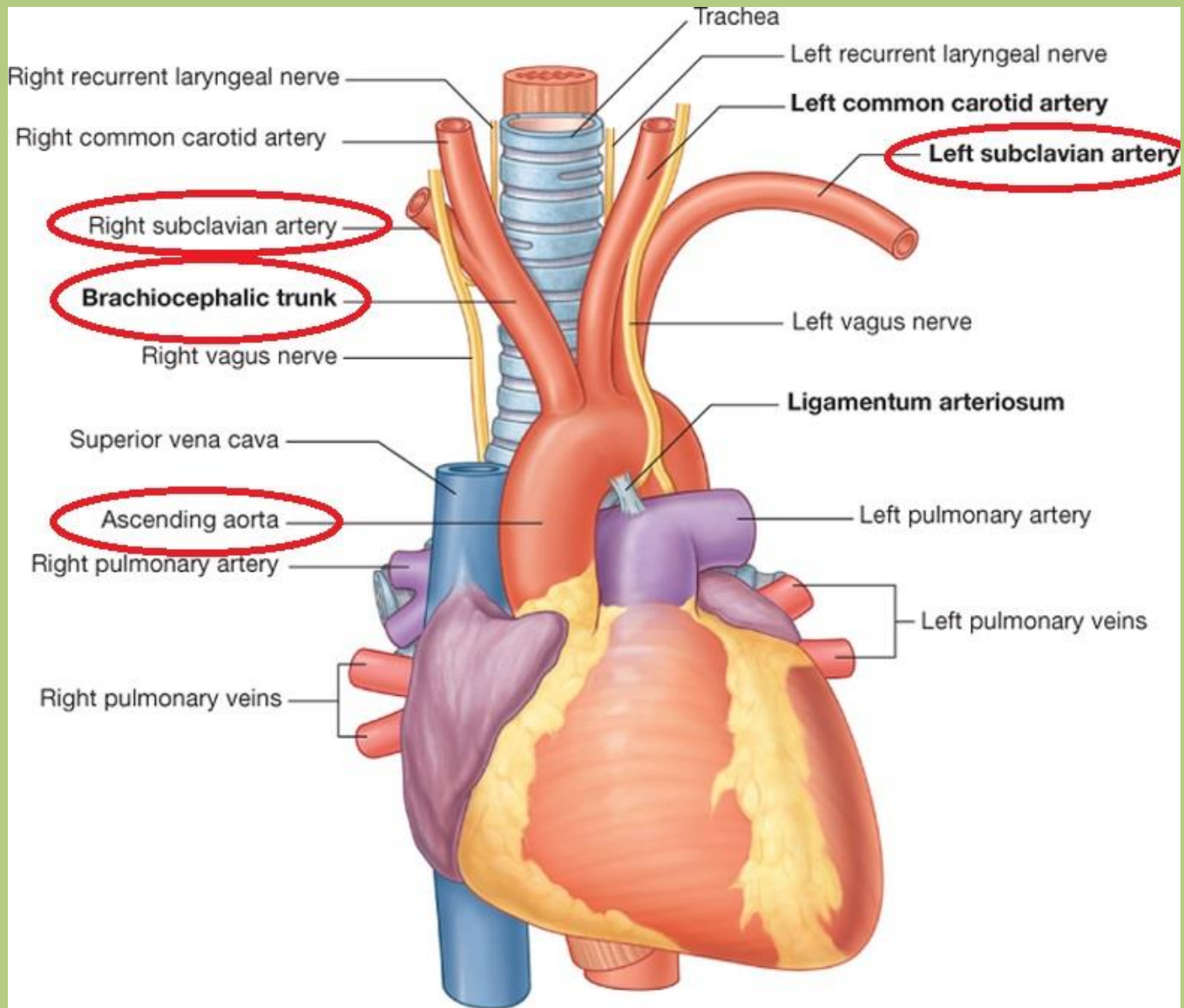


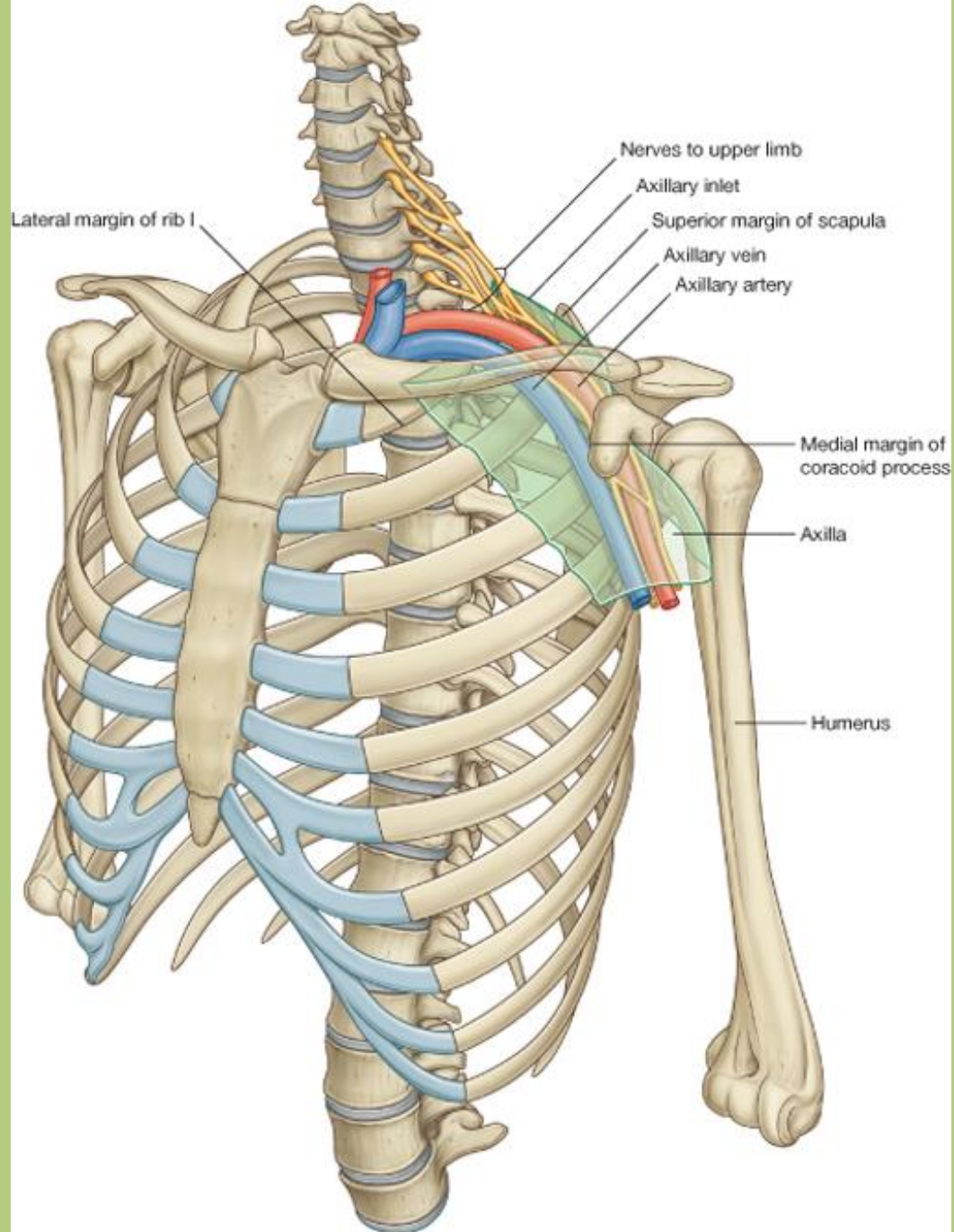
**Dermatomes  
(Dorsal View)**

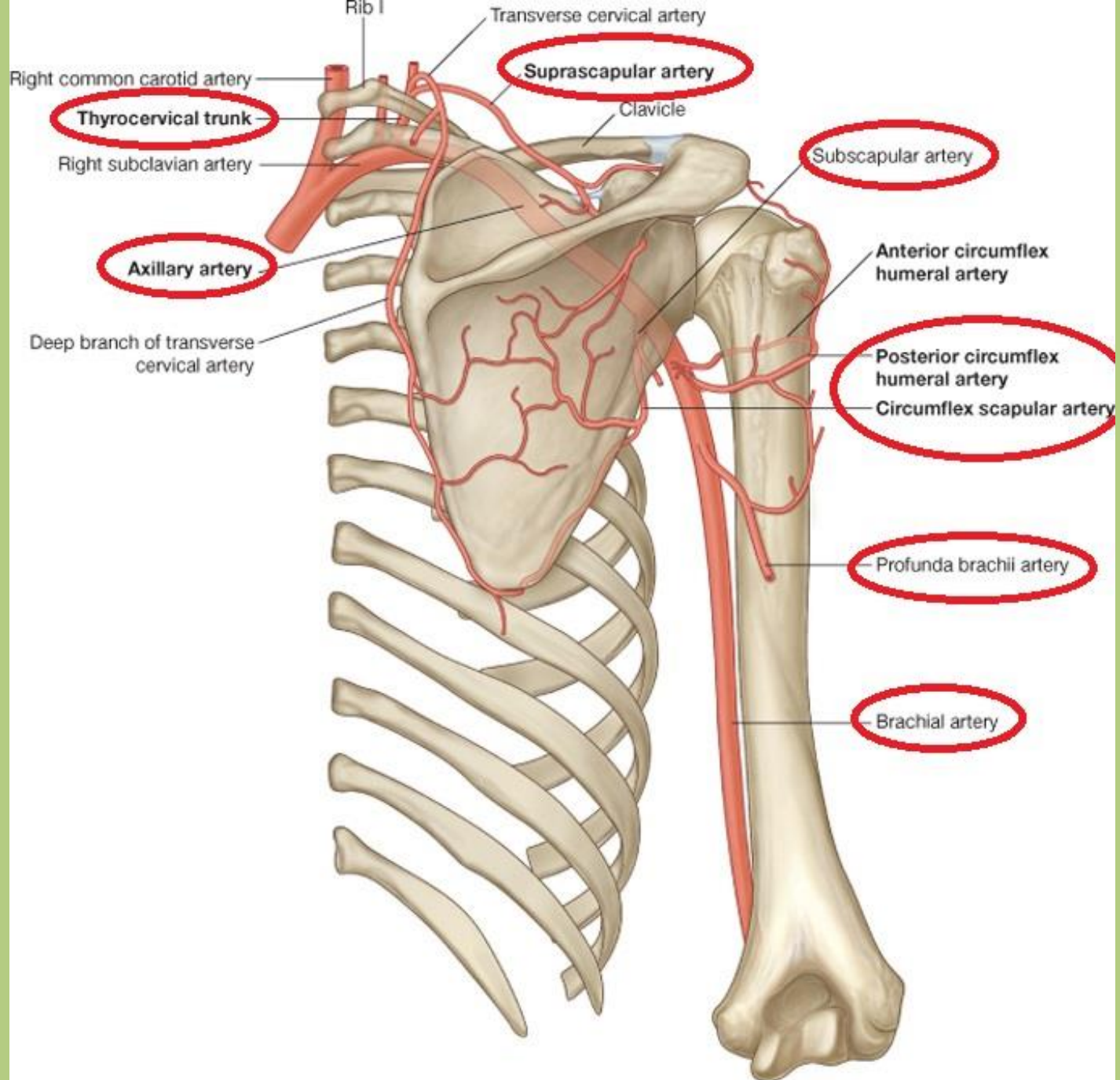


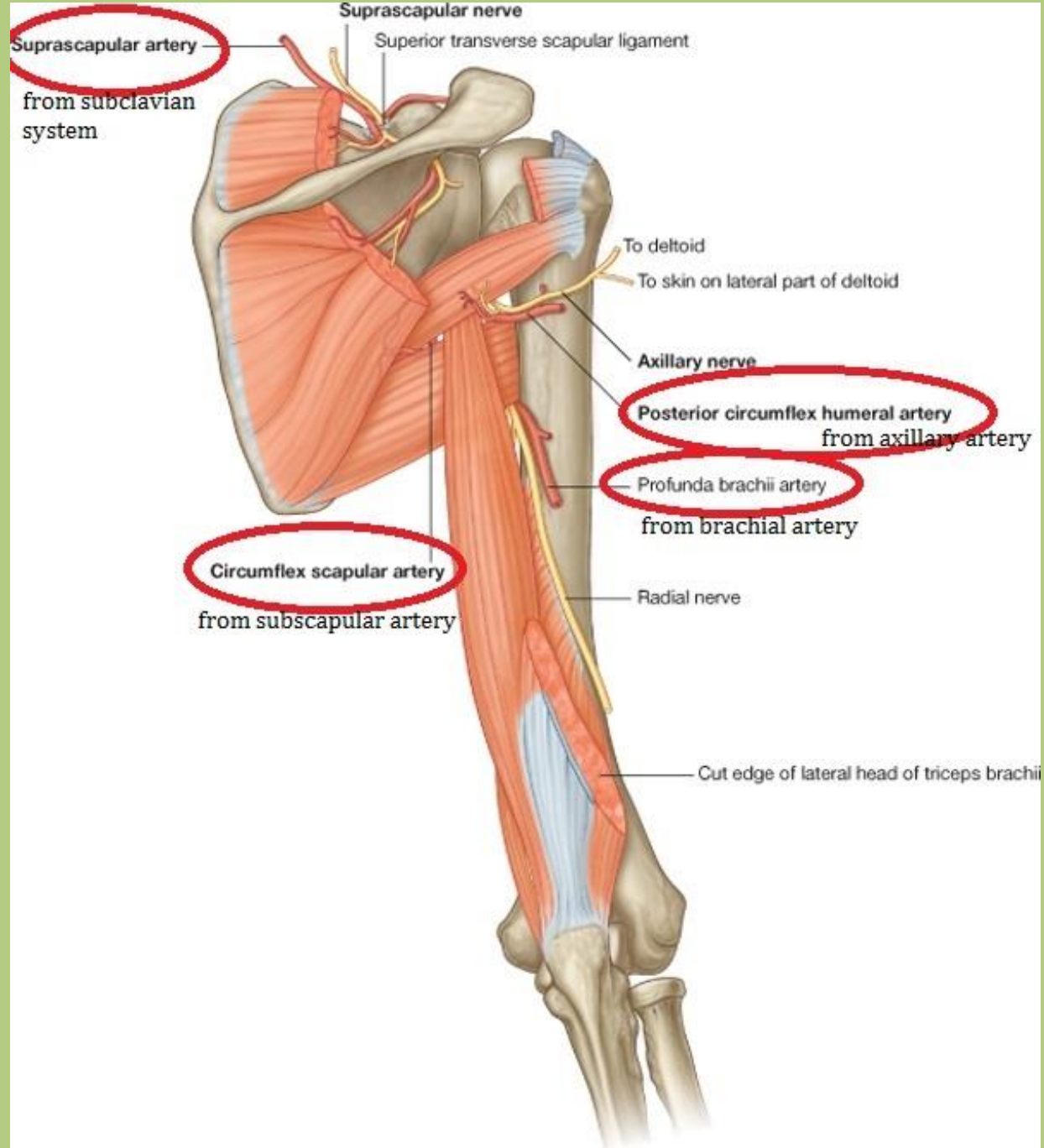
# Vasculature of the upper limb



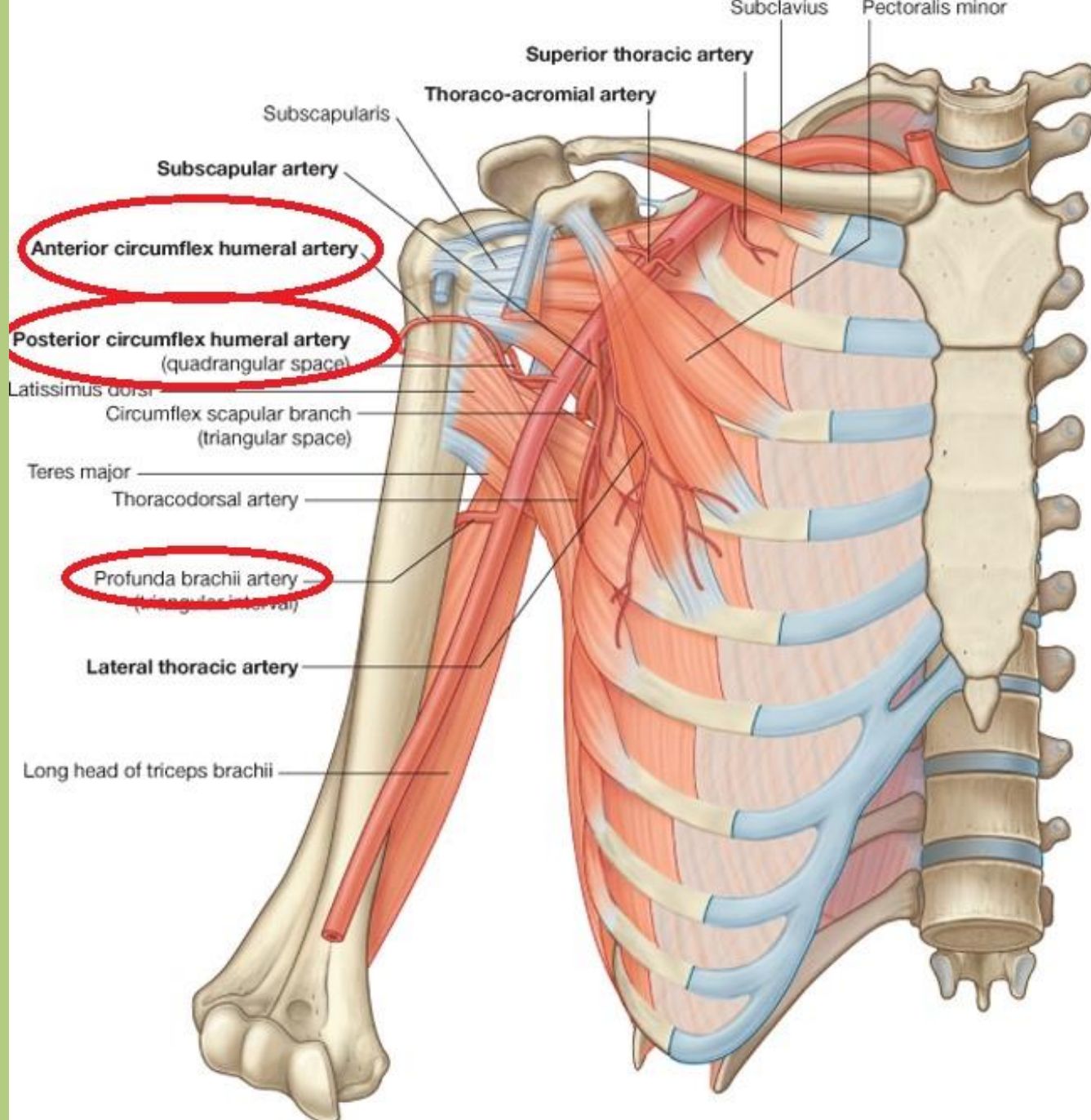


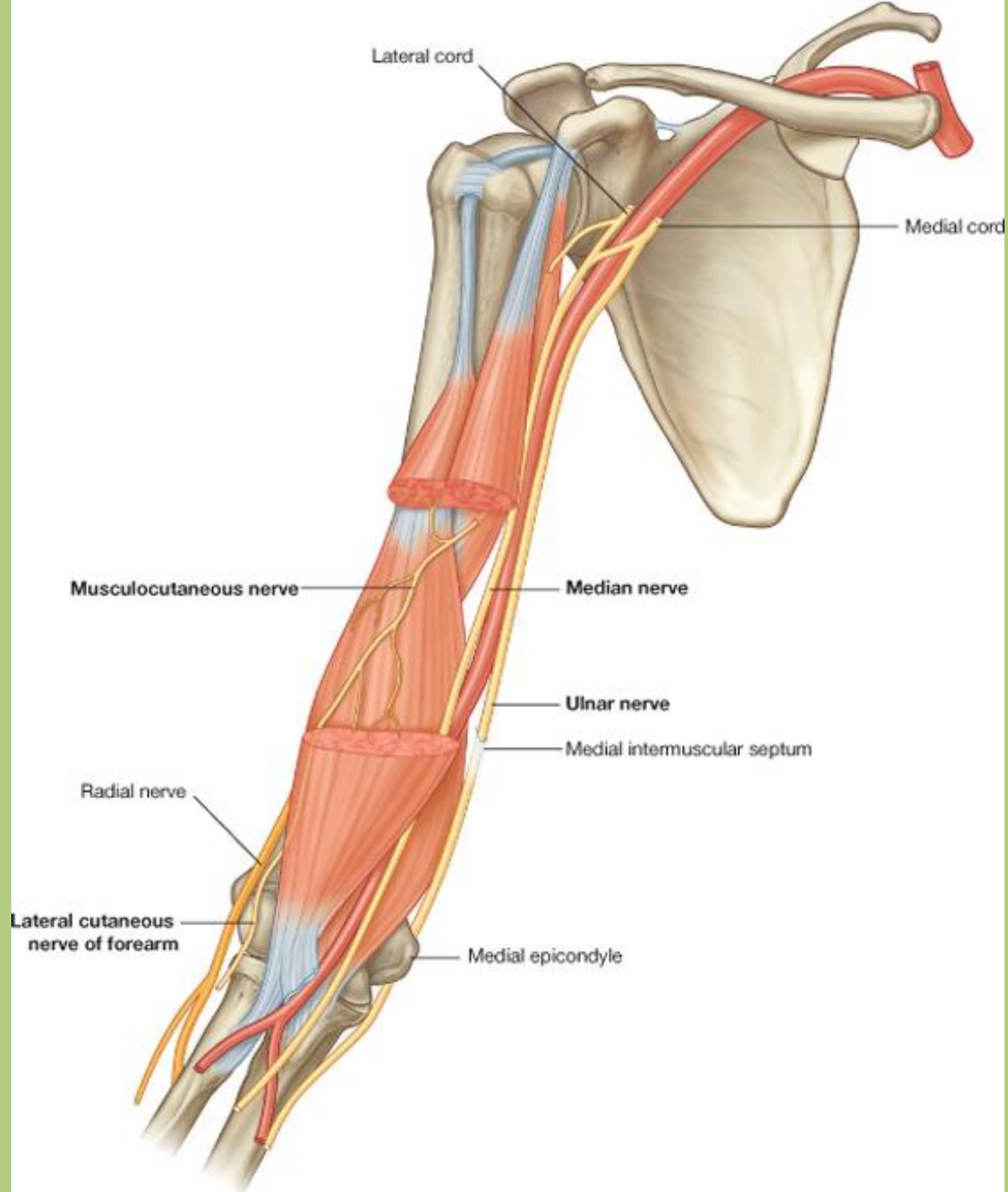




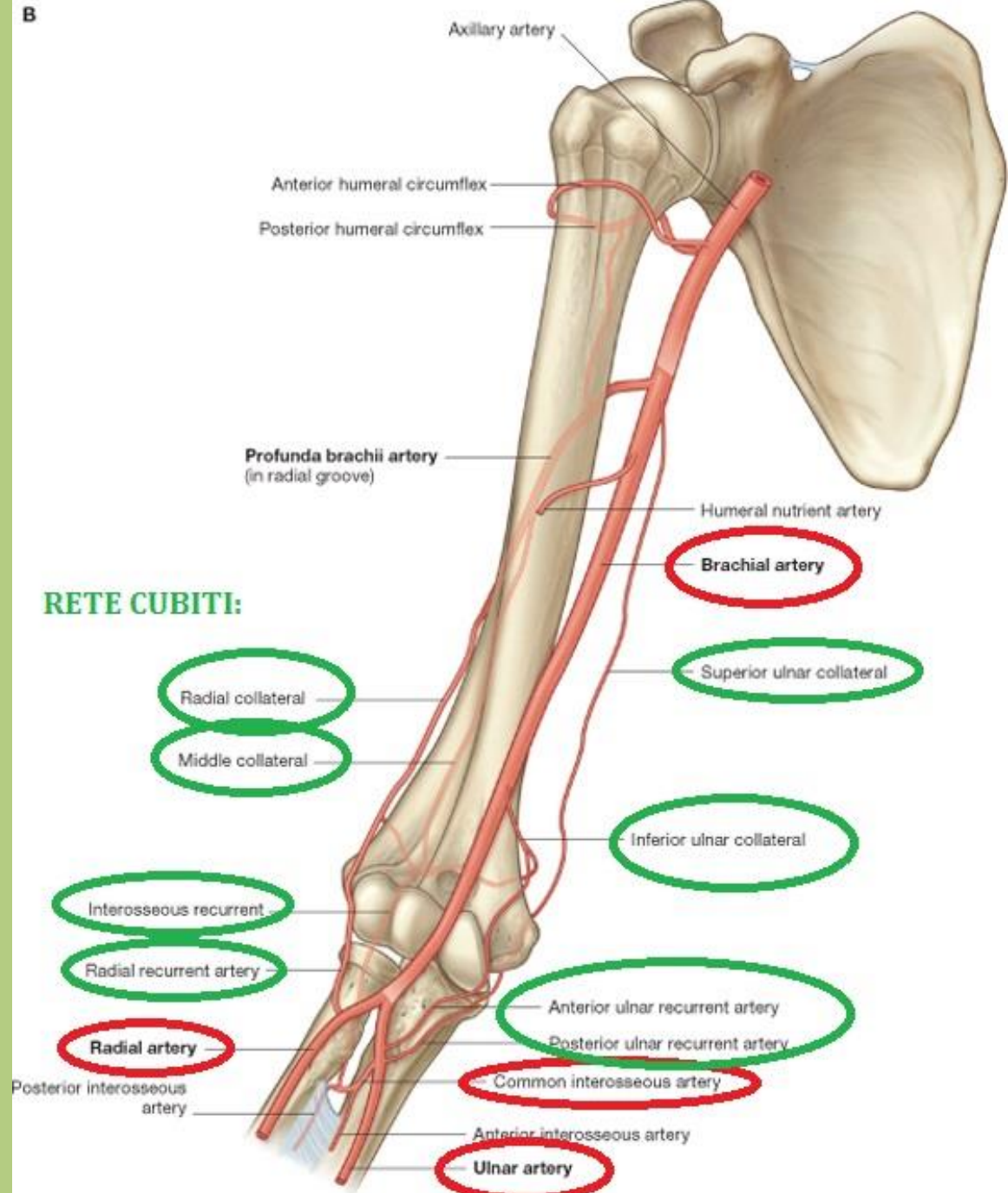


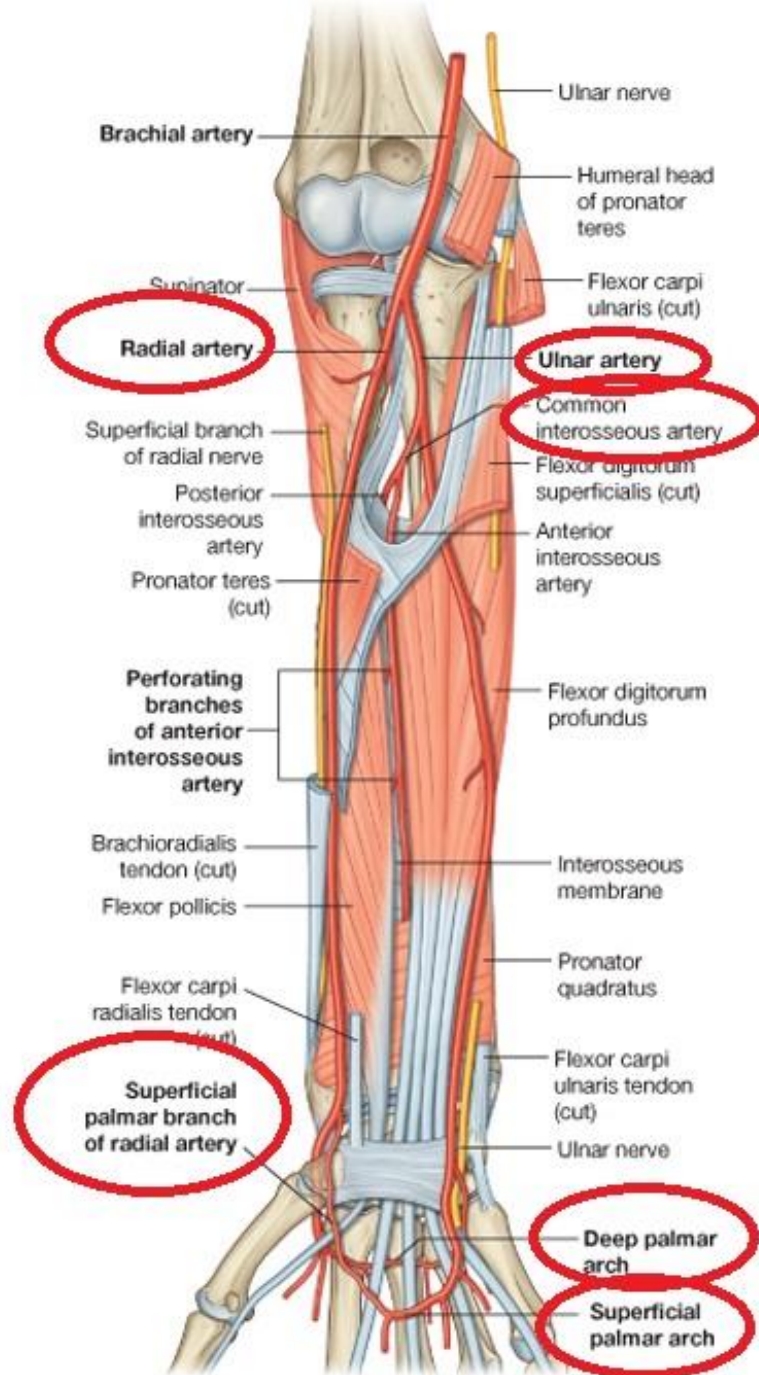




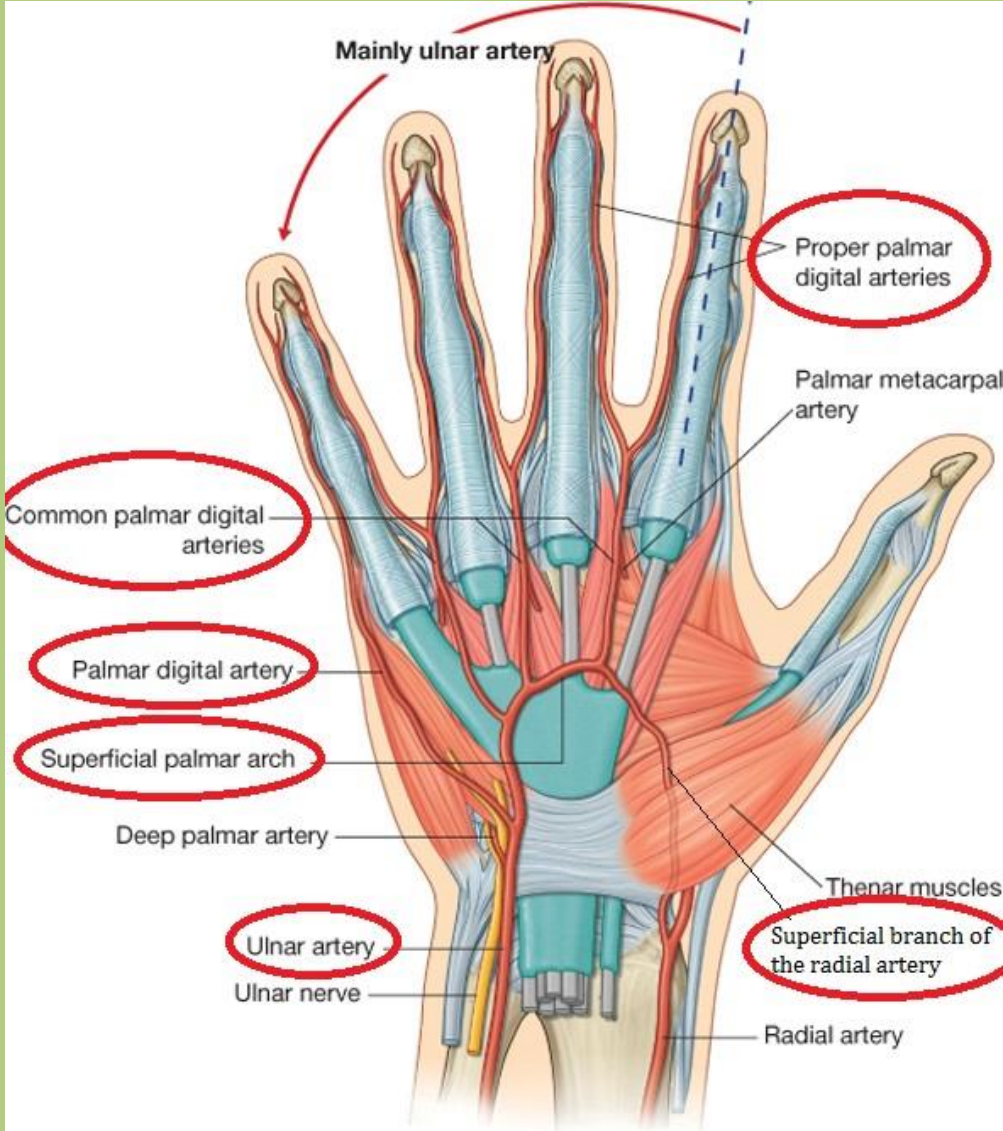


B

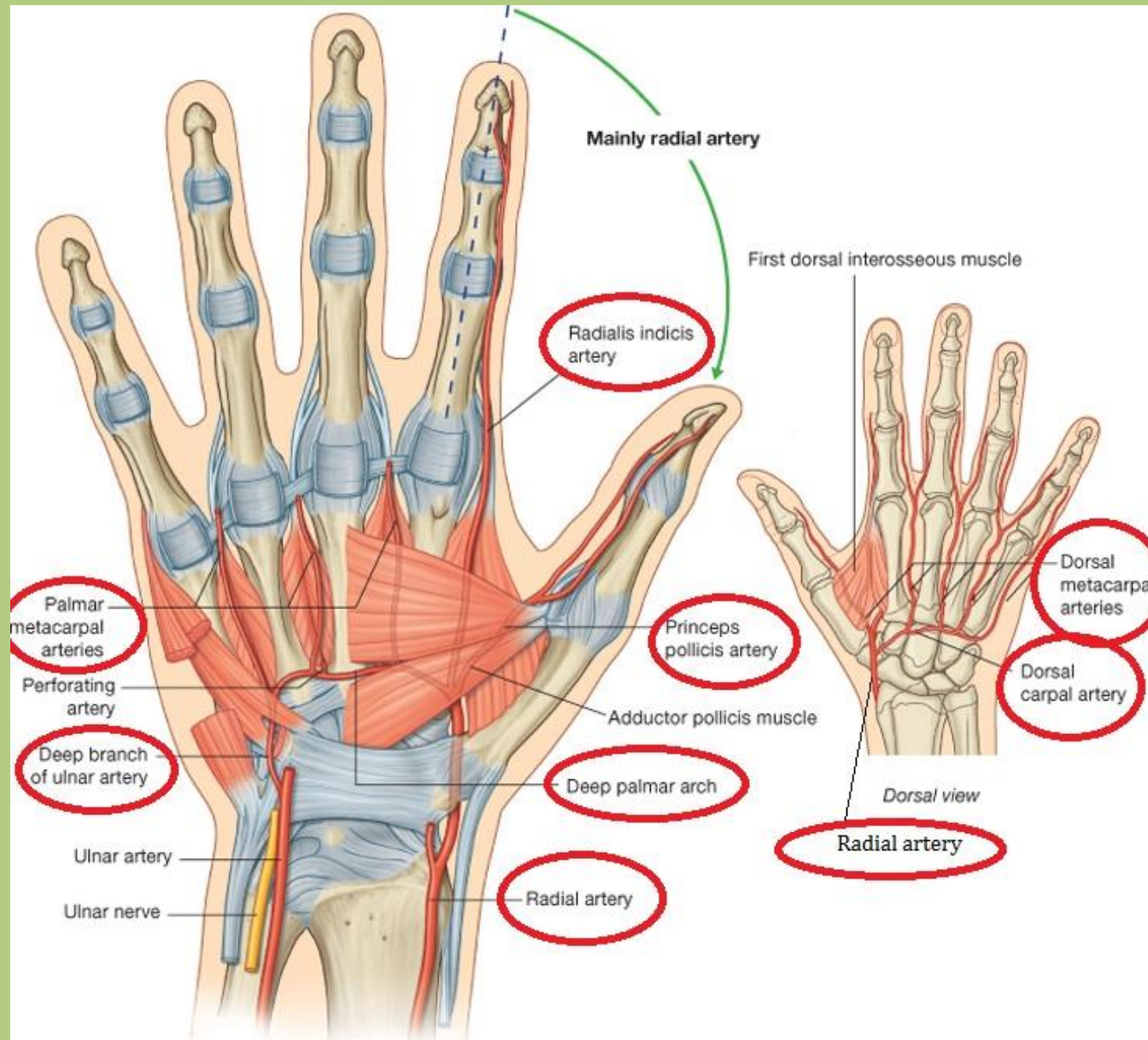




# Superficial palmar arch



# Deep palmar and dorsal arches



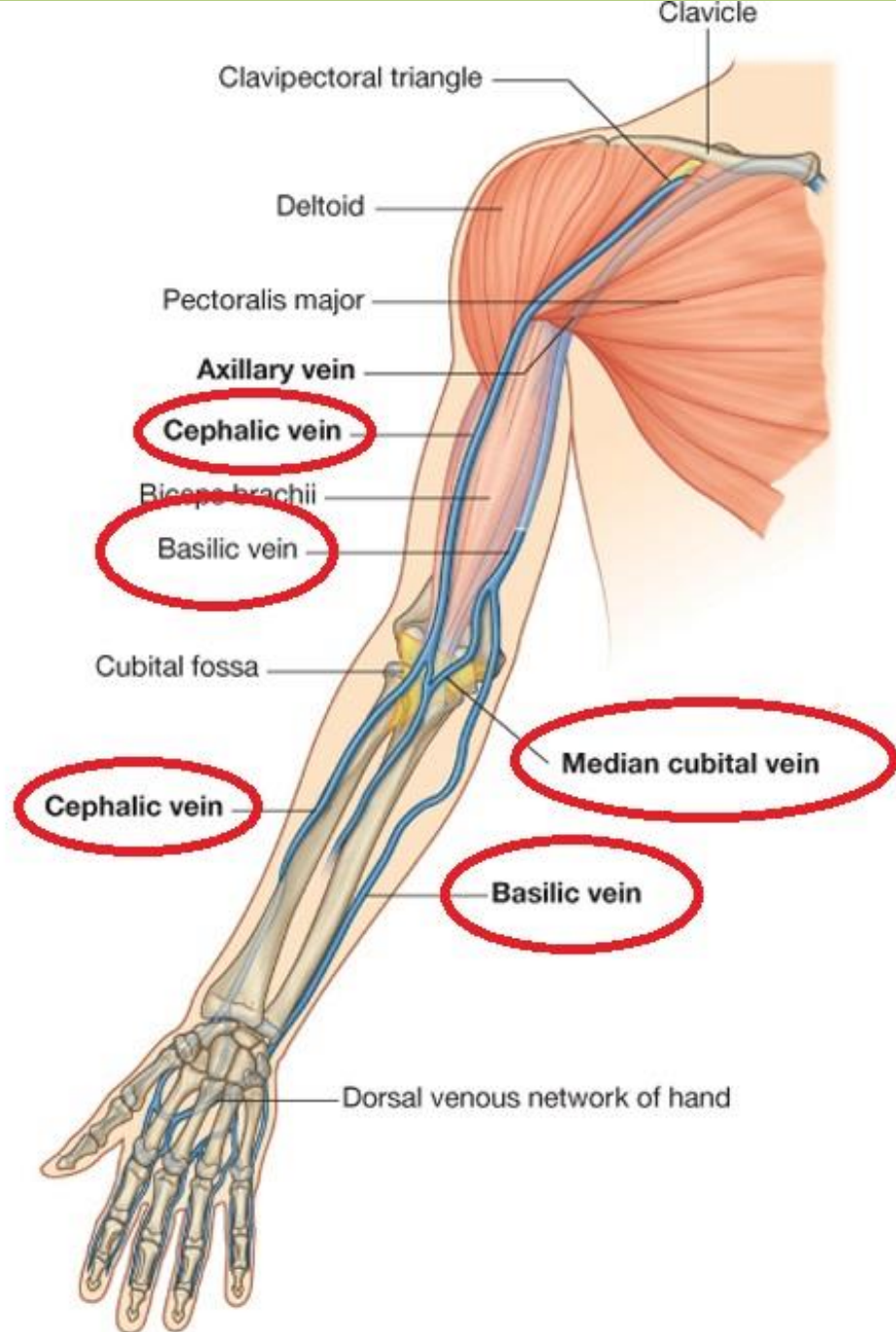
# Deep veins of the upper limb

- the deep veins are accompanying the arteries (their names are the same)
- two veins are accompanying the small and middle arteries below the superior third of the upper limb

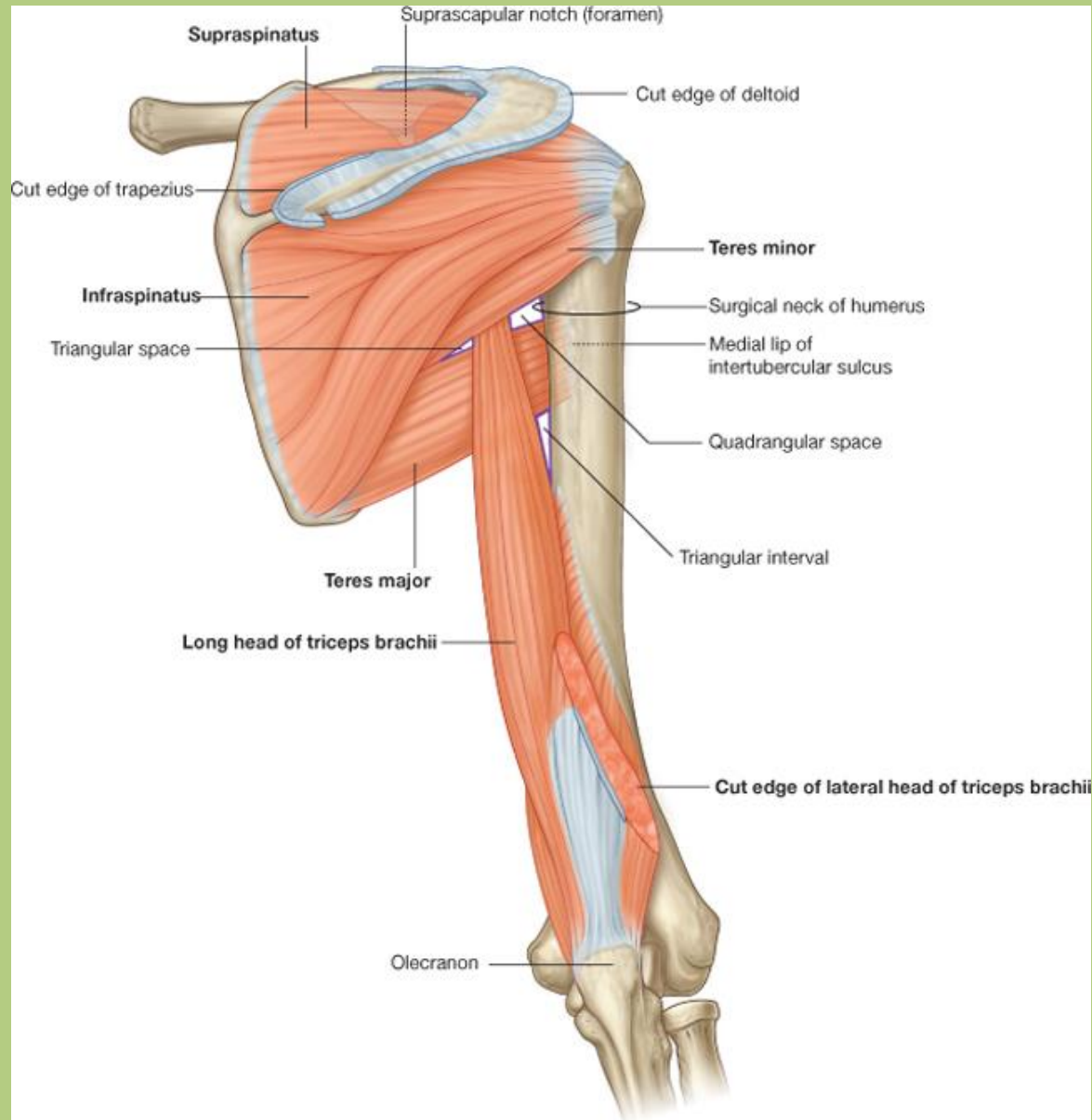
# Superficial veins of the upper limb

- the superficial or subcutaneous veins are independent from the arteries
- two main subcutaneous veins are presented:  
***cephalic and basilic veins***

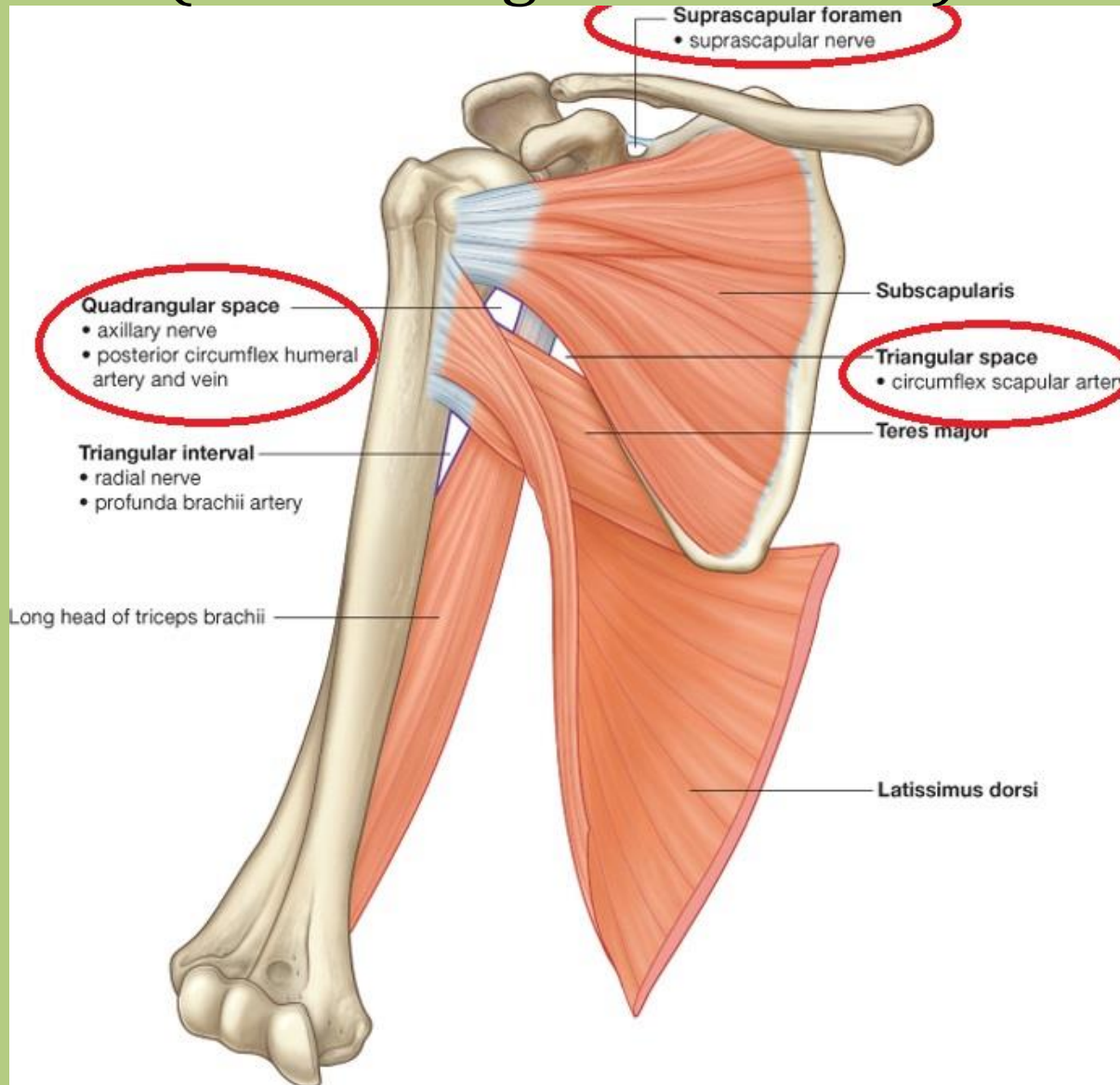


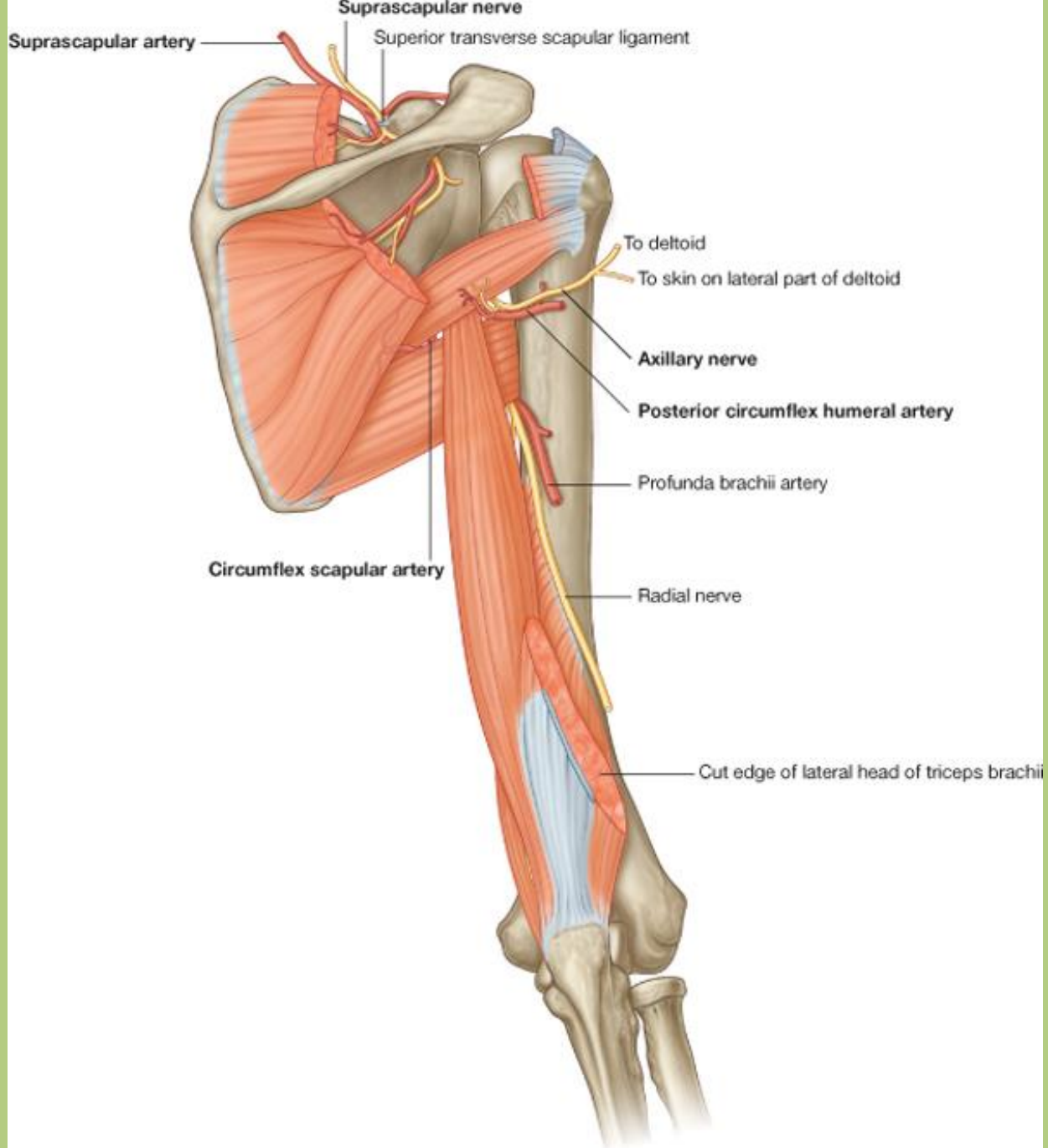


# Triangular, Quadrangular spaces (and Triangular interval)

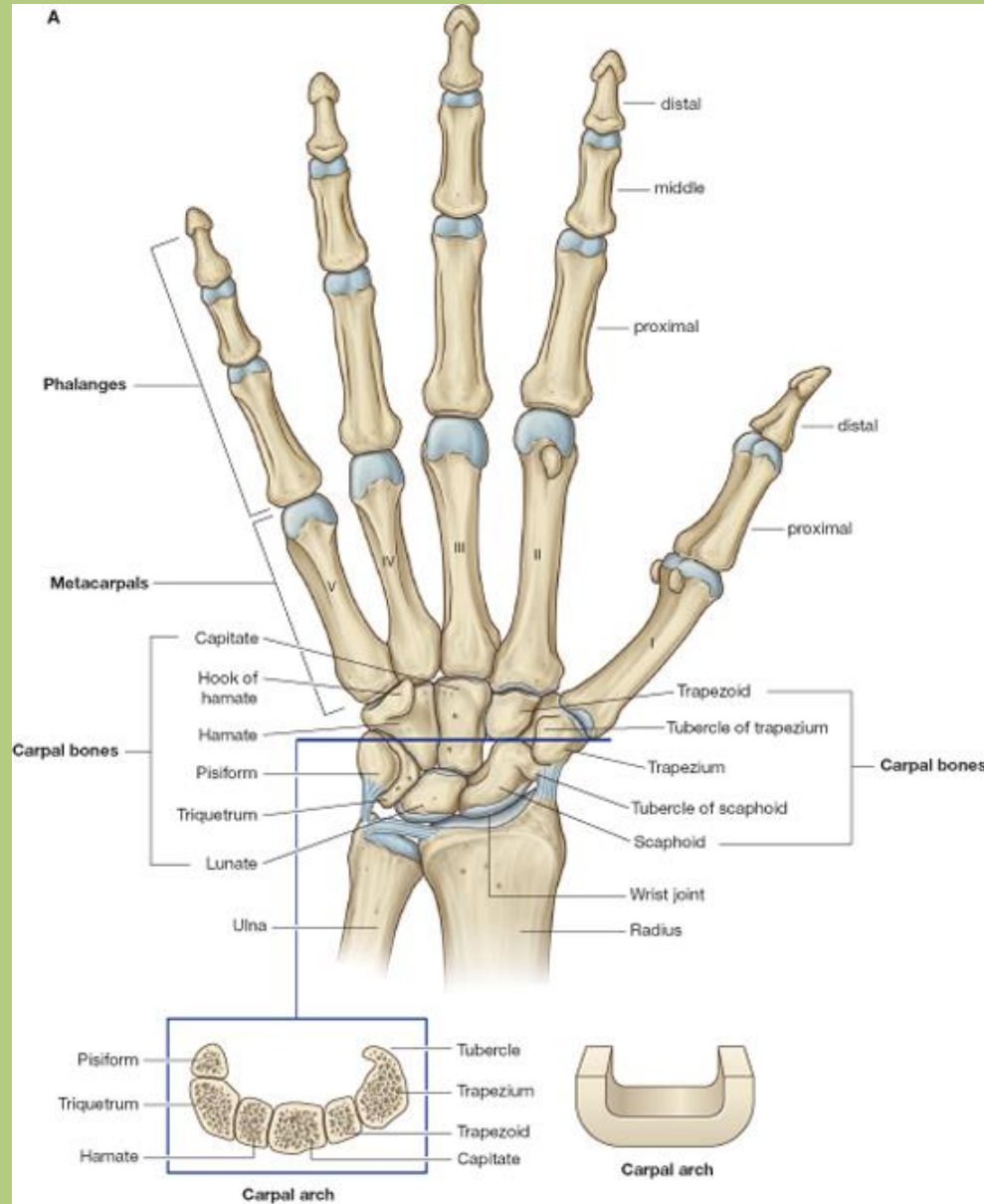


# Triangular, Quadrangular spaces (and Triangular interval)

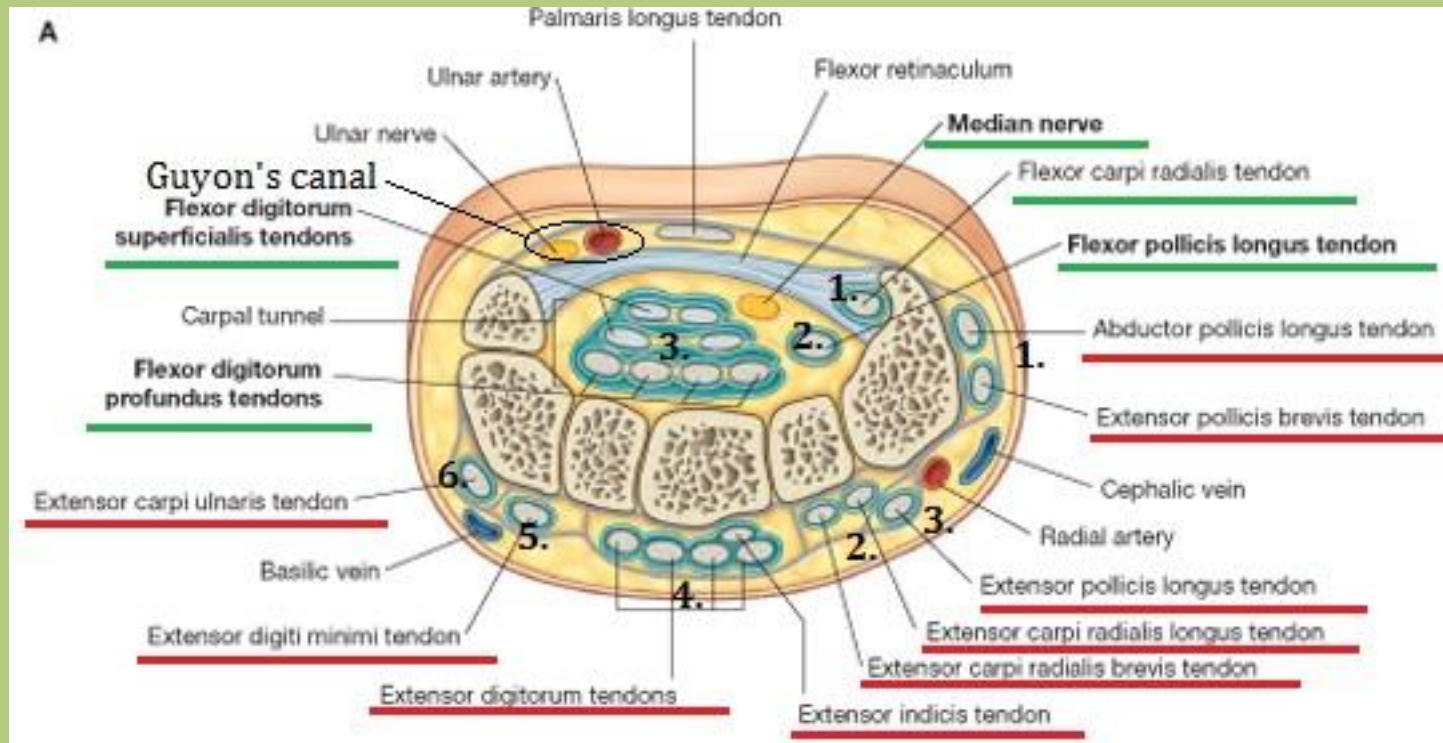




# Carpal tunnel



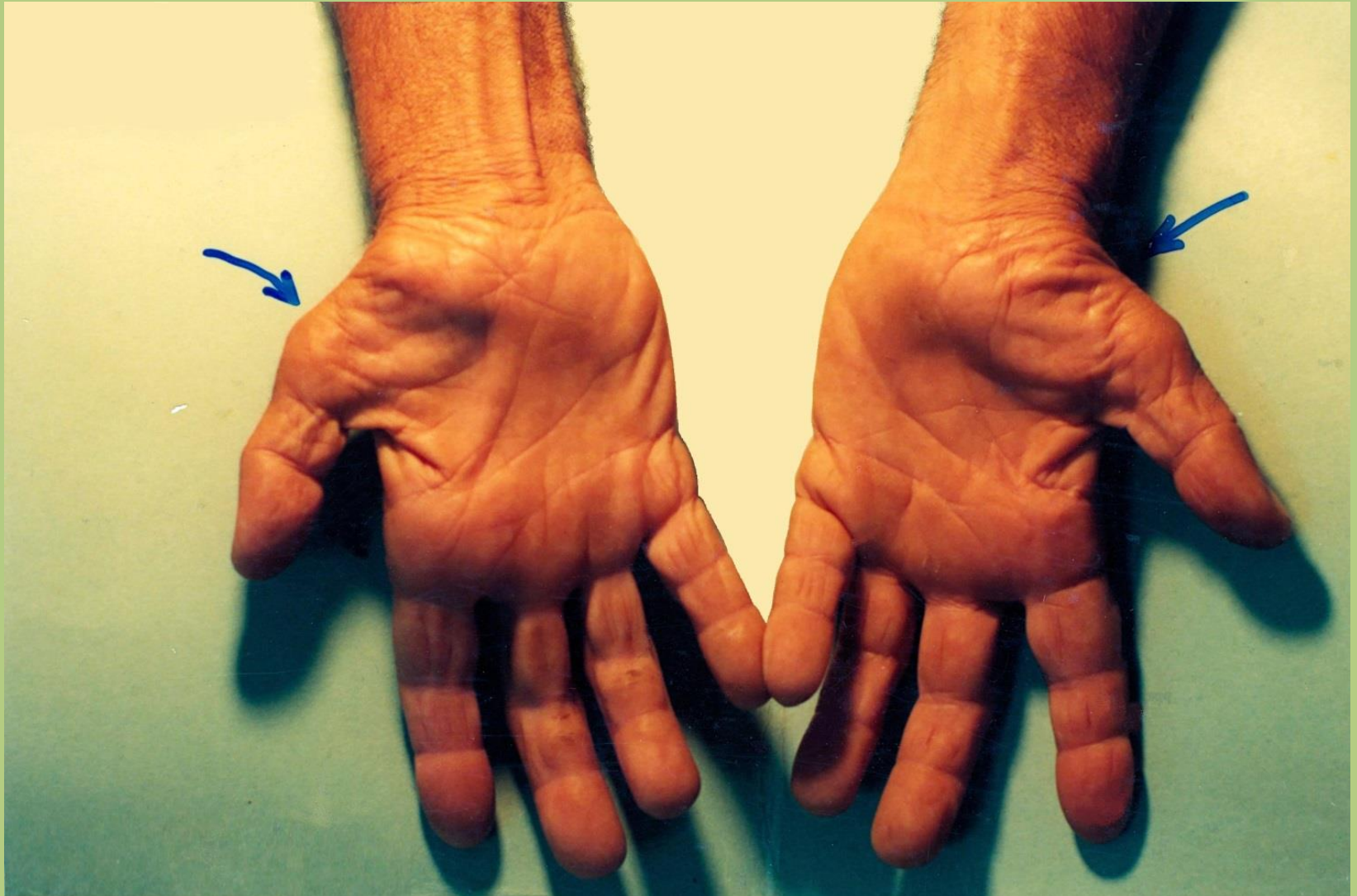# Carpal tunnel



# Carpal tunnel syndrome

- Caused by *pressure on the median nerve within the carpal tunnel.*
- The aetiology of this condition is often obscure, though in some instances the nerve injury may be a direct effect of increased pressure on the median nerve caused by *overuse, swelling* of the tendons and tendon sheaths (e.g.: rheumatoid arthritis) and cysts arising from the carpal joints.
- *Increased pressure can cause venous congestion that produces nerve edema and anoxic damage of the median nerve itself.*
- Patients typically report *pain and pins and needles* in the distribution of the median nerve. *Weakness and loss of muscle bulk of the thenar muscles* may also occur.

# Carpal tunnel syndrome





Thank you for your attention.

References: Gray's Anatomy for Students

Hand out of Dr. Katalin Kocsis

Washington University School of Medicine in St. Louis: Peripheral  
nerve surgery: A Resource for Surgeons