Vessels, conducting system of the heart. Surface projection of the heart, pericardium. Auscultation points

Dr. Alán Alpár

Vessels of the heart - Arteries

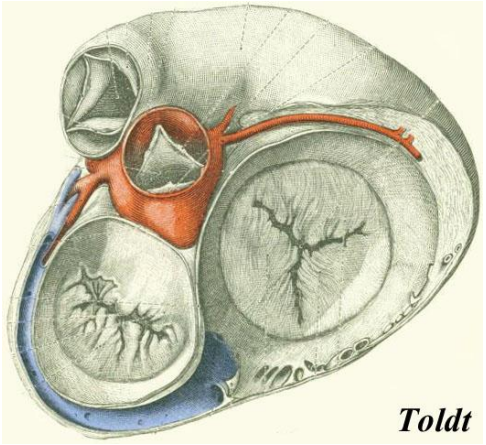

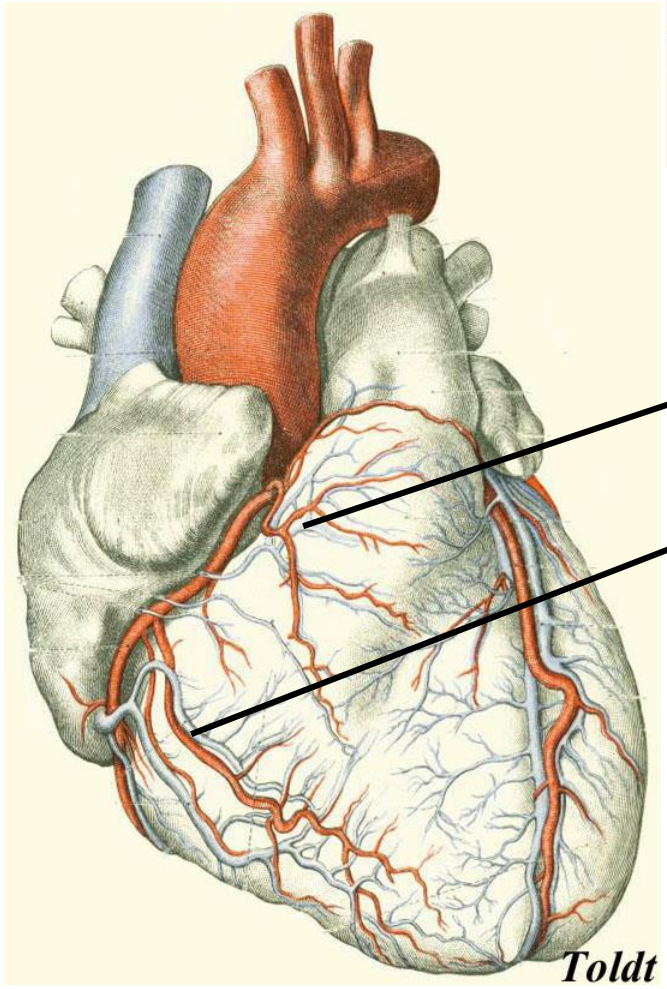

Right coronary art.
conus branches
atrial brachnes
ventricular branches
right marginal branch
Sinu-atrial nodal branch
post. interventr. br.
post. interventrr. rr.

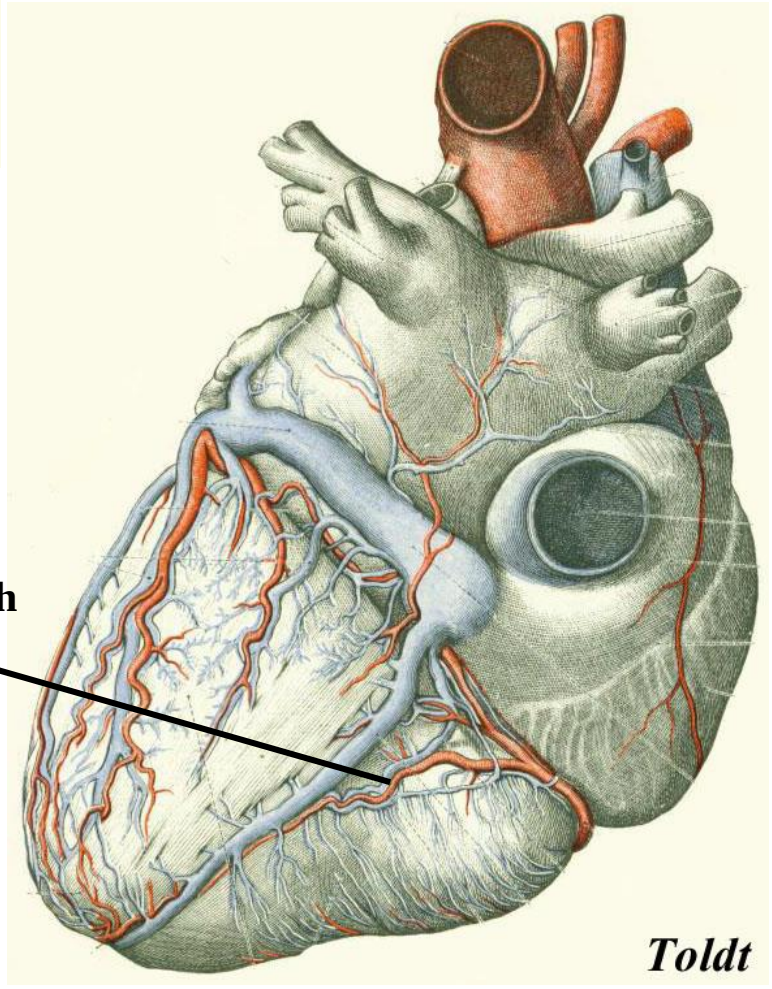

Vessels of the heart - Arteries

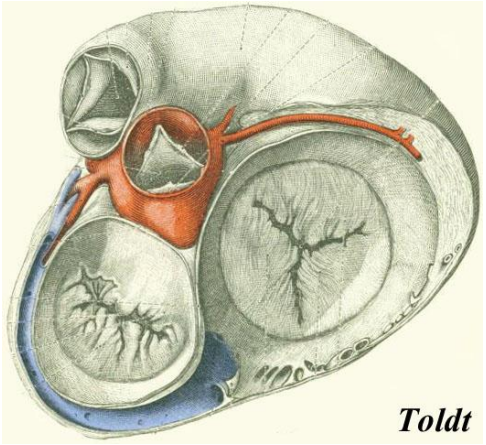

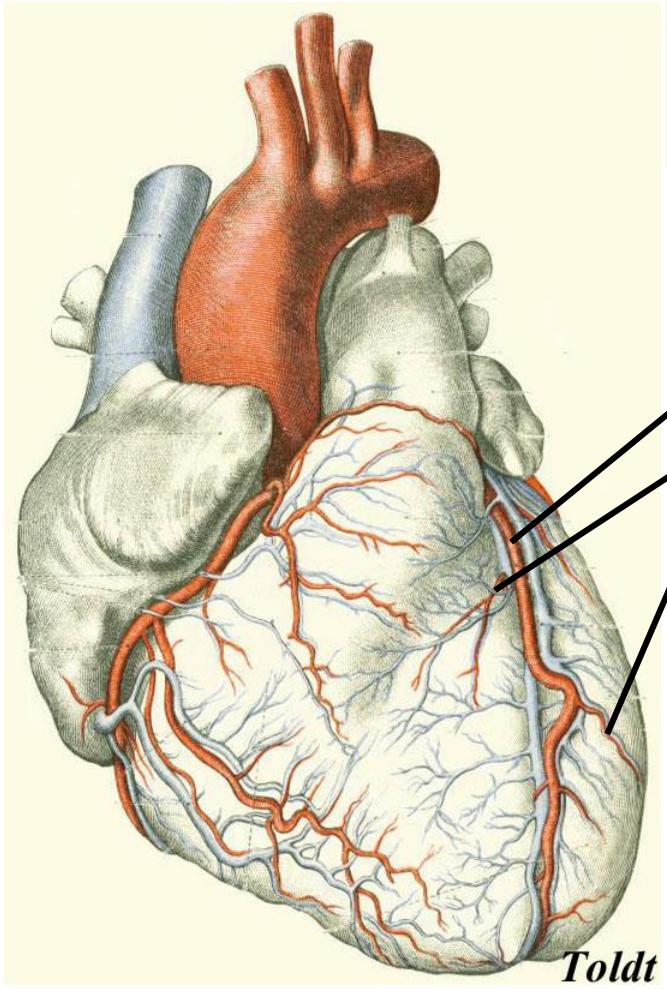

Left coronary art.
ant. interventr. br.
conus branch
lateralis branch
ant. interventr. rr.

circumflex branch
atrioventricular br.
left marg. br.
atrial branches

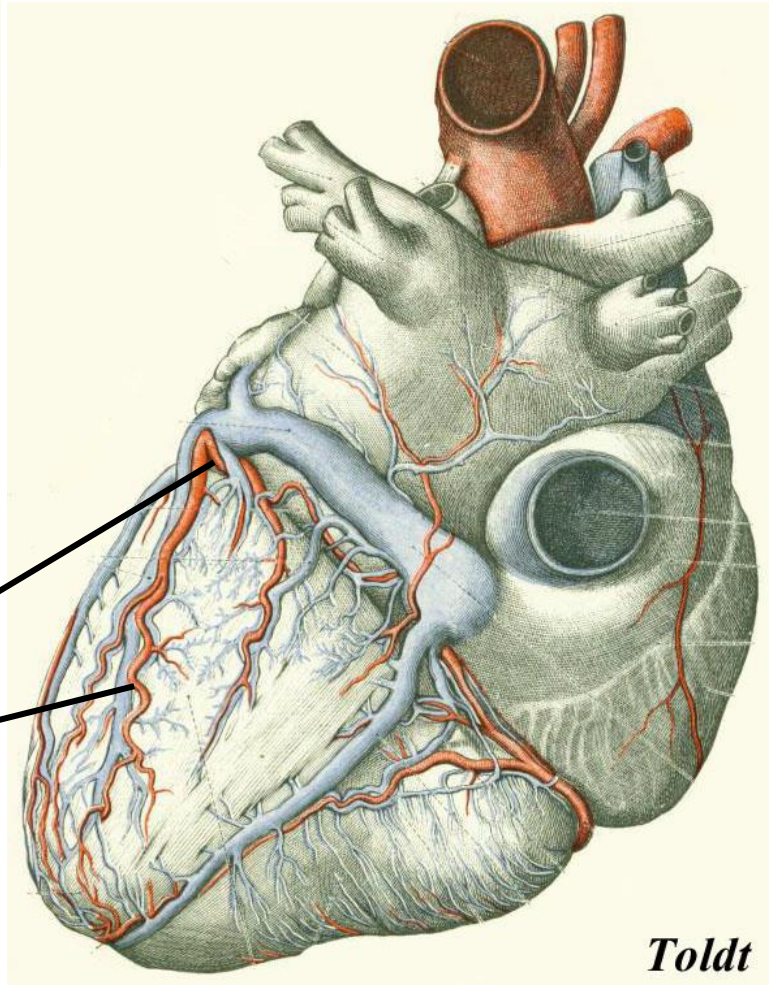

Vessels of the heart - Veins

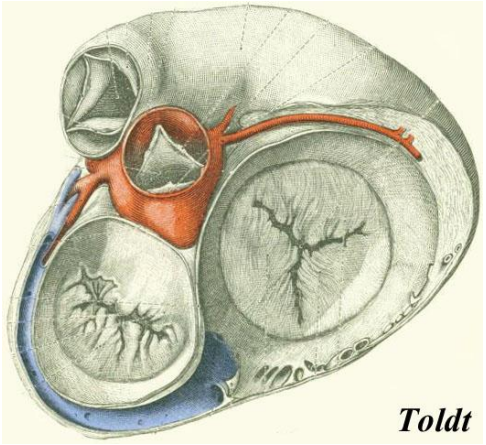

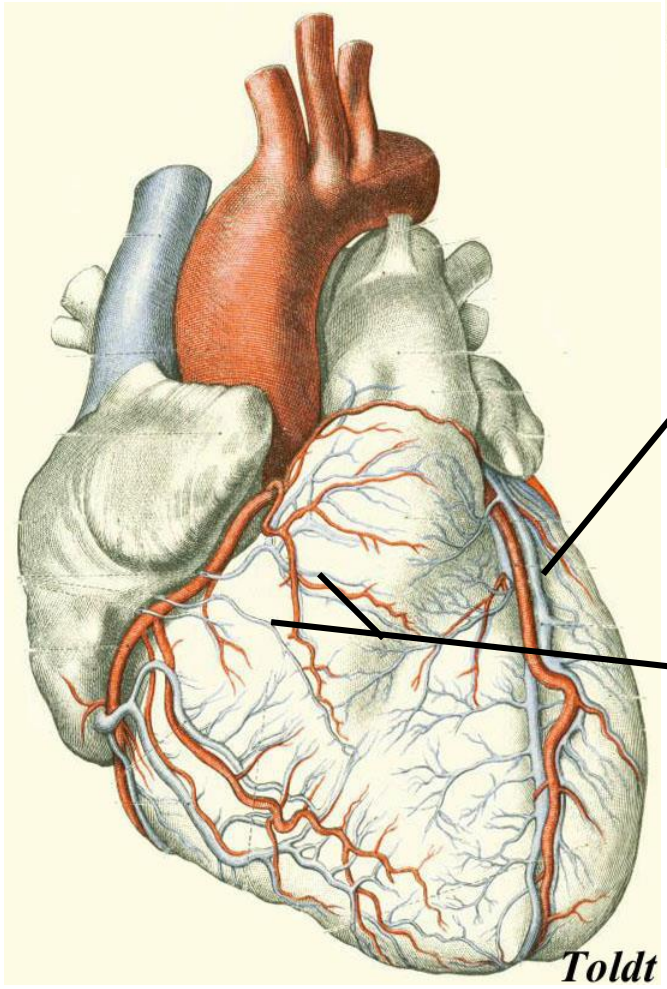

Coronary sinus
great cardiac vein
middle cardiac v.
small cardiac v.
left post. ventr. br.
obl. v. of the left atr. *
anterior cardiac veins
small cardiac veins

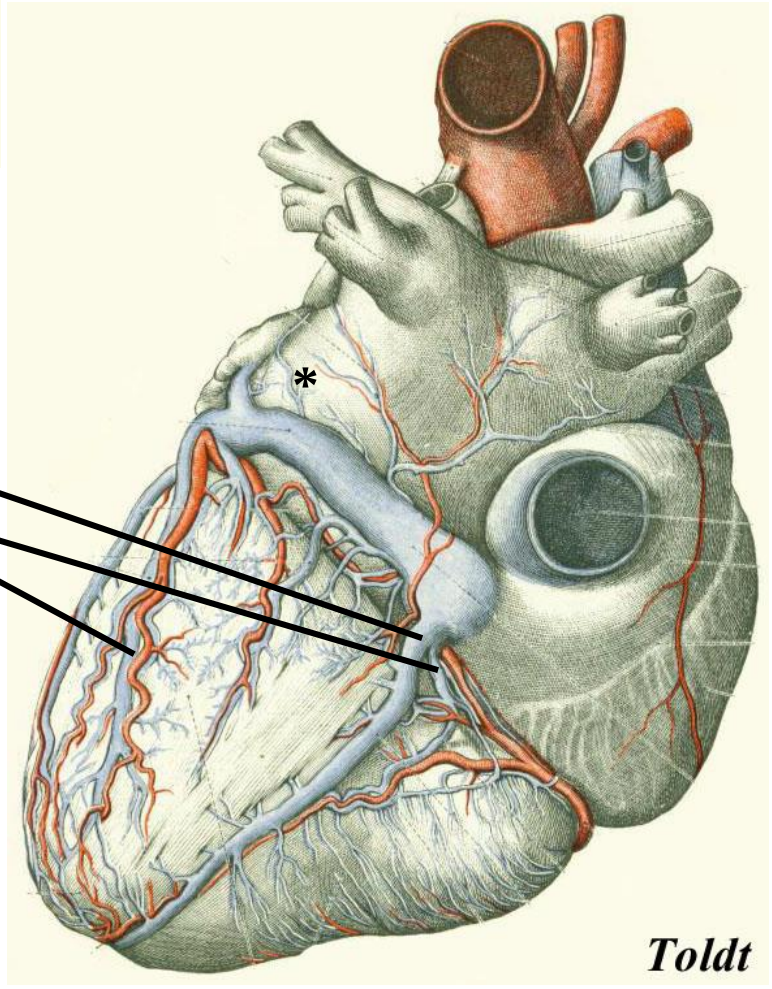

Lymph vessels of the heart

Subendokardial lymphatic network

Myokardial lymphatic network

Subepikardial lymphatic network

↓

Right and left main lymphatic vessels (along the coronary arteries)

↓

Mediastinal lymph nodes

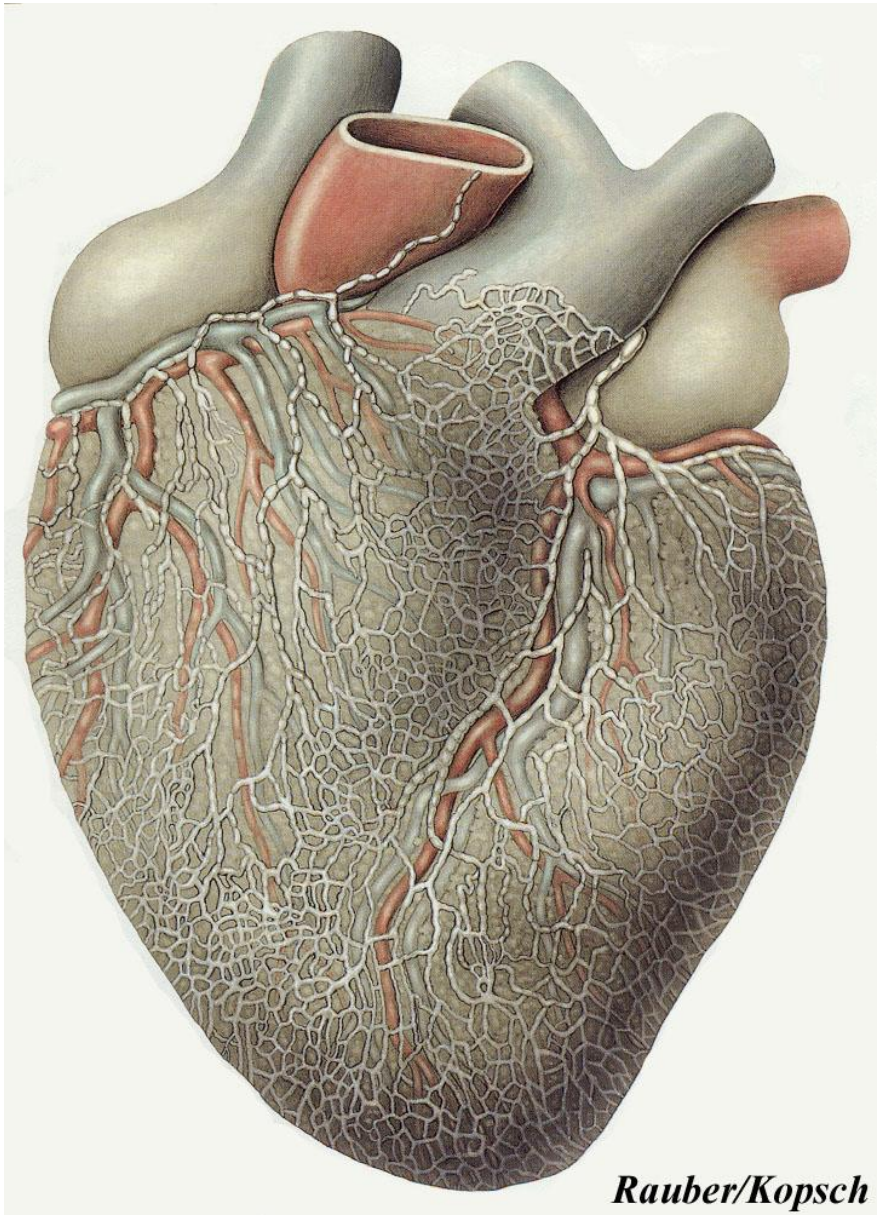

Innervation of the heart

Afferent fibres
pain
from pressor receptors
from chemoreceptors

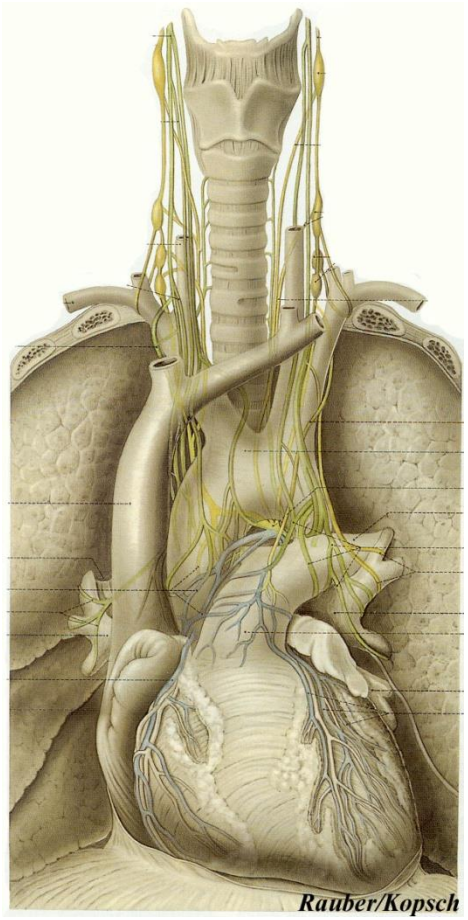

Efferent fibres
Chromotropic effect (frequency)
Inotropic effect (force of contraction)
Dromotropic effect (conduction speed)
(end on cardiac muscle cells and in the nodes)

Sympathic +
Superior, middle, inferior and thoracic cardiac *nerves*

Parasympathic -
Superior, middle, inferior and thoracic cardiac *rami*

Cardiac plexus

Heart failure

„Left-type” and „right-type” hearts

„right half”: **conus segment**
right marginal segment
posterior interventricular segment

„left half”: **anterior interventricular segment**
lateral segment
left marginal segment
posterior ventricular segment

High oxygen demand (5-10%)
Functional end arteries (although anastomosis present)

Conducting system

Autonomous – spontaneous depolarisations

Sinu-atrial node (Keith-Flack)
at v. cava superior and crista terminalis

↓

Wenkebach, Bachmann, Thorel, Tandler bundles (interauricular and sinuatrial bundles)

↓

Atrioventricular node (Aschoff-Tawara)
through right fibrous trigone, next to the orifice of coronary sinus

↓

Bundle of His

↓

Tawara branches

↓

Purkinje fibres

↓

cardiac muscle cells

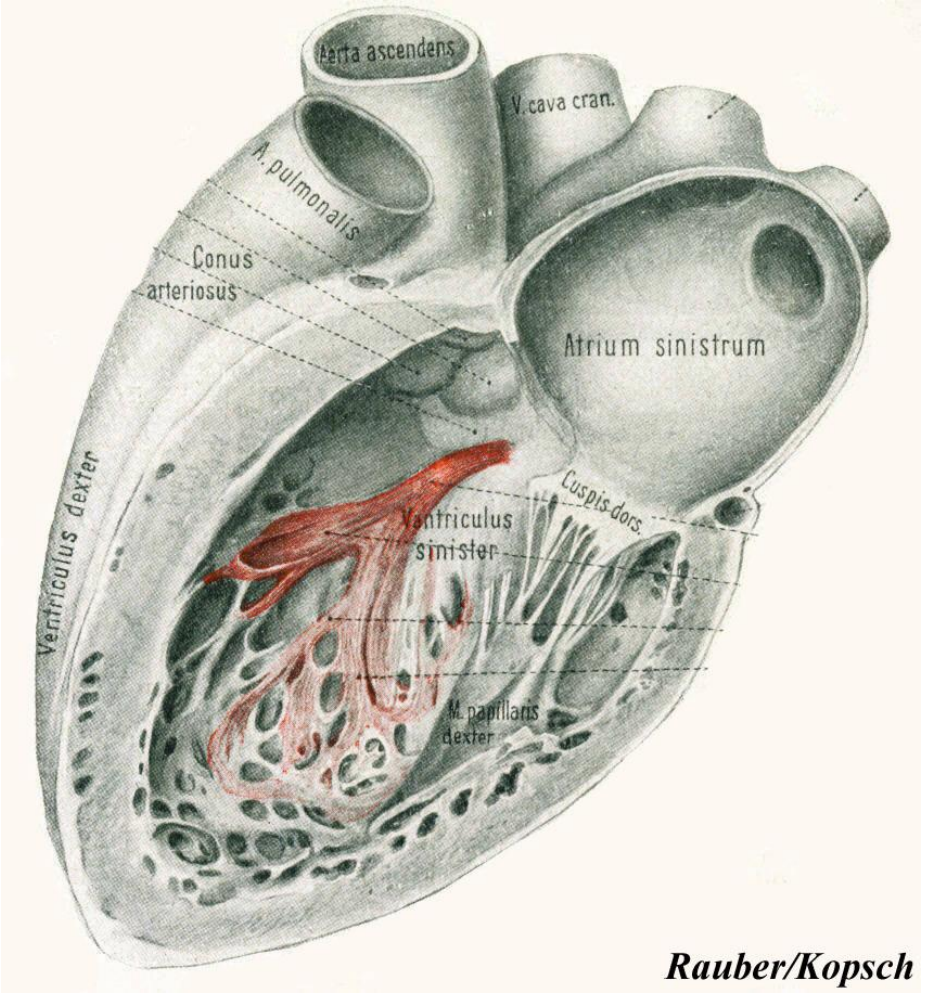

Pericardium

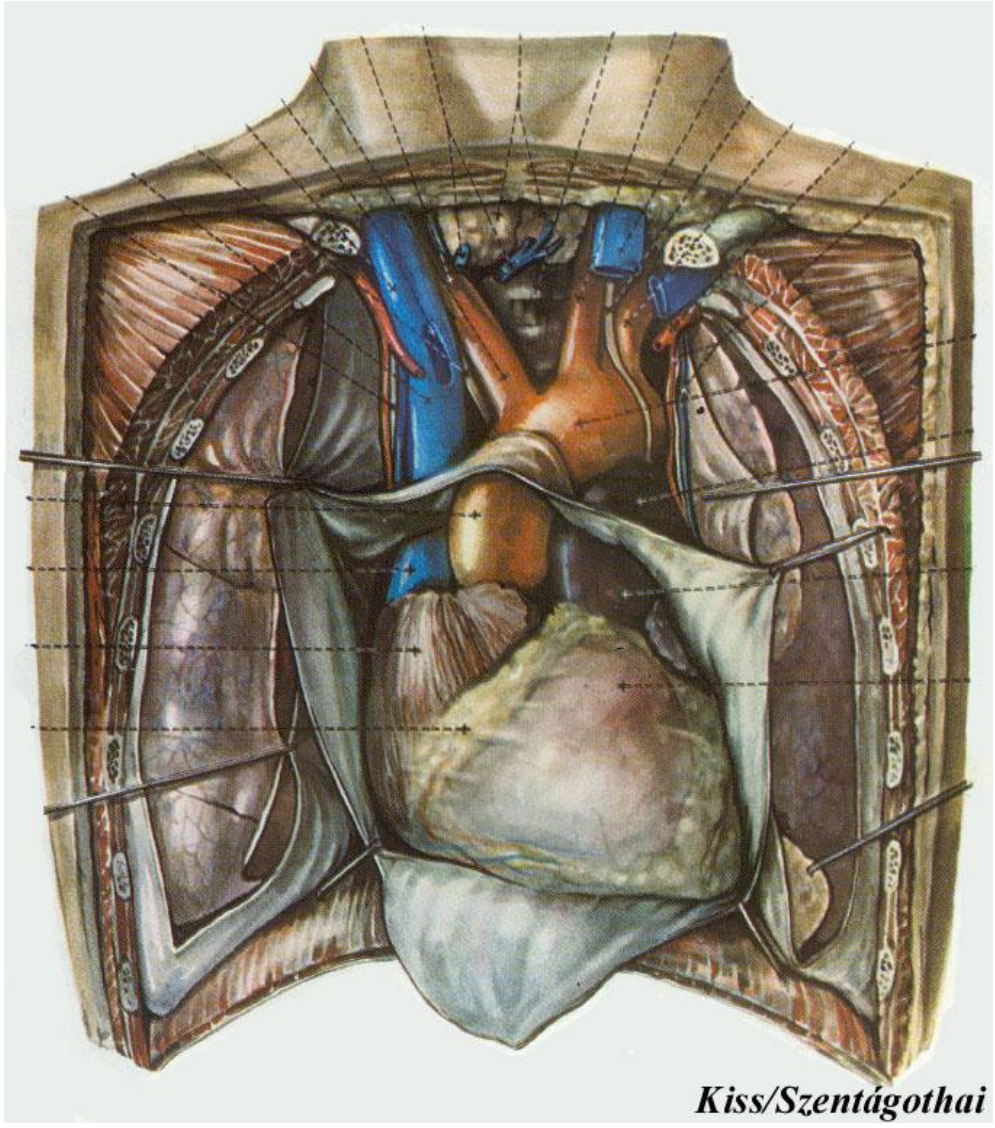

Epicardium
visceral layer of pericard
grown onto the myocardium

Pericardium
Serous coat
Fibrous coat (fibroelastic and fibrillar layers)

Folds
arterial and venous

Pericardium

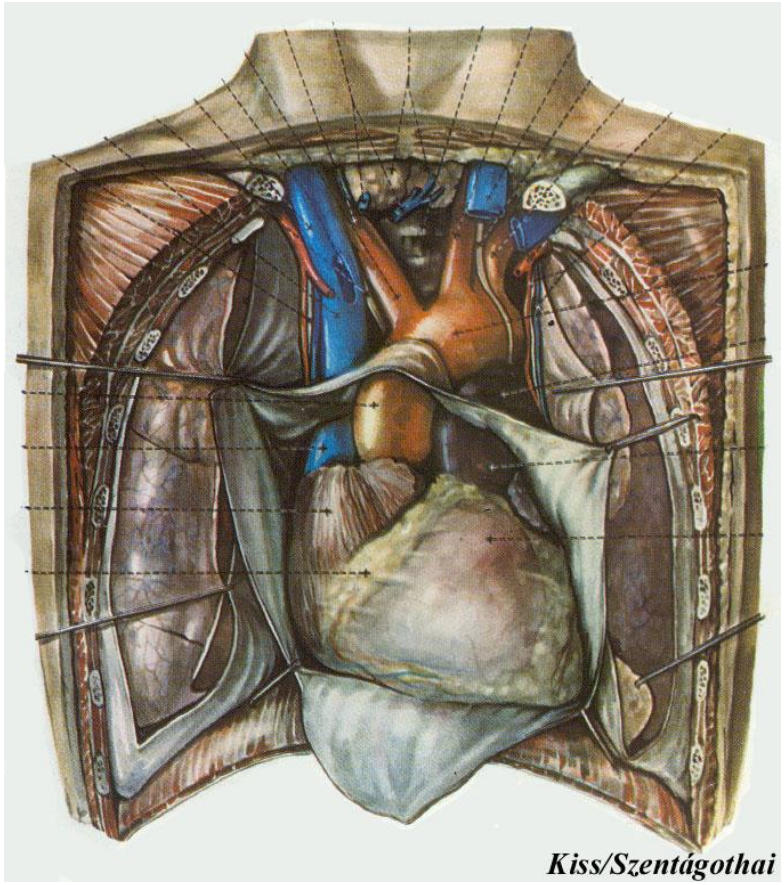

Kiss/Szentágothai

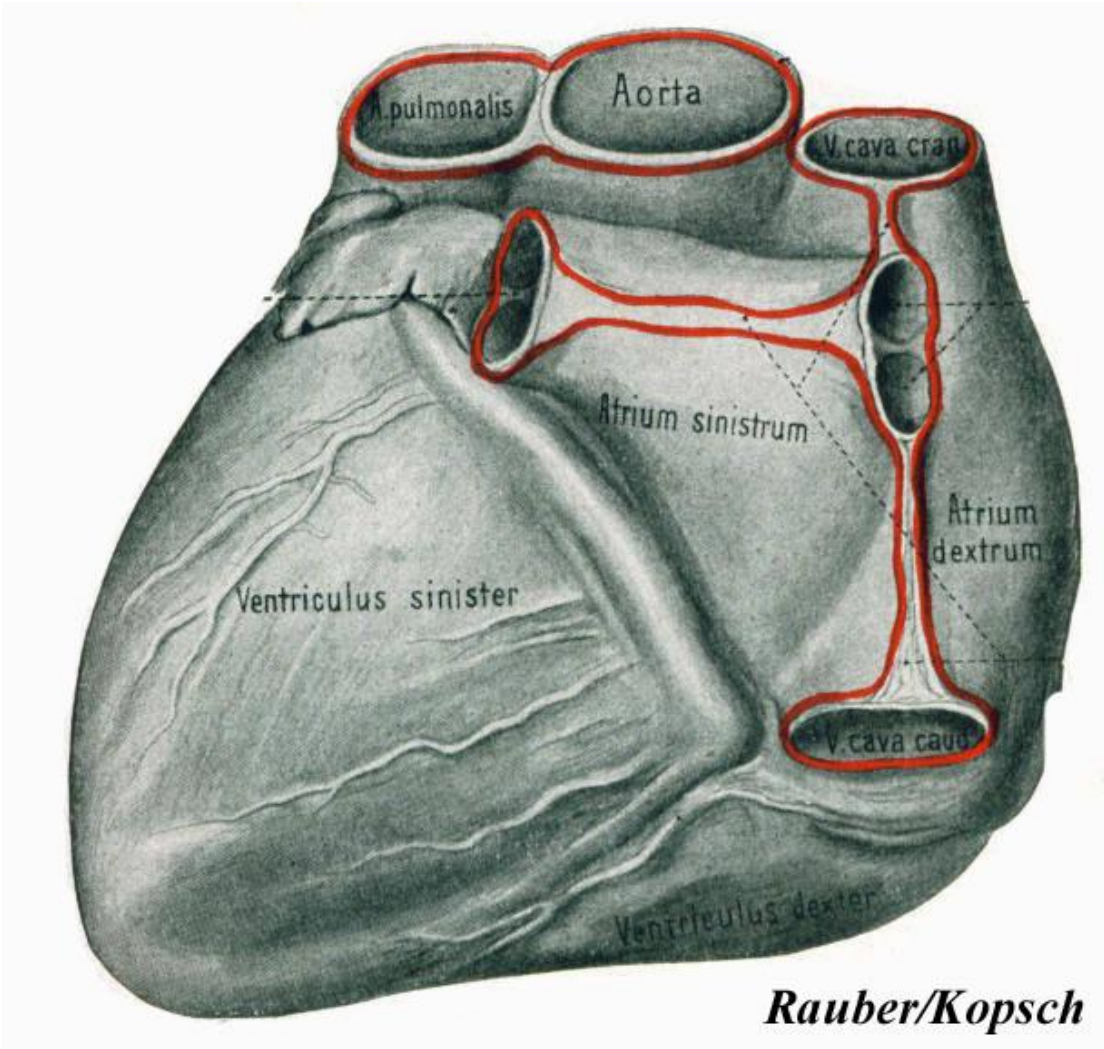

Rauber/Kopsch

Situs cordis - Mediastinum

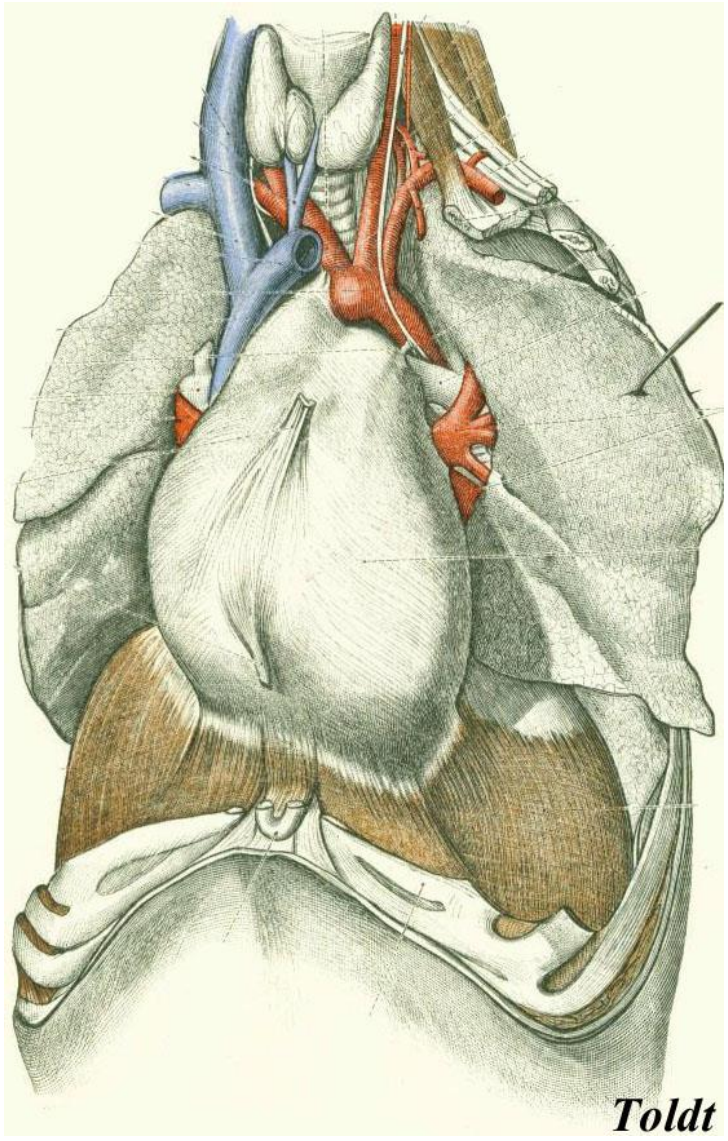

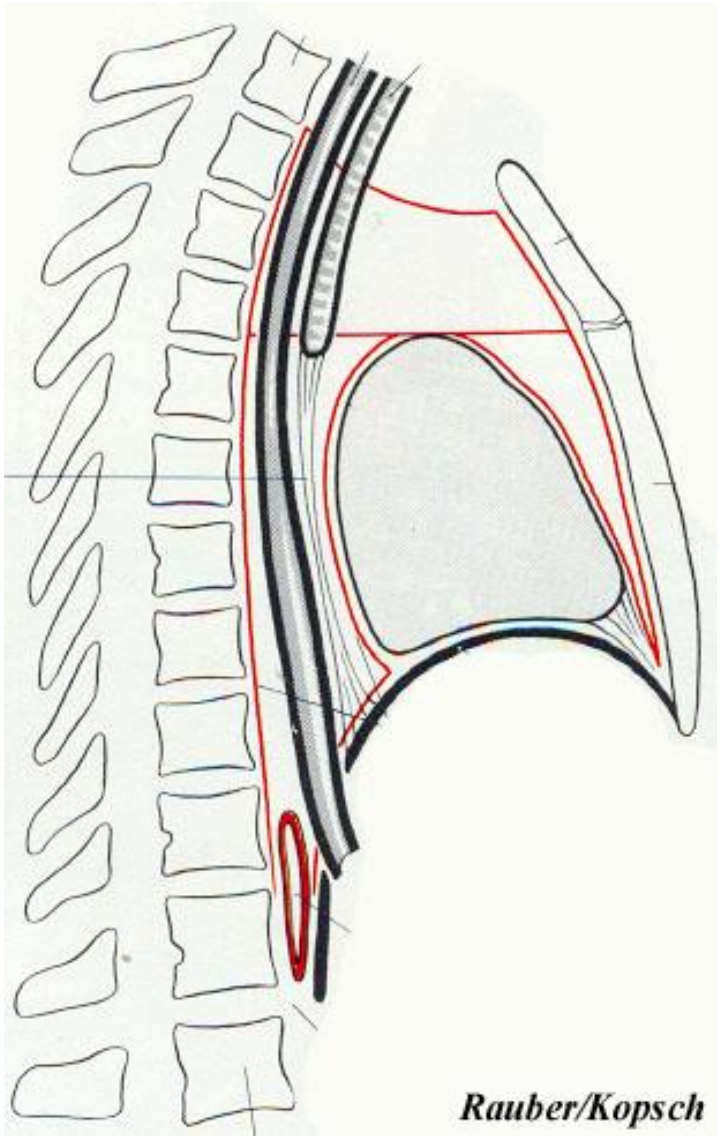

Surface projection

SVC
3. rib cartilage, sternal margin

V. cava inf.
6. rib cartilage sternal margin

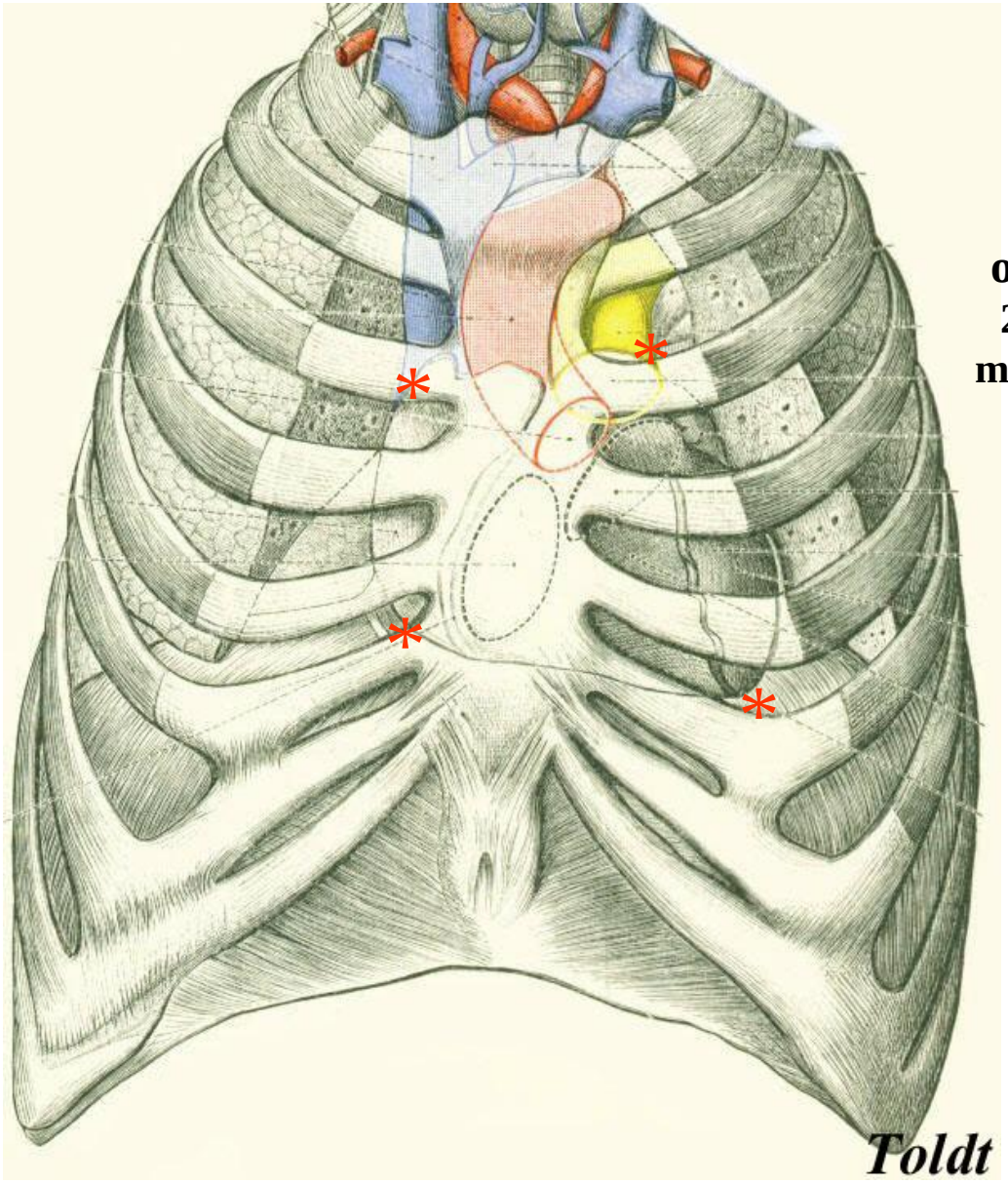

Upper pole of coronary sulcus
2. intercostal space, middle of rib cartilage

Apex of heart
5. intercostal space, medioclavicular line

Surface projection of valves

Aortic orifice *
3. intercostal space, left sternal margin

Tricuspid valve *
behind the sternum, 4. intercostal space

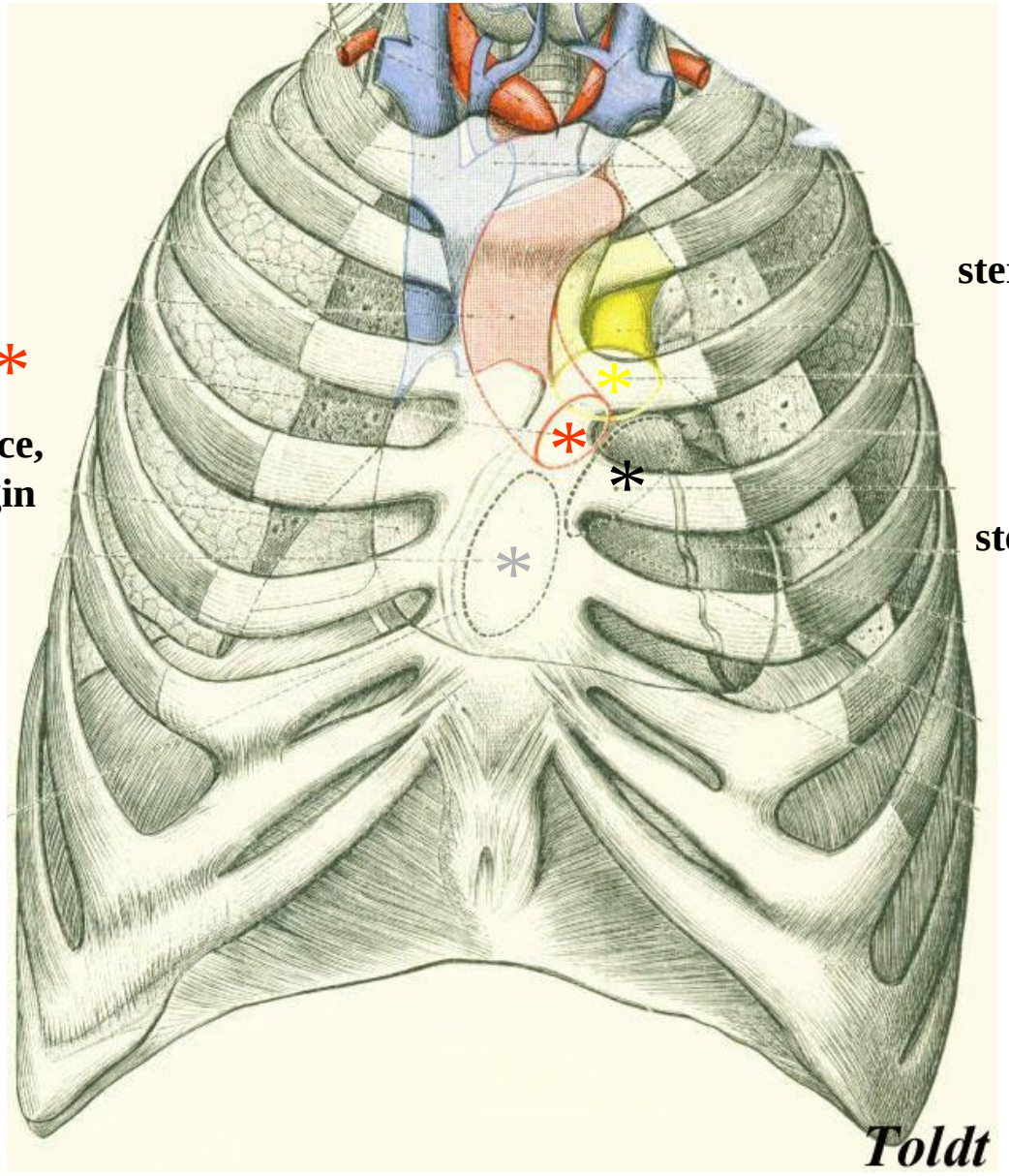

Pulmonary *
sternal end of 3. rib, left

Bicuspid valve *
sternal end of 4. rib, left

Cardiac auscultation

Blood stream

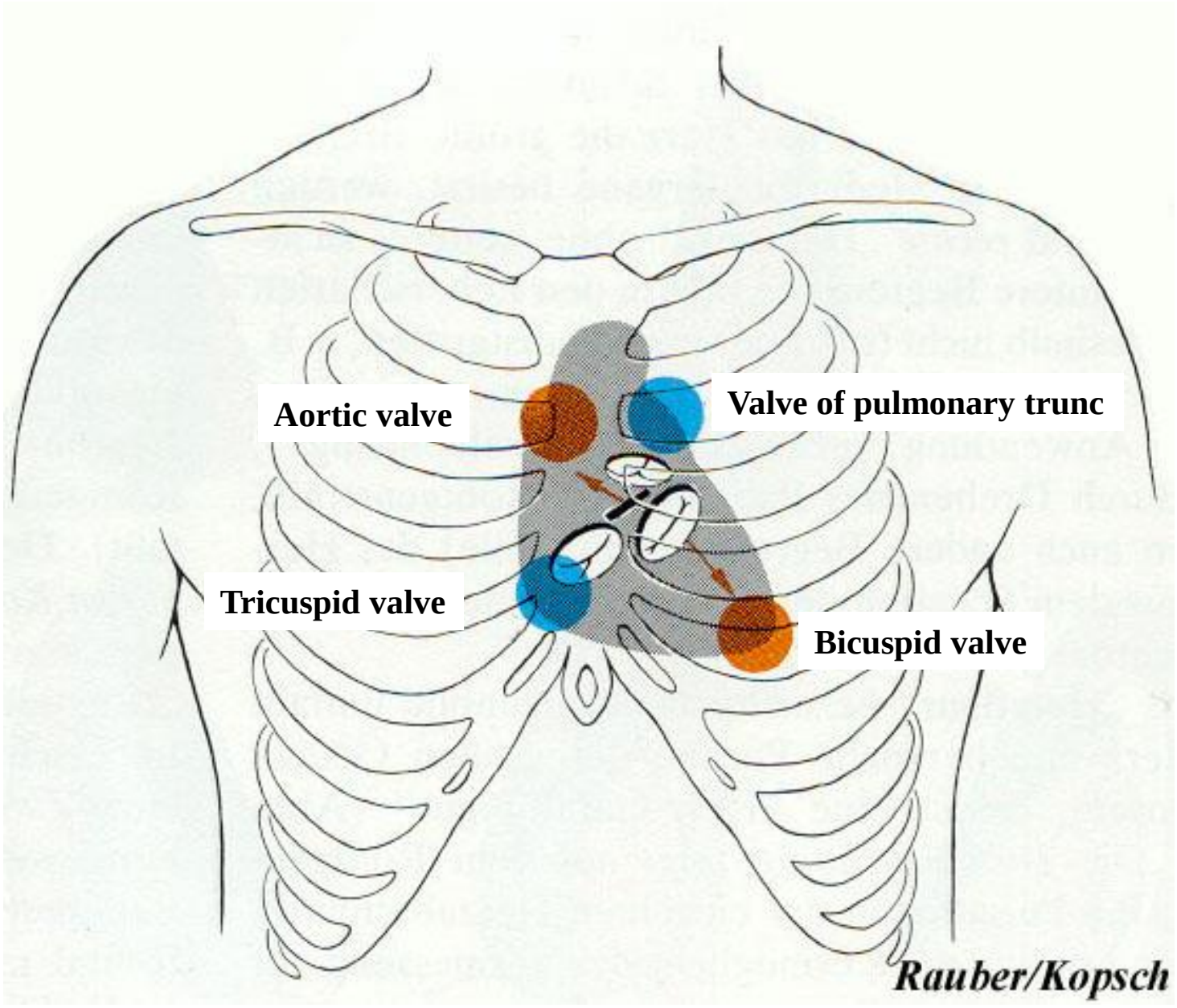

Absolute and relative dullness

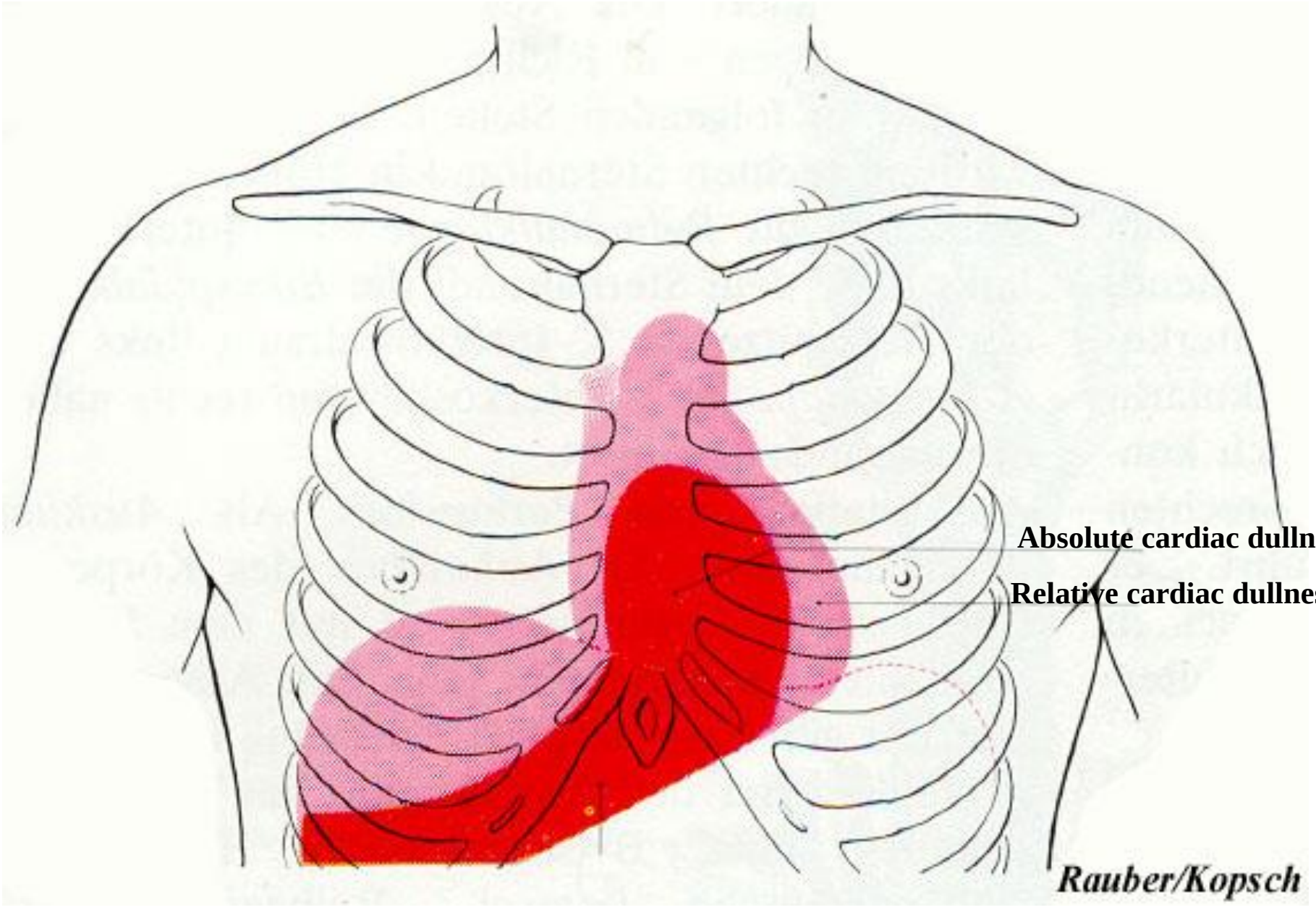

X-ray of the thorax

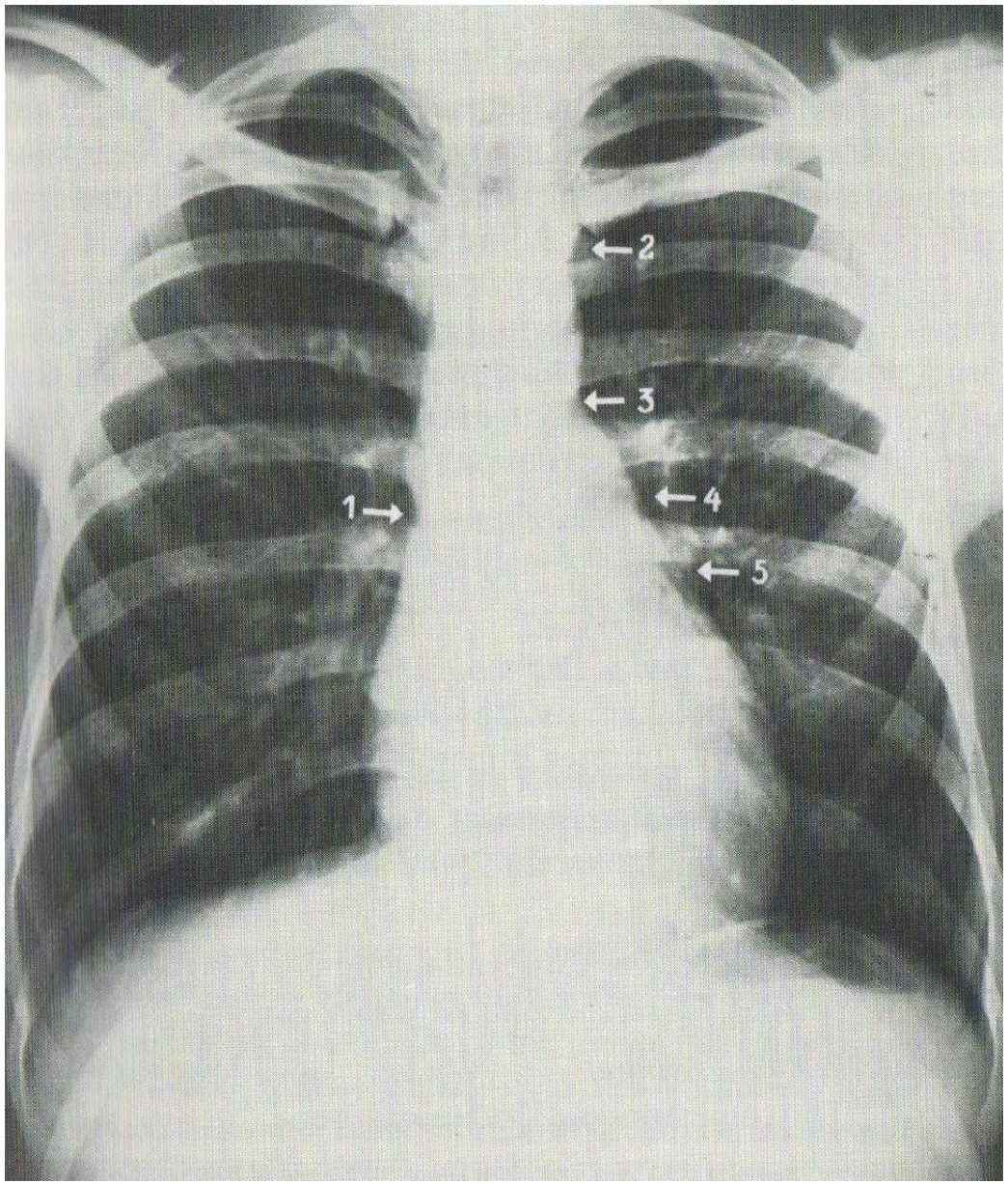

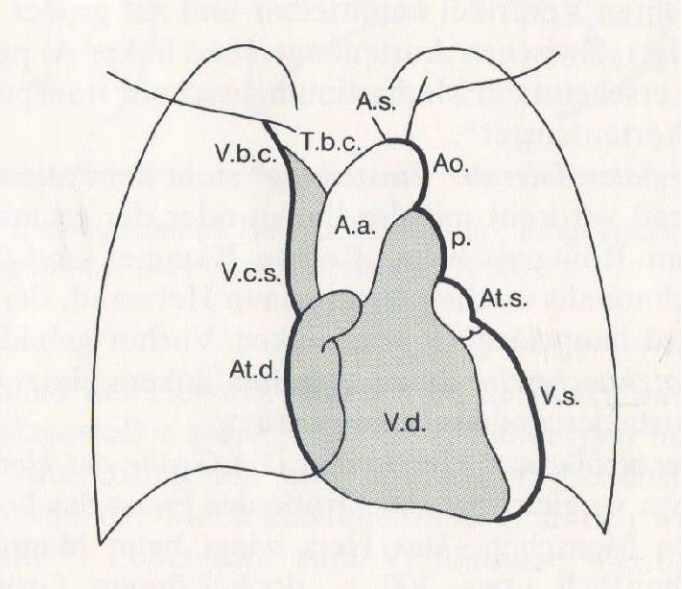

Rauber/Kopsch