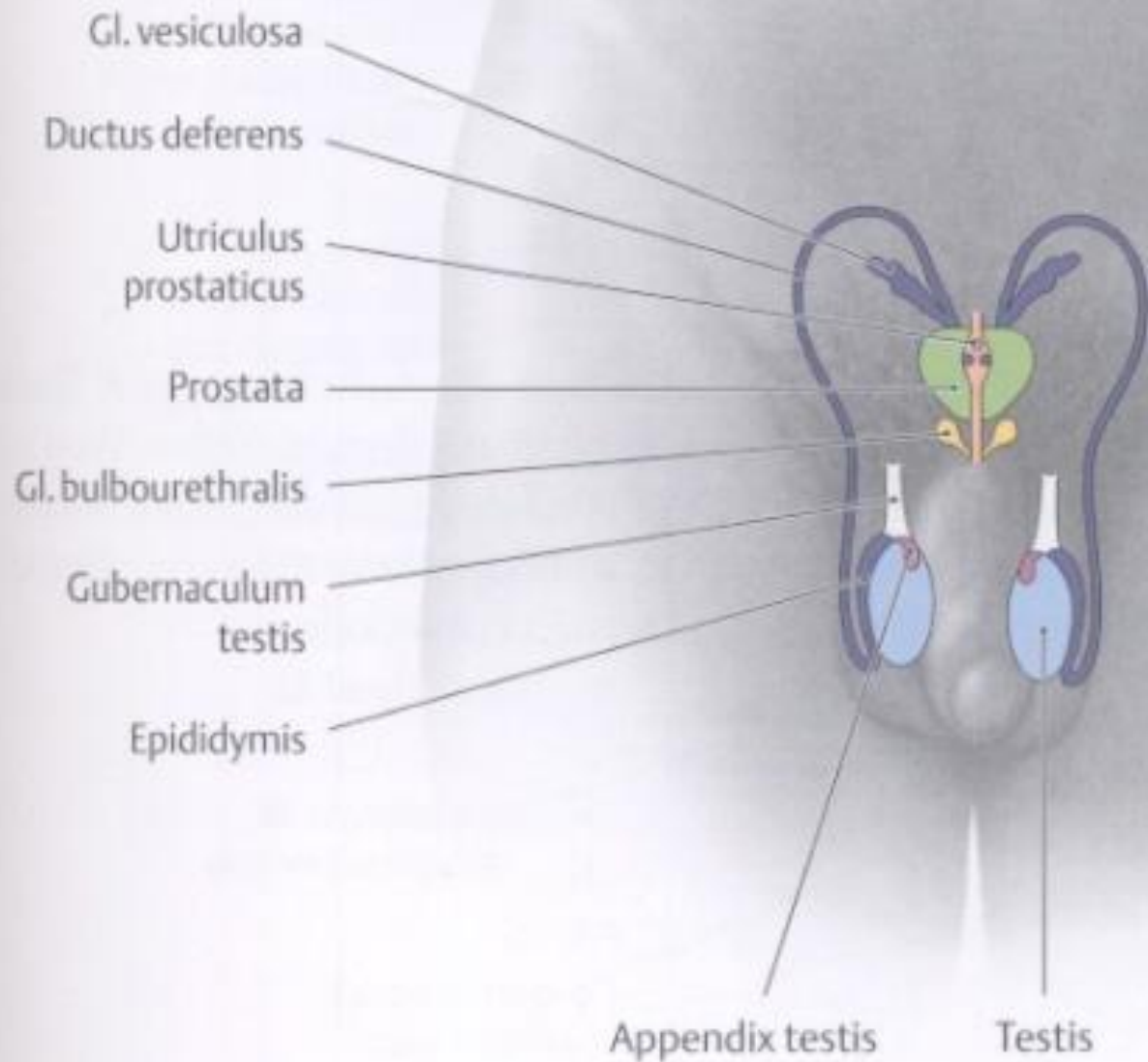
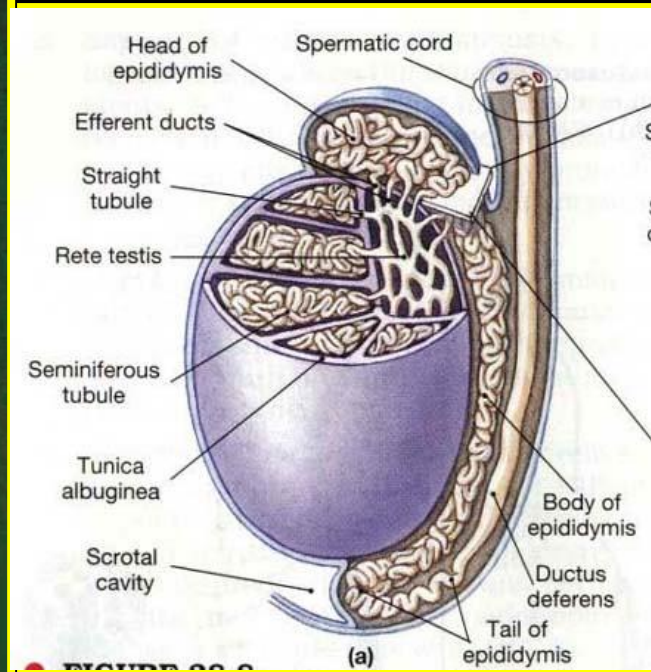
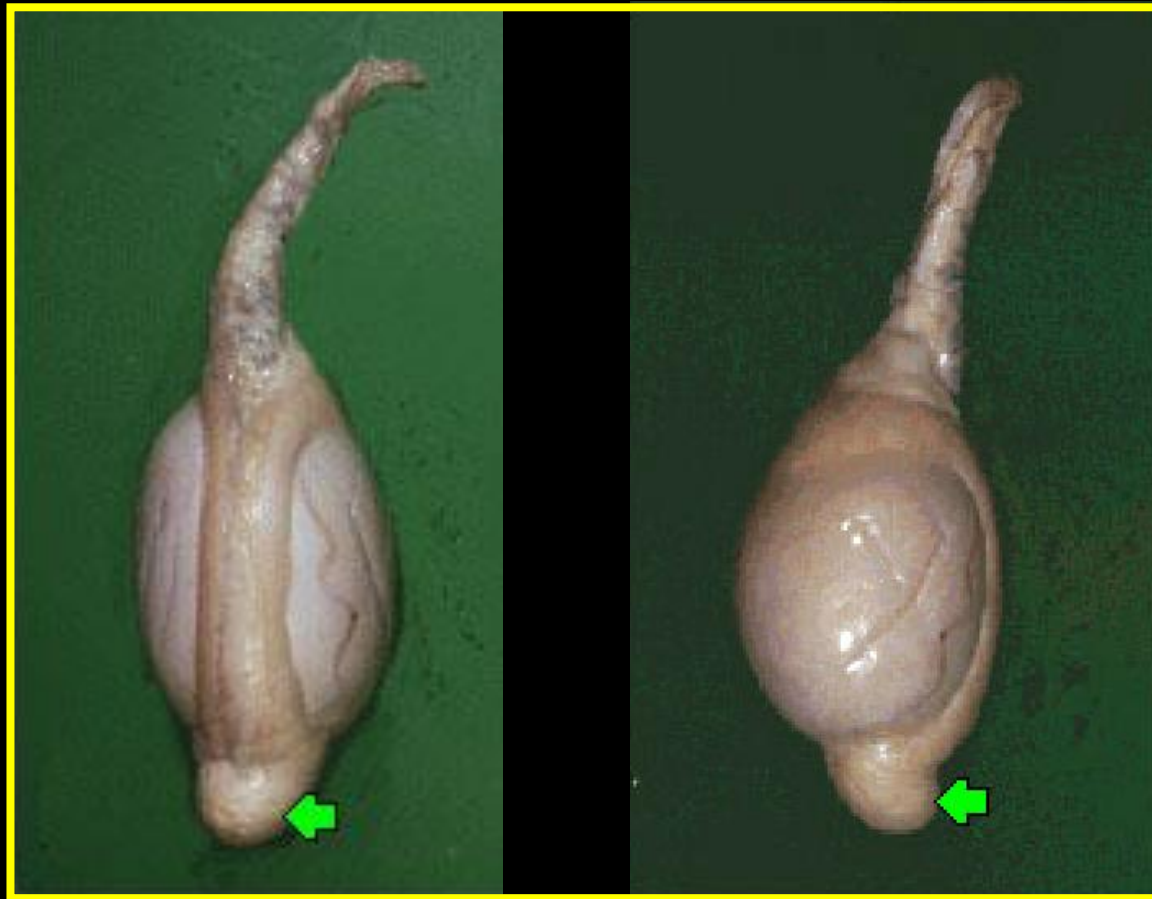

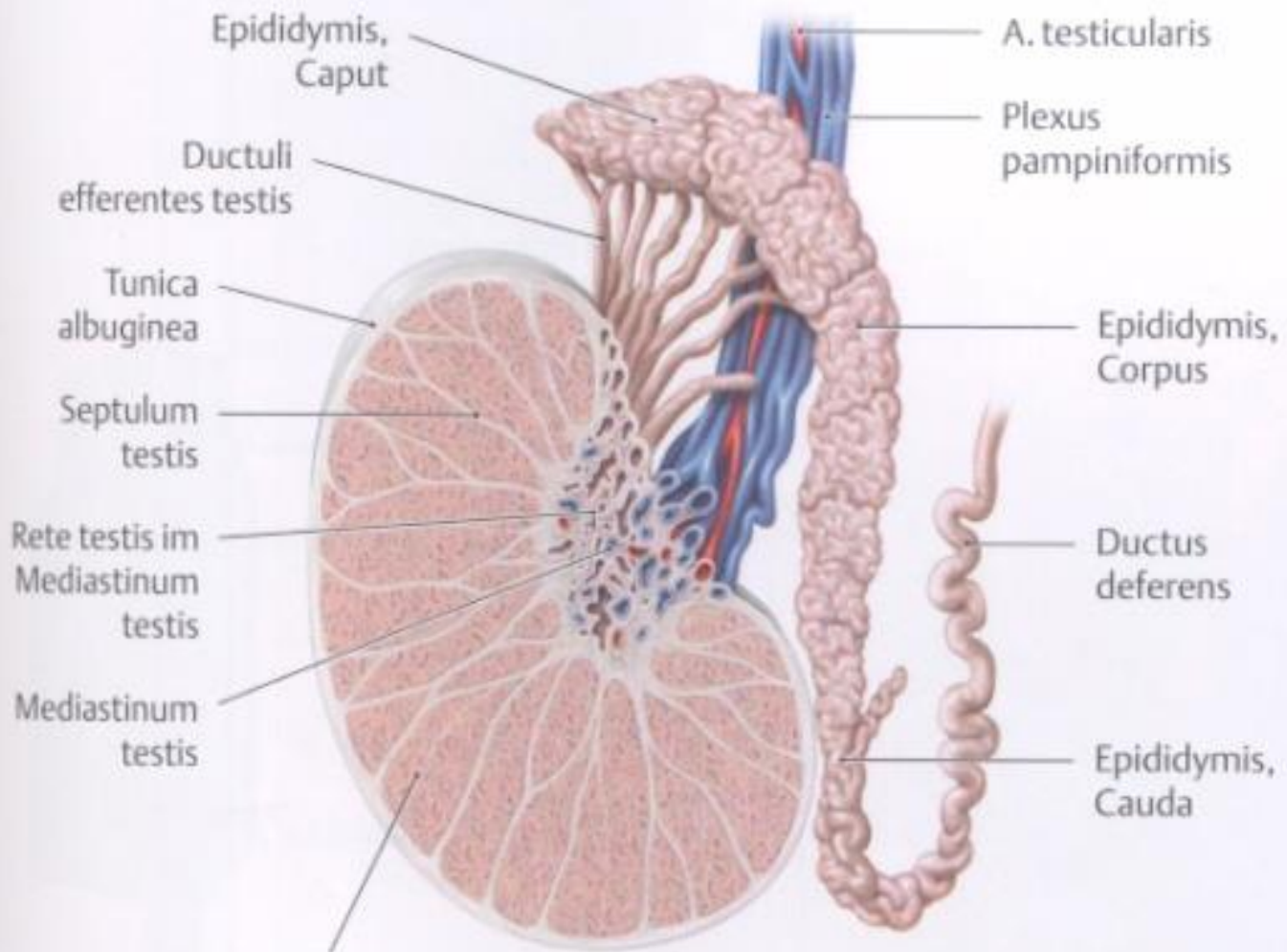
Testis , scrotum and coats of testis

János Barna

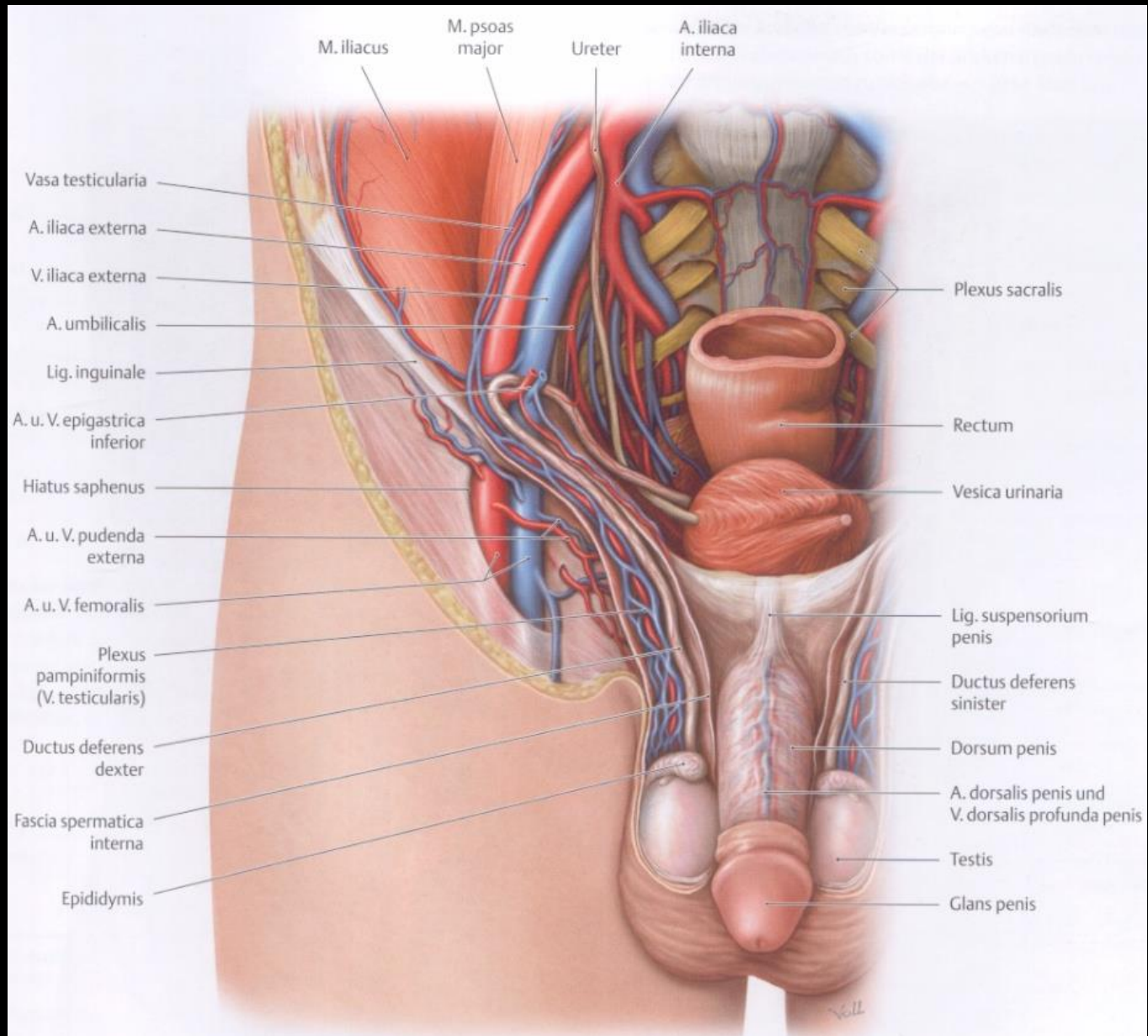


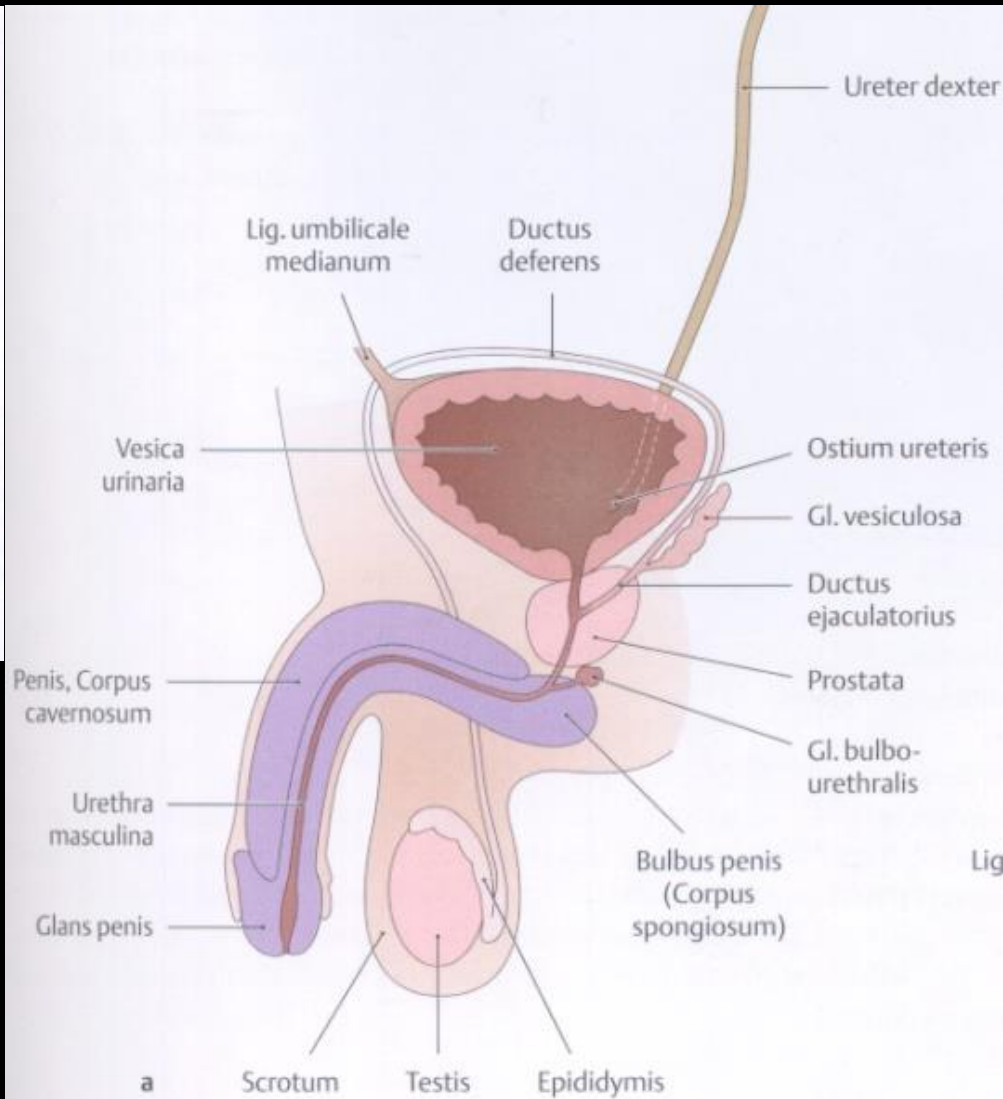
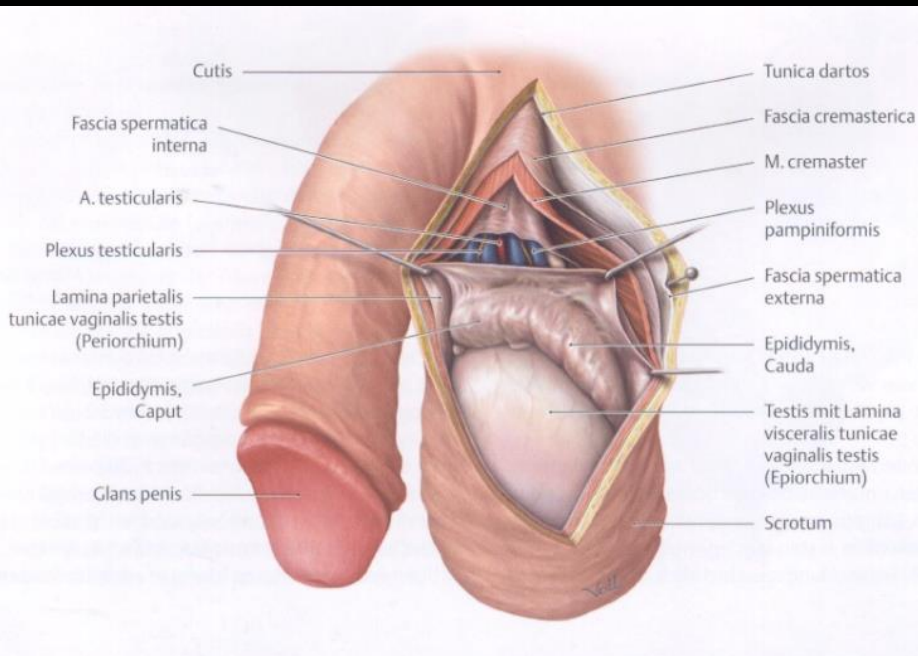
Testis



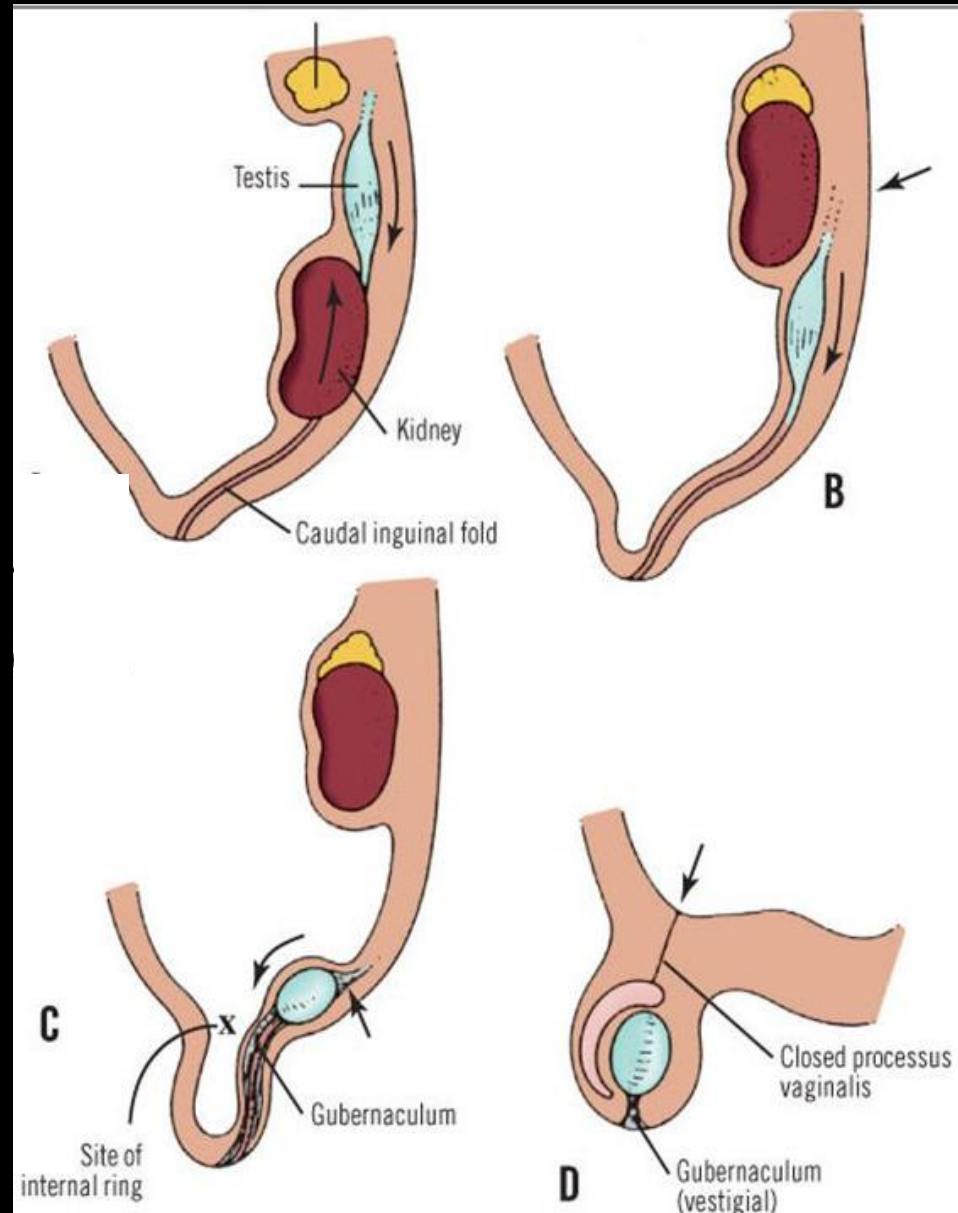


a Lobulus testis



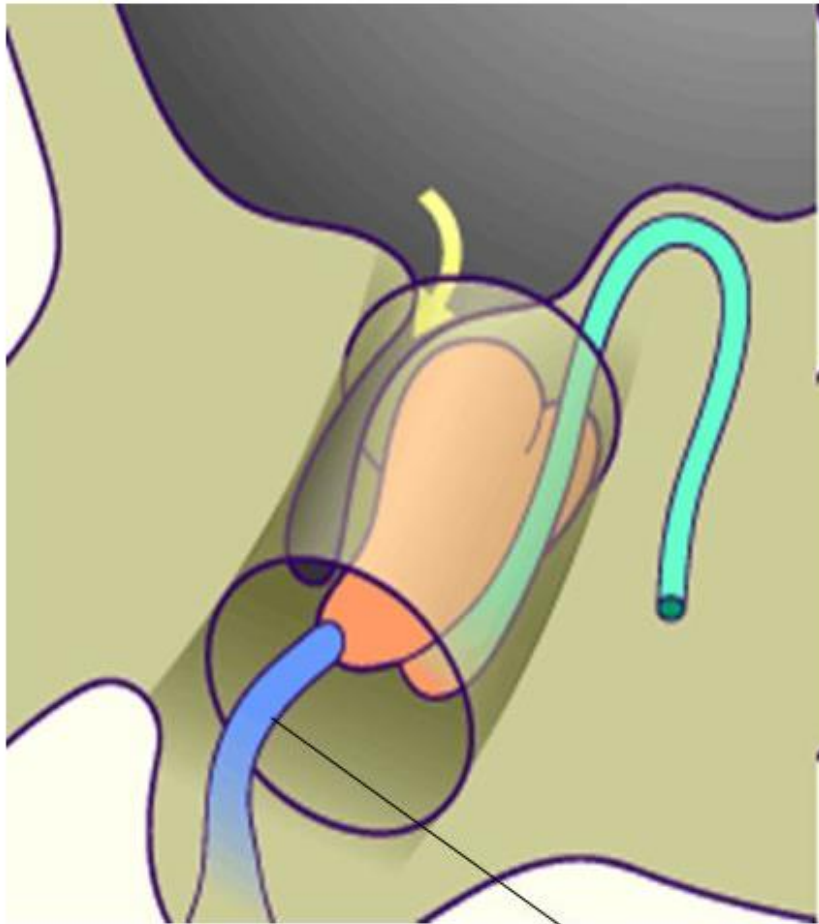


Descent of the testes

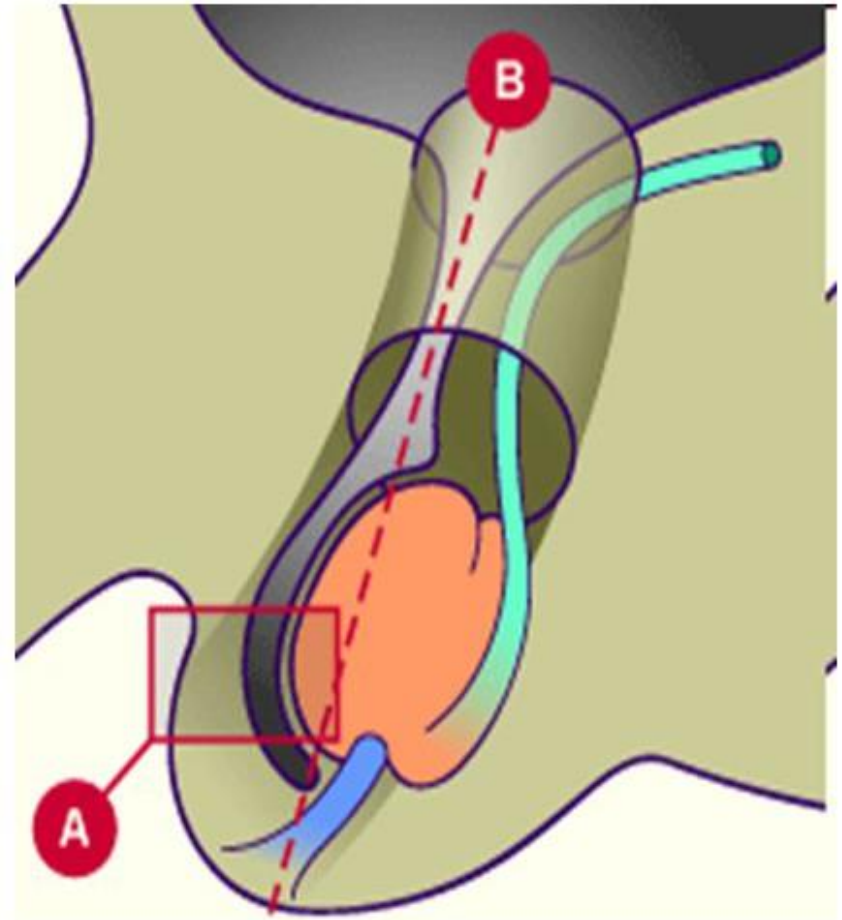


Descent of testis

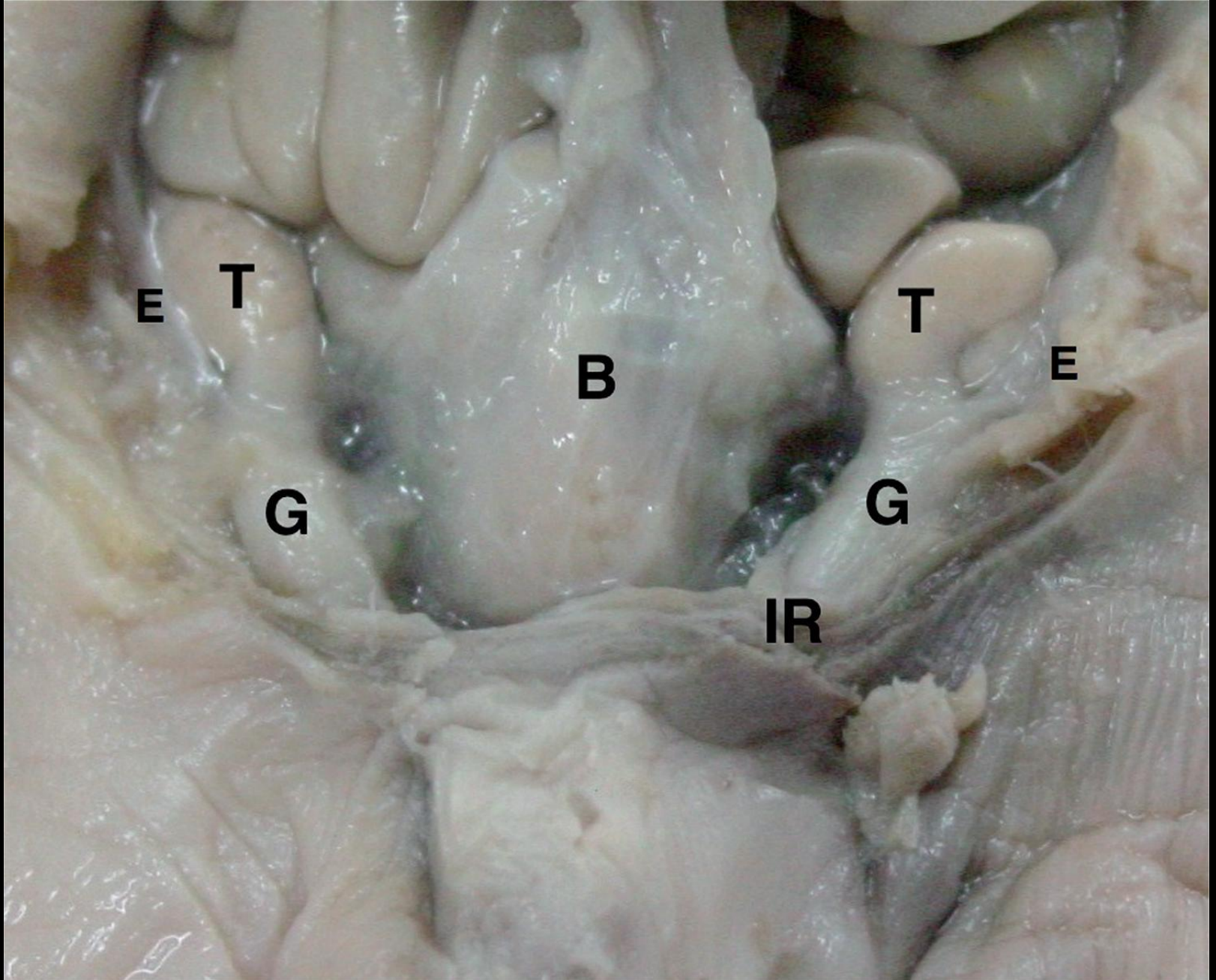
7 month



9 month

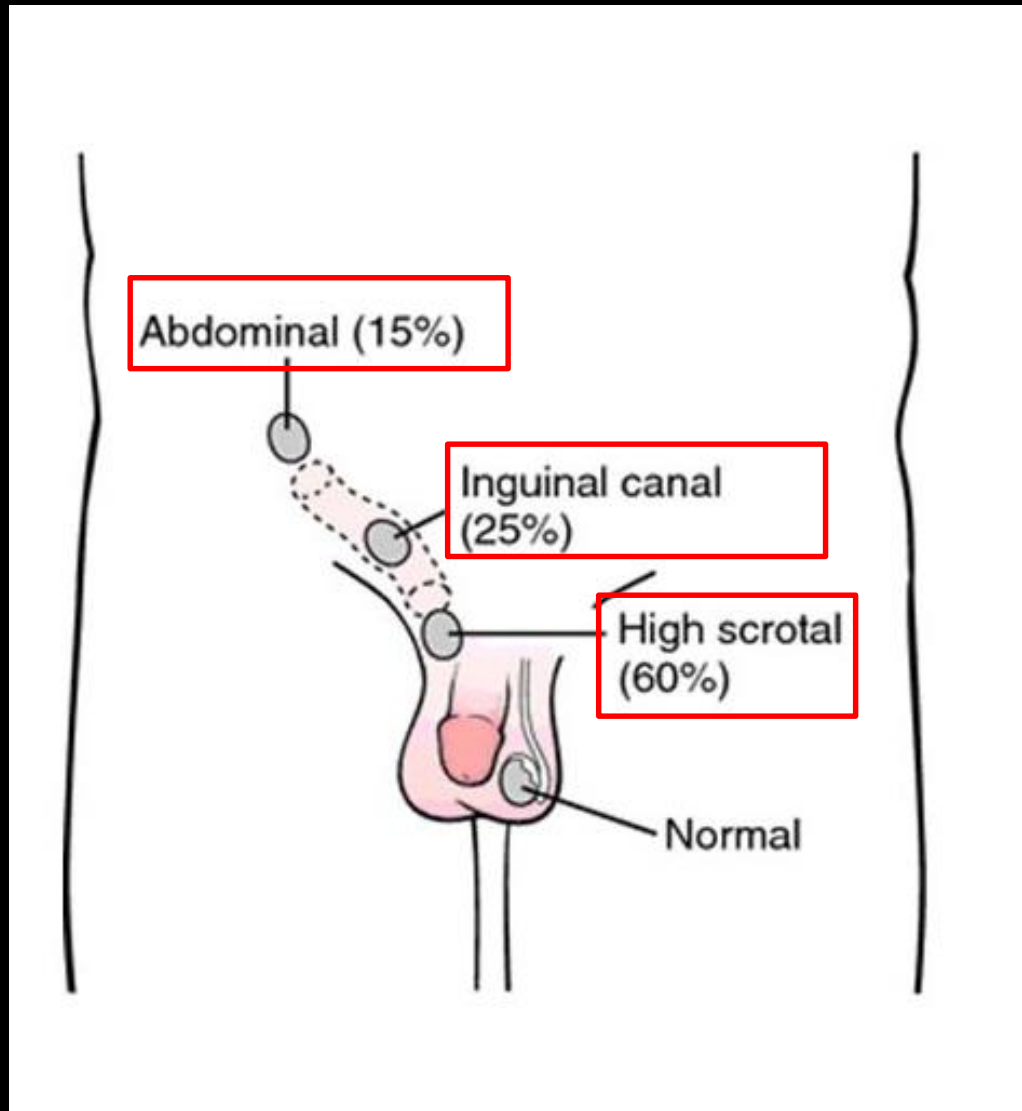


→ Gubernaculum testis

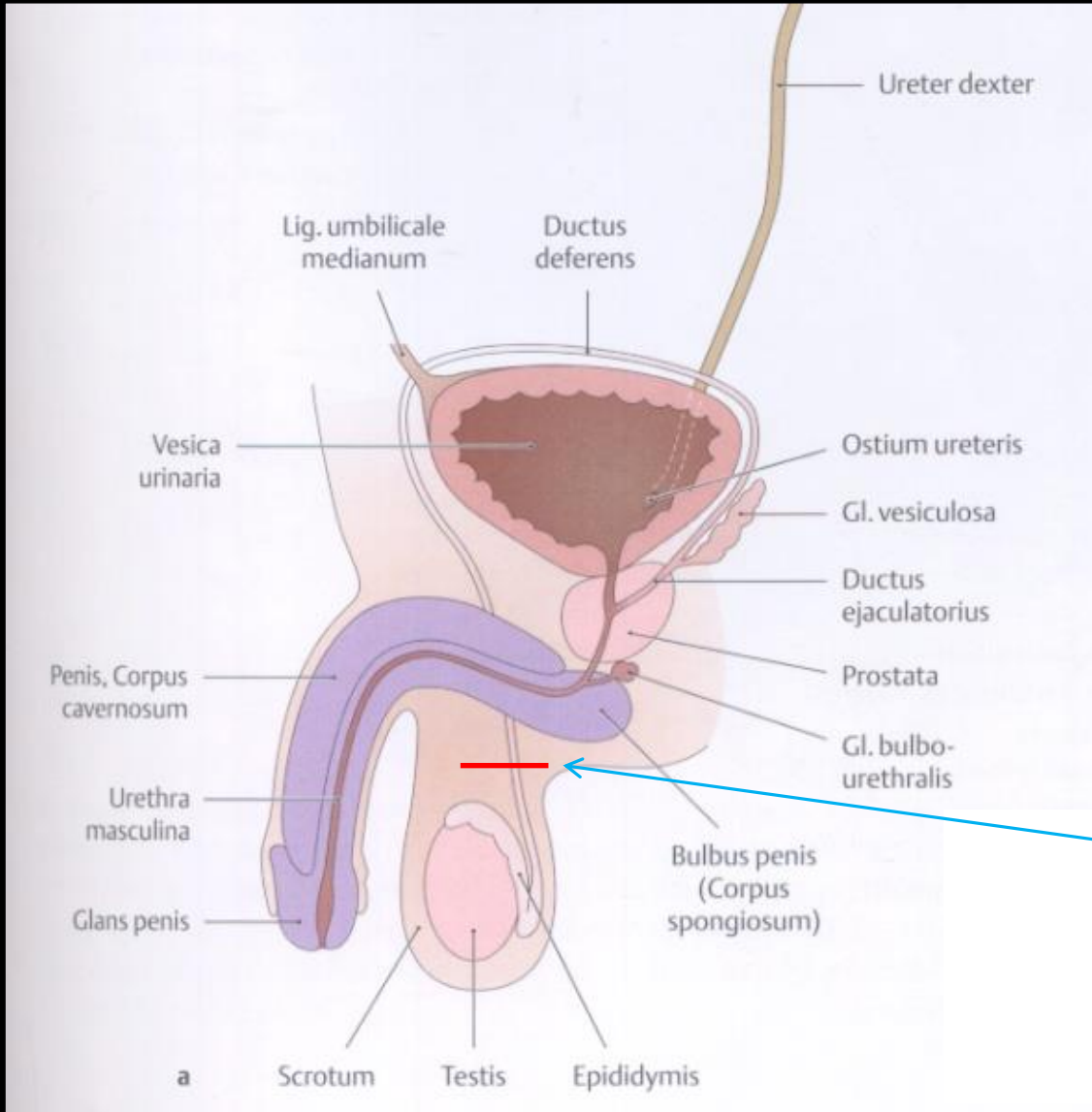


Testis (T) and epididymis (E) above the internal/deep inguinal ring (IR), gubernaculum (G) and the bladder (B)

Cryptorchidism

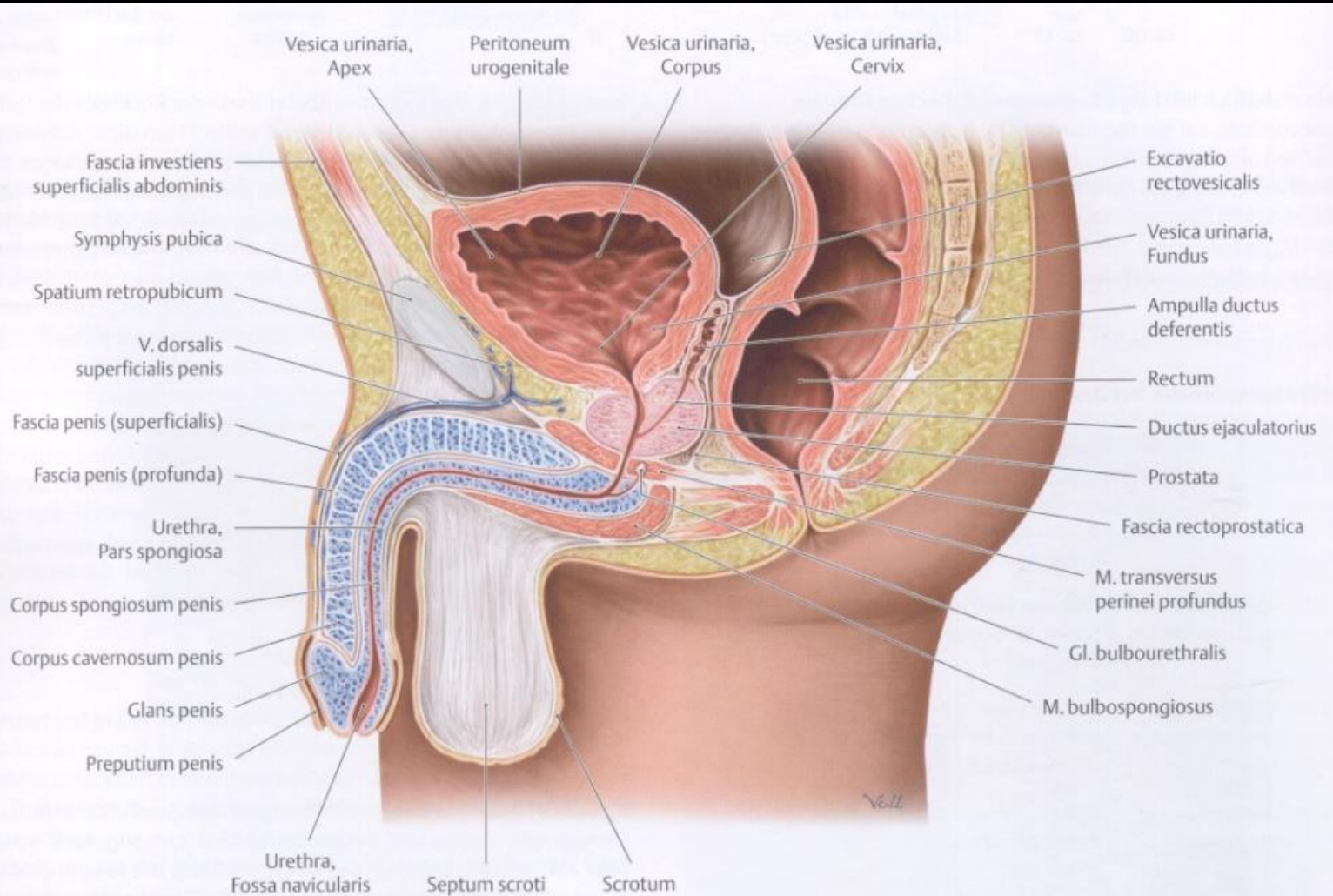
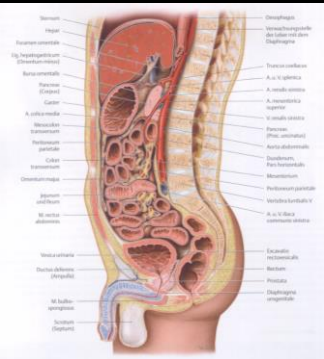


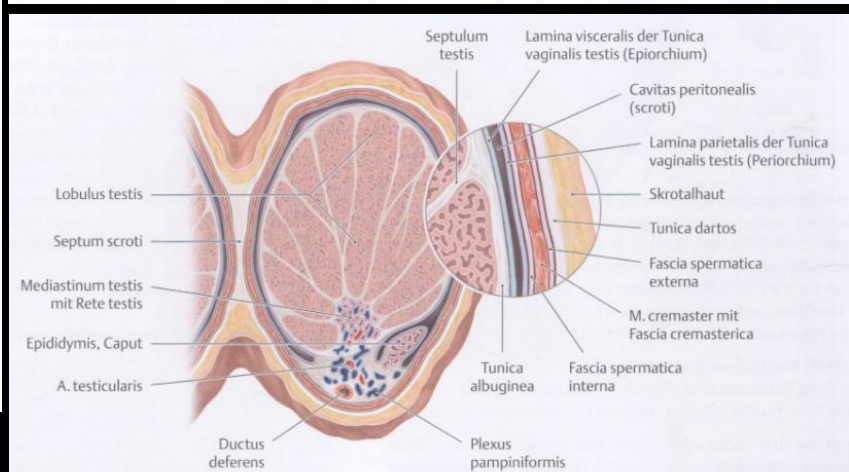
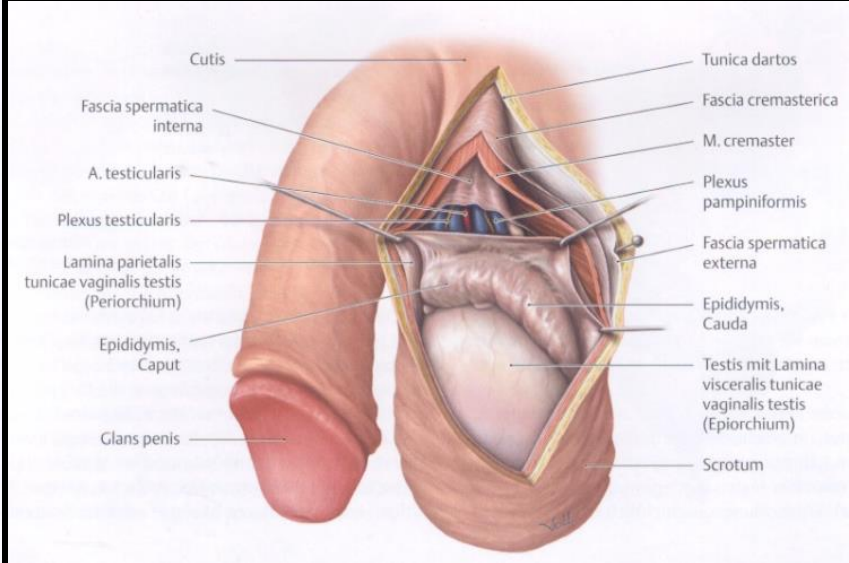
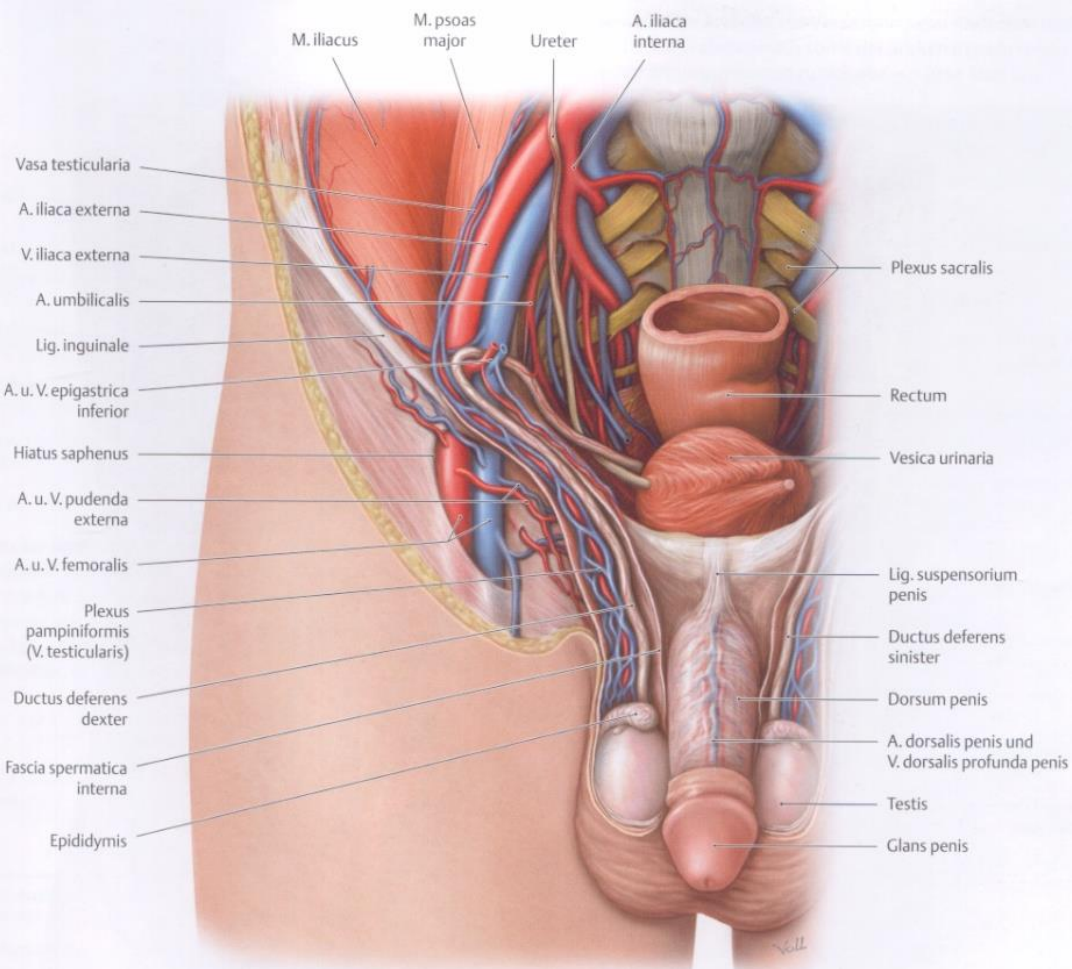
Male sterilization



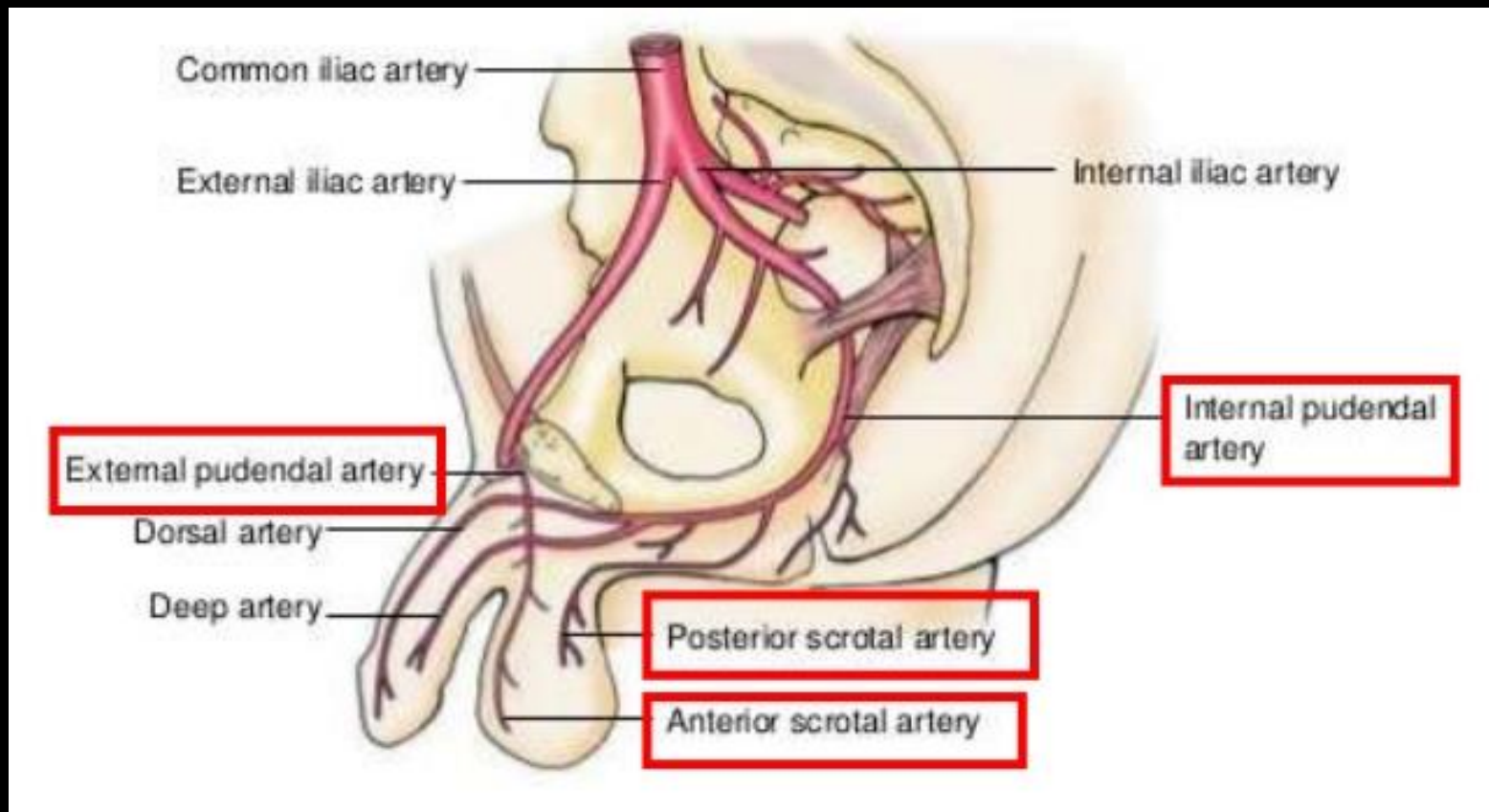
Vasectomy

Scrotum

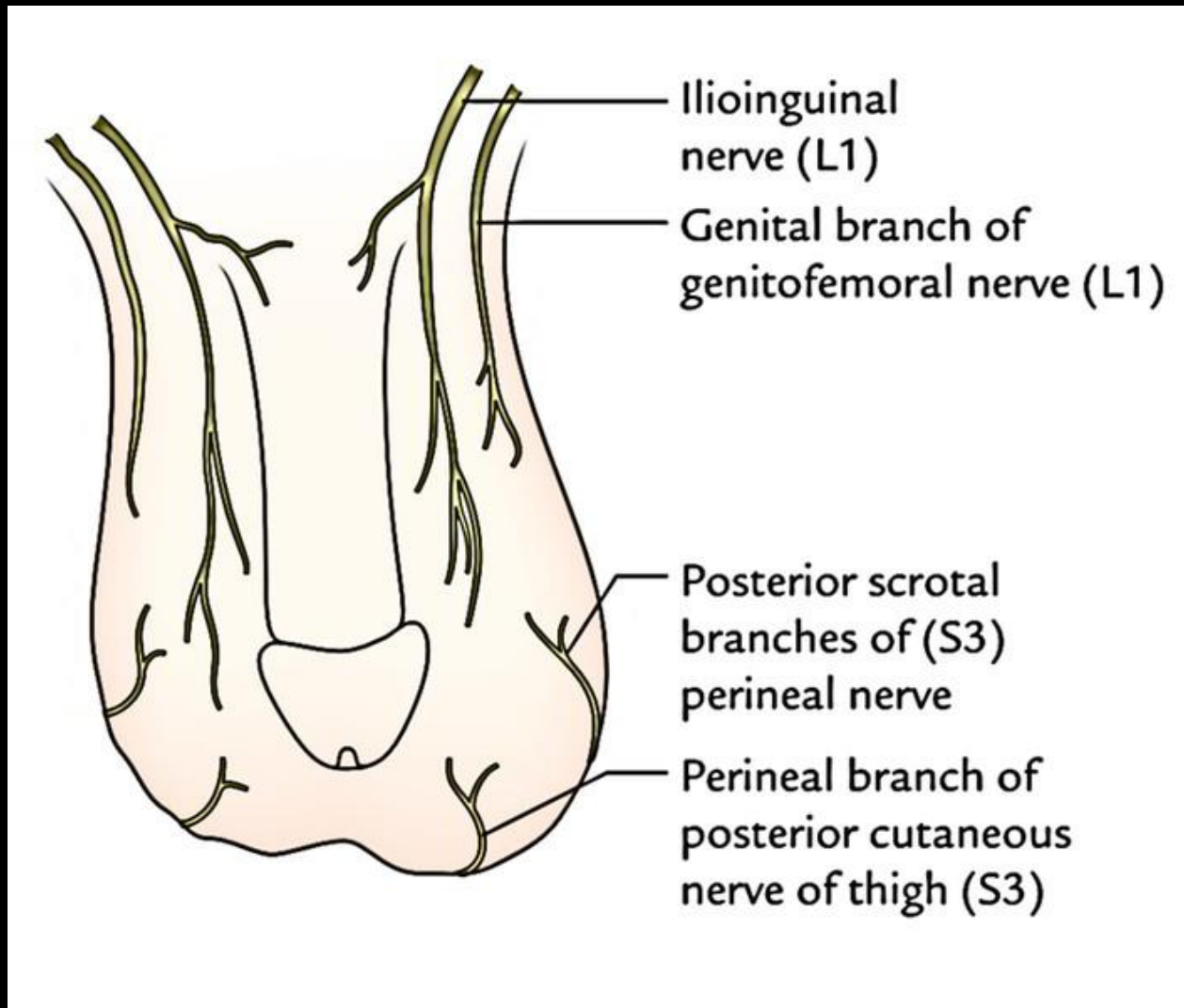




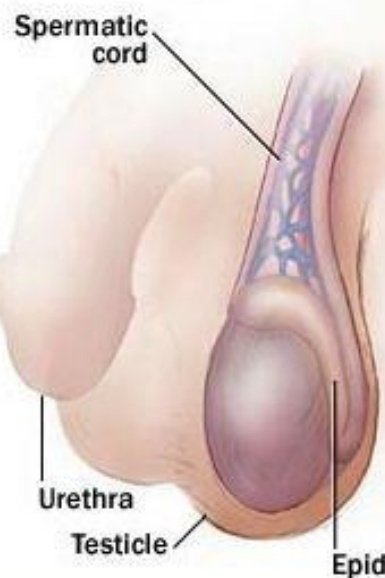
Blood supply of the scrotum



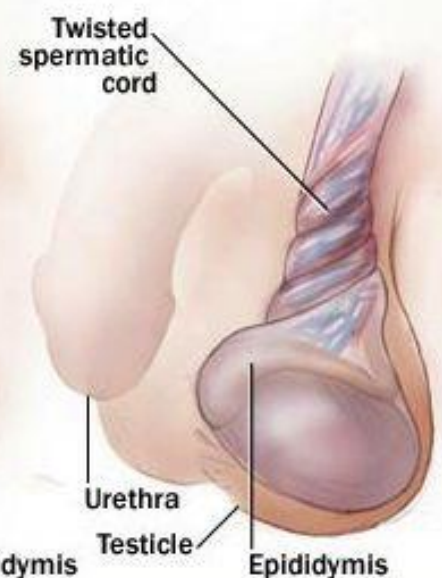
Innervation of the scrotum



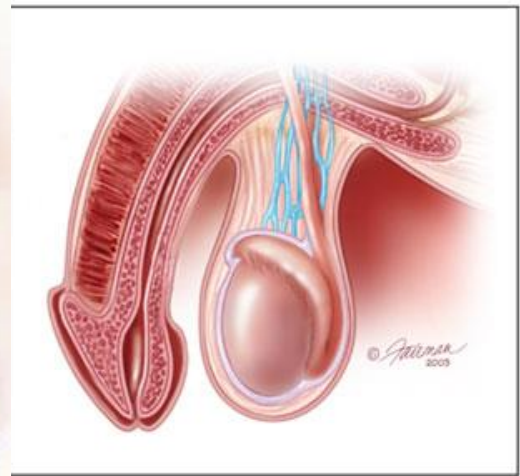
Normal testicle



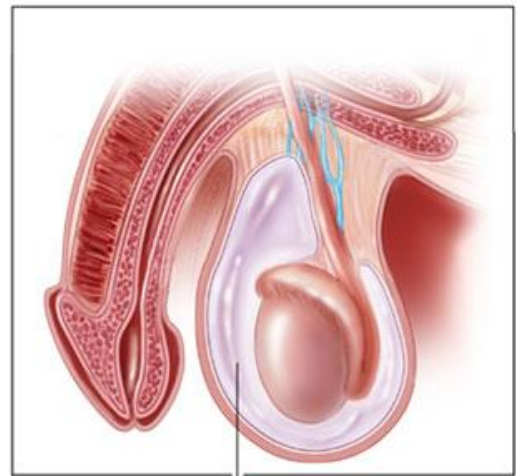
Testicular torsion



NORMAL

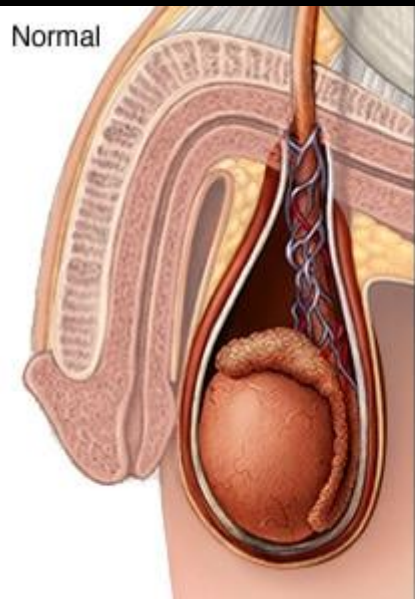


ABNORMAL

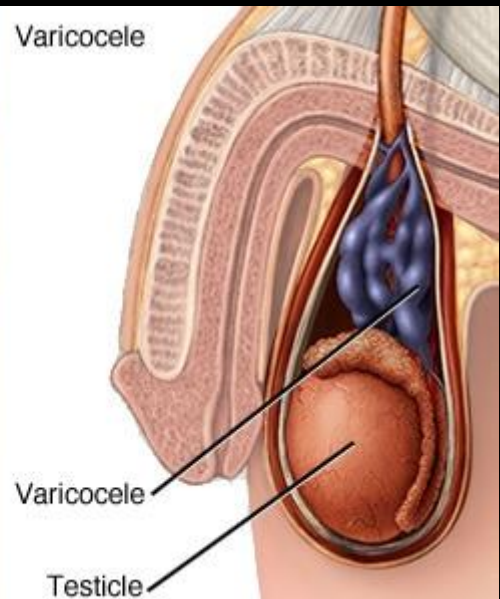


Hydrocele

Normal



Varicocele



hematocele

