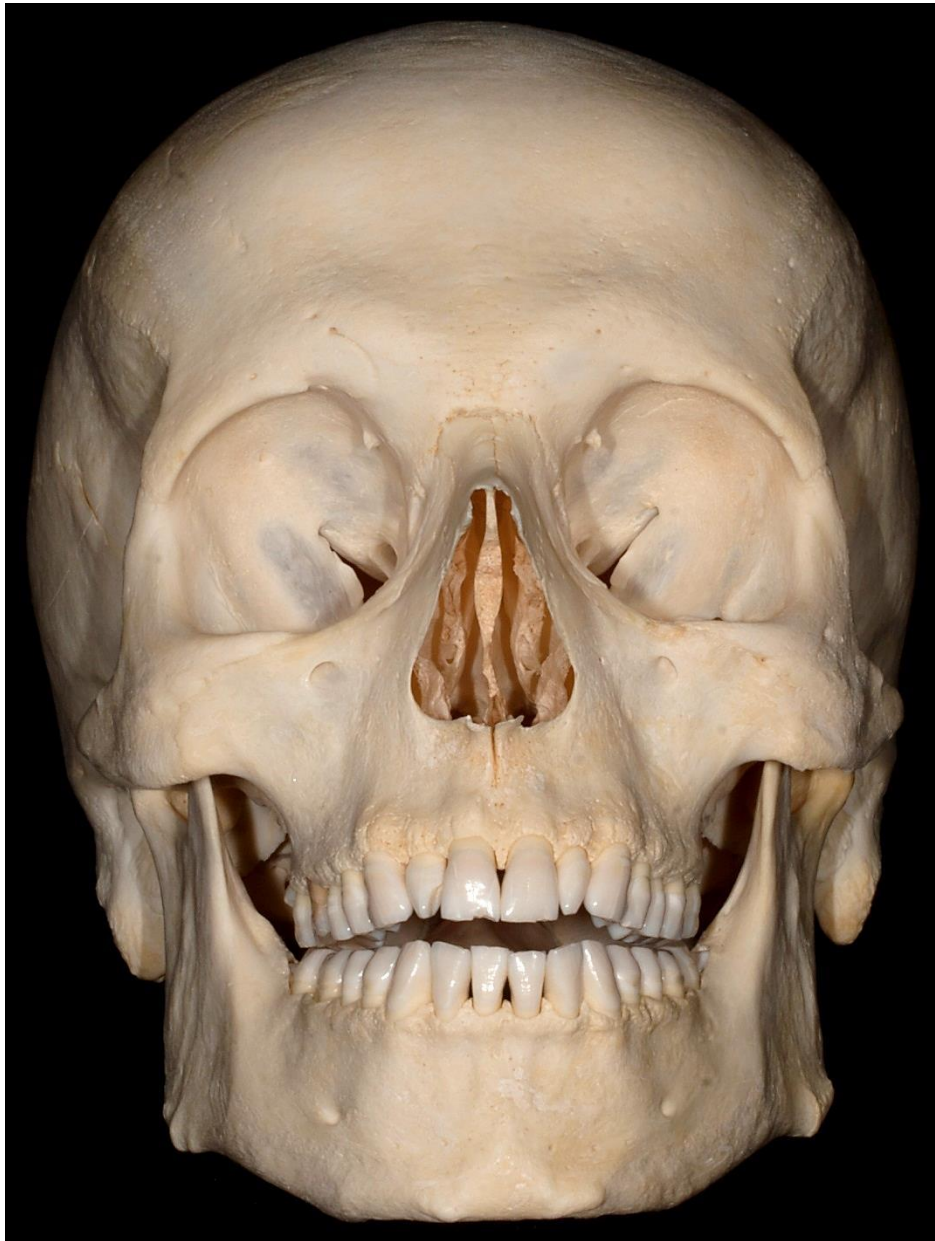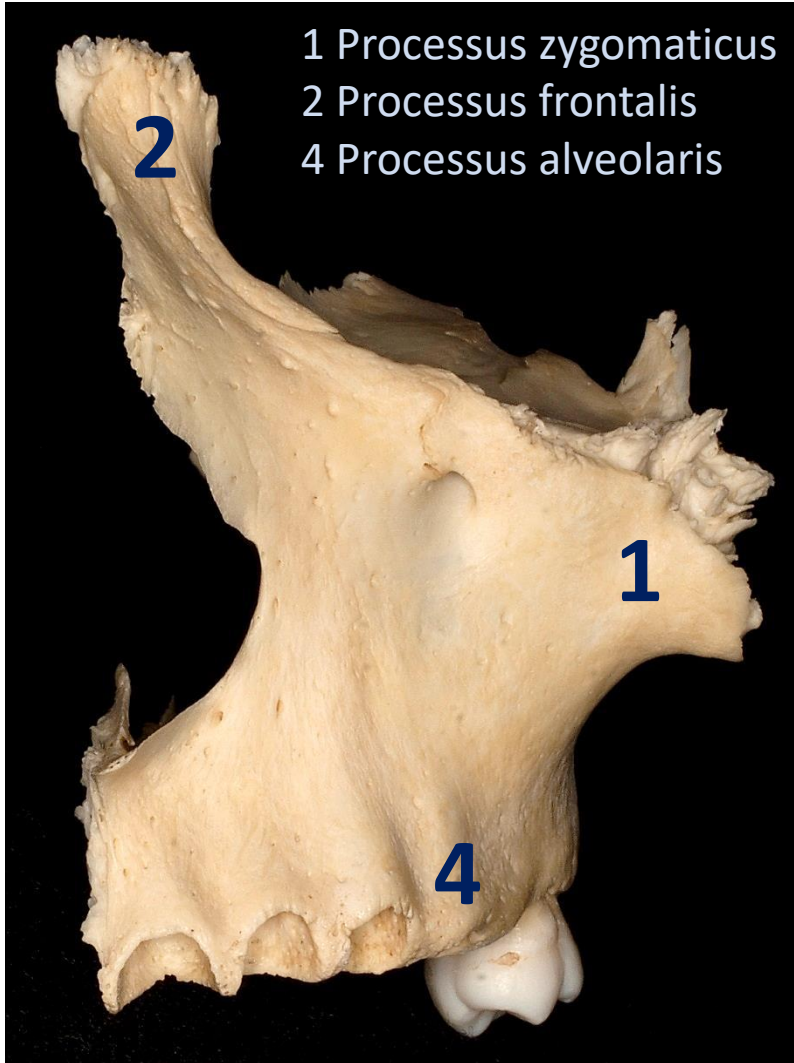


Maxilla

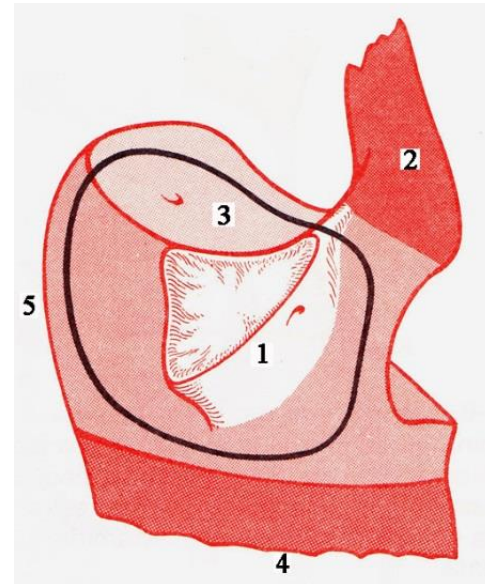
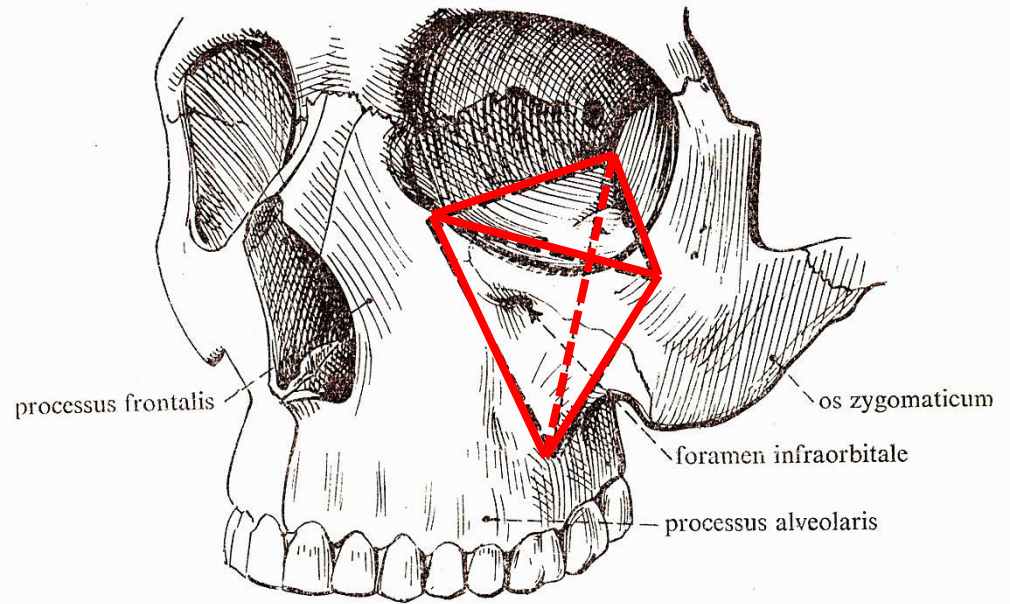
Gábor Baksa - László Bárány



Aspectus anterior



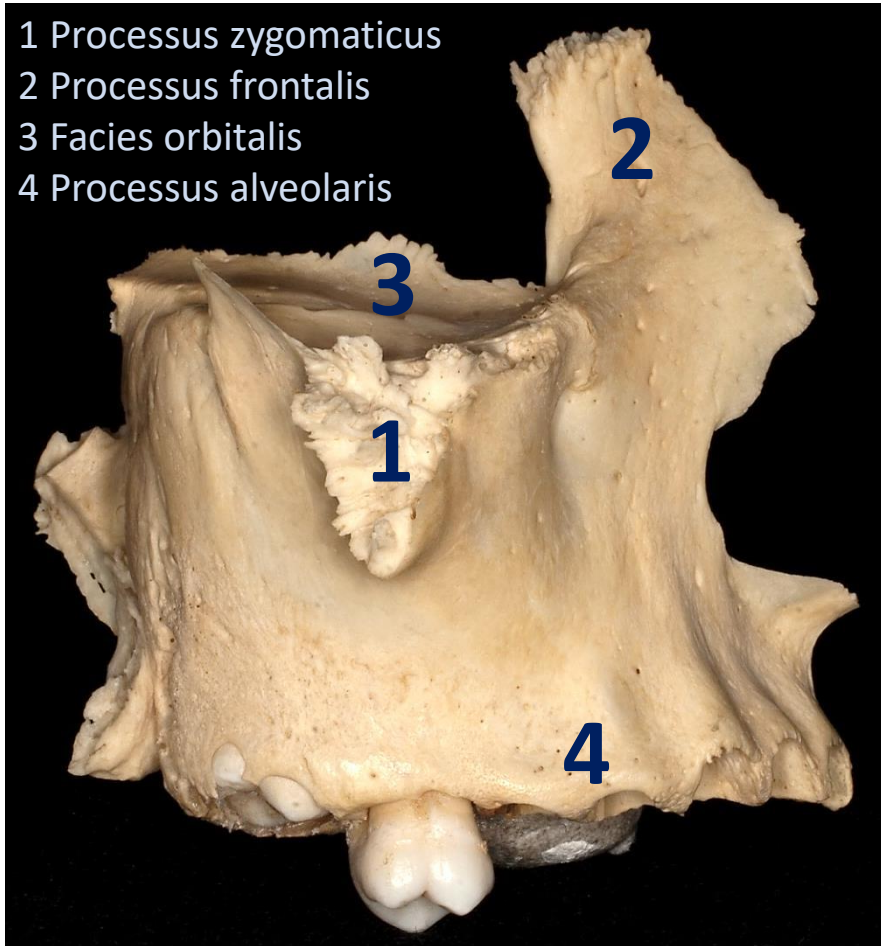
(linke Seite)



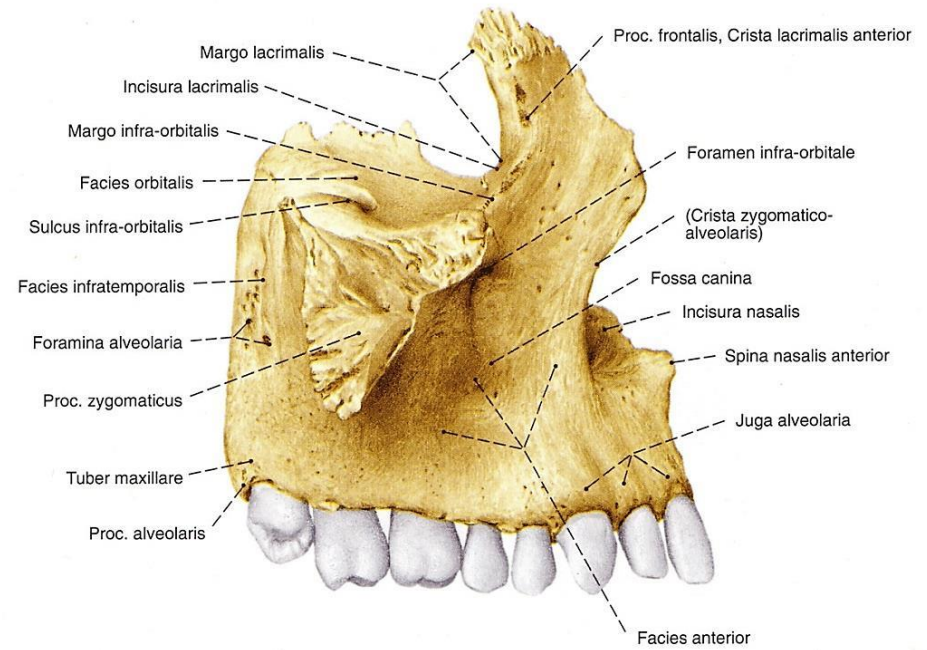
Faller

Aspectus lateralis

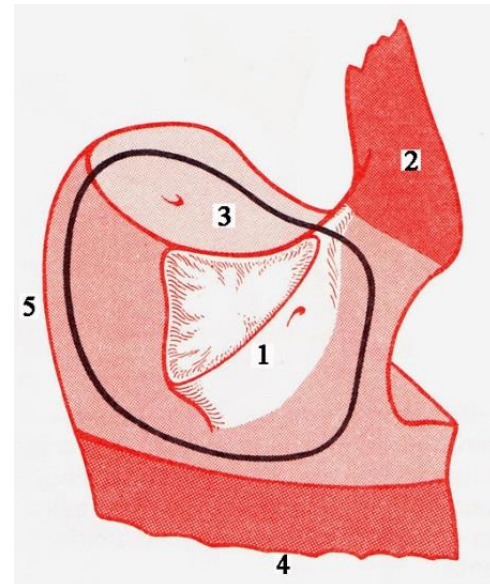
- 1 Processus zygomaticus
- 2 Processus frontalis
- 3 Facies orbitalis
- 4 Processus alveolaris



(rechte Seite)

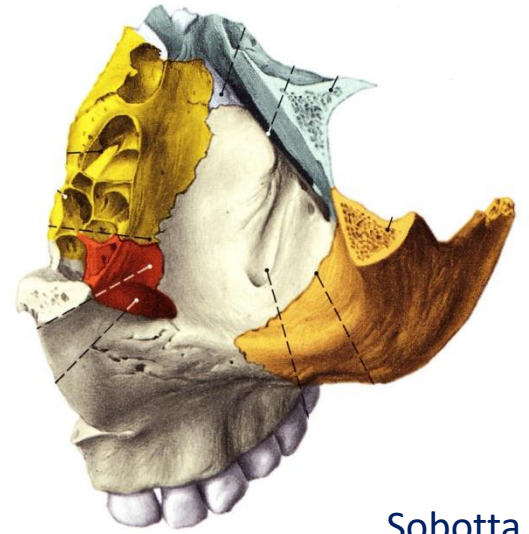


Sobotta

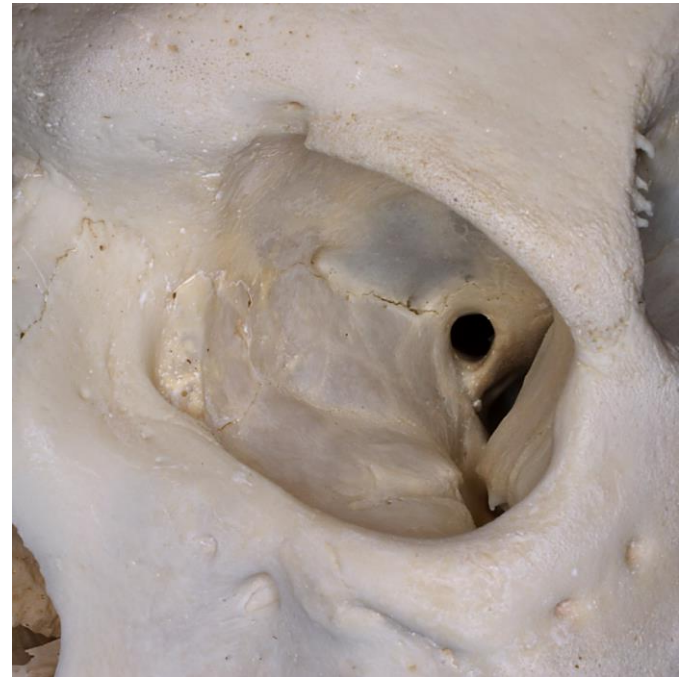
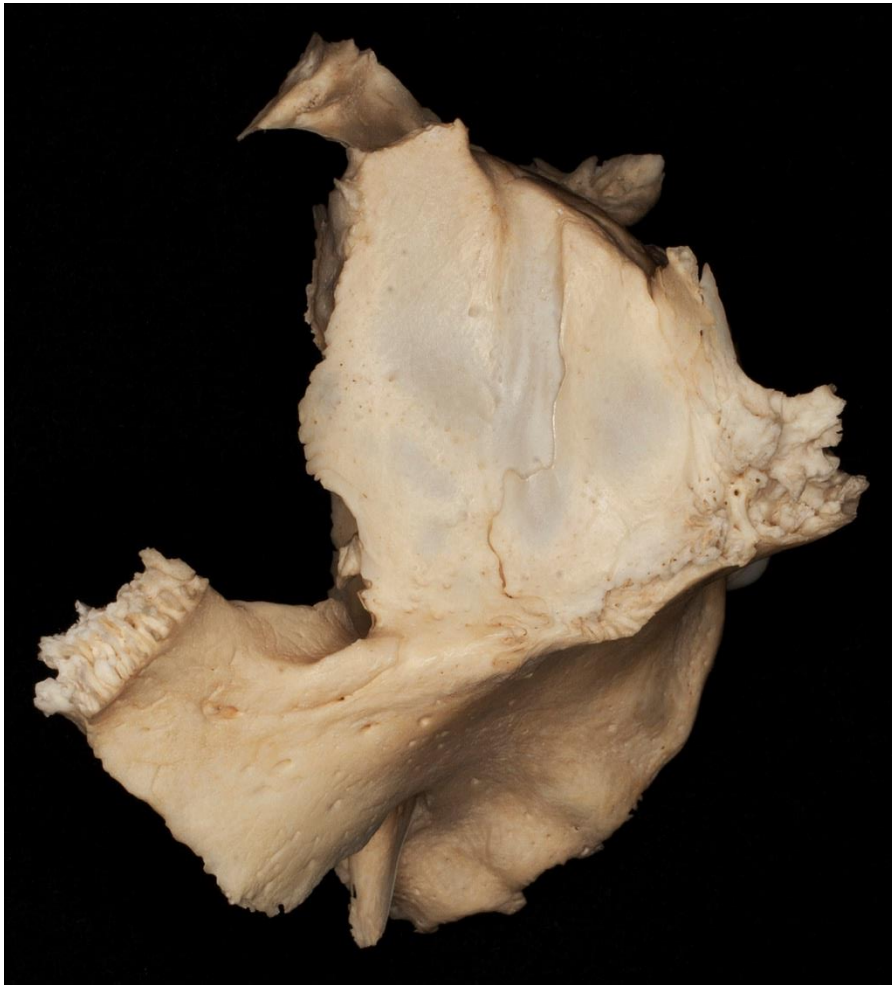

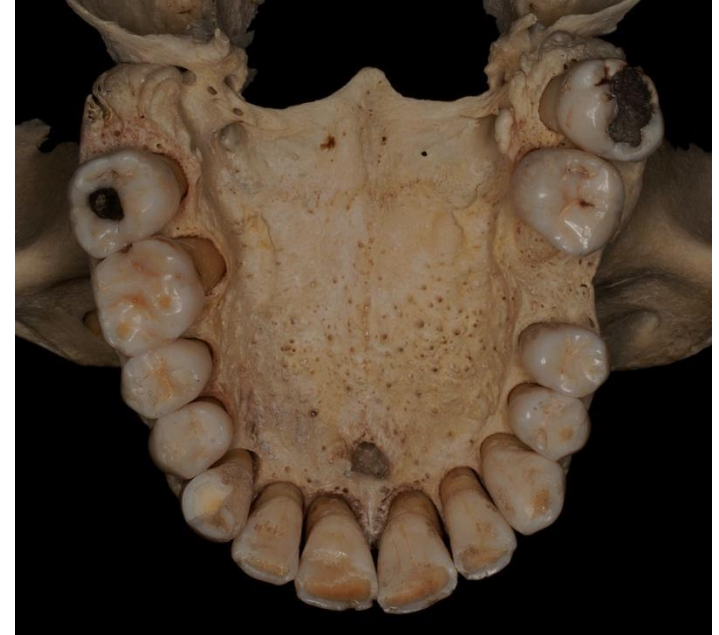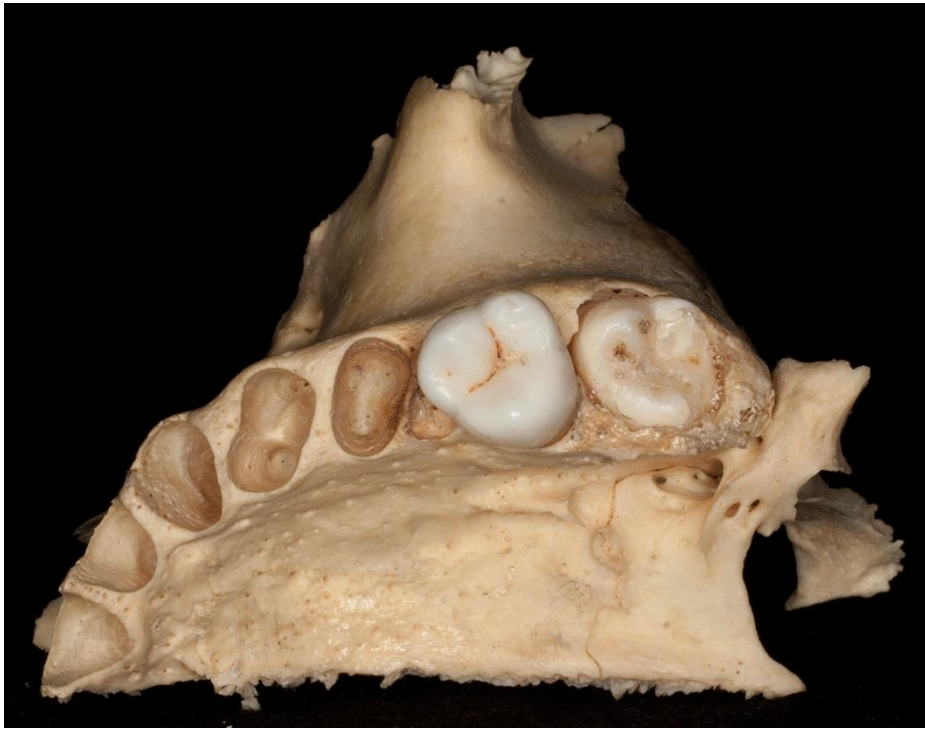
Faller

Aspectus superior

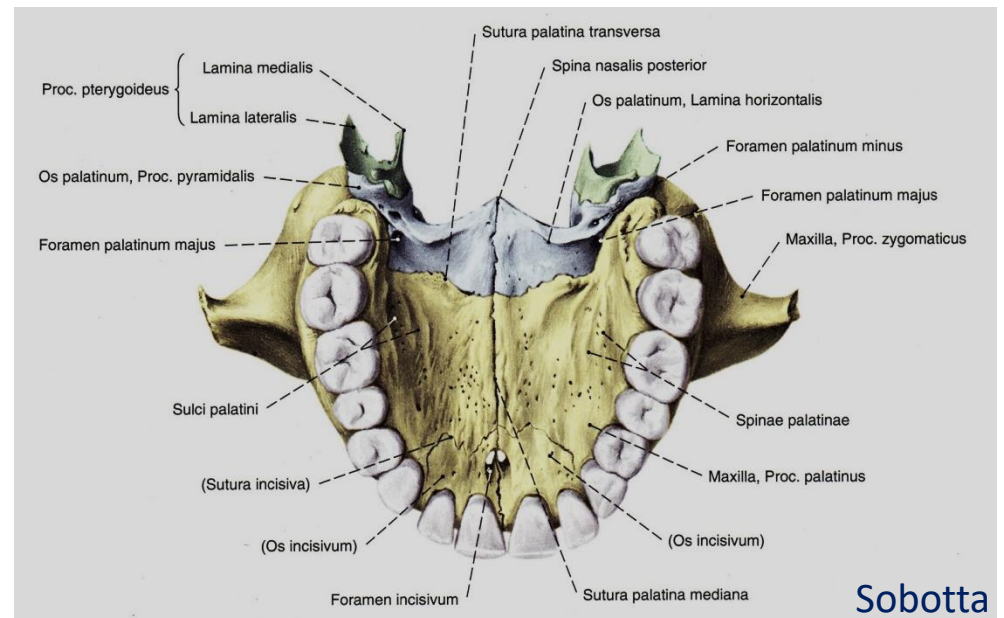


Sobotta

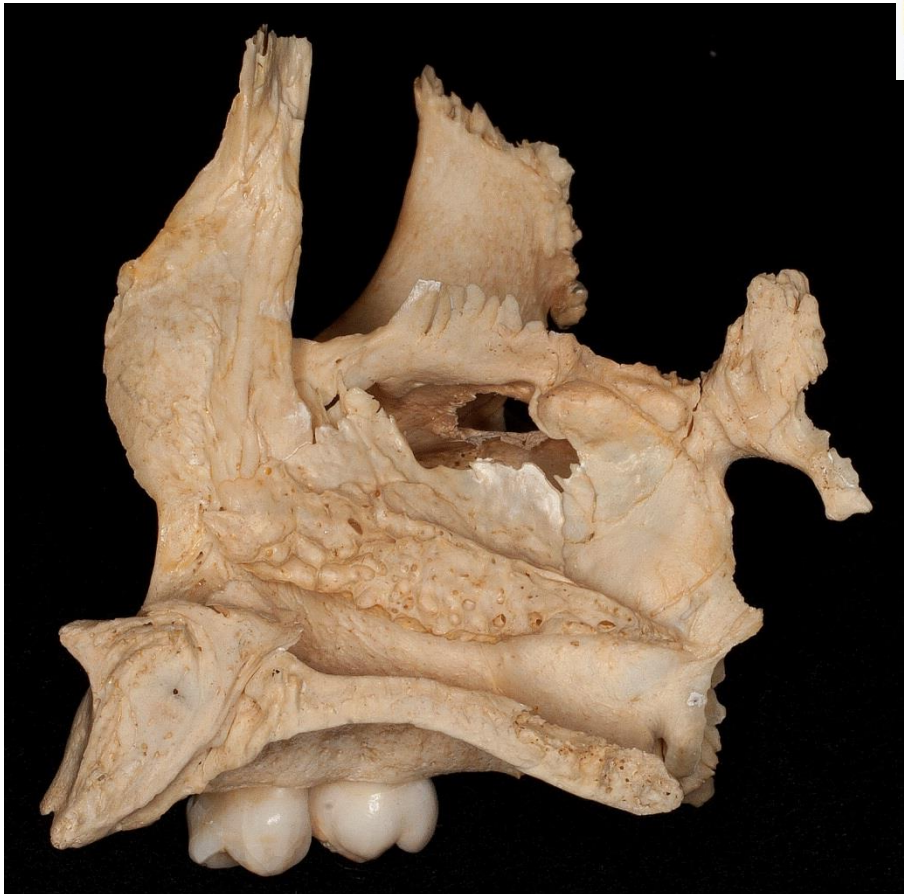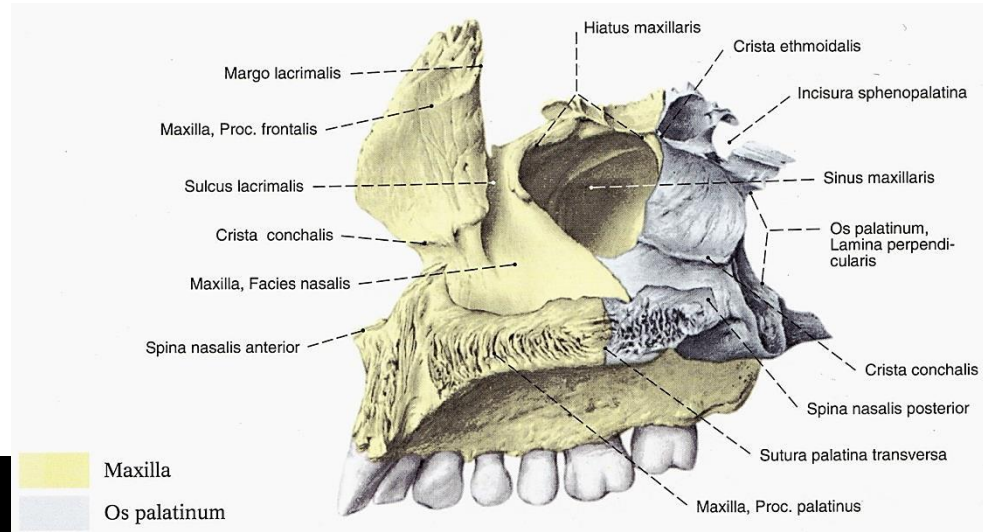




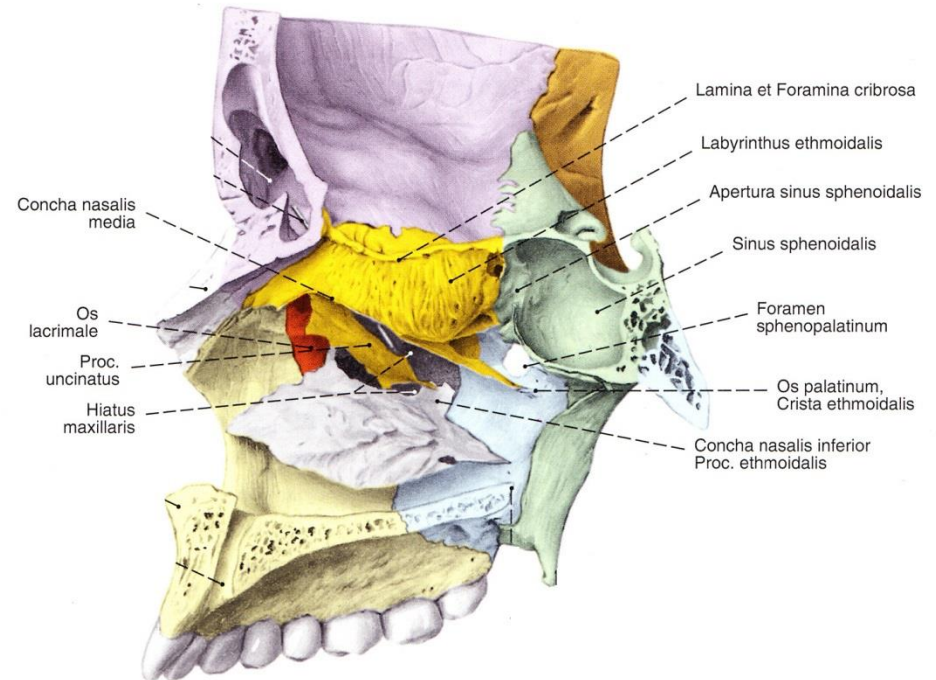
Aspectus inferior

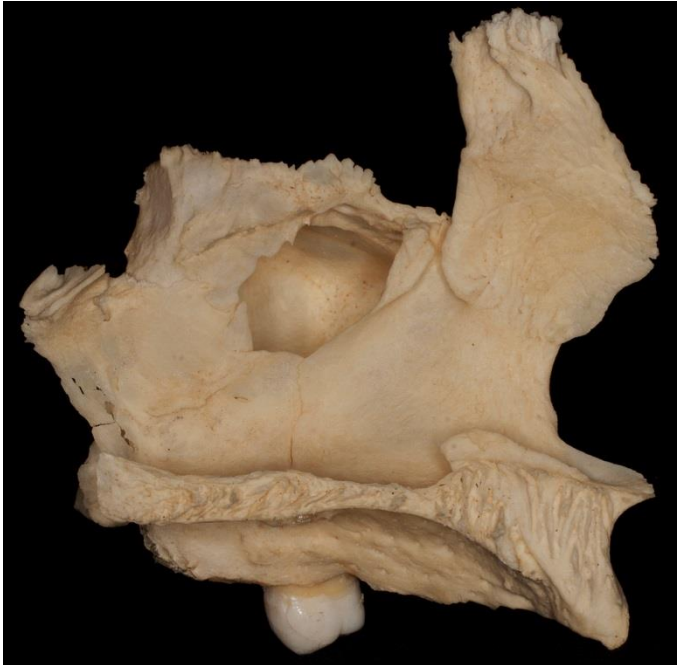
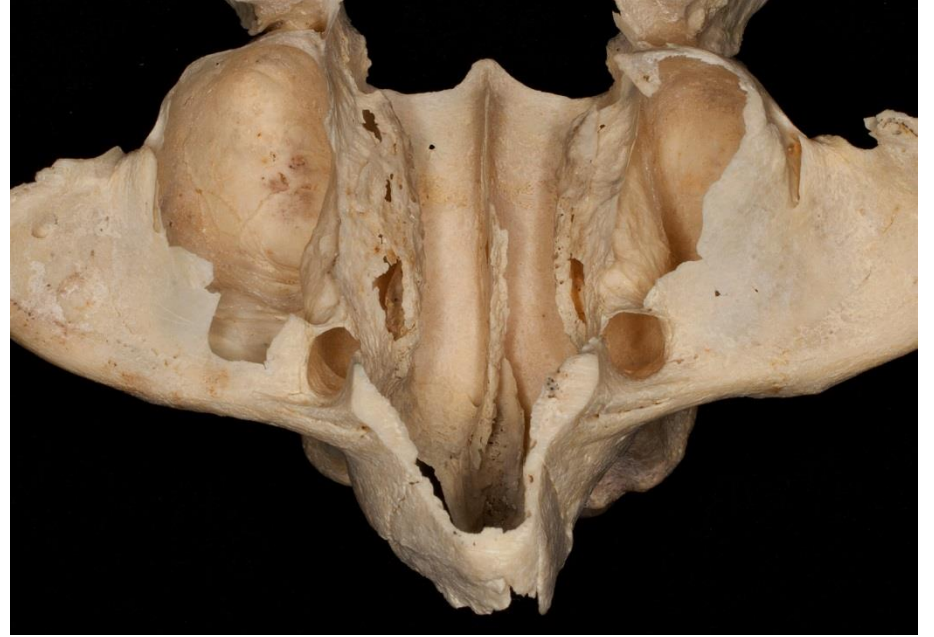
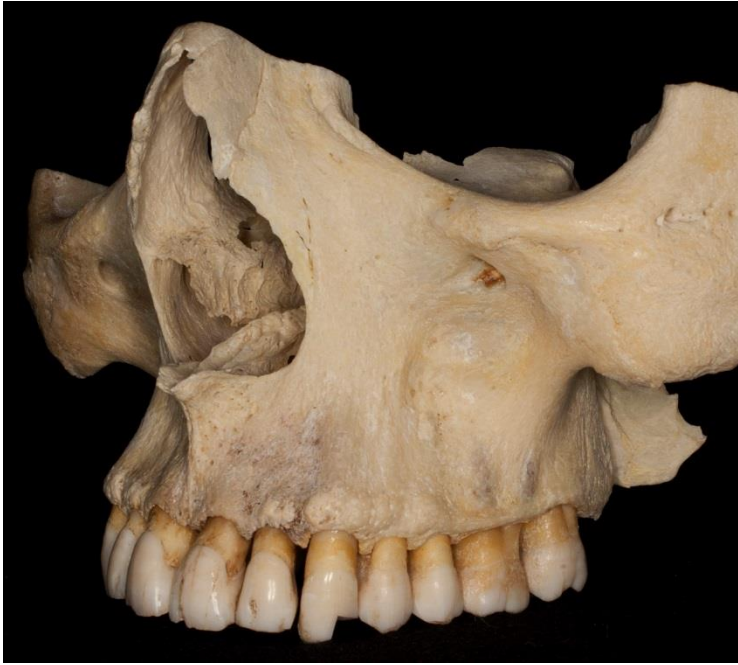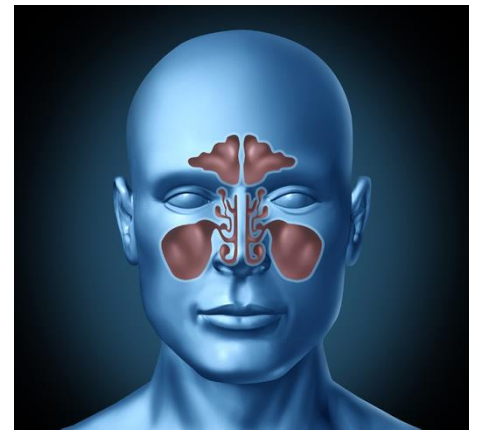
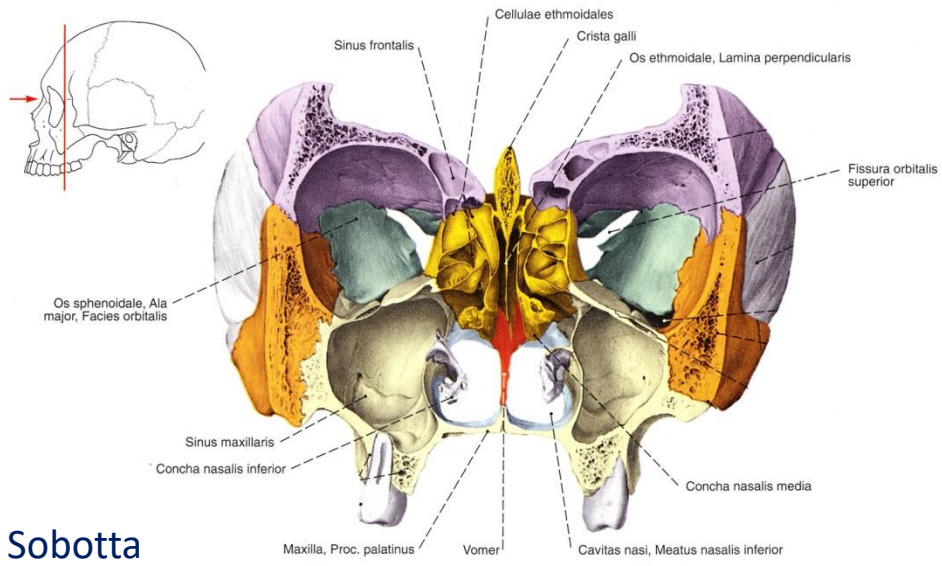
Aspectus medialis



Sobotta

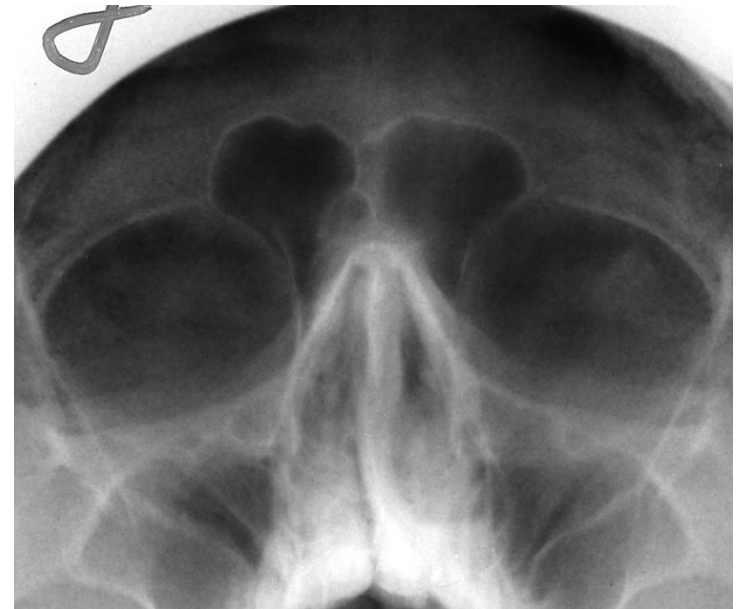
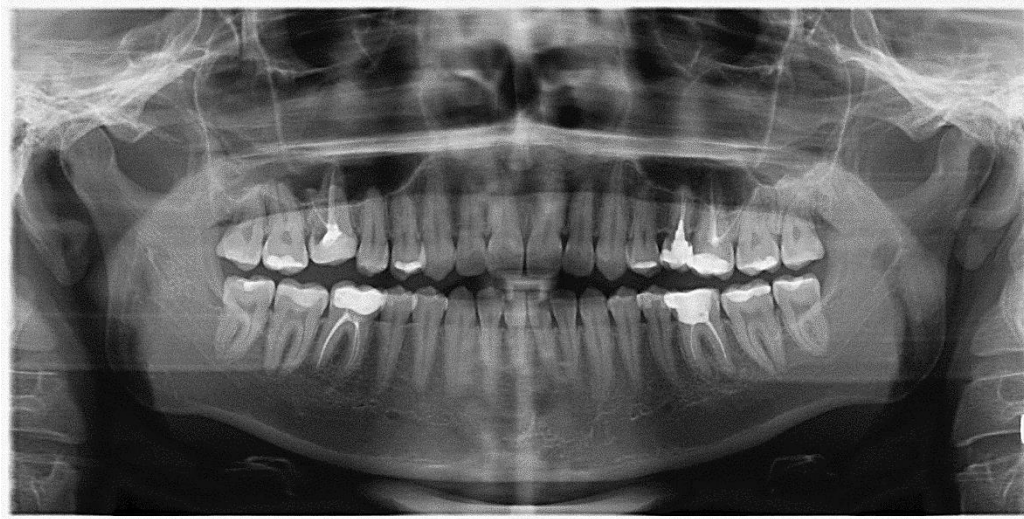




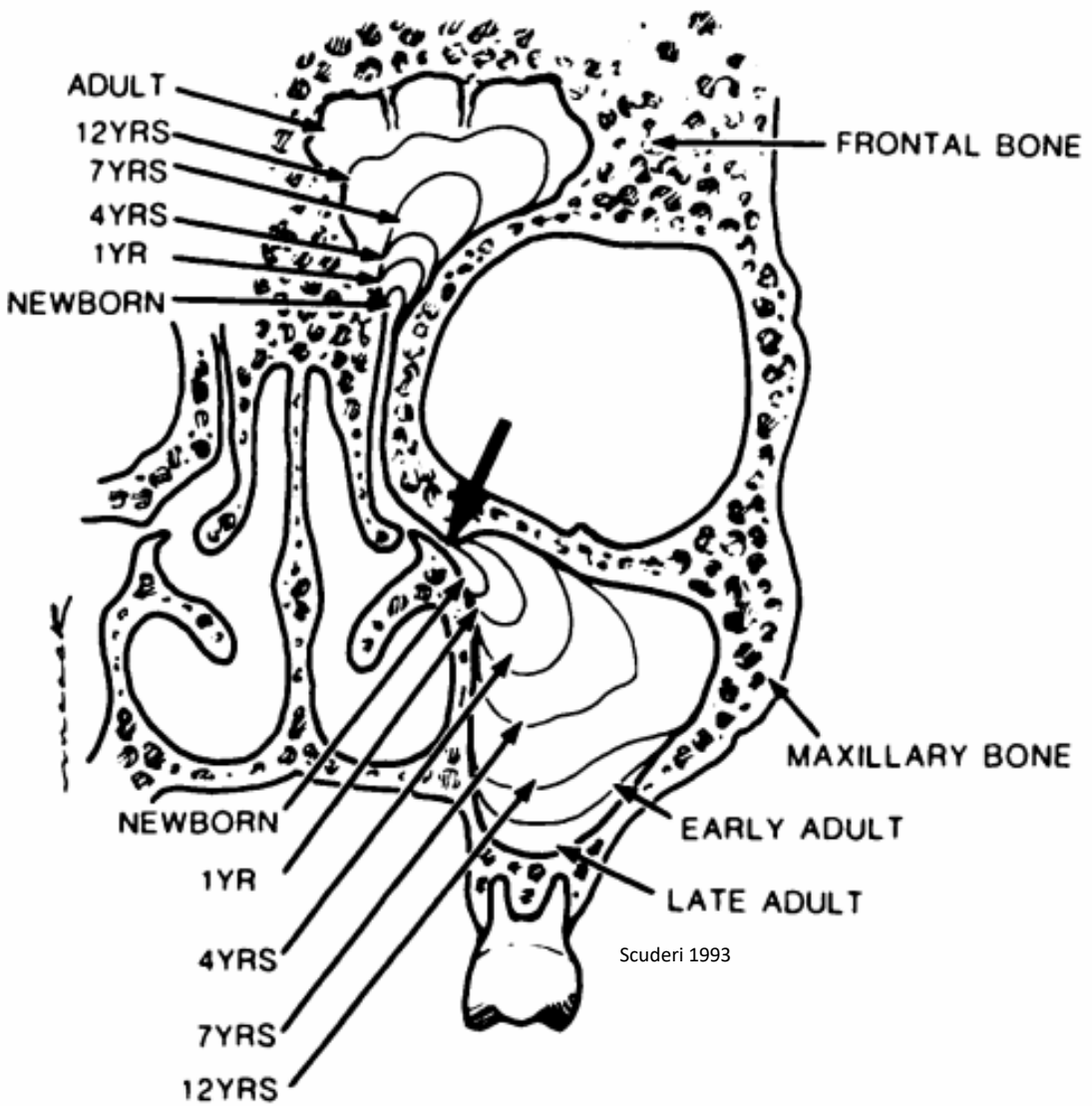
<http://www.almanahmedical.eu>

Sobotta

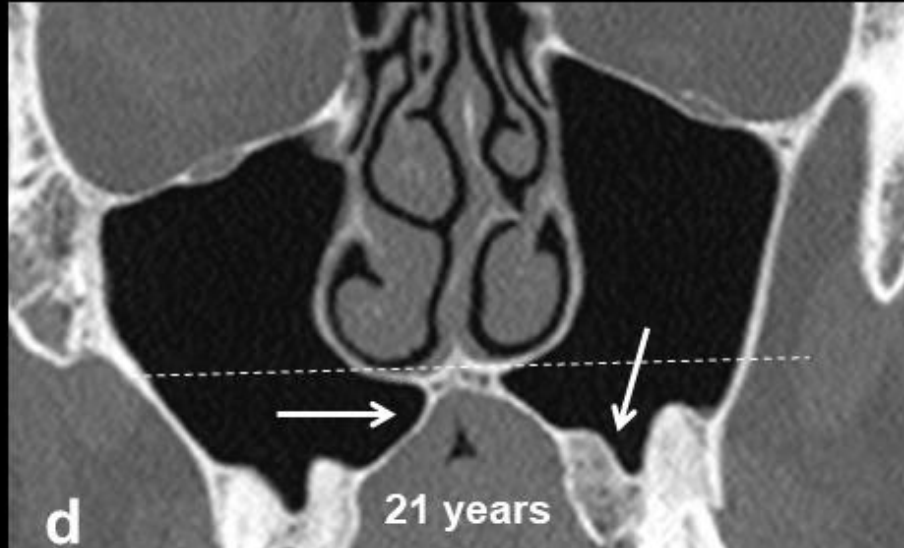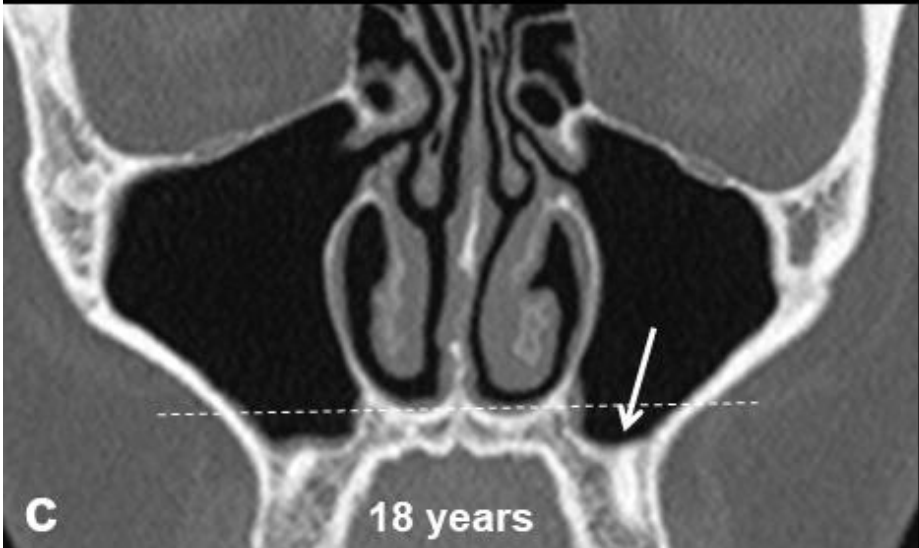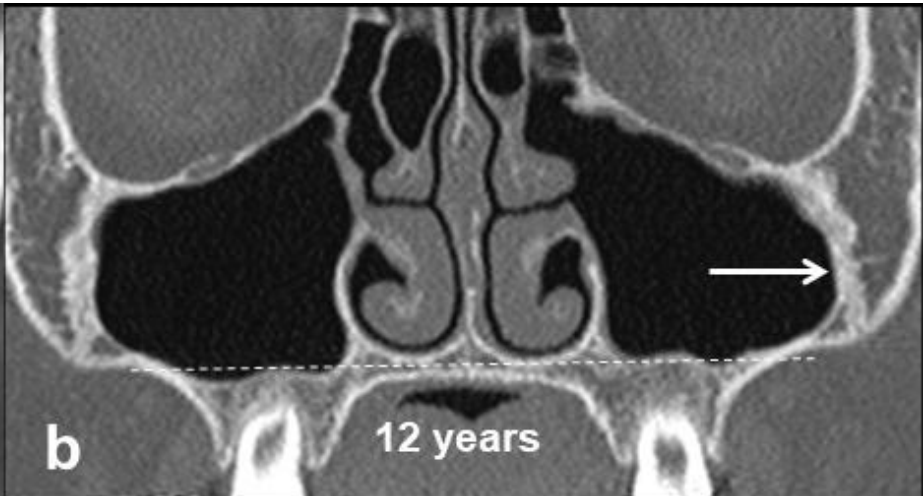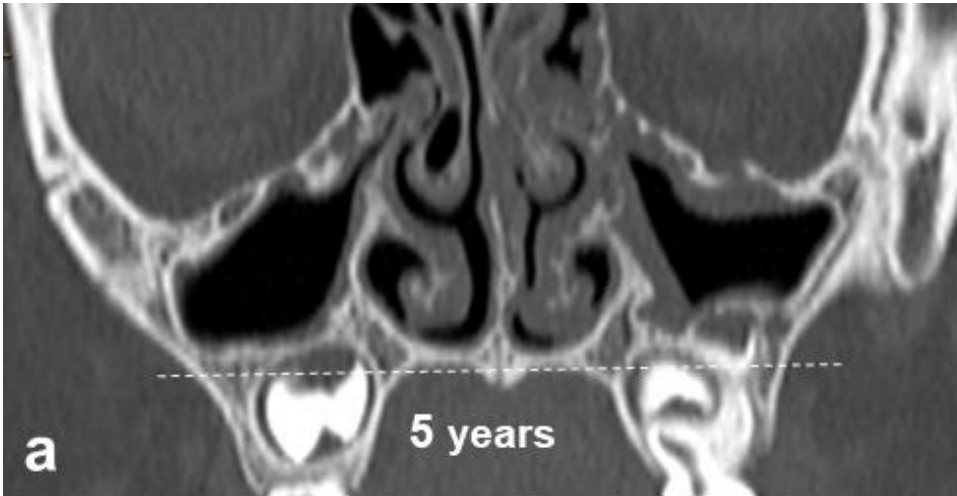


Florian Dental – Dr. S. Kováčh

Entwicklung und Pneumatization

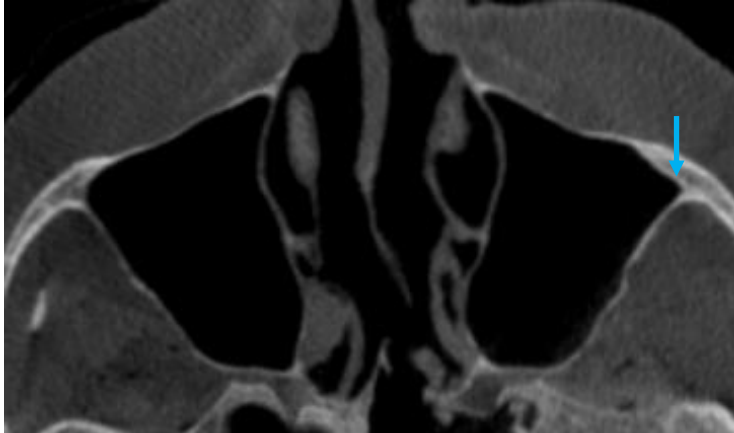

Scuderi 1993

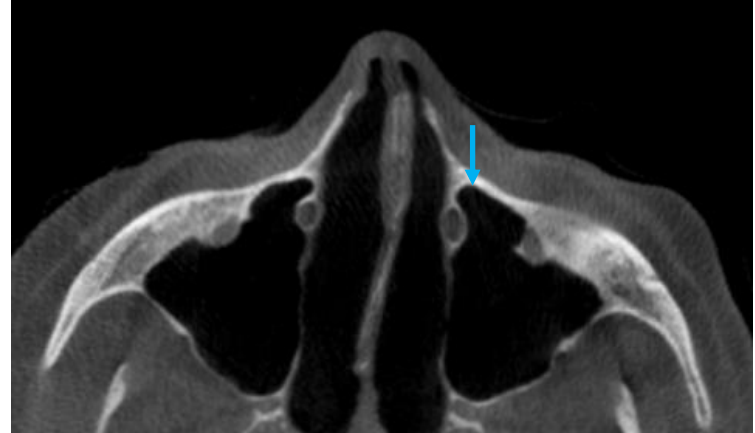


Recessi sinus maxillaris

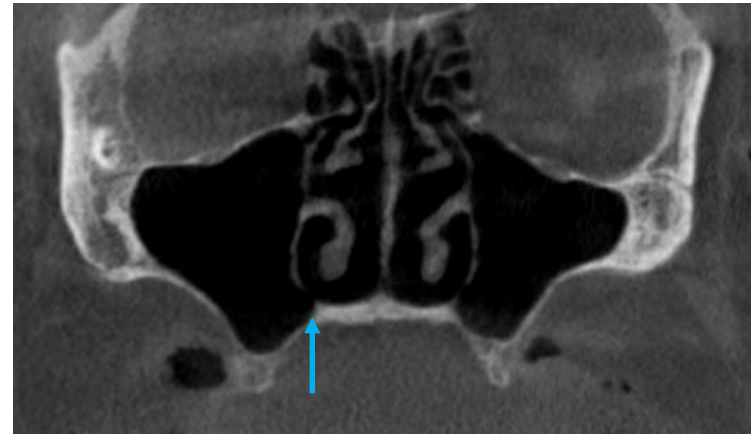
Recessus zygomaticus



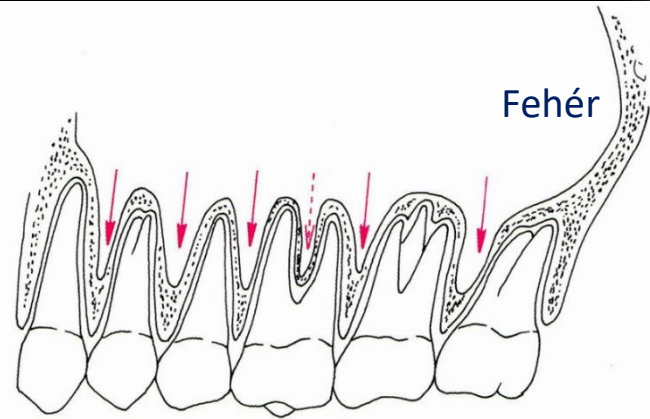
Recessus infraorbitalis (/prelacrimalis)



Recessus palatinus

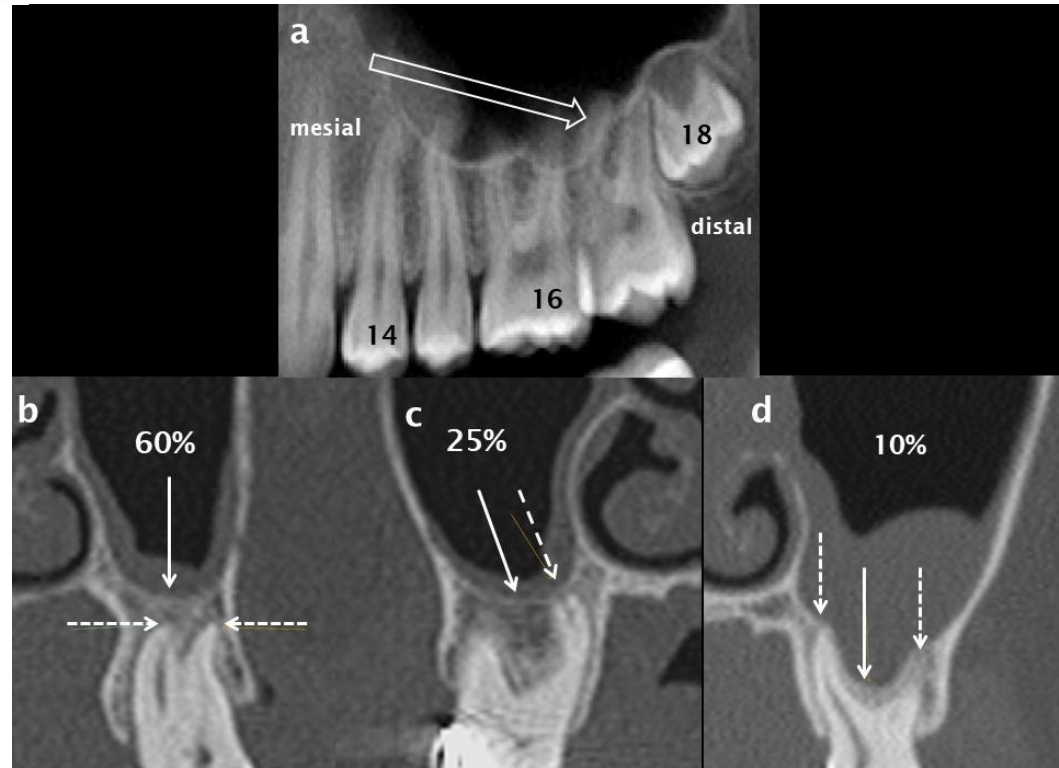


Az orrmelléküregyek beidegzése

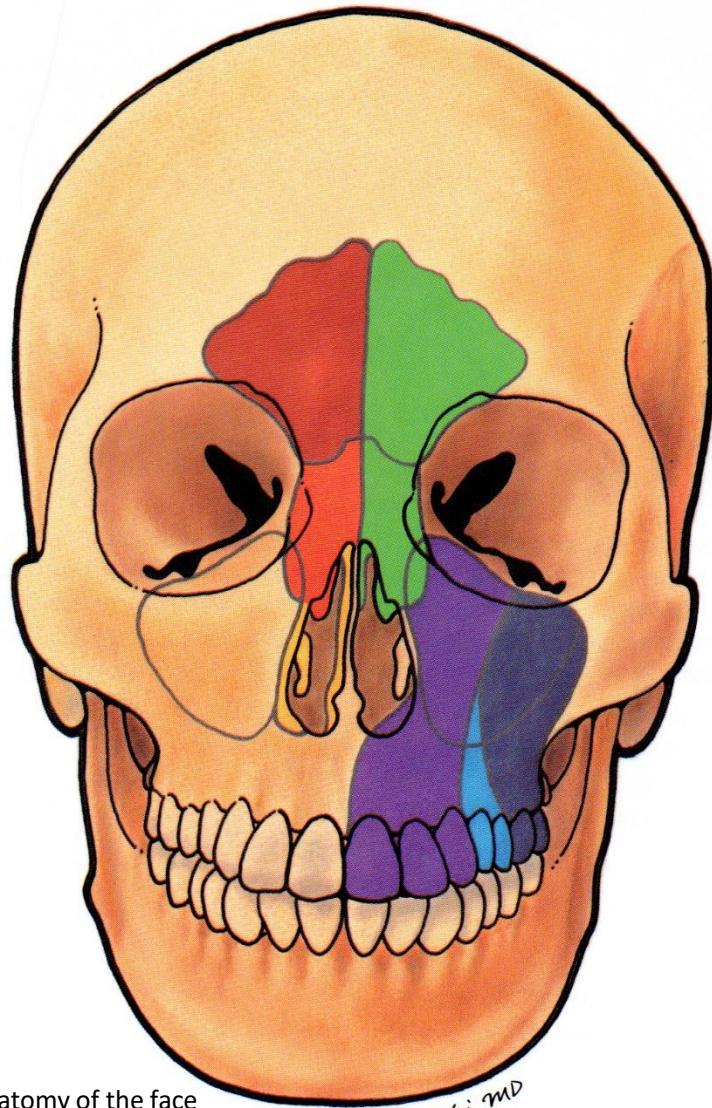


Recessus alveolaris

Sinus interdentalis
Sinus interradicularis



Innervation der Nasennebenhöhlen



Surgical anatomy of the face

Makielski MD

N. supraorbitalis

N. supraorbitalis és N. nasopalatinus

N. sphenopalatinus

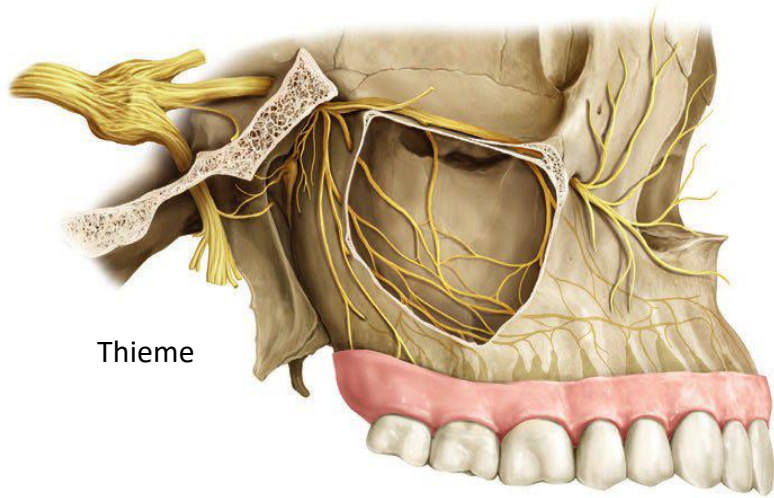
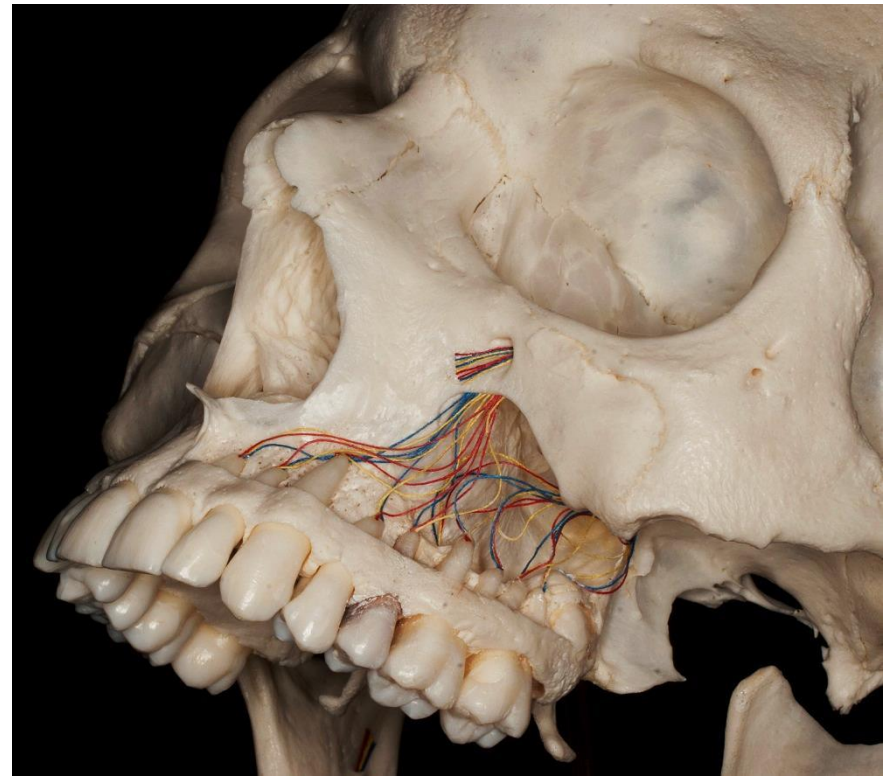
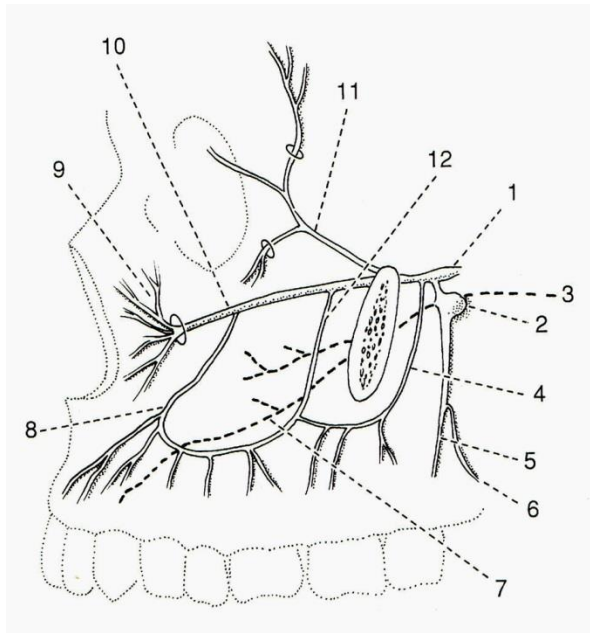
N. ethmoidalis anterior

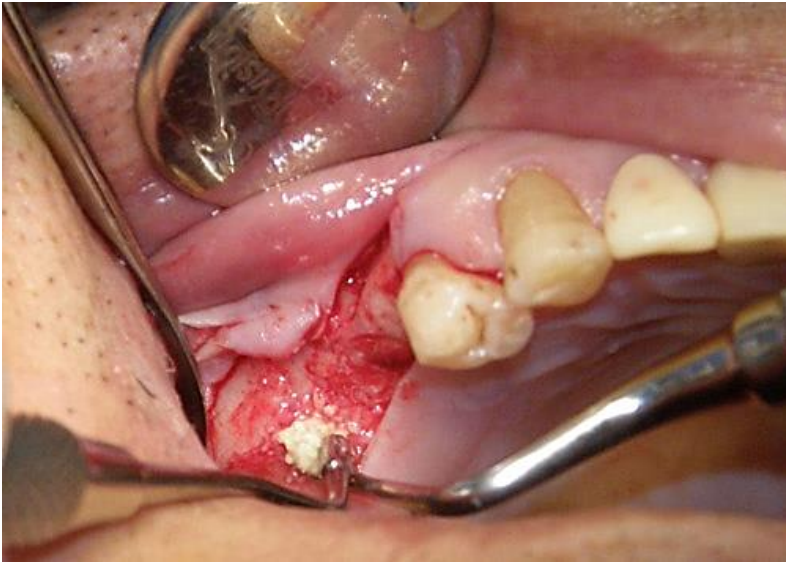N. alveolaris ant. sup.

N. alveolaris ant. med.

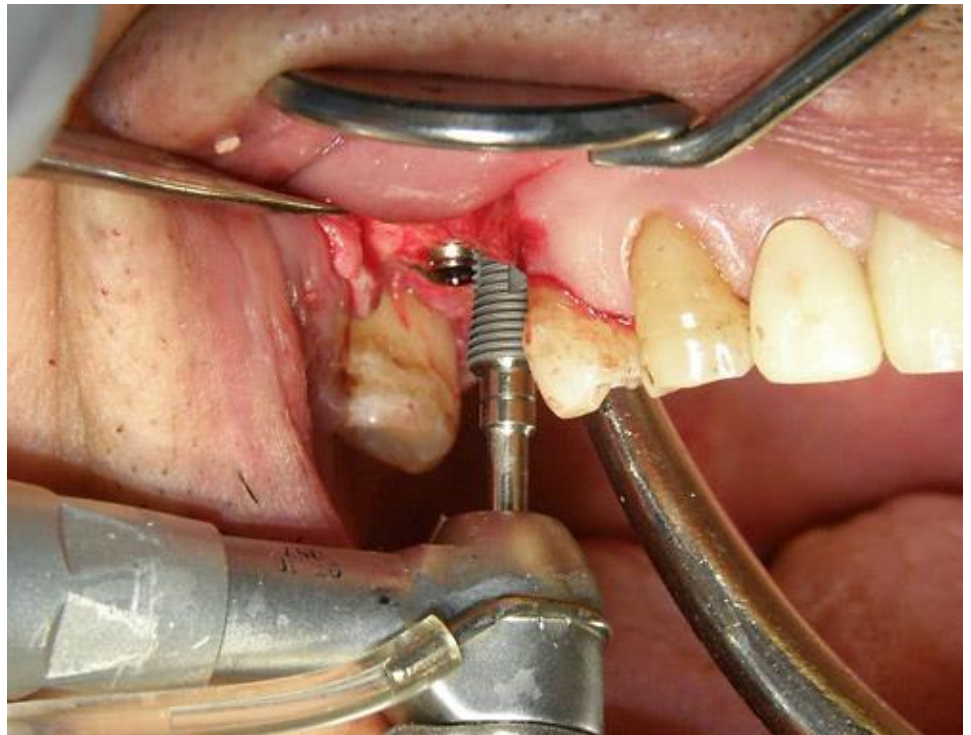
N. alveolaris ant. post

Fehér

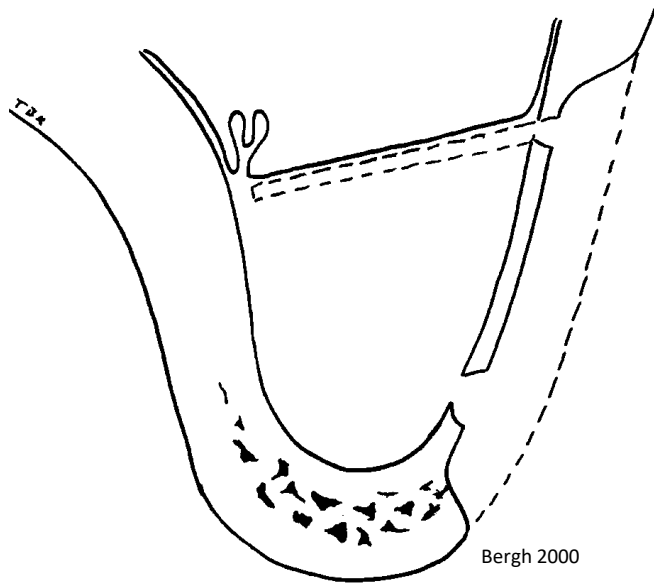




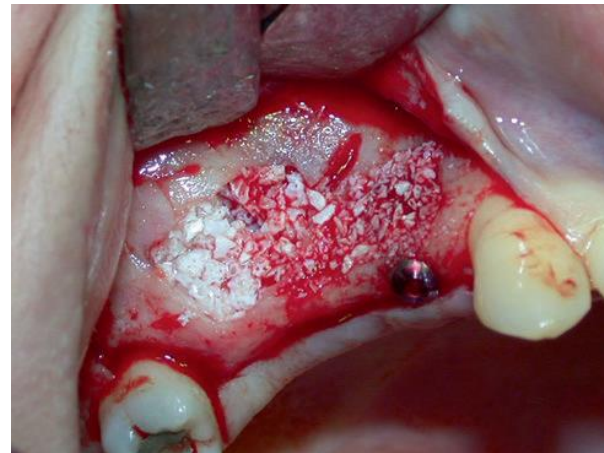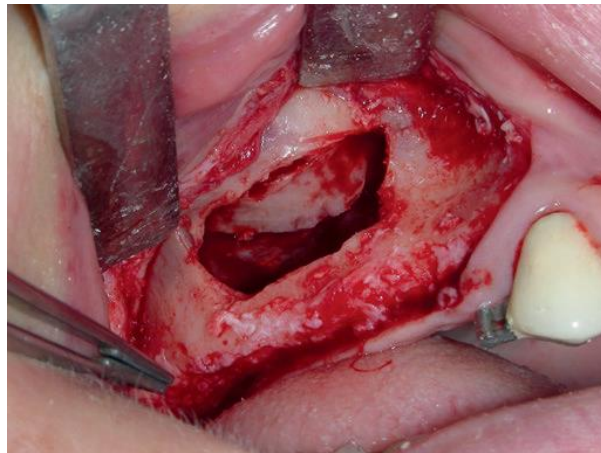
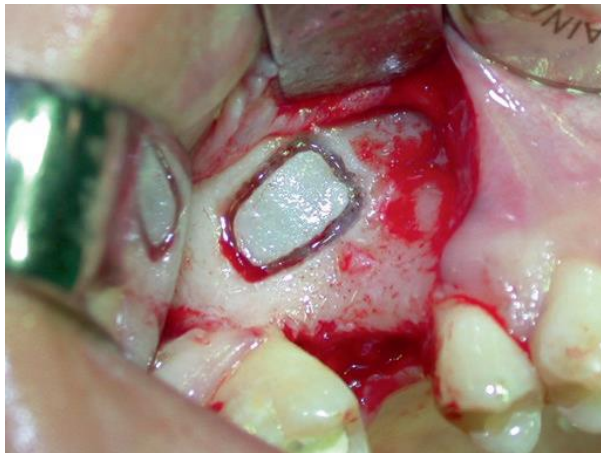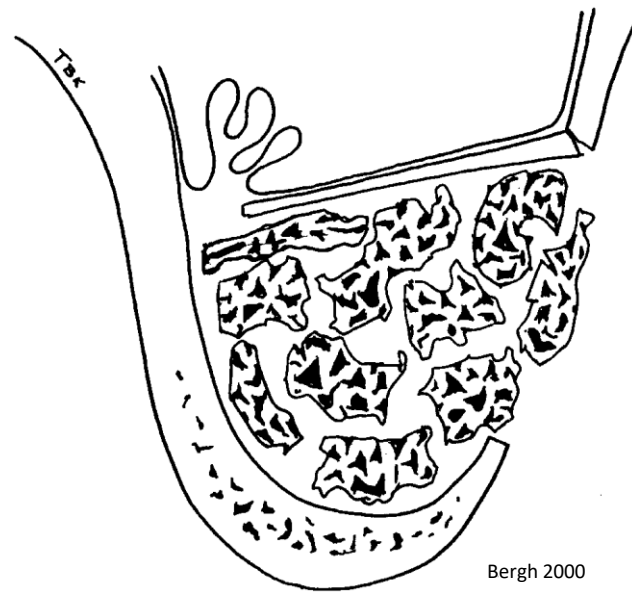
<http://www.hc-bios.com>



Schneidersche Membran

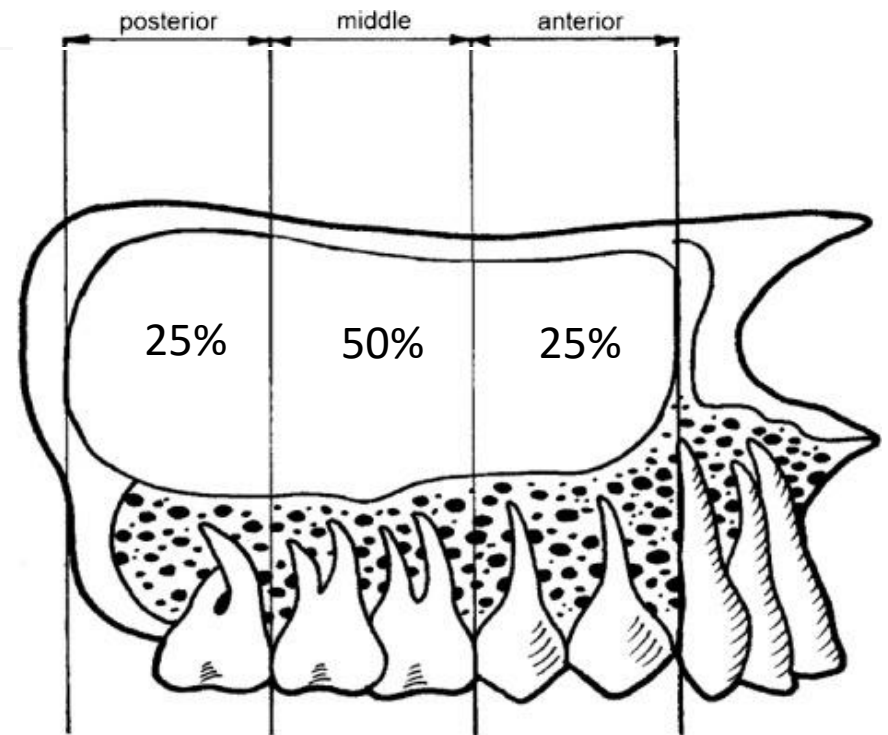
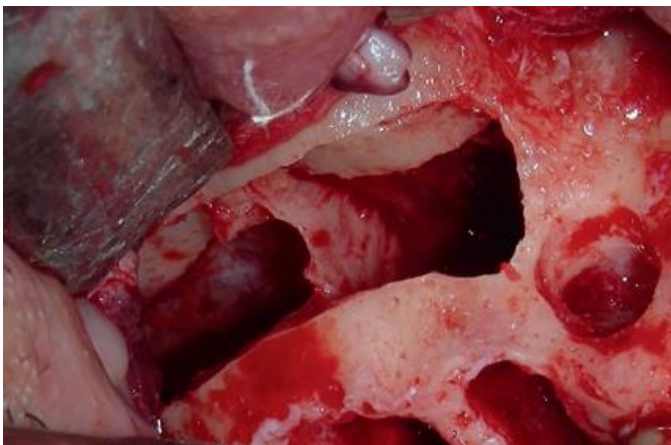
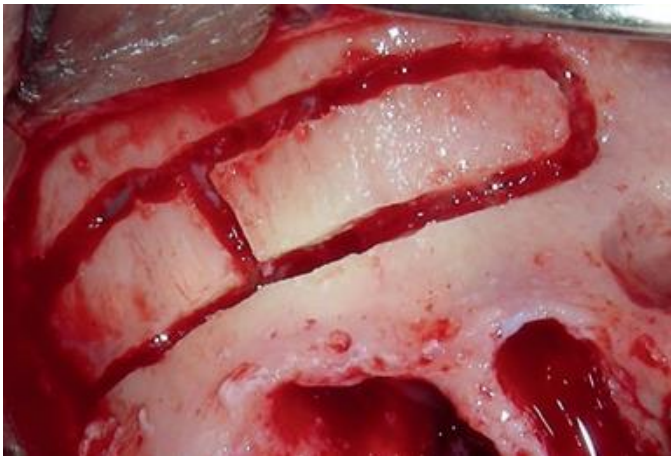

Sinus lifting

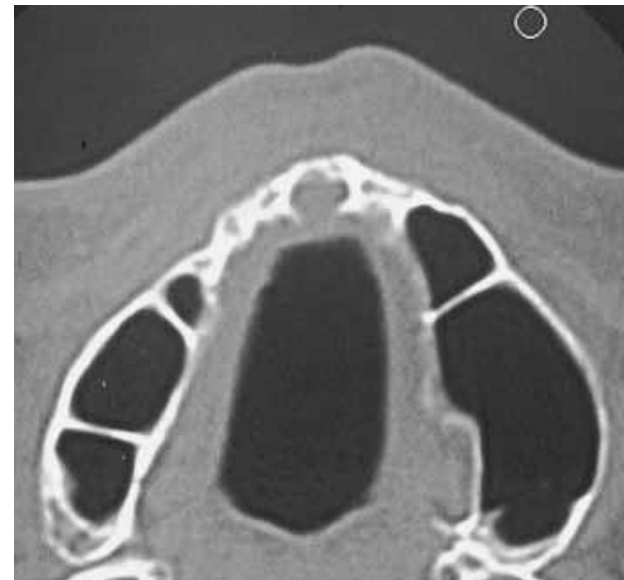

Septum sinus maxillaris

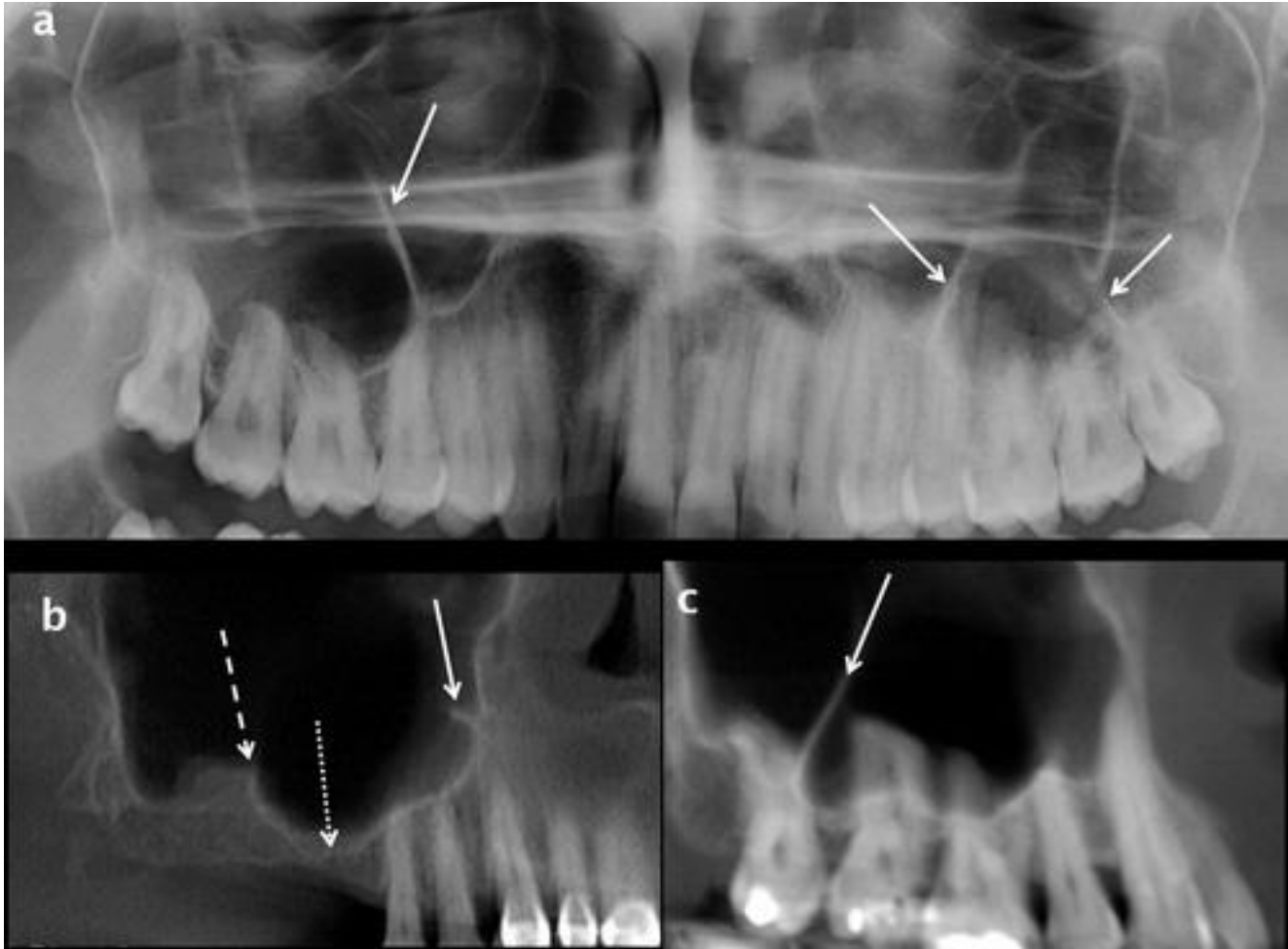- 25-33%
- unilateral
- 99% inkomplet



Hungerbühler 2019



Bergh 2000

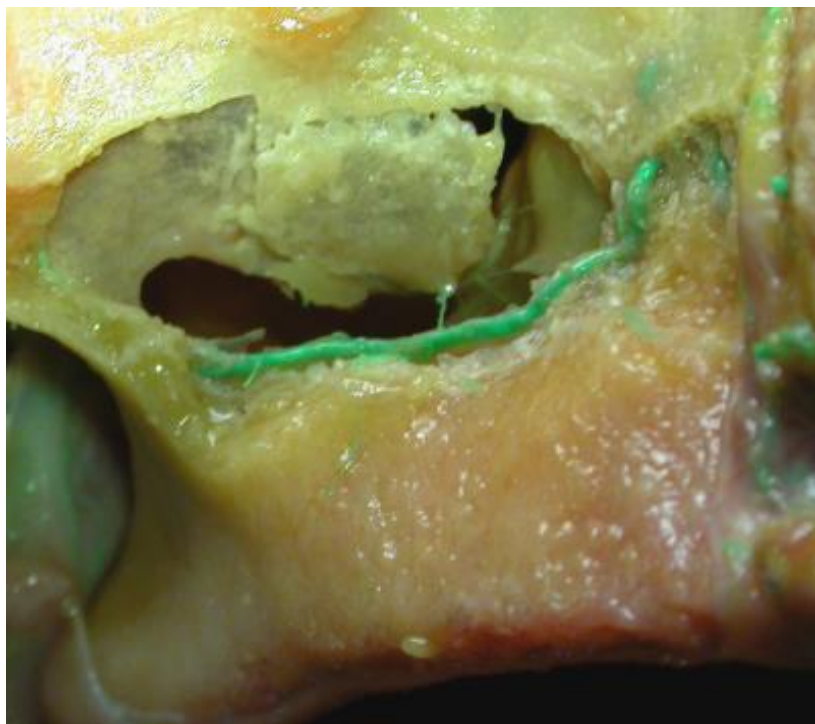


Blutversorgung:

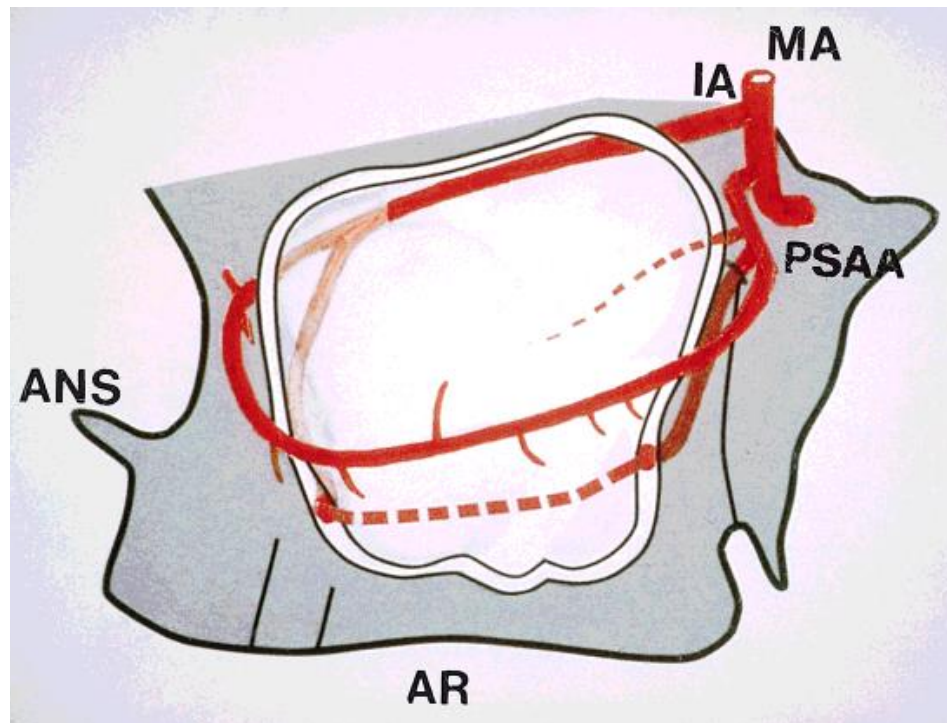
- a. alveolaris superior posterior
- a. infraorbitalis

Es gibt 2 Anastomosen: intraosseal und extraosseal

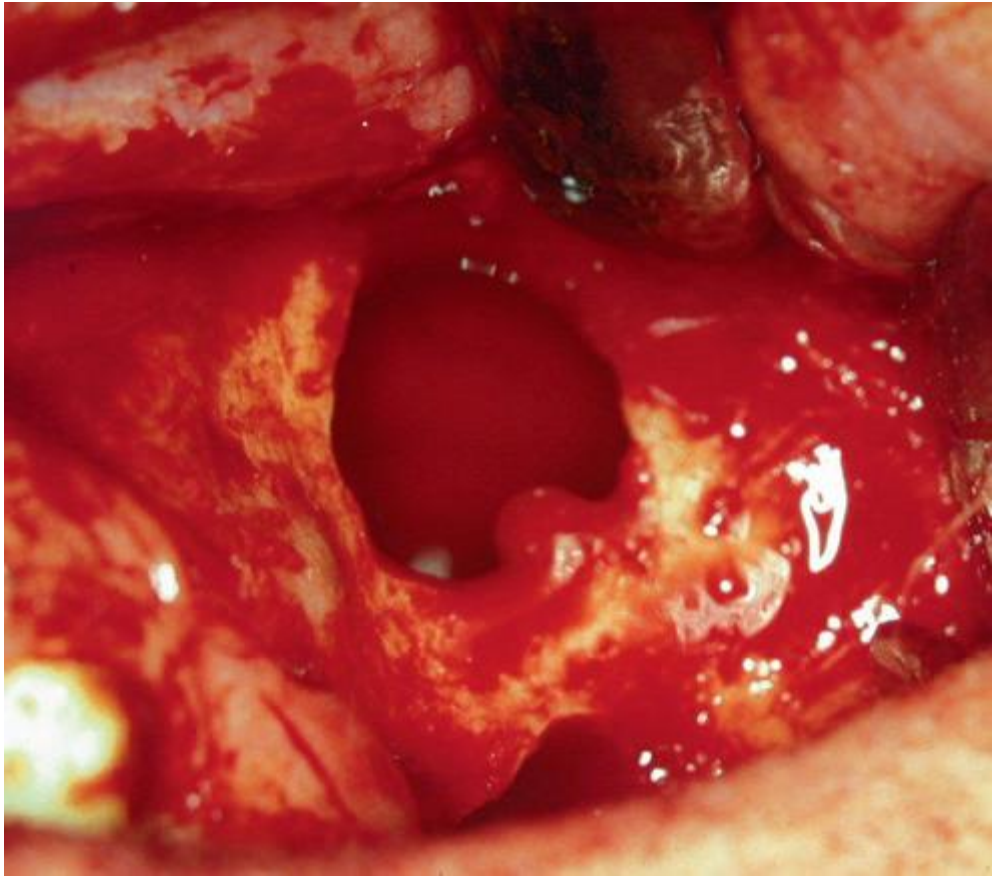
Der durchschnittliche Distanz: 19 mm.



Rosano 2011



Traxler 2009



Literatur und Danksagung

Faller: Anatomie in Stichworten – Ein Arbeitsbuch für Medizinstudente und praktische Ärzte (Ferdinand Enke Verlag 1980.)

Fehér: Maxillofaciális anatómia (Medicina Kiadó 2001.)

Pernkopf: Topographische Anatomie des Menschen. Lehrbuch und Atlas der regionär-stratigraphischen Präparation. (Urban & Schwarzenberg 1952.)

Sobotta: Az ember anatómiájának atlasza (Semmelweis Kiadó 1994.)

Szél: Klinikai anatómia (SOTE Képzéskutató 1999.)

Szentágothai – Réthelyi: Funkcionális anatómia (Medicina Kiadó - Semmelweis Kiadó 1996.)

www.almanahmedical.eu

www.hc-bios.com

www.mng.hu

Knochenpräparate in der Vorlesung: Dr. Lajos Patonay

Panoramaaufnahmen: Florian Dental – Dr. Sándor Kovách