Connective tissue

Monet vs. Movat's stain,

Klimt versus cartilage

Dr. Zita Puskár

EDI M 10/02/2020

https://publicinsta.com/hashtag/pentachrome

https://twitter.com/iamsciart/status/1029850219427586049

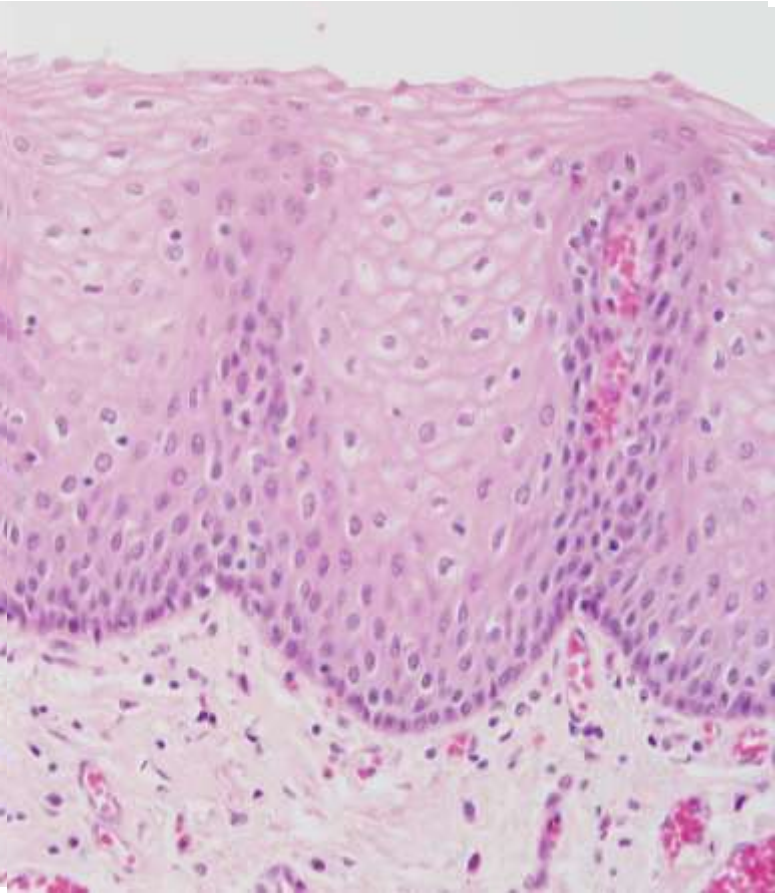

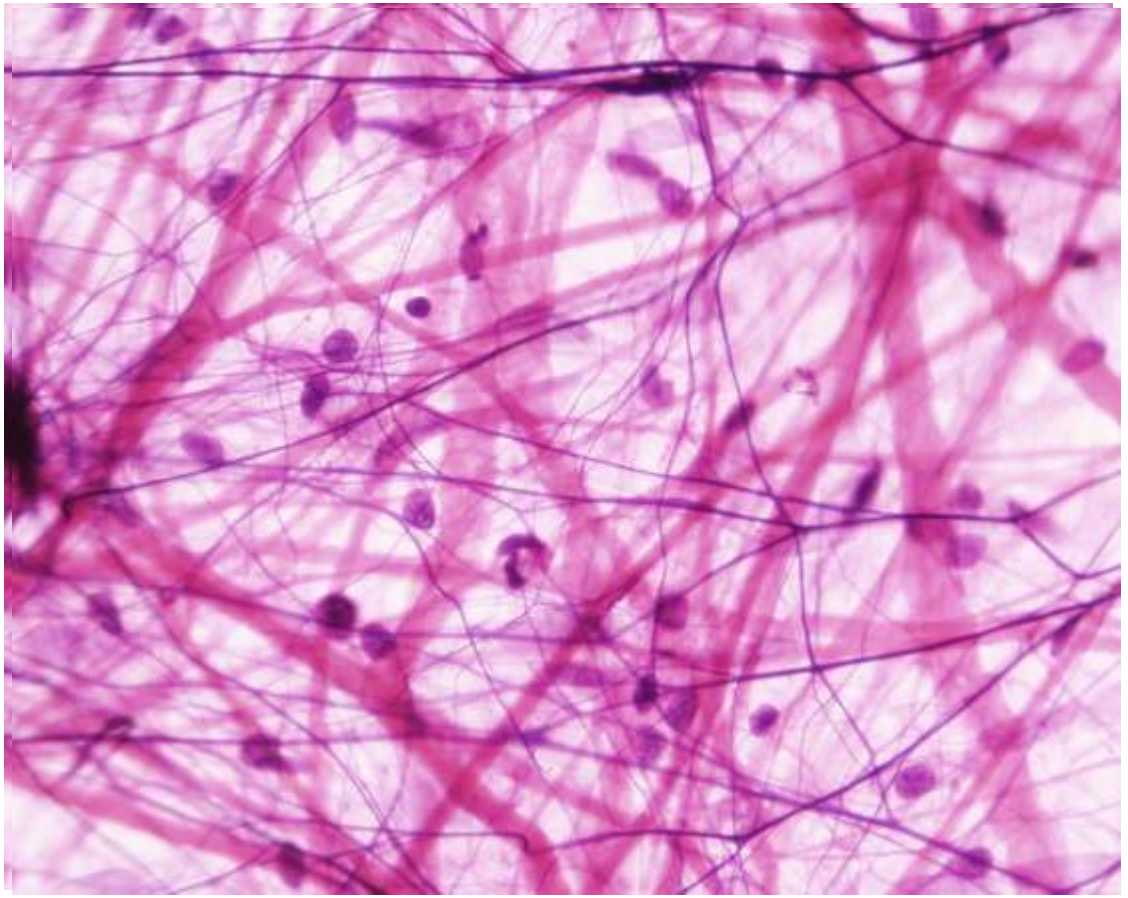

!

Composition of connective tissue

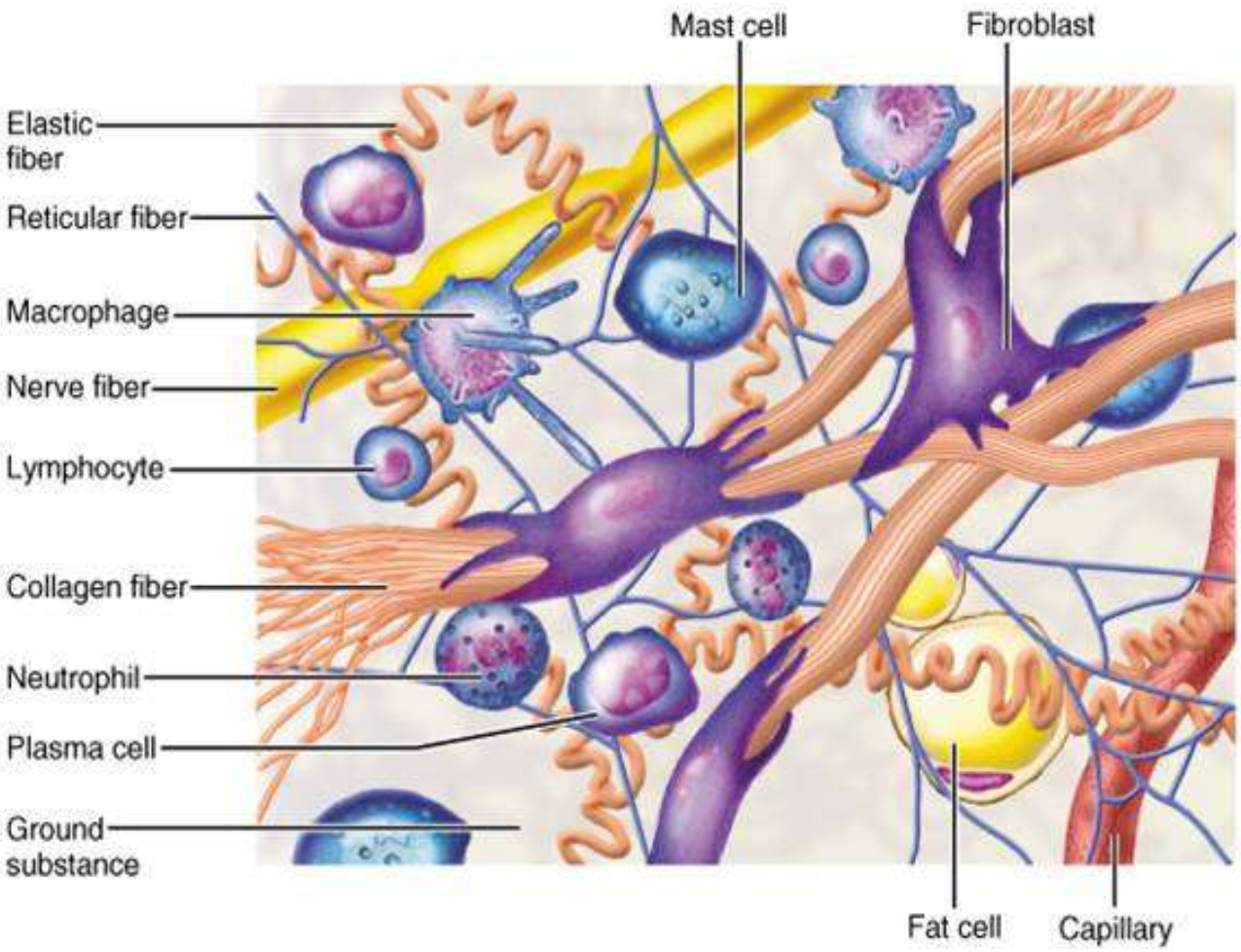

- **Cells**

- **Extracellular matrix (ECM)**

- **Fibers**
- **Macromolecular complexes**
- **Tissue fluid**

Connective tissue fibers

!

collagen

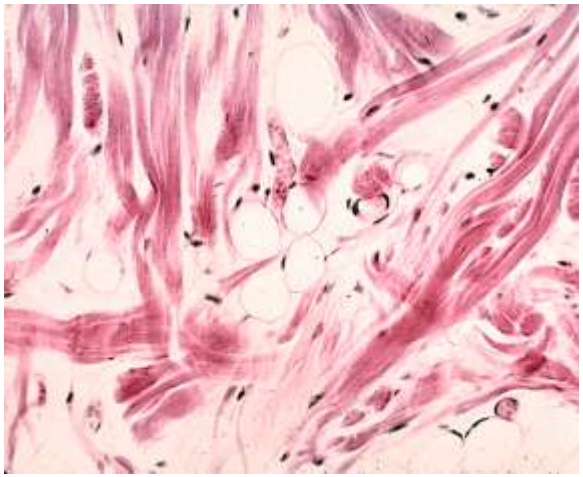

elastic

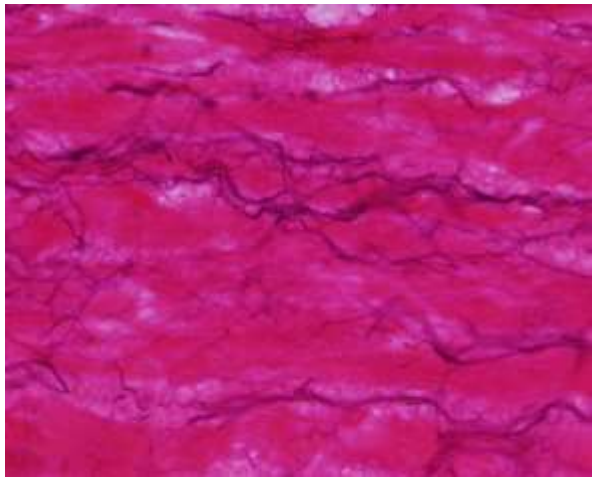

reticular

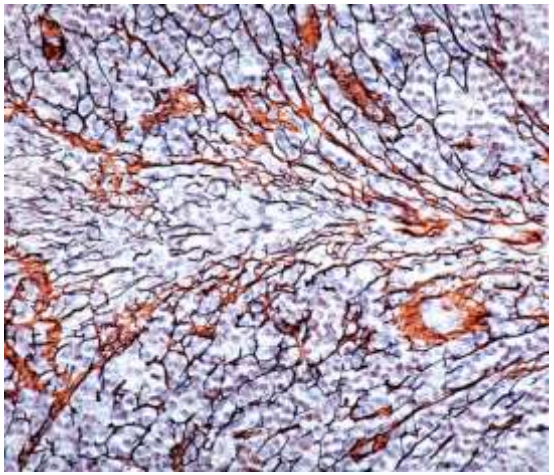

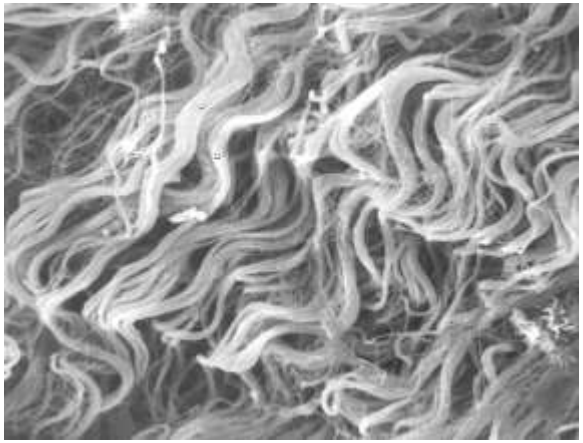

bundles

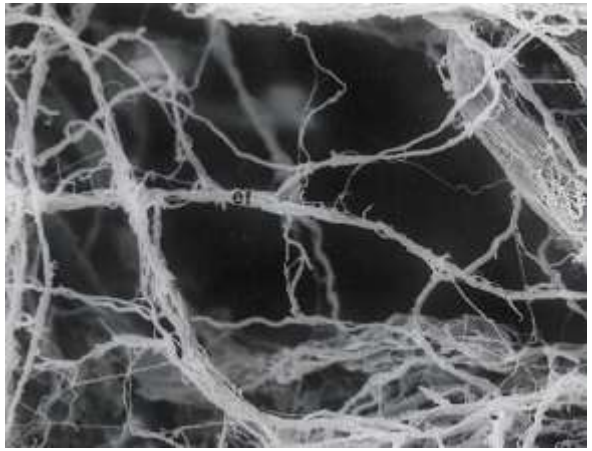

networks

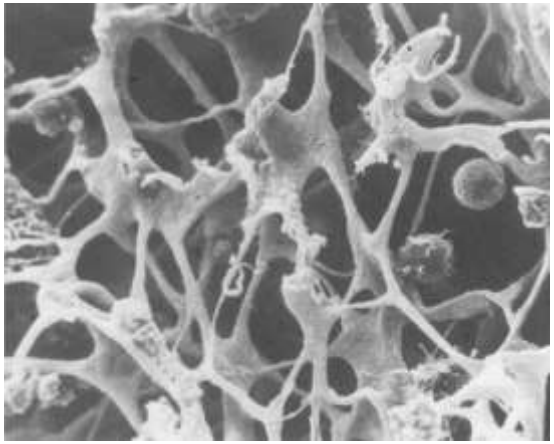

anastomosing bundles

fibrillin → microfilaments

Composition of collagen fibers

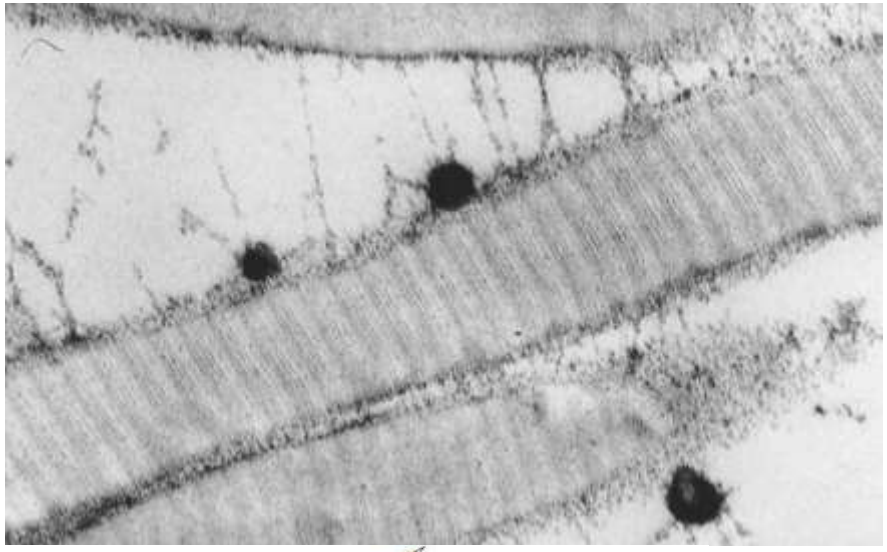

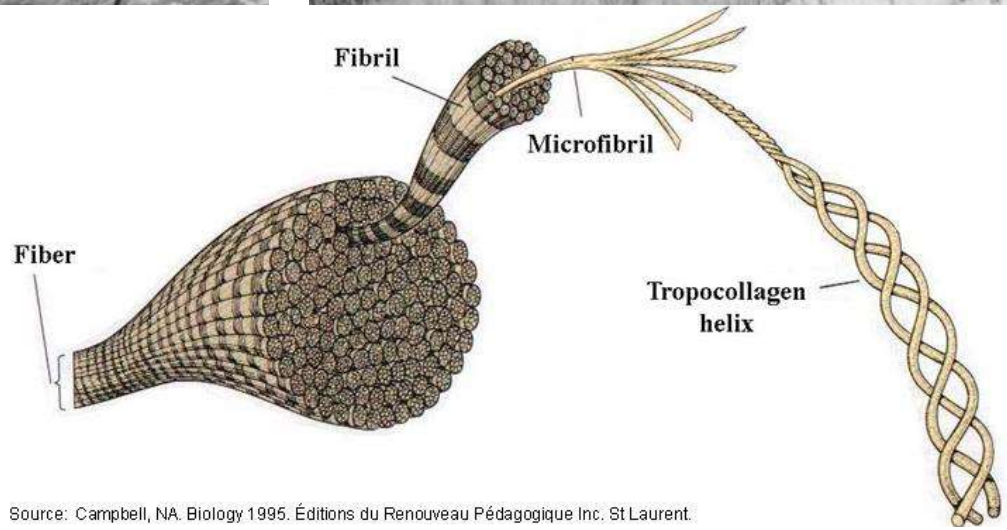

Source: Campbell, NA. Biology 1995. Éditions du Renouveau Pédagogique Inc. St Laurent.

„The word collagen comes from the ancient Greek word κόλλα (kolla), which means to “glue”.It consists of collagen fibrils – type I (tropo)collagen (The most abundant collagen type). Arranged in bundles. Resistance to tension. Examples: Skin, tendon, ligaments, bone .

Tropocollagen

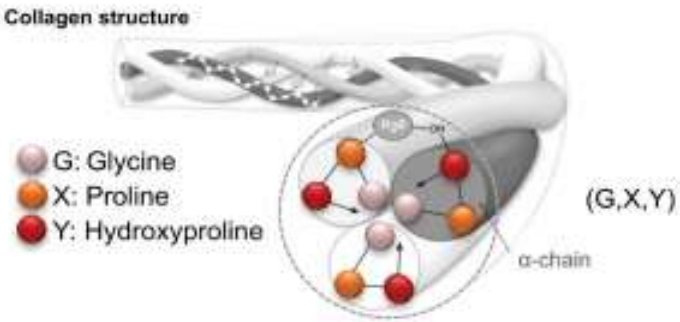

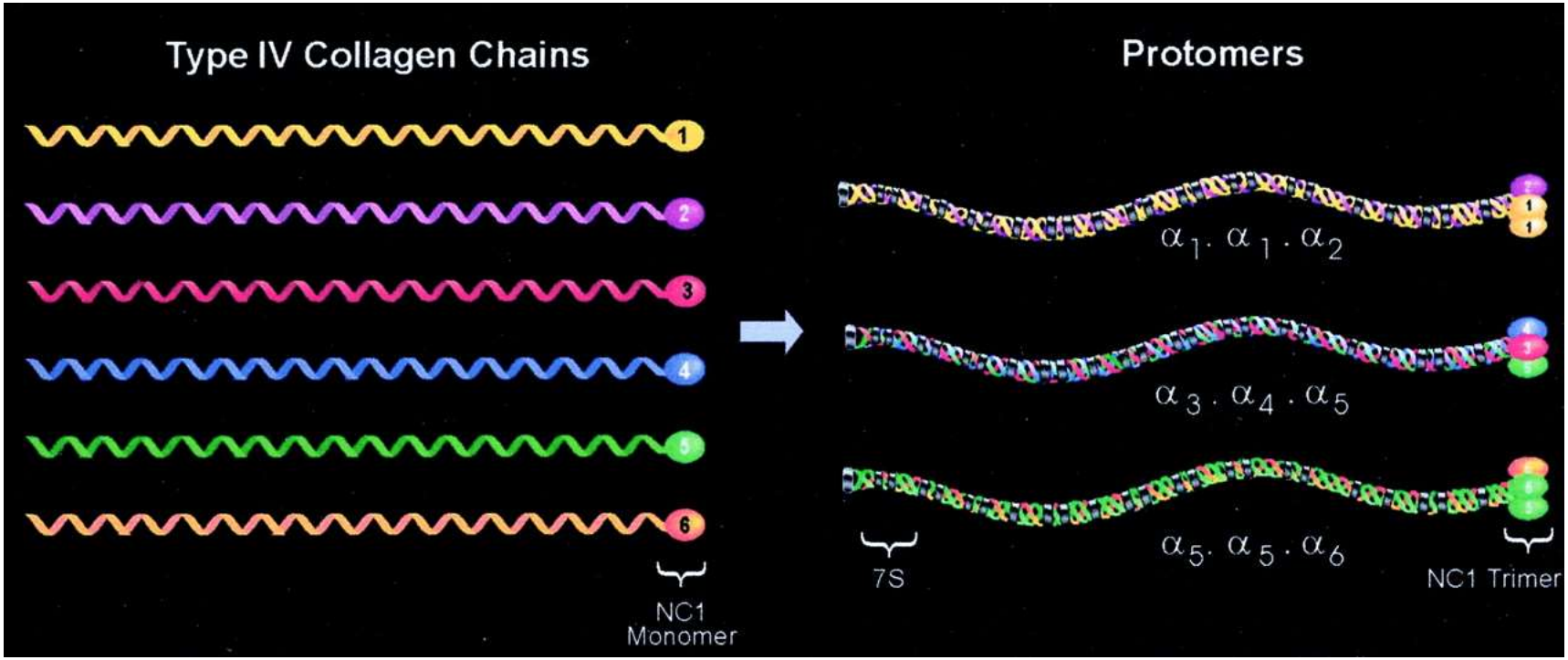

Composition of collagen fibers

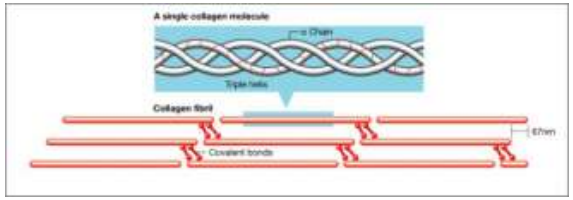

procollagen

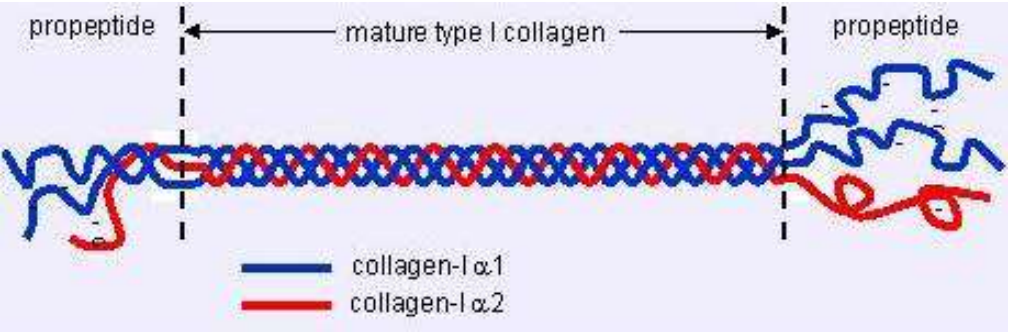

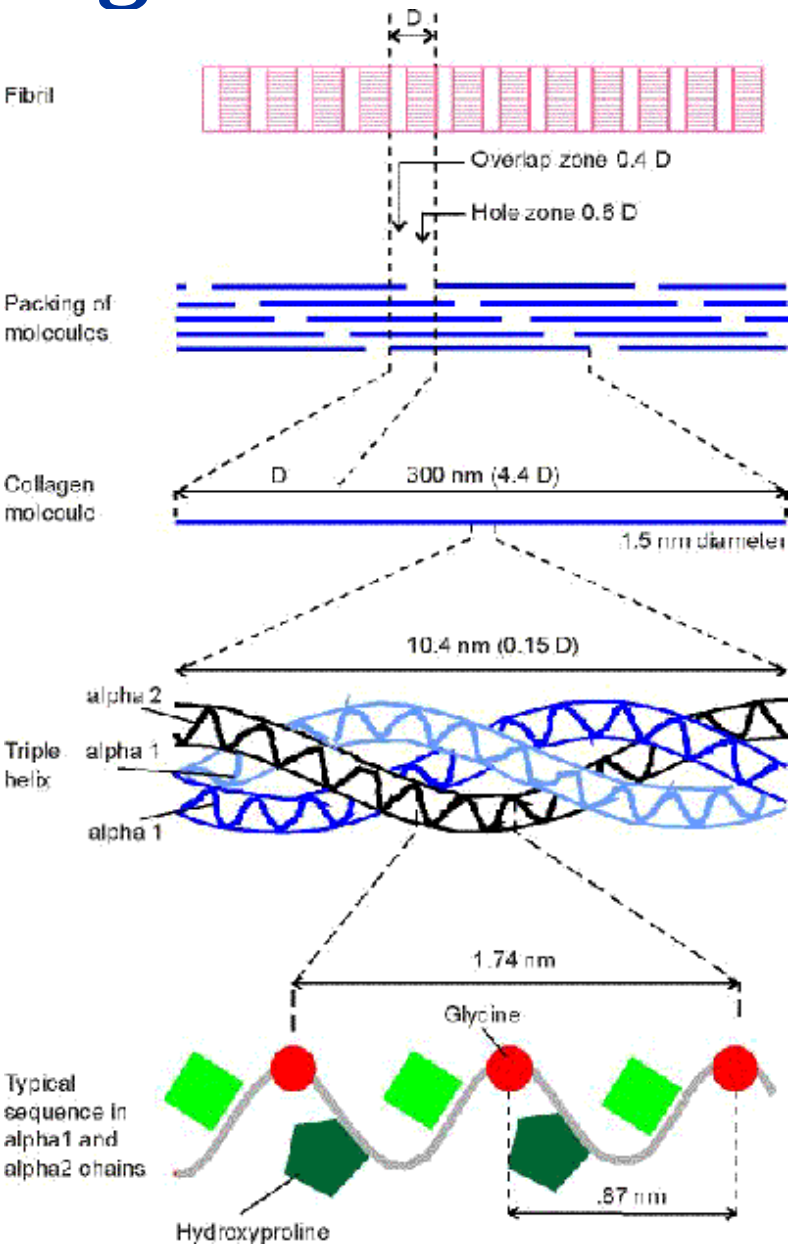

Fibril-forming

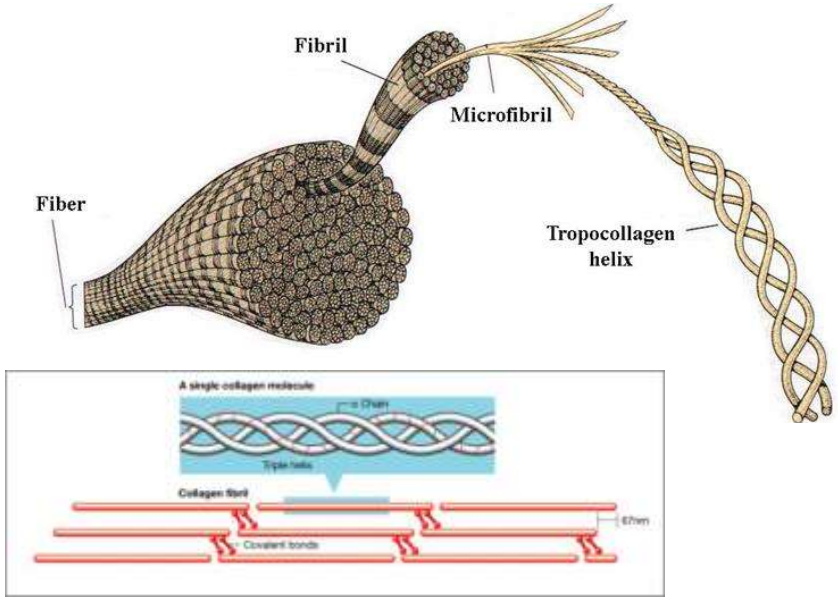

Fibril-associated

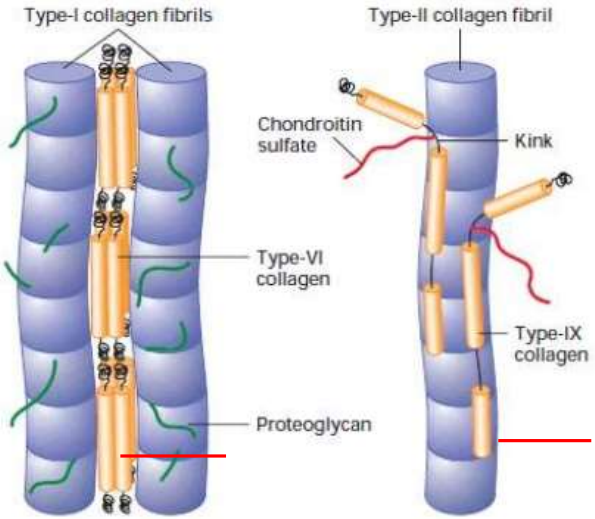

Network-forming

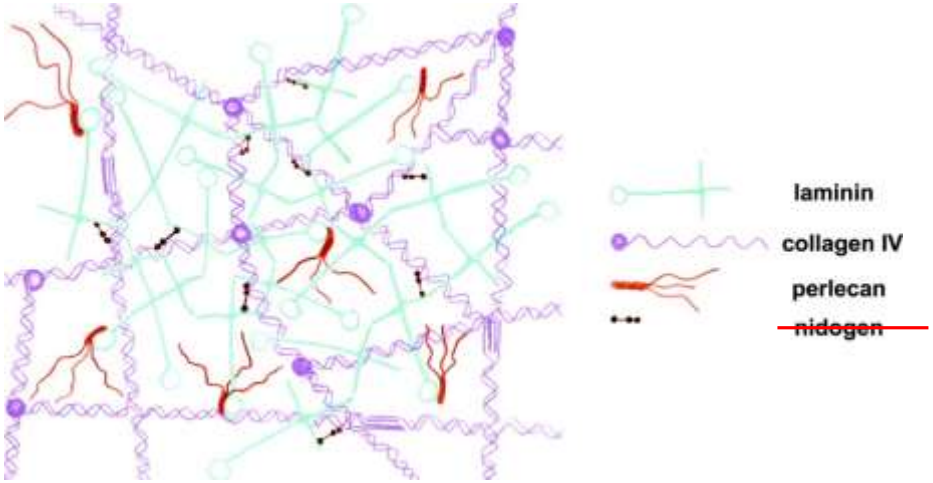

Anchoring fibrils

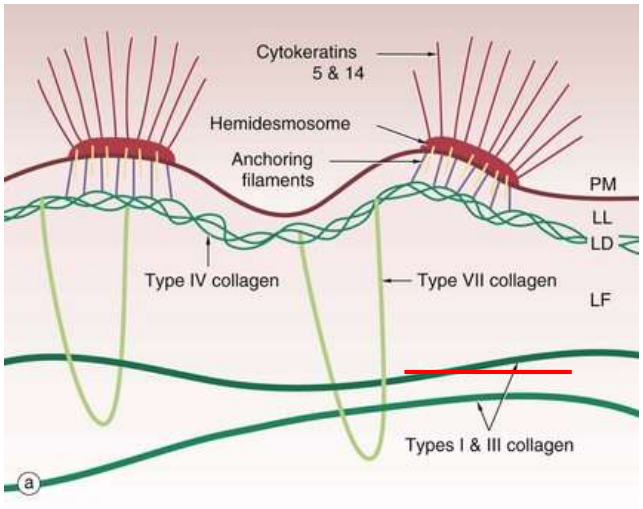

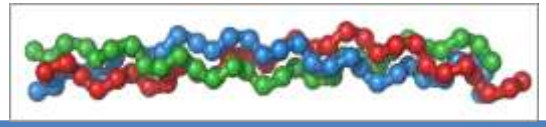

Types of (tropo)collagen !

	type XX<	molecular formula	polymerized form	tissue distribution
Fibril-forming (fibrillar)	**I** **II** **III** V XI	**$[\alpha1(I)]_2\alpha2(I)$** **$[\alpha1(II)]_3$** **$[\alpha1(III)]_3$** $[\alpha1(V)]_2\alpha2(V)$ $[\alpha1(XI)\alpha2(XI)\alpha3(XI)$	**Fibril** **Fibril** **Fibril** Fibril with I Fibril with II	**Type I Collagen Fiber: Bone, skin, tendon, ligaments, cornea, internal organs (90% of body collagen)** **Type II Collagen Fiber: Cartilage,** **Reticular Fiber: intervertebral disc, notochord, vitreous humor of the eye** **Skin, blood vessels, internal organs** As for type I As for type II
Fibril-associated	IX XII	$[\alpha1(IX)\alpha2(IX)\alpha3(IX)$ with type II fibrils $[\alpha1(XII)]_3$ with some type I fibrils	Lateral association Lateral association	Cartilage Tendon, ligaments
Anchoring fibrils	VII	$[\alpha1(VII)]_3$		Beneath stratified squamous epithelia
Network-forming	**IV**	**$[\alpha1(IV)]_2\alpha2(IV)$**	**Sheet-like network**	**Basal lamina**

Collagen stains

intestine

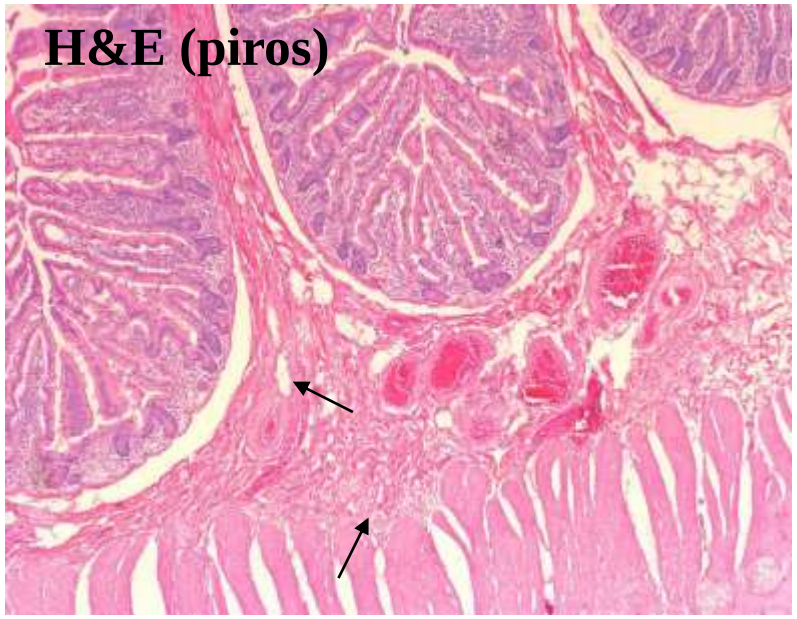

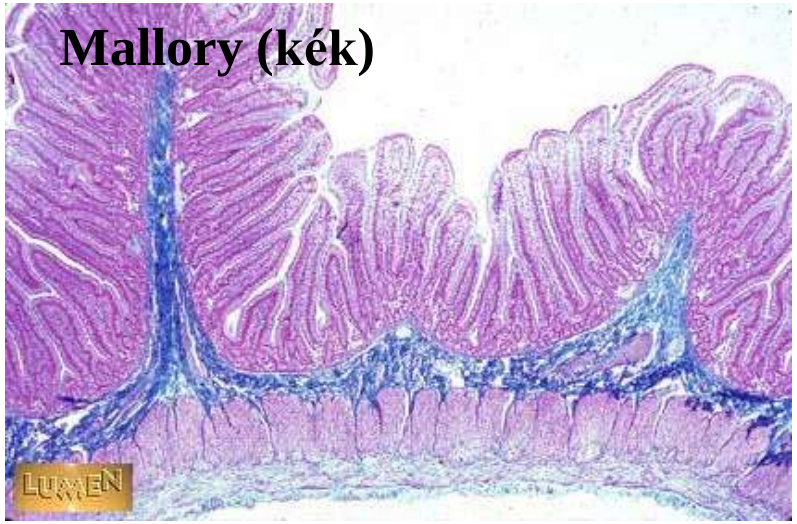

hairy skin

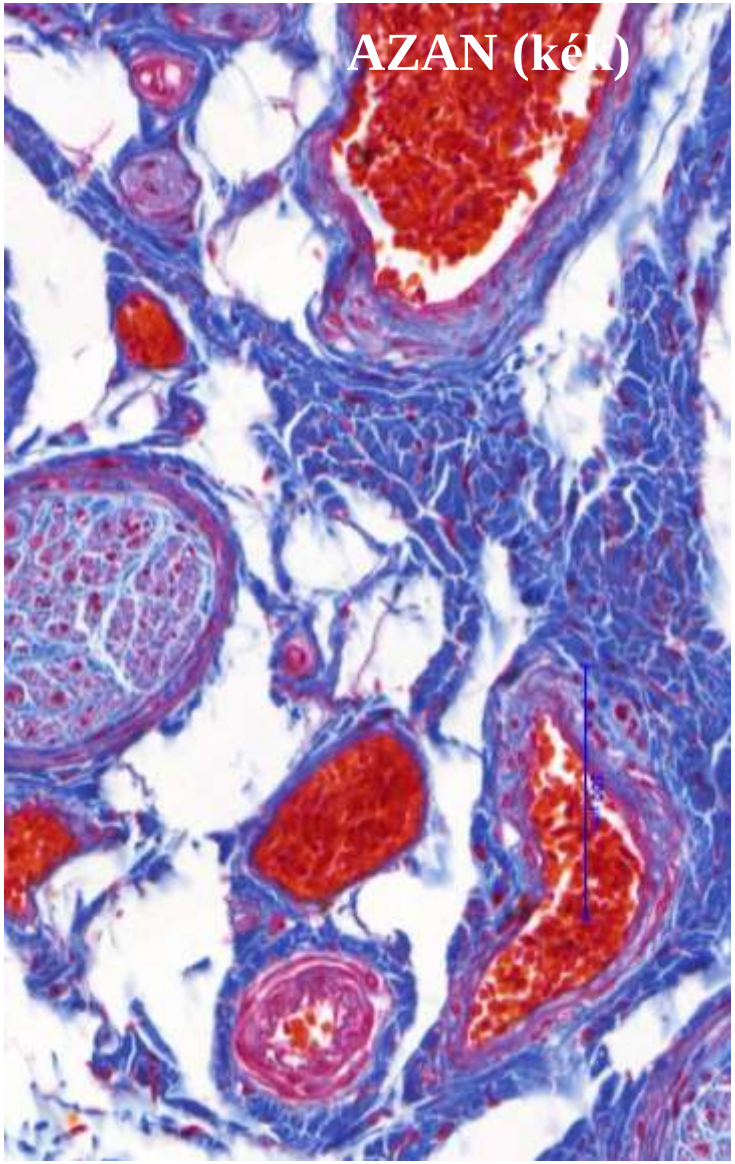

AZAN: **azocarmin** -red: nuclei, **anilin-blue**: collagen (type I) and reticular fibers (type III), **orange G-orange**: muscle, cytoplasm, red blood cells

Collagen/elastin synthesis

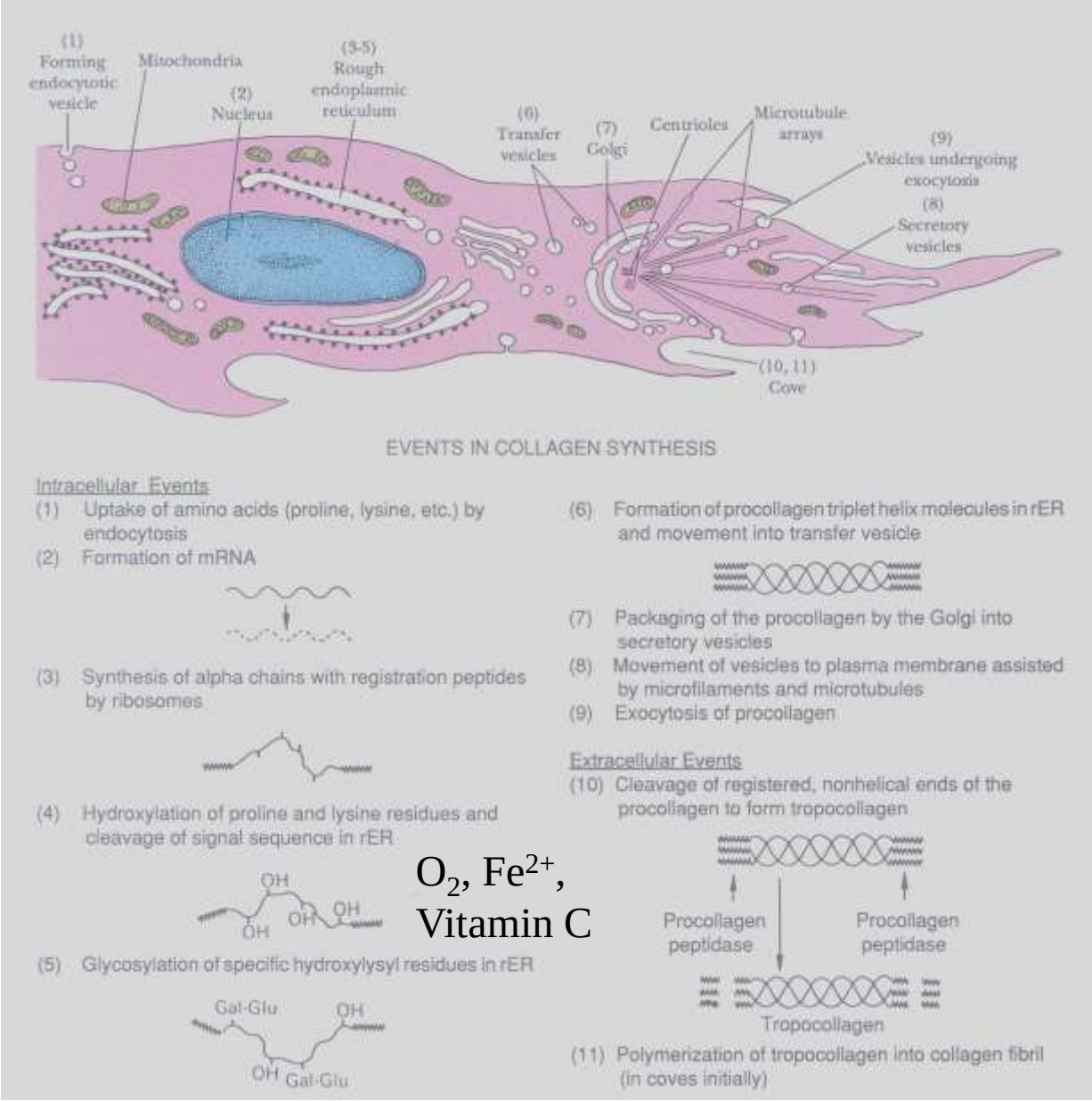

O_2, Fe^{2+}, Vitamin C

Simultaneous processes

procollagen-proelastin

tropocollagen-tropoelastin

Scurvy

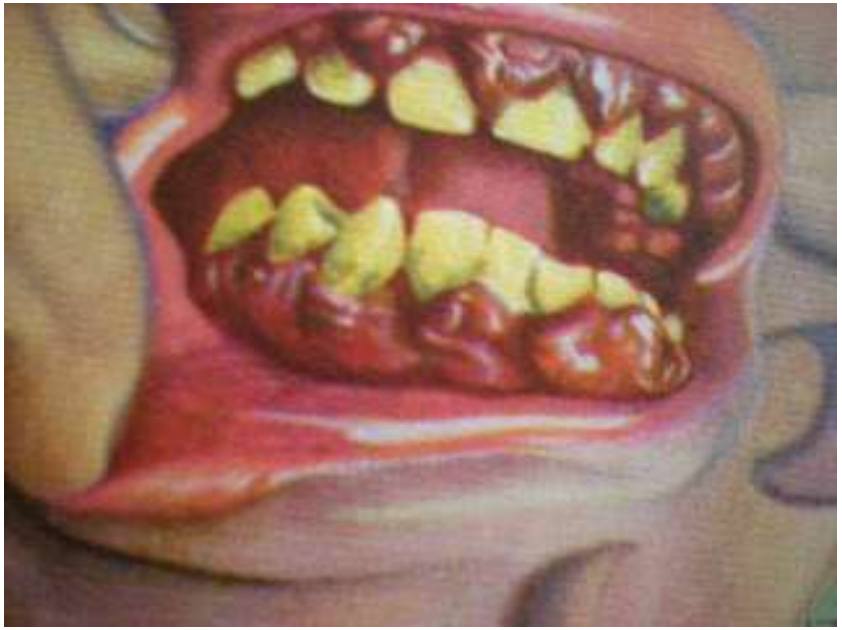

Symptoms of scurvy

James Lind (Scottish physician): in the first ever clinical trial (1747).

Exhaustion, anemia, appetite loss, poor weight gain, diarrhea, rapid breathing, fever, irritability, ulceration of the gums and loss of teeth, bleeding (hemorrhaging), swelling over long bones

„Lind developed the theory that citrus fruits cured scurvy. He also proposed that fresh water could be obtained by distilling sea water. His work advanced the practice of preventive medicine and improved nutrition.”

Osteogenesis imperfecta

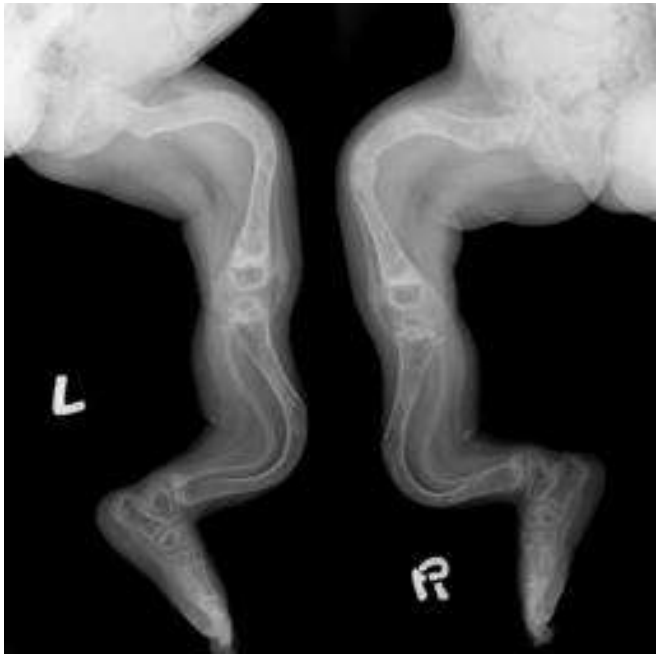

Reticular fibers

!

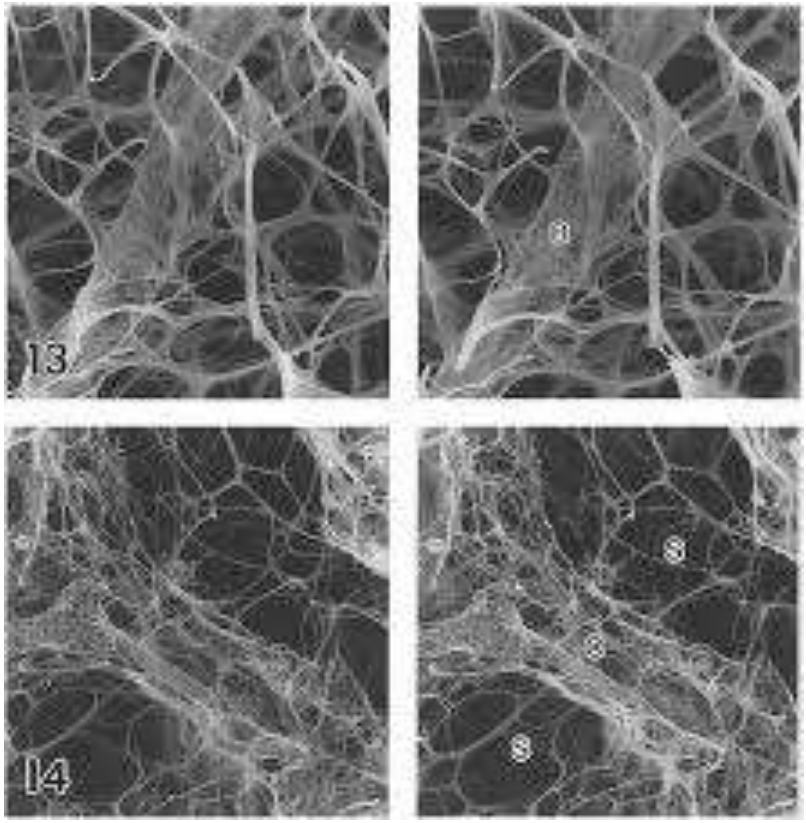

A very delicate strand of collagen fibers. **It consist of collagen fibrils (diameter: 20 nm) – type III (tropo)collagen**

$[\alpha 1(III)]_3$

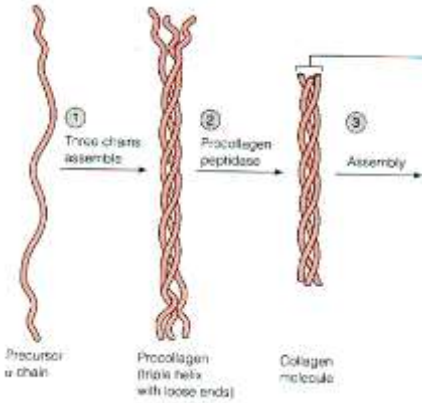

High content of sugar groups. Arranged in a network or mesh like pattern

Examples :boundary of connective tissue with epithelium
mesenchyme but replaced by collagen as the tissue matures
around adypocytes, smooth muscle cells, blood vessels, nerves, glands
hemopoetic and lymphatic tissues (reticular ct)
liver

Reticular fiber stains

(lymphatic tissue-spleen)

H&E
(not identifiable)

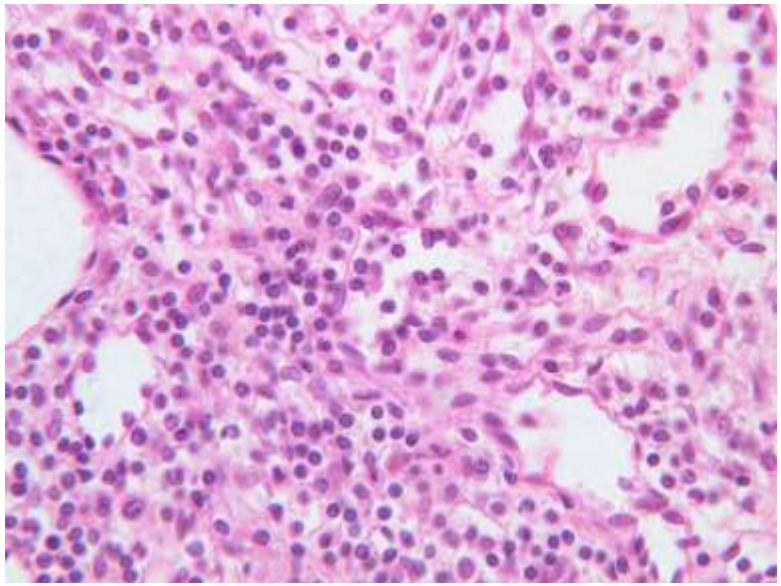

Silver impregnation
(black)

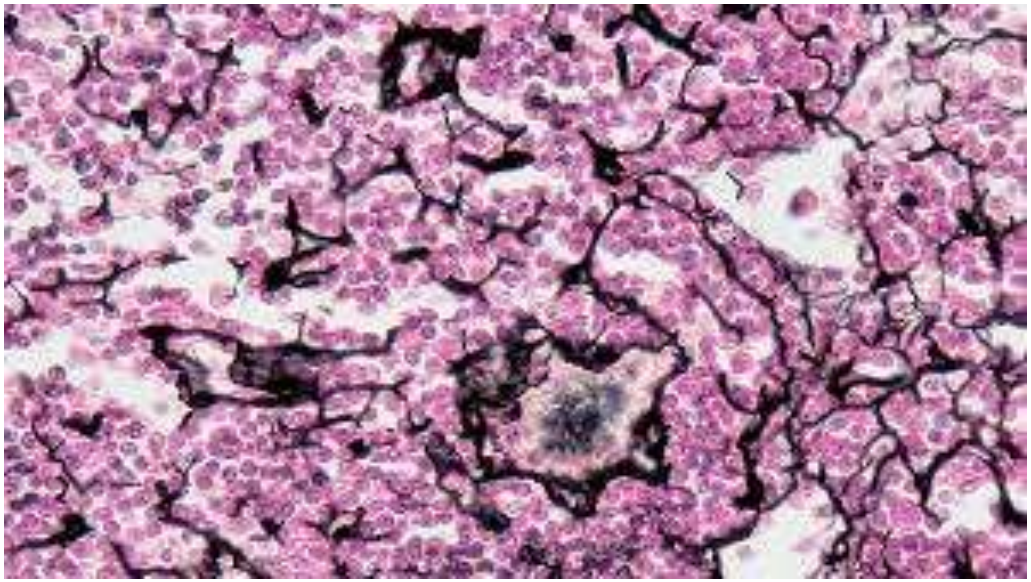

PAS (purple)

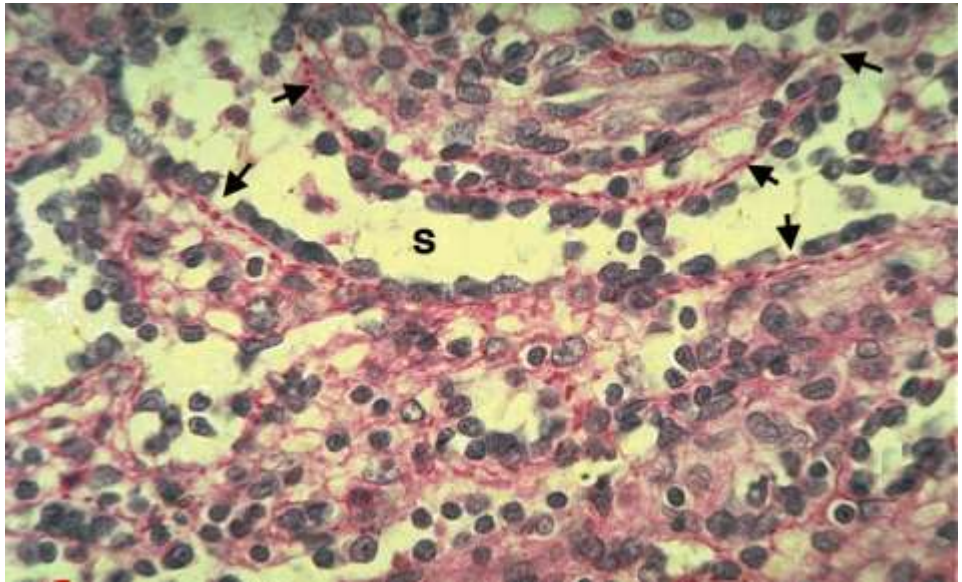

Periodic Acid Schiff (PAS) Reaction

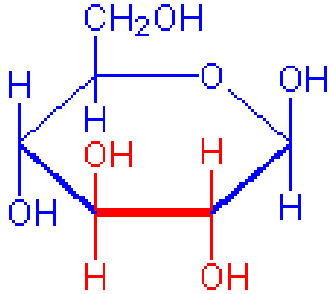

1-2-glycol

oxidation

+ HIO_4 =

Periodic Acid

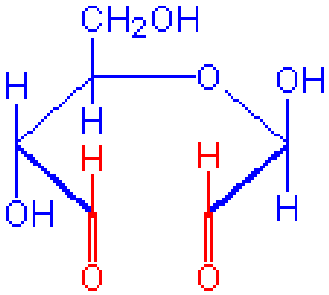

Aldehyde

Aldehyde

+

Schiff's reagent

↓

Purple color

PAS reaction is a technique for the demonstration of certain types of carbohydrates (polysaccharides, mucopolysaccharides, glycoproteins and glycolipids) in tissue sections

Some PAS positive structures:

- **Basement membranes**
- **Kidney tubules**
- **Goblet cells (intestine)**
- **Retinal rods**

Intracranial aneurysms

Eur Arch Psychiatr Neurol Sci (1985) 235:102–106

European Archives of Psychiatry and Neurological Sciences

Reticular Fiber Deficiency in the Intracranial Arteries of Patients with Dissecting Aneurysm and Review of the Possible Pathogenesis of Previously Reported Cases

Katalin Hegedüs

Department of Neurology and Psychiatry, University Medical School of Debrecen, H-4012 Debrecen, Hungary

Summary. The pattern of reticular fibers in the tunica media of the major intracranial arteries was investigated in two patients with dissecting aneurysm. In numerous circumscribed areas, the reticular fibers were absent close to the internal elastic lamina in all major arteries of each patient. It is suggested that the subintimal deficiency in reticular fibers results in insufficient fixing of the tunica intima to the media contributing to their separation when the internal elastic lamina becomes defective. The presumed etiologies of the previously reported cases are reviewed and the possible origin of the deficiency in reticular fibers is discussed.

Key words: Dissecting aneurysm – Intracranial arteries – Reticular fibers

Introduction

Intracranial dissecting aneurysms are rare, although recently it has been recognized more and more as the cause of cerebrovascular diseases, predominantly in younger individuals (< 40 years) [29]. Mostly, the plane of dissection occurs between the internal elastic lamina and the tunica media. This differs from the aorta and other extracranial arteries, where the hemorrhage is commonly found within the media or adventitia. This type of dissection is infrequent in cerebral arteries, it was observed in approximately one-fifth of the reported cases.

The pathogenesis of cerebral dissecting aneurysms is poorly understood. Dissection has been observed within different pathologic conditions. In several reports, however, no definite cause of dissection could be determined [5, 7, 19, 23, 30, 34, 35, 57]. As the amount and distribution of reticular fibers has not yet been investigated in patients with intracranial dissecting aneurysms, we present its pattern in the major intracranial arteries of two patients with subintimal hemorrhage reported previously [21, 30].

Material and Method

All major intracranial arteries of two patients with subintimal dissecting aneurysm were investigated with Gömöri's method for reticulin. One was a 13-year-old boy with dissecting aneurysm of the right carotid and middle cerebral arteries. The other was a 47-year-old man with dissection of the basilar and both vertebral arteries. Case reports have already been published [21, 30].

Samples were taken from the major branching sites and 3 to 5 mm proximal or distal from them. The blocks were serially sectioned, and stained with hematoxylin-eosin, elastic-van Gieson, orcein, trichrome, and PAS.

Results

In the intracranial arteries of the 47-year-old man, various pathologic changes of the internal elastic lamina were observed in the nondissected arteries, especially at the branching points. The findings were similar to those observed in the intracranial arteries of the 13-year-old boy. The degree of intimal proliferation corresponded to the changes considered characteristic of aging.

In contrast to arteries of patients without vascular diseases (Fig. 1), using Gömöri's method for reticulin, numerous areas of various size without reticular fibers were seen next to the internal elastic lamina (Figs. 2 and 3). In the other parts of the muscular layer, the reticular fibers were often irregular and coarser than usual, especially in the arteries of the 47-year-old man. In some places these fibers were also sparse in the outer part of the media (Fig. 4). The changes mentioned above could be found in all major intracranial arteries of each patient. In each artery, however, the segments without reticular fibers alternated with segments with a relatively well-preserved reticulin pattern (Fig. 4).

Discussion

According to Yonas [64] the comparatively rare dissection within the tunica media or adventitia of the arteries supplying the brain may derive from rupture either of vasa vasorum or new vessels which form in the necrotic media. In the absence of necrotizing processes, the vessel lumen is the only source of subintimal hemorrhage in the intracranial arteries, since these arteries generally lack vasa vasorum [54, 64]. However, in severe atherosclerosis the intracranial arteries may also contain vasa vasorum [54].

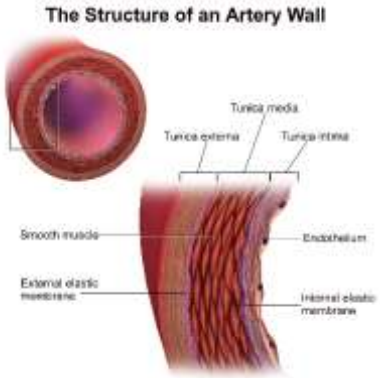

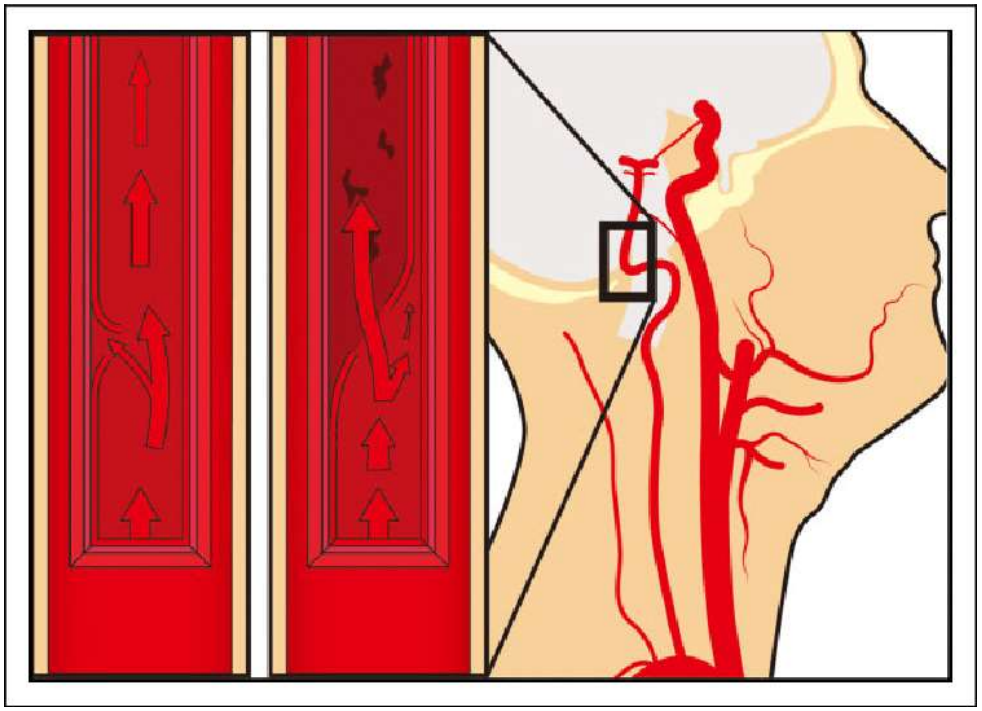

Zhao et al: Angiology 2018, Vol. 69(1) 17-30

Elastic fiber

!

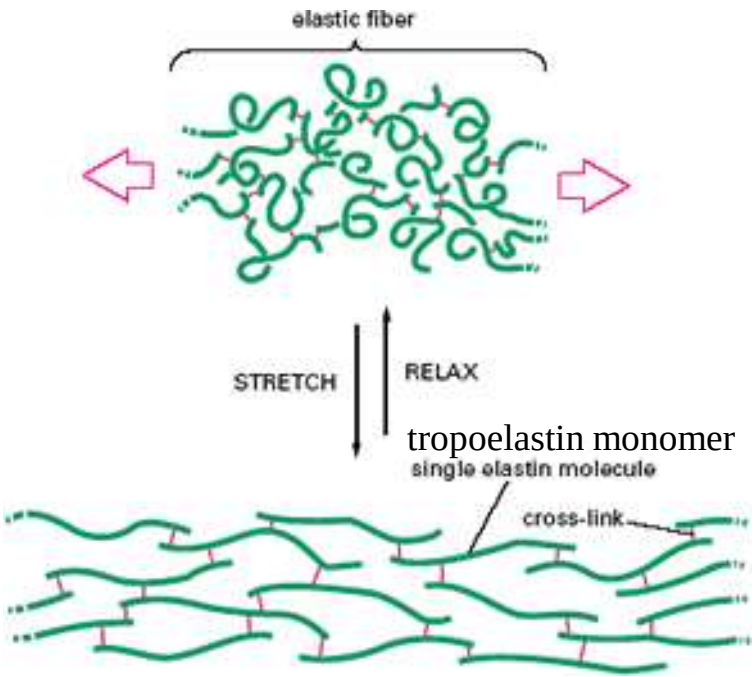

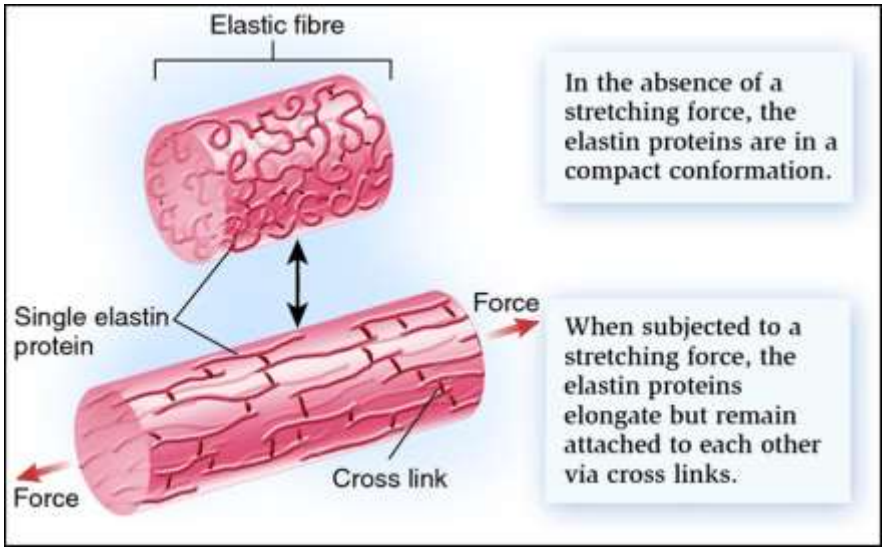

- **consist of**

  amorphous component called elastin

  fibrillar component microfibrils (fibrillin, d= 8-10 nm)

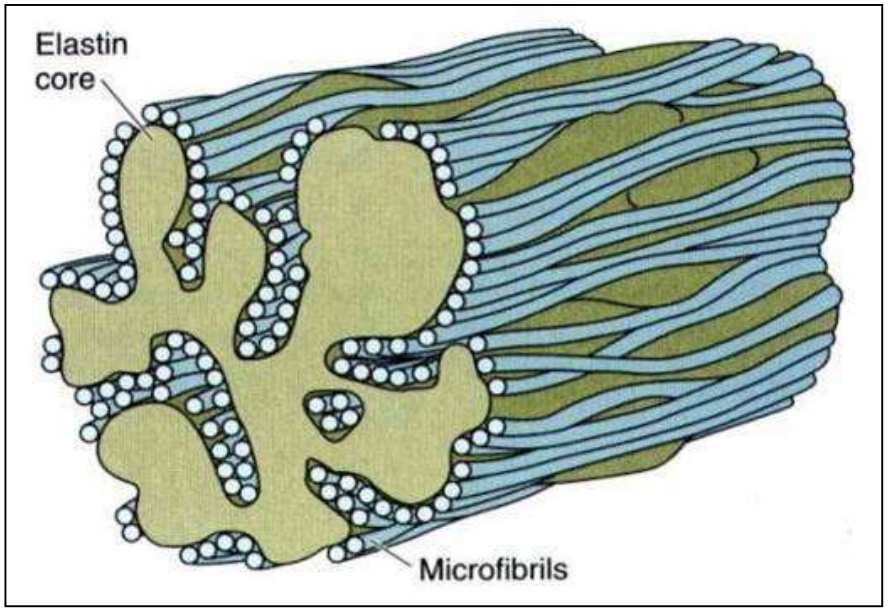

- **have elastic properties**
- **arranged in random fashion**
- **branch and form networks**
- **examples *elastic ligaments* (associated with spinal column), *elastic arteries***

Elastic fiber

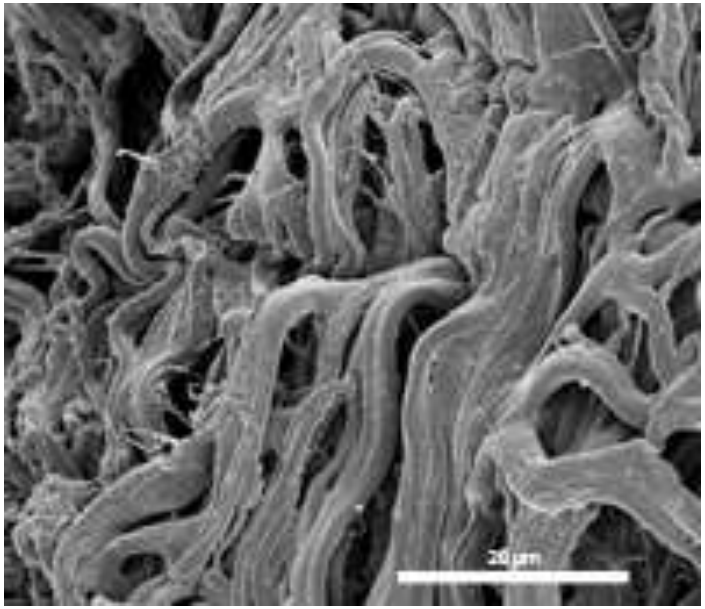

2002 Martin-Luther-Universität
Halle-Wittenberg
Naturwissenschaftliche Fakultät I
- Biowissenschaften
Institut für Pharmazie

Marfan syndrome

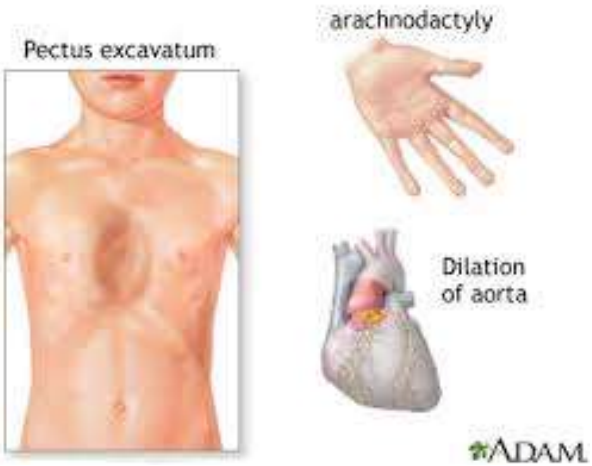

https://positiveexposure.org/frame/marfan-syndrome/

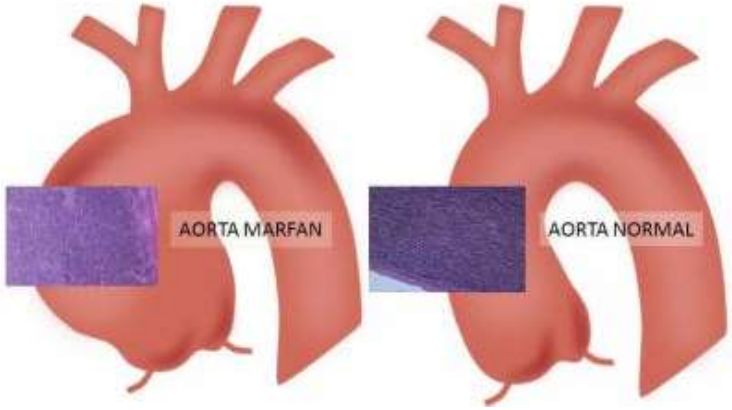

Fibrillin-1 mutations in Marfan syndrome

Elastic *lamellae*

!

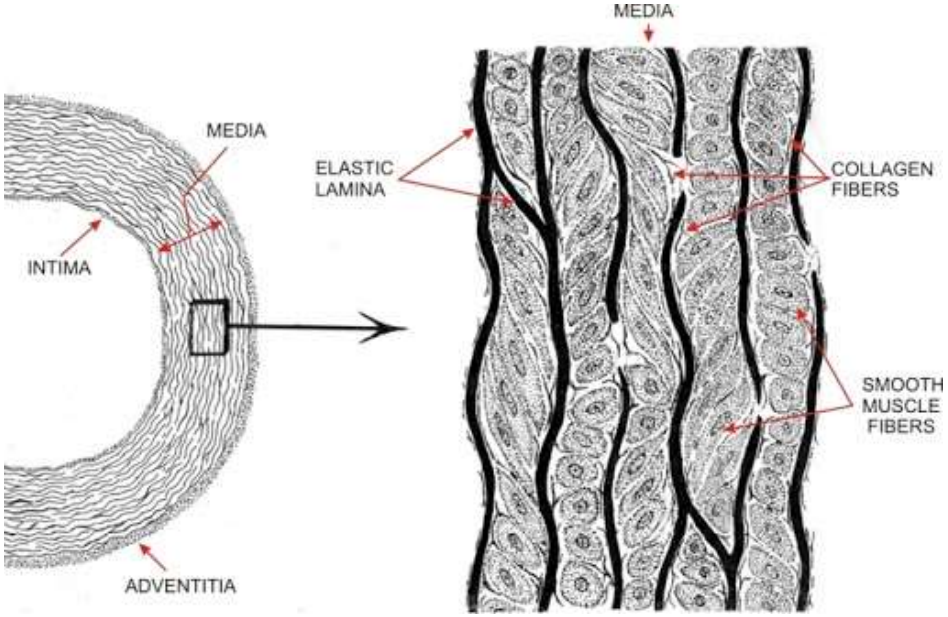

Vascular **smooth muscle cells** produce the elastic lamellae, that consist of **elastine** without fibrillin support.

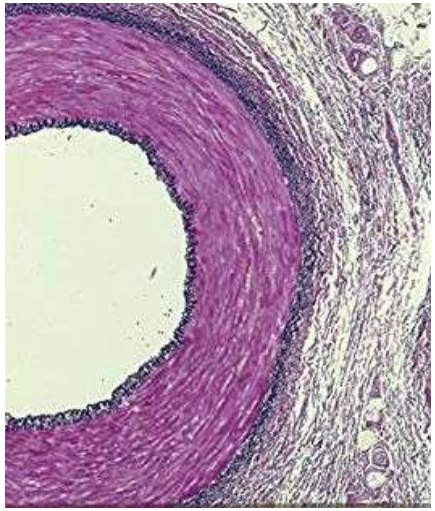

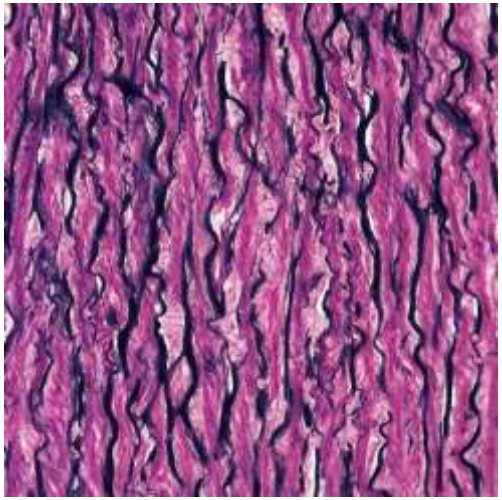

Meghan A. Piccinin and Janice Schwartz: Histology, Verhoeff Stain , Bookshelf ID: NBK519050PMID: 30085592, Copyright © 2020, StatPearls Publishing LLC.

Aortic wall damage in mice unable to synthesize ascorbic acid

Abnormalities in the aorta of Gulo −/− mice.

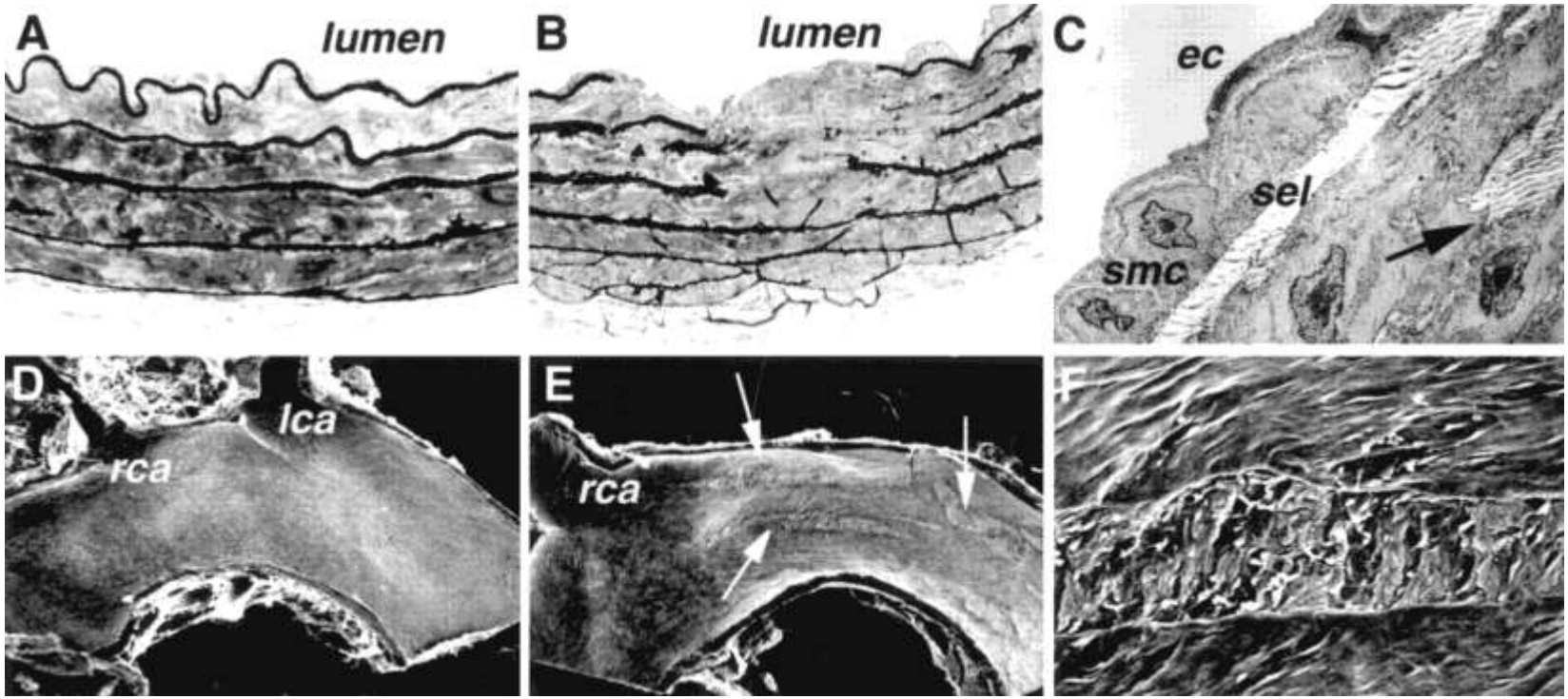

Nobuyo Maeda et al. PNAS 2000;97:2:841-846

Elastic fiber stains

H&E (not identifiable)

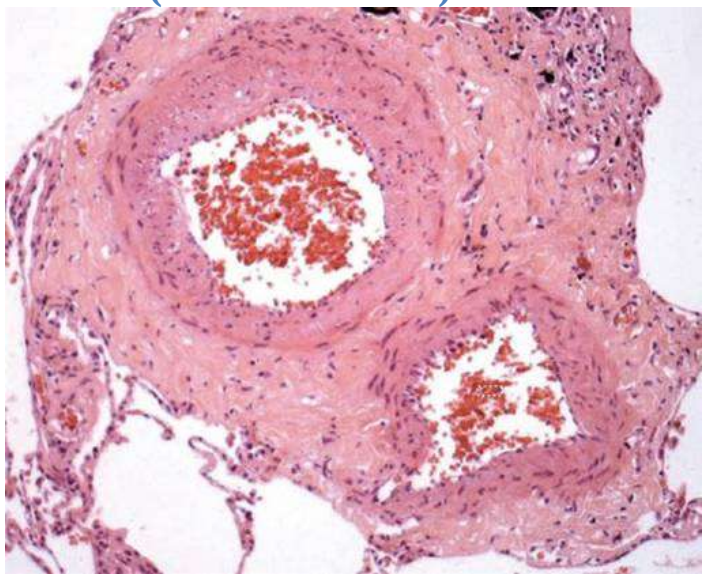

Verhoeff-H (black)

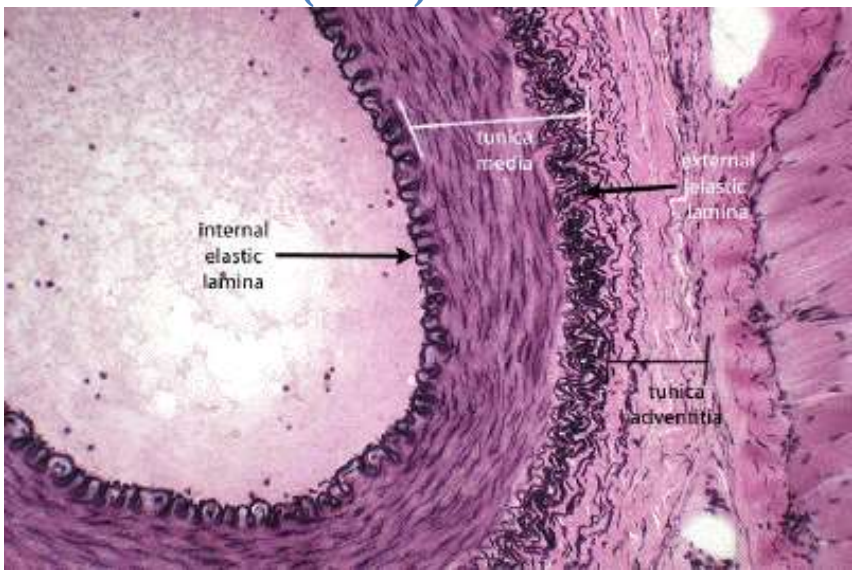

Elastic van Gieson (black)

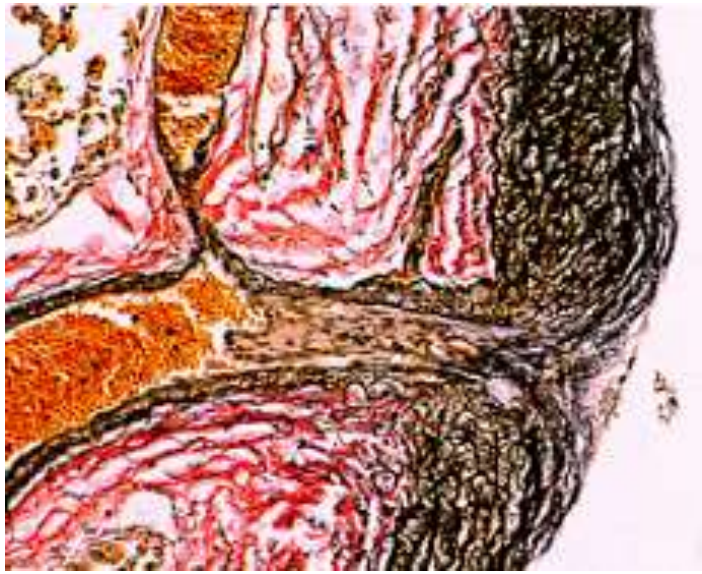

Gömöri trichrome (blue black)

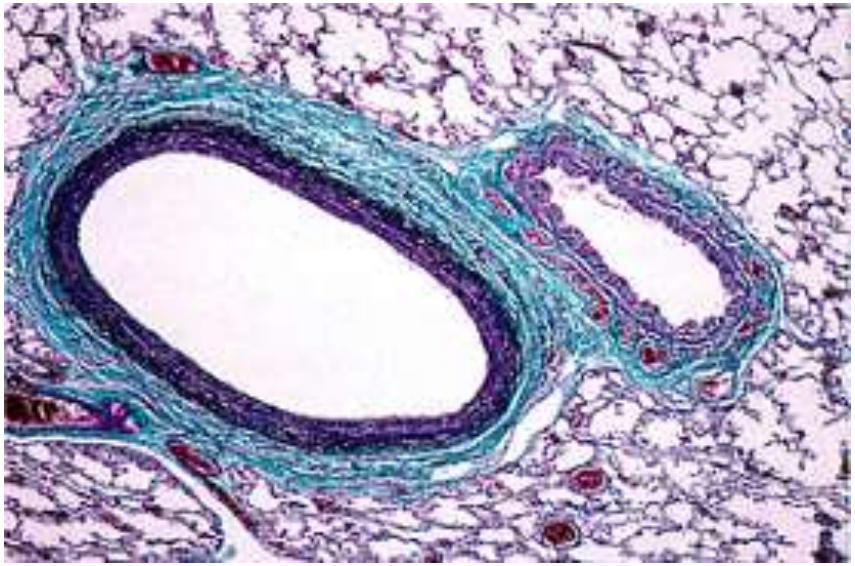

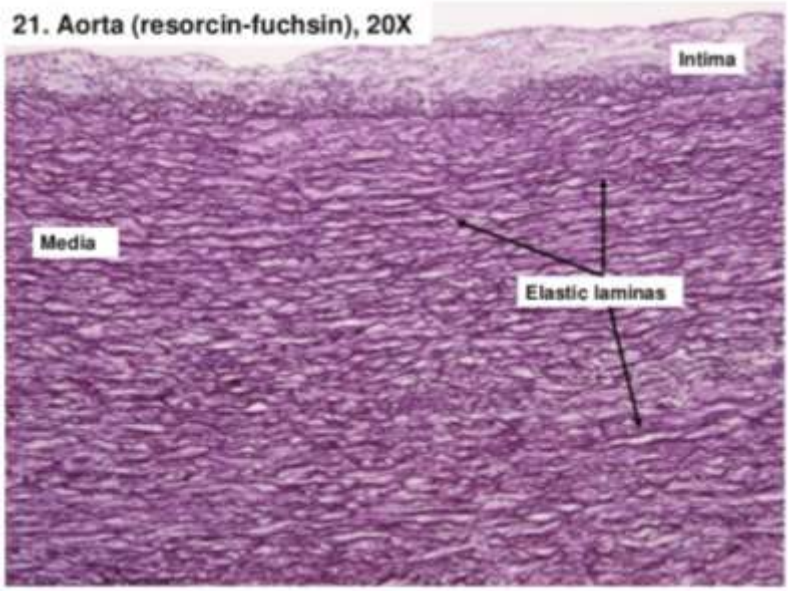

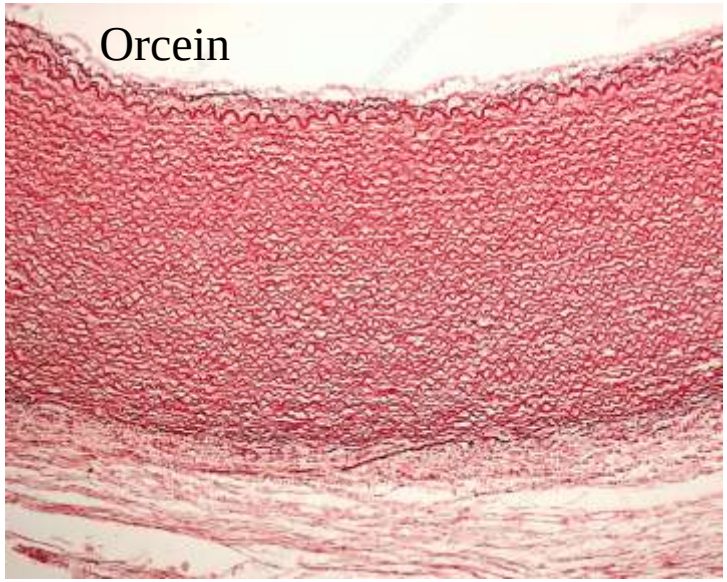

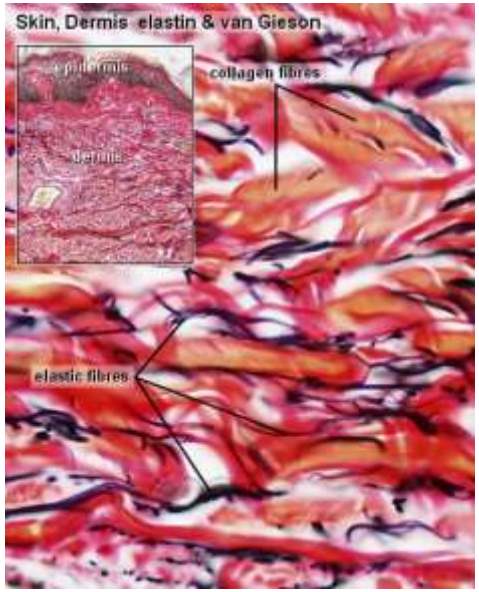

Hornowsky: van Gieson (Iron-hematoxilin, picric acid, acid fuchsin) and resorcin-fuchsin
collagen-red, **elastic**-dark blue, muscle, cytoplasm, red blood cells-yellow, **nucleus**-black

Cutis laxa

Prof Dr Chua Chung Nen

Ground substances

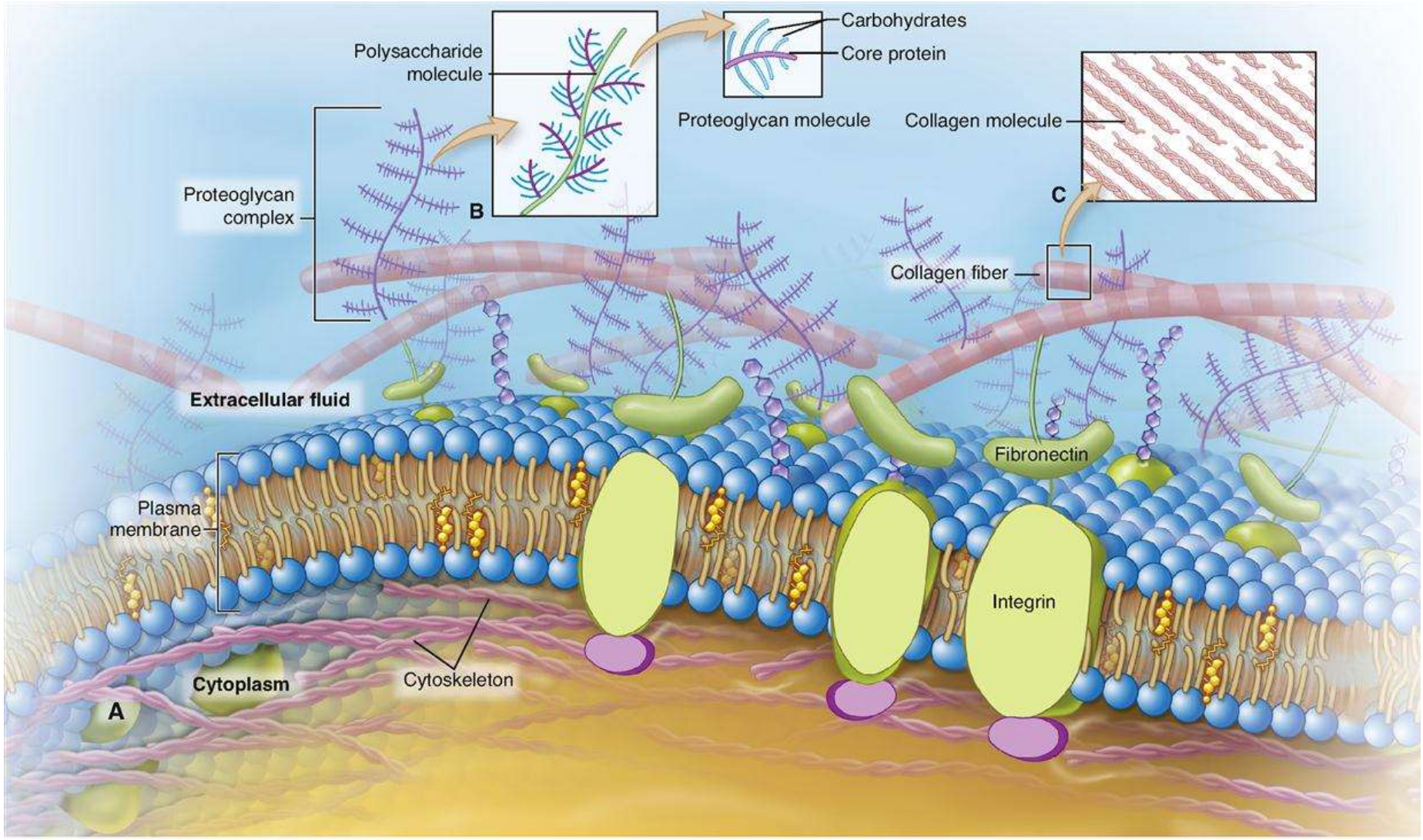

Ground substances

!

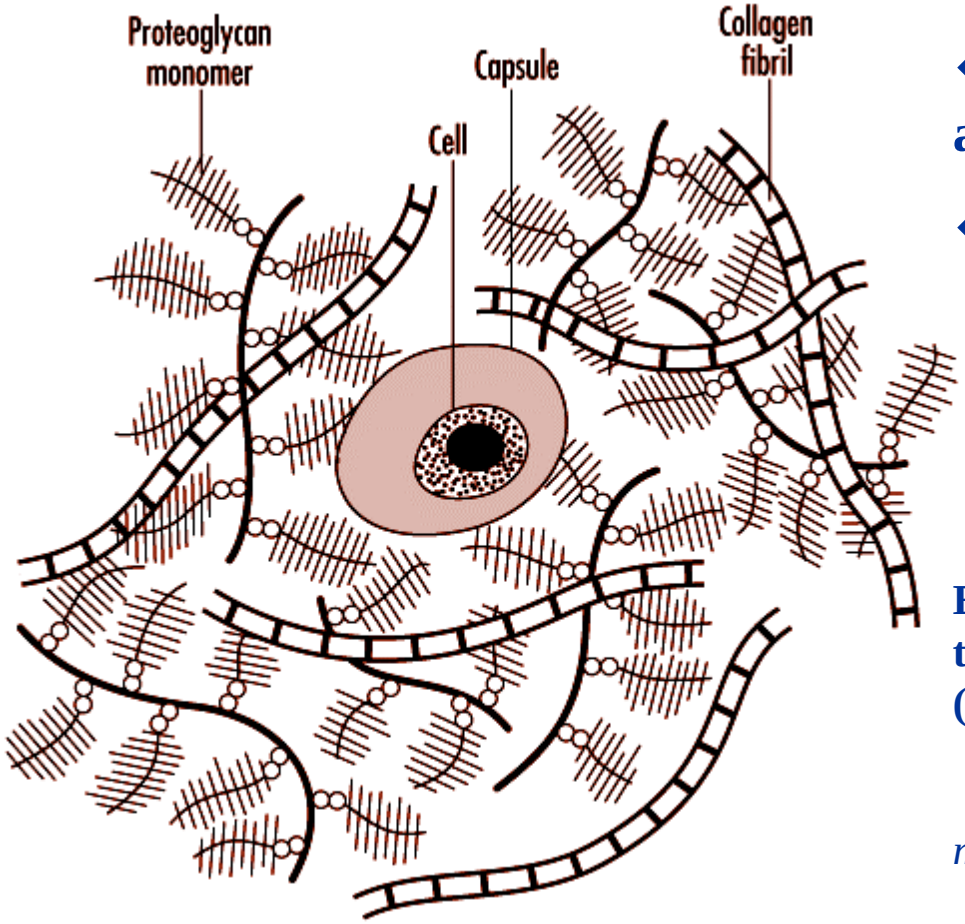

- ❖ **Surround cells and fibers**
- ❖ **Histologycally unstructured or amorphous**
- ❖ **The major components:**

glycosaminoglycans (GAG)

proteoglycans

adhesion glycoproteins

Eg. fibronectin (binds cells to the matrix), tenascin, entactin, trombospondin, laminin (basal lamina)

interstitial fluid (*ions, low molecular weight proteins*

Glycosaminoglycans

!

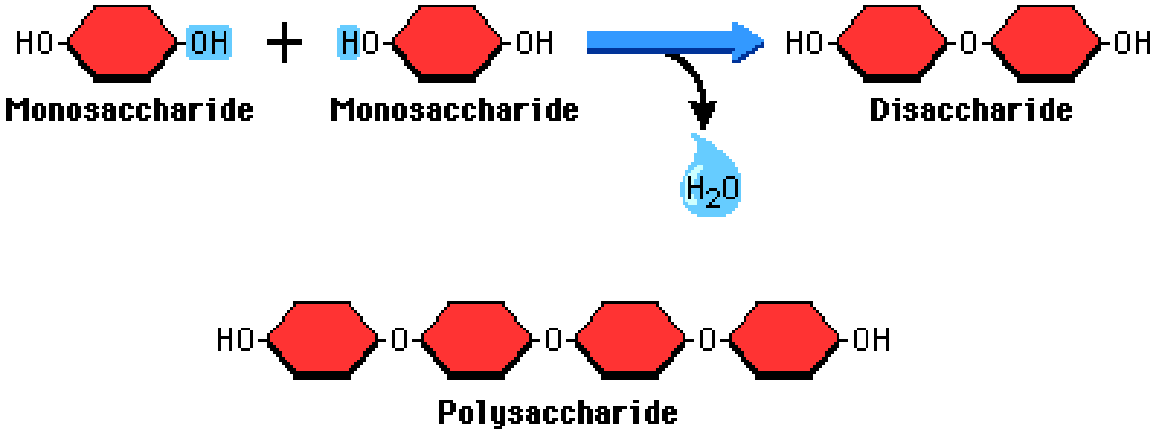

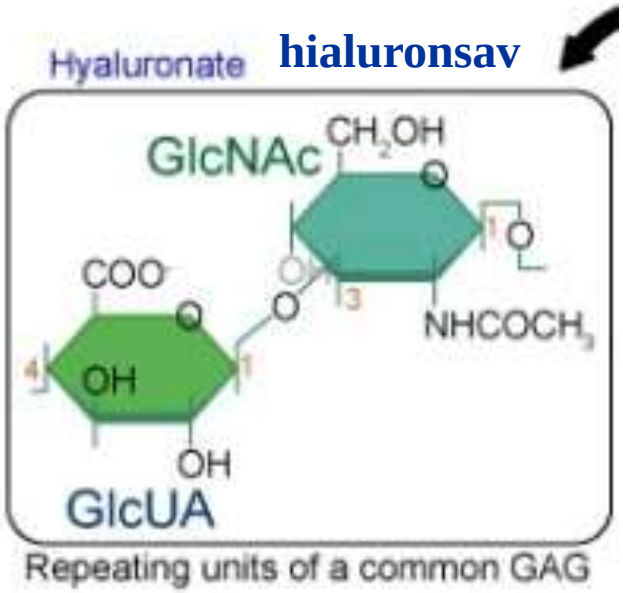

Glycosaminoglycan (GAG): ***linear polisaccharides formed by repeating disaccharid units***

(hexose types, sulphate groups and chemical bonds)

Chondroitin sulfate (cs)

Dermatan sulfate (ds)

Keratan sulfate (ks)

Heparan sulfate *(hs)*

Heparin

Hyaluronic acid (HA) :

Does not form proteoglycan

Not sulphated

Binds water

Lubricant

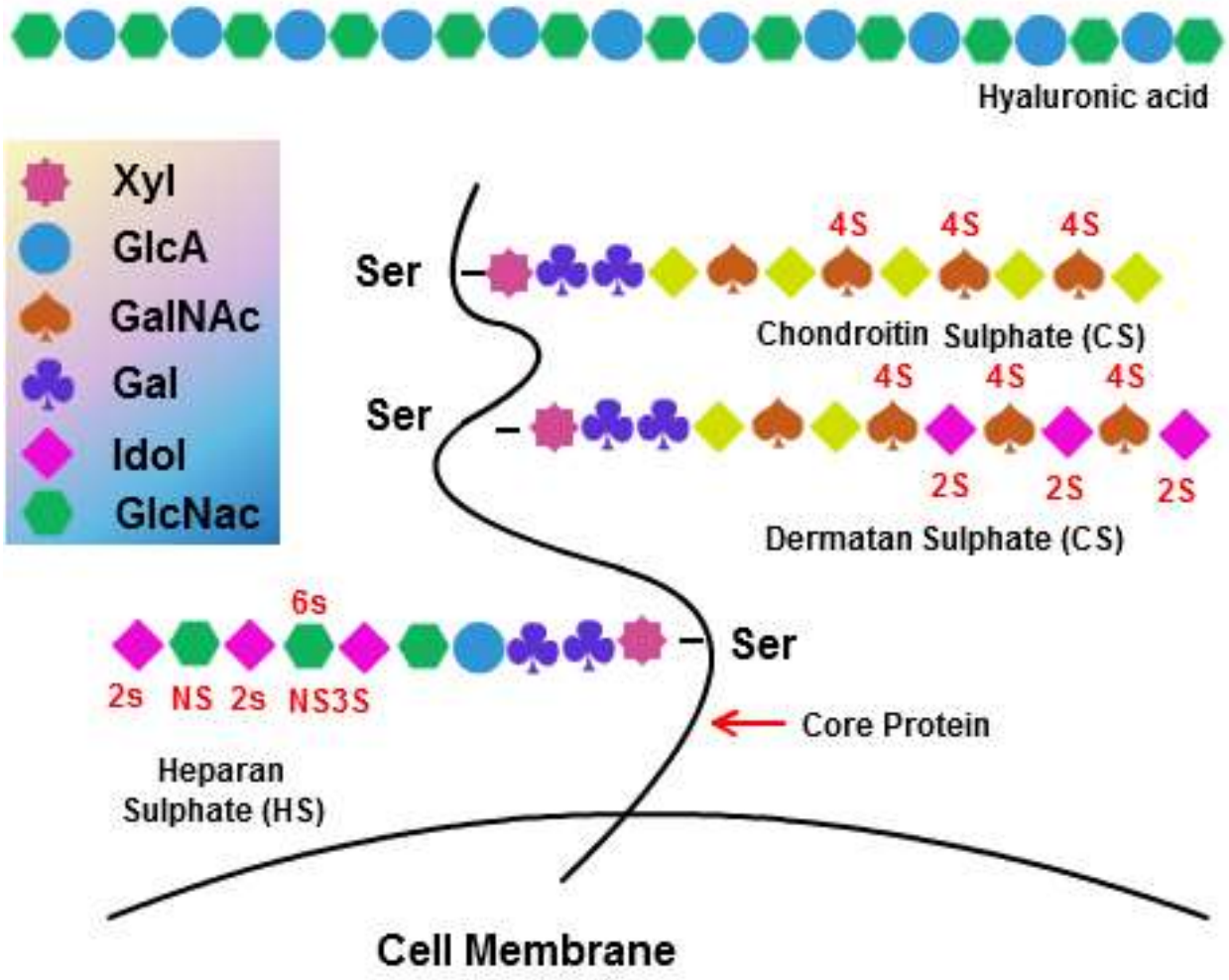
Hyaluronic acid
Xyl
GlcA
GalNAc
Gal
Idol
GlcNac
Ser
4S
4S
4S
Chondroitin Sulphate (CS)
Ser
4S
4S
4S
2S
2S
2S
Dermatan Sulphate (CS)
6s
2s
NS
2s
NS3S
Ser
Core Protein
Heparan
Sulphate (HS)
Cell Membrane

Proteoglycans (PG)

!

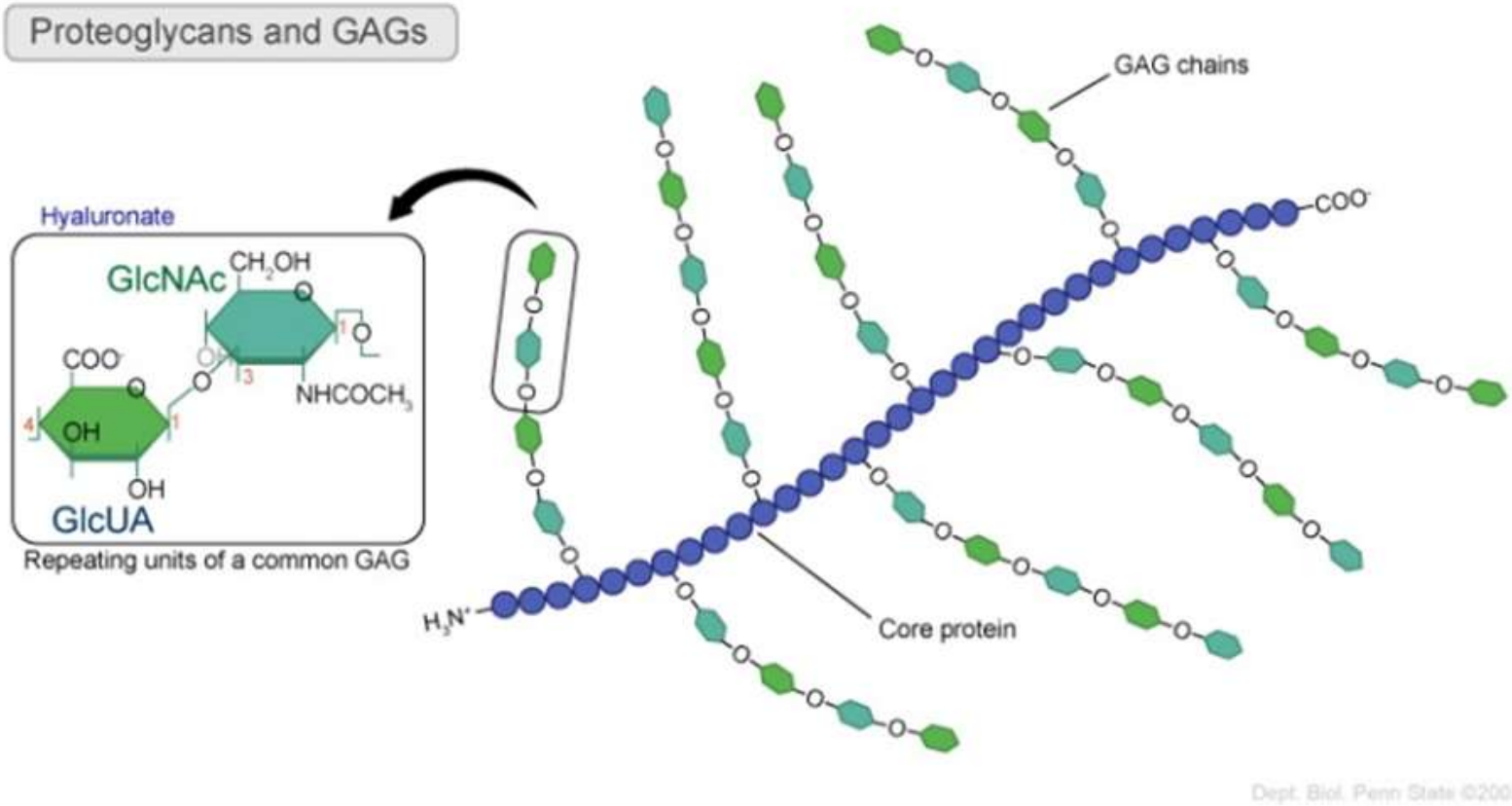

Proteoglycan monomer: GAG chains covalently bound to core protein

(size of the core protein, number of GAG chains 1-2, 30-40, 100-150, composition, sulphation → structure and function)

Significance: negative charges of GAG chains → cation binding , water binding (resistance against pressure), repulsion exists among GAG chains which keeps the chains paralell and stiff.

PGs bind to collagen fibrills adhesion molecules, cell surfaces.

Proteoglycans (PG)

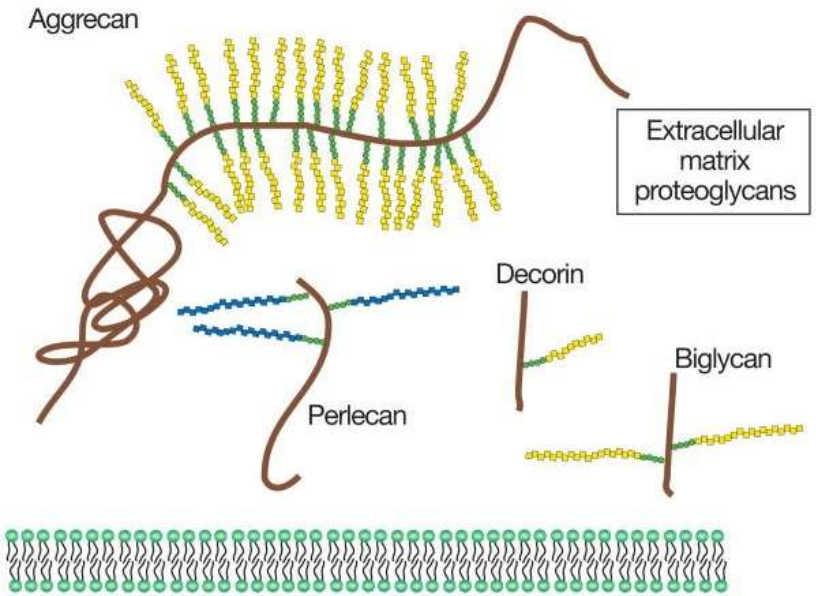

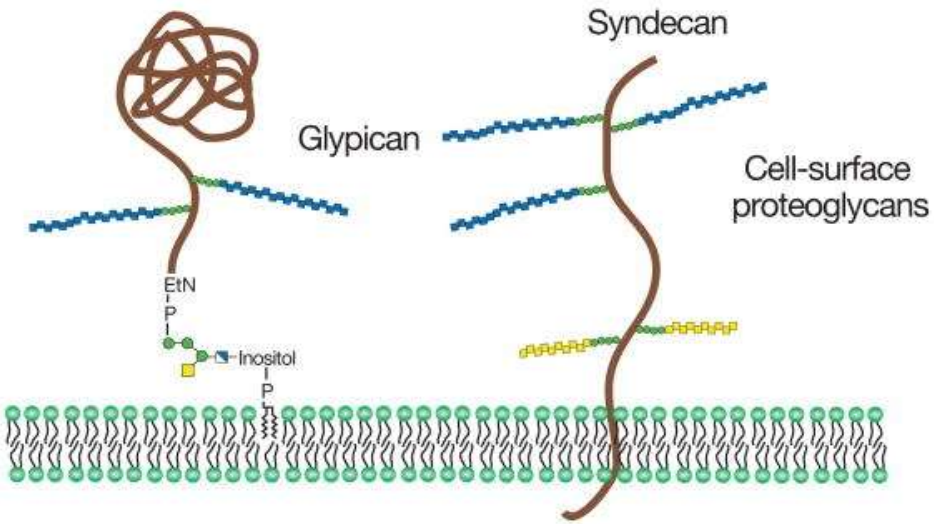

Pl. syndecan (hs,cs), **decorin** (cs,ds), **versican**, **aggrecan** (cs, ks)

Proteoglycan-hialuronan aggregate

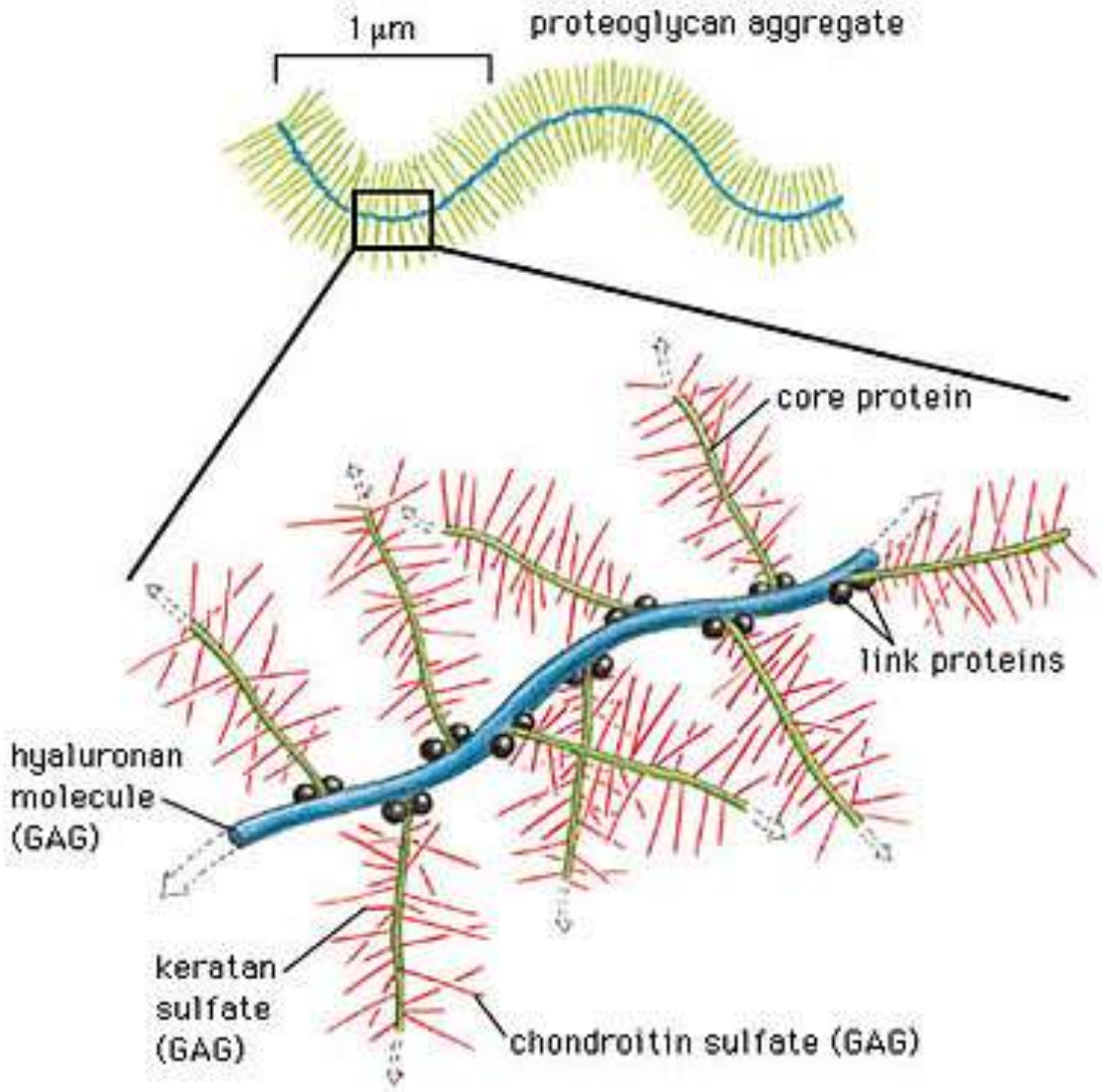

Basement membrane

!

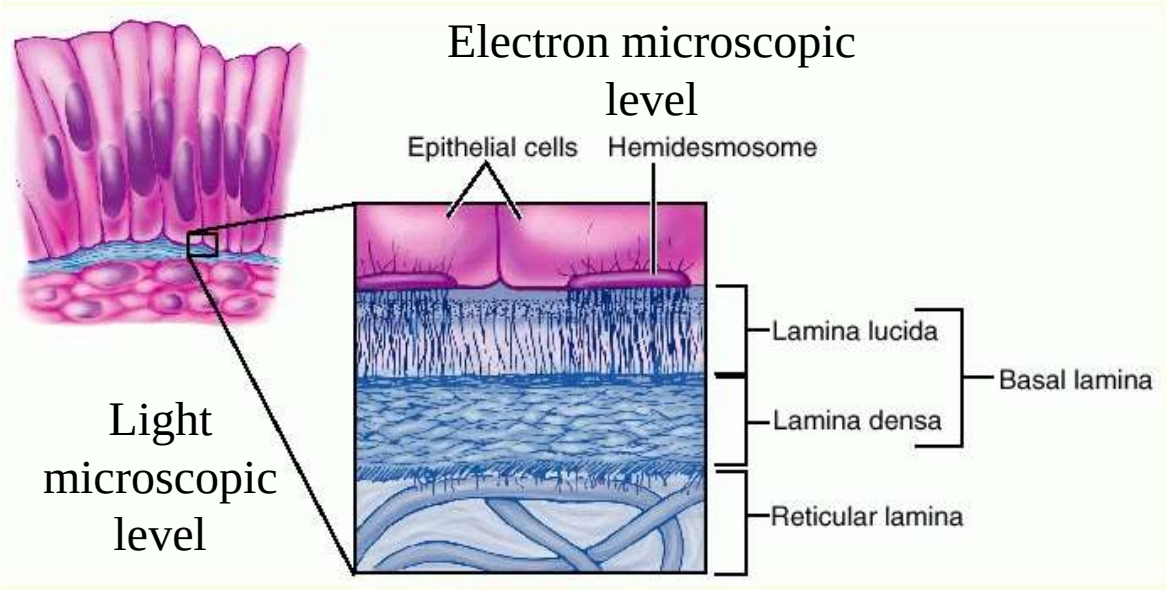

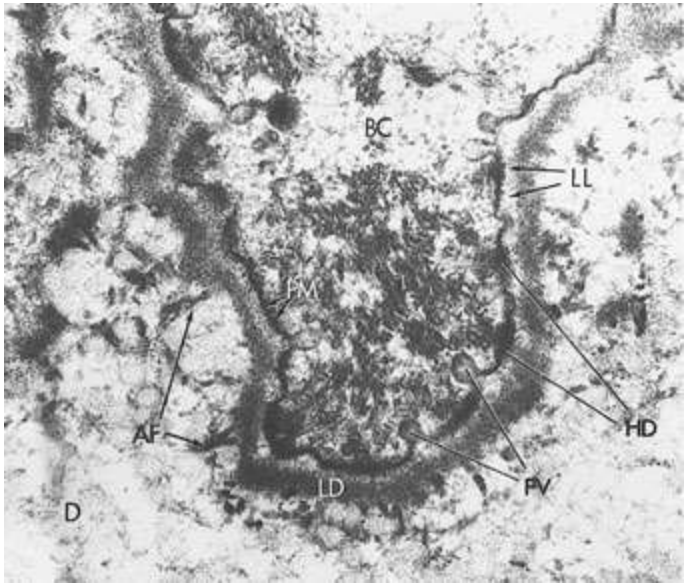

- **Layer of variable thickness beneath basal surface of each cell comprising the epithelium.**
- **Not easily distinguished by H&E.**
- **Easily seen after staining (PAS) that reacts with sugar moieties of proteoglycans produced by the epithelial cells and accumulates under the basal layer.**

Composition of the Basement membrane

!

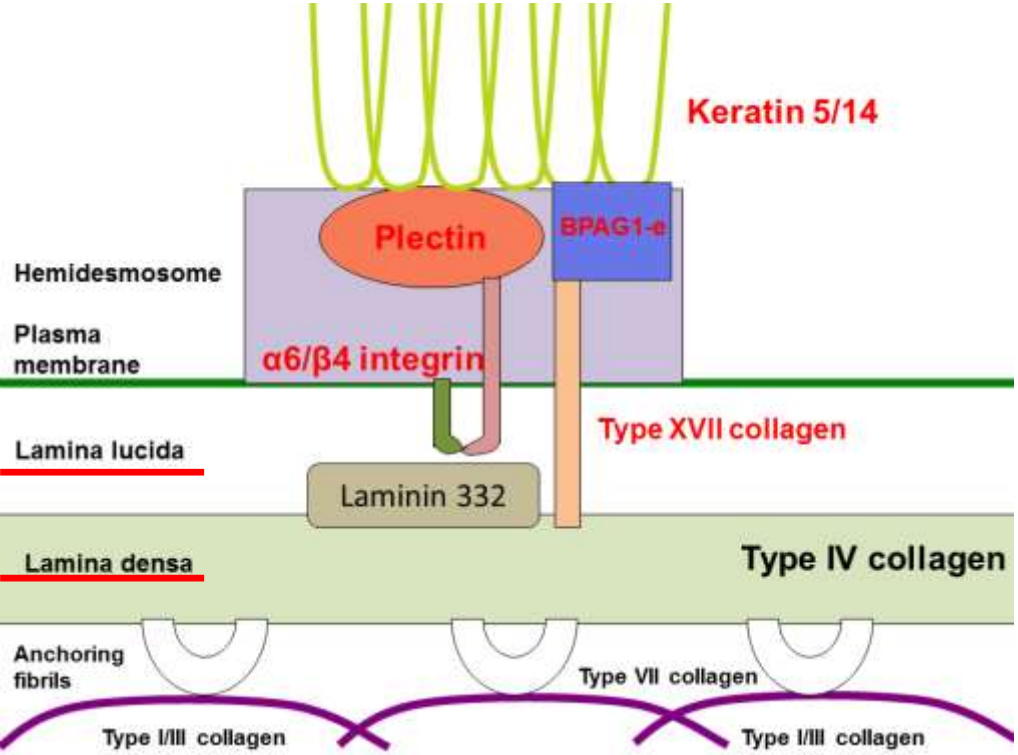

Basal lamina:

Type IV collagen (Provide structural integrity. Secreted by epithelial cells.

Laminin glycoprotein molecule secreted by epithelial cells and bind Type IV collagen, heparan sulphate, & integrins. Bridges lamina lucida and lamina densa to plasma membrane.

Entactin and ***fibronectin*** (Glycoproteins that act as adhesive substance and has binding sites for collagen, GAGs and integrins.)

Proteoglycans (form bulk volume of lamina regulate passage of ions)

Reticular lamina consists of Type III collagen underlies basal lamina and anchor epithelium to CT.

Anchoring fibrils consisting of Type VII collagen extend from basal lamina matrix to connect the reticular fibers.

Function of the basement membrane

i. *Compartmentalization*: Separates CT from epithelia, nerve or muscle tissues.

ii. *Filtration*: Regulates movement of substances to and from CT (mainly by ionic charges).

iii. *Polarity induction*: Basal lamina attributes specific properties to basal membrane surface.

iv. *Tissue scaffolding*: Basal lamina serves as guide or scaffold during regeneration of epithelium.

Connective tissue cells

!

Resident cells (regularly present cells in connective tissue)
mesenchymal origin

mesenchymal cells (mesoblast)

fibroblast-fibrocyte-myofibroblast

reticular or adventitial cell

adipocytes

melanocytes (*neural crest***)**

Transient cells (migrate from the blood)
differentiate from hemopoetic stem cell

mast cell*

monocytes →macrophage*

lymphocytes → plasma cell*

(granulocytes neurotrophil, eosinophil, basophil)

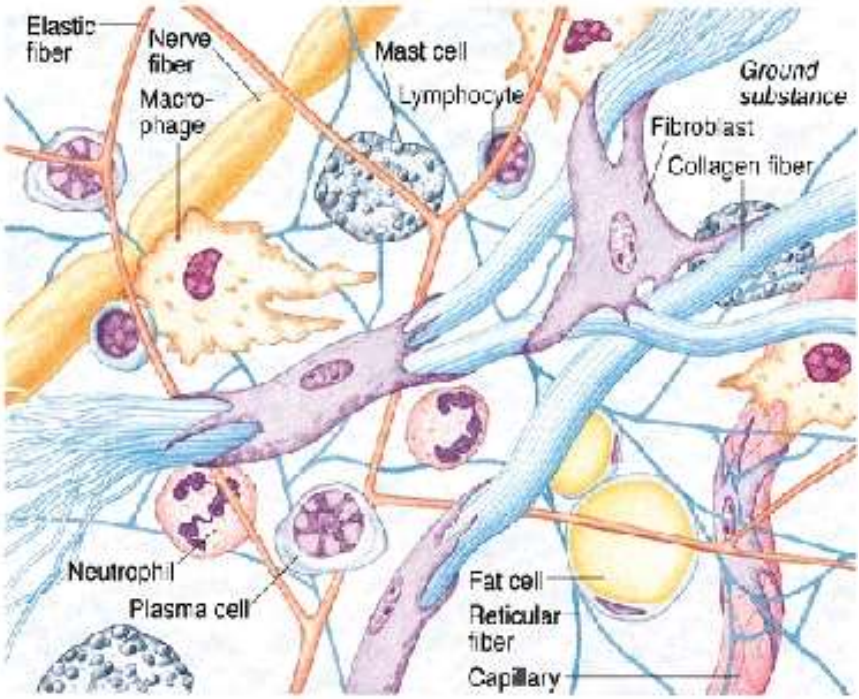

*** become resident cell**

Development of connective tissue

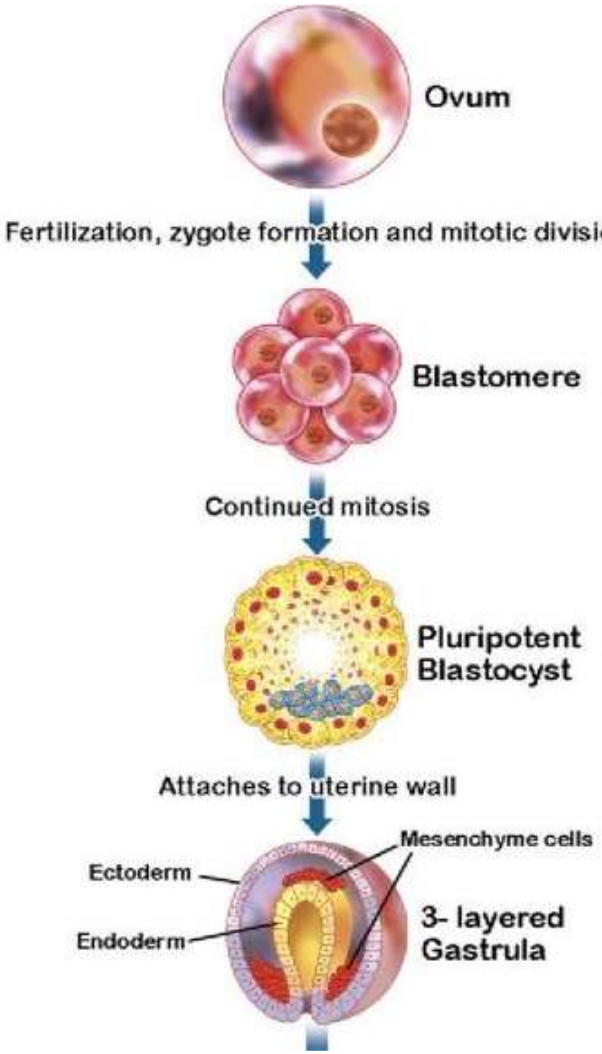

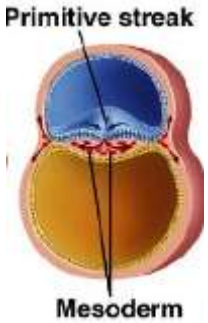

human and mammals

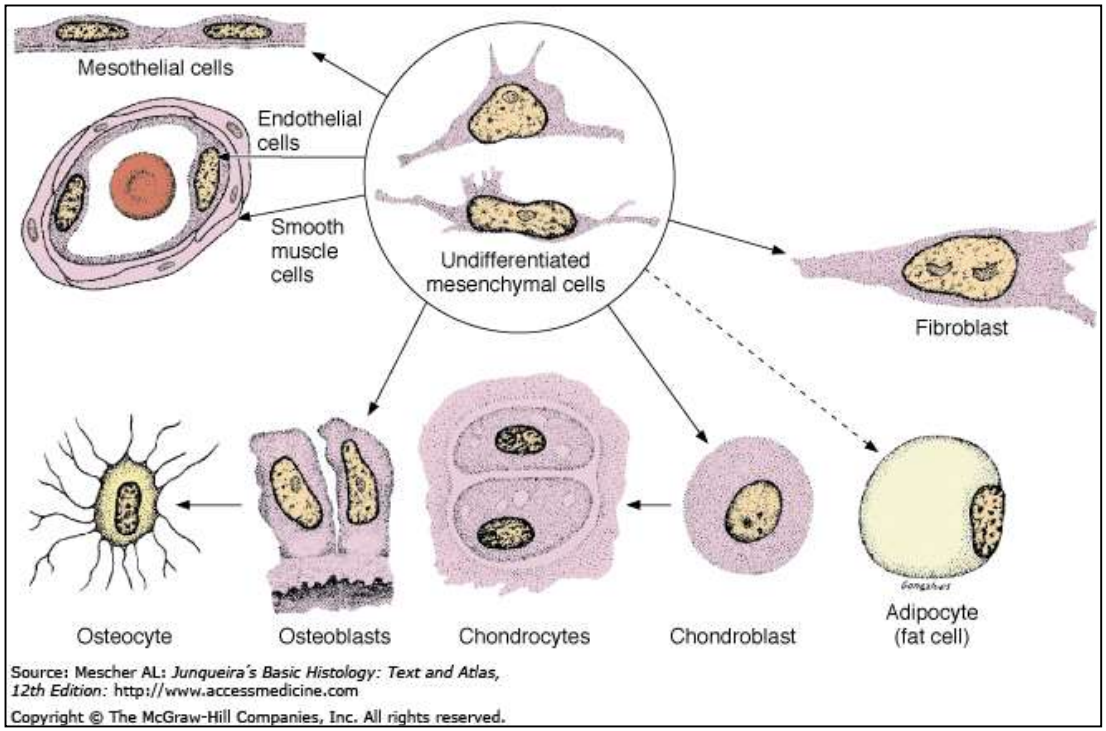

- **Connective tissue proper develops from MESENCHYME, the embryonic connective tissue.**
- **Specialized connective tissue also develops from MESENCHYME, except in the head where certain progenitor cells are derived from the ECTODERM.**

Stem cells

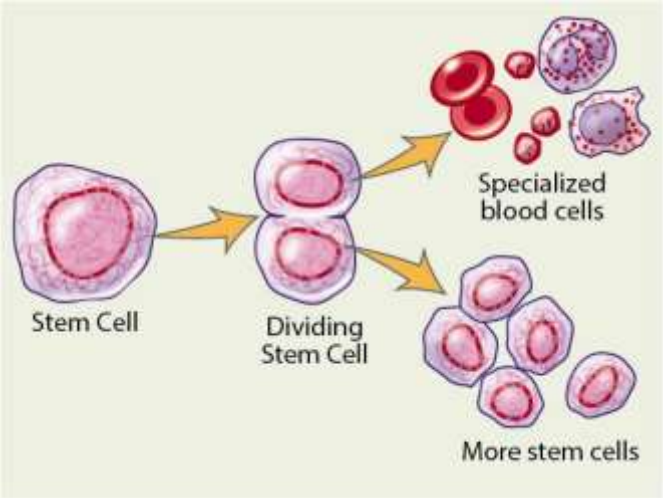

Asymmetric division

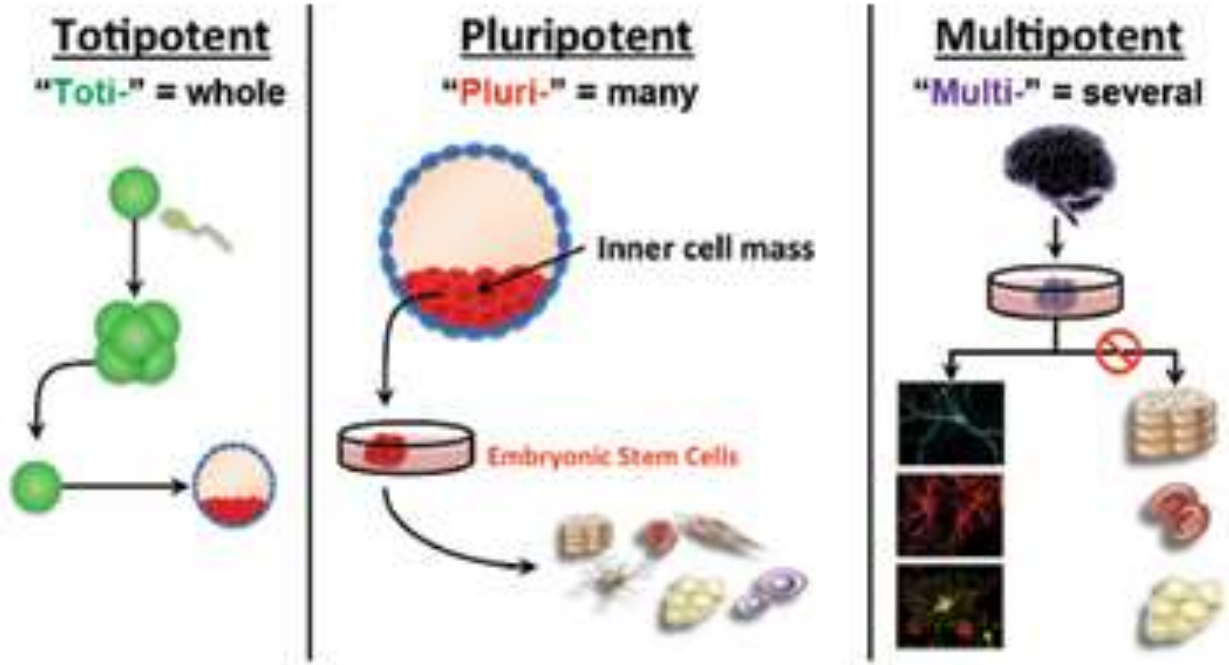

Mesenchymal cell (mesoblast)

!

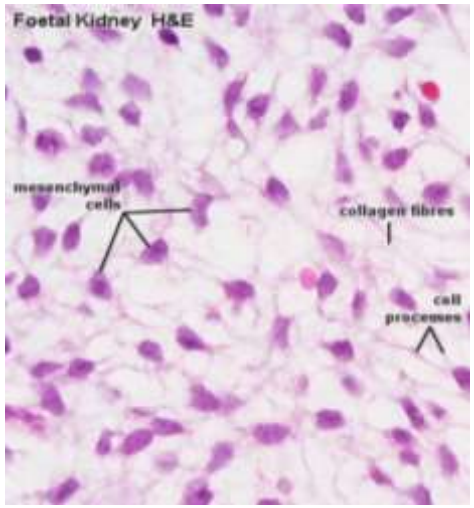

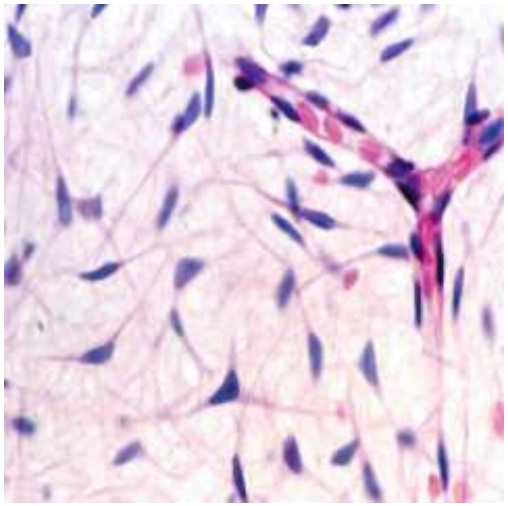

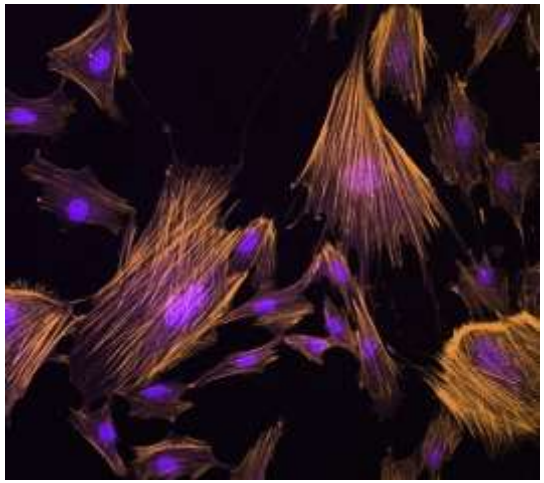

Pluripotent cells of the embryonic connective tissue. Shape: irregular, spindle or stellate shaped. Nucleus: round or oval. The processes are interconnected by gap juncrtions. Small number of mesenchymal cells are found also in adults. (Adult stem cells are found in the bone marrow, adipose tissue, dental pulp, endometrium.)

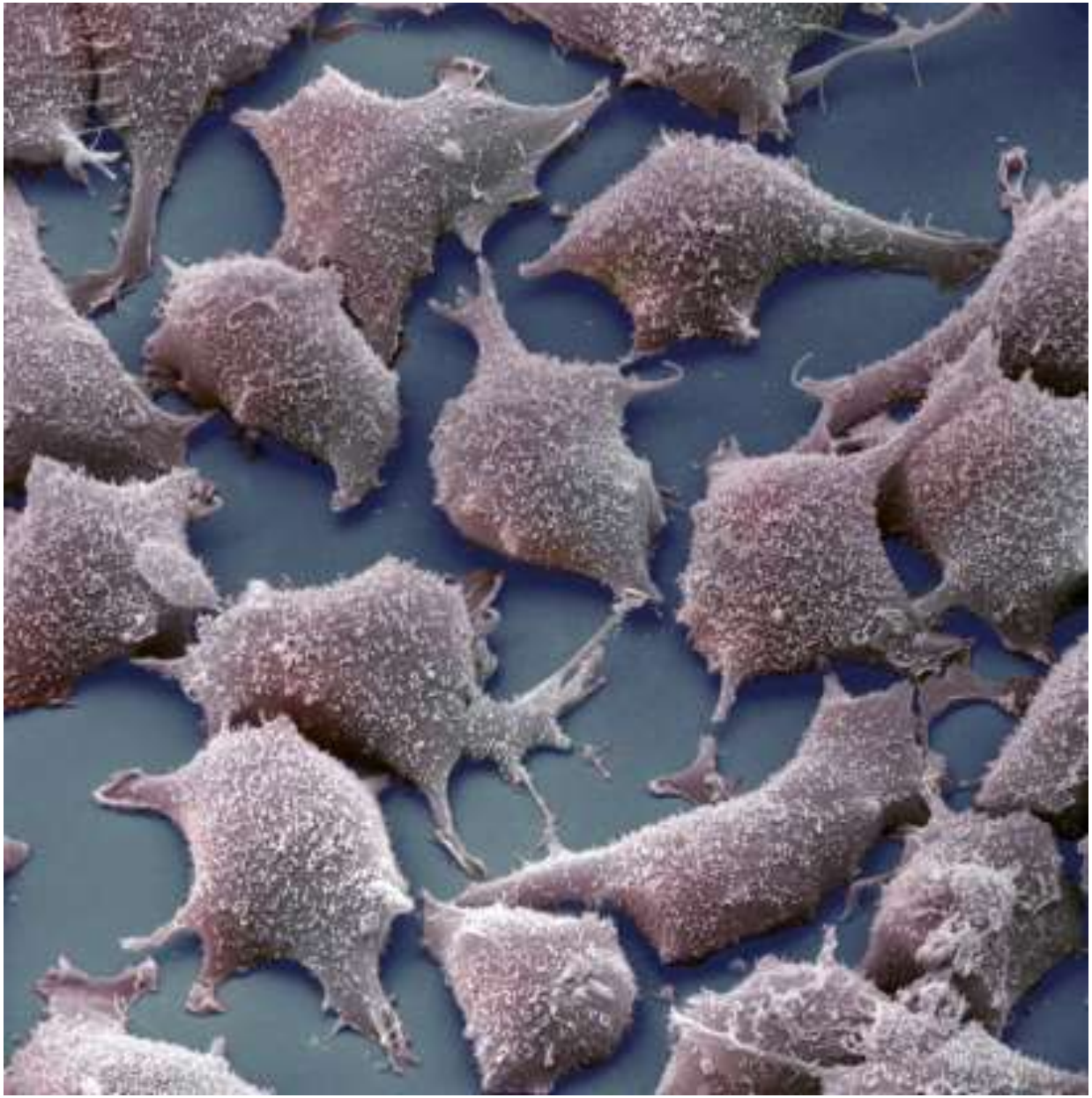

!

Fibroblast and fibrocyte

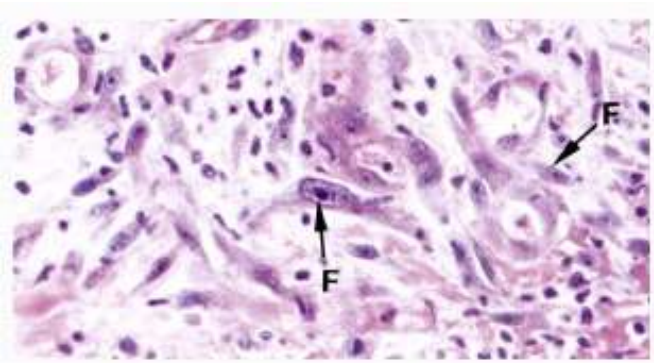

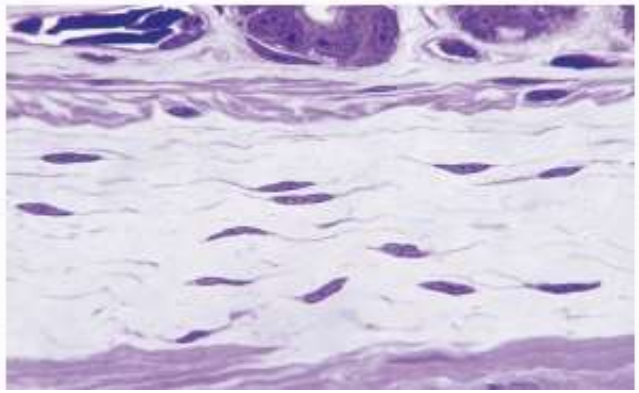

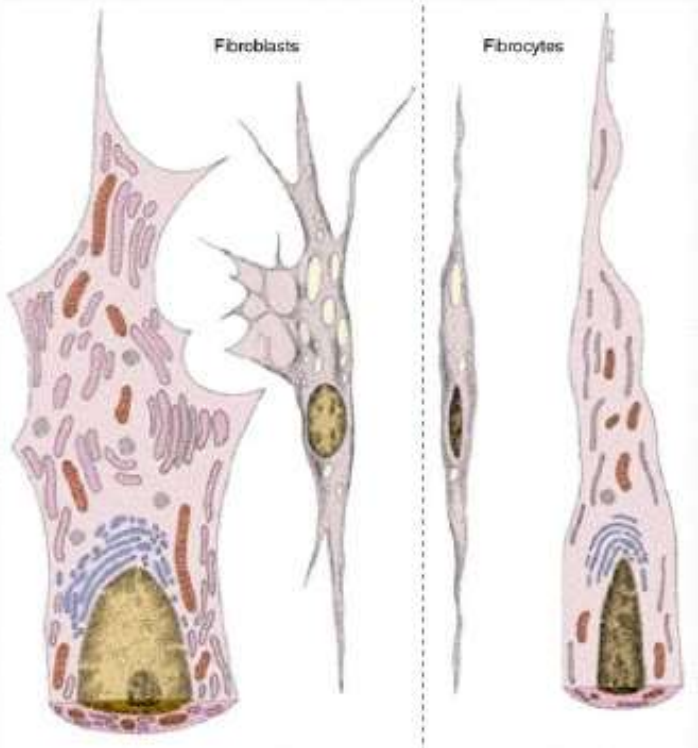

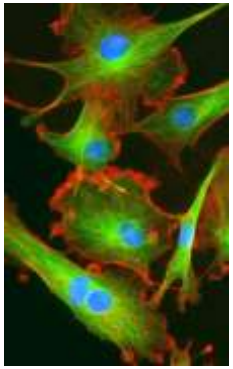

Fibroblasts (active cell): ECM production → high protein synthesis → free ribosomes, rER és Golgi apparatus → large, basophil cytoplasm. Round or oval nucleus with prominent nucleolus.

Fibrocyte (inactive form of fibroblast) is a 15-20 µm long, elongated cell that attached to the collagen fibres. It has thin eosinophil cytoplasm with dark basophilic nucleus.

Fibrocyte transformation into fibroblast !

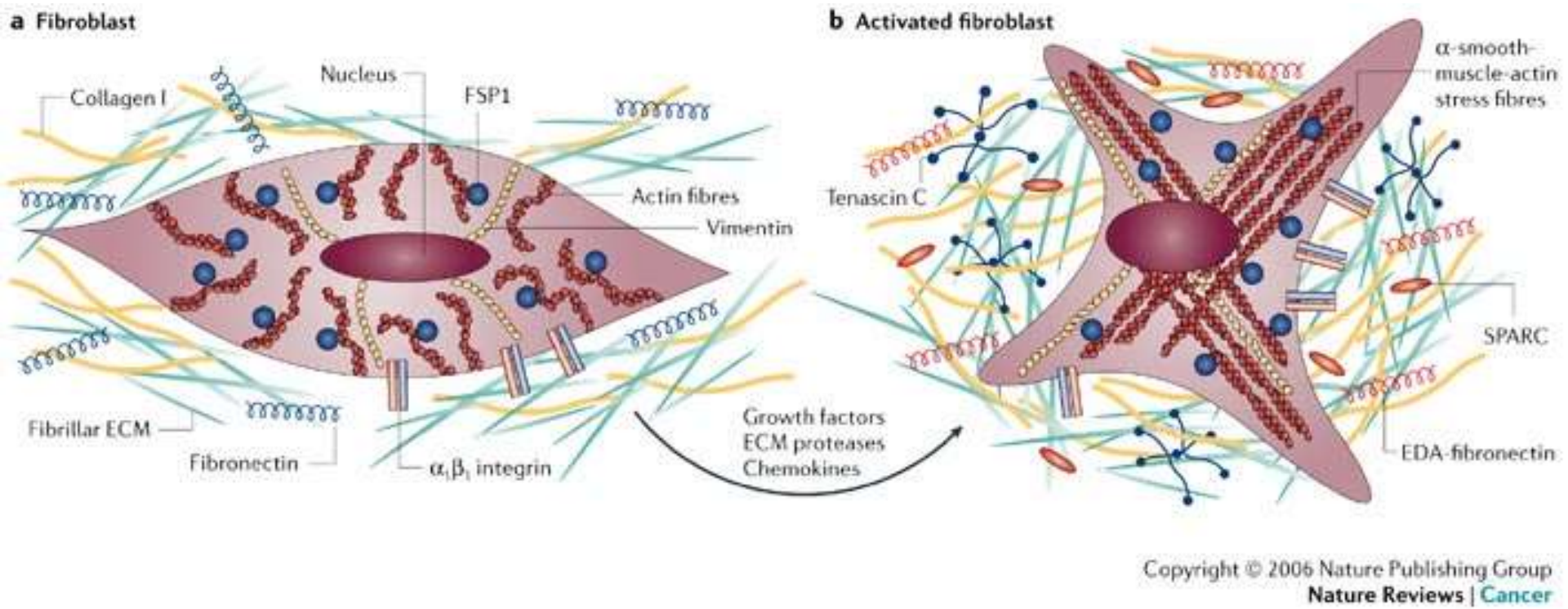

Damage → Cytokines (interleukins) produced by macrophage.
Platelet derived groth factors and cytokines.

→ **Fibrocyte transformes into fibroblast (division)**

Myofibroblast

!

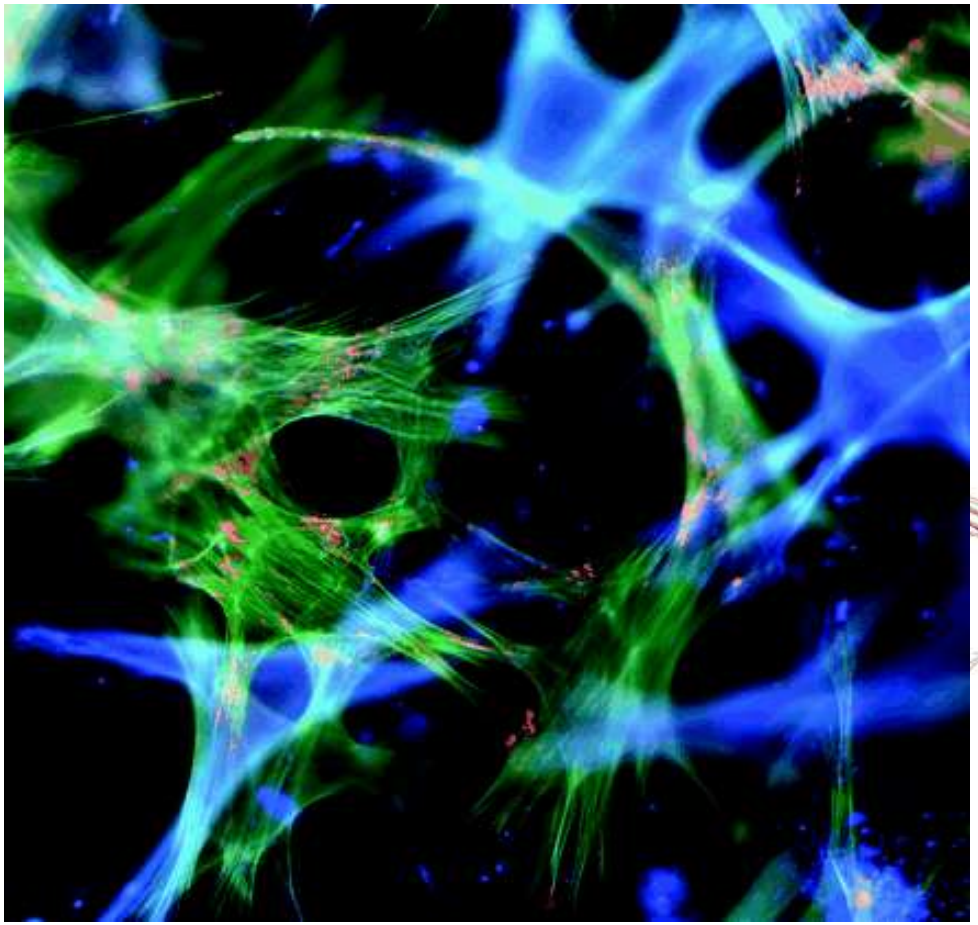

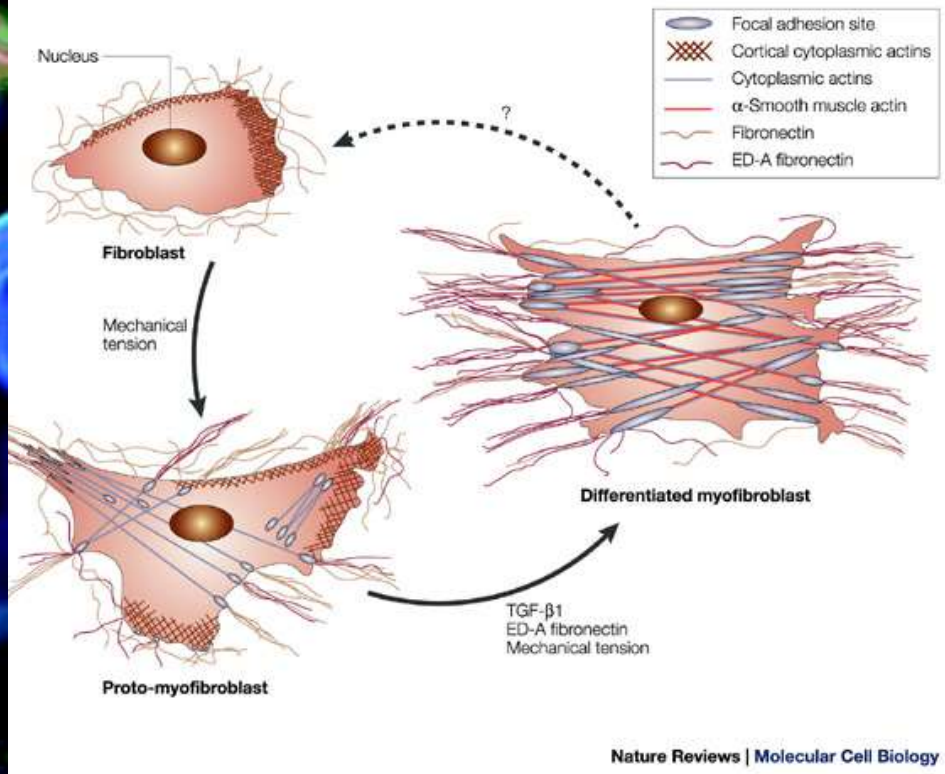

- **Displays properties of both fibroblast and smooth muscle cell**
- **Contains myofilaments (α-smooth muscle actin) characteristics for smooth muscle cell**
- **Contributes to tissue repair in wound healing**
- When contraction and ECM protein secretion become excessive → pathological condition (eg. fibrosis)

Reticular (adventitial) cell

!

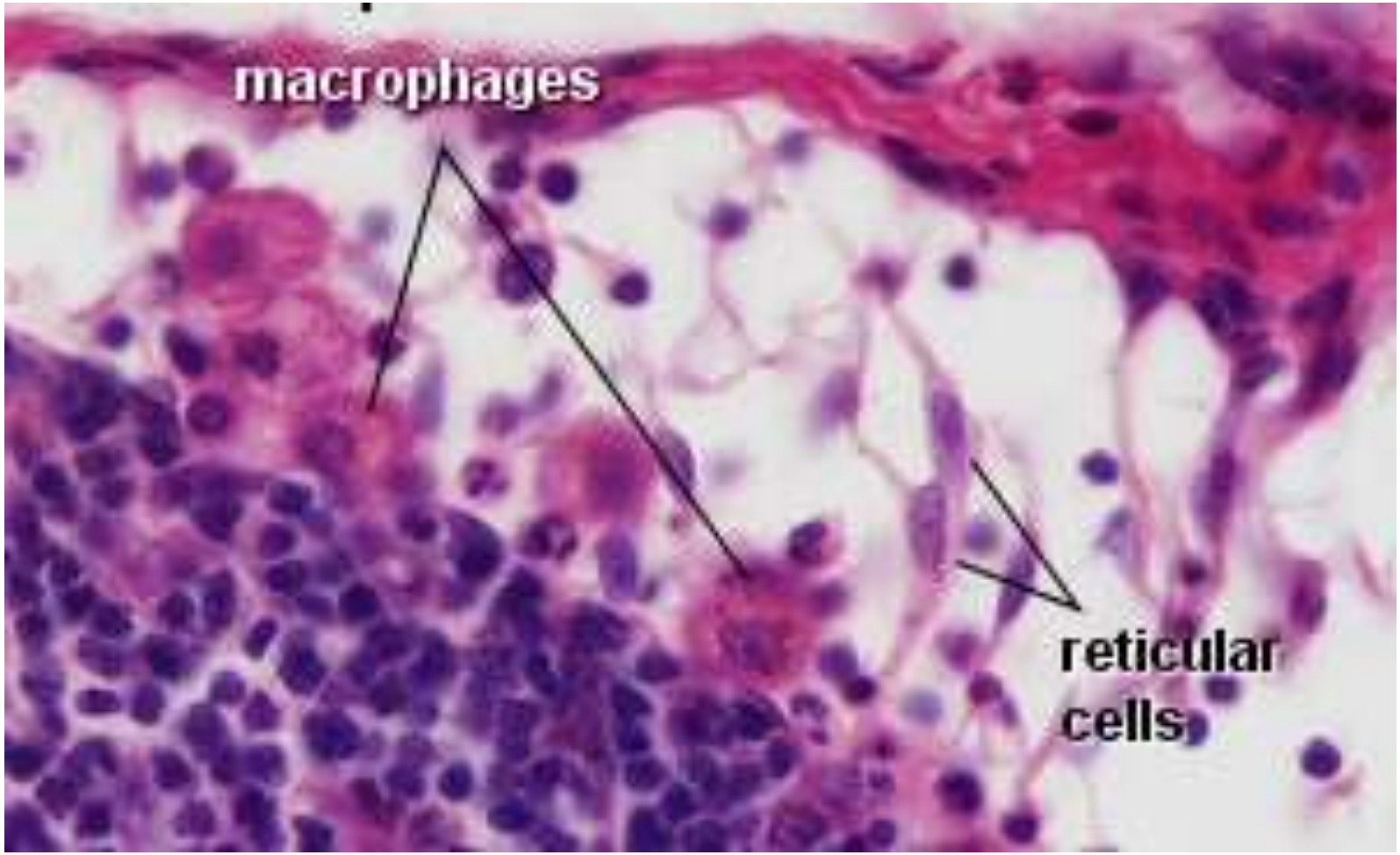

Specialized fibroblastic cell. Star shaped cell with ovoid nucleus. It produces reticular fibers and forms sheats around them. ECM is also produced by these cells. They are found in bone marrow, spleen, tonsills, lymph node etc.

Reticular cell network

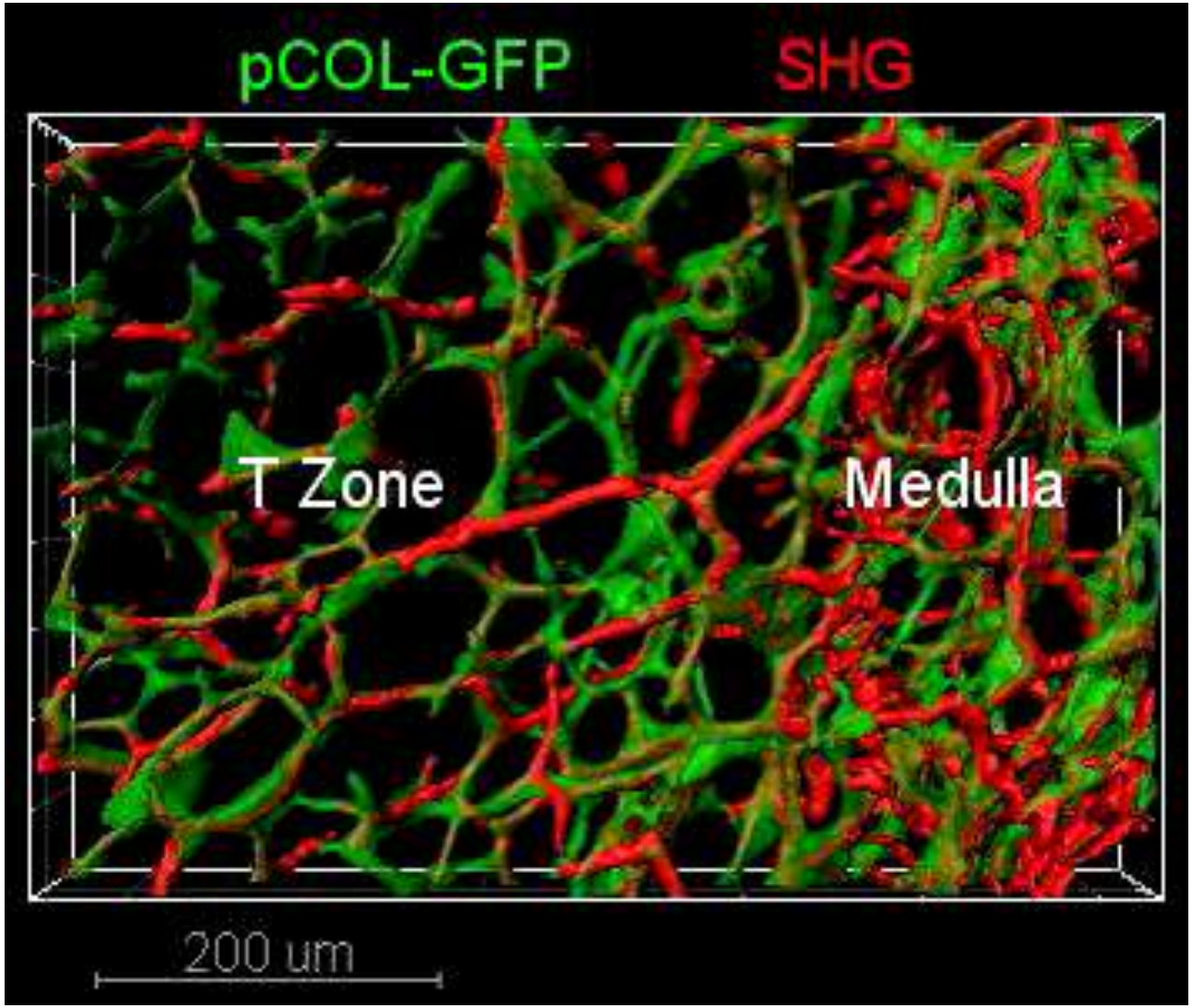

PNAS July 17, 2018 115 (29) E6826-E6835; first published July 2, 2018
https://doi.org/10.1073/pnas.1712628115

Adipocytes

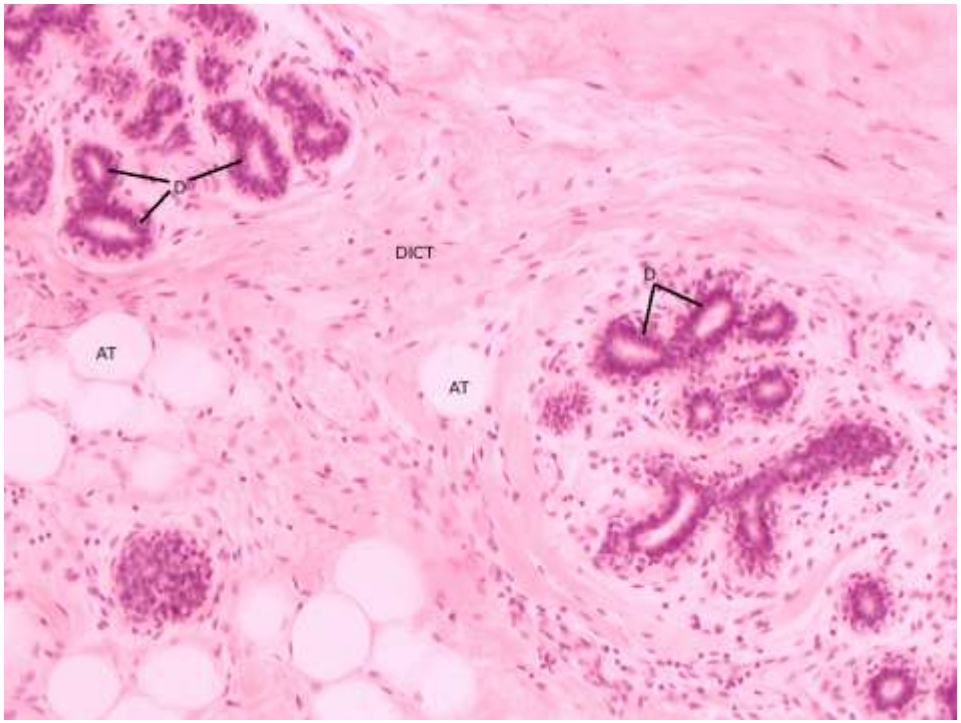

Leptin receptor deficient mice

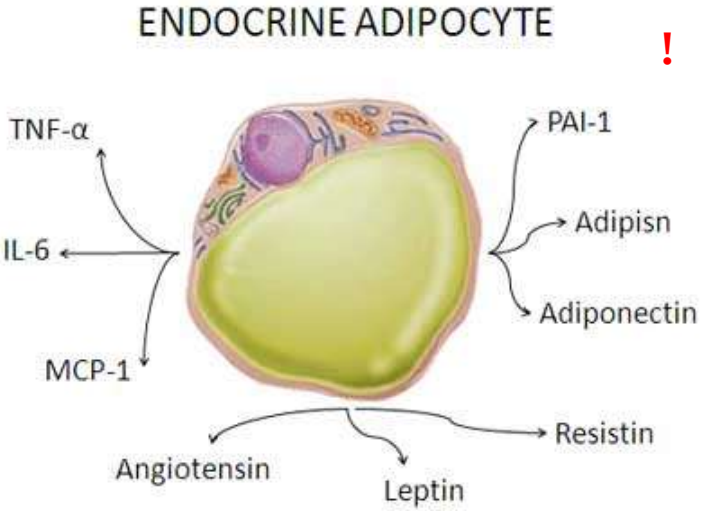

Maintain the homeostasis

- **Support and padding** (shock absorber in the soles and palms)
- **Long-term energy storage**
- **Secretion**

Morphology:
≈50-150 μm
unilocular (univacuolar, triglycerides stored in single locus)
A thin ring of cytoplasm surrounding the vacuole → **signet ring cell**

White and brown adipocytes

!

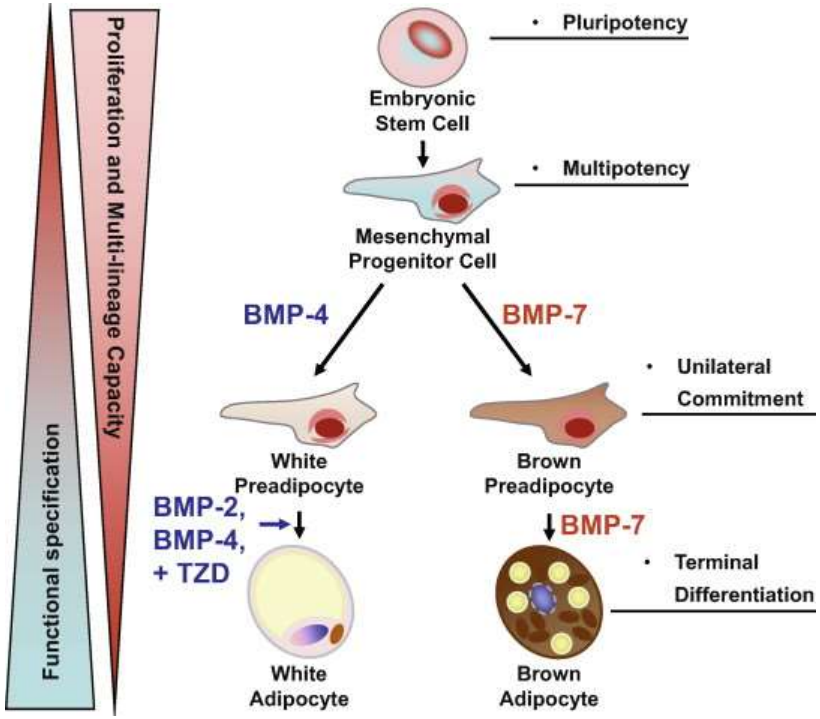

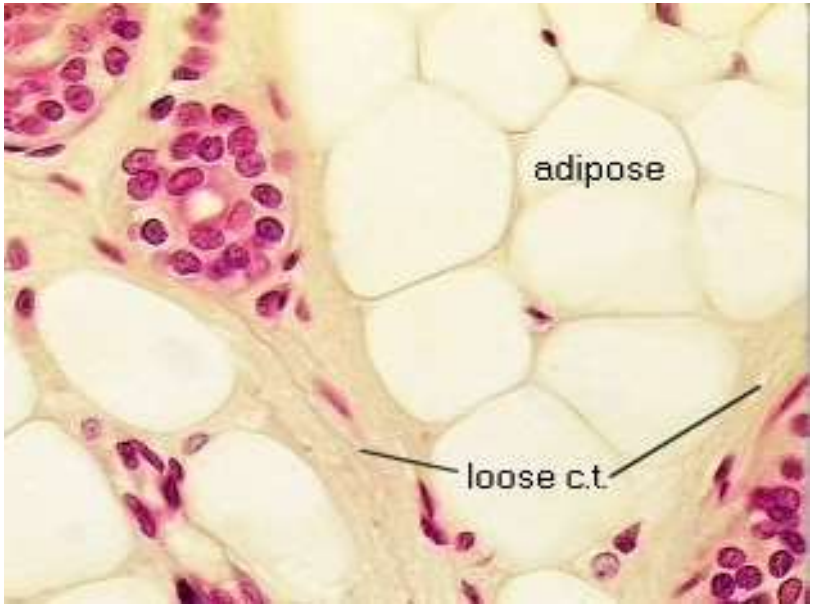

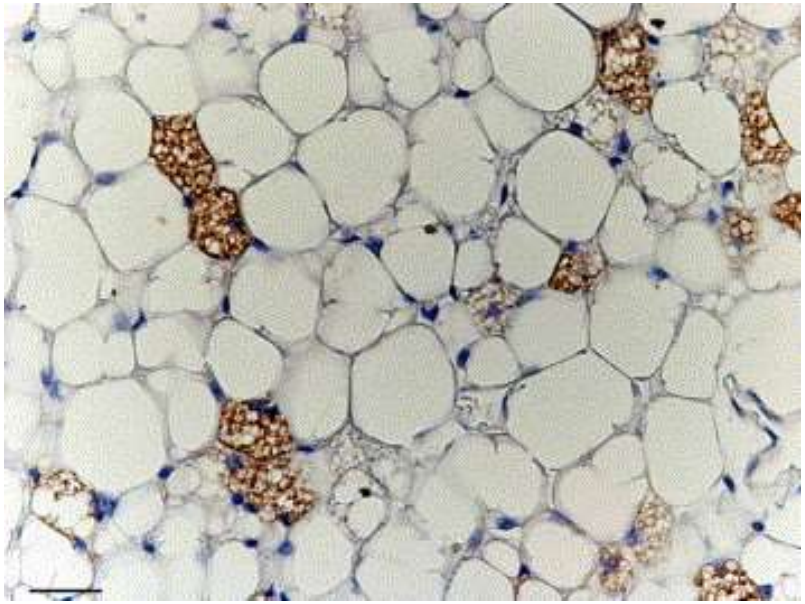

Brown adipoytes are poligonal, smaller than white adipocytes and **multilocular** (contains a great number of lipid droplets). The nucleus is central or eccentric. It has large number of mitochondria containing colored cytochromes (lipochrom)
Main function: **heat production**
During development the tissue disappears or replaced by white adipose tissue. (Remain: interscapular space, kidney, thymus).

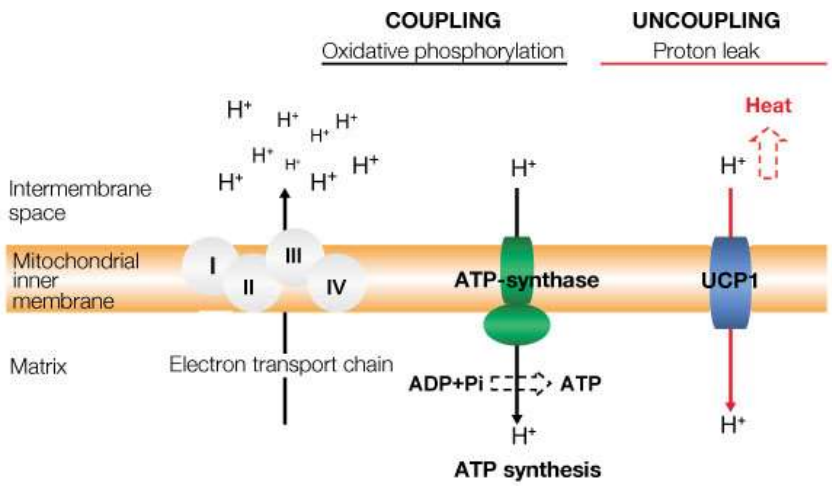

Figure 1. UCP1 location and function in the mitochondrial respiratory chain (MRC). Numbers I-IV corresponds to the MRC complexes. ATP-synthase is the fifth complex of the MRC. During respiration, protons are pumped through the MRC complexes, and a proton gradient is generated. The energy of the proton gradient drives the synthesis of ATP by the ATP-synthase complex. UCP1 catalyzes a regulated re-entry of protons into the matrix, uncoupling the MRC and, consequently, reducing ATP synthesis and generating heat.



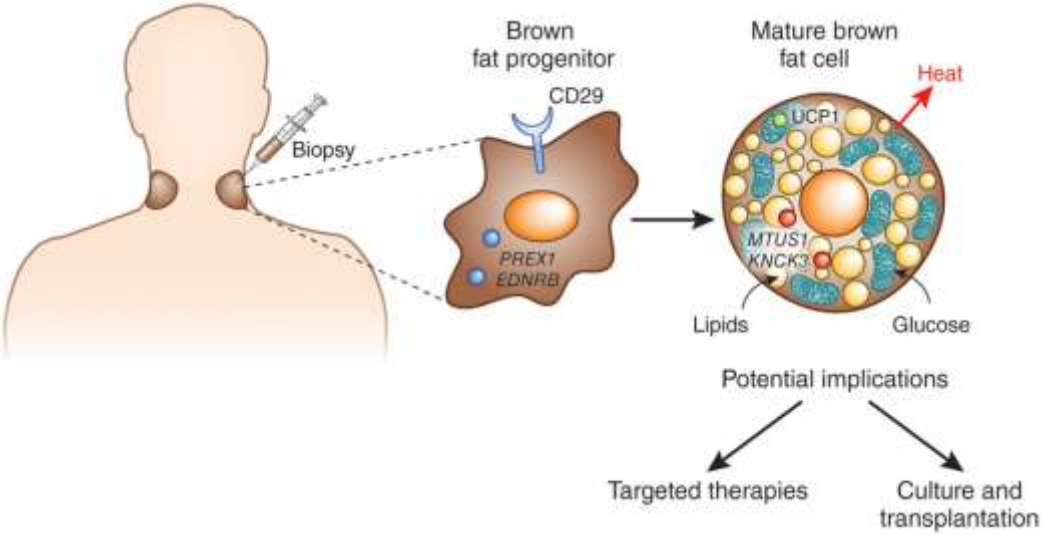

Transgenic mice (shown left, marked TG) with overexpressed levels of the Zfp516 protein gained less weight than their unaltered, wild type (WT) counterparts after both groups were fed a high-fat diet for a month. (Photo by Jon Dempersmier)

Mariëtte R Boon, Emmani B M Nascimento & Wouter D van Marken Lichtenbelt (Nature Medicine 21, 667–668 (2015)

White, *beige* and brown adipose tissue

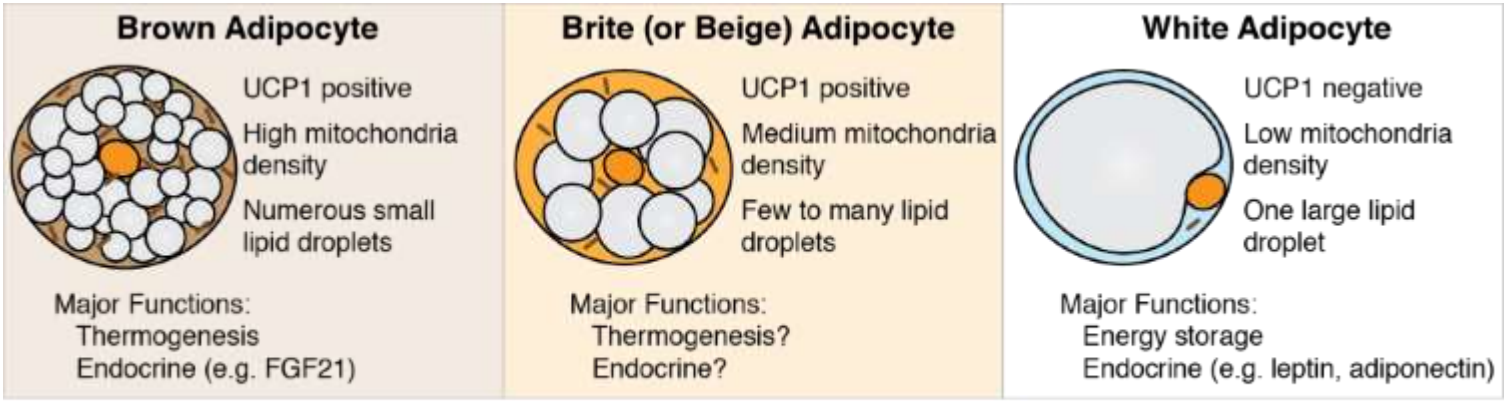

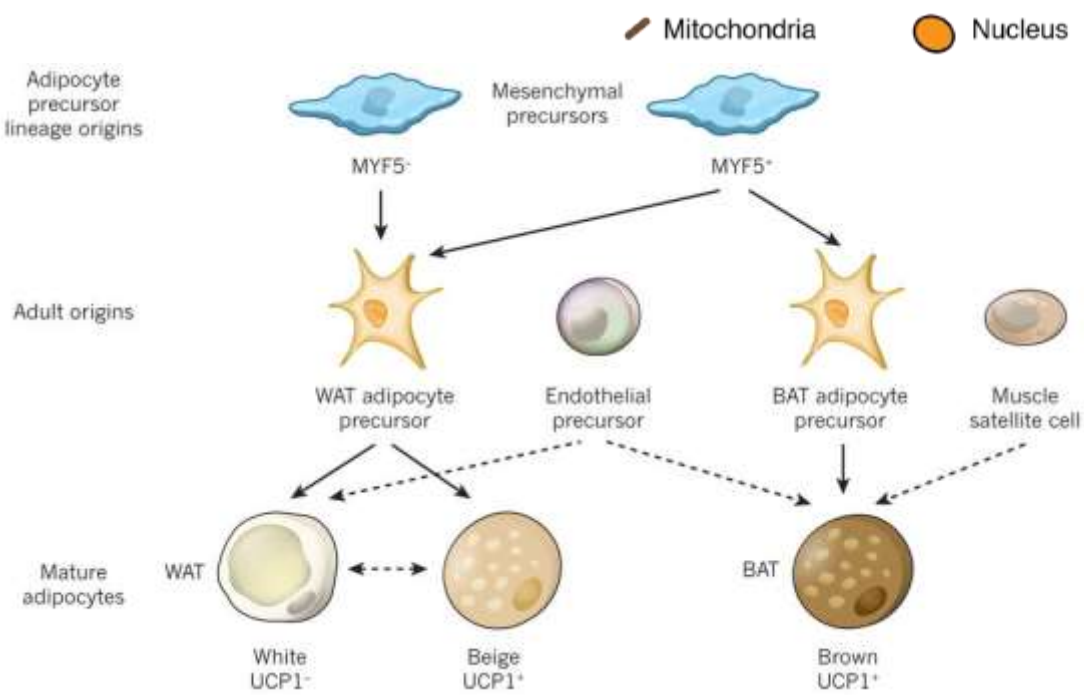

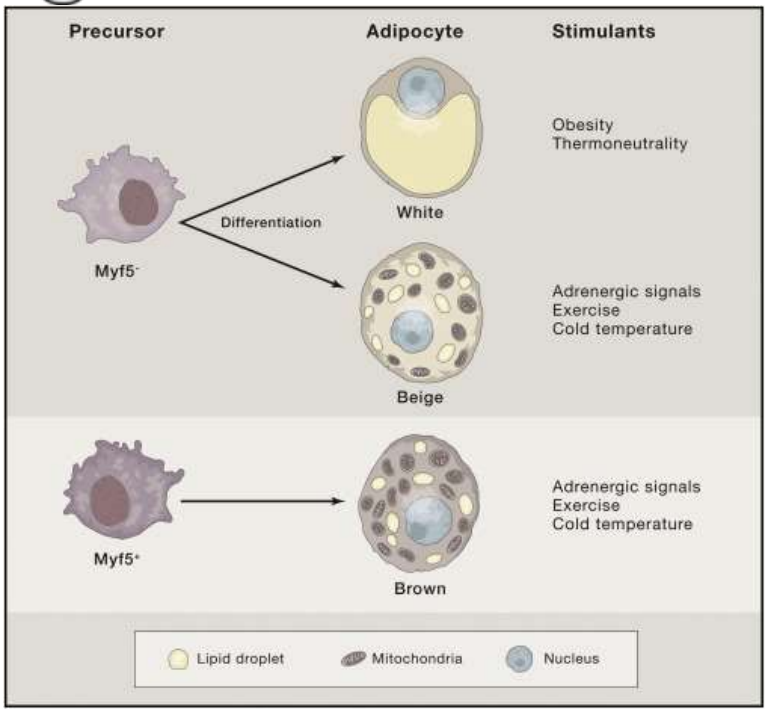

Fat soluble dyes

Oil red

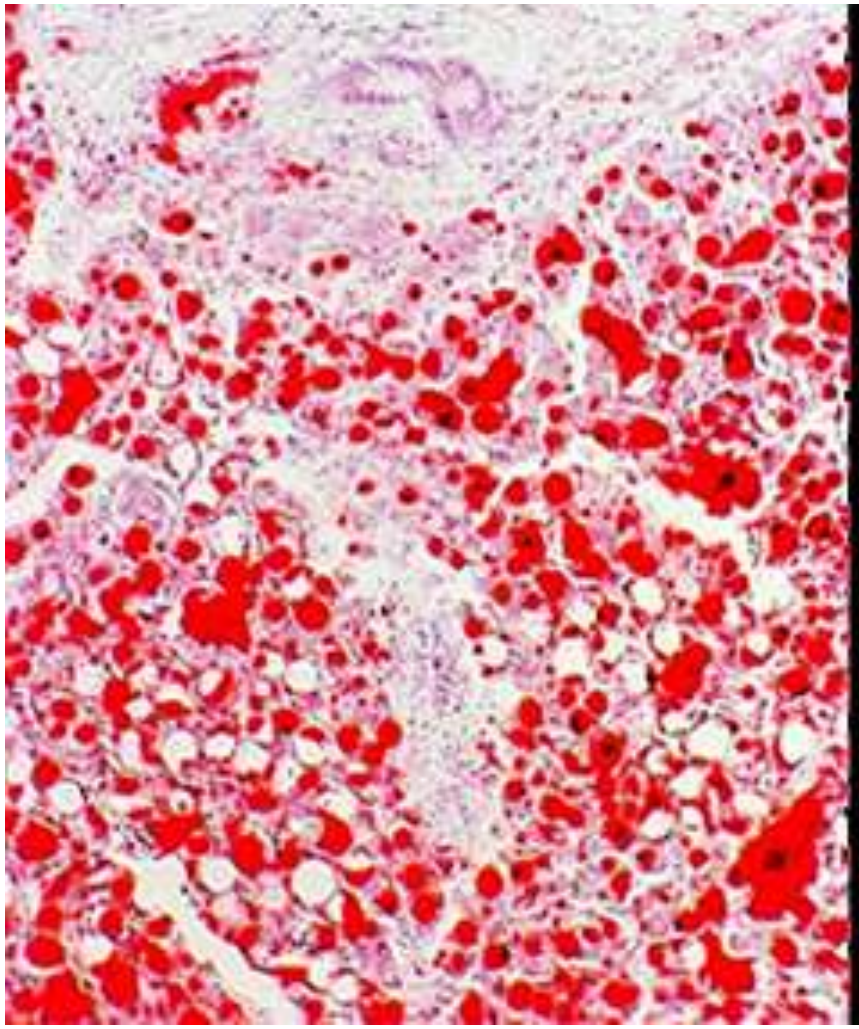

Sudan black

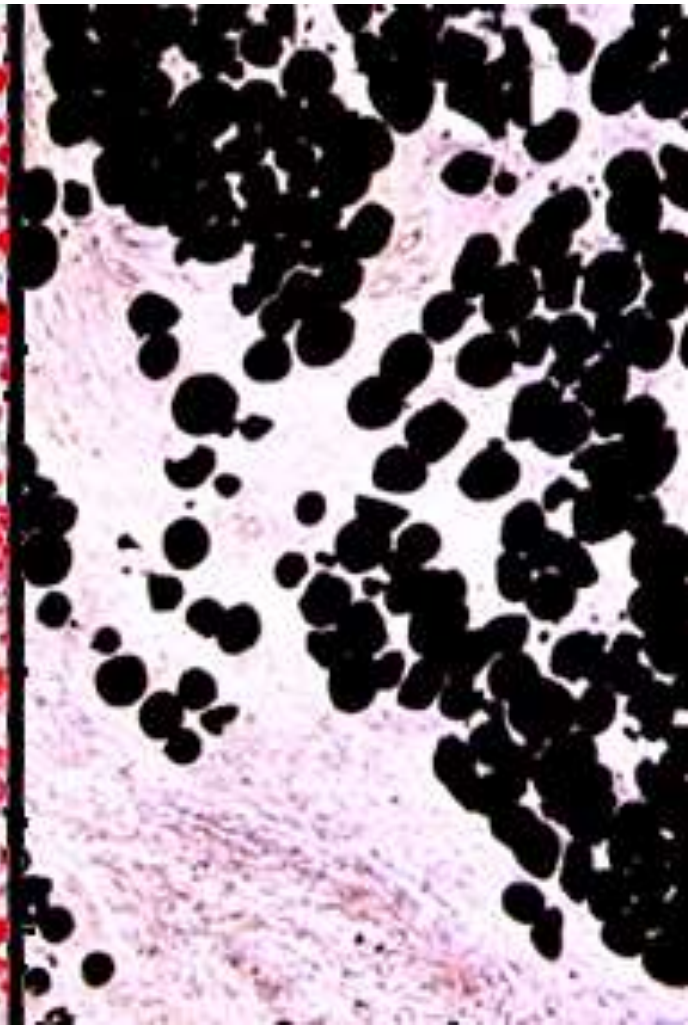

Melanocyte

!

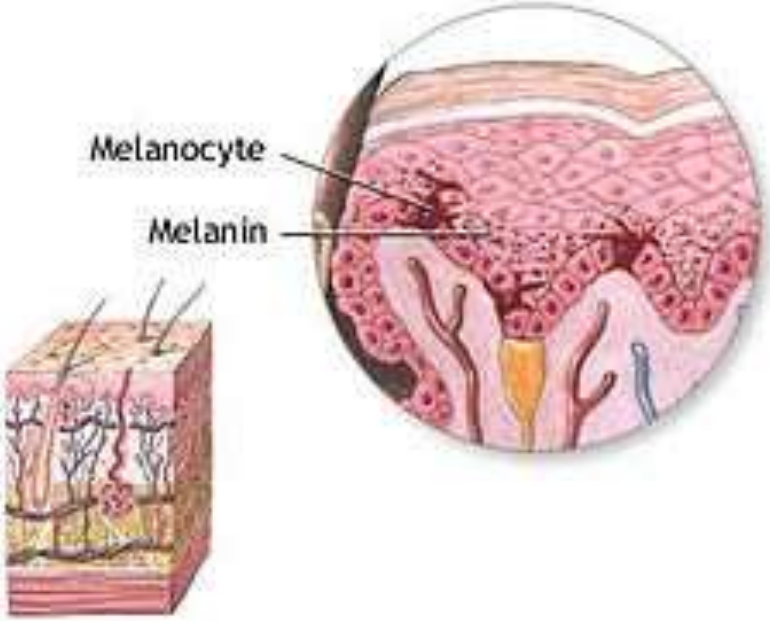

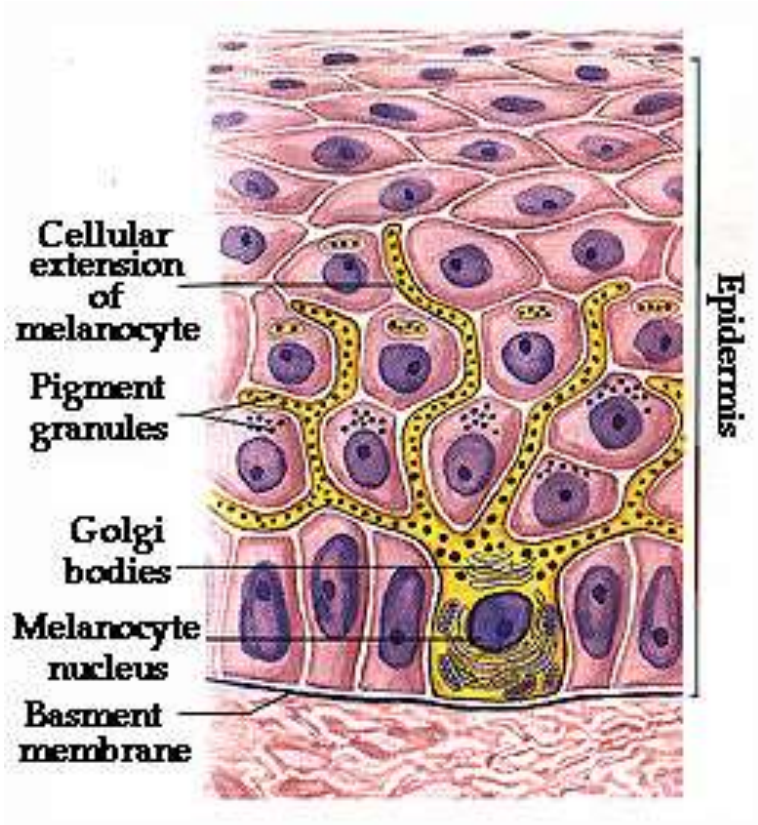

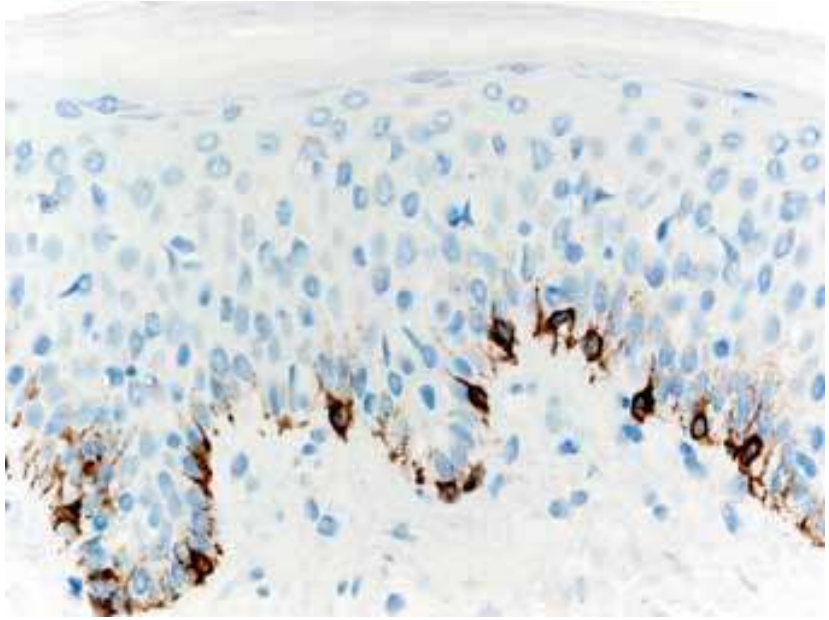

Melanocytes are neural crest origin → migrate into the stratum basale layer of the skin. It has rounded cell body with long dendritic proccesses containing melanin and carotene. In connective tissue of iris, cornea is also found.

UV radiation→ melanin production → cytokin secretion → DNA protection

Melanoma

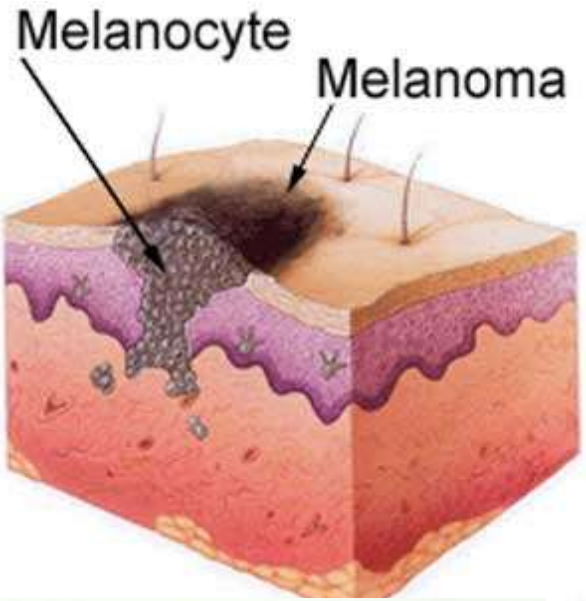

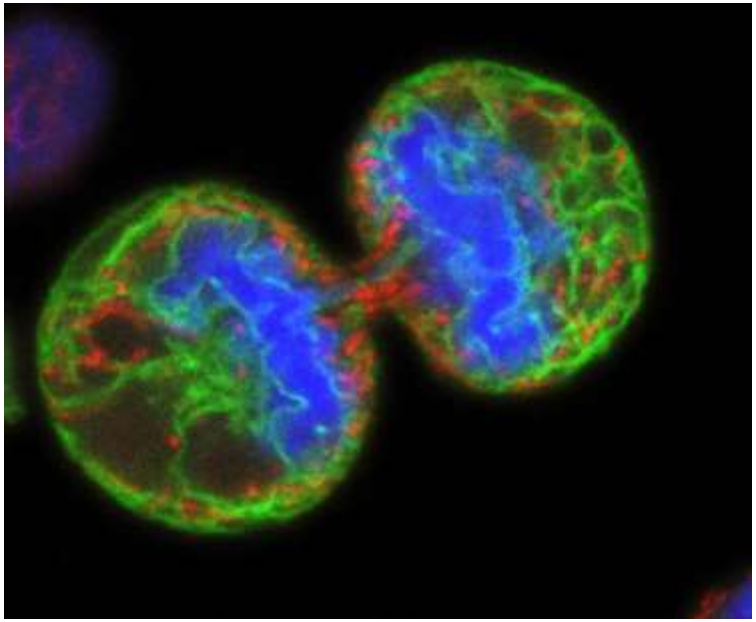

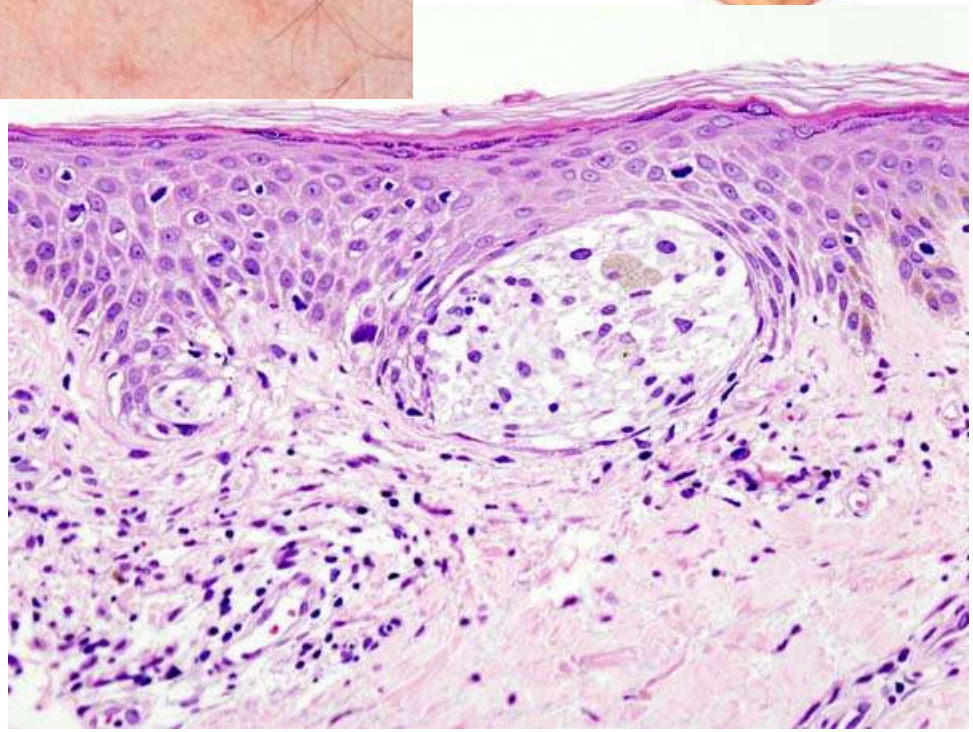

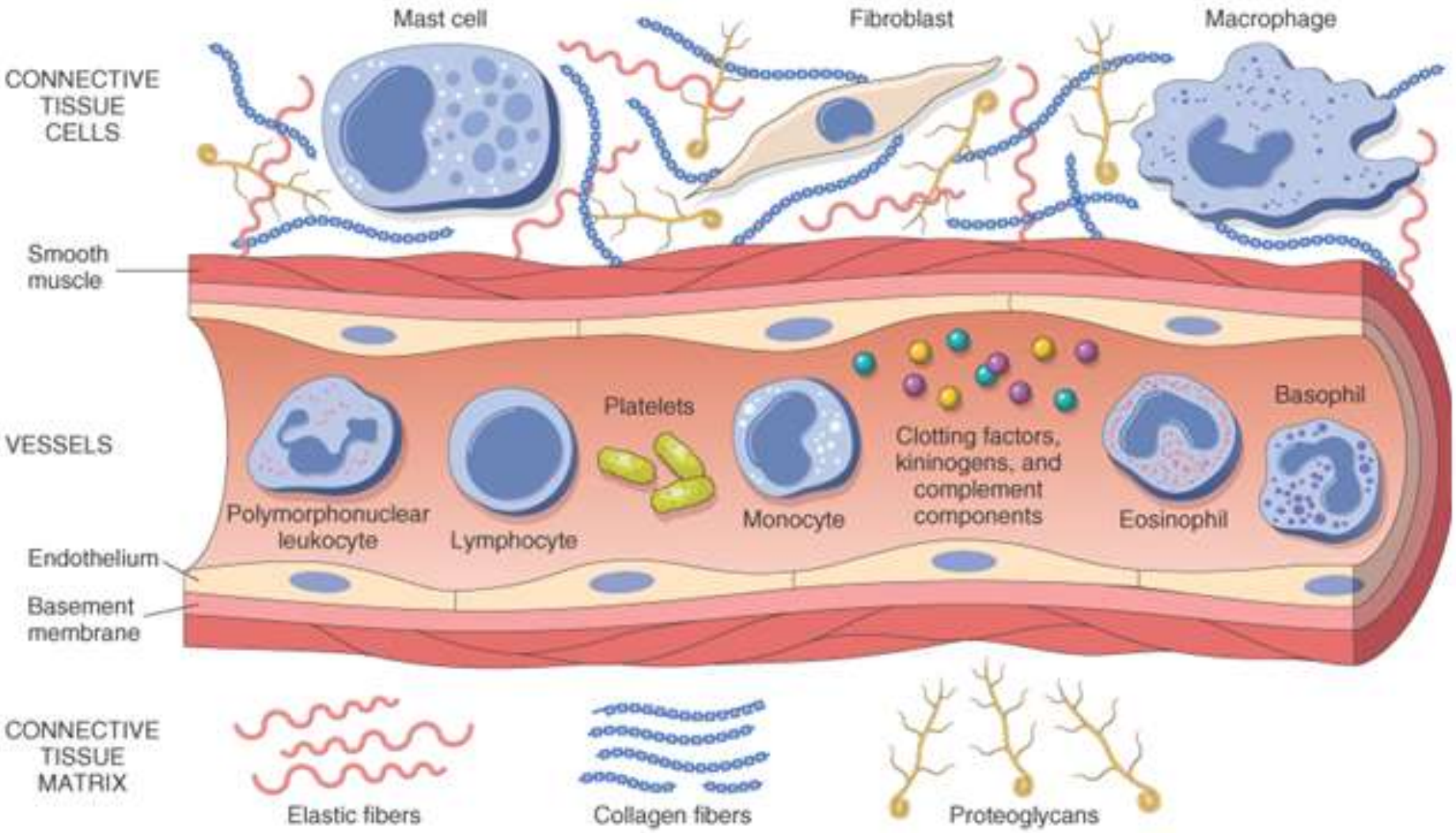
CONNECTIVE TISSUE CELLS
Mast cell
Fibroblast
Macrophage
Smooth muscle
VESSELS
Polymorphonuclear leukocyte
Lymphocyte
Platelets
Monocyte
Clotting factors, kininogens, and complement components
Eosinophil
Basophil
Endothelium
Basement membrane
CONNECTIVE TISSUE MATRIX
Elastic fibers
Collagen fibers
Proteoglycans

!

Monocytes

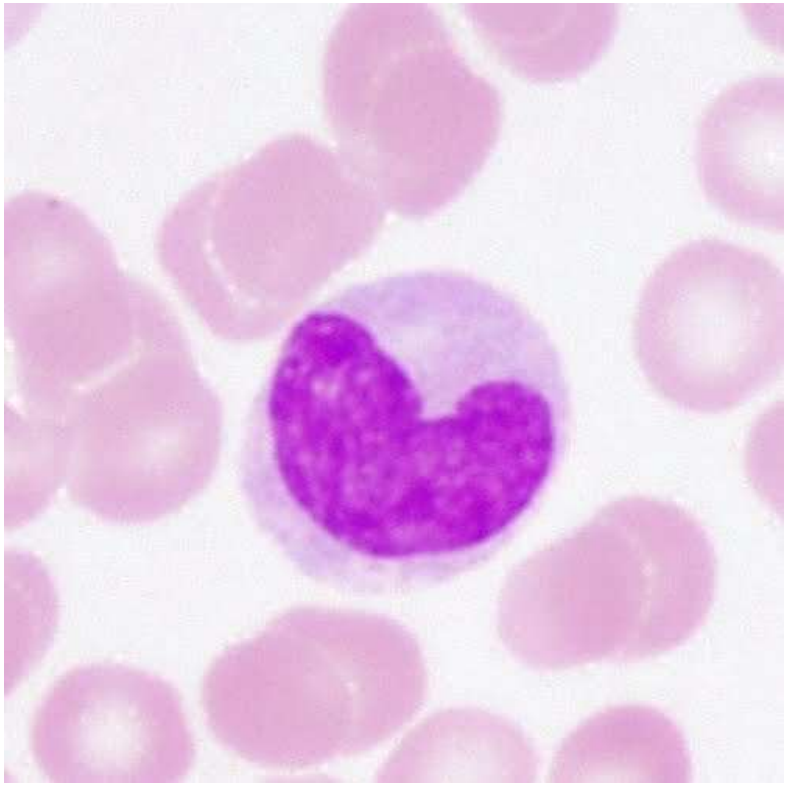

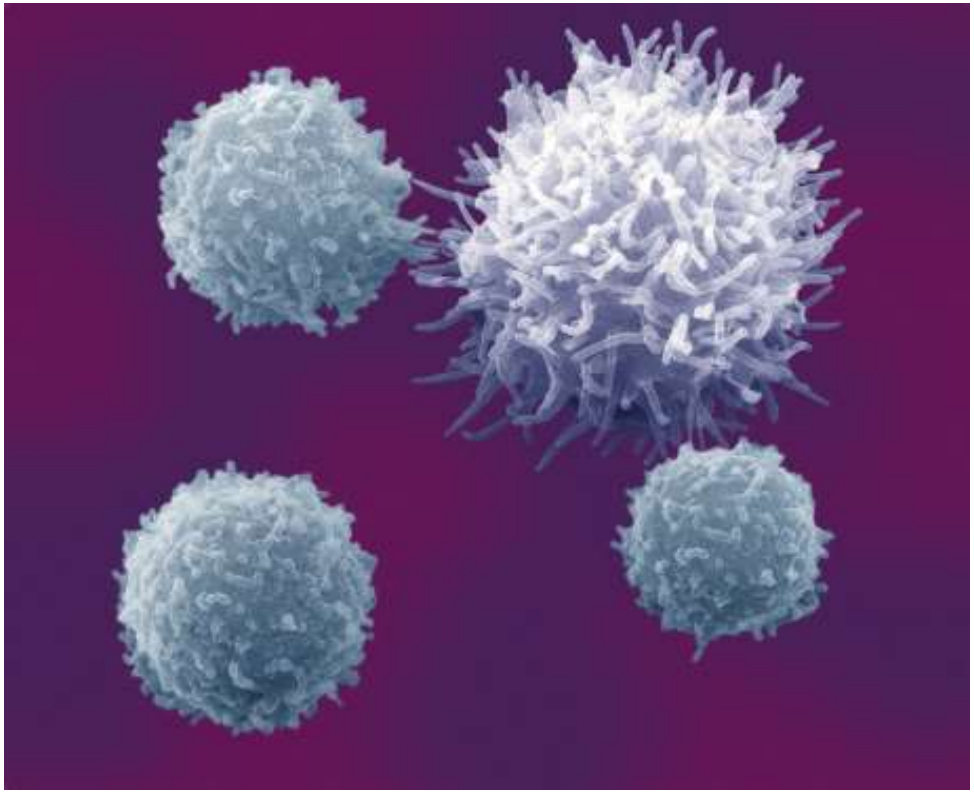

4-6% of the white blood cells

The largest of the white blood cells 15-20 µm

Eccentric indented nucleus (1-2 nucleoli)

Slightly basophilic cytoplasm with dense granules (lysosomes)

!

Functions of monocytes

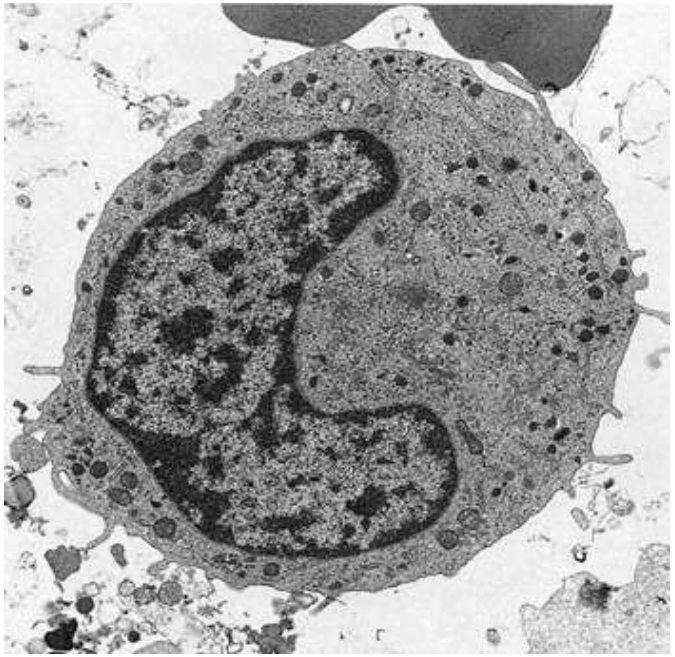

Monocytes

- **are precursor cells of the mononuclear phagocyte system (MPS)**
- **leave the blood vessel → transform into a tissue macrophage → participate in the phagocytosis of bacteria and other tissue debris, present antigens to lymphocytes**

Tissue macrophages:

alveolar macrophage (lung), Kupffer cells (liver), Langerhans cells (skin), microglia (CNS), osteoclast (bone), chondroclast (cartilage), Hofbauer cell (placenta)

Nobel Prize



Ilya Ilyich Mechnikov

Paul Ehrlich

The Nobel Prize in Physiology or Medicine 1908

"in recognition of their work on immunity„

Phagocytosis

Connective tissue macrophage (histiocyte)

!

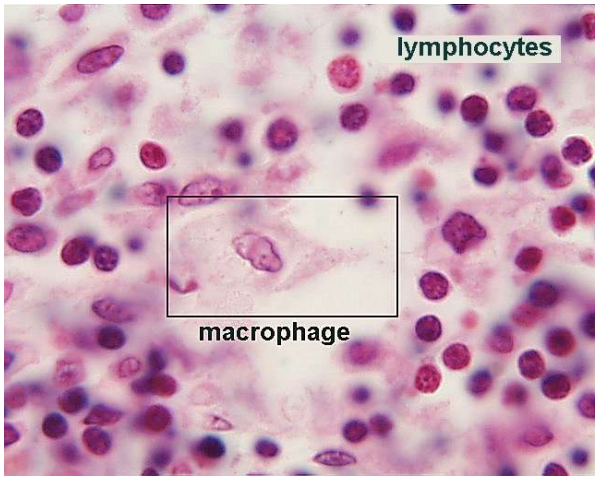

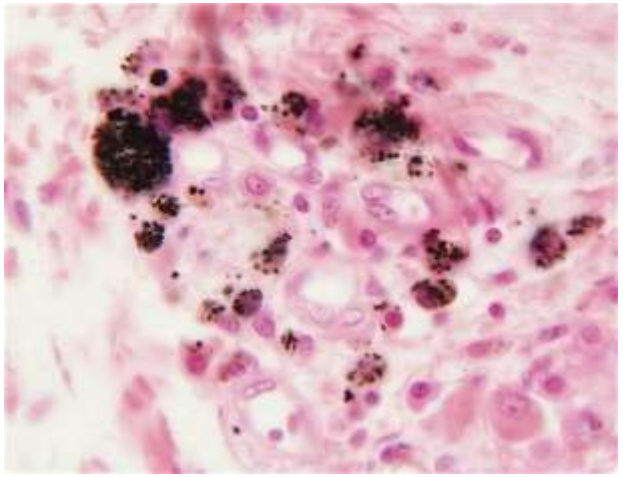

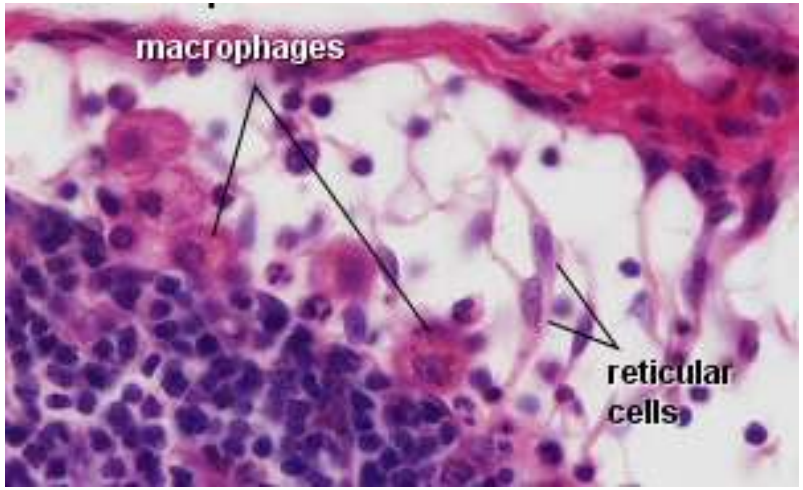

Elongated irregular shape – amoeboid wandering nature. Difficult to recognize in routine preparations - lack distinguishing characteristics. Active macrophage more visible by the indigestible residues (vital dyes)

Connective tissue macrophage (histiocyte)

!

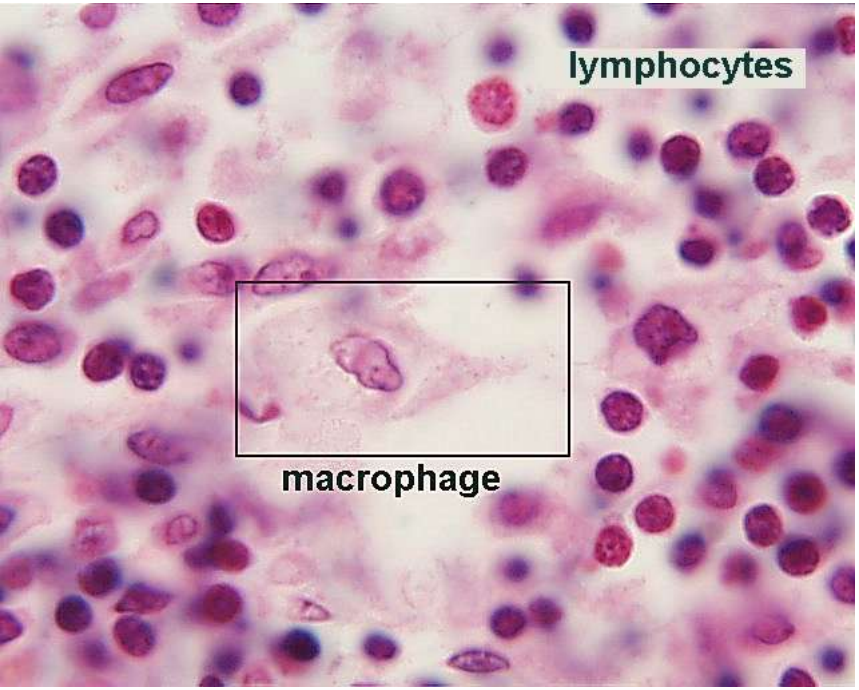

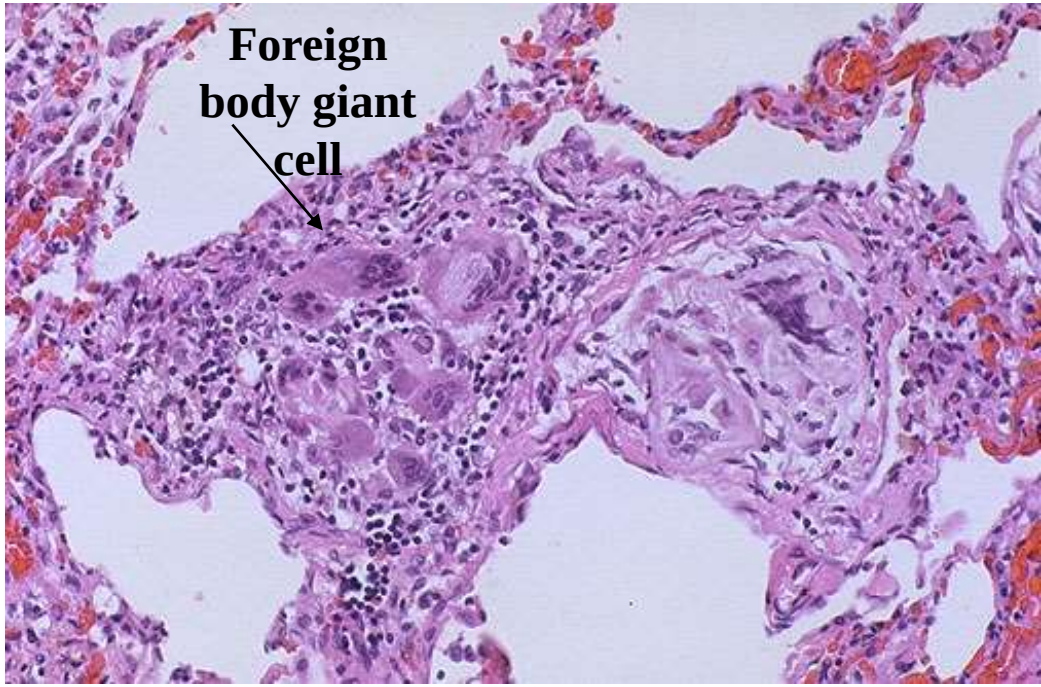

Large ovoid or irregular shaped cell with kidney or irregular shaped nucleus. It has several cytoplasmic extensions. It contains lysosomes, phagosomes and phagocytosed cell fragments, molecules. They can fuse and form giant cells around foreign bodies. (Tingible body macrophage)

!

Functions of macrophage

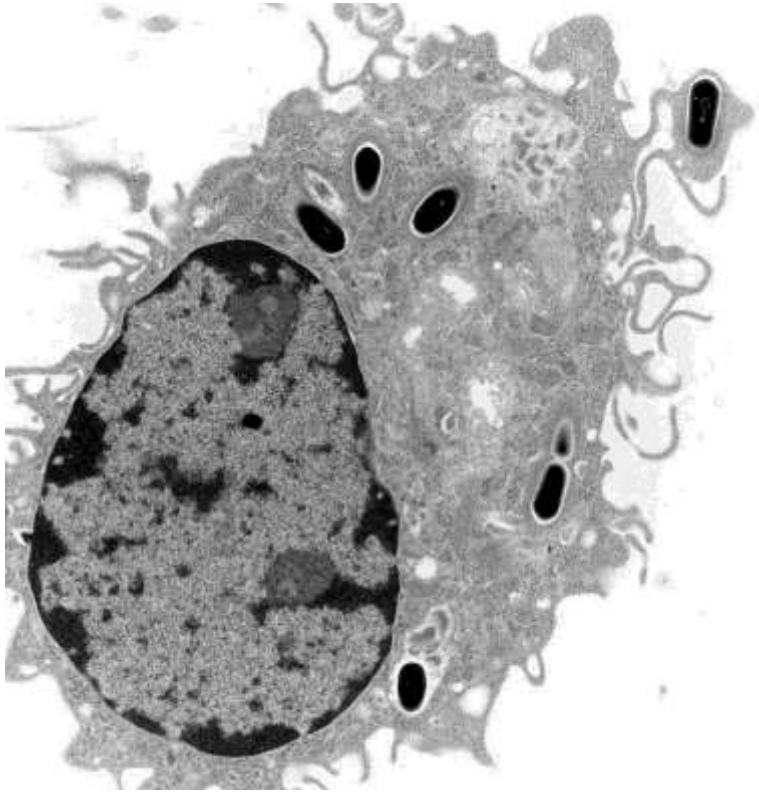

=

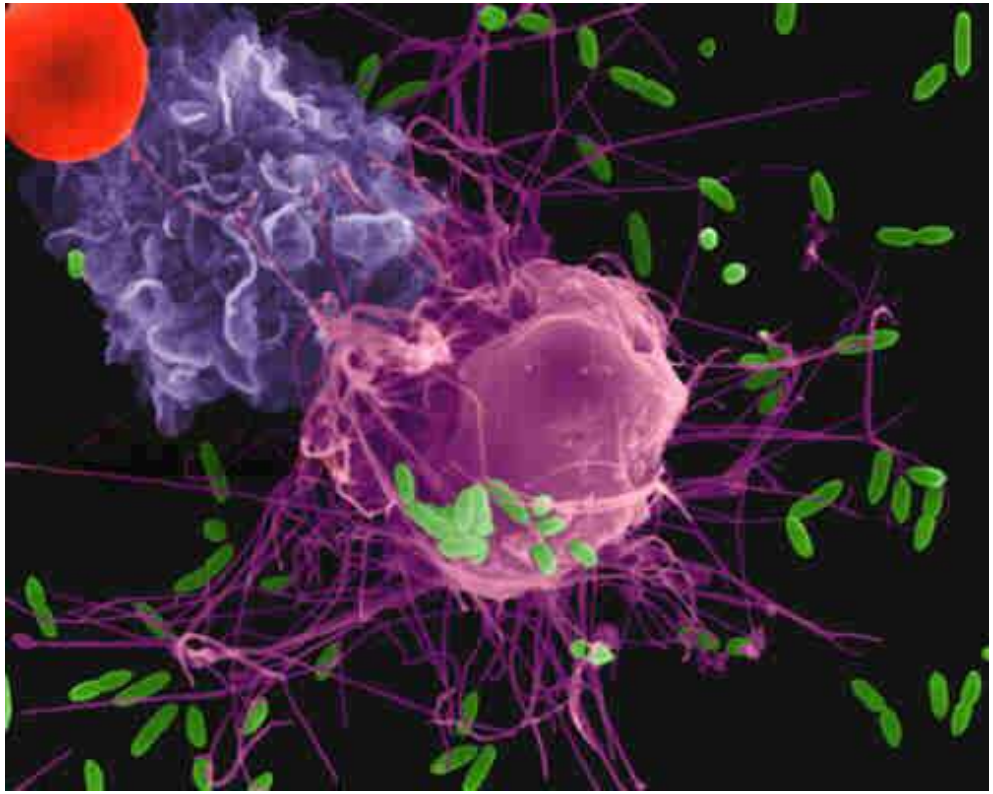

phagocytosis **as a defense activity (bacteria)**

as a clean up operation cell debris

antigen presentation

secretion (cytokines)

Functions of macrophages



1. Phagocytosis

2. Antigénpresentation: display of fragmented antigens on its surface

3. Secretion:

cytokines, growth factors, colonystimulating factors →stimulation of the immune system, hematopoiesis, activation and stimulation of connective tissue cells

Mast cell

!

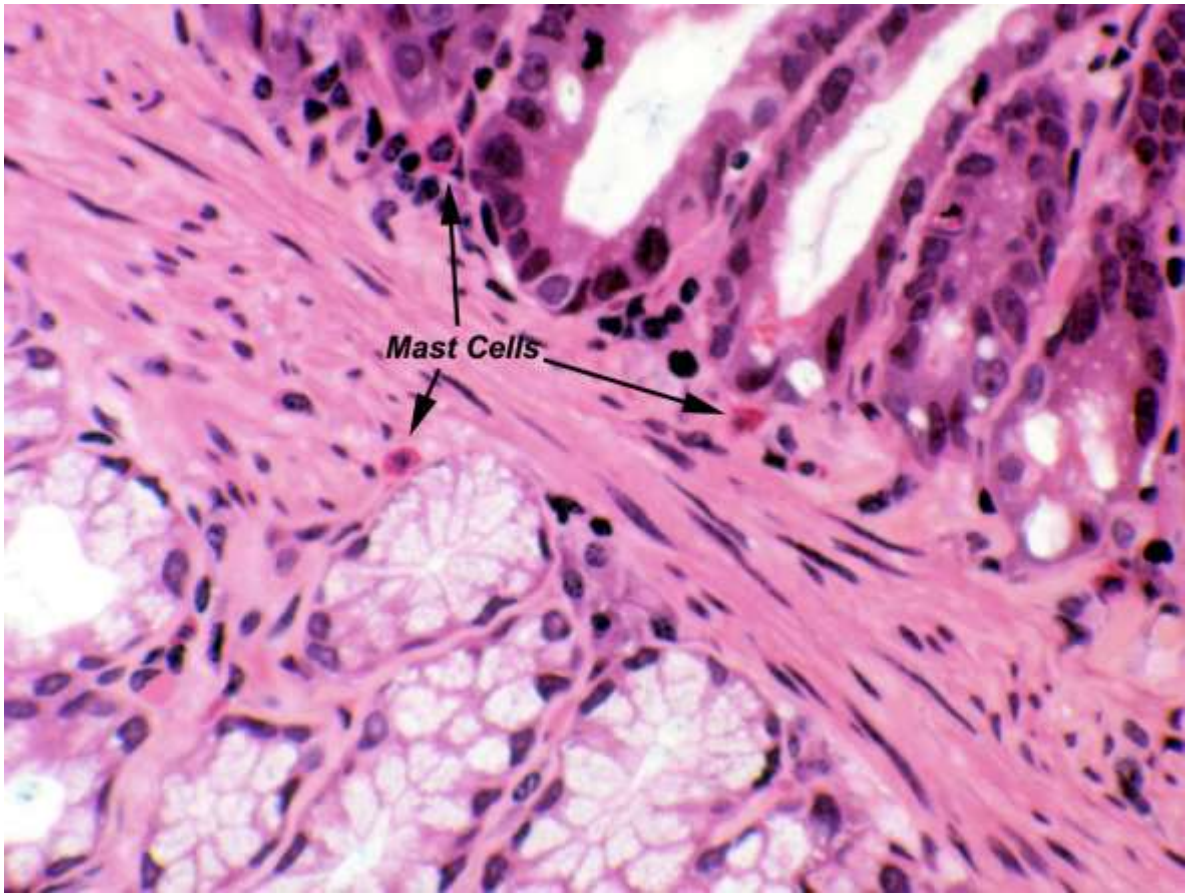

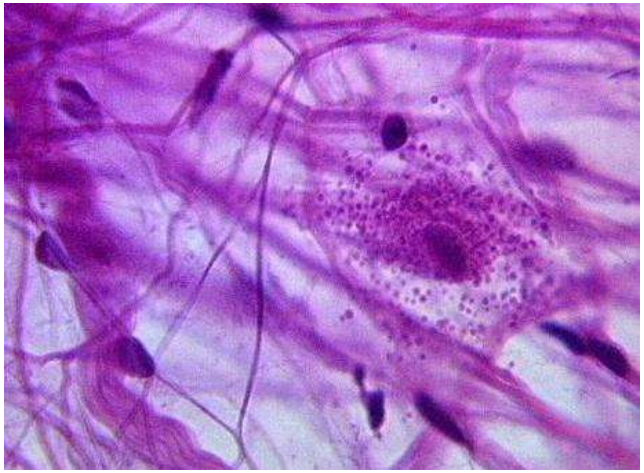

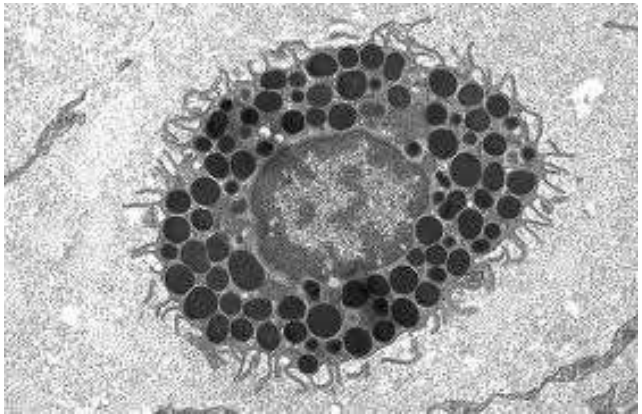

Mast cells are numerous in skin and mucous membranes, capsule of organs, menings (not within the CNS), Thymus (not in spleen).

Ovoid cell with spherical nucleus. Cytoplasm is filled with large membrane limited granules. After glutaraldehyde fixation the granules stain with basic dyes (tolidine blue). (*sulphated PG-heparin*)

Metachromasia

!

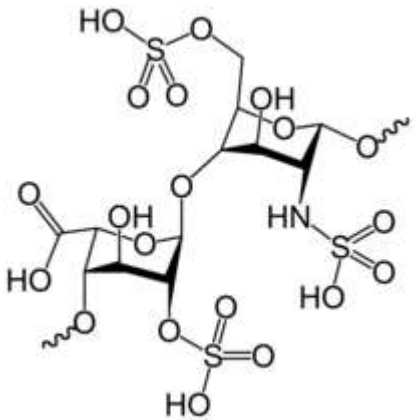

Heparin-sulphated proteoglycan

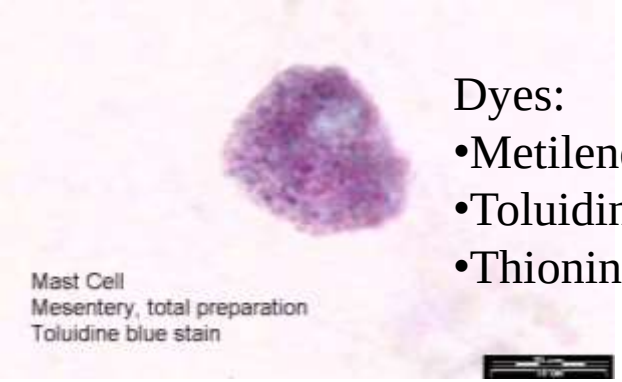

Dyes:
- Metilene blue
- Toluidine blue
- Thionin

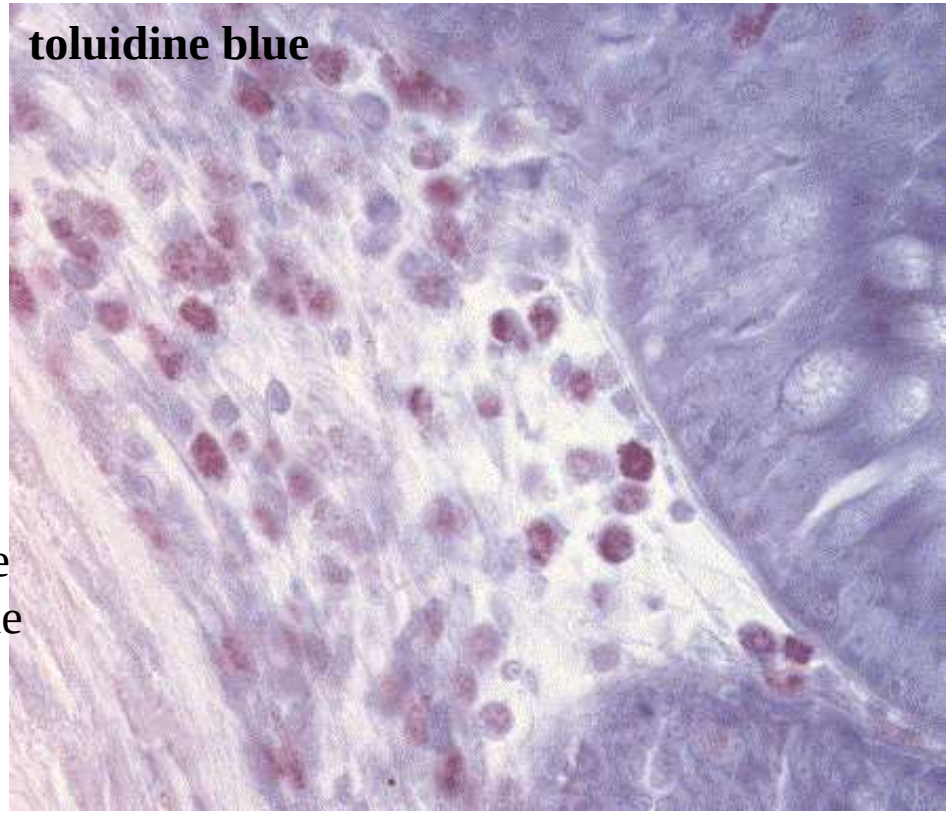

A phenomenon whereby a dye (such as toluidine blue) changes color after reacting with a tissue component is referred to *metachromasia*

Underlying mechanism → presence of polyanions within the tissue

After binding, the dye molecules are sufficiently close to form aggregates whose absorption properties are different from individual dye molecules.

Functions of mast cell

!

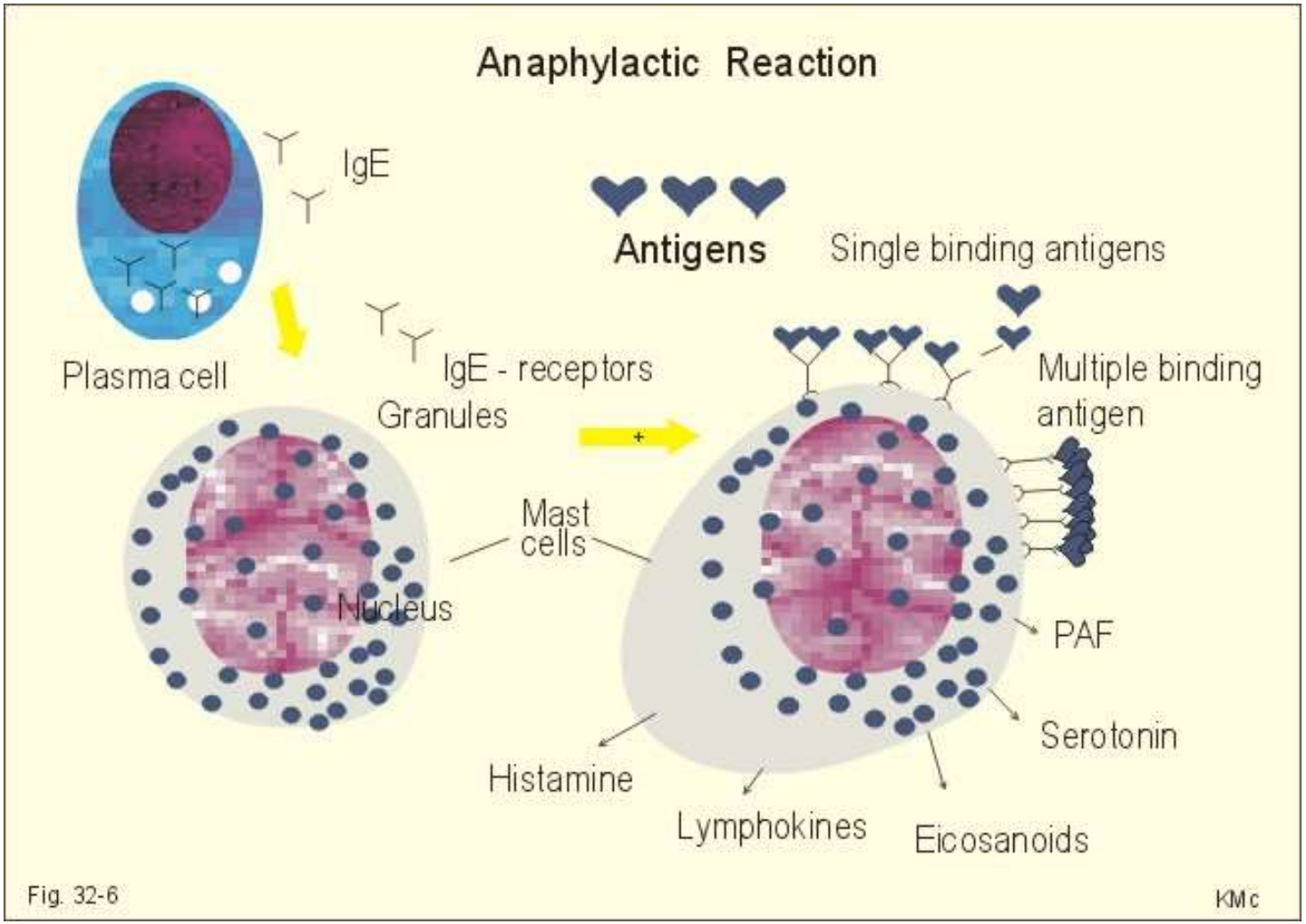

Antigen-antibody reaction → discharge of **histamine**, slow reacting substance of anaphylaxis, eosinophil chemotactic factor of anaphylaxis, **heparin (degranulation**)

Classification of connective tissue

!

Embryonic connective tissue

- **Mesenchyme**
- **Mucous connective tissue (Wharton jelly)**

Matured

- **Loose connective tissue (cells, fibers, matrix)**
  (submucosa, lip, adventitia)
- **Dense (fibrous) connective tissue (cells, fibers, matrix)**
  - **irregular** *(dermis, tunica albuginea)*
  - **regular** *(ligaments, tendons, cornea)*
- **Cell rich (cells, fibers, matrix)**
  - **spinocellular** *(ovarium, uterus)*
  - **reticular** *(hemopoetic tissue, lymphatic tissue)*
  - **areolar** *(omentum majus)*
- **Specialized connective tissue**
  - **cartilage**
  - **bone**
  - **adipose tissue**
  - **blood**

Embryonic connective tissue

!

Mesenchyme

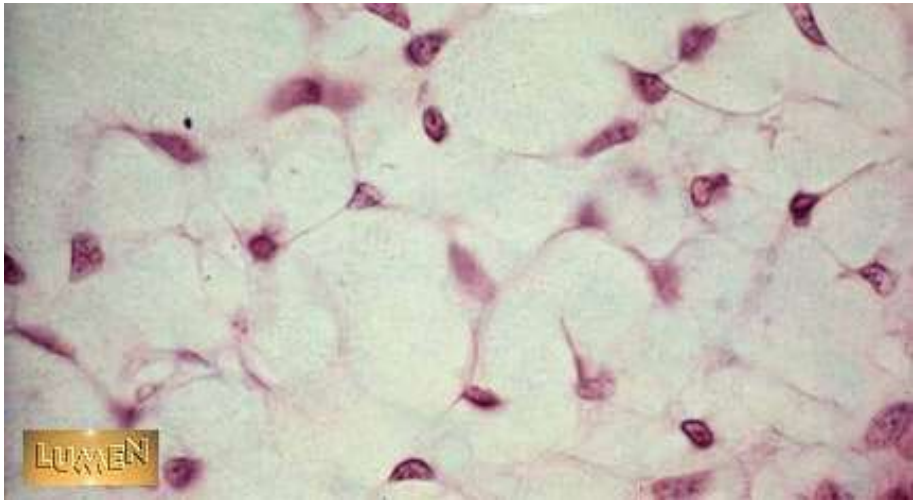

Mesenchyme
Consists of mesenchimal cells
Main components of the ECM:
hyaluronic acid, fibronectin
(collagen and elastic fibers appear later)

Wharton's jelly (a form of mesenchyme)
Slightly basophil cells,
thin collagen fibers
Jelly like structure (abundant ground substance, hyaluronic acid)

Mucous connective tissue
Wharton's jelly

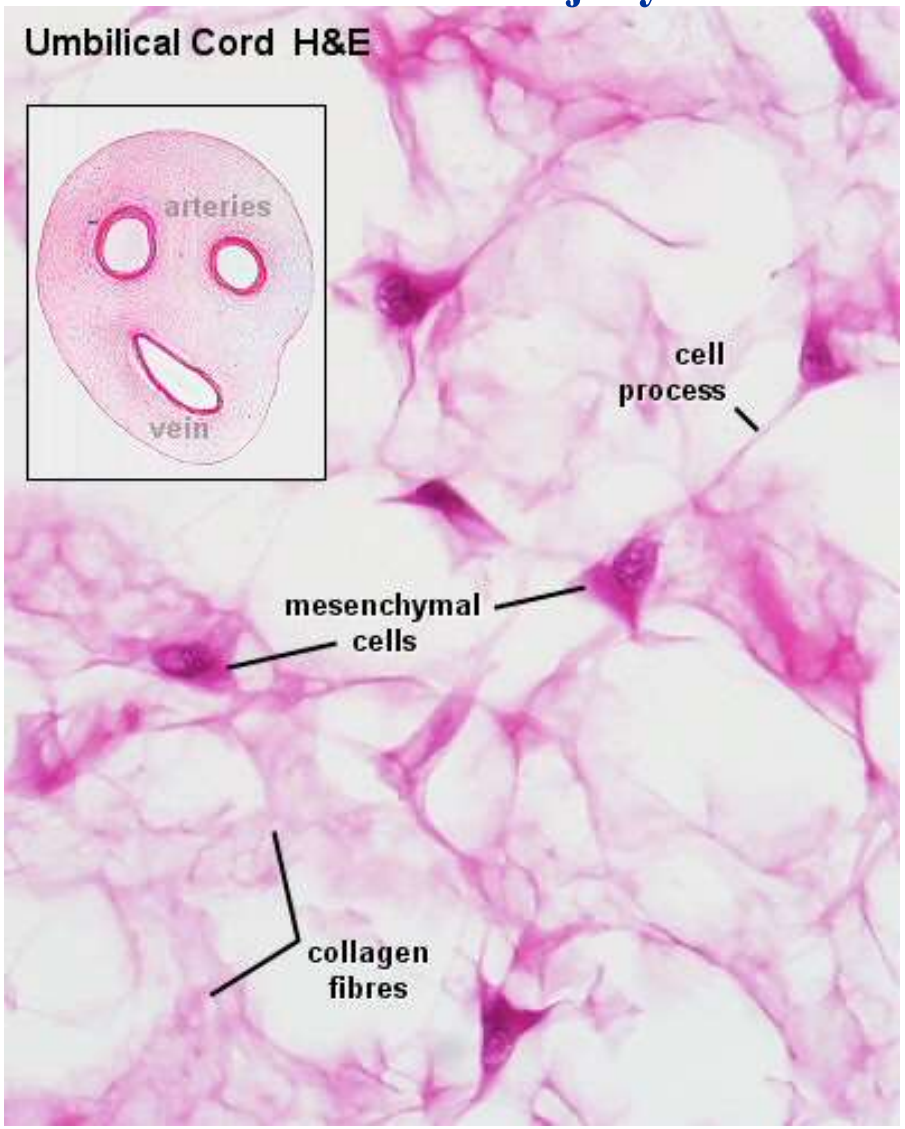

Wharton's jelly in the umbilical cord !

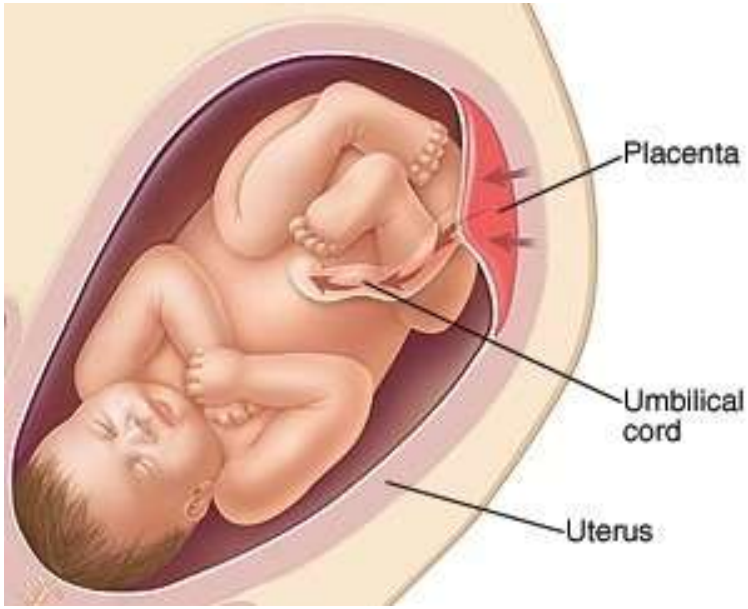

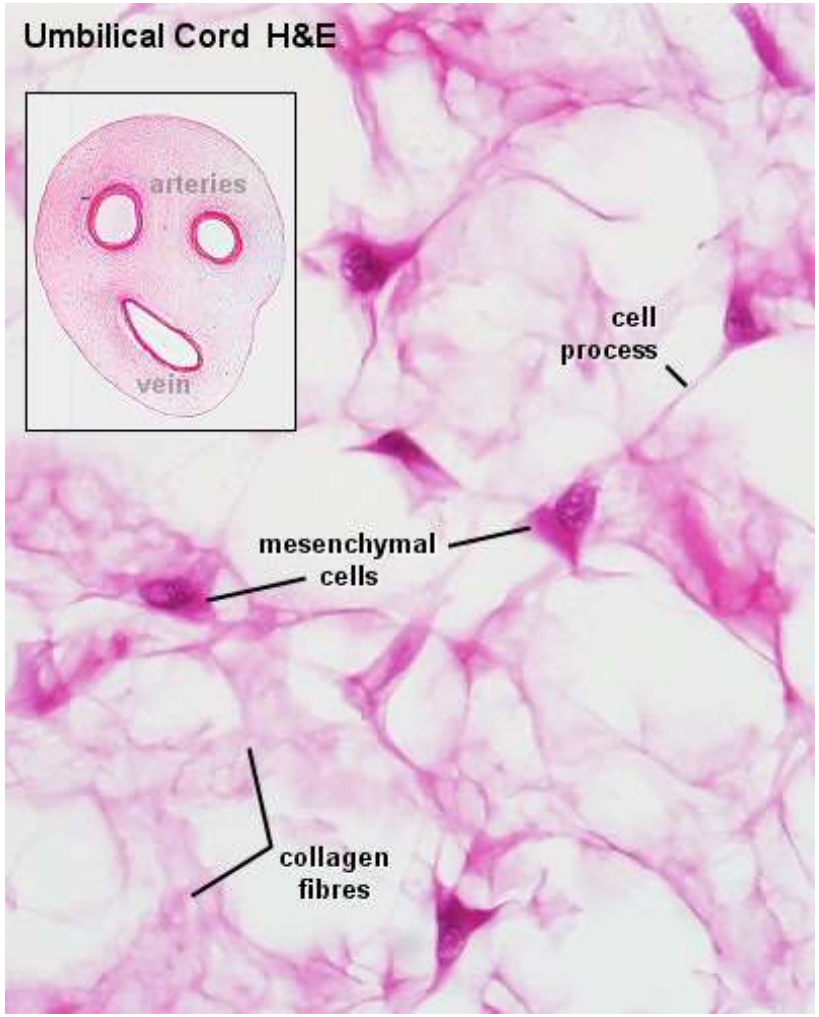

Wharton's jelly is a mucous connective tissue surrounding and protecting the umbilical cord vessels (2 arteries and one vein) against compression, bending twisting etc. It originates from the extraembryonic mesoderm and composed of mesenchymal cells and ECM (collagen, hyaluronan and proteoglycans). Some fibroblasts and macrophages also appear. Hyaluronan makes this tissue highly hydrated, collagen makes it resistant. It is a postnatal source of fetal stem cells.

Loose connective tissue and dense irregular connective tissue

!

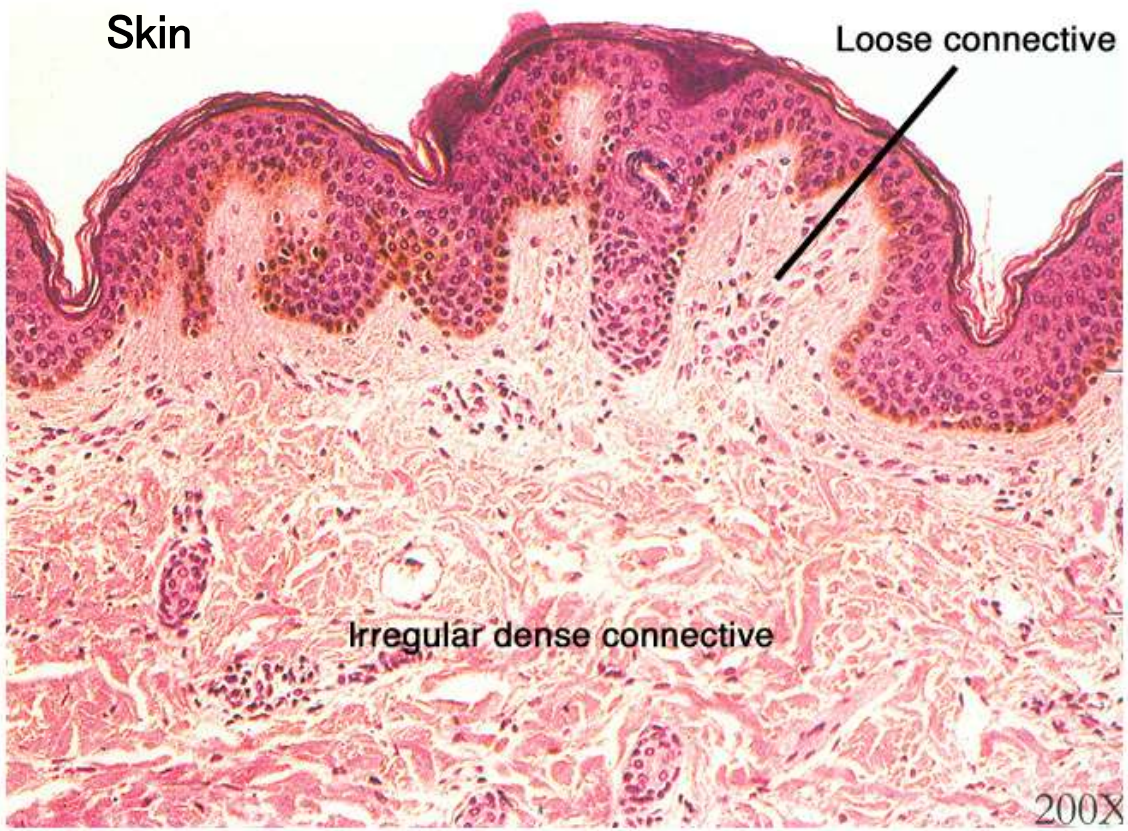

Loose connective tissue:

collagen fibers (type I and type III collagen dominate)

elastic elements, fibrillin

Fibroblasts, fibrocytes, mobile connective tissue cells, adipocytes

(Found in everywhere adventitia, submucosa)

Dense irregular connective tissue: abundant collagen fibers (do not show clear orientation), fibrocytes

Found in the dermis of the skin

Dense regular connective tissue

!

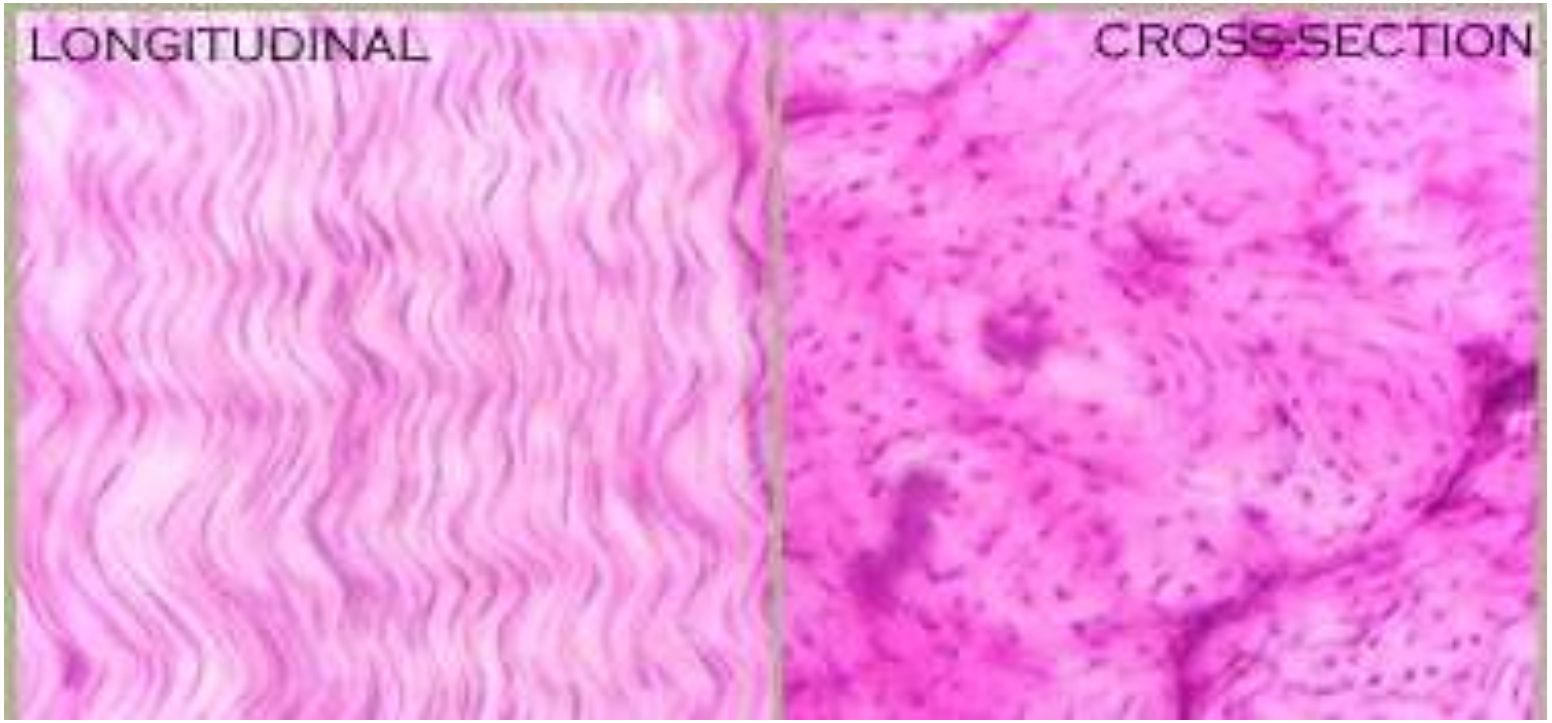

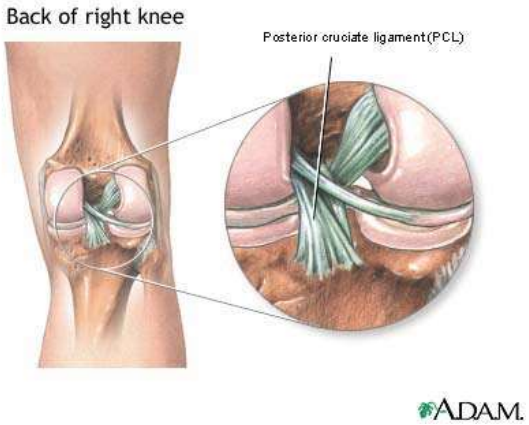

ligament

Consists of parallel bundles of collagen fibers and fibrocytes (called tendocytes - winged cells in tendons)

tendon

Dense regular connective tissue elastic ligaments-ligamentum flavum

!

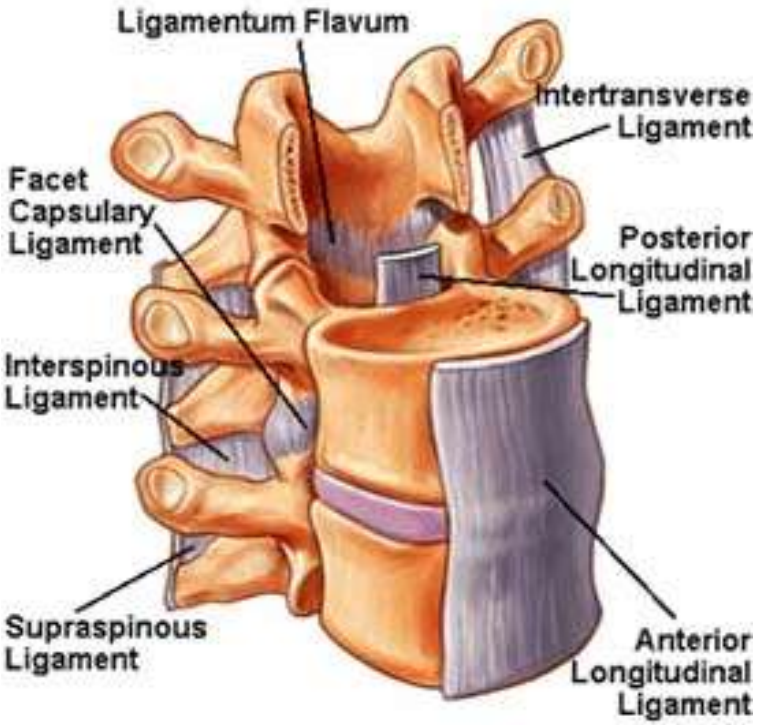

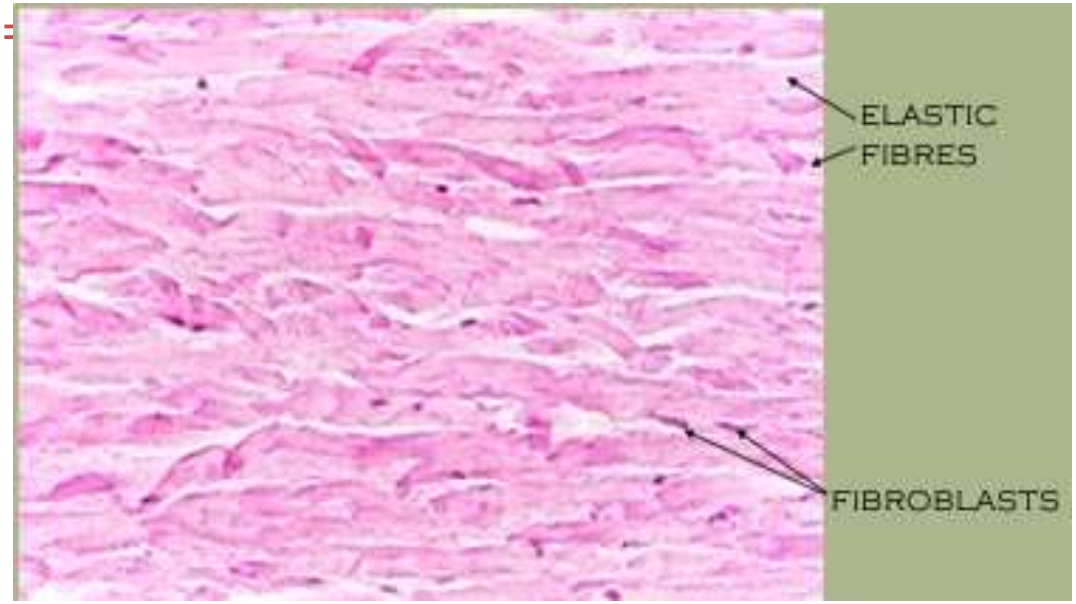

Mainly elastic fibers and lesser amount of collagen

Cell rich connective tissue

!

Reticular (lymph node)

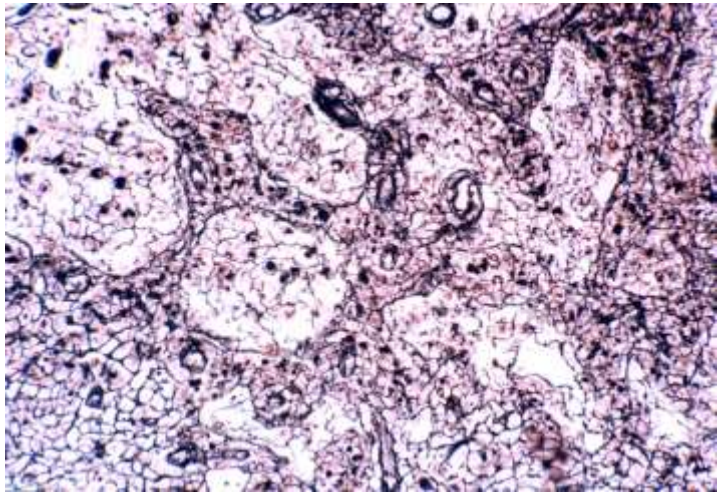

Aleolar (greater omentum)

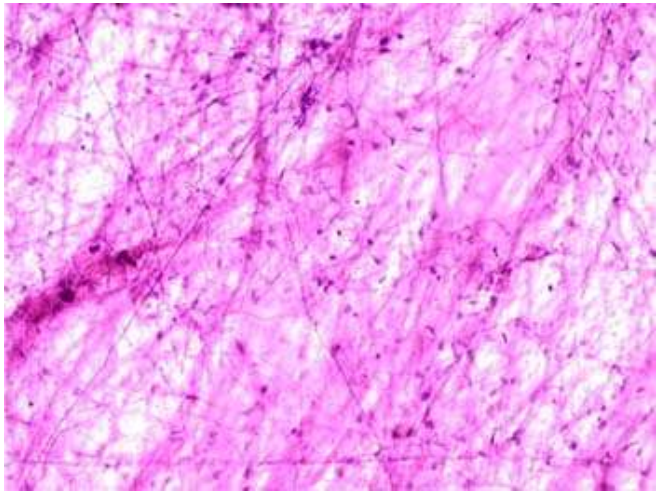

Type III collagen
→ reticular fibers
Modified fibrocyte
→ reticular or adventitial cell

Spinocellular (ovary, uterus)

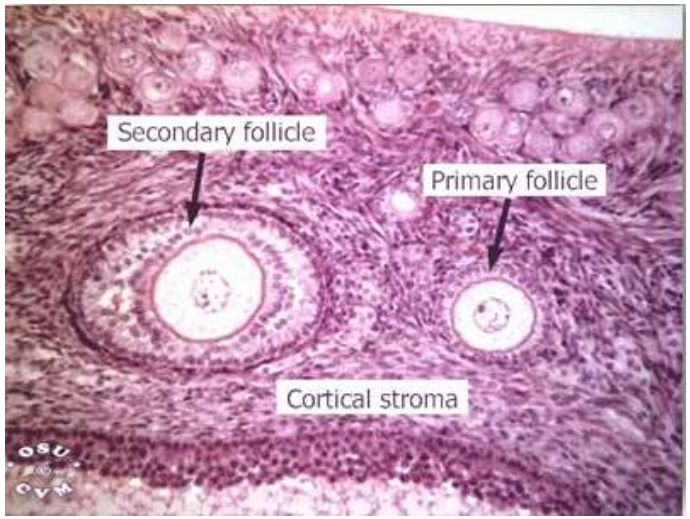

Layers or rows of cells (macrophages, lymphocytes, plasma cells, fibrocytes)

Cells (fish school)

References:

Röhlich Pál: Szövettan. Budapest, 2006

Michael Ross and Lynn J. Romrell: Histology, Baltimore, 1989

Anthony L. Mescher: Junqueira's Basic Histology, New York, 2010

Meghan A. Piccinin and Janice Schwartz: Histology, Verhoeff Stain , Bookshelf ID: NBK519050PMID: 30085592, Copyright © 2020, StatPearls Publishing LLC.

Nobuyo Maeda et al. PNAS 2000;97:2:841-846

Huang et al. PNAS July 17, 2018 115 (29) E6826-E6835; first published July 2, 2018 https://doi.org/10.1073/pnas.1712628115