

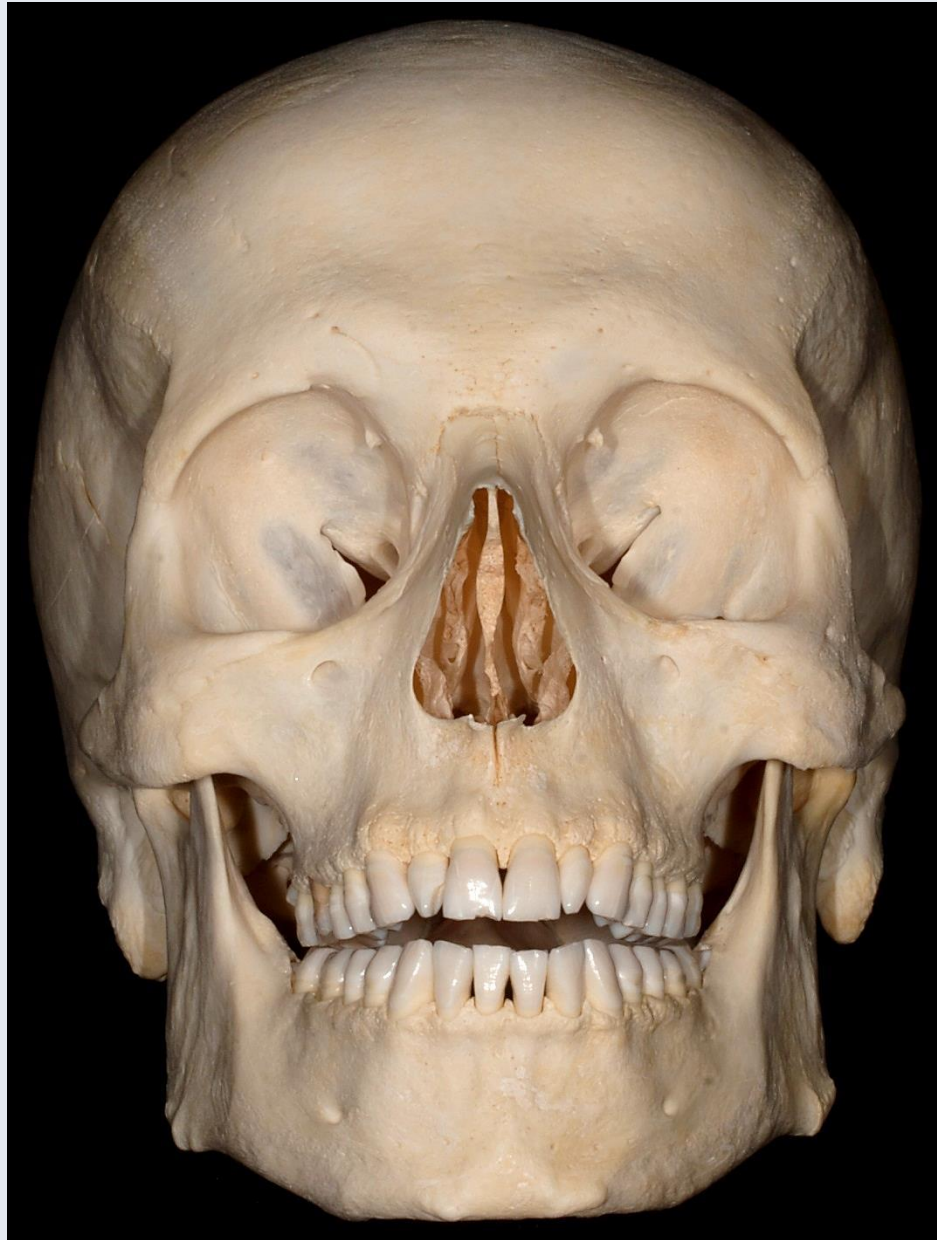Maxillofaziale Aspekte von Mandibula



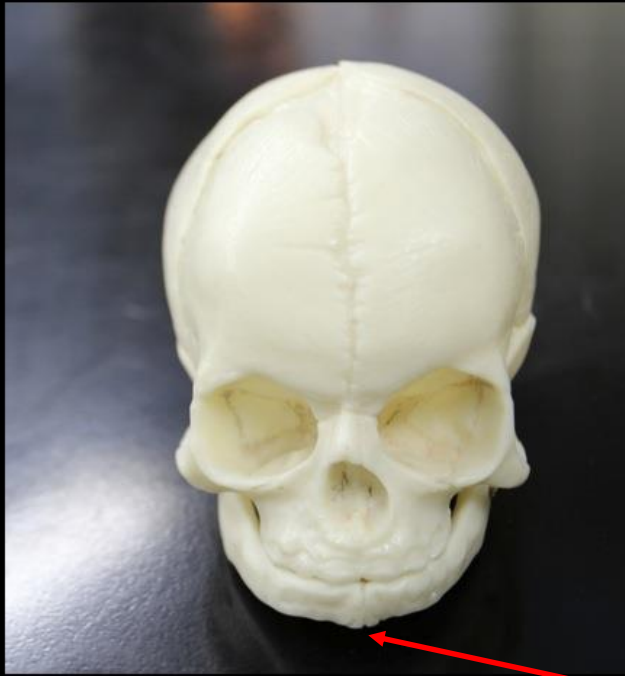
Malerei: Mihály von Munkácsy: Gährender Lehrling (1868-69.)
www.mng.hu

Ph.D., Dr. Dávid Lendvai

Anatomisches, Histologisches- und Embryologisches Institut
2020.



Neonatale Mandibula



Aus 1. Kiemenbogen (paarige Anlage

lat. vom Meckel-Knorpel), desmale

Ossifikation

Gelenkkopf: chondrale Ossifikation

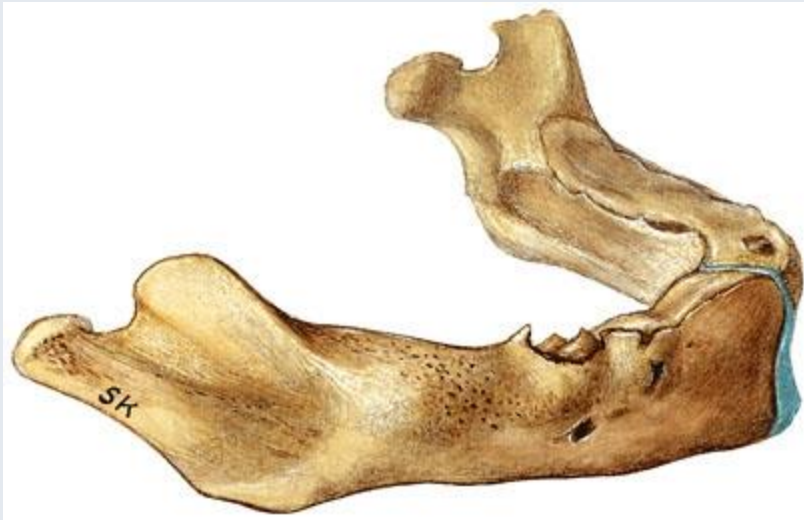Symphysis mentalis: verknöchert am

Ende des 1. LJ

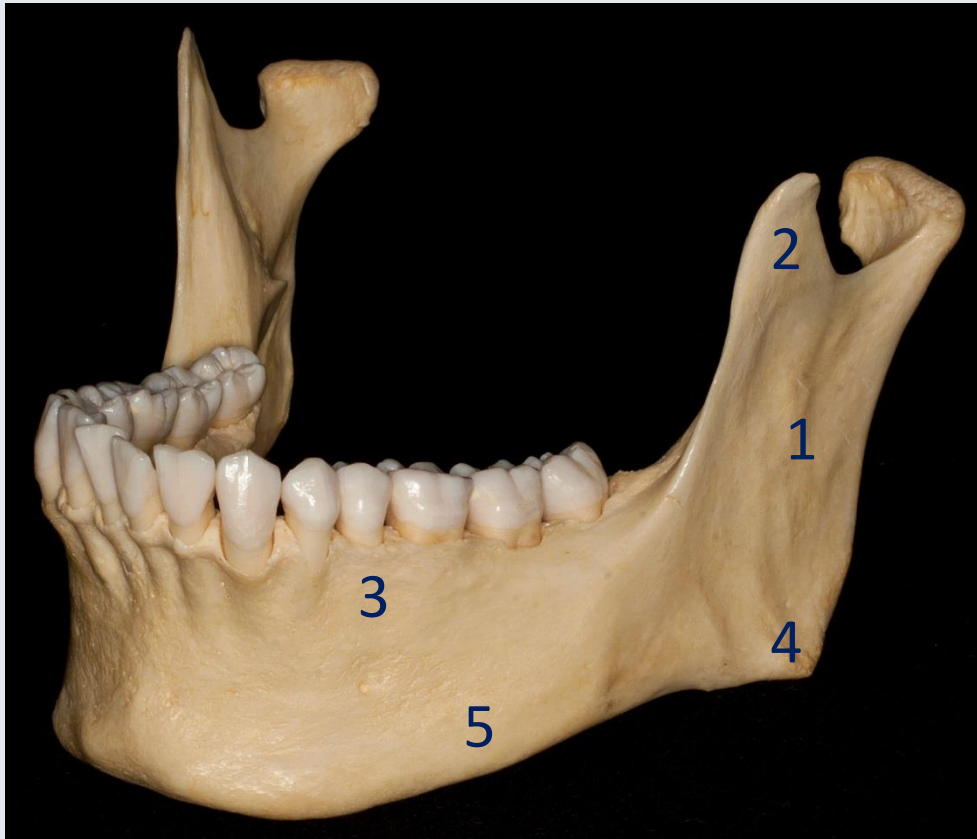
Hier: Schaltknochen → beteiligen sich

an Tuberculum mentale

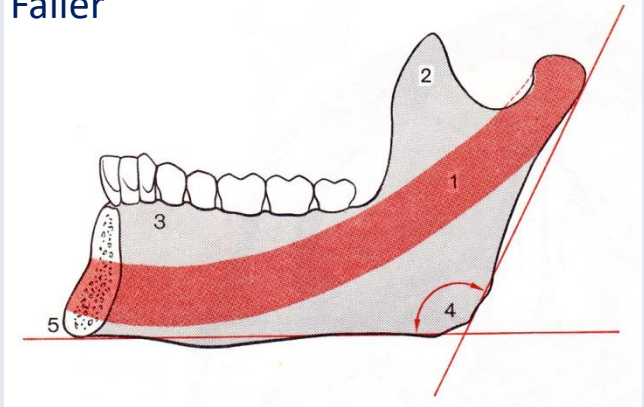
Angulus mandibulae: $\sim 150^\circ$



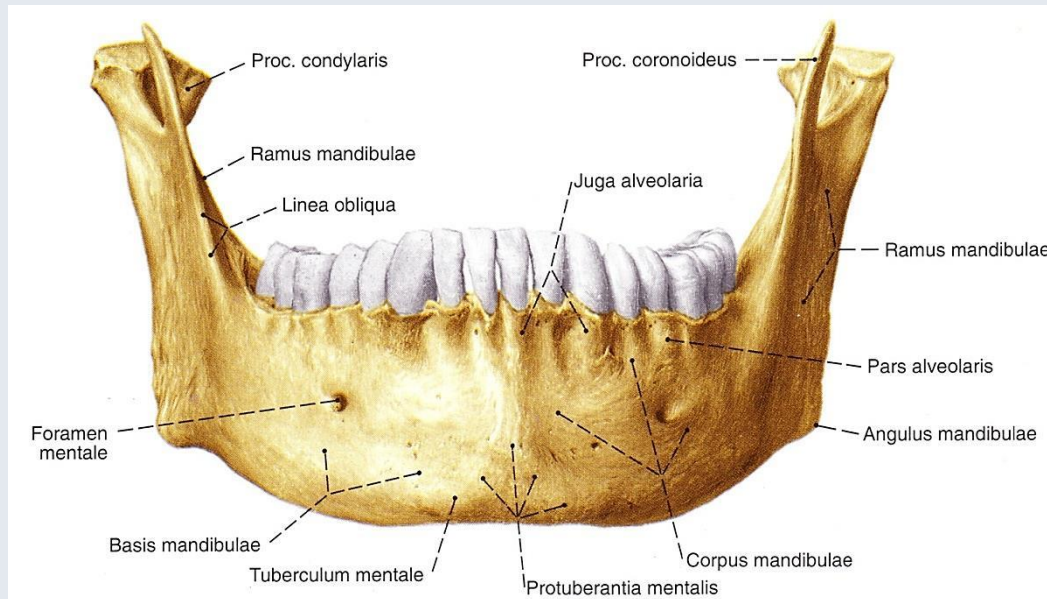
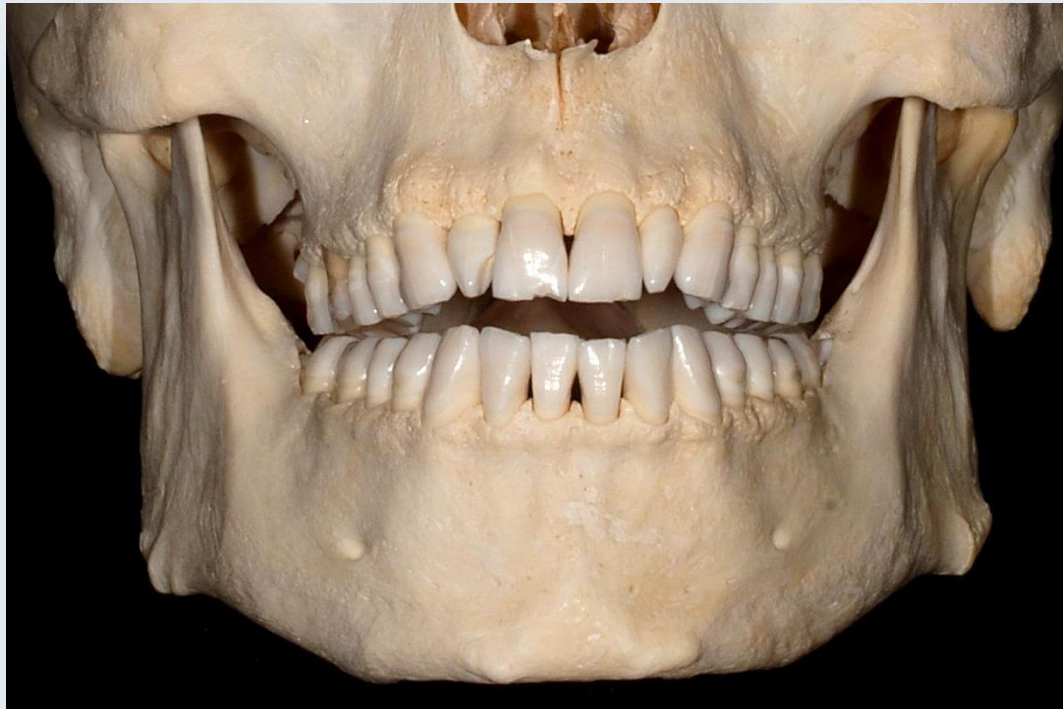Mandibula - Teile

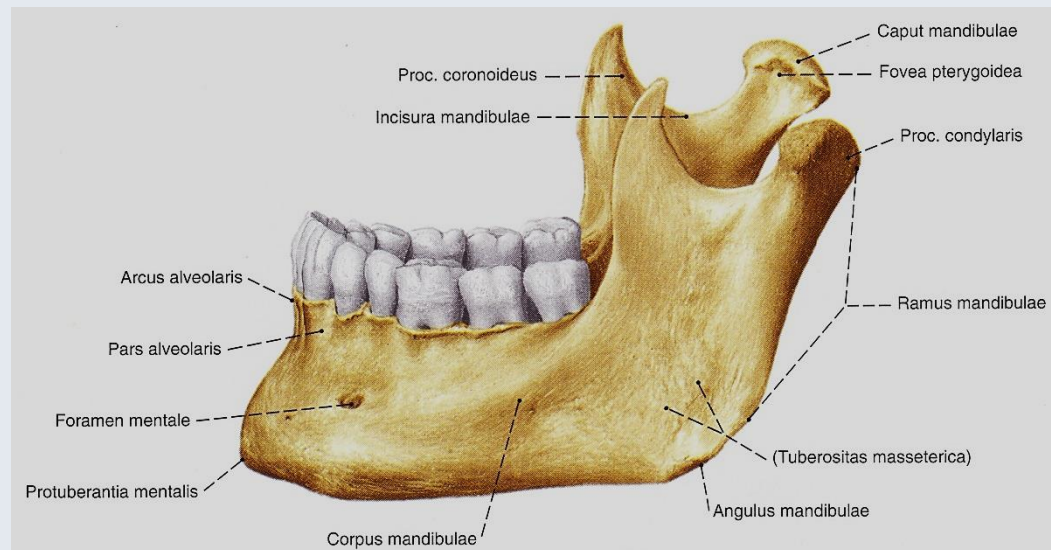
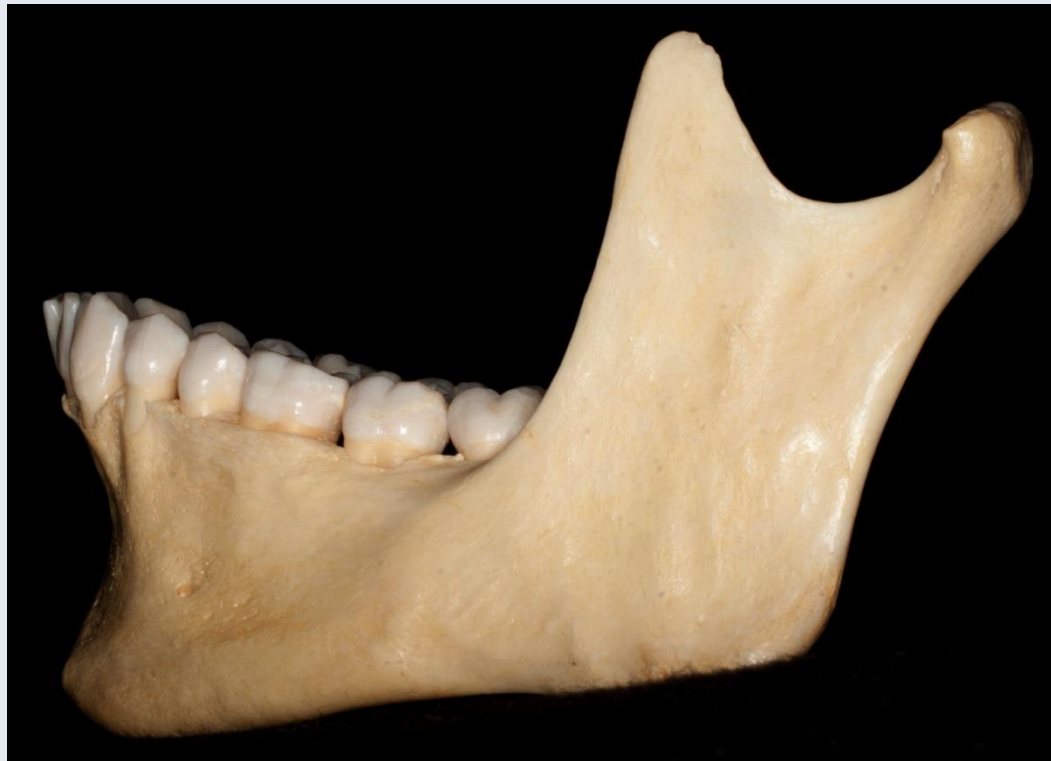

Faller

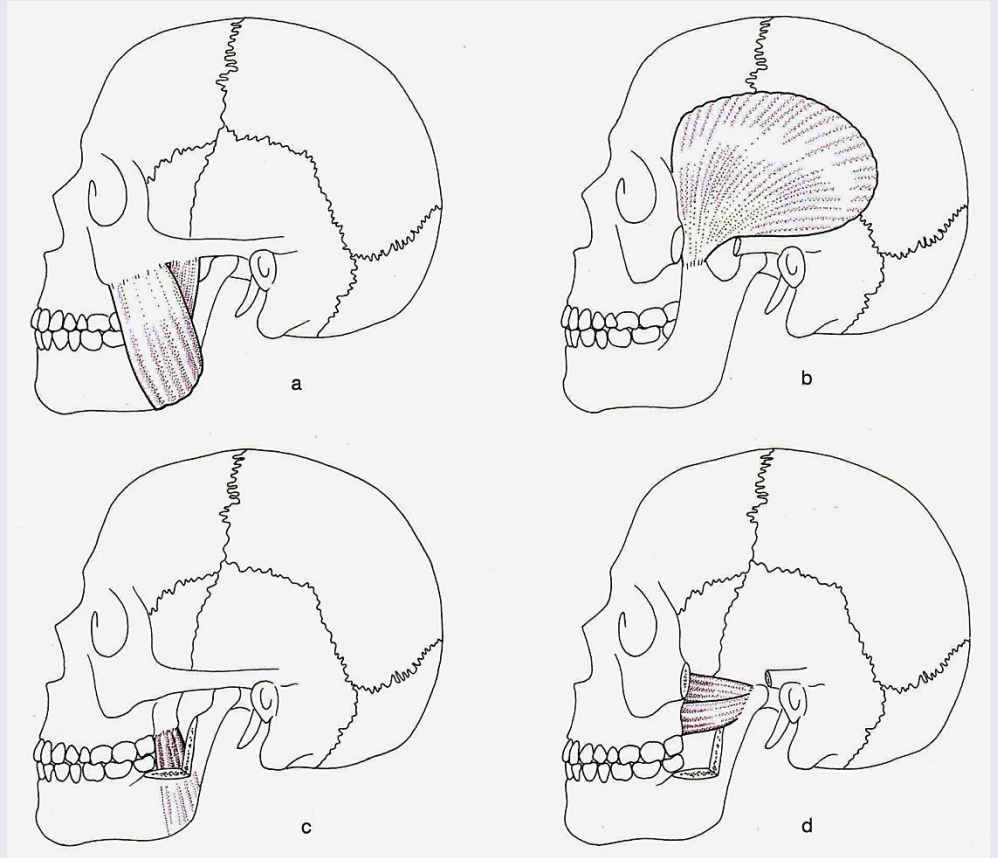
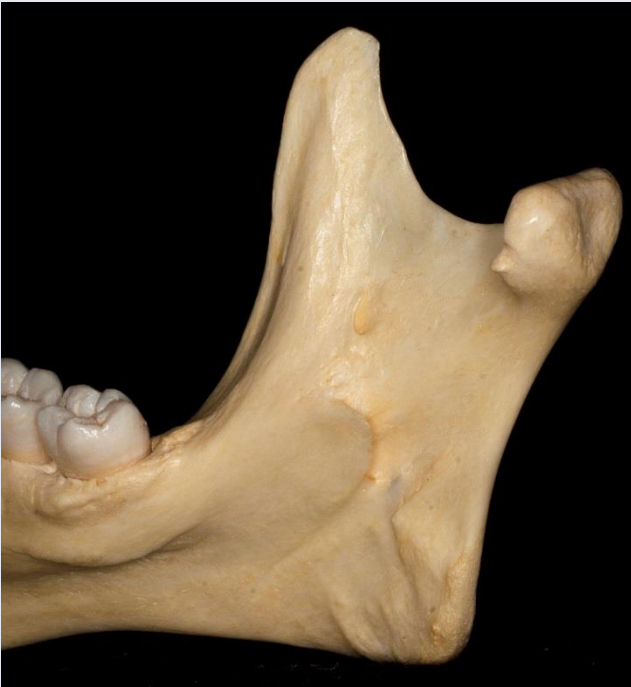
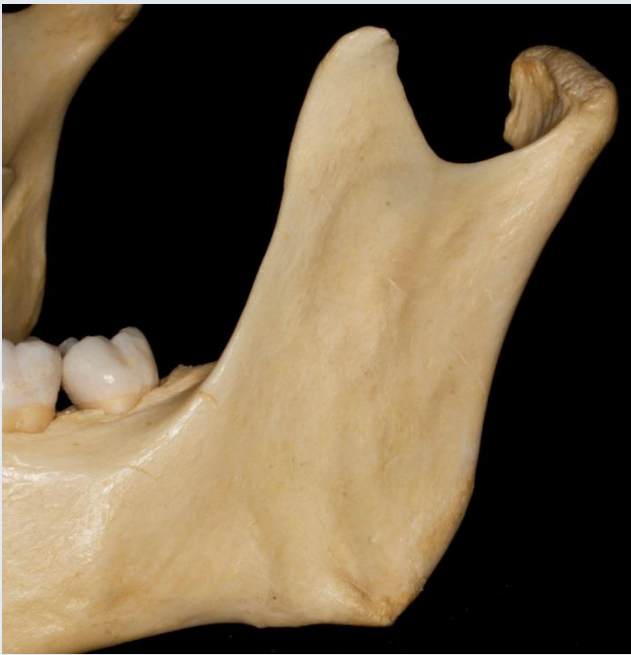
- 1 Ramus mandibulae
- 2 Processus coronoideus
- 3 Processus alveolaris
- 4 Angulus mandibulae
(~90-140°)
- 5 Basis mandibulae

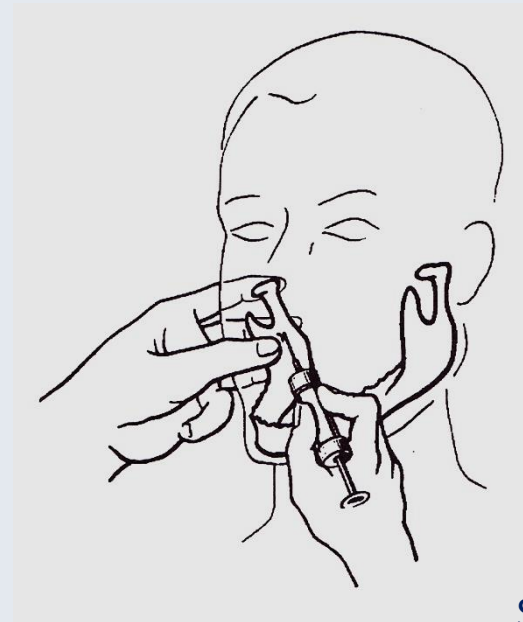
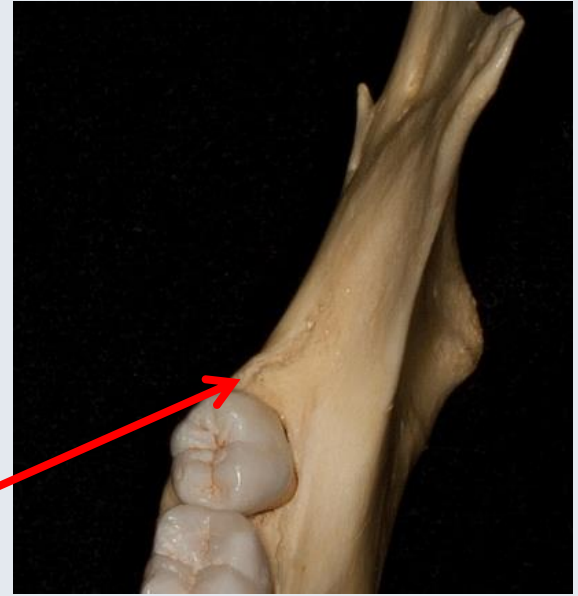
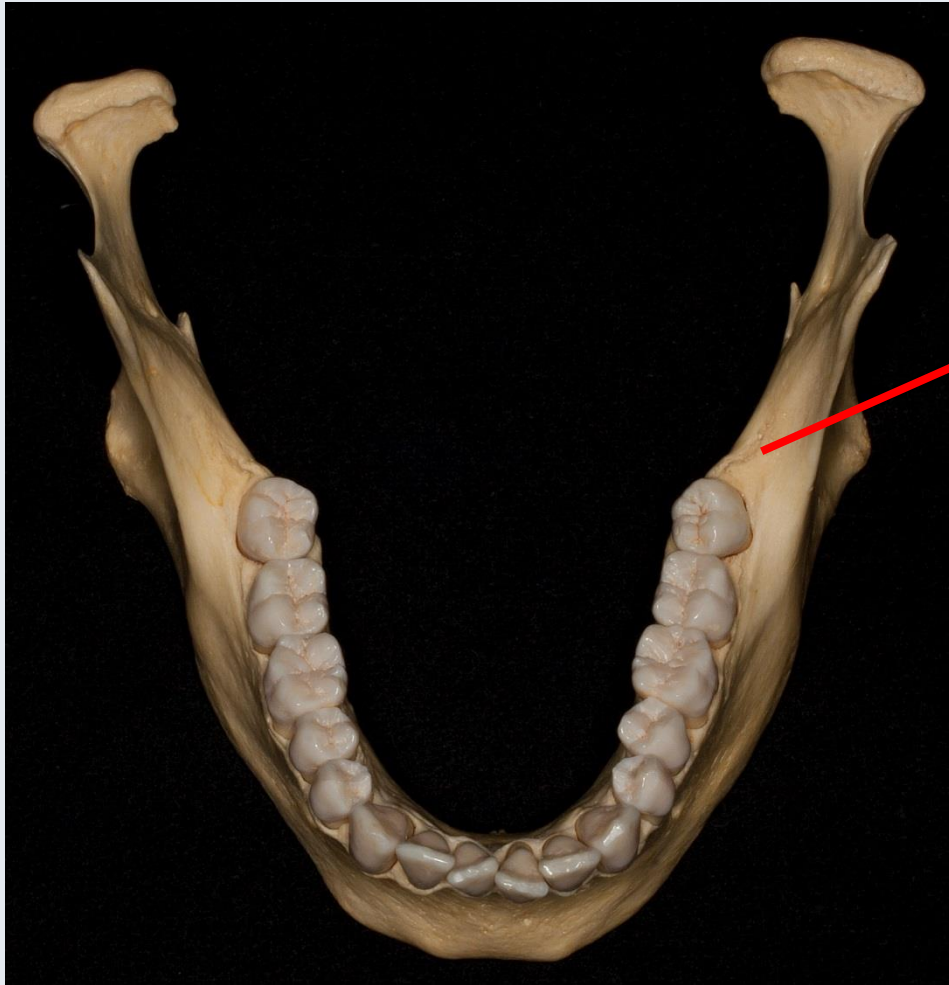




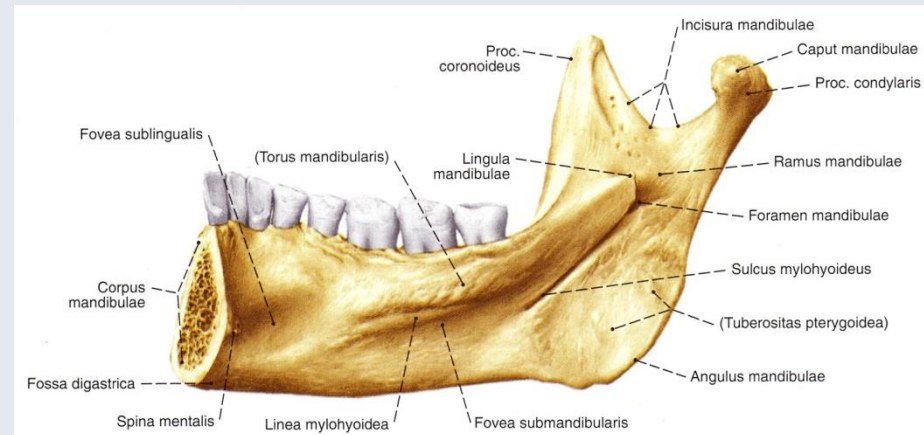
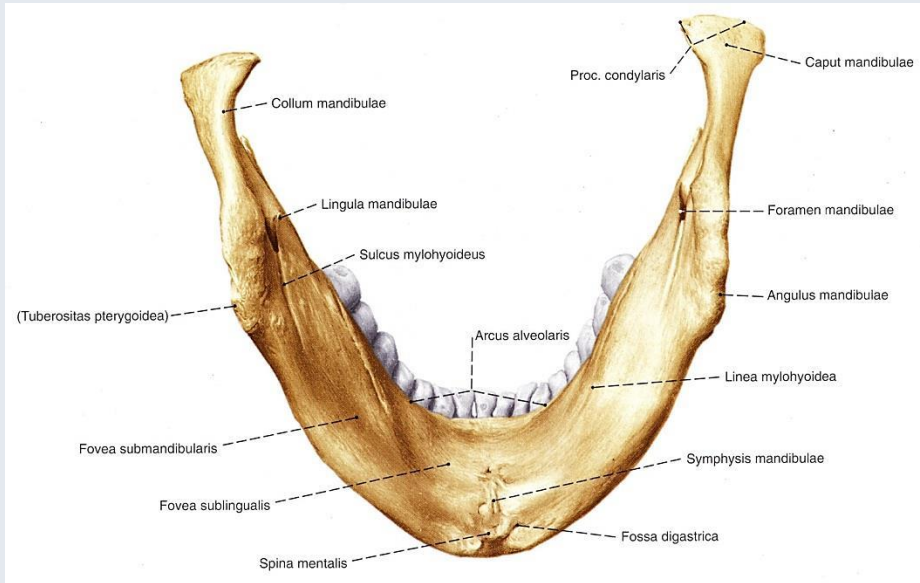
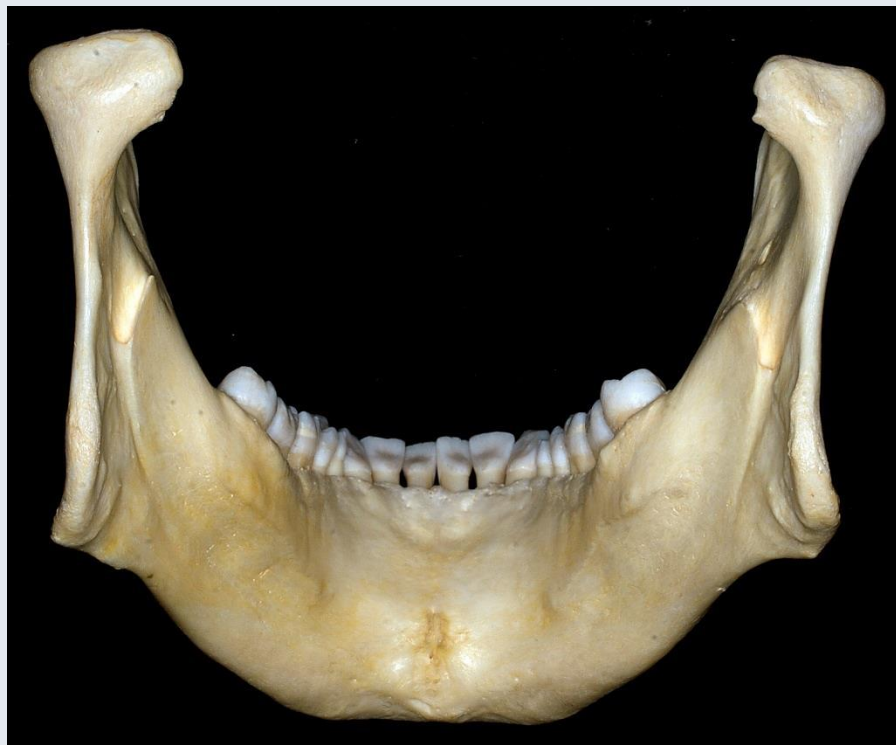For. mentale: bei bezahnter Mandibula etwa Mitte des Corpus, zw. 1. u. 2. Prämolaren



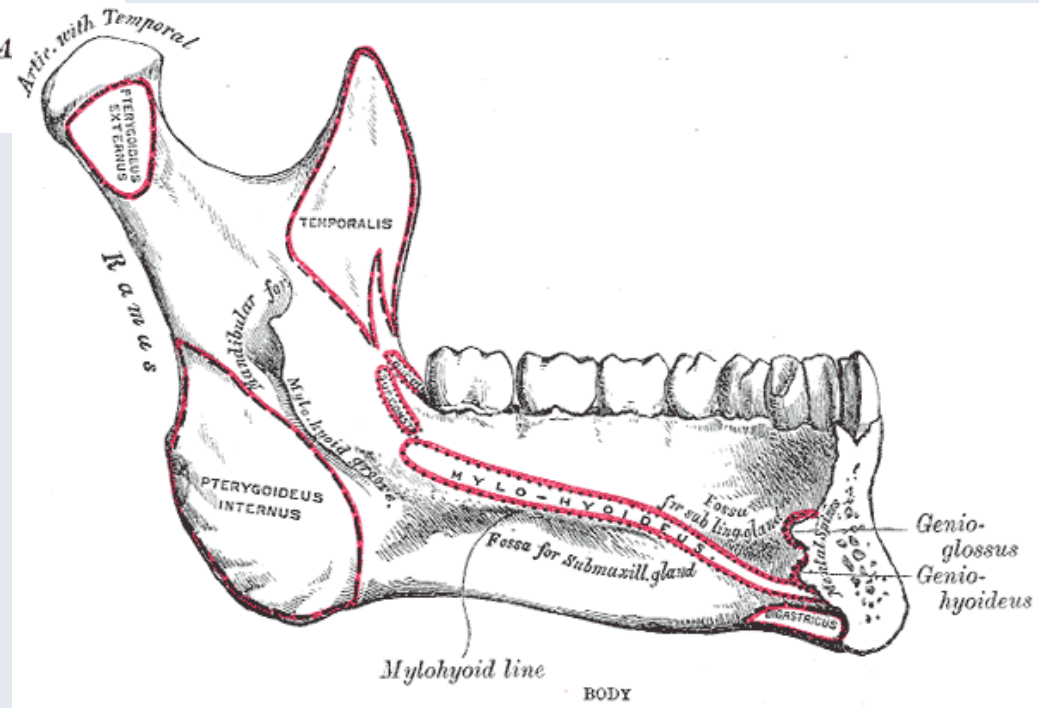
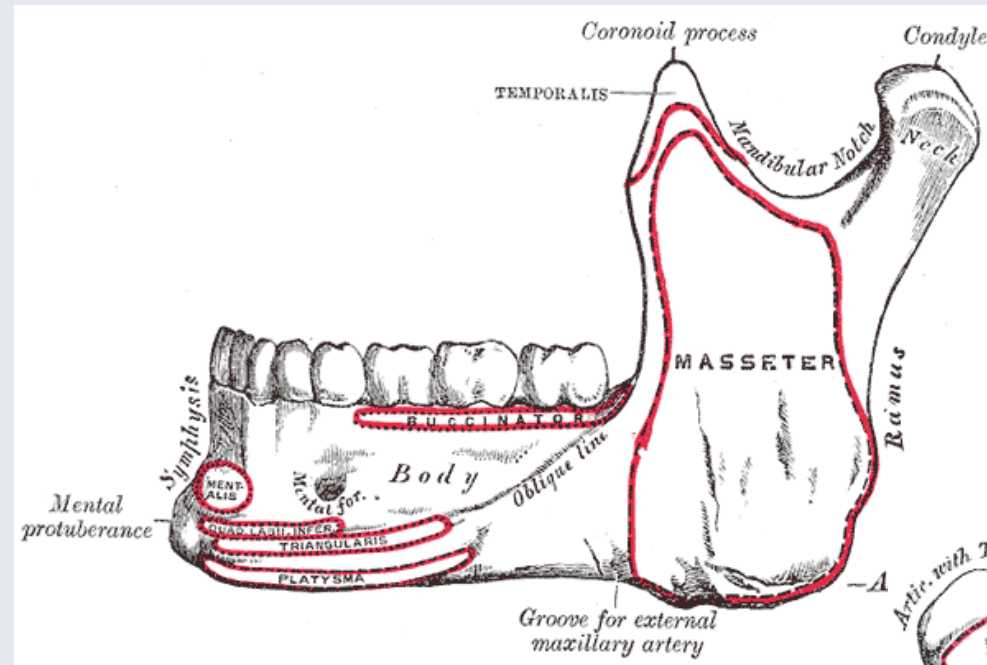
Fehér

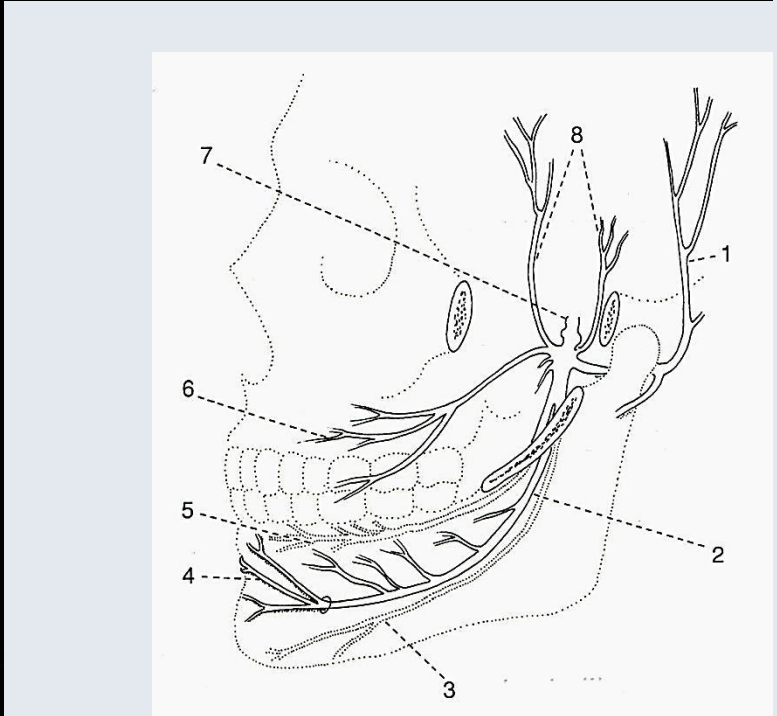
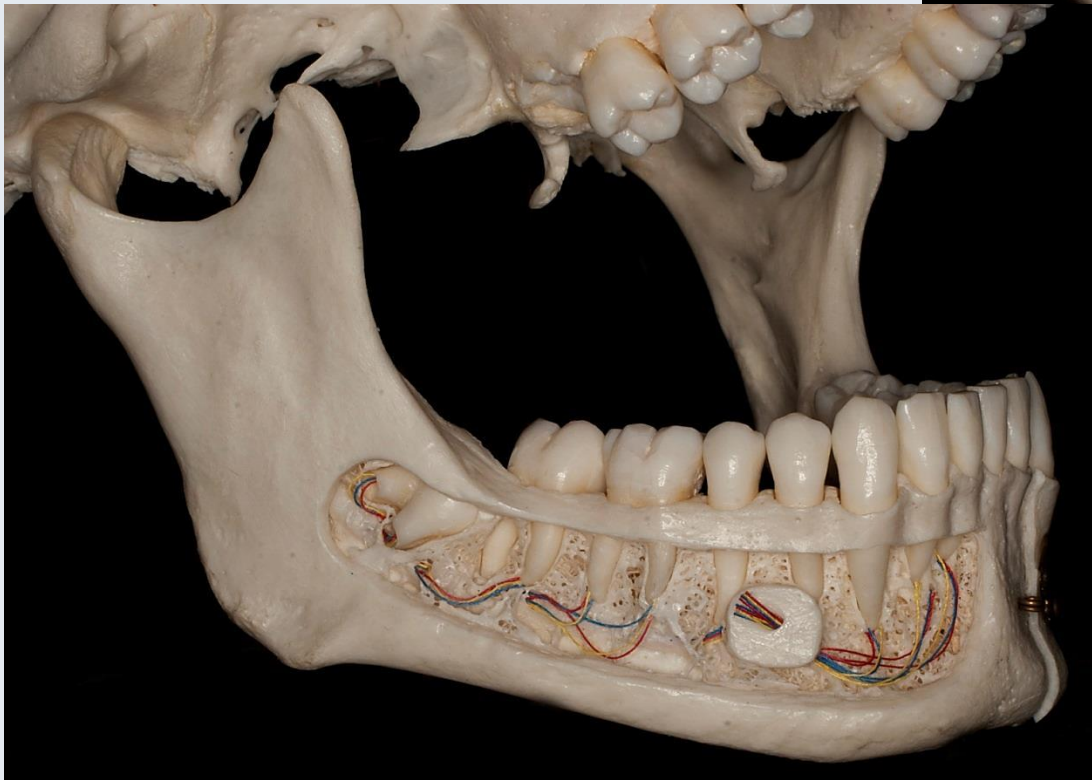
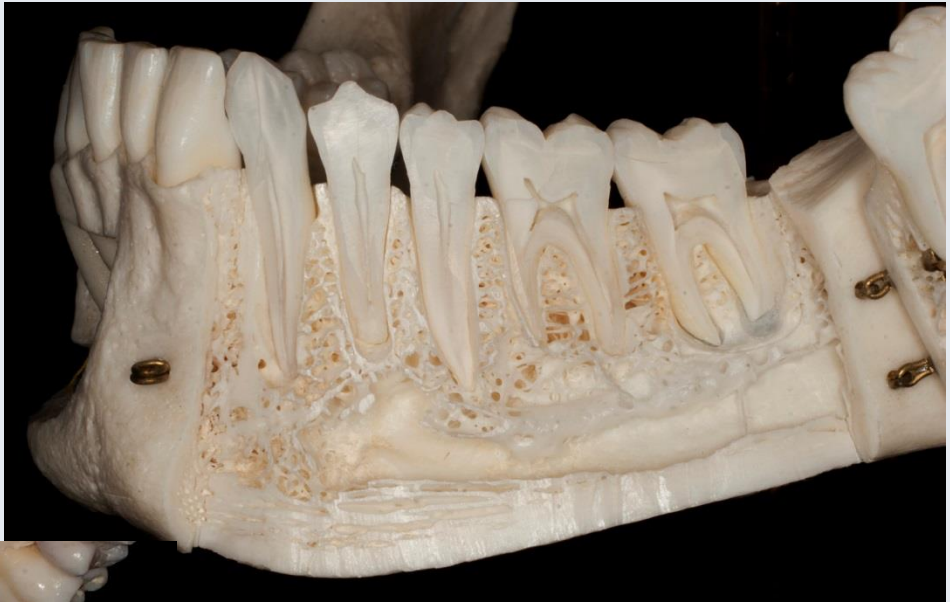

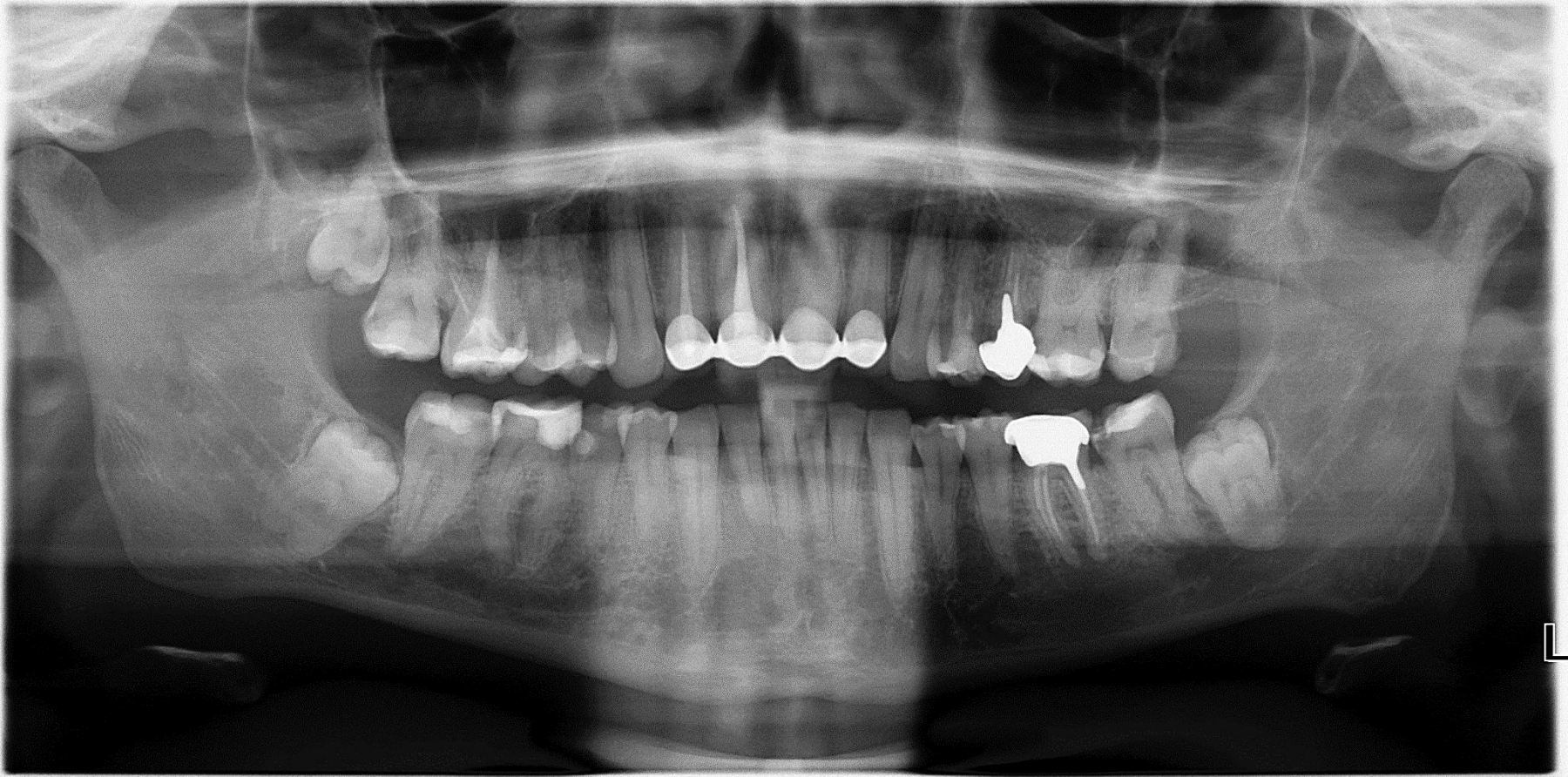Szél



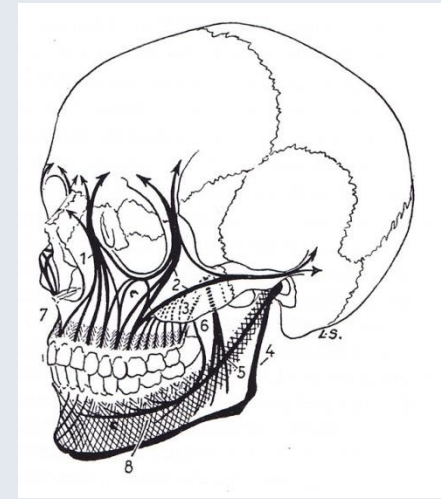
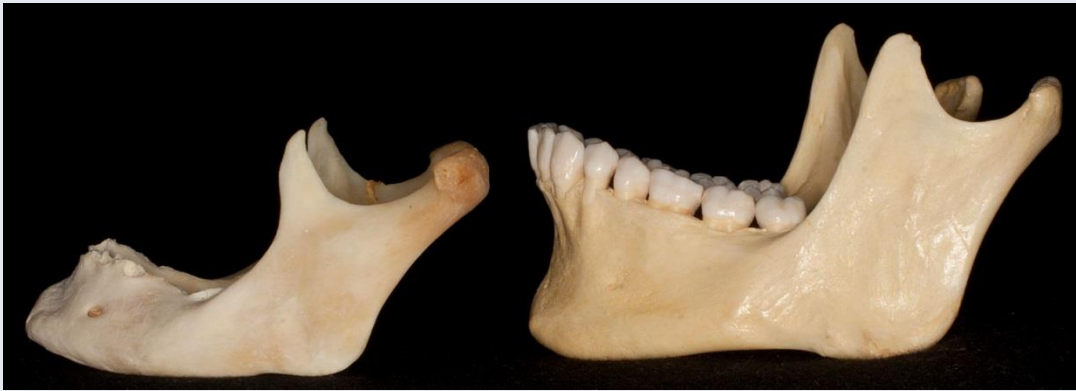Ursprung- und Ansatzfelder für Muskeln



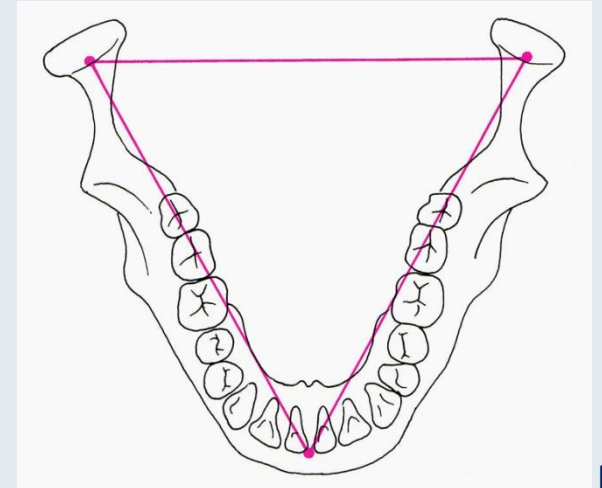
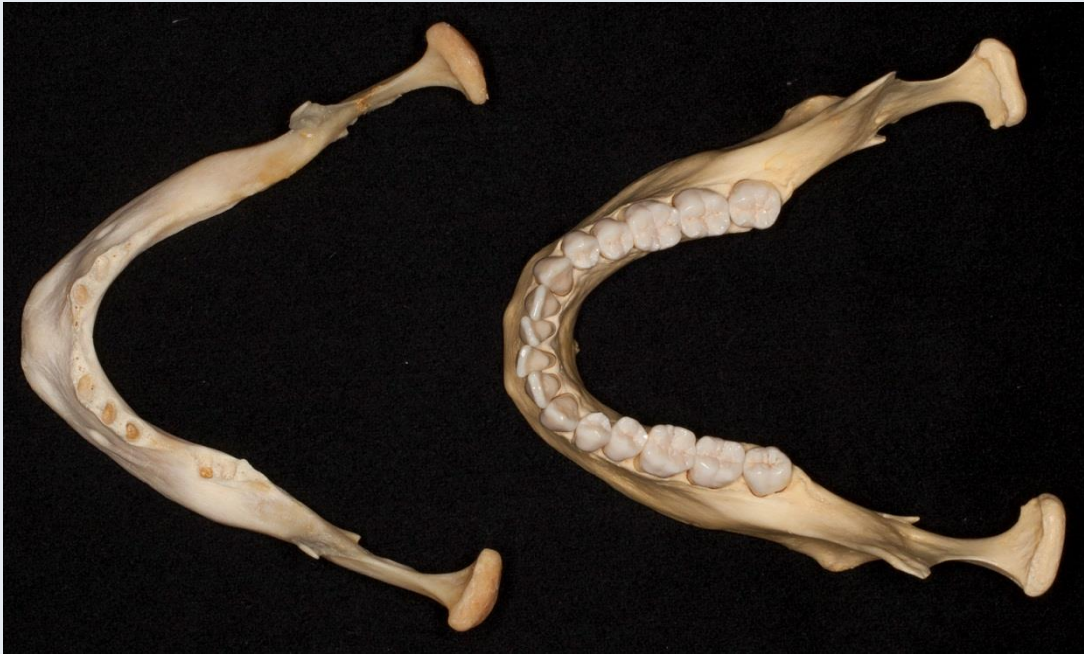



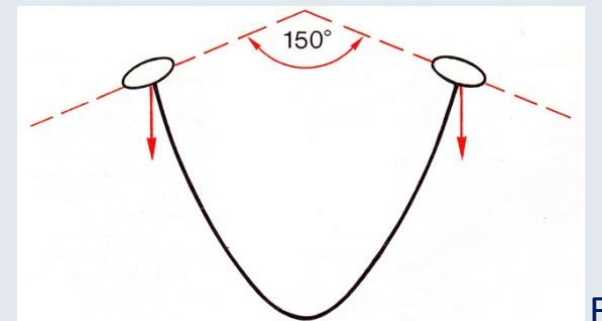
Florian Dental – Dr. S. Kovách



Pernkopf

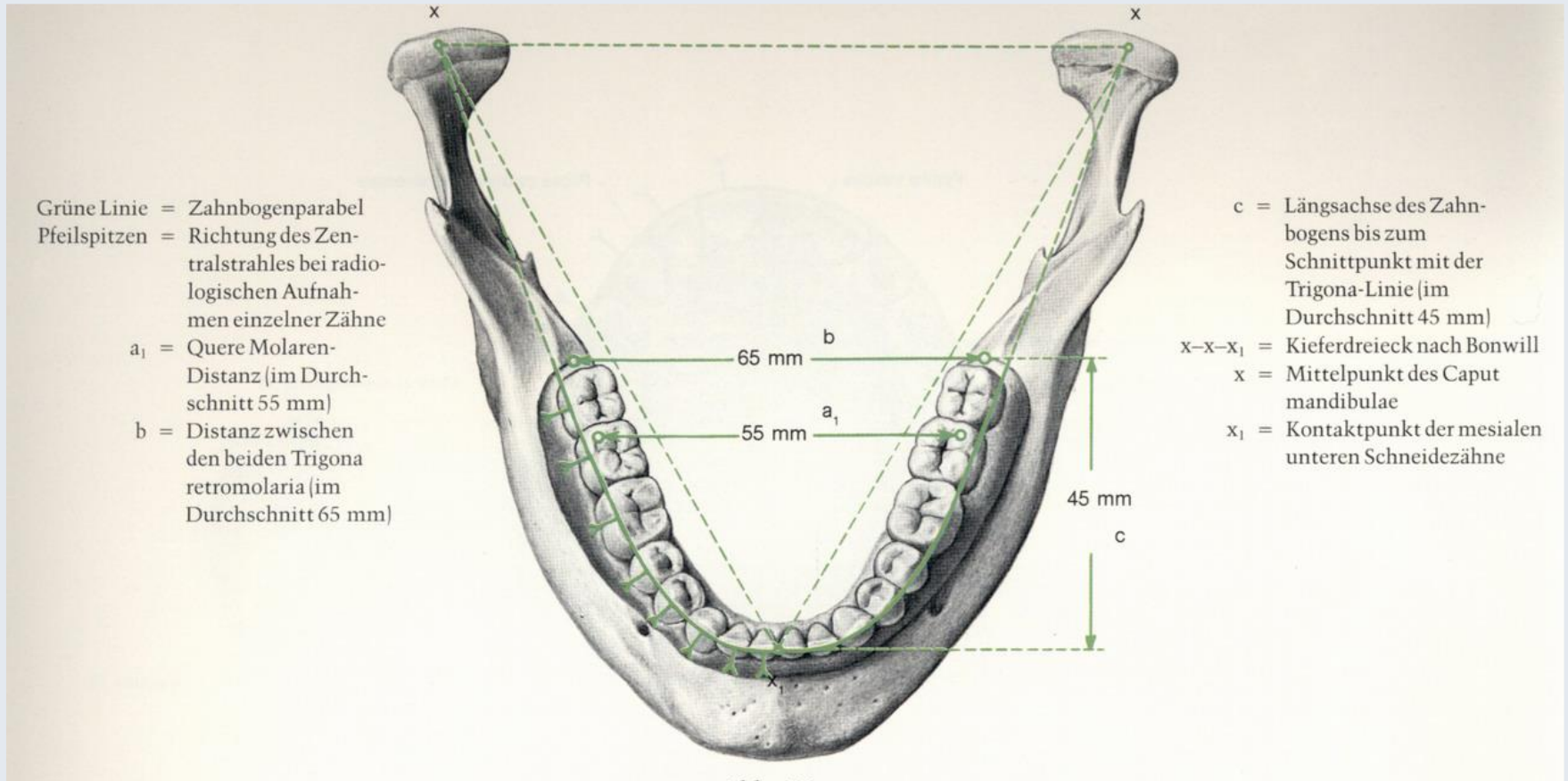


Fehér



Faller

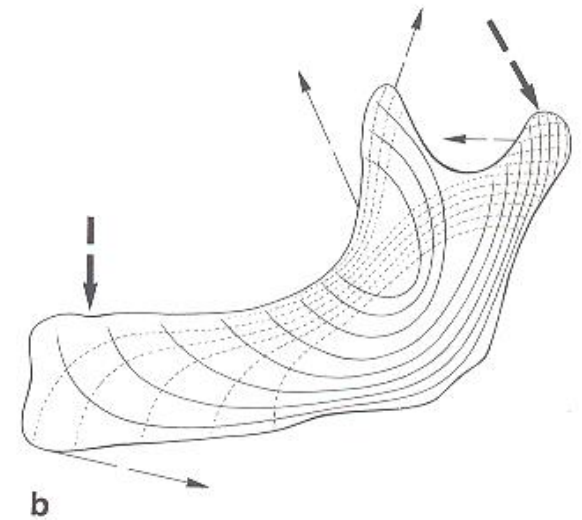
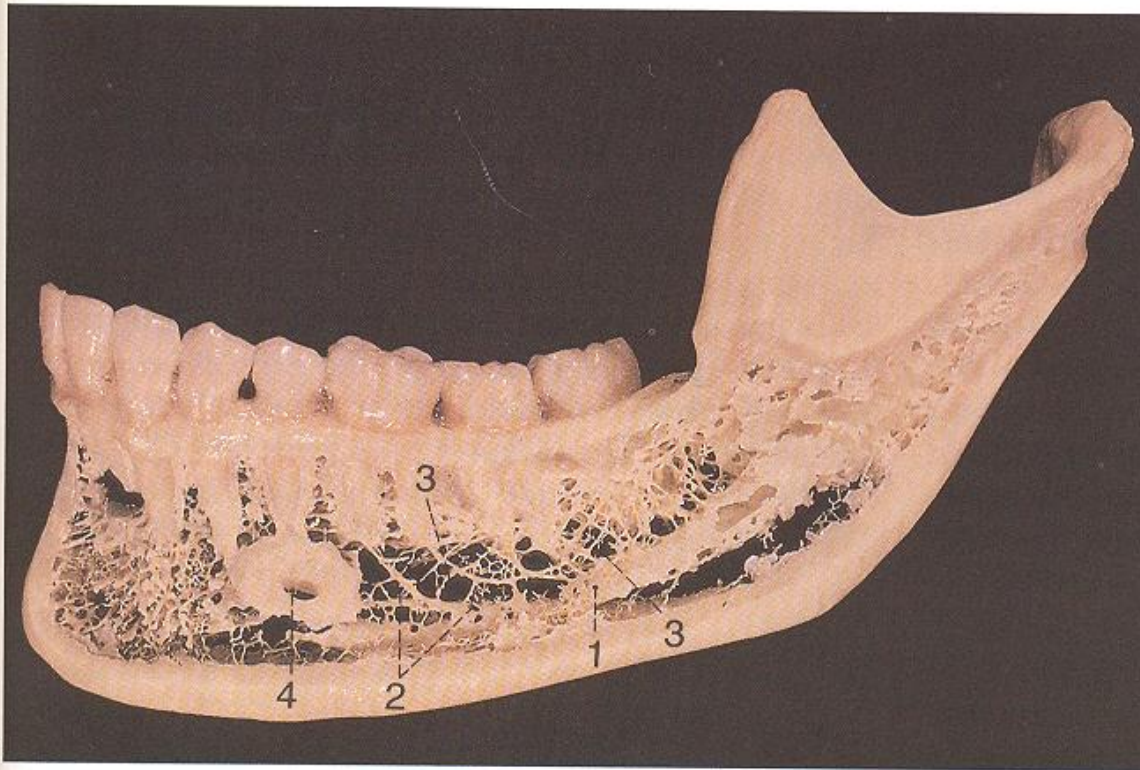
Achsen schneiden sich vor Foramen magnum



Alveolarbogen: Bogen der Zahnreihe;
 hinten ist enger als Kieferbogen → hintere Zähne mehr am Innenrand der Basis verlagert

Kieferbogen: Bogen der Basis mandibulae

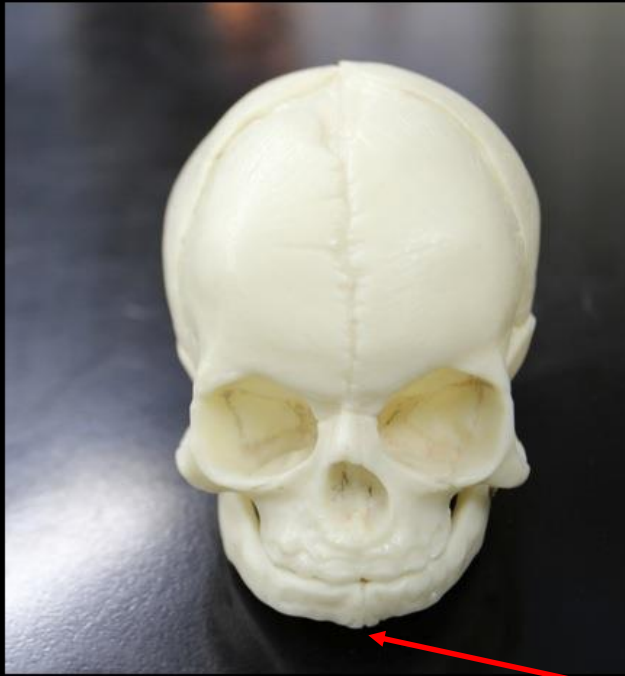
Trajektorieller Aufbau



————— Drucktrajektorien

- - - - - Zugtrajektorien

Neonatale Mandibula



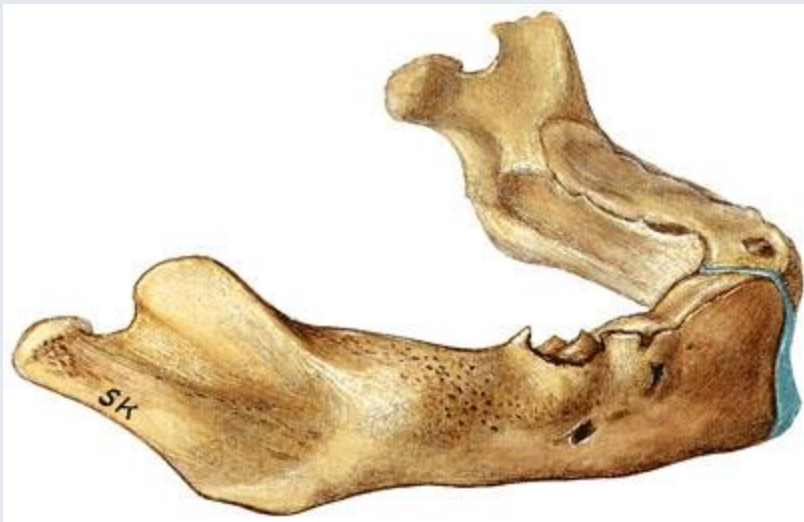Aus 1. Kiemenbogen (paarige Anlage
lat. vom Meckel-Knorpel),
desmale Ossifikation

Gelenkkopf: chondrale Ossifikation

Symphysis mentalis: verknöchert am
Ende des 1. LJ

Hier: Schaltknochen → beteiligen sich
an Tuberculum mentale

Angulus mandibulae: $\sim 150^\circ$

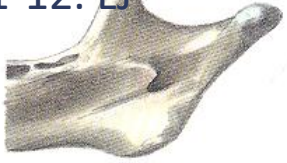


Säugling

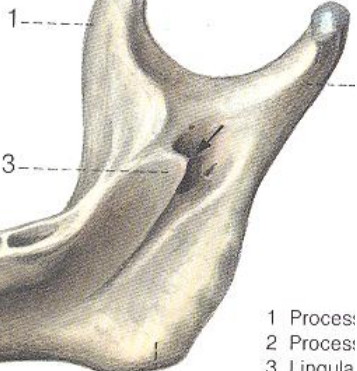
4-5. LJ



11-12. LJ



15-16. LJ



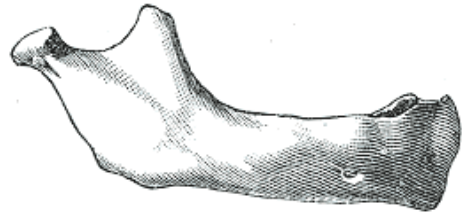
- 1 Proce:
- 2 Proce:
- 3 Lingula
- 4 Angulu:

Erwachsener

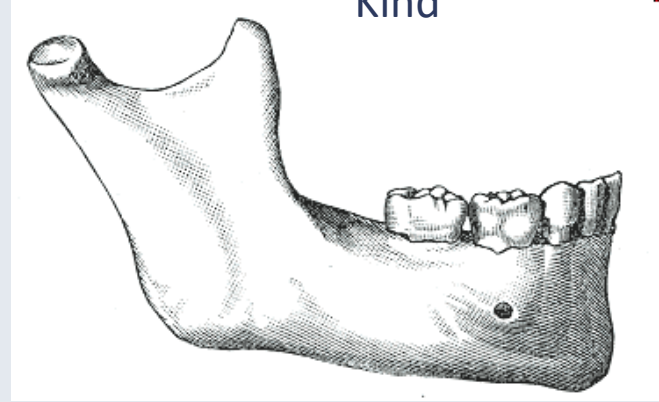
4

Änderung der Mandibula mit dem Alter

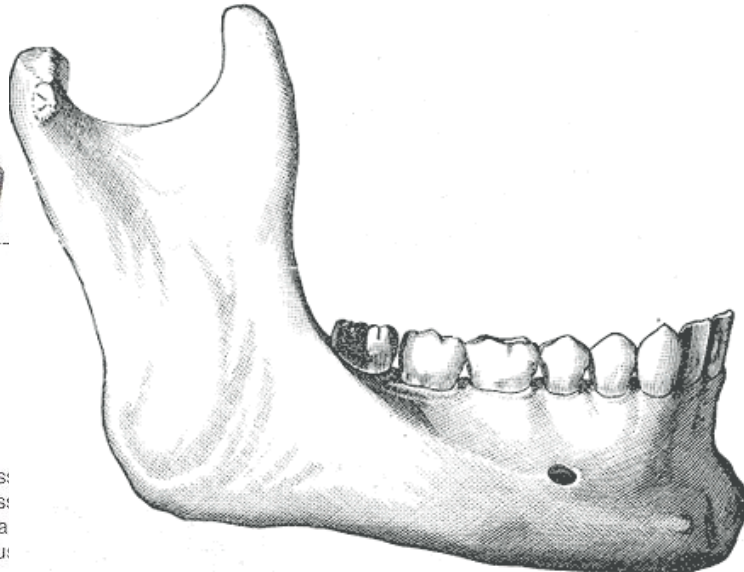
Säugling



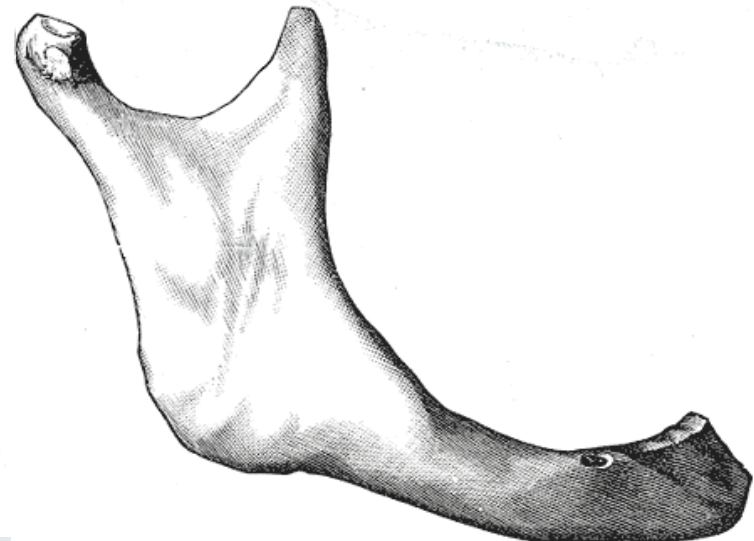Kind

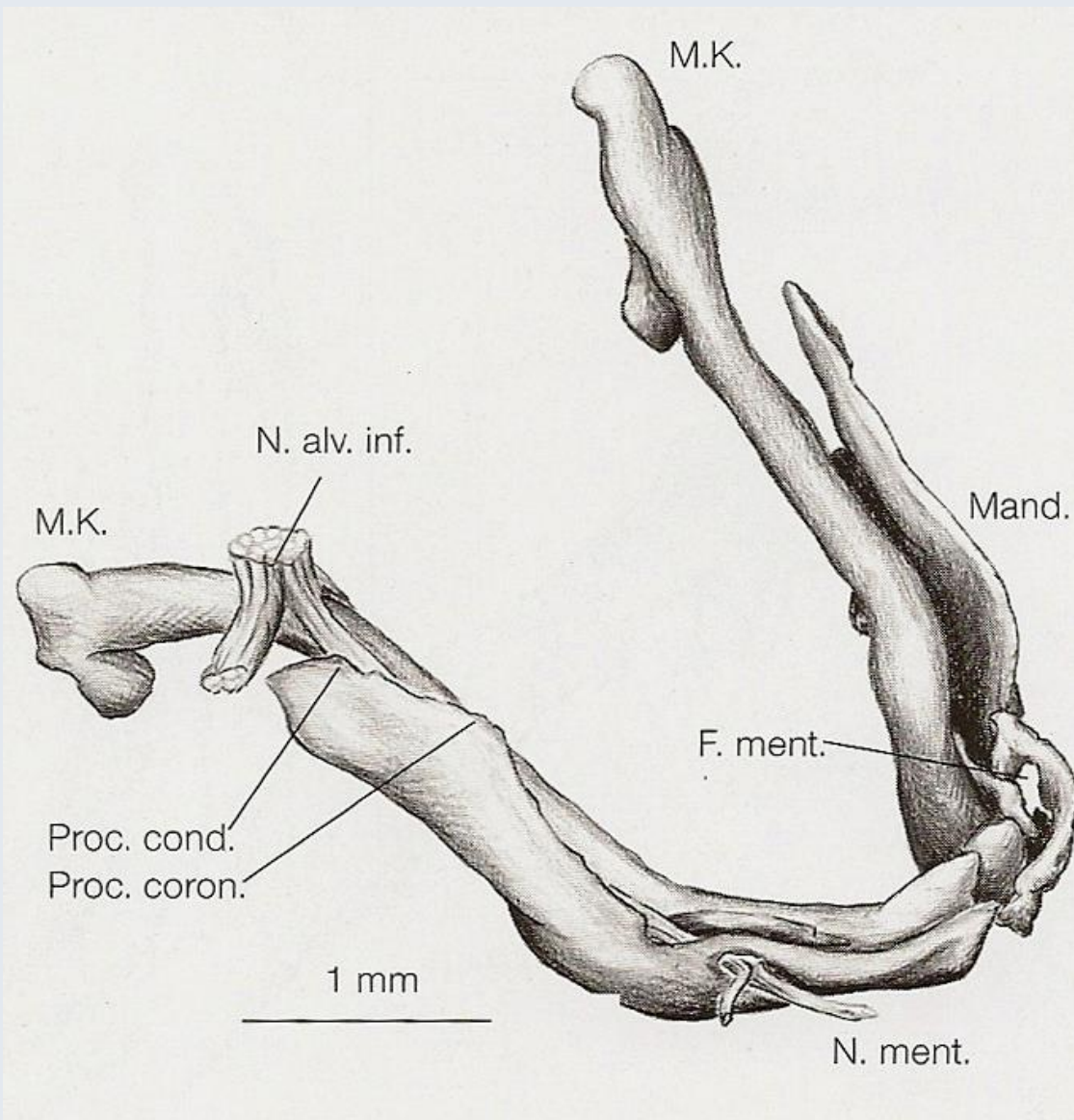


Erwachsener



Greis





Proc. coron.

Proc. cond.

M.K.

M.K.

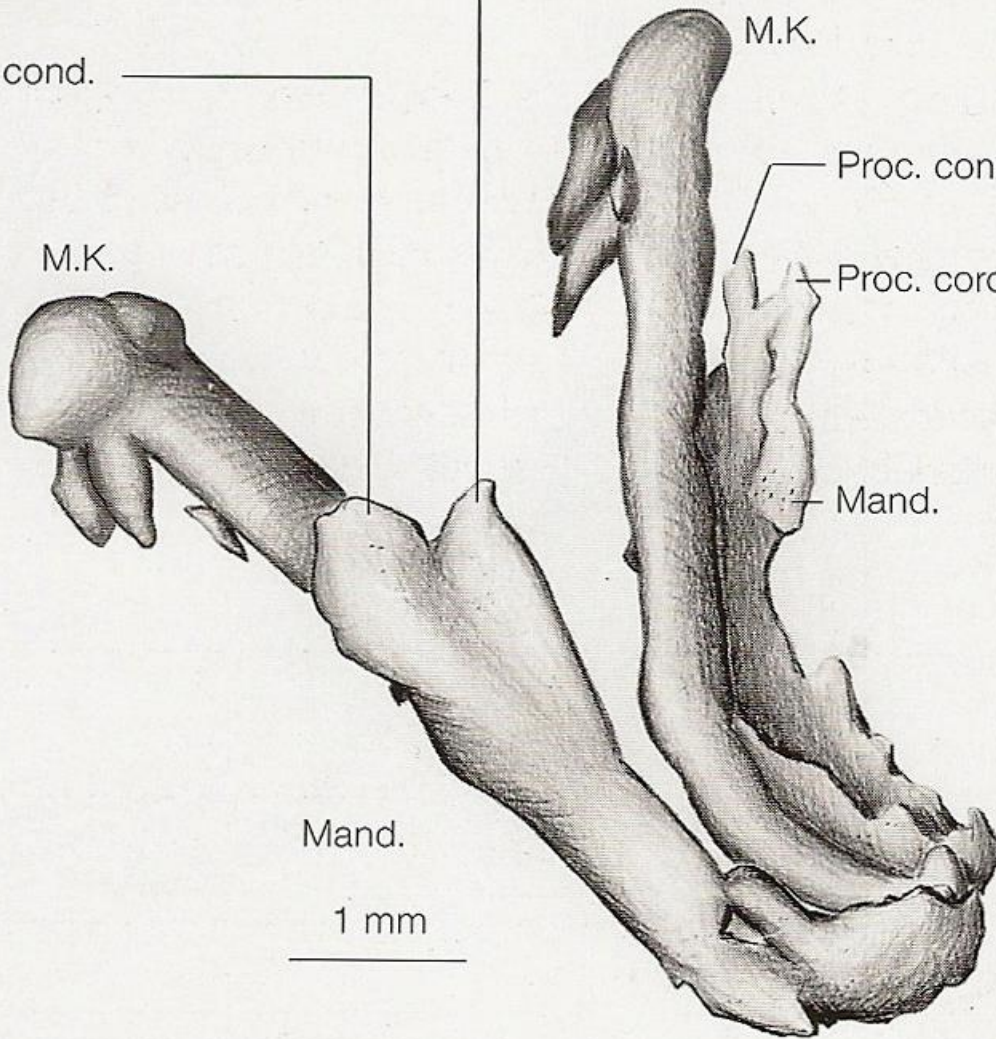
Proc. cond.

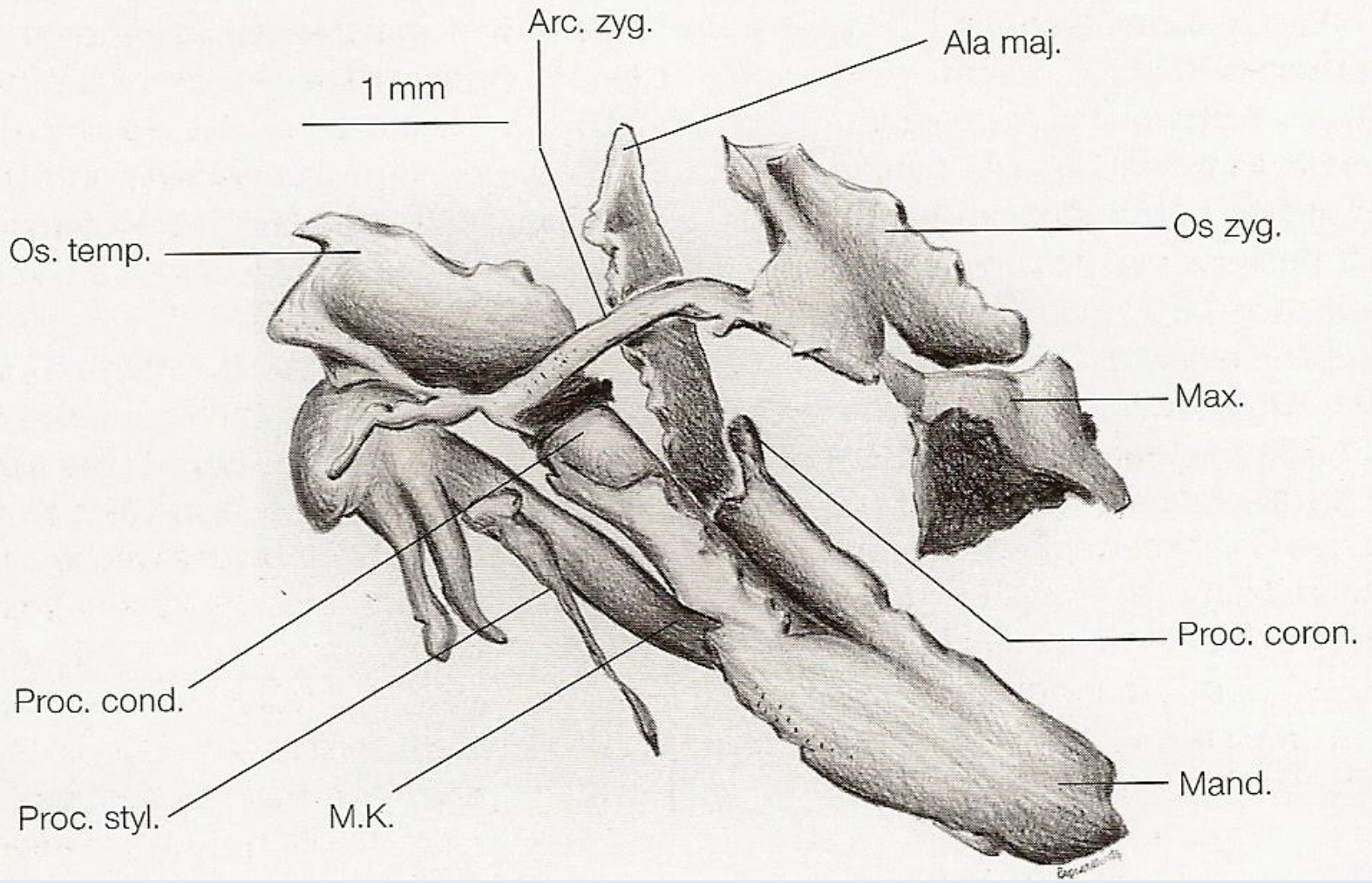
Proc. coron.

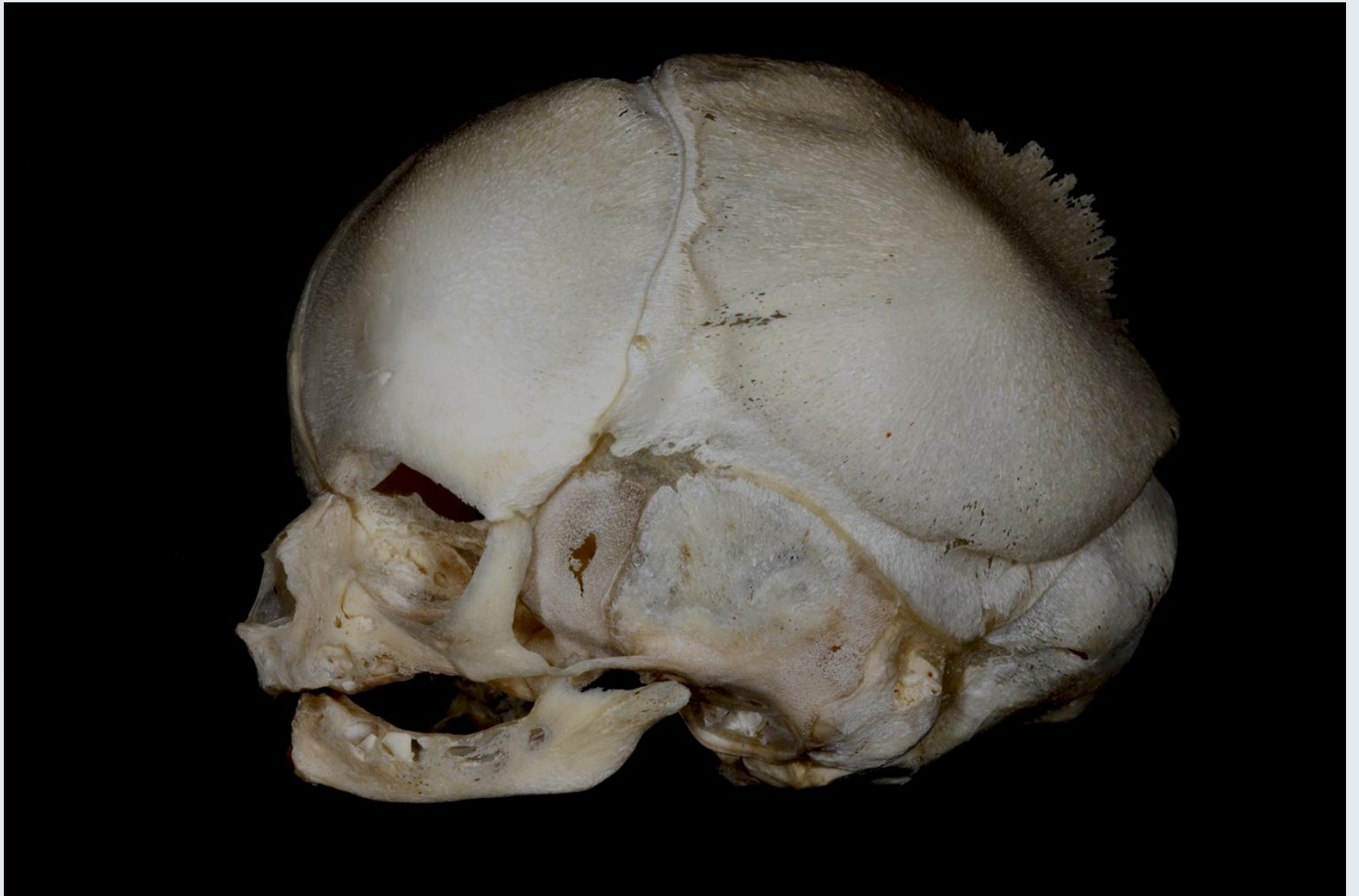Mand.

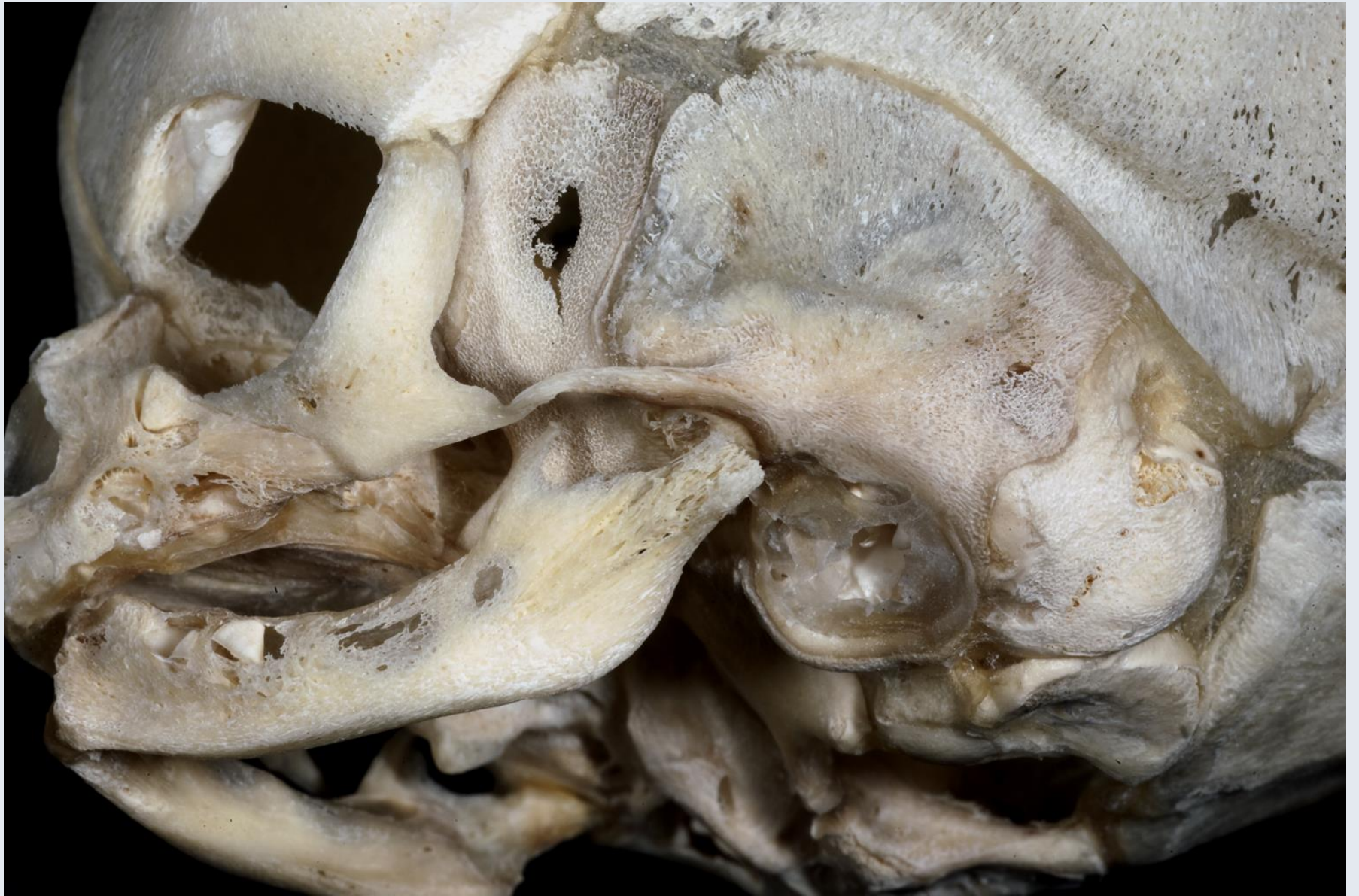Mand.

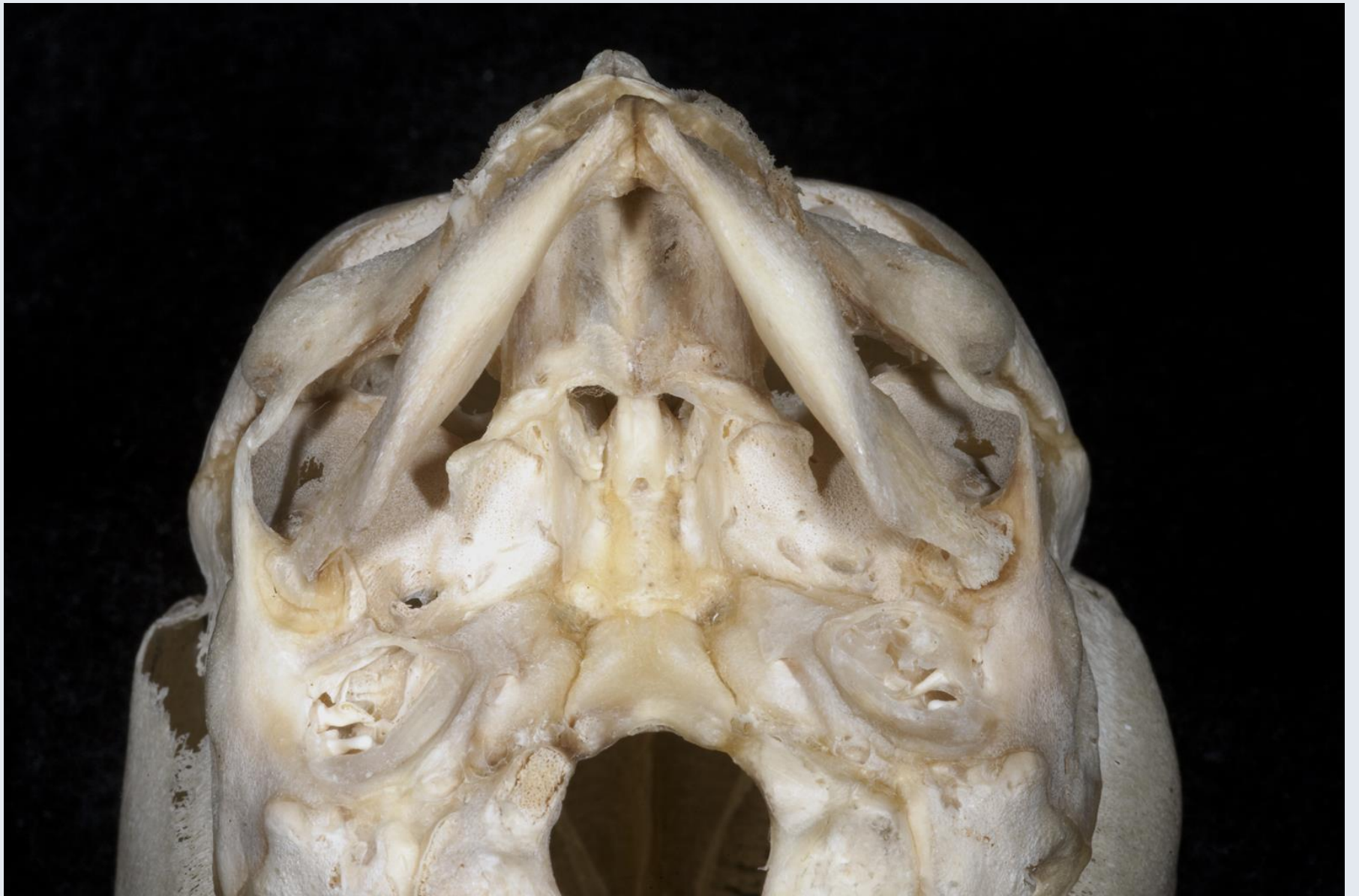1 mm







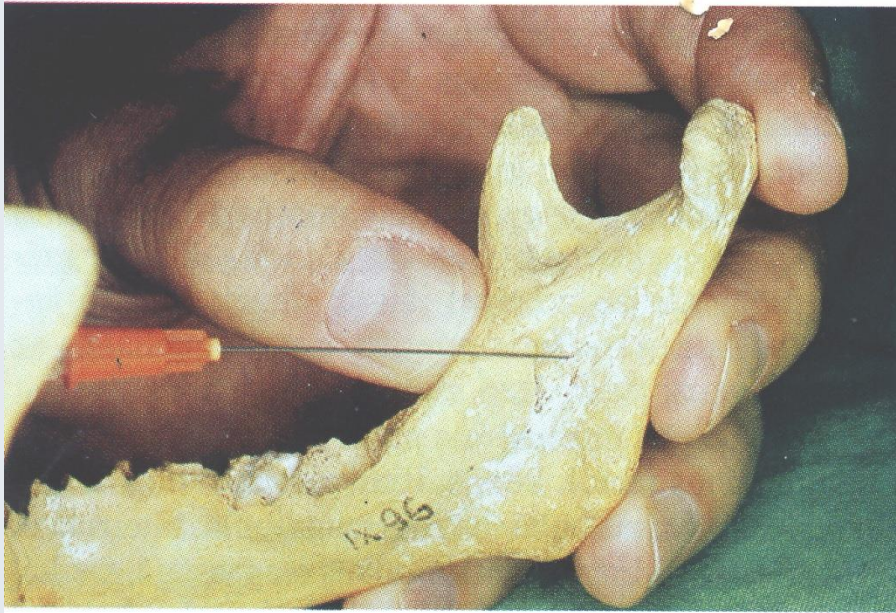



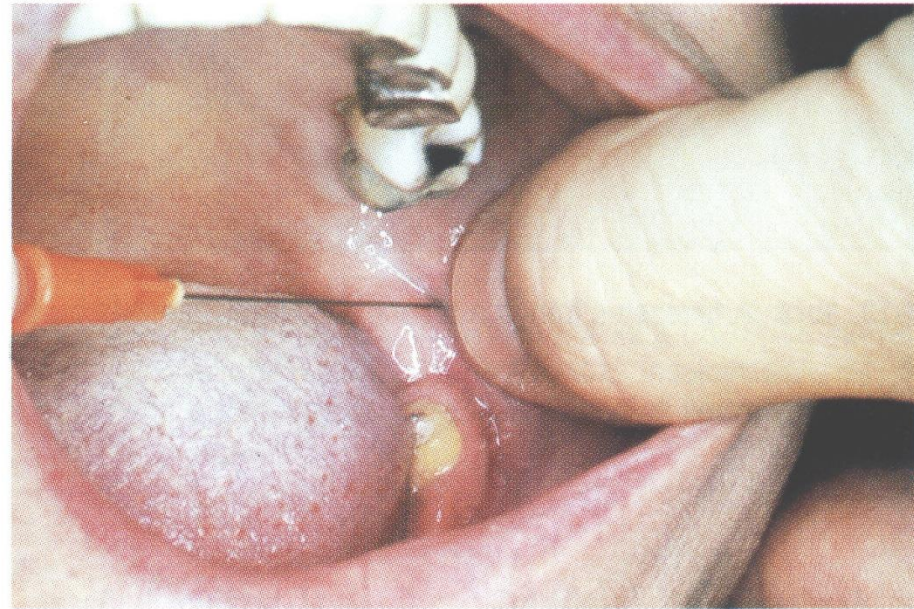
Klinische Aspekte ...

Anästhesie

Szokolóczy-Manöver

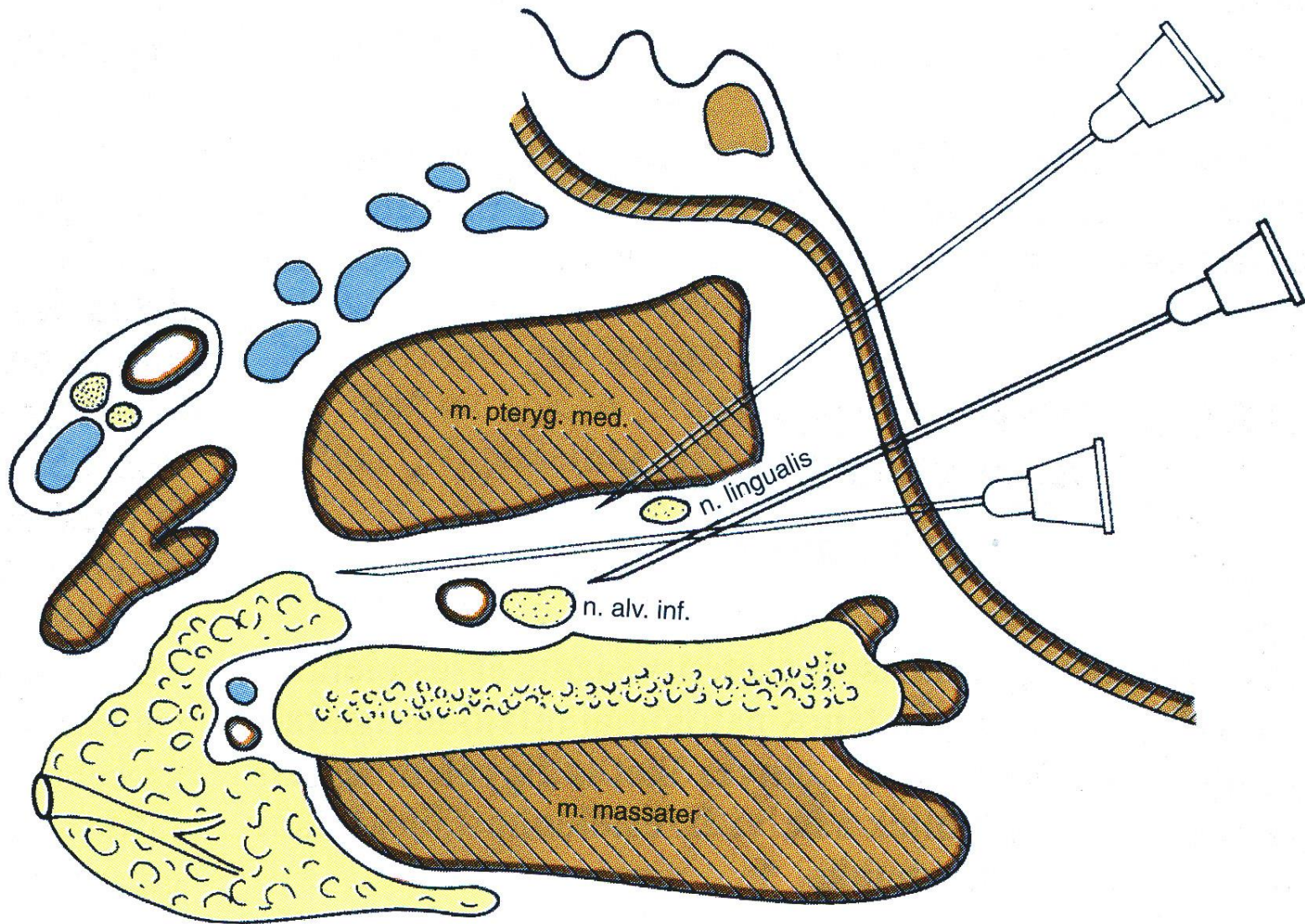


1-14. ábra A Szokolóczy-féle műfogás modellezése a mandibula belső felszíne felől nézve



1-15. ábra A tű beszúrásának a helye az alsó vezetékes érzéstelenítésnél

<https://www.youtube.com/watch?v=kmPqV-dMo98>



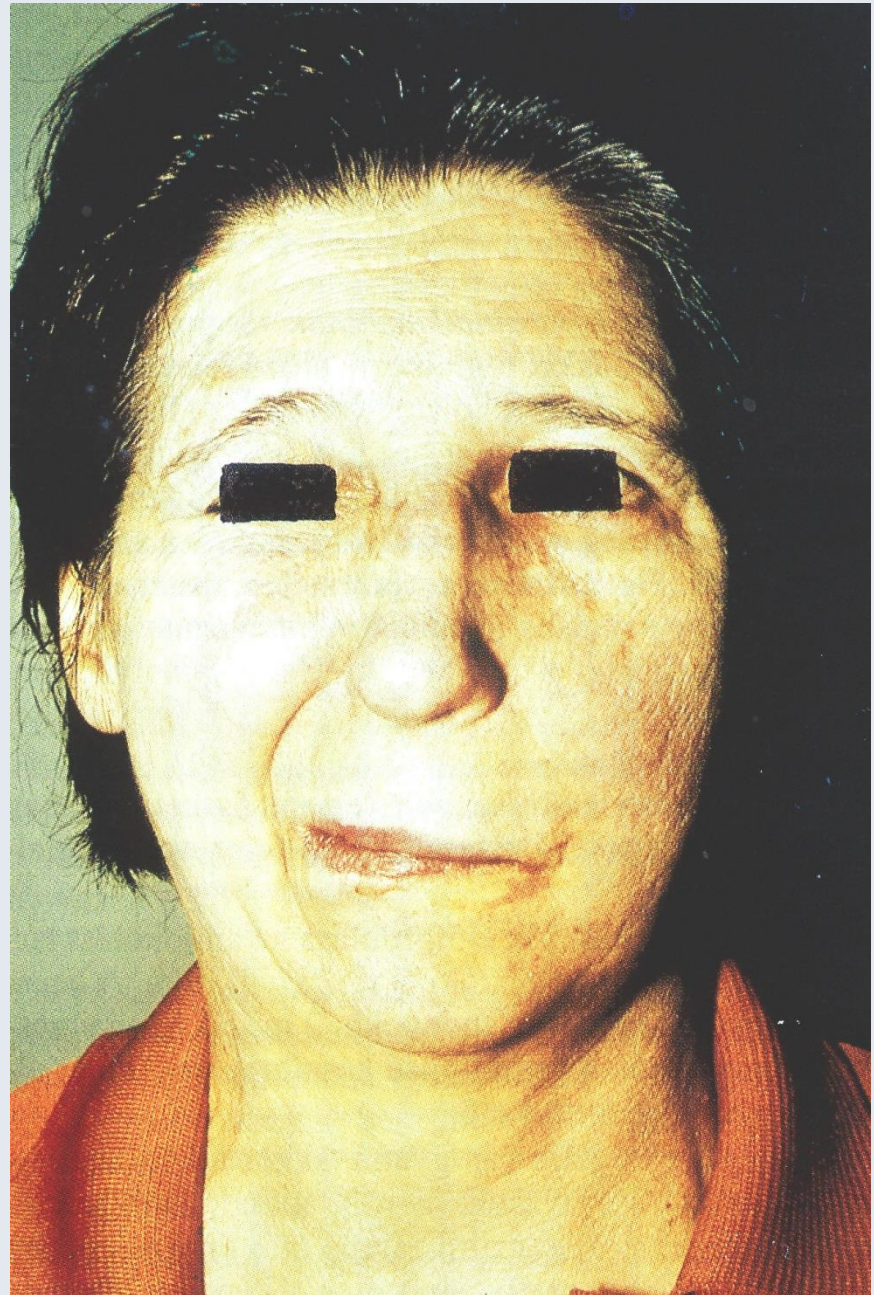Komplikationen

Allergie,

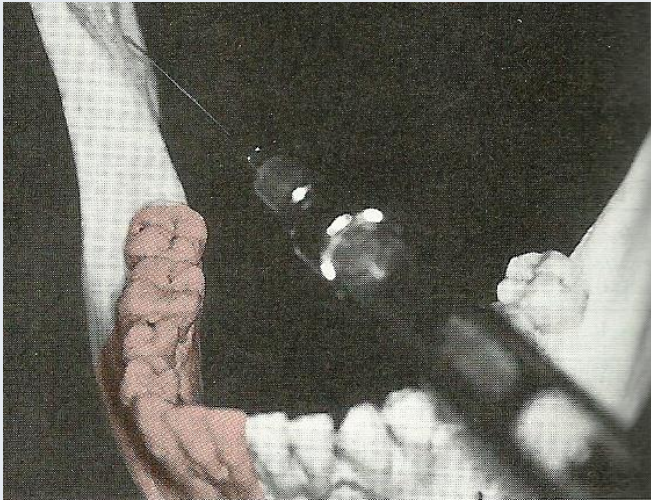
Hämatome,

N. Facialis Lähmung ,

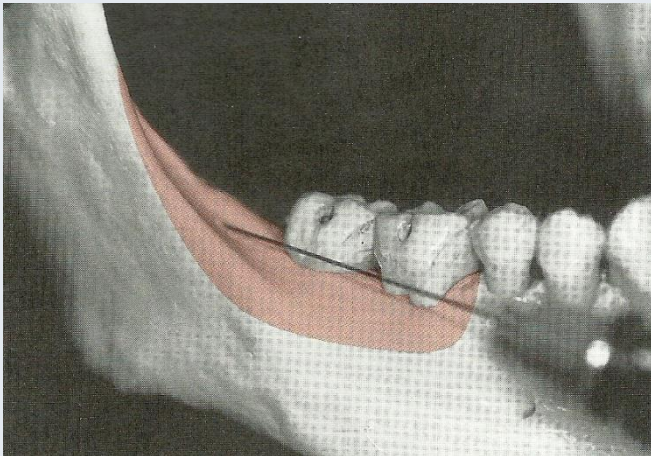
Nervenschädigung



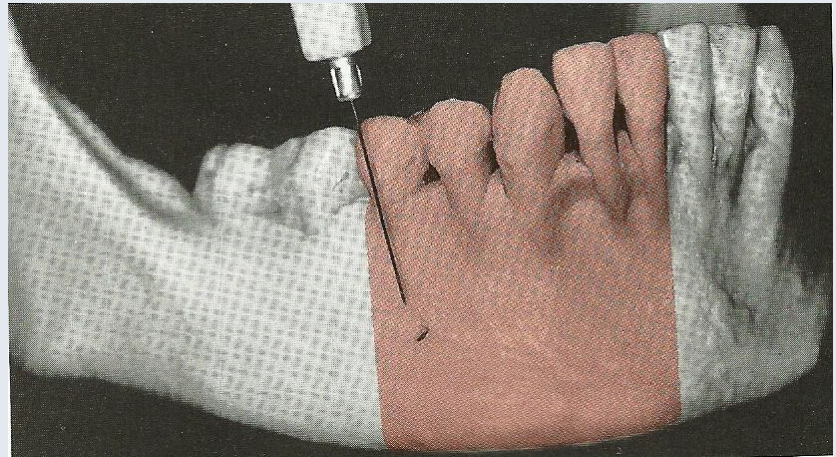
IA-block



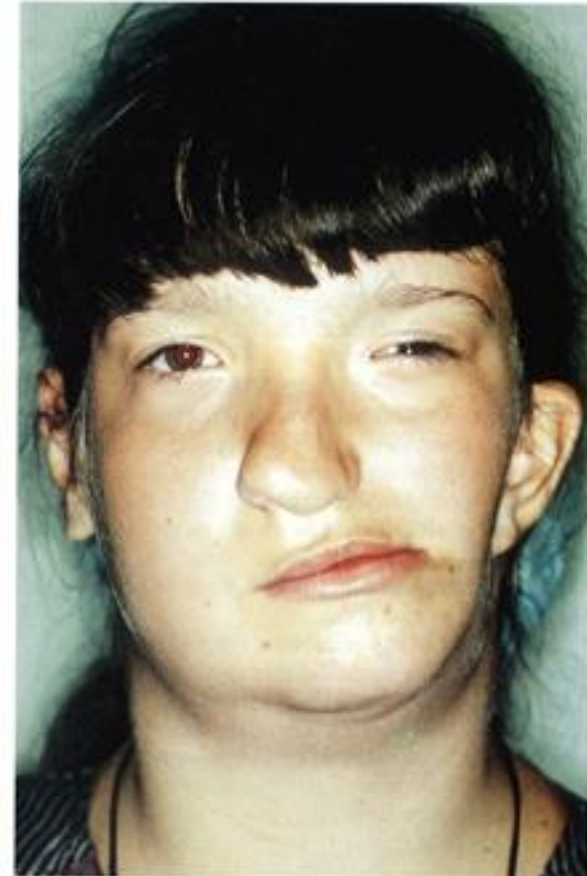
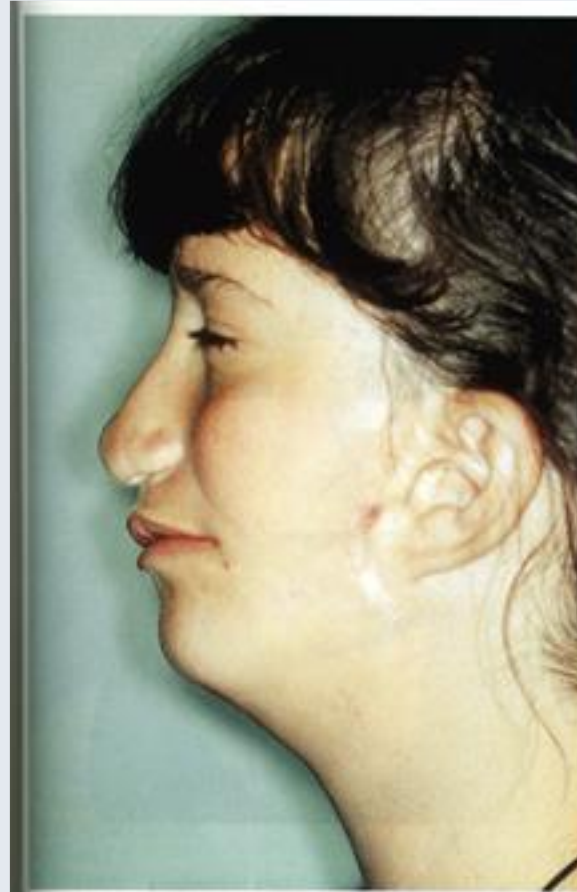Buccal-block



Mental-block



Störungen



Hemifaziale Microsomia

Torus mandibularis

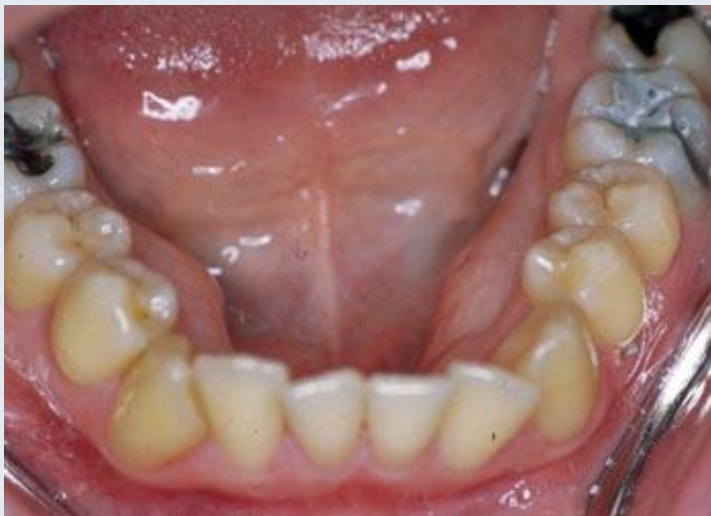
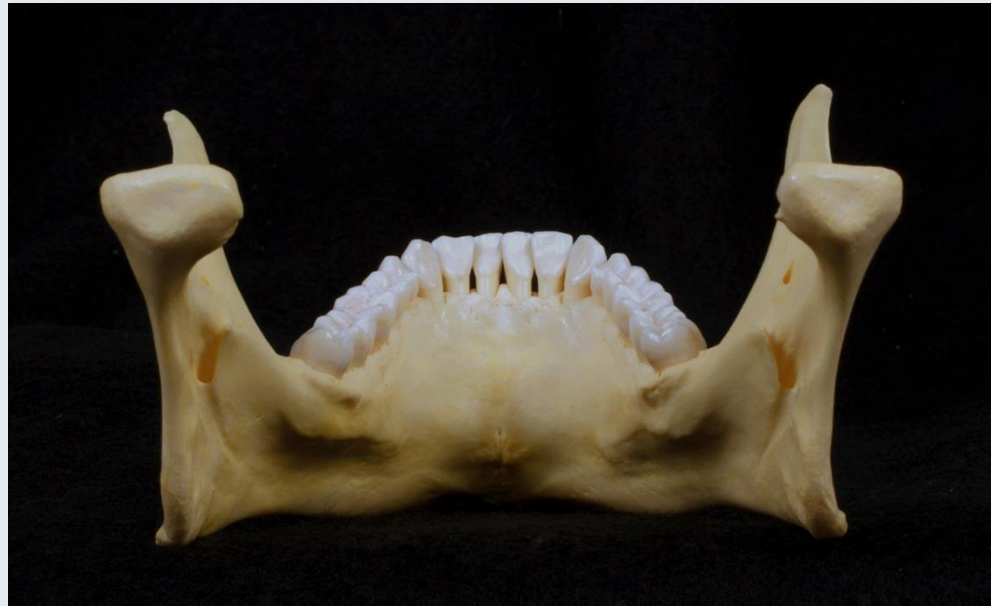
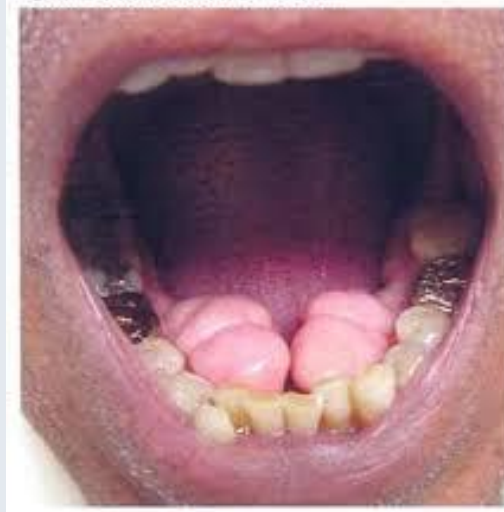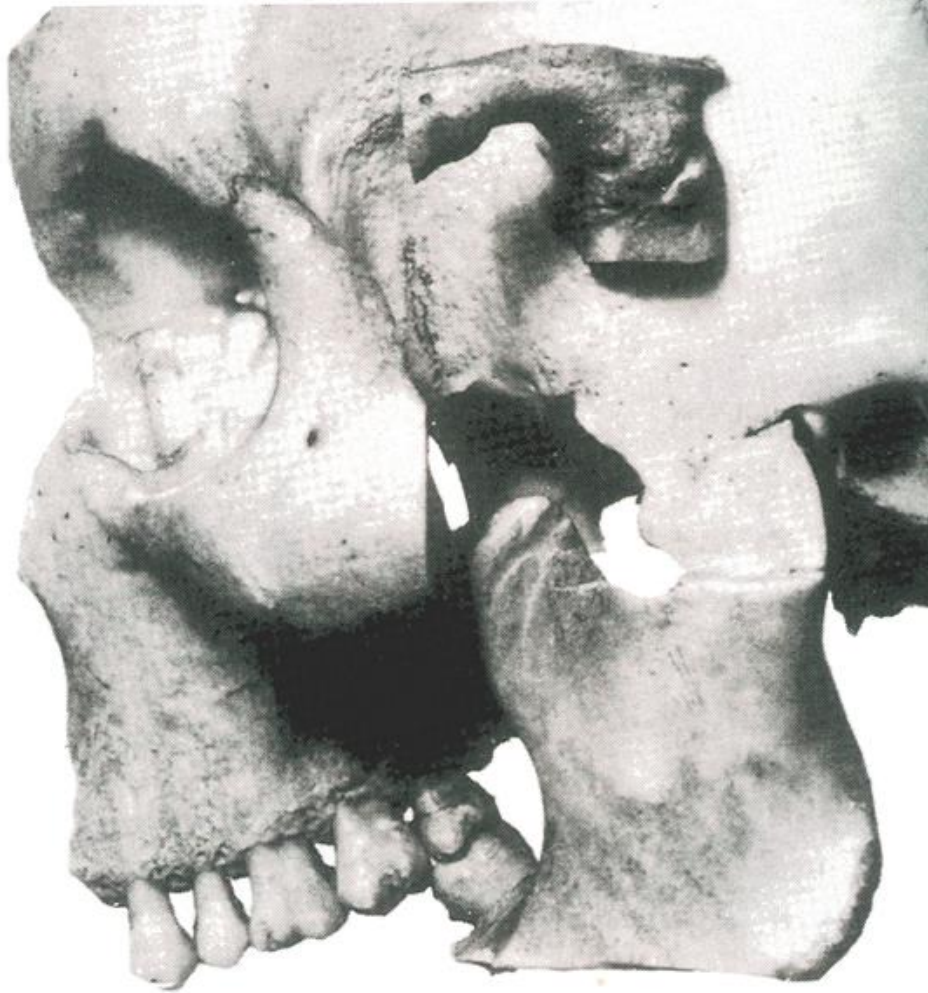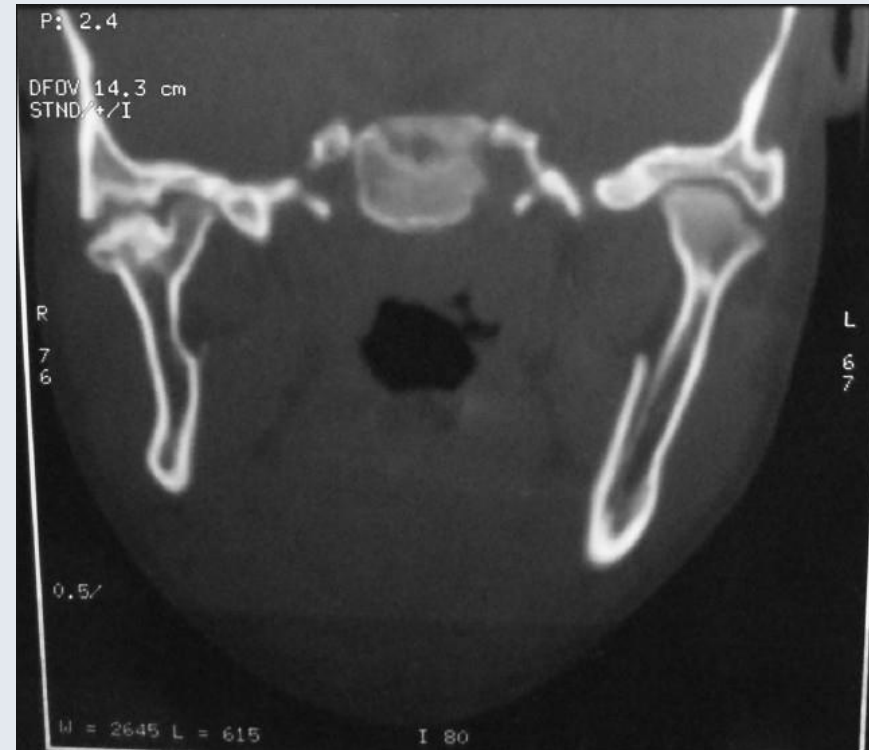Figura 2.- Torus Mandibularis Múltiple.



Ankylosis





Knöcherner Ankylose



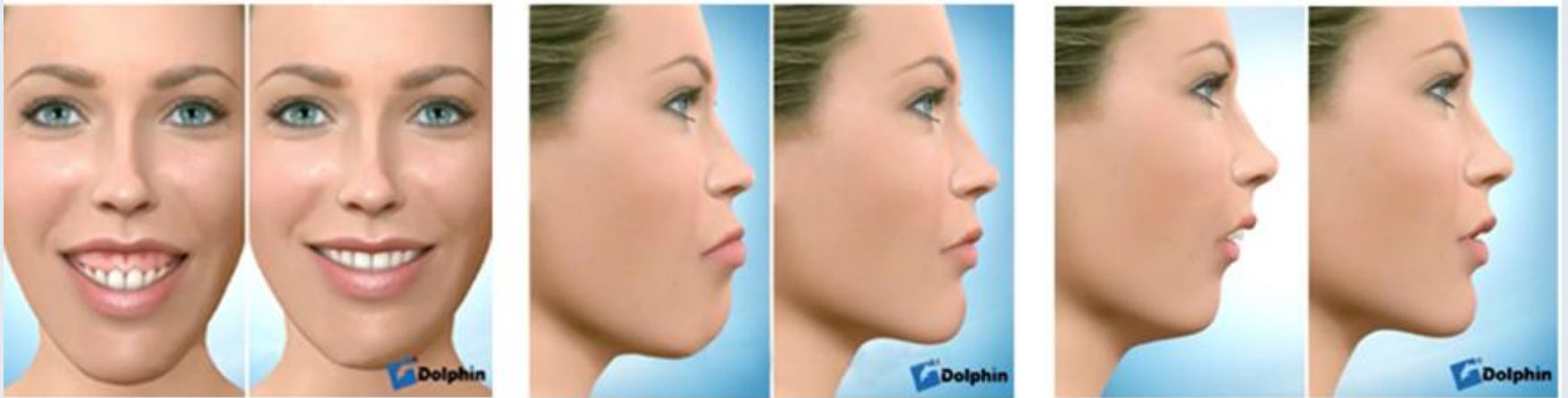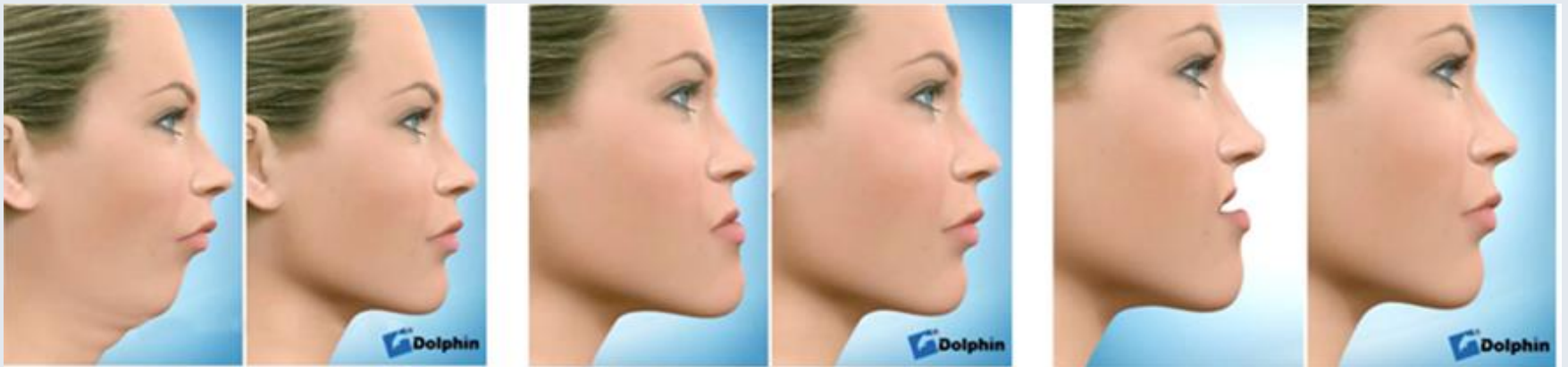Ursache: kongenital, Infektionen, Traumen

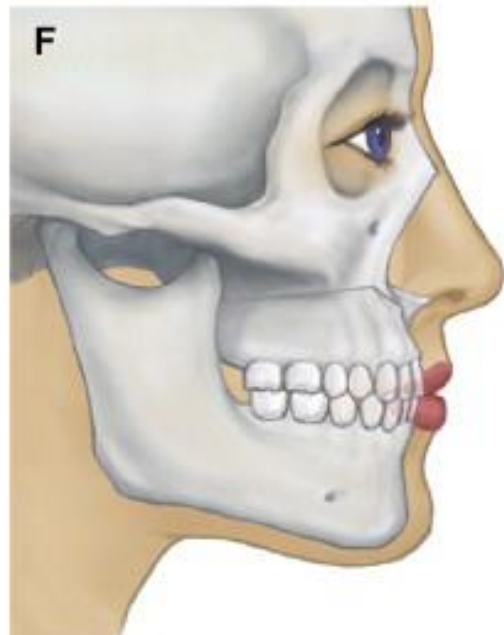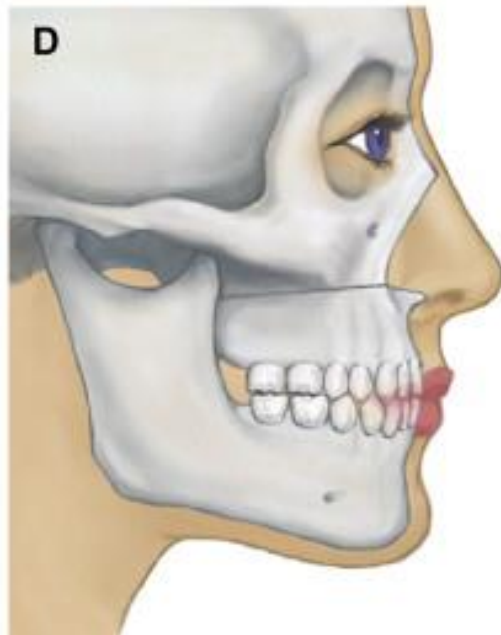
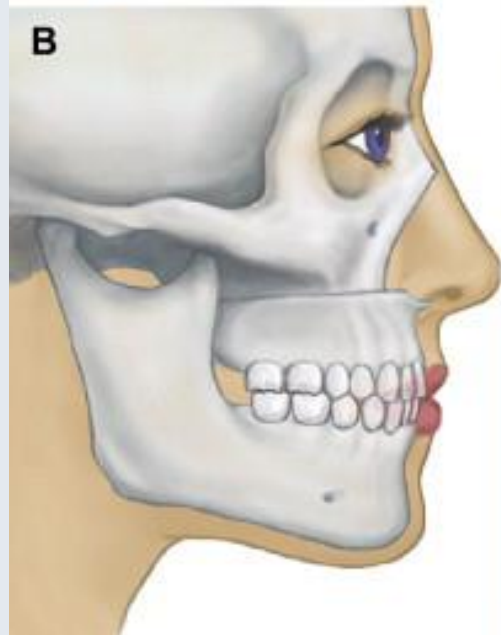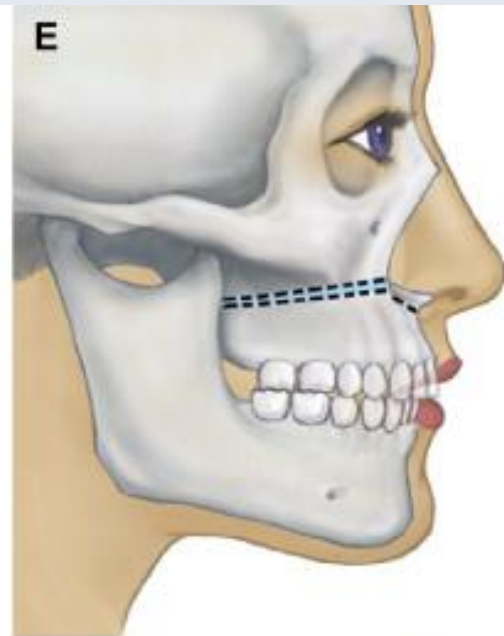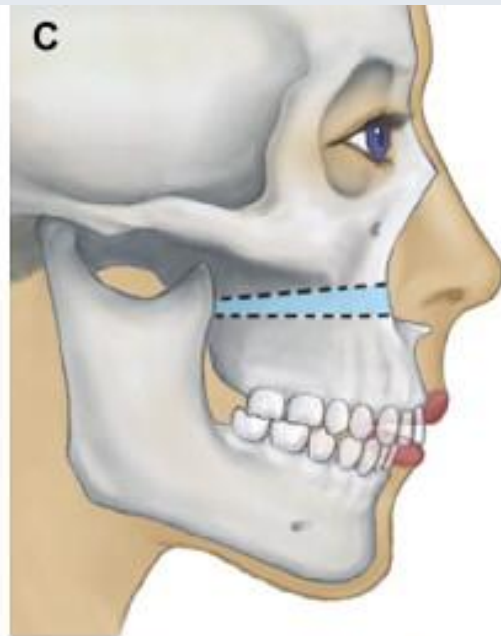
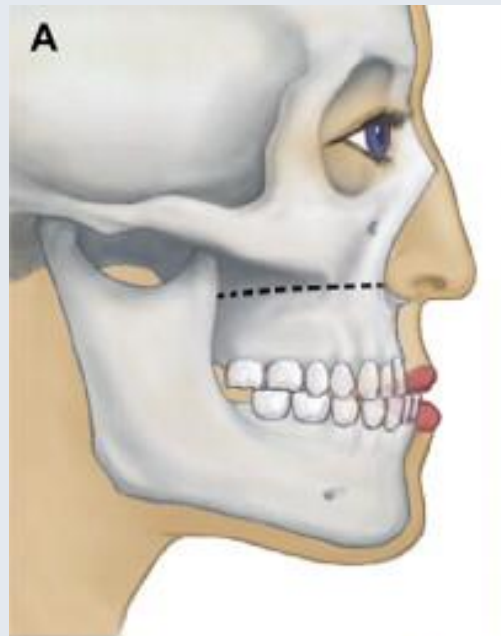
Prognathie

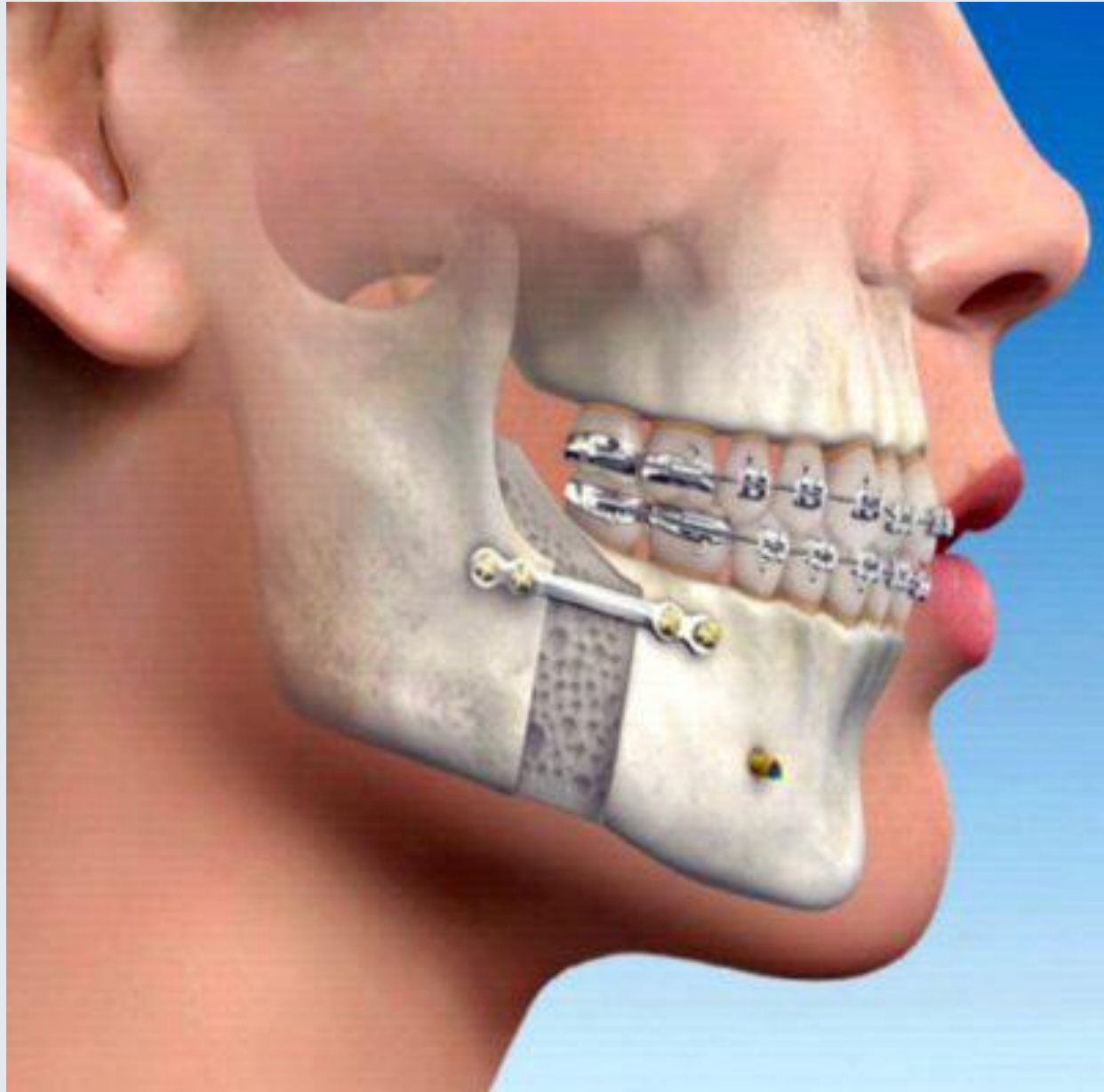
(Habsburg Jaw)

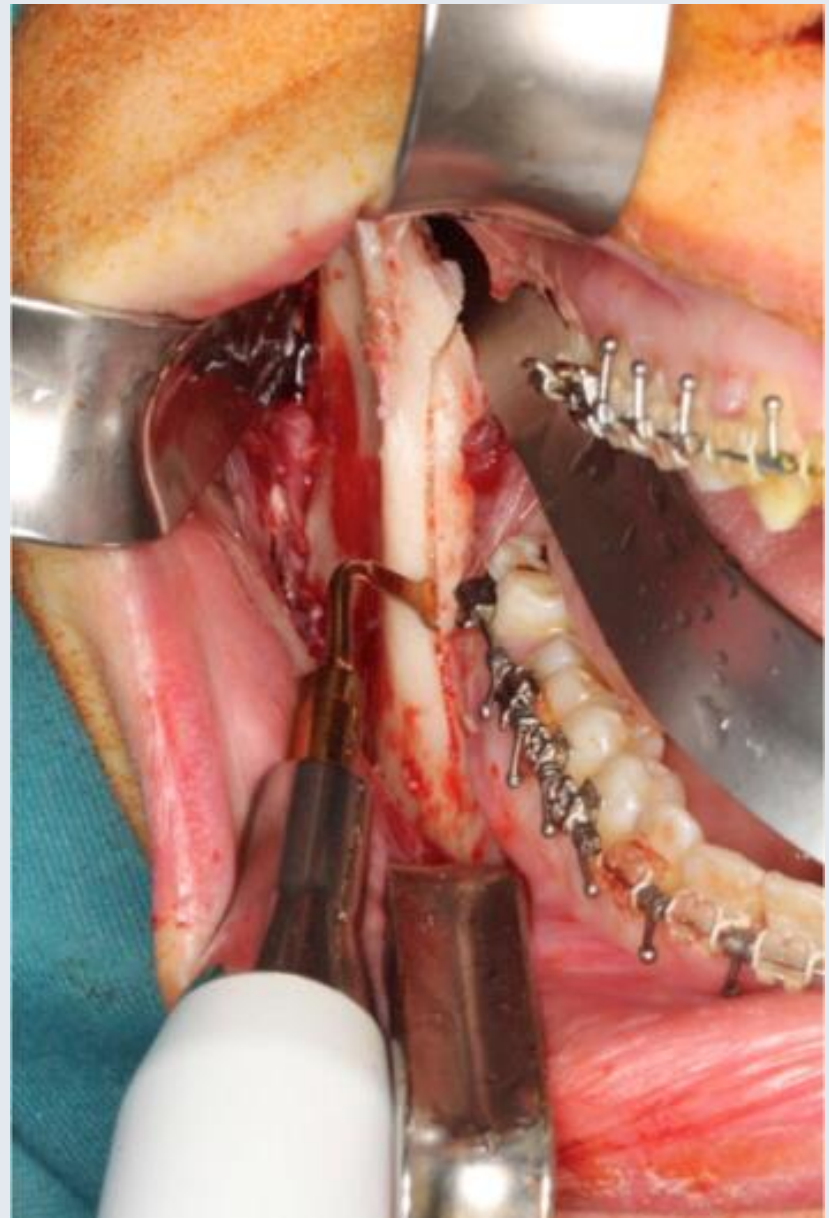
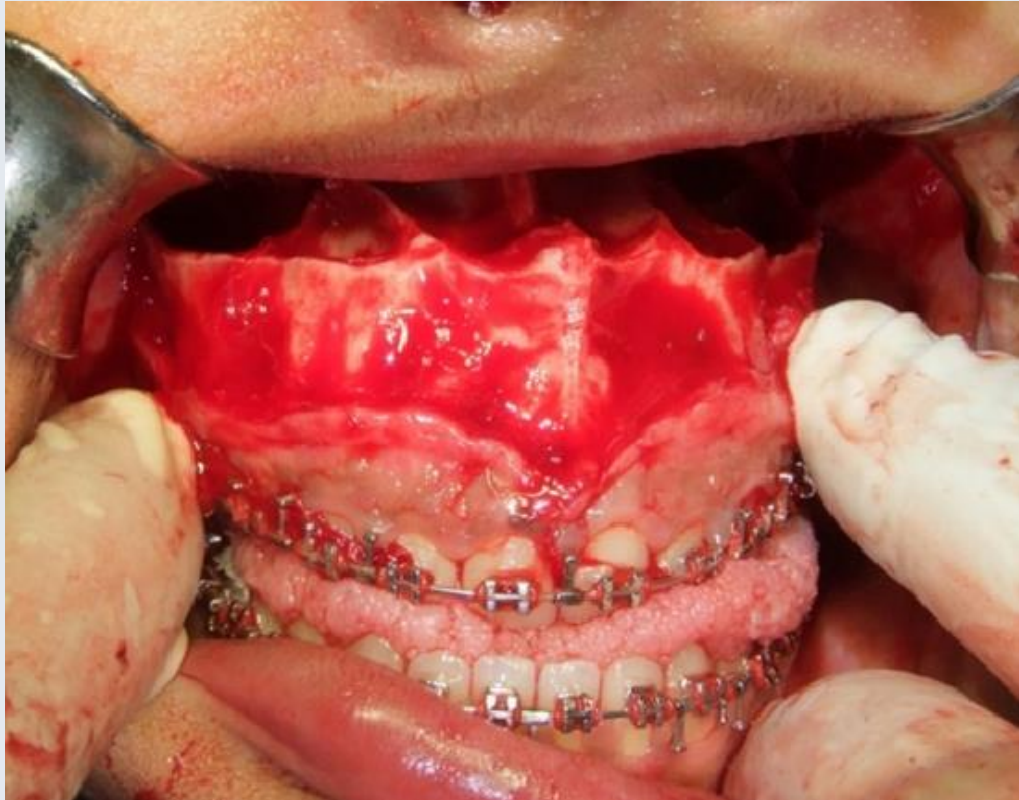

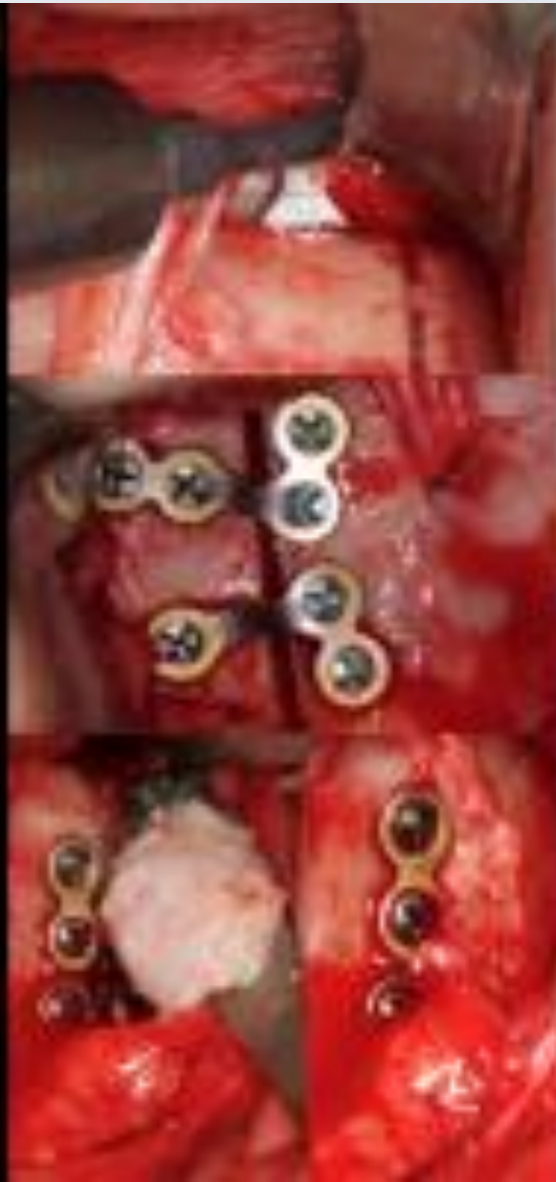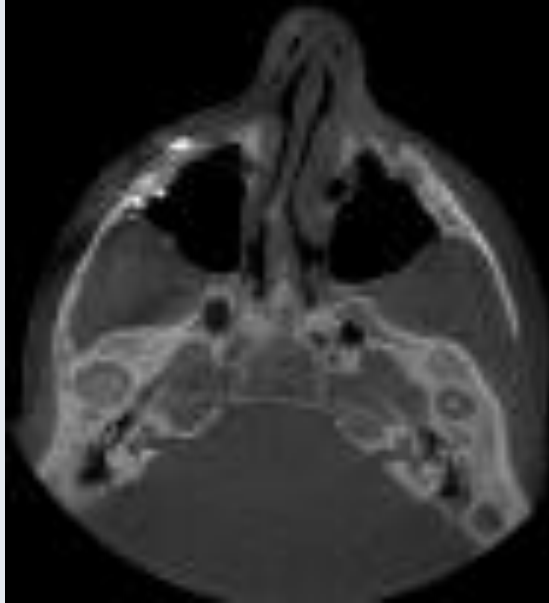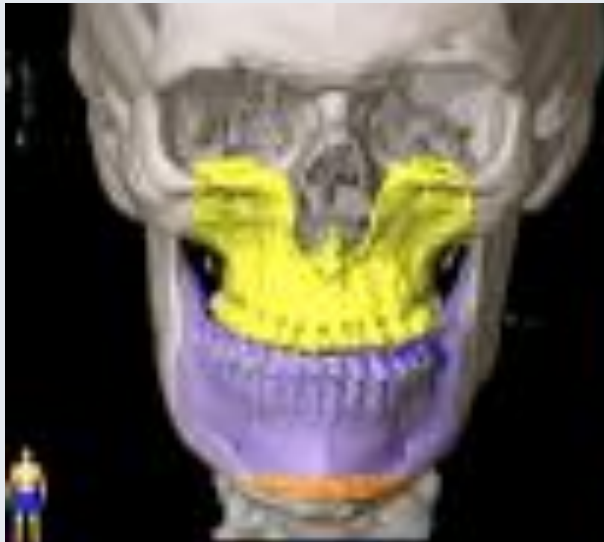
- <http://www.youtube.com/watch?v=b97T3v15cMk>



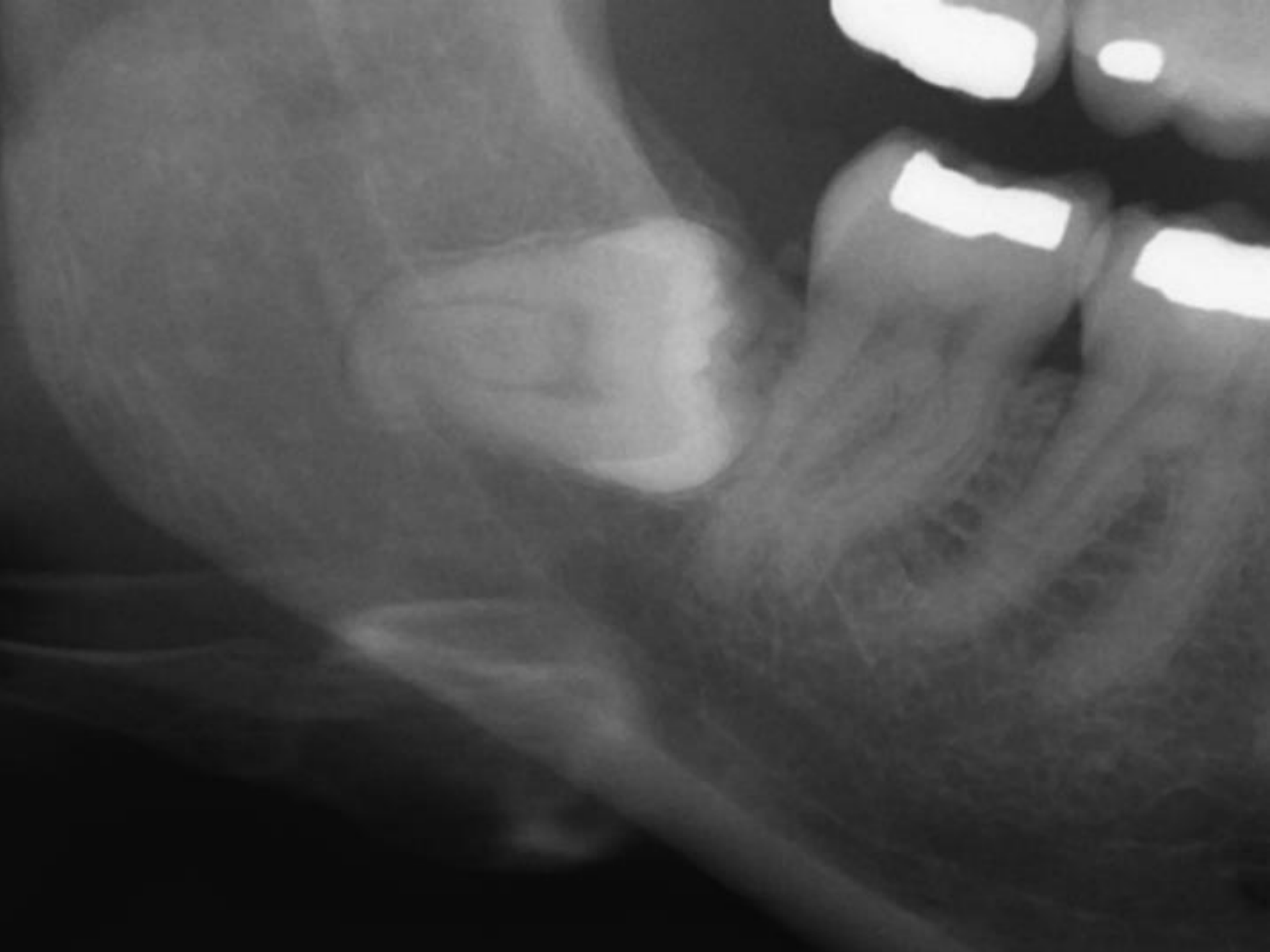



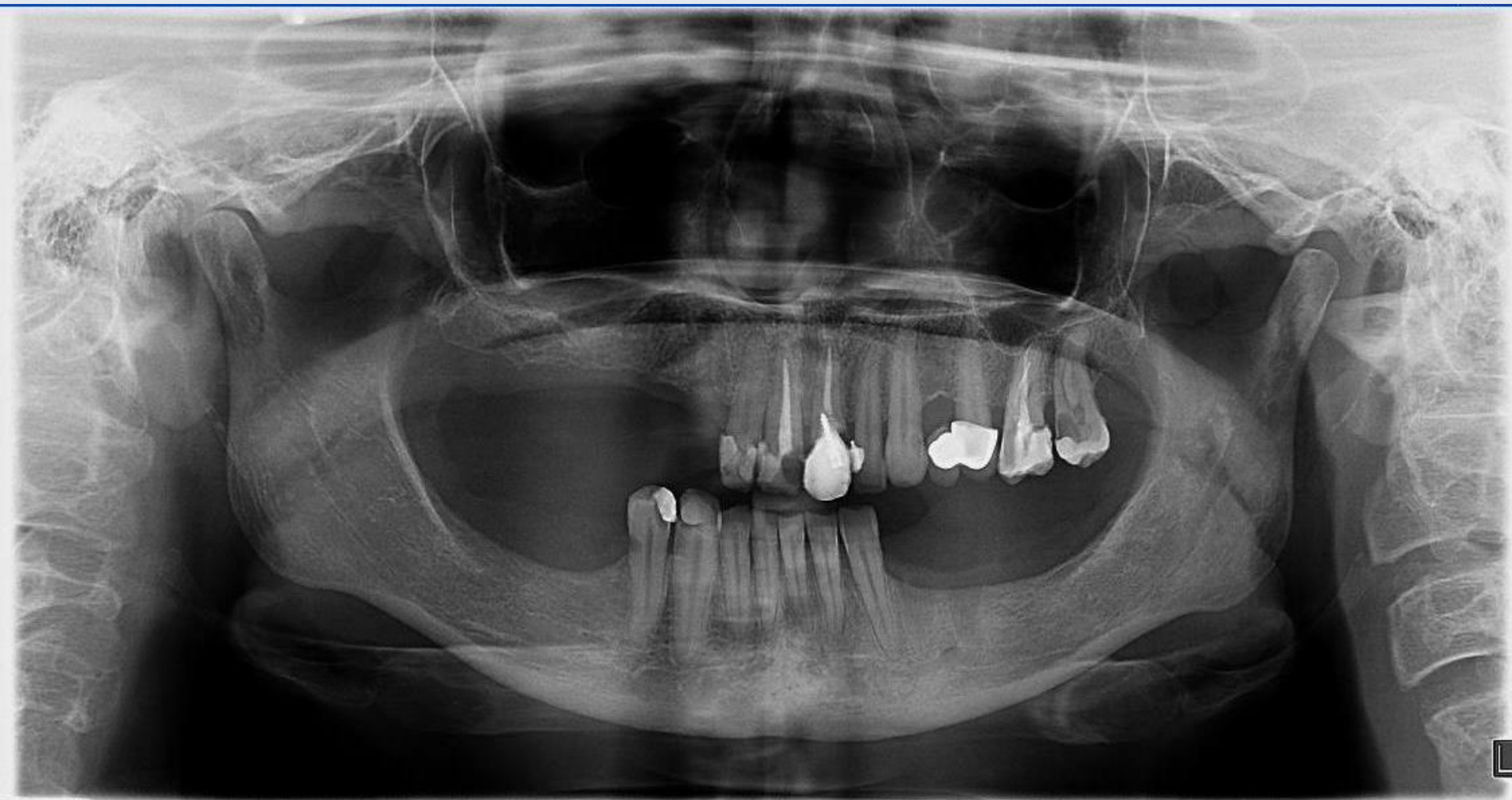




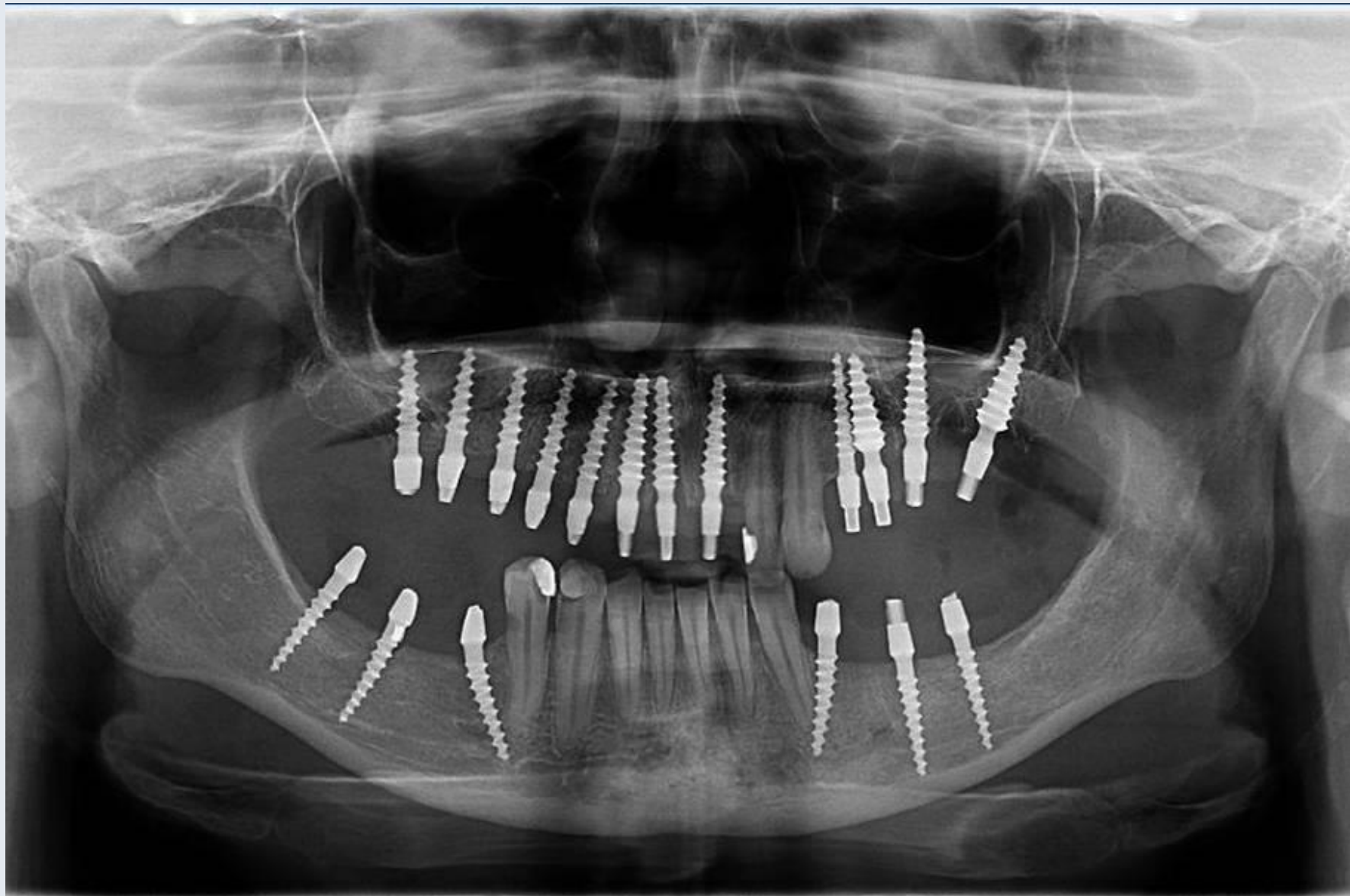
<http://www.youtube.com/watch?v=b97T3v15cMk>



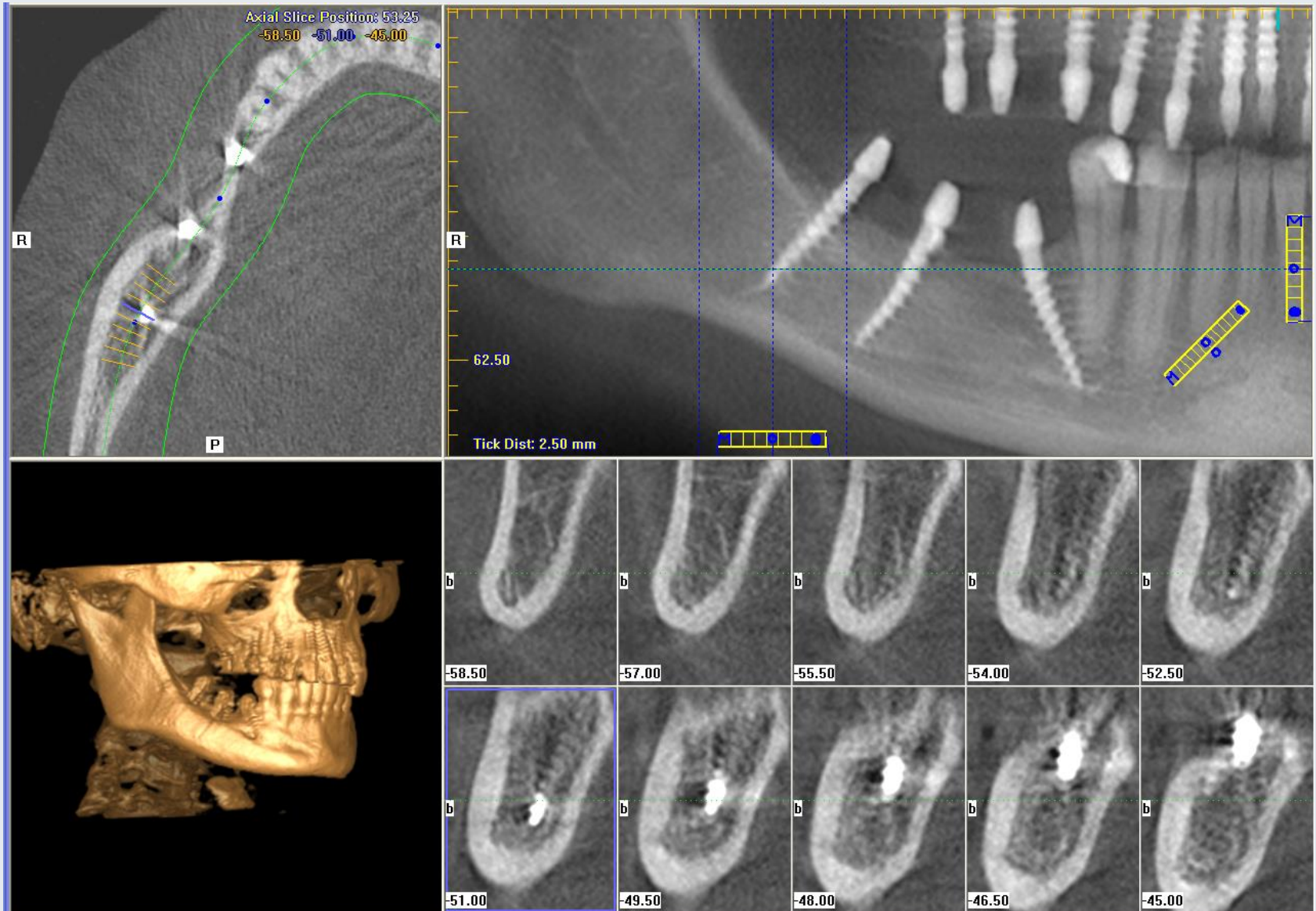Patient II.



Patient II.



Patient II.



Literatur und Danksagung

Faller: Anatomie in Stichworten – Ein Arbeitsbuch für Medizinstudente und praktische Ärzte (Ferdinand Enke Verlag 1980.)

Fehér: Maxillofaciális anatómia (Medicina Kiadó 2001.)

Pernkopf: Topographische Anatomie des Menschen. Lehrbuch und Atlas der regionär-stratigraphischen Präparation. (Urban & Schwarzenberg 1952.)

Sobotta: Az ember anatómiájának atlasza (Semmelweis Kiadó 1994.)

Szél: Klinikai anatómia (SOTE Képzéskutató 1999.)

Szentágothai – Réthelyi: Funkcionális anatómia (Medicina Kiadó - Semmelweis Kiadó 1996.)

www.almanahmedical.eu

www.hc-bios.com

www.mng.hu

Knochenpräparate in der Vorlesung: Dr. Lajos Patonay

Panoramaaufnahmen: Florian Dental – Dr. Sándor Kovách