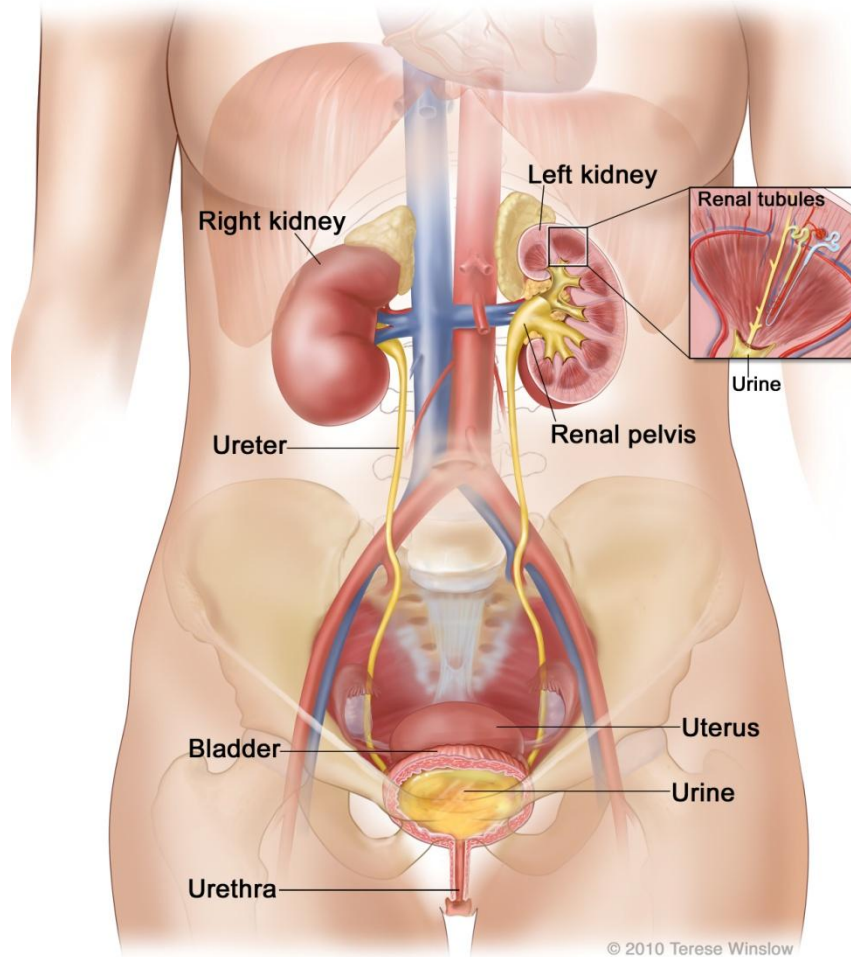
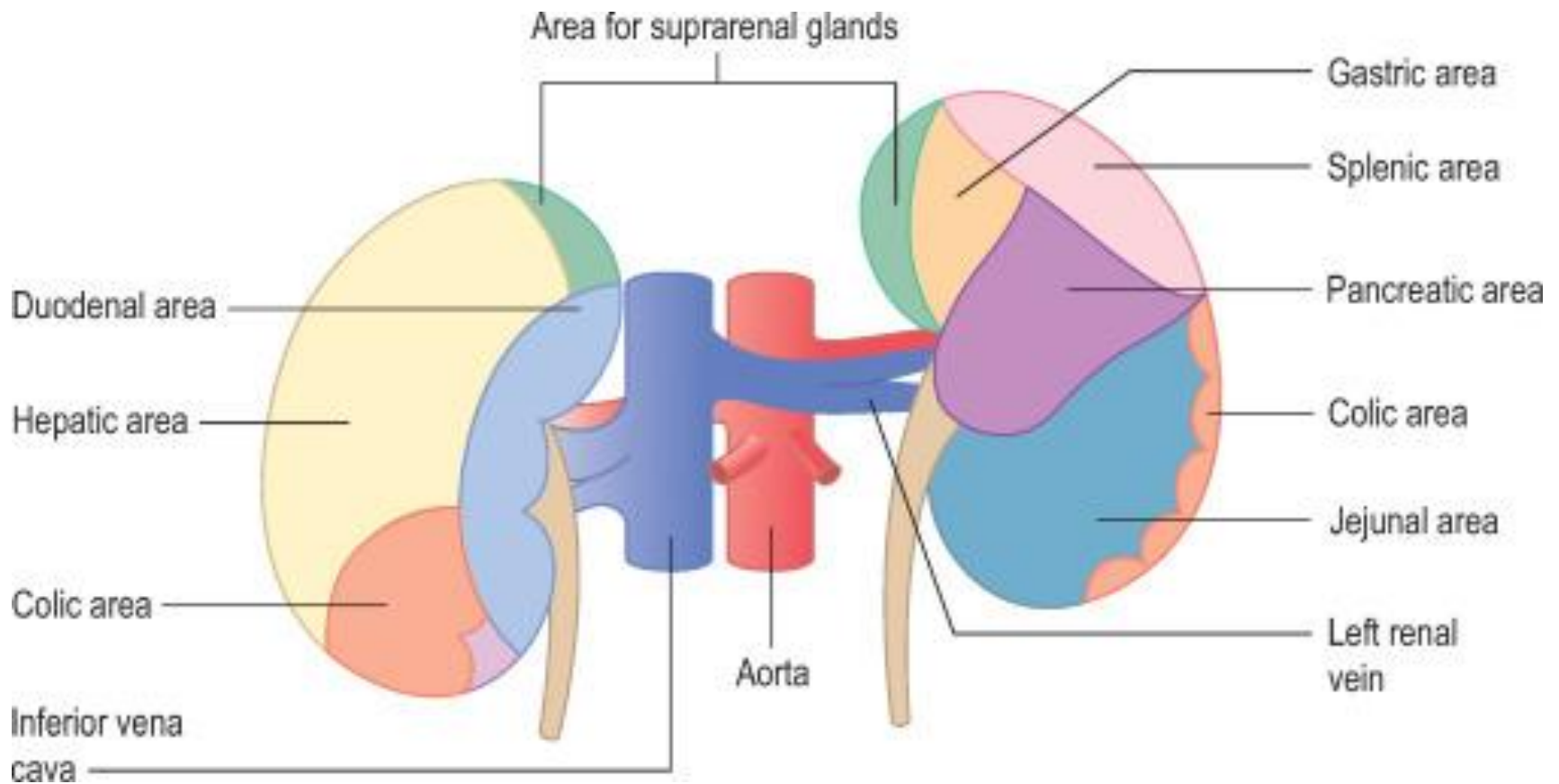


# Vese, ureter, húgyhólyag

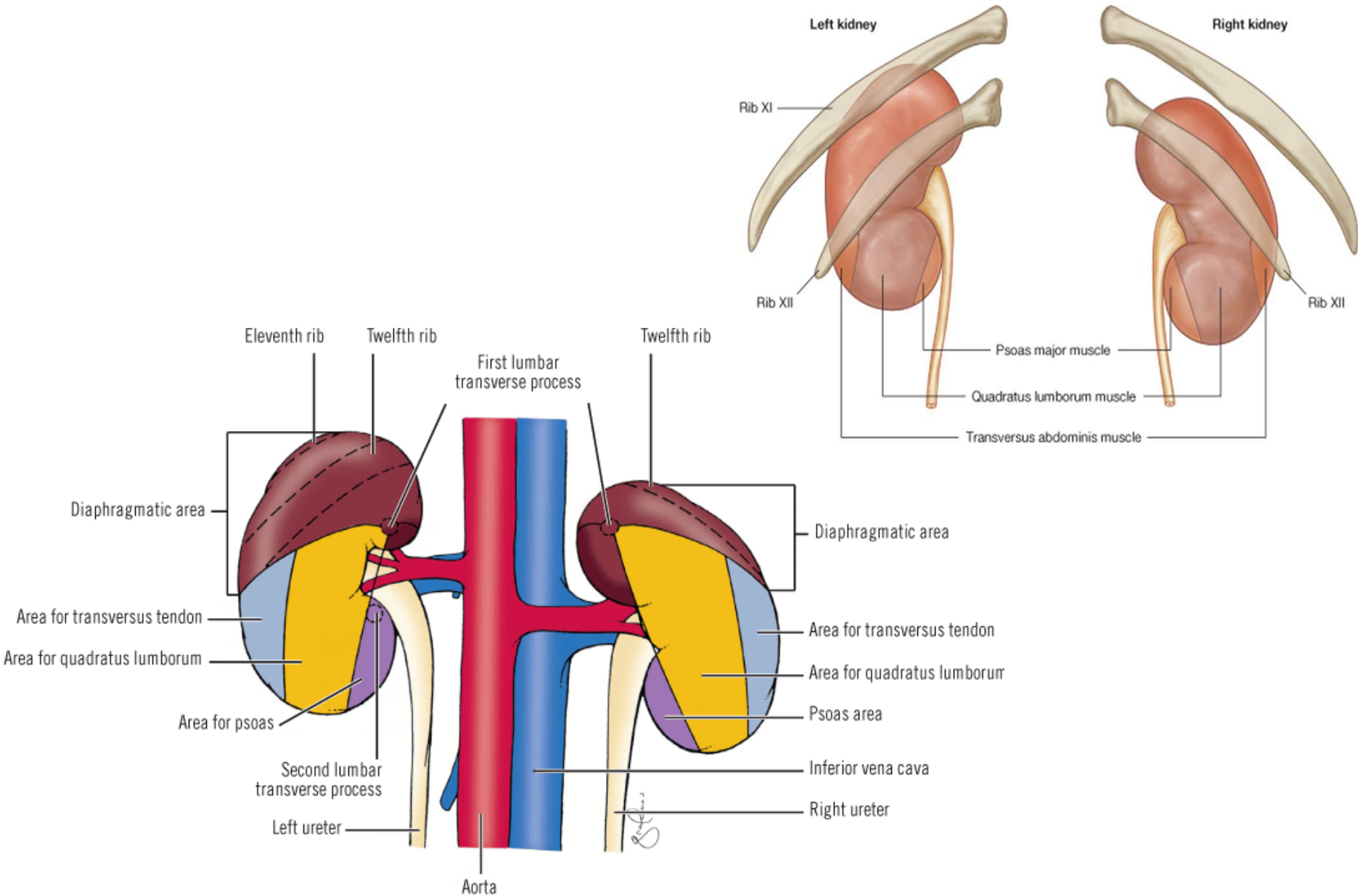


Dr. Ádám Ágota

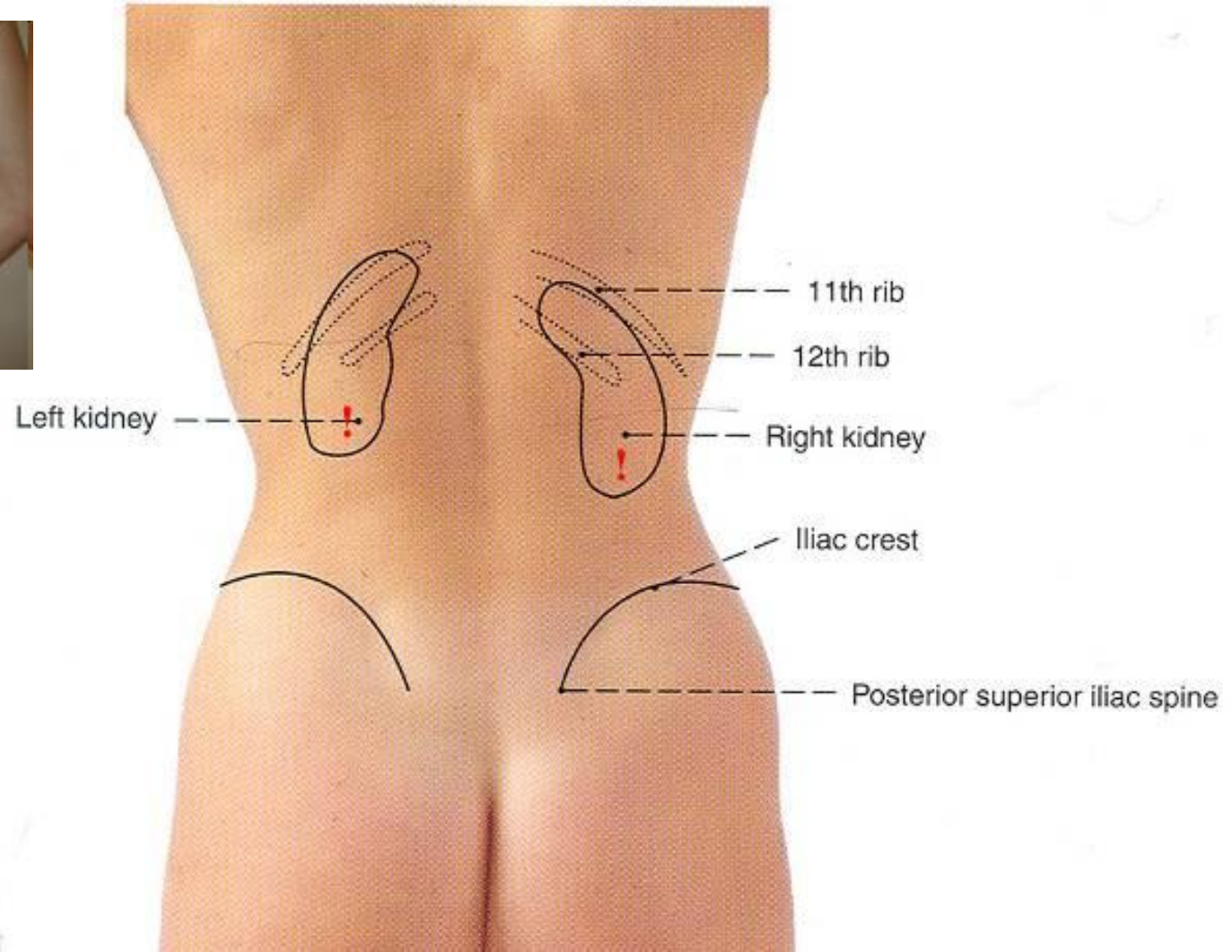
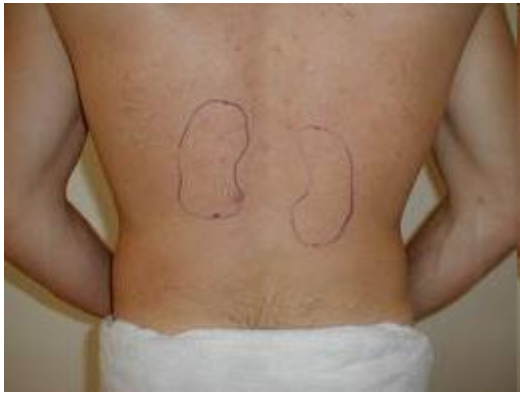# A vese felszínei – Ventralis nézet



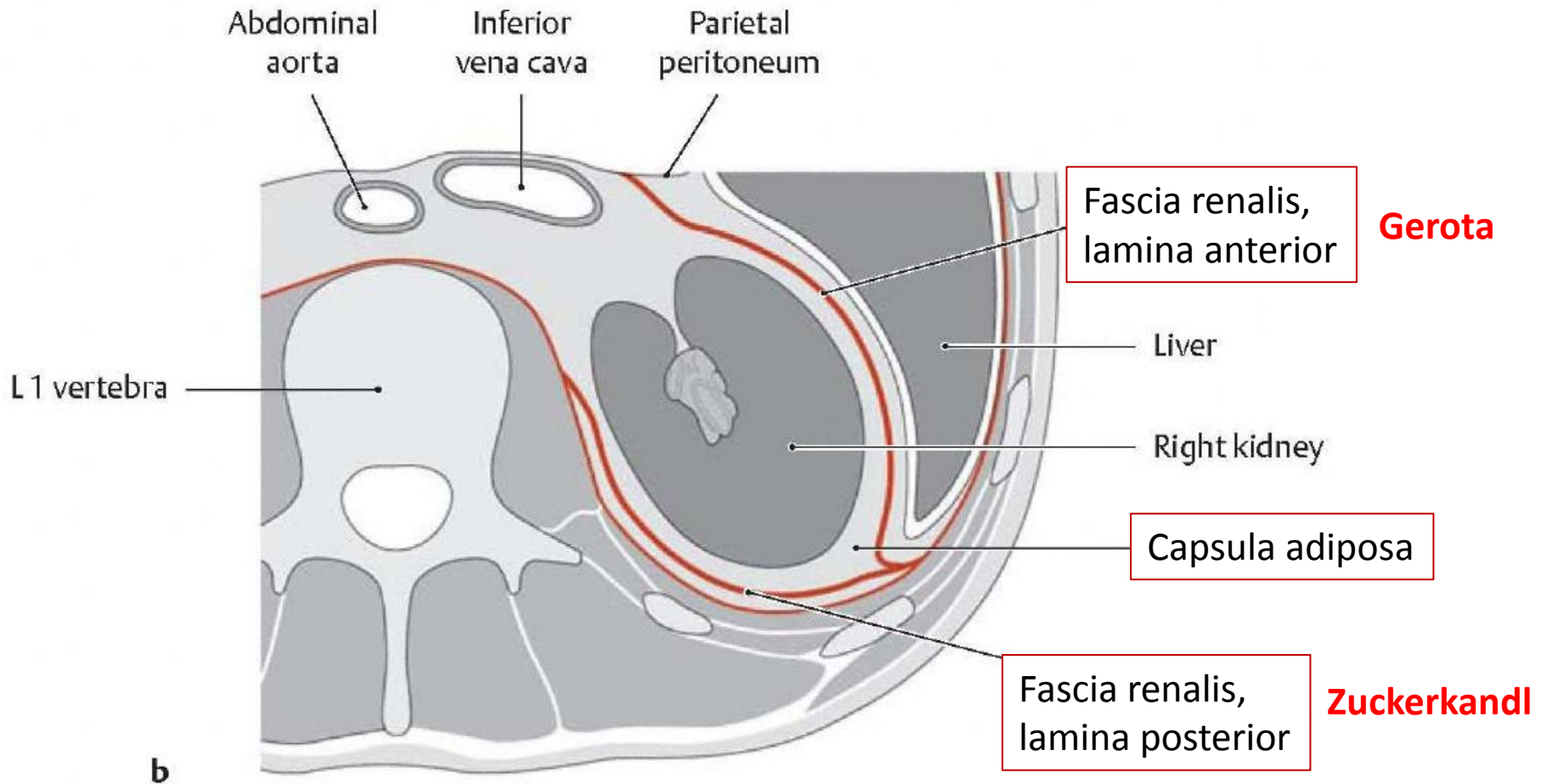
# A vese felszínei – dorsalis nézet



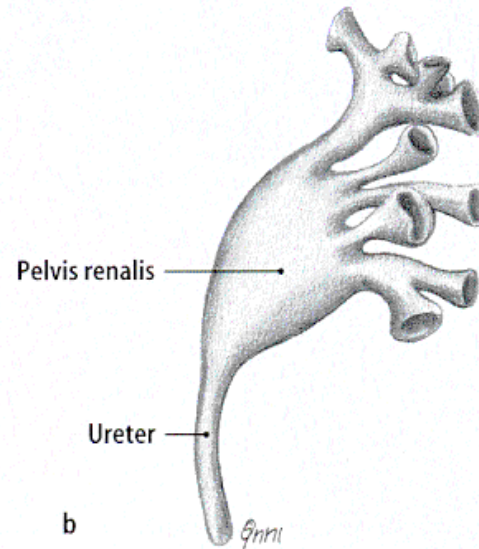
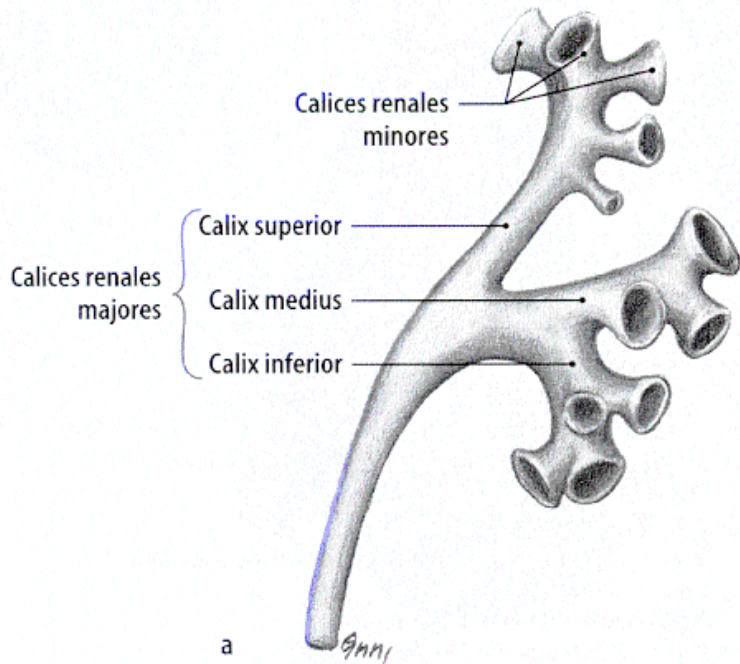
# A vese topográfiája, vetülete



# Vesetokok



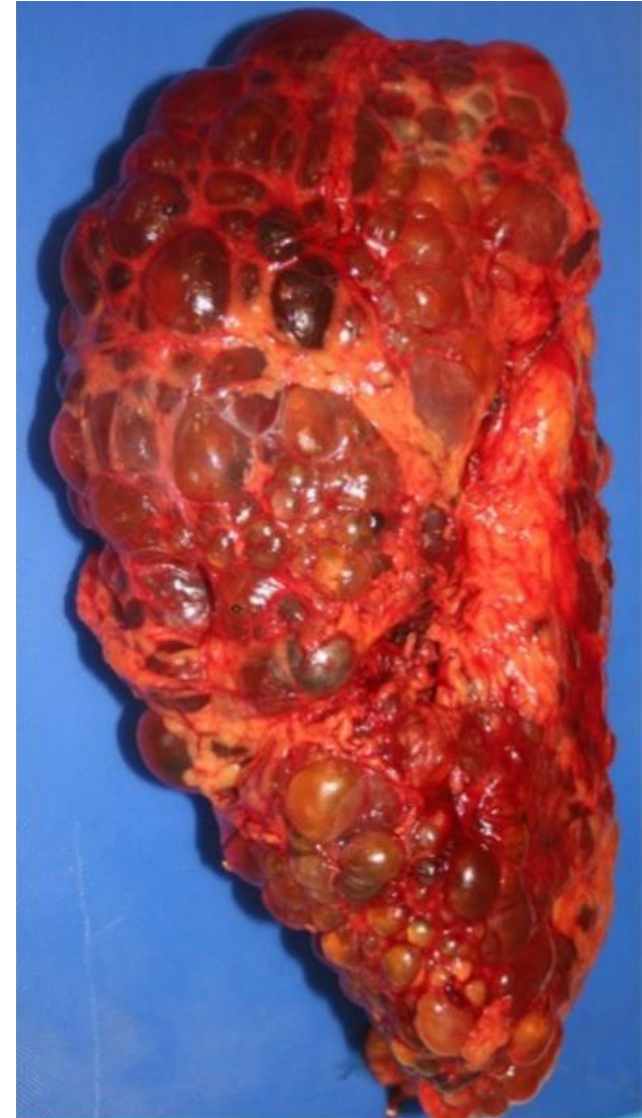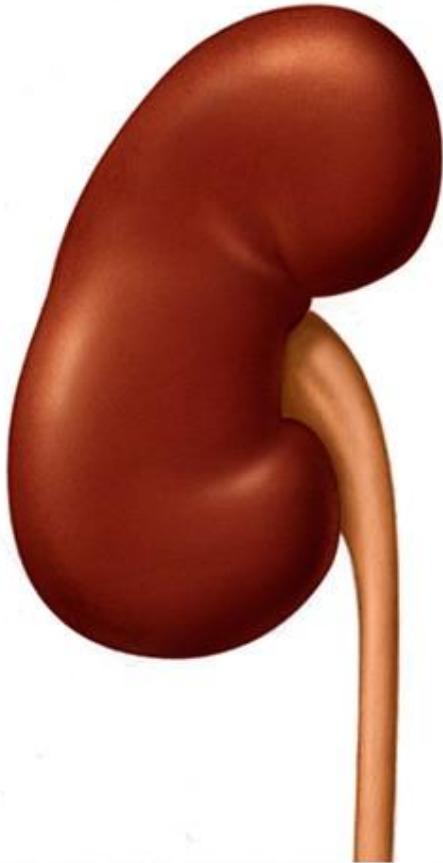
# Vesemedence - típusok



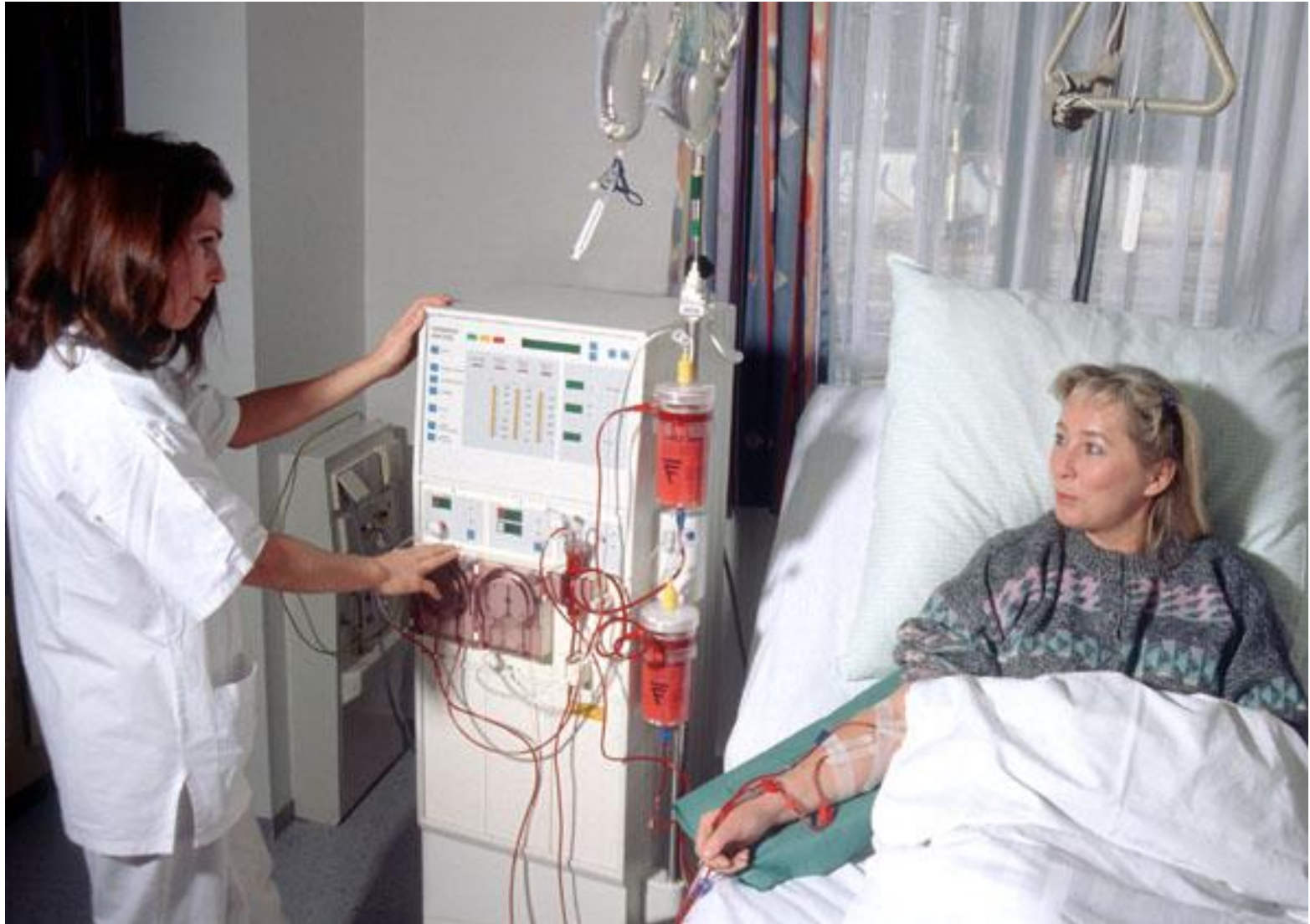- a. dendriticus
- b. ampullaris

a Typus dendriticus;  
b Typus ampullaris

# Policisztás vese

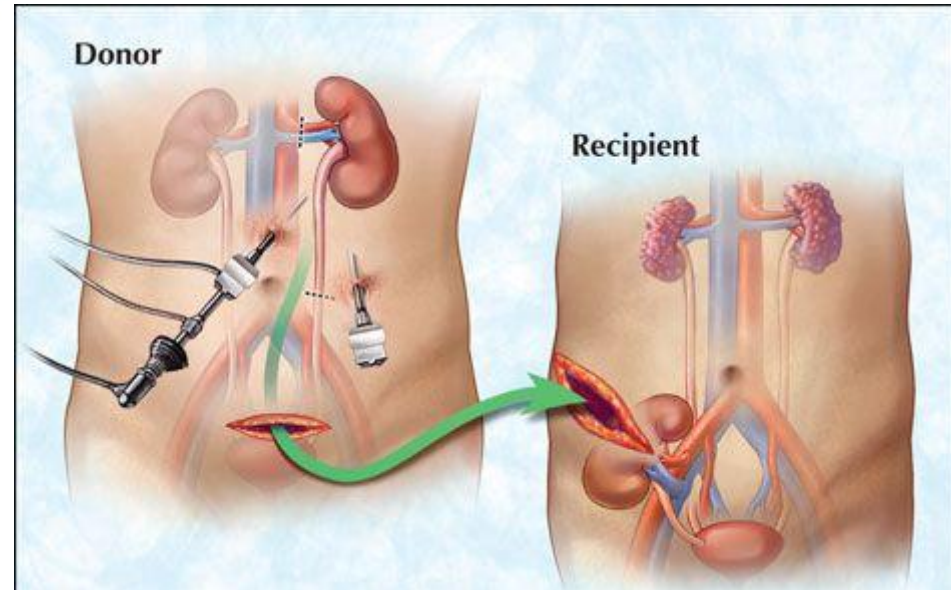
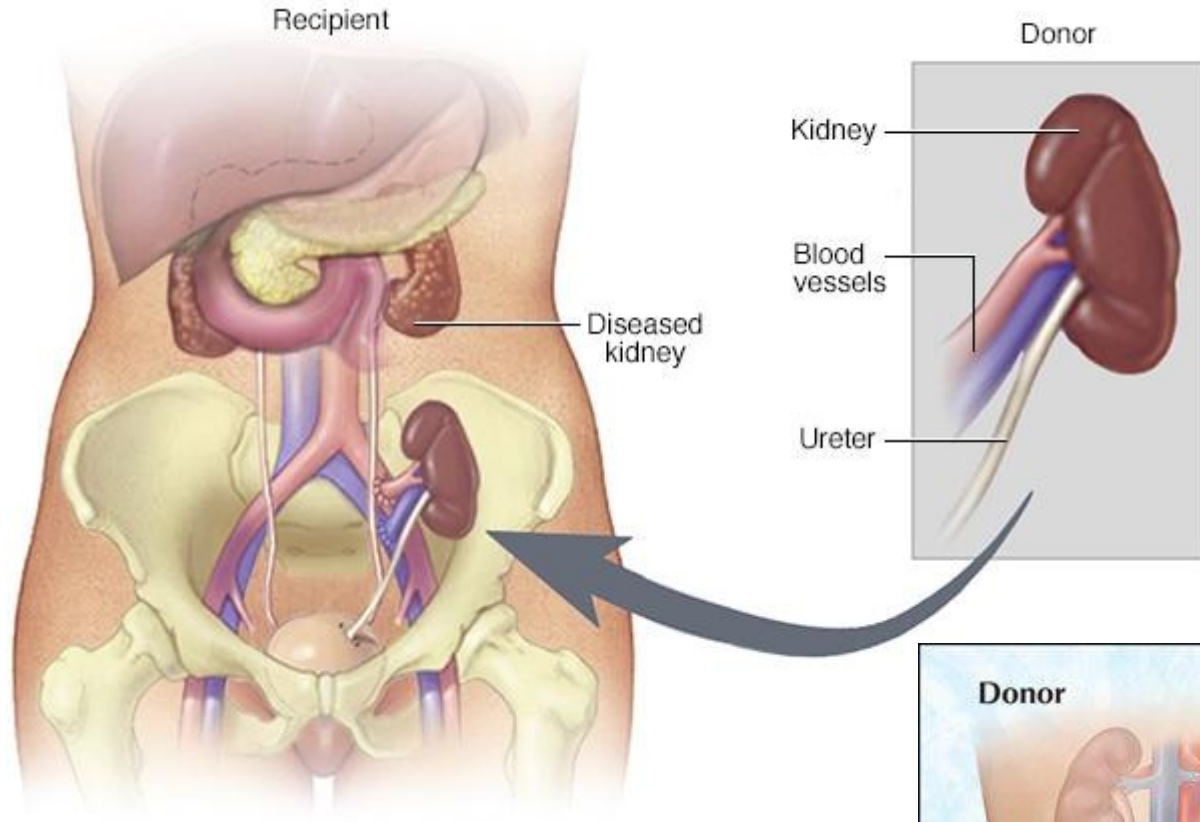


# Hemodialysis

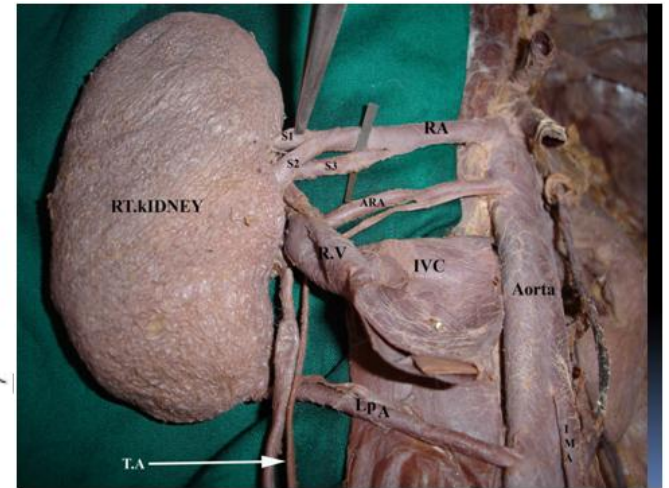
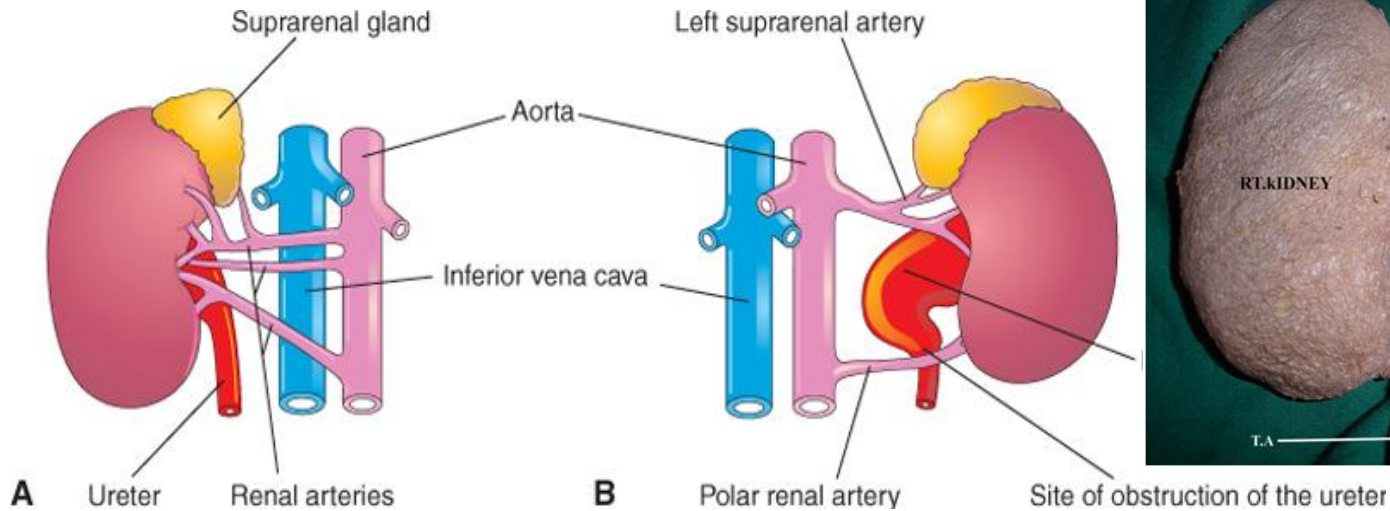




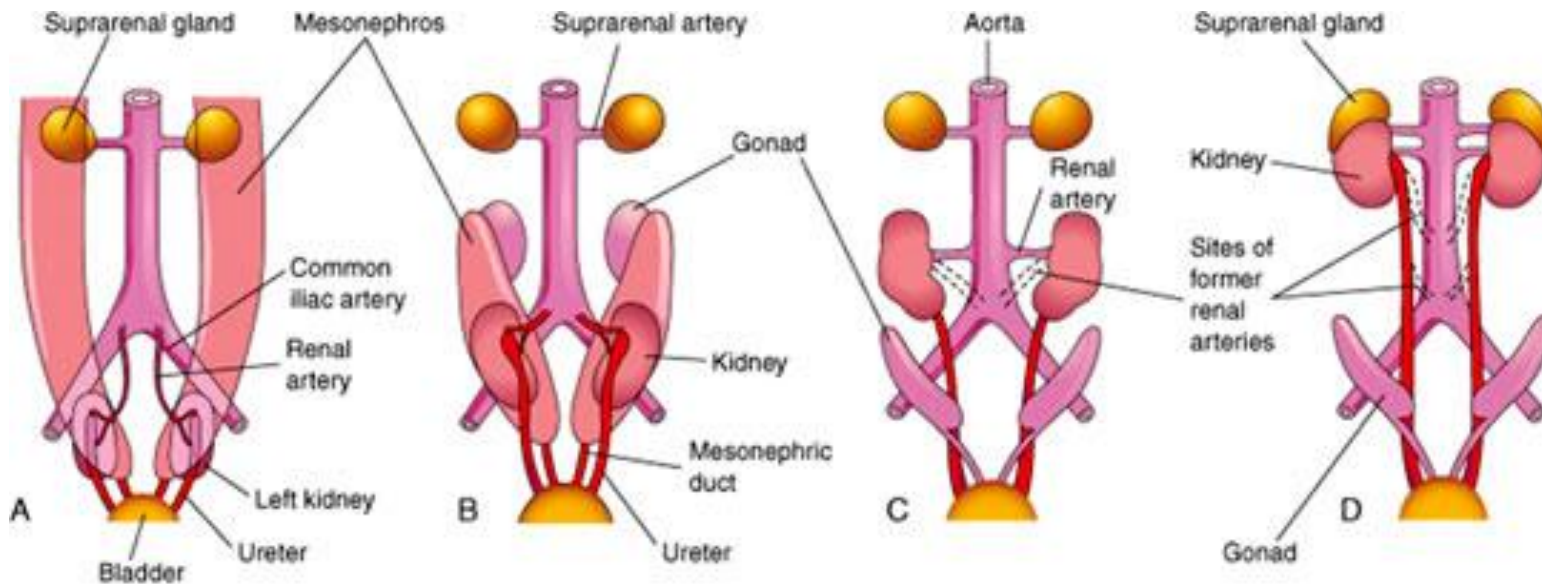
# Vesetranszplantáció



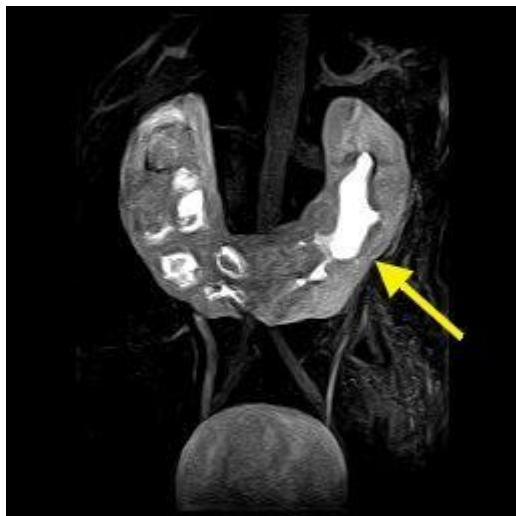
# Gyakori anatómiai variáció: a. polaris



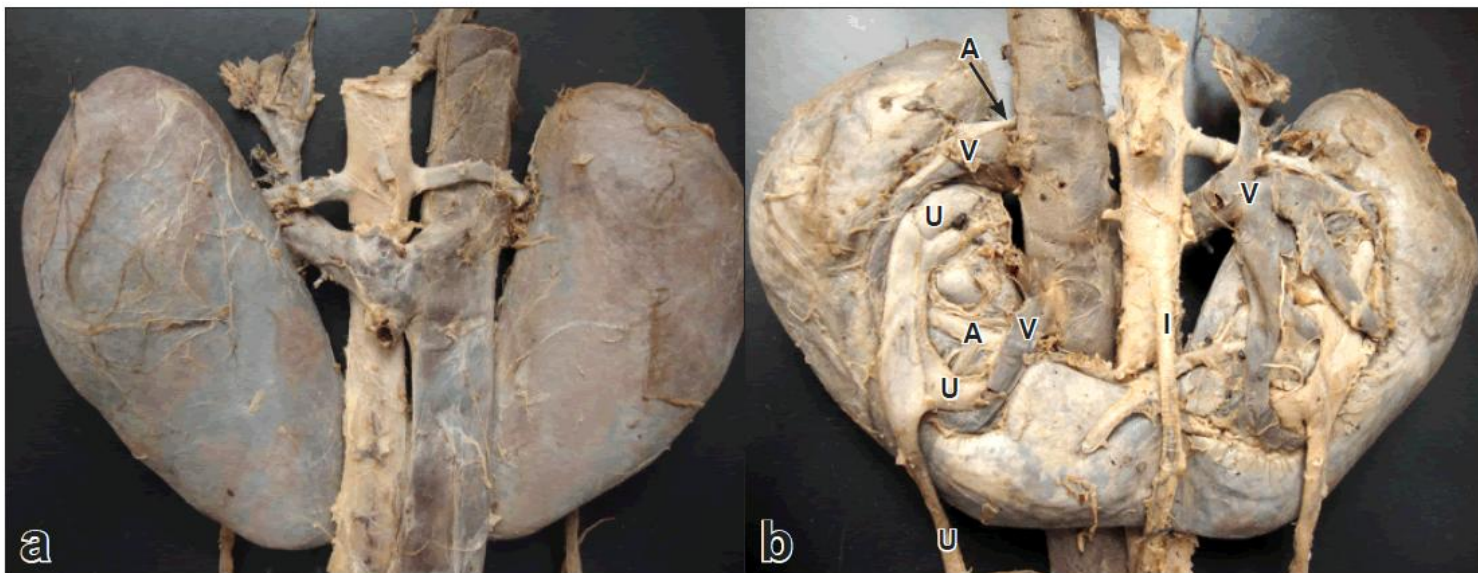
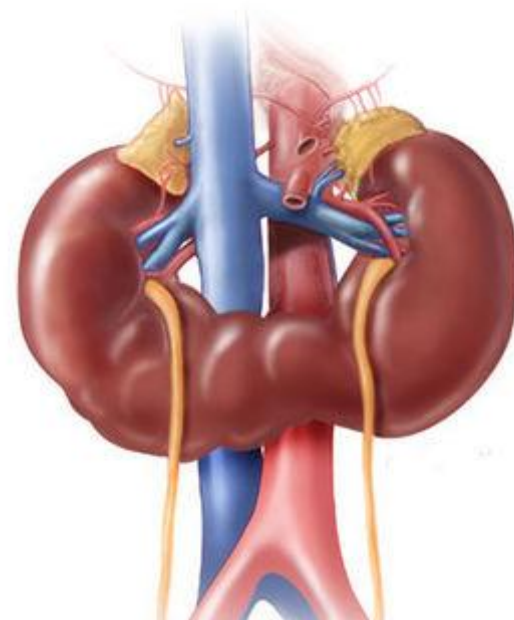
Oka: A vérellátás változása a vese fejlődése során (lásd később):



# Patkóvese

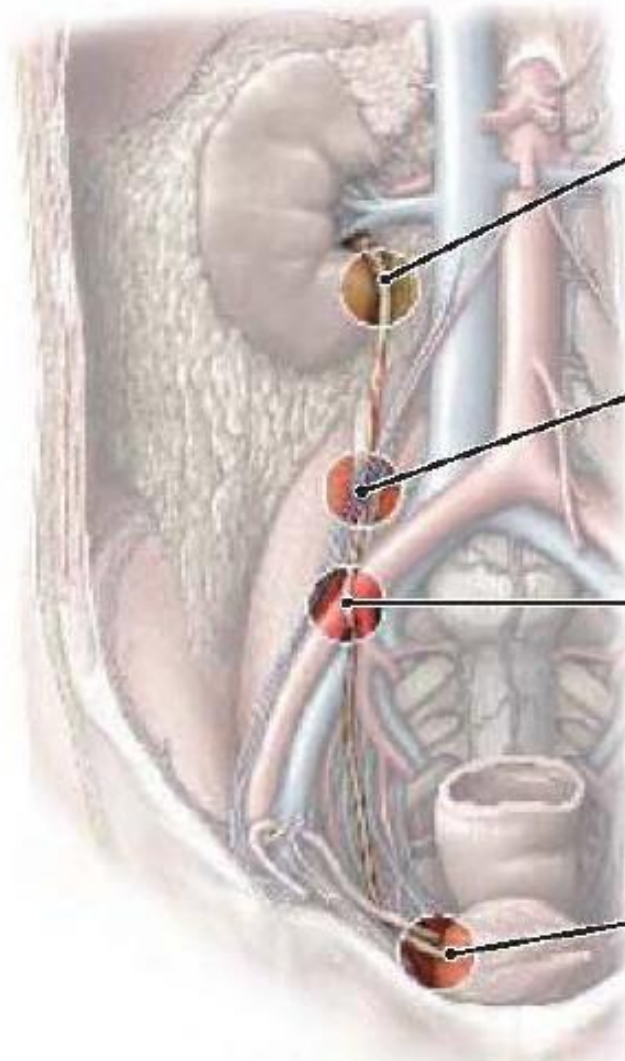


Gyakori fejlődési rendellenesség, amelyben a vesék a fejlődés során a medencéből felszállva egymással összeolvadnak



**Figure 1.** a) Posterior view of the horseshoe kidney. b) Anterior view of the horseshoe kidney. A horseshoe kidney with a wide hilum, fused inferiorly, below the *inferior mesenteric artery (I)* with double *renal arteries (A)*. There are two *renal veins (V)* on the right with a single *renal vein (V)* on the left.

# Az ureter fiziológias szűkületei



1. A vesemedencéből való kilépésénél

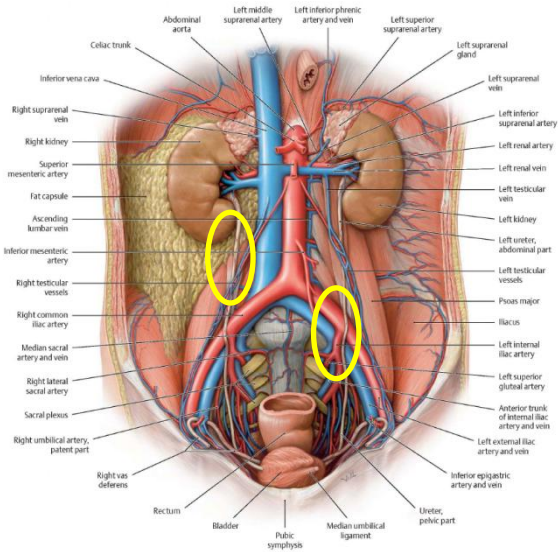
Lehetséges szűkület: ahol keresztezi a gonadalis ereket

2. Ahol keresztezi az a. és v. iliacát

3. Ahol belép és rövid ideig halad a hólyag falában (intramuralis rész)

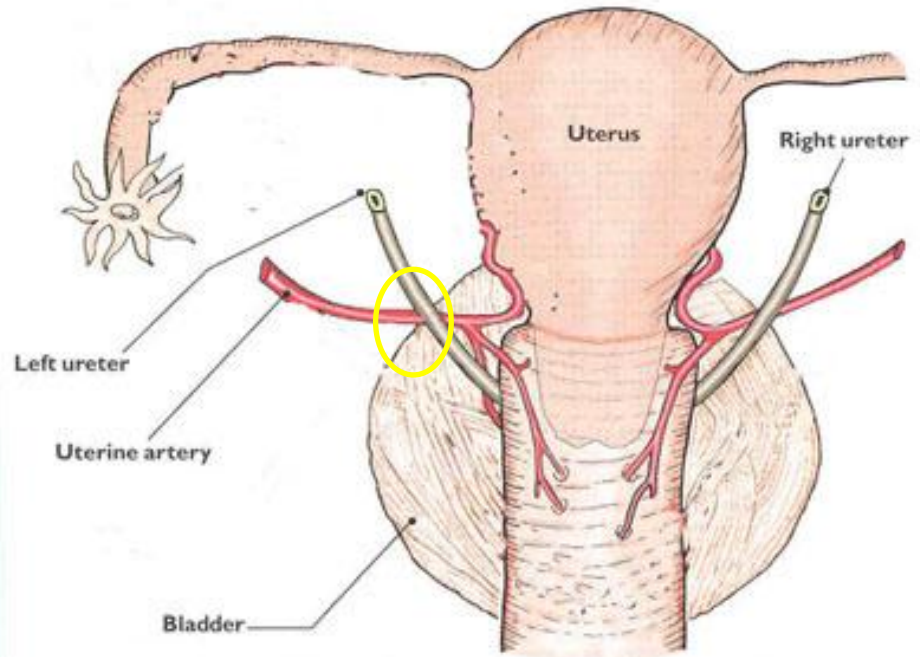
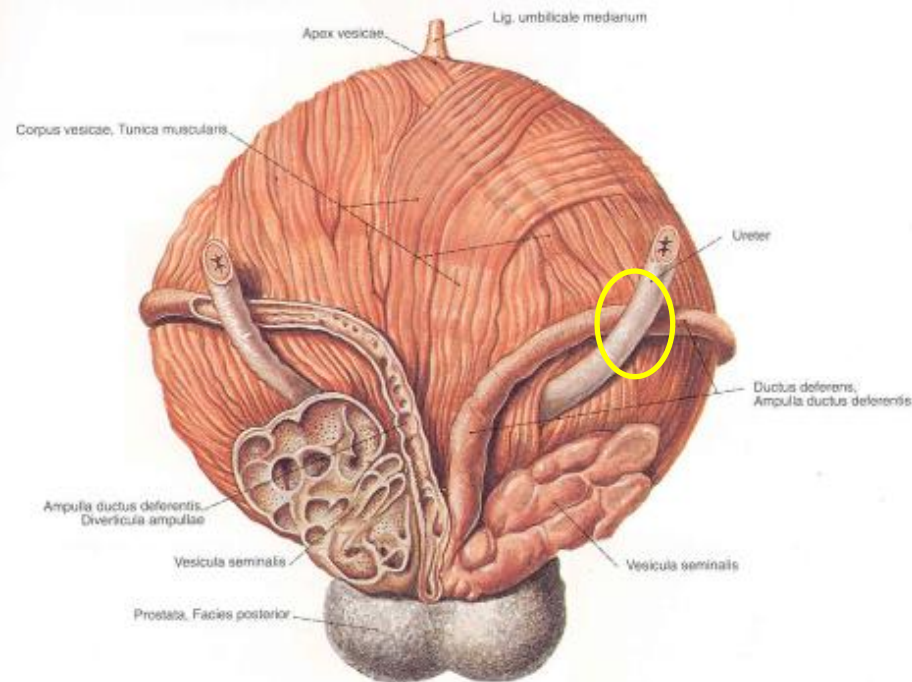
# Az ureter kereszteződései

1. Gonadalis erekkel
2. A. és v. iliaca externával

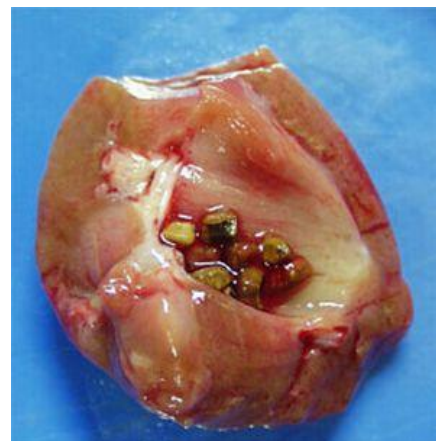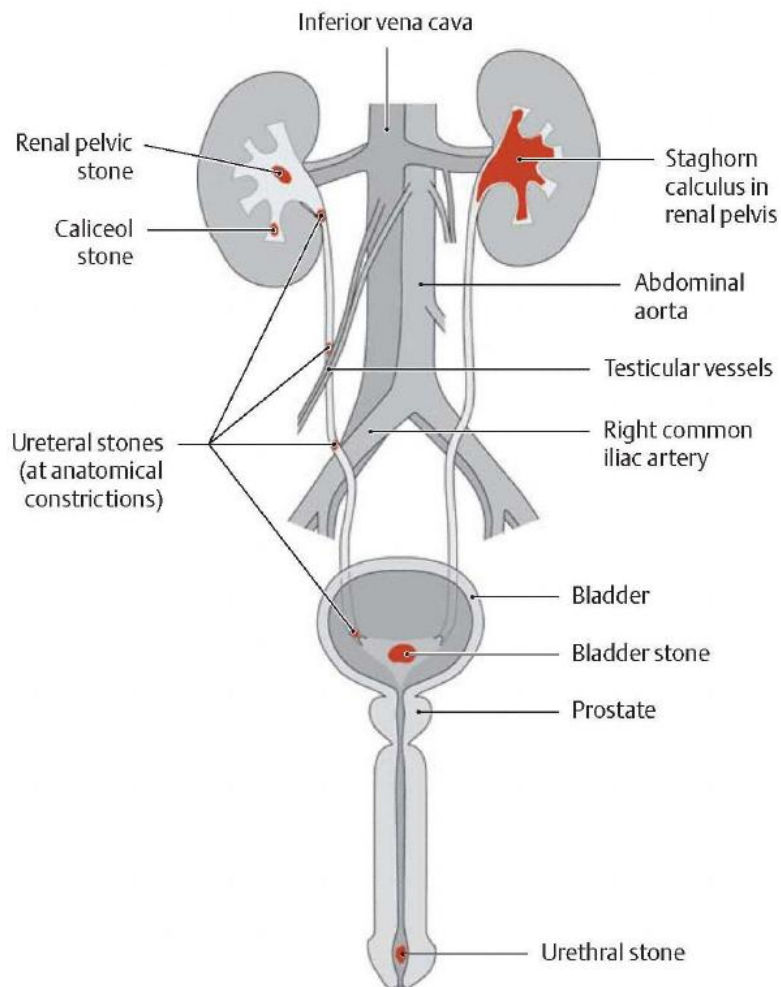


## 3. Férfiakban: vas deferenssel

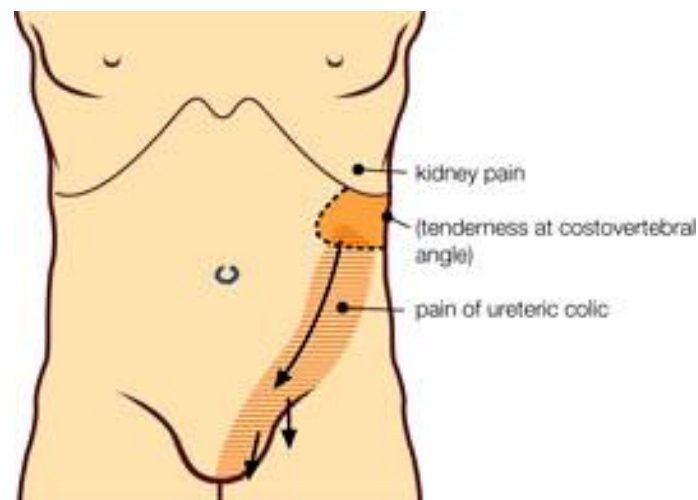
## 3. Nőkben: a. uterinával



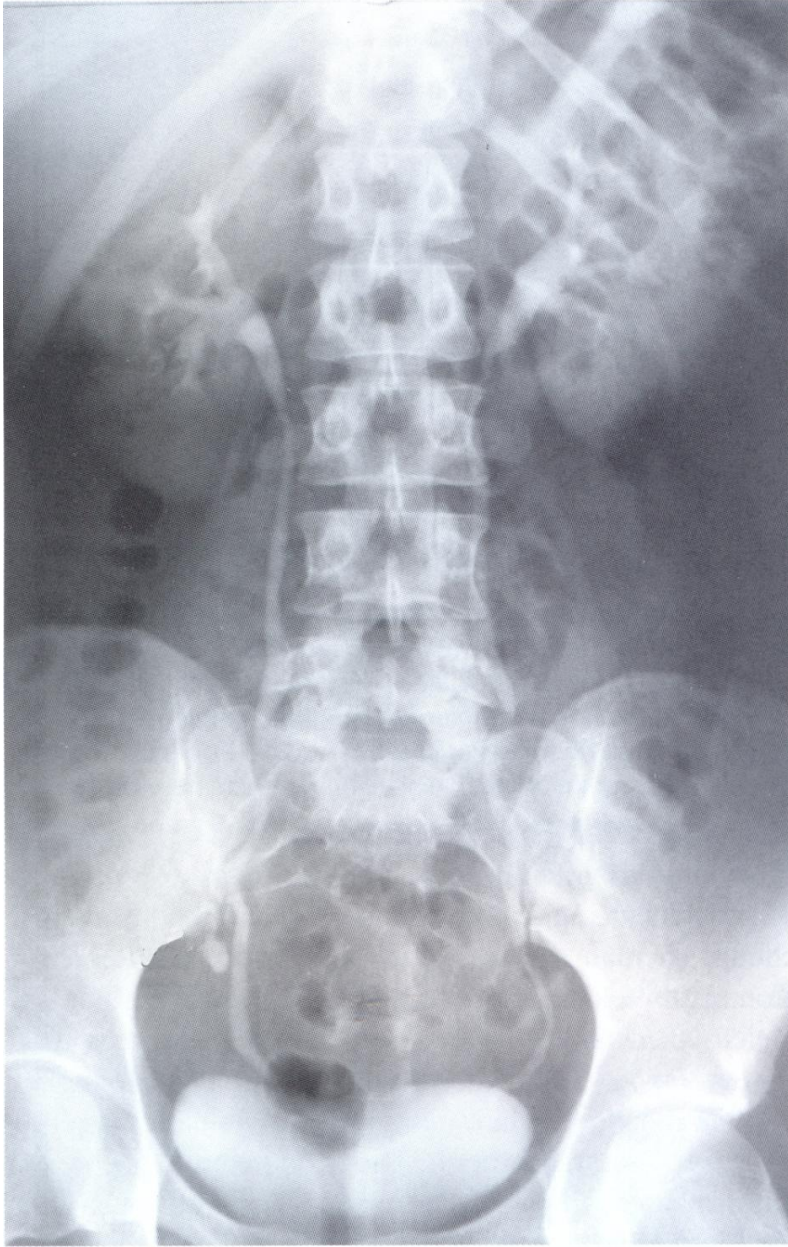
# A vesekövek leggyakoribb elakadási helyei



A vesekövesség vezető tünete a típusos helyen megjelenő **fájdalom**.



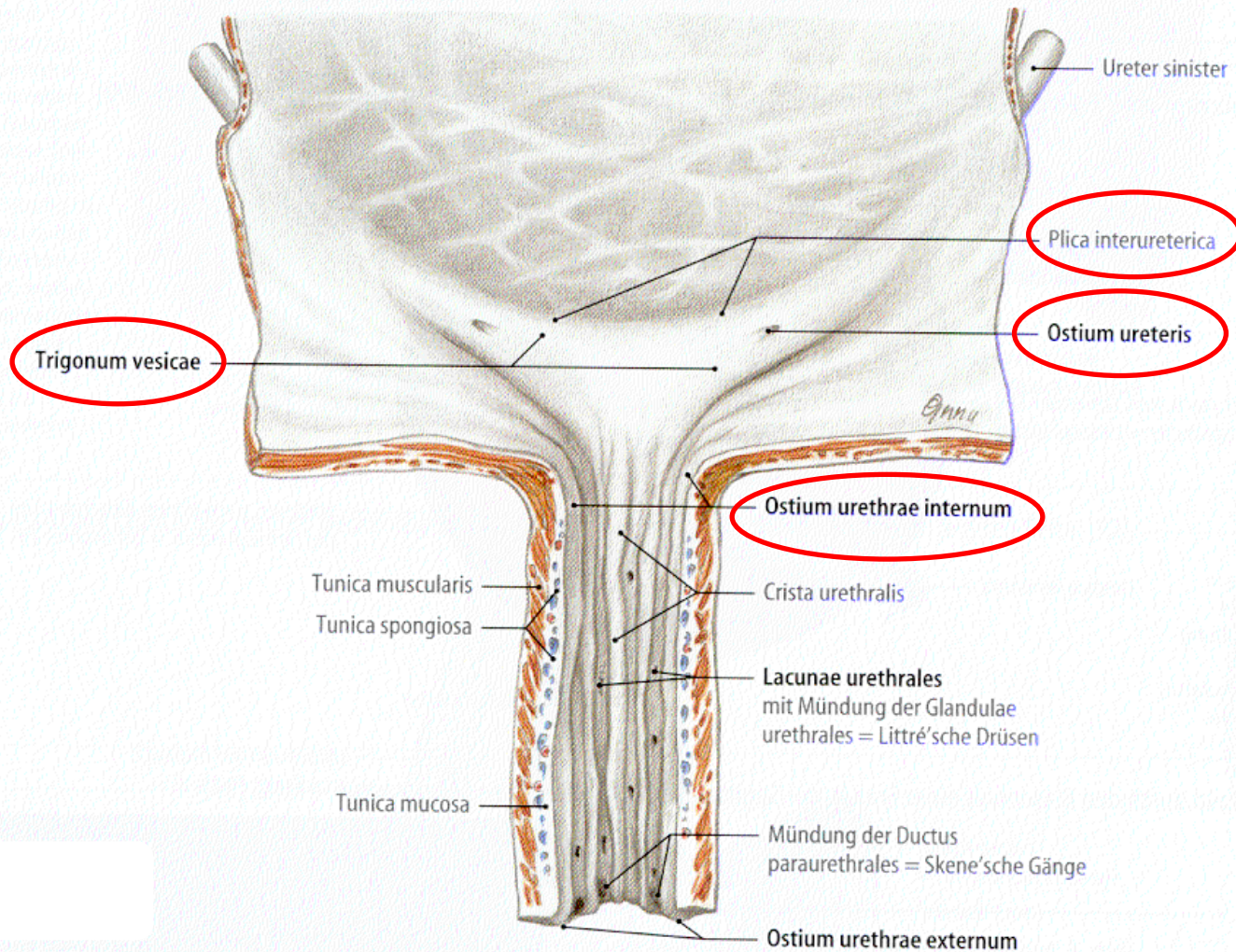
# Urographia



Pl. Vesekövek helyzetének megállapítására

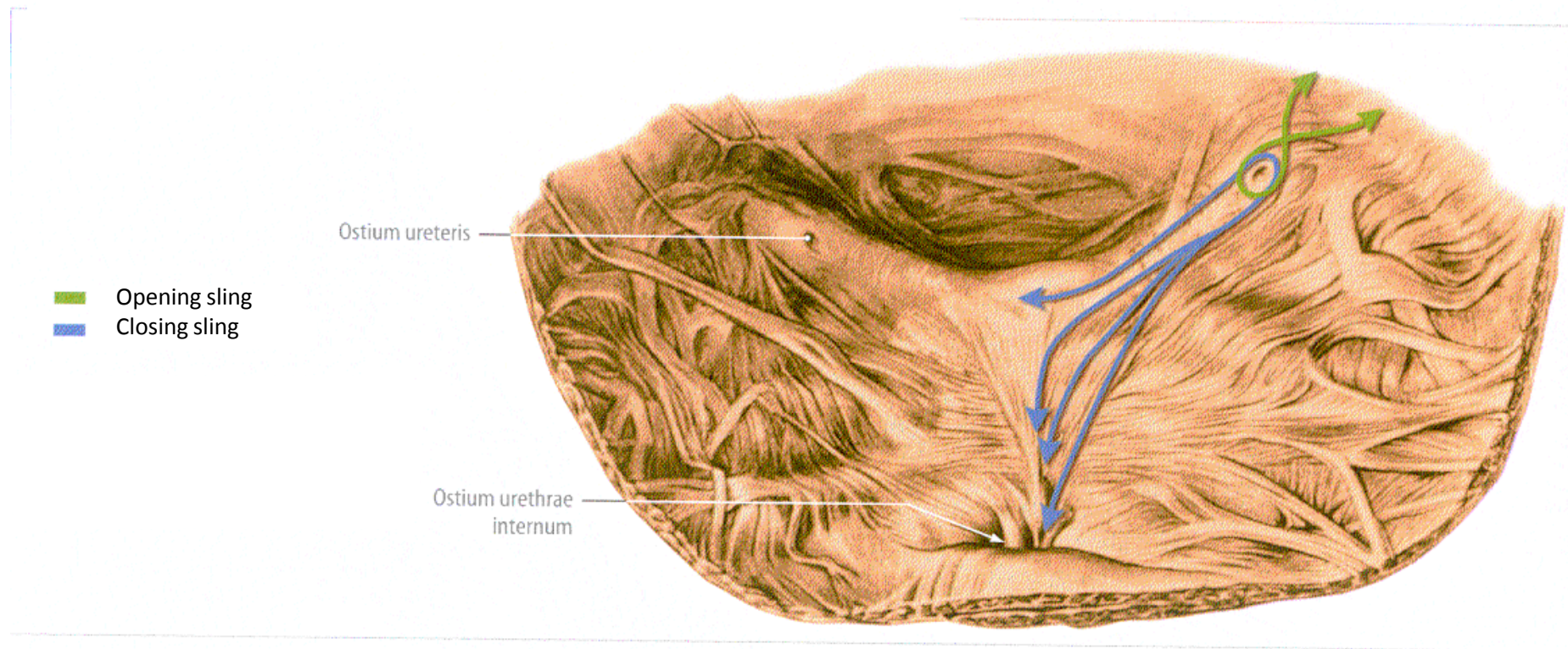
(Csak a kalcium tartalmú kövek látszanak)

# Trigonum vesicae






# Trigonum vesicae



Köszönöm a figyelmet!



Hello Kidney