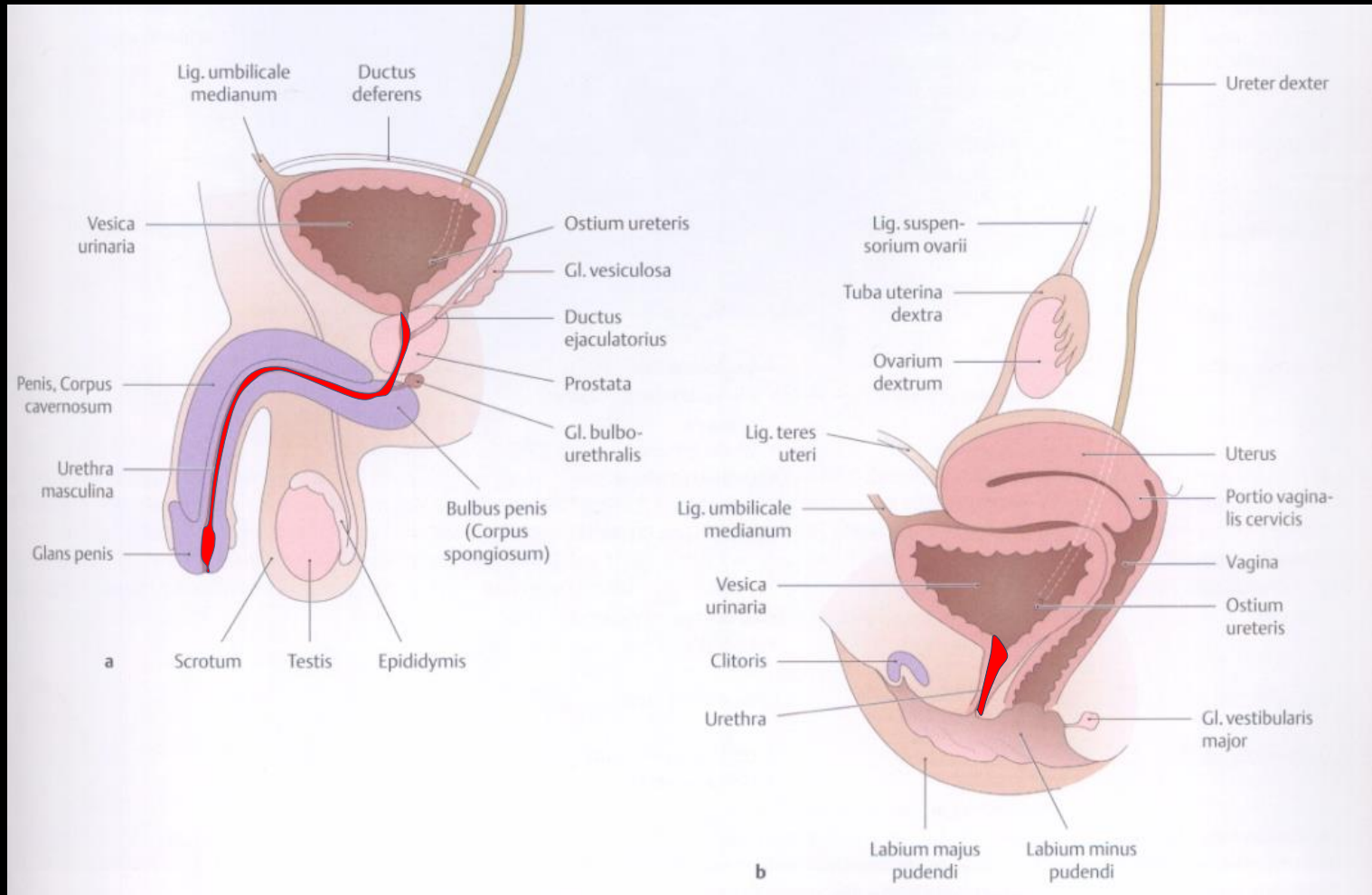
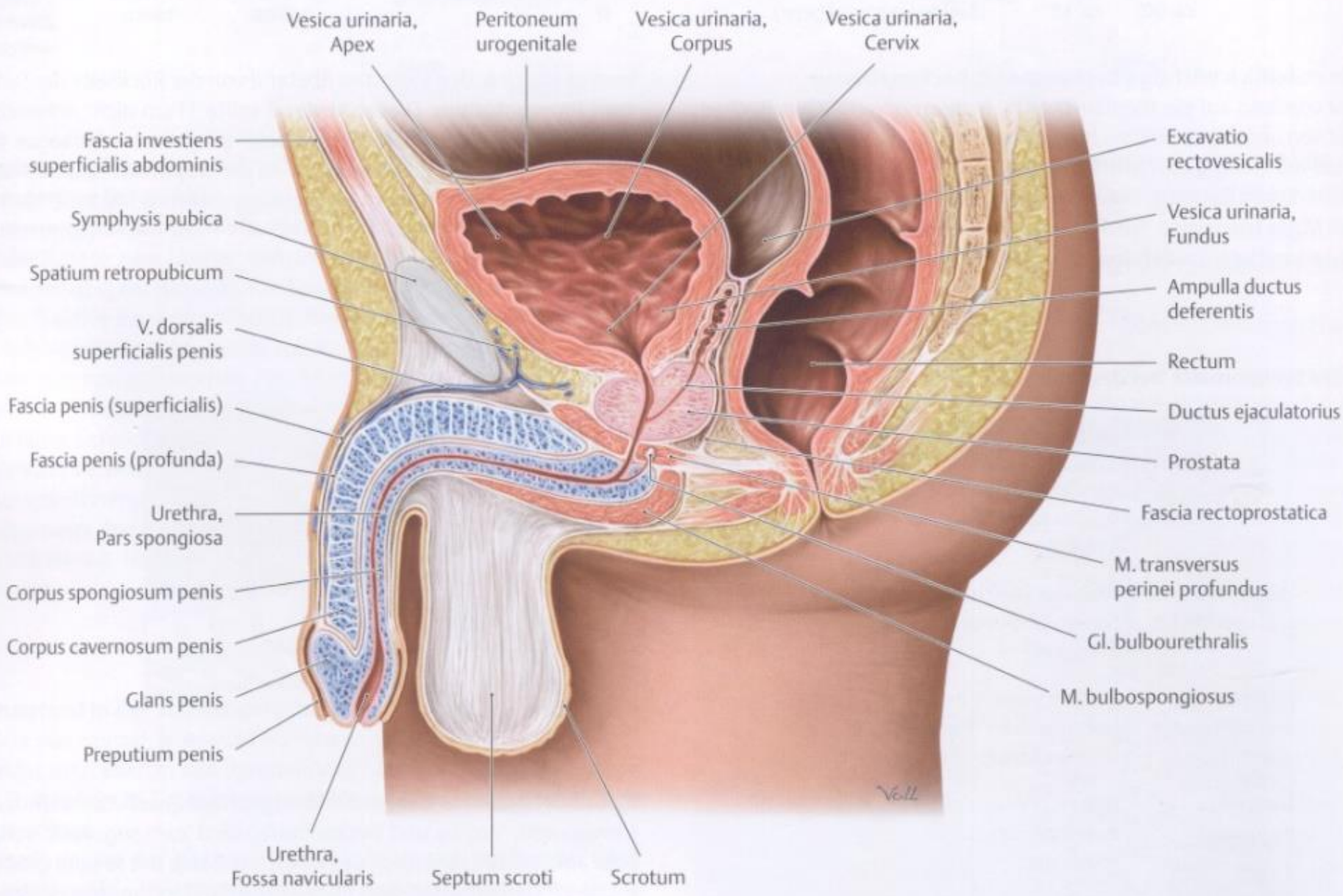


Penis, férfi húgycső, medencefenék és gát

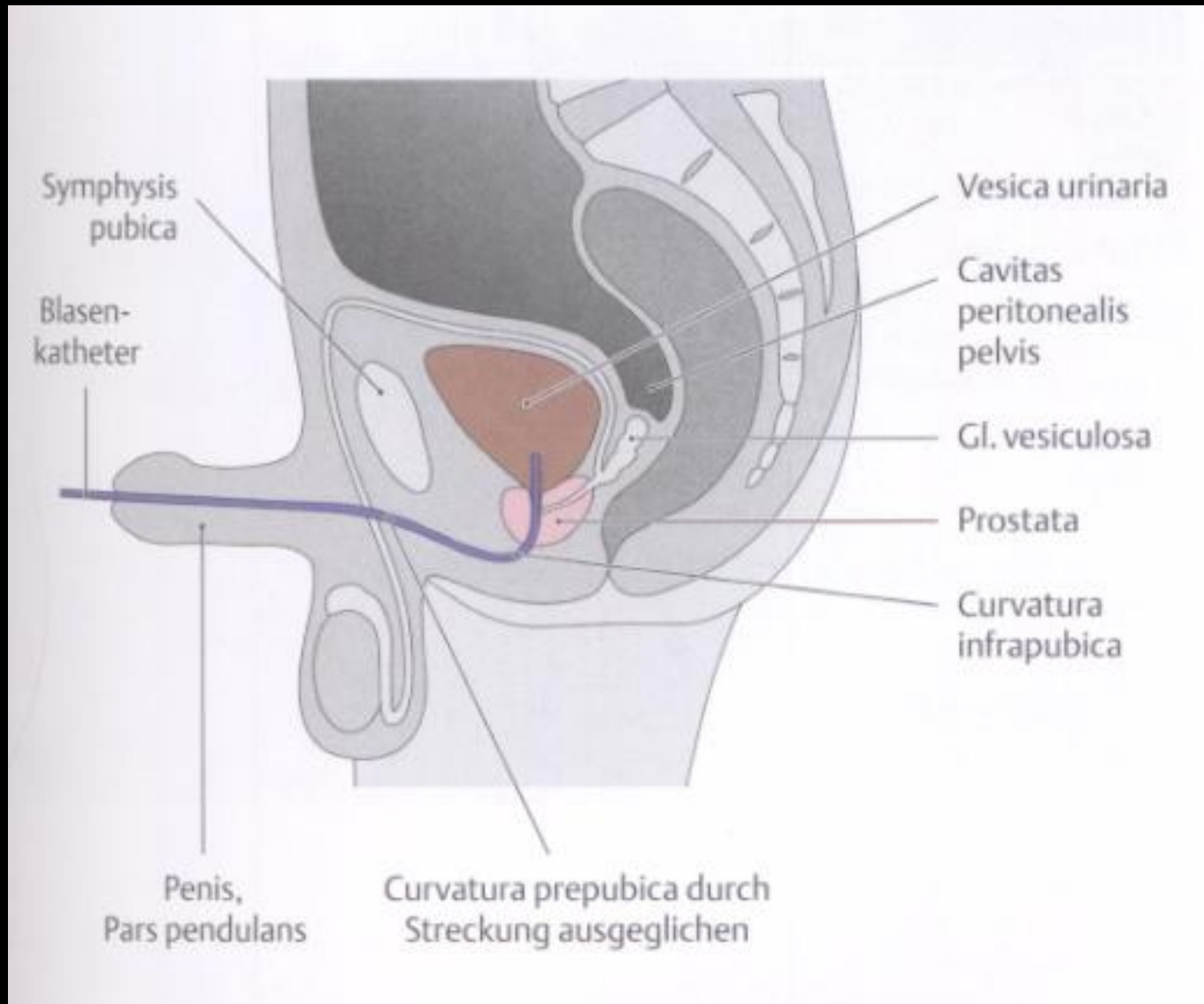
Barna János

Urethra

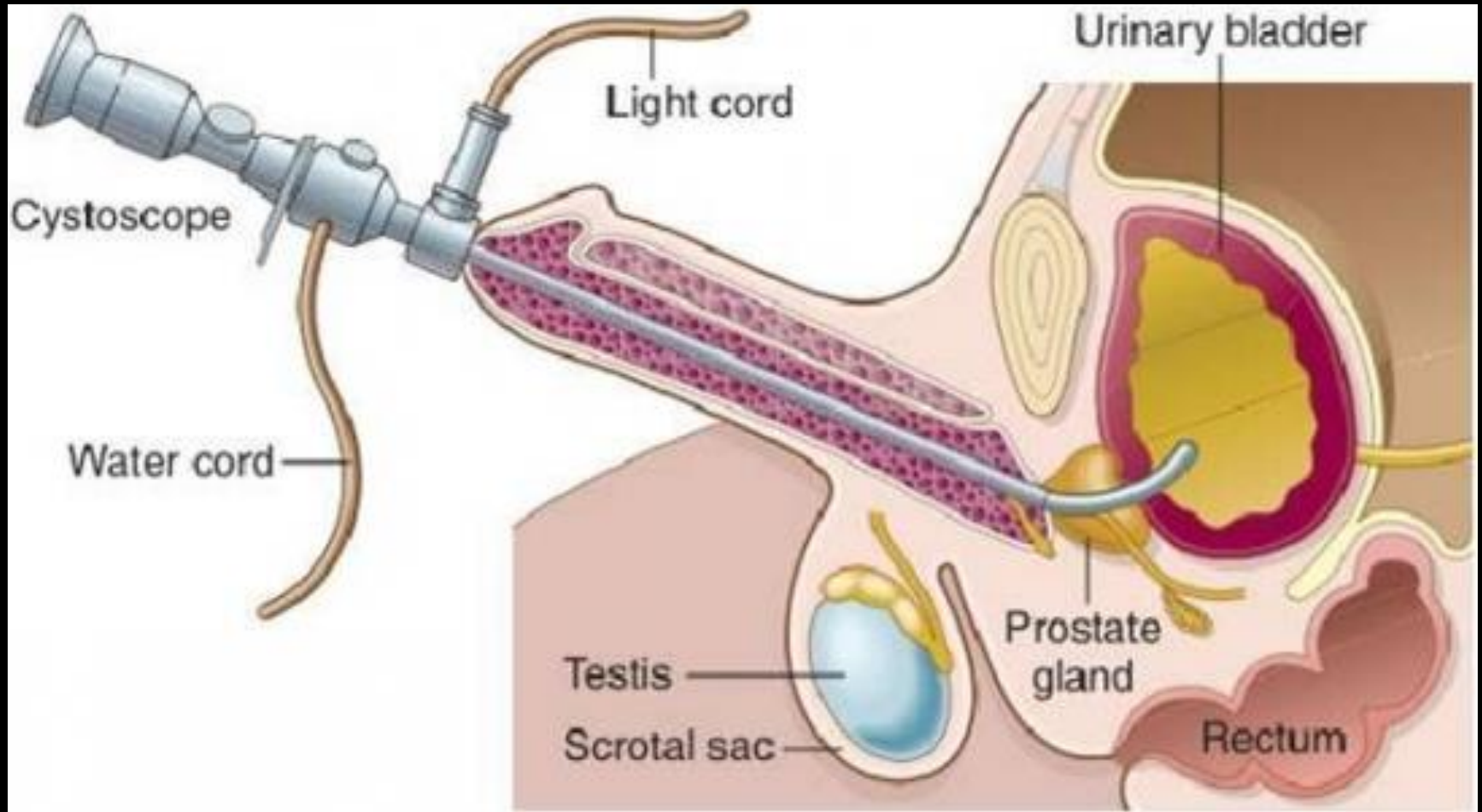




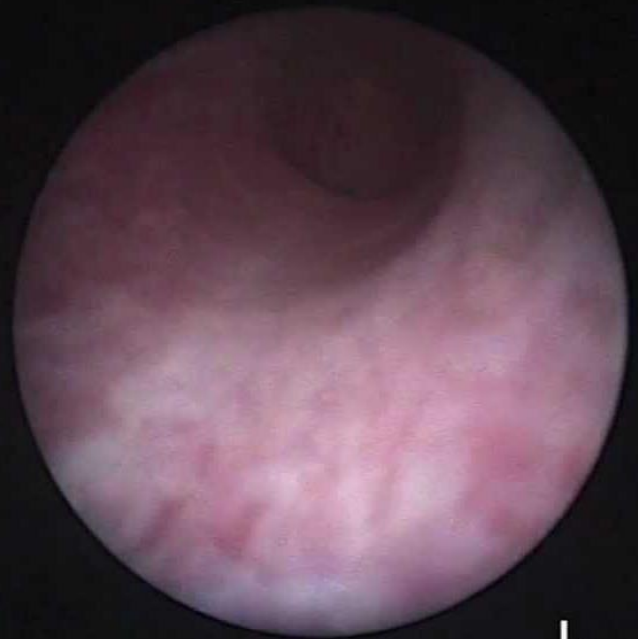Hólyag katéterezés



Citoszkópia (hólyagtükrözés)

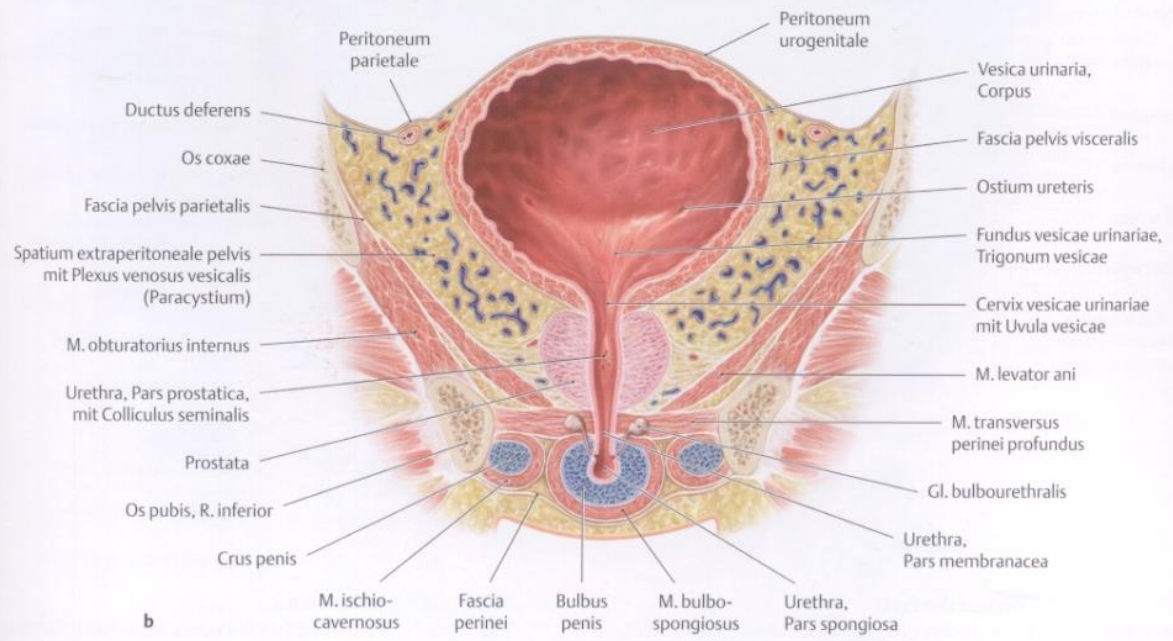
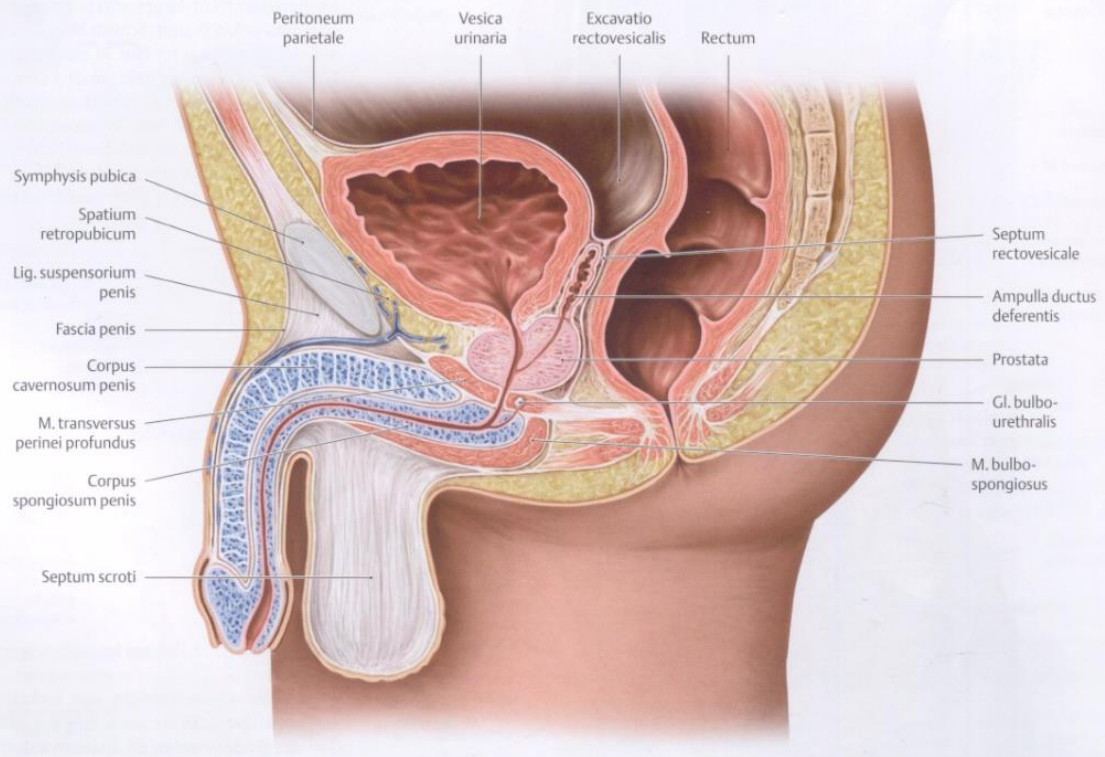


Hólyagkövek

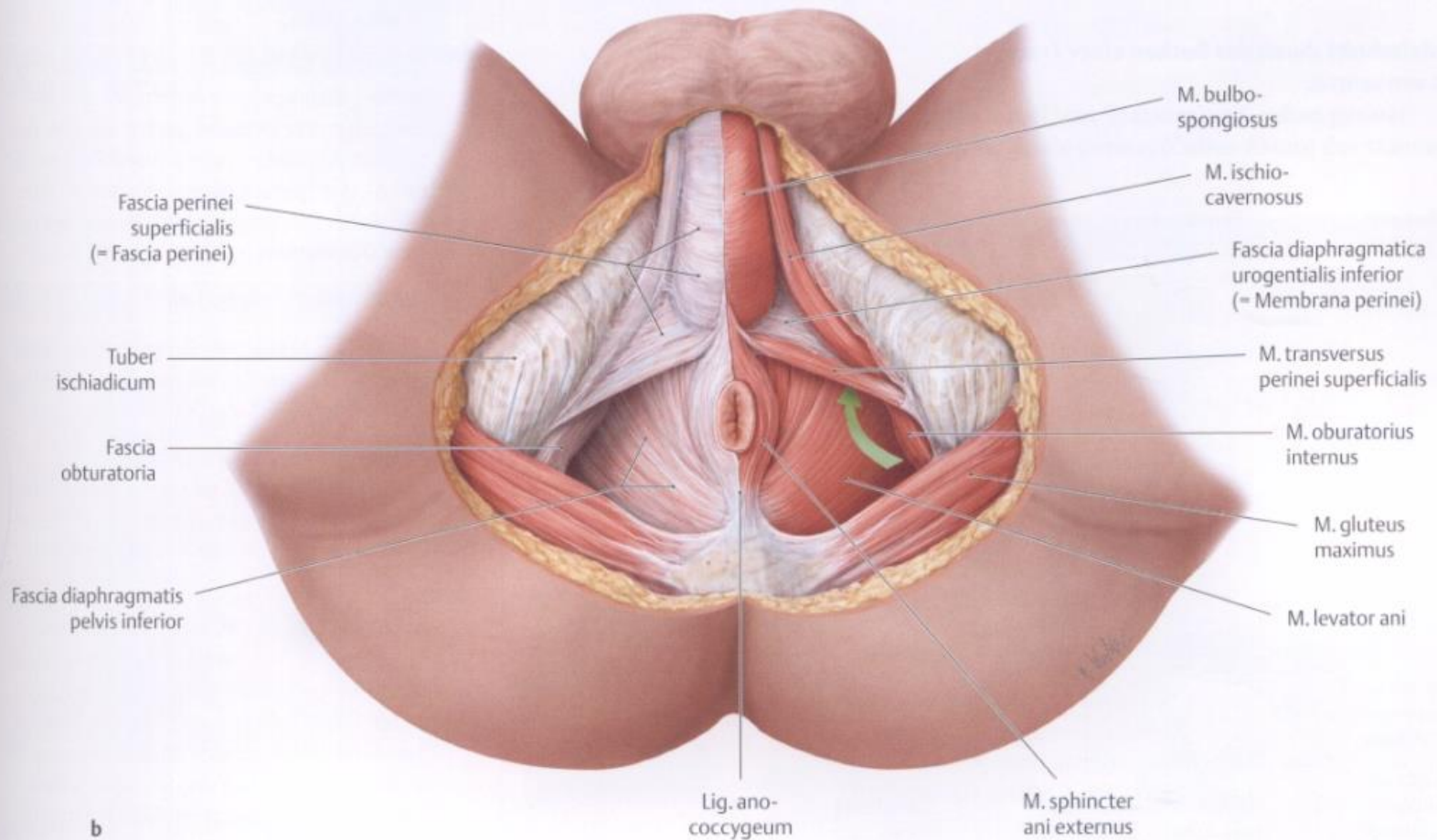


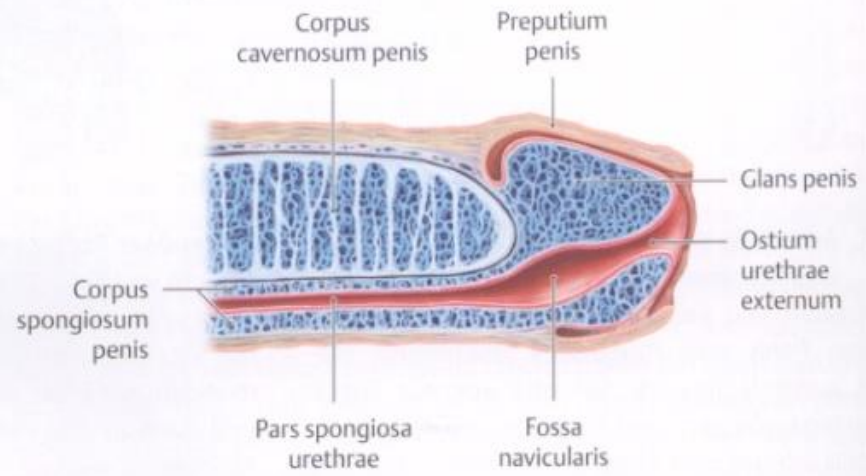
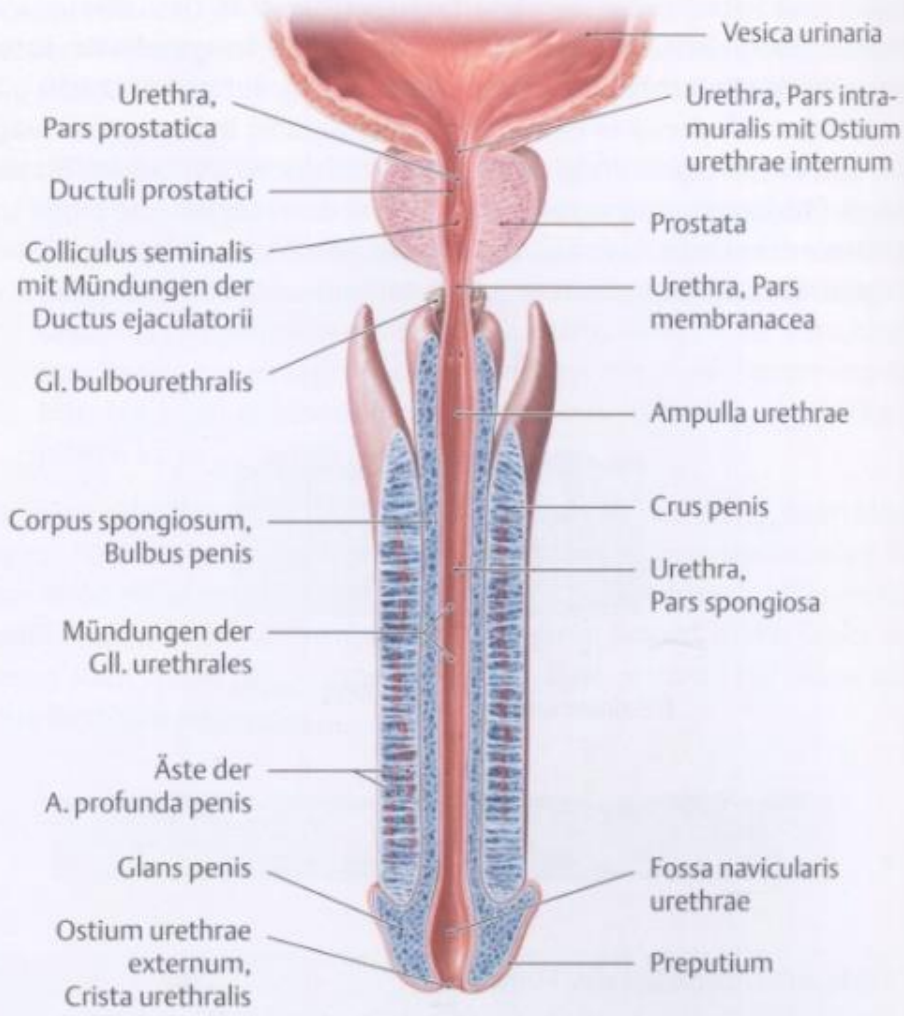
L

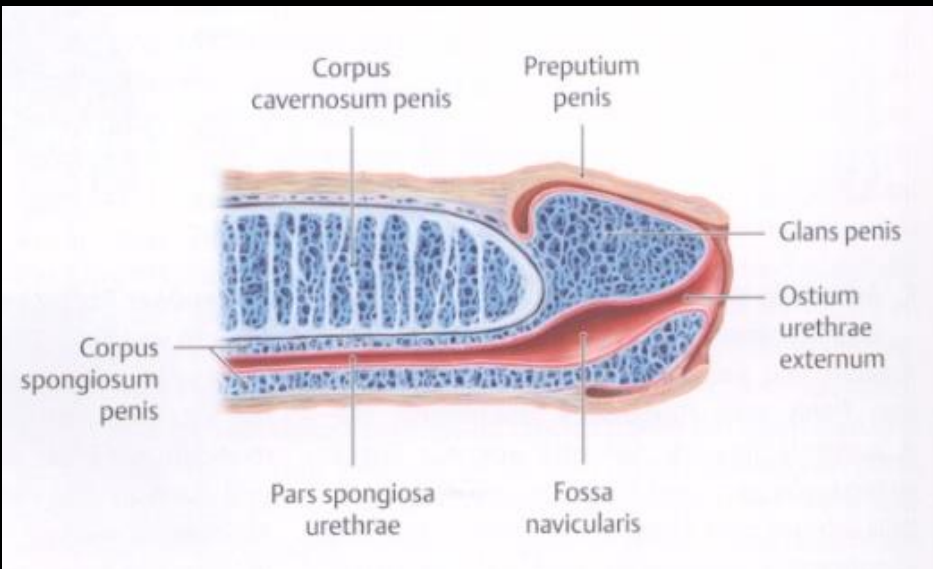
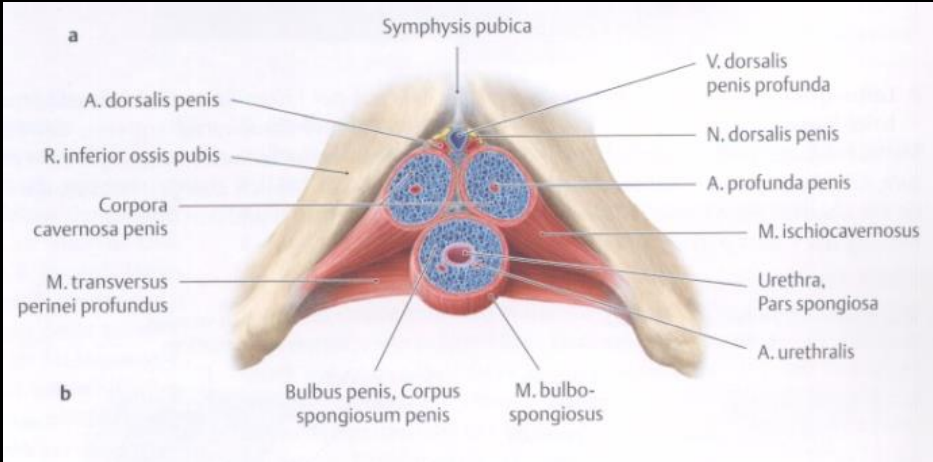
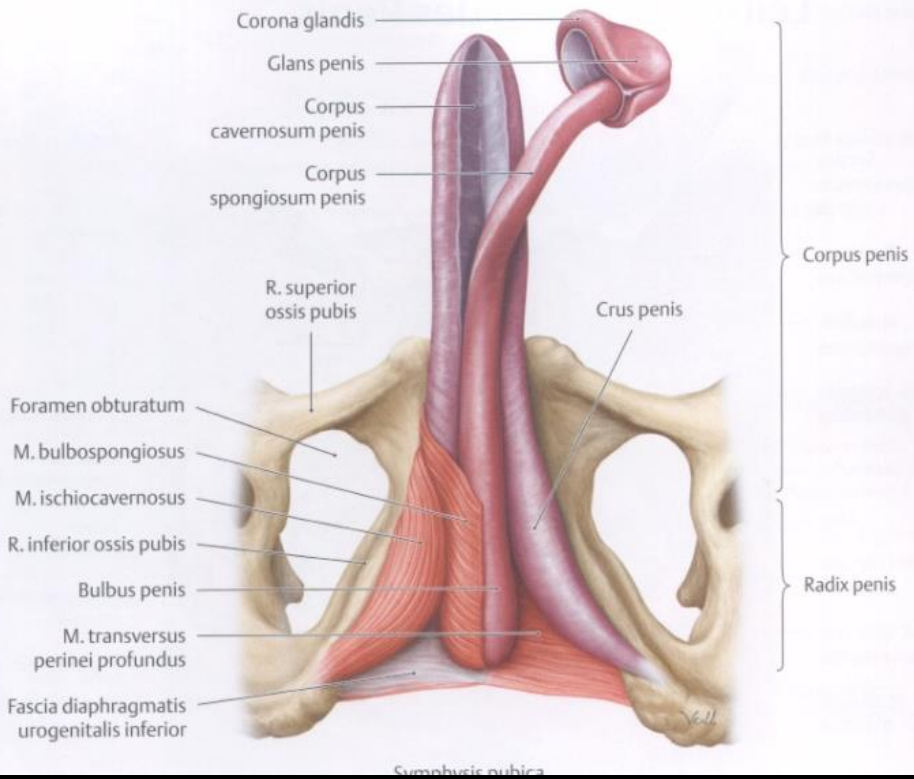




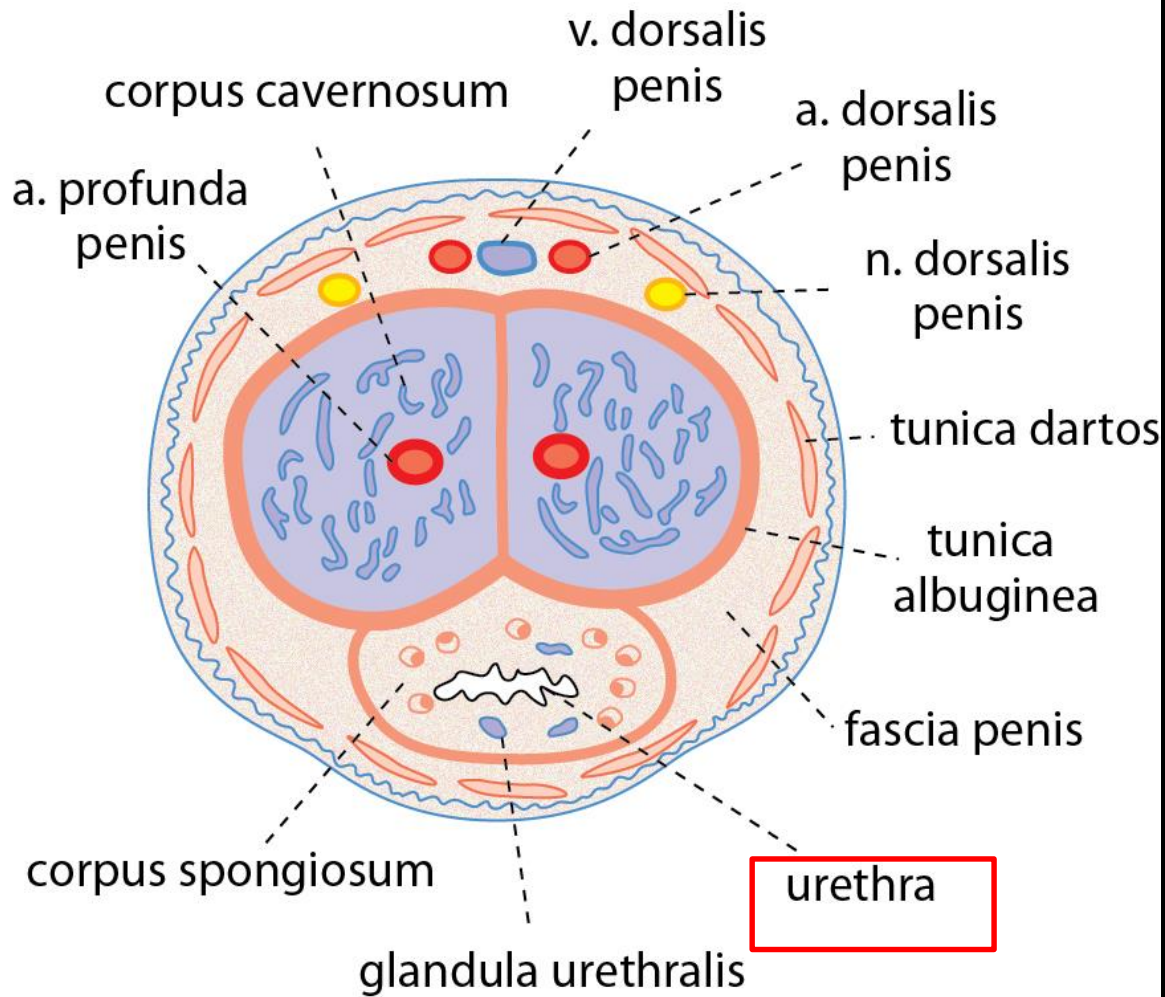
Radix penis

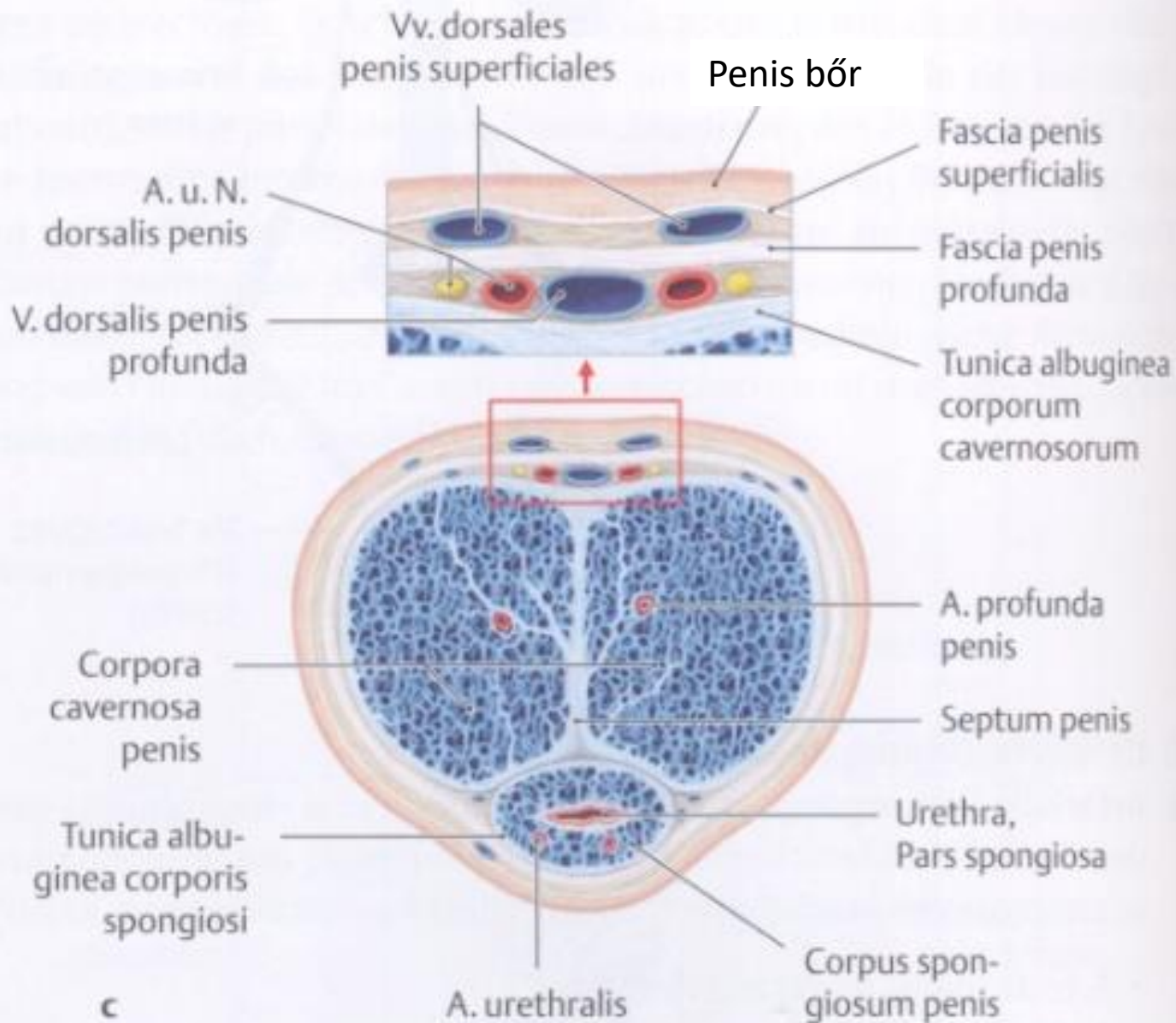




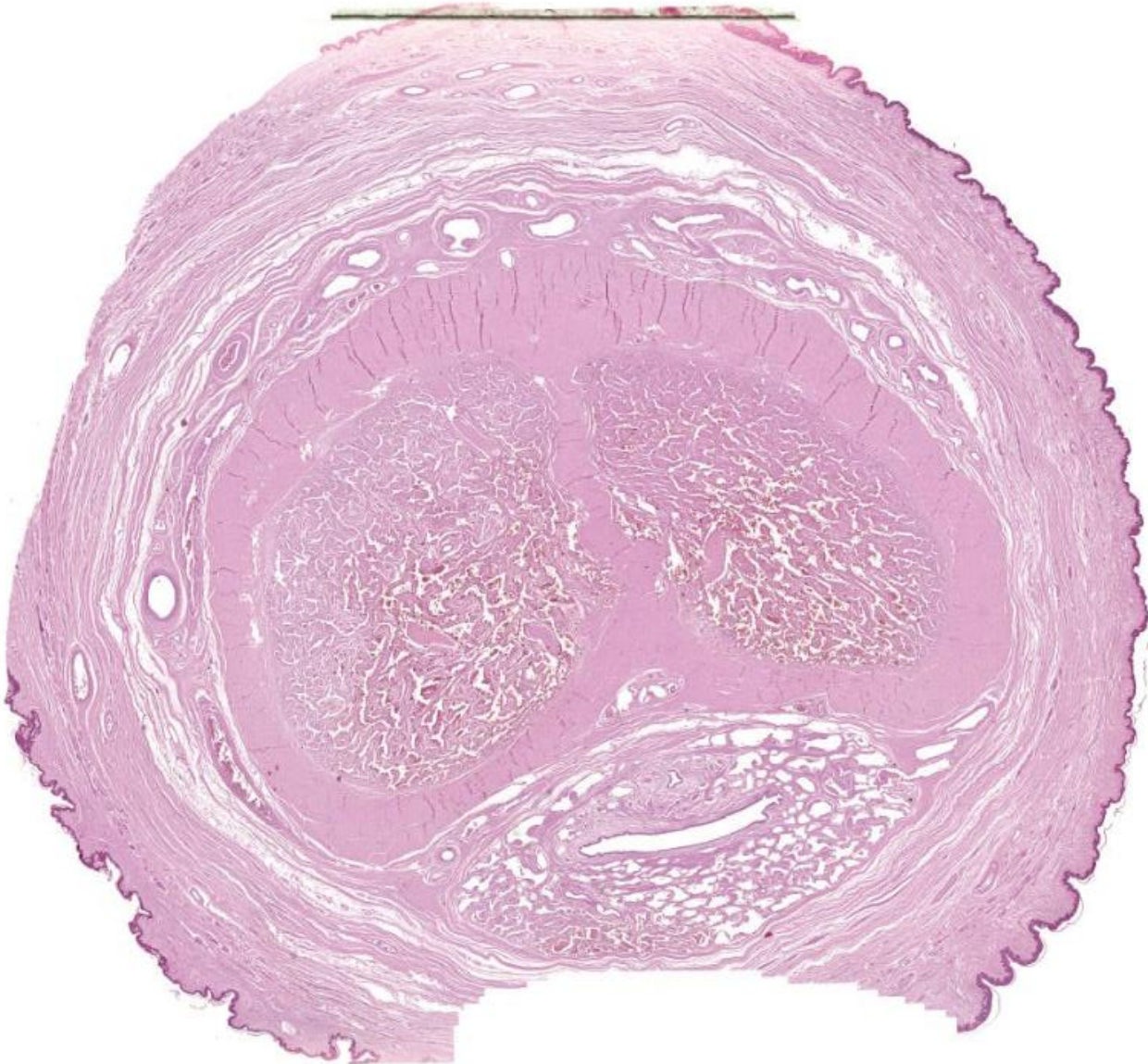


Corpus penis

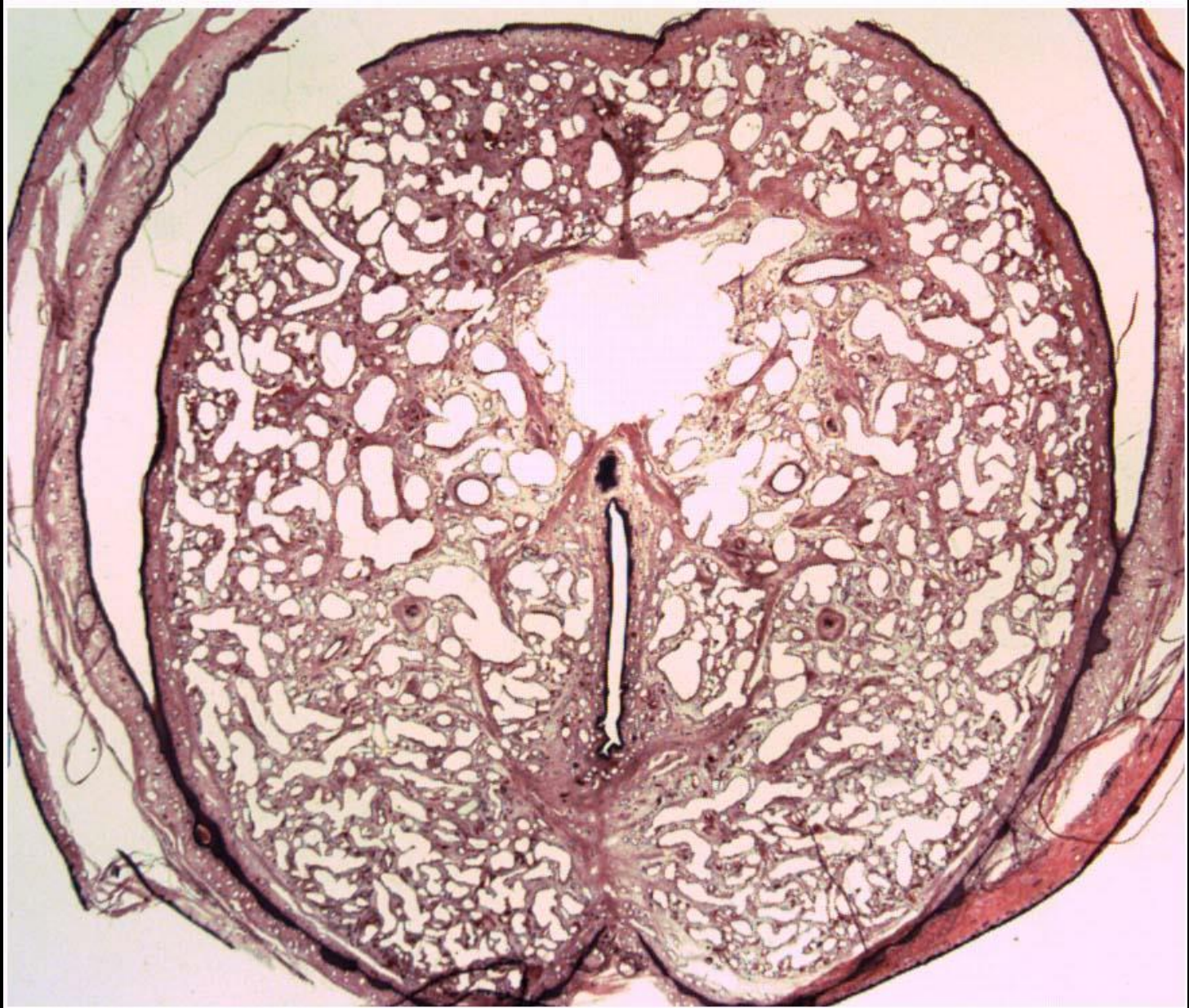


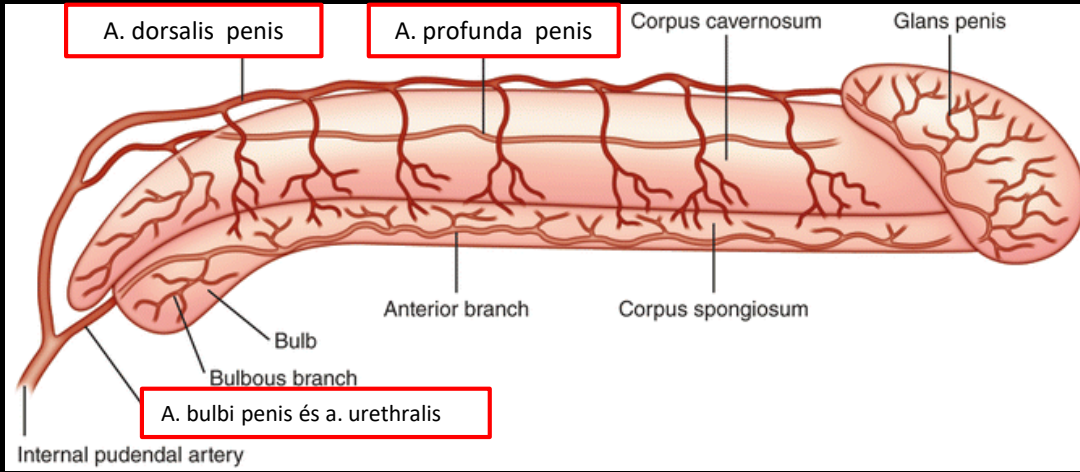


Corpus penis

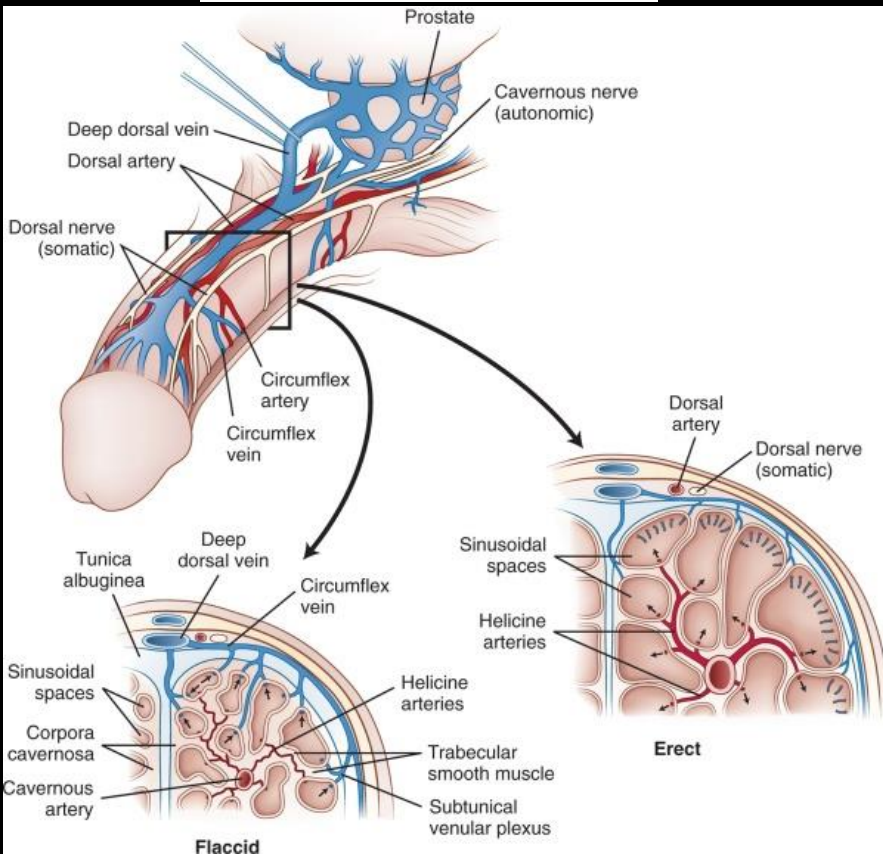


Glans penis

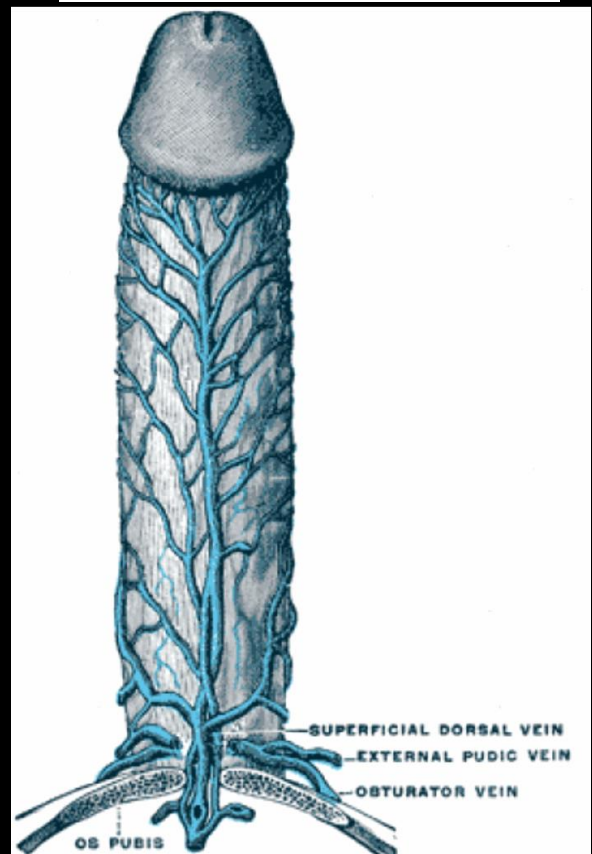


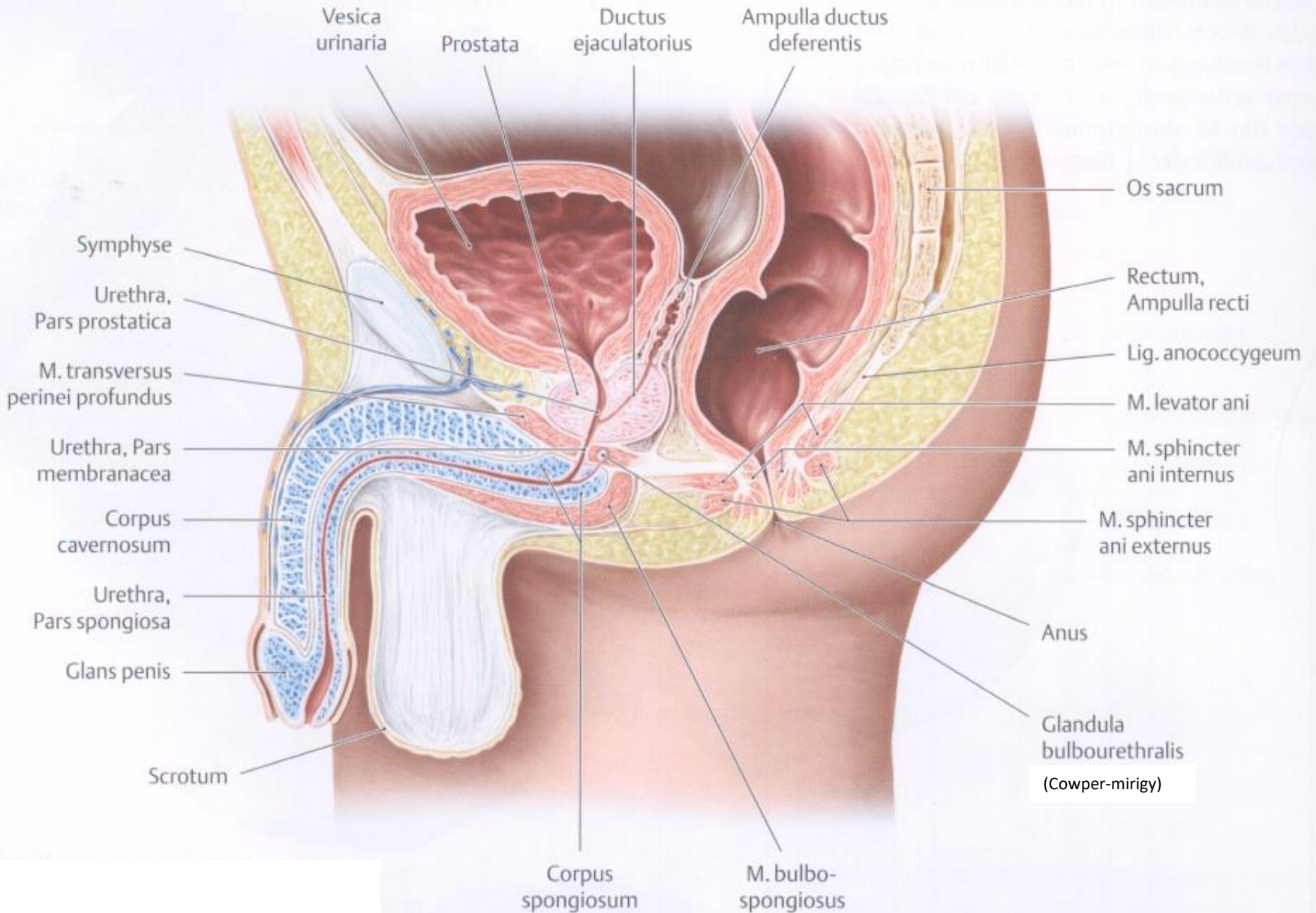


V. dorsalis profunda penis

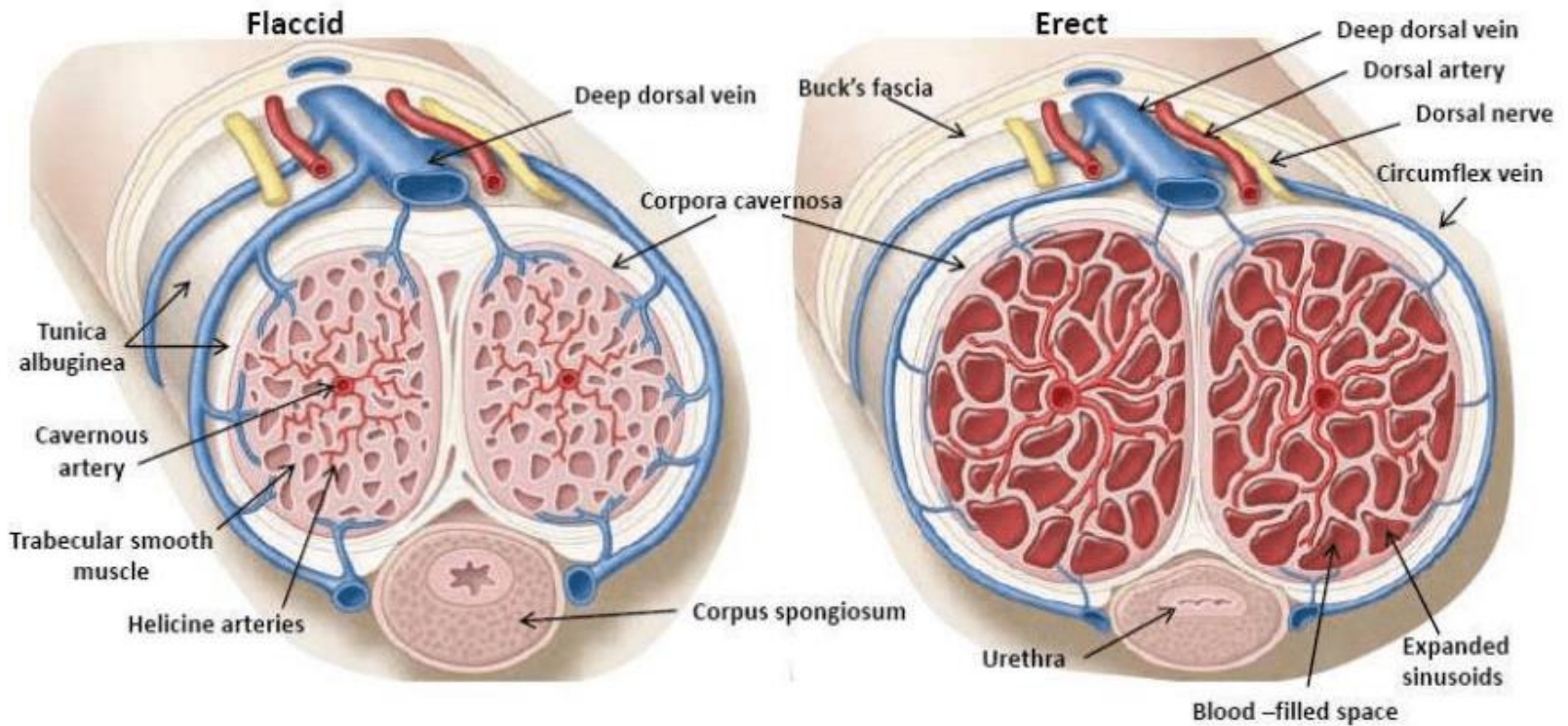


V. dorsalis superficialis penis

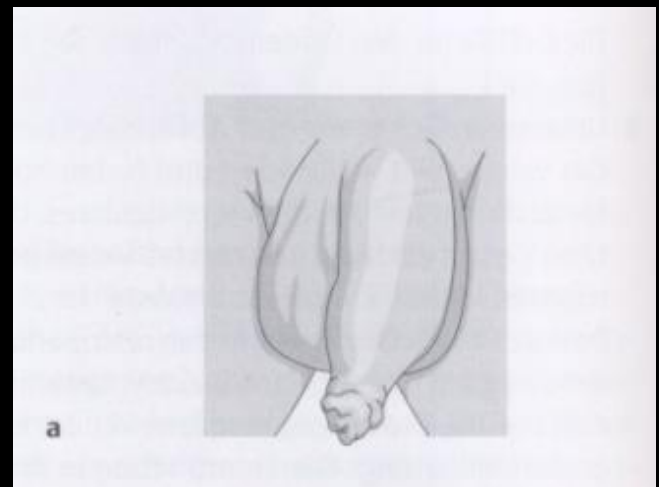
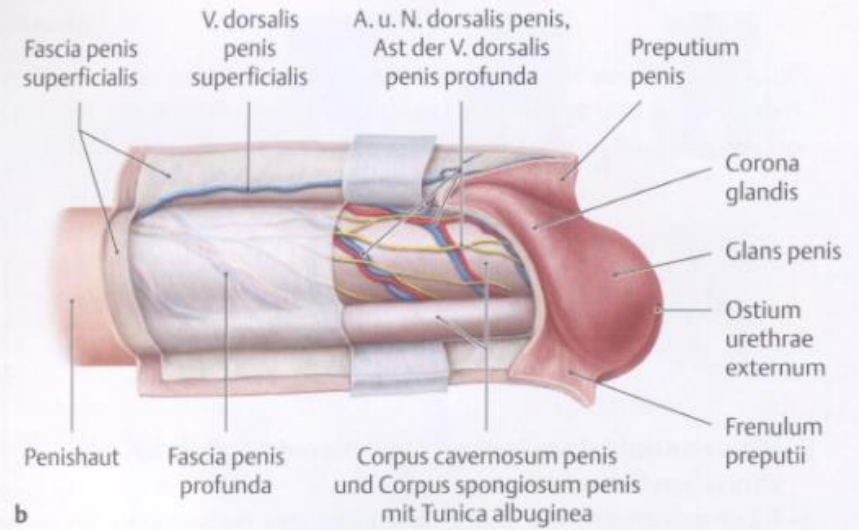
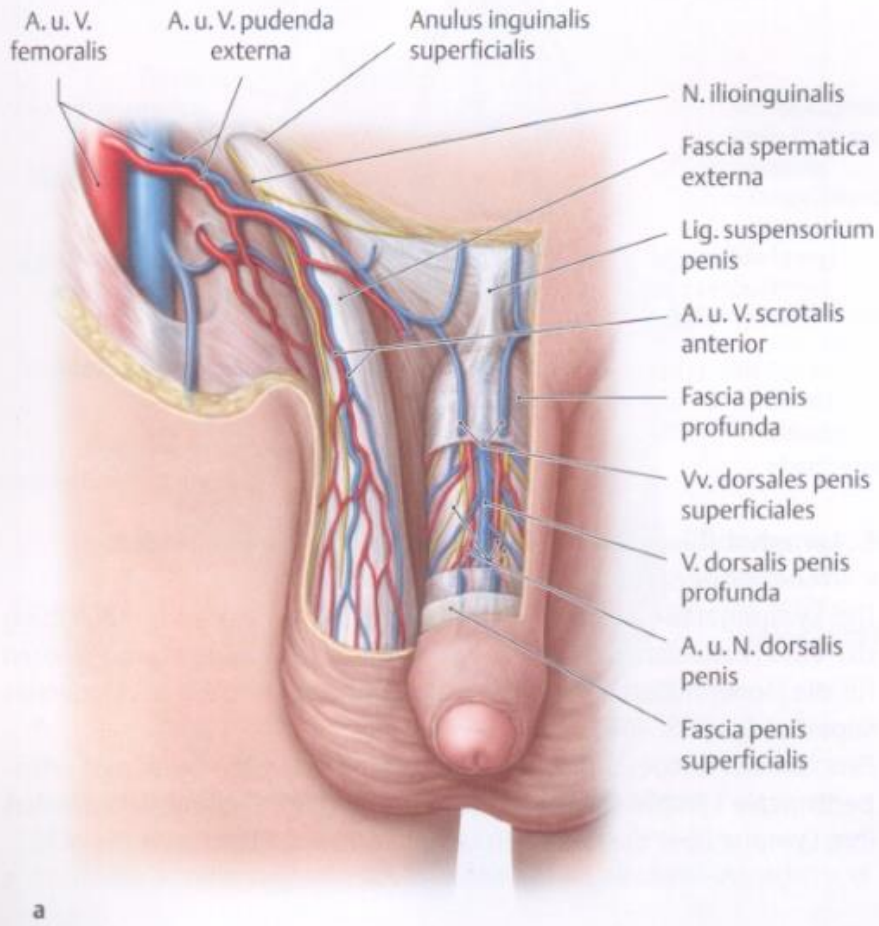




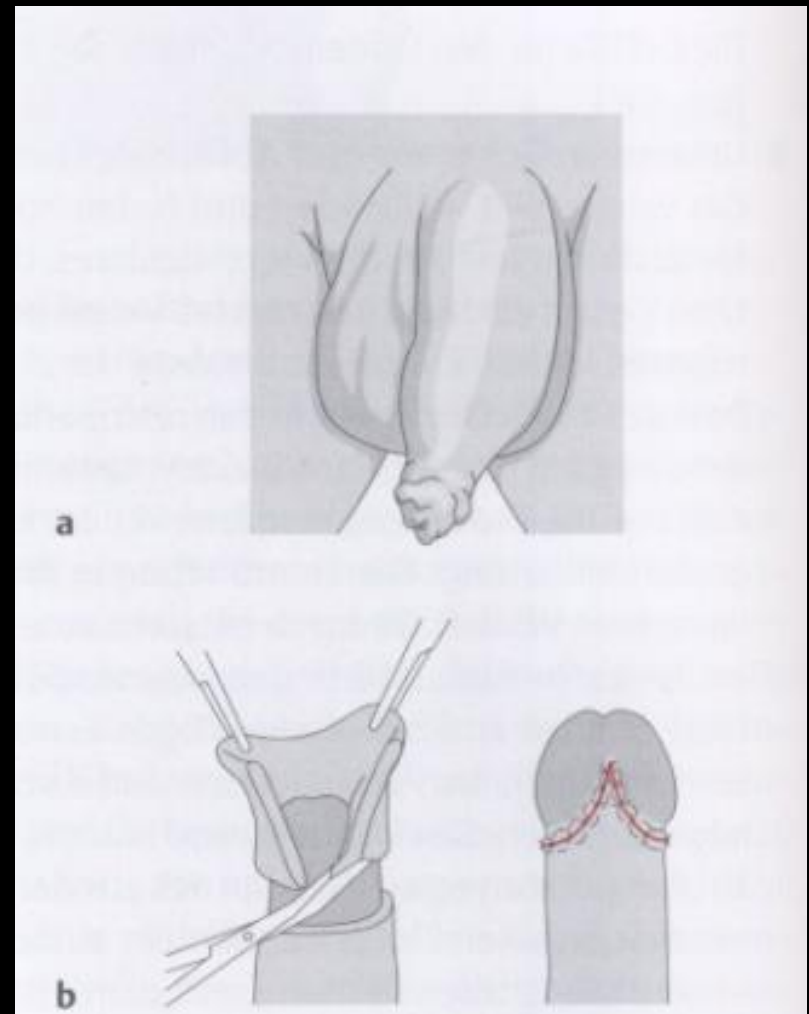
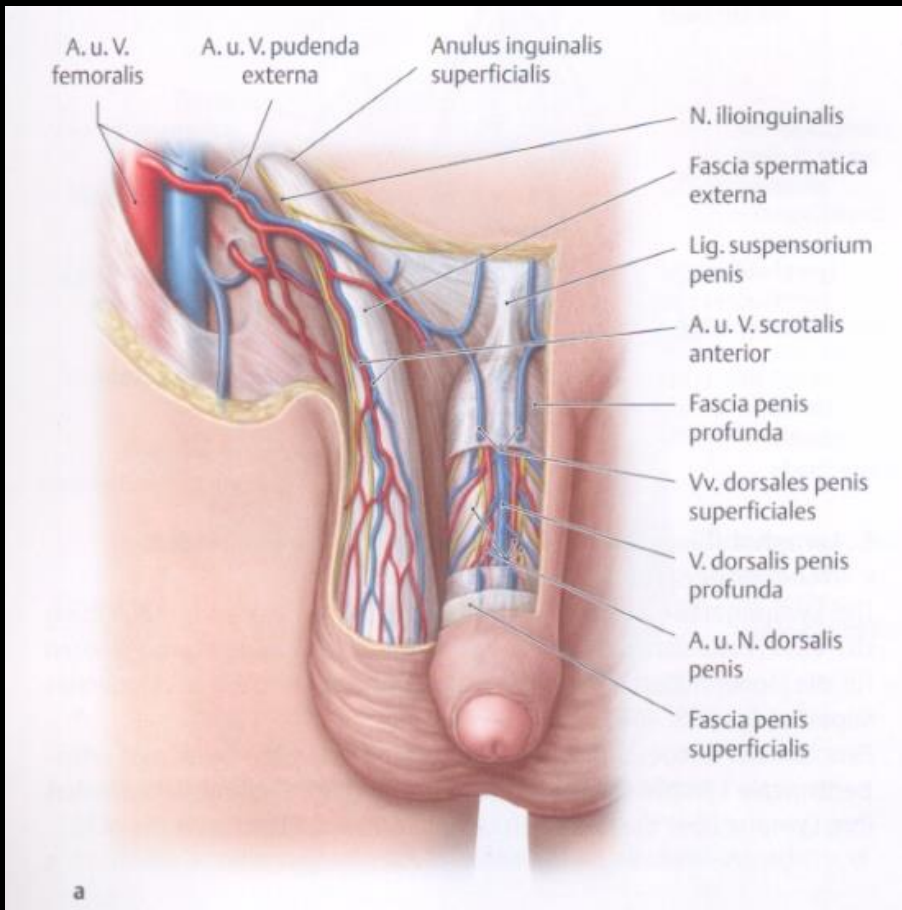
Erekció



Előbőr – fityma (preputium)



Körülmetélés (circumcisio)



Férfi medencefenék és gátizmok

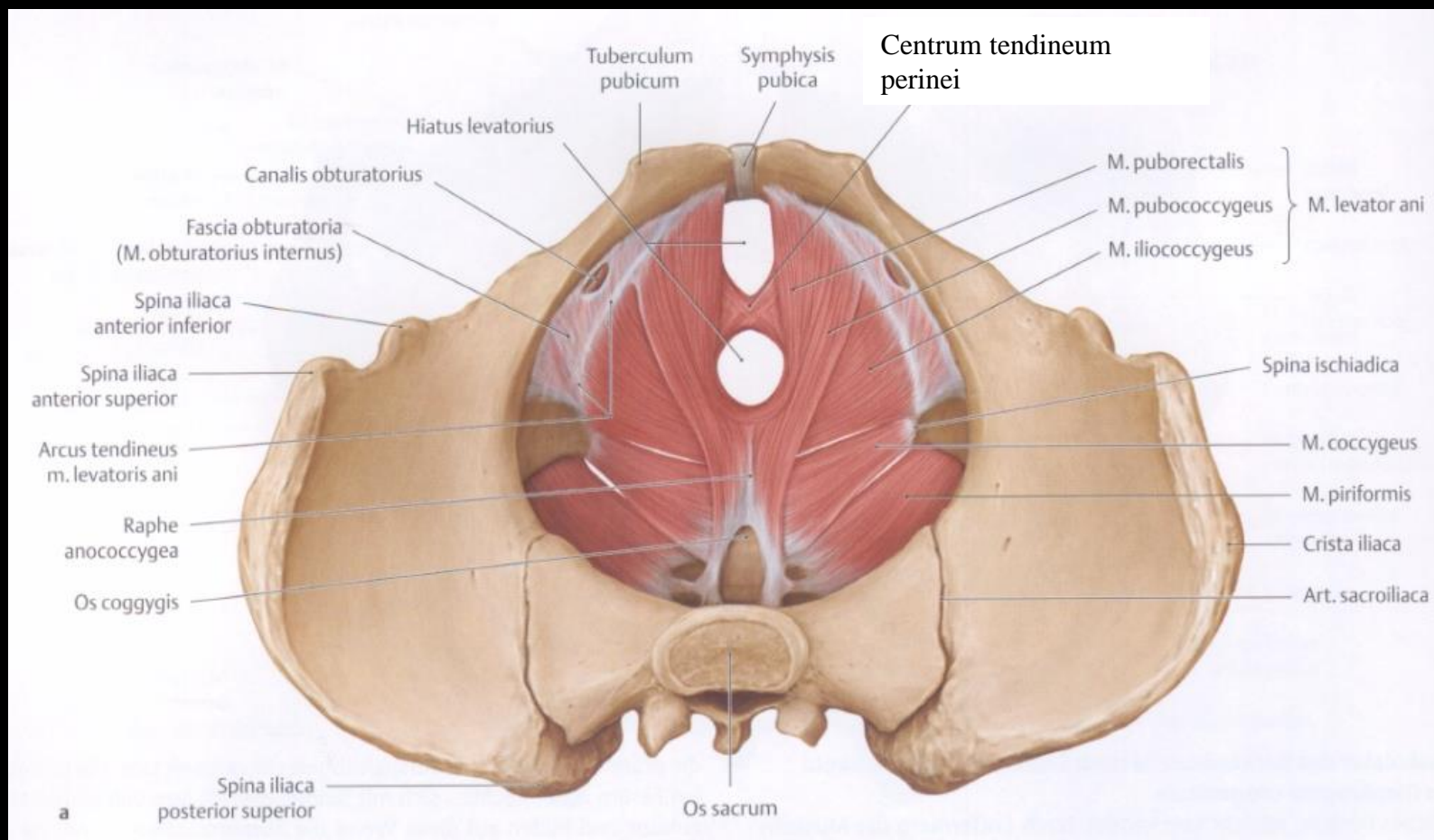
A medencefenék izmai

diaphragma pelvis

m. coccygeus

m. piriformis

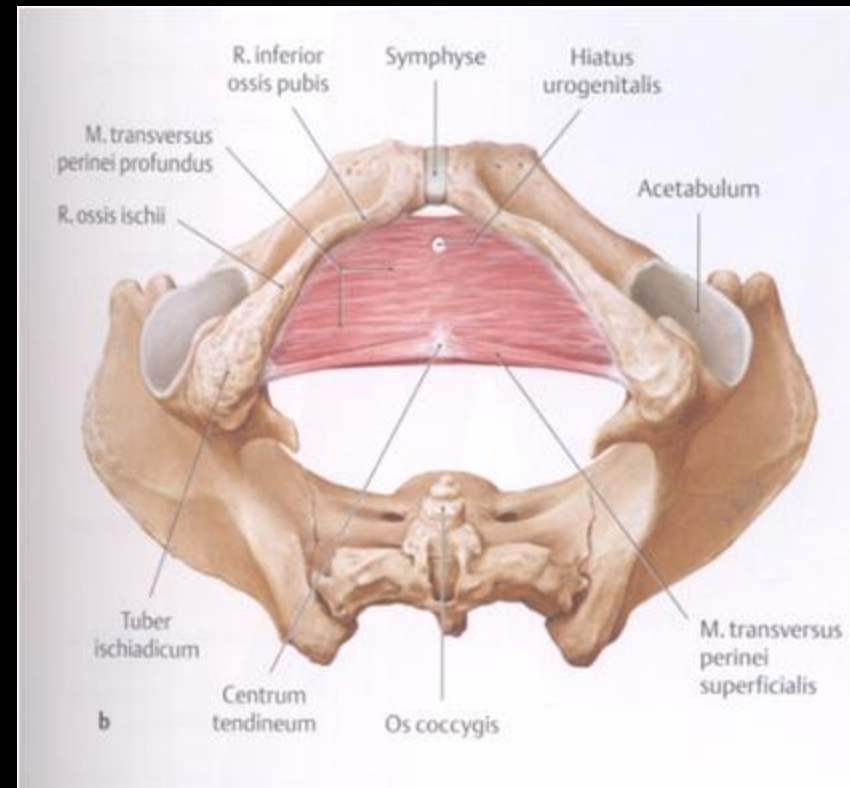
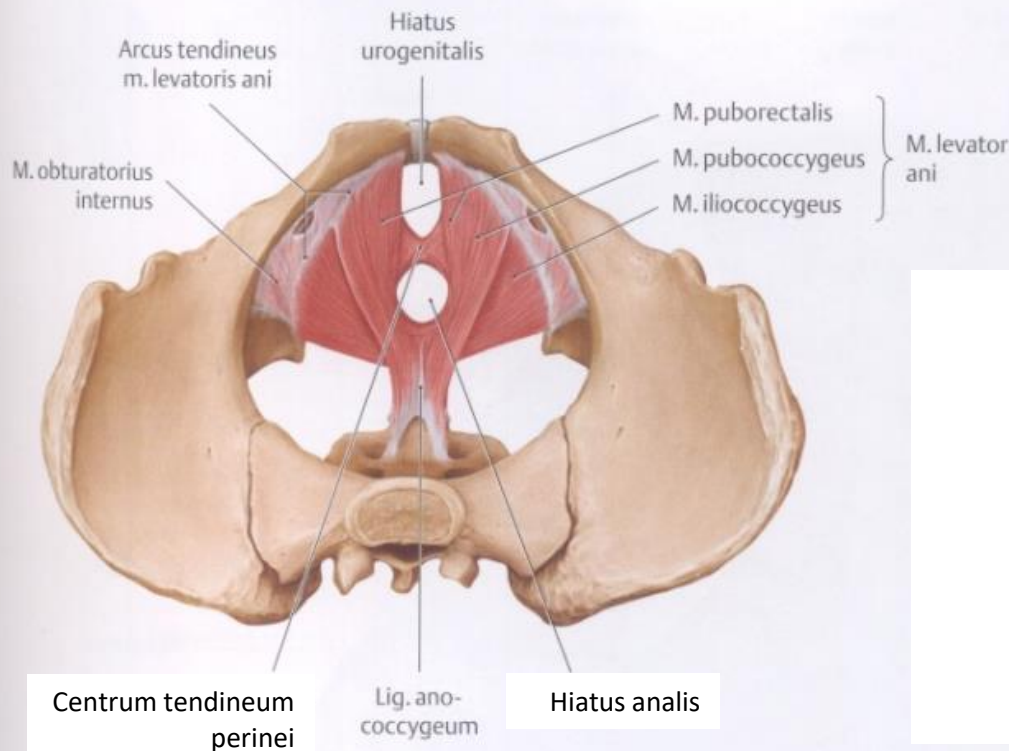
m. obturator internus



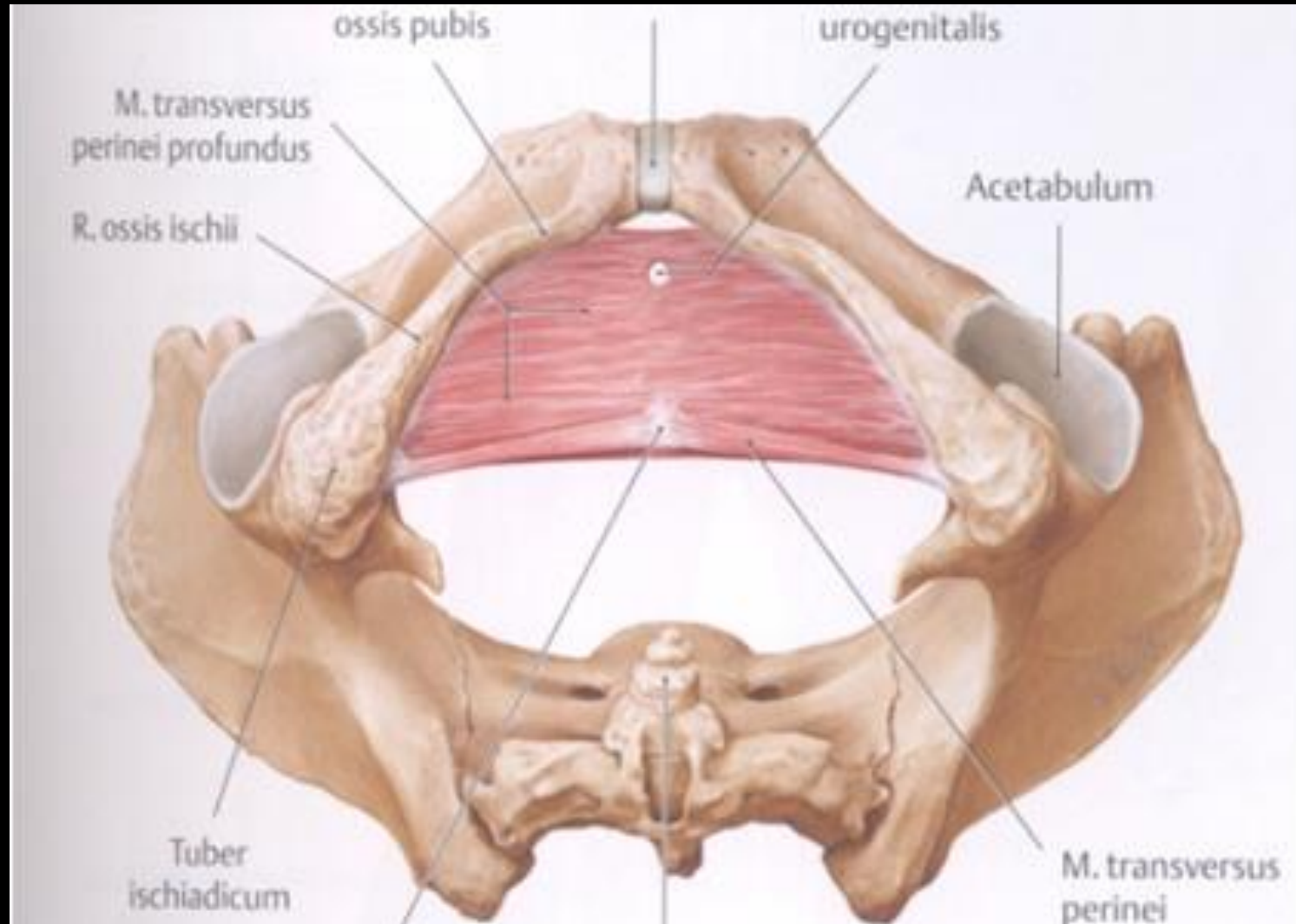
A medencefenék és gátizmok

diaphragma pelvis

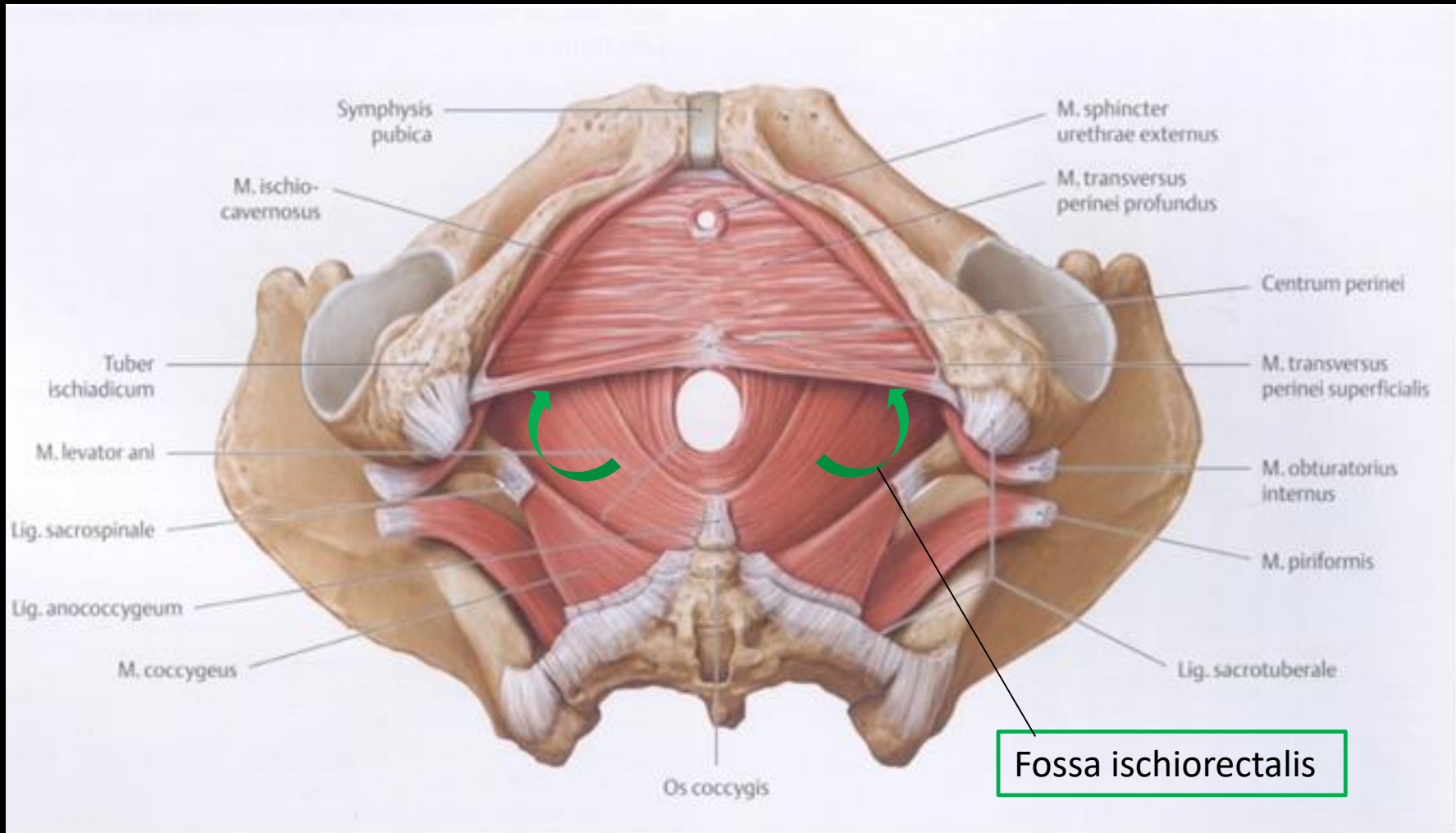
diaphragma urogenitale



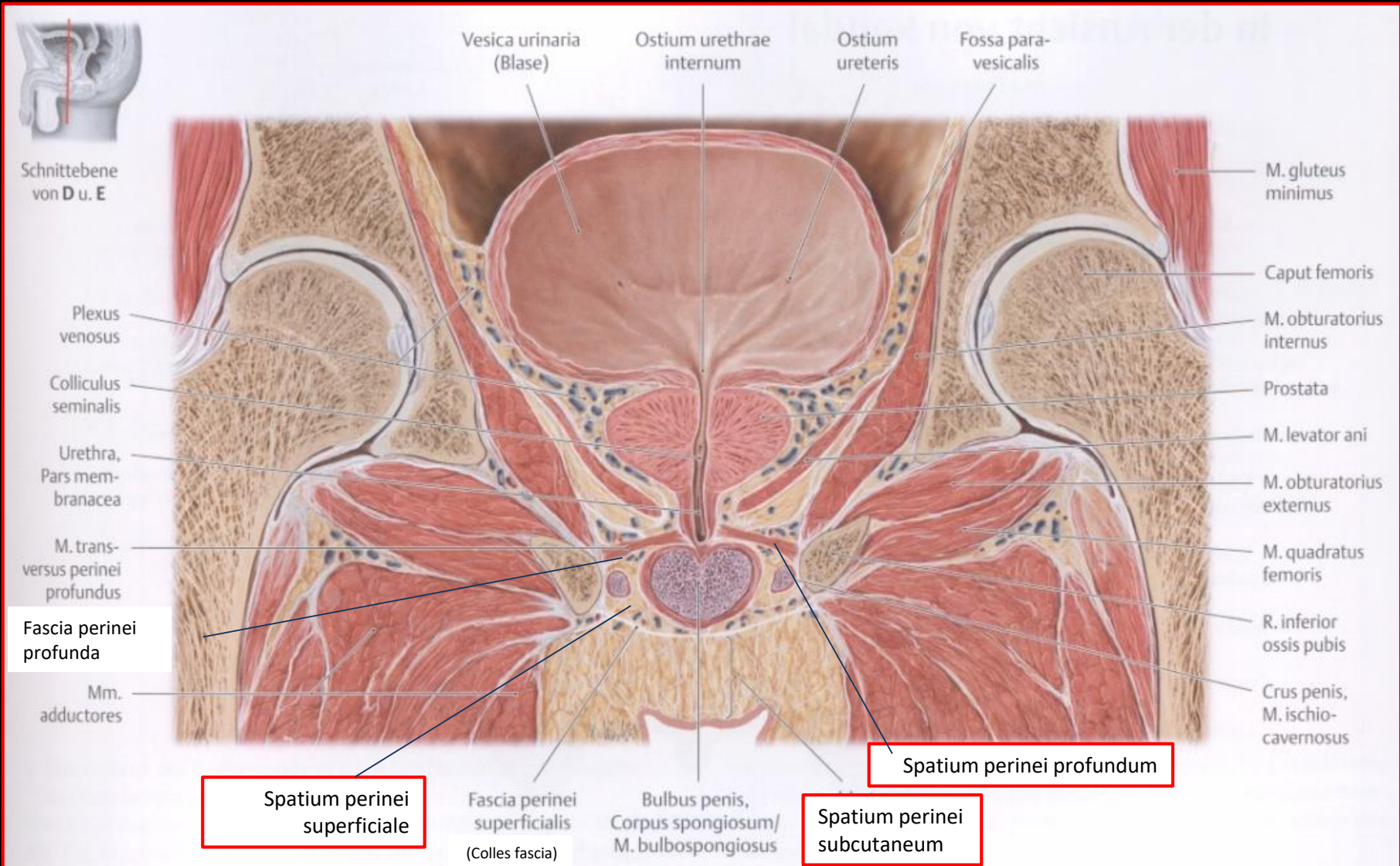
A gát területe (regio perinealis)



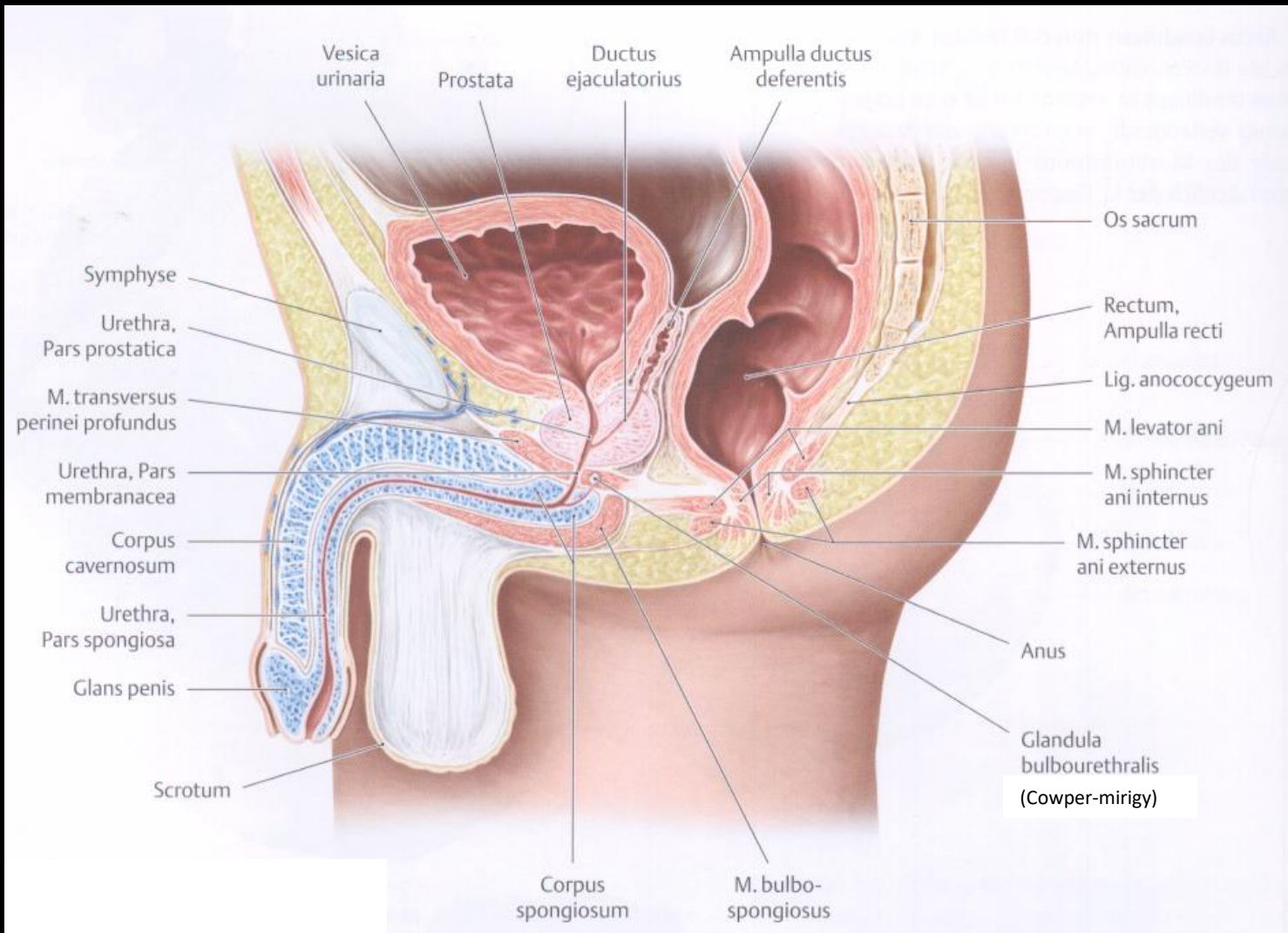
A gát területe (regio perinealis)



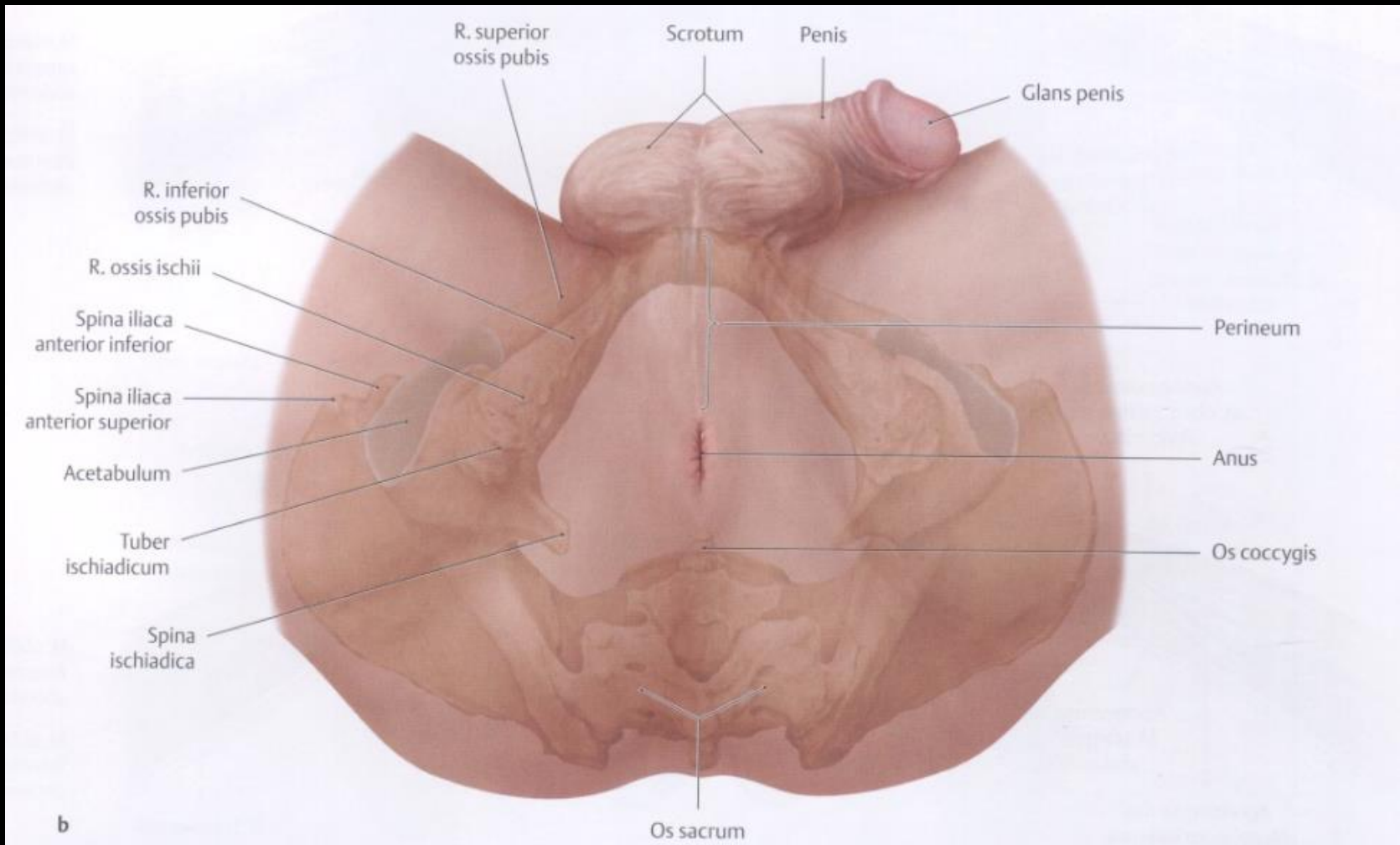
A medencefenék, a gátizmok és a **gát** szövetei



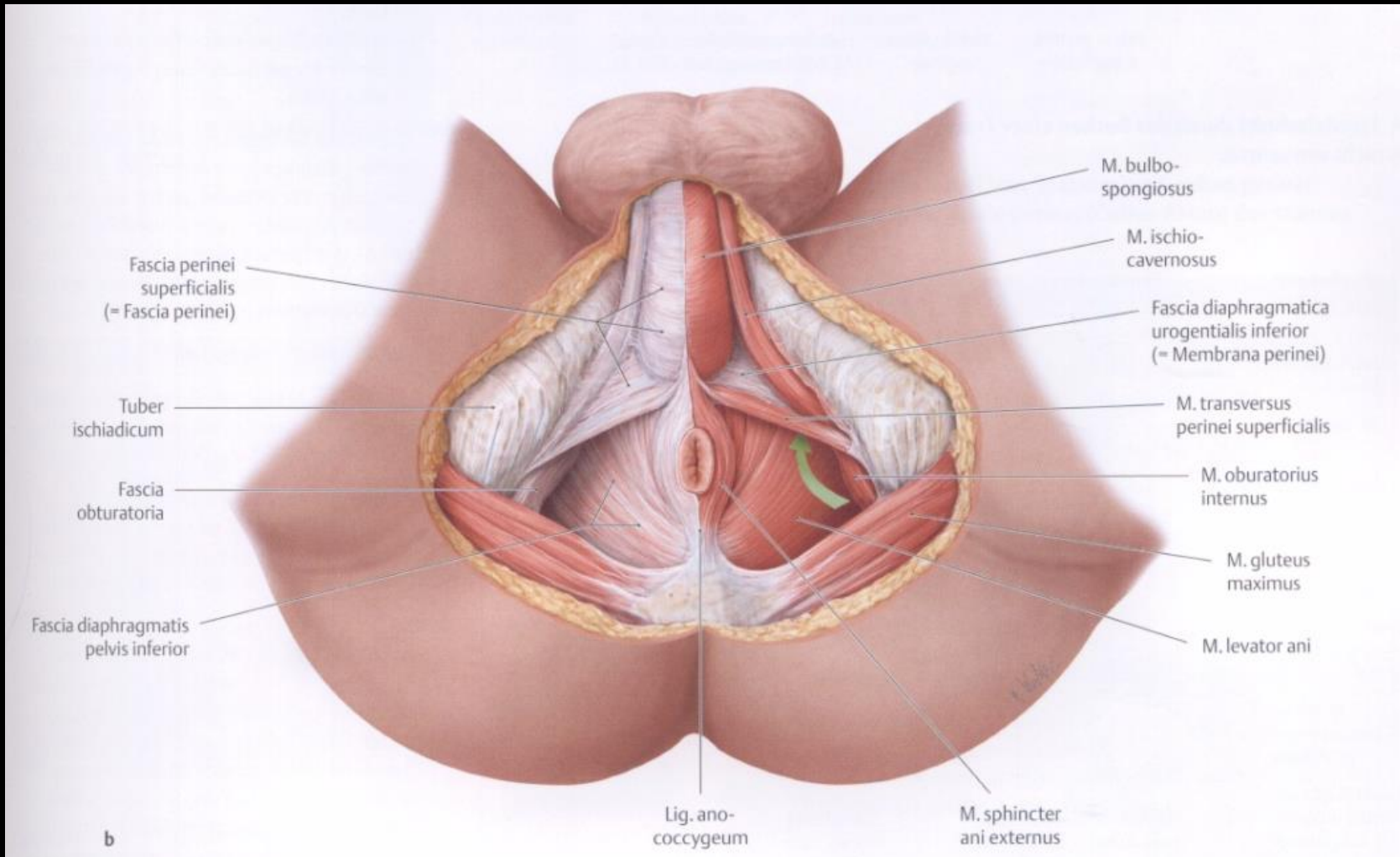
A medencefenék és gátizmok



A gát területe (regio perinealis)



A gát területe és a felszínes gátizmok



A gát területe (regio perinealis)

