Sympathetic nervous system, clinical relevances.

János Hanics M.D., Ph.D.

Vegetative (autonomic) nervous system

General function: to keep the homeostasis of the body.

Fast reactions to inner and outer stimuli independently from will (=autonomic: cardiavascular regulation, alimentary functions etc…). The stuctural basis is the vegetative **reflex arc**.

- The impulses of visceral receptors convey to the **central nervous system**, where they can integrate in different levels.

- The efferent pathways of the vegetative system regulate different organ systems.

- It has two main parts:

A. **Sympathetic** nervous system.

B. **Parasympathetic** nervous system.

Generally they cause opposite effects, which normally complete each other – create homeostasis. Differenciation based on their:

1) anatomy,

2) neurotransmitters,

3) effect on organs.

Vegetative nervous system

It has a central and peripheral part.

Central part:

1. Hypothalamus

2. Vegetative centers of the brainstem:

- respiratory and vasomotor center of the brainstem
- periaquaeductal grey matter of the midbrain
- the visceromotor and viscerosensory nuclei of cranial nerves

3. Spinal cord level (intermediolateral cell column)

DLF – dorsal longitudinal fasciculus (of Schütz) – band of ascending and descending pathways which connect central vegetative centers.

Peripheral part:

1. cranial outflow (CN. III; VII; IX; X) parasympathetic
2. thoracolumbar outflow (T1-L3) sympathetic
3. sacral outflow (S2-S4) parasympathetic

Vegetative efferents

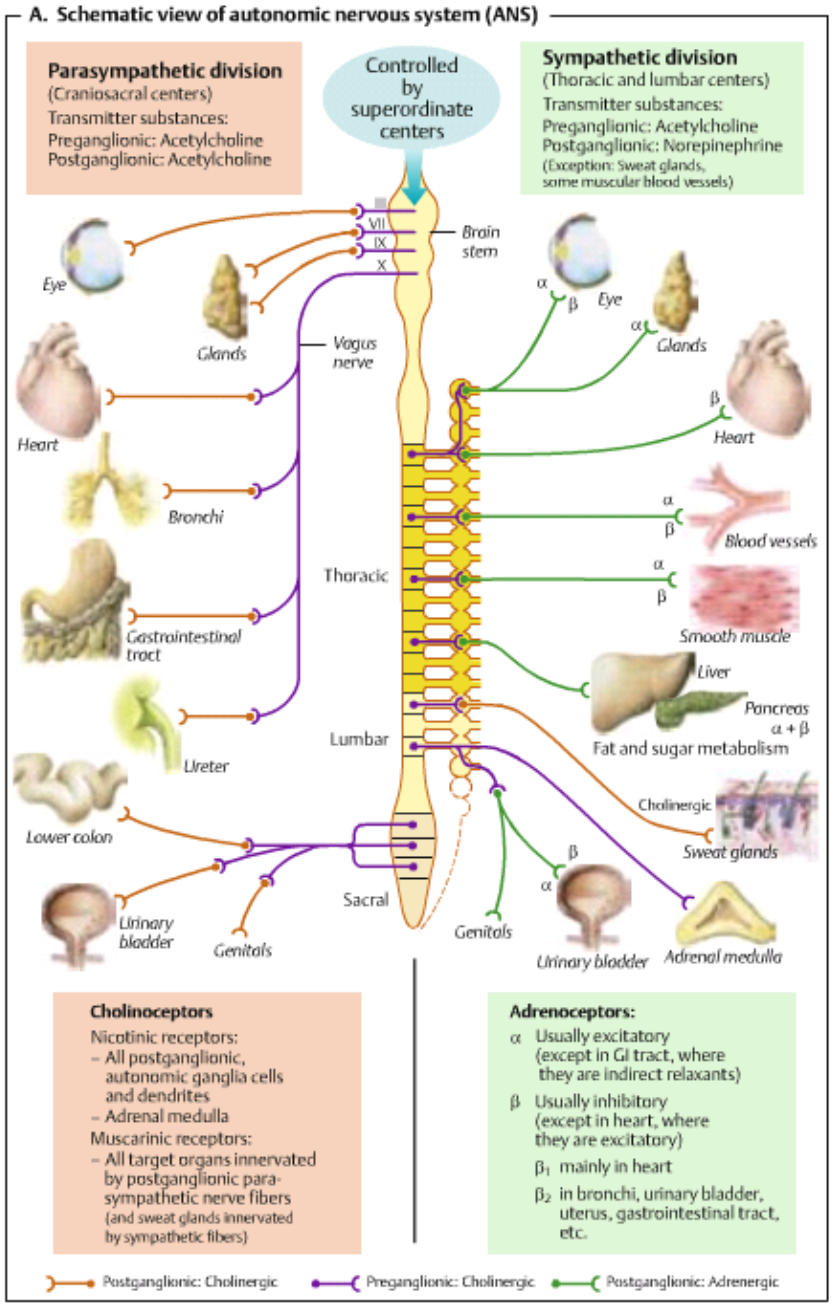

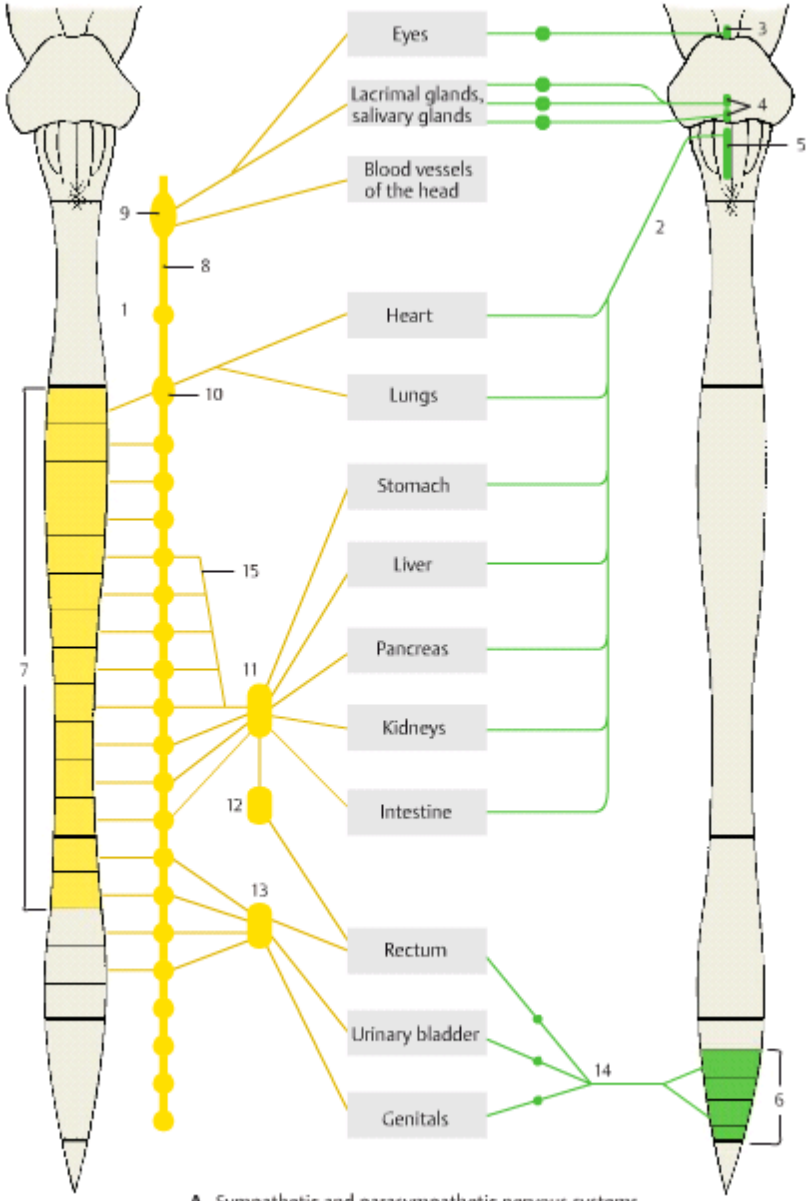

A Sympathetic and parasympathetic nervous systems (adapted from *Villiger and Ludwig*)

Para – and praevertebral ganglia

Intramural ganglia

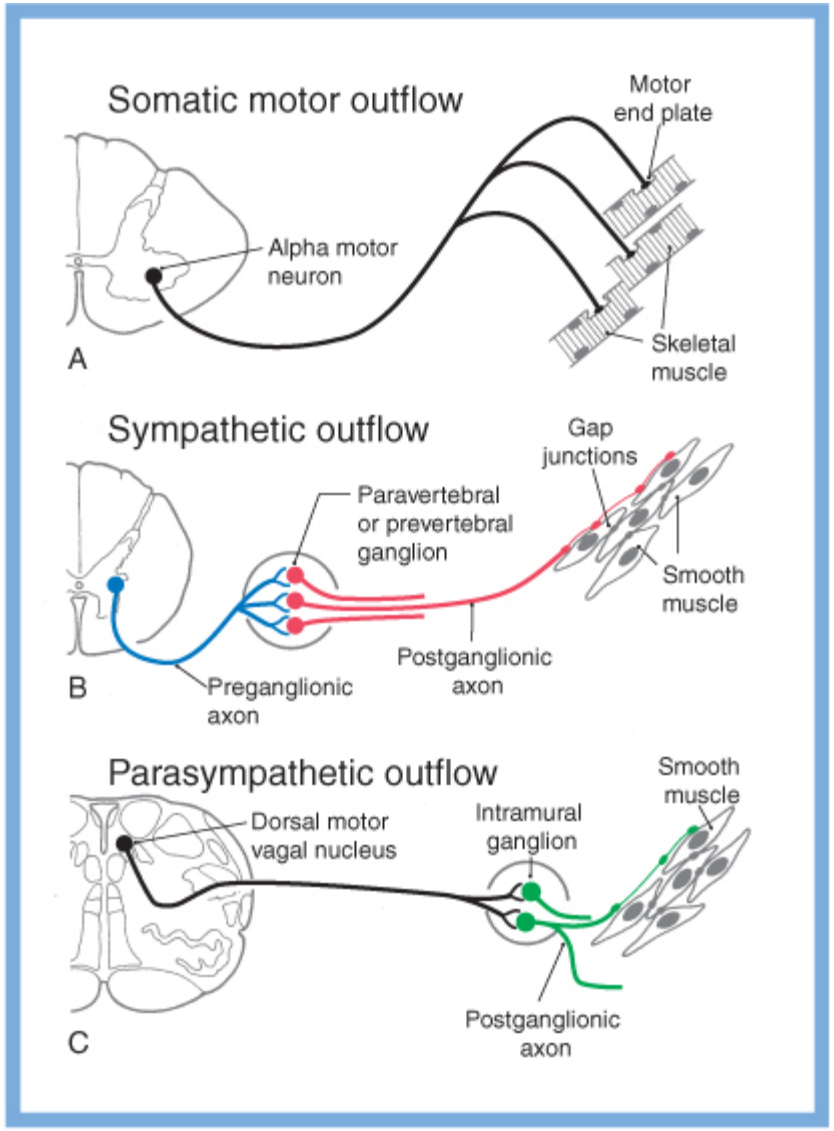

EFFERENTS

Always in „two step”

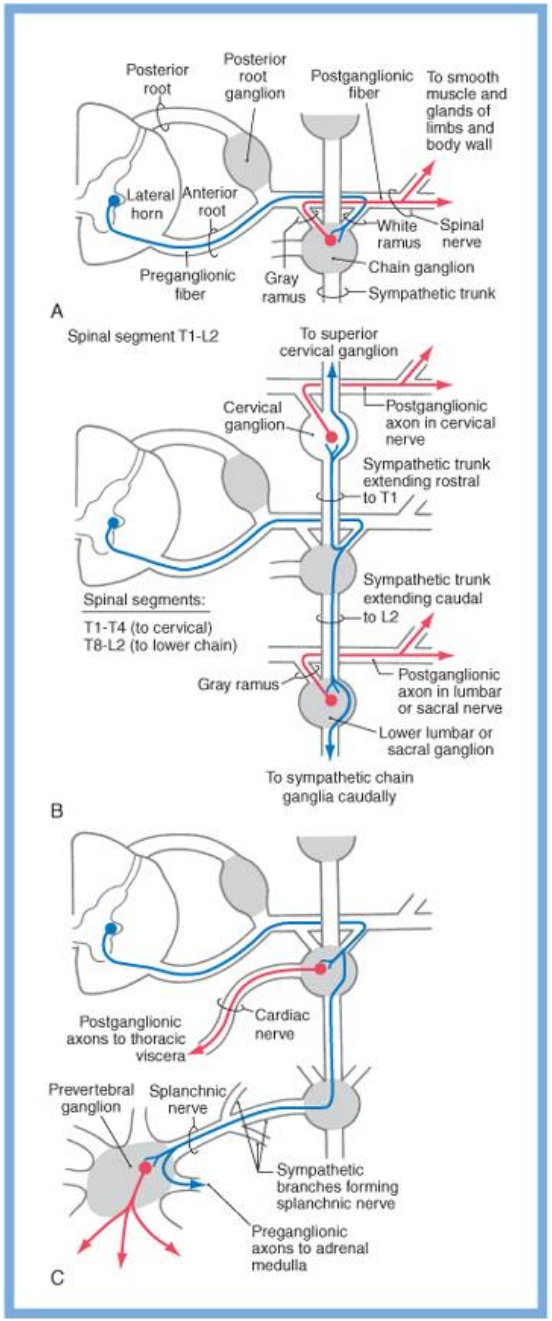

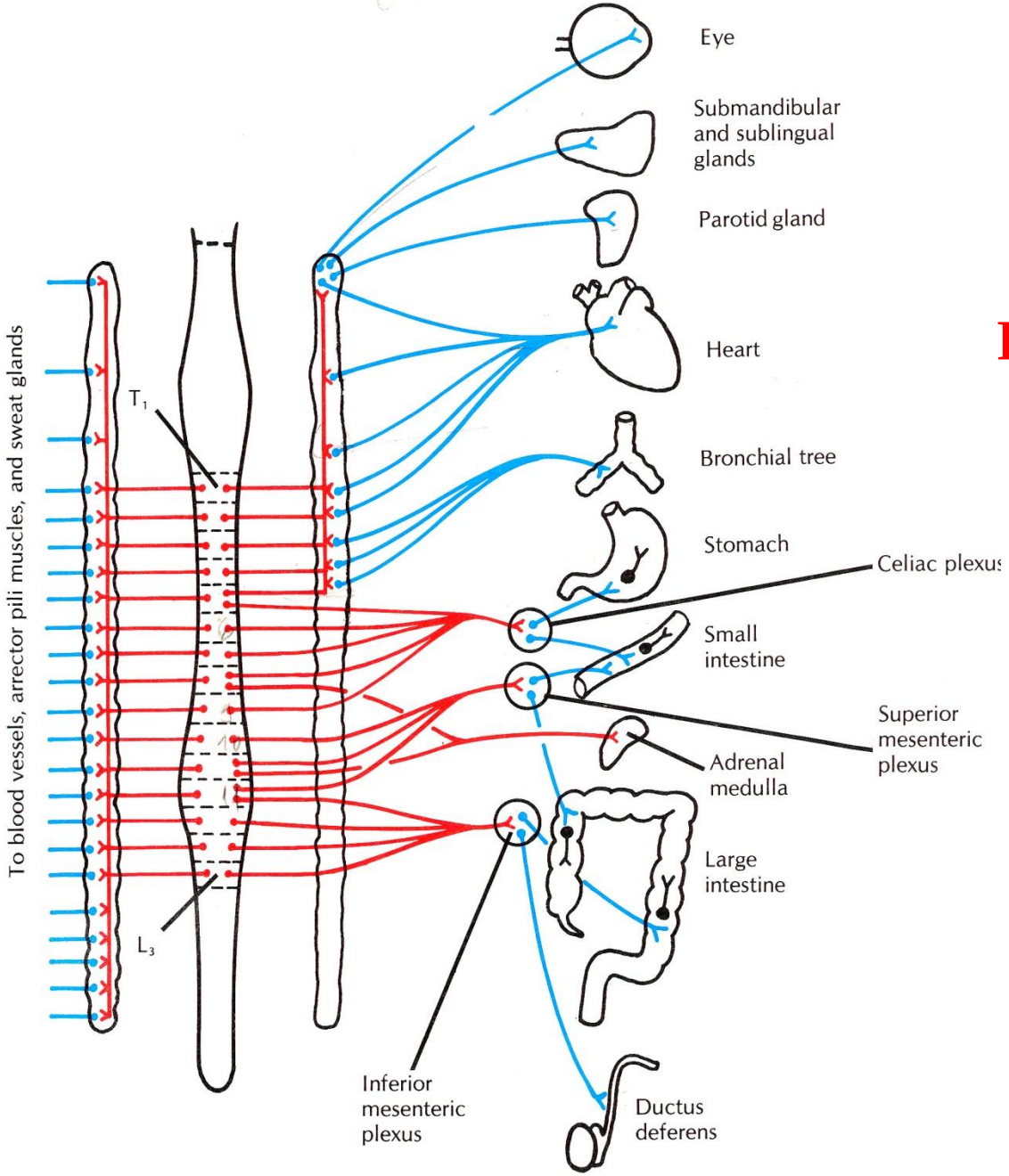

FIGURE 24-4.
The sympathetic nervous system.

Parts of the sympathetic nervous system

Cephalic and cervical parts

Thoracic part

Abdominal part

Pelvic part

Grey and white communicating rami
(Ramus communicans albus et griseus)
= paravertebral ggl.
Sympathetic trunk

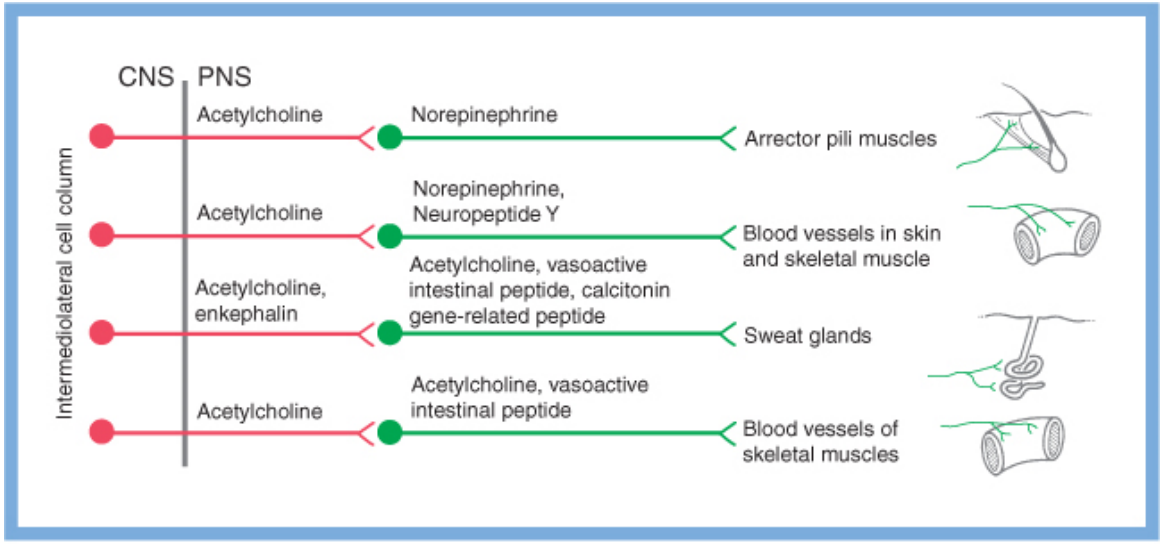

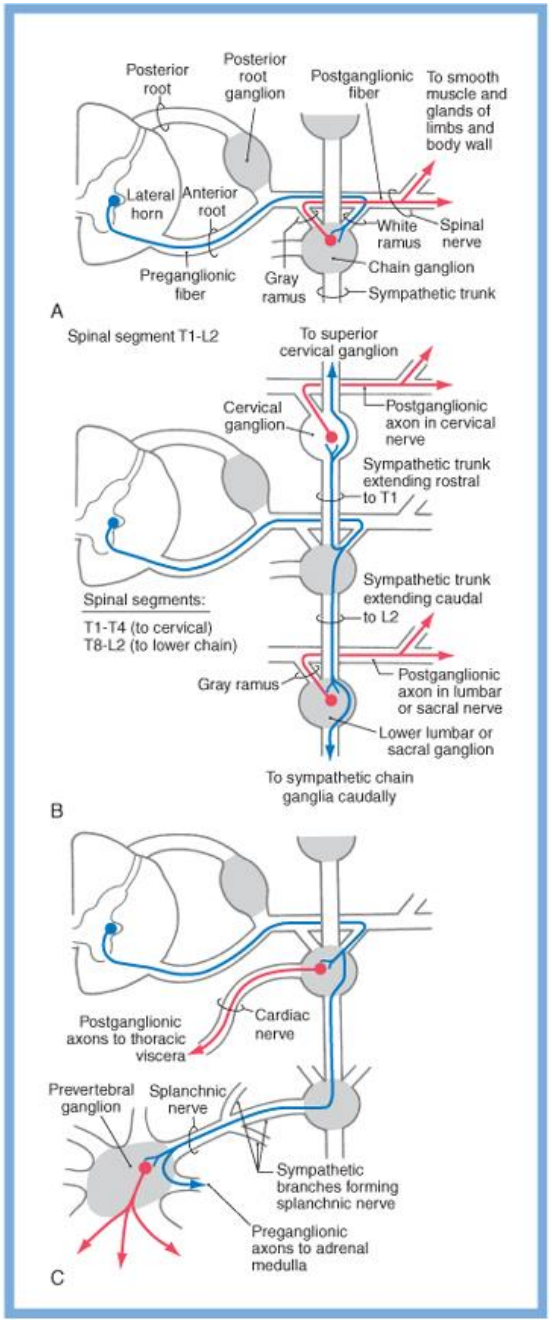

Cephalic and cervical parts (Sup. and med. cervical ggl.)

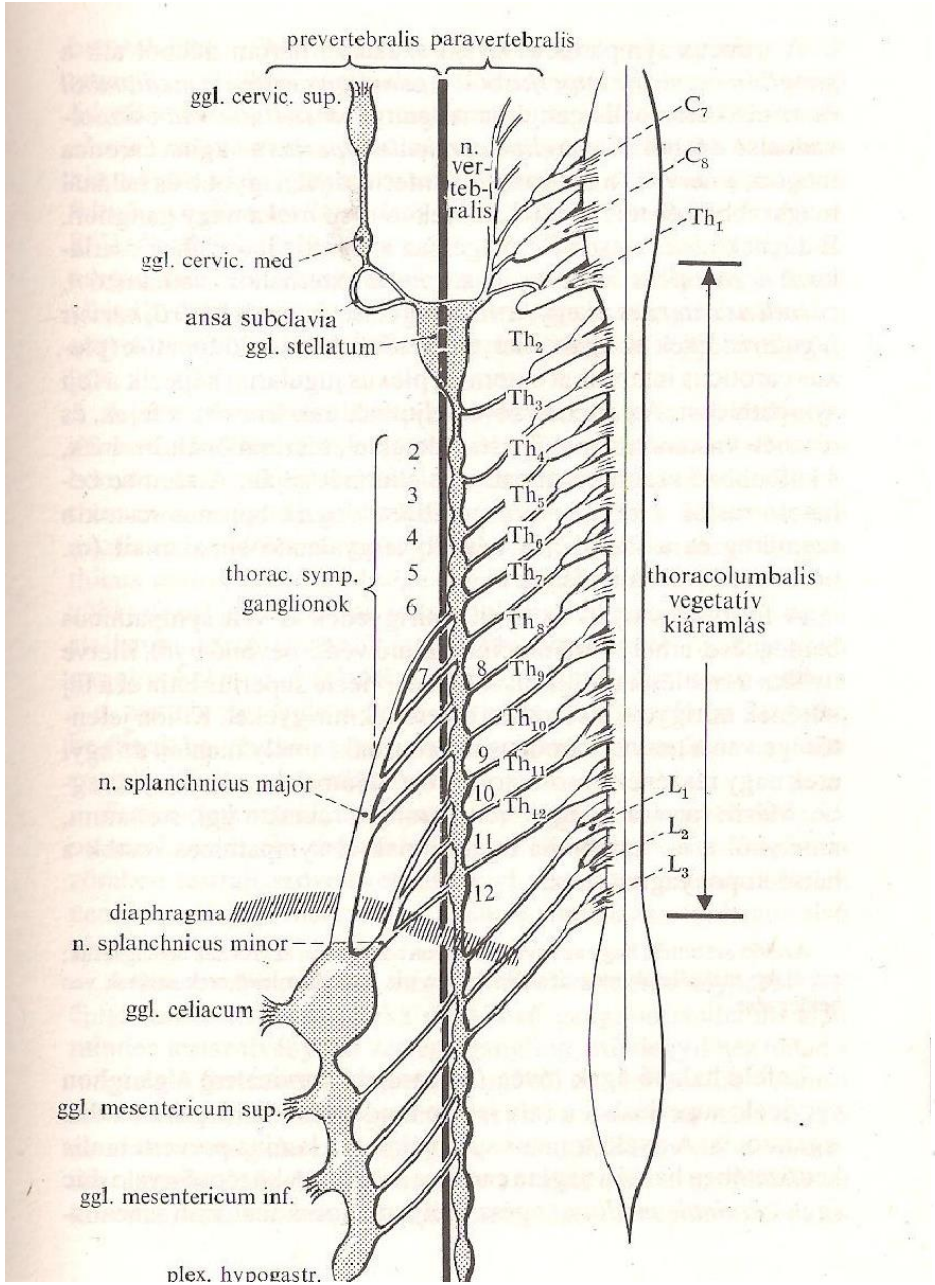

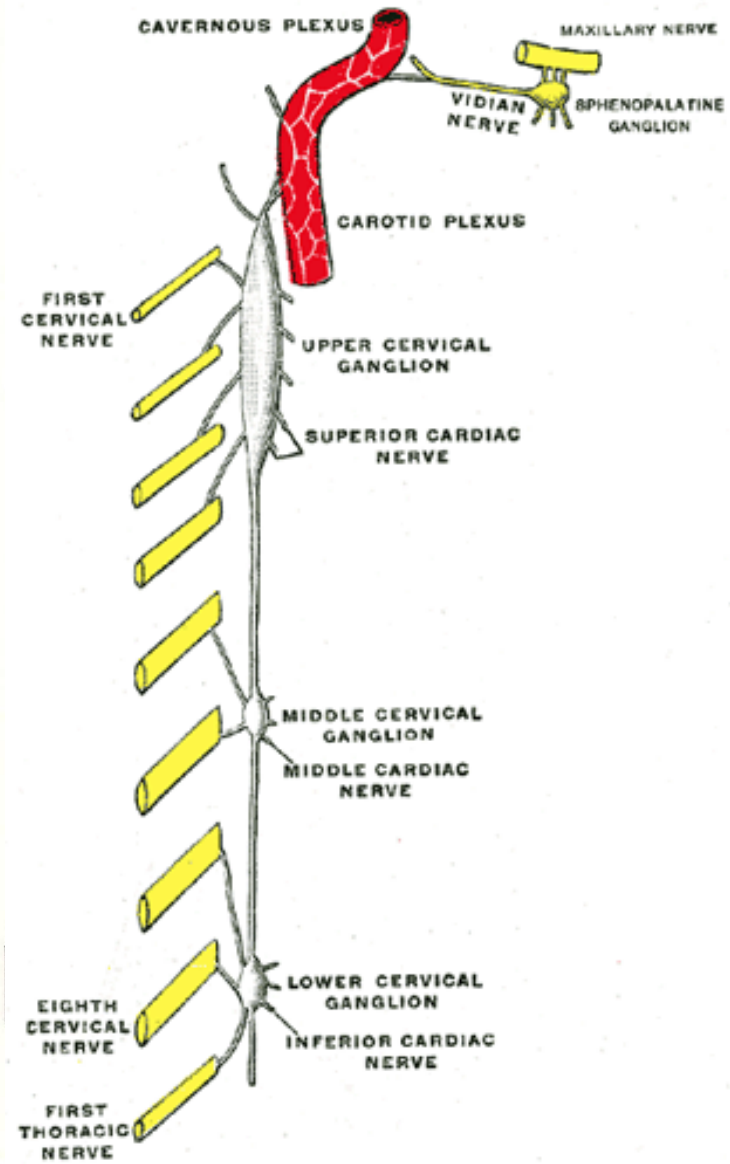

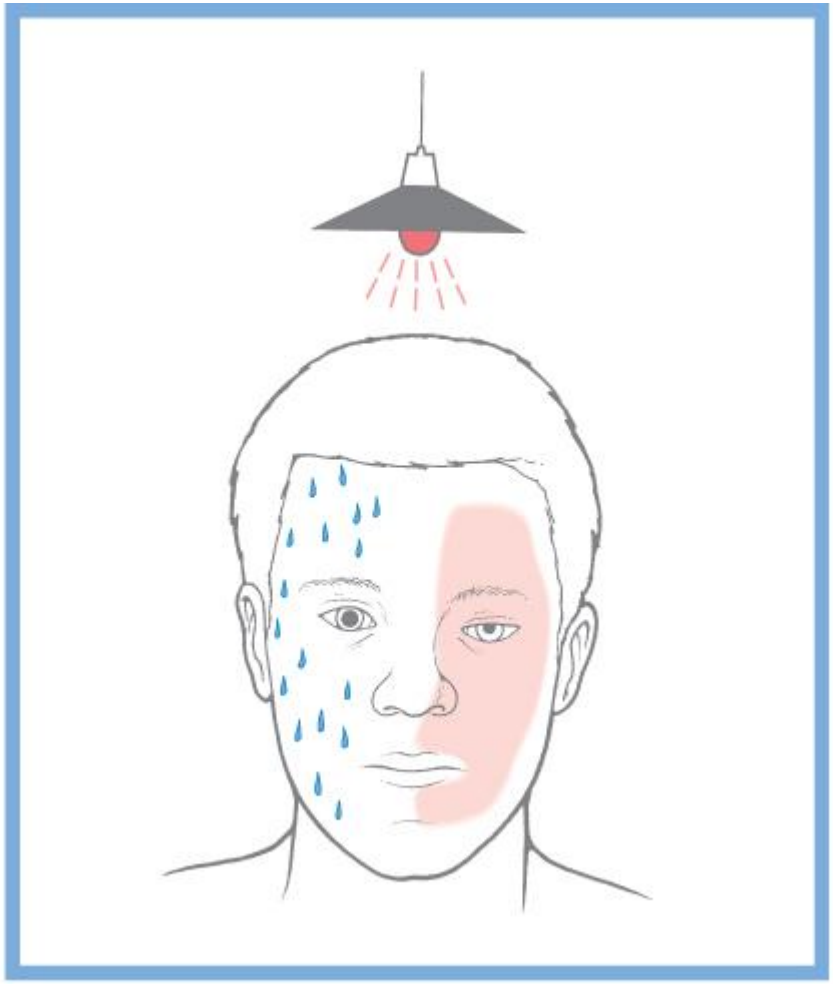

Horner's symptompts

Ptosis (sup. tarsal m.)
Enophtalmus (orbitalis m.)
Miosis (dilatator m. of pupillae)
Anhidrosis (sweat glands)

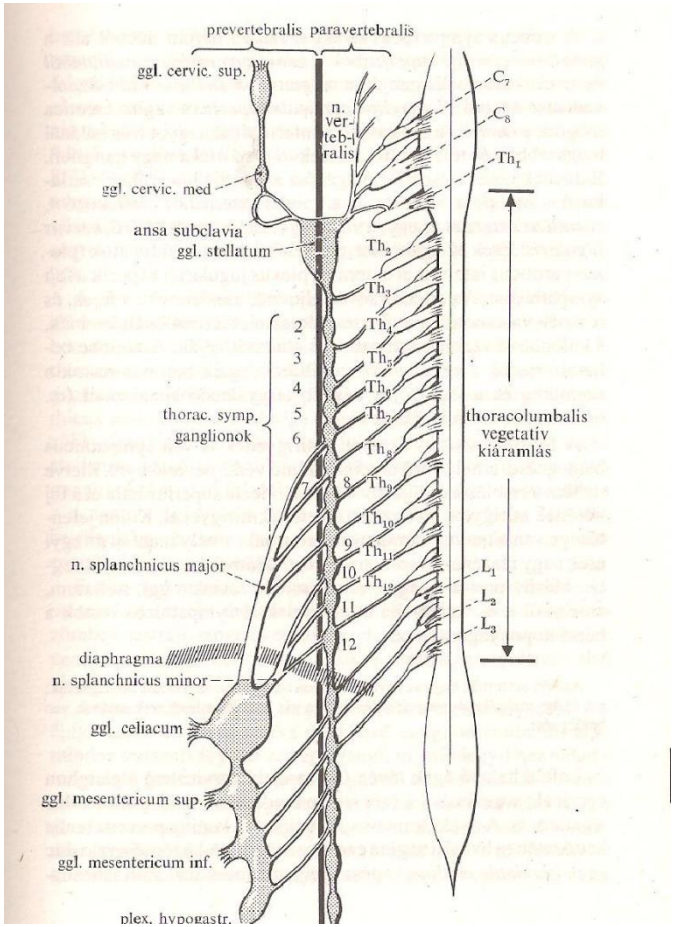

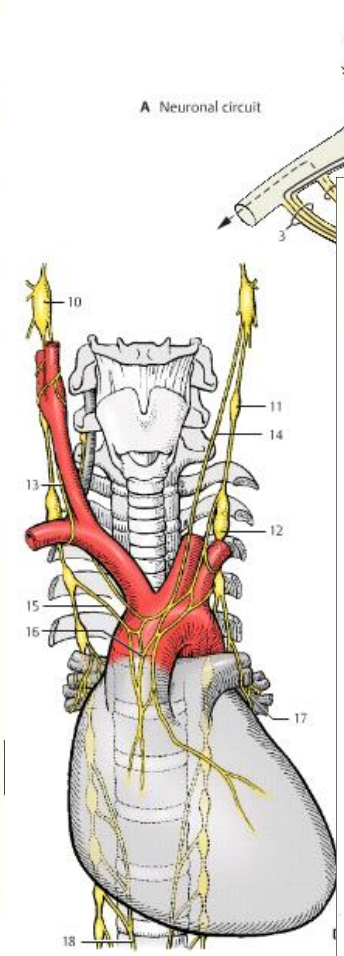

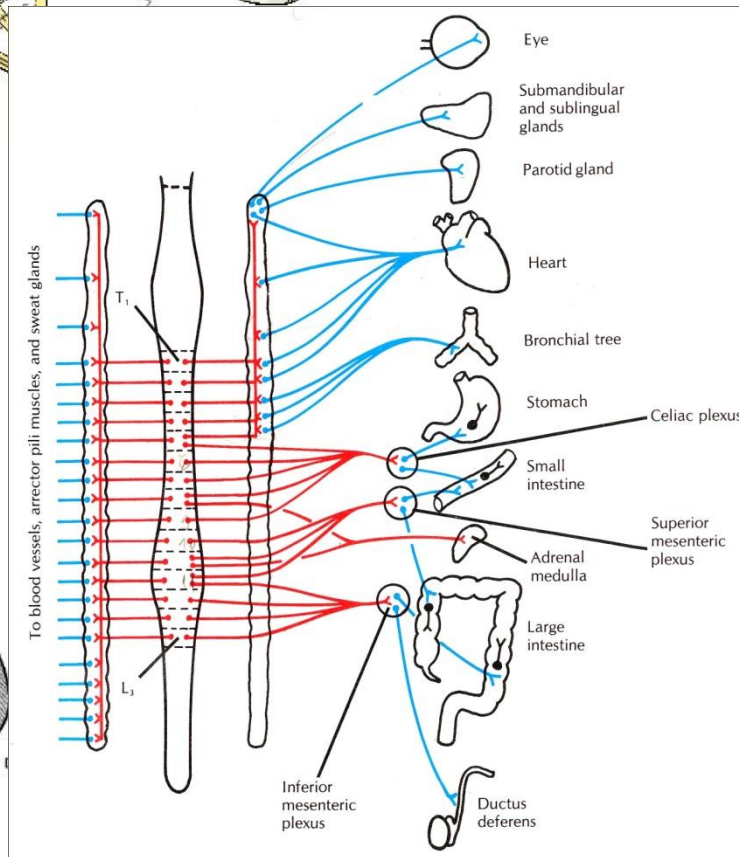

FIGURE 24-4.
The sympathetic nervous system.

Thoracic part
(Stellate ggl. (ggl. cervicothoracicum)

Abdominal and pelvic parts

Splanchnic nerves!!!

Adrenal medulla!!!

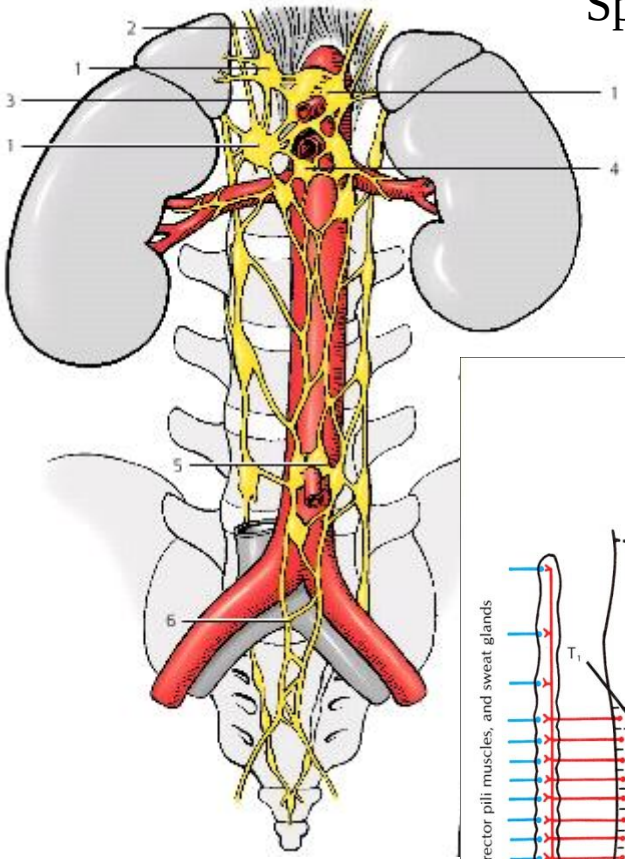

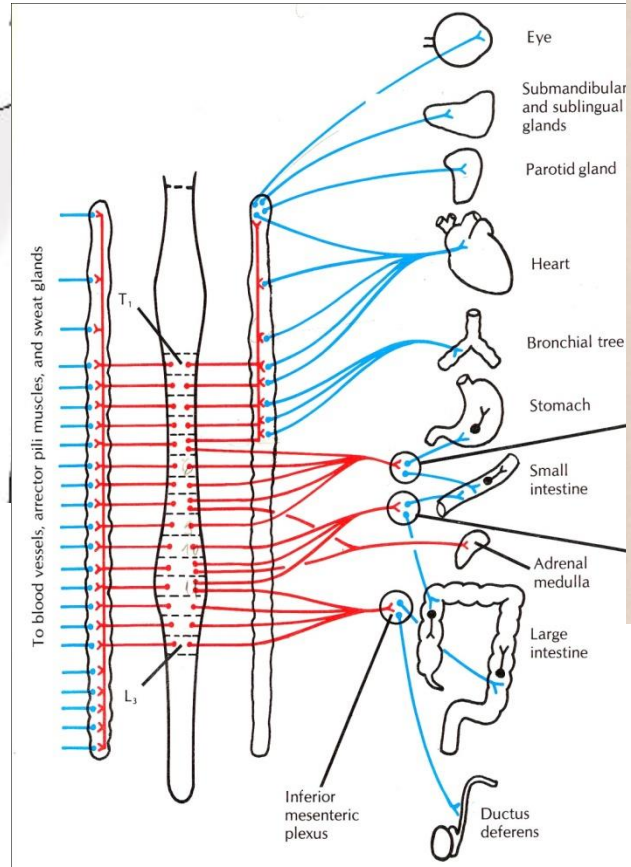

FIGURE 24-4.
The sympathetic nervous system.

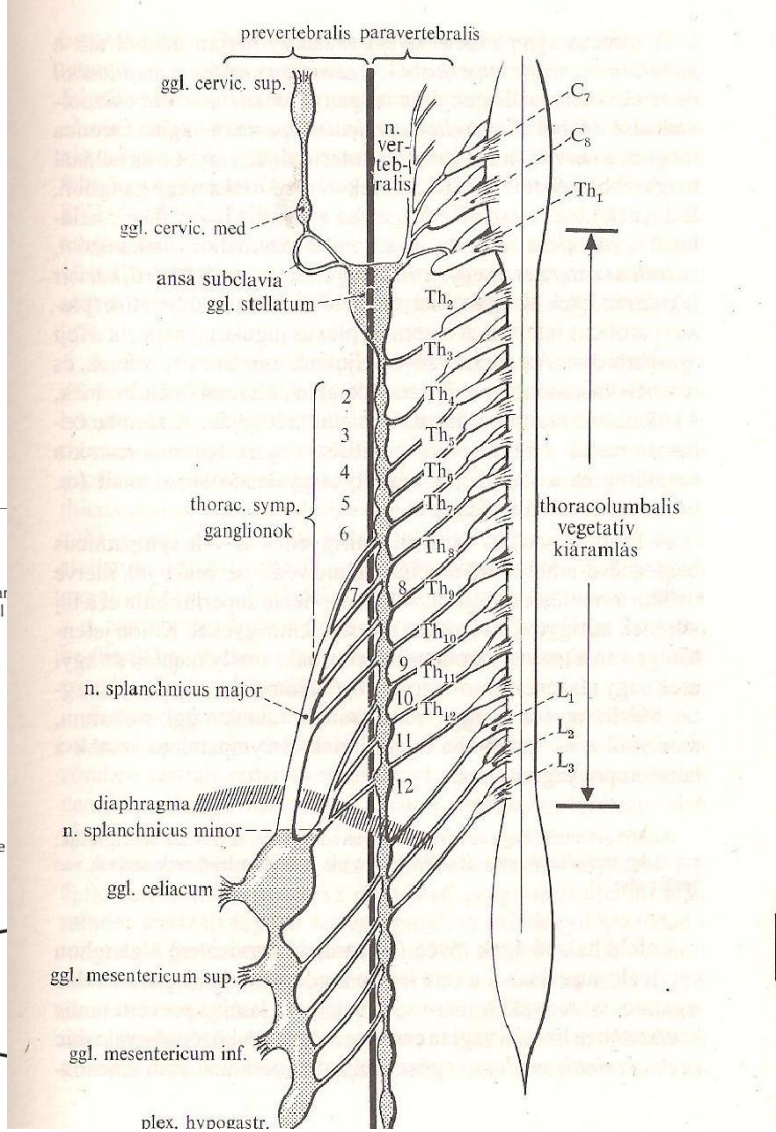

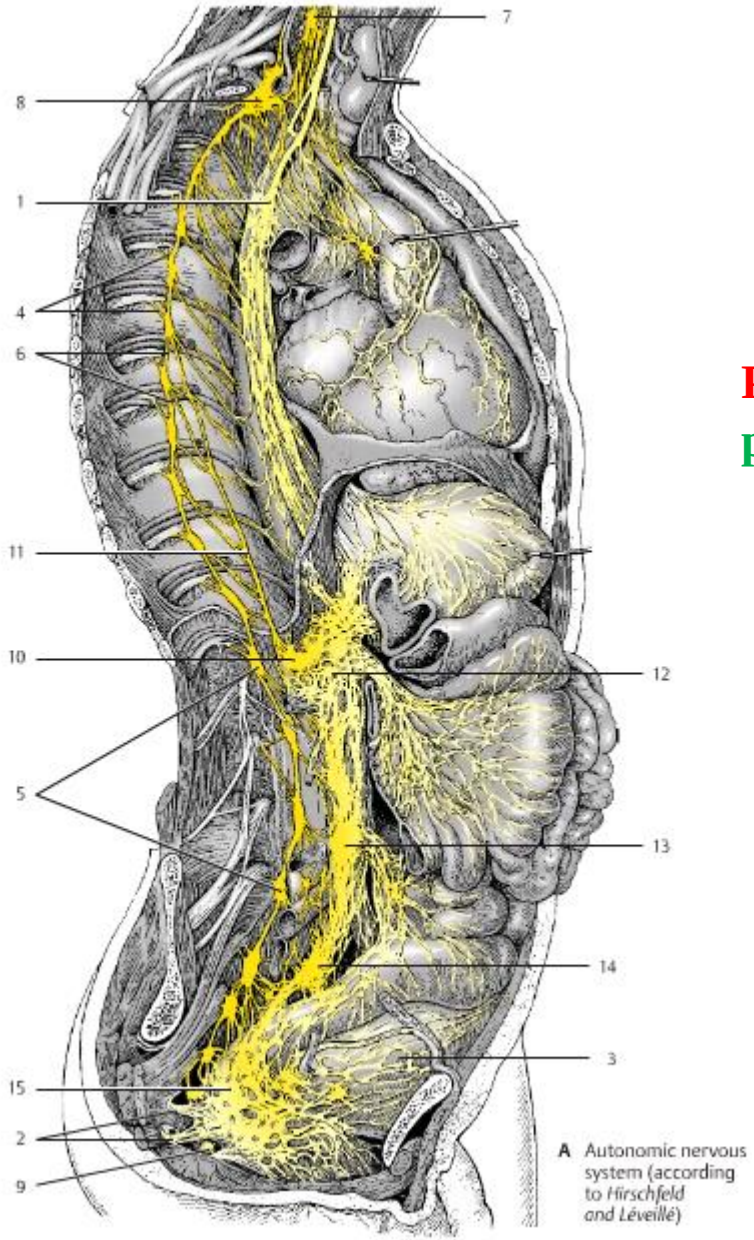

A Autonomic nervous system (according to *Hirschfeld and Léveillé*)

Vegetative plexuses

Postganglionic sympathetic and **praeganglionic parasympathetic** fibers

Enteric nervous system

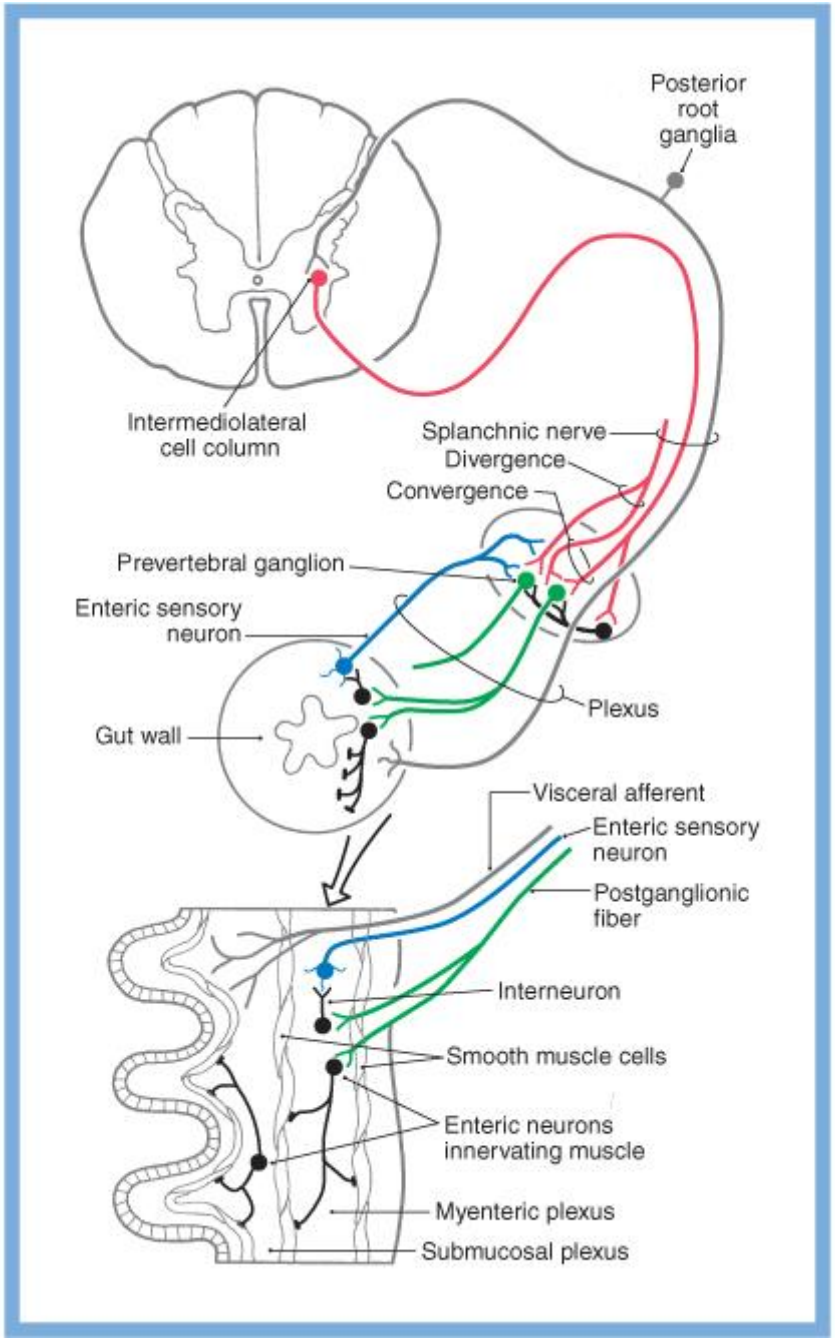

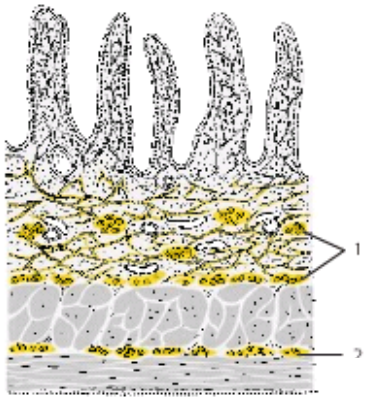

C Intestinal wall, diagram

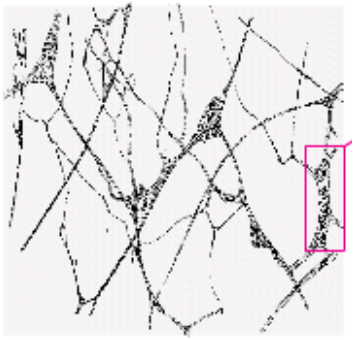

D Submucous plexus

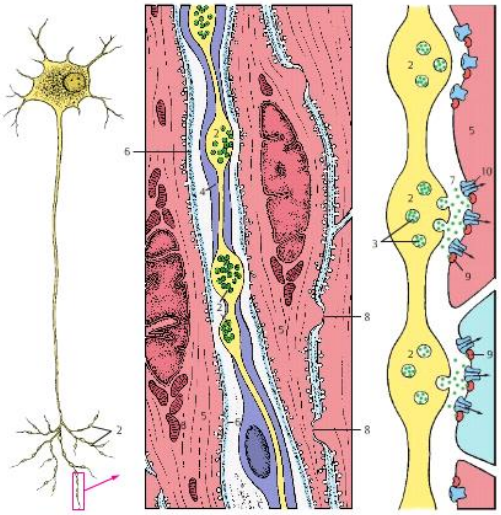

A Autonomic neuron B Autonomic nerve fiber, electron-microscopic diagram C Signal transmission

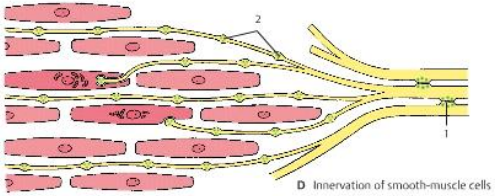

D Innervation of smooth-muscle cells

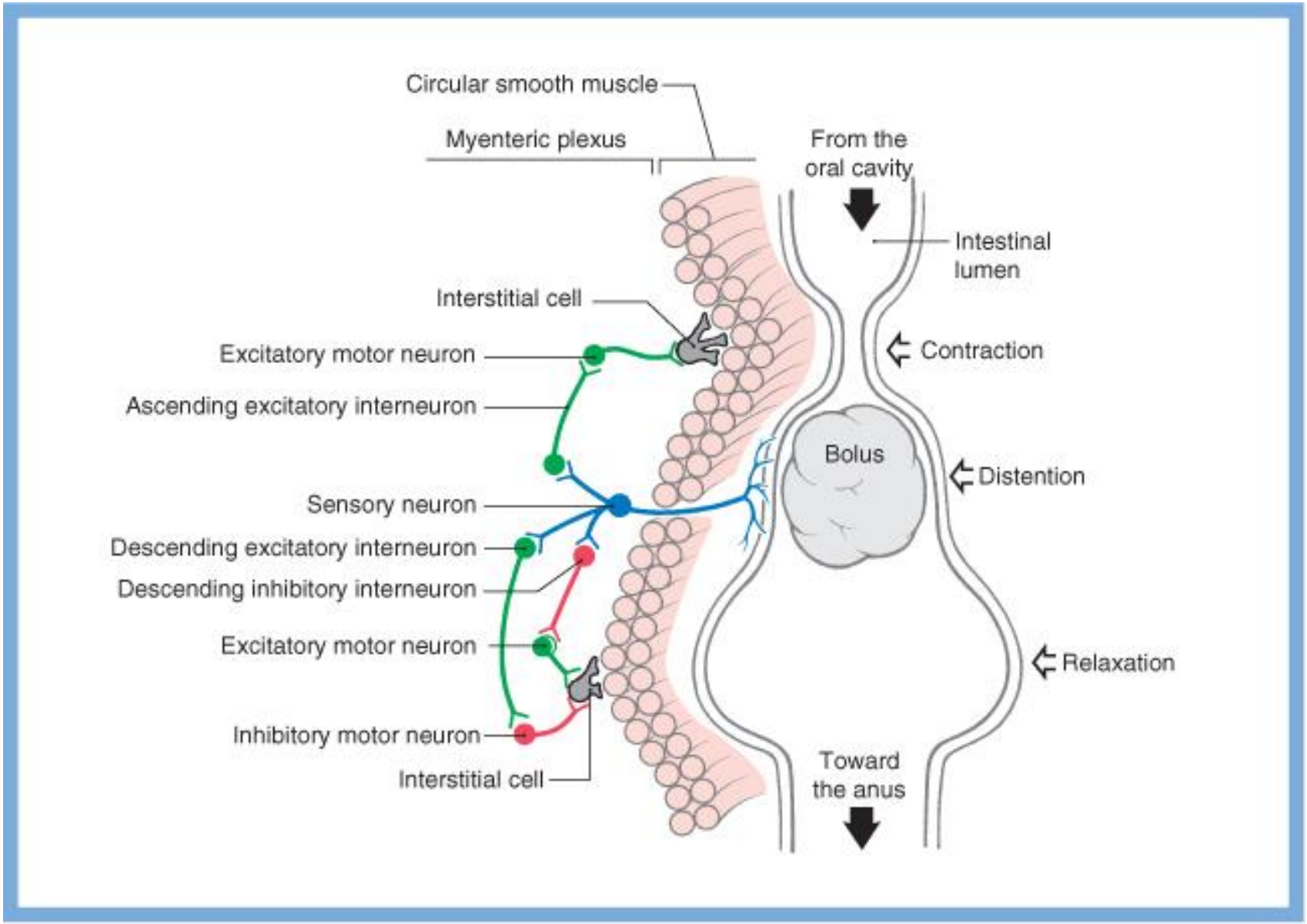

Vegetative afferents
(blood pressure regulation, gas level monitoring, regulation of digestion)

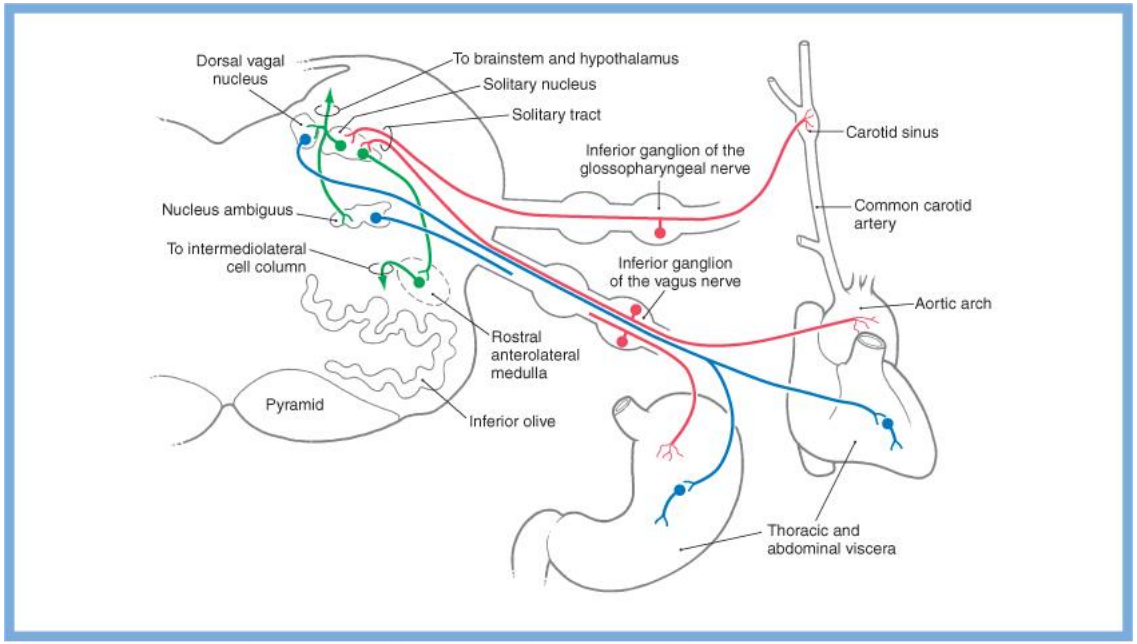

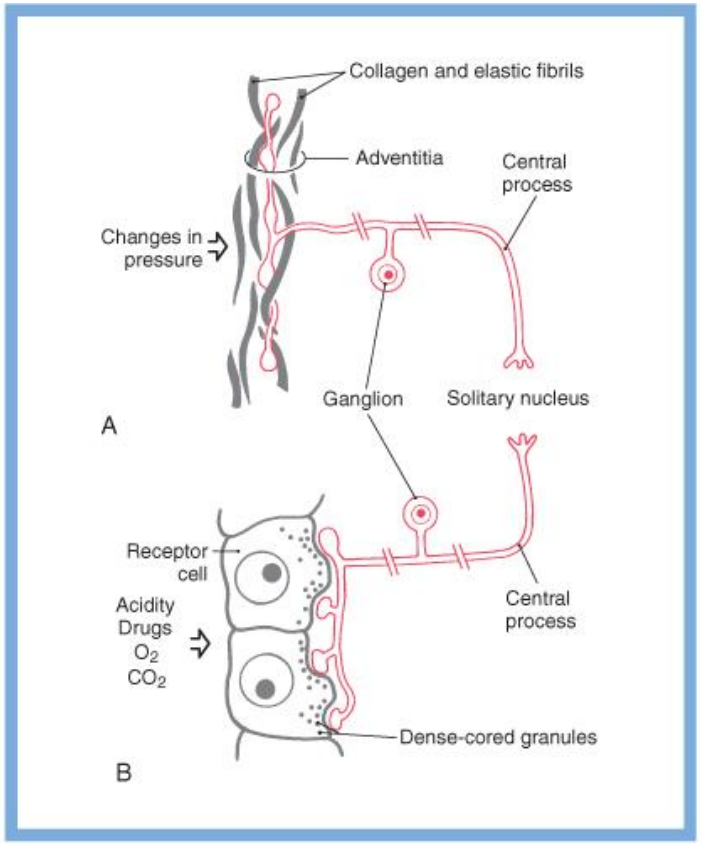

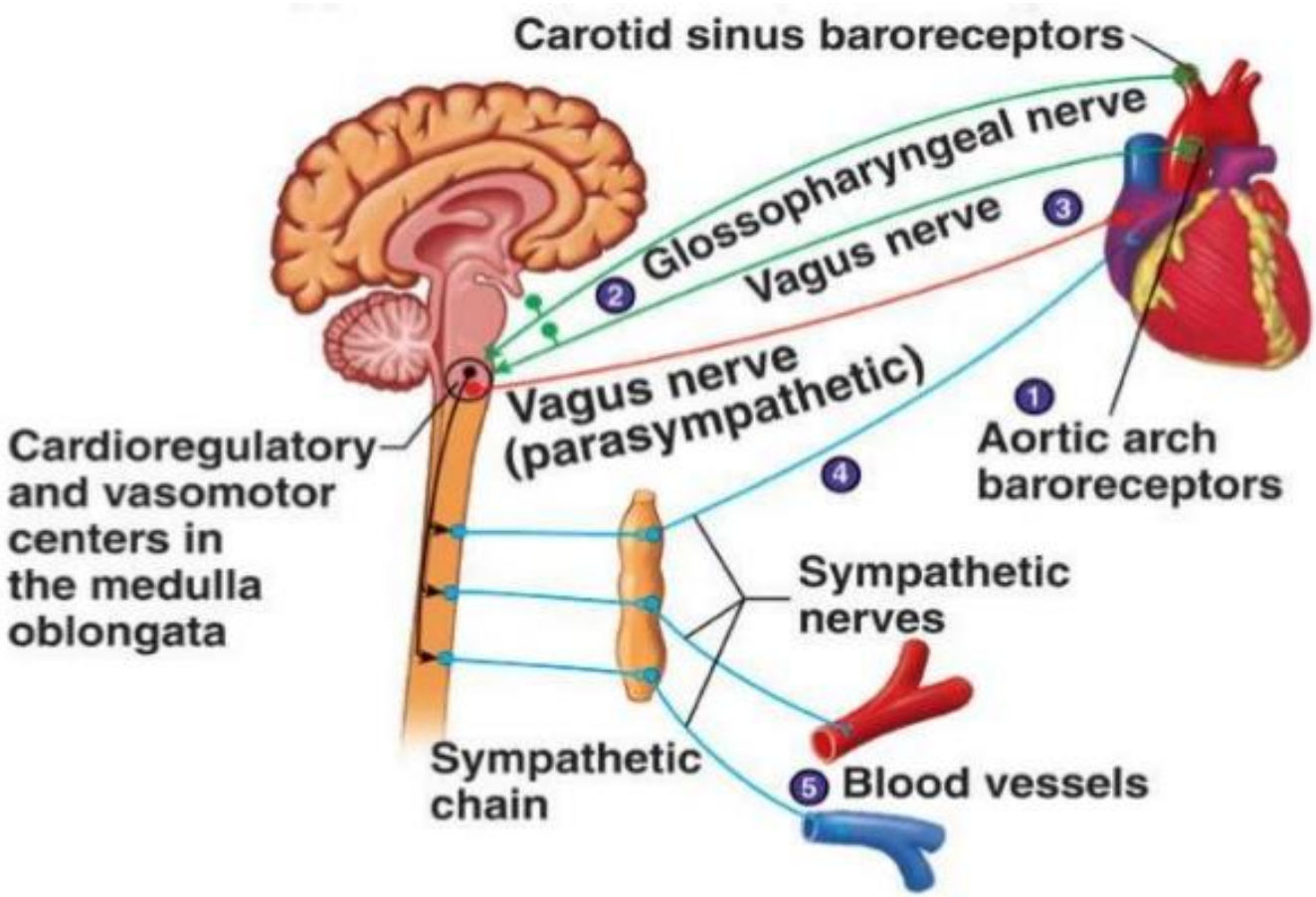
Carotid sinus baroreceptors
Glossopharyngeal nerve
Vagus nerve
Vagus nerve (parasympathetic)
Cardioregulatory and vasomotor centers in the medulla oblongata
Aortic arch baroreceptors
Sympathetic nerves
Sympathetic chain
Blood vessels
1
2
3
4
5

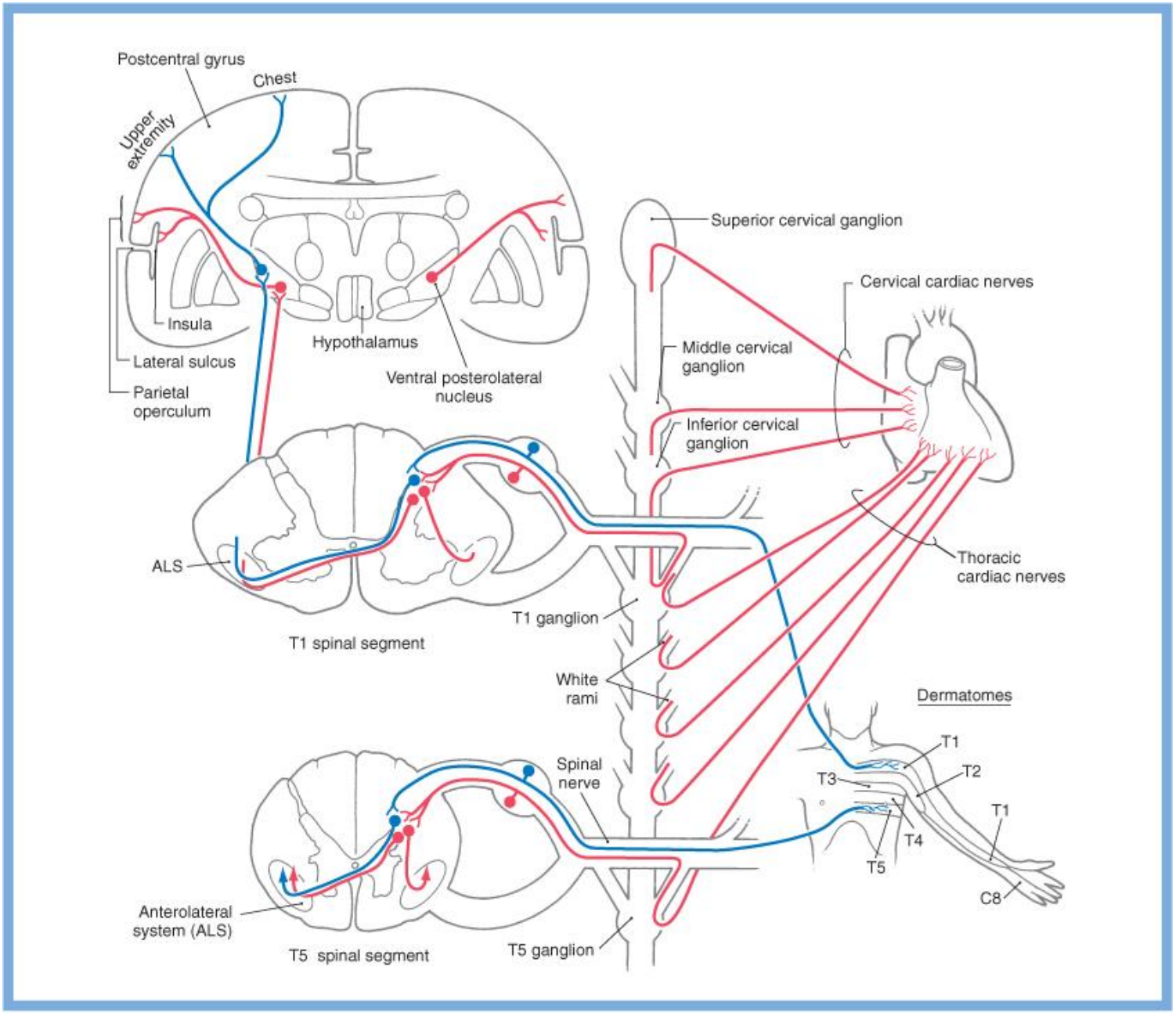

Head's zones

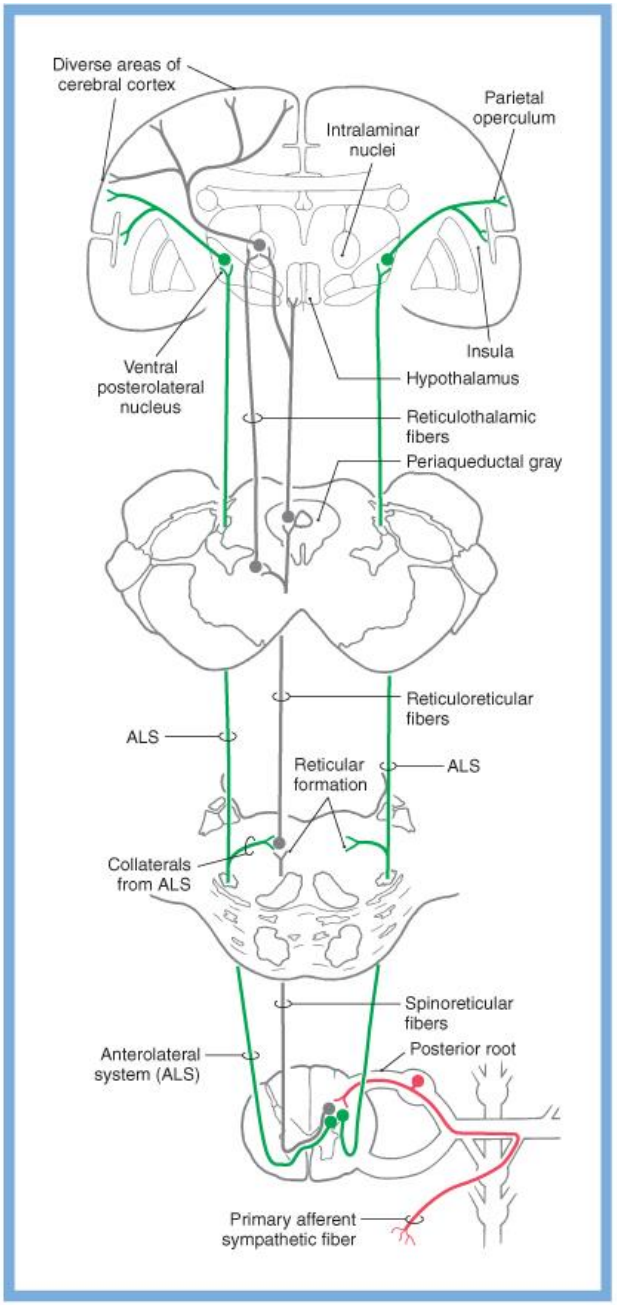
Diverse areas of cerebral cortex
Parietal operculum
Intralaminar nuclei
Insula
Ventral posterolateral nucleus
Hypothalamus
Reticulothalamic fibers
Periaqueductal gray
Reticuloreticular fibers
ALS
Reticular formation
ALS
Collaterals from ALS
Spinoreticular fibers
Anterolateral system (ALS)
Posterior root
Primary afferent sympathetic fiber

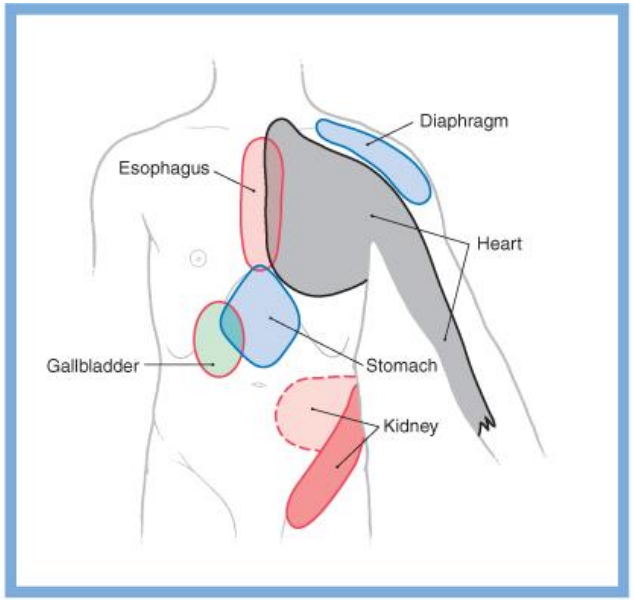
Diaphragm
Esophagus
Heart
Gallbladder
Stomach
Kidney

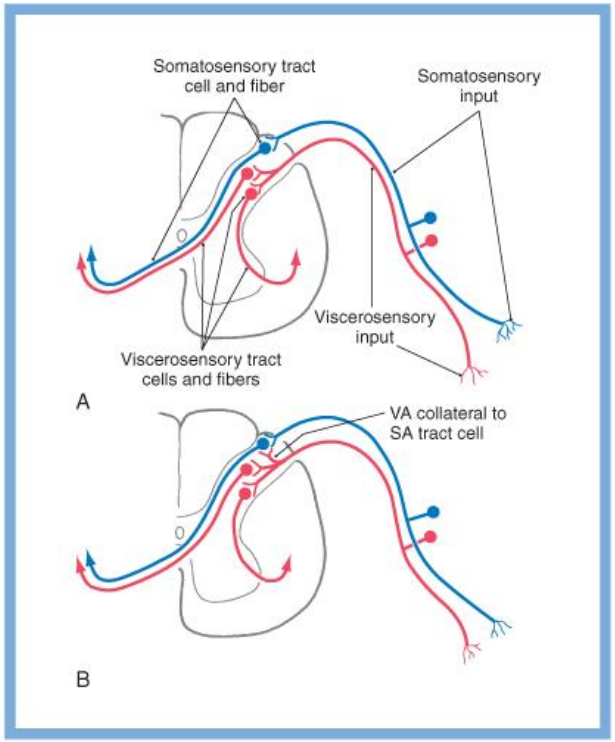
Somatosensory tract cell and fiber
Somatosensory input
Viscerosensory input
Viscerosensory tract cells and fibers
A
VA collateral to SA tract cell
B

Vegetative afferents

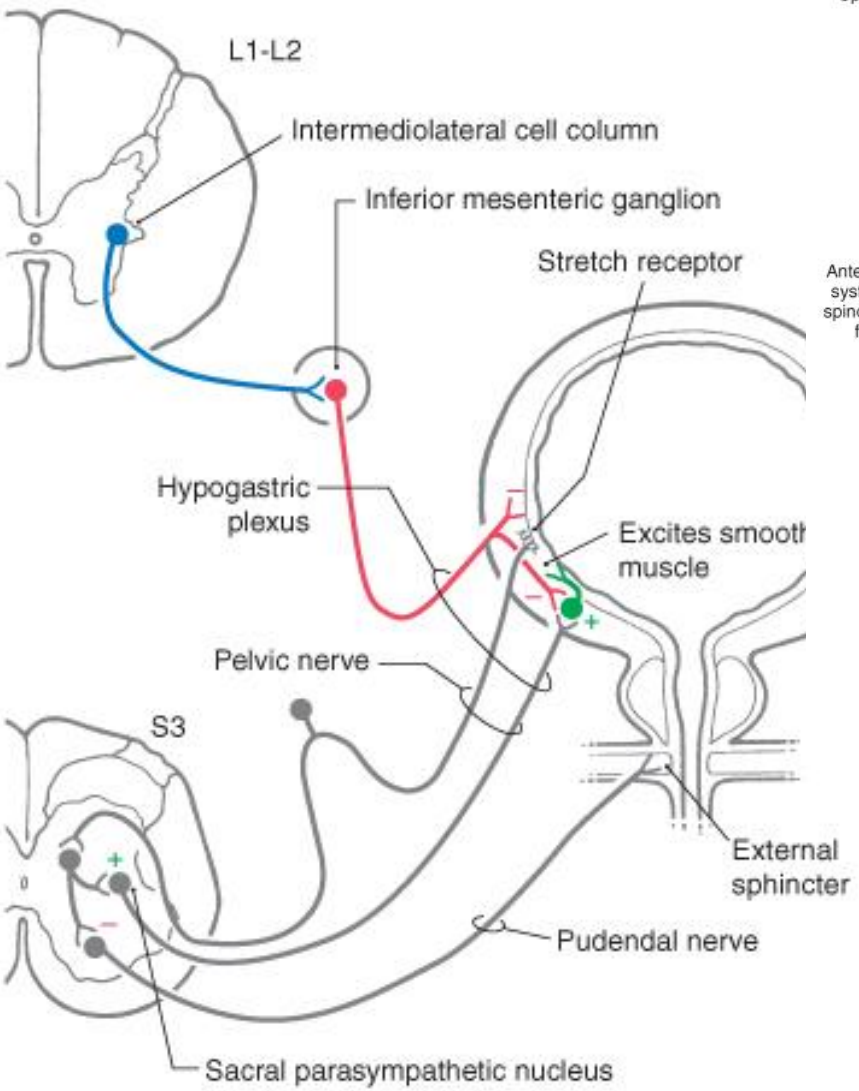

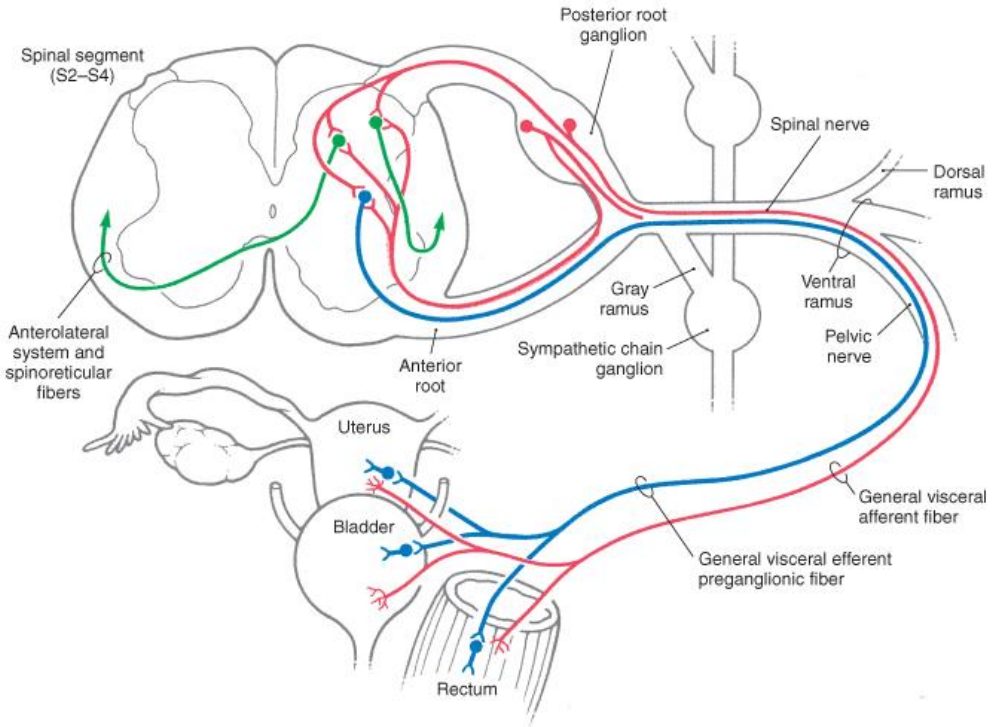

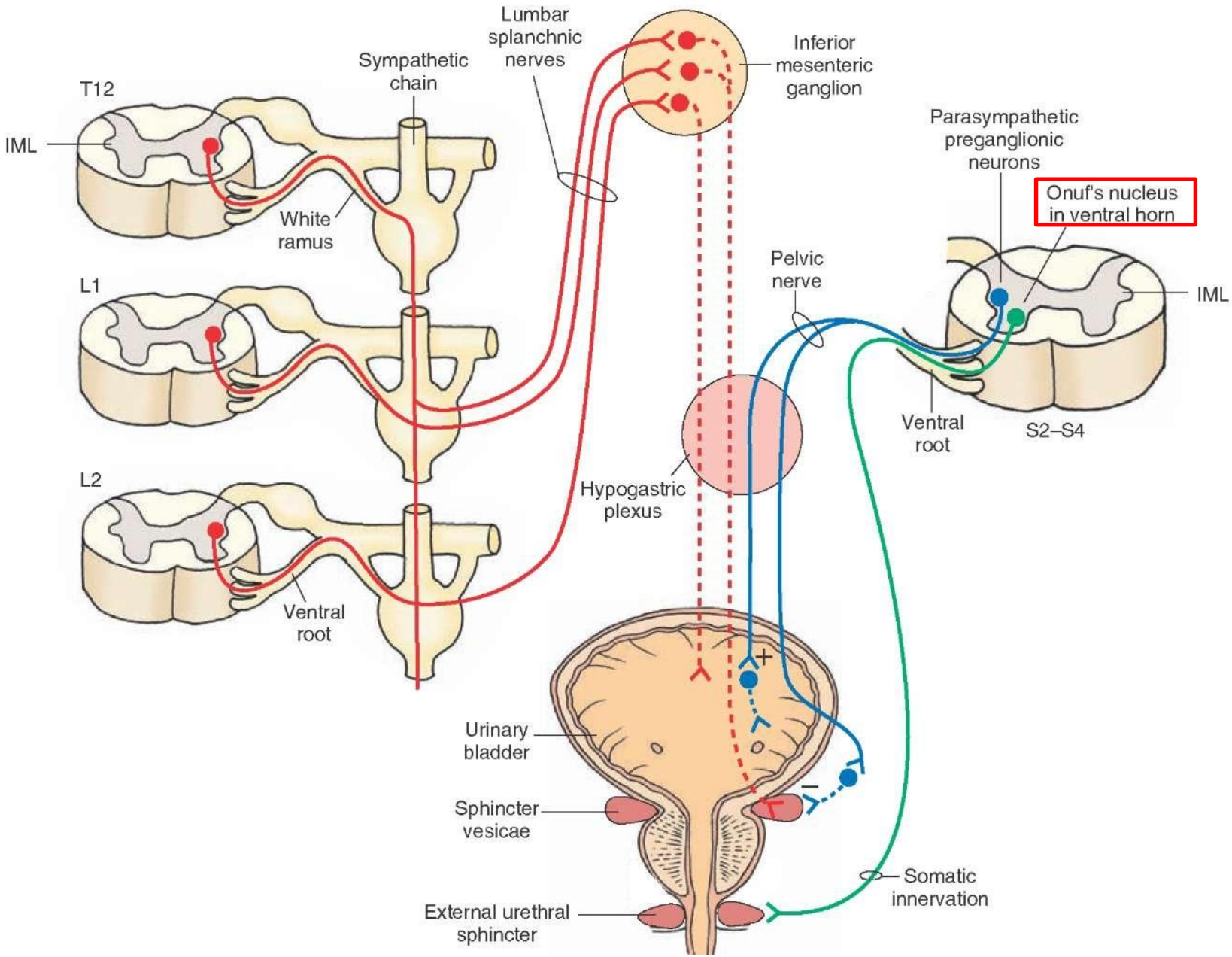
T12
IML
Sympathetic chain
Lumbar splanchnic nerves
Inferior mesenteric ganglion
White ramus
L1
L2
Ventral root
Parasympathetic preganglionic neurons
Onuf's nucleus in ventral horn
Pelvic nerve
IML
Ventral root
S2–S4
Hypogastric plexus
Urinary bladder
Sphincter vesicae
External urethral sphincter
Somatic innervation

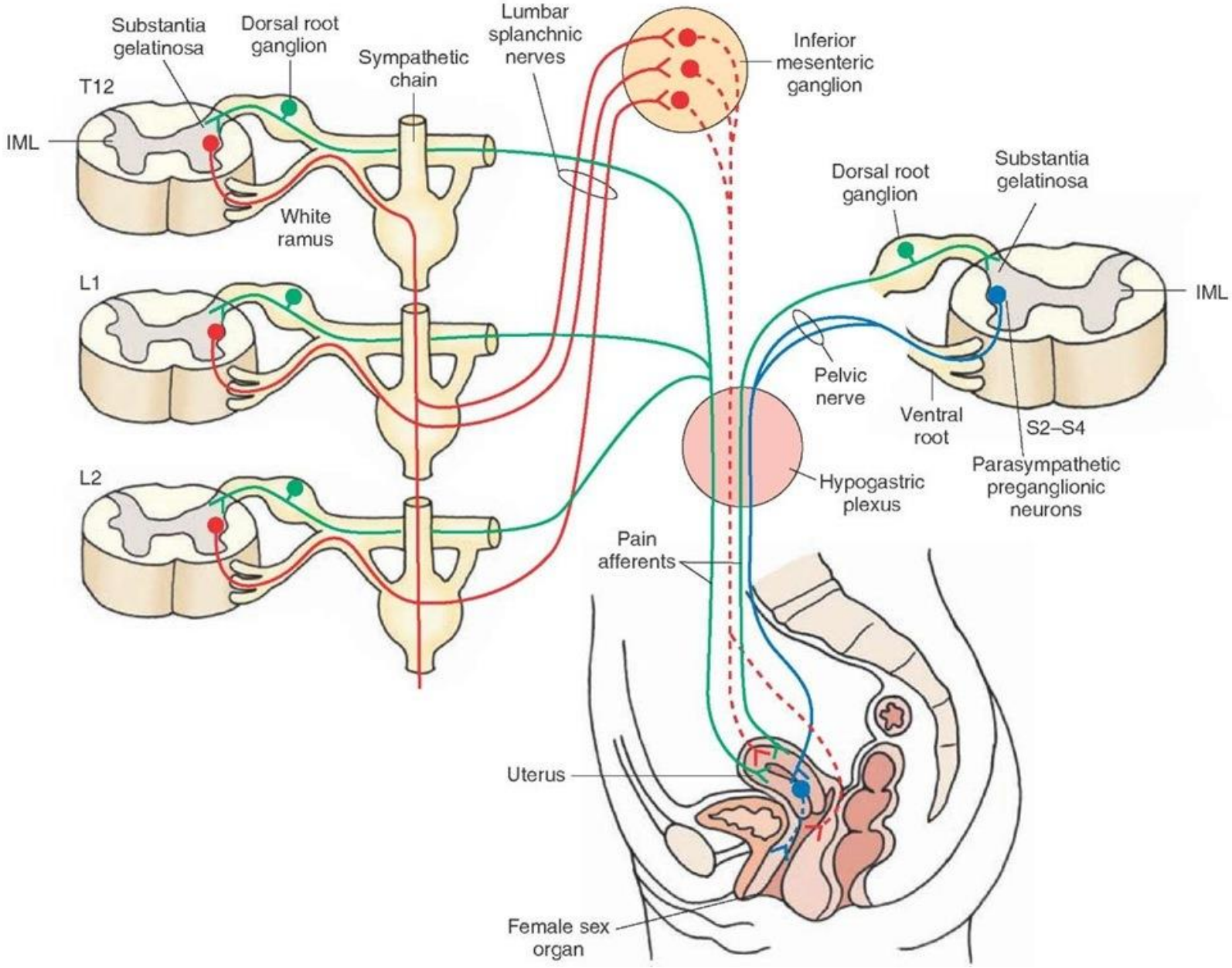
Substantia gelatinosa
Dorsal root ganglion
Sympathetic chain
Lumbar splanchnic nerves
Inferior mesenteric ganglion
T12
IML
White ramus
L1
L2
Dorsal root ganglion
Substantia gelatinosa
IML
Pelvic nerve
Ventral root
S2–S4
Parasympathetic preganglionic neurons
Hypogastric plexus
Pain afferents
Uterus
Female sex organ

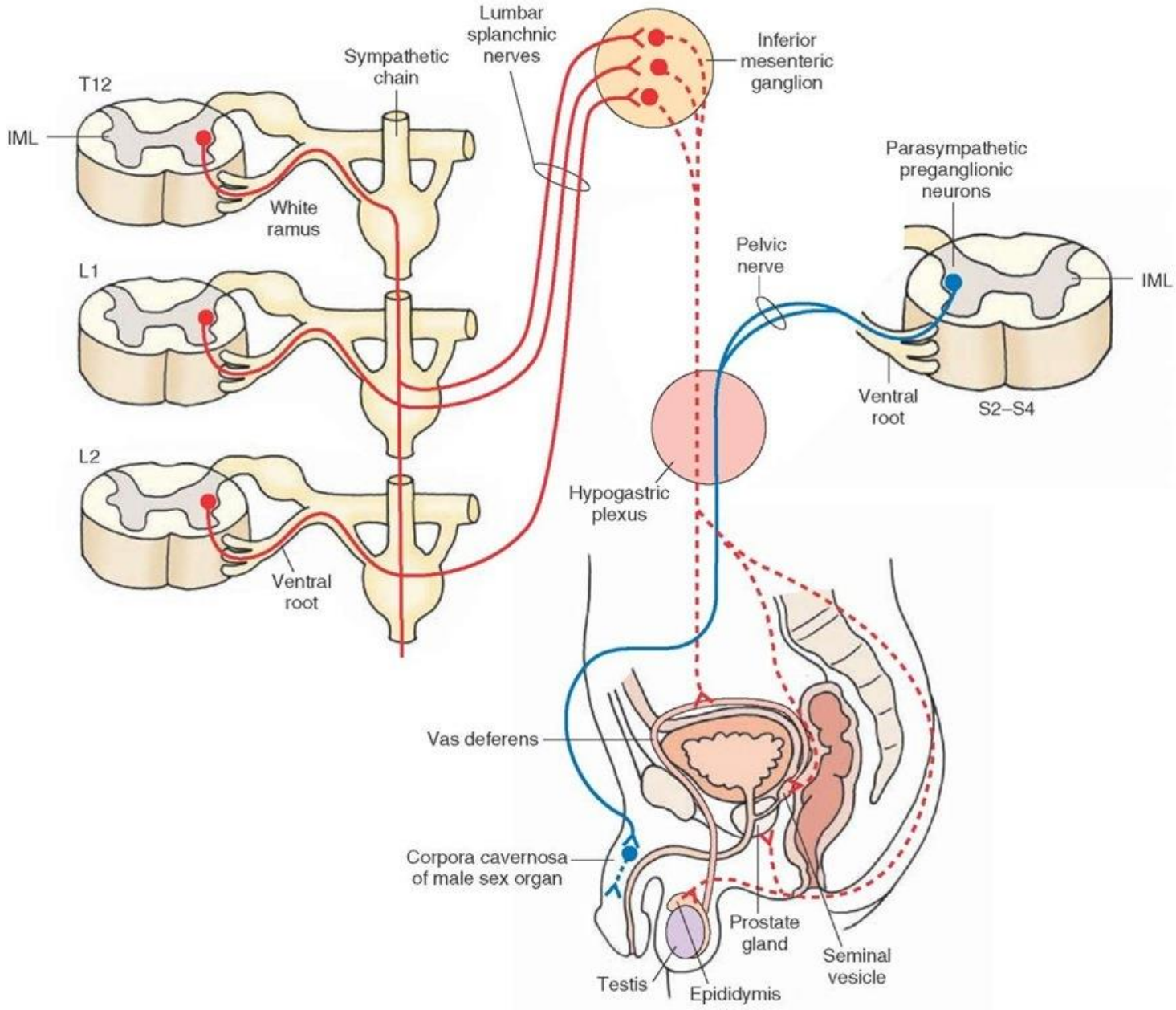
Lumbar splanchnic nerves
Inferior mesenteric ganglion
Sympathetic chain
T12
IML
White ramus
L1
L2
Ventral root
Parasympathetic preganglionic neurons
Pelvic nerve
IML
Ventral root
S2–S4
Hypogastric plexus
Vas deferens
Corpora cavernosa of male sex organ
Prostate gland
Seminal vesicle
Testis
Epididymis

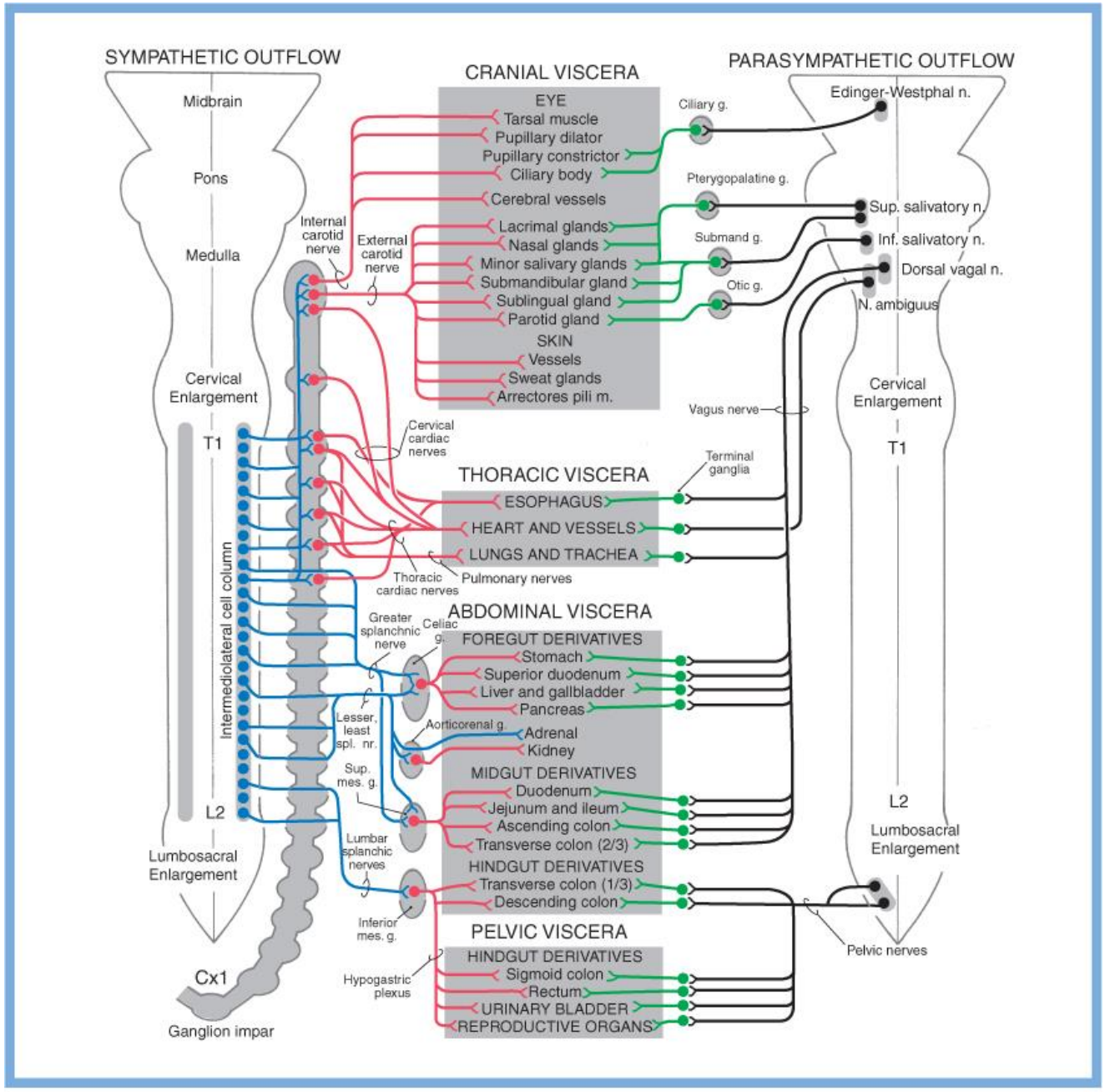

The central regulation of the vegetative nervous system

Hypothalamus

The main central CNS region which influences the vegetative NS

- cardiovascular system
- body temperature
- osmotic regulation (water and ions)
- energy and metabolism

Vegetative nervous system and endocrine system together maintaned the homeostasis of the body

Hypothalamus has connections with higher brain regions and influenced by them (limbic system - how emotions are affected us somatically?).