

Nervus facialis

Klinikai vonatkozások
(kiegészítés az előadáshoz)

Dr. Ádám Ágota

N. Facialis - magok

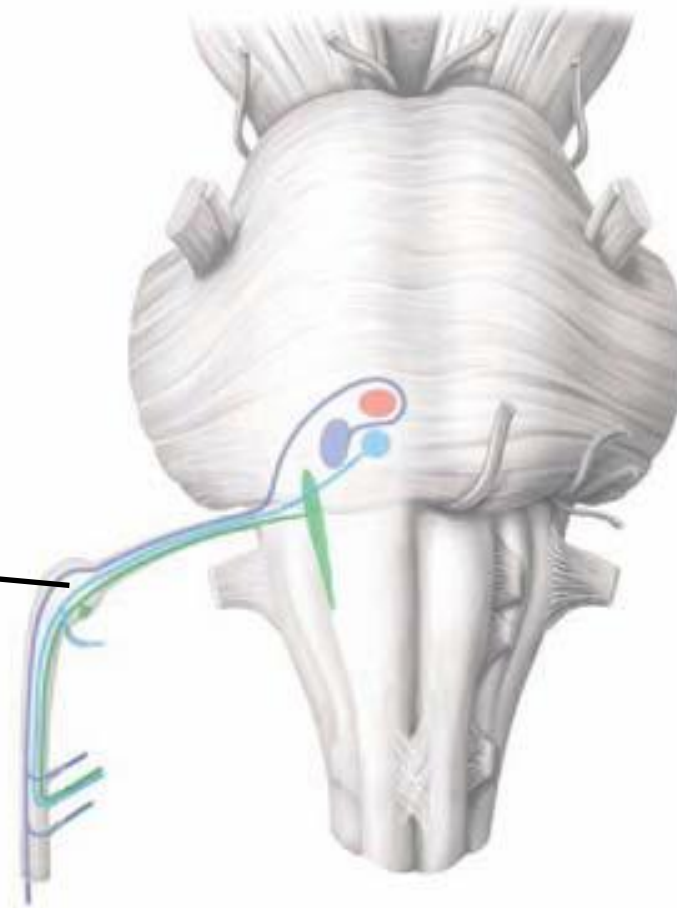
nucl. n. facialis (BM)

nucl. tractus solitarii (VSS)

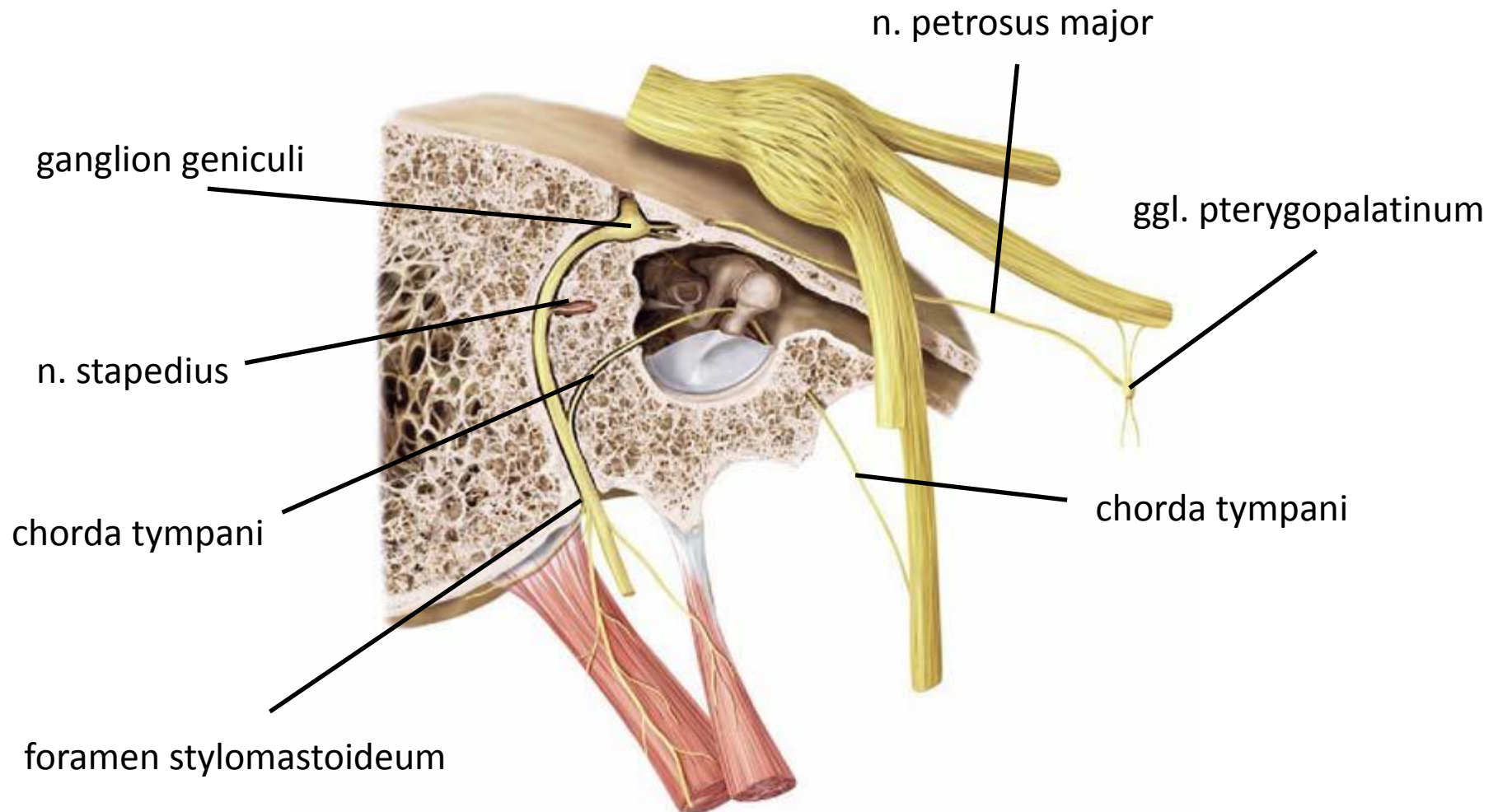
nucl. salivatorius sup. (VMÁ)

(nucl. tr. Spin. N. V. (SSÁ))

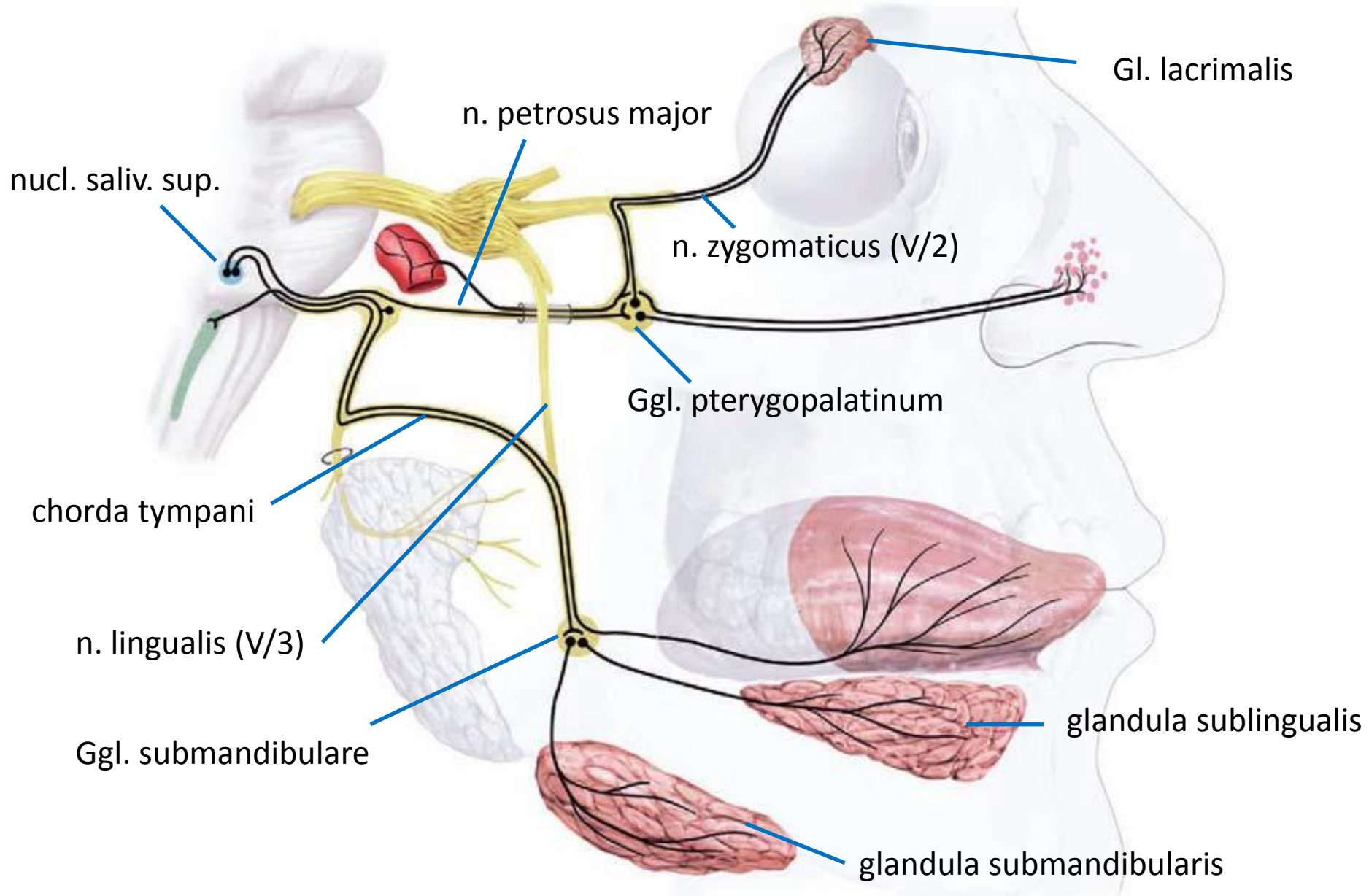
ganglion geniculi



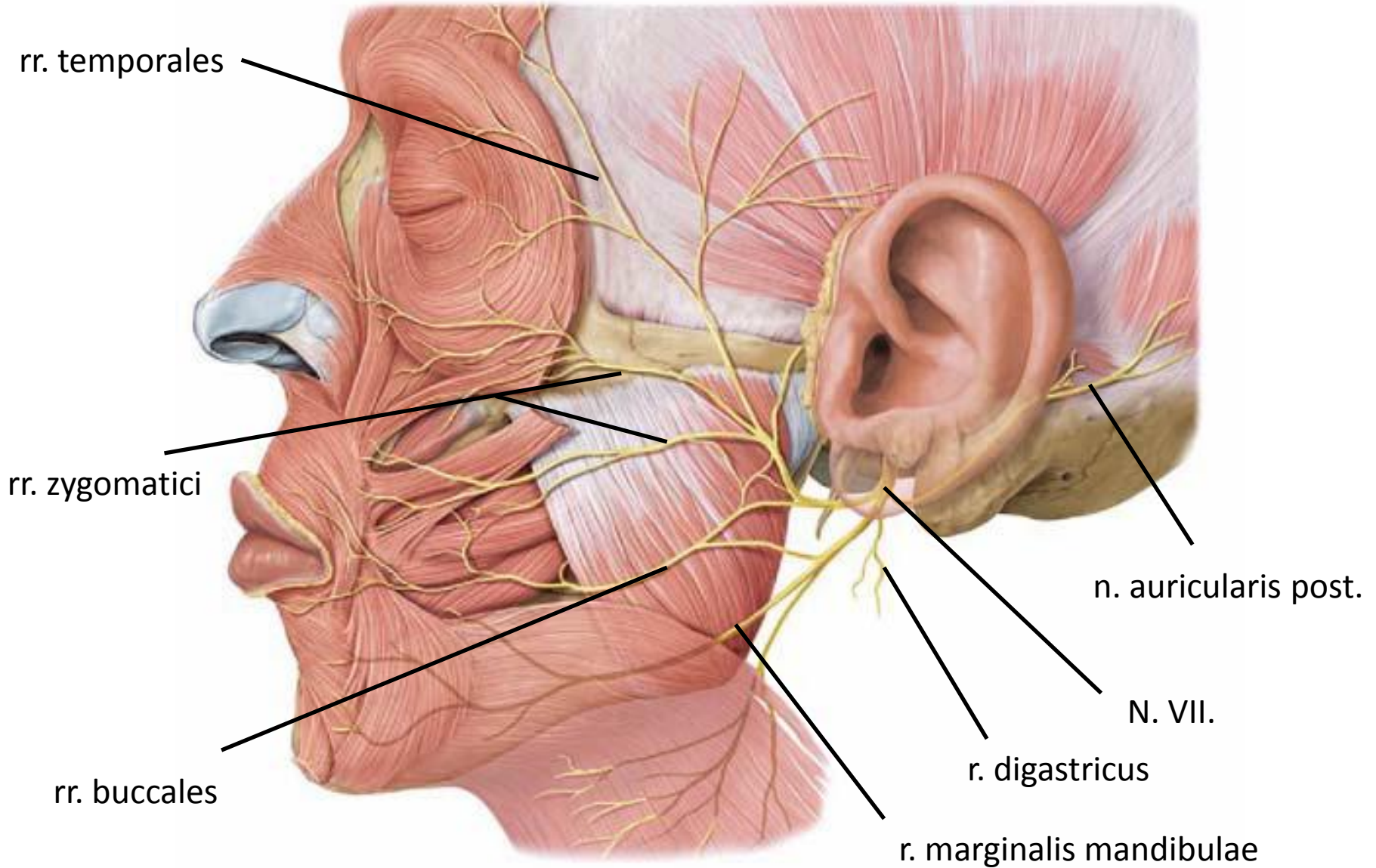
N. Facialis – intracranialis ágak



N. Facialis – vegetatív ágak

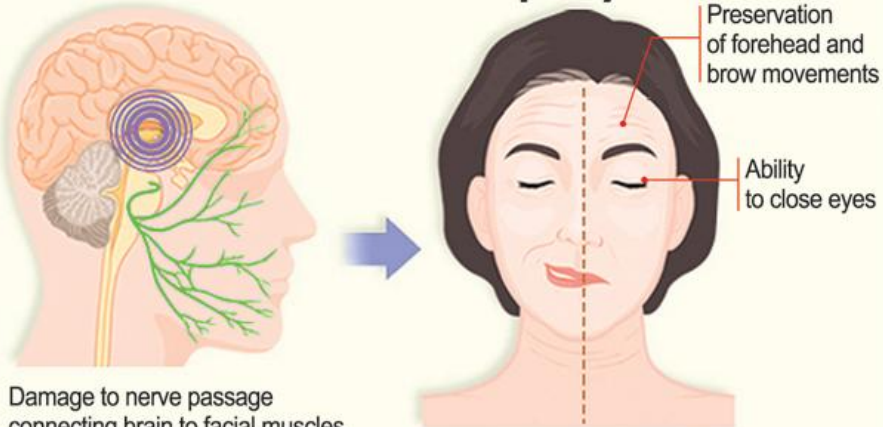


N. Facialis – extracranialis ágak (motoros)



N. Facialis – centrális és perifériás bénulás

Central facial palsy



Peripheral facial palsy

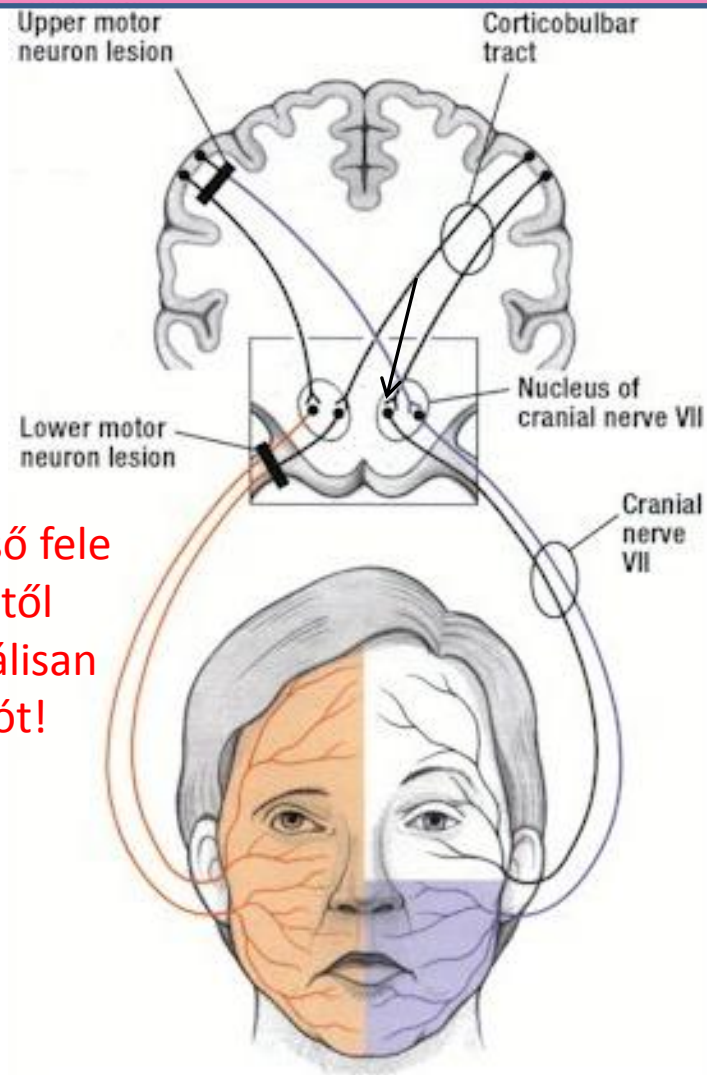
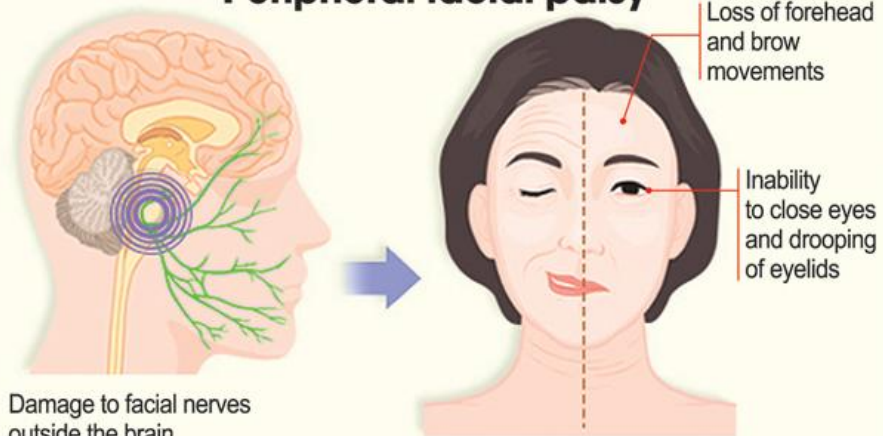
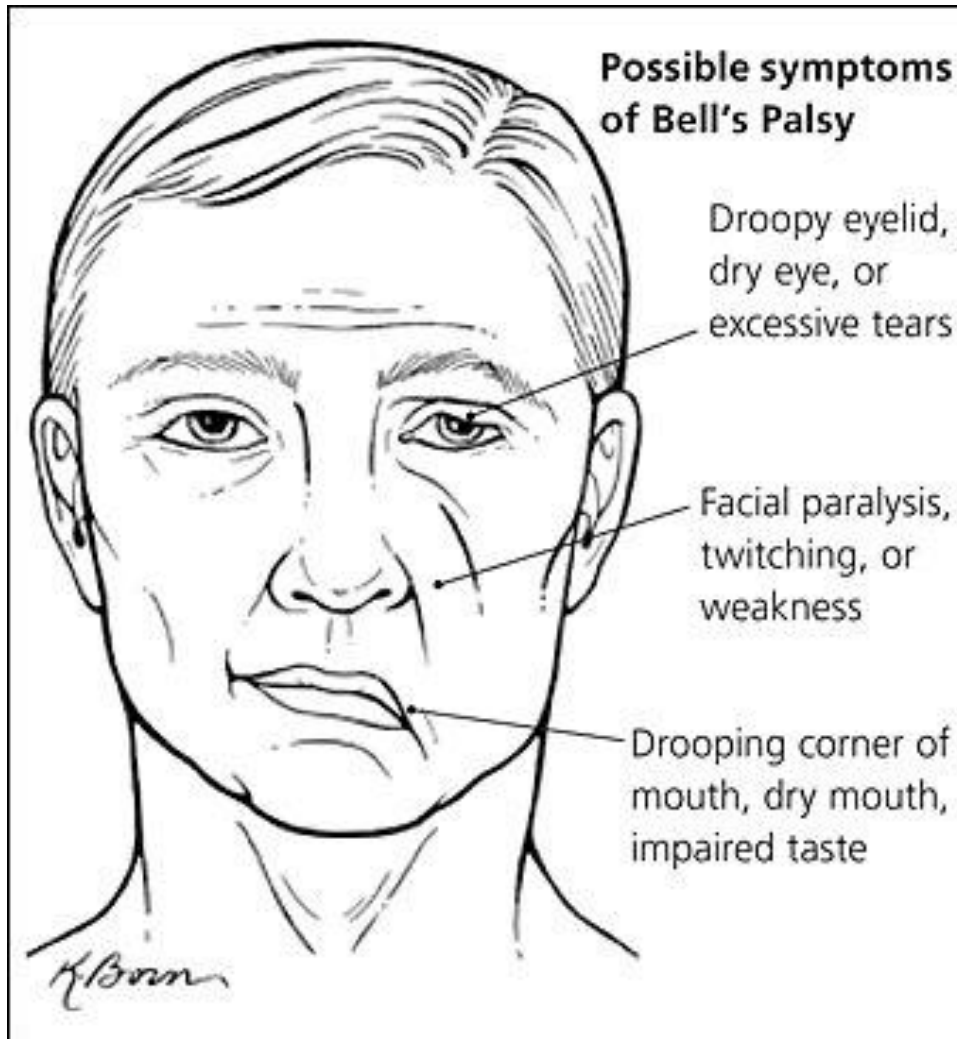


Figure 2a: The color lines show the distribution of facial muscles paralyzed after a supranuclear lesion of the corticobulbar tract and after a lower motor neuron lesion of the facial nerve.

N. Facialis – centrális és perifériás bénulás

Bell-féle tünetegyüttes – perifériás facialis bénulás



Köszönöm a figyelmet!



temporalis zygomaticus buccalis marginalis mandibulae colli

The facial nerve exam:

<https://www.youtube.com/watch?v=BPDbWP2FhLA>