



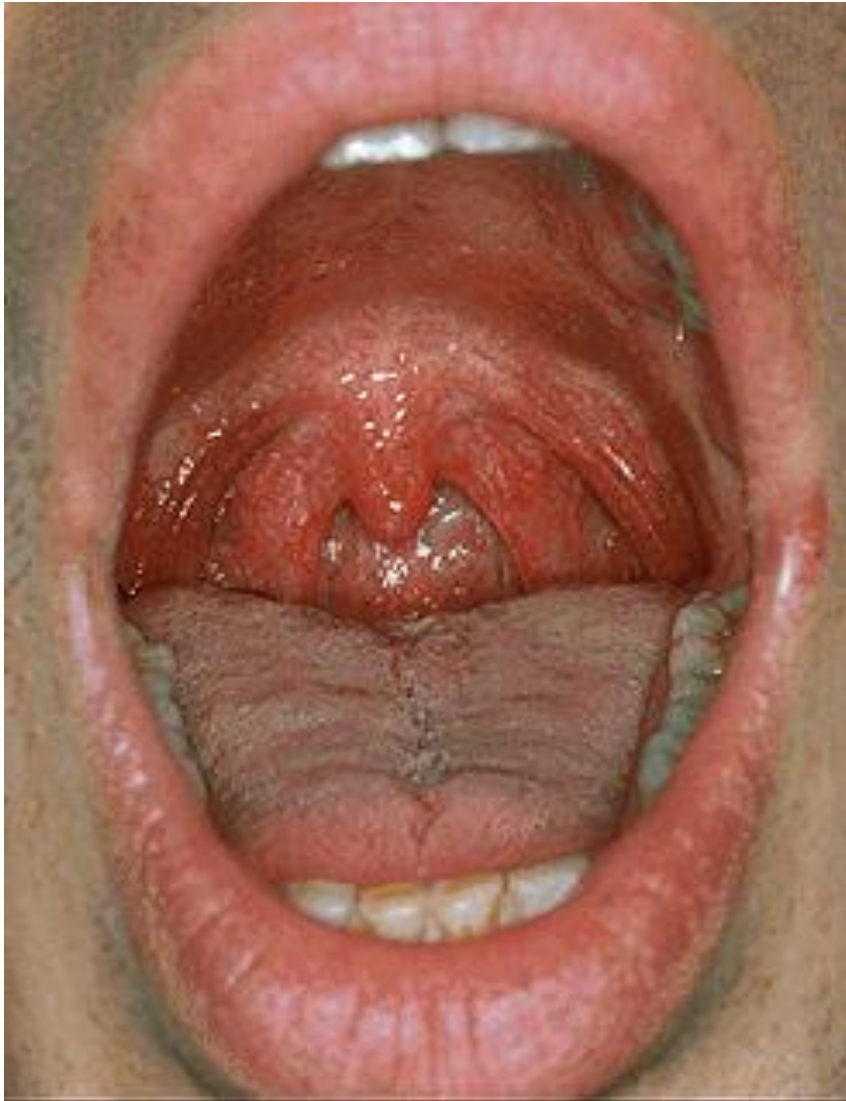Mundhöhle, Zunge Schlundenge und Rachen

Dr. Andrea D. Székely

***Anatomisches, Histologisches und Embryologisches Institut
Semmelweis Universität
BUDAPEST***



CAVUM ORIS - WOFÜR IST DIE GUT?



Beginn des Verdauungstraktes

Nahrungsaufnahme, -zerkleinerung

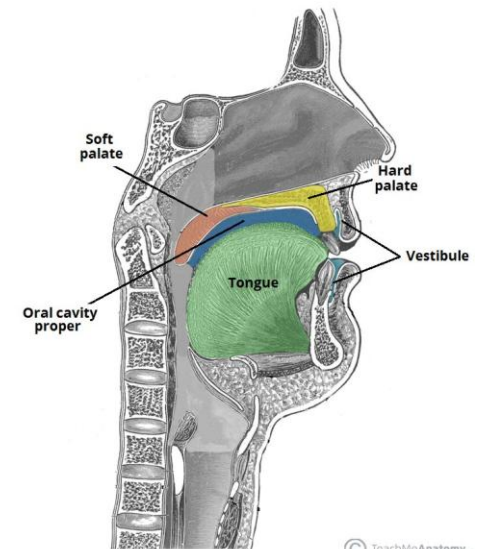
Lautbildung und Sprache

Rezeptoren (Geschmack, Temperatur, Tast)

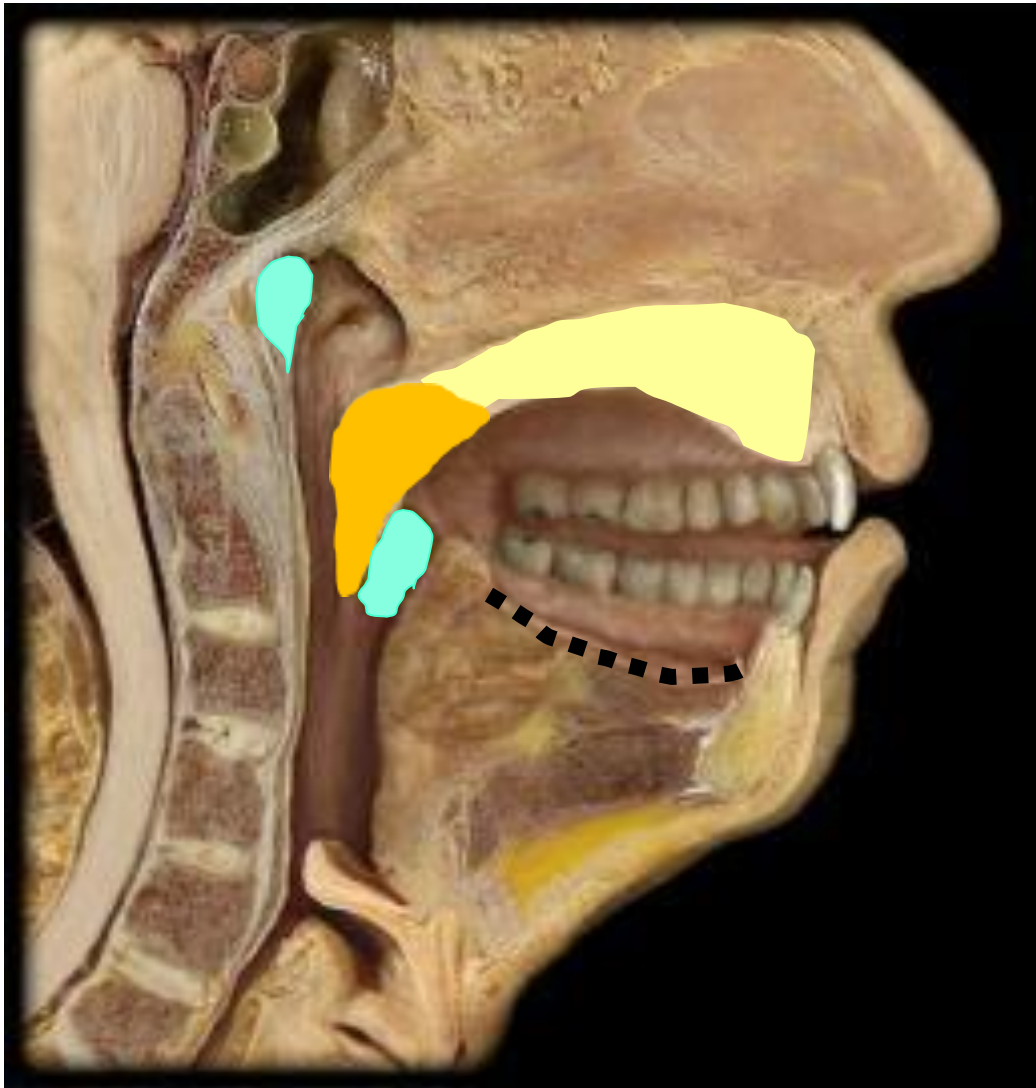
Alternativer Atemweg

GRENZEN

- vorne Lippen
- hinten Schlundenge
- oben Gaumen
- unten Mundboden
- seitlich Wange



CAVUM ORIS - TOPOGRAPHIE UND AUFBAU

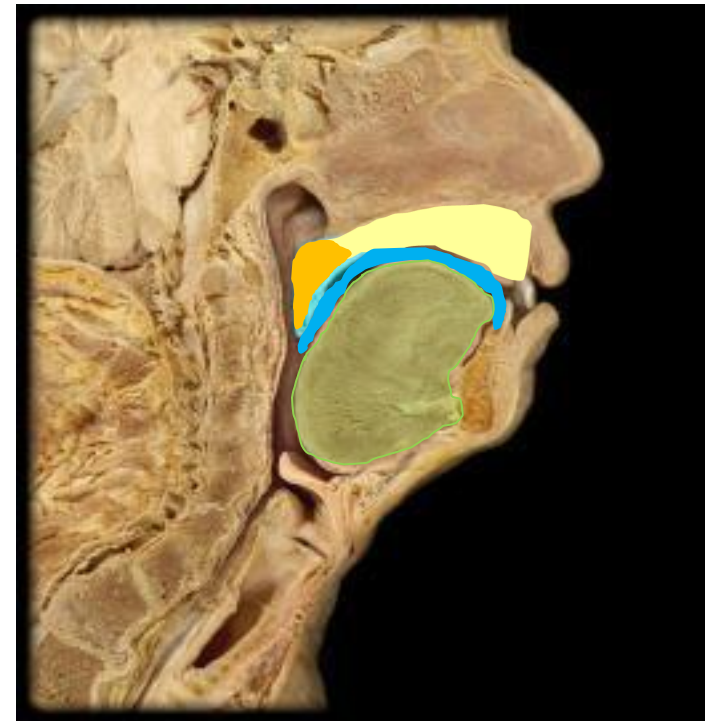


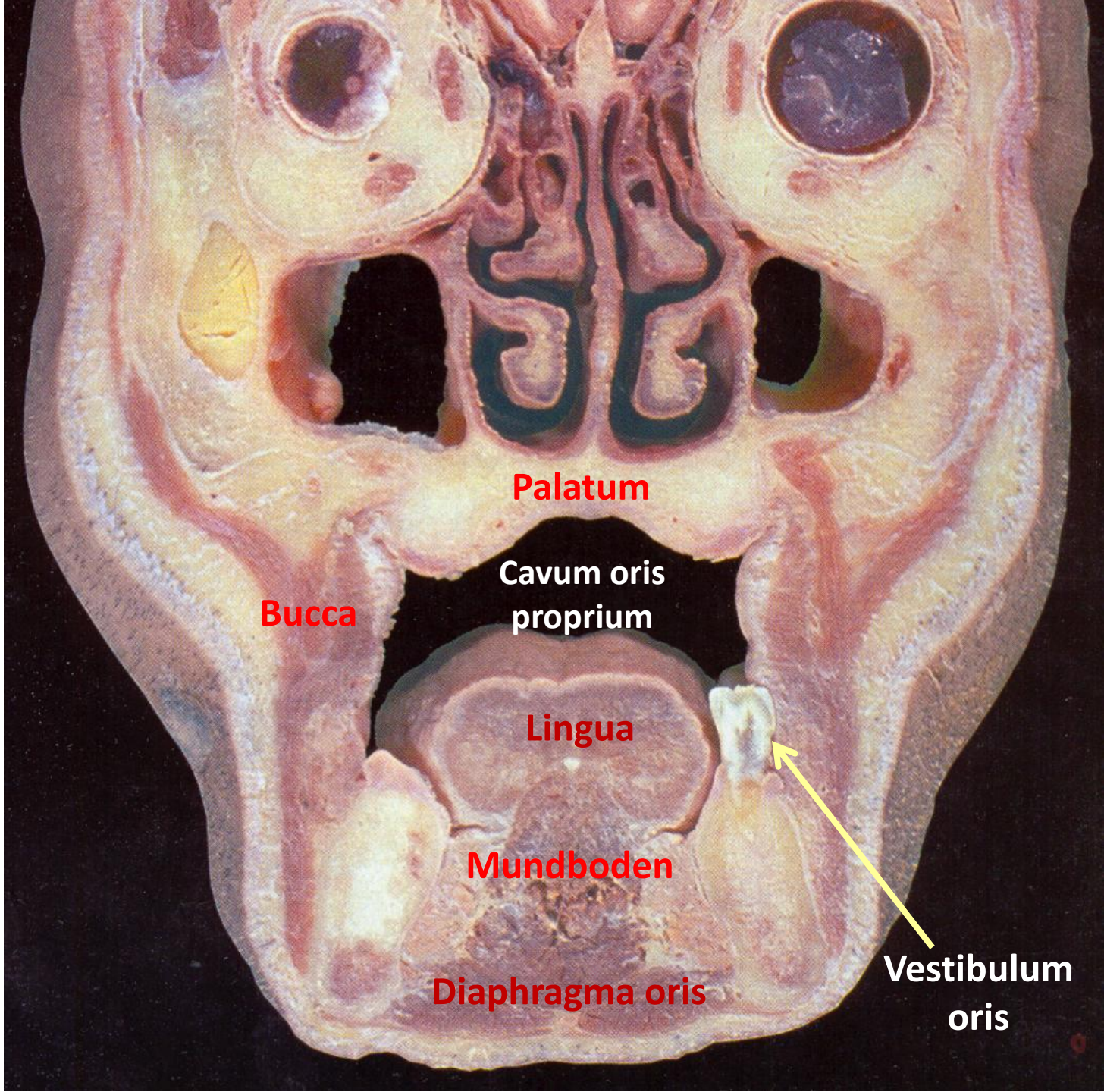
EINTEILUNG DER MUNDHÖHLE

Vestibulum oris

Cavum oris proprium

(*Isthmus faucium*)





Palatum

Bucca

**Cavum oris
proprium**

Lingua

Mundboden

Diaphragma oris

**Vestibulum
oris**

BLUTVERSORGUNG DER MUNDHÖHLE

A. CAROTIS EXTERNA

THY

LI

PHA

FA

MA

TE

O

(SCM

AUR)

ÄSTE

a. nasopalatina

a. palatina asc.

a. palatina desc.

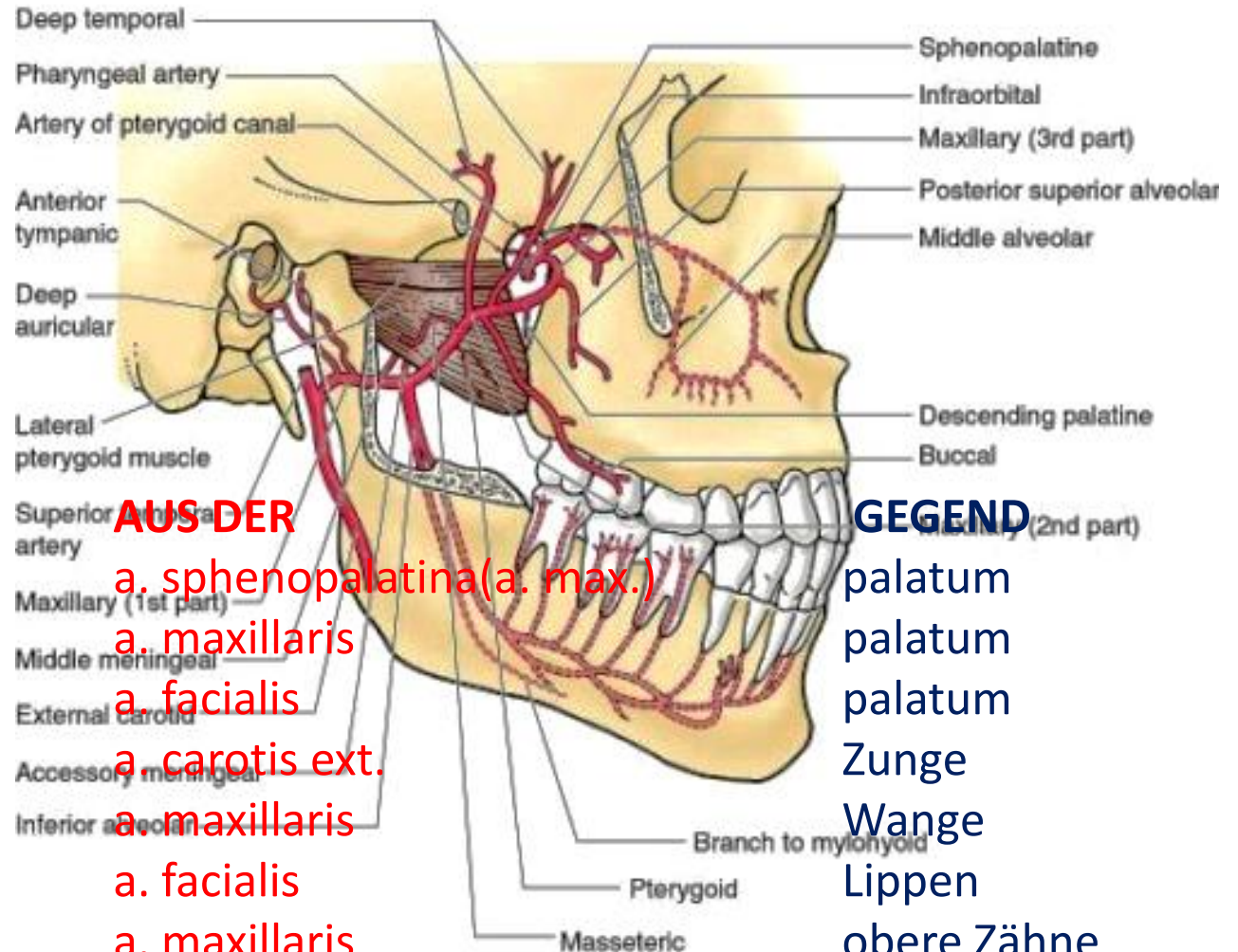
a. lingualis

a. buccalis

a. labialis sup. et inf.

a. infraorbitalis

a. alveolaris inf.



AUS DER

a. sphenopalatina (a. max.)

a. maxillaris

a. facialis

a. carotis ext.

a. maxillaris

a. facialis

a. maxillaris

a. maxillaris

GEGEND

palatum

palatum

palatum

Zunge

Wange

Lippen

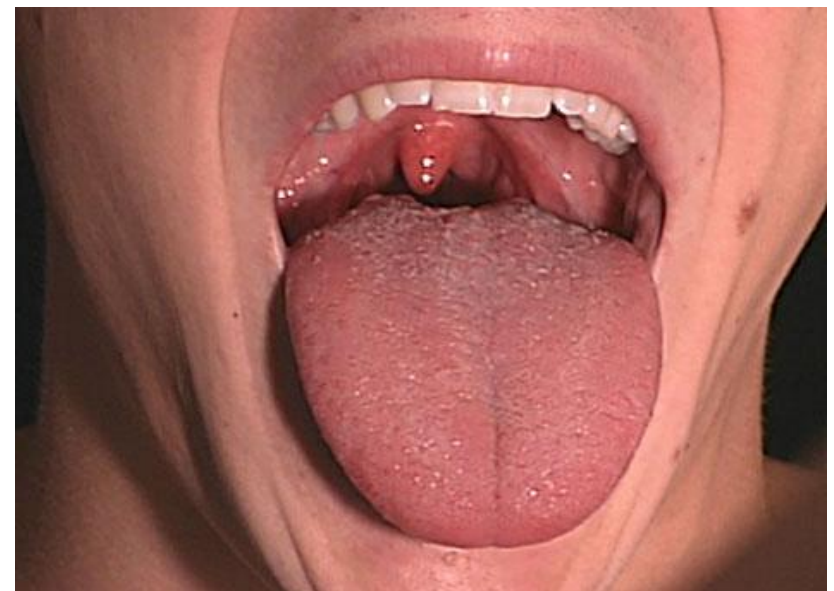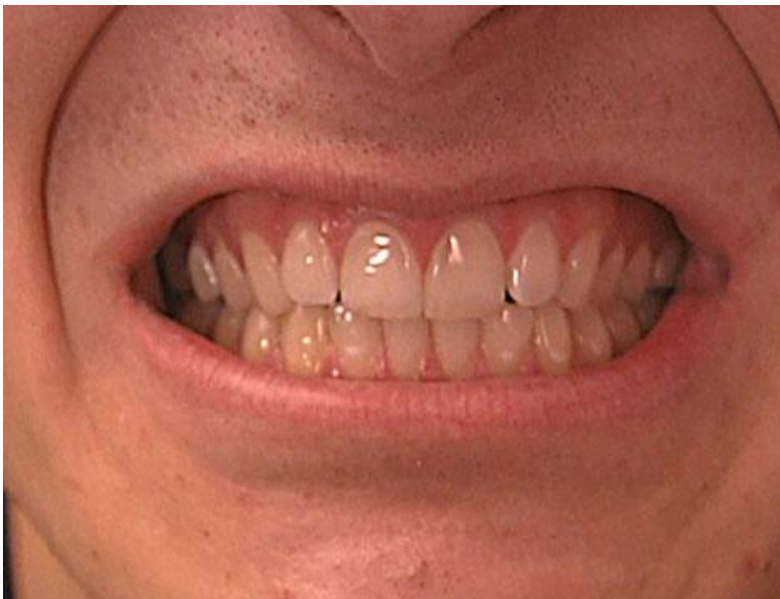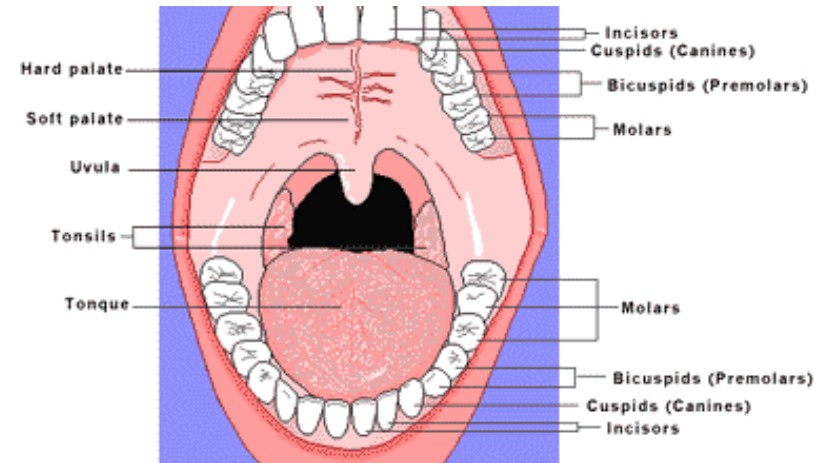
obere Zähne

untere Zähne

CAVUM ORIS

INHALT

- PROCESSUS ALVEOLARIS & ZÄHNE
- DORSUM LINGUAE
- DUCTUS PAROTIDEUS MÜNDUNG
- DUCTUS SUBMANDIBULARIS MÜNDUNG
- DUCTUS SUBLINGUALIS MÜNDUNG




DUCK FACE



What you do...



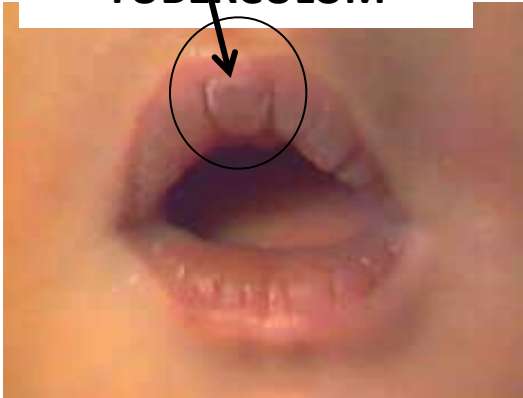What you think
you look like...



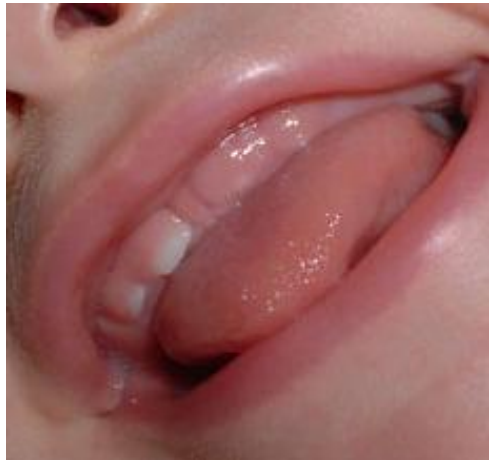What you really
look like...

STRUKTUR DER LIPPE

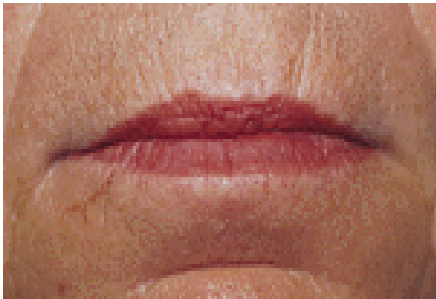
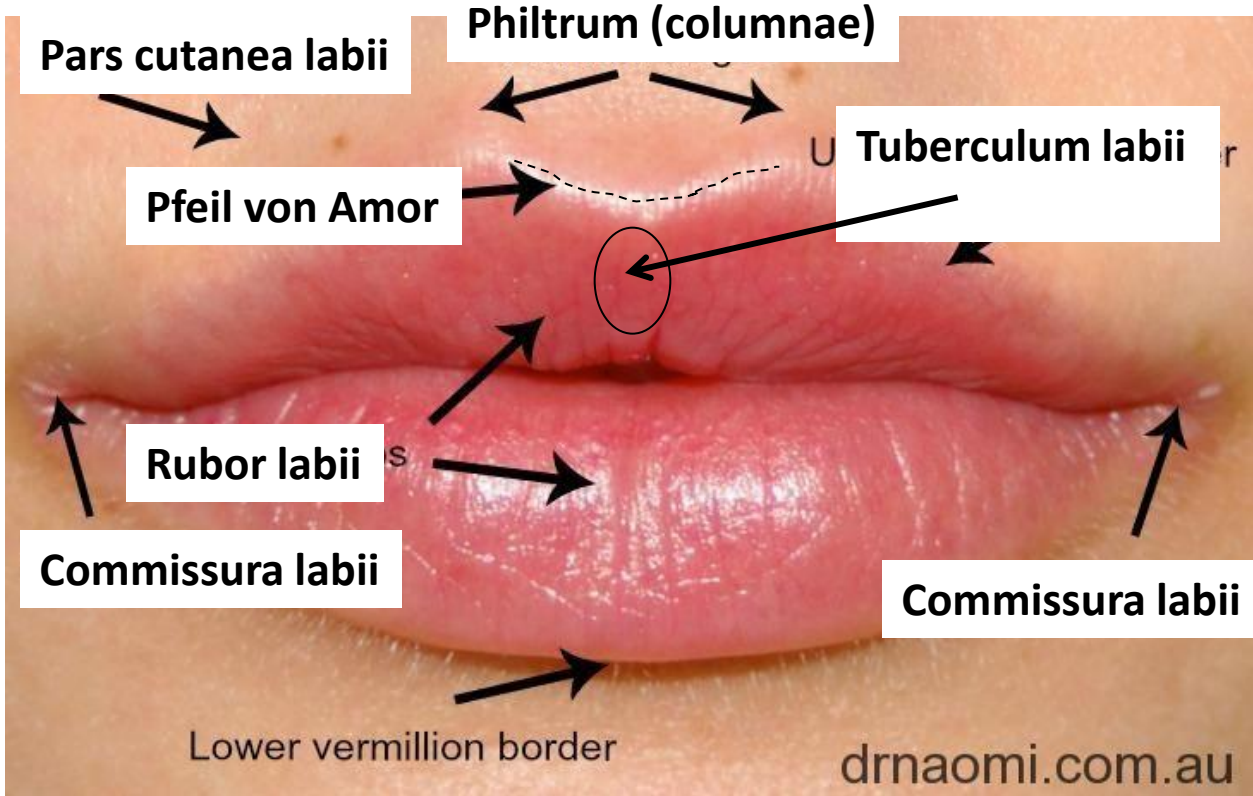
PHILTRUM
und ein
ausgeprägtes
TUBERCULUM



Saugling

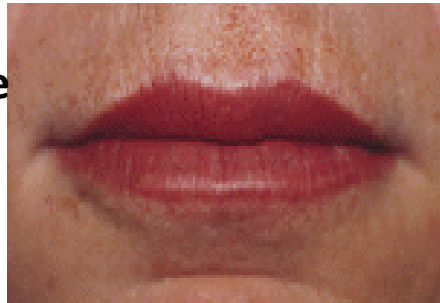

Kleinkind

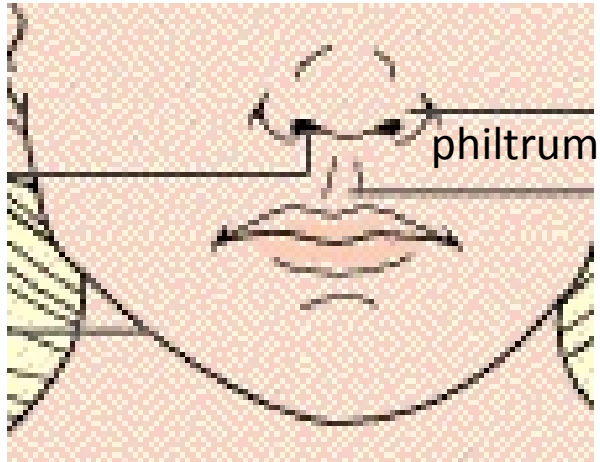


Erwachsene

Vor und nach Kollagen

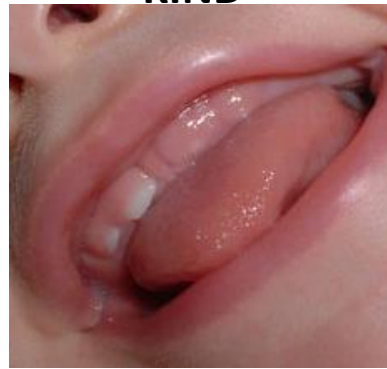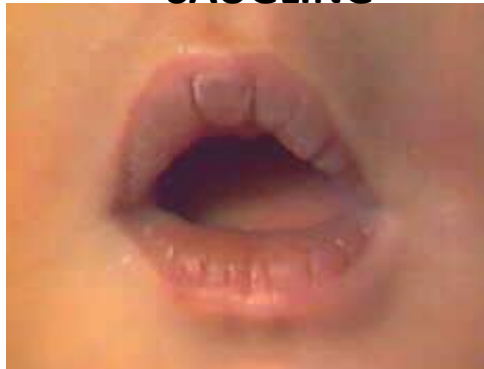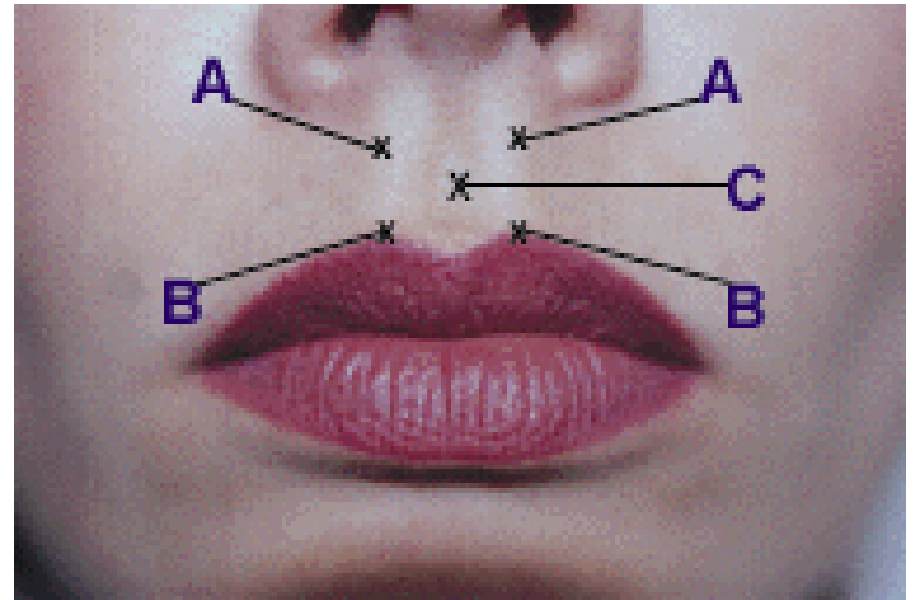


MORPHOLOGIE DER LIPPE

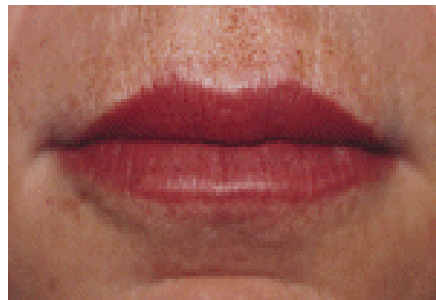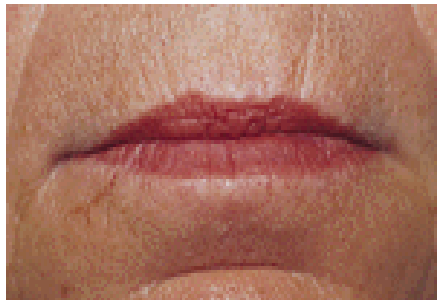


SÄUGLING

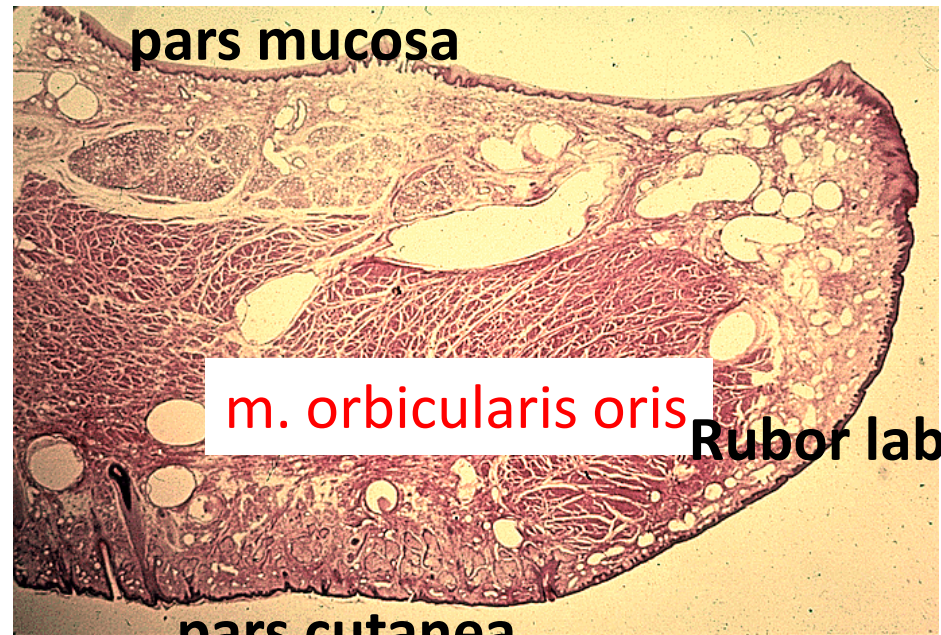
KIND



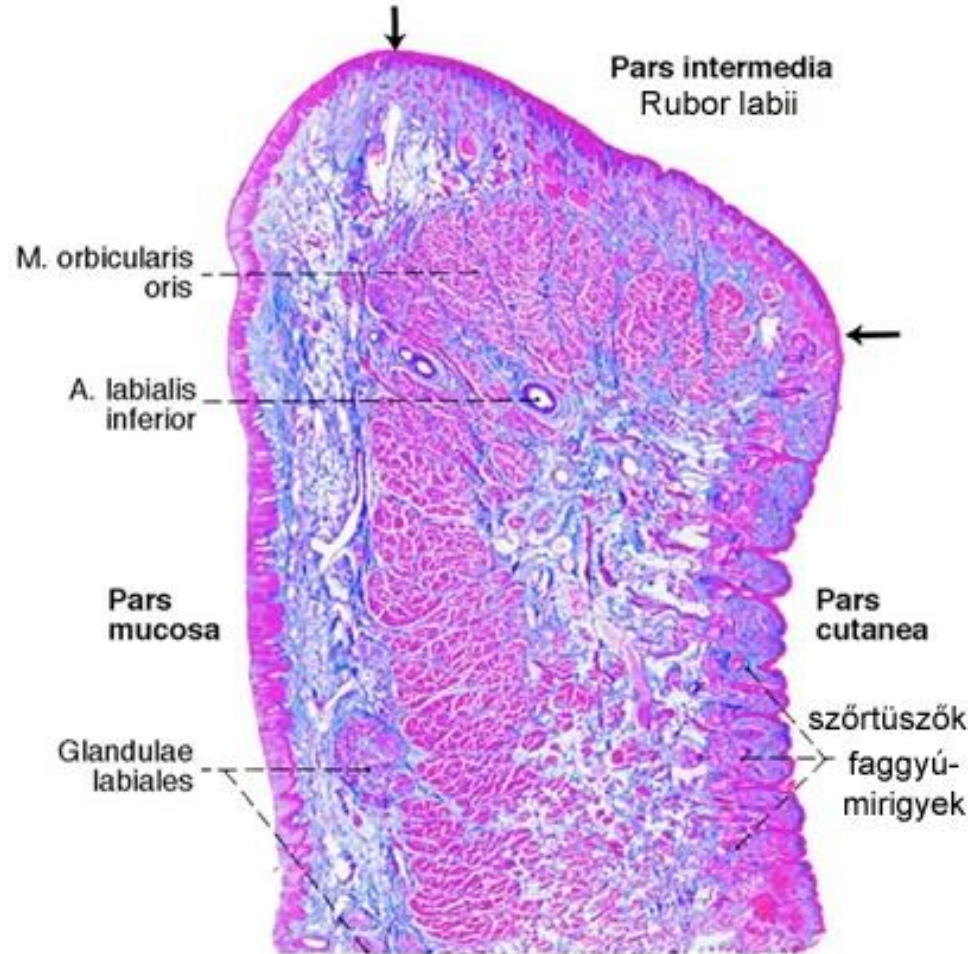
ERWACHSENE



„BEFORE UND AFTER“ KOLLAGEN



LABIA



Innervierung:

N. infraorbitalis (V/2)

N. mentalis (V/3)

Füllung: m. orbicularis oris

Pars cutanea:

mehrsch, verhorntes Plattenepithel
Haarfollikeln, Talg- und Schweißdrüsen

Rubor labii:

Keine Drüse (bei der Grenze sind die „freie Talgdrüsen - ohne Haarfollikeln)
Hohe BGWBpapillen, Kapillarenetz,
Keine Pigmentation → **LIPPENROT**

Pars mucosa:

Mehrsch, unverhorntes Plattenepithel,
Gll. labiales (seromukös, gemischt)

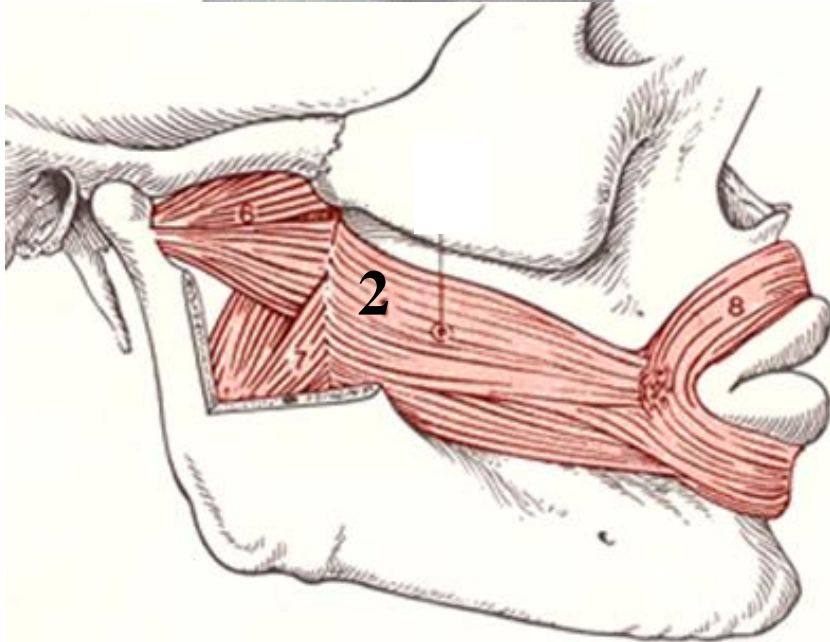
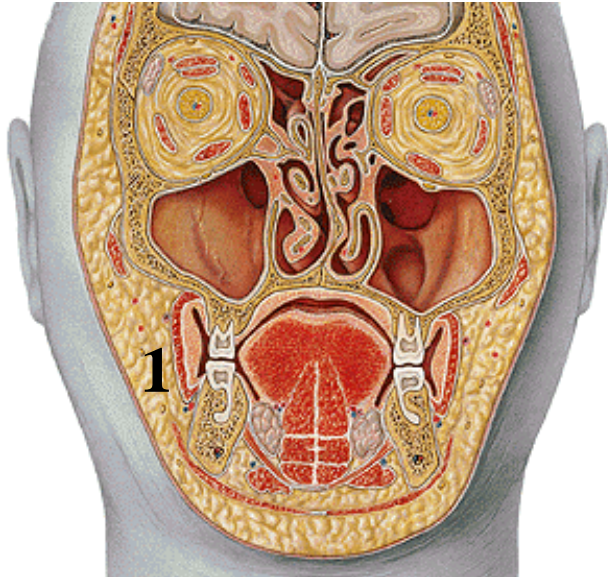
Blutversorgung:

A. facialis → **A. labialis sup., inf.** →
arterielle RING → **V. angularis/facialis**

Lymphabfluss:

Nn. ll. submandibulares, submentales,
obere Zervik. Lymphknoten

GESICHT (BUCCA)



Aussen: **Haut**

Corpus adiposum buccae (1, Bichat)

Hauptstruktur: **m. buccinator** (2)
(zygomaticus, risorius, platysma)

Innen: **Mukosa**, gl. Buccales

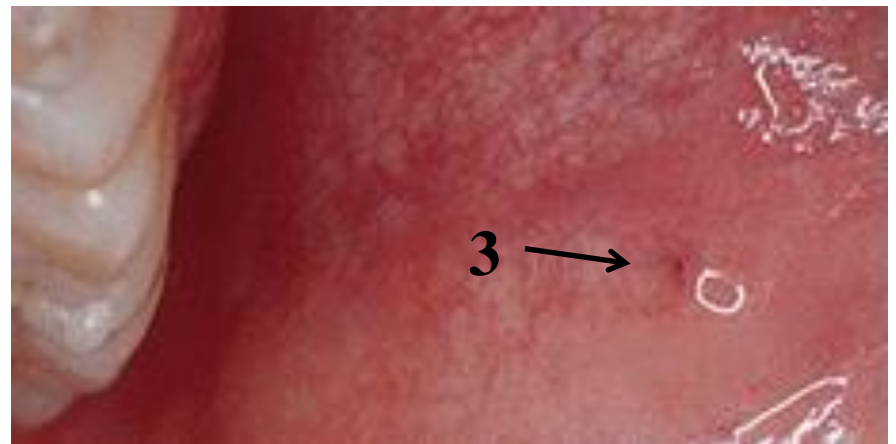
In der höhe vom 2. oberen

Molarzahn : ductus parotideus

Mündung, papilla parotidea (3)

Blutversorgung: **a. transversa faciei**,
a buccalis → **V. transversa faciei**, **v.**
faciei prof.

Innervierung: **N. buccalis** (V/3)



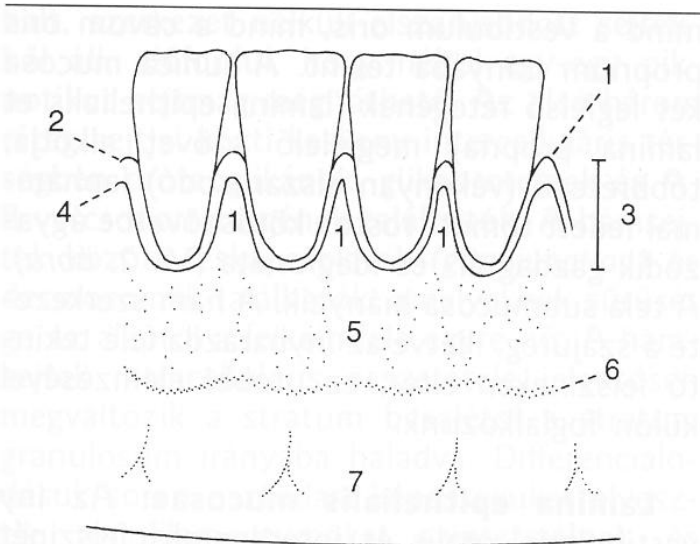
DAS PARODONTIUM = ZAHNHALTEAPPARAT

EINTEILUNG:

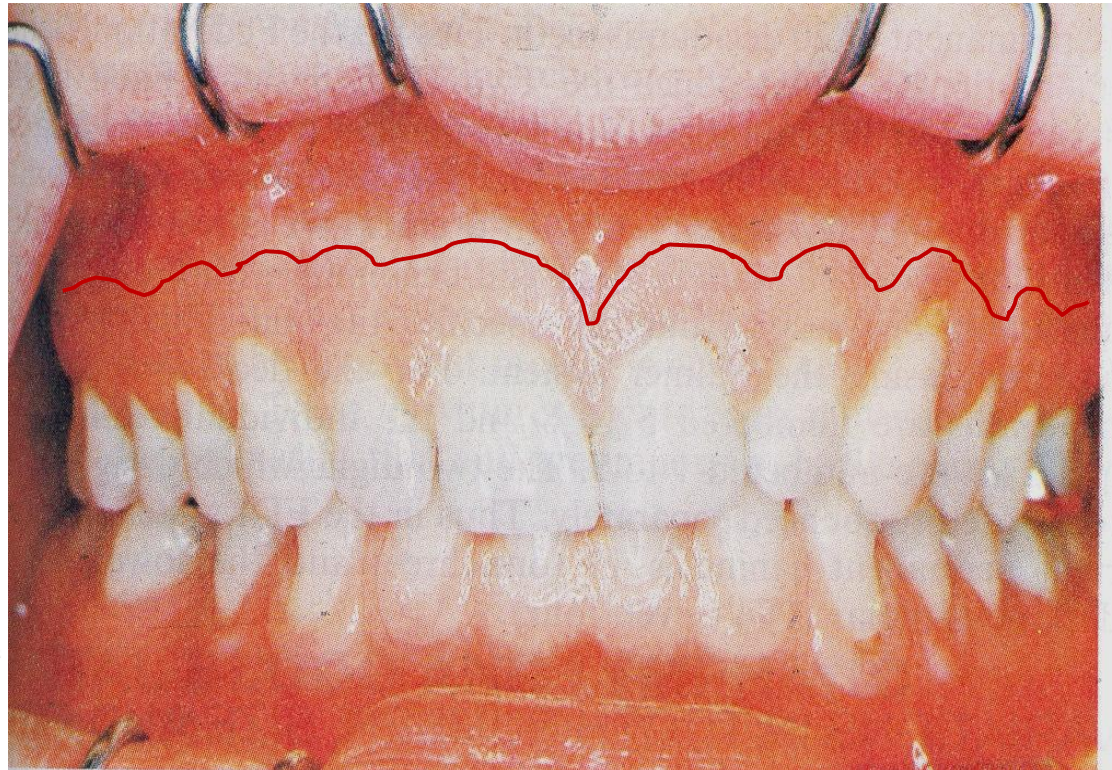
GINGIVA

PROCESSUS ALVEOLARIS

PERIODONTIUM



VI. 1. ábra. **A gingiva részei.** 1. papilla interdentalis, 2. limbus gingivae, 3. marginalis gingiva, 4. sulcus gingivae vonala, 5. alapjához feszesen rögzülő gingiva, 6. linea girlandiformis (mucogingivalis junctio), 7. szájnyálkahártya



DENTES - ALLGEMEINE BEGRIFFE

HETERODONTIA

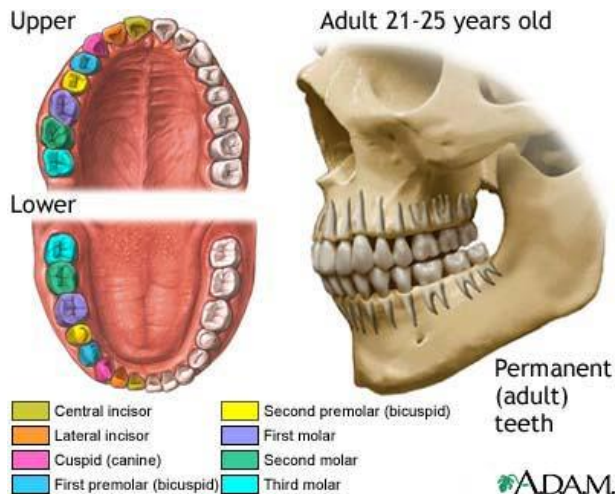
aus verschiedenen aufgebauten
Zähnen bestehendes Gebiss

DIPHYDONTIA

ein Zahnwechsel
zwei Zahn generationen:
Milchgebiss und Dauergebiss

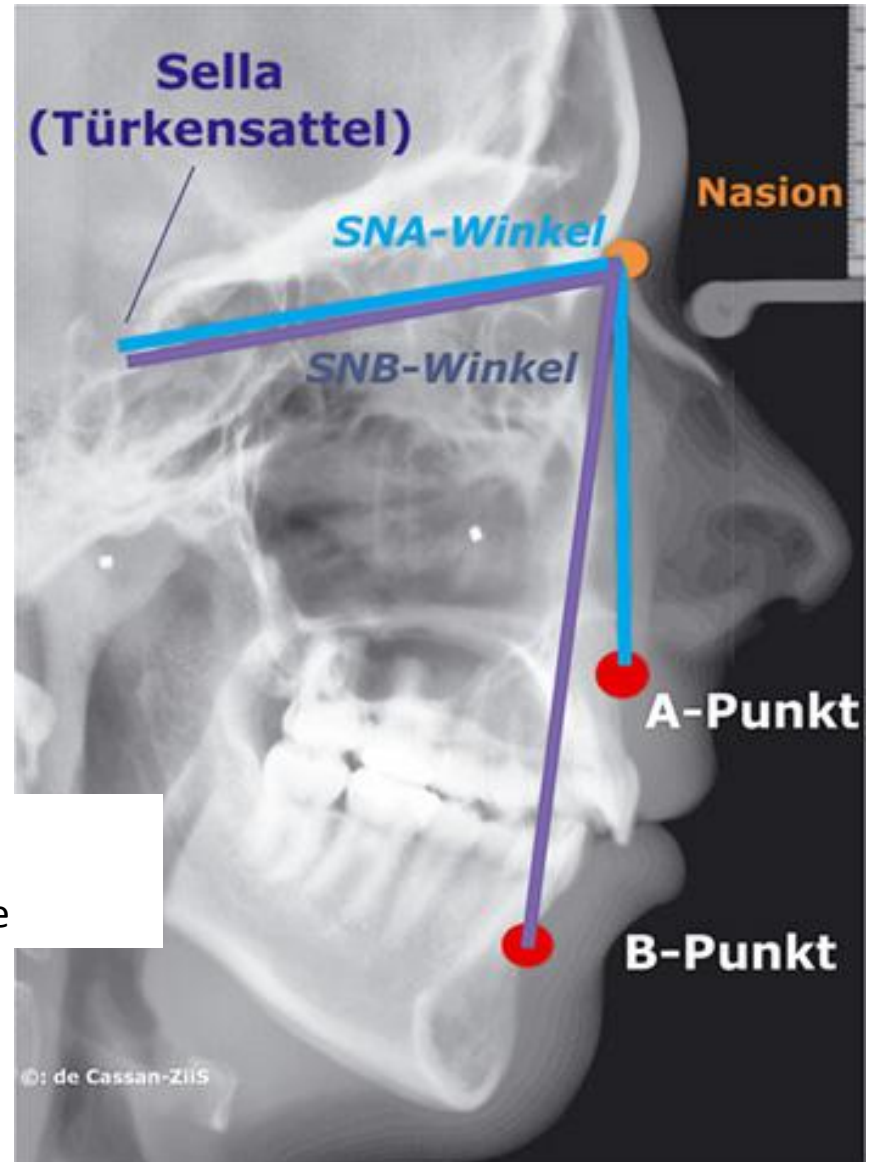
PSALIODONTA

„Scherenbiss“



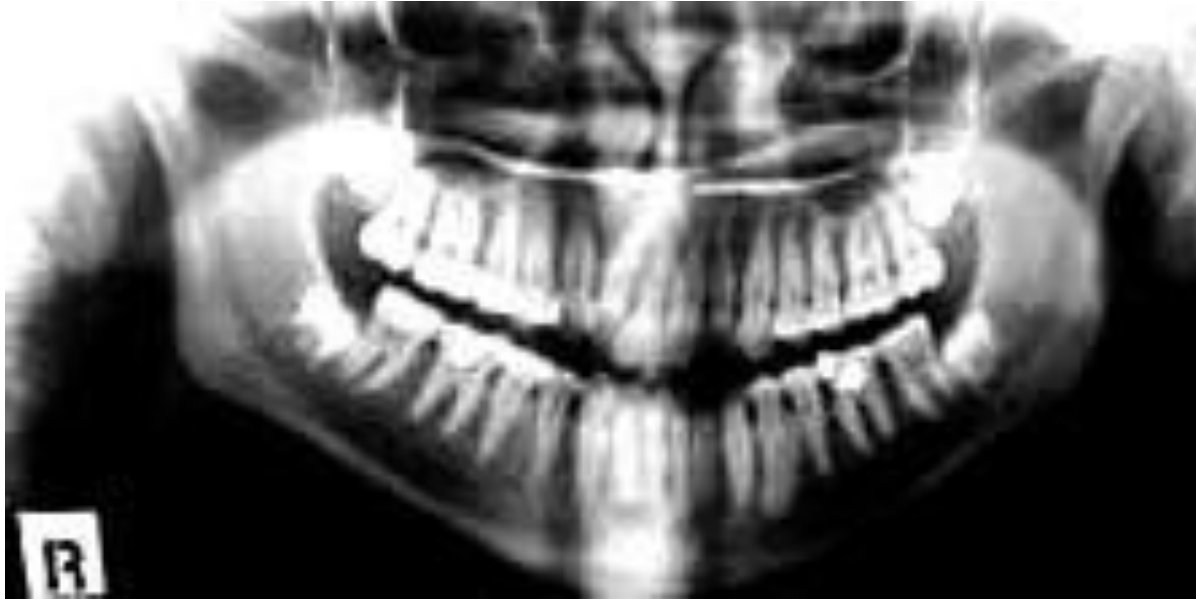SPEE-KURVE

Okklusionslinie

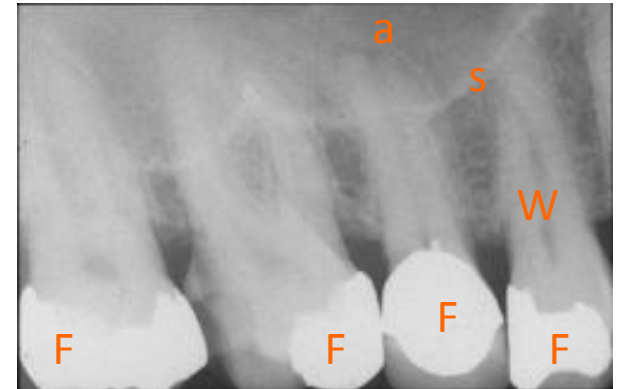


RÖNTGENANATOMIE

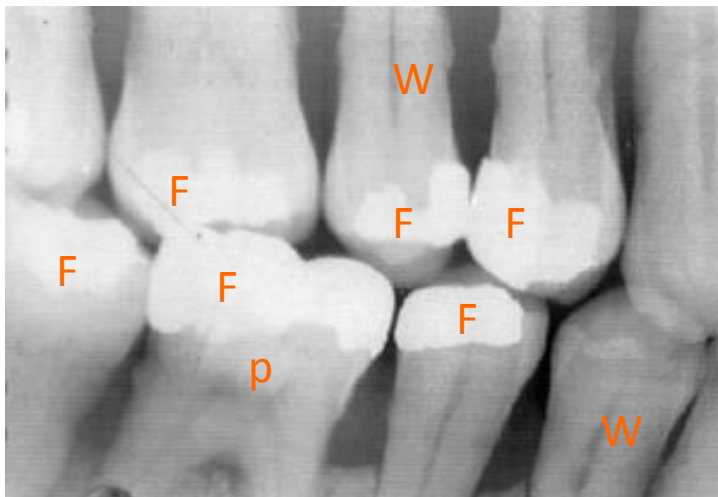
Orthopantomogramm



Sinus maxillaris

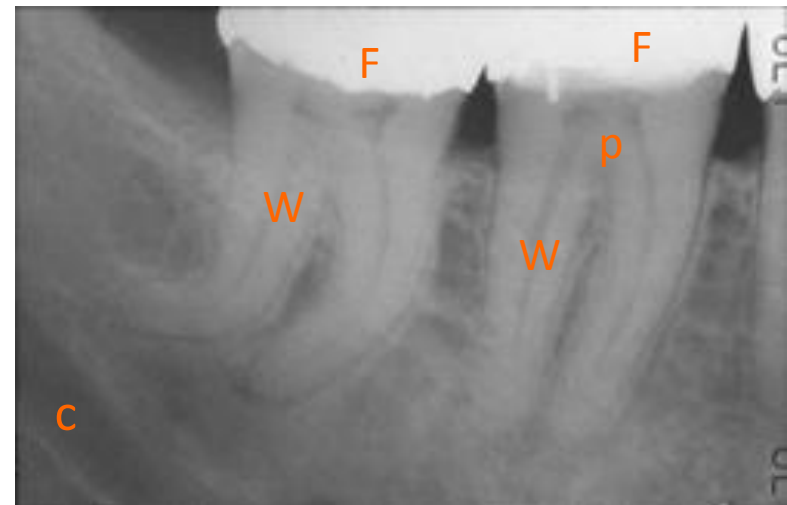

Canalis mandibulae

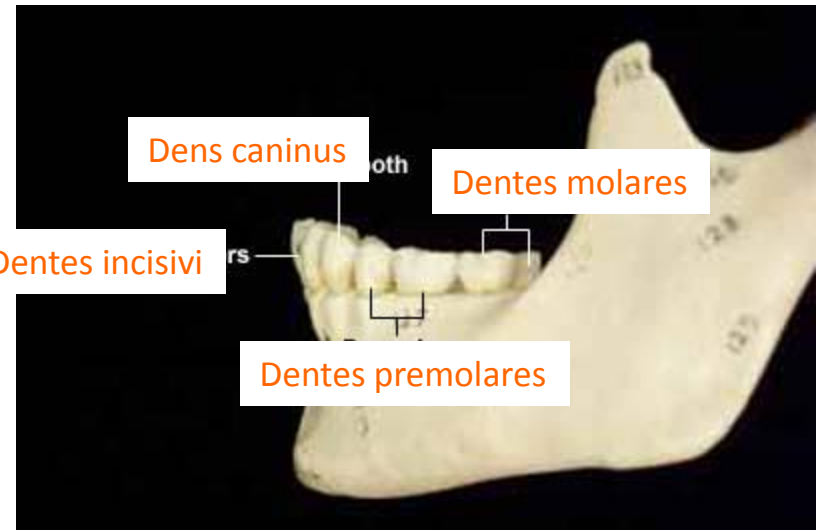
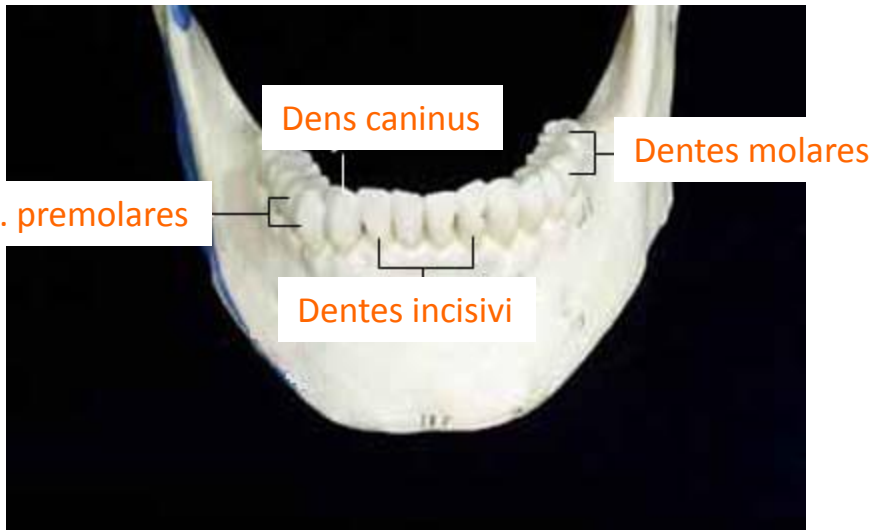
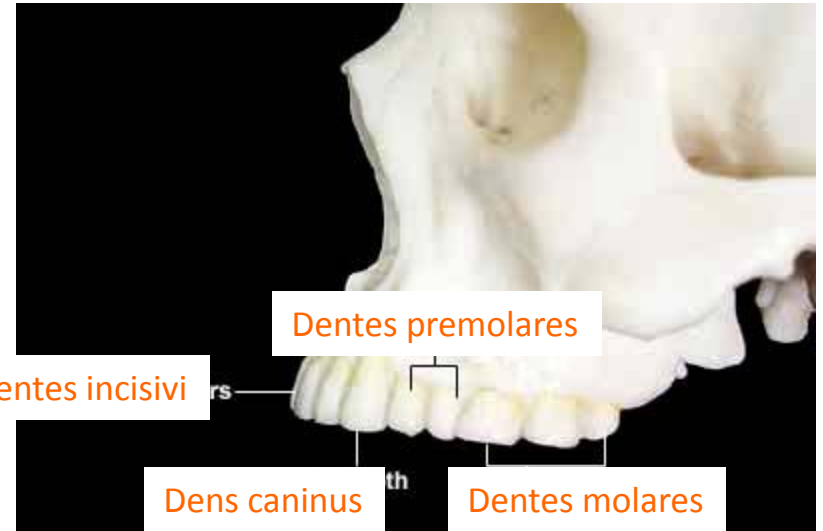
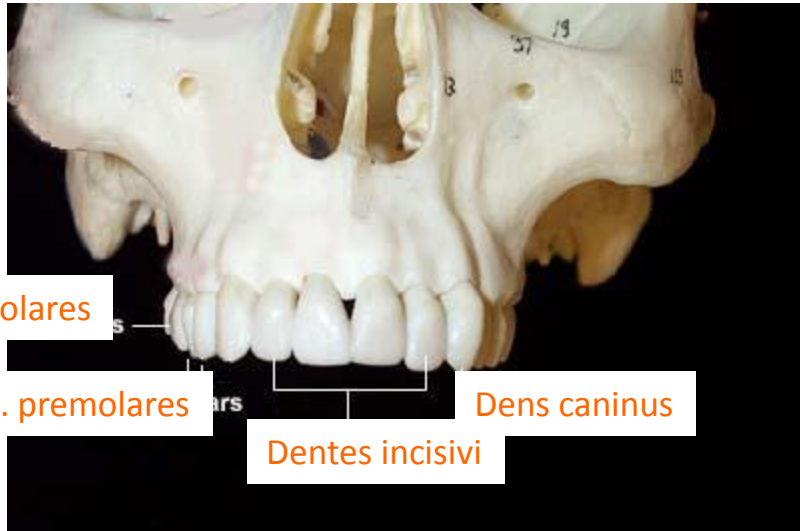


Zahnfüllungen

Der Wurzelkanal
und die Pulpe



ZAHNGRUPPEN

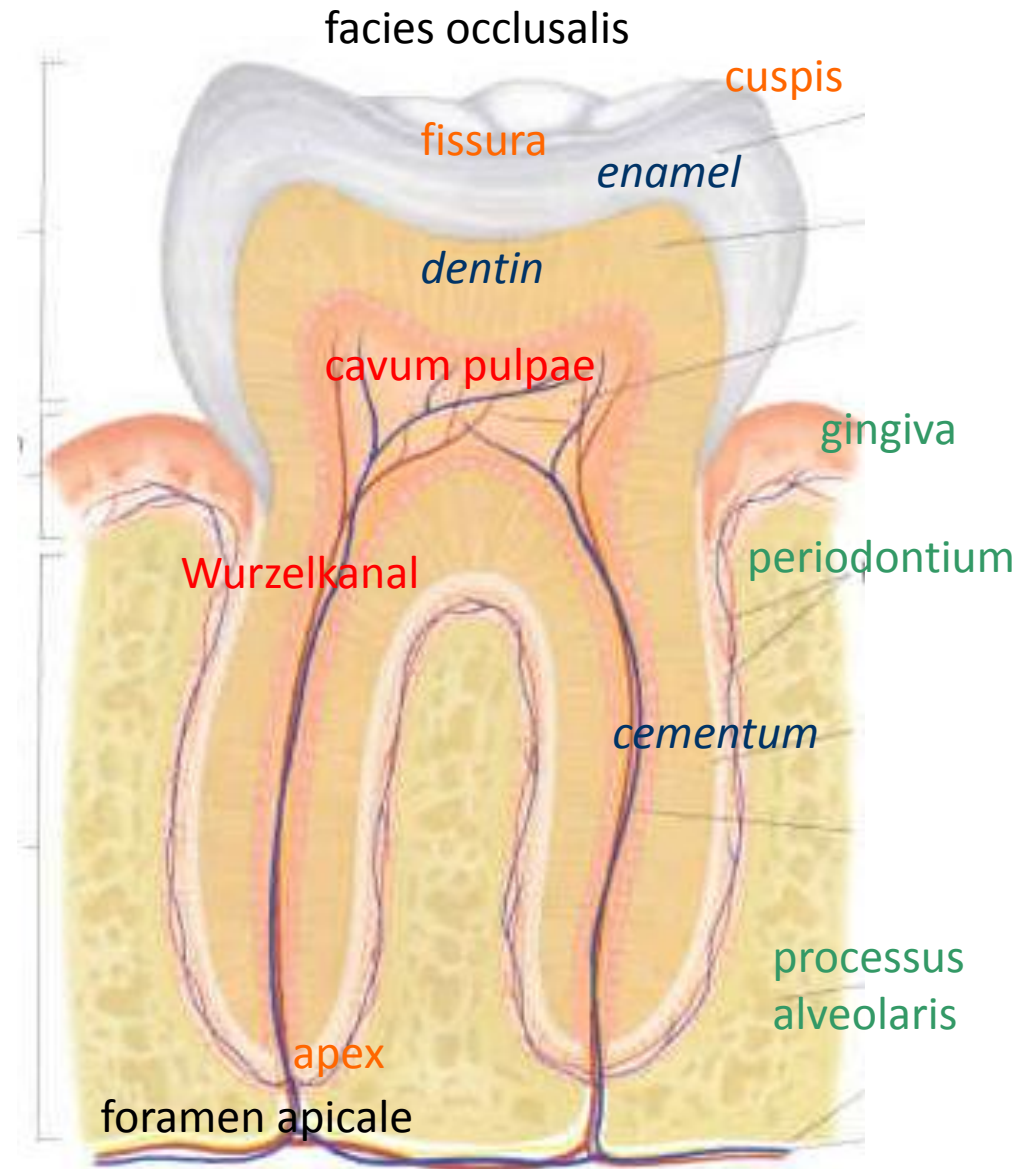


ÜBERBLICK DER ZAHNSTRUKTUR

Corona dentis

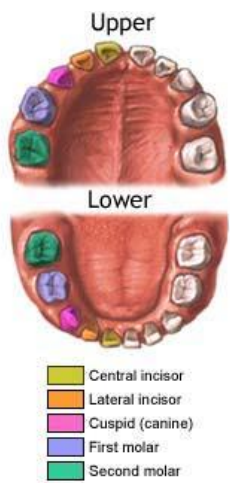
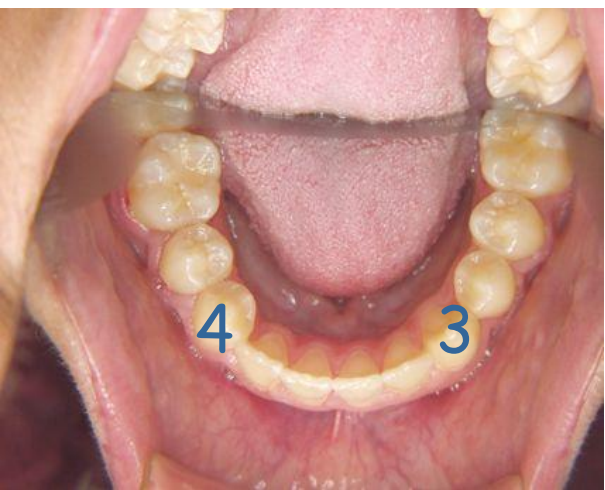
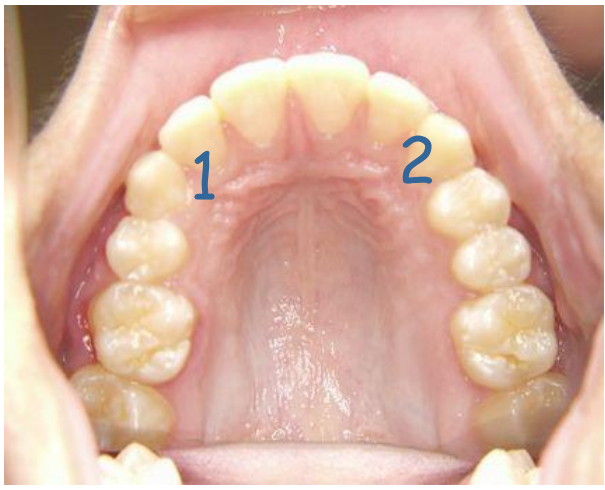Cervix (collum) dentis

Radix dentis



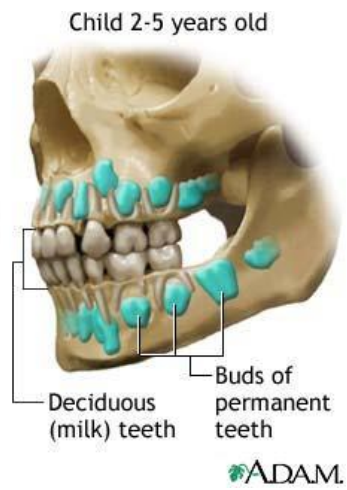
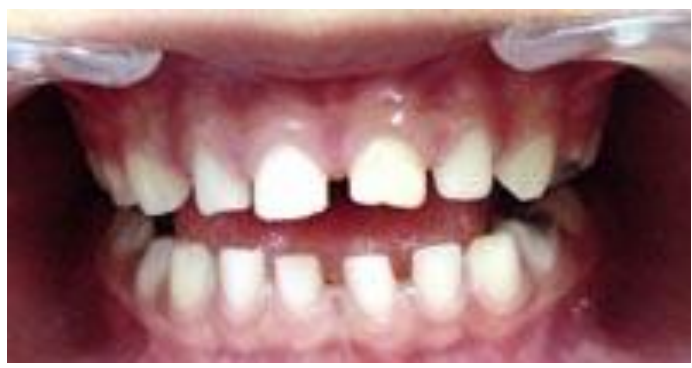DENTES PERMANENTES

ZAHNFORMEL $\frac{M \ 2 \ 1 \ 2 \ 3}{M \ 2 \ 1 \ 2 \ 3}$



MILCHZÄHNE

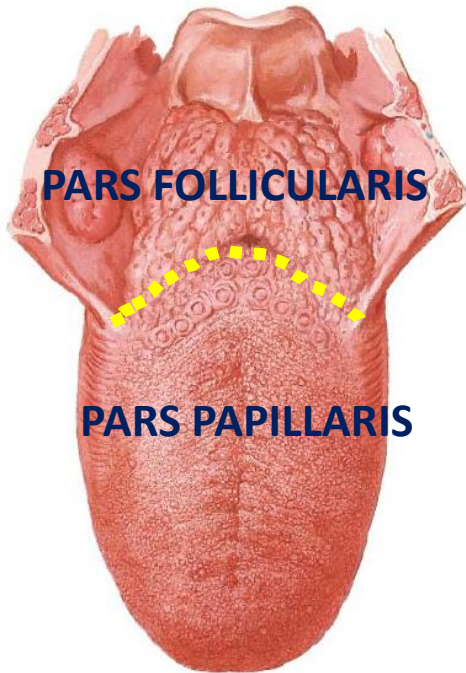
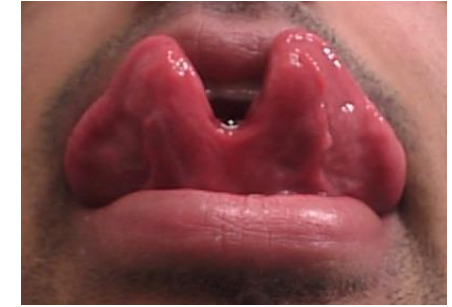ZAHNFORMEL $\frac{M \ 2 \ 1 \ 0 \ 2}{M \ 2 \ 1 \ 0 \ 2}$



ZAHNWECHSEL

- untere 1. Schneidezähne
- untere 2. Schneidezähne
- obere 1. Schneidezähne
- obere 2. Schneidezähne
- obere 1. Mahlenzähne
- untere 1. Mahlenzähne
- obere Eckzahn
- untere Eckzahn
- obere 2. Mahlenzähne
- untere 2. Mahlenzähne

EINTEILUNG DER ZUNGE



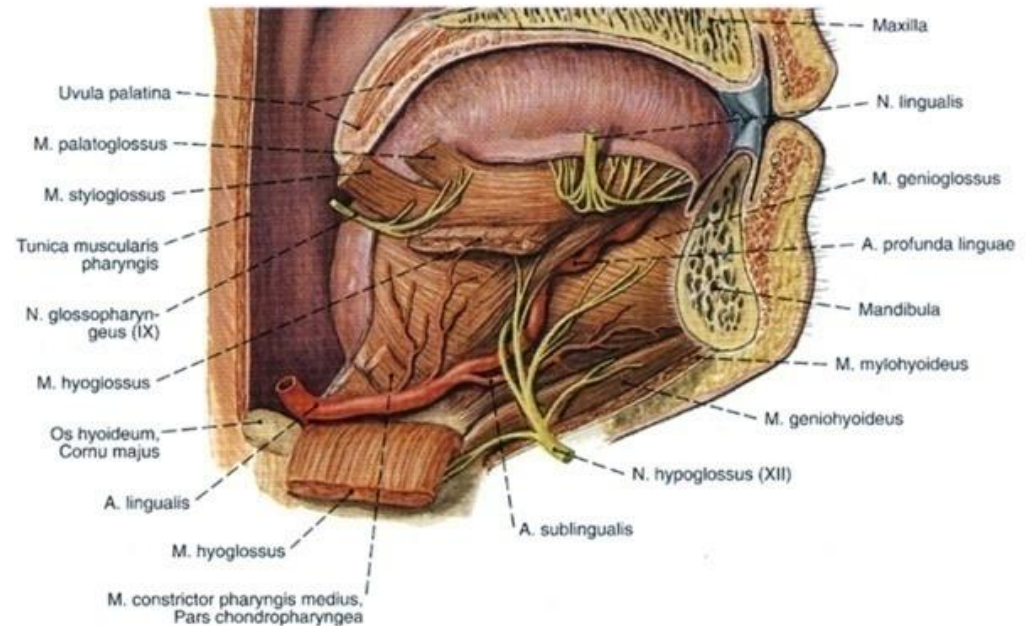
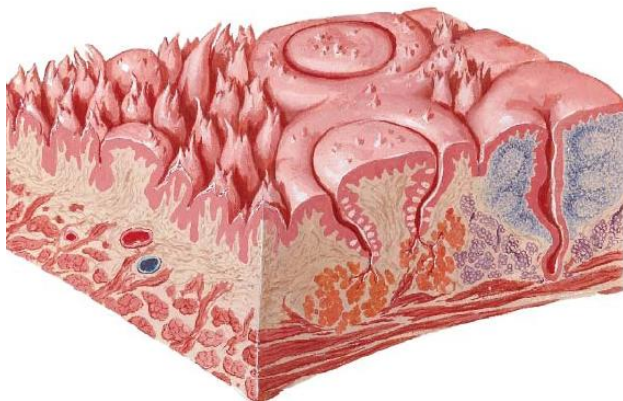
Radix linguae

Corpus linguae

Dorsum linguae

Apex linguae

PARS FOLLICULARIS
Sulcus terminalis
PARS PAPILLARIS



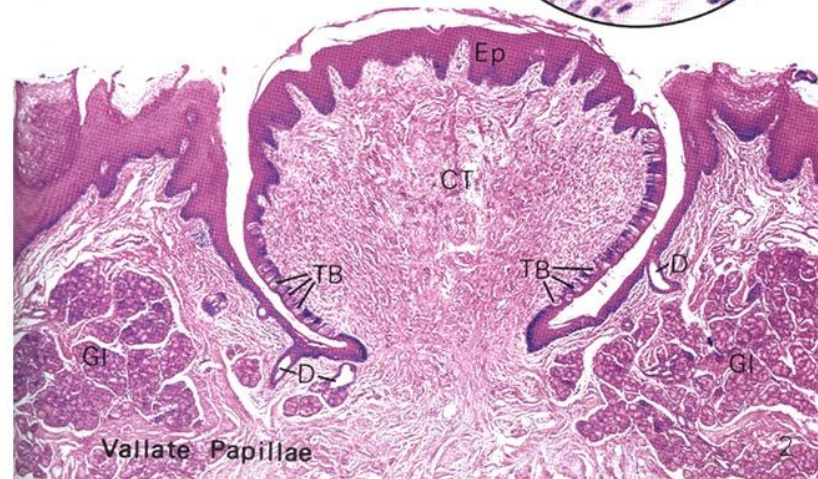
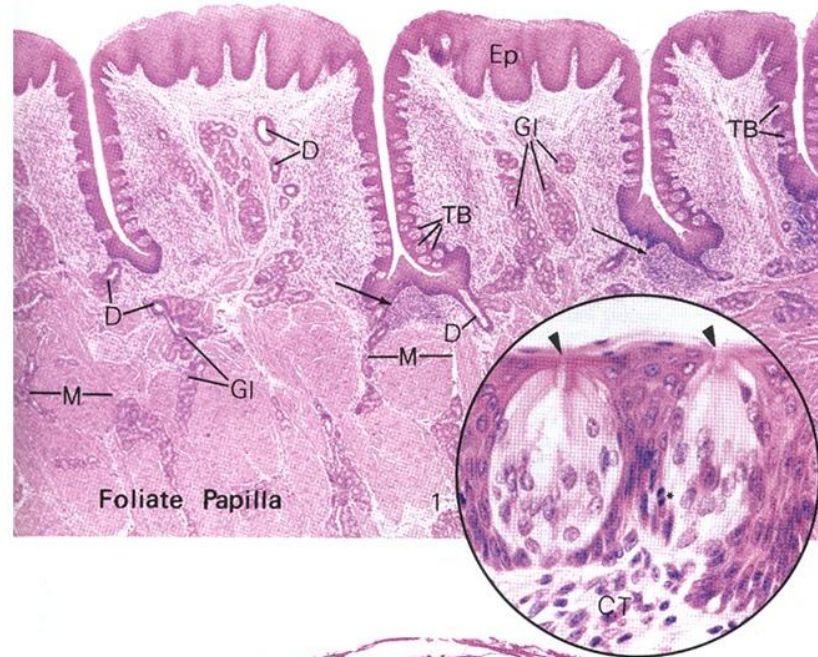
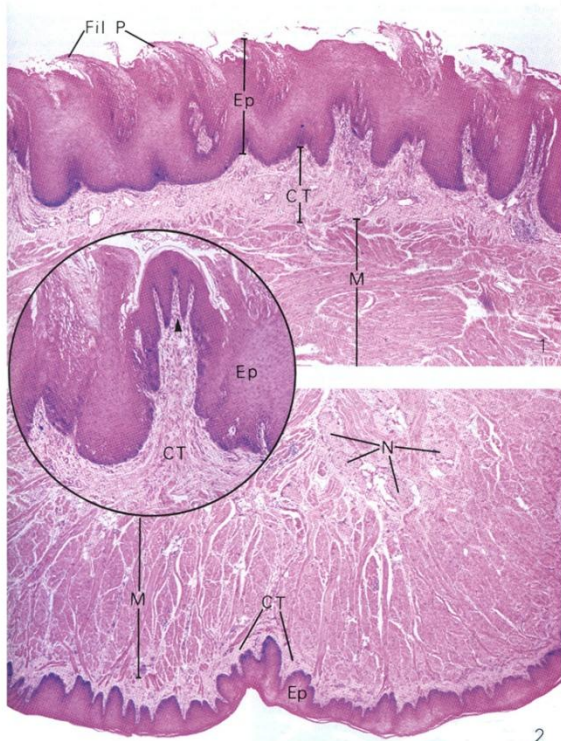
ZUNGENPAPILLEN

PAPILLA FILIFORMIS

PAPILLA FUNGIFORMIS

PAPILLA FOLIATA

PAPILLA VALLATA



ZUNGENMUSKULATUR

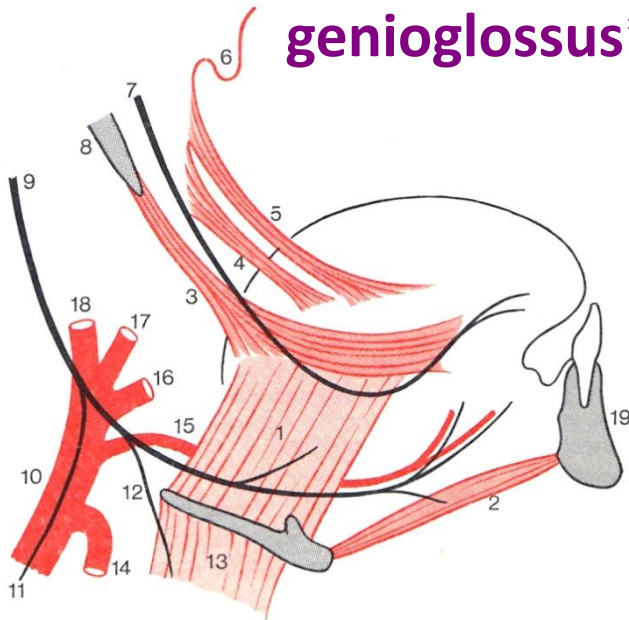
EXTRINSISCHE

palatoglossus**

styloglossus*

hyoglossus*

genioglossus*



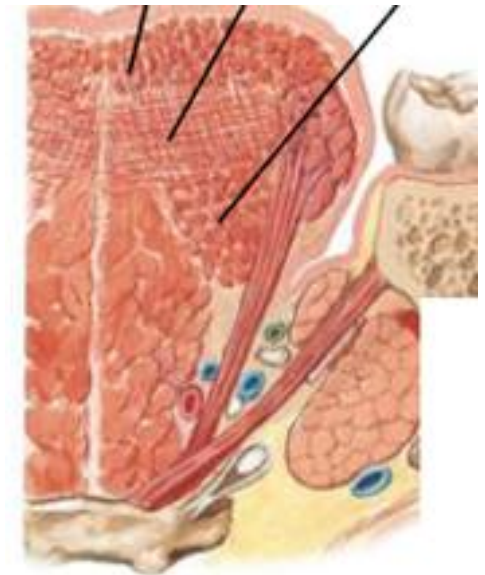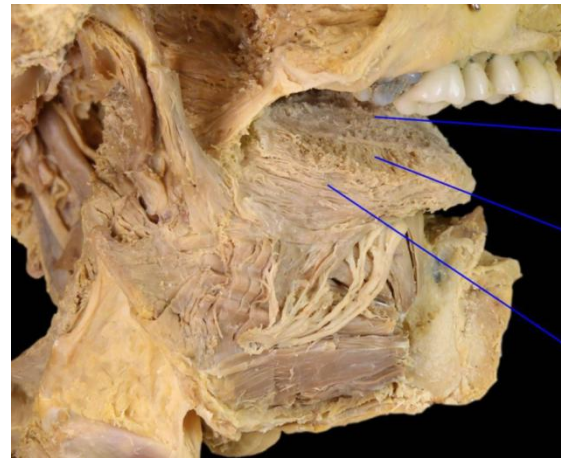
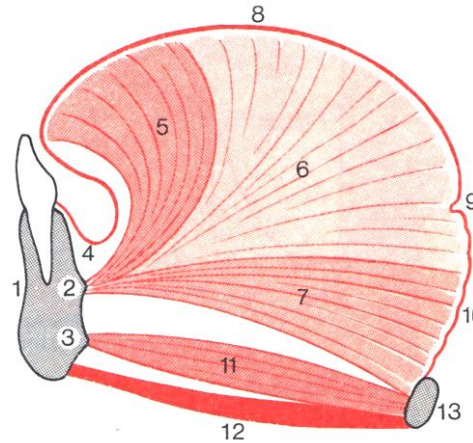
INTRINSISCHE

verticalis*

tranversus*

longitudinalis sup.*

longitudinalis inf.*

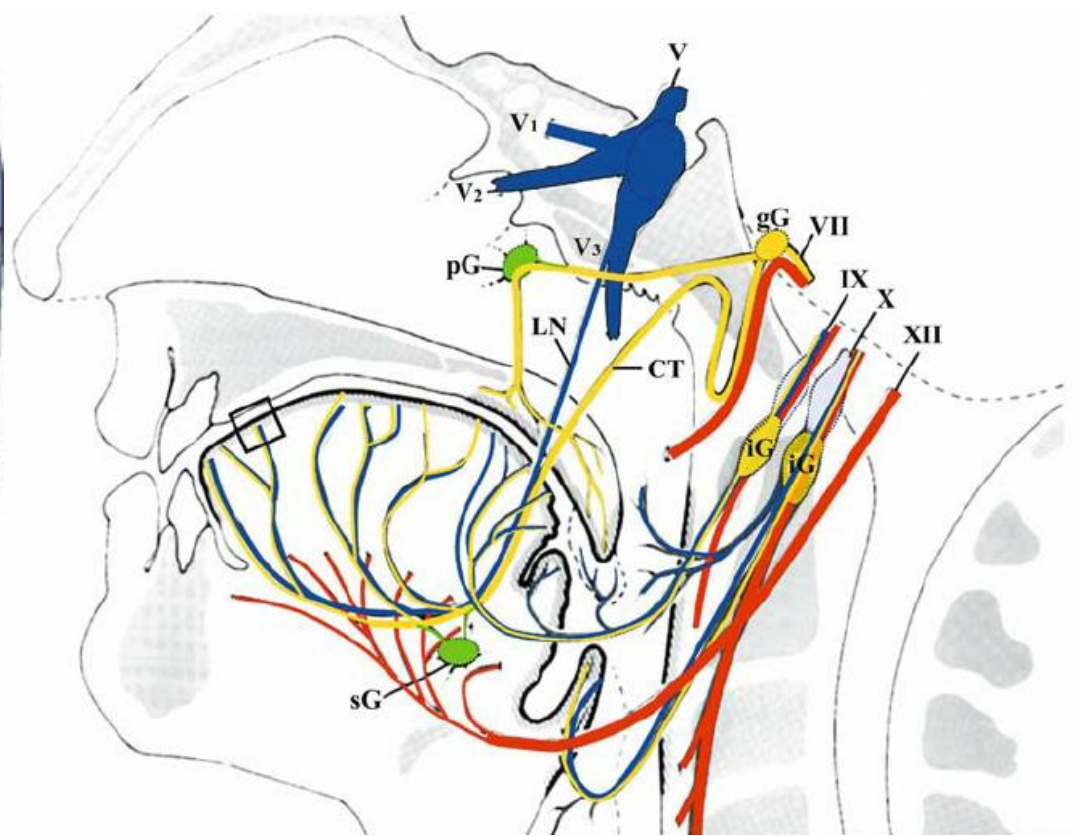
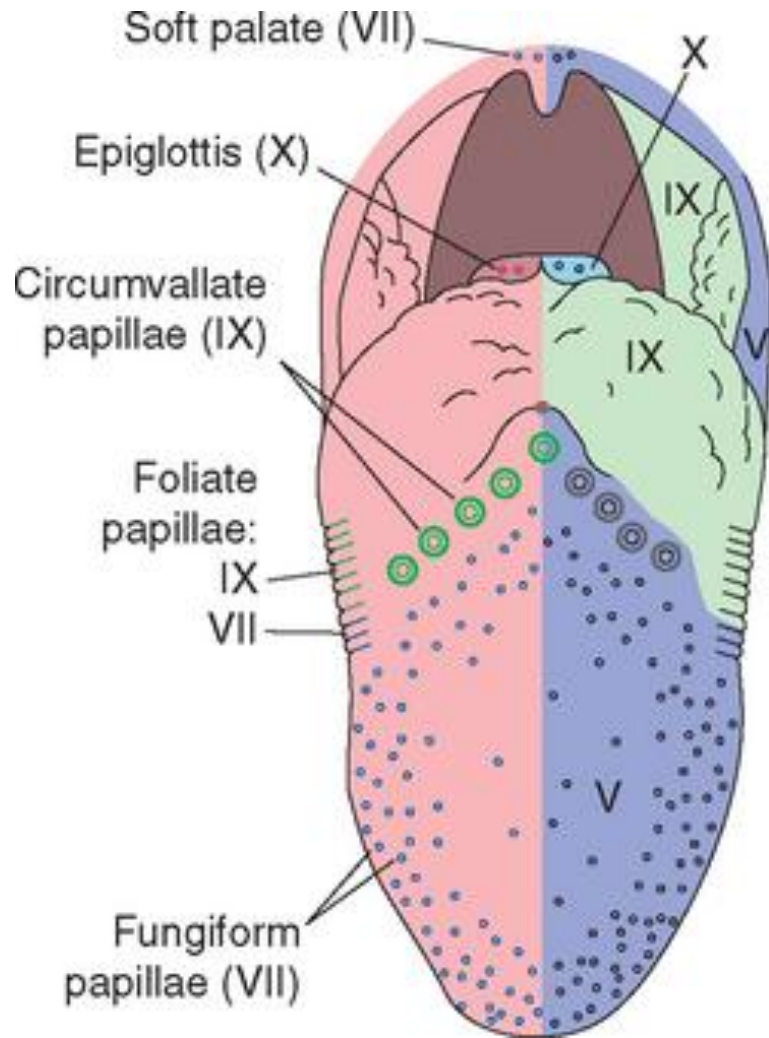


Innervation:

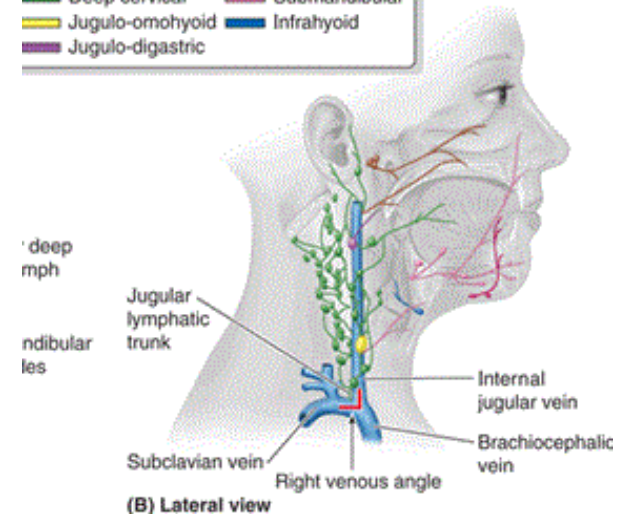
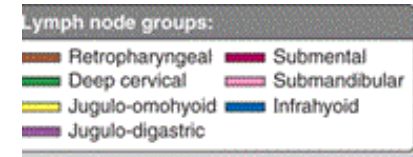
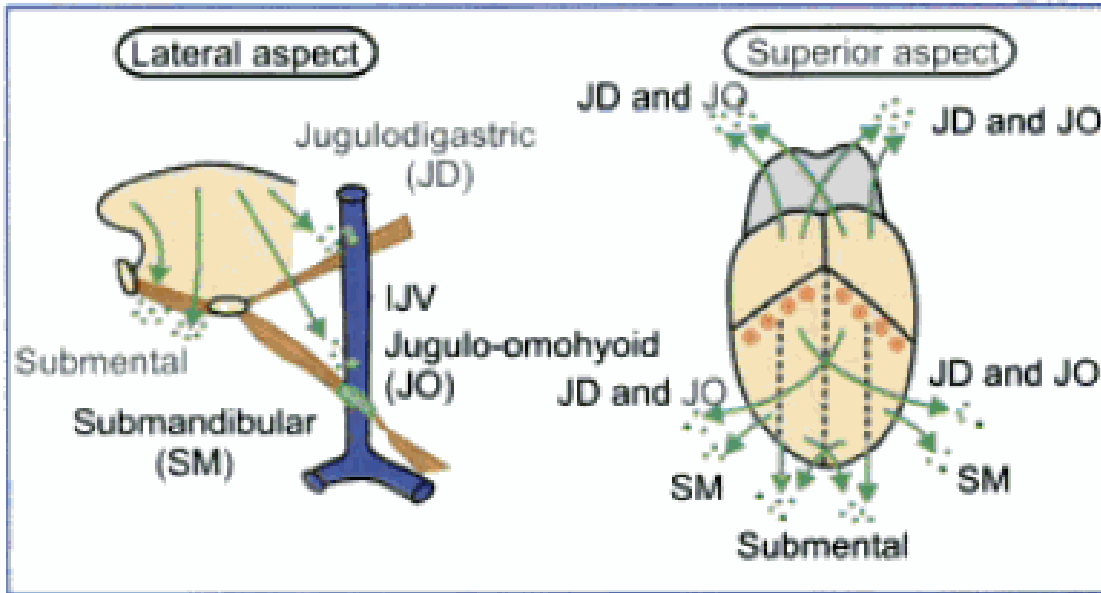
*n. XII

**n. IX (bzw X-XI) ☺

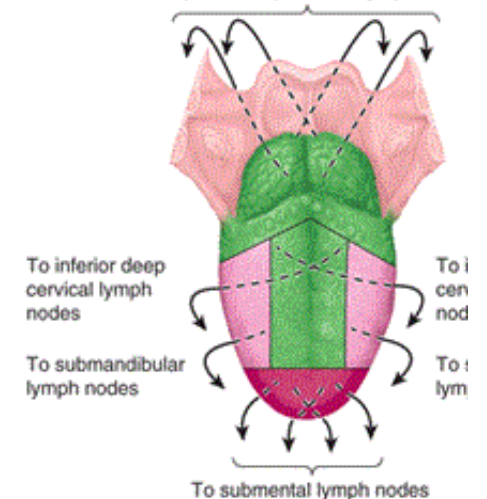
NERVENVERSORGUNG DER ZUNGE



LYMPHABFLUSS DER ZUNGE



To superior deep cervical lymph node:



(A) Superior view

APEX

DORSUM (med)

DORSUM (lat)

PARS TONSILLARIS

EPIGLOTTIS **

Weniger Lymphgefäße

nn. ly. submentales

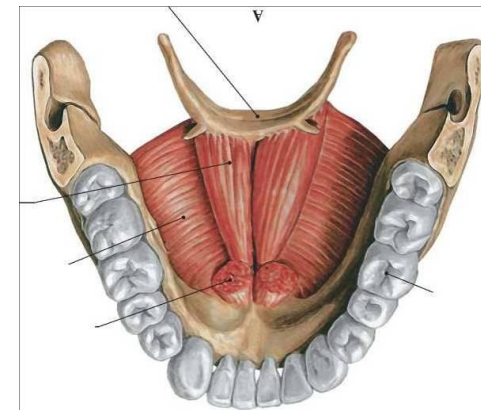
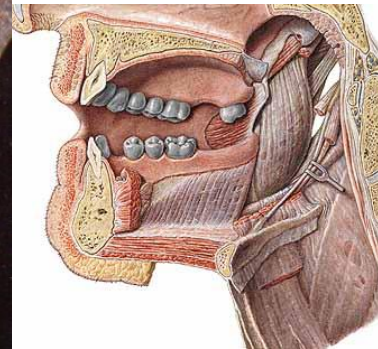
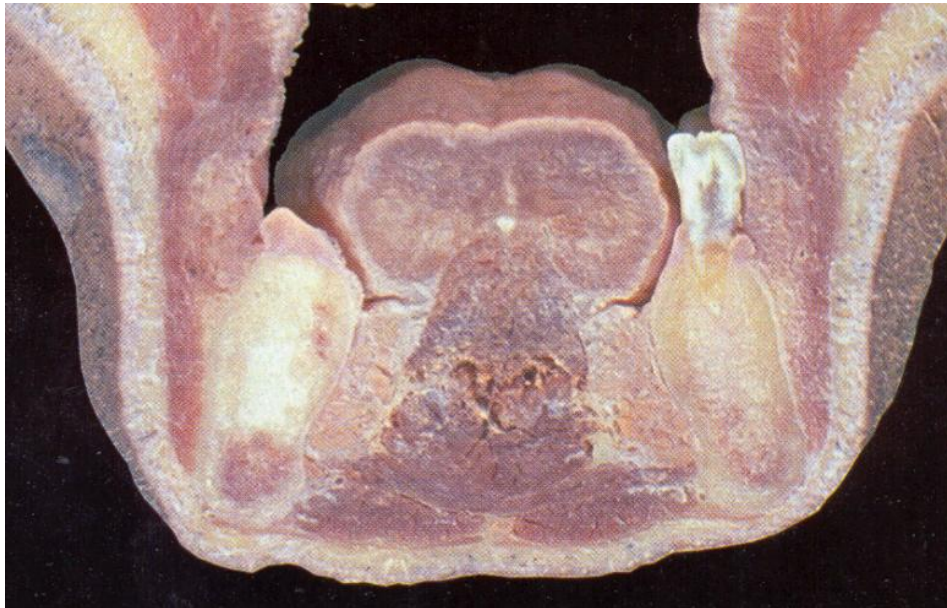
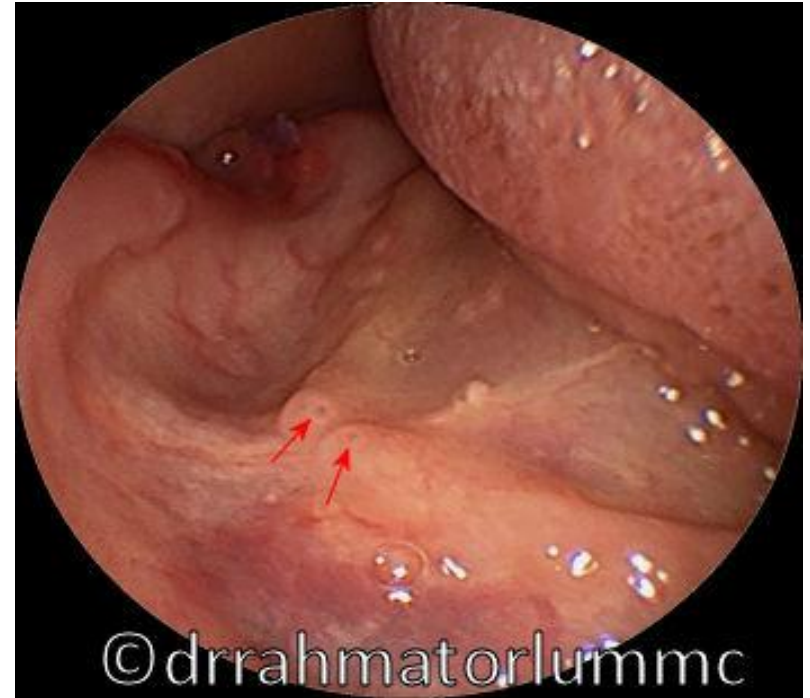
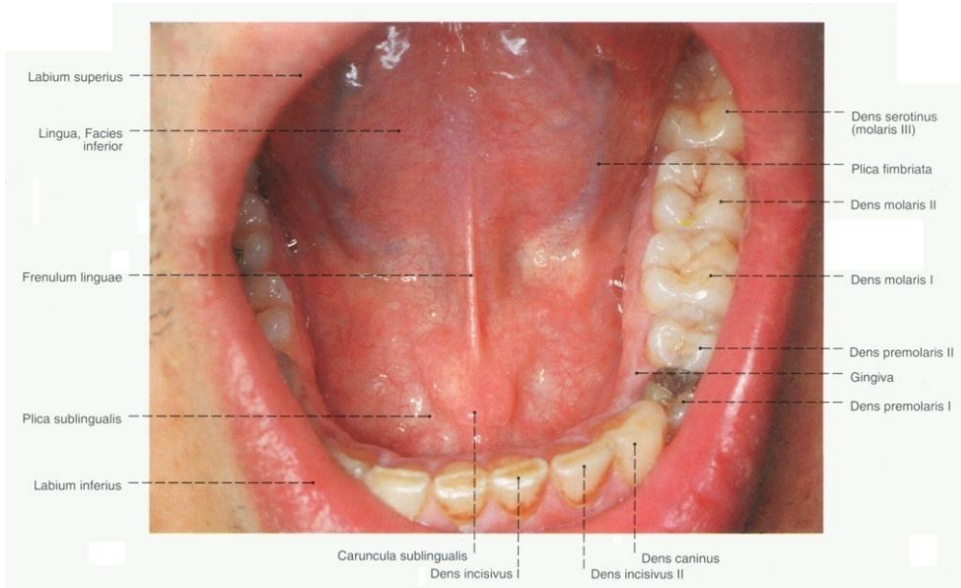
nn. ly. cervicales inferiores (JO) bilat

nn. ly. submandibulares unilat

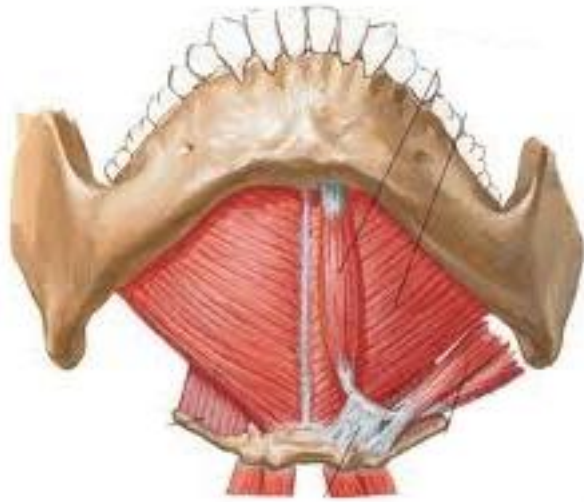
nn. cervicales superiores (JO und JD)

nn. ly. cervicales superiores

MUNDBODEN



DIAPHRAGMA ORIS



M. mylohyoideus + BGW

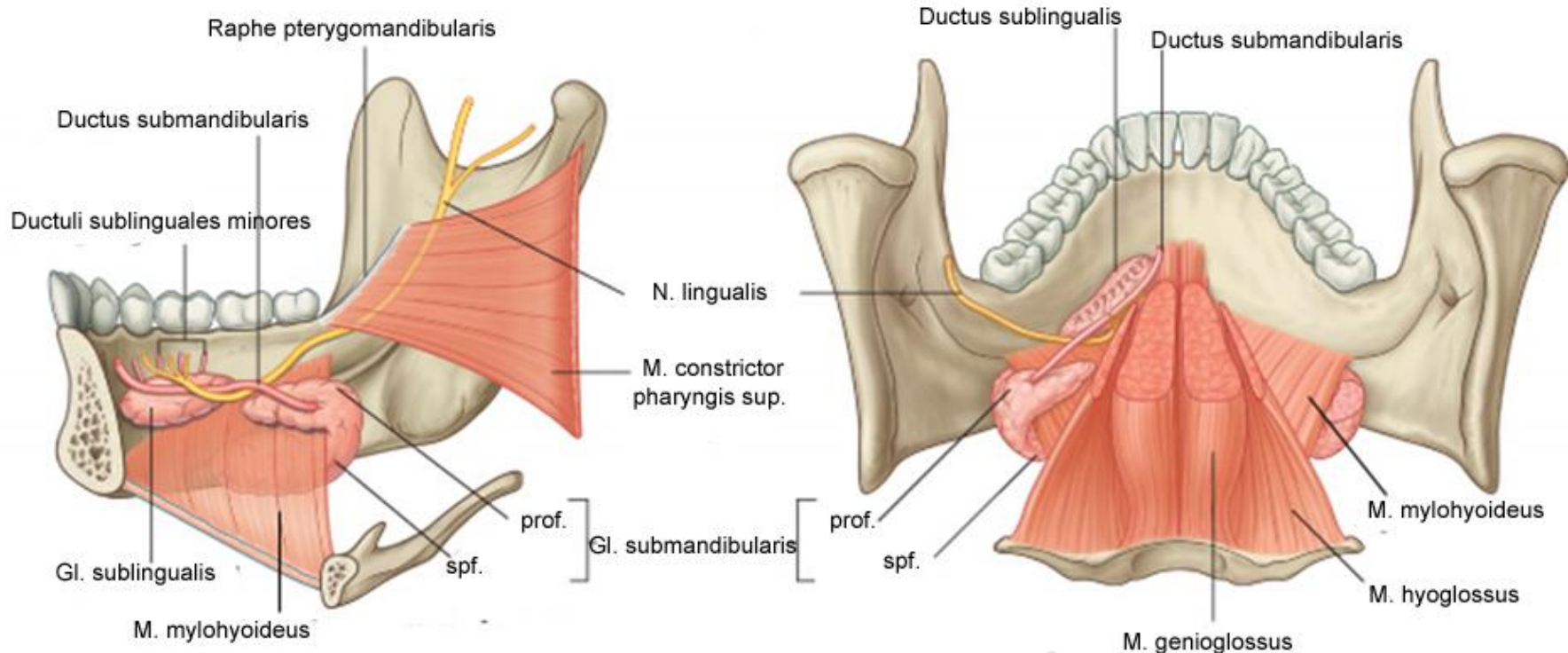
INNEN: m. geniohyoideus

AUSSEN: m. digastricus venter ant.

Mundöffner

Kehlkopfheber, Schluckakt

„Erhöht den negativen Druck in der Mundhöhle“



SULCUS LATERALIS LINGUAE

Grenzen:

medial: m. hyoglossus
lateral: m. mylohyoideus
oben: paralinguale Schleimhaut

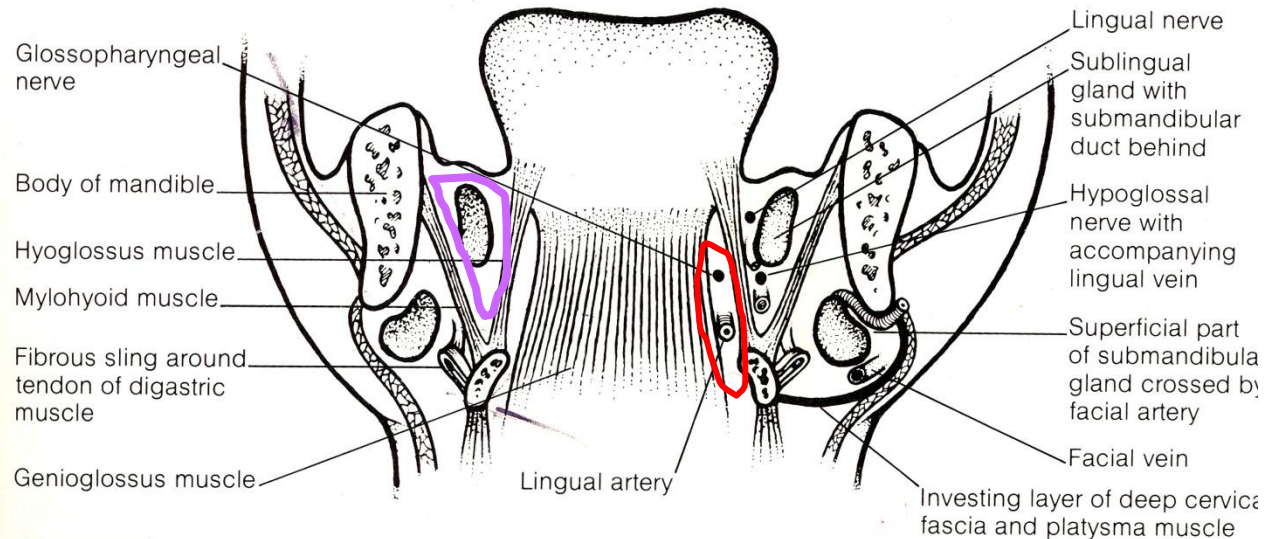
Inhalt: n. lingualis
d. submandibularis
n. hypoglossus

SULCUS MEDIALIS LINGUAE

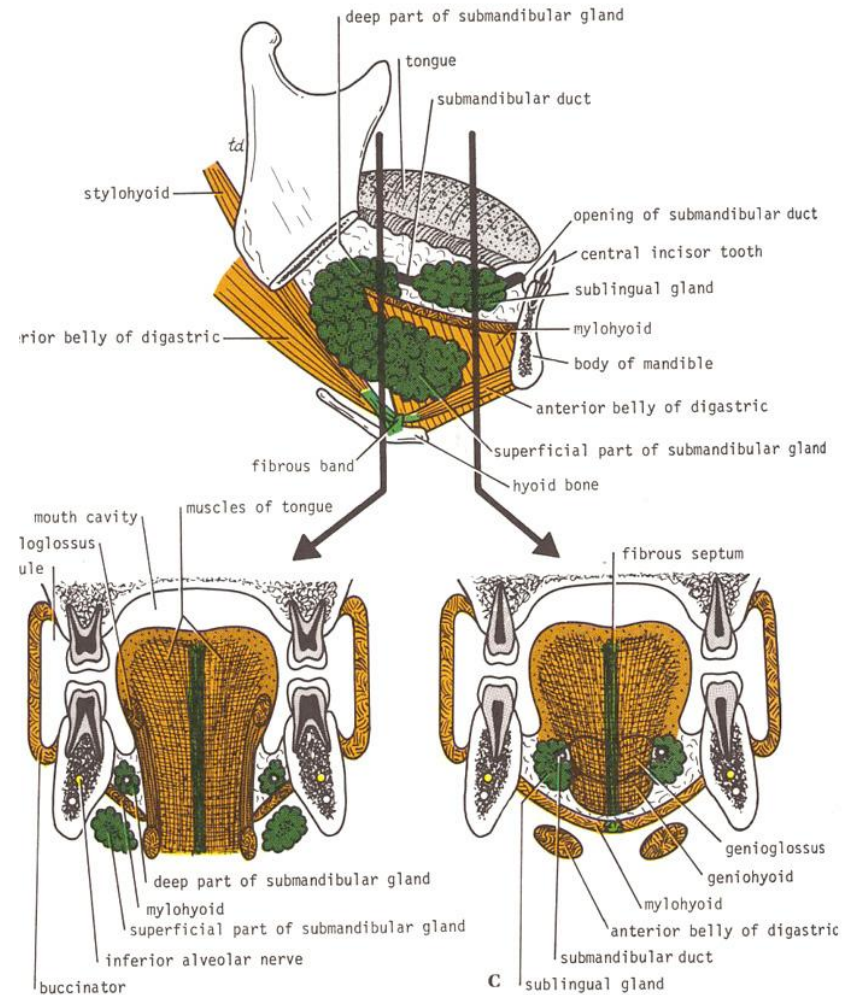
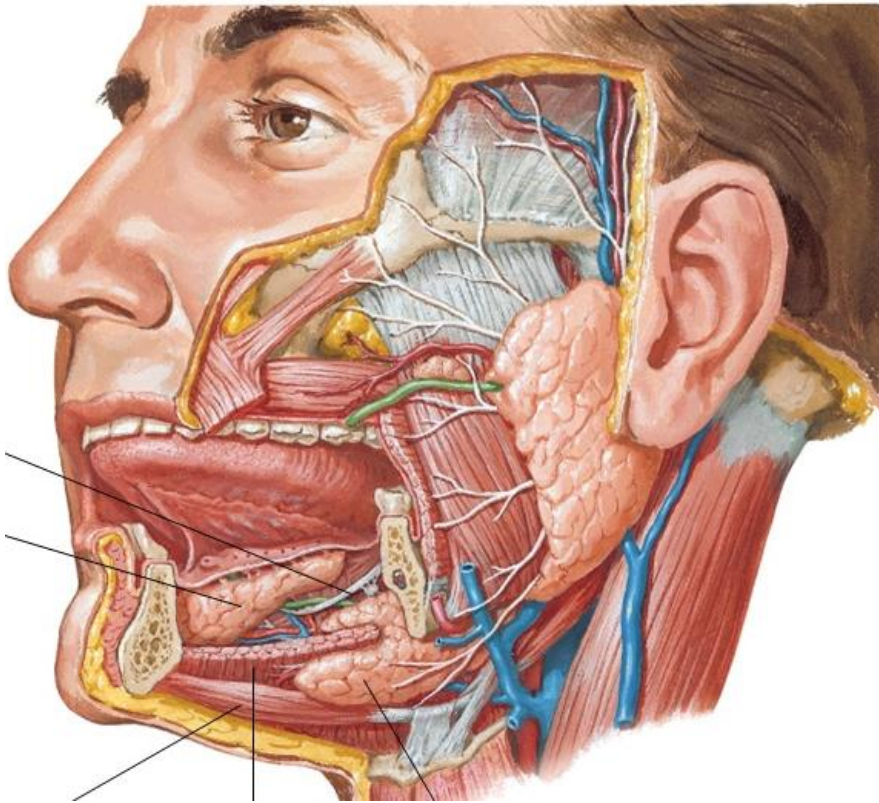
Grenzen:

medial: m. genioglossus
lateral: m. hyoglossus

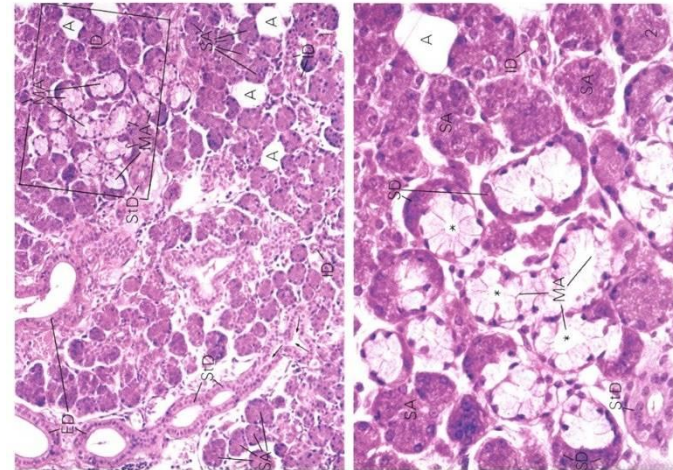
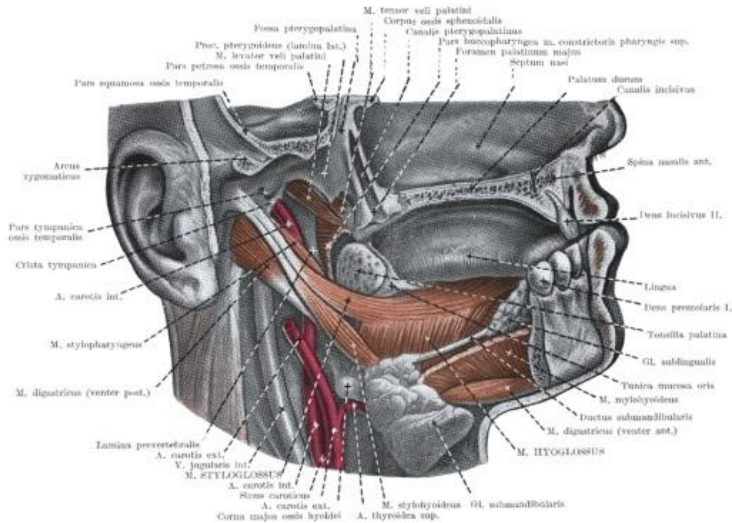
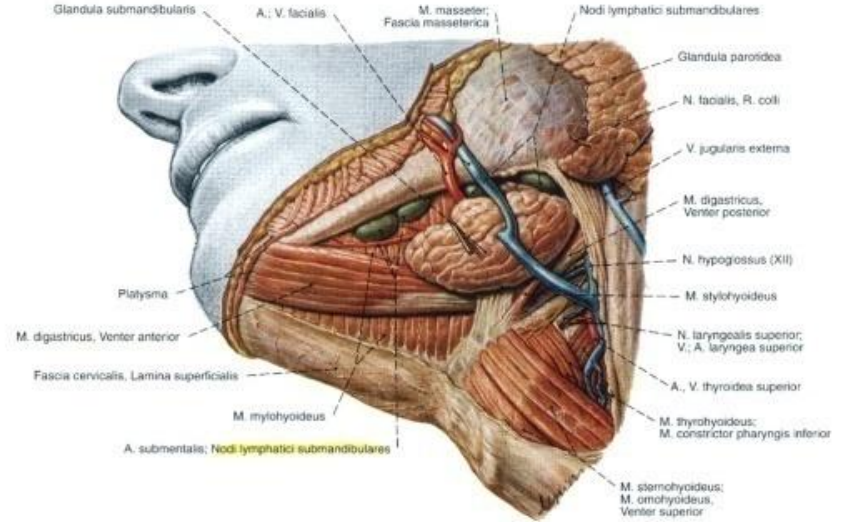
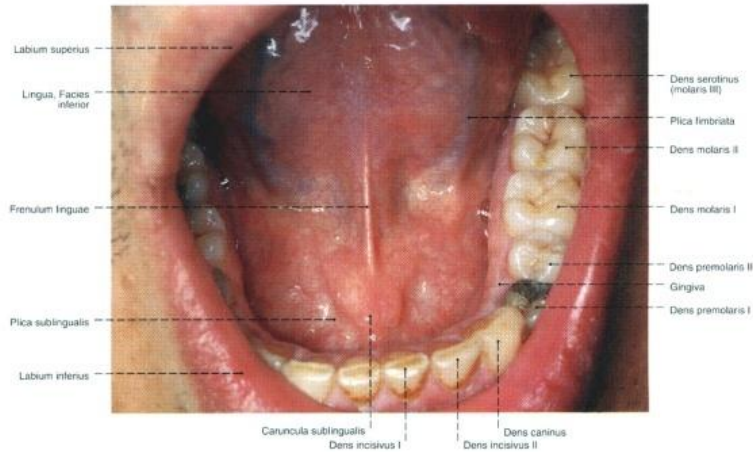
Inhalt: a. lingualis
n. glossopharyngeus



LAGE DER GL. SUBMANDIBULARIS UND DER GL. SUBLINGUALIS



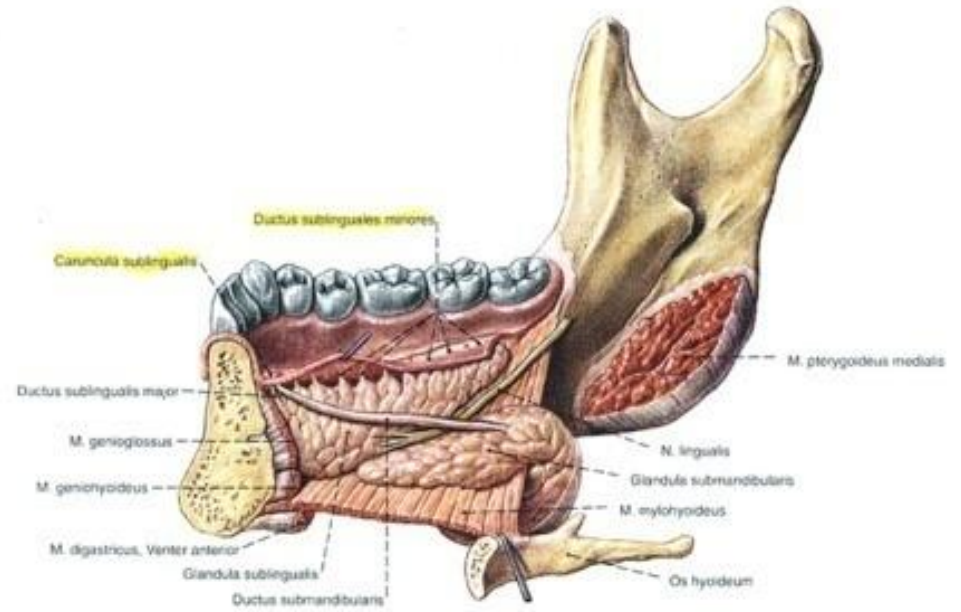
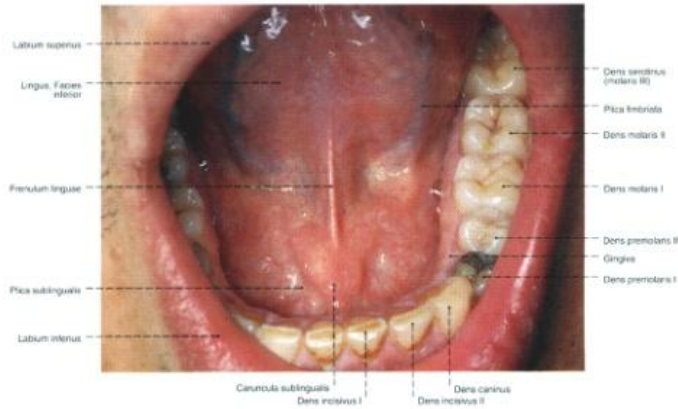
GLANDULA SUBMANDIBULARIS



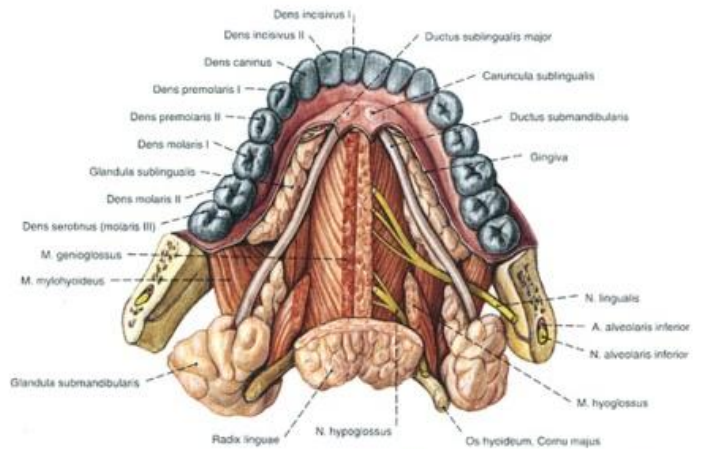
Lappenstruktur, seromukös, komplexe tubuloalveoläre Drüse

2/3 serös 1/3 mukös

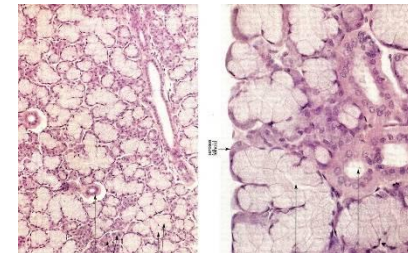
GLANDULA SUBLINGUALIS



Lásd a n. lingualis és a ductus submandibularis szoros topográfiai viszonyát.



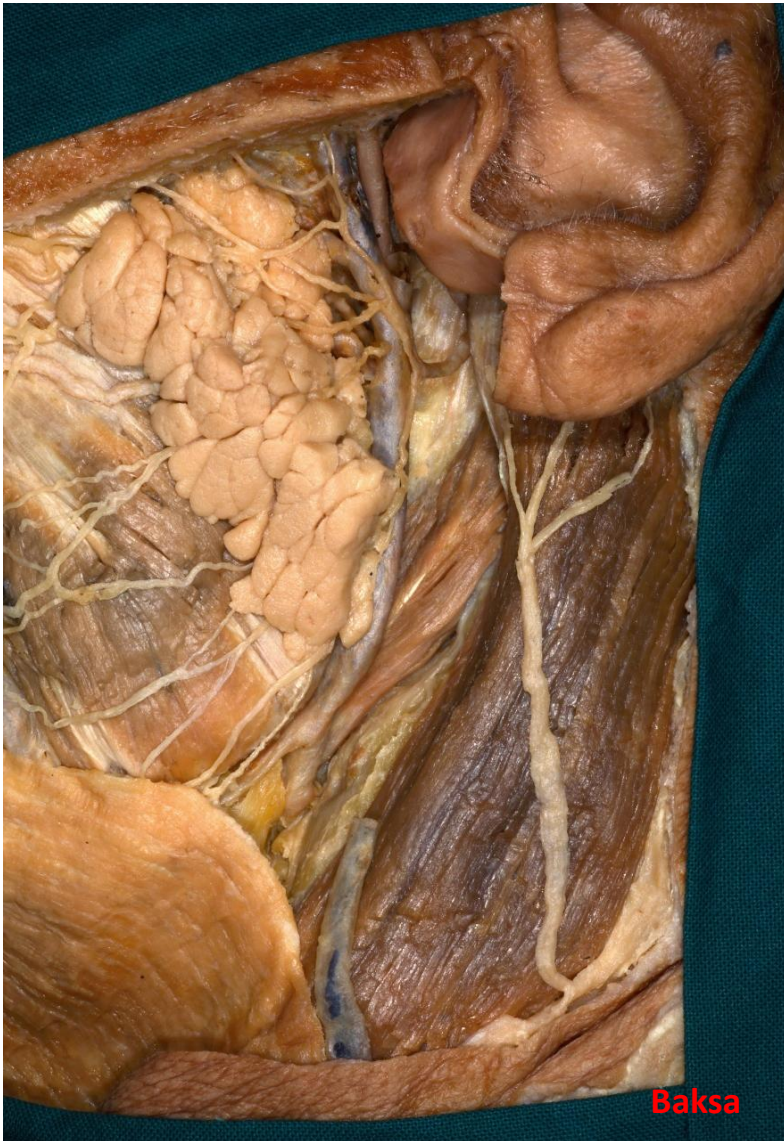
A n. lingualis és ductus submandibularis szoros topográfiai kapcsolata szembetűnő.



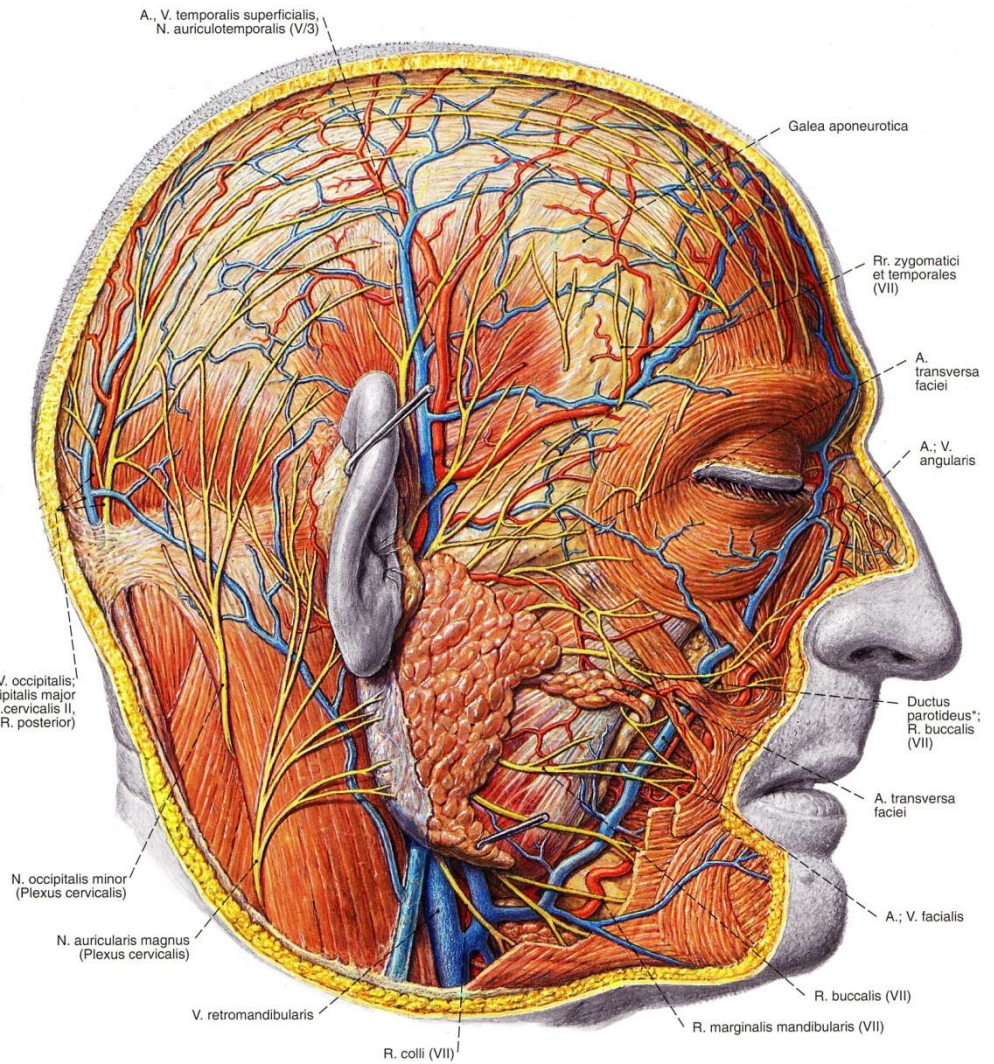
Lappenstruktur, seromukös, komplexe tubuloalveoläre Drüse

1/3 serös (Gianuzzi – Halbmond) 2/3 mukös

PAROTIS



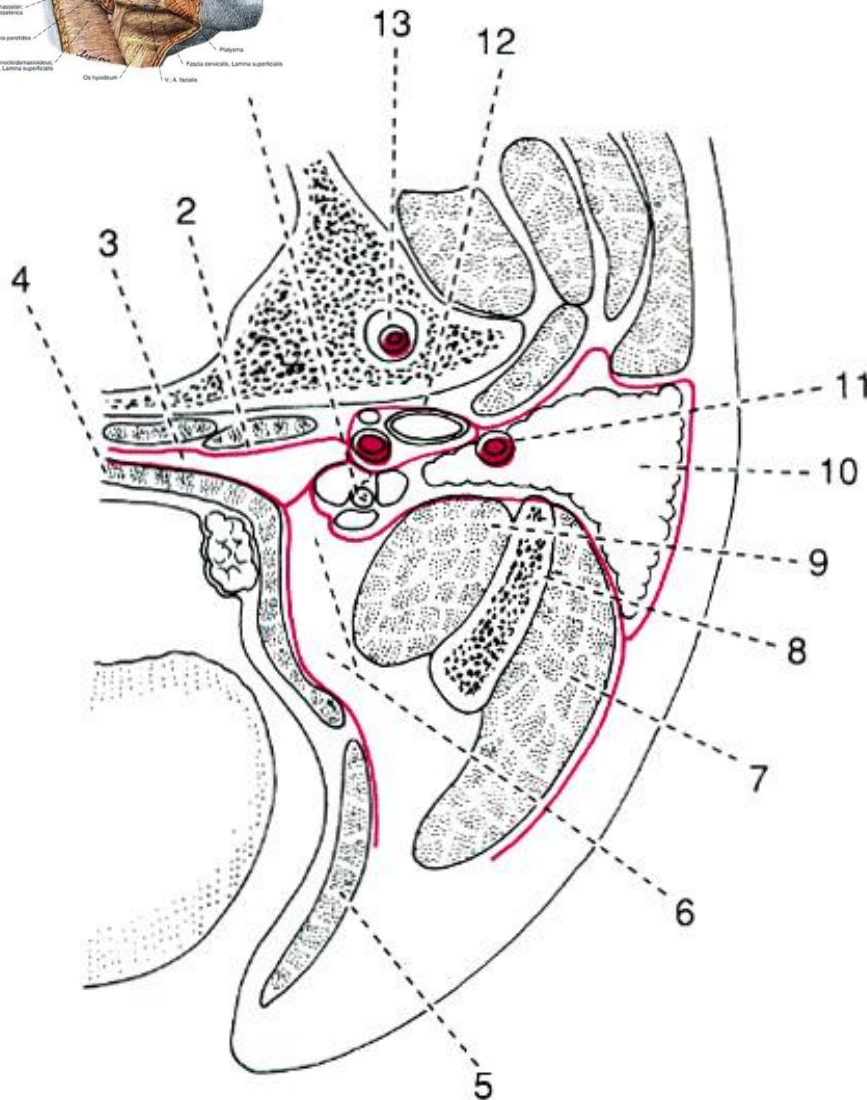
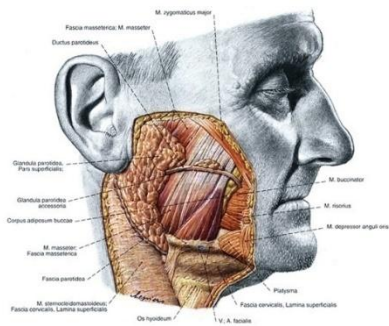
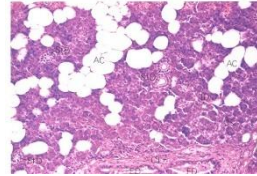
Baksa



Sobotta

PAROTIS

Rein serös, Lappenstruktur,
tubuloalveoläre Drüse



NIDUS PAROTIDEUS

anterior:

m. masseter
ramus mandibulae
m. pterygoideus med.

posterior:

m. sternocleidomastoideus
m. digastricus

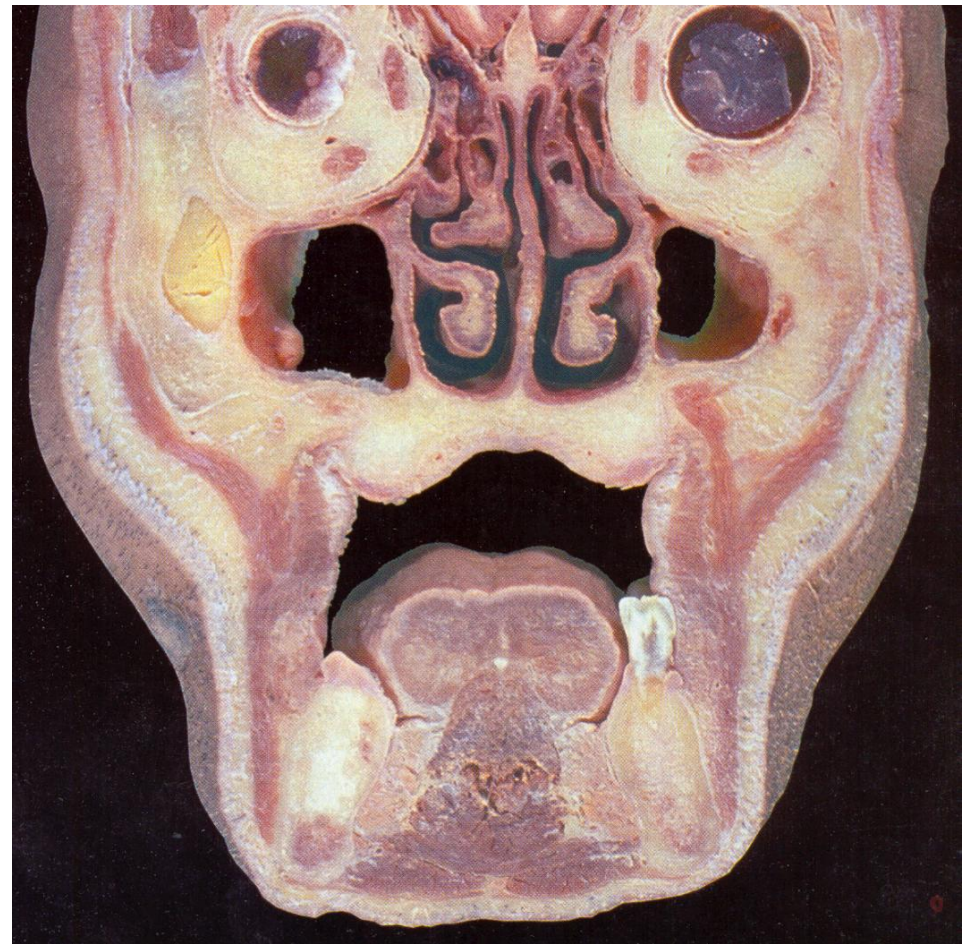
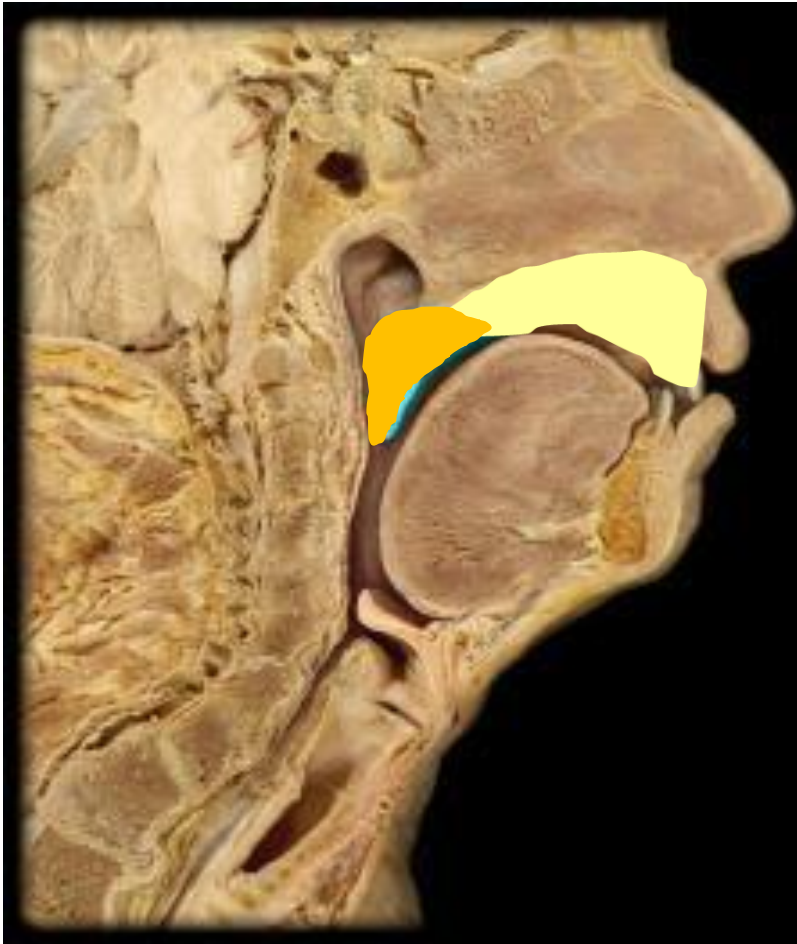
medialis:

m. stylohyoideus
m. stylopharyngeus
m. styloglossus

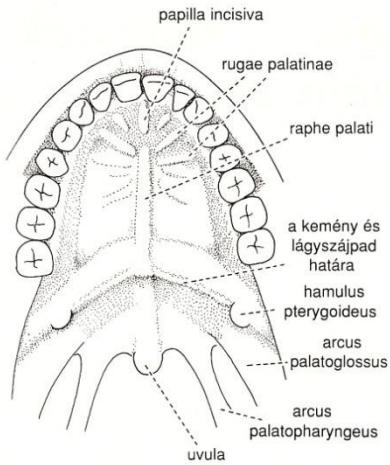
STRUKTUR DES PALATUMS

Palatum molle

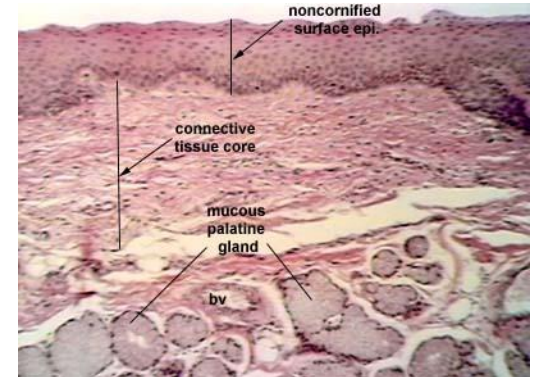
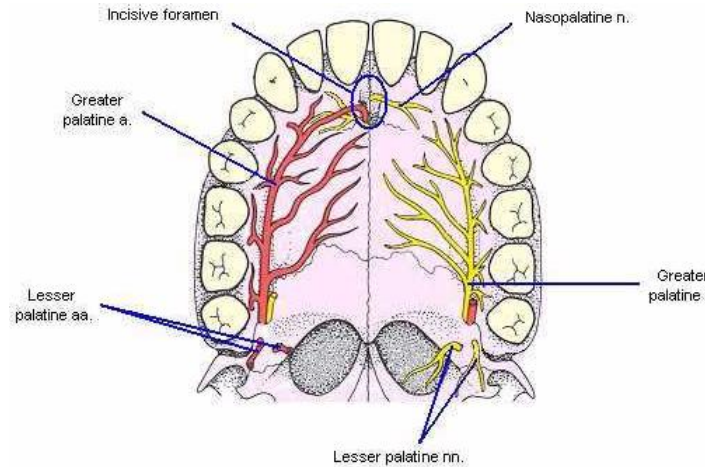
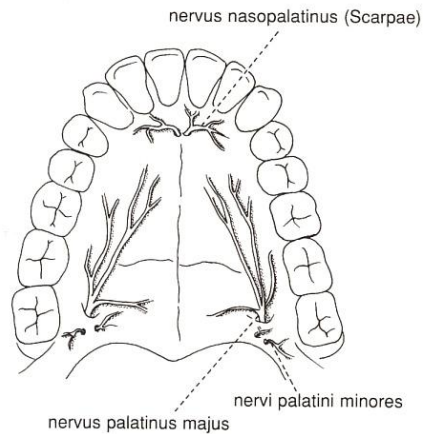
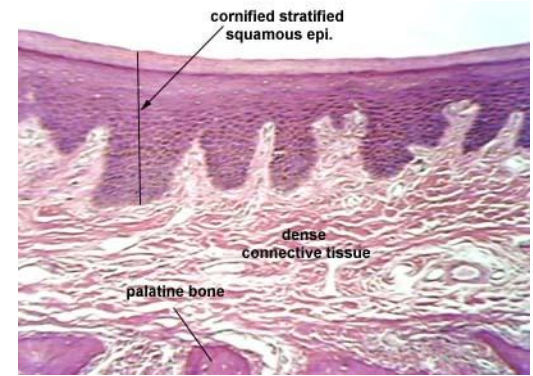
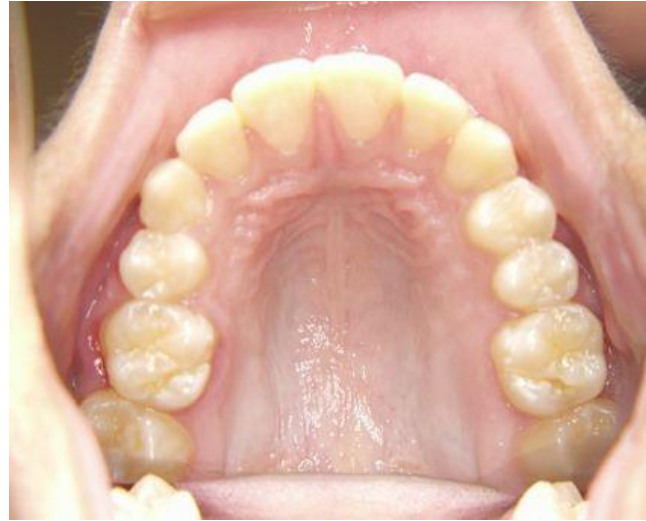Palatum durum



STRUKTUR DES PALATUMS



IV. 1. ábra. A kemény és lágy szájpad képletei



PALATUM MOLLE

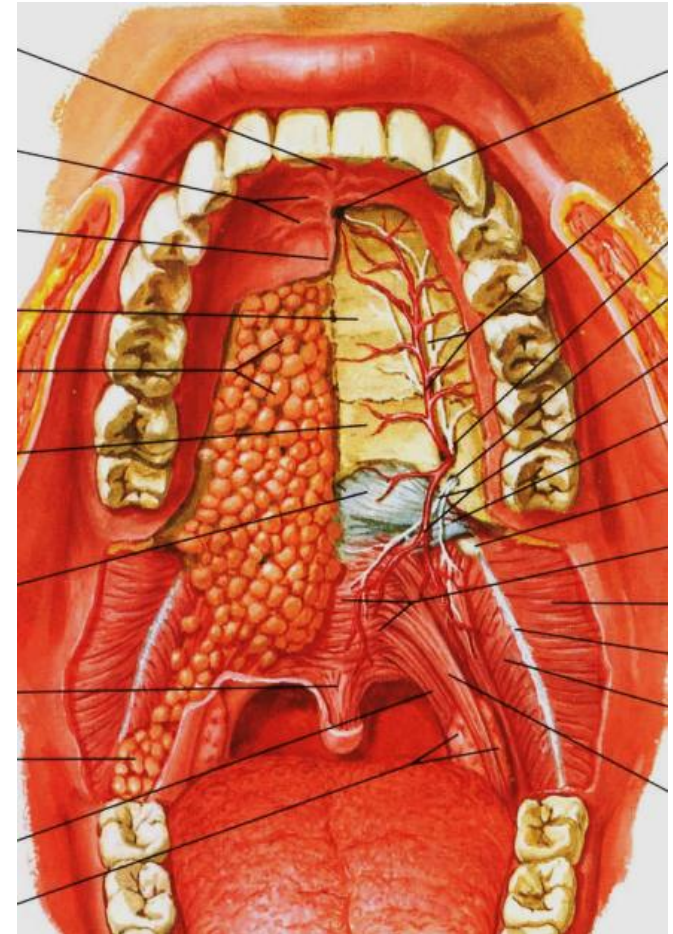
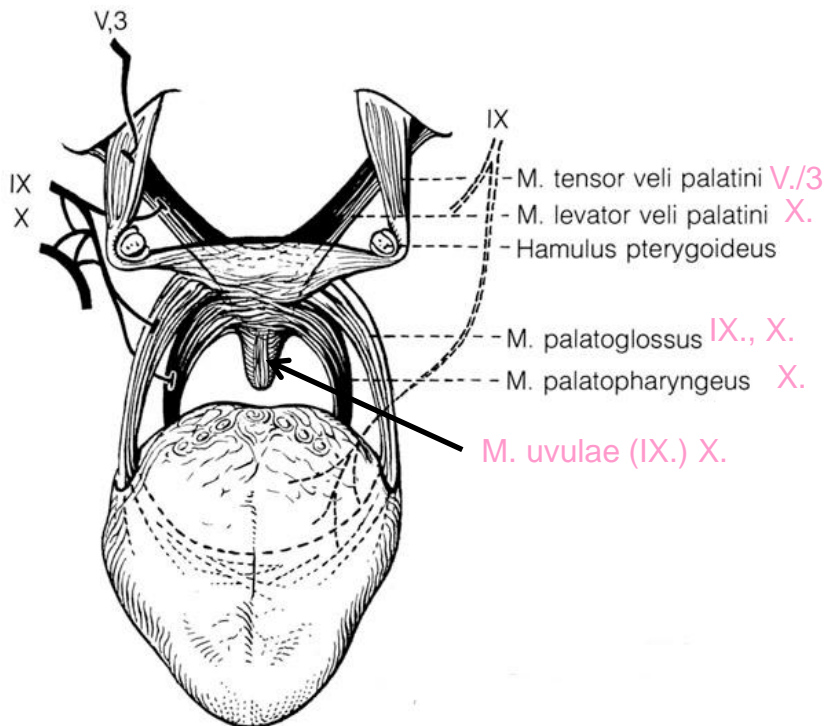
Gerüst: Aponeurosis palatina

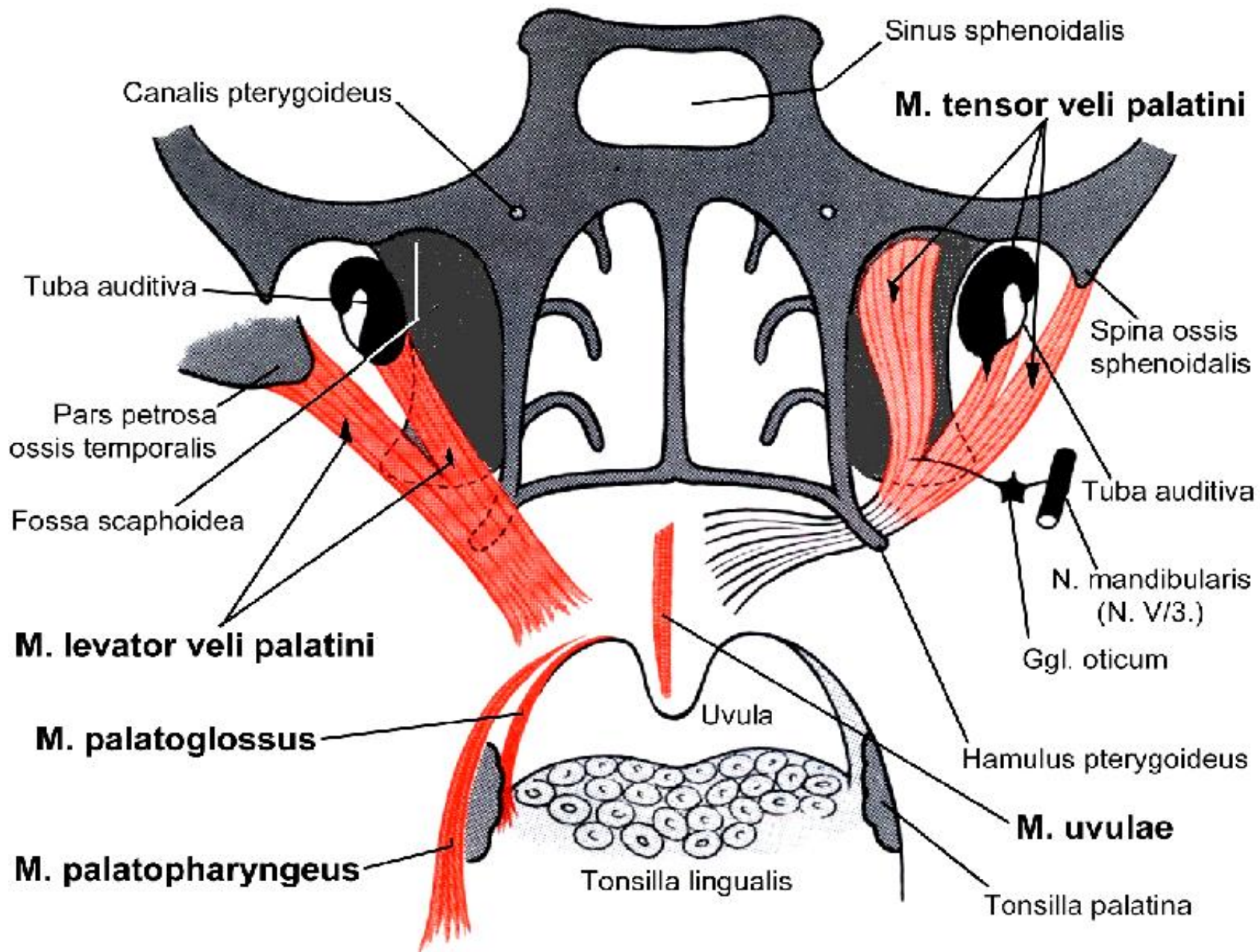
Schleimhaut:

Orale Seite: mehrsch. unverh. Plattenepithel

Nasale Seite: mehrreihiges Flimmerepithel

Mit Submucosa (Fett, Gll. palatinae)





	Ursprung	Ansatz	Funktion	Innervation
<i>M. levator veli palatini</i>	Unterseite des Pars petrosa, Cartilago Tubae auditivae	Aponeurosis palatina	Spannt und hebt das Velum, öffnet die Tuba, schließt den Nasopharynx	R. pharyngeus nervi vagi (X.)
<i>M. tensor veli palatini</i>	Lamina med. Proc. pterygoidei, Fossa scaphoidea, Ala major, Lam. membranacea tubae Um den Hamulus pter.	Aponeurosis palatina	Spannt und verformt das Velum öffnet die Tuba	N. musculi tensoris veli palatini (ex V/3)
<i>M. palatopharyngeus</i>	Aponeurosis palati, Hamulus pter., Lamina med. proc. pter.	Seitl. Rachenwand bis zur Raphe	Schlundheber, Grundlage für Arcus palatopharyngeus	N. glosso-pharyngeus (IX.)
<i>M. palatoglossus</i>	Abspaltung aus dem M. transversus linguae	Aponeurosis palatina	Senkt das Velum, schließt die Schlundenge, zieht den hinteren Teil der Zunge hoch, Grundlage für Arcus palatoglossus	Rr. pharyngei (ex IX., ggf. X.)
<i>M. uvulae</i>	Aponeurosis palatina	Schleimhaut an der Uvulaspitze	Verkürzt die Uvula	Rr. Pharyngei (ex X., ggf. IX.)

PALATUM MOLLE - GEFÄSSE UND NERVEN

Arterien:

- A. palatina ascendens (A. facialis)
- A. palatina descendens (A. maxillaris)
- A. pharyngea ascendens

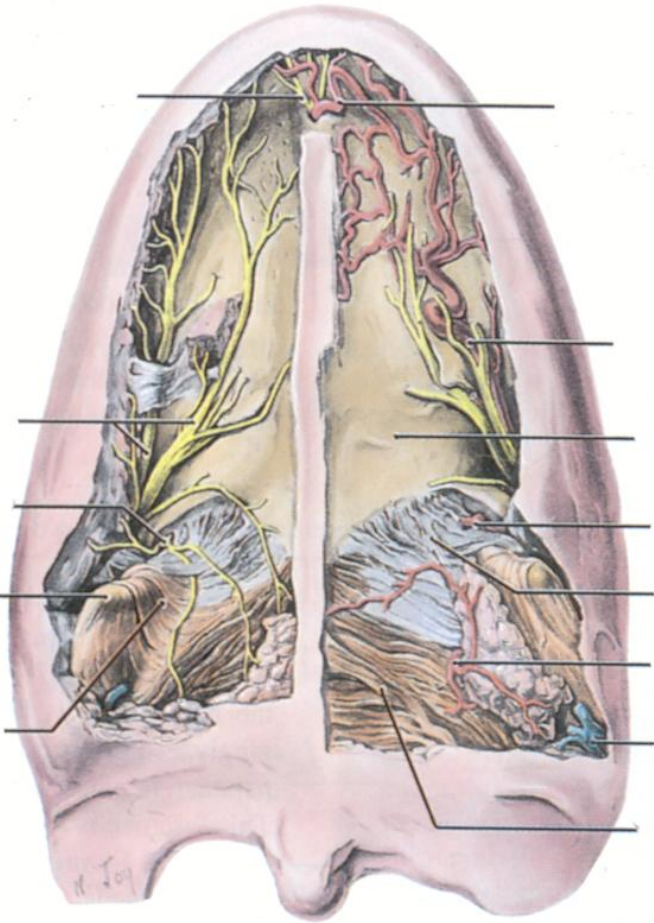
Venen:

- Plexus pterygoideus
- V. facialis, V. jugularis interna

Nerven:

- Somatomot.:* Plexus phar. (IX, X, auch V/3)
- Secretomot.:* Nn. palatini (Ggl. pterygop.)
- Somatosensibel:* Nn. palatini (maj., min.)
 - N. nasopalatinus (V/2)
- Geschmack:* Nn. palatinus major (VII)

Lymphknoten: Nn. ly. submandibulares

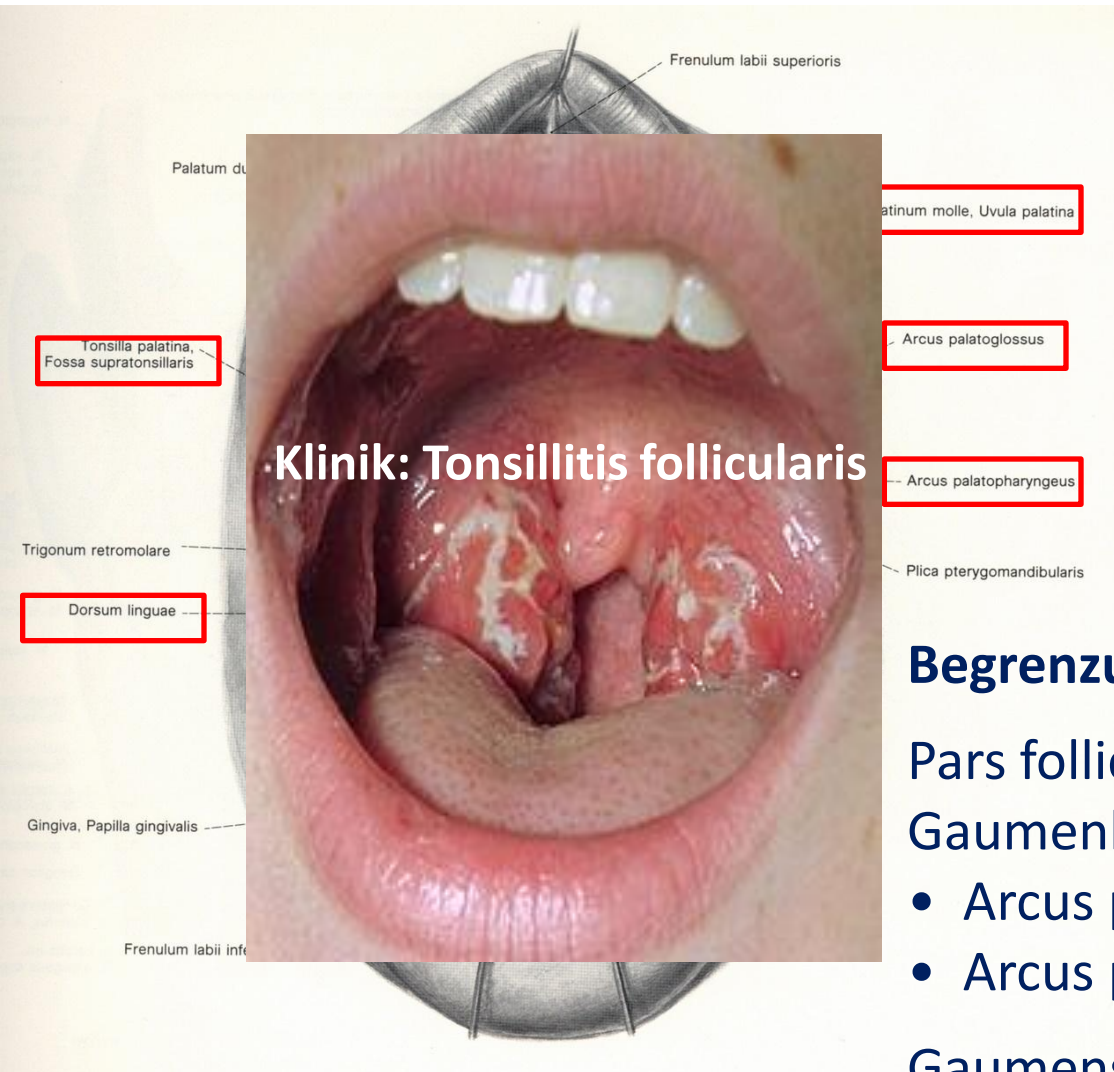


ISTHMUS FAUCIUM = SCHLUNDENGE

Übergang zwischen Mundhöhle und Rachen

Blutversorgung der Tonsilla palatina:

- A. palatina ascendens
- A. pharyngea ascendens
- Rr. tonsillares der A. lingualis
- A. palatina descendens
- Nn.Ly. submandibulares



Klinik: Tonsillitis follicularis

Begrenzung:

Pars follicularis linguae (**Tonsilla lingualis**)

Gaumenbögen:

- Arcus palatoglossus
 - Arcus palatopharyngeus
- } Fossa Tonsillaris + Tonsilla palatina

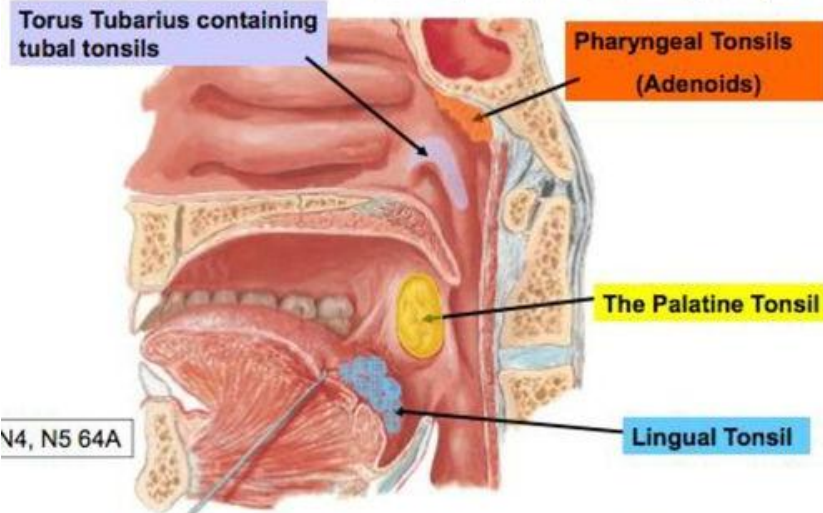
Gaumensegel: Velum palatinum mit Uvula

WALDEYERSCHER LYMPHATISCHER RACHENRING

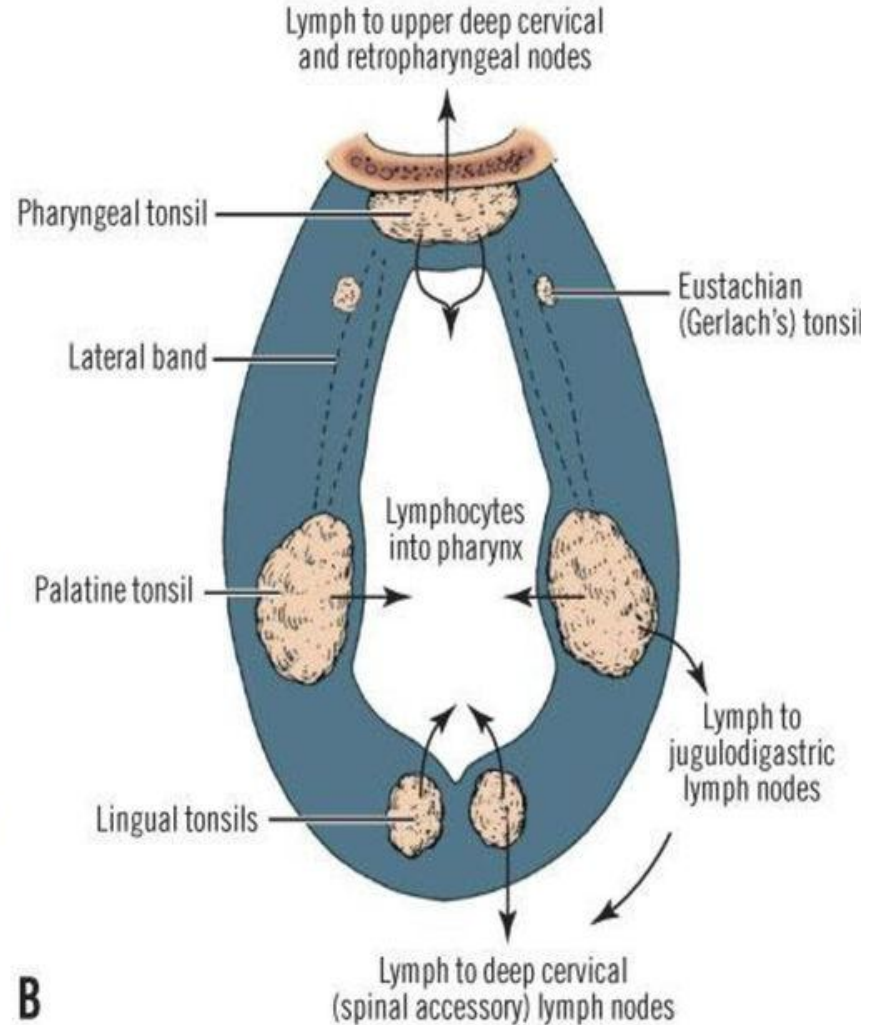
Tonsillen in der Gegend des Isthmus faucium:

- Tonsilla palatina
- Tonsillae linguales
- Tonsilla pharyngea
- Tonsillae tubariae

Tonsillar Tissue in the Nasopharynx & Oropharynx

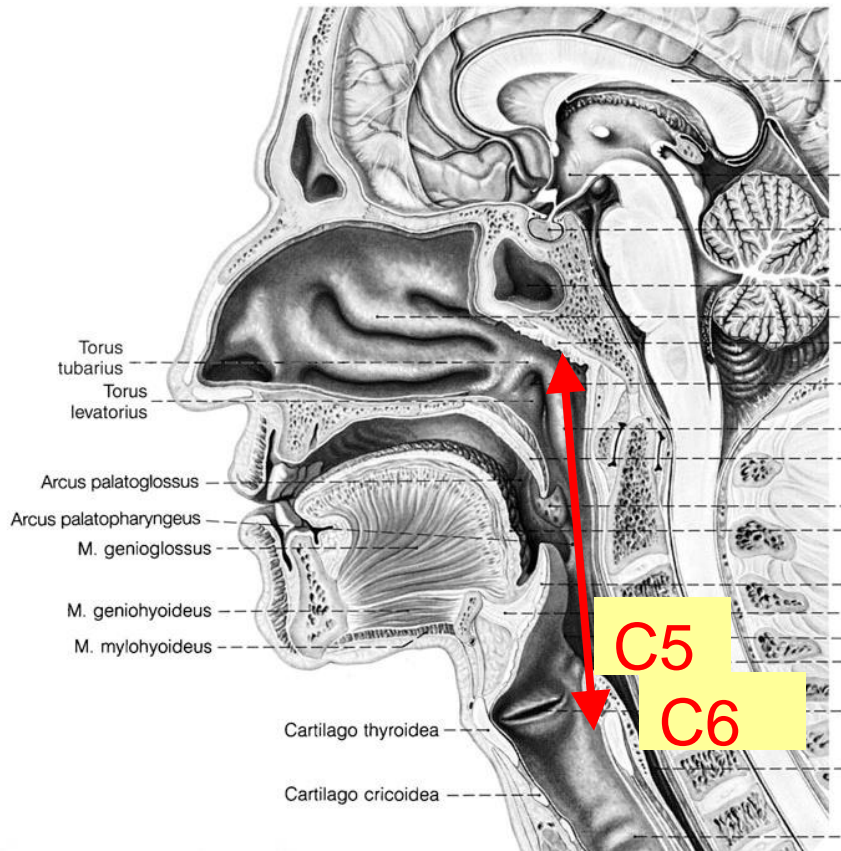


A circular "ring" of lymphoid tissue guards the entrance to the nasopharynx and oropharynx – the tonsillar ring (Waldeyer)



Copyright ©2006 by The McGraw-Hill Companies, Inc. All rights reserved.

PHARYNX



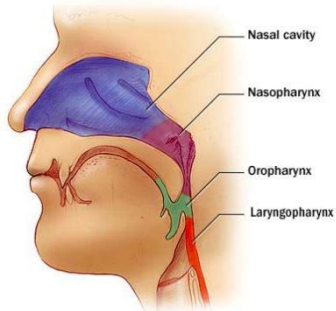
~ 13 cm

- Fibro-muskulöser Schlauch, vorne offen
- Schädelbasis- C5/6
- Kreuzung der Luft- und Speisewege
- Einzelne Geschmacksknospen
- *Immunabwehr: lymphatischer Rachenring *****

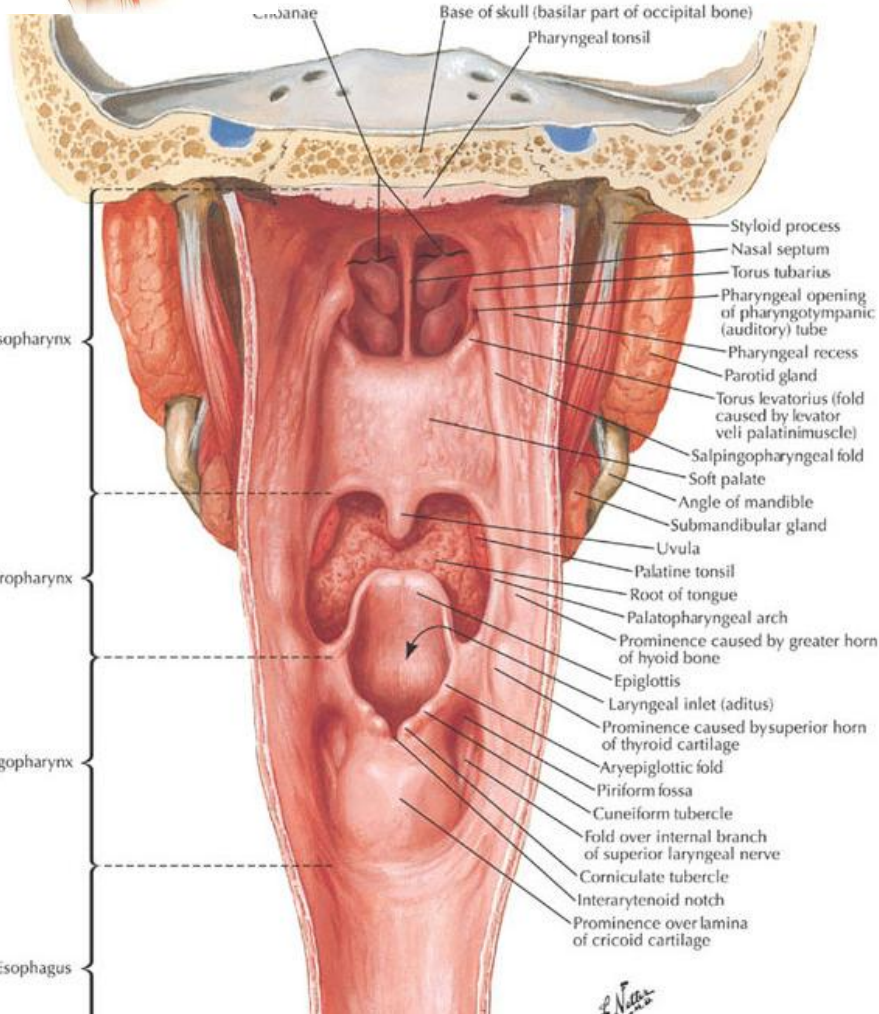
3 Etagen:

- 1 Epipharynx (Nasopharynx)
- 2 Mesopharynx (Oropharynx)
- 3 Hypopharynx (Laryngopharynx)

PHARYNX - EINTEILUNG



Pharynx: Opened Posterior View



Pars nasalis pharyngis epipharynx

- choanae nasi
- ostium pharyngeum tubae auditivae, torus tubarius
- plica salpingopalatina et salpingopharyngea

- 2 x tonsilla tubaria ****

- 1 x tonsilla pharyngea ****

Pars oralis pharyngis mesopharynx

- isthmus faucium, plica glossoepiglottica mediana, vallecula epiglottica
- plica glossoepiglottica lateralis

Pars laryngea pharyngis hypopharynx

- aditus laryngis
- recessus piriformis → oesophagus

PHARYNX - MUSKELN

MUSCULI LEVATORES PHARYNGIS

(Rachenhebern)

M. stylopharyngeus – proc. styloideus (os temporale)

M. salpingopharyngeus – tuba aud., proc. pterygoideus lamina medialis

M. palatopharyngeus – velum palatinum

MUSCULI CONSTRICTORES PHARYNGIS

(Rachenschnürern):

M. constrictor pharyngis superior

pars pterygopharyngea

pars buccopharyngea

pars mylopharyngea

pars glossopharyngea

M. constrictor pharyngis medius

pars chondropharyngea

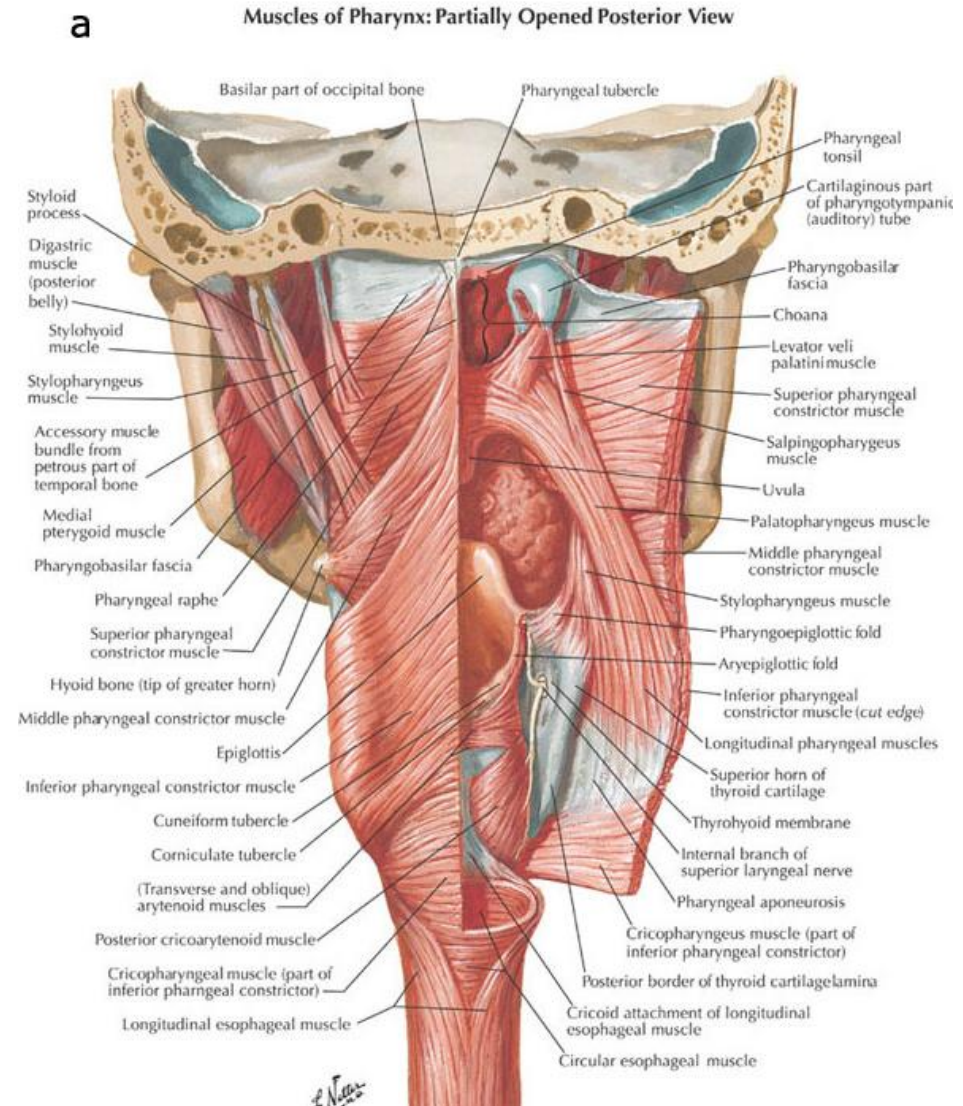
pars ceratopharyngea

M. constrictor pharyngis inferior

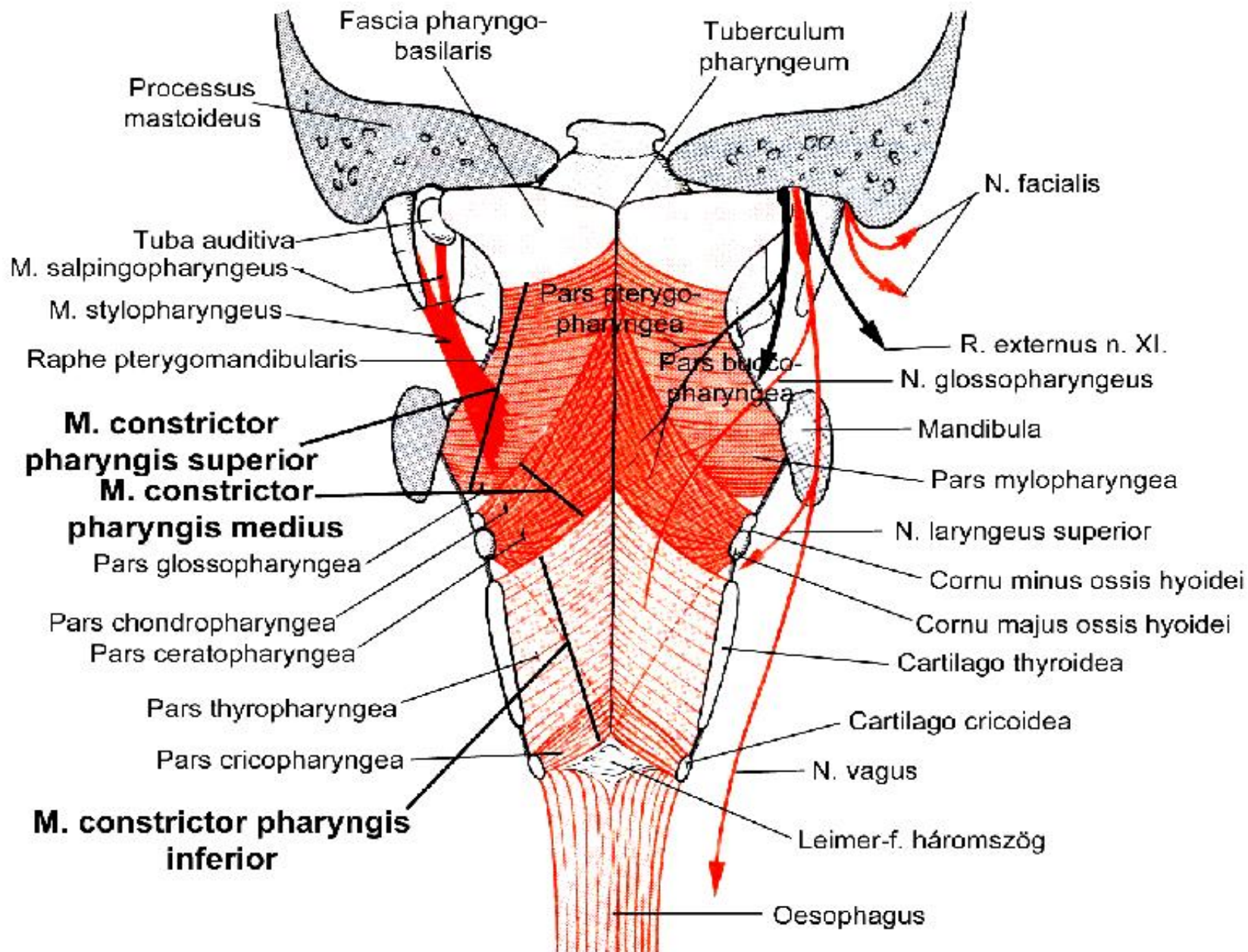
pars thyropharyngea

pars cricopharyngea = oberer

Oesophagussphincter



PHARYNX - MUSKELN



PHARYNX - GEFÄSSE UND NERVEN

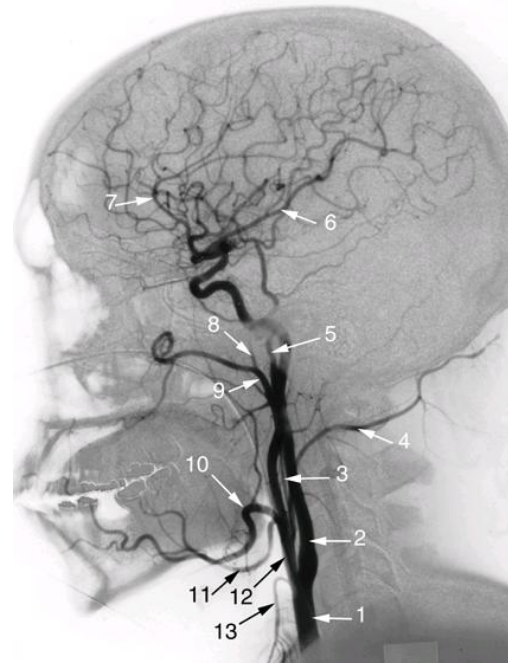
GEFÄSSE

- a. pharyngea ascendens (ACE)
- r. tonsillaris (a. facialis)
- r. palatinus asc. (a. facialis)
- a. palatina desc. (a. maxillaris)
- r. pharyngeus (a. maxillaris)
- r. pharyngeus (a. thyroidea sup.)
- r. pharyngeus (a. thyroidea inf.)

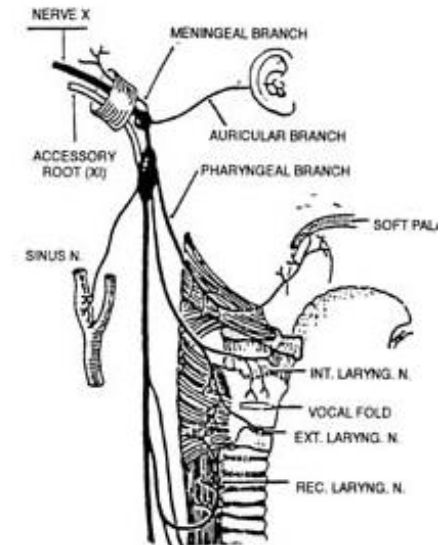
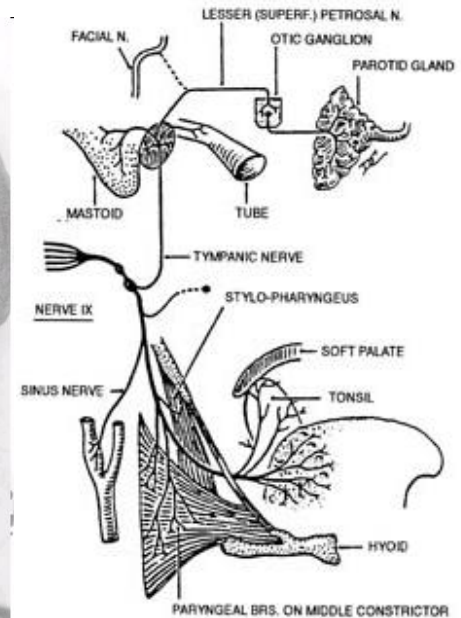
plexus venosus pterygoideus et
plexus venosus pharyngeus
(→ v. jugularis interna)

NERVEN

- n. glossopharyngeus (IX.) obere Hälfte vom Rachen (motorisch)
- n. vagus (X.) → untere Hälfte vom Rachen (sensorisch und motorisch)
- truncus sympathicus (ggl. cerv. sup.)



1. Common Carotid Artery.
2. Internal Carotid Artery.
3. Ascending pharyngeal Artery.
4. Occipital Artery.
5. Superficial Temporal Artery.
6. Middle cerebral Artery.
7. Anterior cerebral Artery.
8. Middle meningeal Artery.
9. Maxillary artery.
10. Facial artery.
11. Lingual artery.
12. External carotid artery.
13. Superior thyroid artery.



PARA- UND RETROPHARYNGEALE RAUME

SPATIUM RETROPHARYNGEUM

GRENZEN: hintere Rachenwand + lamina prevertebralis (alaris)
 – die vagina carotica auf beiden Seiten ist direkt mit dem mediastinum posterius verbunden

SPATIUM PARAPHARYNGEUM ET SPATIUM PARATONSILLARE

GRENZEN: BGW/fascia um den m. stylopharyngeus u. die *vagina carotica* separiert es vom spatium retropharyngeum

Nach medial : Rachenwand

(die Arterien der T palatina durchbohren die Wand),

Hinten: STYLOMUSKELN (U. auf dem proc. Styloideus)

m. stylopharyngeus + m. stylohyoideus + m. styloglossus

Seitlich : m. pterygoideus medialis

Vorne : corpus adiposum buccae (Bichat)

INHALT

vv. pharyngeae = plexus venosus pharyngeus

Truncus sympathicus

N. hypoglossus (XII.)

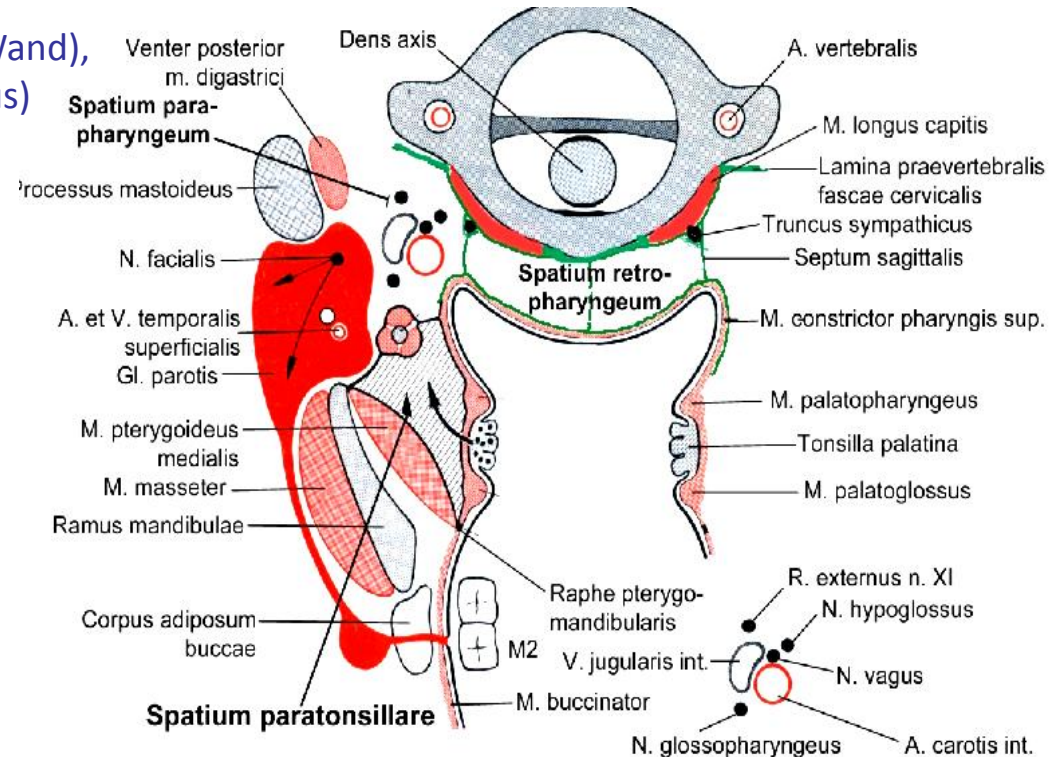
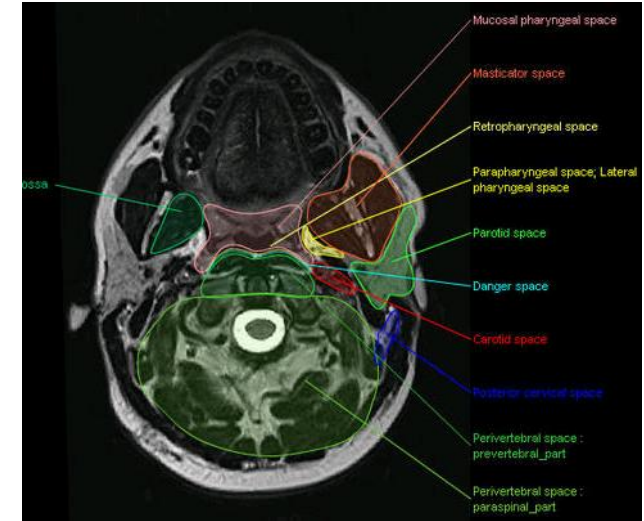
N. glossopharyngeus (IX.)

a. carotis interna

v. jugularis interna

N. vagus (X.)

} *vagina carotica*





DANKE SCHÖN FÜR IHRE AUFMERKSAMKEIT!



LITERATUR

Drake: Gray's Anatomy for Students, 2nd ed.

Sobotta Atlas of Human Anatomy

Kenhub.com

Folien von Dr. Cs. Dávid, Dr. O. Kántor, Dr. S. Katz