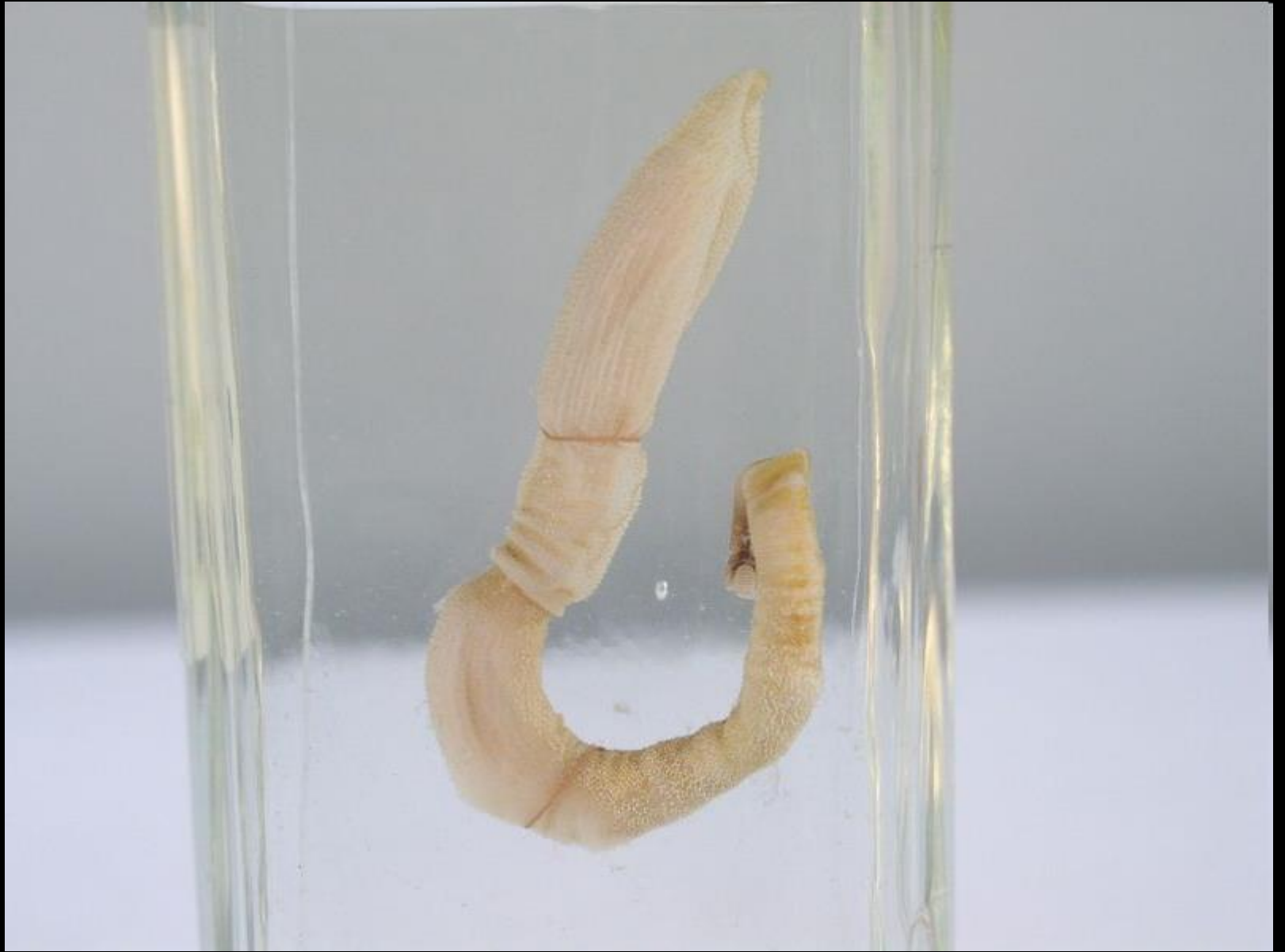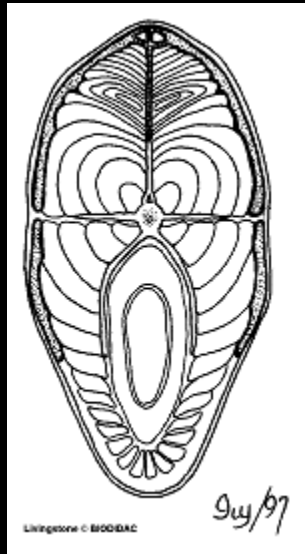



A HASFAL SZERKEZETE, RECTUS-HÜVELY

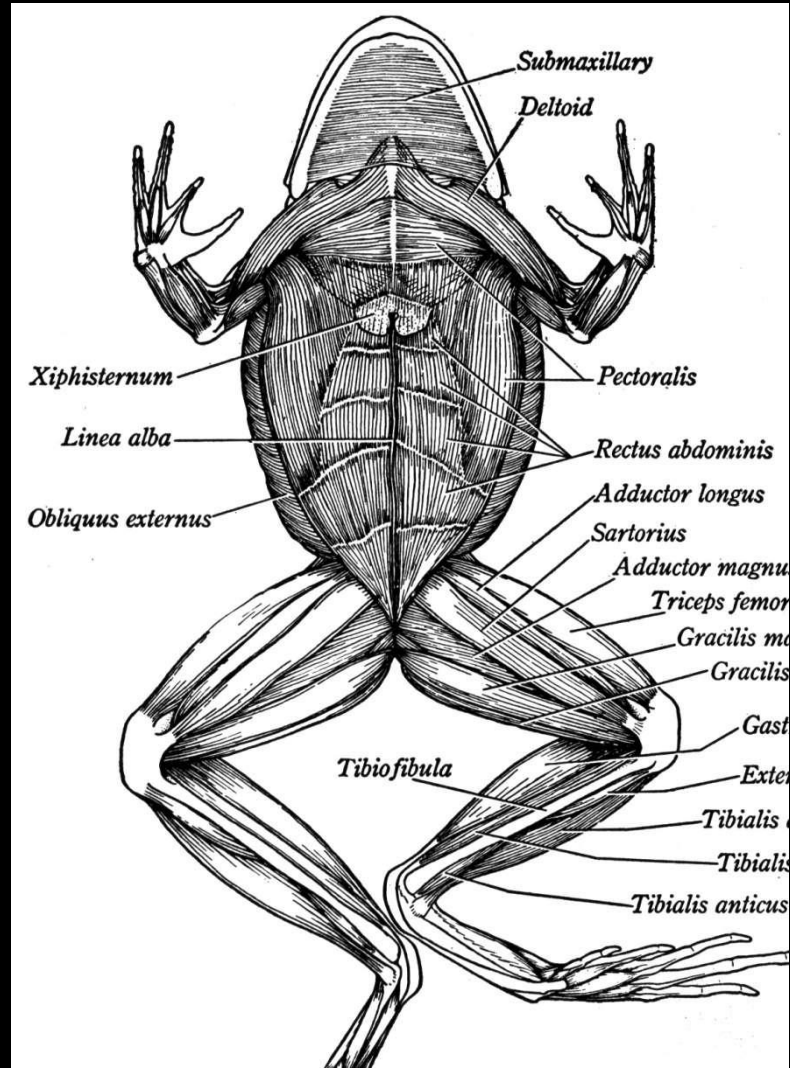
Barna János



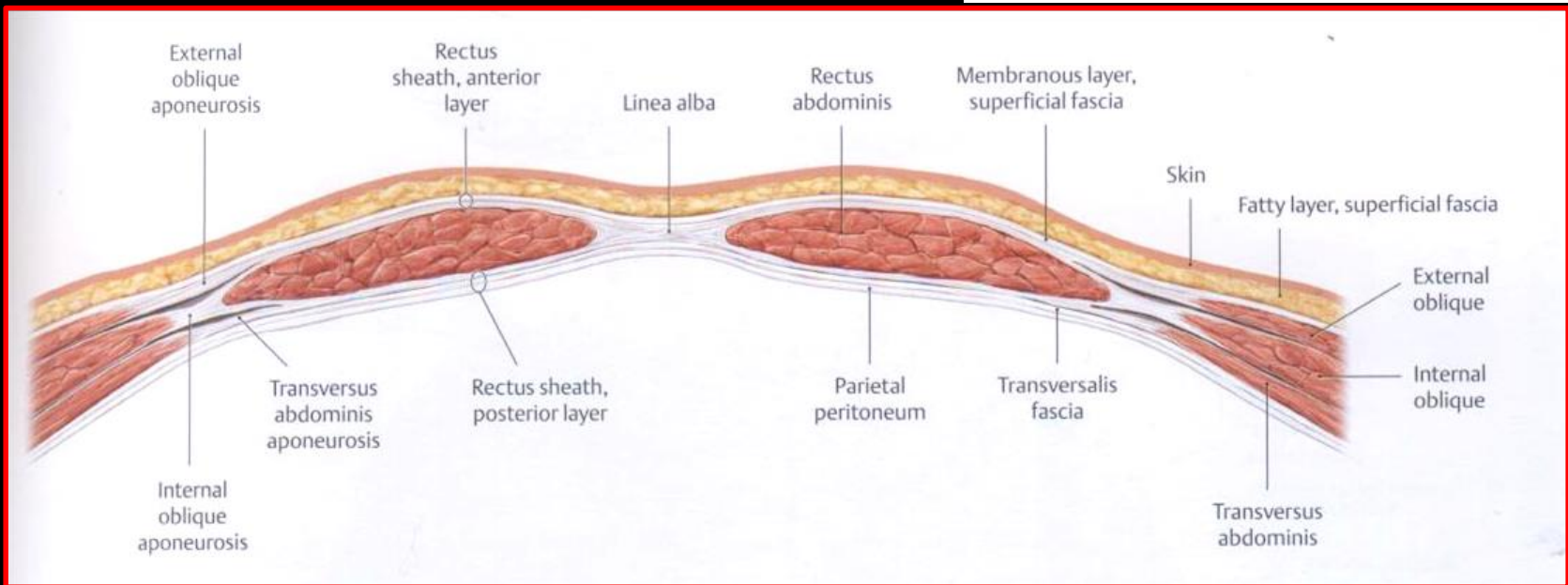
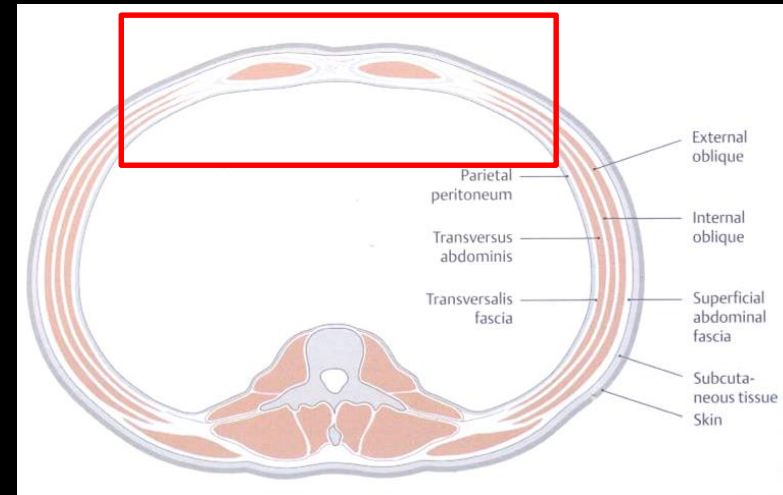


A törzs izmai

hasizmok




A hasfal szerkezete



A hasfal szerkezete



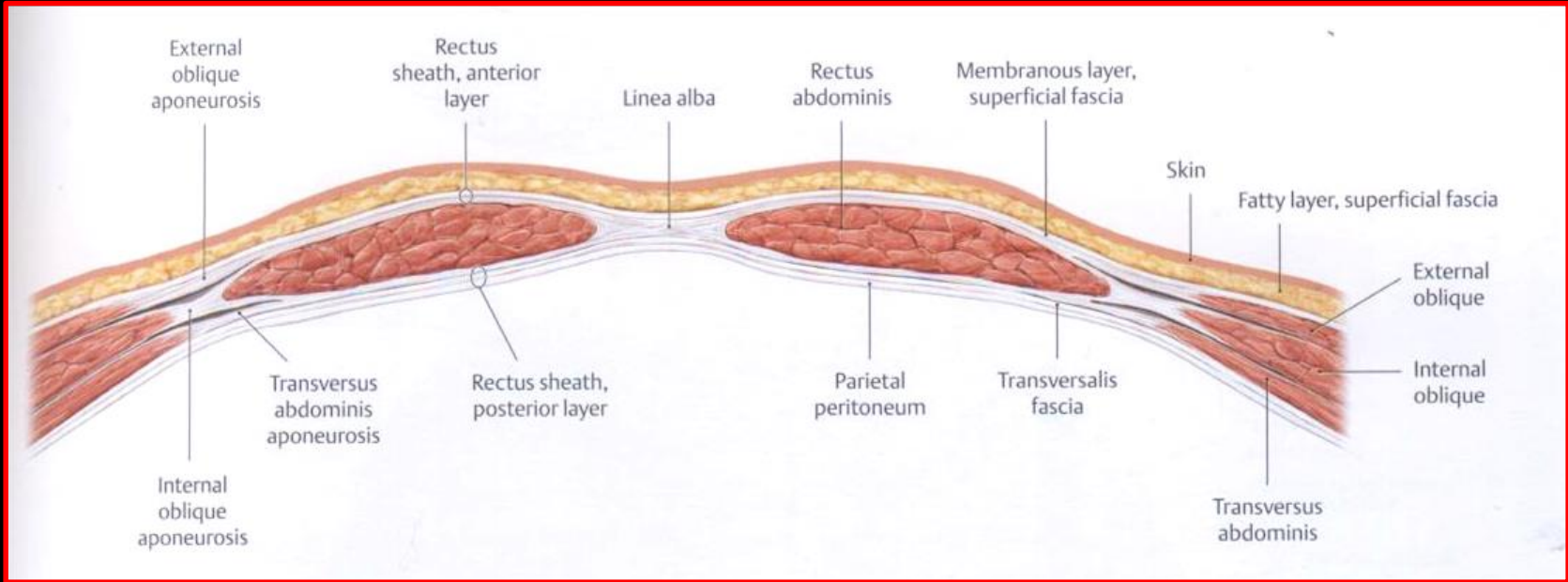
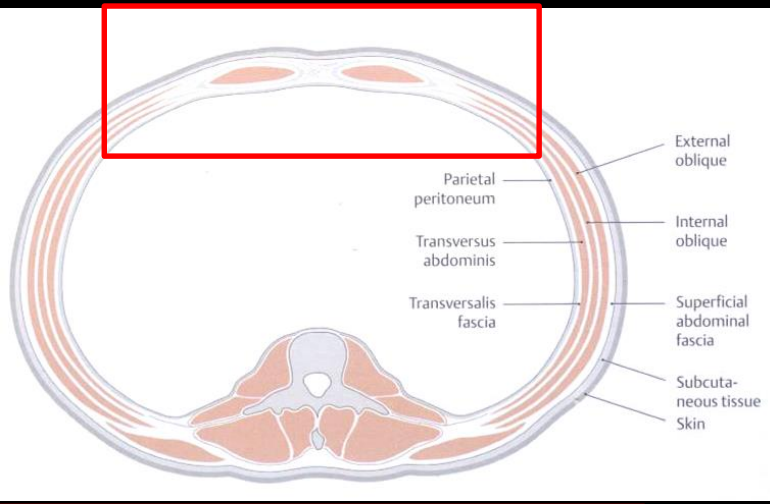
Anorexia nervosa

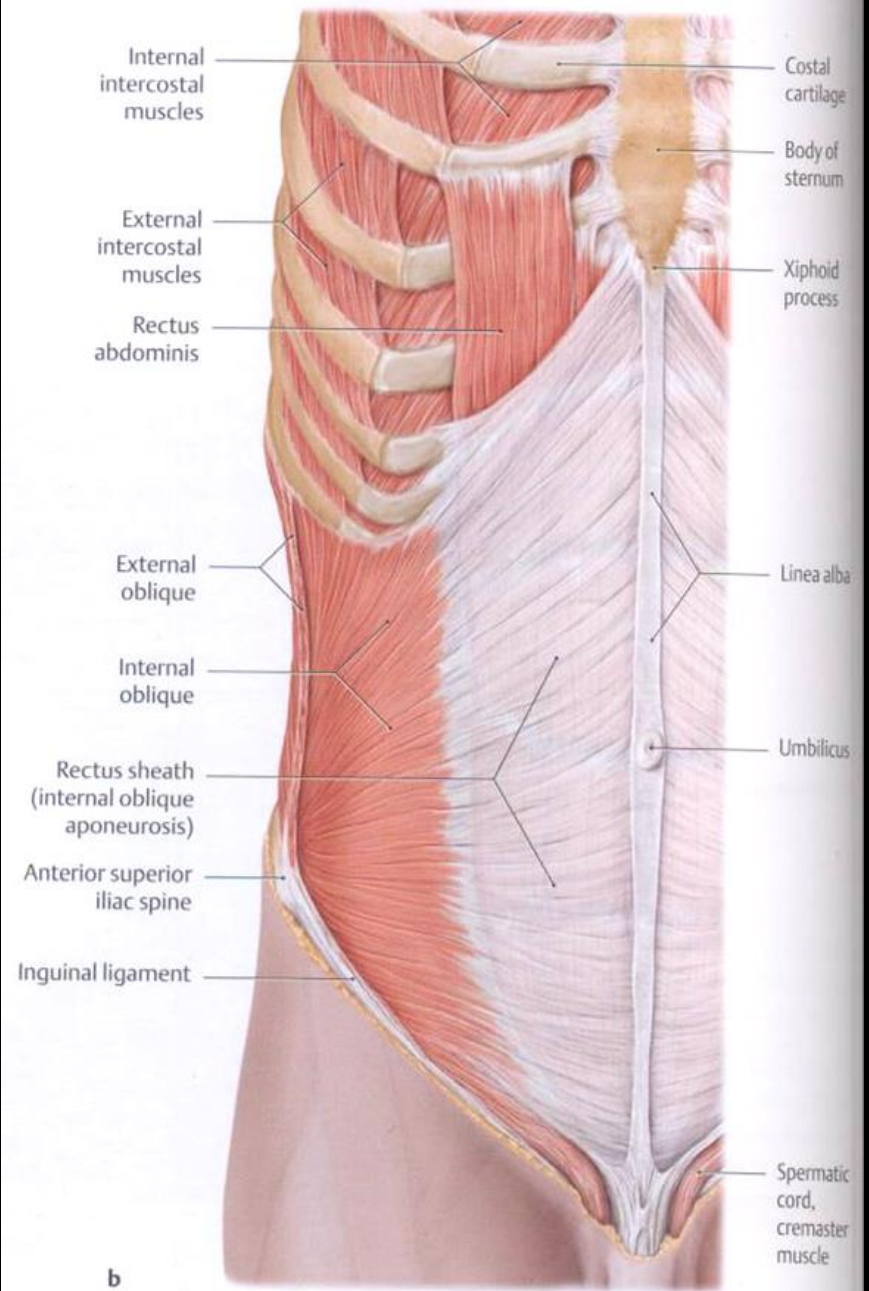
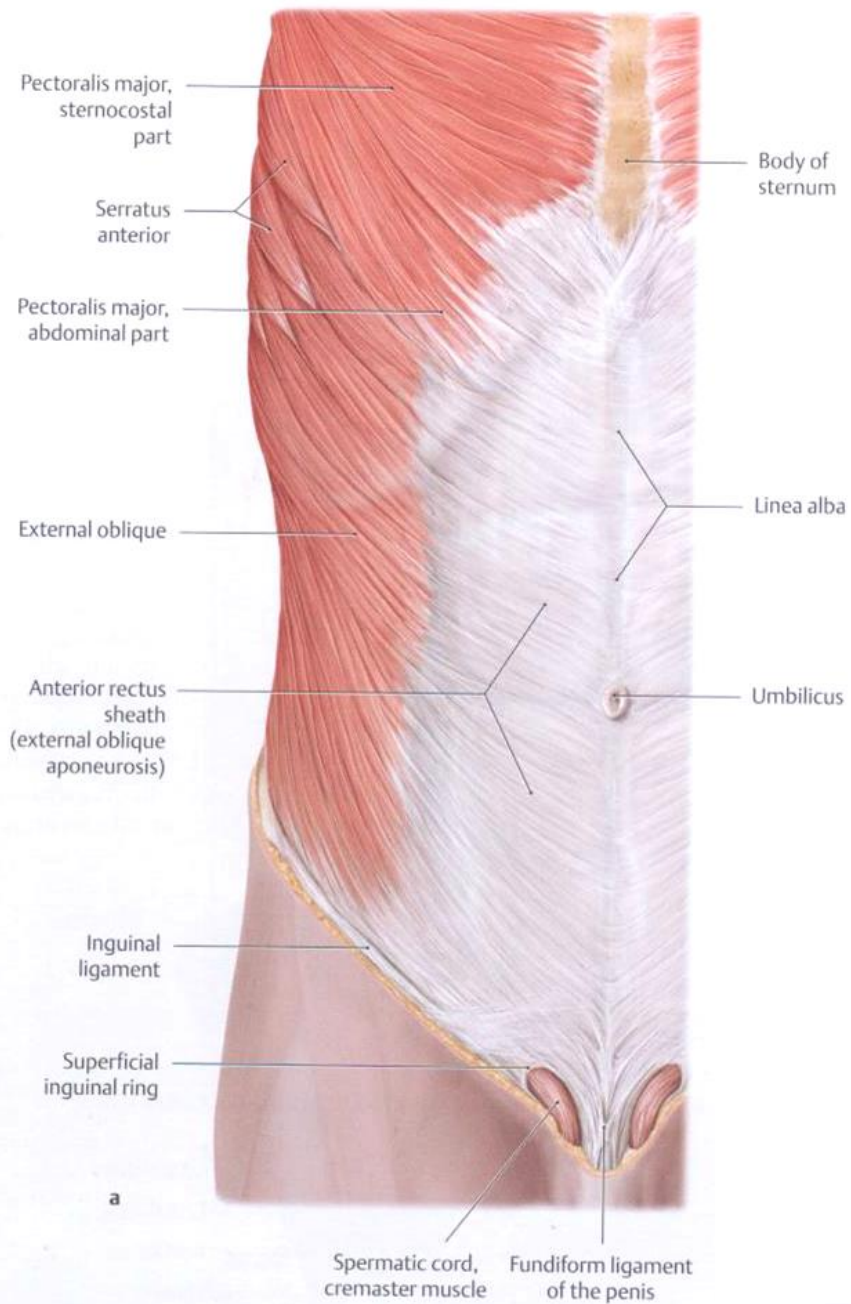


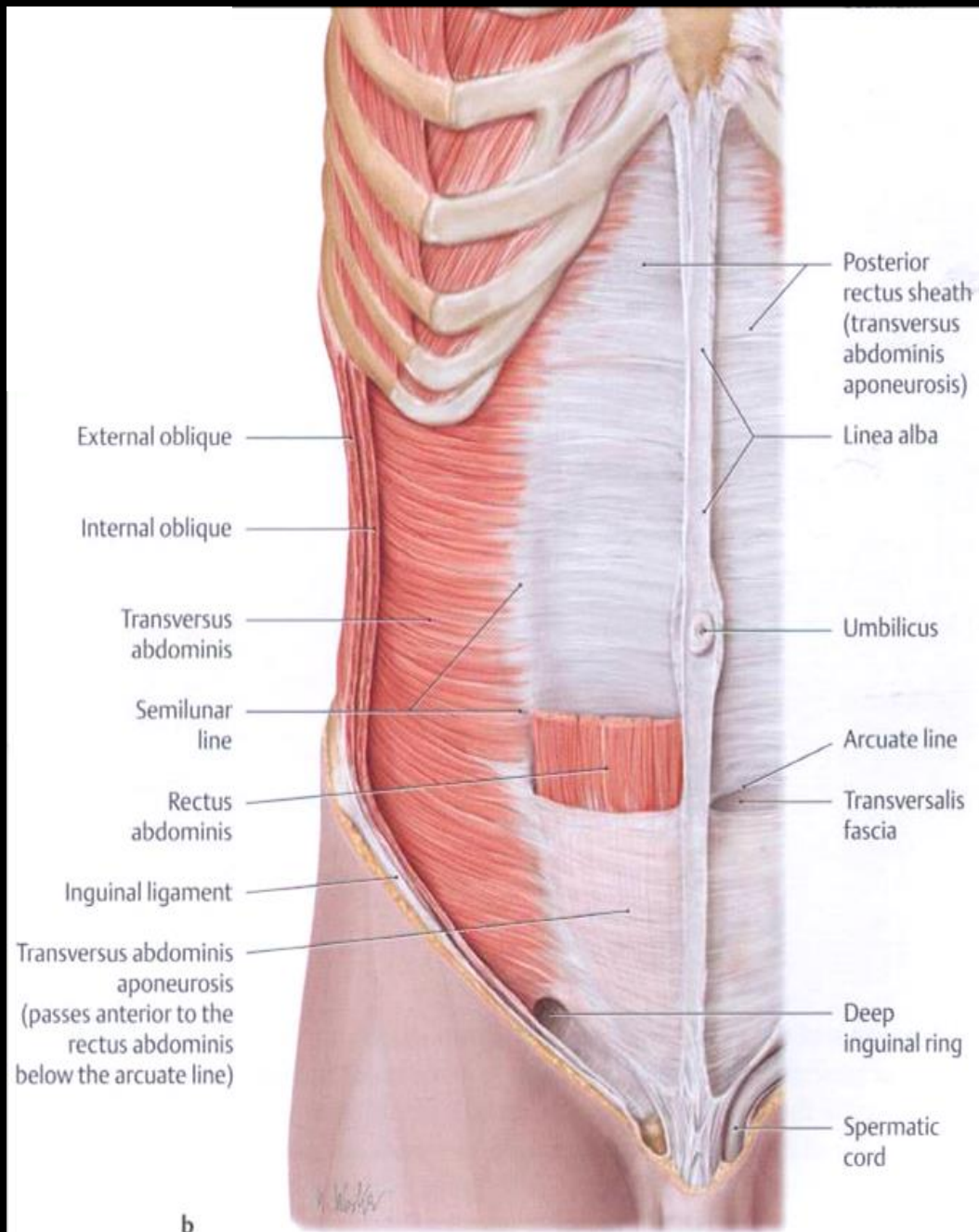
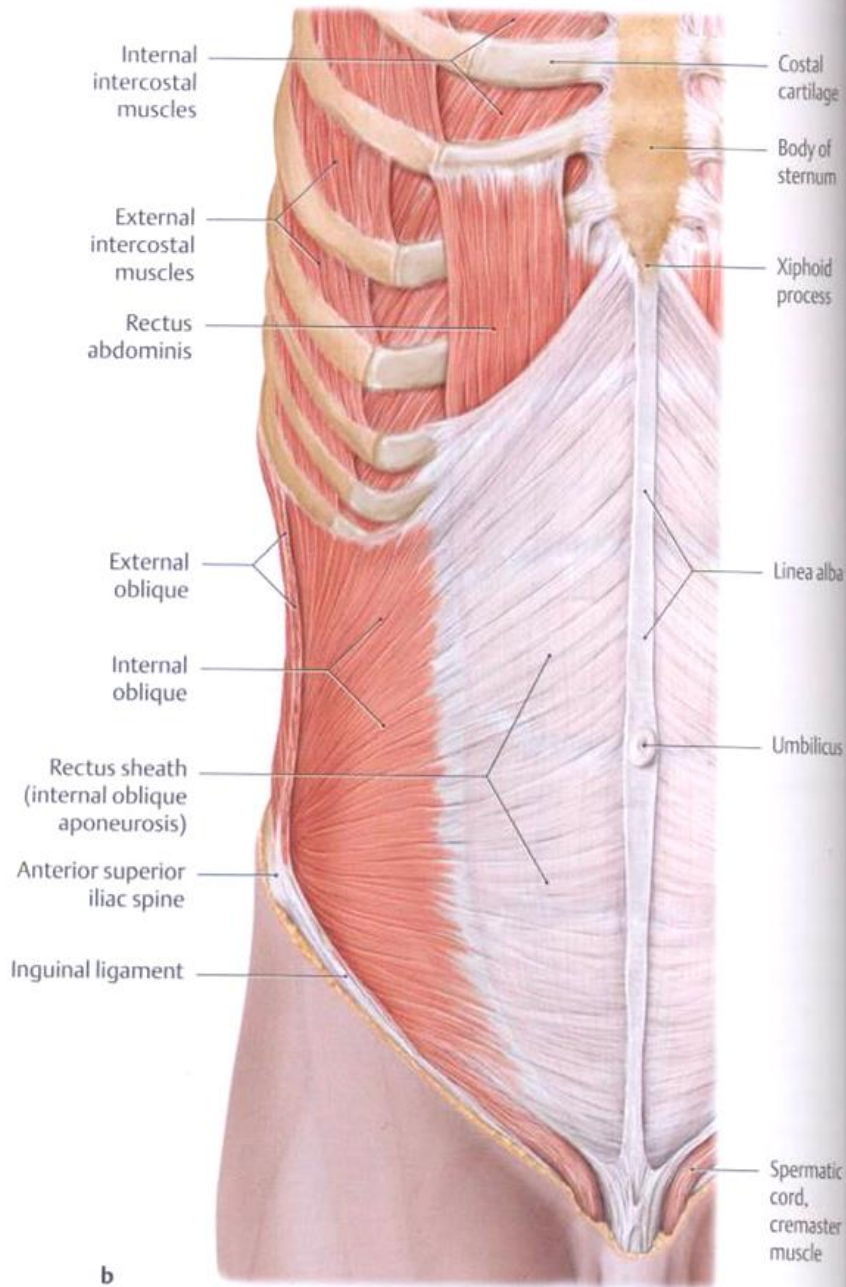


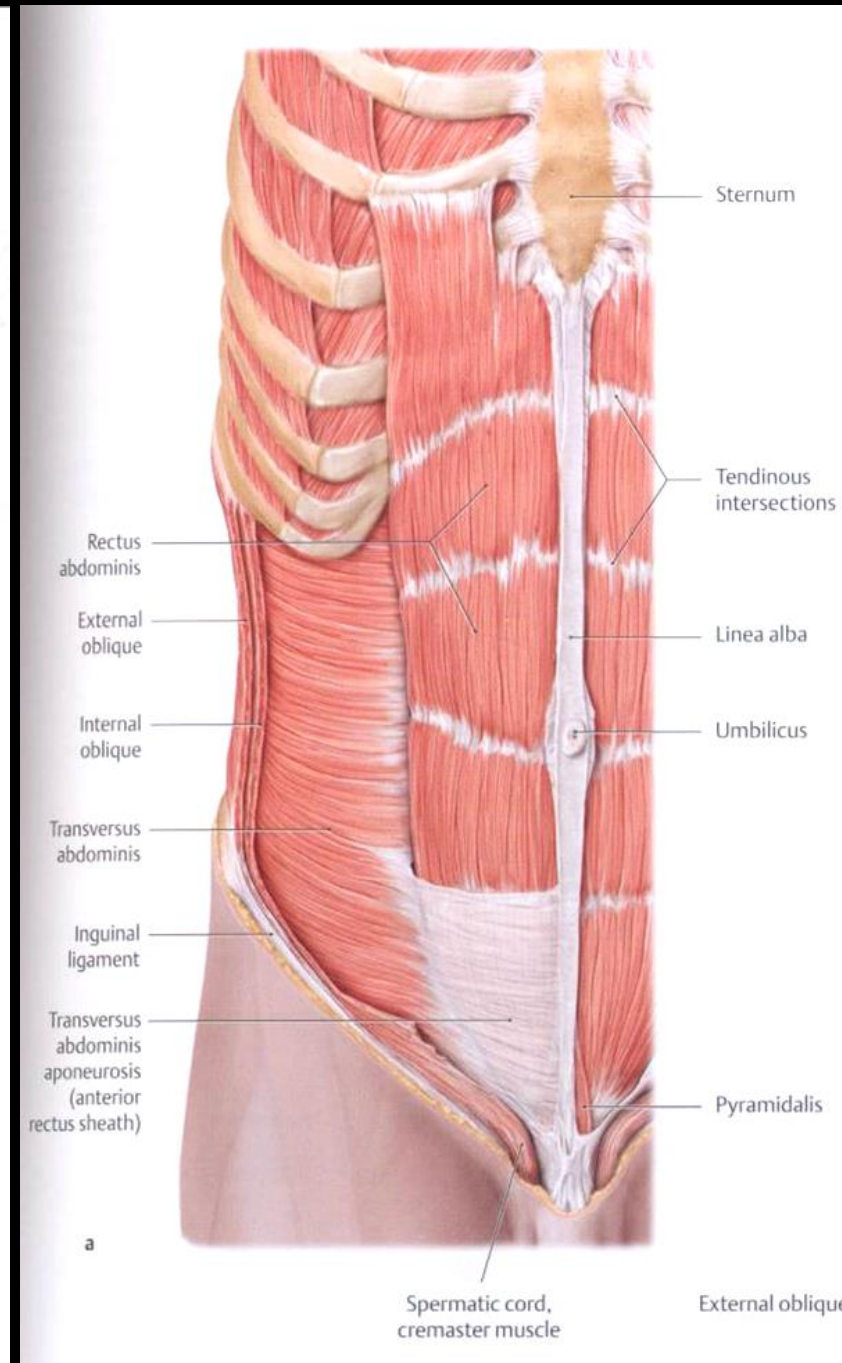
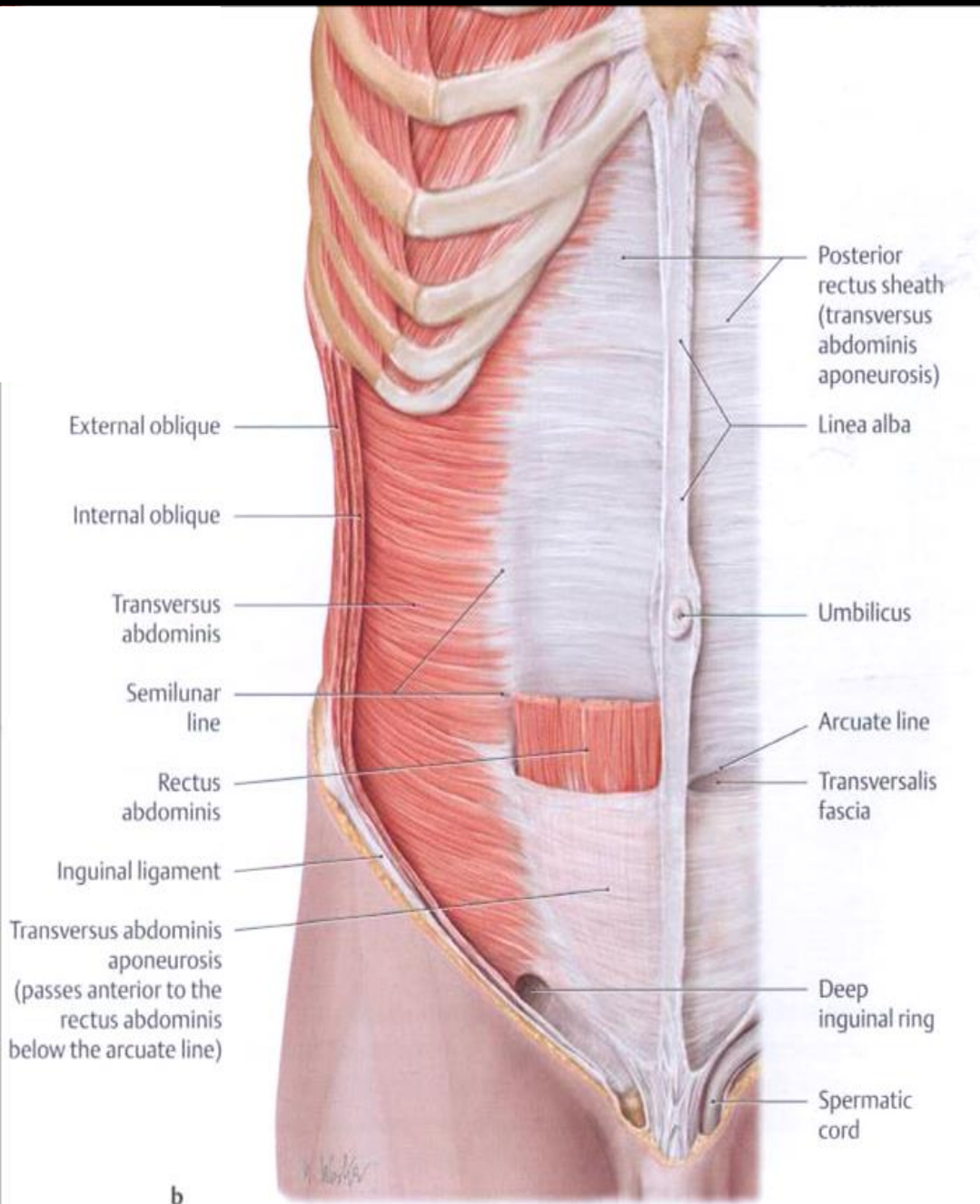


Hasizmok

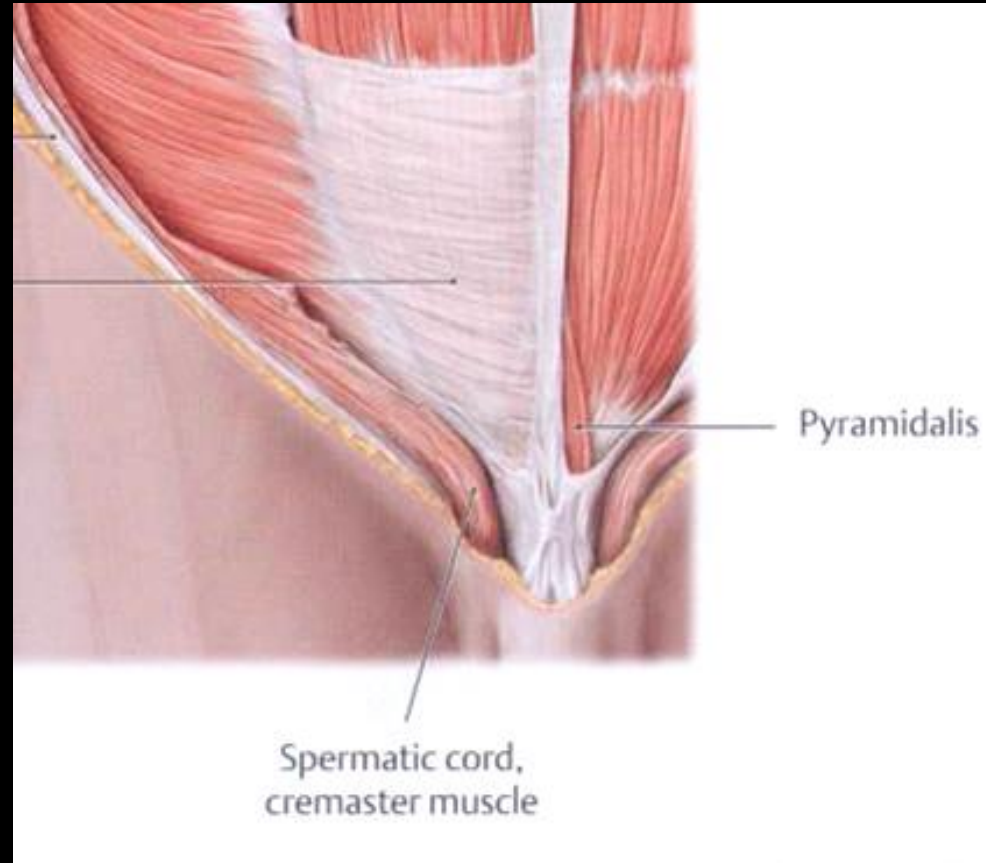
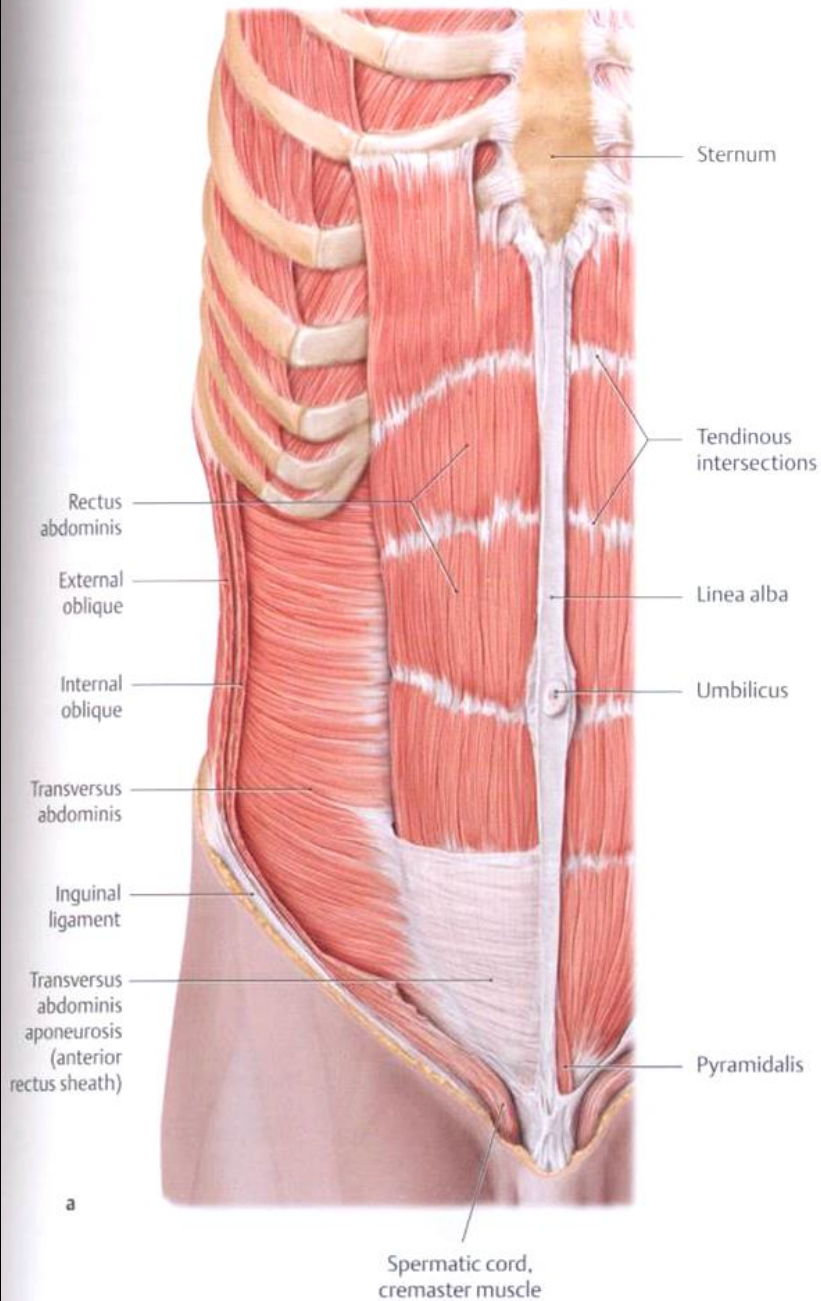


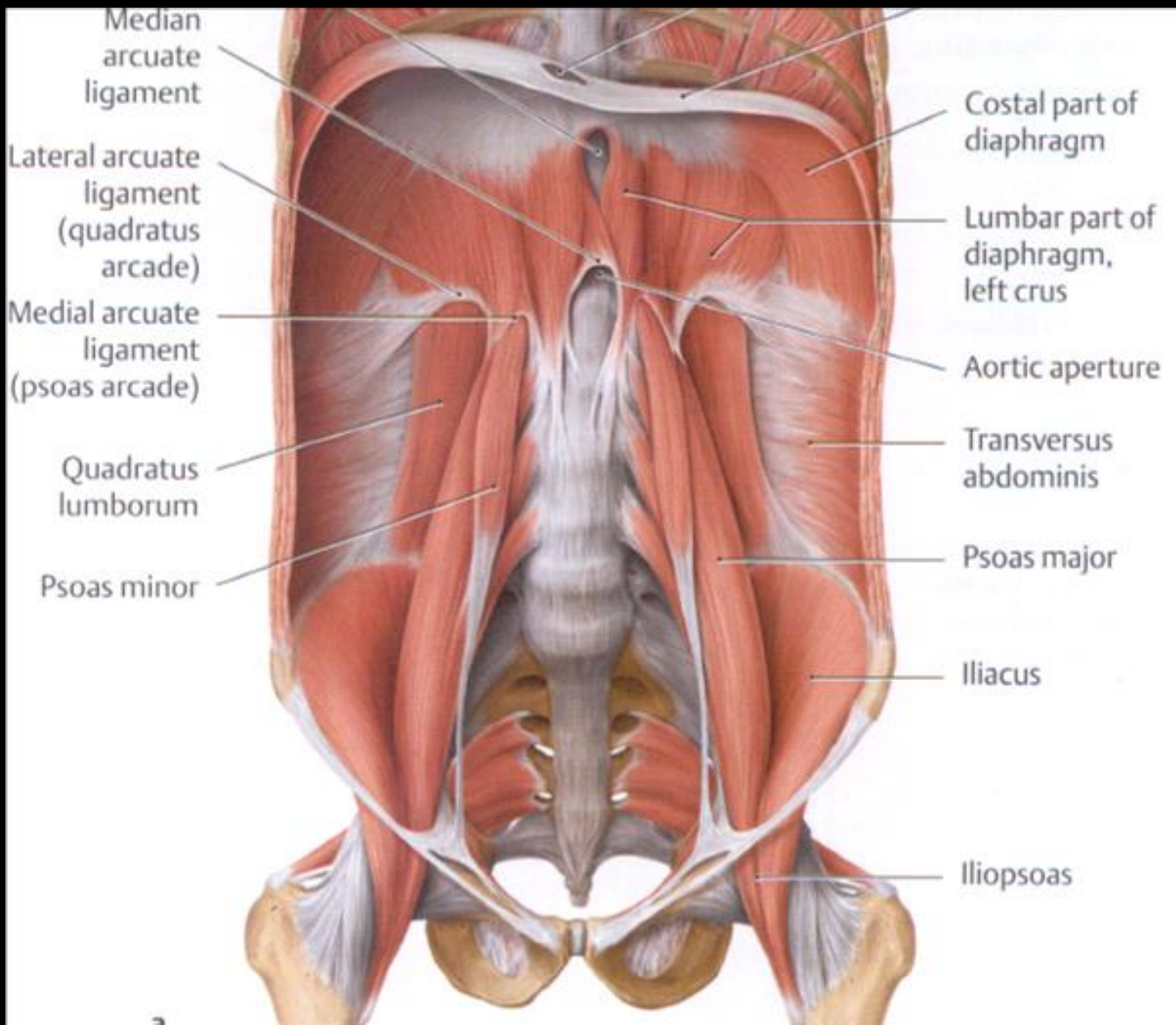




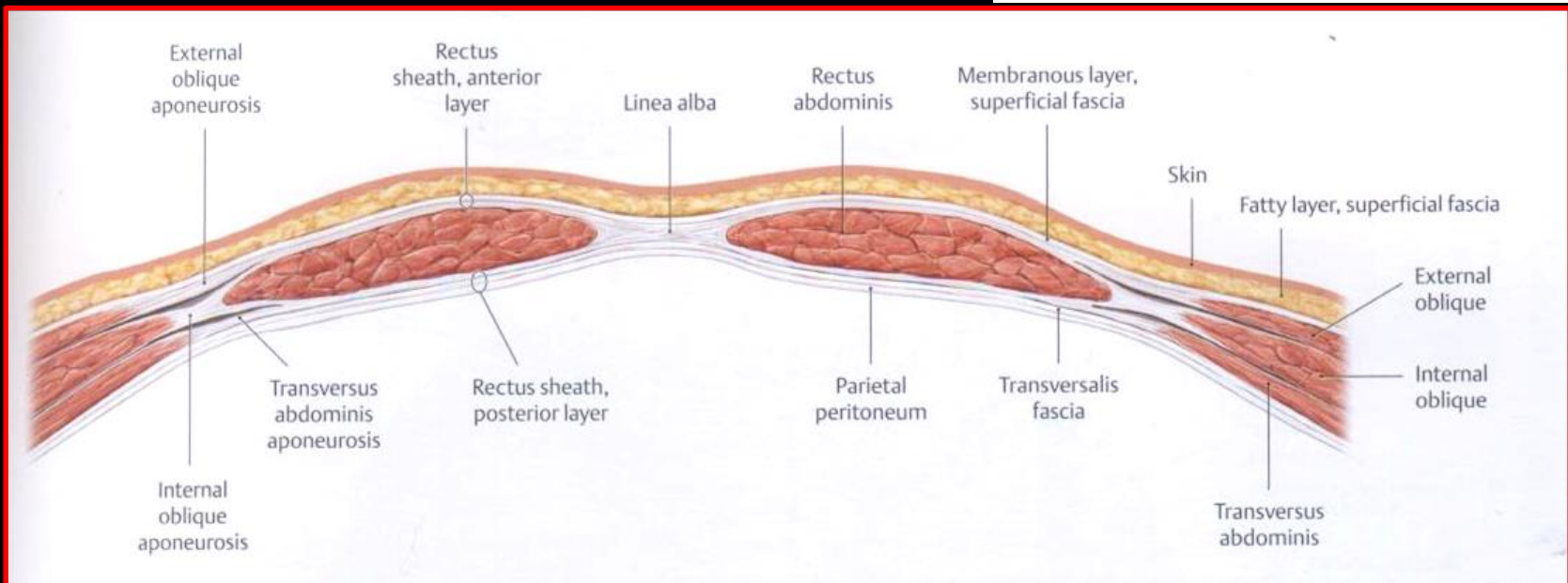
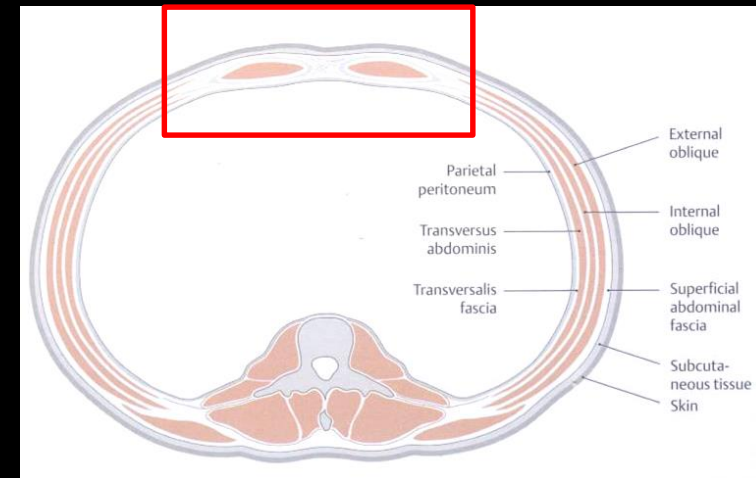


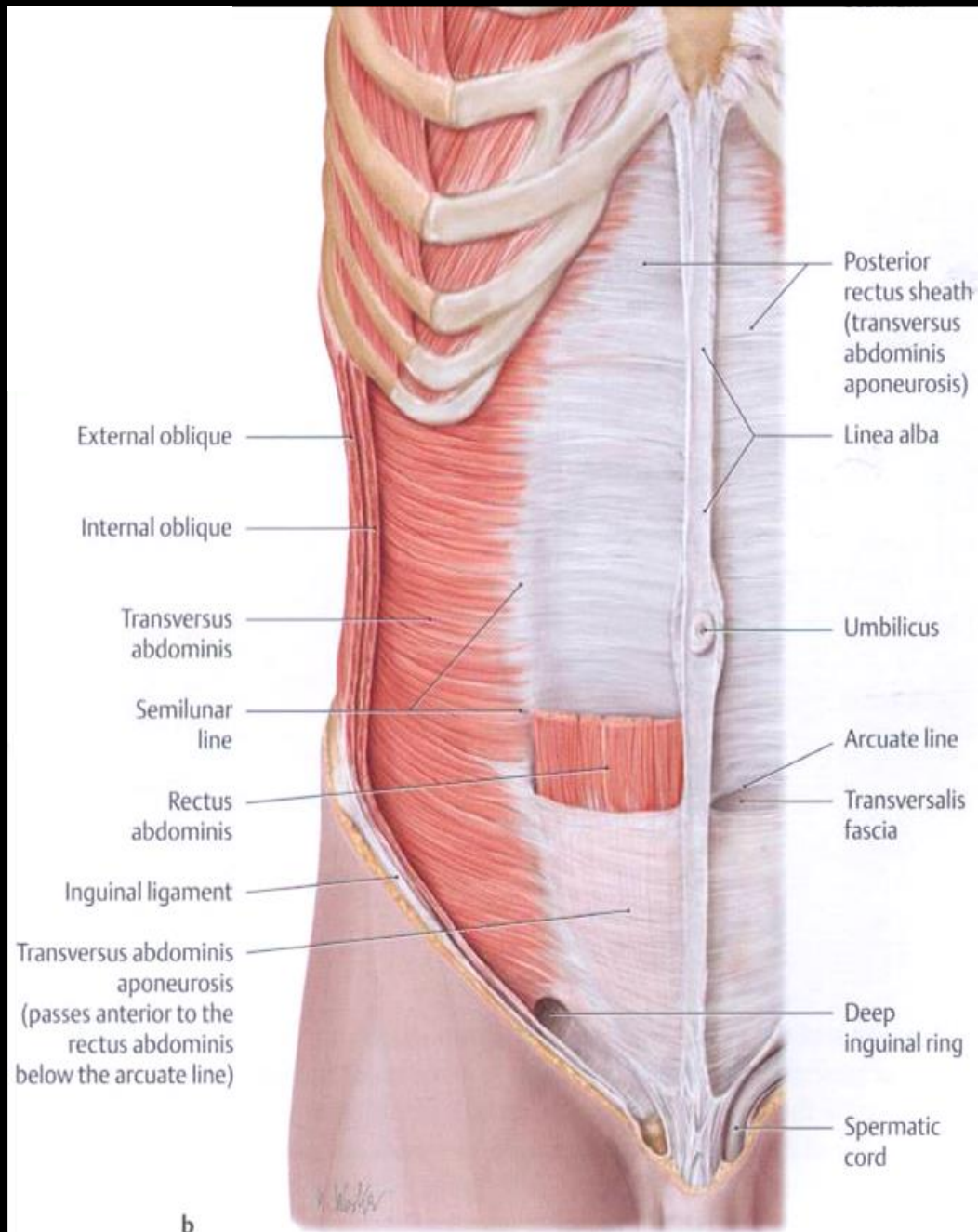
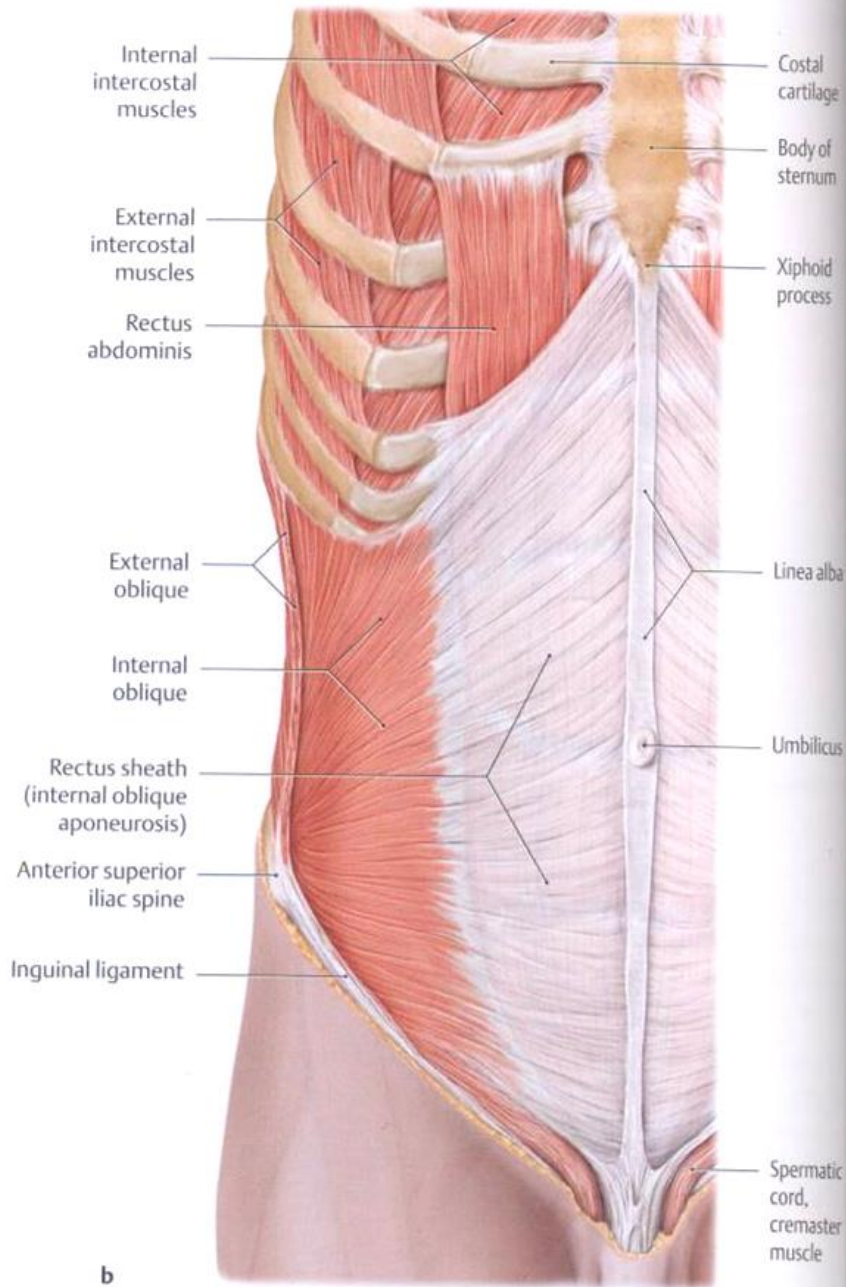


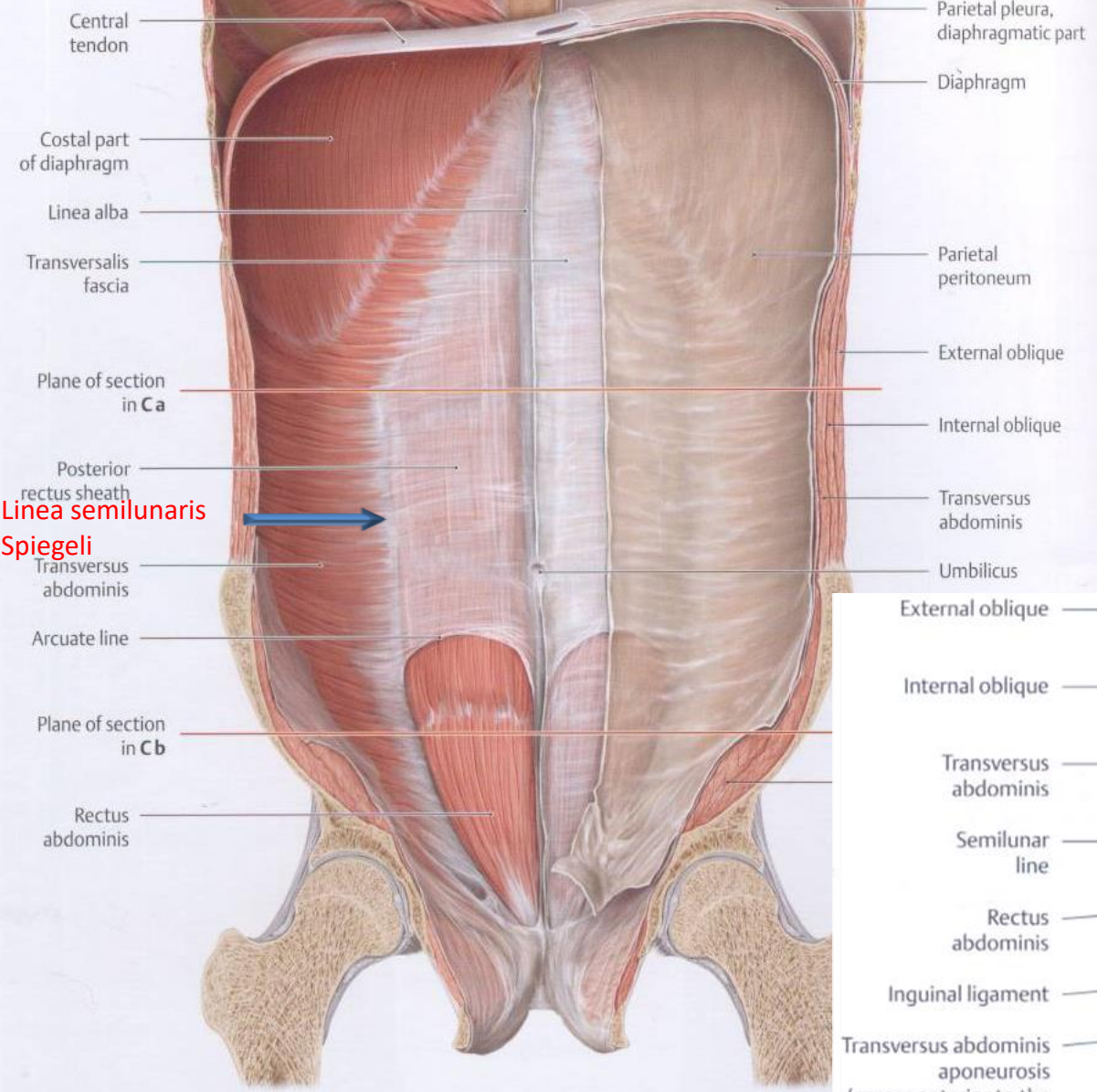




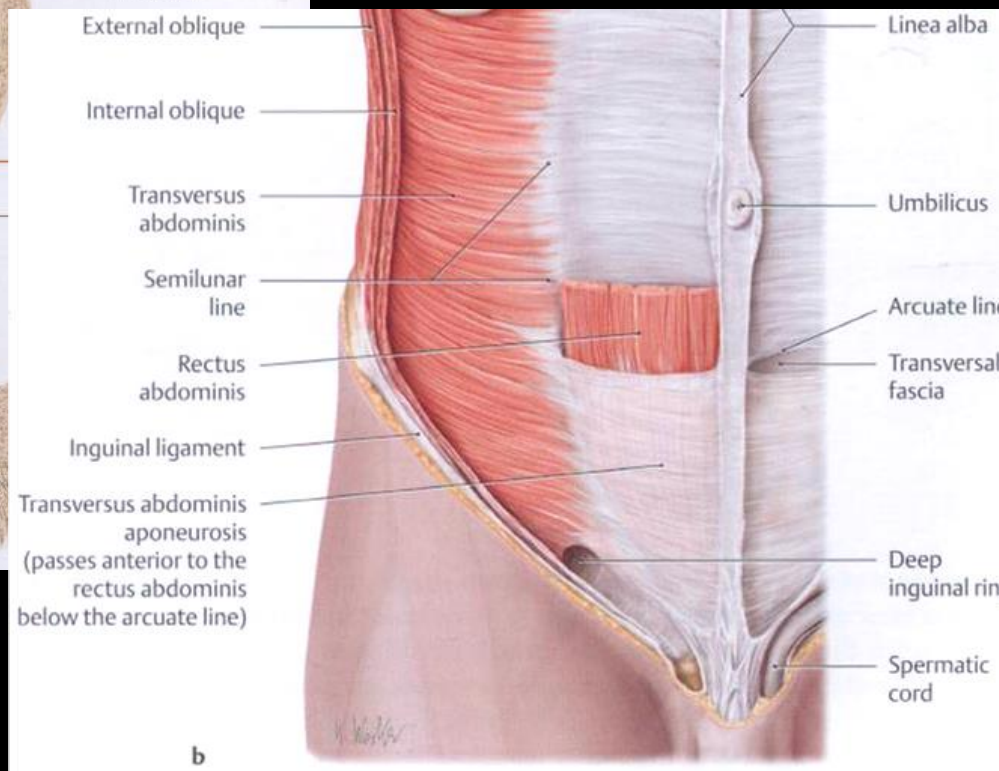
VAGINA MUSCULI RECTI ABDOMINIS (RECTUS-HÜVELY)



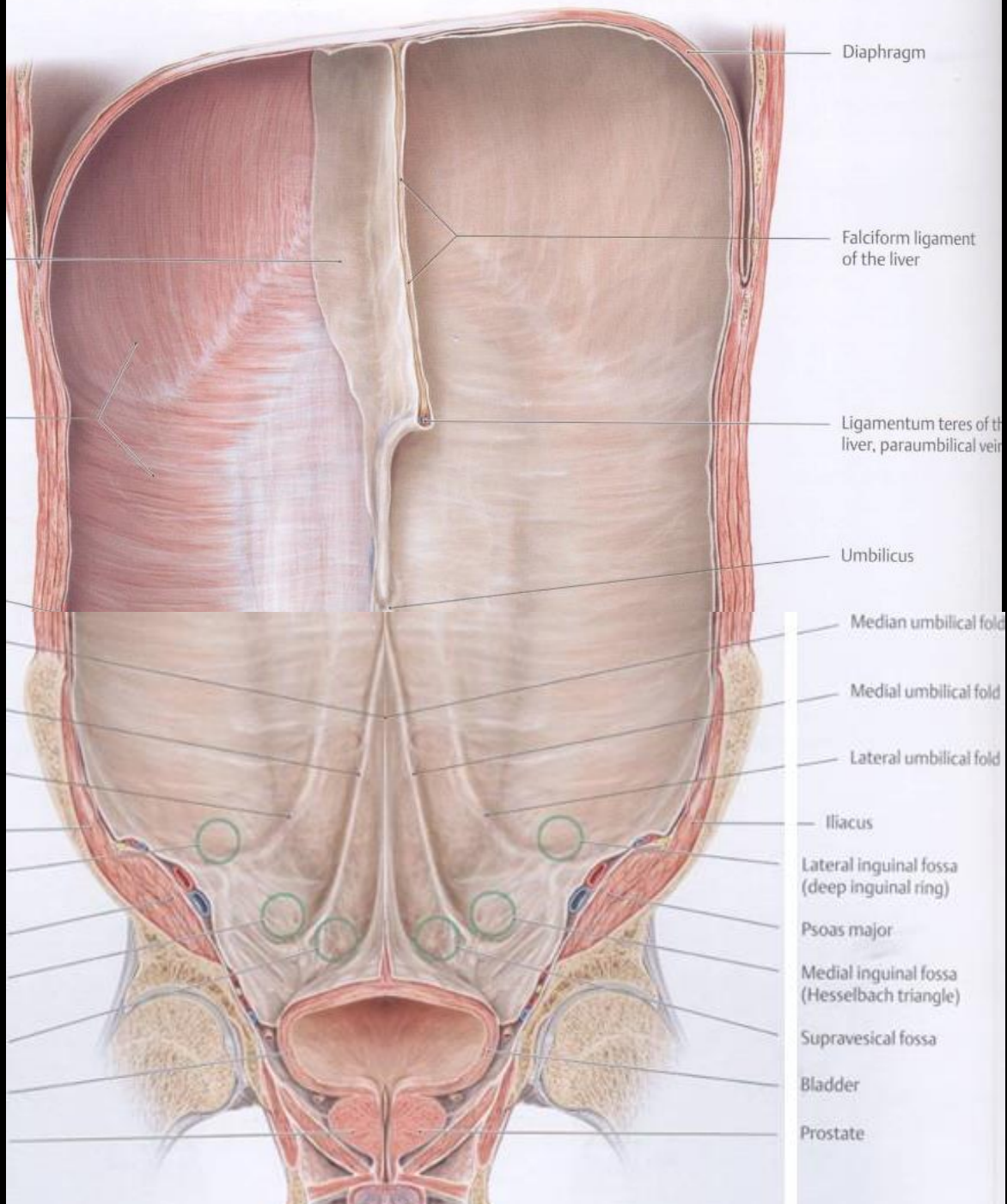




Linea semilunaris
Spiegeli



b



Diaphragm

Falciform ligament of the liver

Ligamentum teres of the liver, paraumbilical vein

Umbilicus

Median umbilical fold

Medial umbilical fold

Lateral umbilical fold

Iliacus

Lateral inguinal fossa (deep inguinal ring)

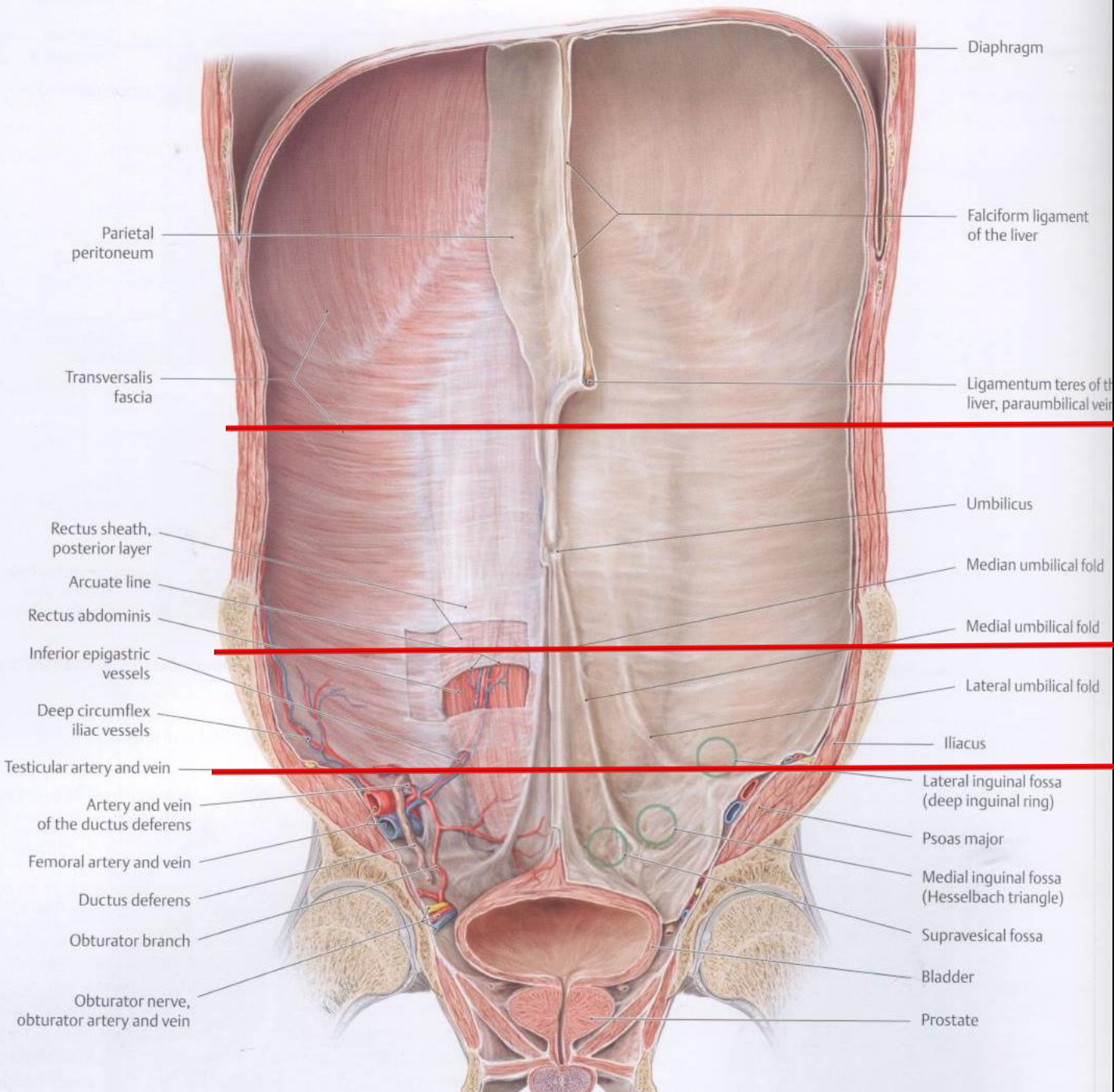
Psoas major

Medial inguinal fossa (Hesselbach triangle)

Suprapubic fossa

Bladder

Prostate



Diaphragm

Falciform ligament of the liver

Parietal peritoneum

Ligamentum teres of the liver, paraumbilical vein

Transversalis fascia

Umbilicus

Rectus sheath, posterior layer

Median umbilical fold

Arcuate line

Medial umbilical fold

Rectus abdominis

Lateral umbilical fold

Inferior epigastric vessels

Iliacus

Deep circumflex iliac vessels

Testicular artery and vein

Lateral inguinal fossa (deep inguinal ring)

Artery and vein of the ductus deferens

Psoas major

Femoral artery and vein

Medial inguinal fossa (Hesselbach triangle)

Ductus deferens

Suprapubic fossa

Obturator branch

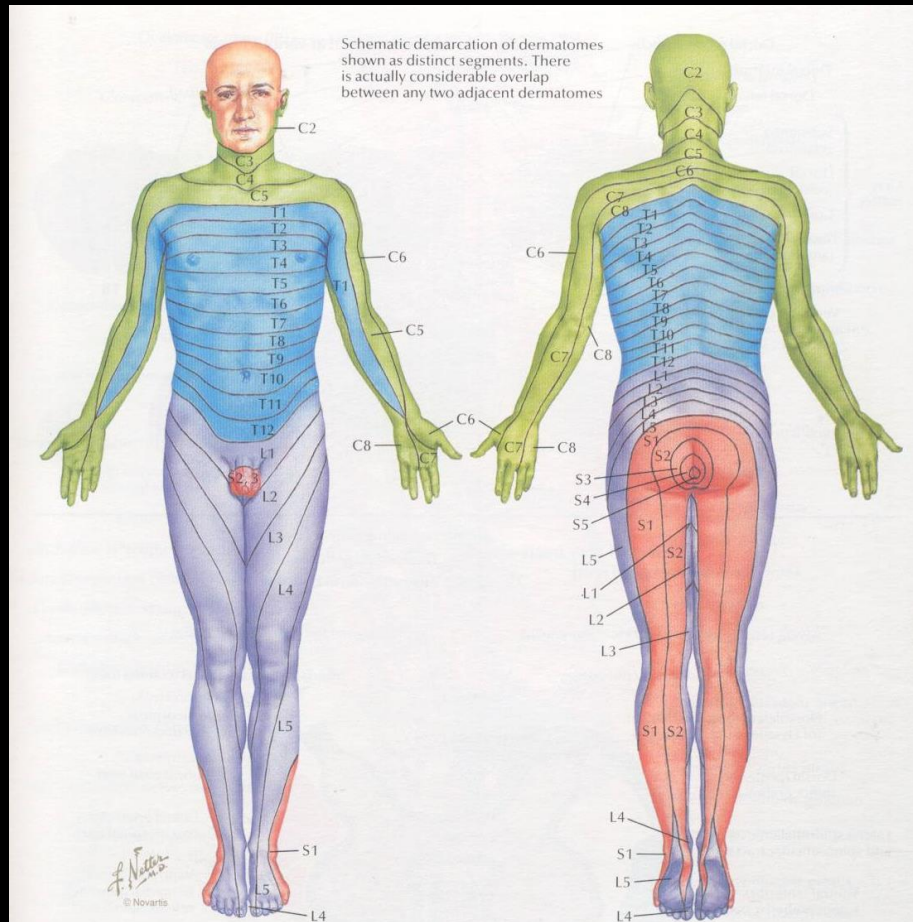
Bladder

Obturator nerve, obturator artery and vein

Prostate



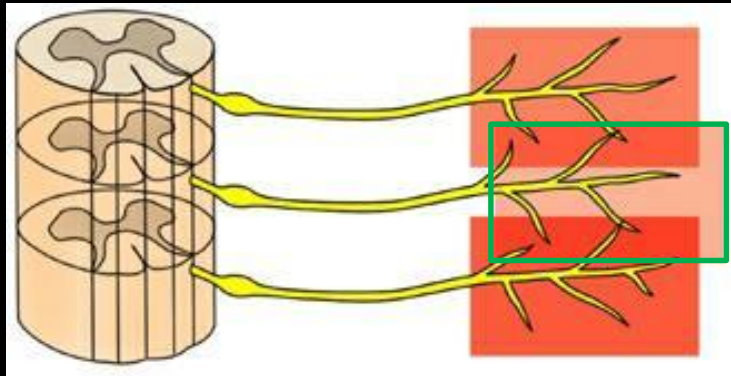
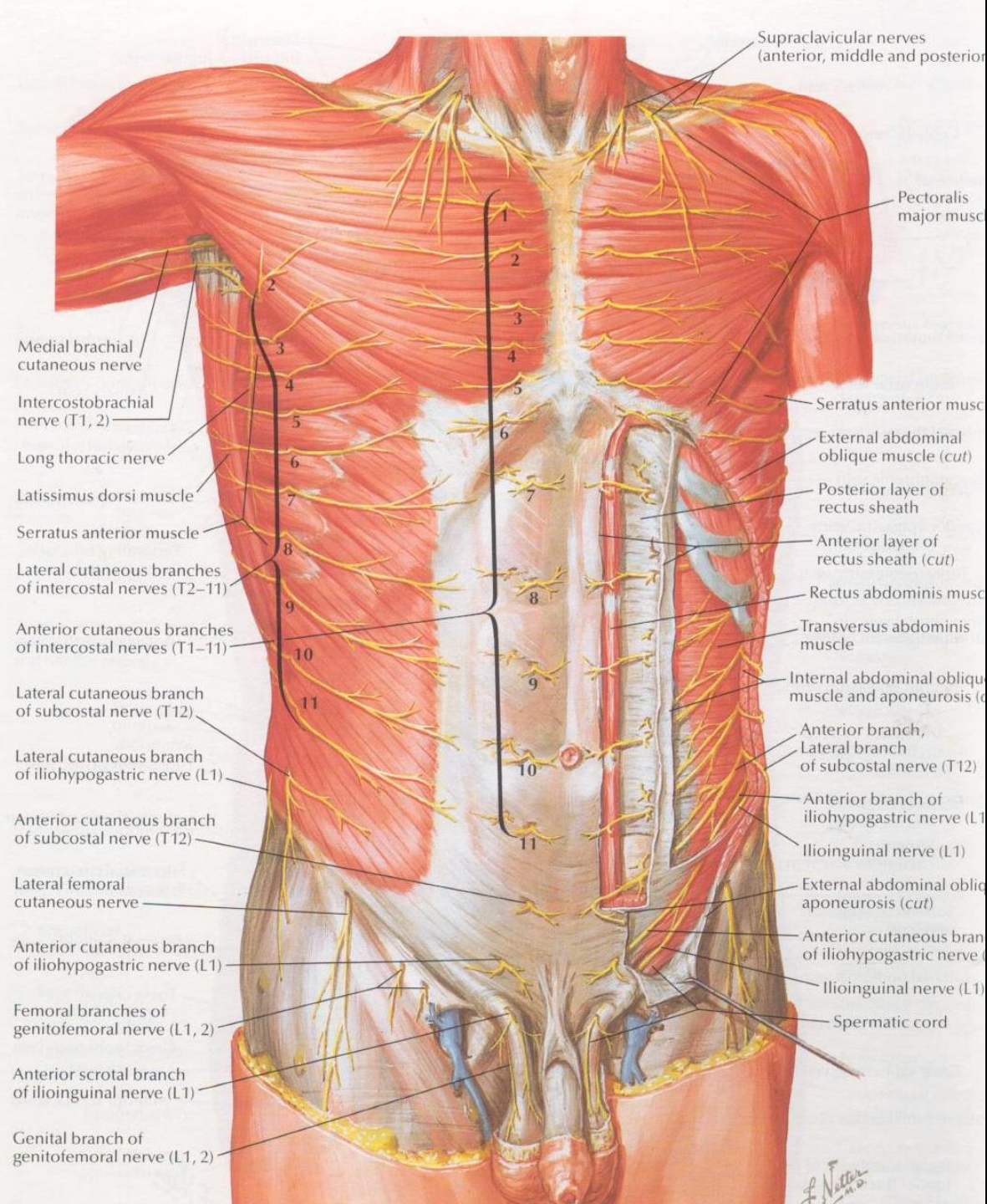
A hasizmok beidegzése



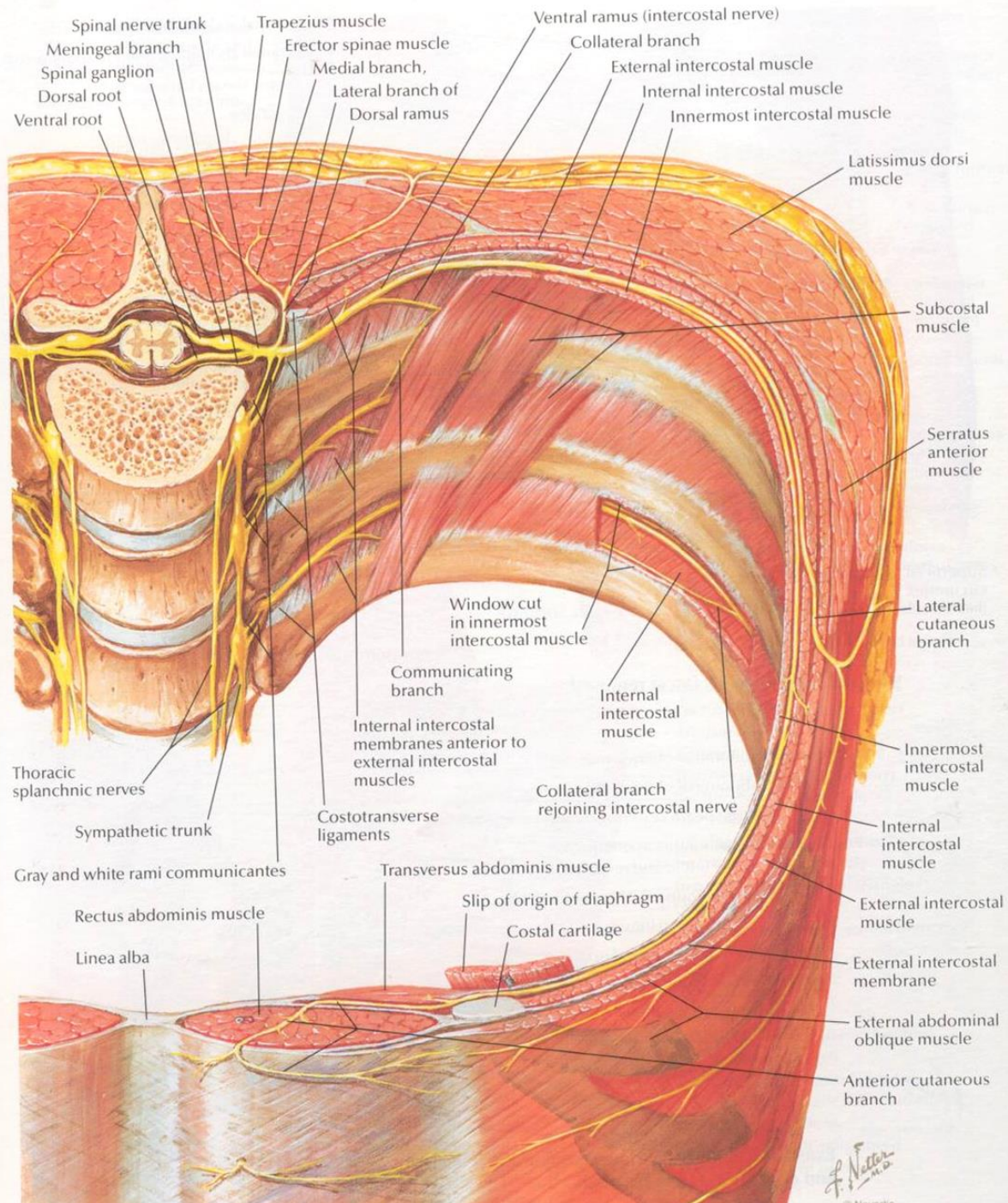
Levels of principal dermatomes

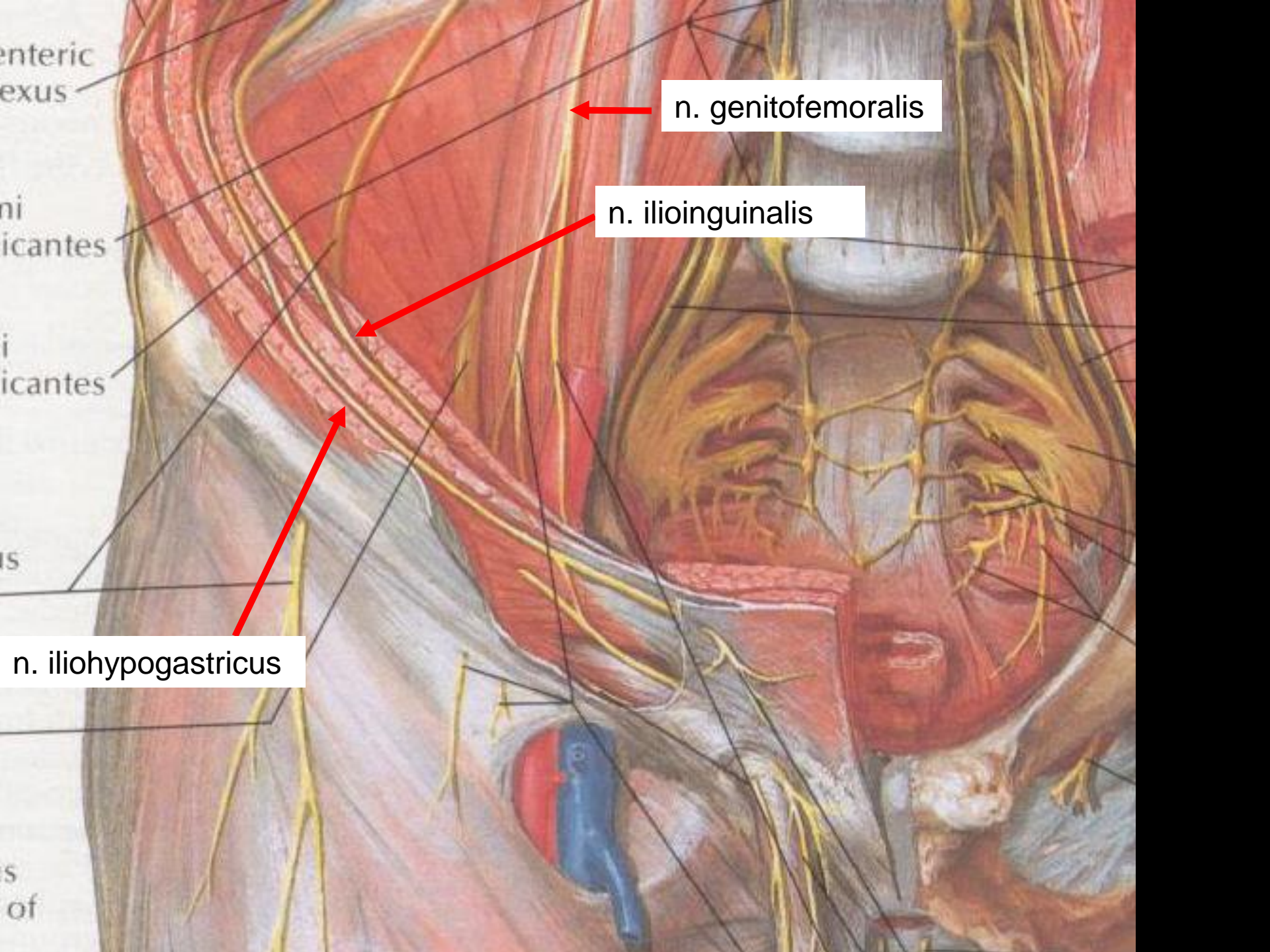
C5	Clavicles
C5, 6, 7	Lateral parts of upper limbs
C8, T1	Medial sides of upper limbs
C6	Thumb
C6, 7, 8	Hand
C8	Ring and little fingers
T4	Level of nipples

T10	Level of umbilicus
T12	Inguinal or groin regions
L1, 2, 3, 4	Anterior and inner surfaces of lower limbs
L4, 5, S1	Foot
L4	Medial side of great toe
S1, 2, L5	Posterior and outer surfaces of lower limbs
S1	Lateral margin of foot and little toe
S2, 3, 4	Perineum



W. Netter M.D.





enteric
plexus

ni
cantes

i
cantes

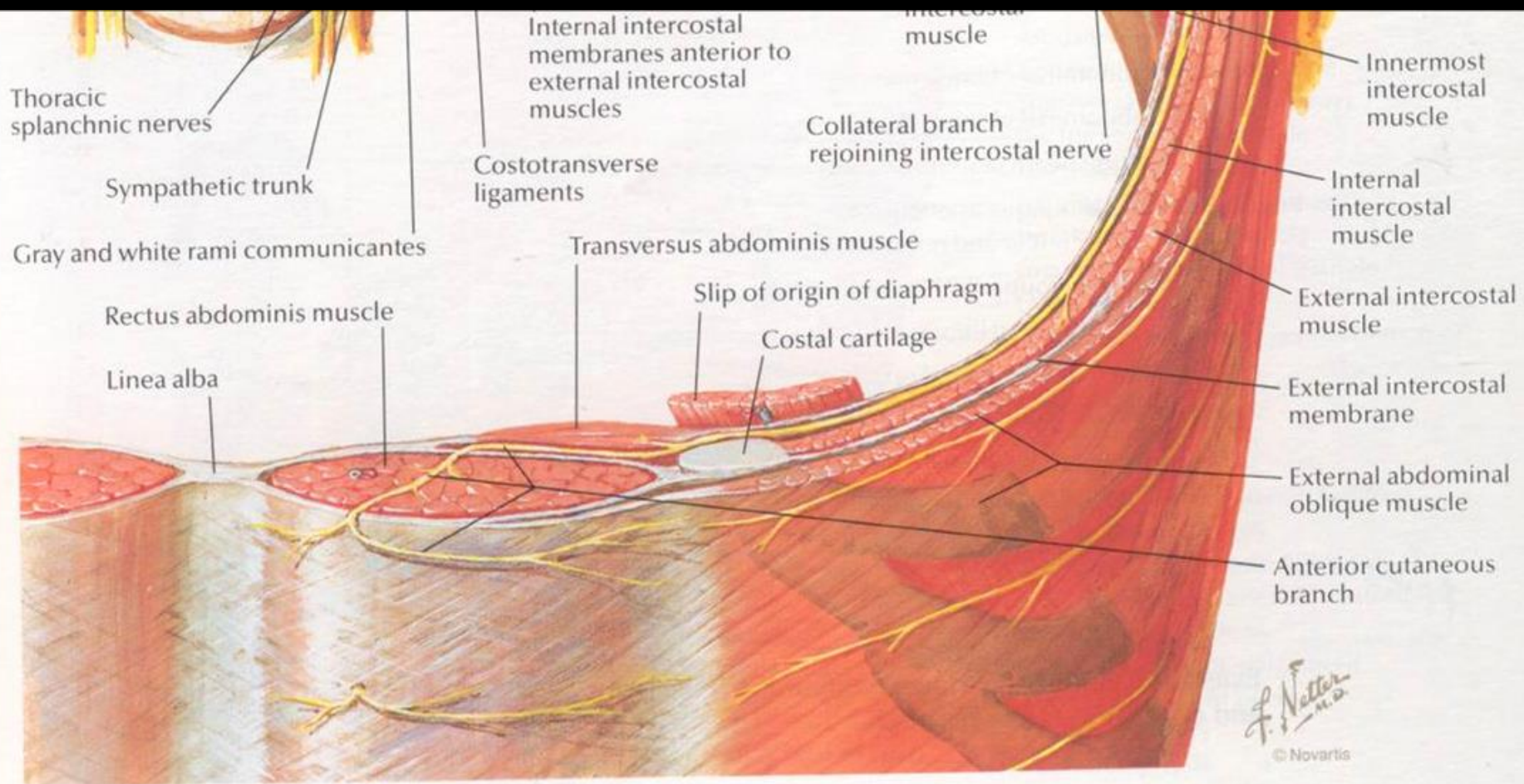
is

n. iliohypogastricus

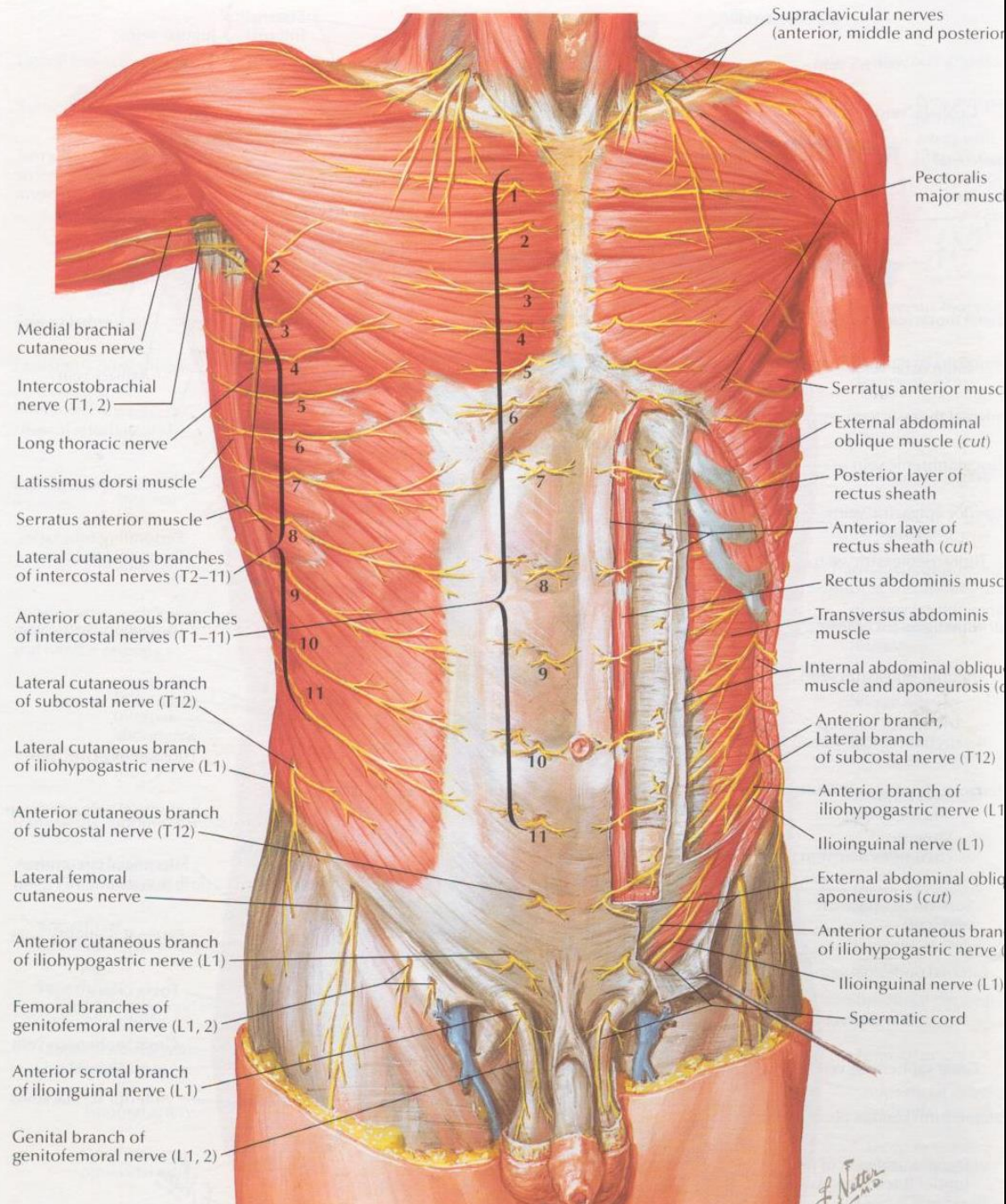
s
of

n. genitofemoralis

n. ilioinguinalis



F. Netter M.D.
© Novartis



Supraclavicular nerves
(anterior, middle and posterior)

Pectoralis major muscle

Medial brachial cutaneous nerve

Intercostobrachial nerve (T1, 2)

Long thoracic nerve

Latissimus dorsi muscle

Serratus anterior muscle

Lateral cutaneous branches of intercostal nerves (T2-11)

Anterior cutaneous branches of intercostal nerves (T1-11)

Lateral cutaneous branch of subcostal nerve (T12)

Lateral cutaneous branch of iliohypogastric nerve (L1)

Anterior cutaneous branch of subcostal nerve (T12)

Lateral femoral cutaneous nerve

Anterior cutaneous branch of iliohypogastric nerve (L1)

Femoral branches of genitofemoral nerve (L1, 2)

Anterior scrotal branch of ilioinguinal nerve (L1)

Genital branch of genitofemoral nerve (L1, 2)

Serratus anterior muscle

External abdominal oblique muscle (cut)

Posterior layer of rectus sheath

Anterior layer of rectus sheath (cut)

Rectus abdominis muscle

Transversus abdominis muscle

Internal abdominal oblique muscle and aponeurosis (cut)

Anterior branch, Lateral branch of subcostal nerve (T12)

Anterior branch of iliohypogastric nerve (L1)

Ilioinguinal nerve (L1)

External abdominal oblique aponeurosis (cut)

Anterior cutaneous branch of iliohypogastric nerve (L1)

Ilioinguinal nerve (L1)

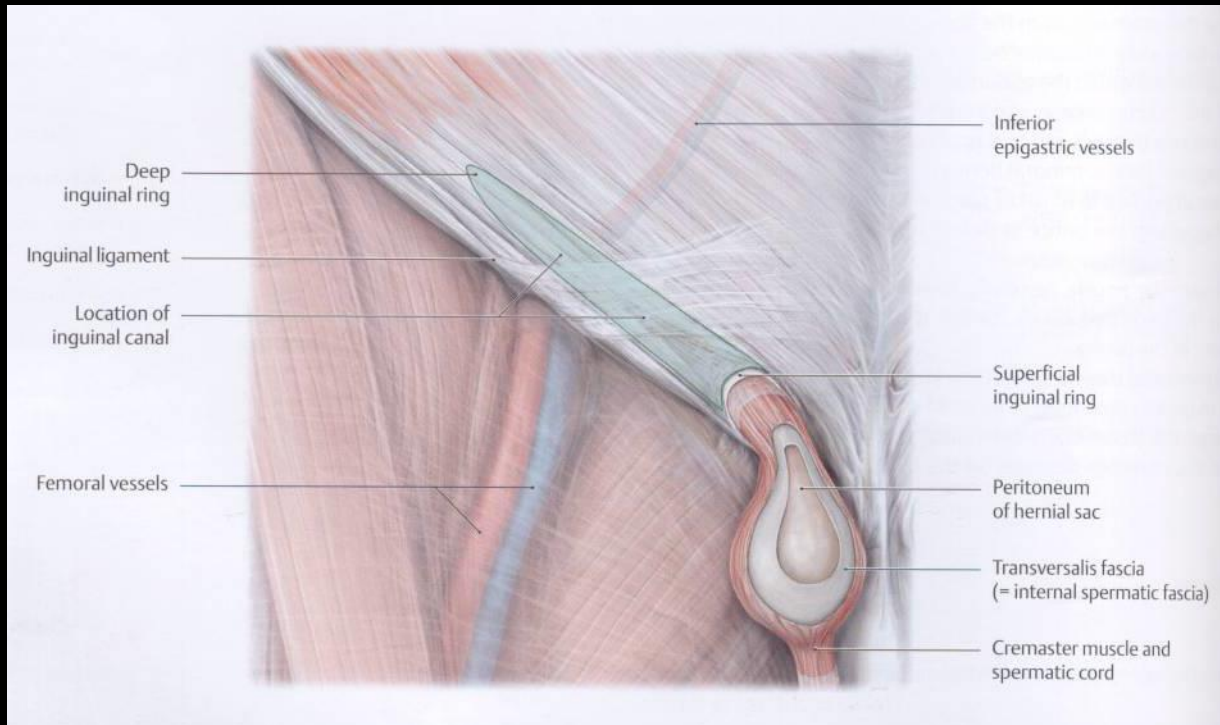
Spermatic cord

F. Netter M.D.

A hasfal gyenge pontjai (locus minoris resistentiae abdominis)

Hernia inguinalis

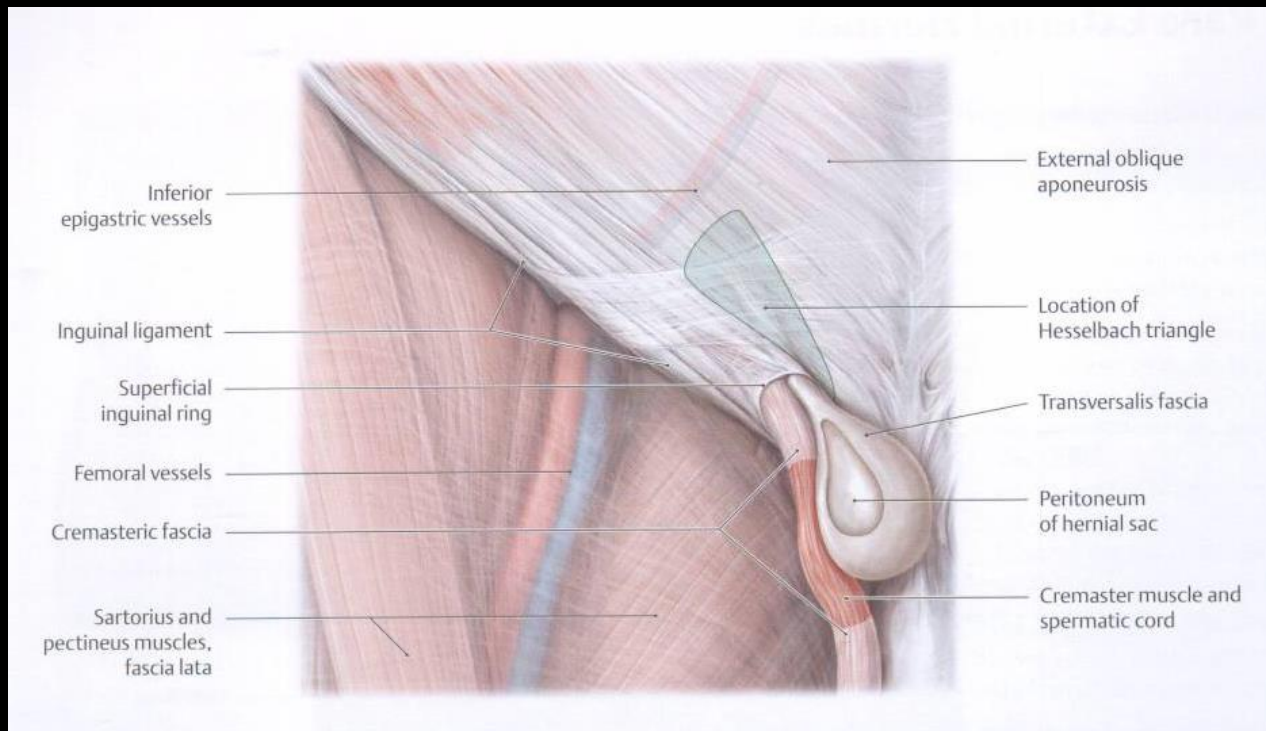
Hernia inguinalis lateralis/indirecta



A hasfal gyenge pontjai (locus minoris resistentiae abdominis)

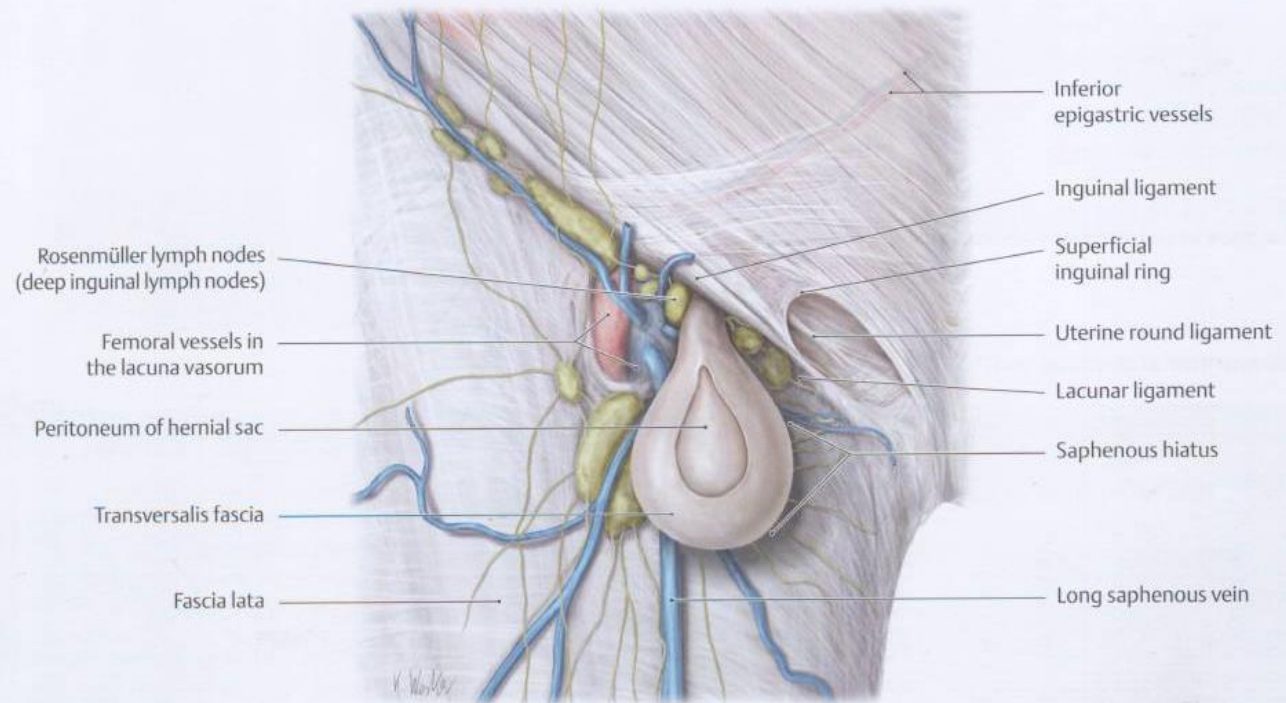
Hernia inguinalis

Hernia inguinalis medialis/directa



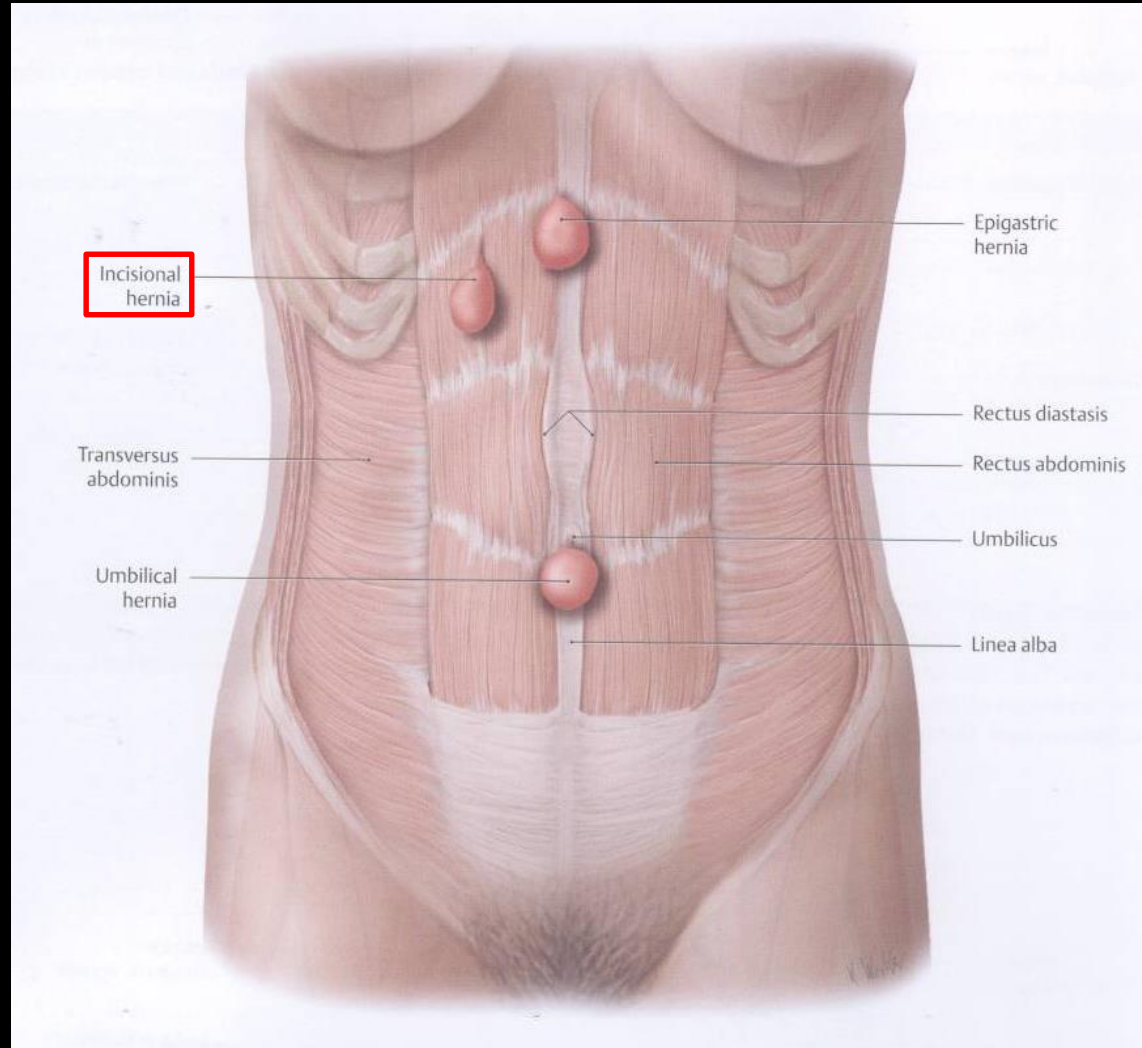
A hasfal gyenge pontjai (locus minoris resistentiae abdominis)

Hernia femoralis



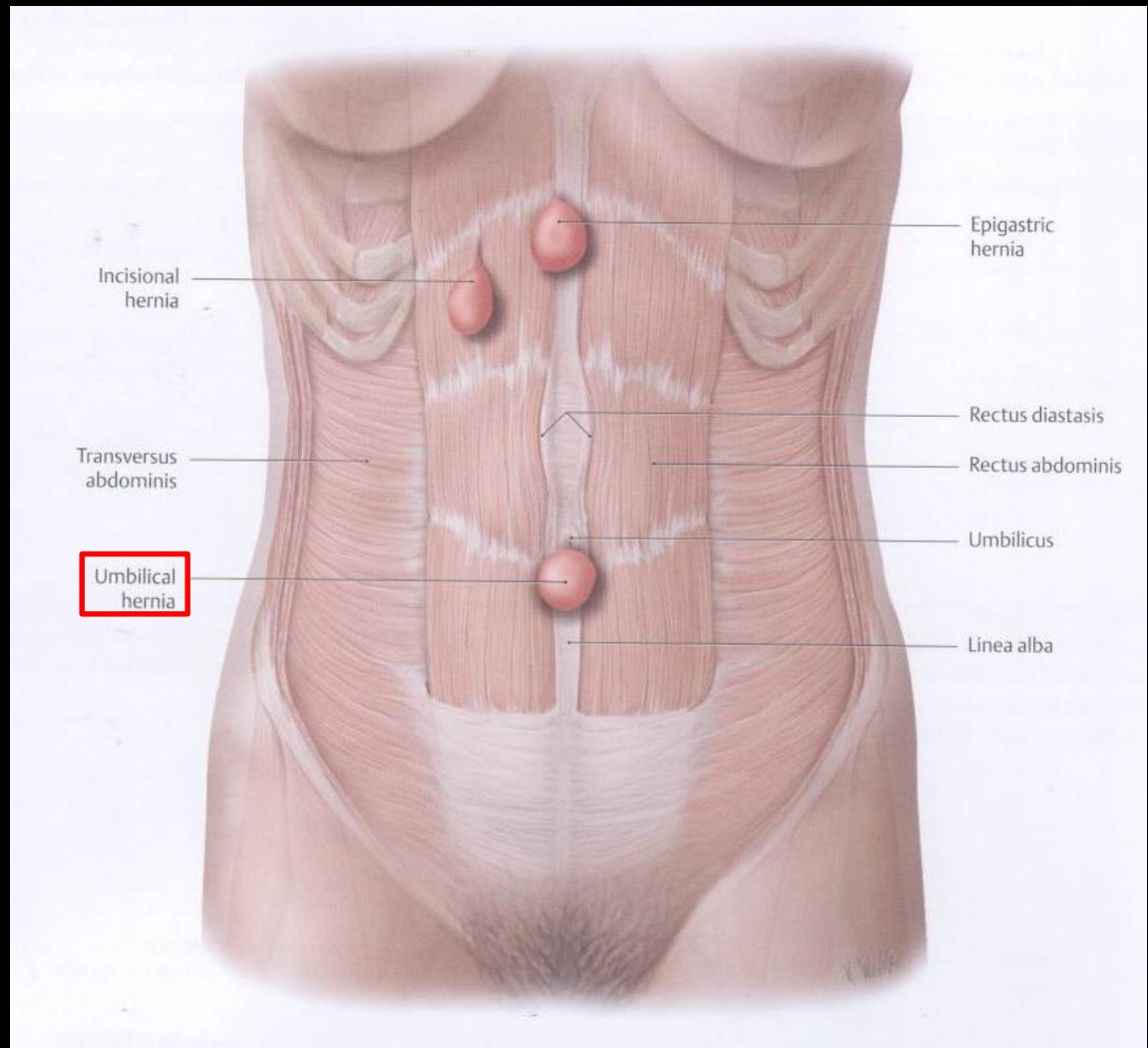
A hasfal gyenge pontjai (locus minoris resistentiae abdominis)

Hernia postoperativa/incisionalis



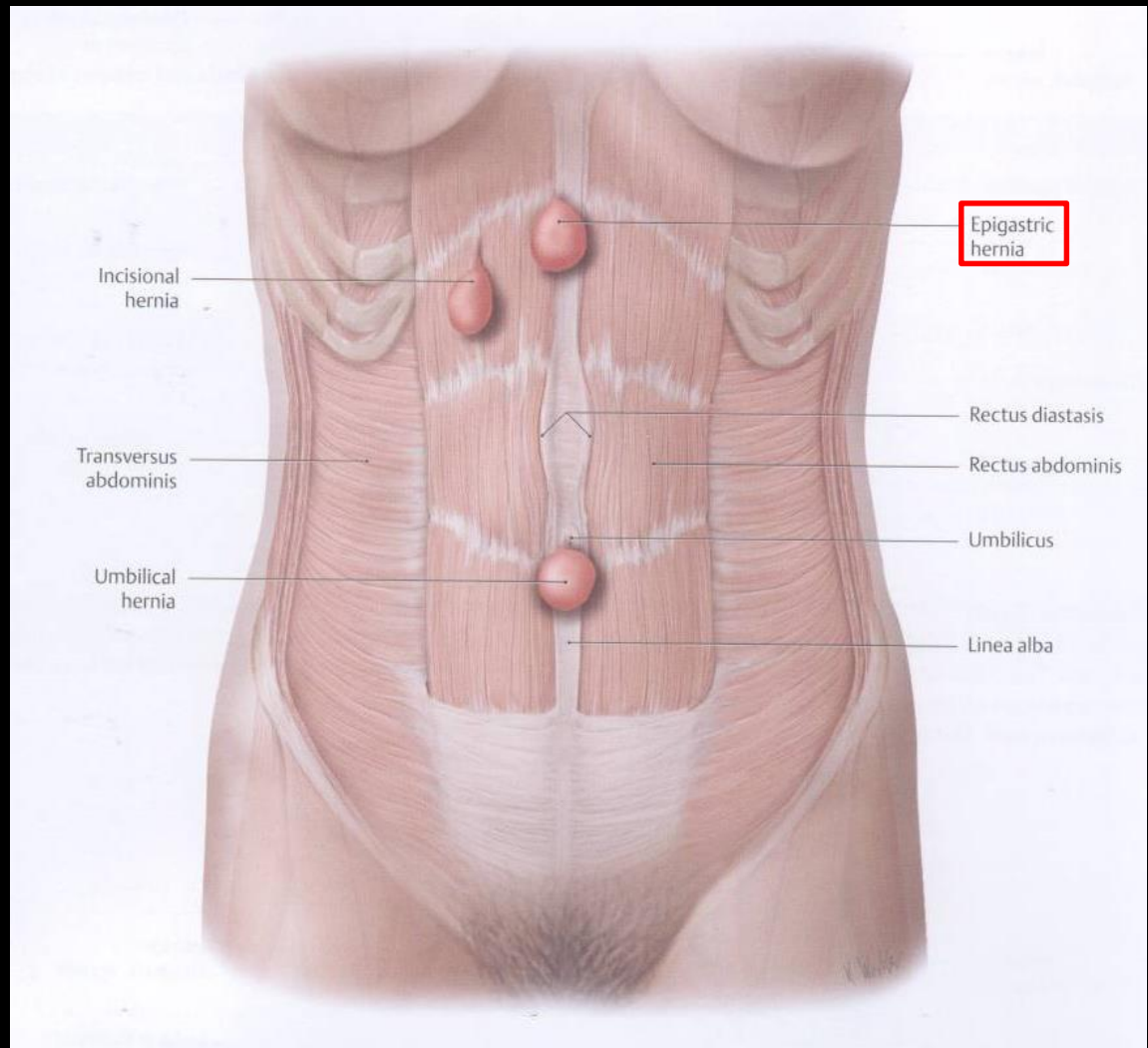
A hasfal gyenge pontjai (locus minoris resistentiae abdominis)

Hernia umbilicalis



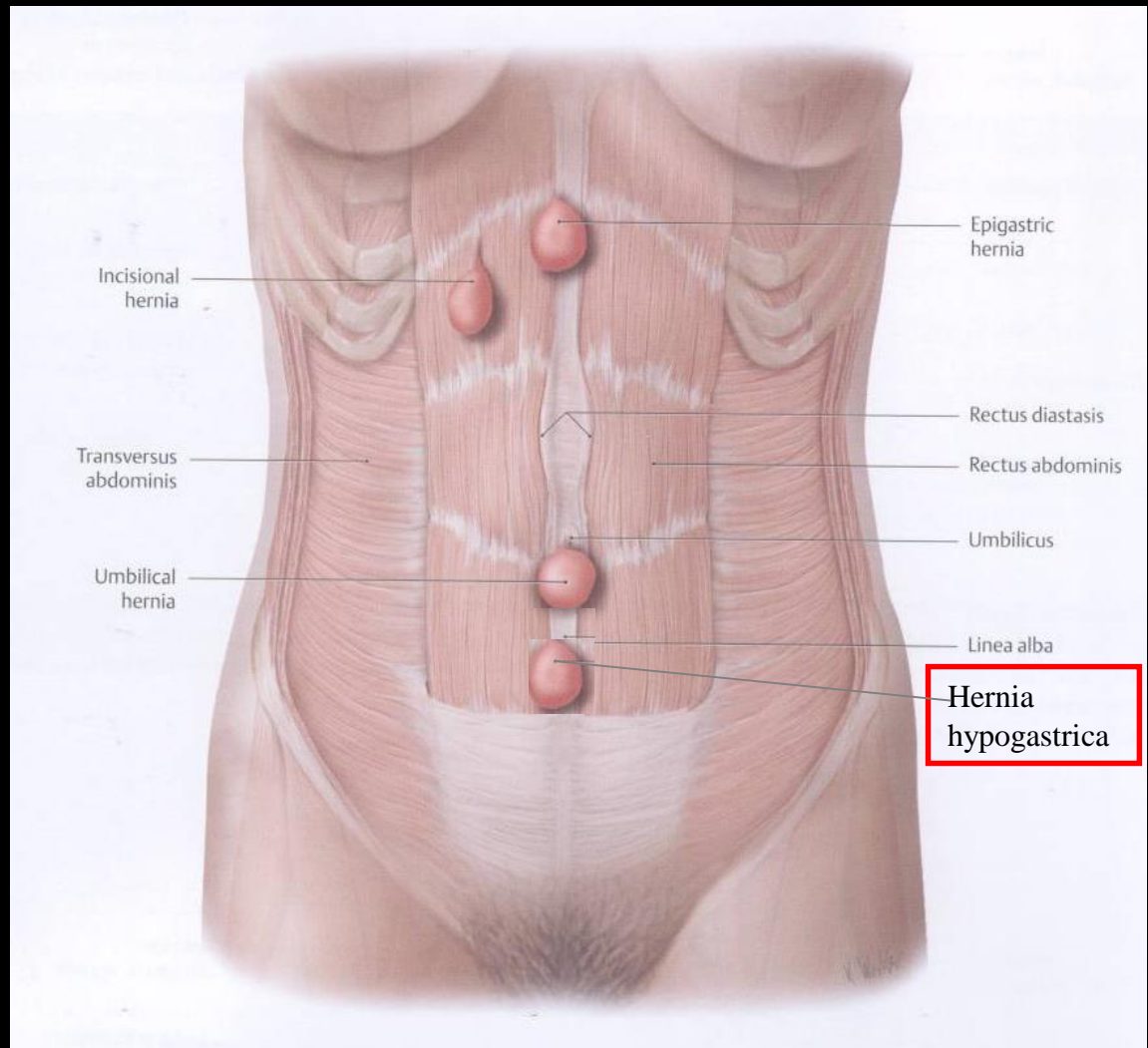
A hasfal gyenge pontjai (locus minoris resistentiae abdominis)

Hernia epigastrica



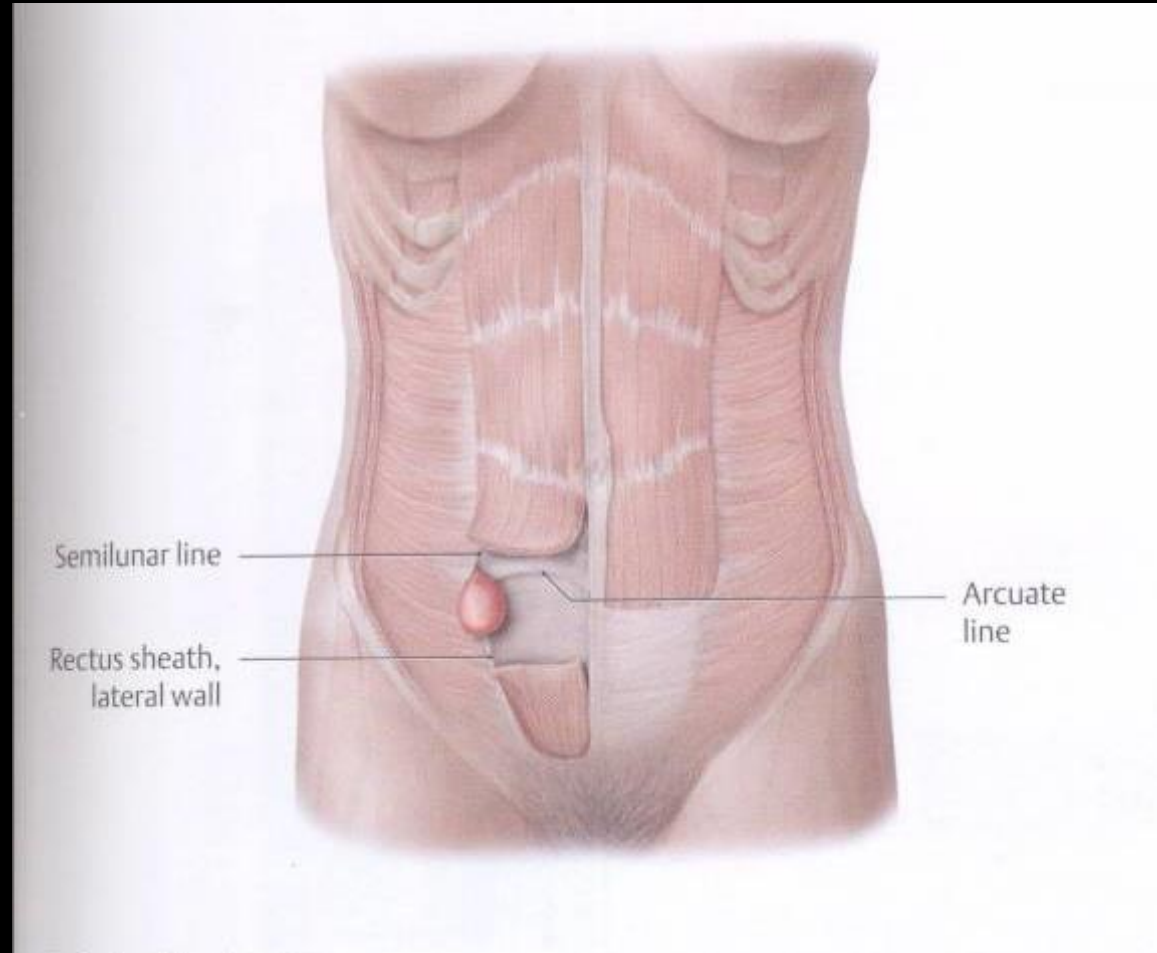
A hasfal gyenge pontjai (locus minoris resistentiae abdominis)

Hernia hypogastrica



A hasfal gyenge pontjai (locus minoris resistentiae abdominis)

Hernia semilunaris
(Spiegel-féle sérv)



A hasfal gyenge pontjai (locus minoris resistentiae abdominis)

Hernia lumbalis inferior
(Petit-féle sérv)

Hernia lumbalis superior
(Grynfelt-féle sérv)

