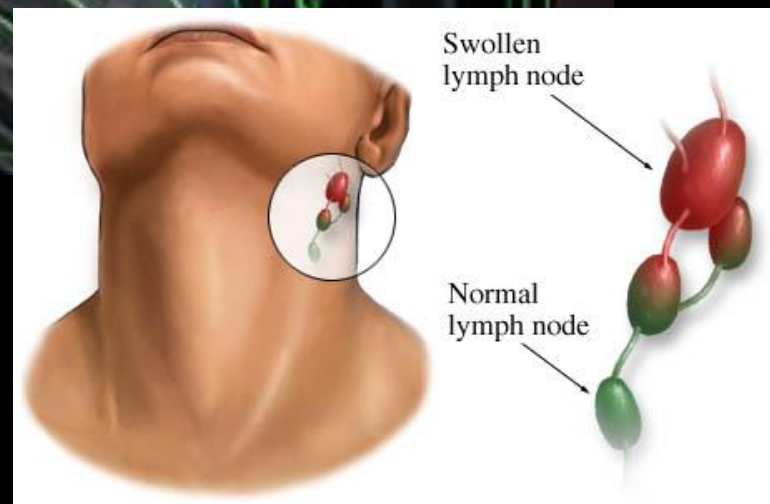
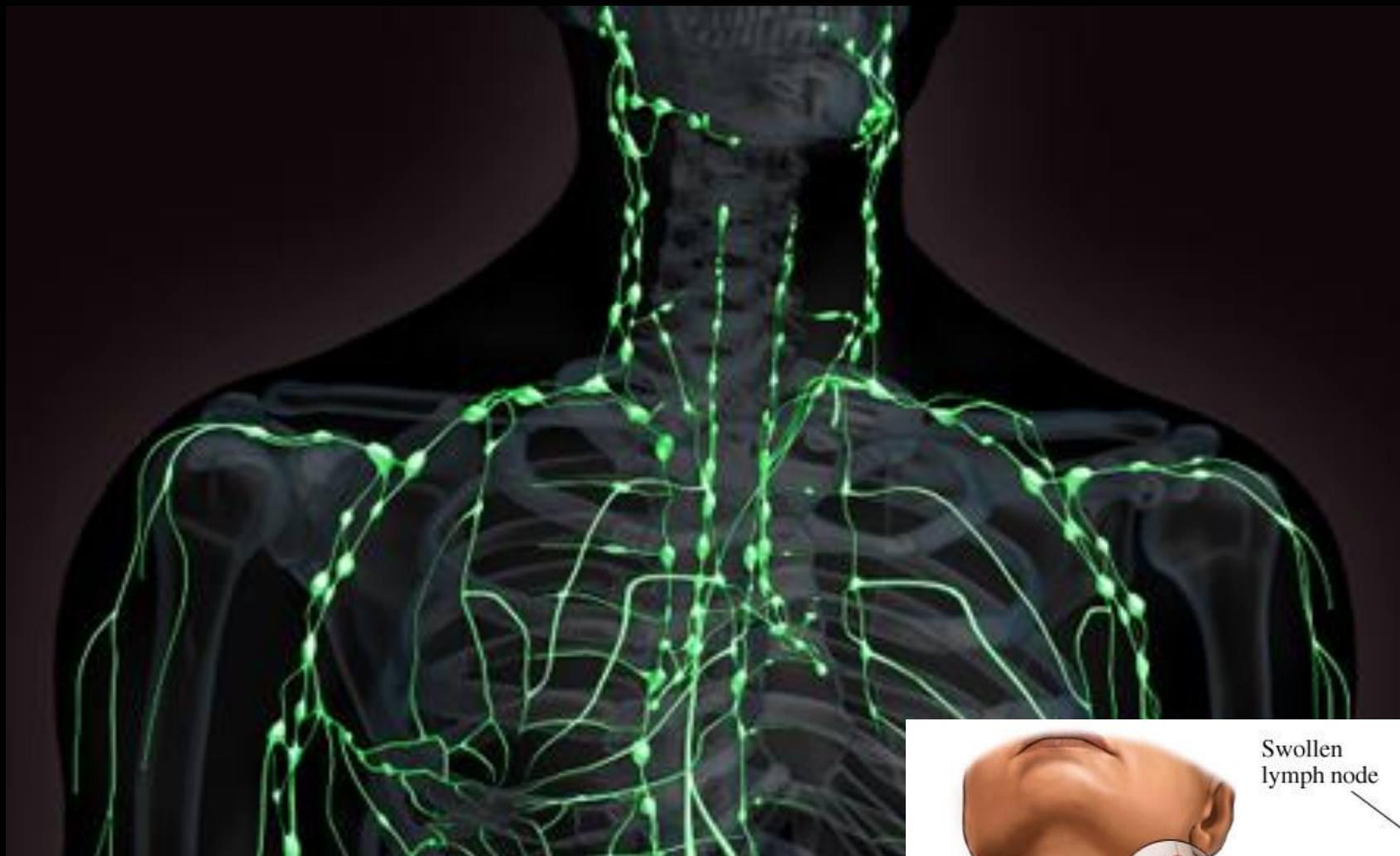
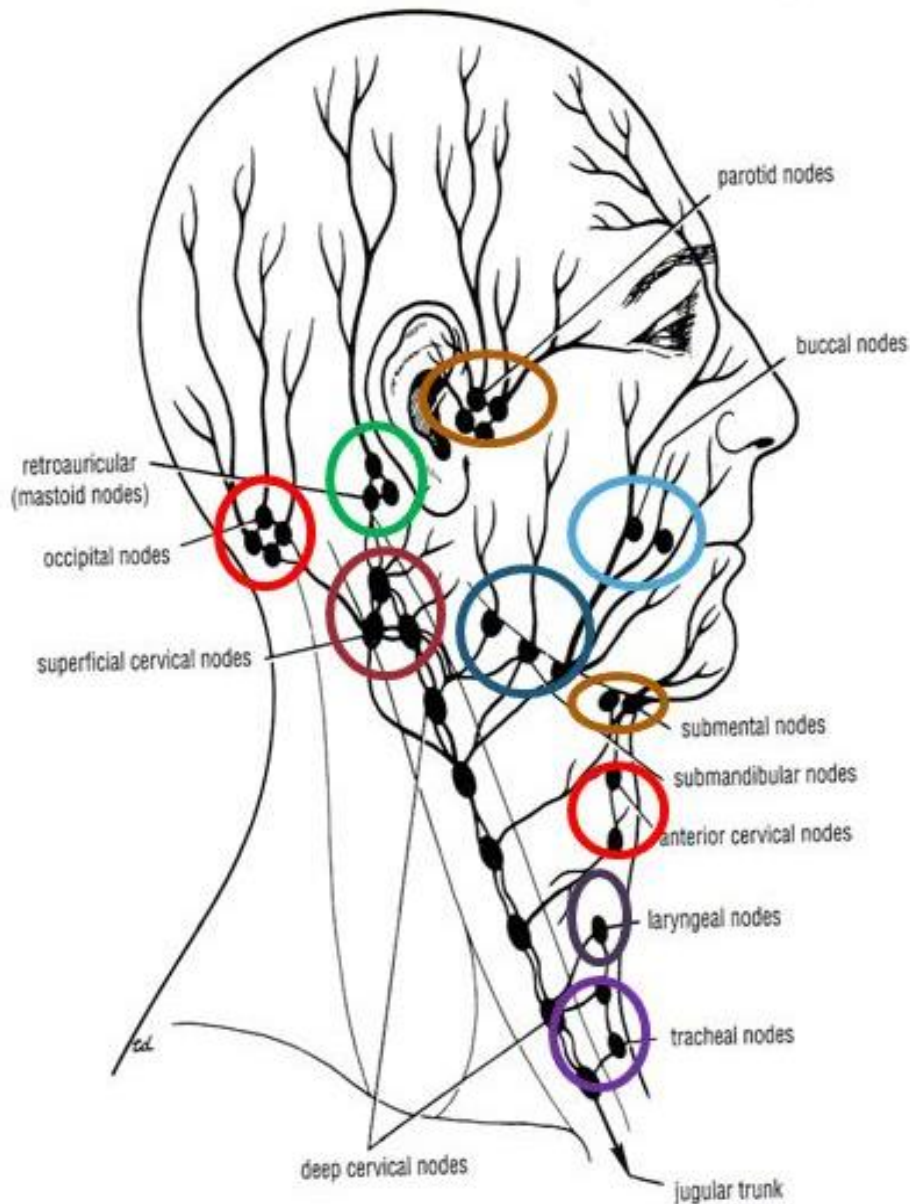


Lymphatic drainage of the head and neck

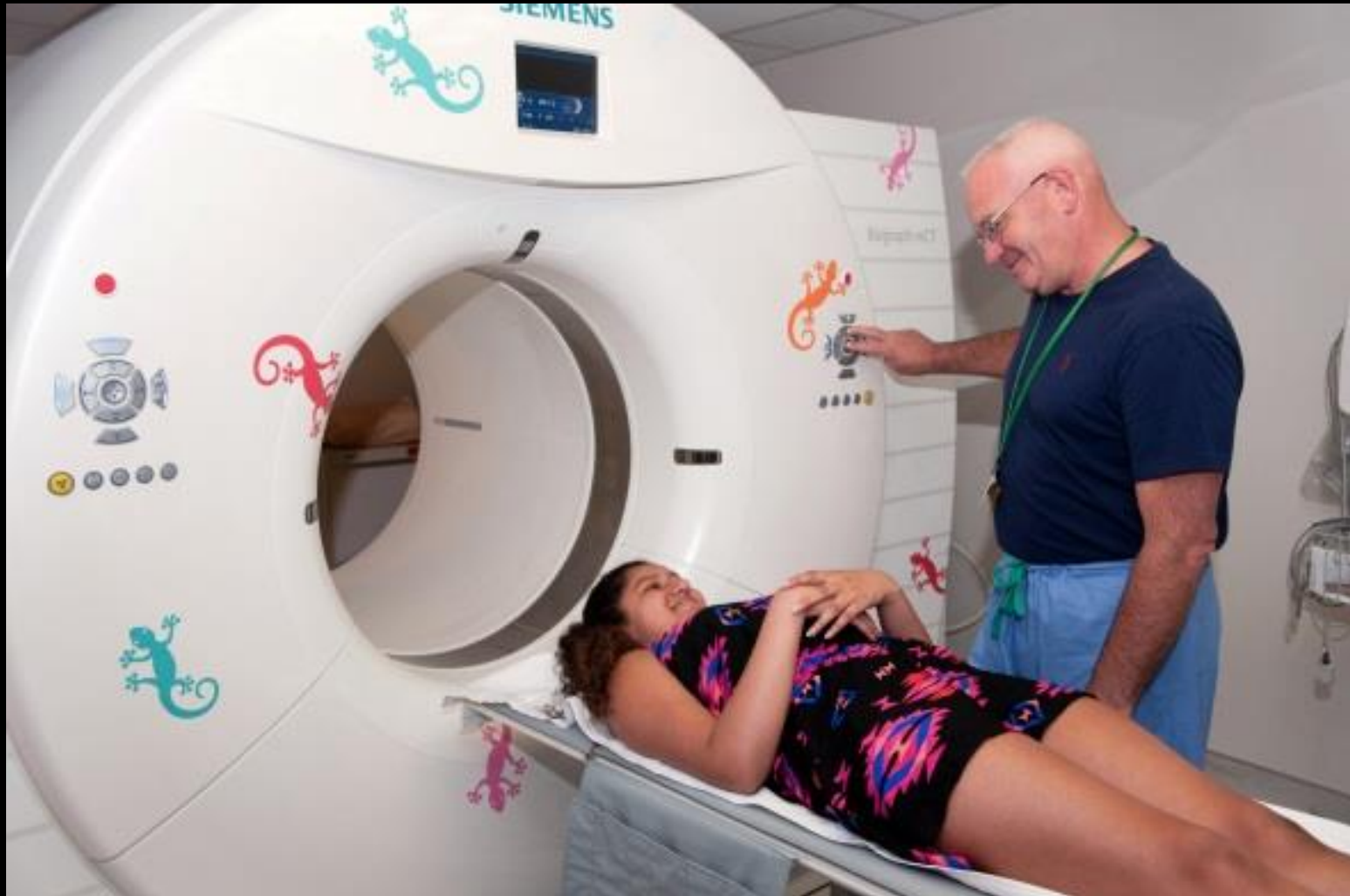János Barna



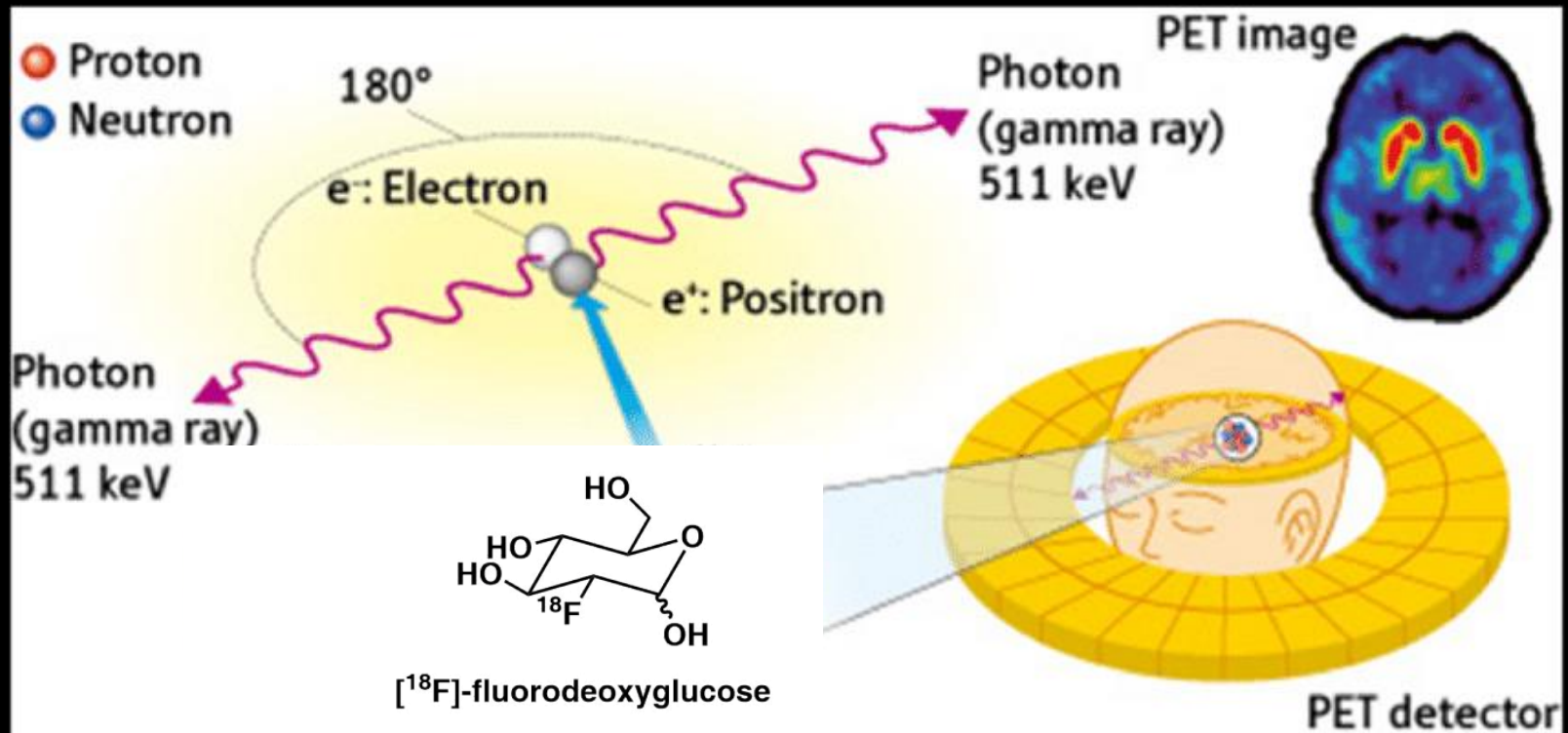


- 1- Occipital.
- 2- Mastoid or retroauricular
- 3- Parotid or preauricular
- 4- Buccal or facial.
- 5- Submandibular.
- 6- Submental.
- 7- Anterior cervical
- 8- Superficial cervical
- 9- Laryngeal.
- 10- Tracheal.
- 11- Retropharyngeal.

Positron Emission Tomography (PET)

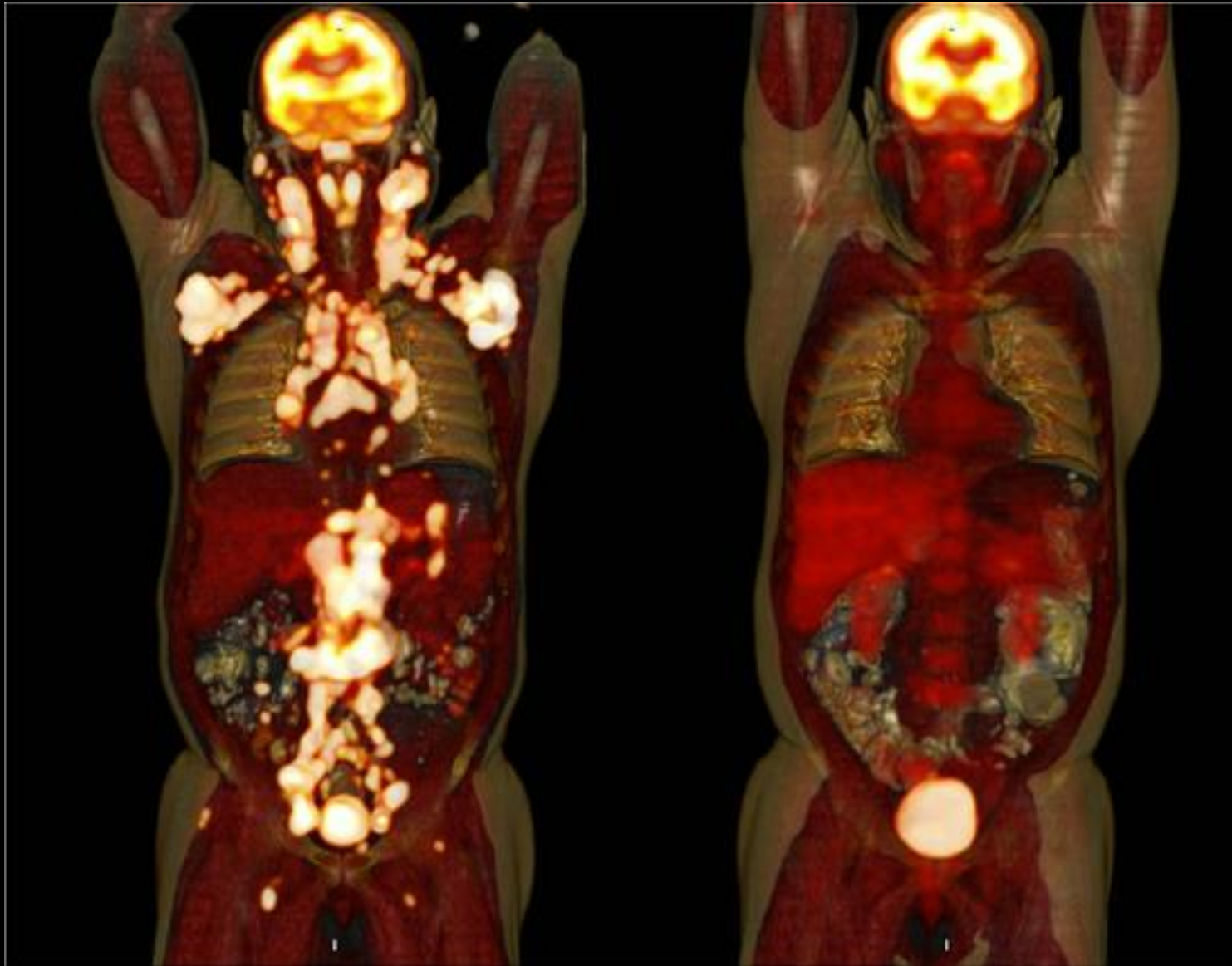

Positron Emission Tomography (PET)

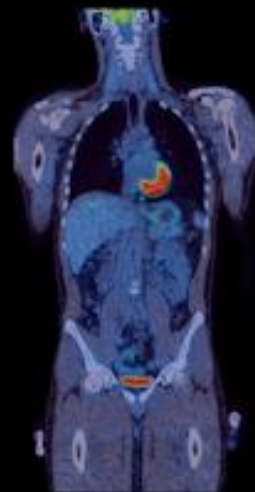
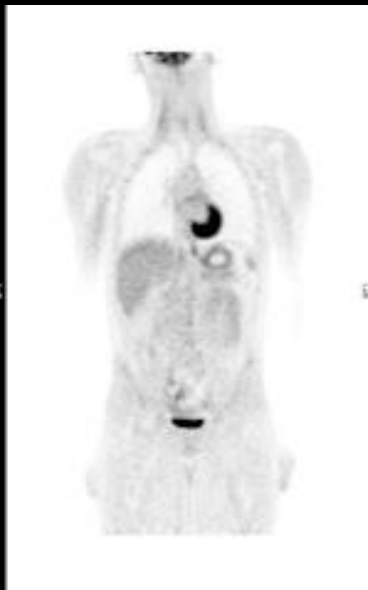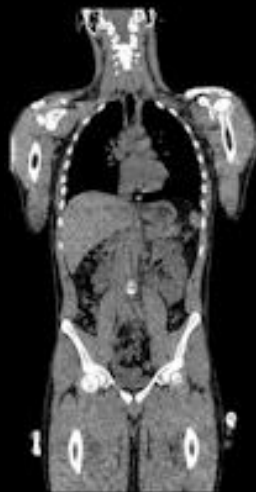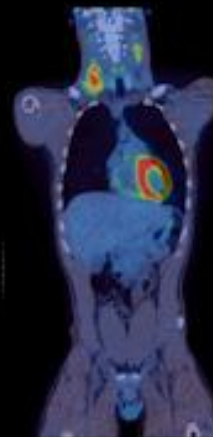


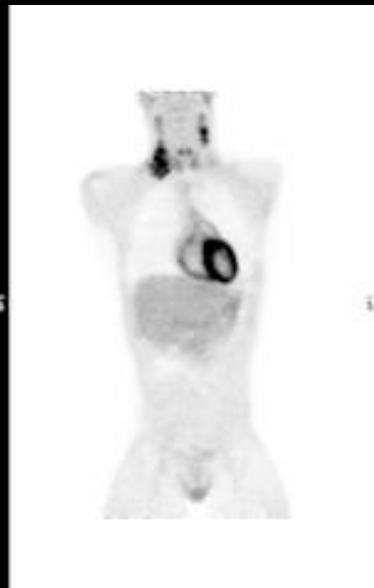
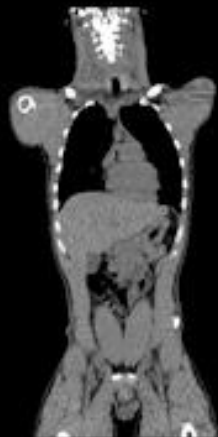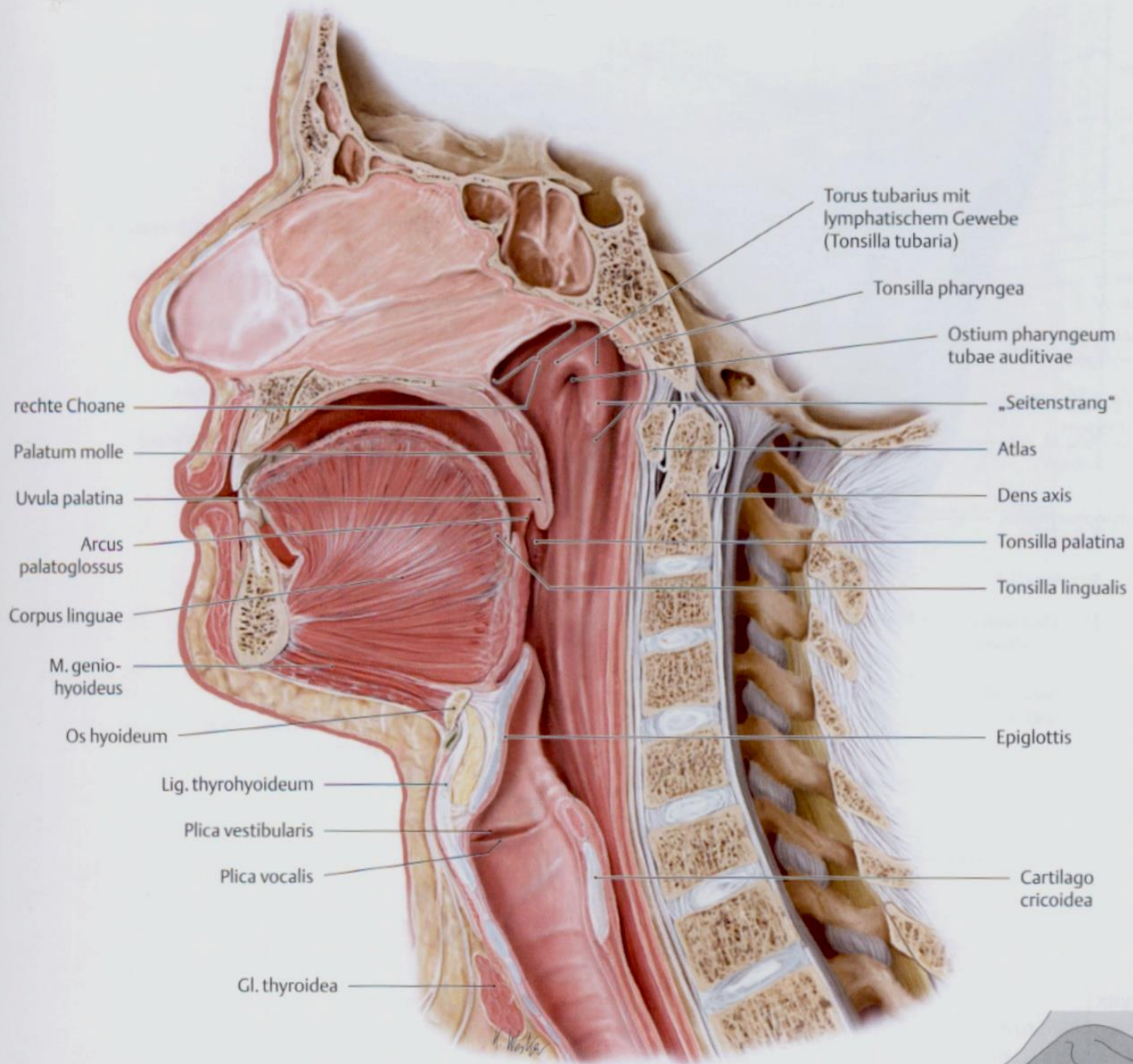
Pretreatment PET/CT scan

Posttreatment PET/CT scan



Pretreatment and posttreatment PET/MR scans





Metastatic tumor is located in the submandibular lymph nodes

