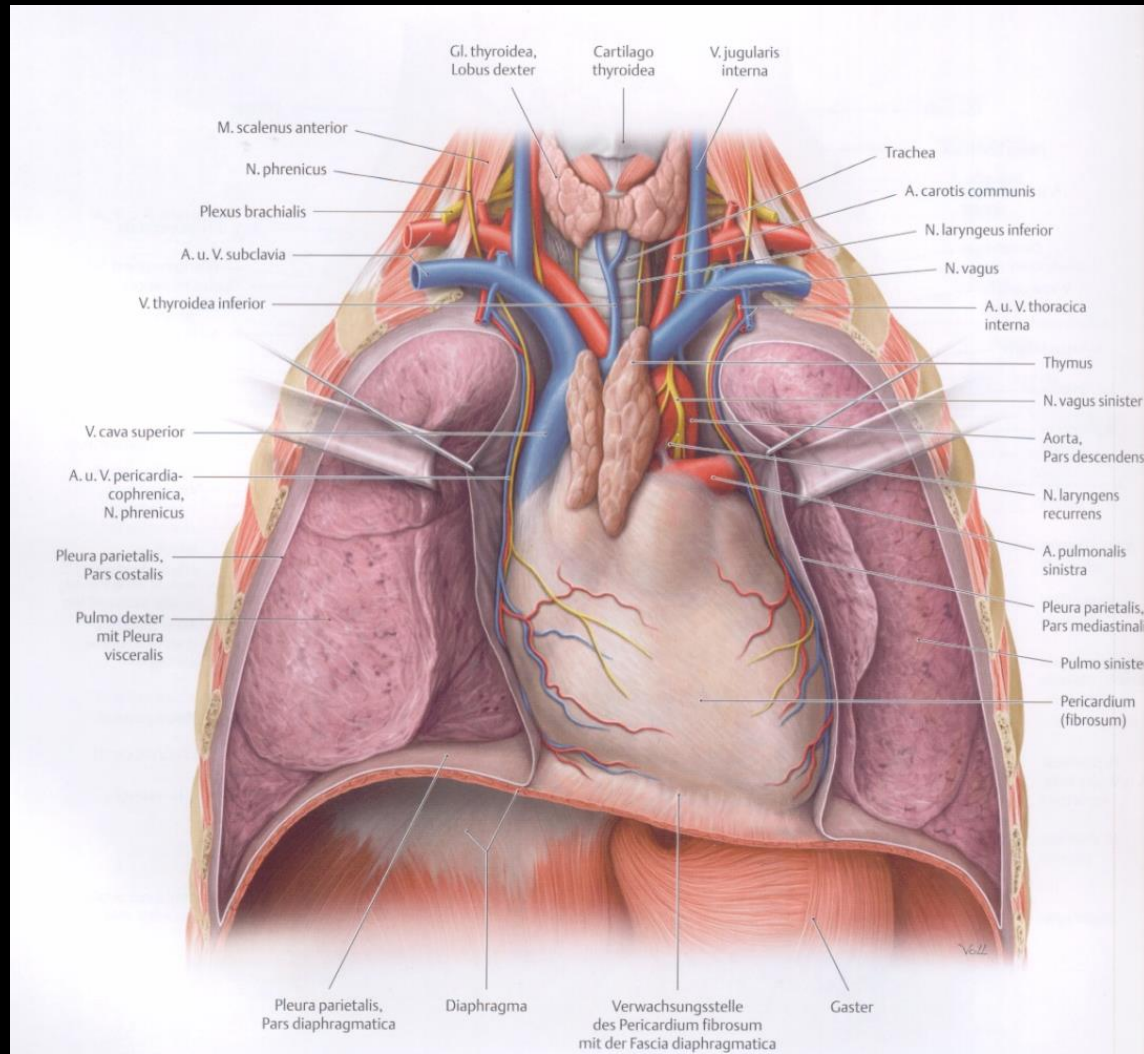
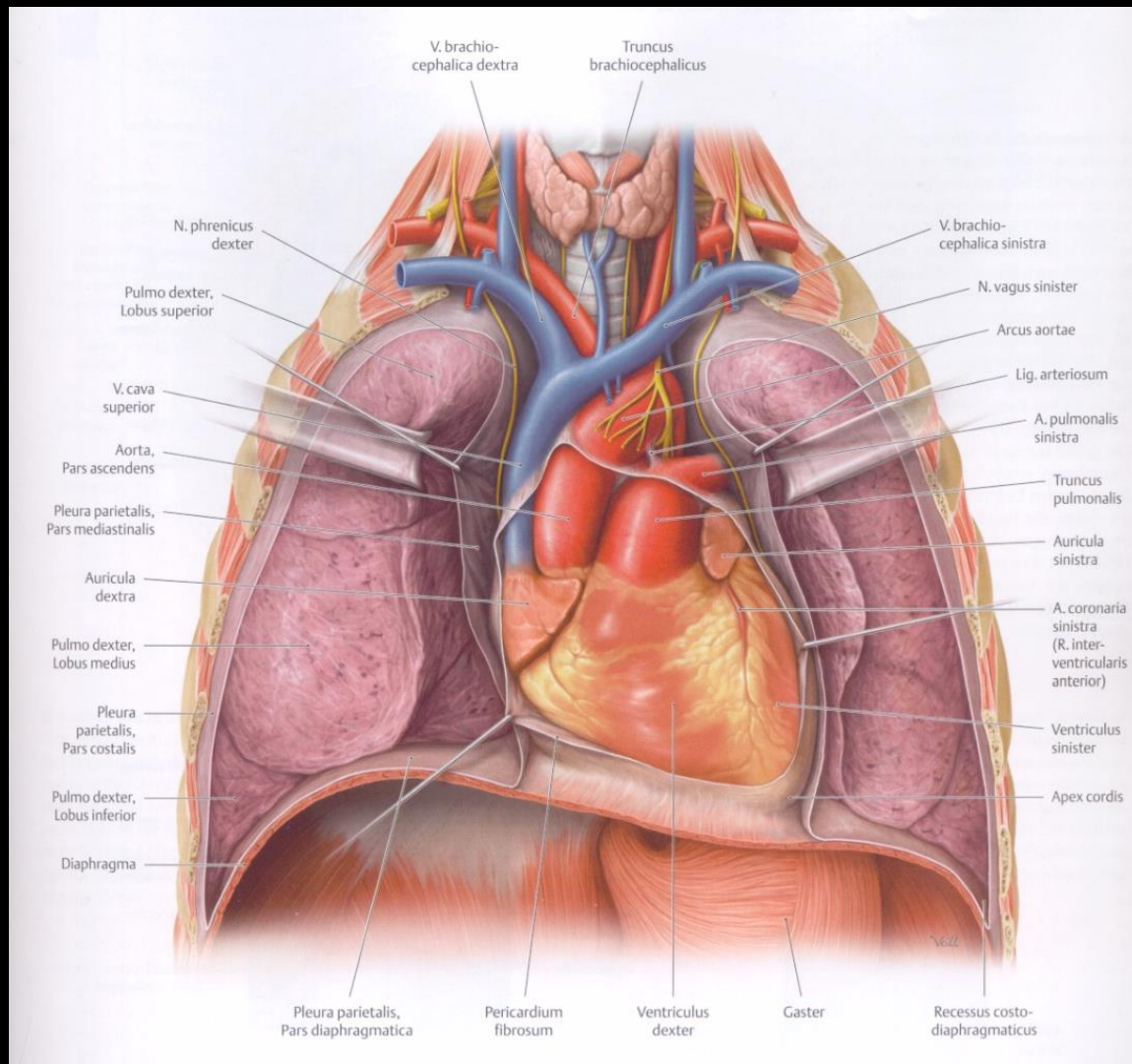


Vessels, innervation, conducting system,
surface projection of the heart; pericardium

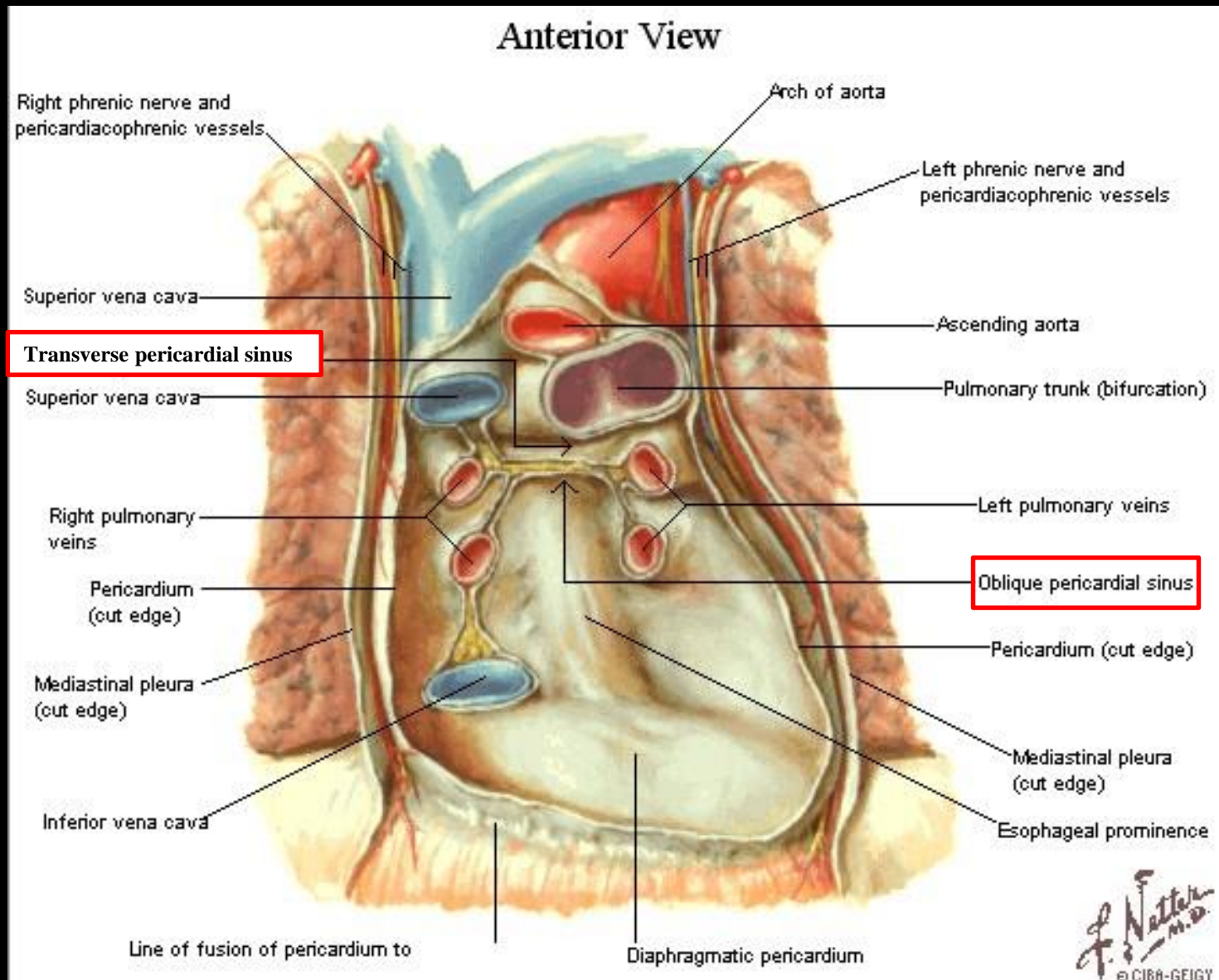
Barna János

Pericardium



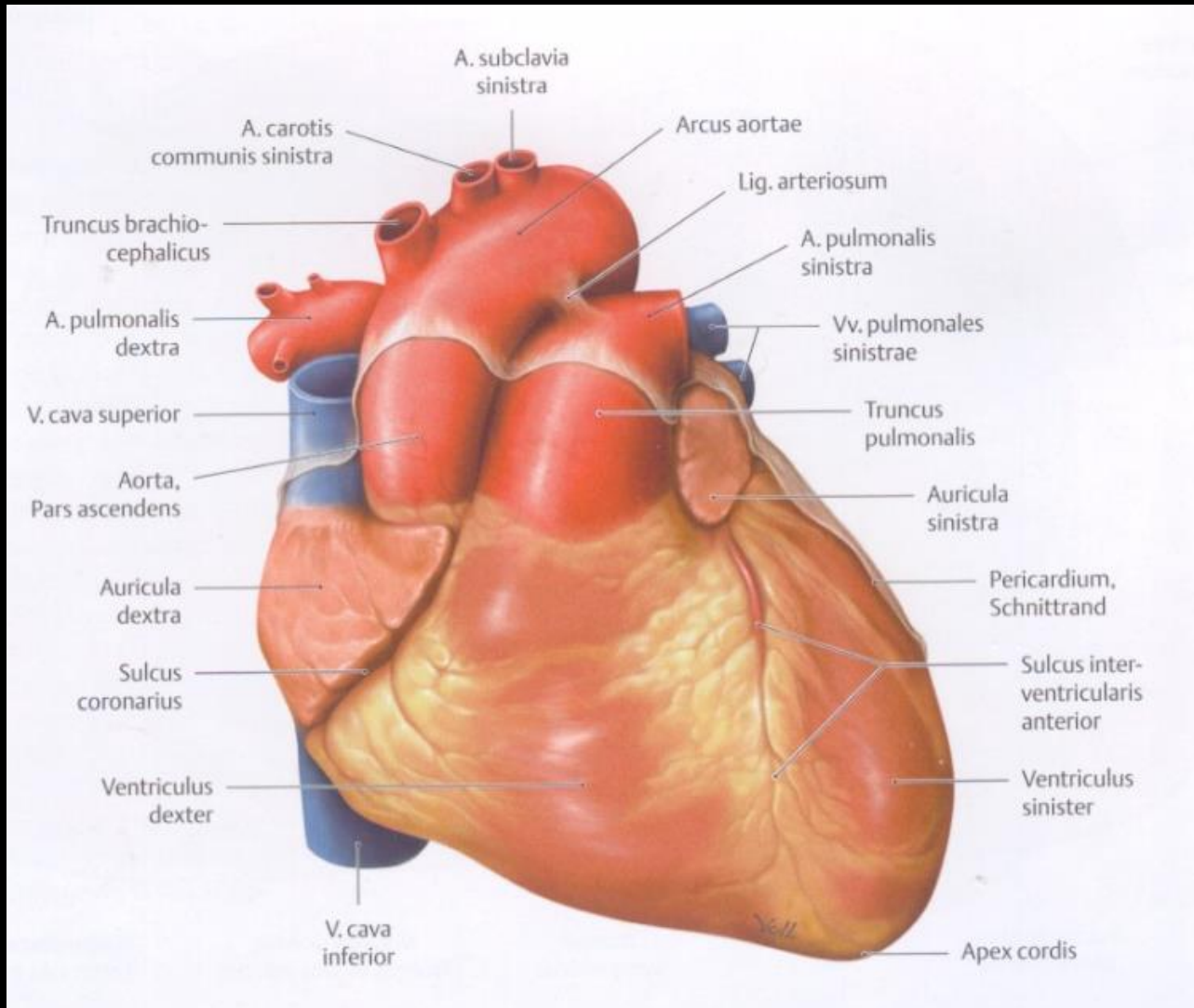


Pericardial reflexions



Pericardial reflexions

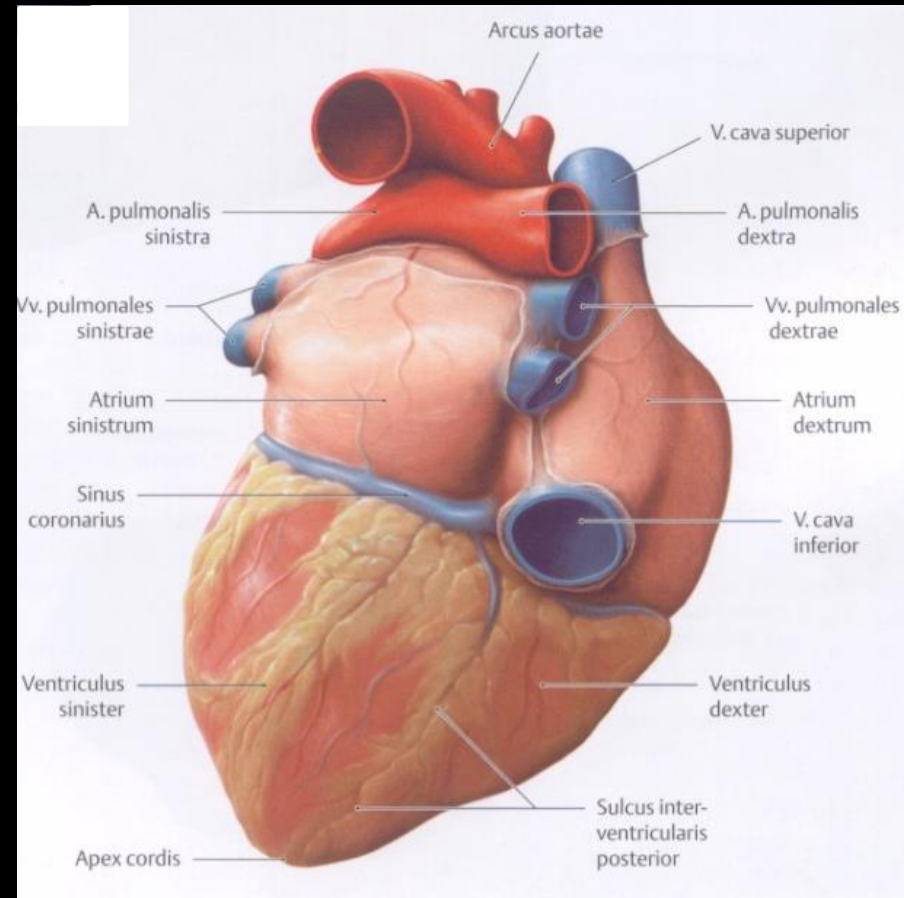
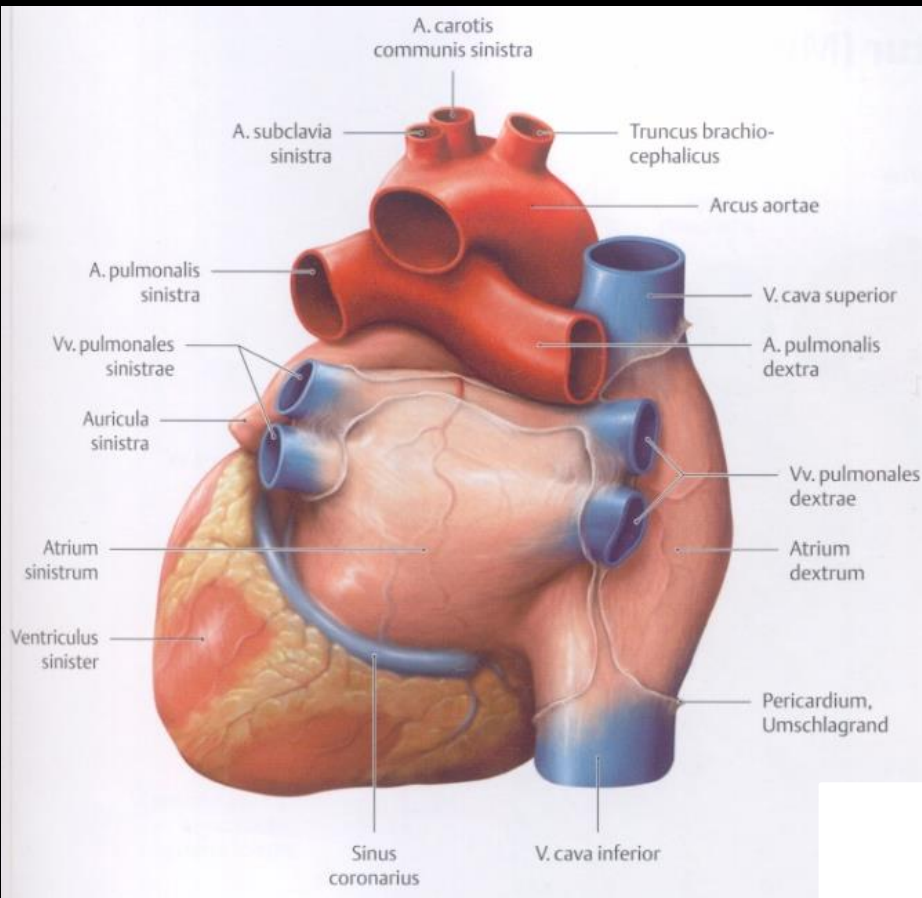
anterior view



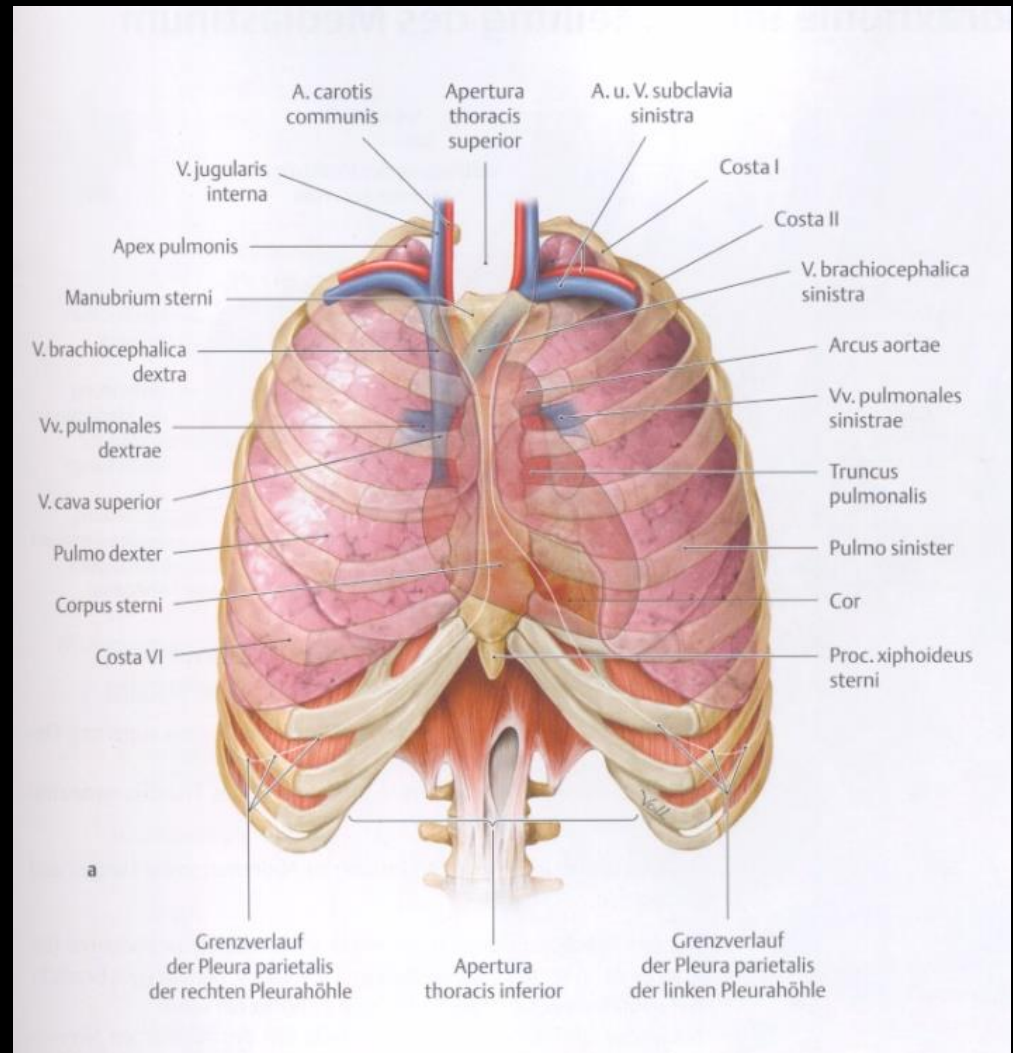
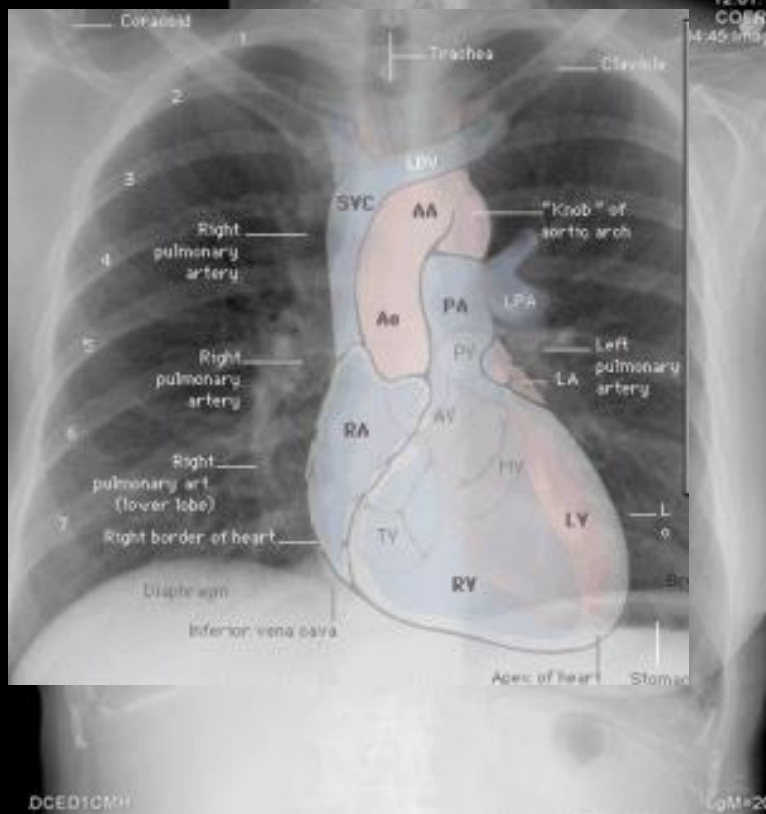
Pericardial reflexions

postero-superior view

posterior view

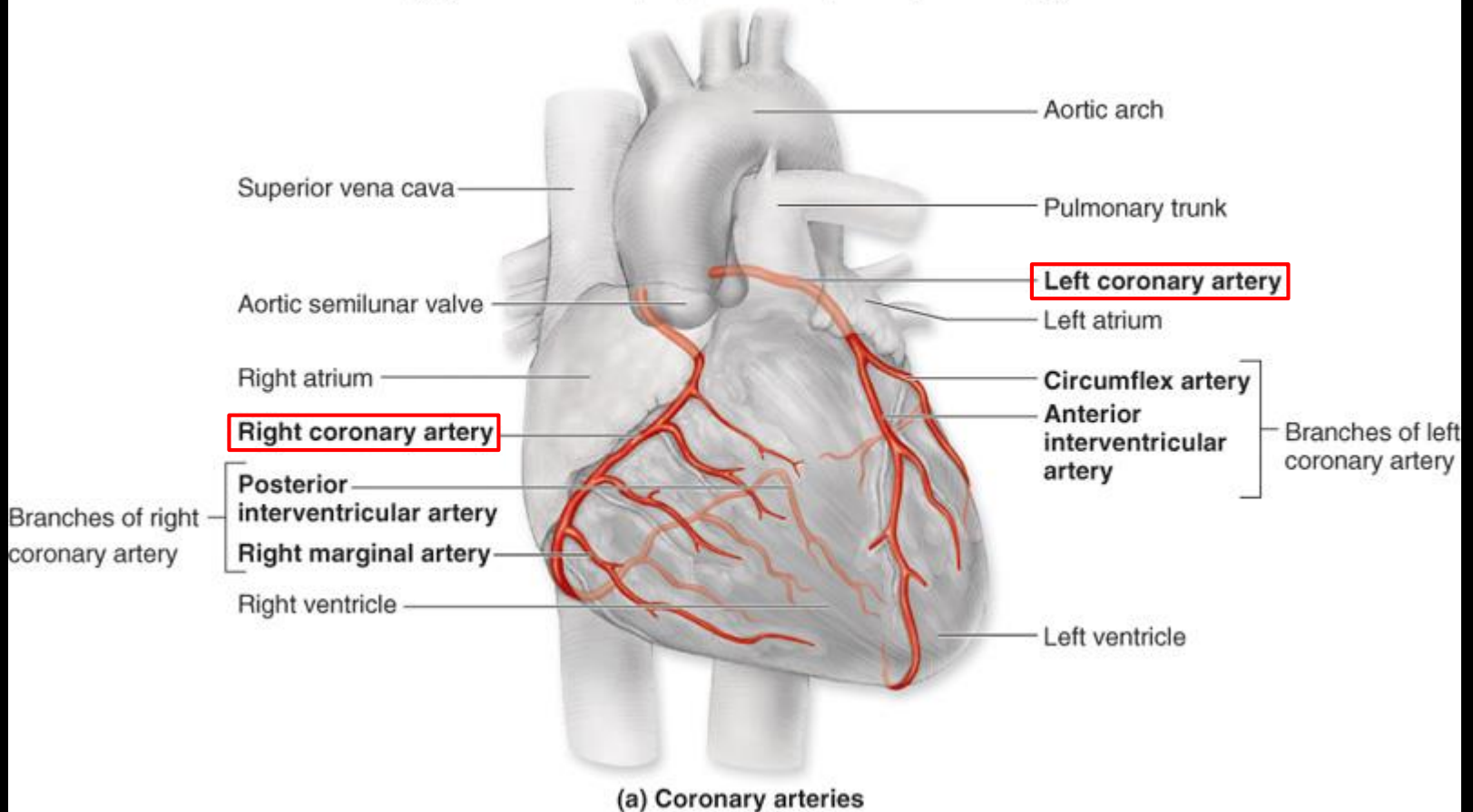


Location and surface projection of the heart

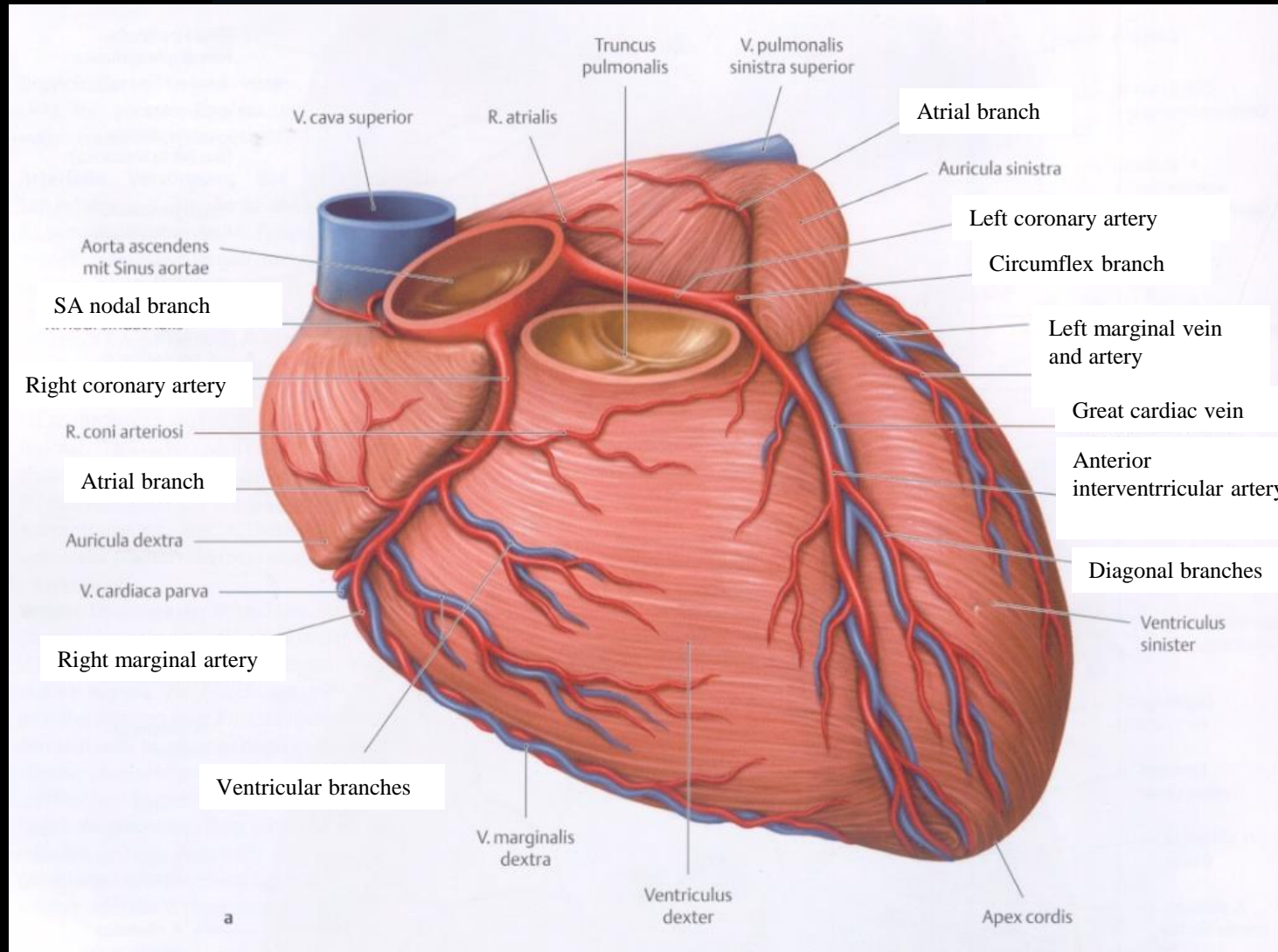


Arteries of the heart

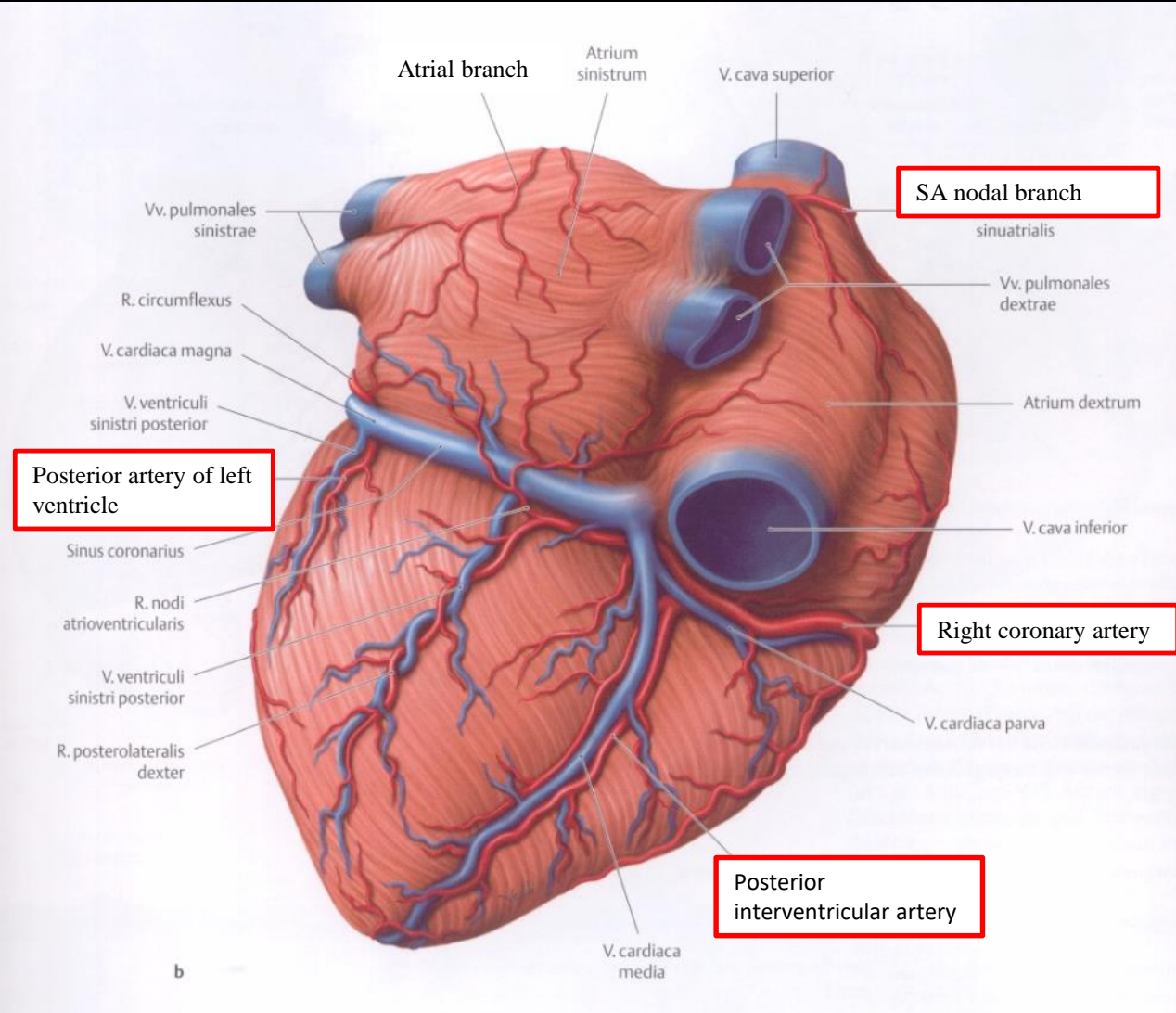
Copyright © The McGraw-Hill Companies, Inc. Permission required for reproduction or display.



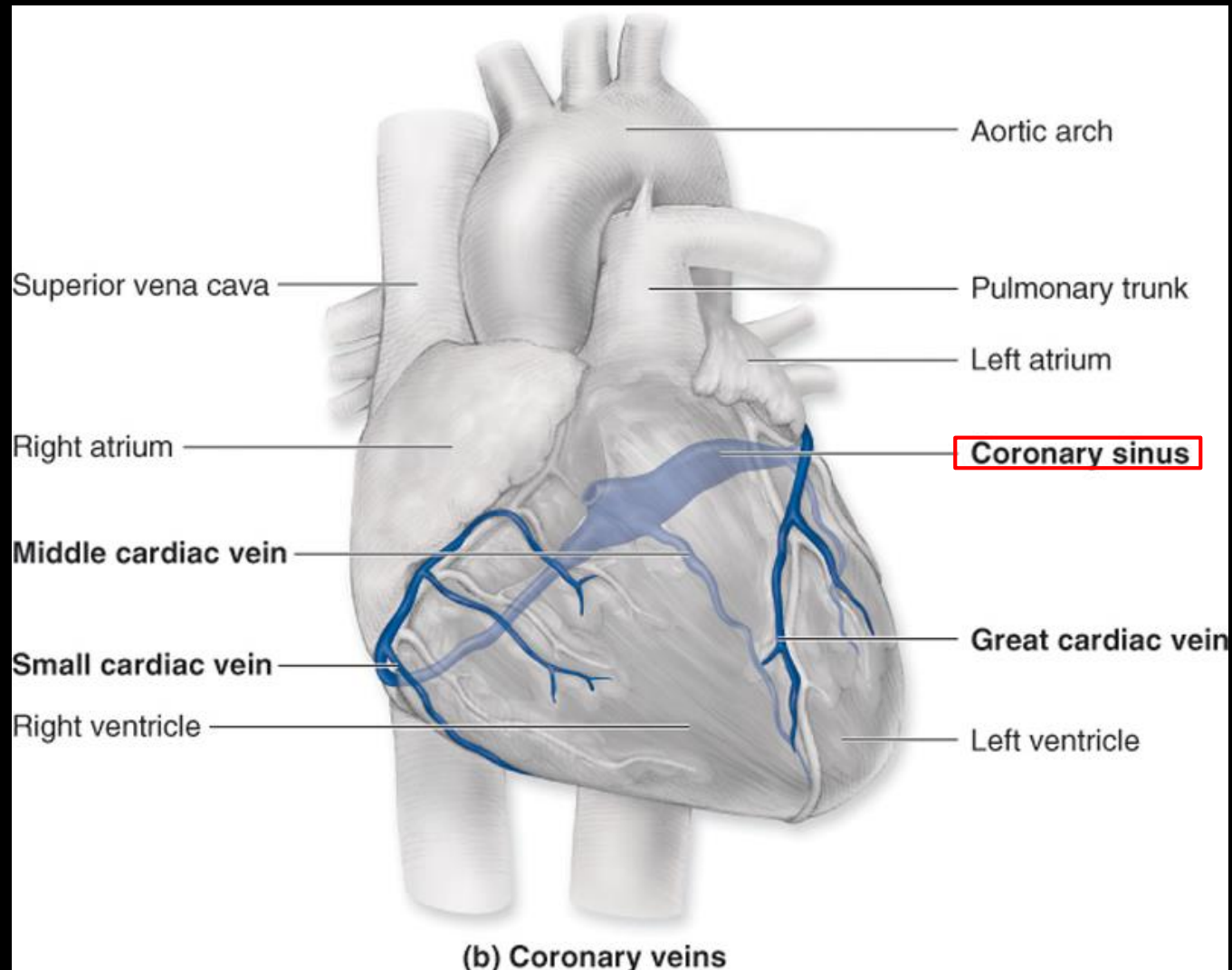
anterior view



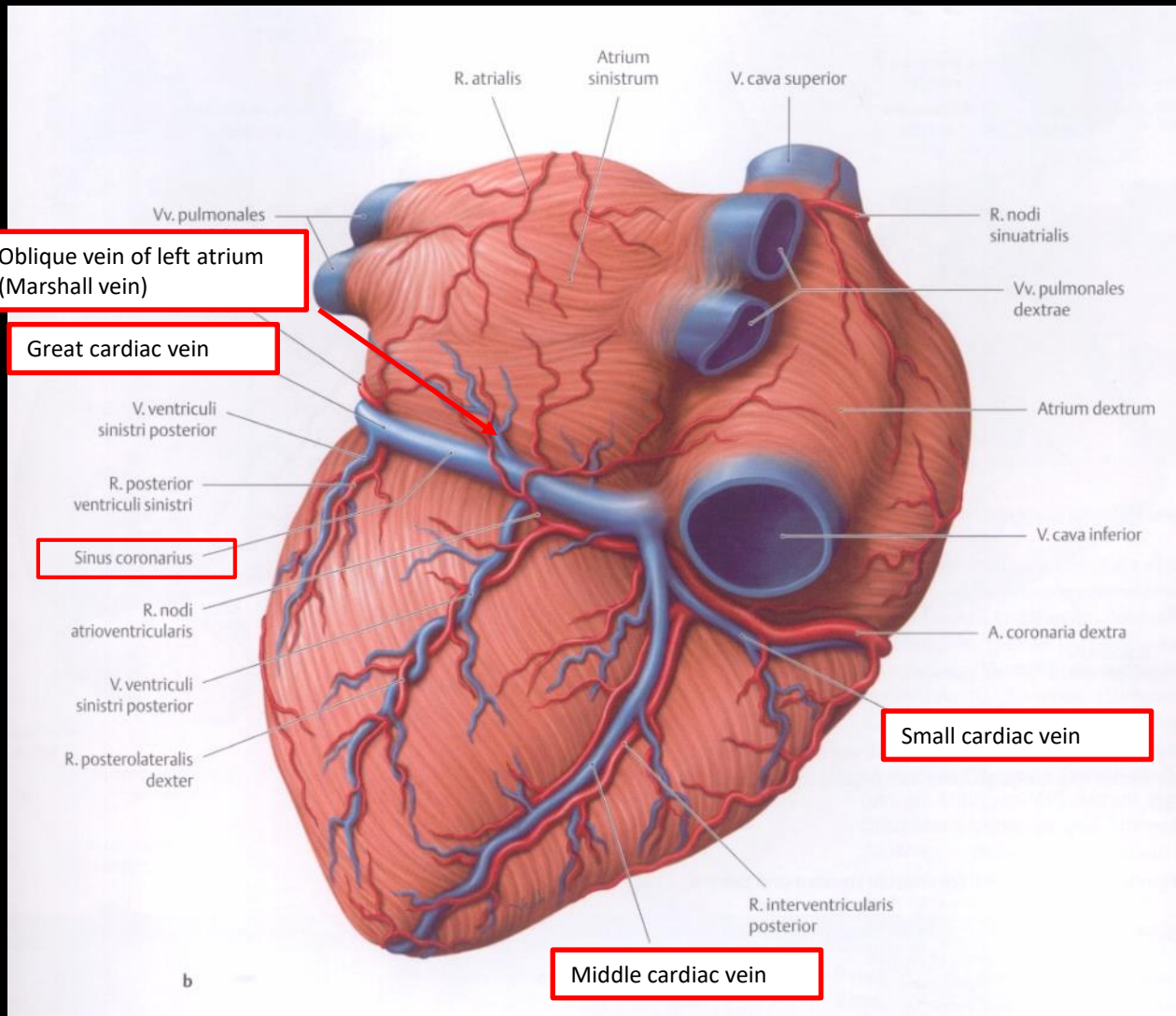
posterior view



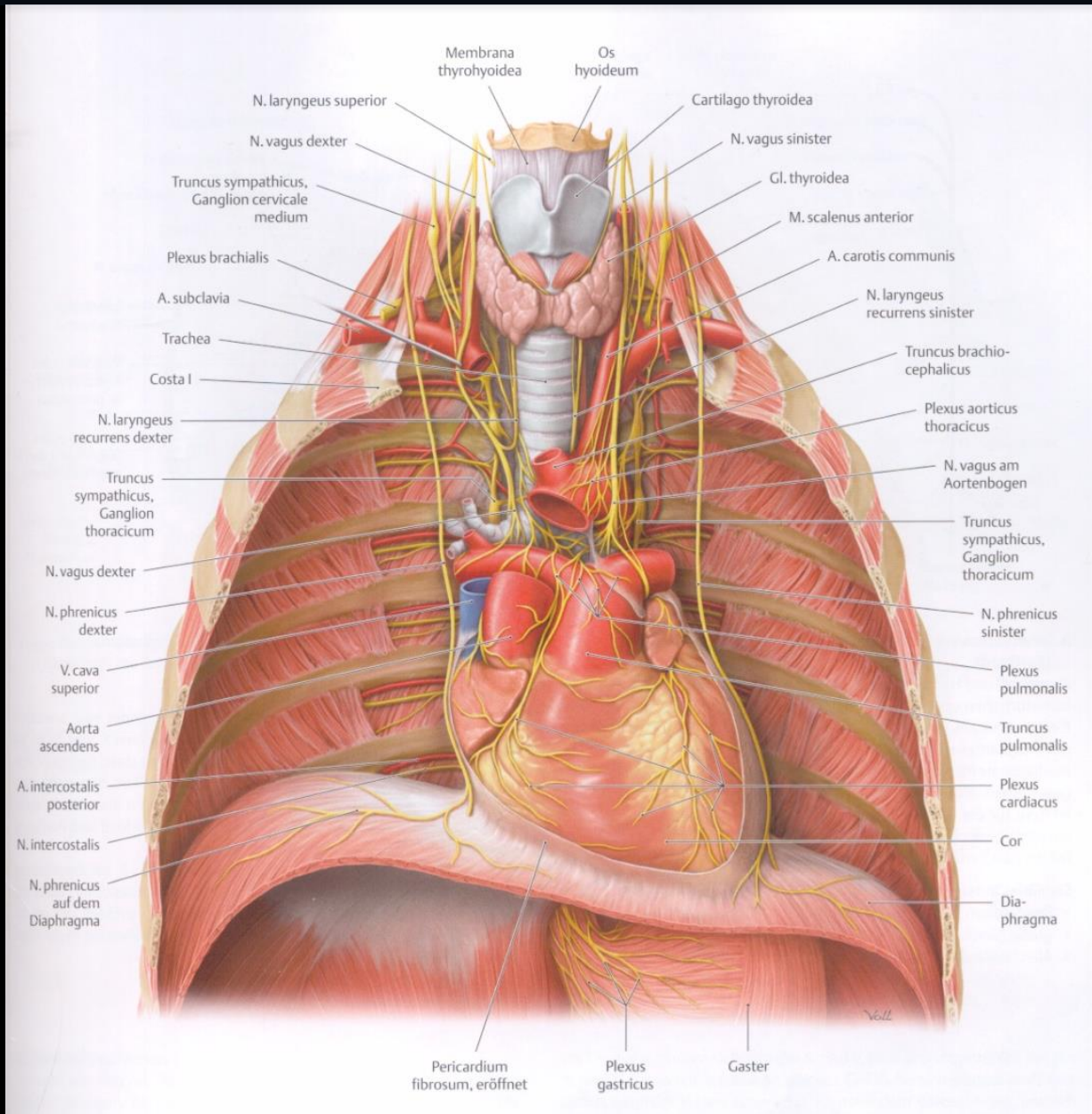
Veins of the heart



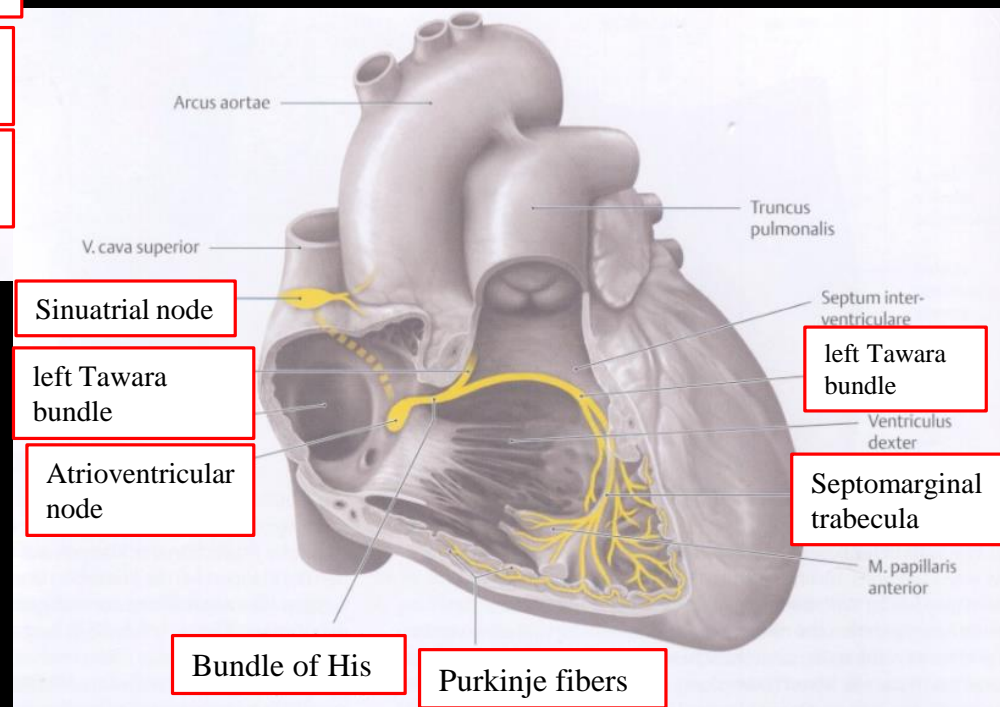
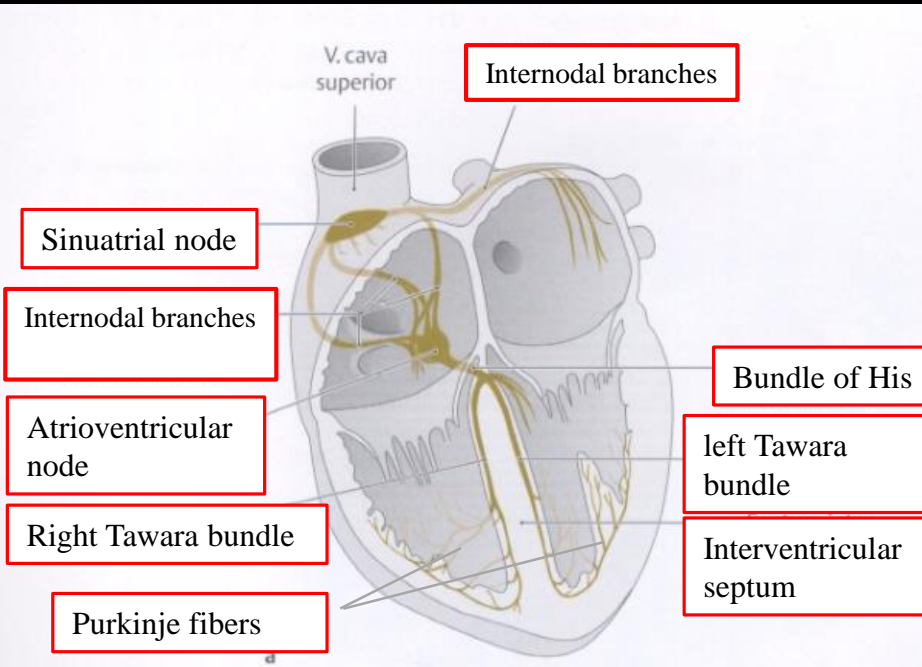
posterior view

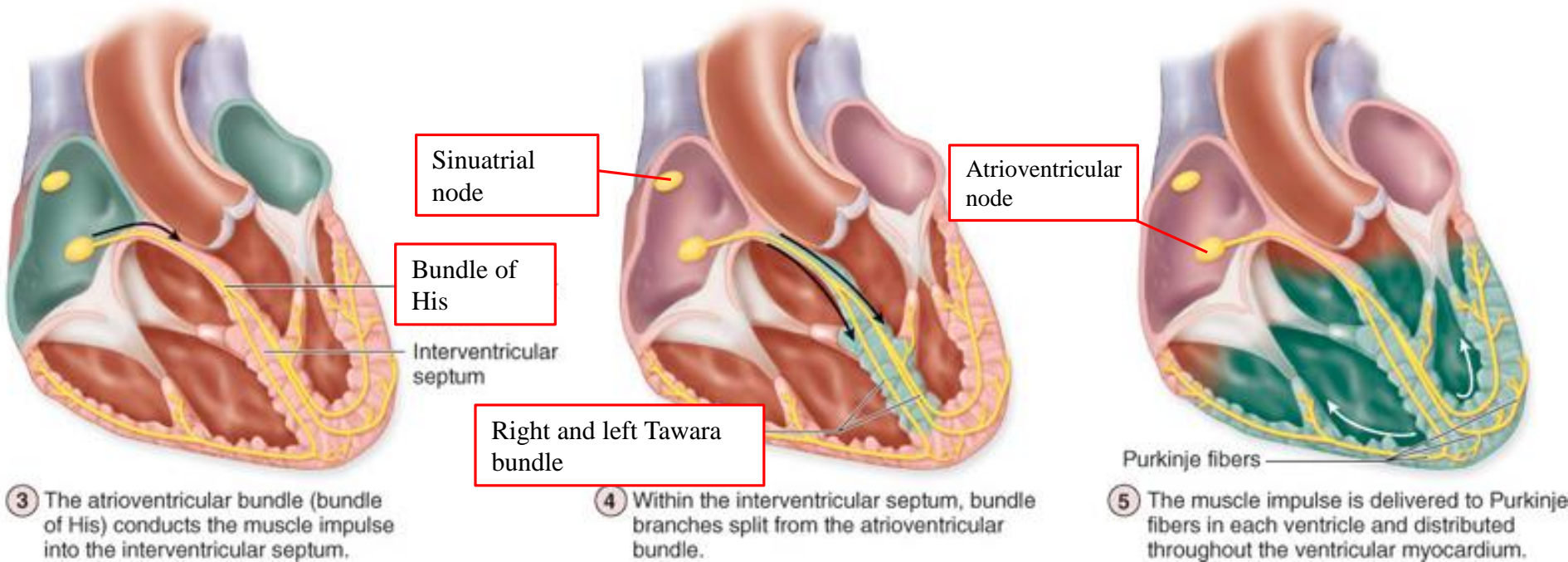


Innervation of the heart



Impulse generating and conducting system





Sinuatrial node

Bundle of His

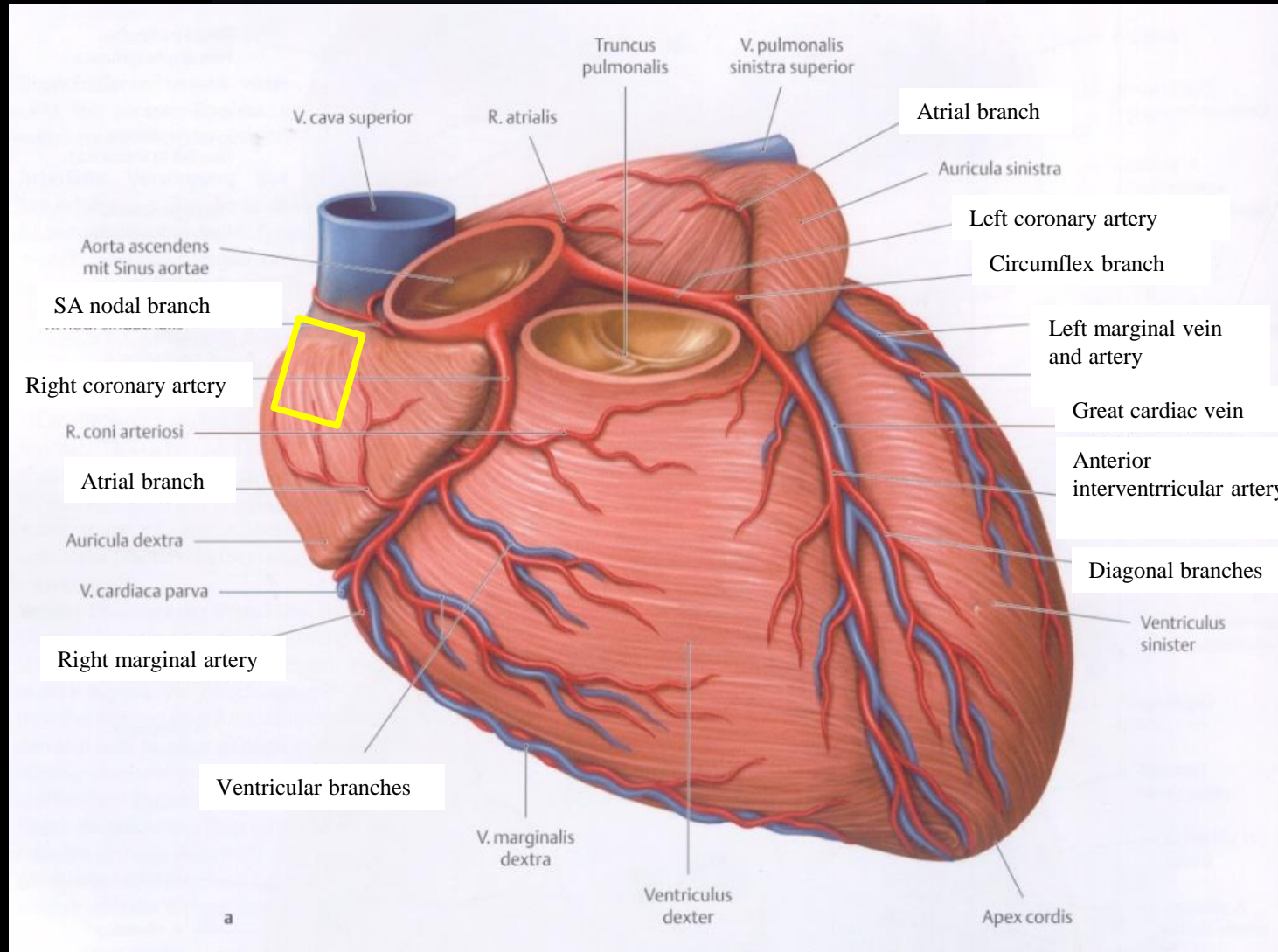
Interventricular septum

Right and left Tawara bundle

Atrioventricular node

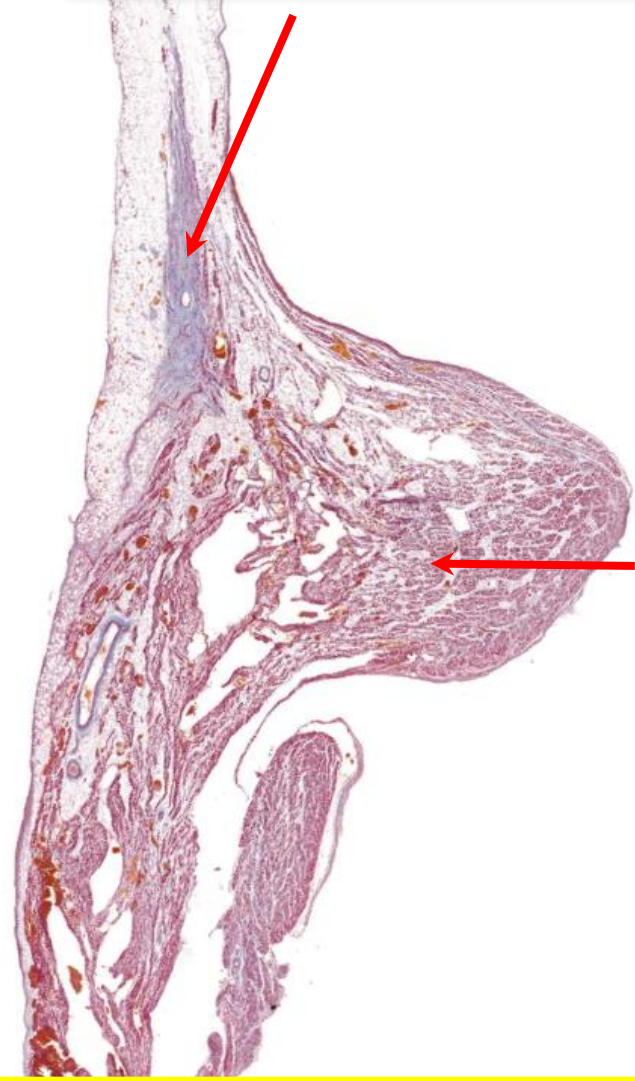
Purkinje fibers

anterior view



5000 μ m

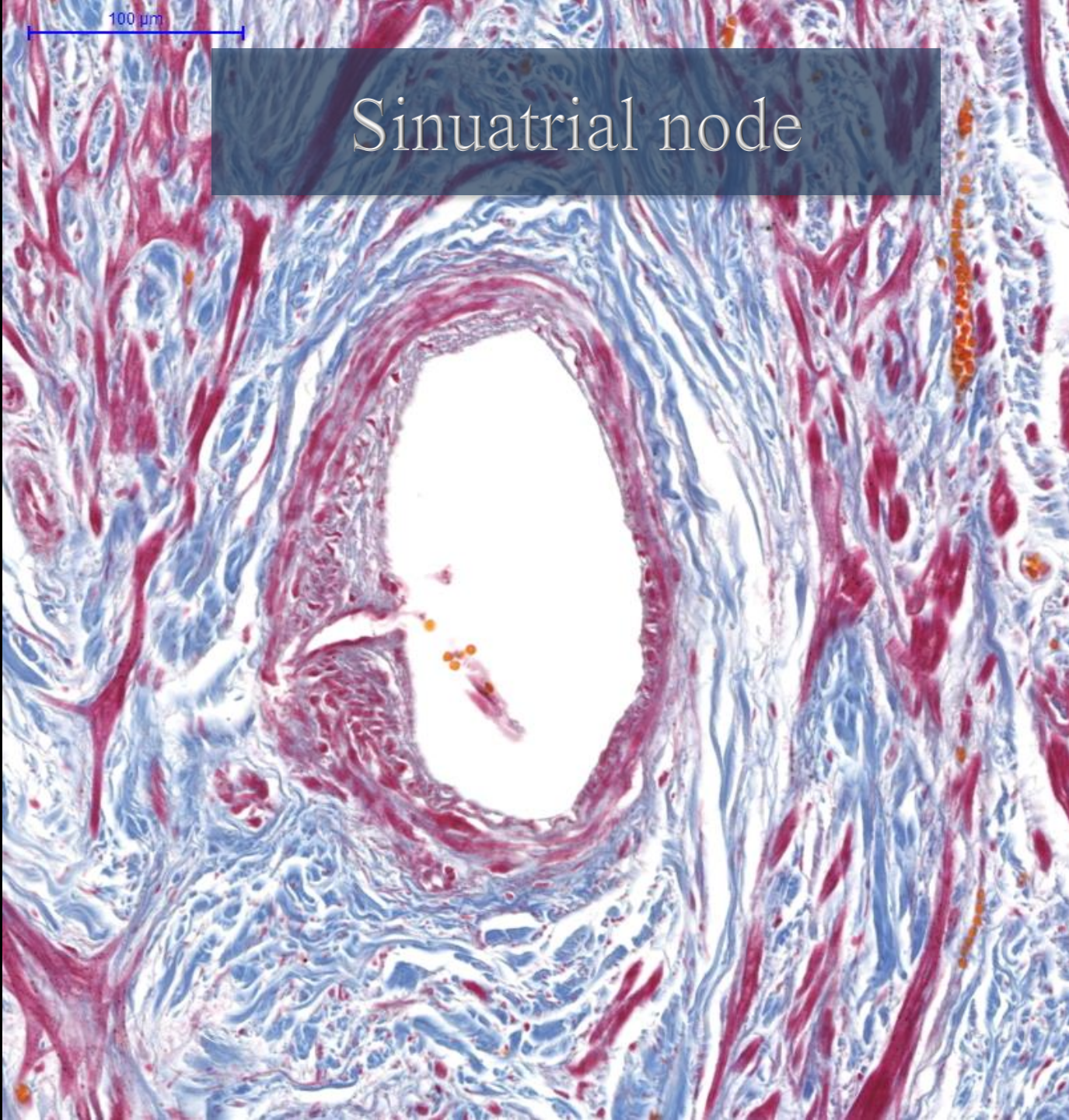
Sinuatrial node



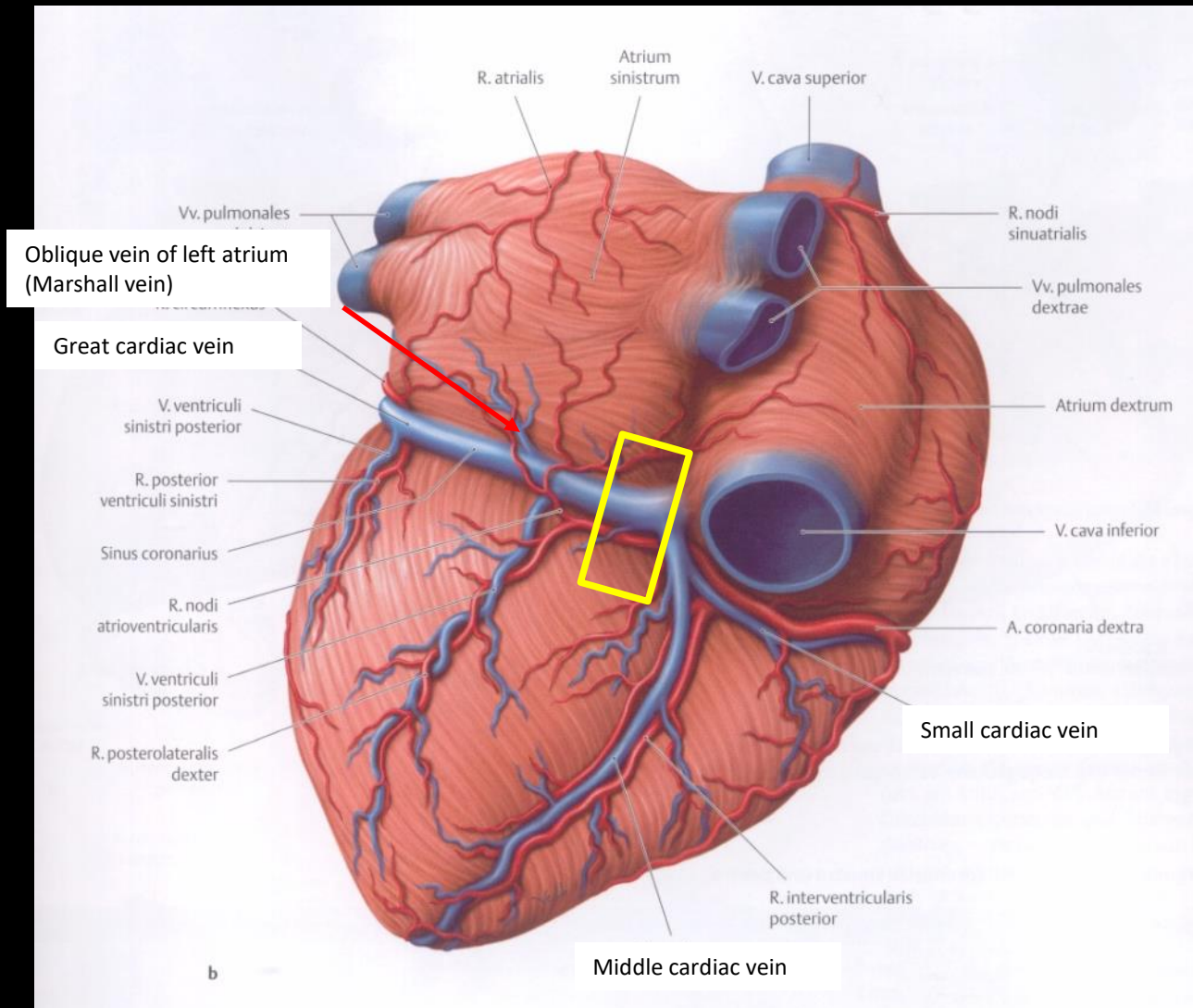
Crista terminalis

100 μ m

Sinuatrial node



posterior view



5000 μm

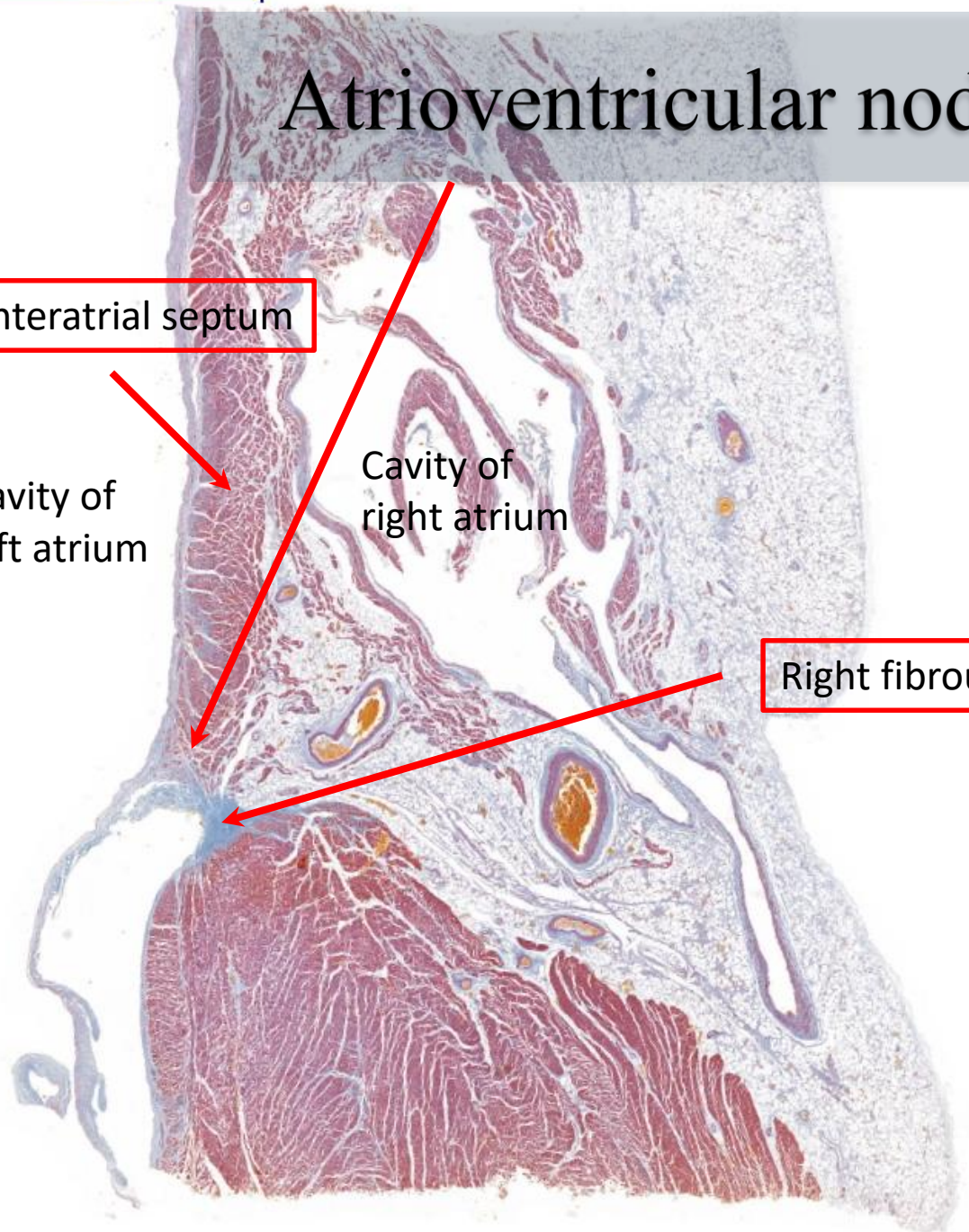
Atrioventricular node

Interatrial septum

Cavity of left atrium

Cavity of right atrium

Right fibrous trigone



Atrioventricular node

