



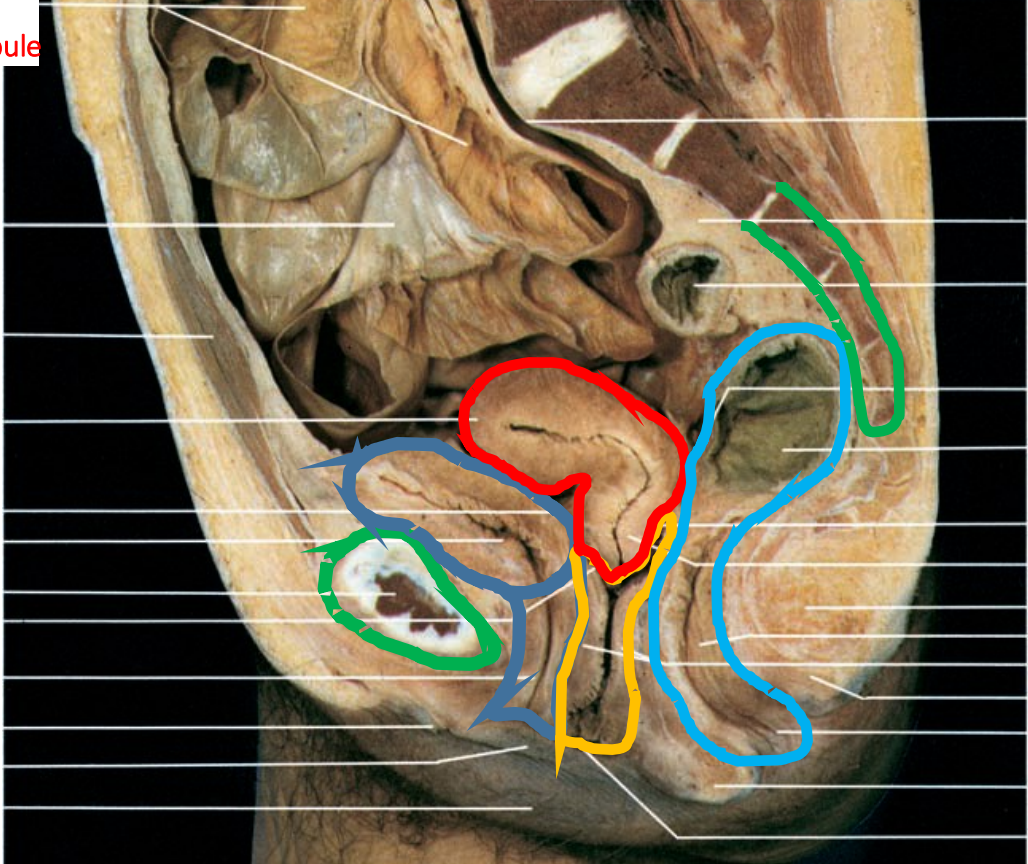
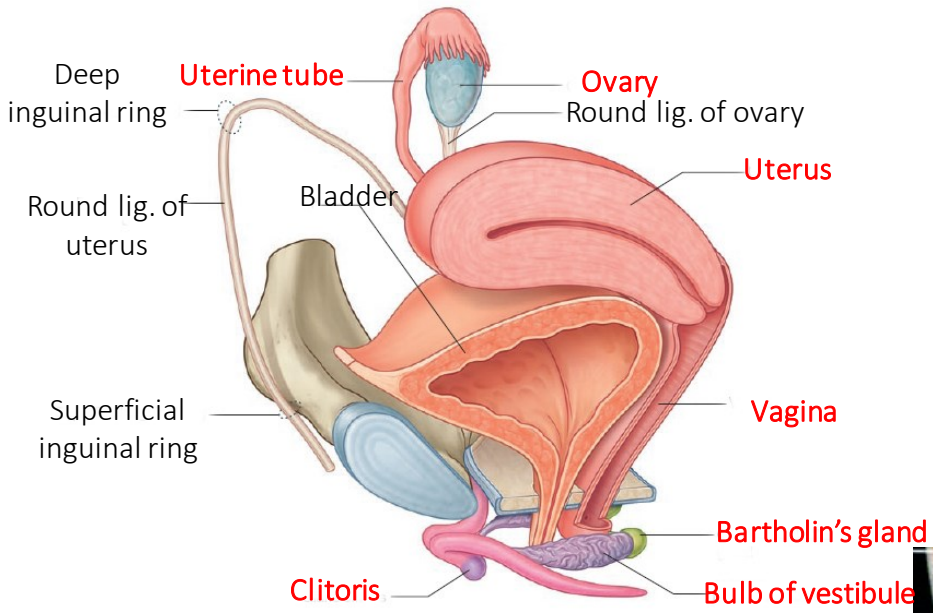
Leonardo da Vinci: Leda and the swan

Morphology and histology of the vagina and the external genital organs.

Emese Pálfi

Semmelweis University

Department of Anatomy, Histology and Embryology



Morphology of the vagina

Anterior wall - 6 to 7.5 cm

Posterior wall - 9 cm

Width: 2-3 cm

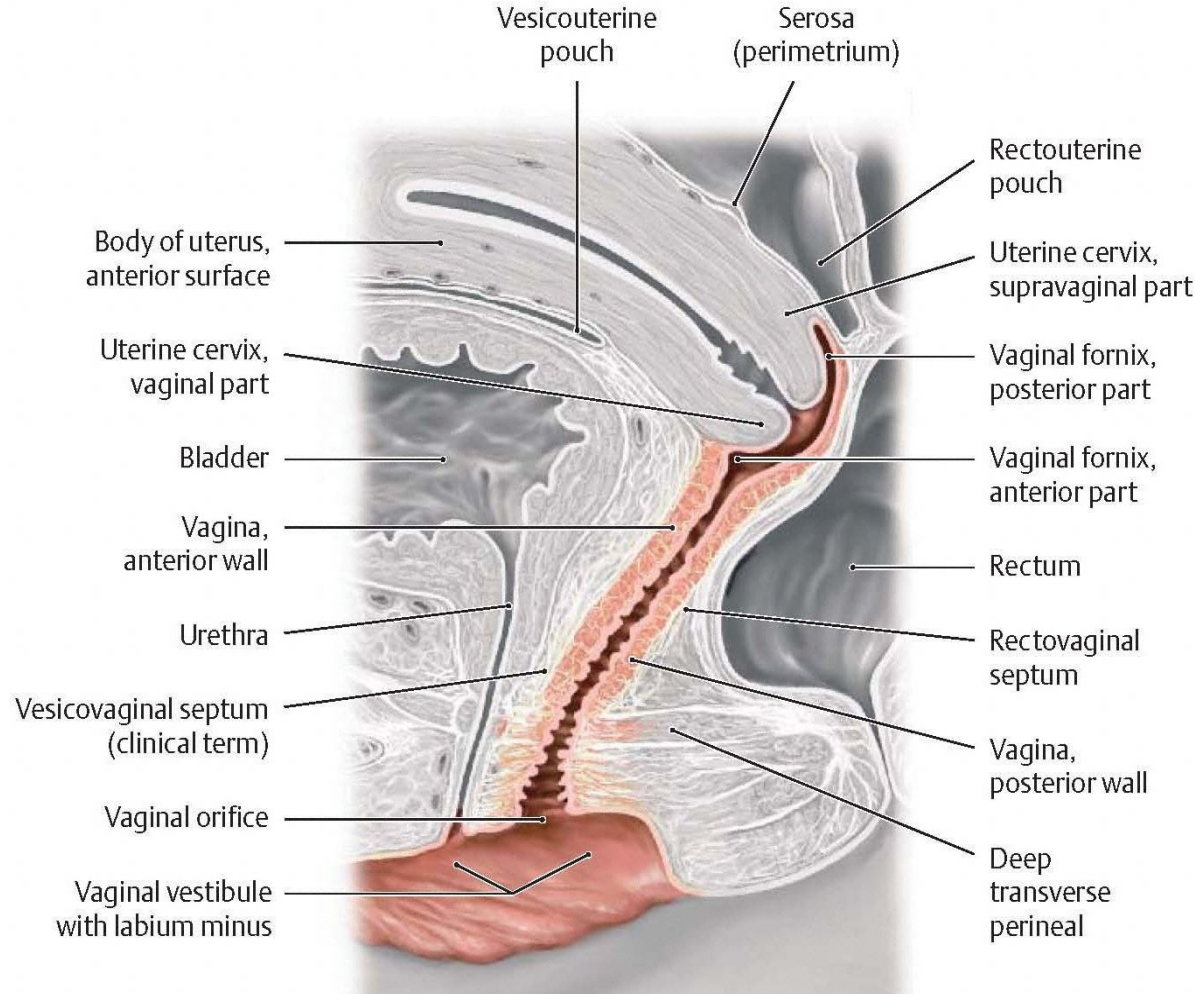
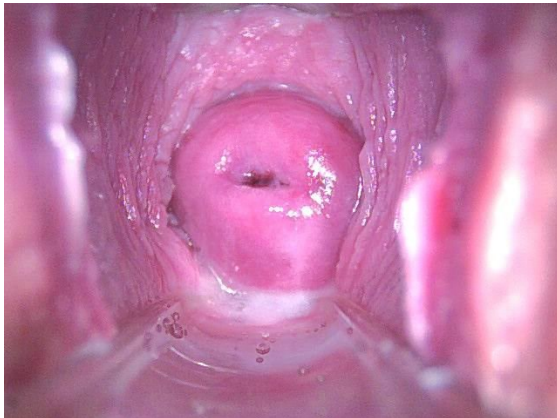Cervix bulges into the vagina

→ Anterior fornix

→ Posterior fornix

→ Lateral fornices

Opening is at the posterior end of the vestibule.

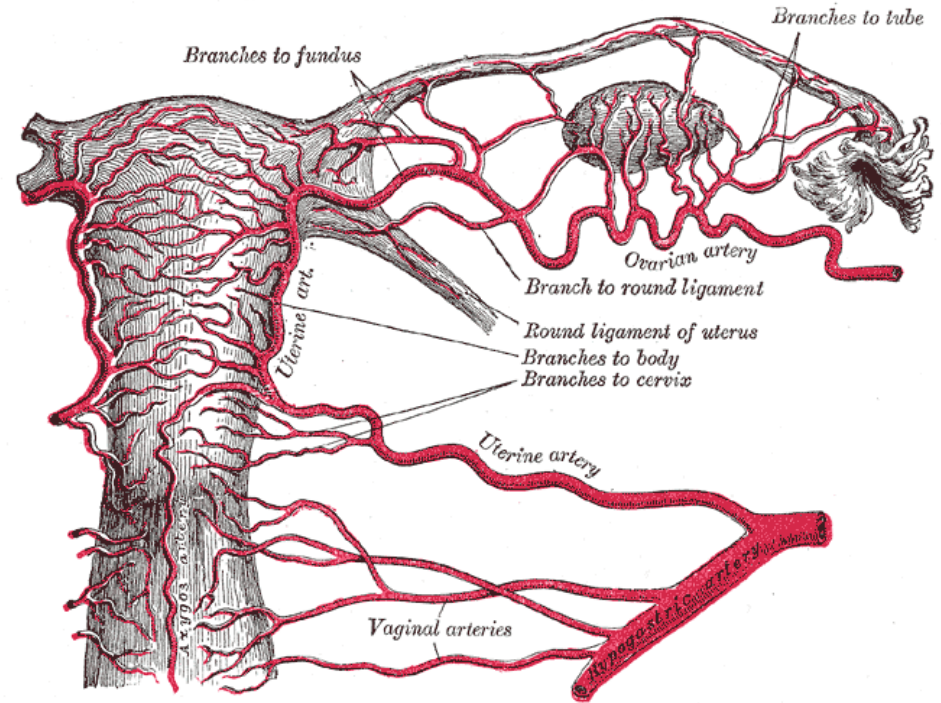


Blood supply and innervation

Vaginal artery (← uterine artery)
Branches of the internal pudendal artery

Vaginal venous plexus → internal iliac vein

Lymphatic drainage is via
the iliac and superficial inguinal lymph
nodes

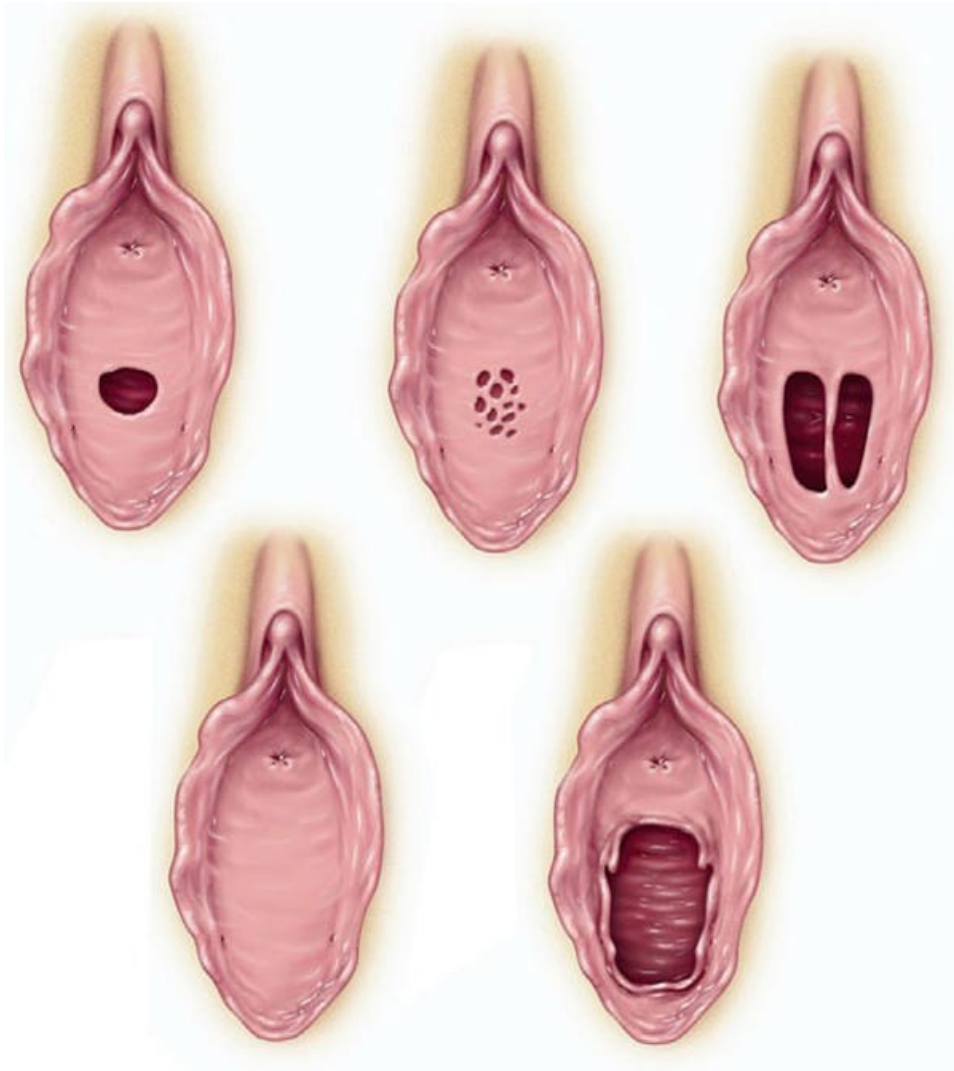


Uterovaginal nerve plexus: symp. and parasymp. innervation

superior part of the vagina: inferior hypogastric plexus and pelvic splanchnic nerves

inferior part of the vagina: deep perineal nerve (← pudendal nerve)

Hymen



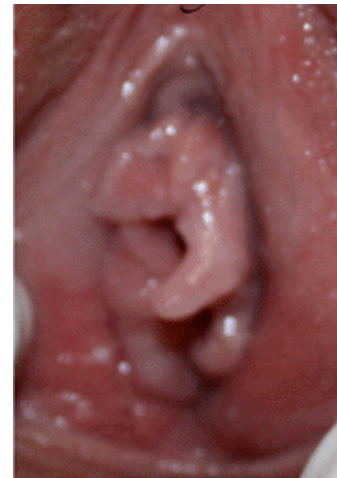
Virgo intacta:

- Hymen semilunaris
- Hymen annularis
- Hymen cribriformis
- Hymen septus
- Hymen imperforatus

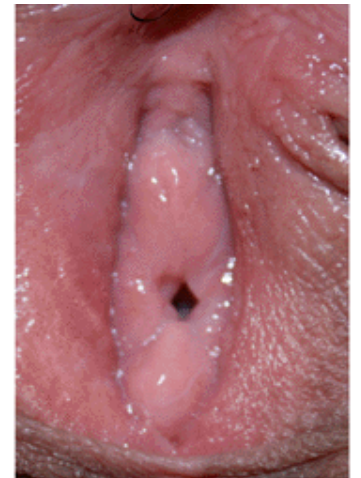
Remnant:

Carunculae hymenales/myrtiformes

Hymenoplasty/Virginity surgery

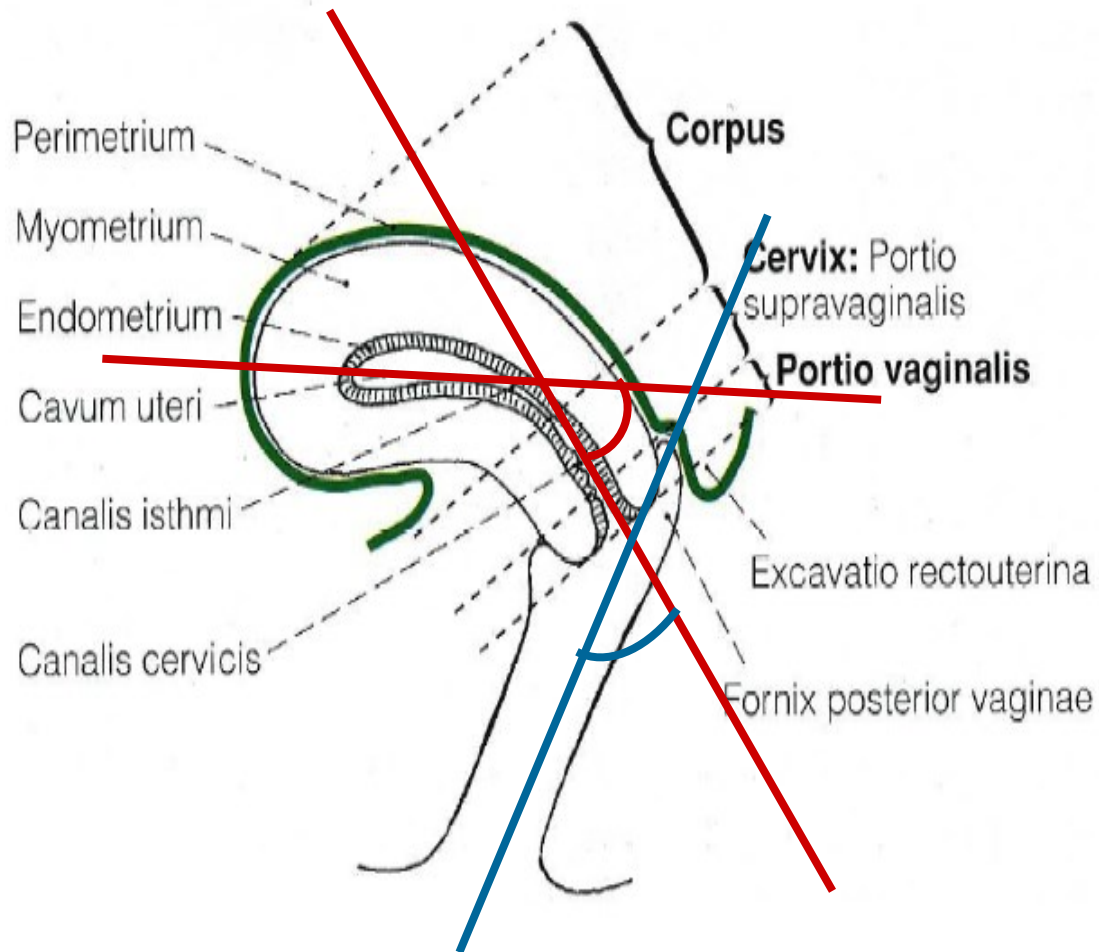


Before



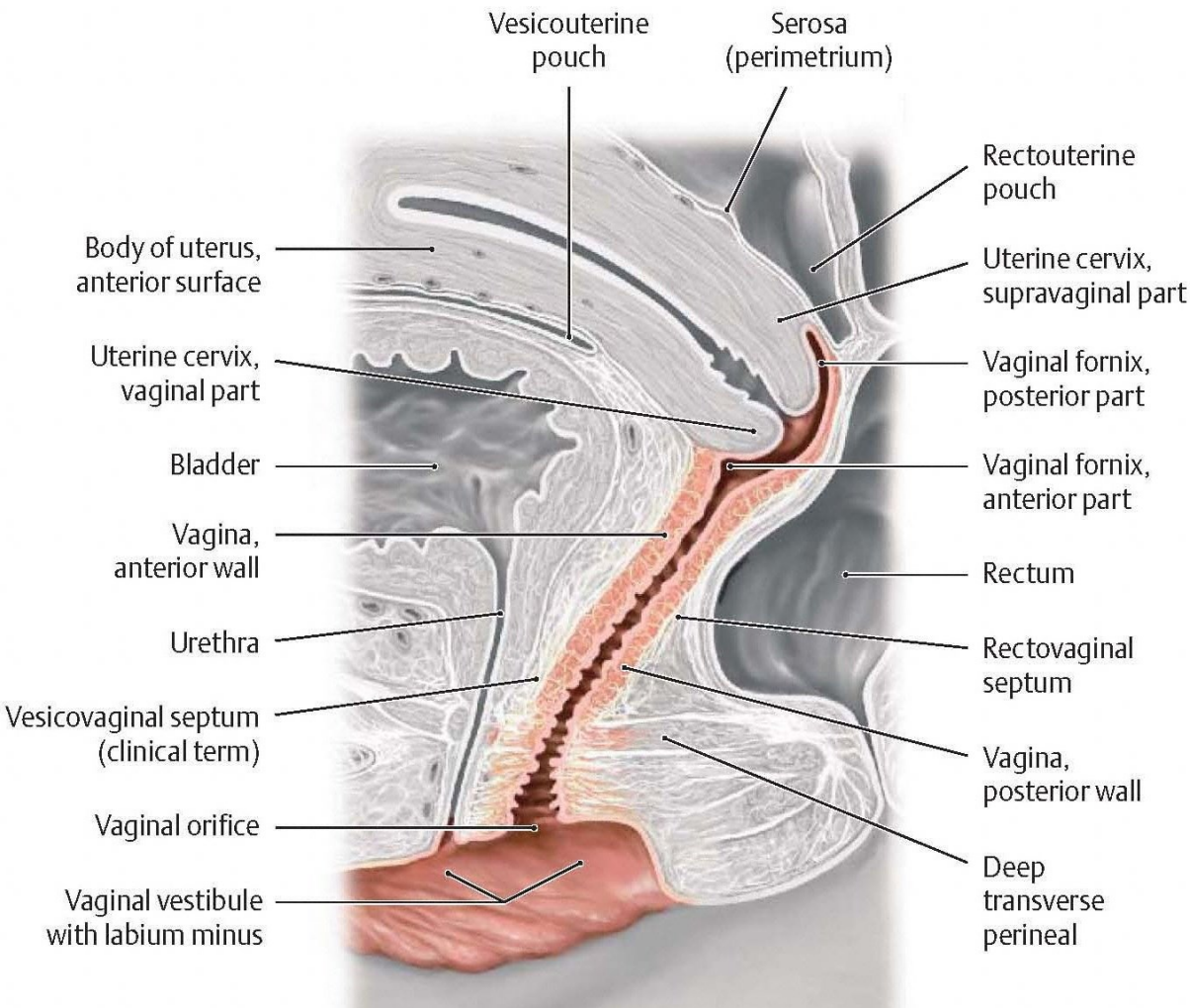
After

Topography of the vagina



Tilted 30-40° posteriorly
Cervix tilted 70° anteriorly

Vesicouterine pouch
Rectouterine pouch



Anterior wall

- *Ureter*
At the level of the uterine portion
- *Urinary bladder*
Vascular rich connective tissue
Pawlik's - triangle
(fornix ant. – corresponding to the trigone of the bladder)
- *Urethra*
Fused with the wall of vagina

Posterior wall

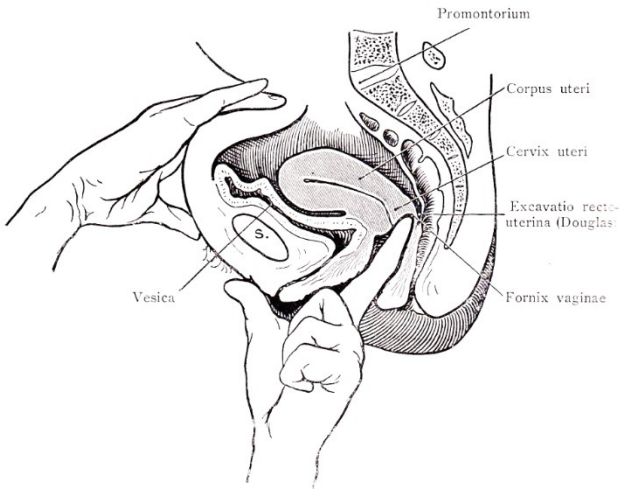
- *Rectovaginal septum*

Lateral wall (paracolpium)

- *Ureters*
- *Uterine arteries.*
- *Gartner's ducts* (vestigial remnant of the mesonephric duct)

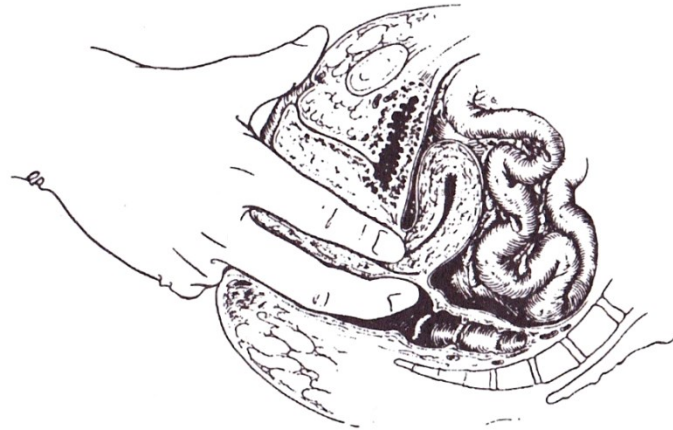
Clinical aspects

Bimanual examination



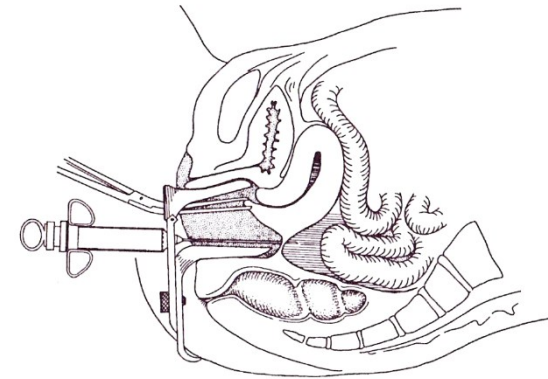
- Assess uterus size
- Determine if anteverted or retroverted

Rectovaginal examination



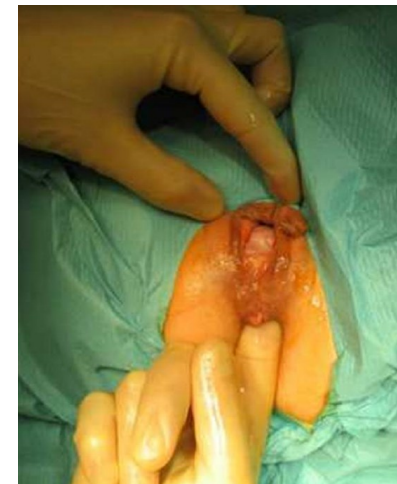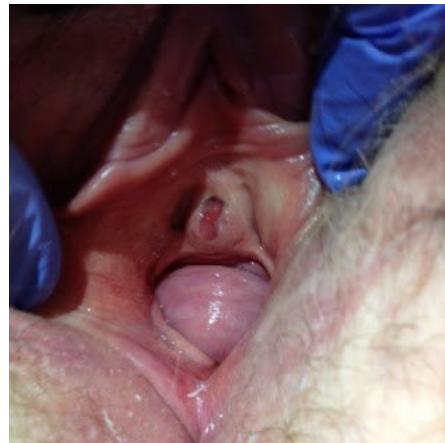- Assess rectovaginal septum

Douglas puncture

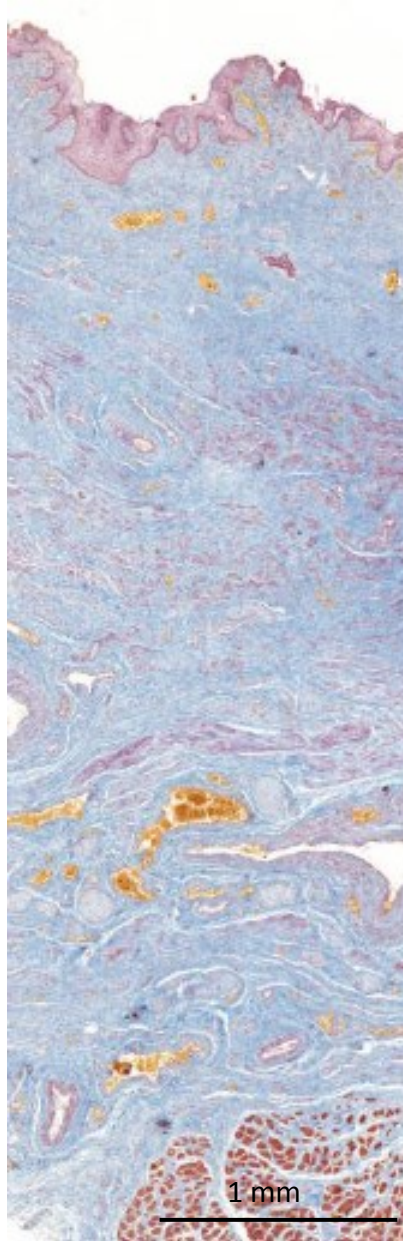
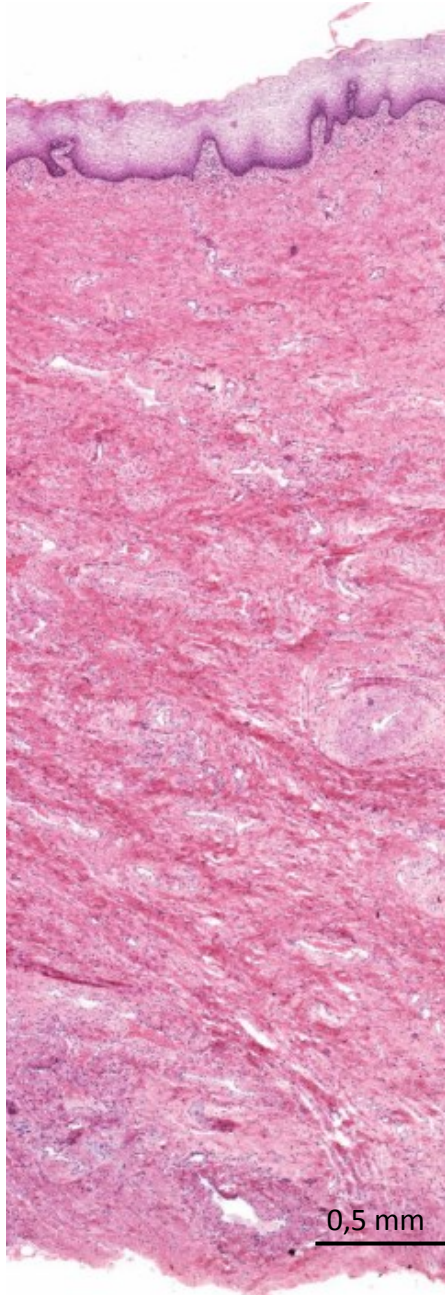


- Homeoperitoneum
- Ectopic pregnancy

Vaginal (obstetric) fistulae:
vesicovaginal (cystocele)
ureterovaginal
rectovaginal (rectocele)



Histology of the vagina



Tunica mucosa

stratified squamous non-keratinized epithelium

connective tissue papillae

high glycogen content

lamina propria mucosae

dense irregular connective tissue

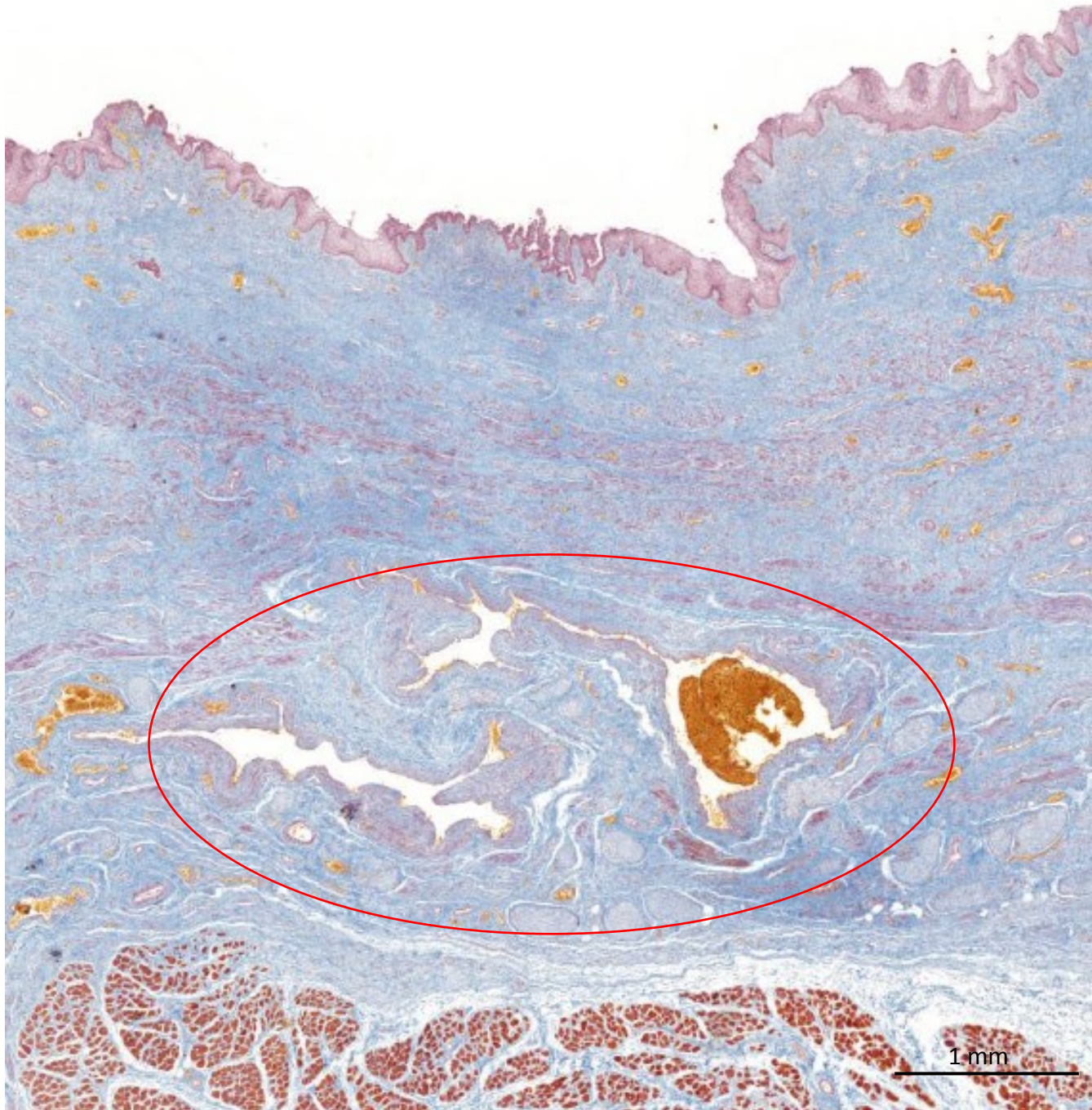
collagen + elastic fibers

∅ glands

∅ Tunica submucosa!

Tunica muscularis

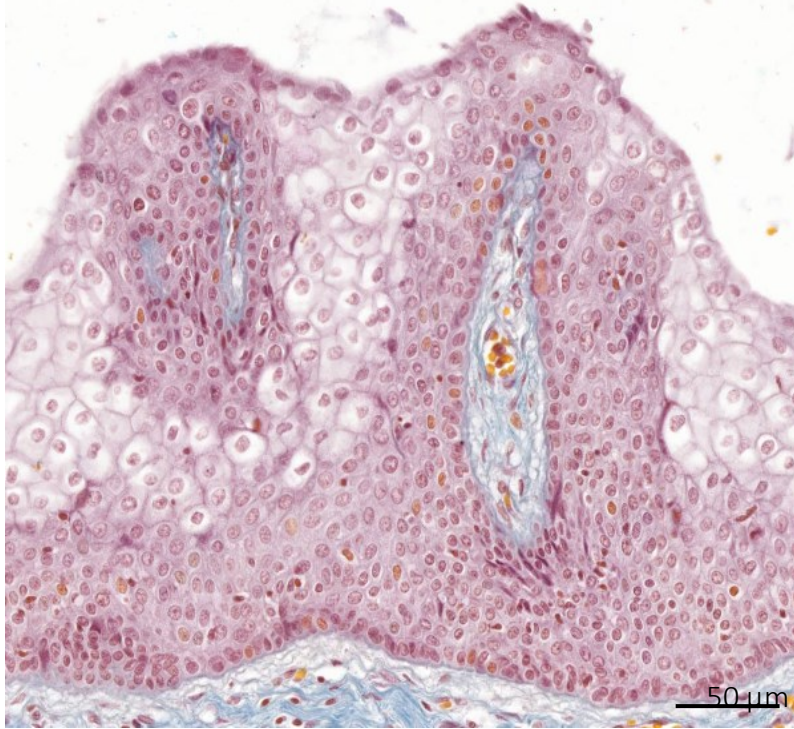
Adventitia – dense and loose connective tissue



Erectile tissue

Skeletal muscle

1 mm



Döderlein bacteria (lactobacilli)

Glycogene



Lactic acid

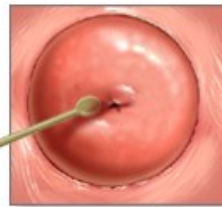

low pH (4-4,5)



protect against colonization by other microbes

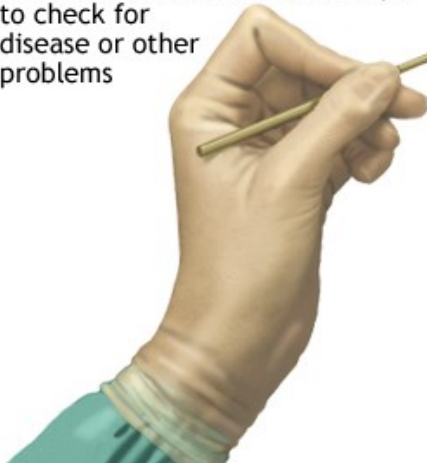Pap smear:
cells are scraped from the cervix
and examined under a microscope
to check for
disease or other
problems



Cervix viewed
through speculum
with patient in
lithotomy position

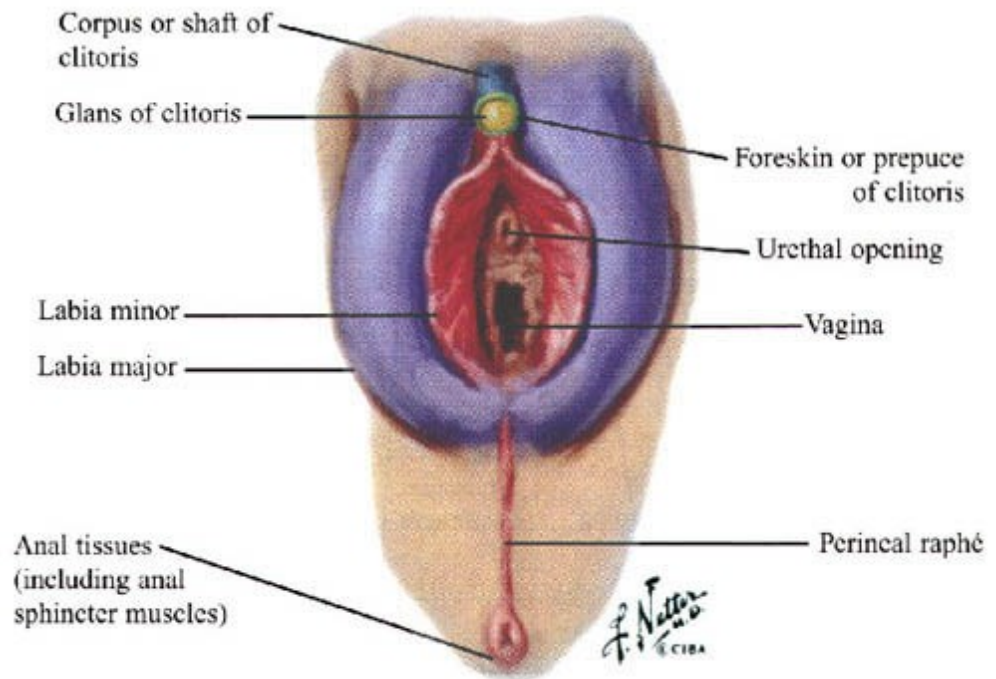
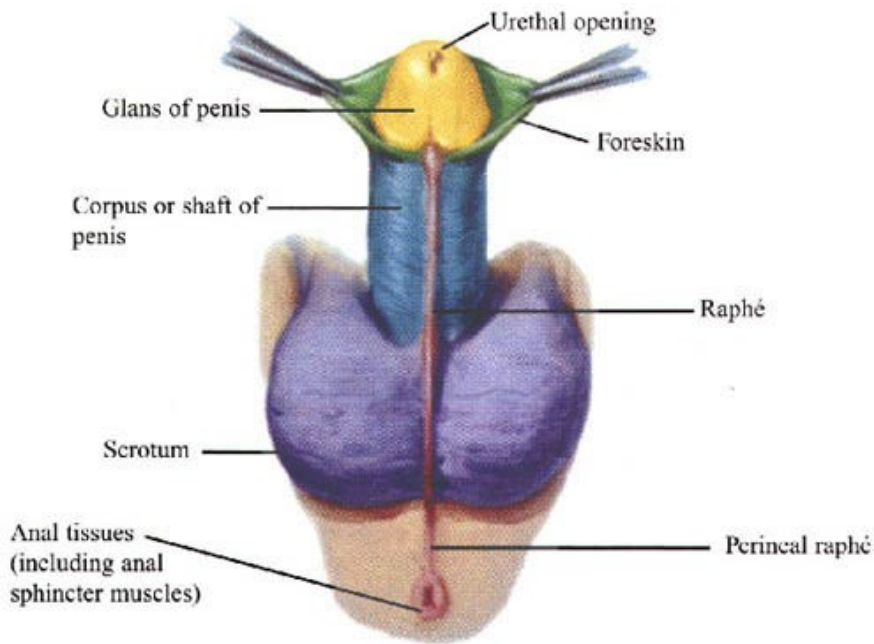
Vaginal (stratified non-keratinizing squamous)
epithelium is replaced by (simple columnar)
cervical epithelium at the orifice

Diagnostic spot for cervical carcinogenesis

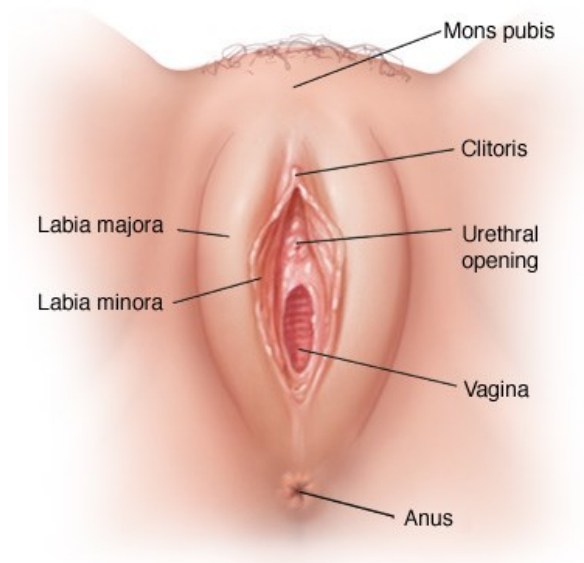


External female genital organs

Homologous organs



Labia majora



Two longitudinal cutaneous folds from the mons pubis to the perineum.

- external part: pigmented and covered with hair
- internal part: large sebaceous glands
- anterior labial commissure
- posterior labial commissure

- lateral boundaries of the pudendal cleft

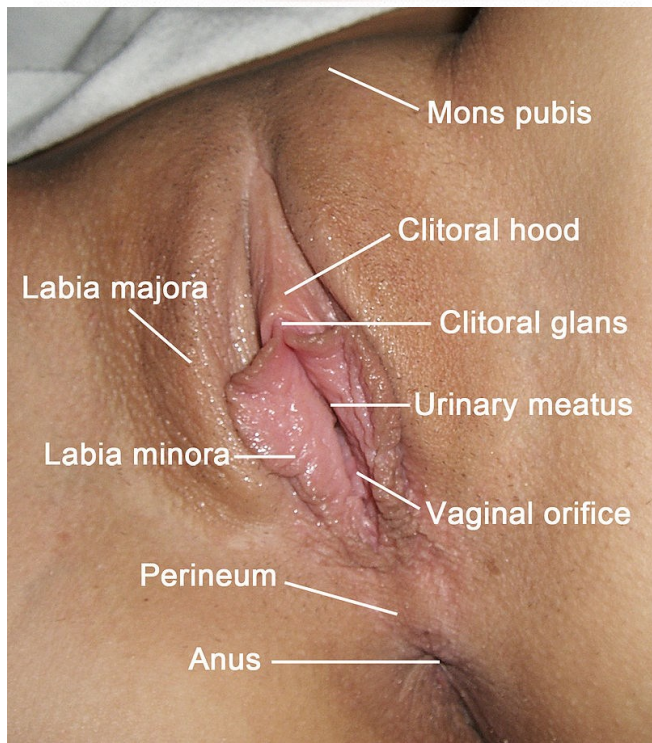
- composition: areolar tissue, fat, and a tissue resembling the dartos tunic

- round ligament of the uterus

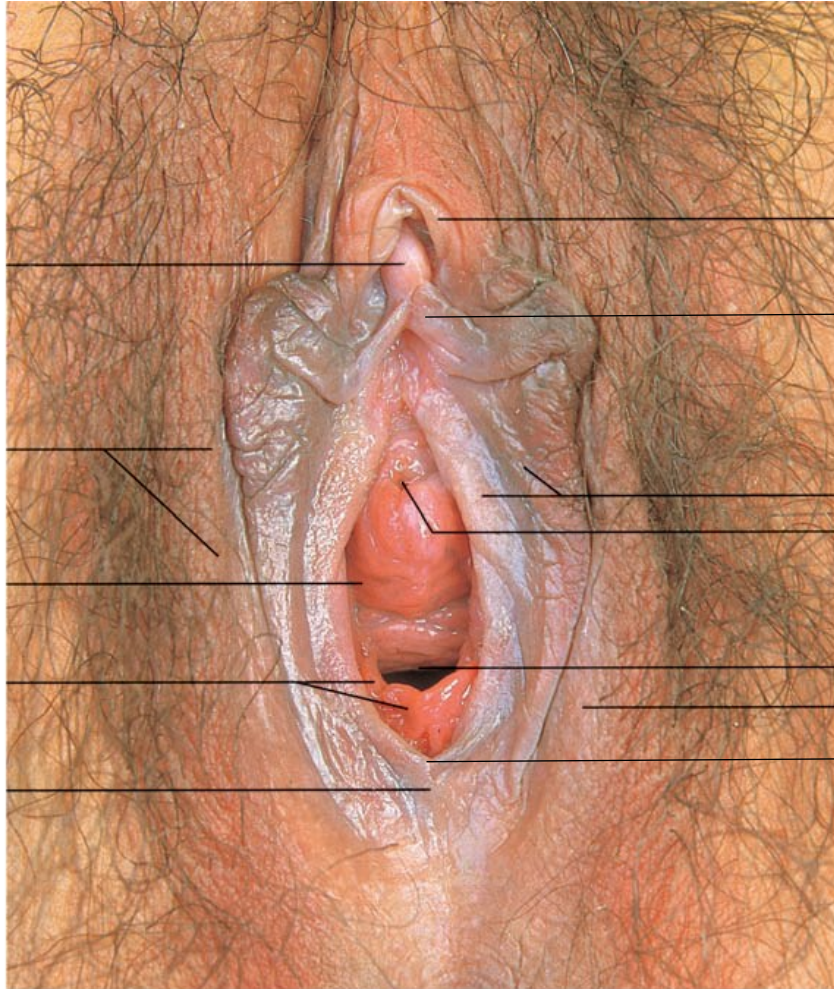
- perineal artery (← internal pudendal artery)

Clinical aspects:

- atrophy after menopause
- fat pad grafts



Labia minora



- | | |
|-------------------------------|-----------------------------|
| 1 Glans of clitoris | 6 Prepuce of clitoris |
| 2 Labium majus | 7 Labium minus |
| 3 Vestibule of vagina | 8 External urethral orifice |
| 4 Hymen | 9 Vaginal orifice |
| 5 Posterior labial commissure | 12 Preputium |
| | 13 Frenulum |
| | 14 Fourchette |

Two longitudinal folds in the vulva, they vary in size.

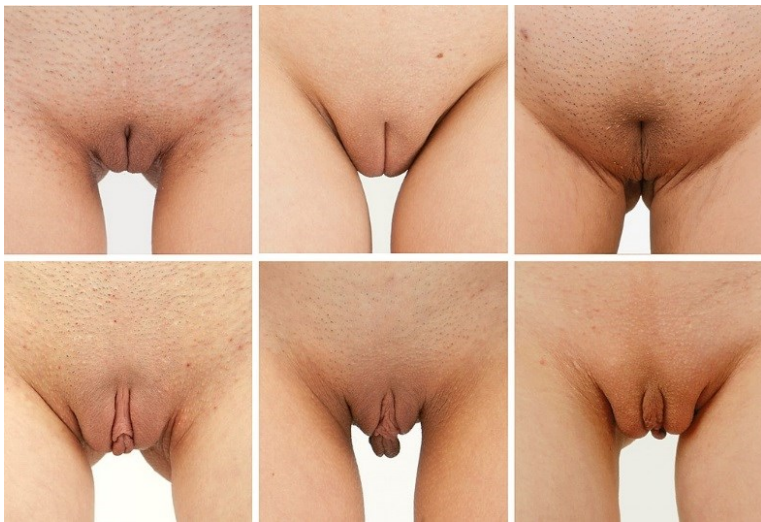- extend from the clitoris obliquely downward, laterally, and backward

- vulval vestibule

- the upper division passes above the clitoris forming the preputium clitoridis

- the lower division passes beneath the glans clitoridis forming the frenulum clitoridis

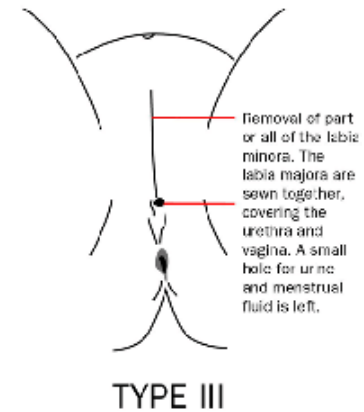
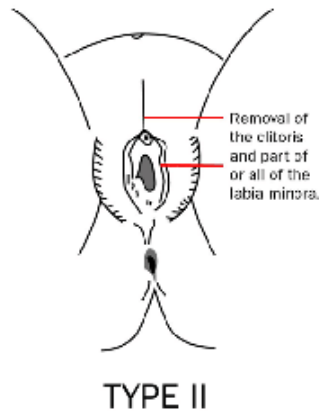
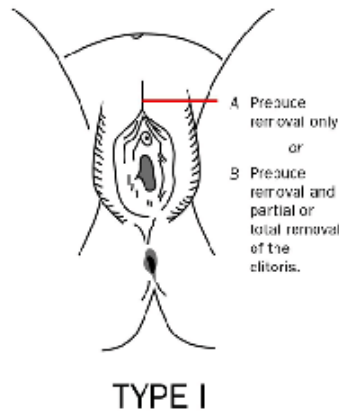
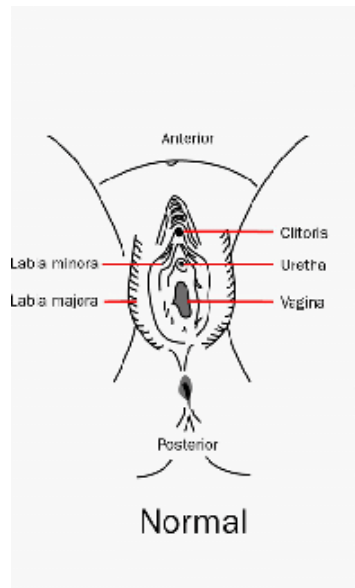
In virgins, there is a frenulum labiorum pudendi (fourchette).



Vulvitis
Labial fusion



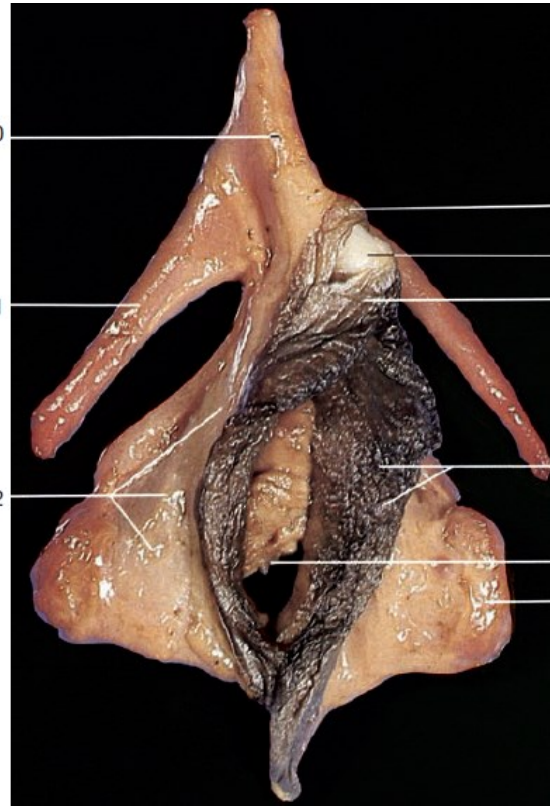
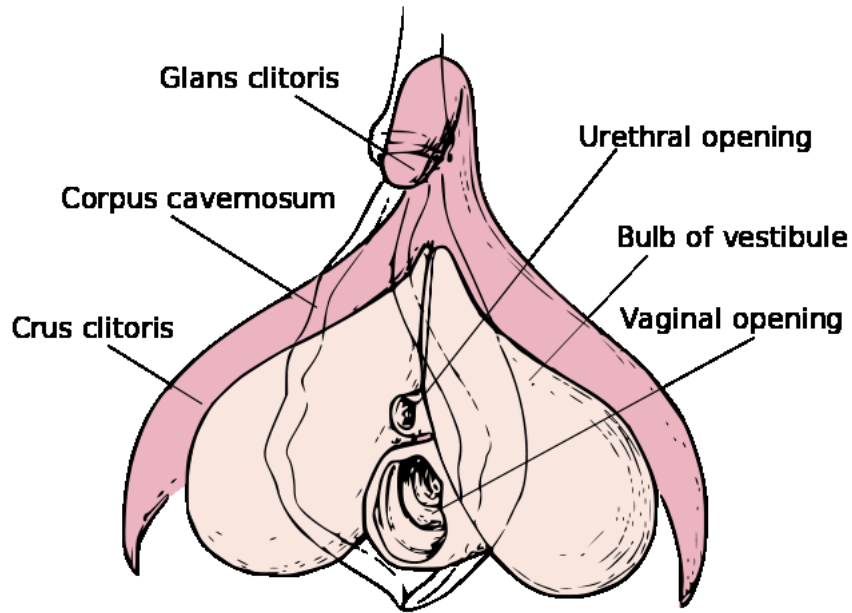
Labioplasty



Female circumcision

Partial or total removal of the external female genitalia or other injury to the female genital organs for non-medical reasons. (WHO)

Clitoris



- 1 Glans of clitoris
- 6 Prepuce of clitoris
- 1 Labium minus
- 13 Vaginal orifice
- 10 Body of clitoris
- 11 Crus of clitoris
- 12 Bulb of vestibule with bulbospongiosus muscle
- 7 Frenulum of clitoris
- 9 Greater vestibular gland

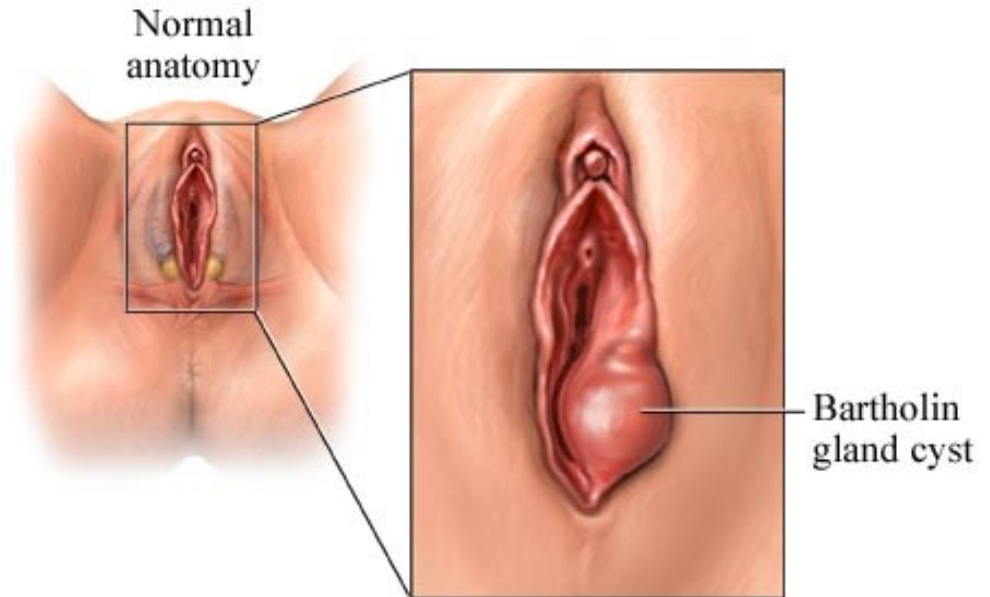
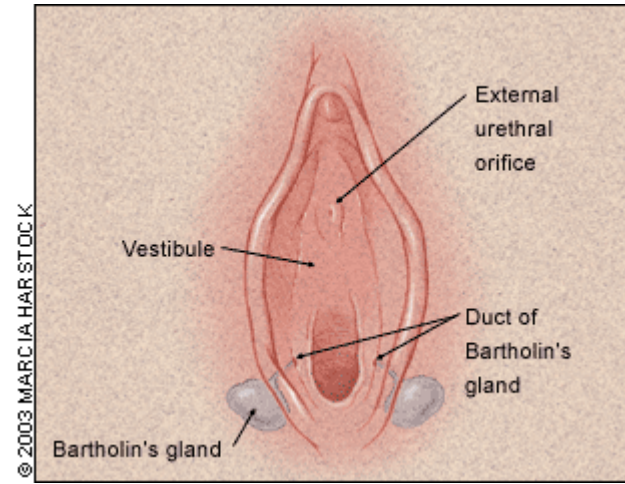
Crura- m. ischiocavernosus
 Bulb of vestibule- m. bulbospongiosus

artery of bulb of vestibule
 dorsal artery of the clitoris
 deep artery of the clitoris } internal pudendal artery

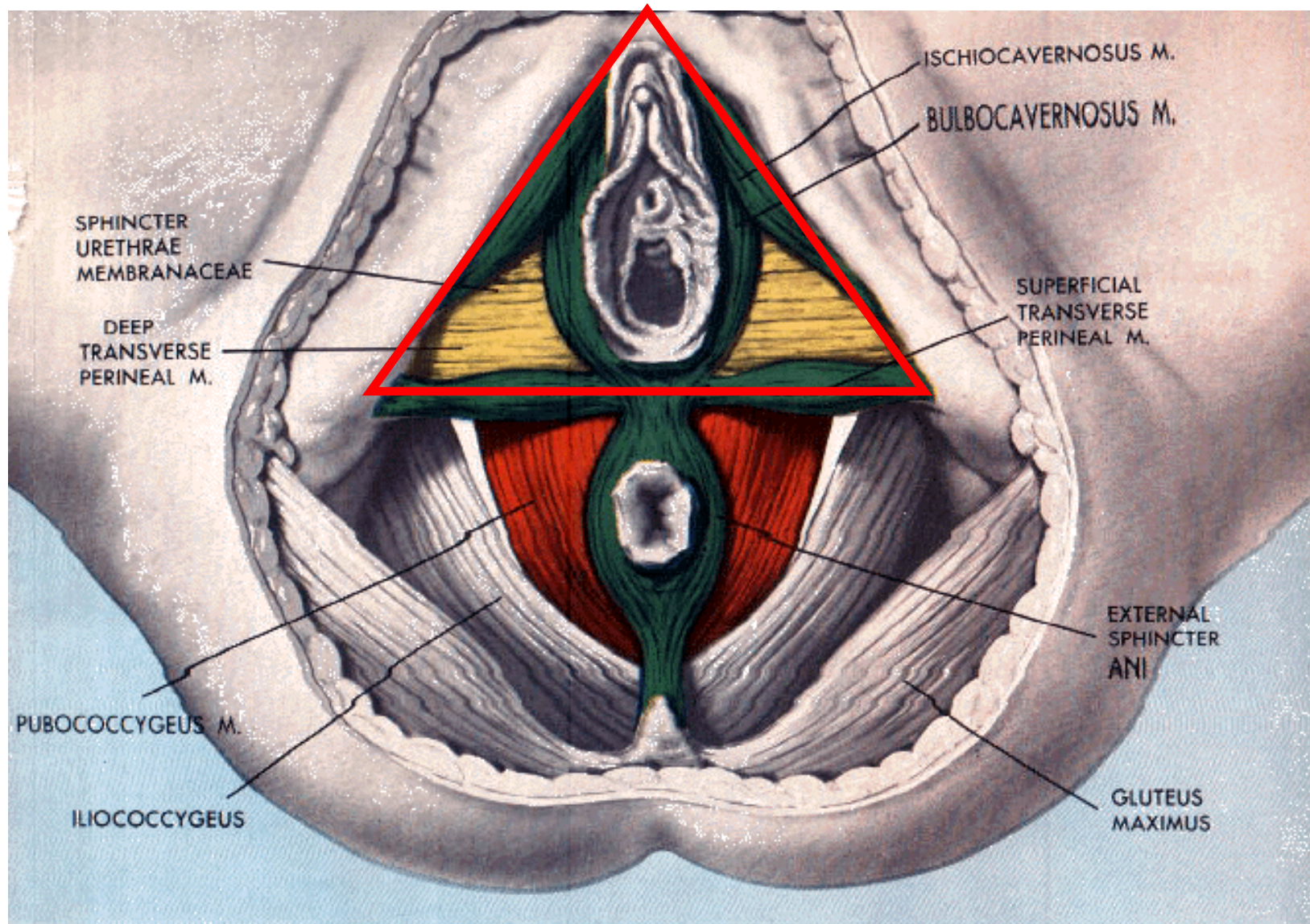
ilioinguinal nerve
 genitofeoral nerve
 pudendal nerve → dorsal nerve of the clitoris

Bartholin's gland/Greater vestibular gland

- pea sized
- compound alveolar glands
- secrete mucus → lubricate the vagina
- opens of the surface of the vestibule

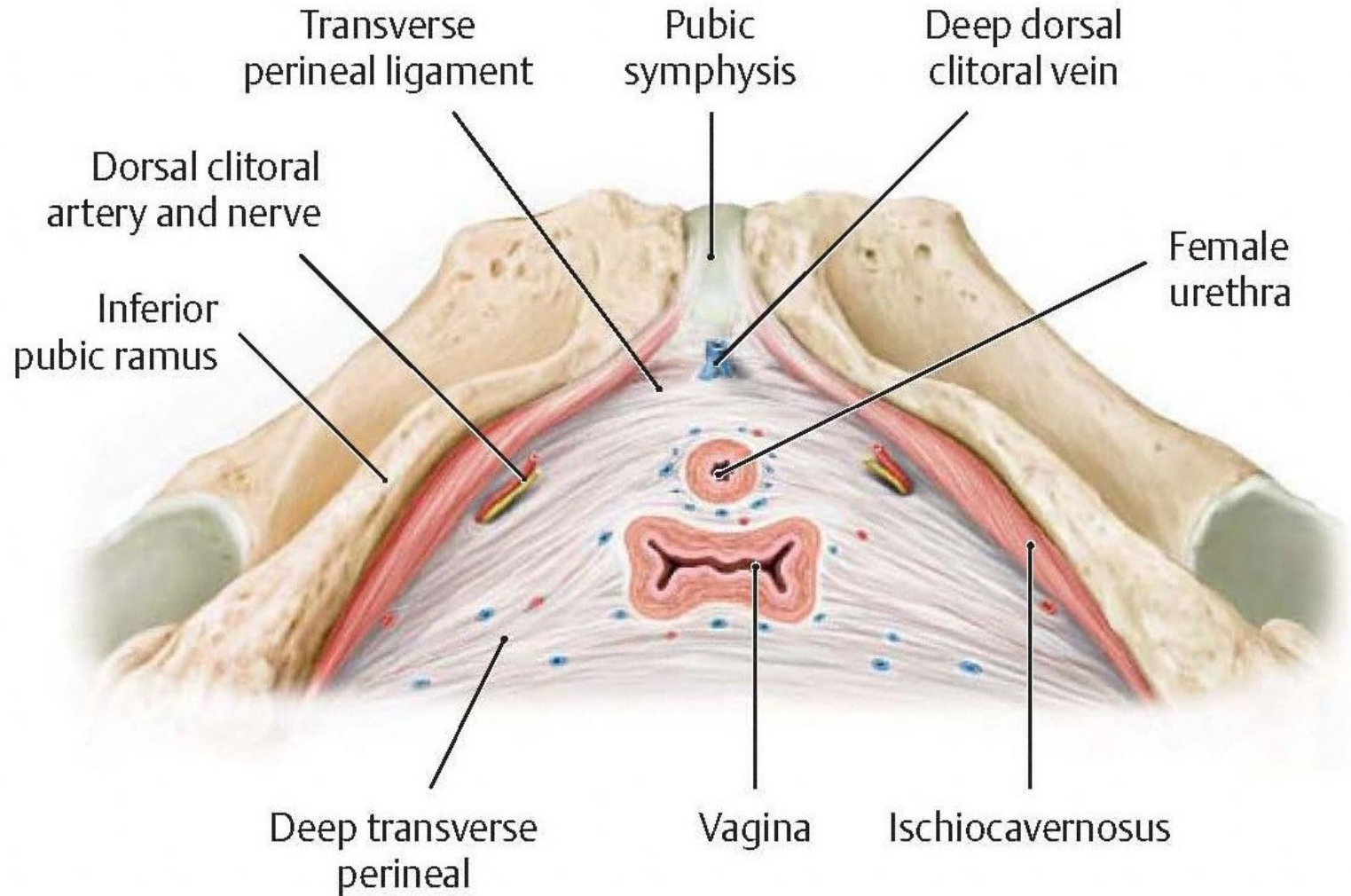


Female perineum

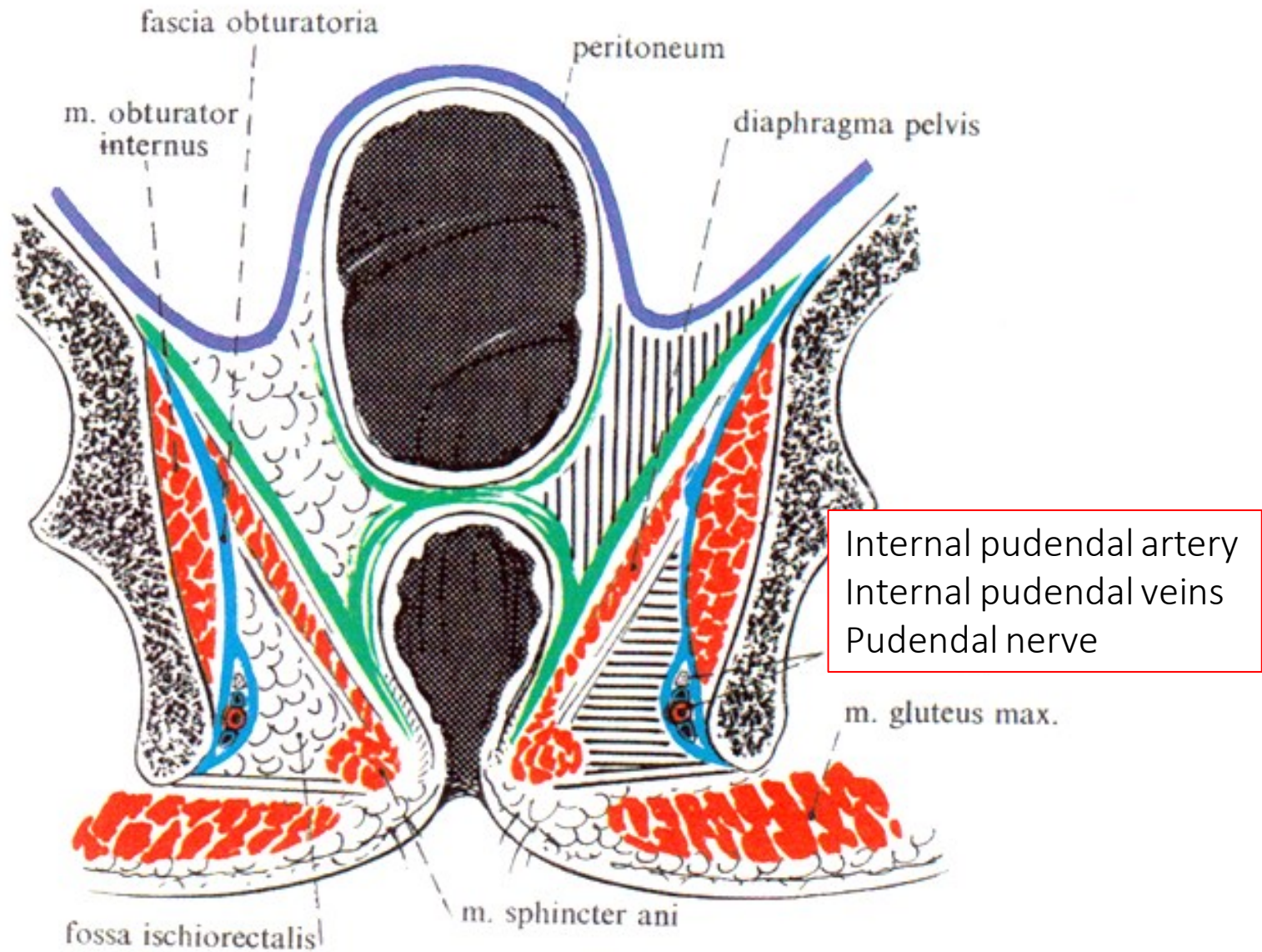


Urogenital triangle

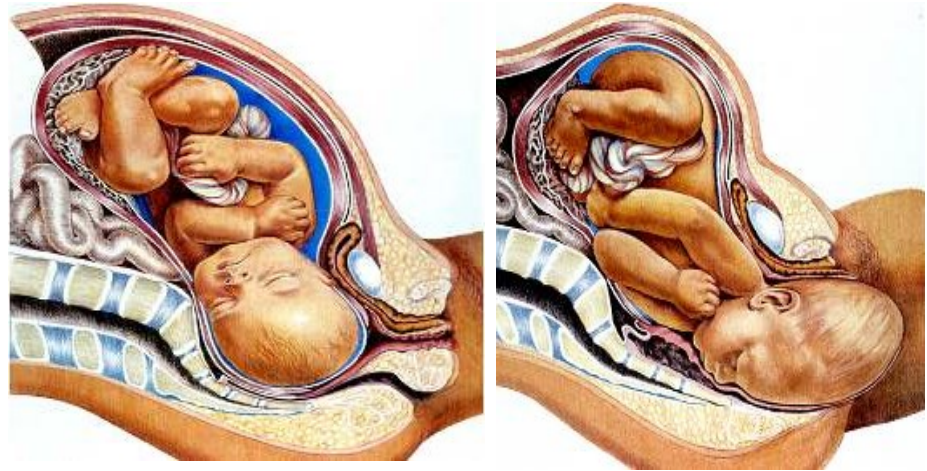
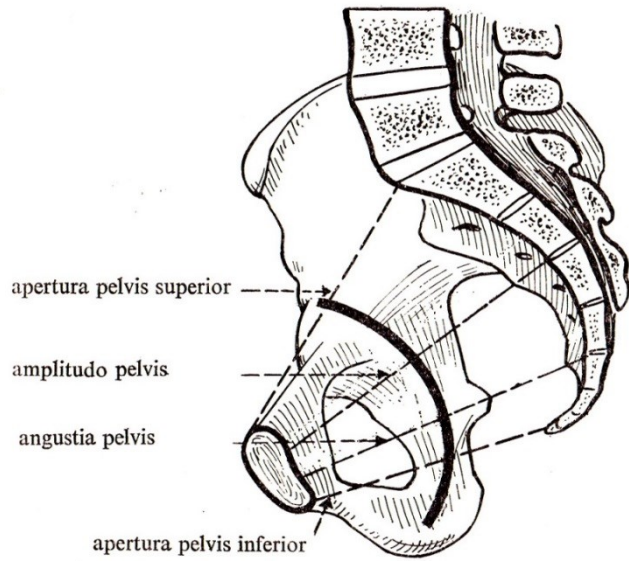
Urogenital triangle



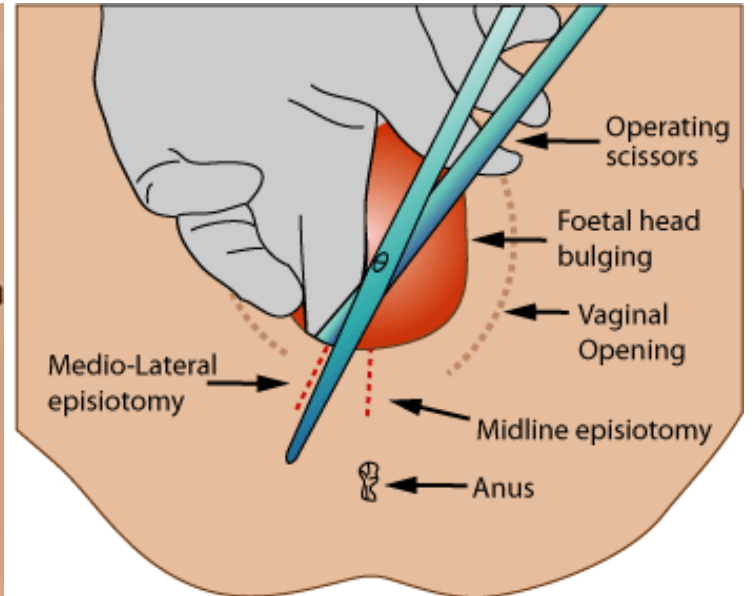
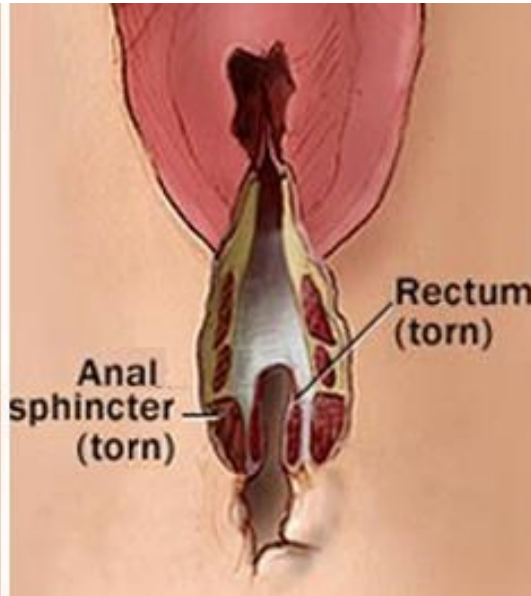
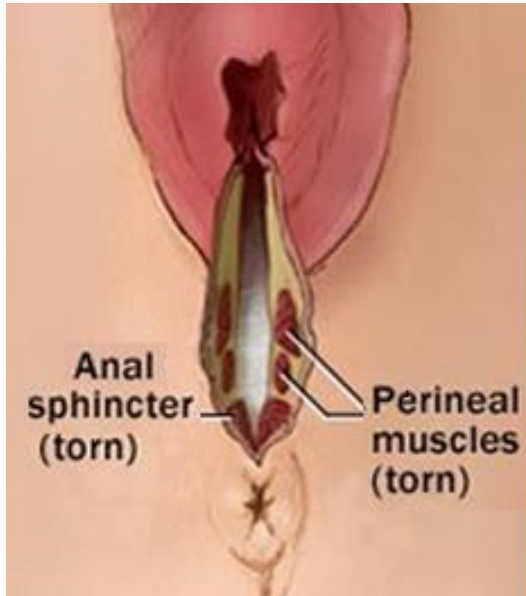
Pudendal/Alcock's canal



Birth canal



Episiotomy



Thank you for your attention!

Dr. Georgina Gáti: A külső női nemi szervek. A medencefenék szerkezete. A férfi és női gát
Dr. Andrea Székely: MORPHOLOGY AND HISTOLOGY OF THE VAGINA, THE EXTERNAL
GENITAL ORGANS, FEMALE PERINEUM

https://en.wikipedia.org/wiki/Labia_minora#/media/File:Vulva_labeled_english.jpg

https://en.wikipedia.org/wiki/Labia_minora#/media/File:Auspr%C3%A4gung_der_Labia_Minora.jpeg

https://en.wikipedia.org/wiki/Labioplasty#/media/File:Labioplasty_and_Clitoral_Hood_Reduction.jpg

https://www.researchgate.net/figure/Types-of-Female-Genital-Mutilation_fig1_288686137