# DEVELOPMENT OF THE HEART II.

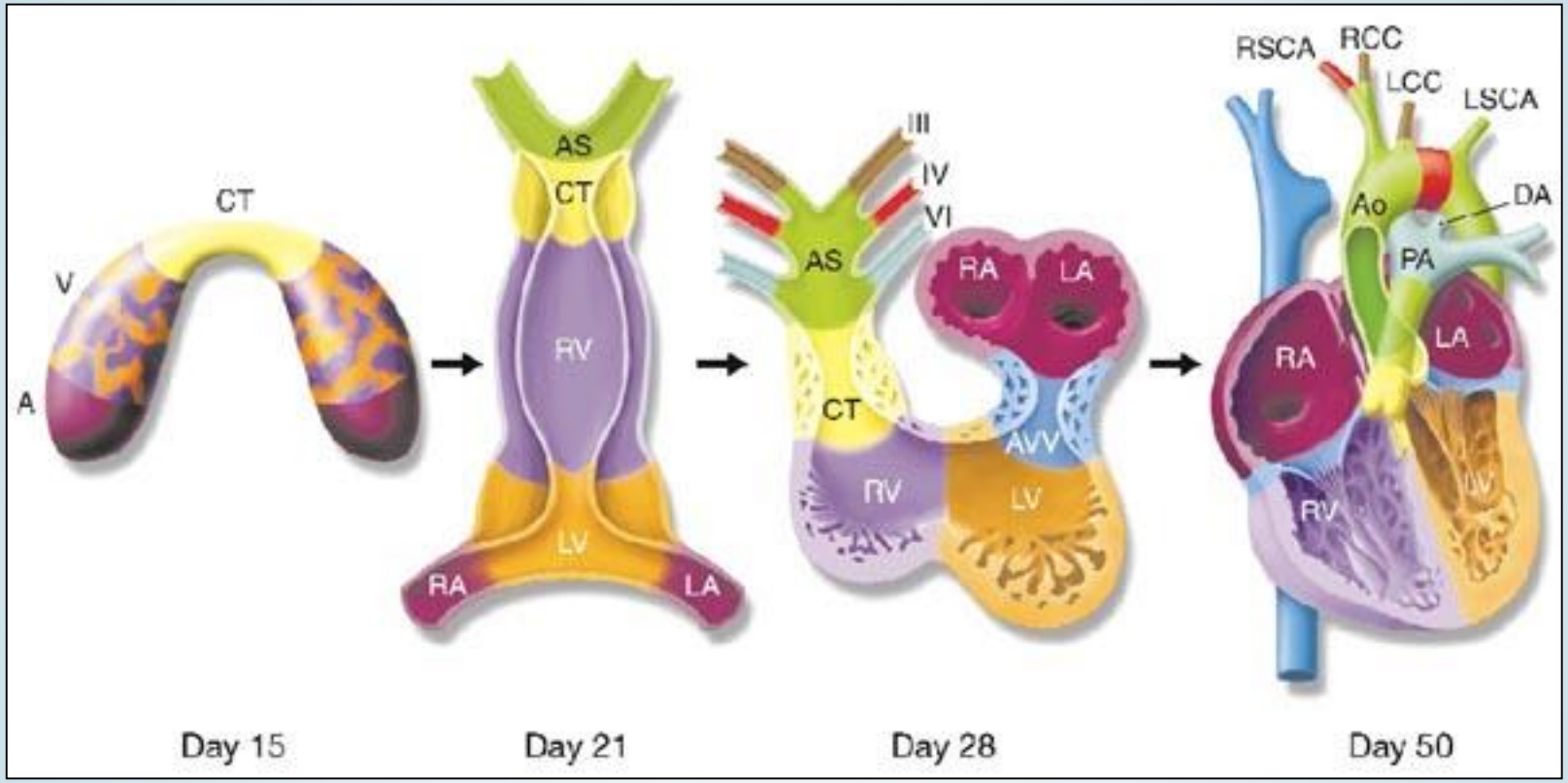


*David Lendvai M.D., Ph.D.*
*Mark Kozsurek, M.D., Ph.D.*

- *Septation of the common atrioventricular (AV) orifice.*
- *Formation of the interatrial septum.*
- *Formation of the muscular interventricular septum.*
- *Appearance of the membranous interventricular septum and the spiral aorticopulmonary septum.*

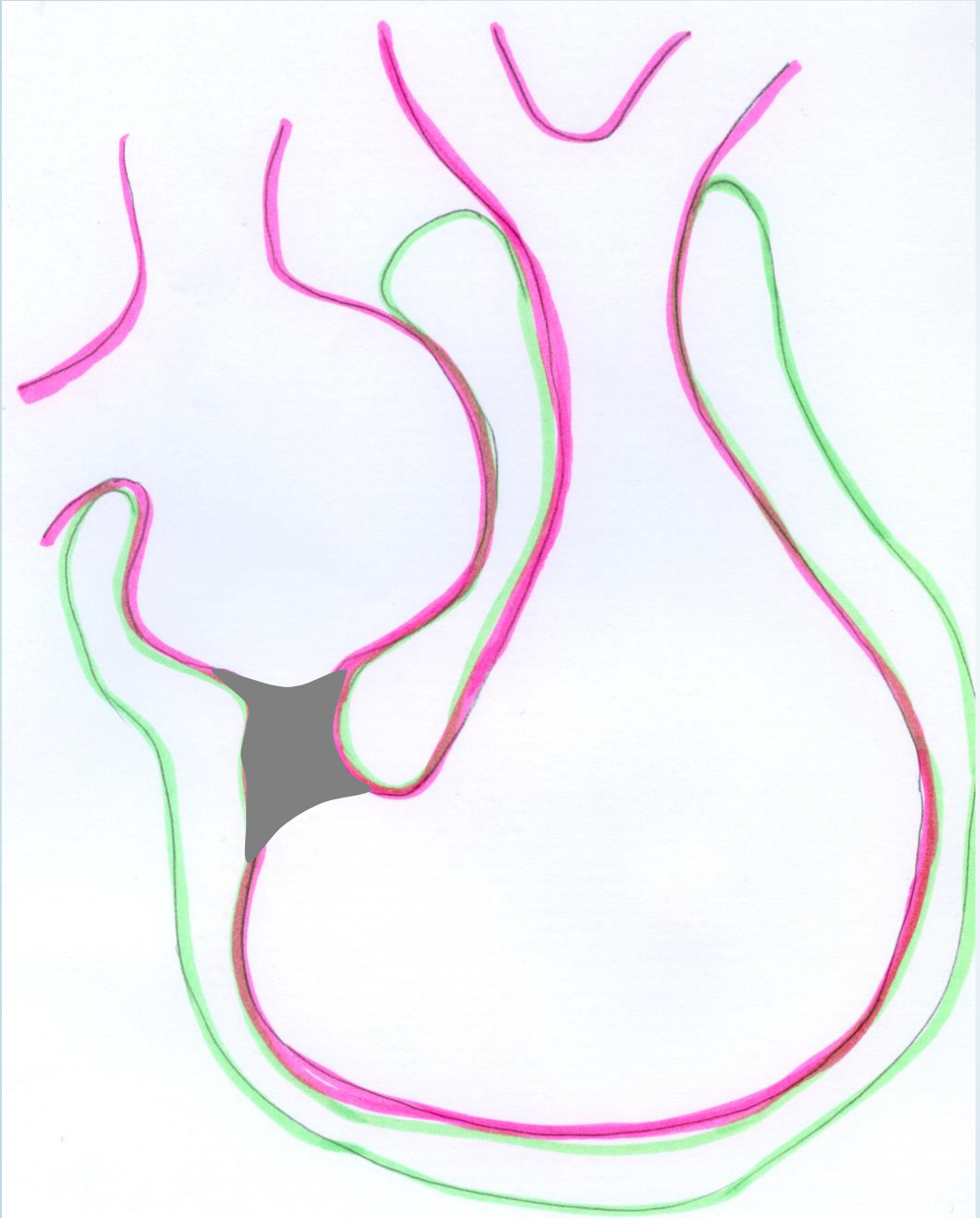

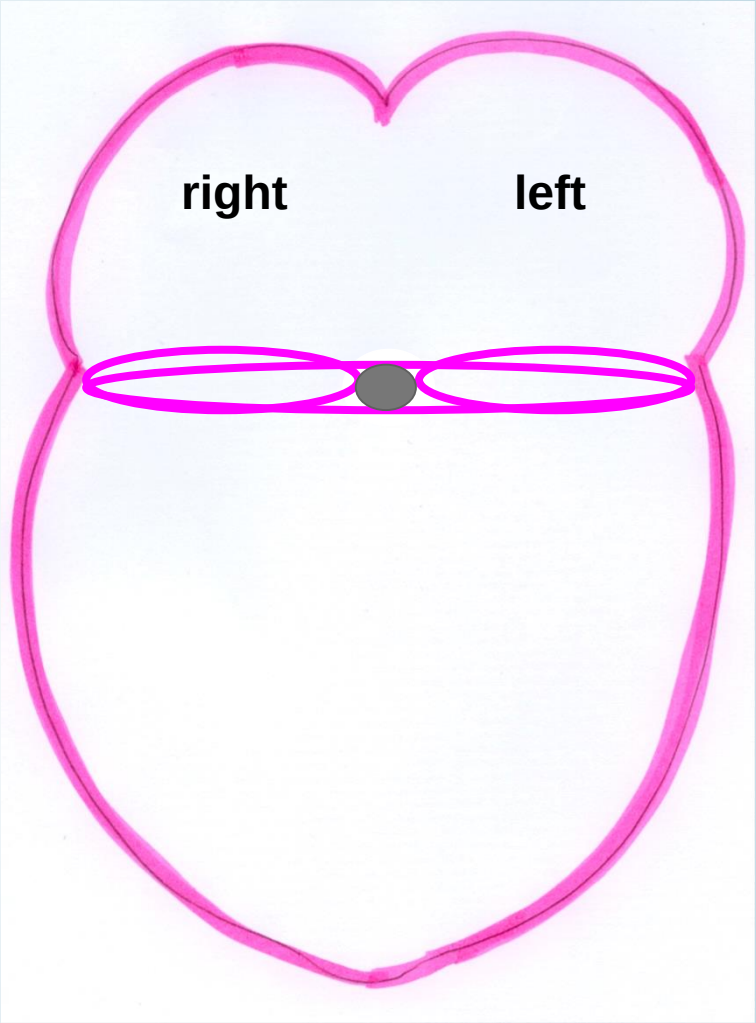
right
left

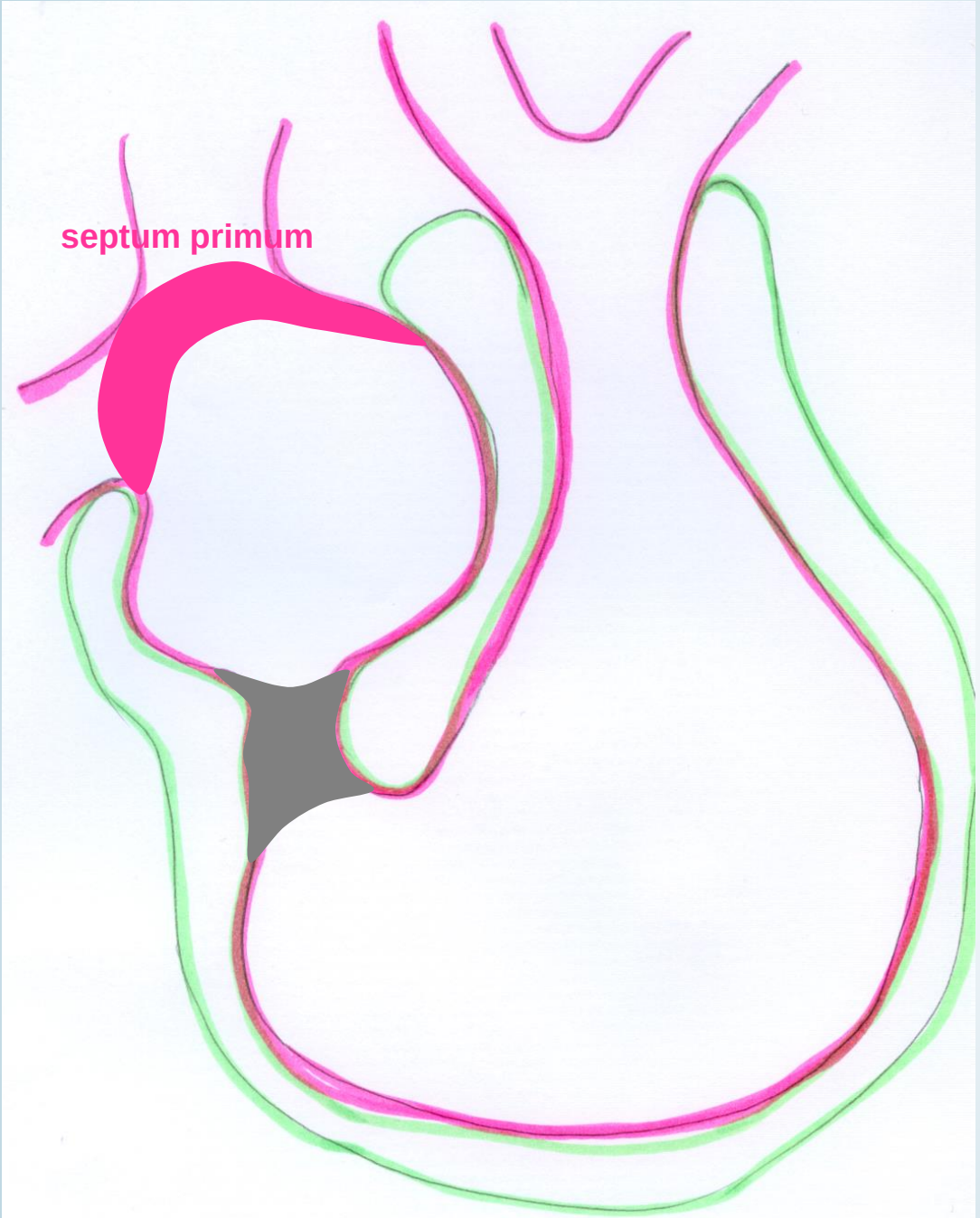
septum primum

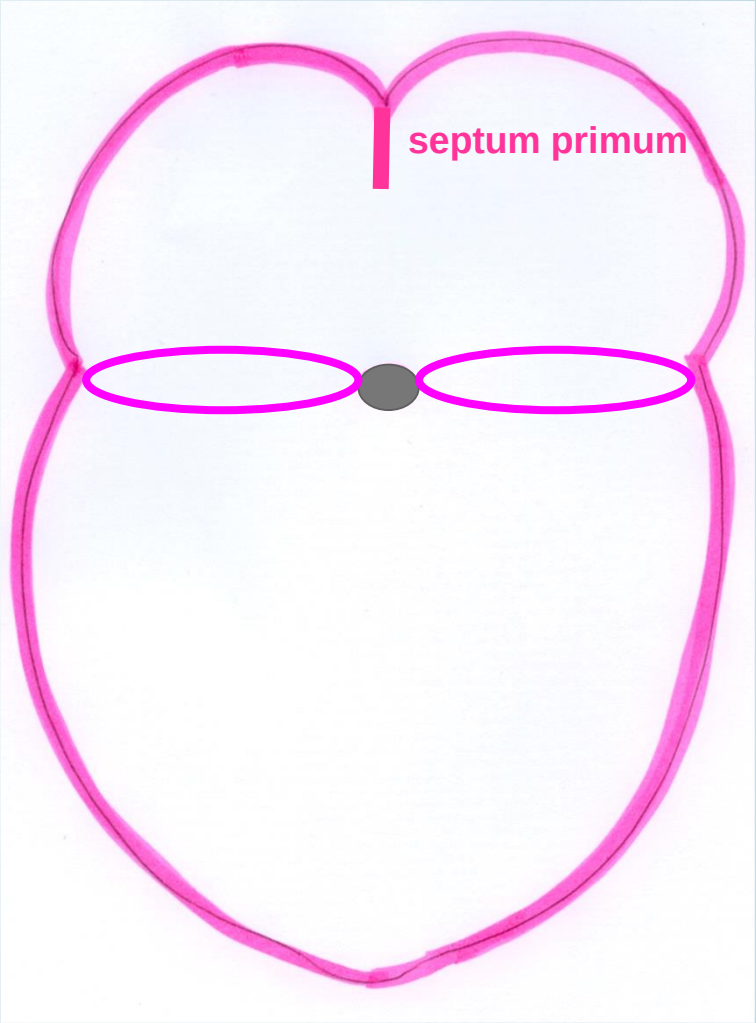
septum primum

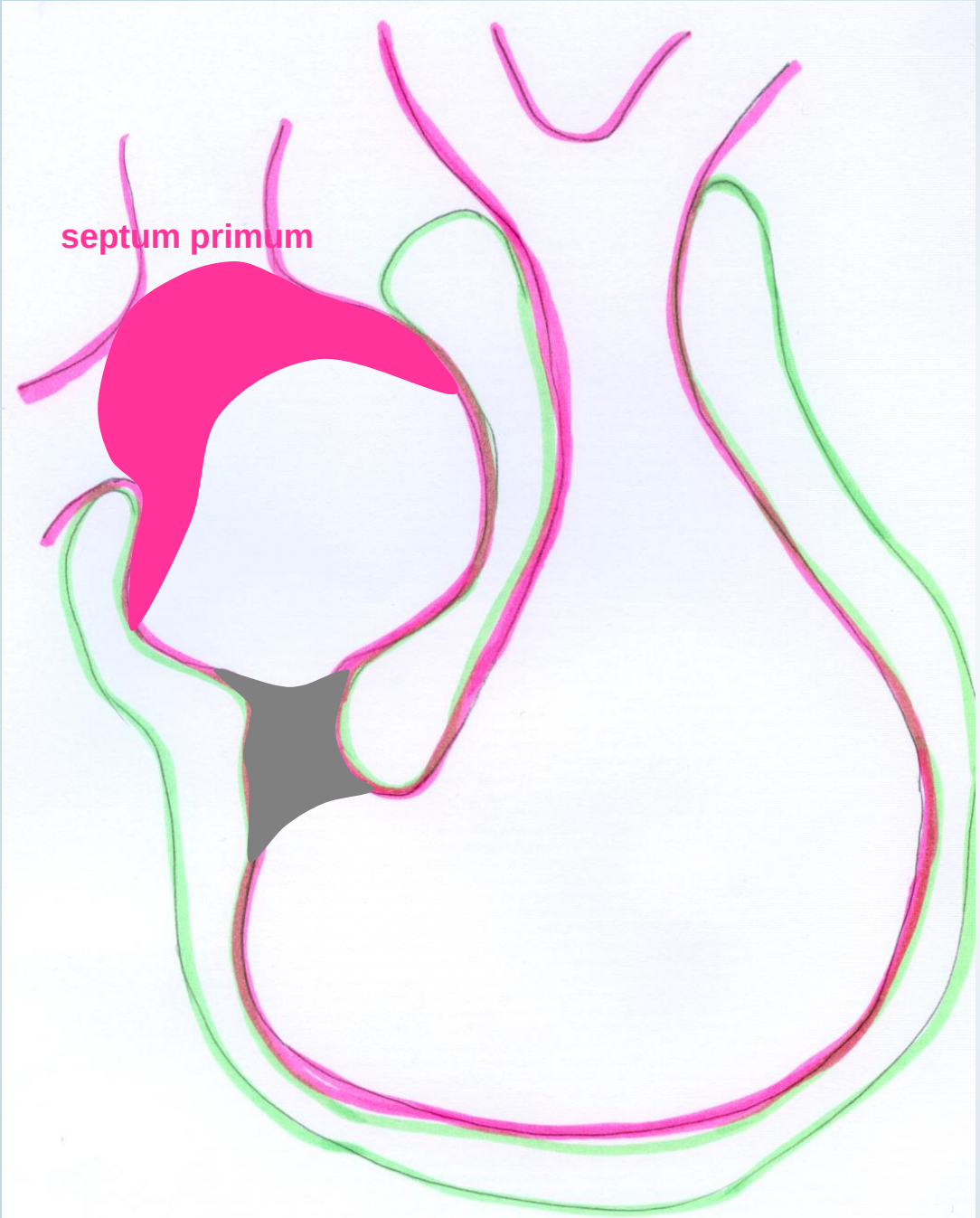
septum primum

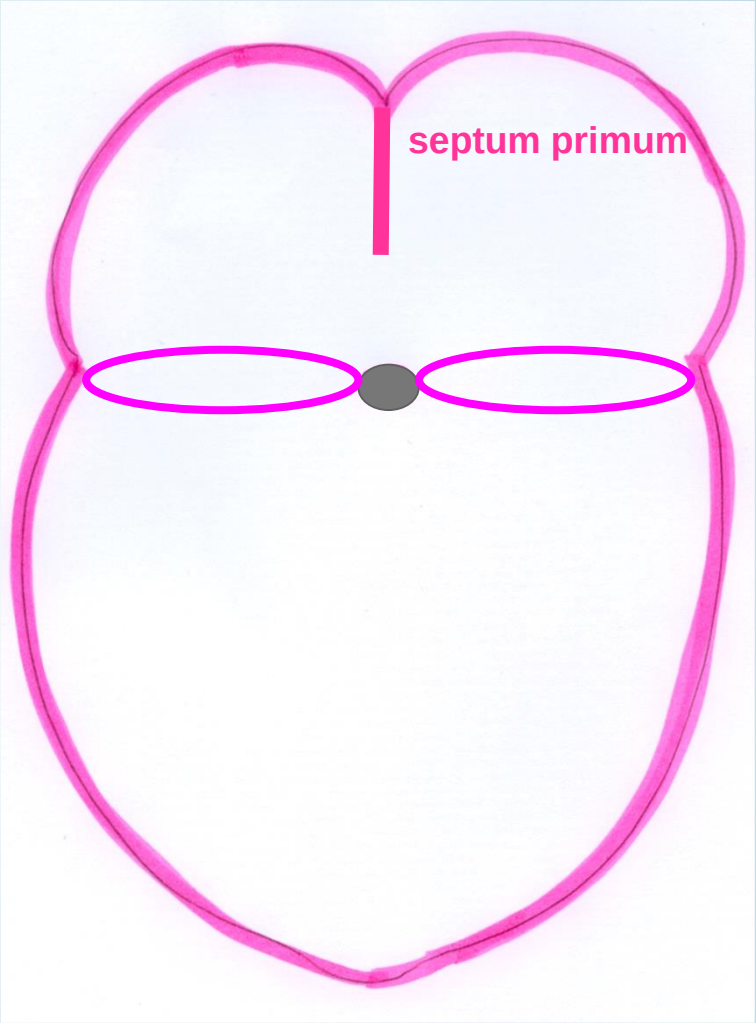
septum primum

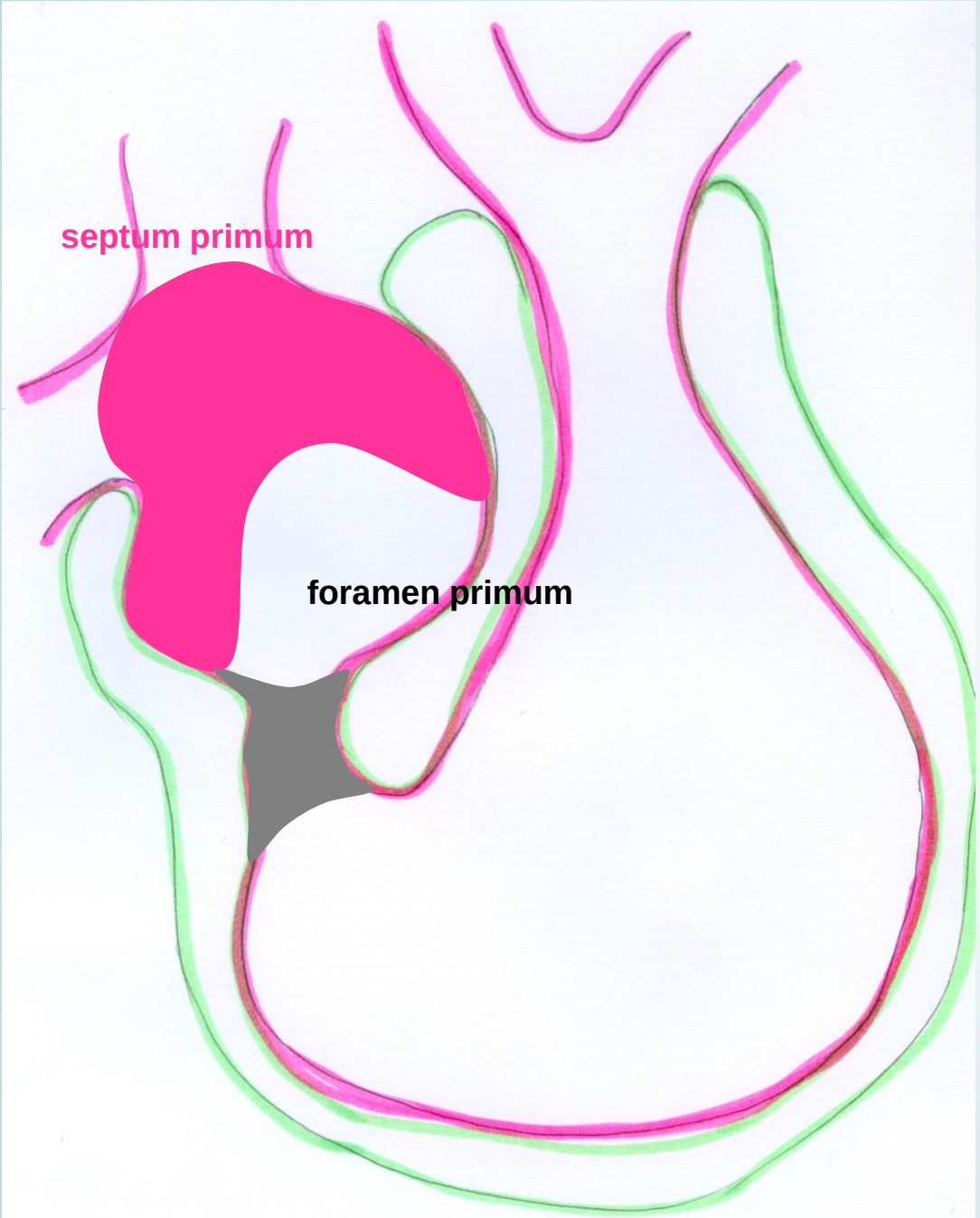
septum primum
foramen primum

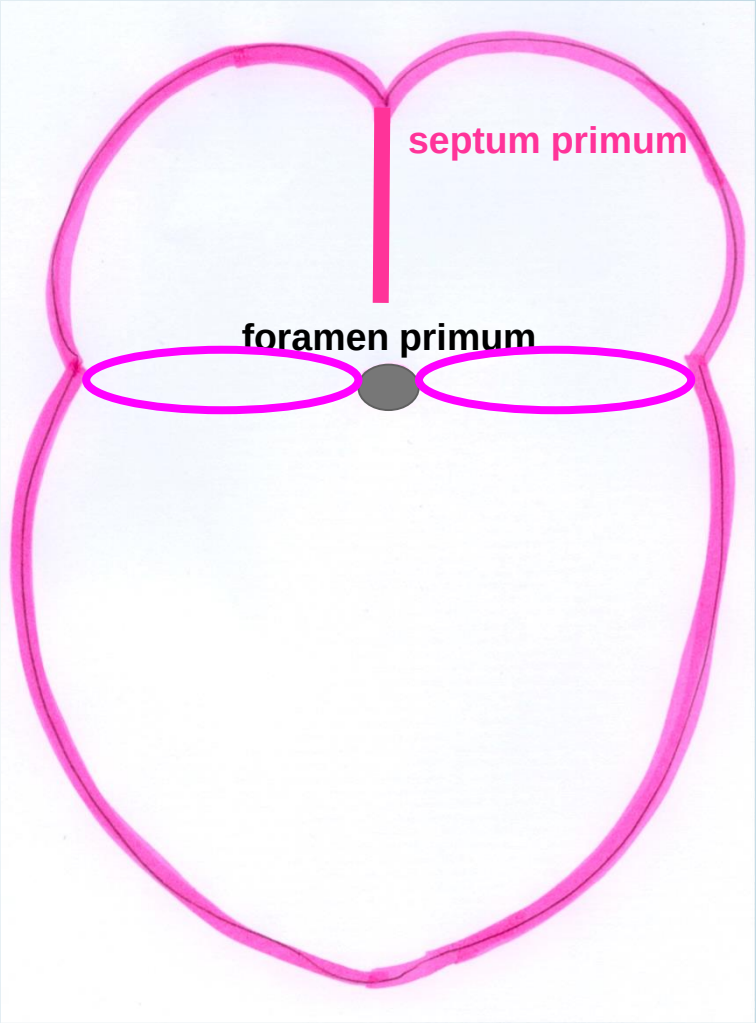
septum primum
foramen primum

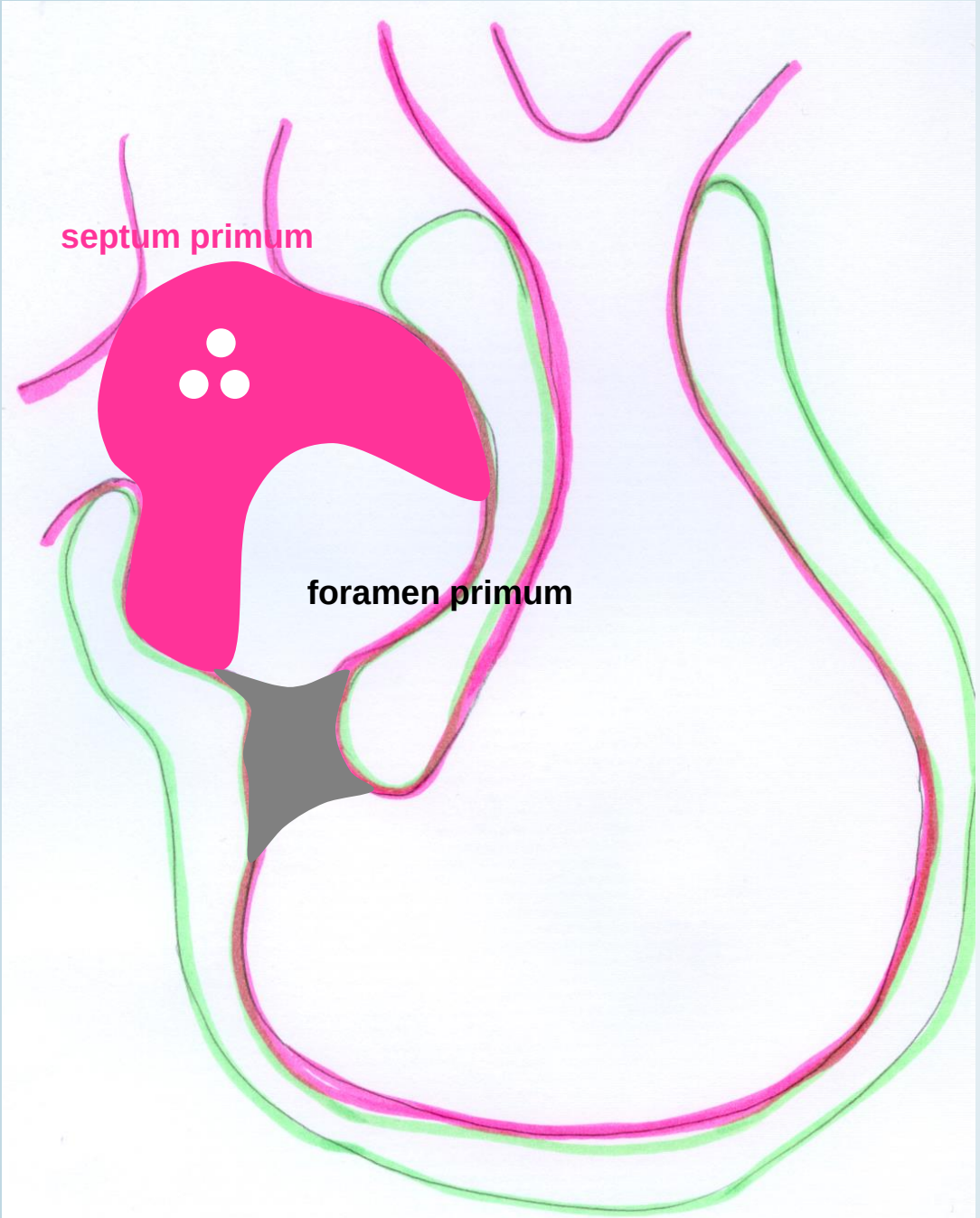
septum primum
foramen primum

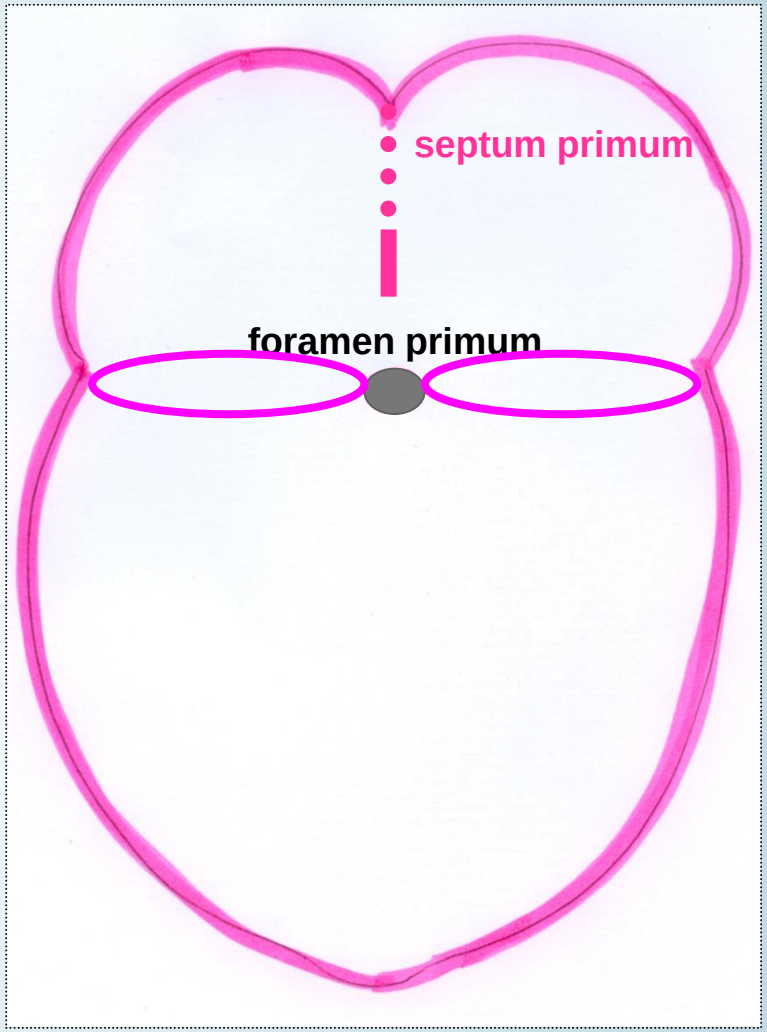
septum primum
foramen primum

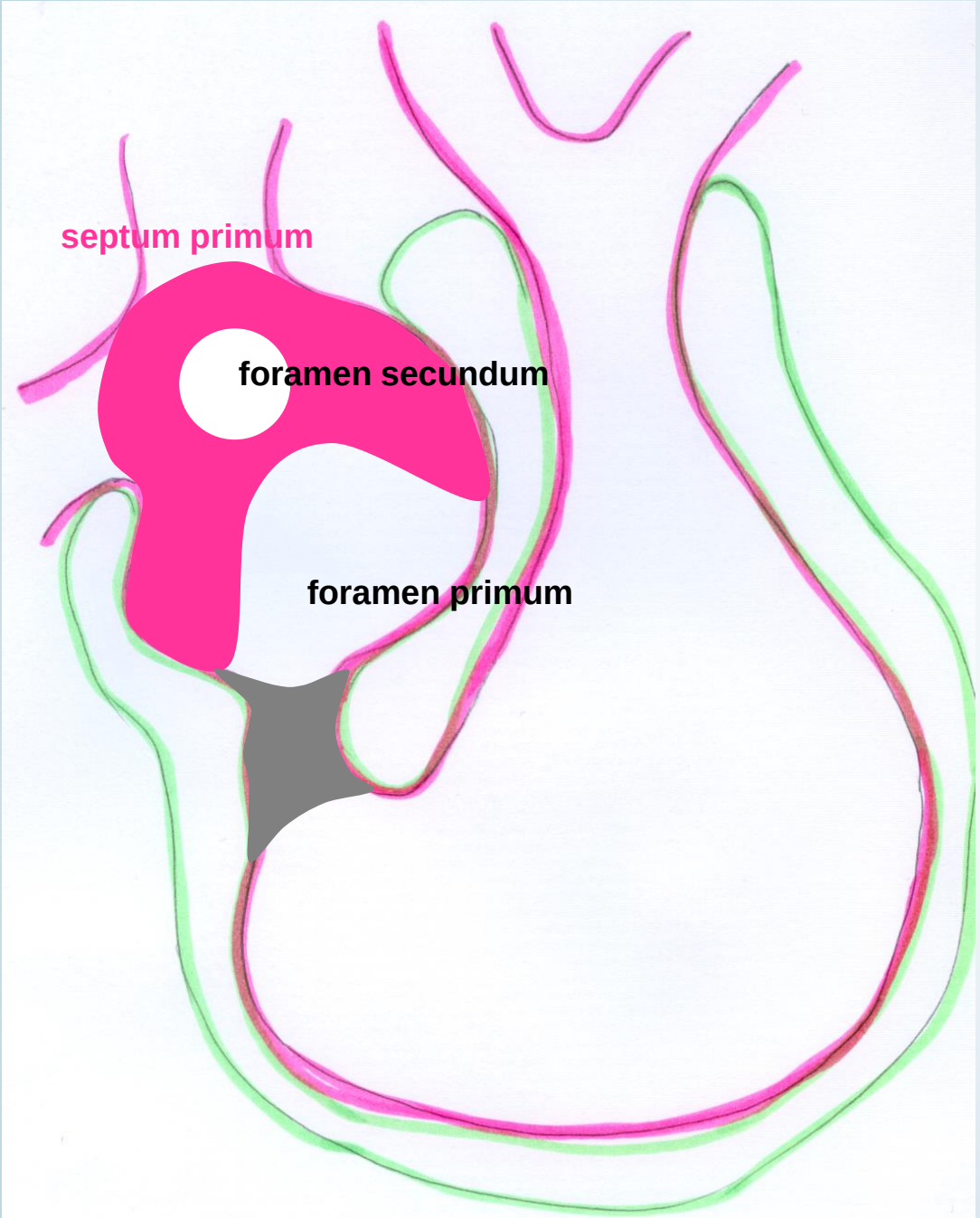
septum primum
foramen secundum
foramen primum

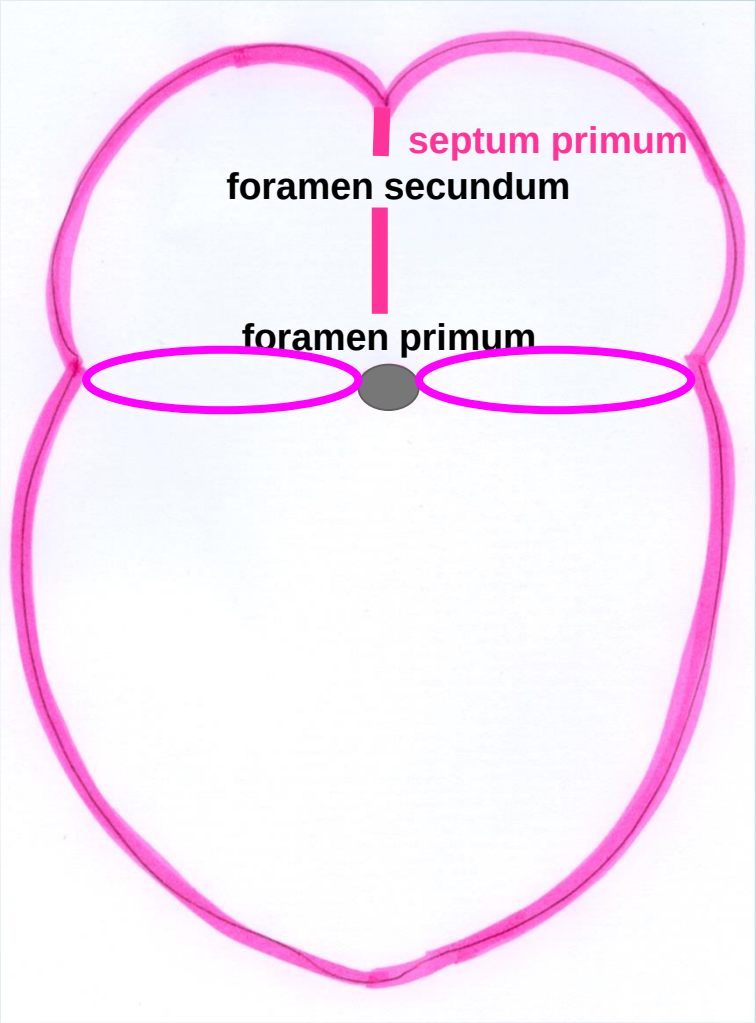
septum primum
foramen secundum
foramen primum

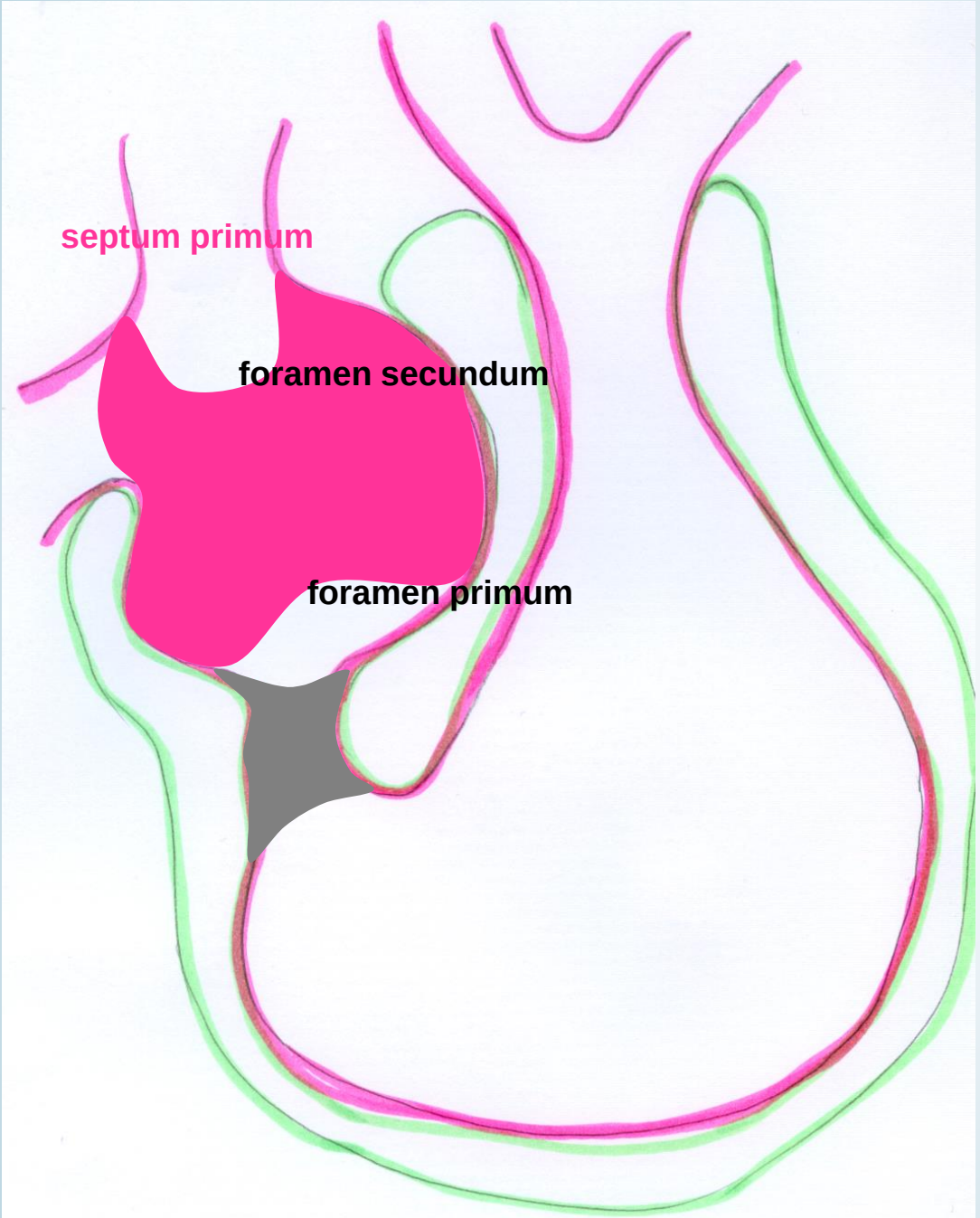
septum primum
foramen secundum
foramen primum

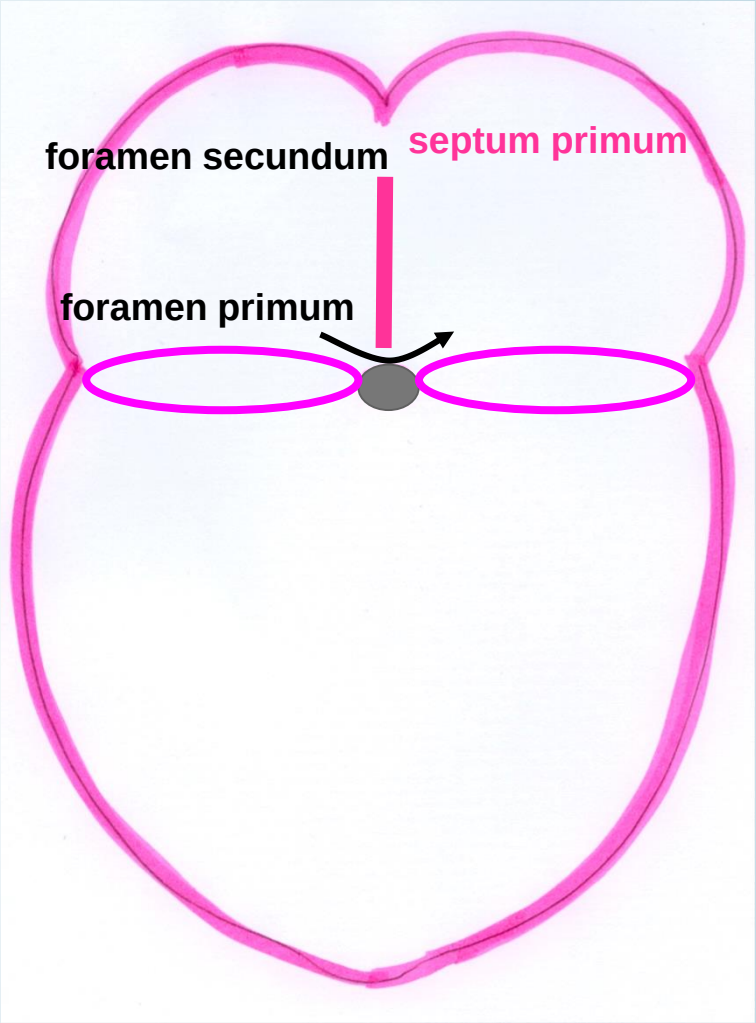
foramen secundum
septum primum
foramen primum

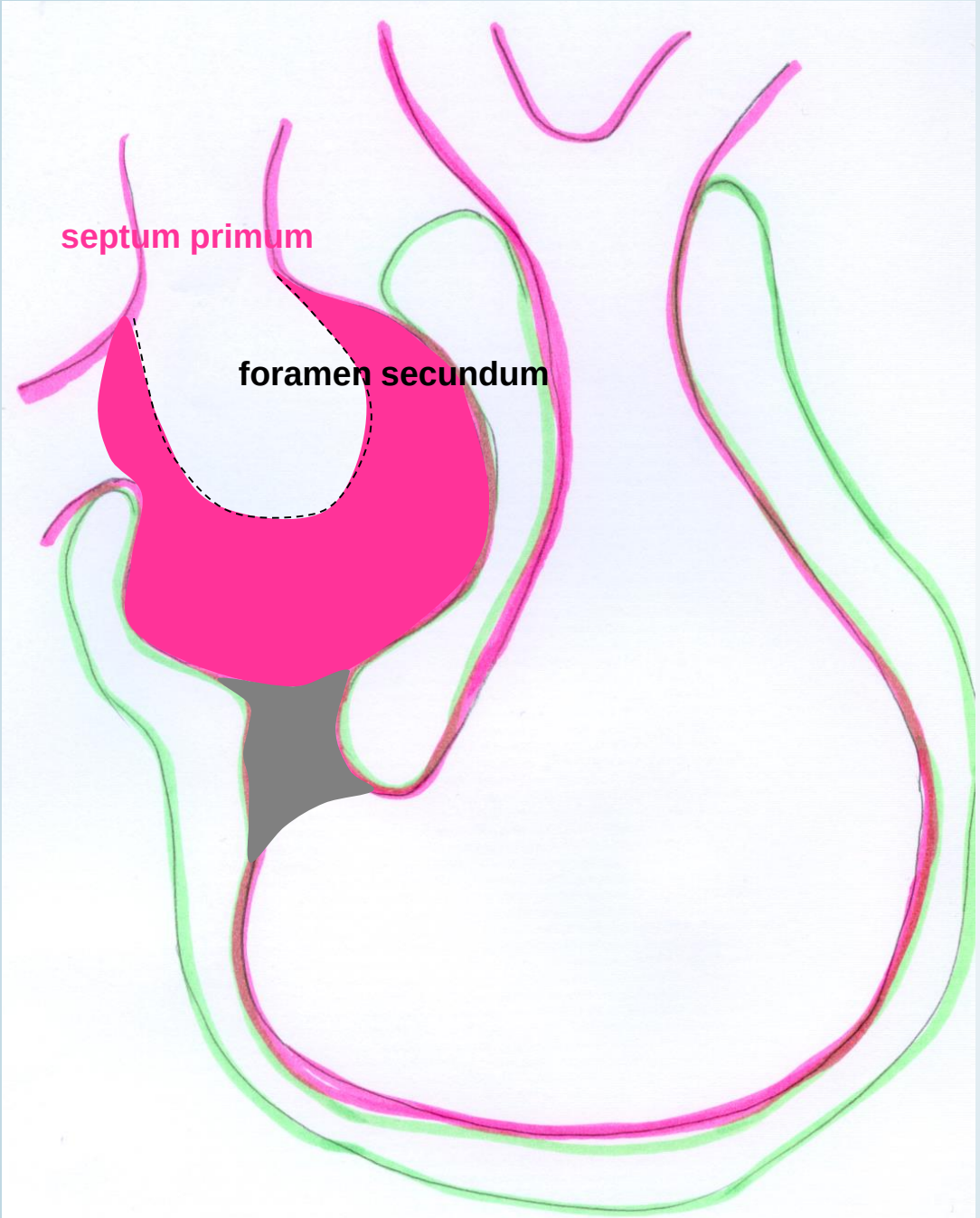
septum primum
foramen secundum

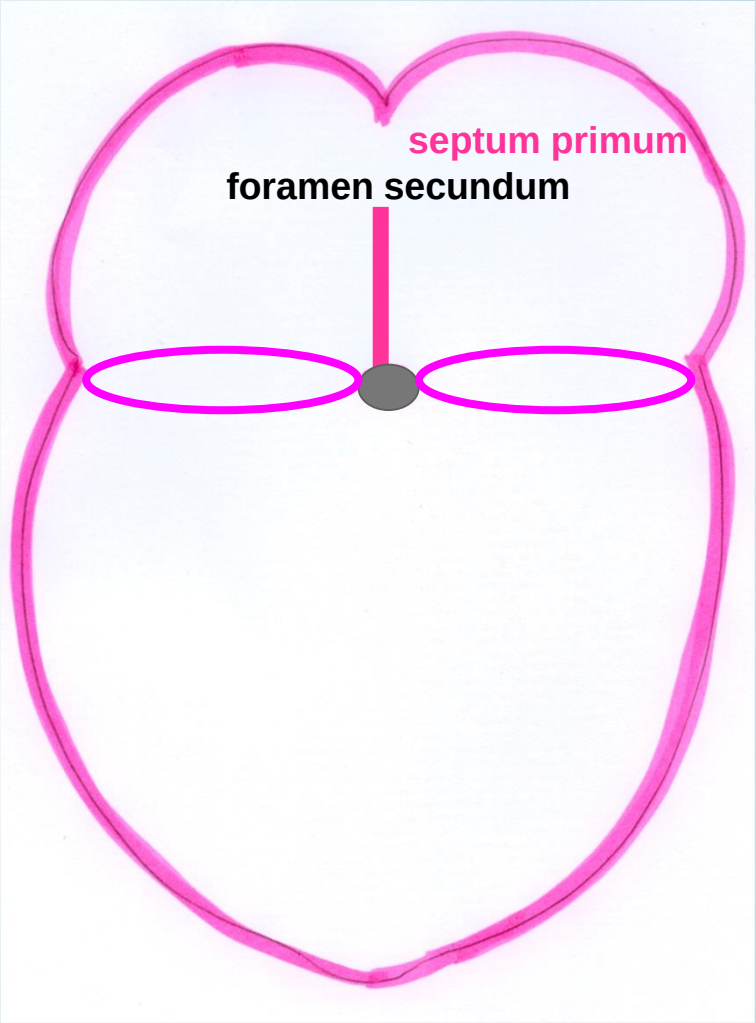
septum primum
foramen secundum


septum secundum
foramen ovale
septum primum

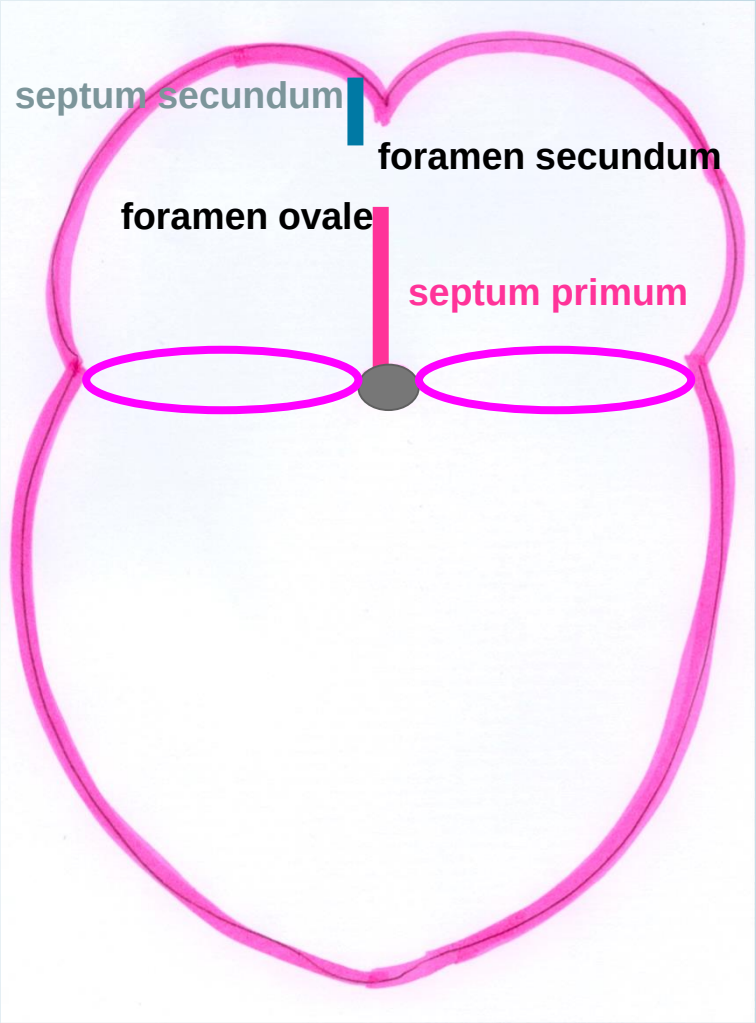
septum secundum
foramen secundum
foramen ovale
septum primum

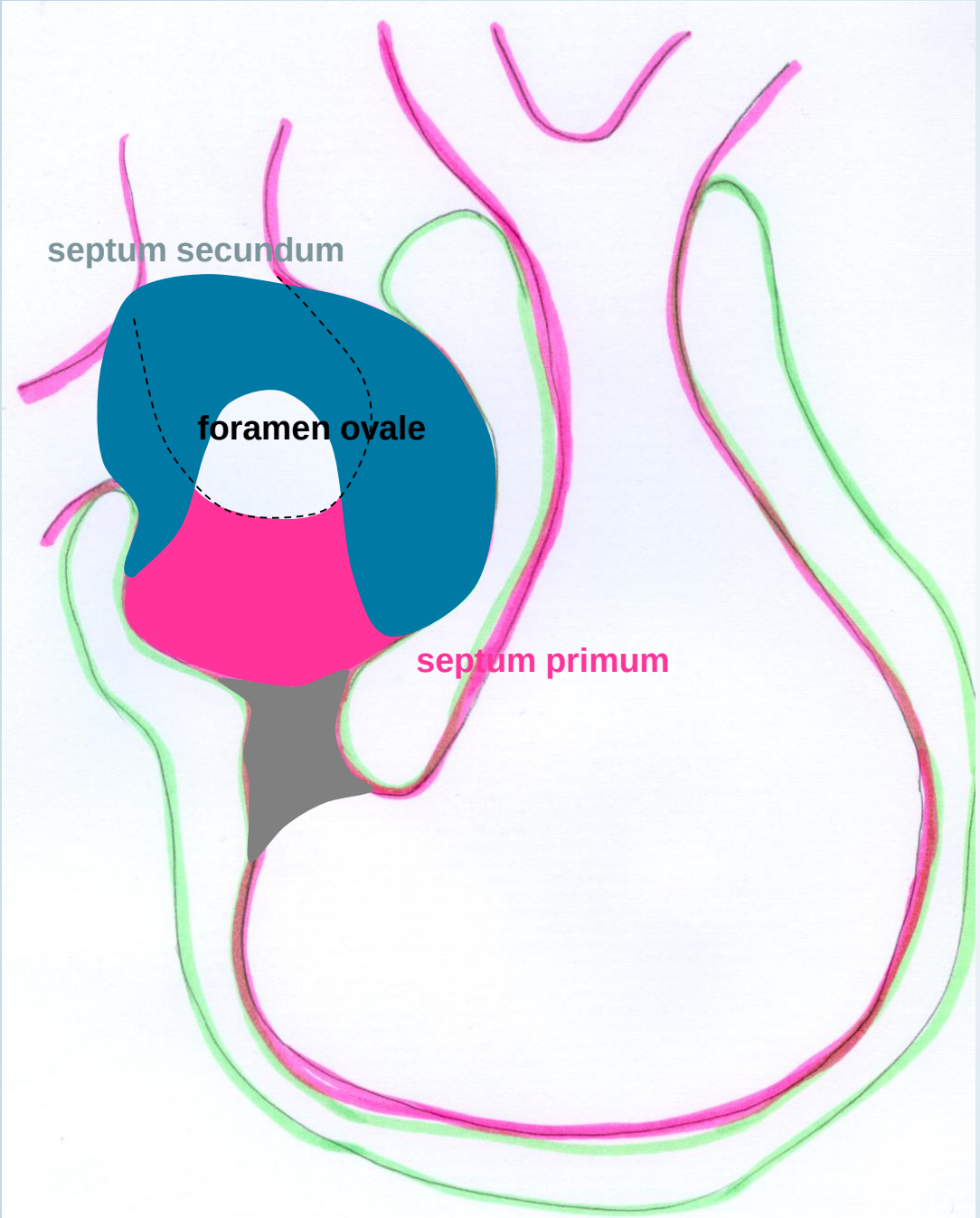
septum secundum
foramen ovale
septum primum

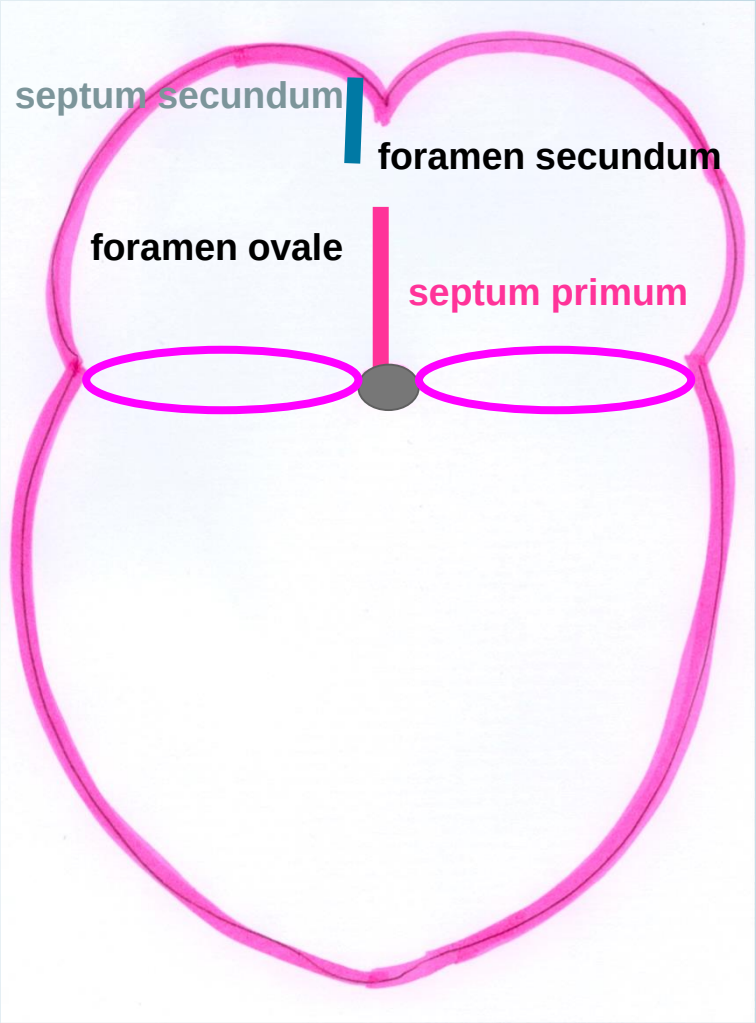
septum secundum
foramen secundum
foramen ovale
septum primum

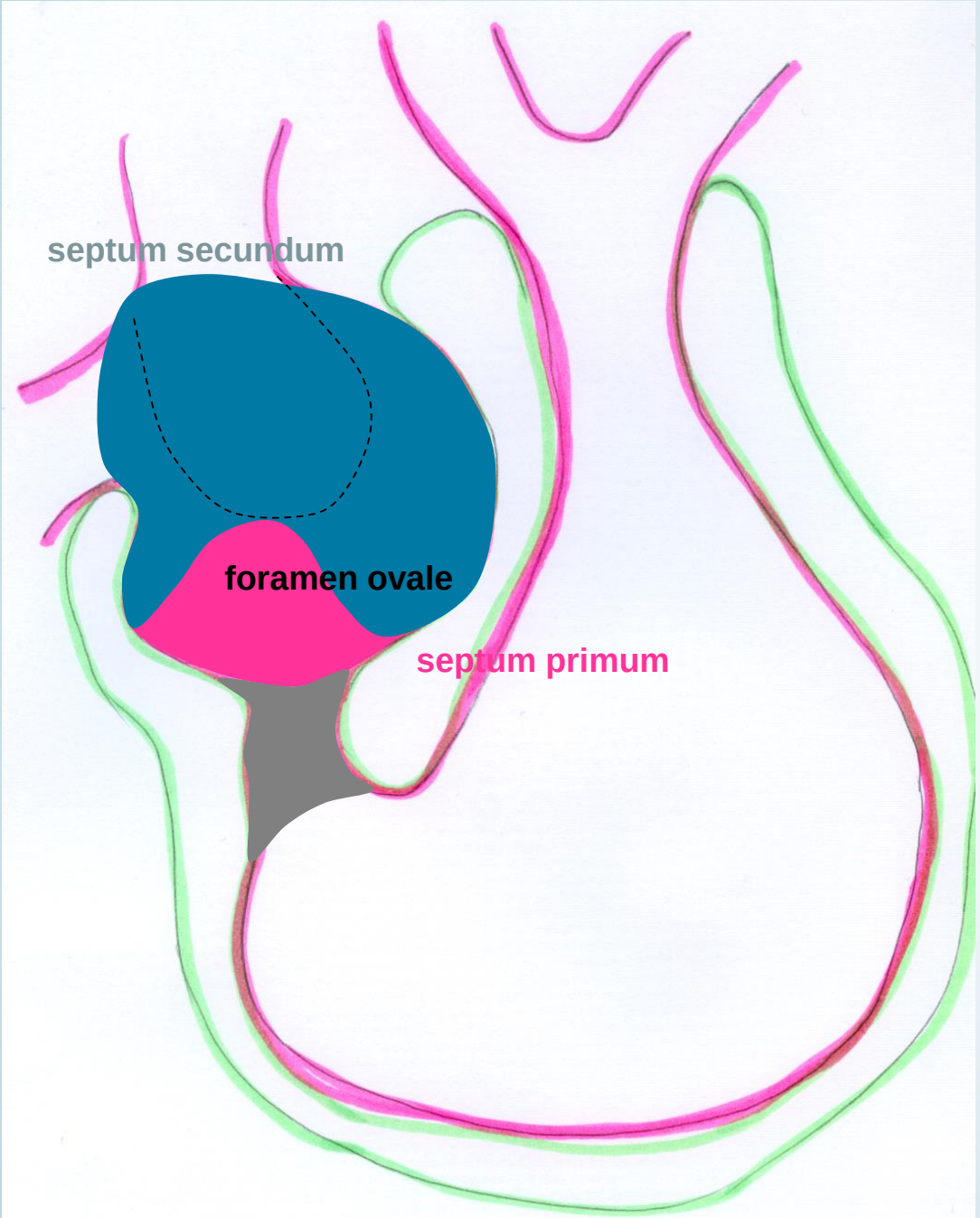
septum secundum
foramen ovale
septum primum

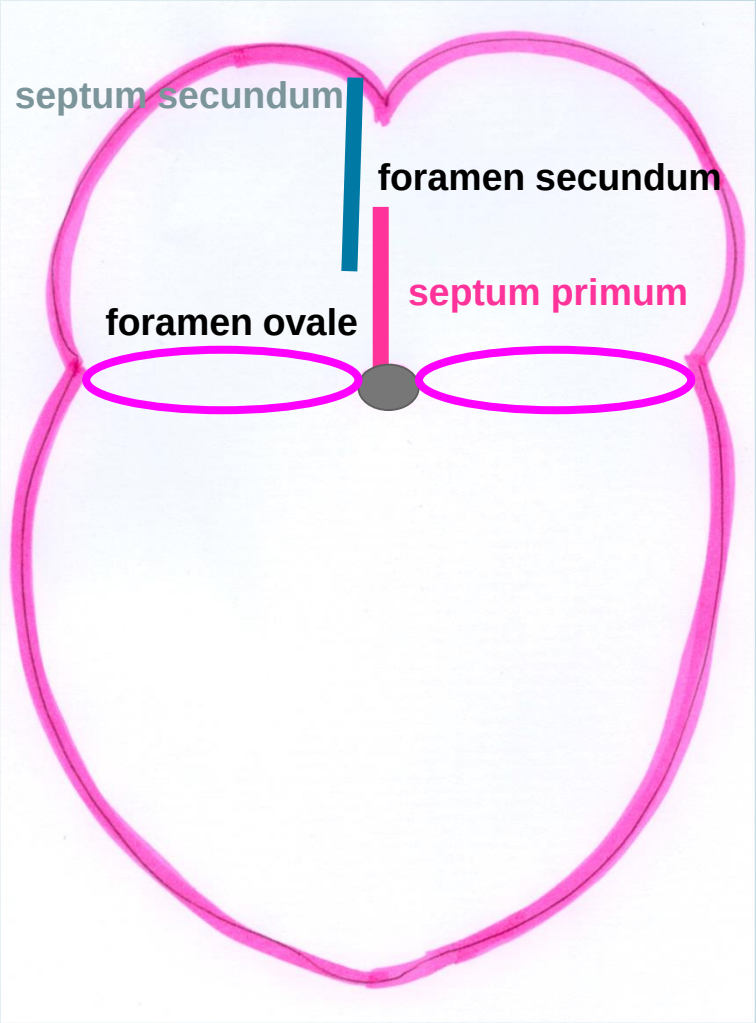
septum secundum
foramen secundum
septum primum
foramen ovale

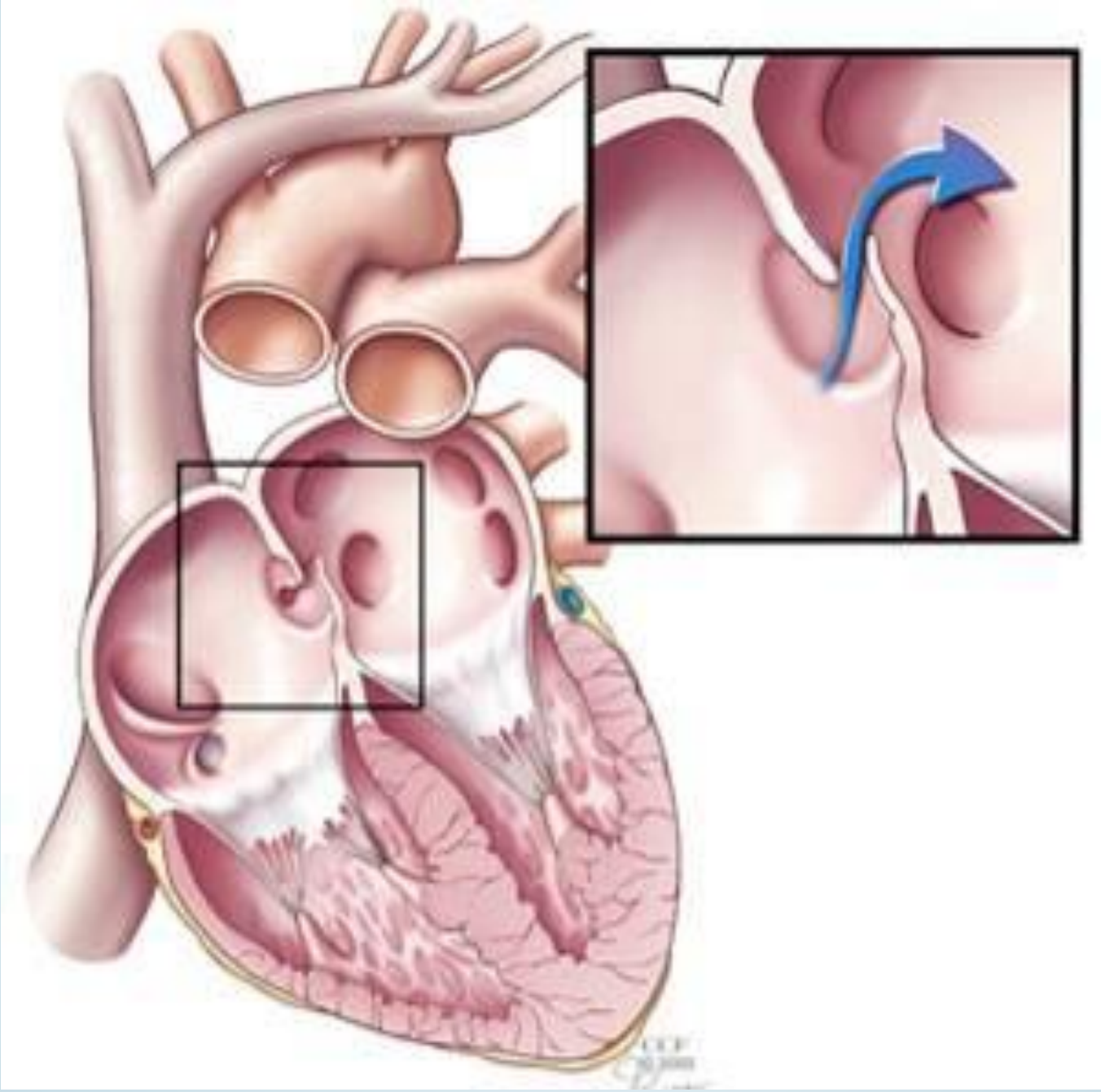

# SUMMARY

- *The septation of the common atrium starts with the appearance of the crescent-shaped septum primum. The opening of this septum, the foramen primum, becomes progressively smaller.*
- *Before the foramen primum completly closes, postero-superiorly several small openings appear on the septum primum. These perforations coalesce later and form the foramen secundum.*
- *On the right side of the septum primum a new septum, the septum secundum, starts to grow. The orifice of the septum secundum is the foramen ovale.*
- *Finally two crescent-like, incomplete, partially overlapping septa exist with one hole on each. Septum secundum is more rigid and the septum primum on its left side acts as a valve letting the blood flow exclusively from the right to the left. Its importance will become obvious when the fetal circulation is discussed.*

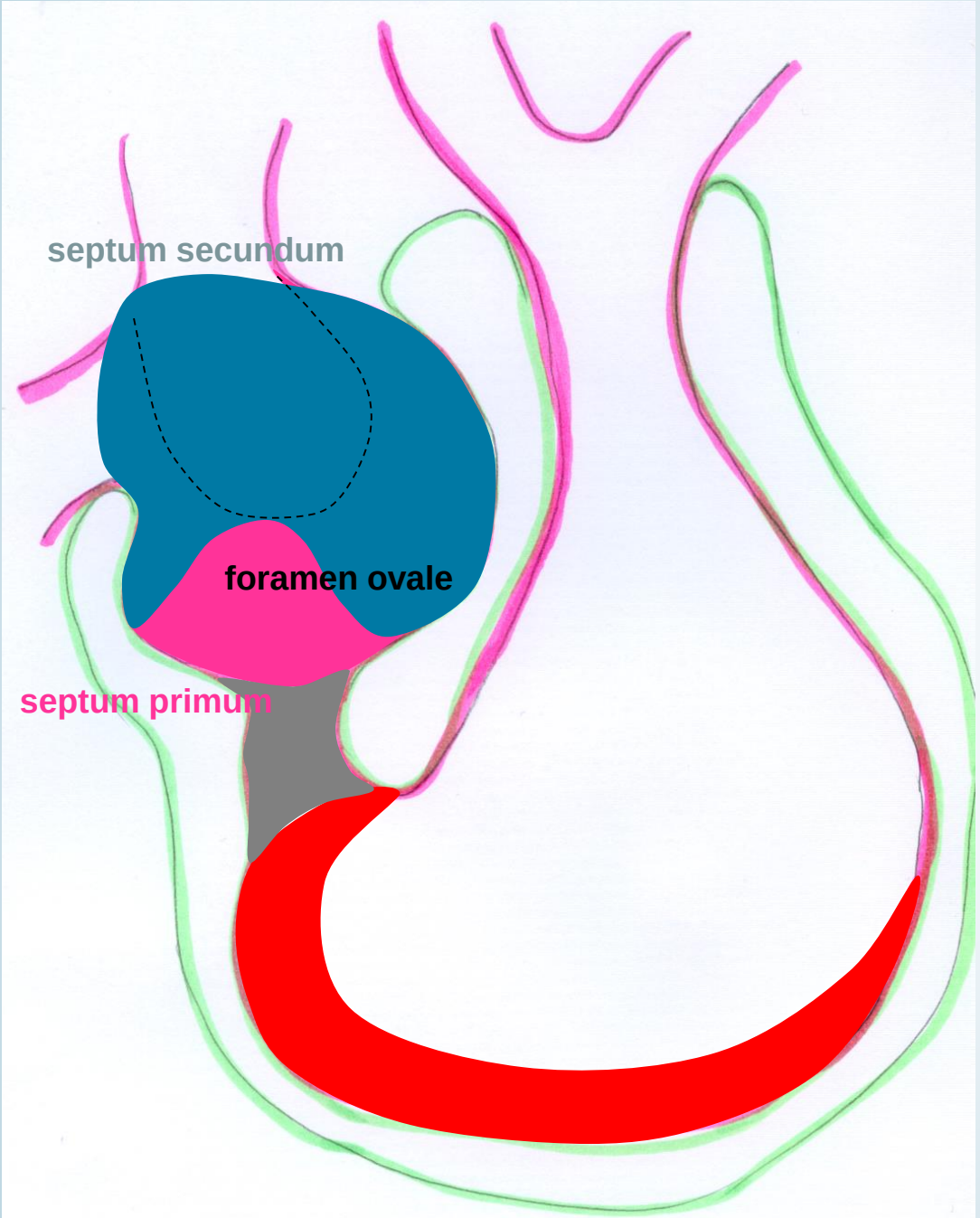
septum secundum
foramen ovale
septum primum

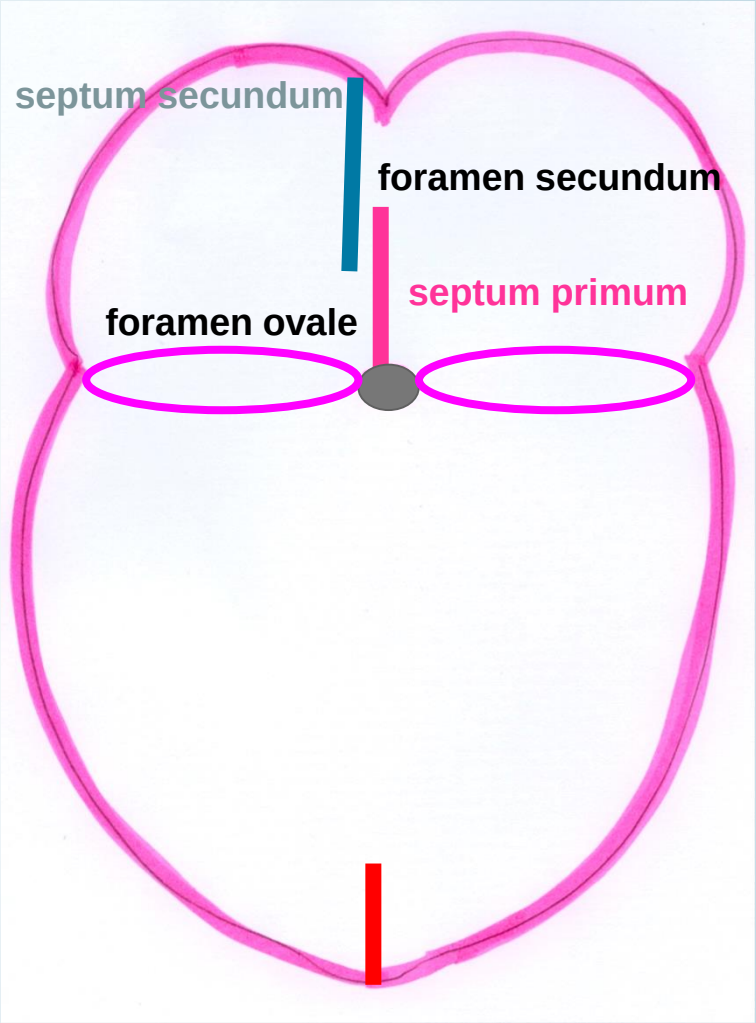
septum secundum
foramen secundum
septum primum
foramen ovale

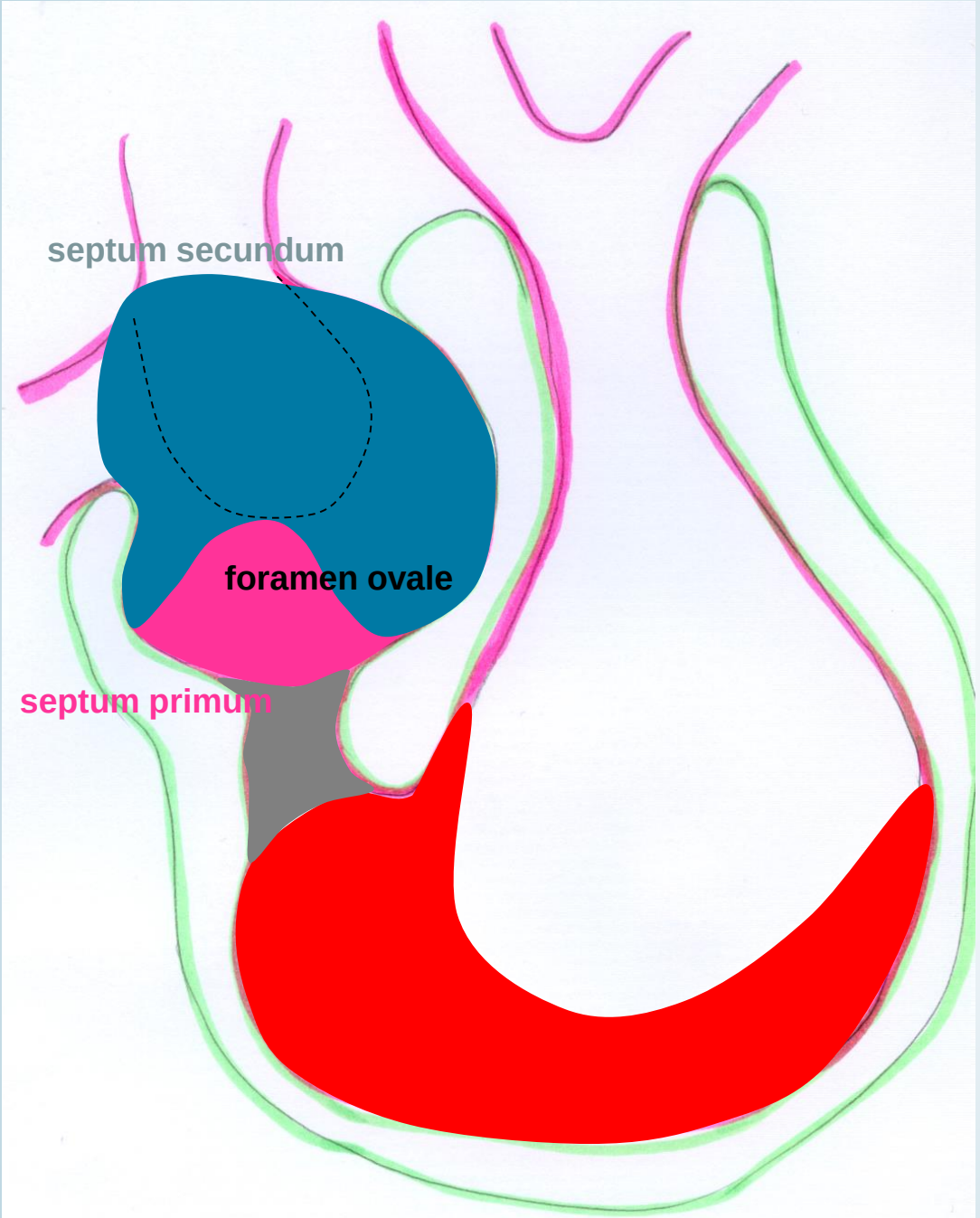
septum secundum
foramen ovale
septum primum

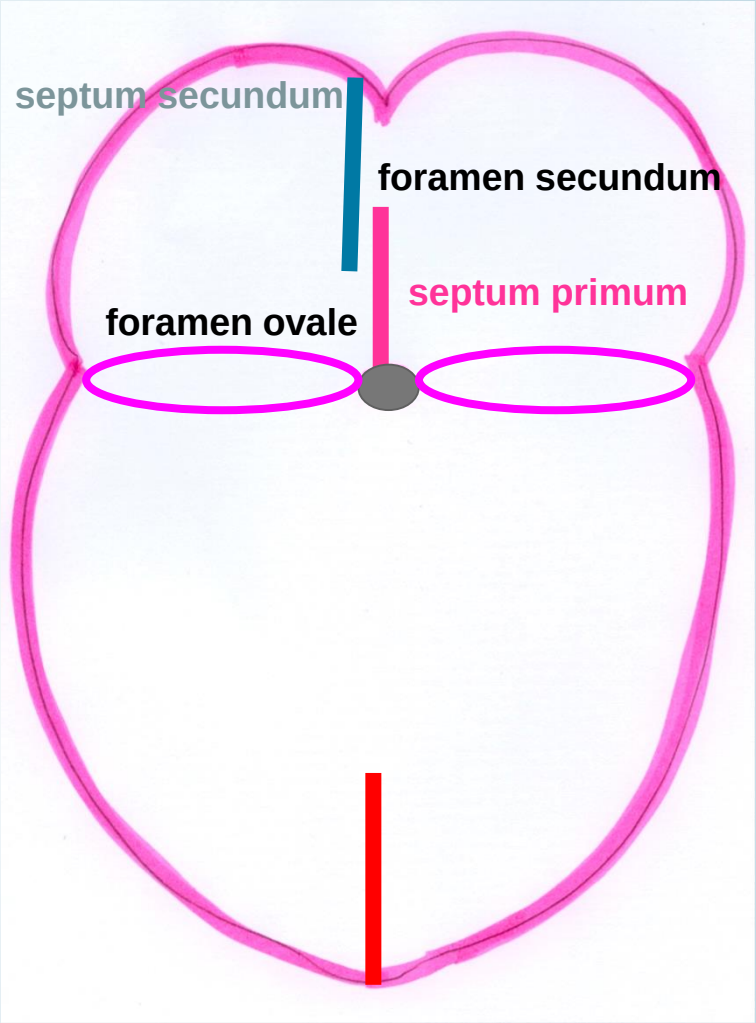
septum secundum
foramen secundum
septum primum
foramen ovale

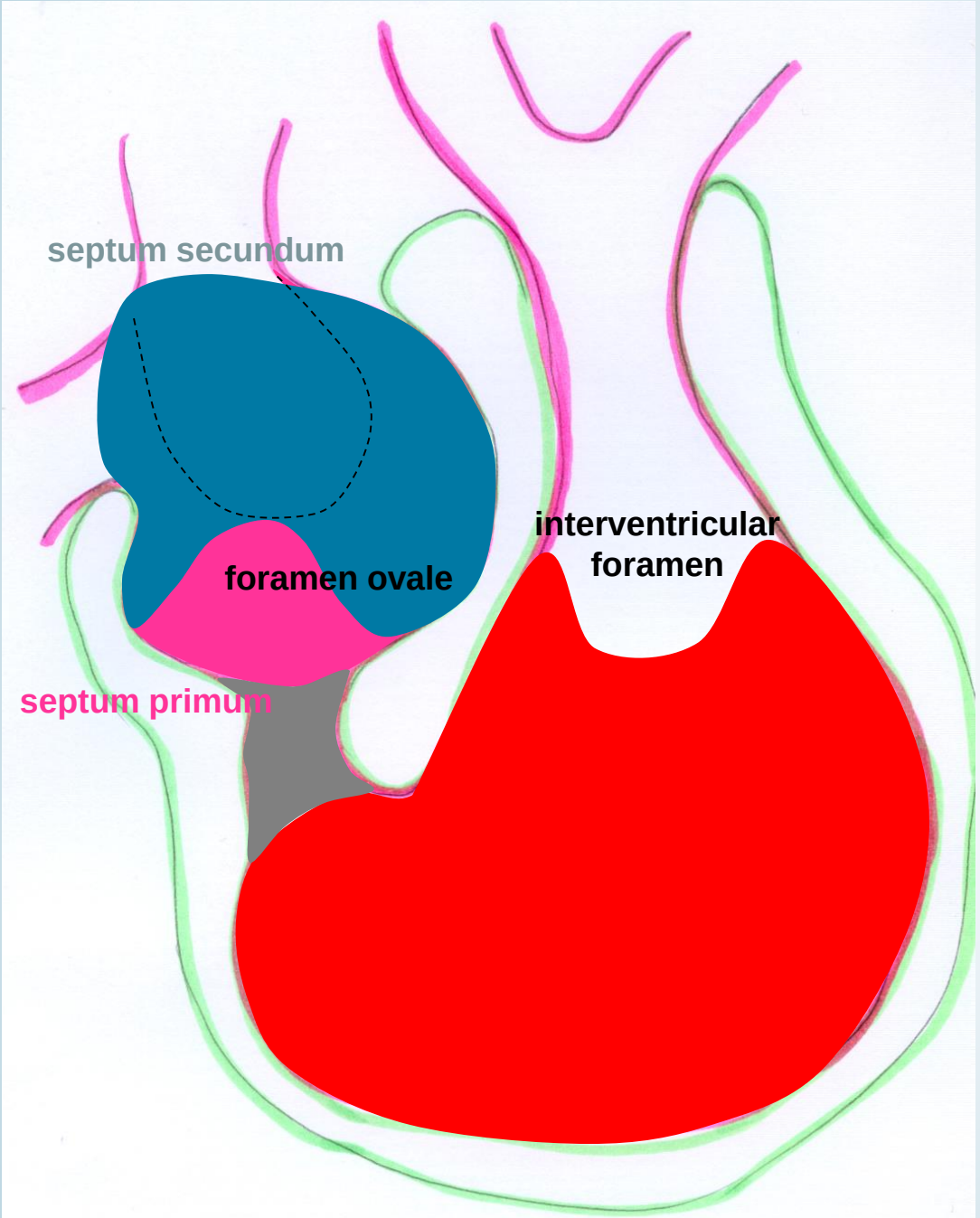
septum secundum
foramen ovale
interventricular
foramen
septum primum

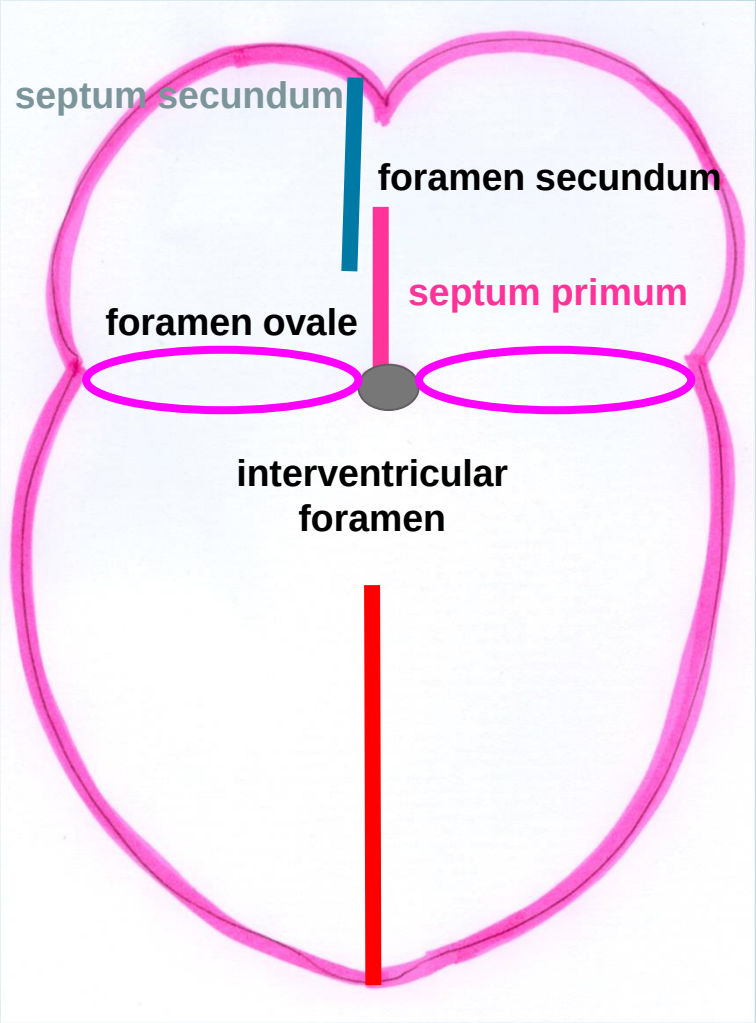
septum secundum
foramen secundum
septum primum
foramen ovale
interventricular
foramen

# SUMMARY

- *Nothing is simplier then the development of the muscular part of the interventricular septum.*

- *Similarly to the processes observeble at the level of atria, a crescent-like septum appears on the floor of the common ventricle. This septum grows upward until it reaches the bulbus cordis. Here the interventricular foramen persists for a while and will be closed by an other septum.*

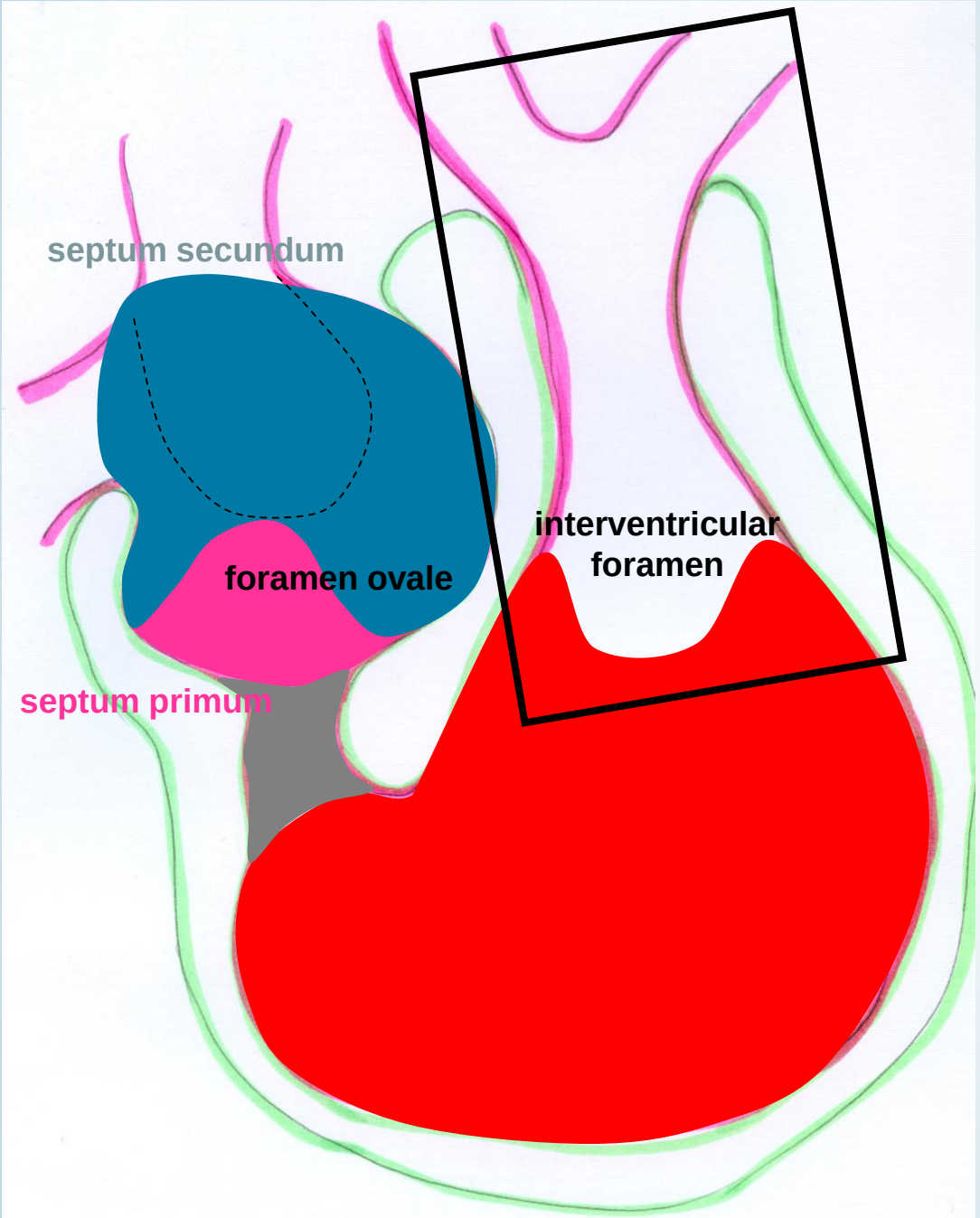
septum secundum
foramen ovale
septum primum
interventricular
foramen

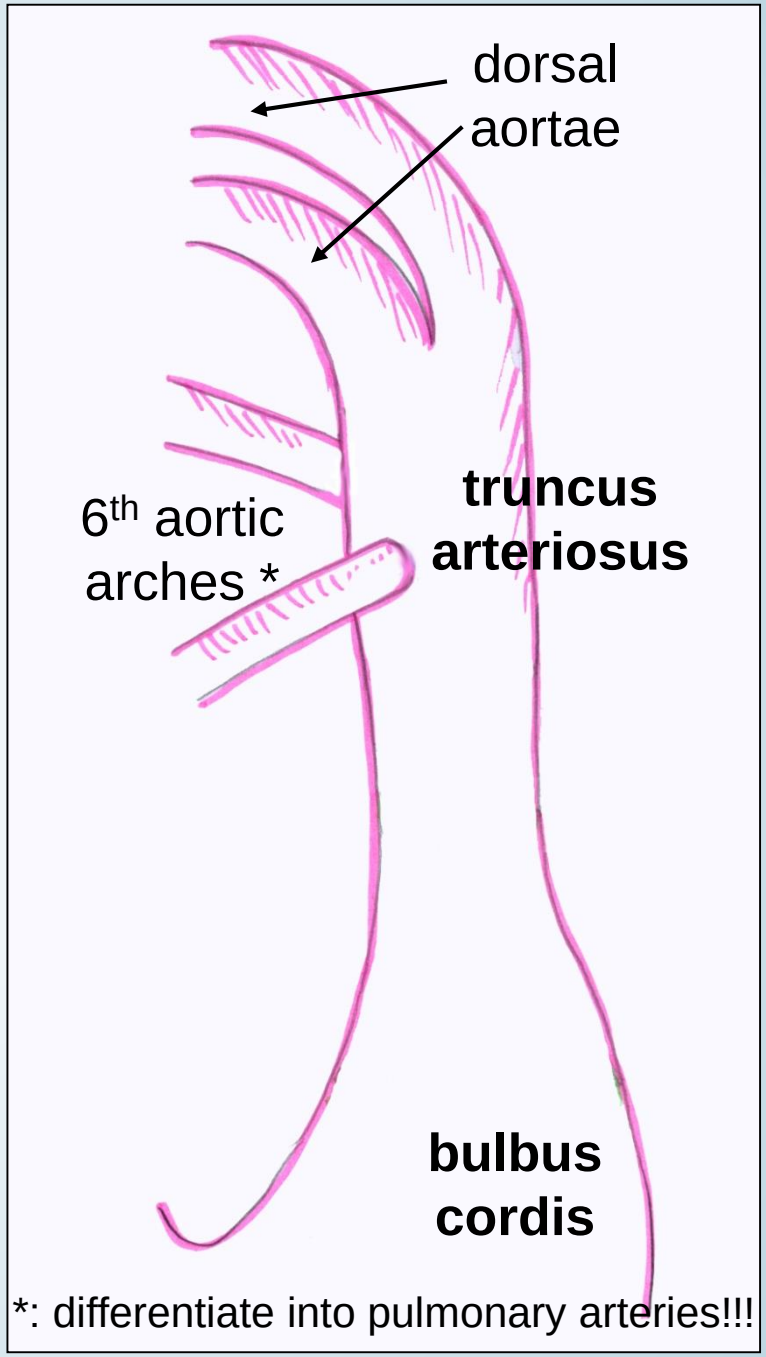
dorsal
aortae
6th aortic
arches *
truncus
arteriosus
bulbus
cordis
*: differentiate into pulmonary arteries!!!

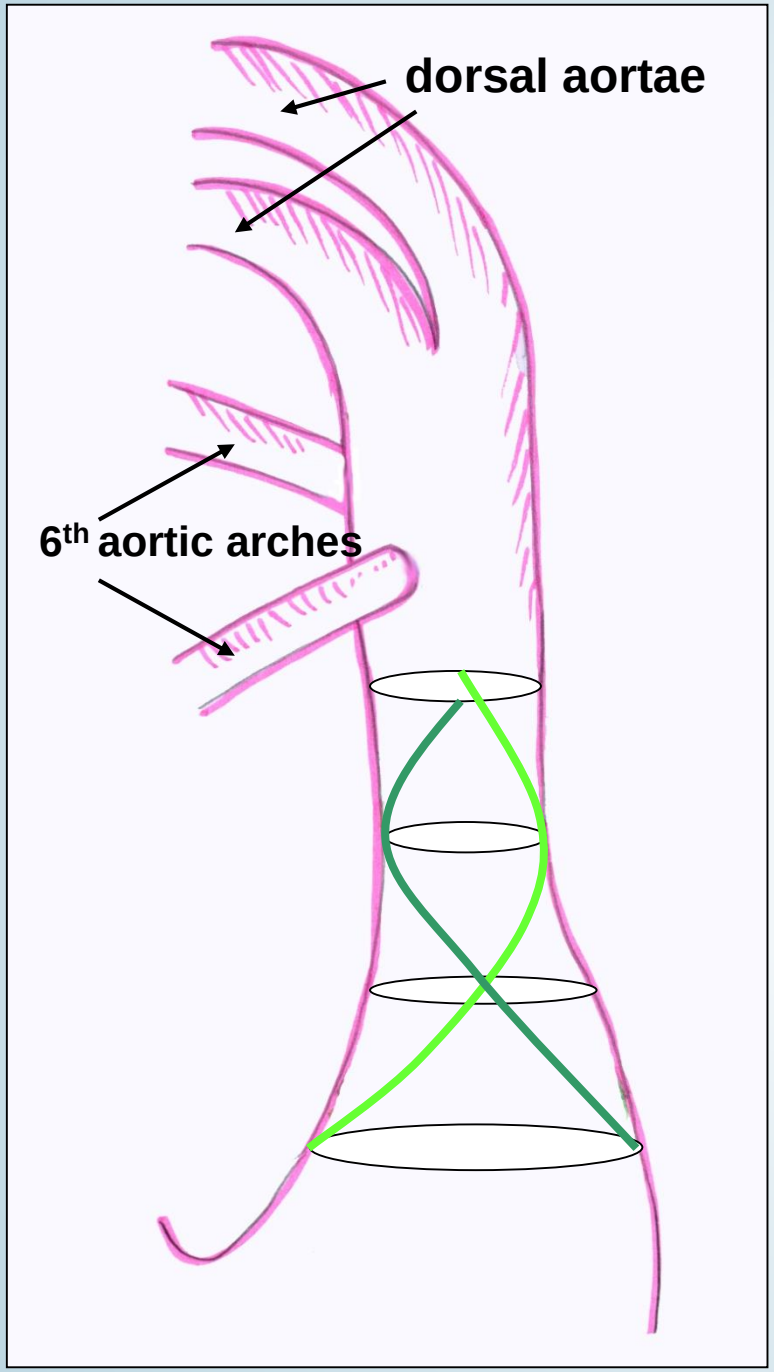


In the bulbus cordis and the truncus arteriosus two endocardial thickenings, bulbar and truncal ridges appear and exhibit a spiral course twisting 270 degrees* (90 degrees in each third of the full length).

* Different values between 180 and 270 degrees can be found in different textbooks.

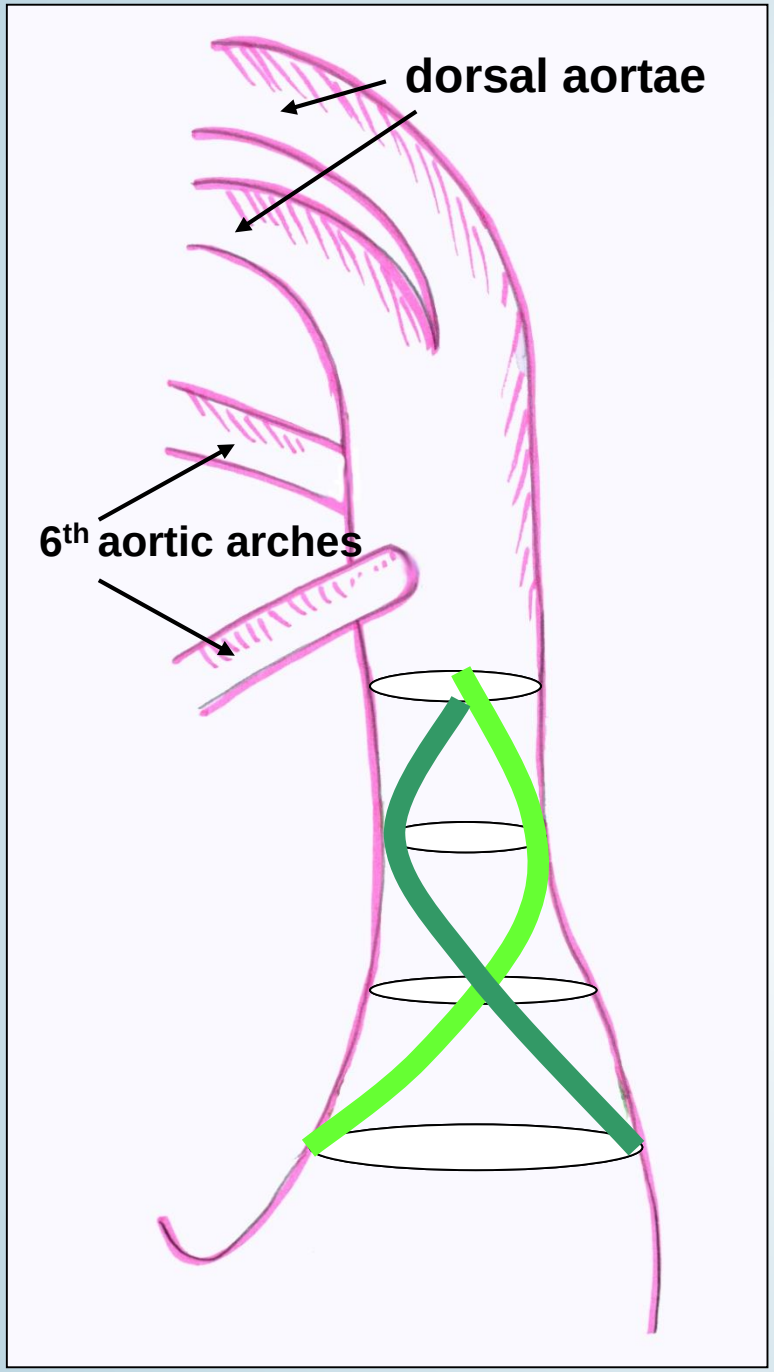


The two bulbar and truncal ridges
(= conotruncal ridges as used by others)
approach each other.

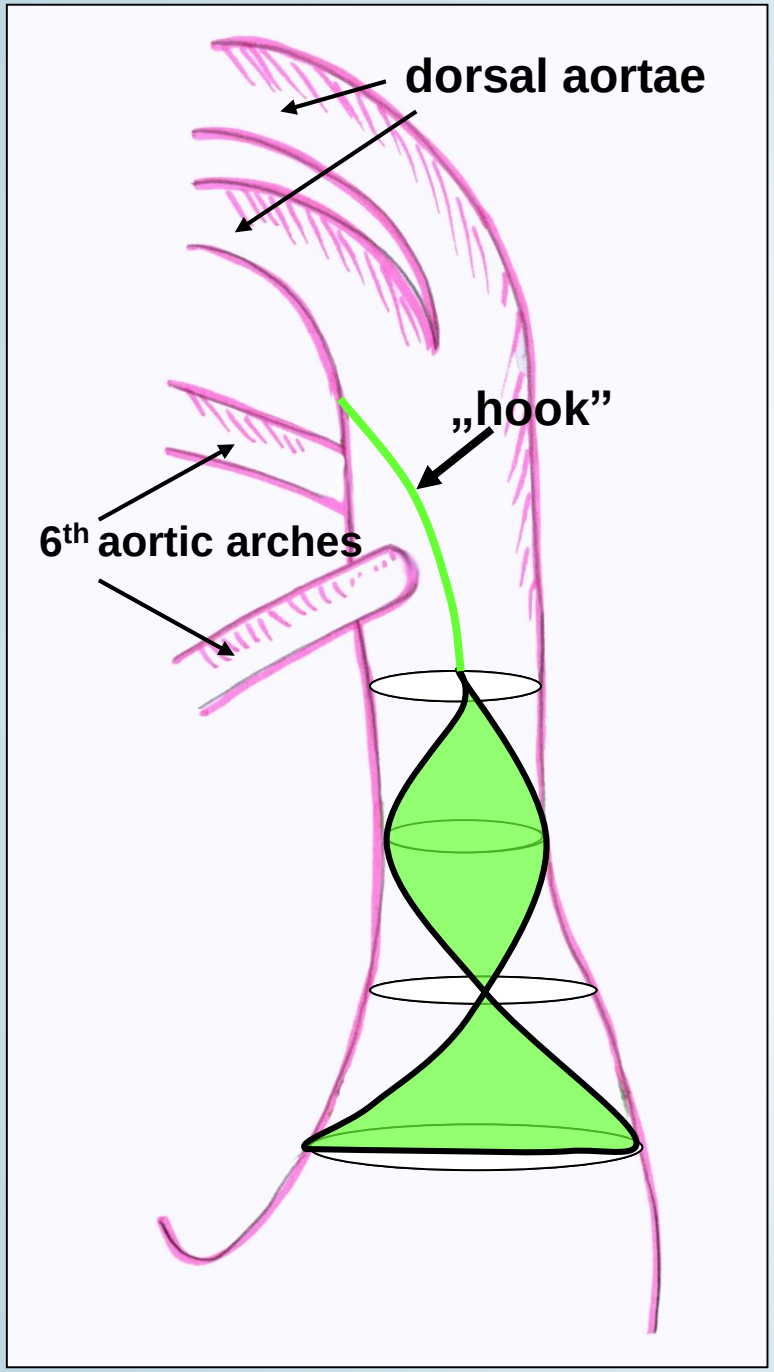


Finally, a complete spiral septum is formed. An additional hook-shaped septum arises from the superior edge of this septum and isolates the posterior portion of the truncus arteriosus.

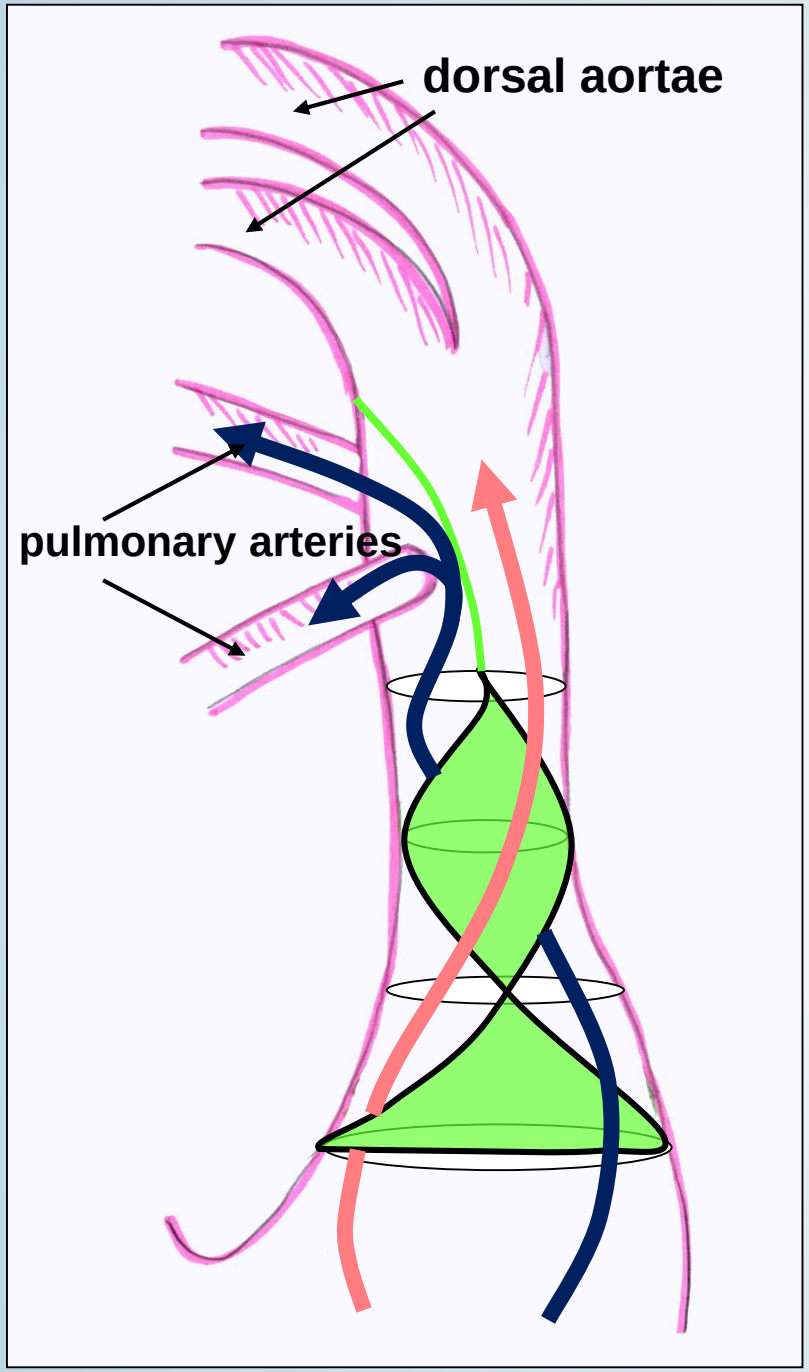


Venous blood (blue) from the right ventricle ascends and from the posterior portion of the truncus arteriosus may only flow toward the pulmonary arteries developing from the 6th aortic arches. Blood from the left ventricle (red) exits through the two dorsal aortae.

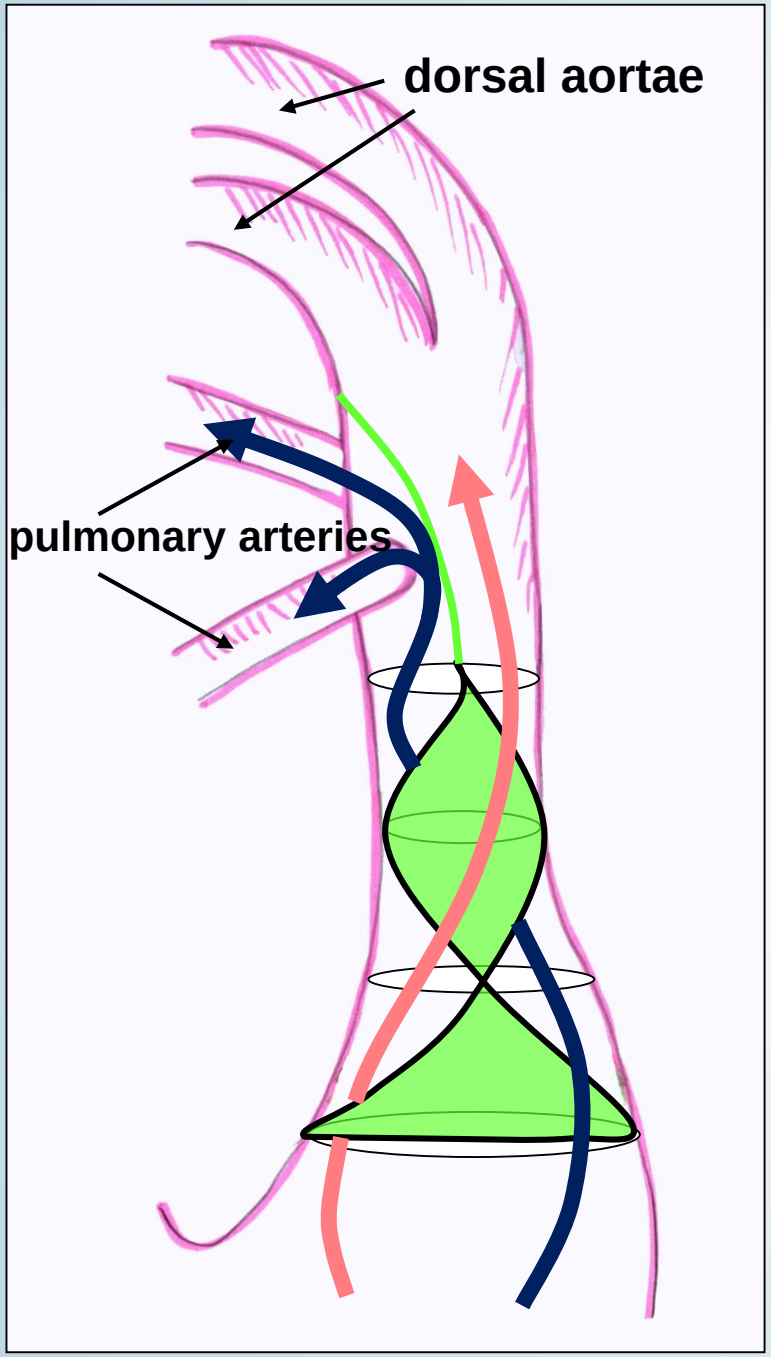
dorsal aortae
pulmonary arteries

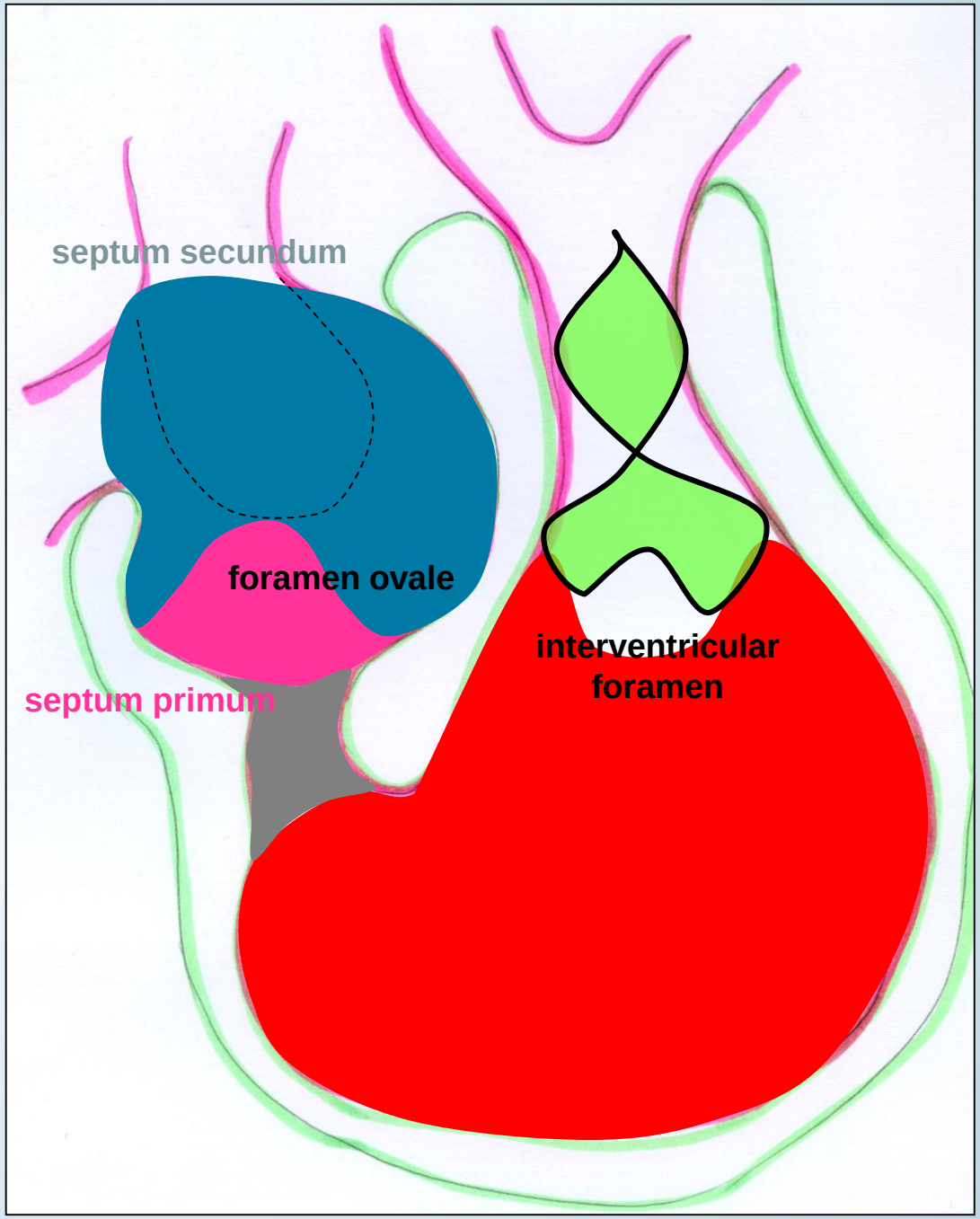
septum secundum
foramen ovale
septum primum
interventricular
foramen

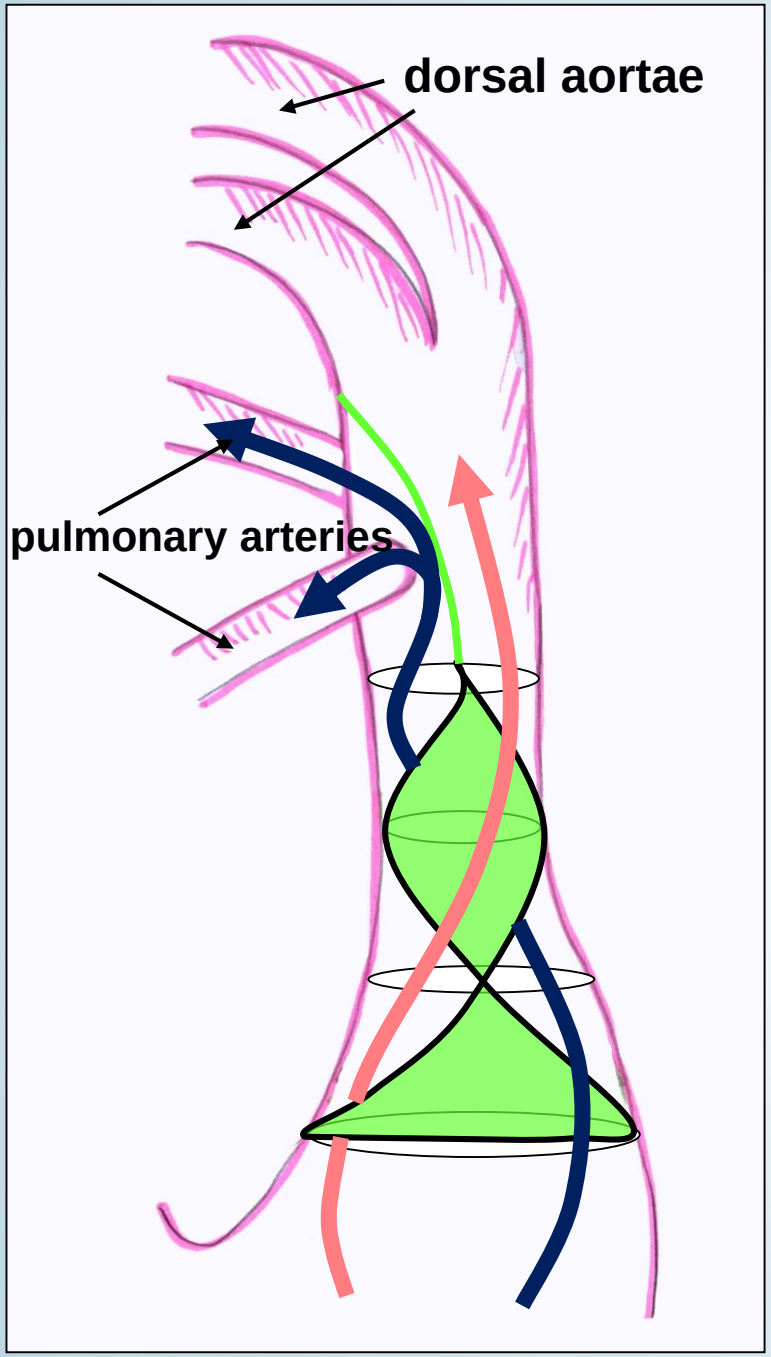
dorsal aortae
pulmonary arteries

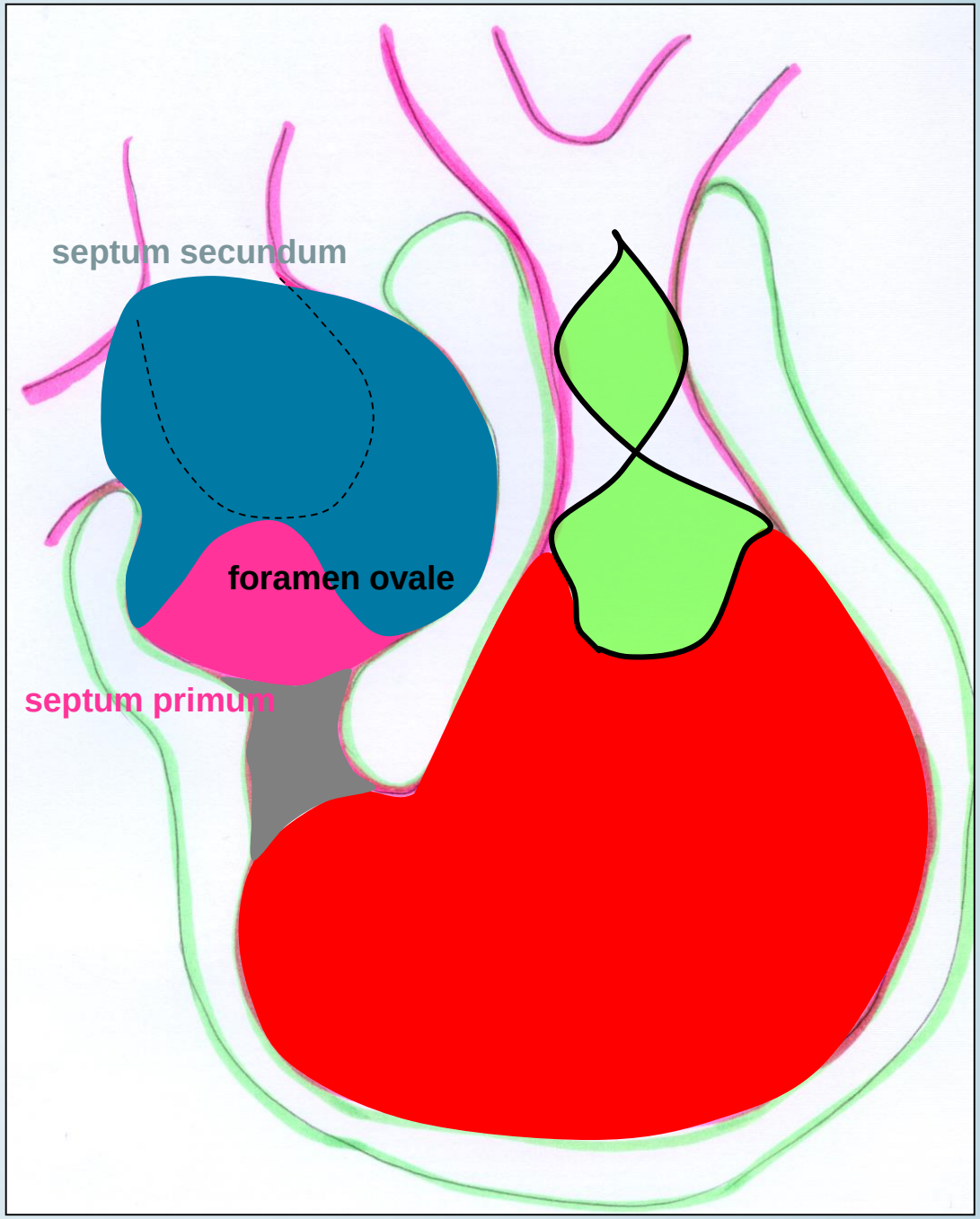
septum secundum
foramen ovale
septum primum

conotruncal = bulbar/truncal ridges

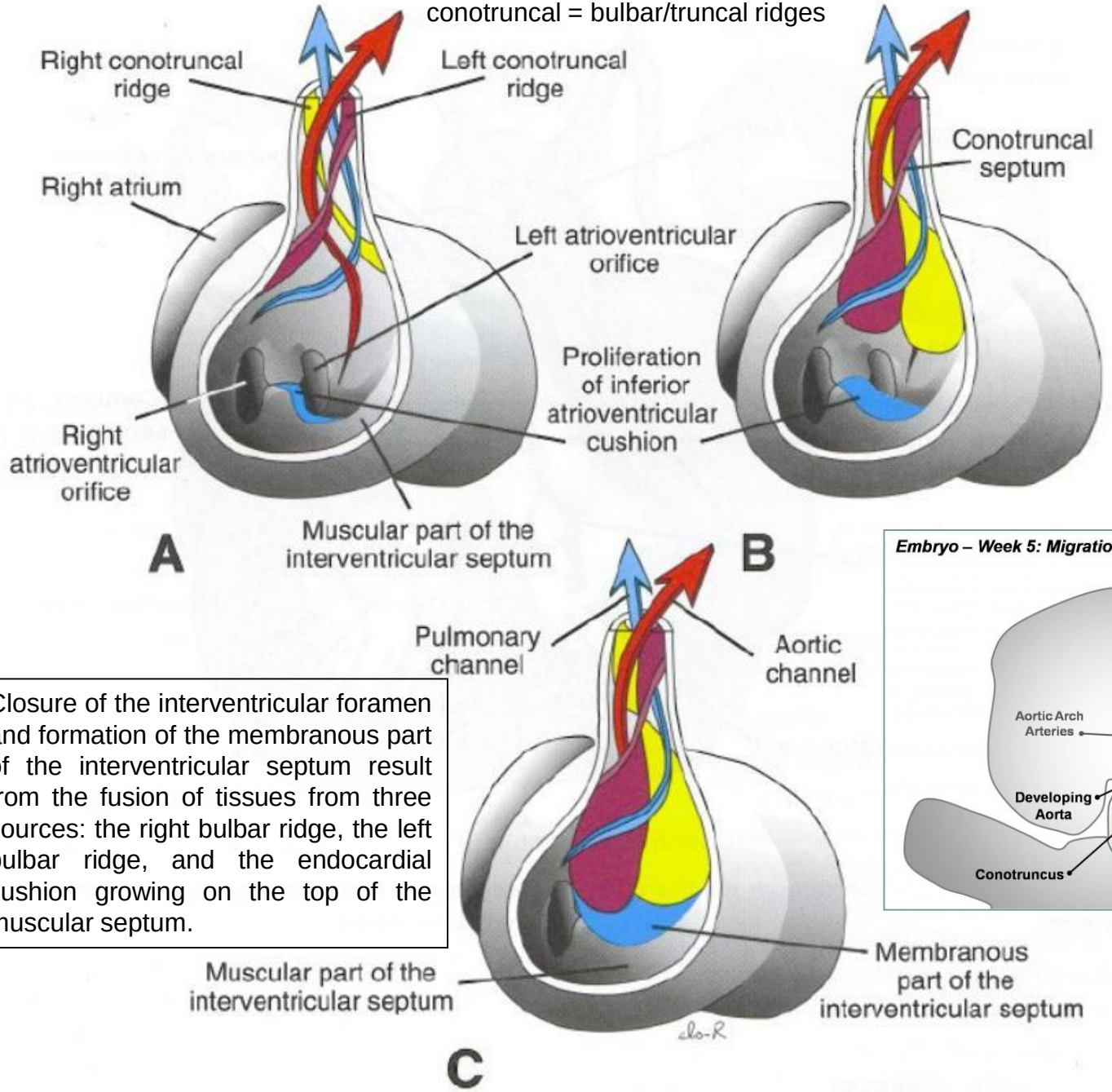


Closure of the interventricular foramen and formation of the membranous part of the interventricular septum result from the fusion of tissues from three sources: the right bulbar ridge, the left bulbar ridge, and the endocardial cushion growing on the top of the muscular septum.

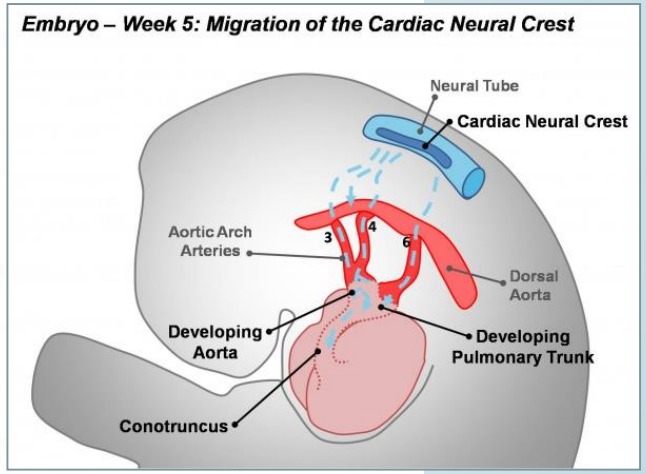

# Why is the formation of the aorticopulmonary septum so complicated?

**straight tube**

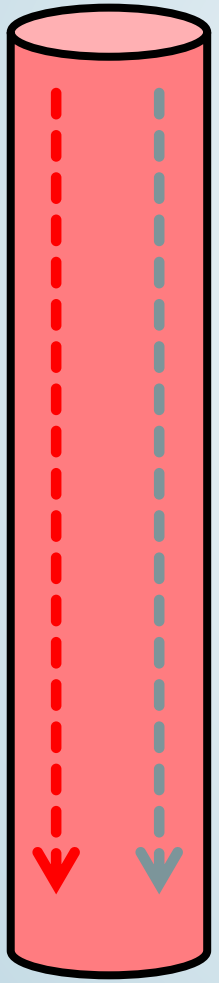

**bent tube**
discrepancy between the length of the red and blue patways

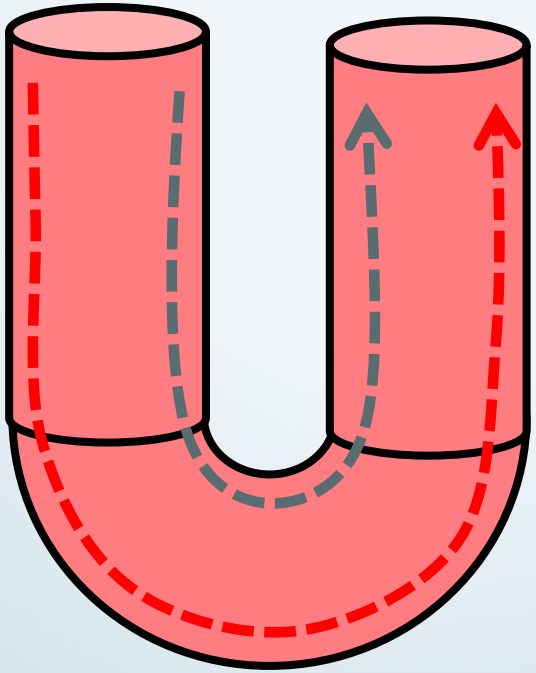

**bent tube**
crossing of the two patways eliminates the former discrepancy

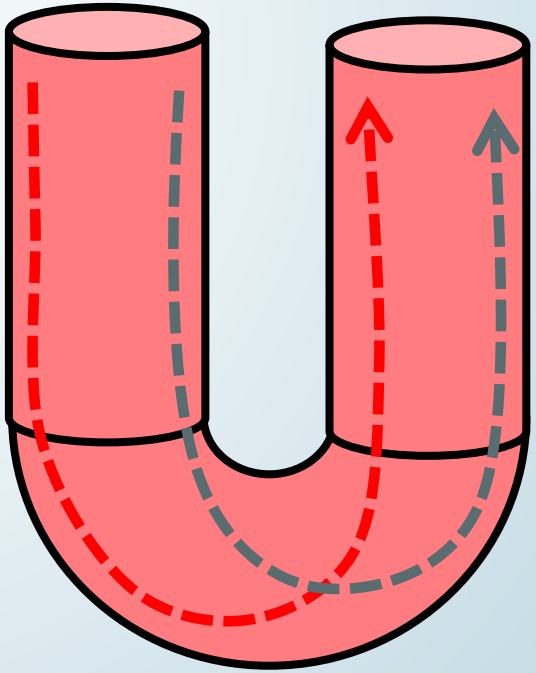

# Summary

- *Finally a spiral septum twisting 270 degrees develops within the bulbus cordis and truncus arteriosus. The inferior portion of the spiral septum (also called bulbar septum) unites with the muscular interventricular septum. The superior part of the spiral septum (truncal septum or more commonly the aorticopulmonary septum) isolates the aorta and the pulmonary trunk. With this step, the septation of the common ventricle into a left and right half is completed.*

- *Must be noted, that the uncomplete union of the membraneous aorticopulmonary and the muscular interventricular septum is the most frequent reason of the ventricular septal defect, one of the most common heart malformations. (Roughly occurs in 1 out of 100 newborns.)*

- *Spiral orientation of the aorticopulmonary septum can be explained by the spiral blood flow due to the bending of the heart. Walls develop where they are let to develop: where the blood streams are relatively quiet.*

# IV. A few words about the valves...

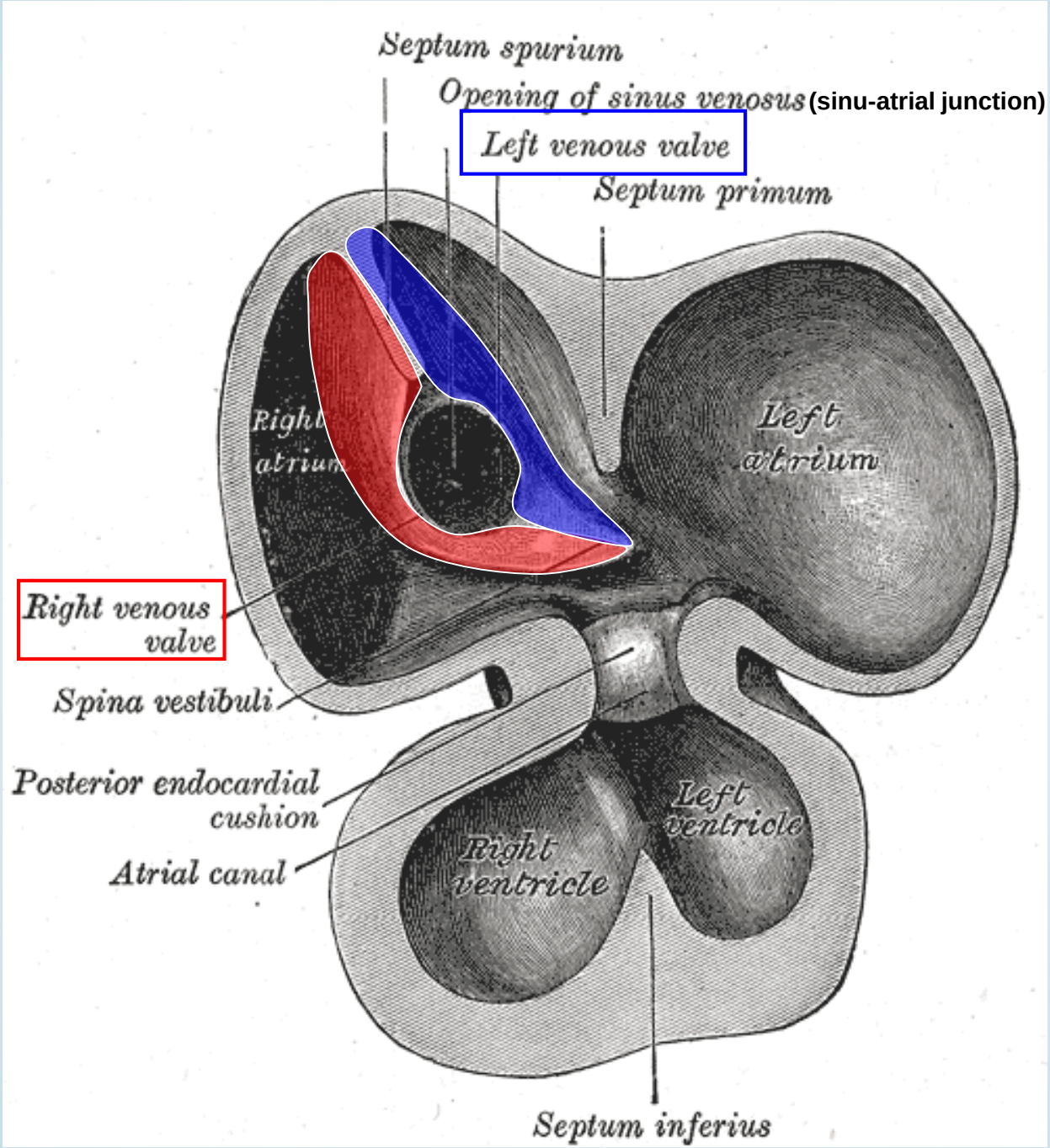
Septum spurium
Opening of sinus venosus (sinu-atrial junction)
Left venous valve
Septum primum
Right atrium
Left atrium
Right venous valve
Spina vestibuli
Posterior endocardial cushion
Atrial canal
Right ventricle
Left ventricle
Septum inferius

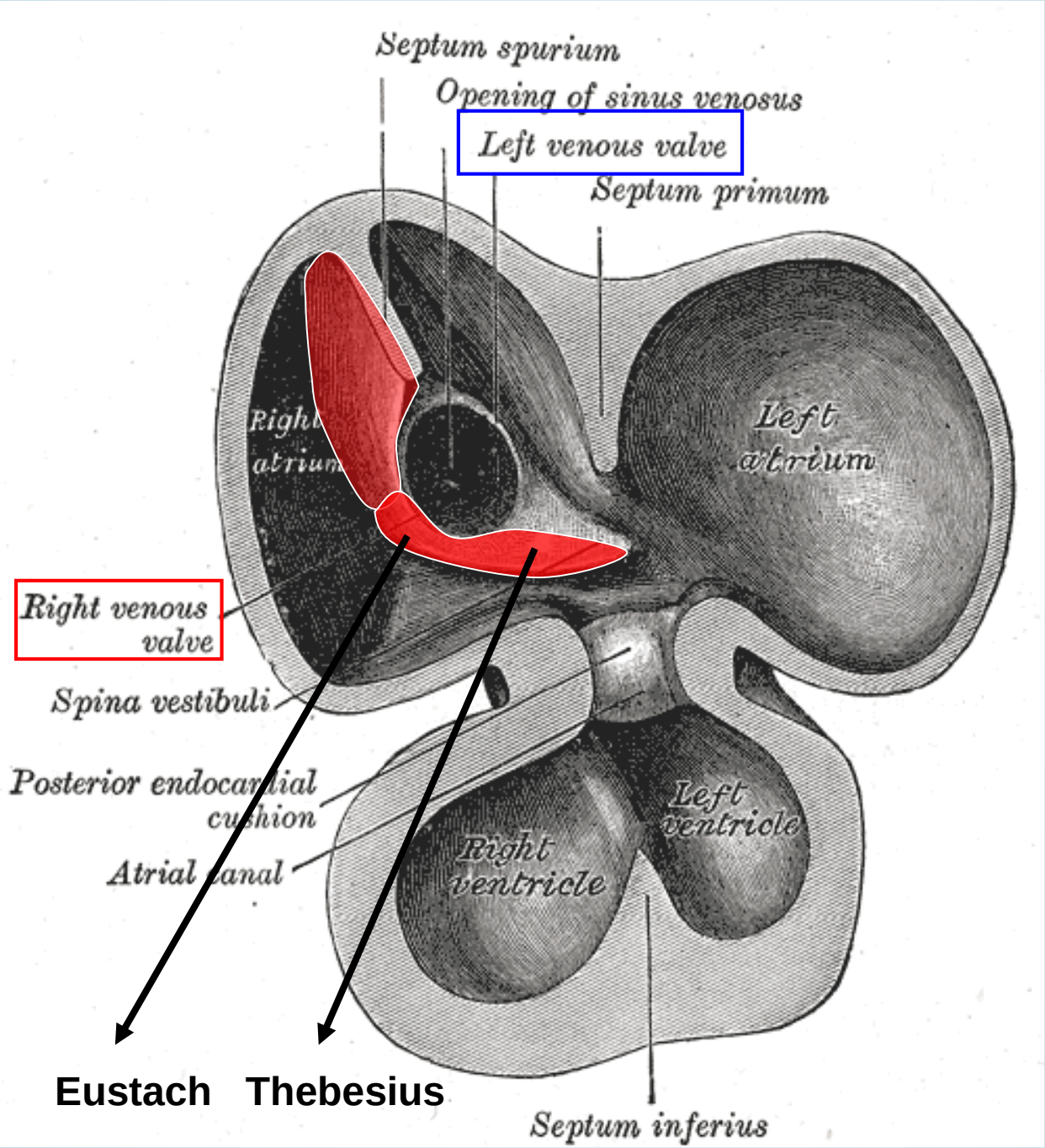
Septum spurium
Opening of sinus venosus
Left venous valve
Septum primum
Right atrium
Left atrium
Right venous valve
Spina vestibuli
Posterior endocardial cushion
Atrial canal
Right ventricle
Left ventricle
Septum inferius
Eustach
Thebesius

- *Right and left venous valves: two semilunar structures at the sinu-atrial junction. Postero-superiorly they unite and form the septum spurium. The left one later completly disappears by fusing with the interatrial septum. The right one divides into two: the upper part persists as a part of the crista terminalis, while the lower gives the mass of the Thebesian and the Eustachian valves.*

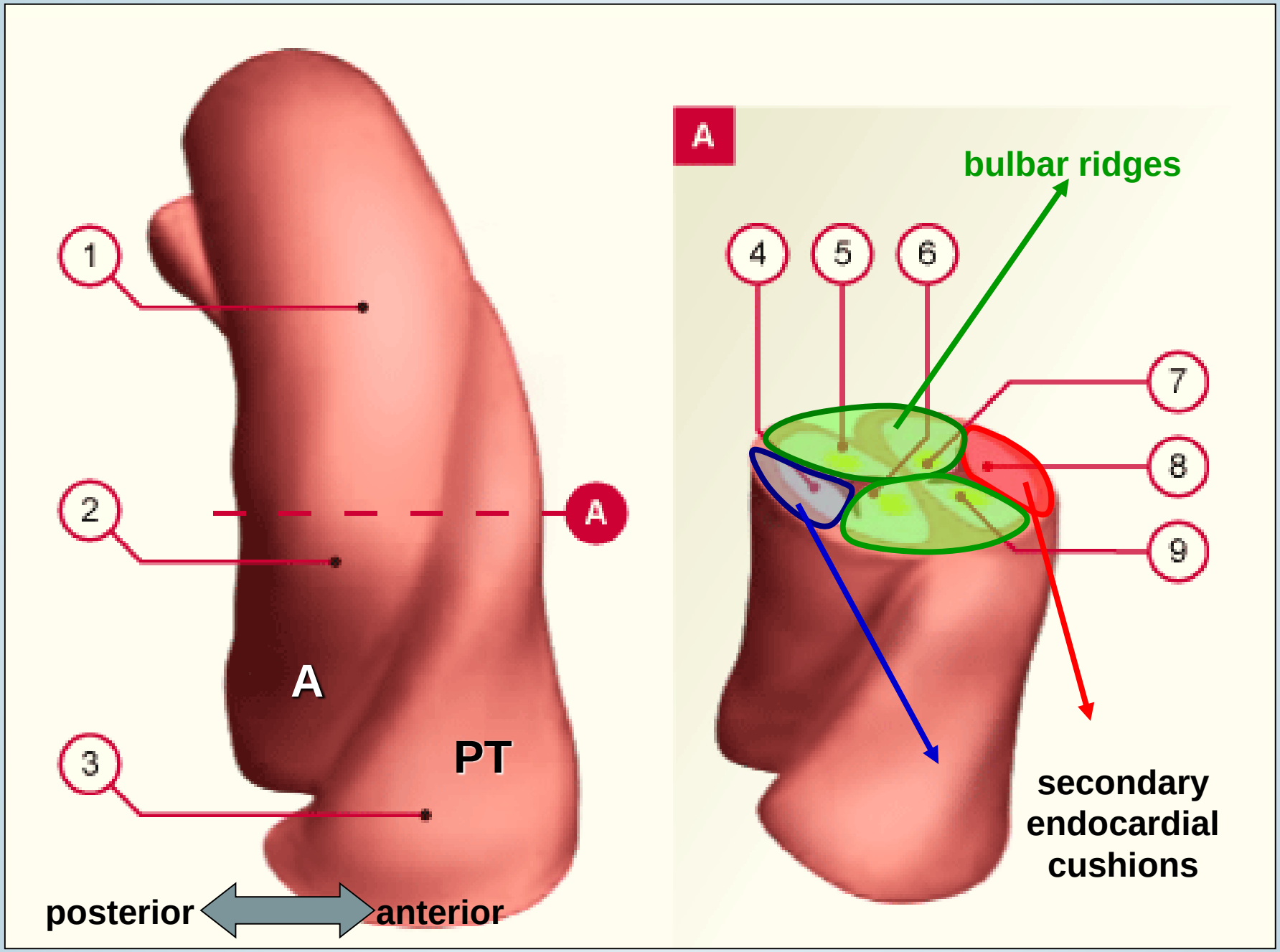
1
2
3
A
A
PT
posterior
anterior
A
bulbar ridges
4
5
6
7
8
9
secondary endocardial cushions

- *<u>Semilunar valves:</u> right and left semilunar valvulae of the aorta and the pulmonary trunk develop from the bulbar ridges (primary endocardial cushions) also beeing responsible for the formation of the aorticopulmonary septum; anterior semilunar valvula of the pulmonary valve and the posterior valvula of the aorta arise from secondary endocardial cushions.*

- *<u>Atrioventricular valves:</u> endocardial proliferation around the AV orifices.*



# MALFORMATIONS

- **Patent Ductus Arteriosus (**5 to 10% of all congenital heart disease**)**
- **Atrial Septal Defect (10%)**
- **Ventricular Septal Defect (30%)**
- **Tetralogy of Fallot (6%)**
- **Transposition of the Great Arteries (4%)**
- **Coarctation of the Aorta (5-8 %)**
- **Persistent Truncus Arteriosus**
- **Hypoplastic Left-Heart Syndrome**
- **Dextrocardia**

# MALFORMATIONS

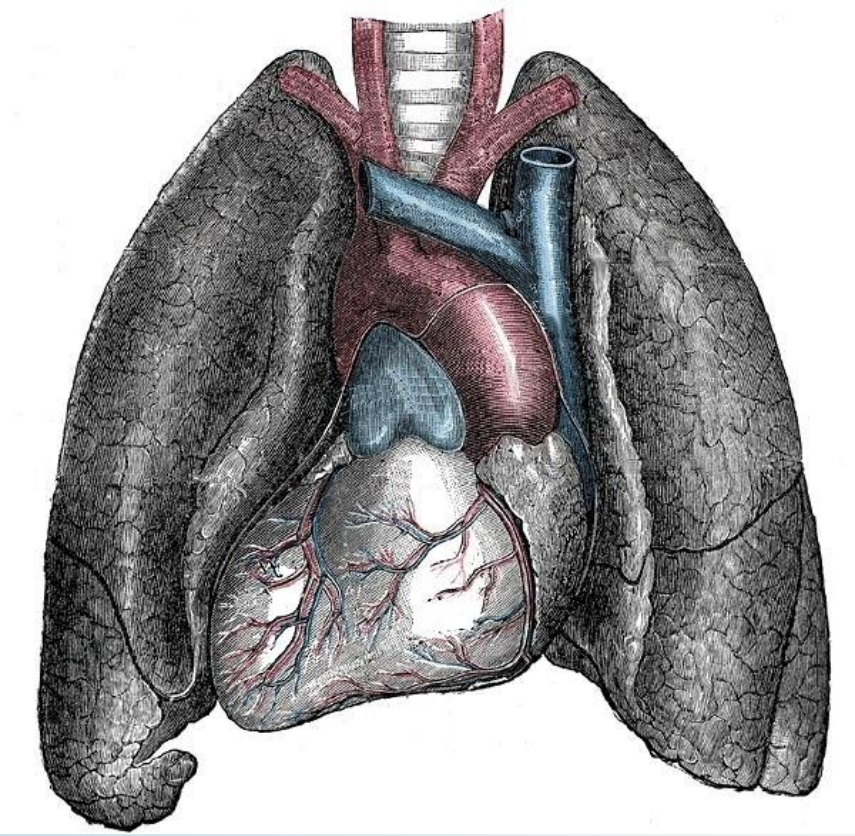

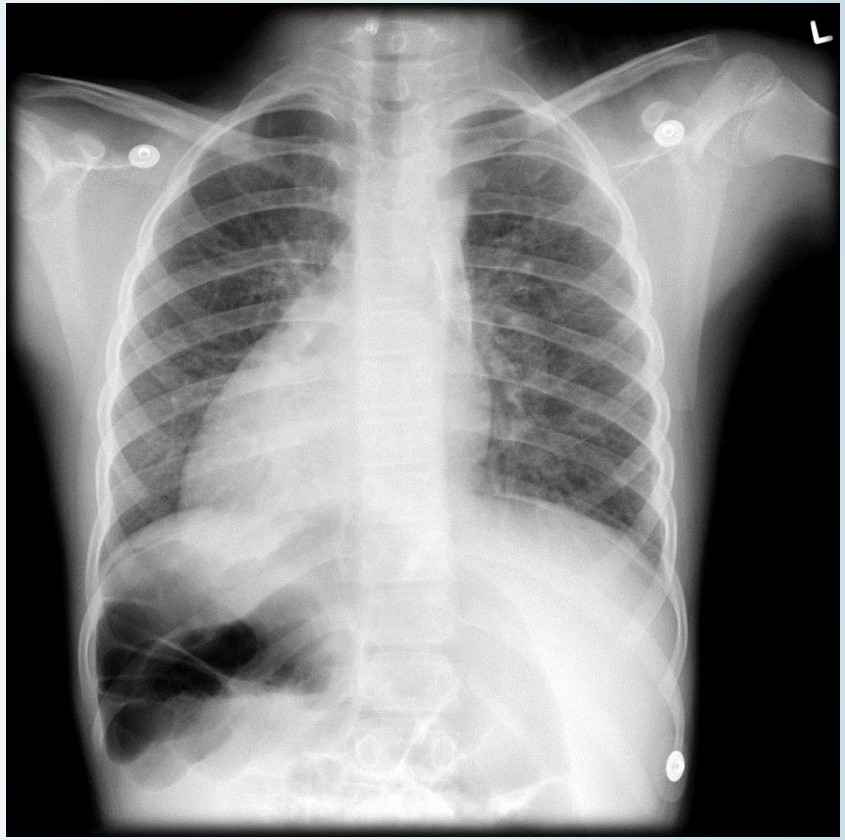


**1. situs inversus totalis:** all the viscera are mirrored. Prevalance is less than 1/10 000.

**2. dextrocardia:** only the heart is swapped to the right side of the thorax (first seen and drawn by Leonardo da Vinci in 1452–1519)

# PATENT DUCTUS ARTERIOSUS (10%)

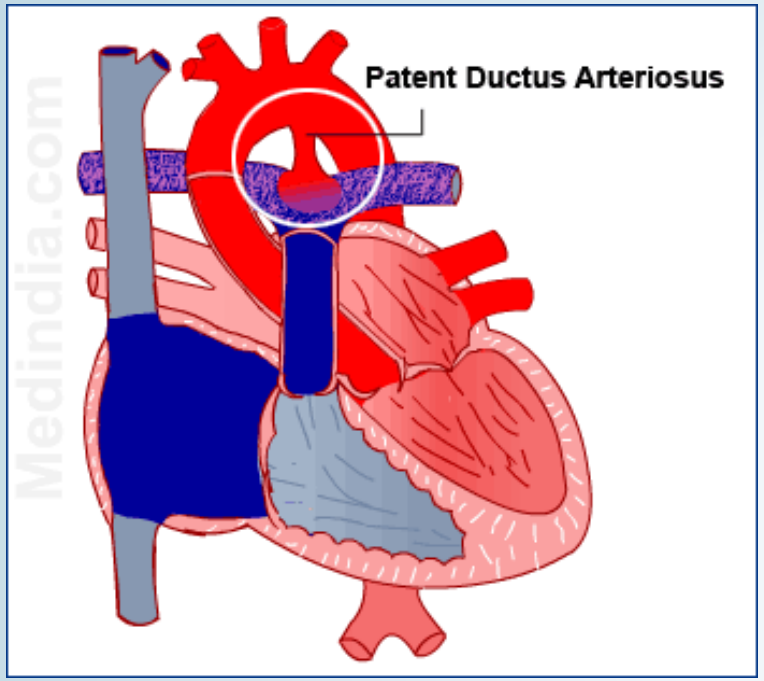


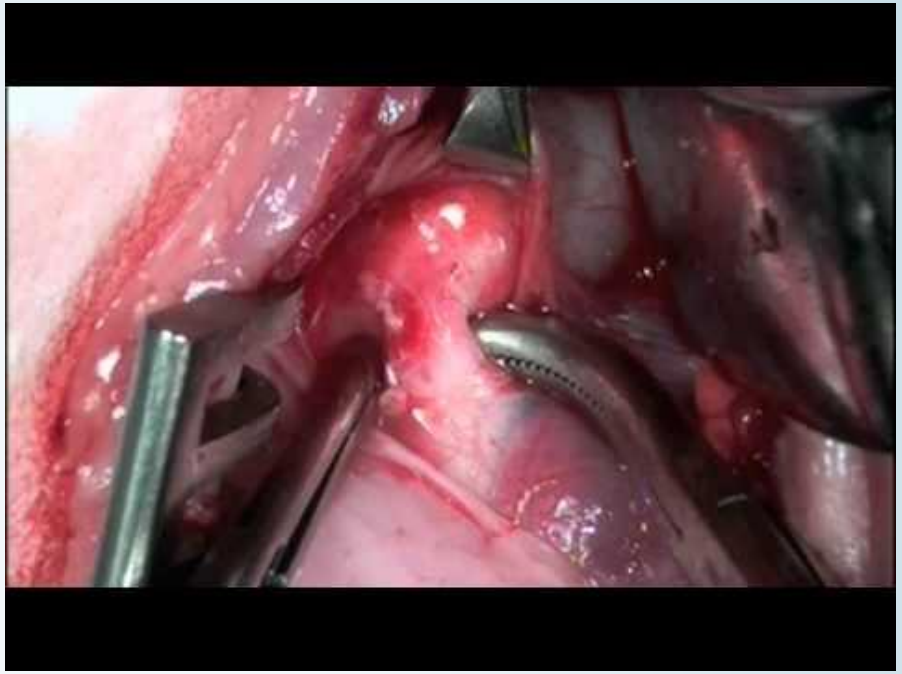

In the most severe forms, infants with a moderate or large PDA will present with **progressive congestive heart failure**, often within 8 to 10 weeks after birth.

The **ductus arteriosus** is a large channel found normally **in all mammalian foetuses**, **connecting the main pulmonary trunk with the left-sided descending aorta**, about 5 to 10 mm distal to the origin of the left subclavian artery in a full-term infant.

-**locally produced prostaglandins**, and local **nitric oxide** production by endothelial cells of ductus, and from placenta – maintaining ductal patency

-**normal closure after birth**: higher oxygen - prostaglandin is metabolized in the lungs and its concentration falls rapidly within 3 hours - **constriction of the ductus**

# ATRIAL SEPTAL DEFECT
# (6-10% OF ALL CONGENITAL HEART DISEASES )

-foramen ovale allows blood to bypass the nonfunctional fetal lungs while the fetus obtains its oxygen from the placenta

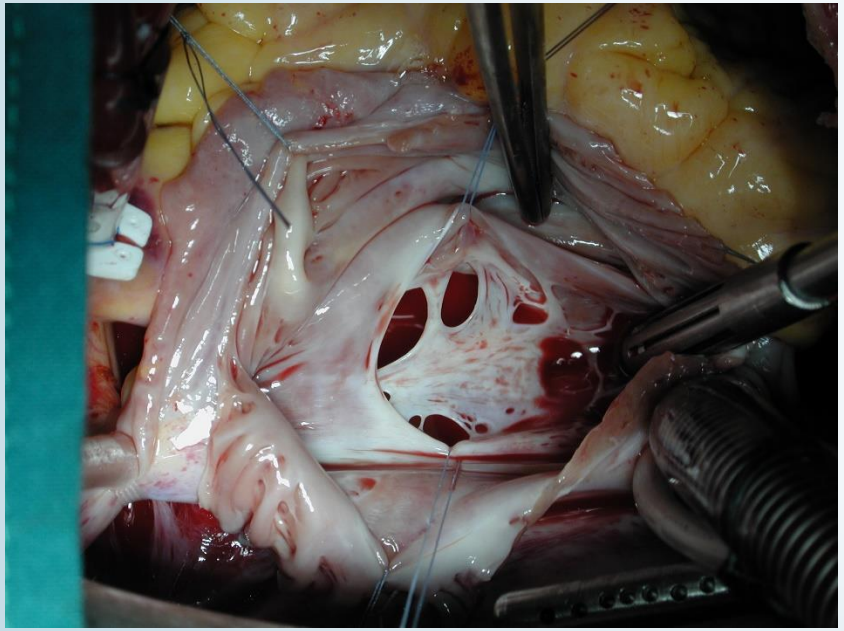

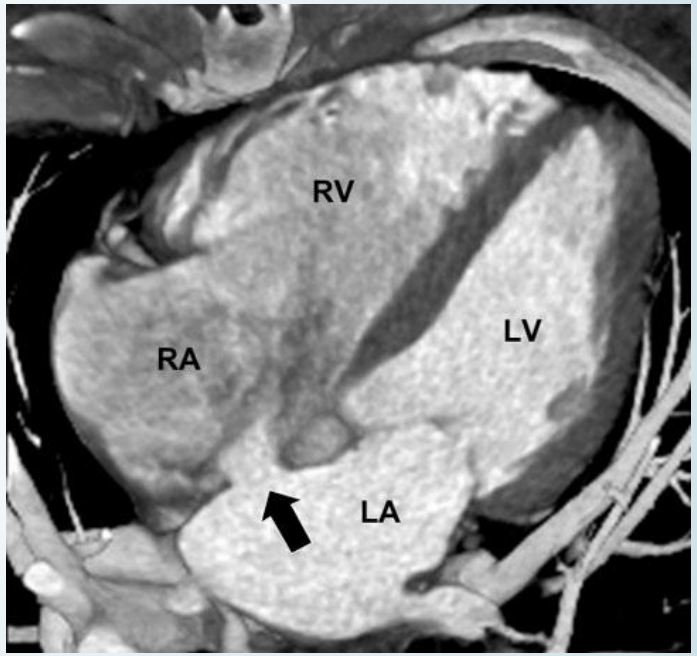


**Catheter procedure -** percutaneous closure safer

**3. atrial septal defect (ASD) / persisting foramen ovale (PFO):**
septum primum and secundum do not overlap completly.

# VENTRICULAR SEPTAL DEFECT
# (30% - MOST COMMON CONGENITAL CARDIAC ANOMALY)

-causes of congenital ventricular septal defect:

-include the incomplete looping of the heart during days 24-28

-faults with **NKX2.5 gene** are usually associated with isolated ASD in humans when one copy is missing

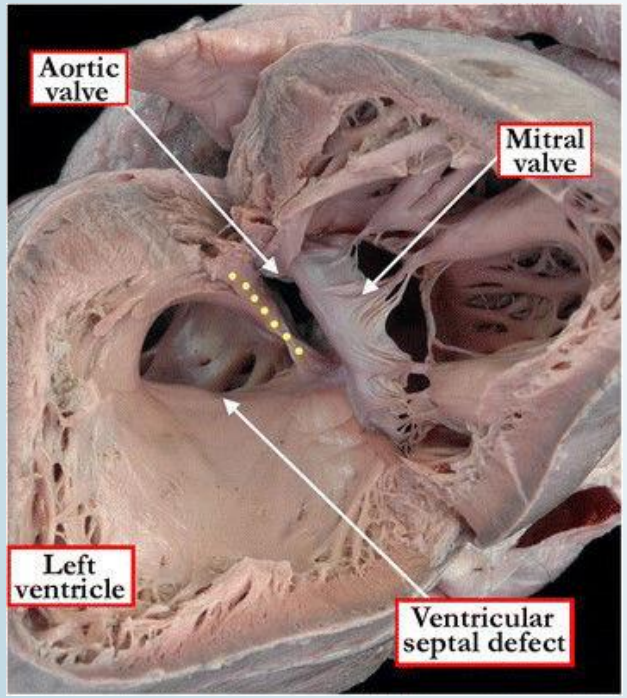


membranous

most commonly require surgical intervention

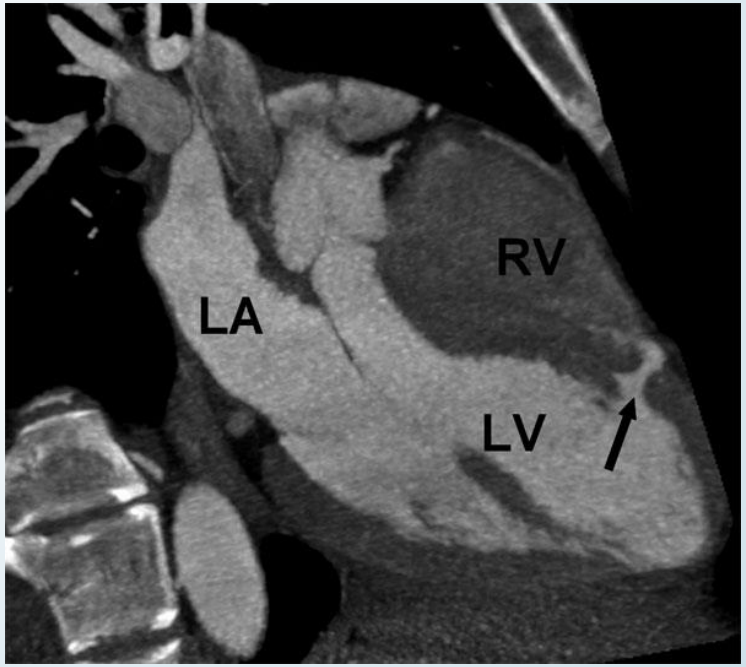


coronary CT angiogram

muscular

# 4. ventricular septal defect (VSD)

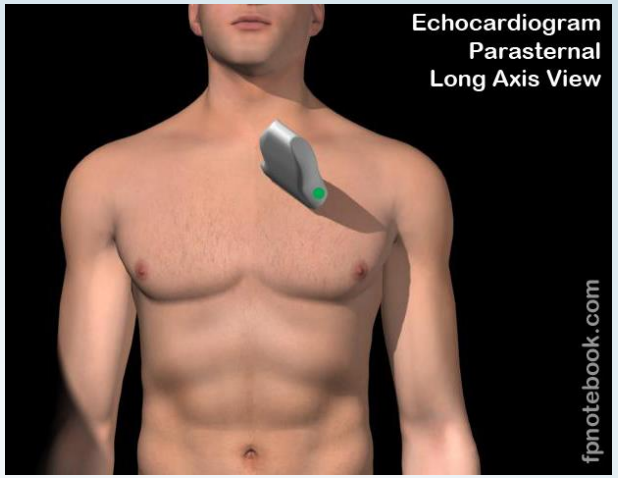


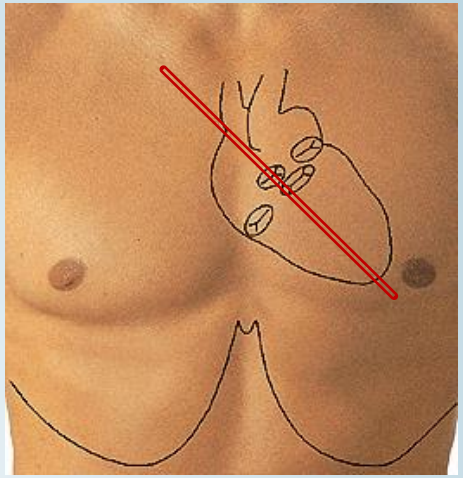

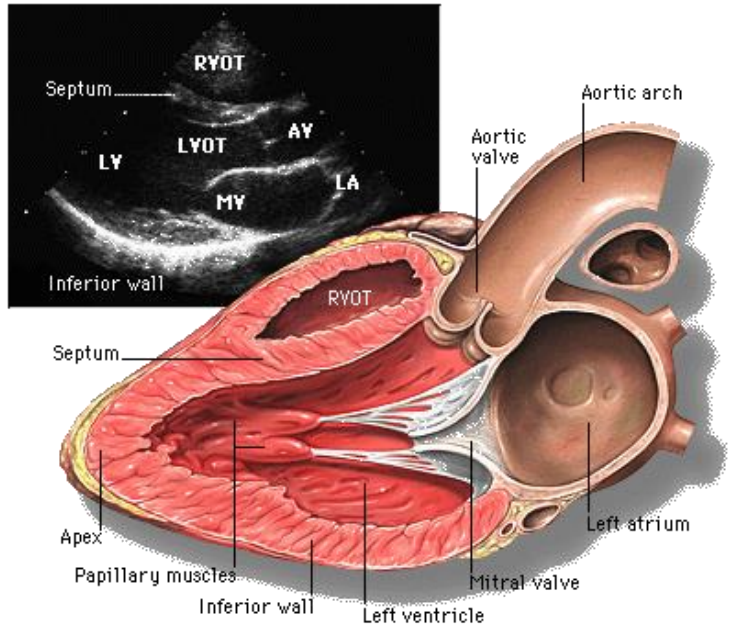

# COARCTATIO AORTAE (5-8 %)

**5. transposition of the great vessels:** aorticopulmonary septum twists only 90 degrees.

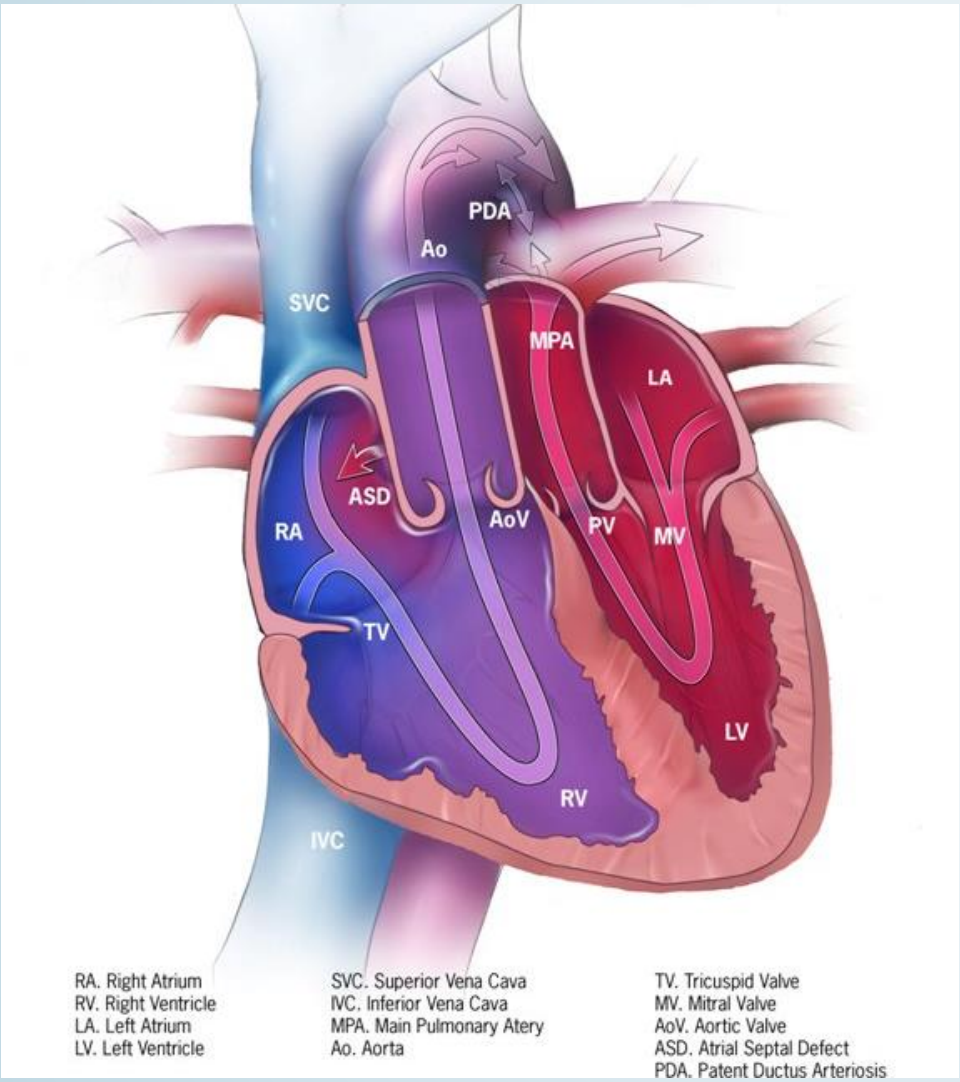


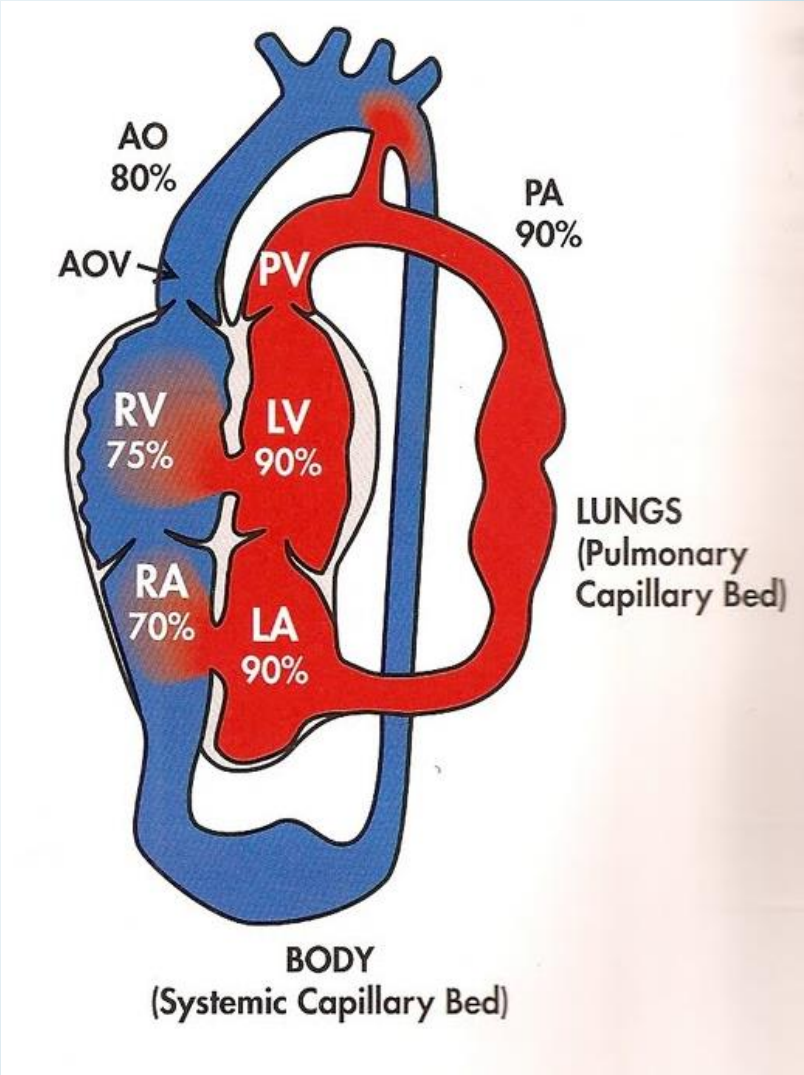

# **6. Tetralogy of Fallot:** a complex malformation

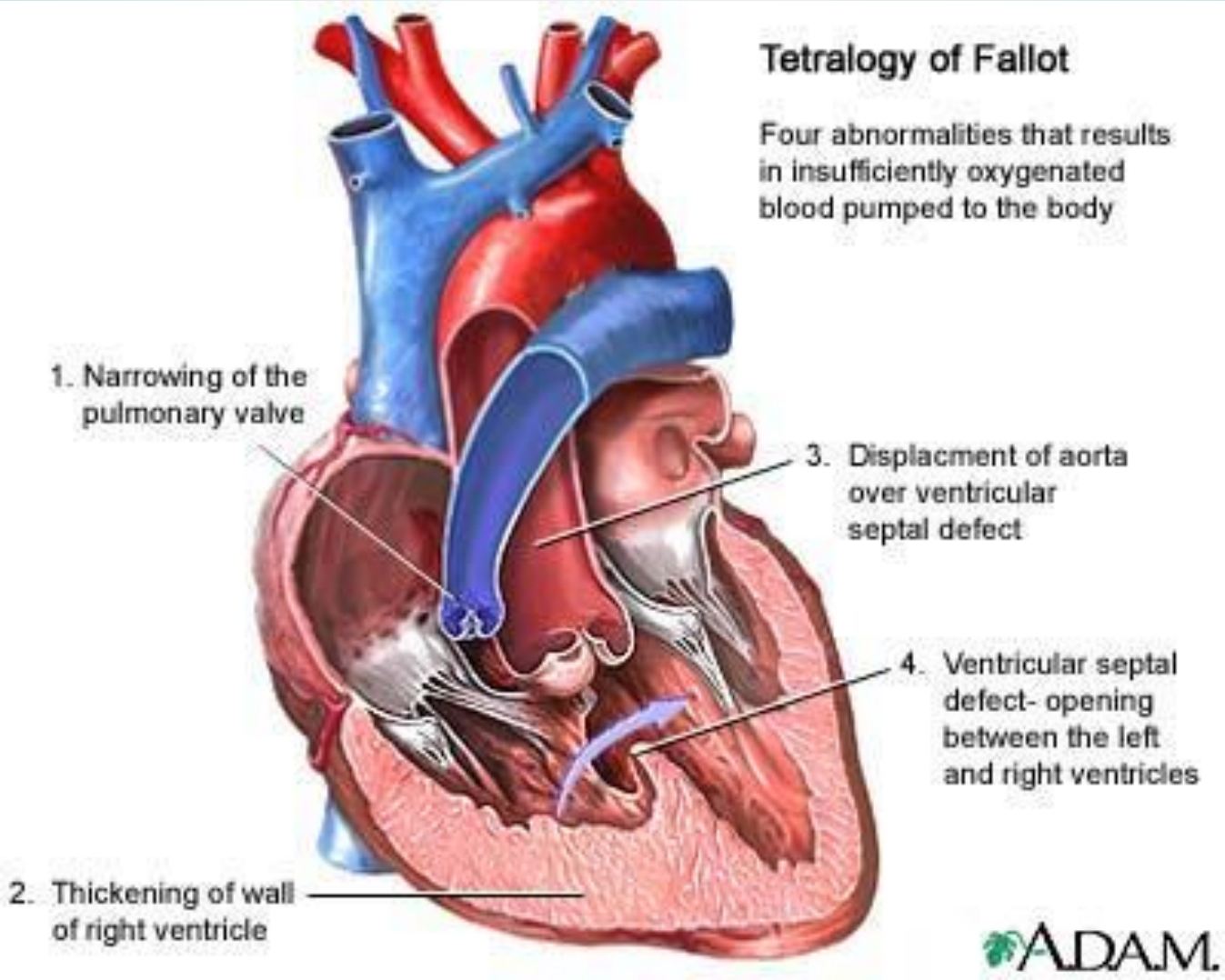

# Fetal circulation

# Postnatal adaptation of the circulatory system

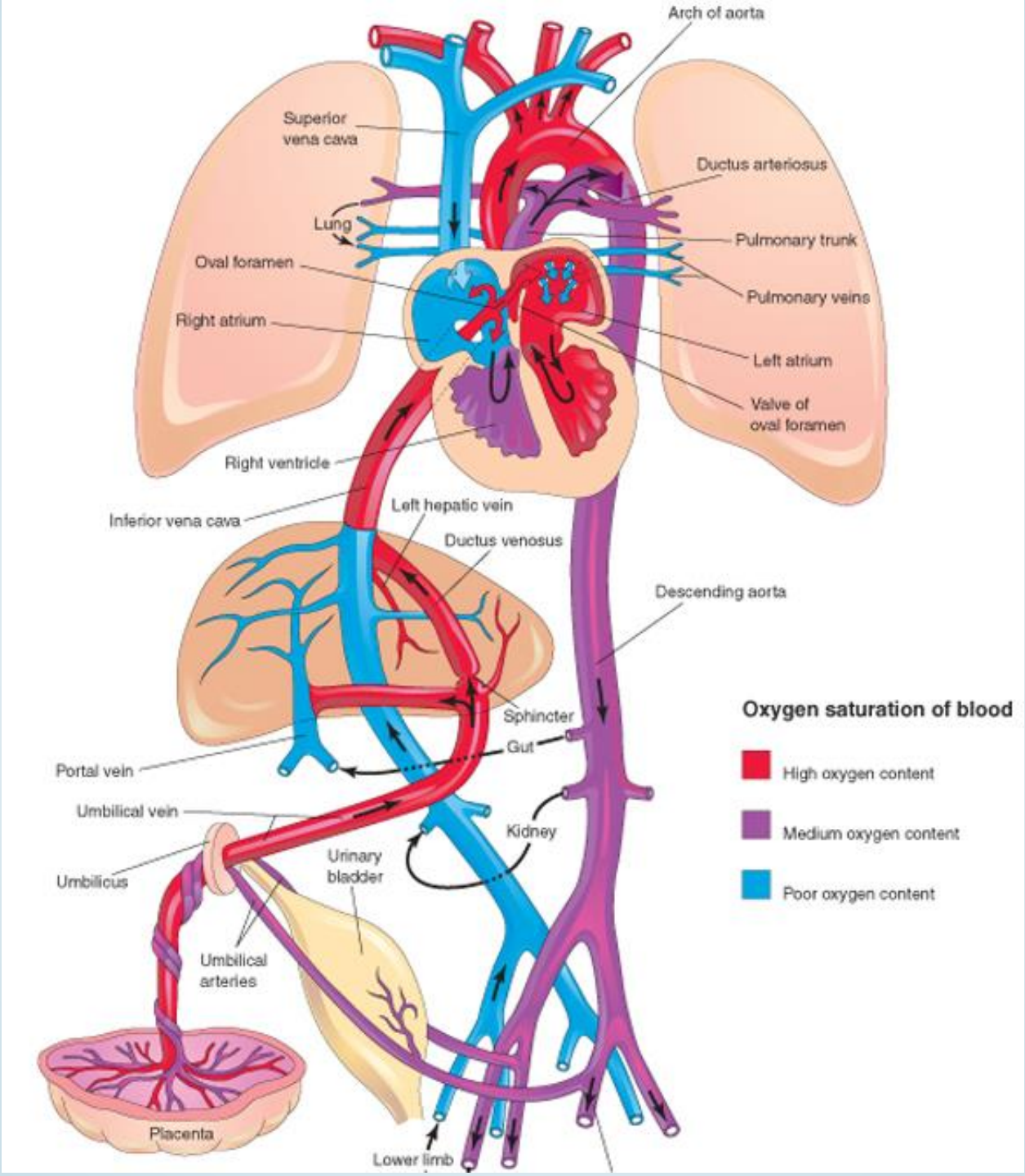
Arch of aorta
Superior vena cava
Ductus arteriosus
Lung
Pulmonary trunk
Oval foramen
Pulmonary veins
Right atrium
Left atrium
Valve of oval foramen
Right ventricle
Inferior vena cava
Left hepatic vein
Ductus venosus
Descending aorta
Sphincter
Gut
Portal vein
Umbilical vein
Kidney
Urinary bladder
Umbilicus
Umbilical arteries
Placenta
Lower limb
Oxygen saturation of blood
High oxygen content
Medium oxygen content
Poor oxygen content

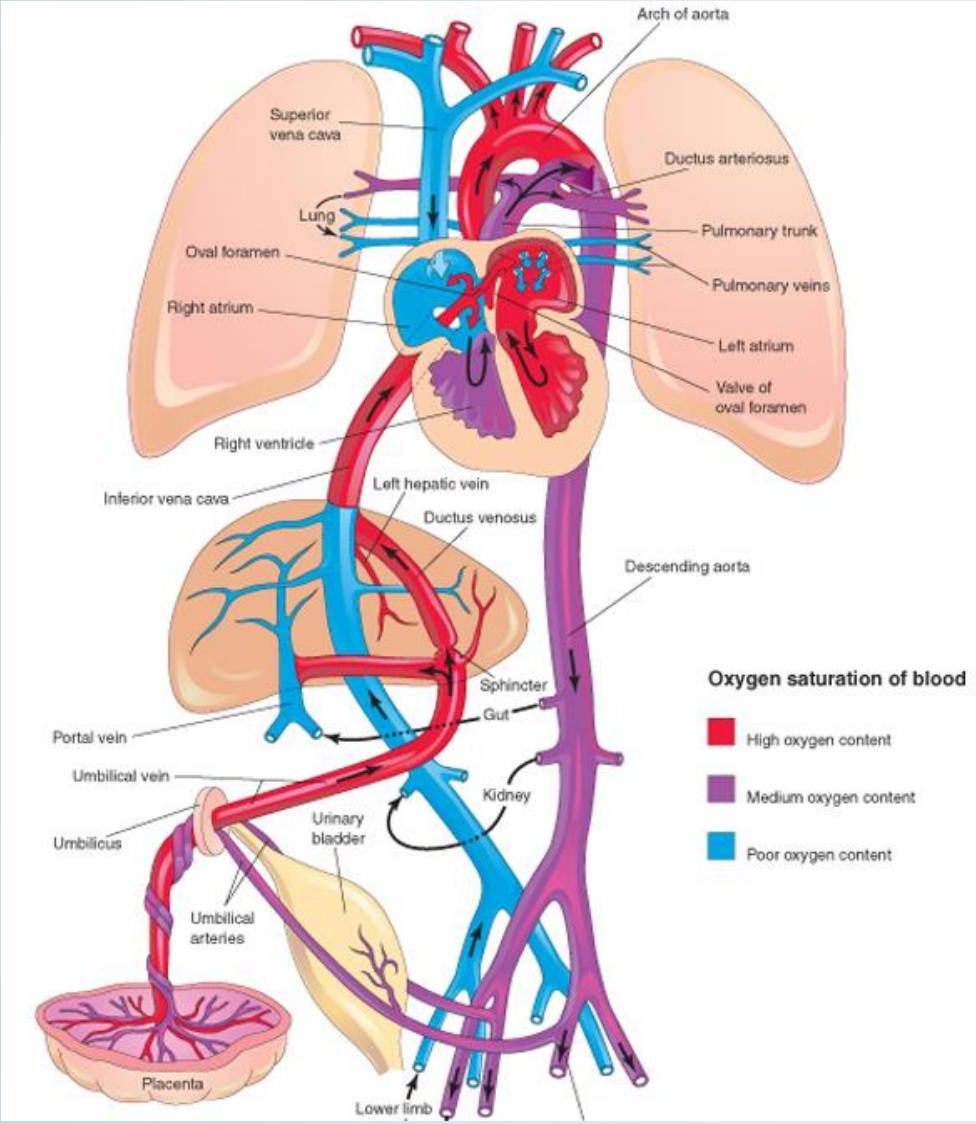


Arterious blood is carried into the fetus by the umbilical vein.
A smaller proportion of this blood passes through the liver and is collected by the IVC.
The majority of the oxygeneted blood bypasses the liver through the ductus venosus and drains directly into the IVC.
The Eustachian valve directs the blood toward the foramen ovale and the left atrium.
This blood is then pumped into the aorta and supplies the tissues of the fetus.
Finally returnes to the placenta via the two umbilical erteries arising from the internal iliac arteries.

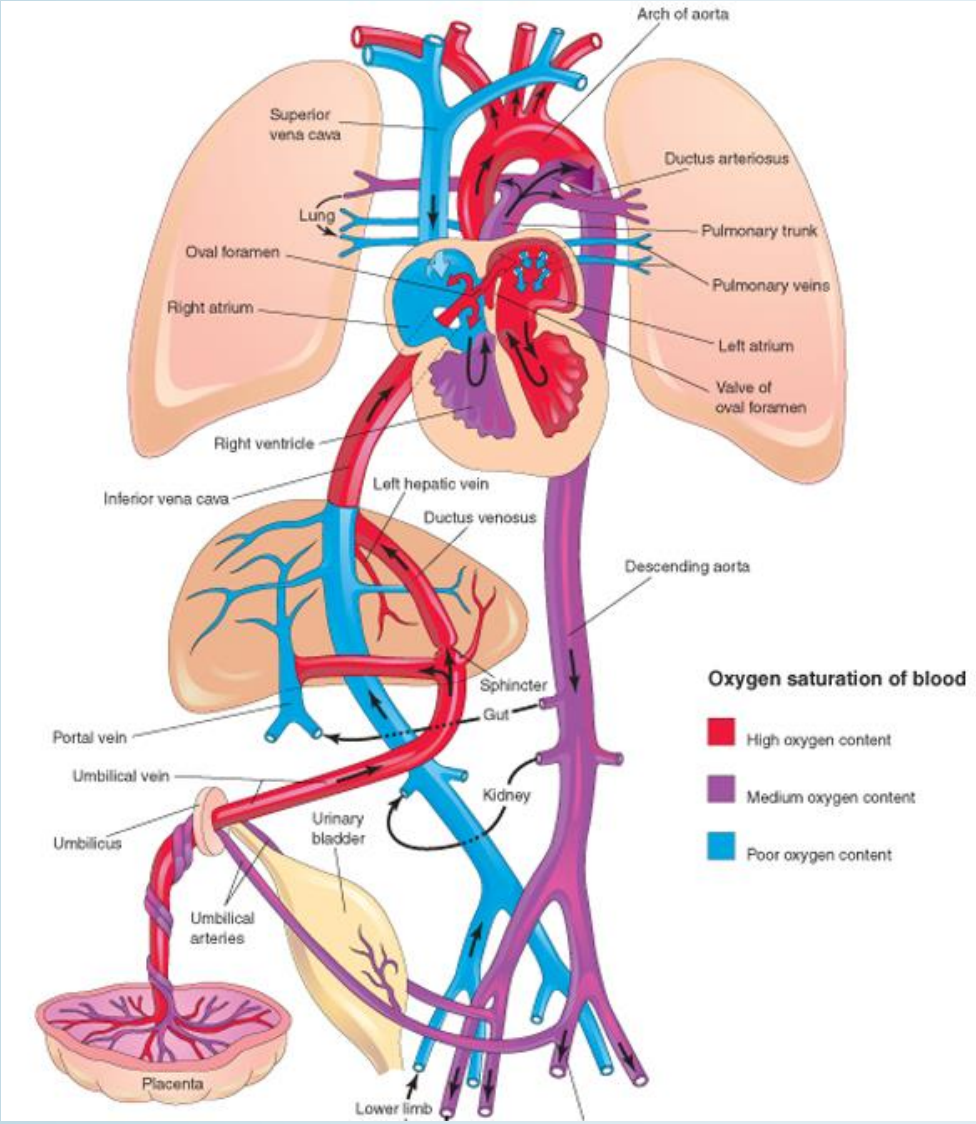


Venous blood derived from the head and neck regions as well as from the upper limb is collected by the SVC.
This venous blood gets into the right atrium then into the right ventricle.
As the lungs are collapsed the vascular resistance is very high: the blood may not flow toward the pulmonary arteries.
This is why the ductus arteriosus is essential: it drains the venous blood of the pulmonary trunk into the aorta.
Briefly: during the fetal period both of the ventricles eject blood into the aorta!!!

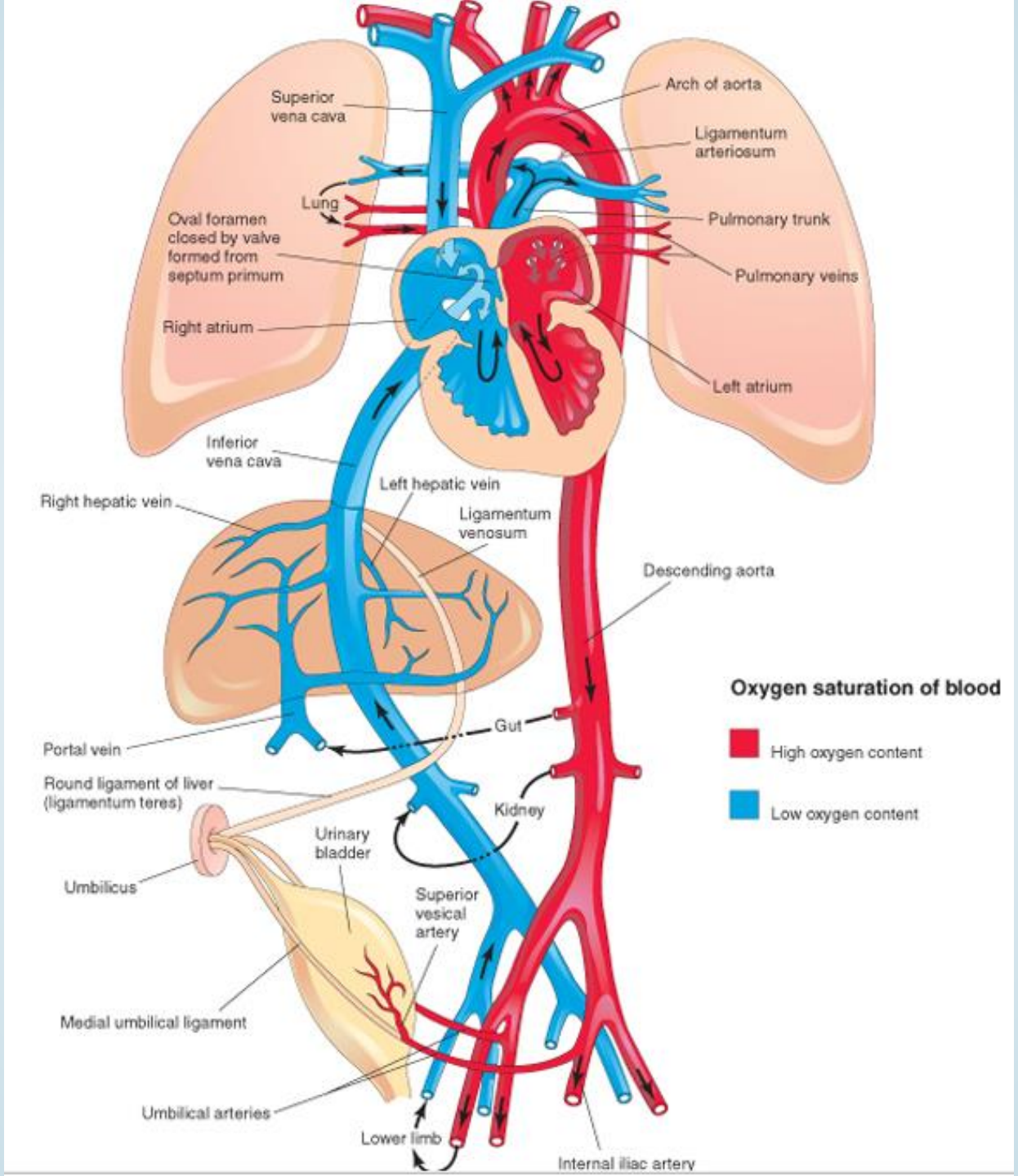
Superior vena cava
Arch of aorta
Ligamentum arteriosum
Lung
Pulmonary trunk
Oval foramen closed by valve formed from septum primum
Pulmonary veins
Right atrium
Left atrium
Inferior vena cava
Left hepatic vein
Right hepatic vein
Ligamentum venosum
Descending aorta
Oxygen saturation of blood
High oxygen content
Low oxygen content
Gut
Portal vein
Round ligament of liver (ligamentum teres)
Kidney
Urinary bladder
Umbilicus
Superior vesical artery
Medial umbilical ligament
Umbilical arteries
Lower limb
Internal iliac artery

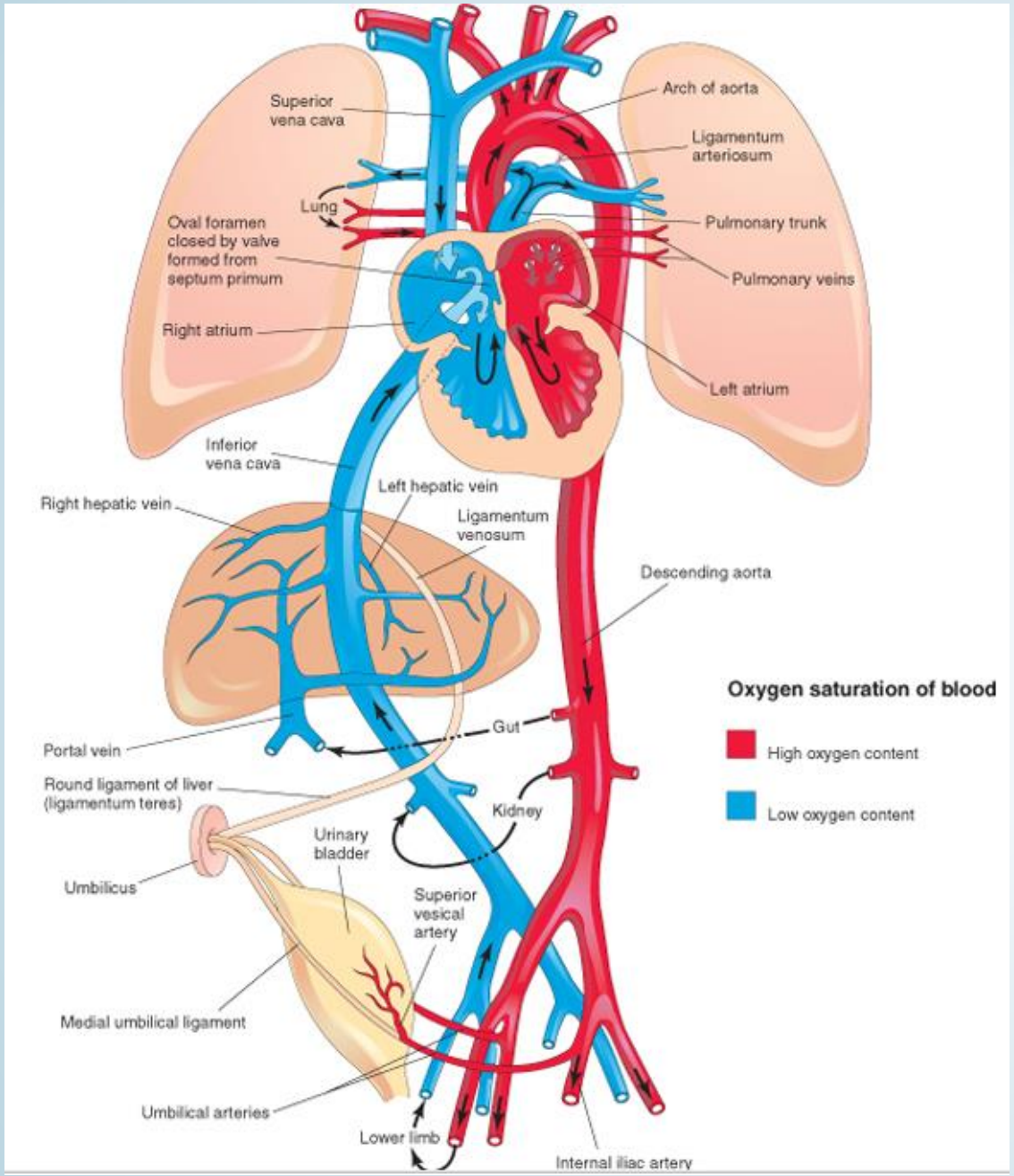


After birth no more arterious blood arrives through the umbilical vein. The lungs are inflated, the vascular resistance suddenly drops. There is no further reason for the blood ejected by the right ventricle to join the aorta.
As more blood reaches the lungs, more returns through the pulmonary veins into the left atrium. The pressure increases here and the septum primum is pushed against the septum secundum: the foramen ovale closes, later the two septa completly fuse.

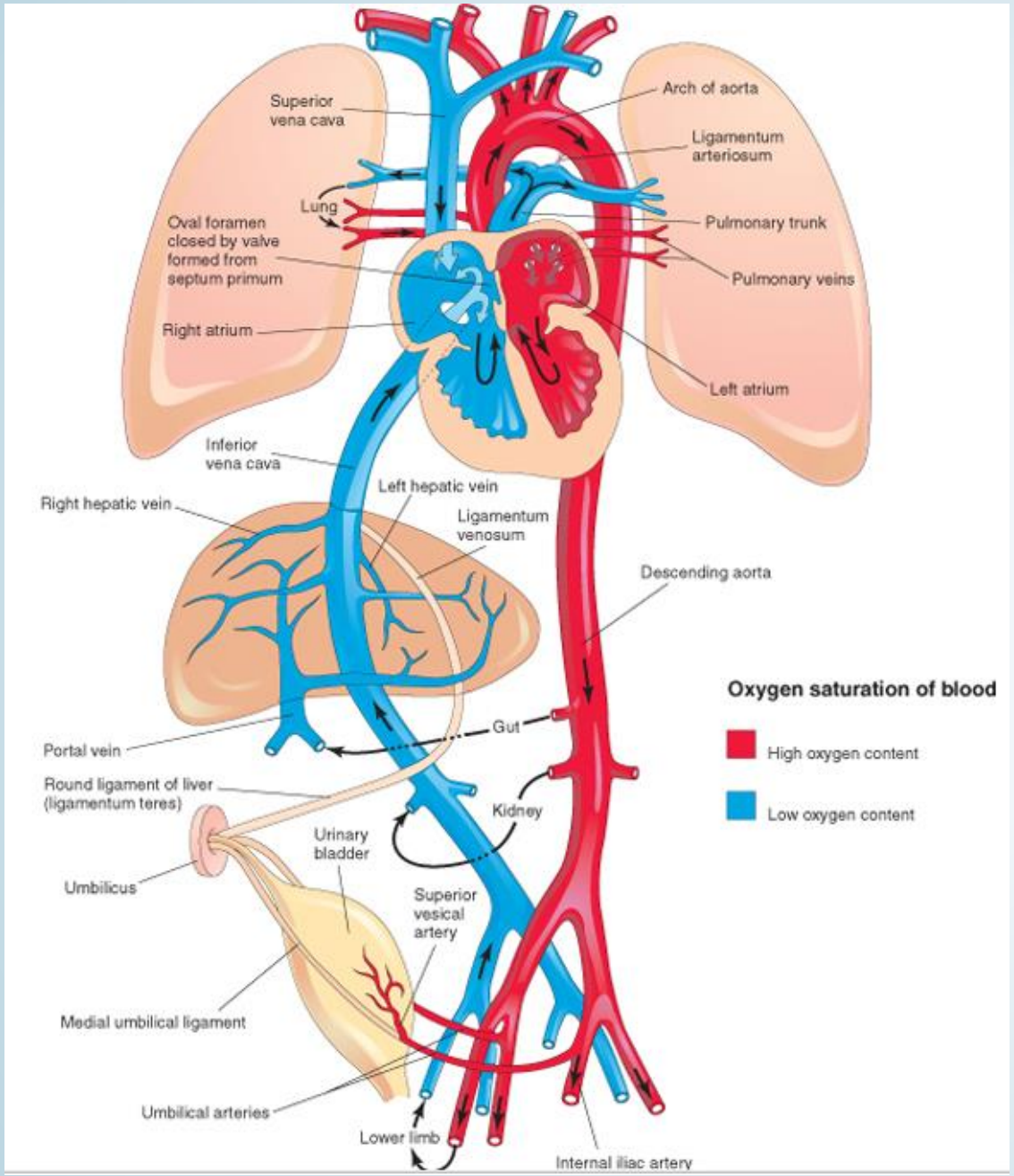


Due to the increased oxygen levels smooth muscles of the ductus arteriosus contract and obliterate the lumen. (Otherwise the higher pressure in the aorta would result in a reversed flow through the ductus venosus.)

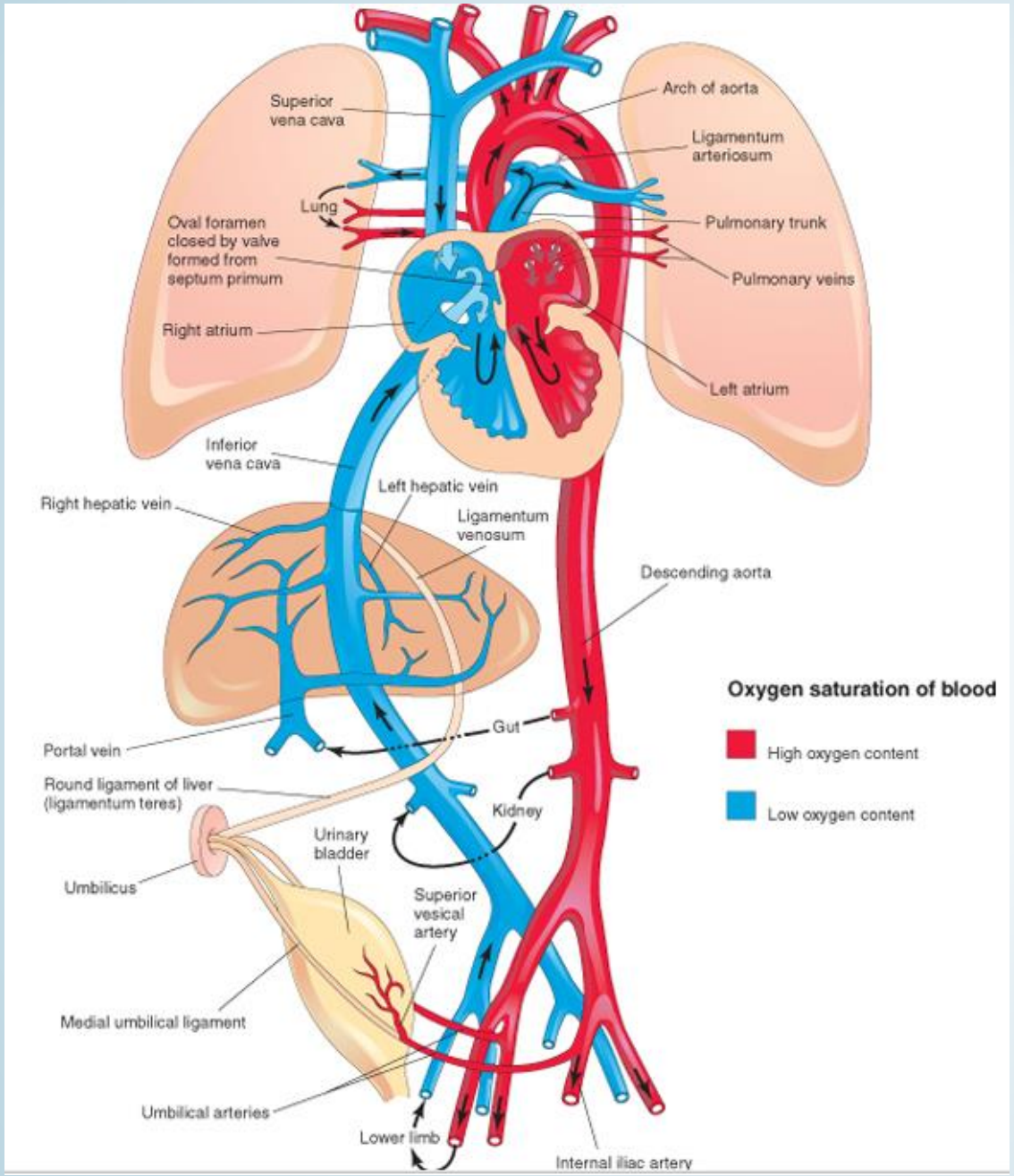


Ductus venosus is slowly occupied by proliferating connective tissue and remains observable on the visceral surface of the liver as the venous ligament.

# Thank you for your attention!

# DEVELOPMENT OF THE HEART VENTRICLES FETAL CIRCULATION

*Agnes Nemeskeri*

*2018*

*Department of Anatomy, Histology and Embryology*

*Clinical Anatomy Research Laboratory*

*nemeskeri.agnes@med.semmelweis-univ.hu*

# ENDOCARDIUM, MYOCARDIUM, AND EPICARDIUM – MESODERMAL ORIGIN

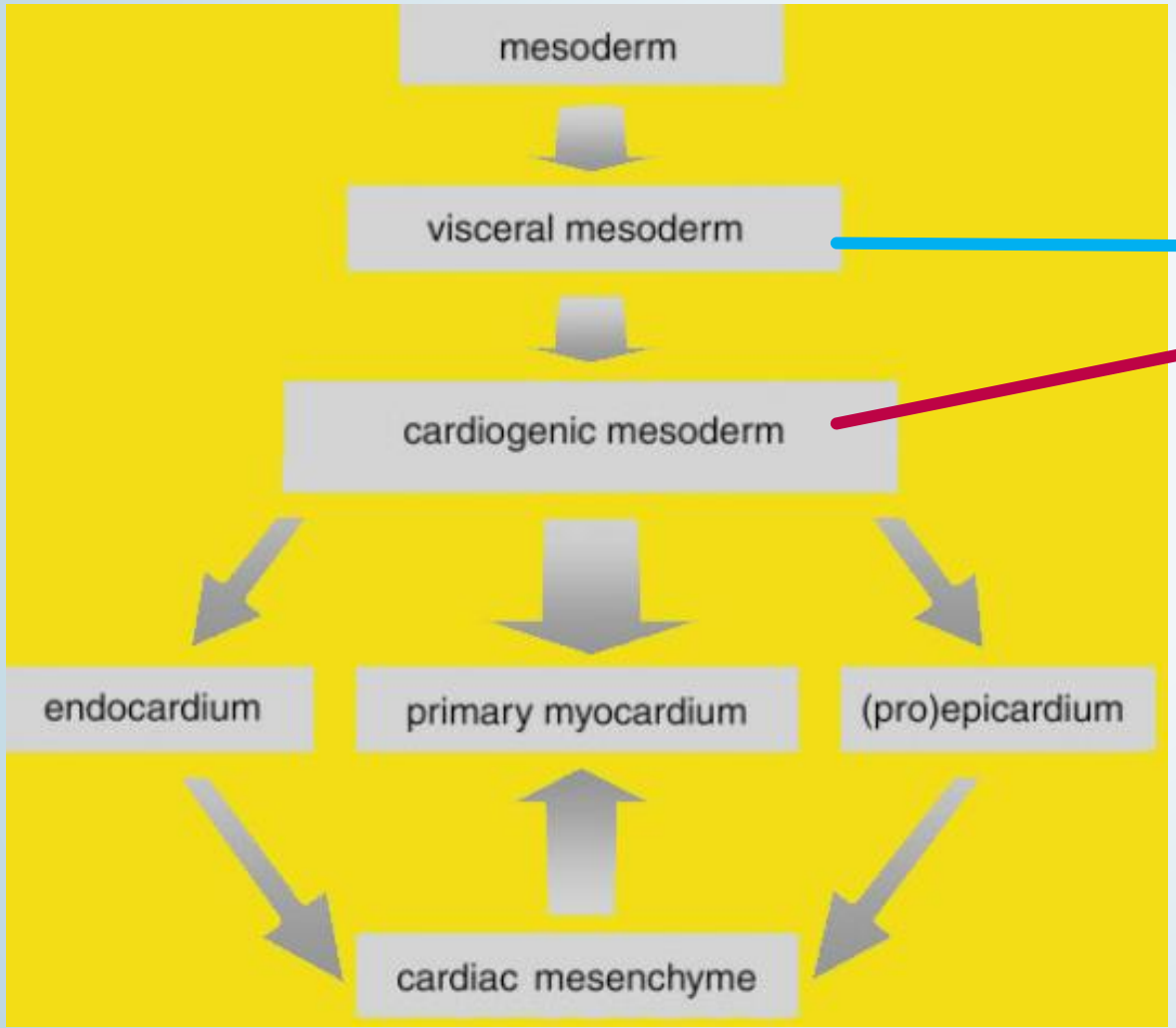


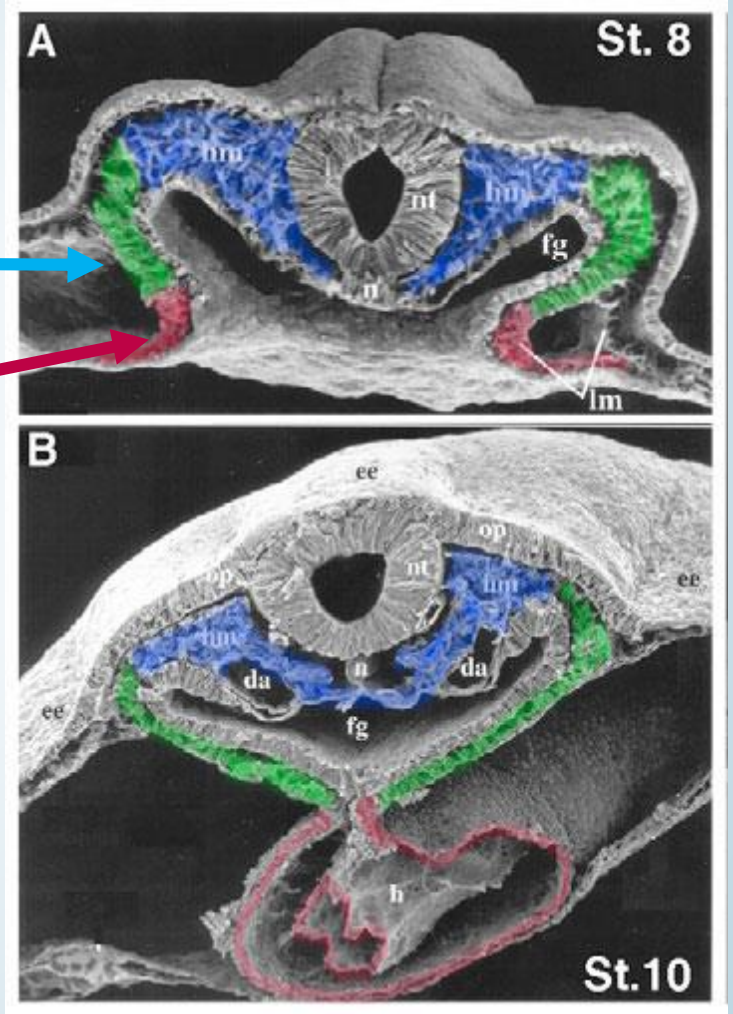


The contribution of Islet1-expressing splanchnic mesoderm cells to distinct branchiomeric muscles reveals significant heterogeneity in head muscle development
**Elisha Nathan et al. 2008**

http://www.mdpi.com/jcdd/jcdd-03-00021/article_deploy/html/images/jcdd-03-00021-g001.png

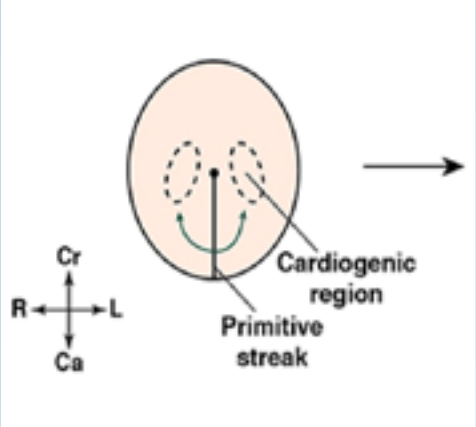


first heart field

second heart field

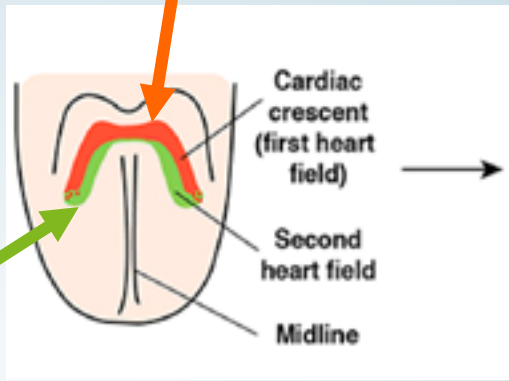


During gastrulation:
myocardial progenitor cells
arise from the mesoderm

-migrate to the ventral midline to the anterior part of the embryo
-progenitor cells form the **cardiac crescent** first heart field
-already includes differentiated cardiomyocytes
-Fgf8 expression in the anterior endoderm plays a vital role during the early specification of cardiogenic mesoderm

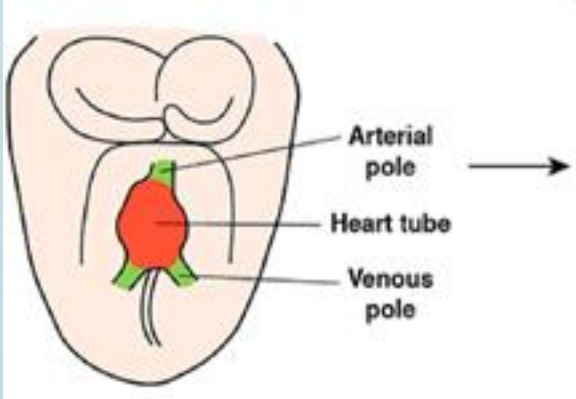


-folding of embryonic disc
-fusion of bilateral heart-forming fields, detach from the coelomic wall
-primary heart tube is formed at the ventral midline
-tubular heart remains attached to the coelomic wall at the arterial and venous poles
- starts to beat and undergoes looping

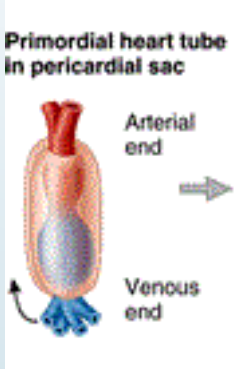


REVIEW
A molecular and genetic outline of cardiac morphogenesis
M. S. Rana, V. M. Christoffels and A. F. M. Moorman

-the linear tube does not contain all the component parts of the definitive heart

-new material is added at both its venous and arterial poles

-"revolutionized our understanding of cardiac development „ (Moorman et al., 2007)


New!

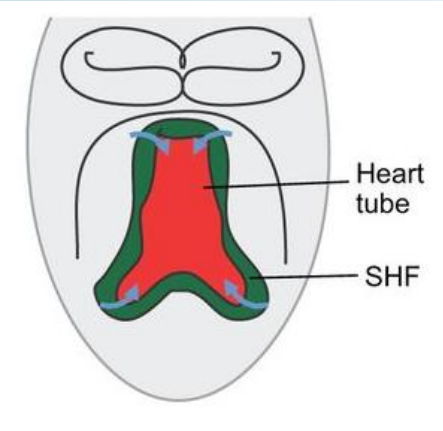


New!

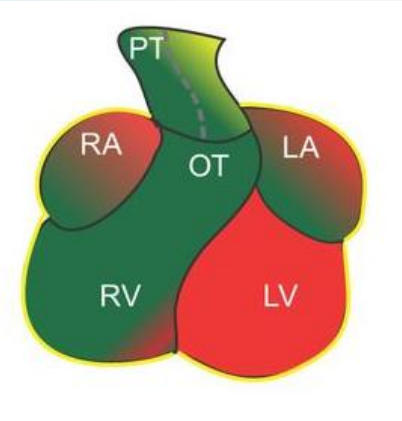


New!

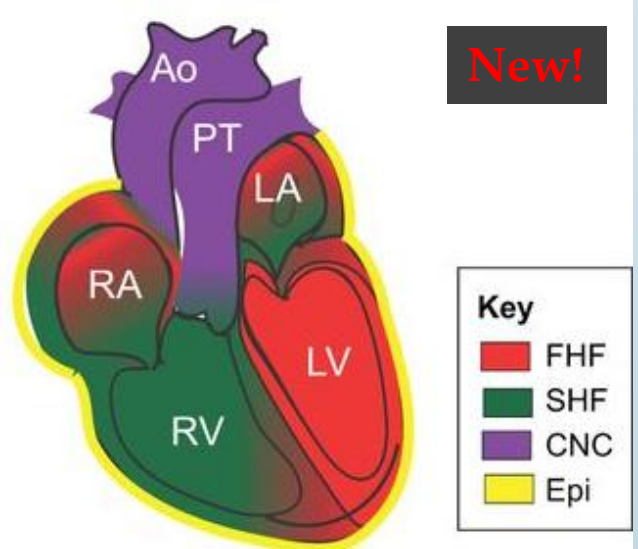


http://dev.biologists.org/content/develop/143/8/1242/F2.large.jpg?download=true

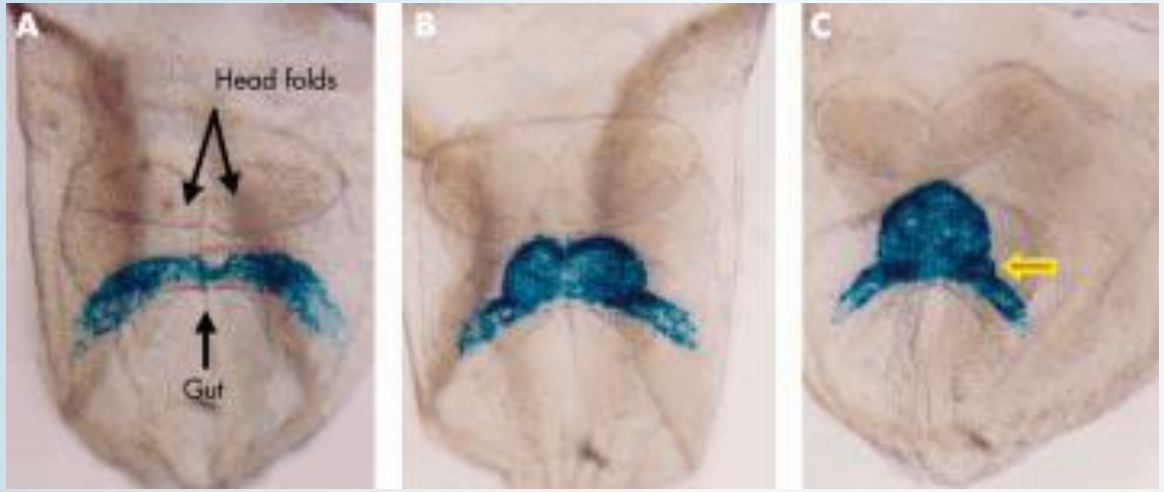


myocardium has been labelled blue using a reporter transgene for myosin light chain.
The arrowed bulge in panel C is fated to contribute to the atrioventricular canal.

# LOOPING OF EMBRYONIC HEART

The addition of differentiating cardiac progenitor cells to the heart is paralleled by **asymmetric growth of the elongating heart tube**,
establishing a **dextral movement of the heart known as cardiac looping ?????**

Hensen's node **monocilia** : leftward nodal flow, direction of these movements establishes an **asymmetric leftward extracellular fluid flow** of secreted growth factors and signalling molecules.
These signalling events activate a bilateral asymmetric pattern of gene expression and determine the left–right (L-R) axis of the embryo and developing organs

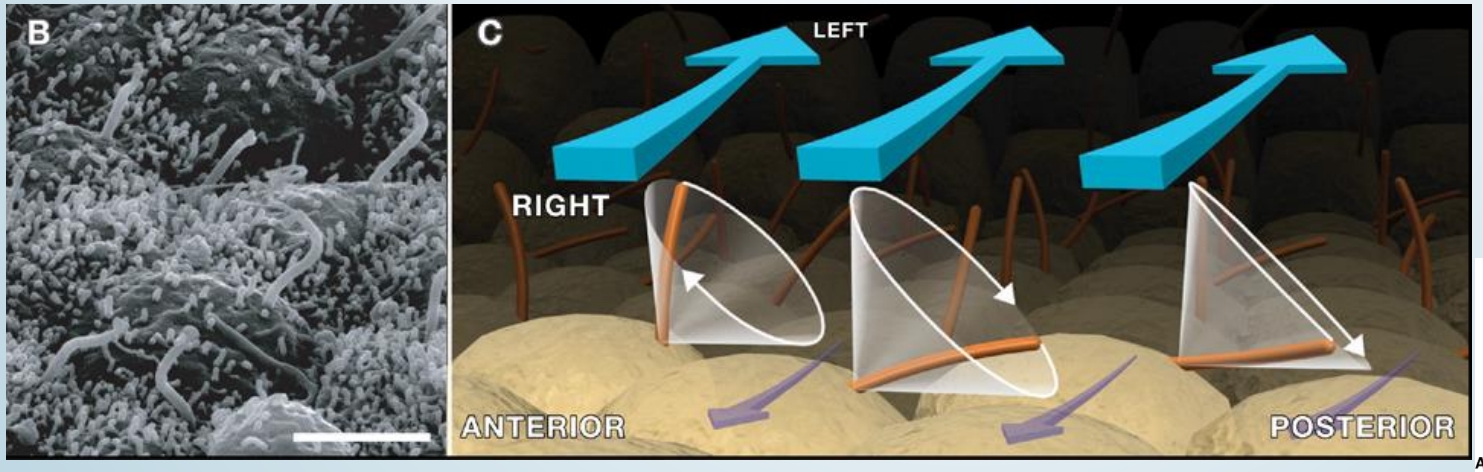


https://encrypted-tbn0.gstatic.com/images?q=tbn:ANd9GcSHDfyz5CdD3NWaIZfsHjbHUXsG2xMcpqCfazXw4cbVcym2NmEM2w

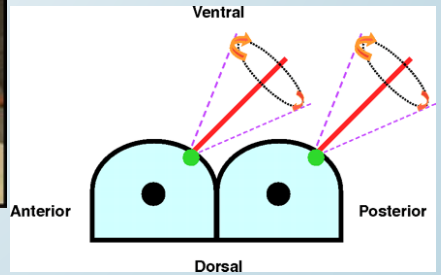


http://dev.biologists.org/content/develop/133/11/2095/F3.medium.gif

# MULTIPLE HEART FIELDS

## first heart field

-first differentiating cells
-pivotal role in development of embryonic ventricle

## second heart field

-in the cardiac mesderm most of the cells remains undifferentiated medial and posterior to the cardiac crescent
-high proliferation rate
-these cells gradually added to the heart – primitive heart tube elongates
-temporal aspect of delayed differentiation

-impaired development of the SHF results in a wide spectrum of cardiac defects, including conotruncal, ventricular, atrial septal and atrioventricular septal defects

# DEVELOPMENT OF SHF AND DERIVATIVES

- ventriclus dexter
- one part of septum interventriculare
- myocardium and smooth muscle cells of arterial outlet
- atria depend on the continuously accumulating and differentiating **SHF cells**

-**pharyngeal endoderma has contact with SHF cells**

-induces cardiogenic progenitor cell differentiation

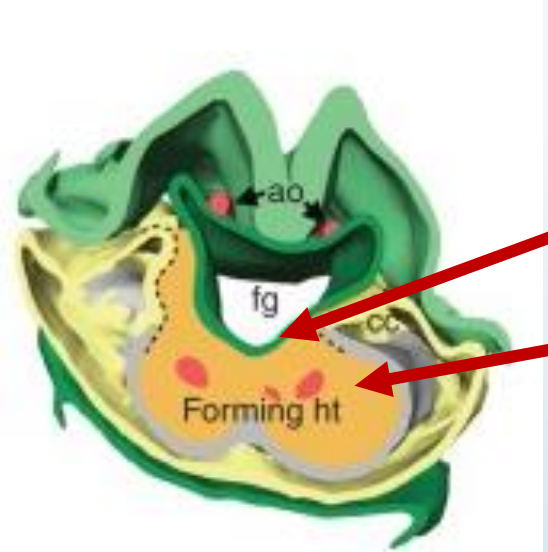


Cold Spring Harb Perspect Med 2014;4:a015750

**pharyngeal endoderma**

**heart tube before closing**

**CONCEPT I.**
The four chambers of the formed heart are arranged in parallel. The right atrium is exclusively connected to the right ventricle and the left atrium exclusively to the left ventricle.

The right half of the heart drives blood from the body through the lungs to the left half that drives the blood through the rest of the body.
The two halves can **only beat in synchrony**, the right half pushing the pulmonary circulation and the left half the systemic circulation.

**This parallel-arranged four-chambered heart develops from a single circuited tubular heart.**

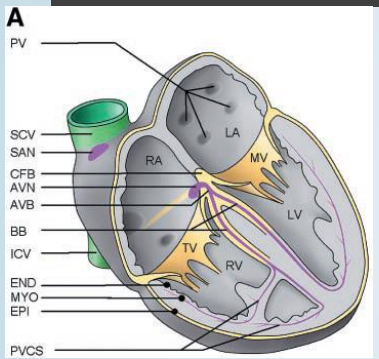


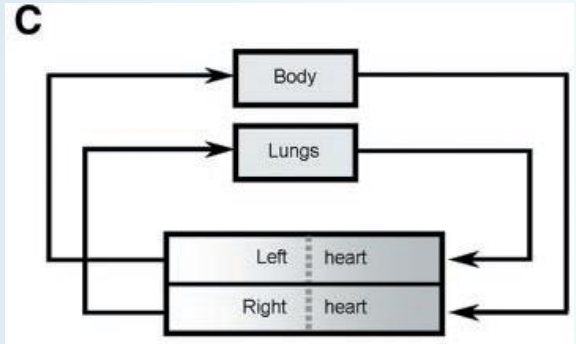


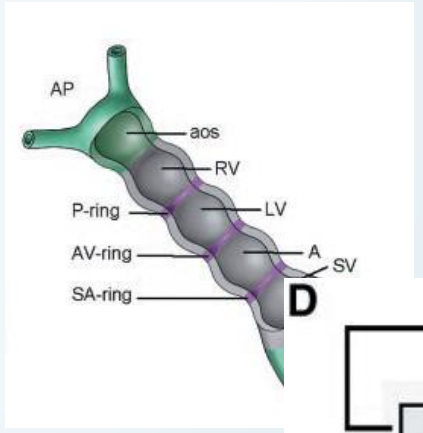



**CONCEPT II.**
The current concept is that this heart tube is composed of a **linear array of segments**.
In this model the atrium is not connected to the right ventricle and the left ventricle not to the outflow tract.

The conversion of such a serial arrangement of segments into the proper parallel arrangement has remained one of the most difficult concepts of heart development, for it seems illogical first to make a serial arrangement of cardiac segments and then a parallel one.

# LOOPING

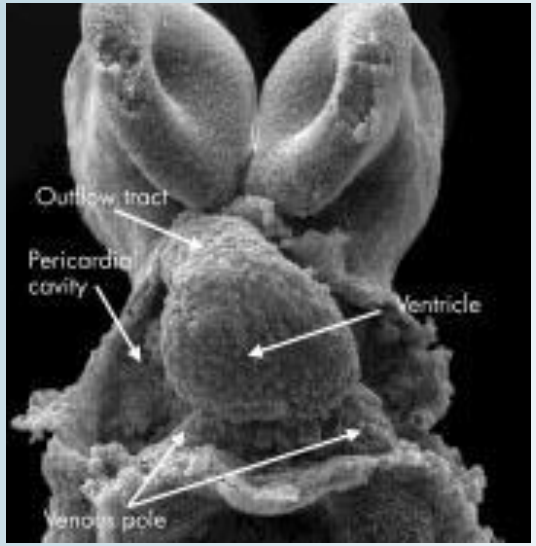


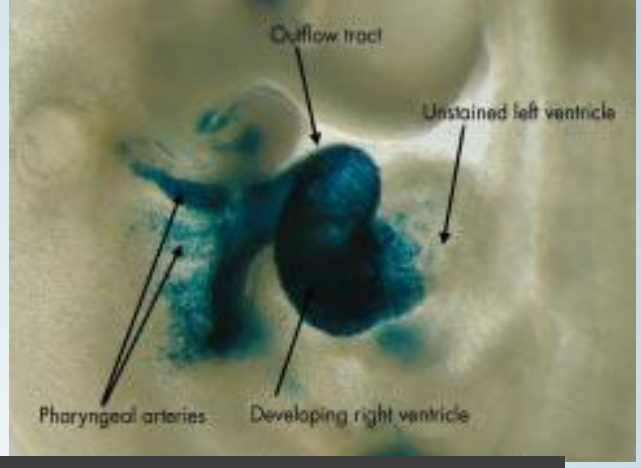


- cells from the **secondary heart field**, are labelled with a reporter transgene for FGF10.
- the cells from the secondary field populate the pharyngeal arches, the outflow tract, and the **developing right ventricle**
- they do not, however, extend beyond the interventricular groove to enter the left ventricle.

This scanning electron micrograph shows the stage of the **"straight heart tube".** Note that the tube is composed primarily of the ventricle, which **will become the definitive left ventricle**. As yet, there is no formation of an atrial component, and the outlet is similarly rudimentary.

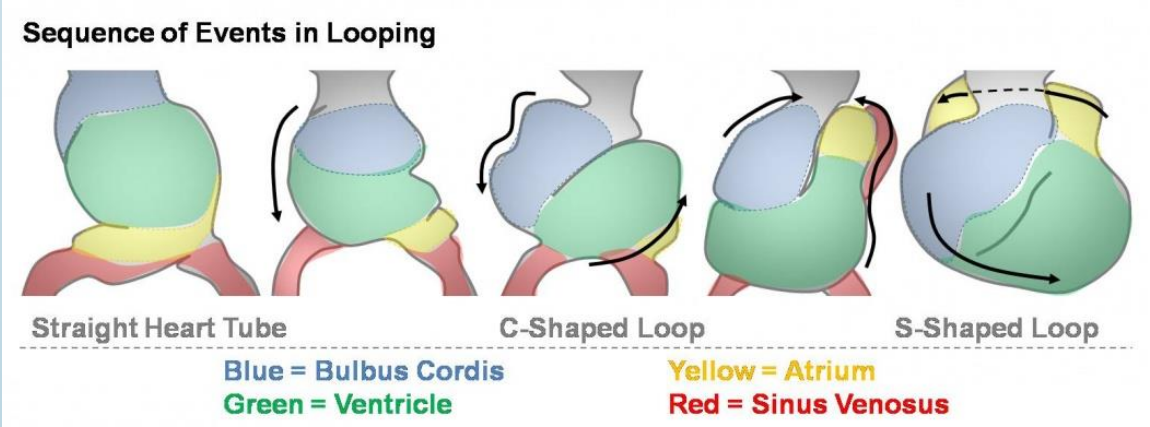

# BALLONING MODEL OF CHAMBER FORMATION

**NEW CONCEPT**
"the ballooning model of chamber formation."
Ontogenesis of the heart the chambers develop from a linear tube by local differentiation
From the outset, the right and left halves of the heart are brought into parallel position by looping of the heart tube.

As the tubular heart continues to develop, its **outer curvature initiates a distinct gene programme** by which localized differentiation and proliferation cause expansion of atrial and ventricular chambers.

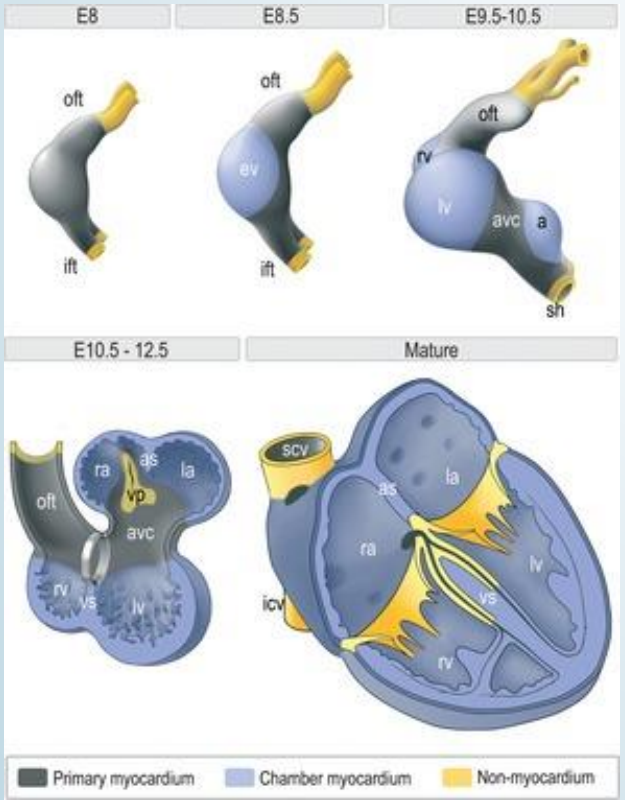


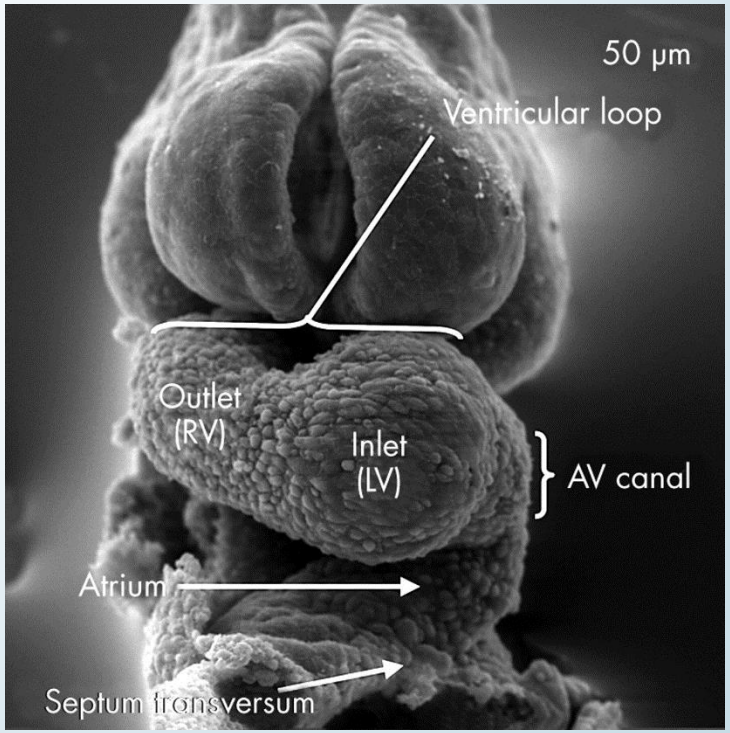

# TRANSCRIPTIONAL REGULATION OF CHAMBER-SPECIFIC GENE EXPRESSION

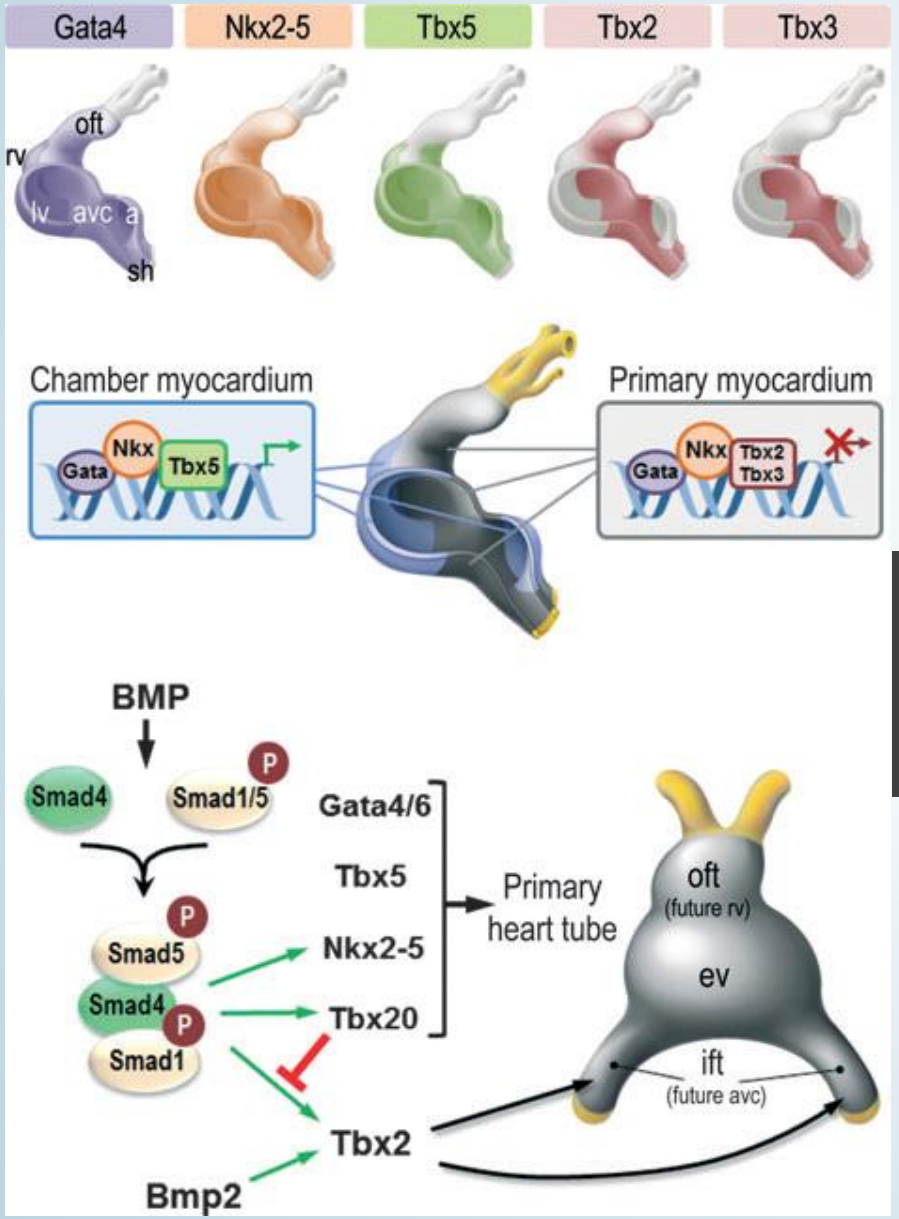


At early stages, blood drains from the venous pole into the common atrium and travels via the atrioventricular canal and embryonic ventricle to the outflow tract.

atrial and ventricular chambers are physically separated by the atrioventricular canal, which retains primary myocardial properties

The transcription factors Hand1, Irx4 and Irx5, Nkx2-5, Gata4, Tbx2, Tbx3, Tbx5 and Tbx20 are all known to be required during chamber morphogenesis and regulate a number of genes, such as those encoding the gap-junction proteins connexin40 (Cx40) and connexin43

**Chamber-specific gene program** or repression of chamber formation in primary myocardium

# BALLONING AND RIGHTWARD TURNING

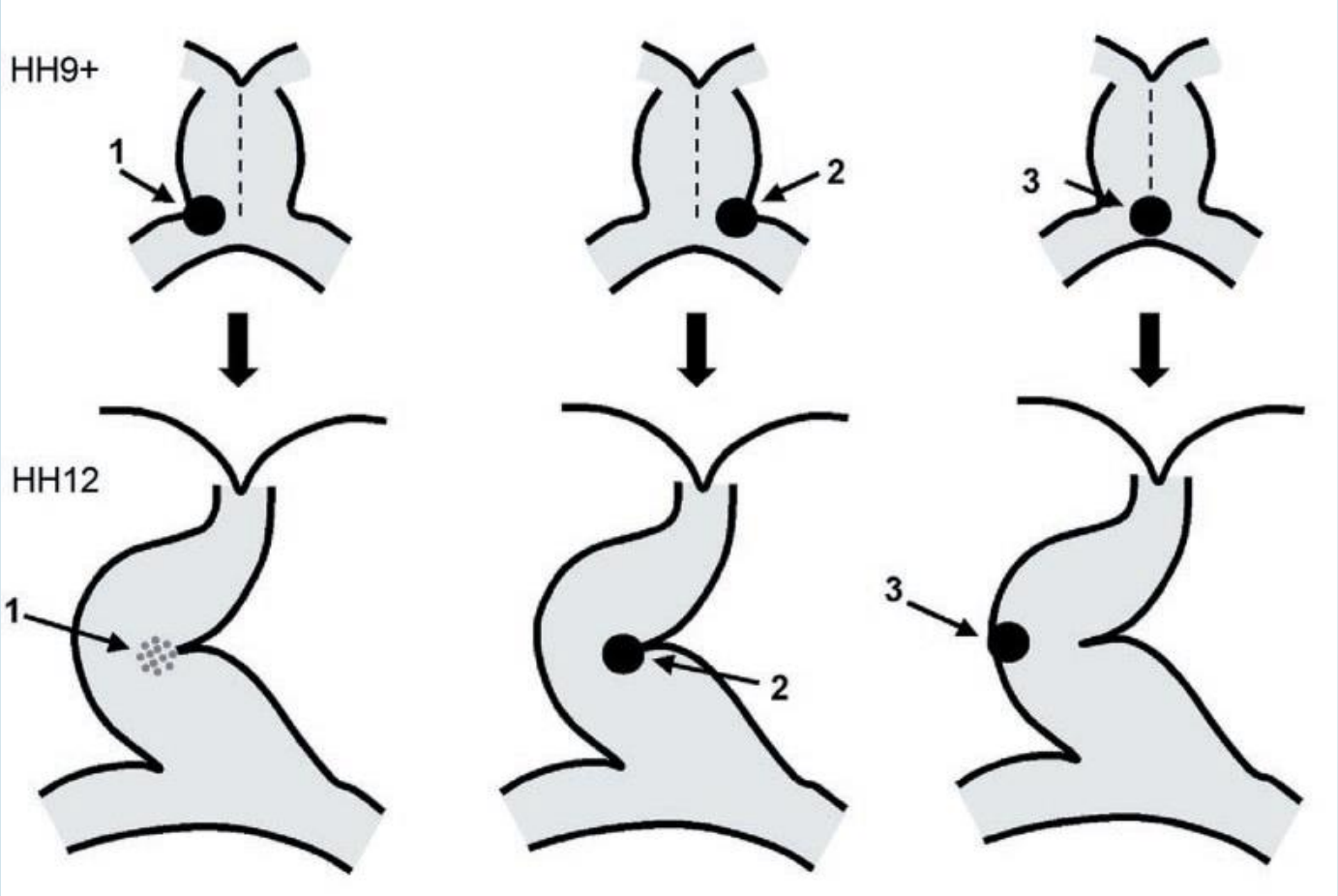


- enormous growth - **ballooning of the ventral side of the heart tube**, relative to the dorsolateral side
- by which the label placed at the left or right interventricular groove becomes positioned at the inner curvature
- illustrate the **rightward turning of the heart tube** by which the ventrally positioned label becomes positioned at the outer curvature and by which the left part of the heart tube becomes positioned ventrally

# DEVELOPMENT OF ATRIA

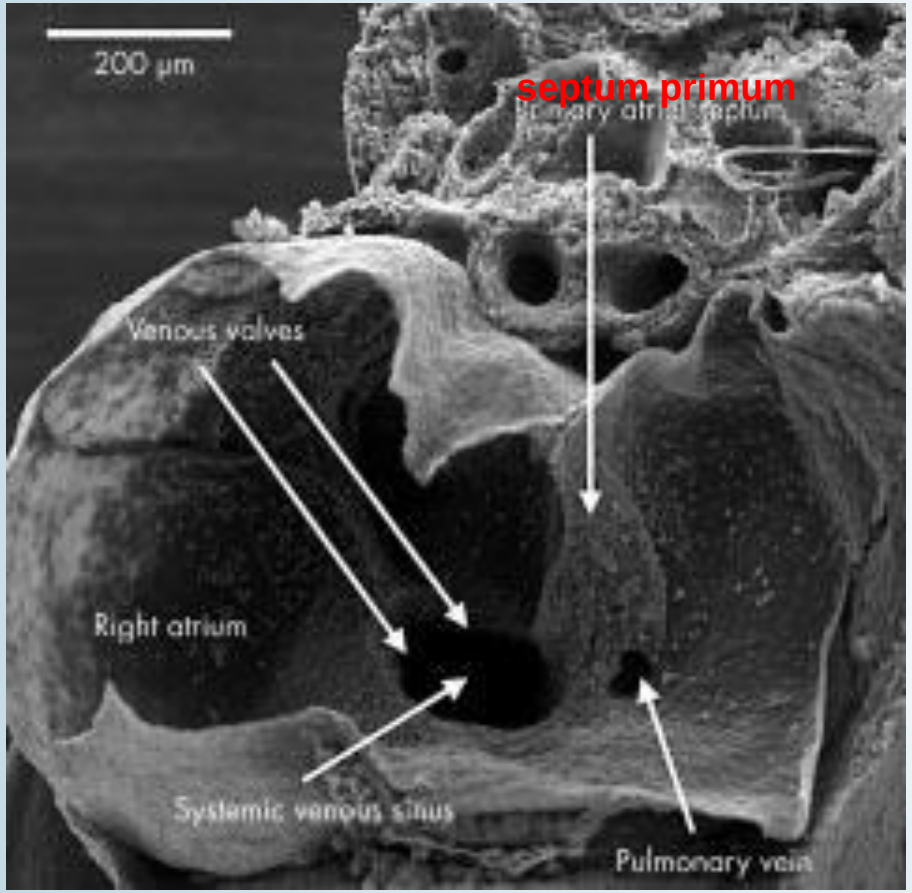


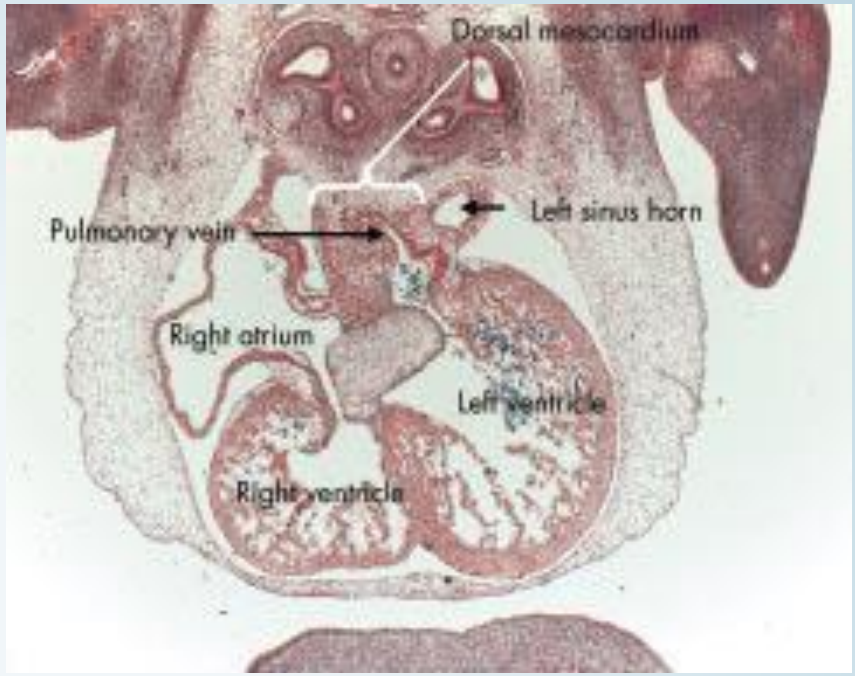


Completion of the development of the **left atrium** requires **formation of the lungs** and the **pulmonary vasculature.**

-lung buds form
-**plexus of vessels develops around them**
-plexus establishes a **direct connection** with the primary atrial component of the heart tube via the **pulmonary vein**
-area initially bounded by the reflections of the **dorsal mesocardium**

**-superolateral** walls of the **atrial component** of the **primary heart tube** have **ballooned out** to either side of the outflow tract to form the **atrial appendages**

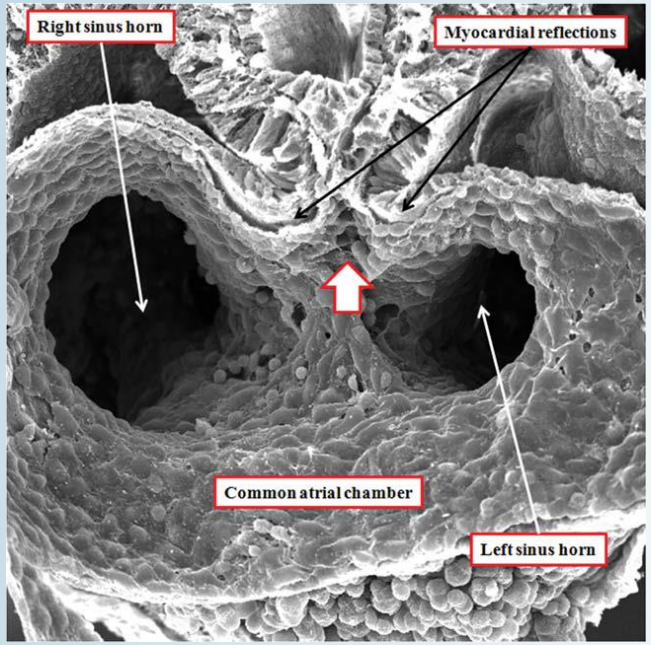


-yet almost symmetrical

-**left sinus horn** is becoming incorporated into the developing left atrioventricular groove, passing beneath the posterior mesocardium
-diminution in size of the left sinus horn, which persists as the **coronary sinus**, developing so as to receive most of the venous return from the heart itself

-lateralization of the systemic venous return
-**venoatrial junction is committed exclusively to the right side** of the developing common atrial chamber
-septation of the cardiac chambers

# SEPTUM PRIMUM – OSTIUM PRIMUM – FORAMEN SECUNDUM

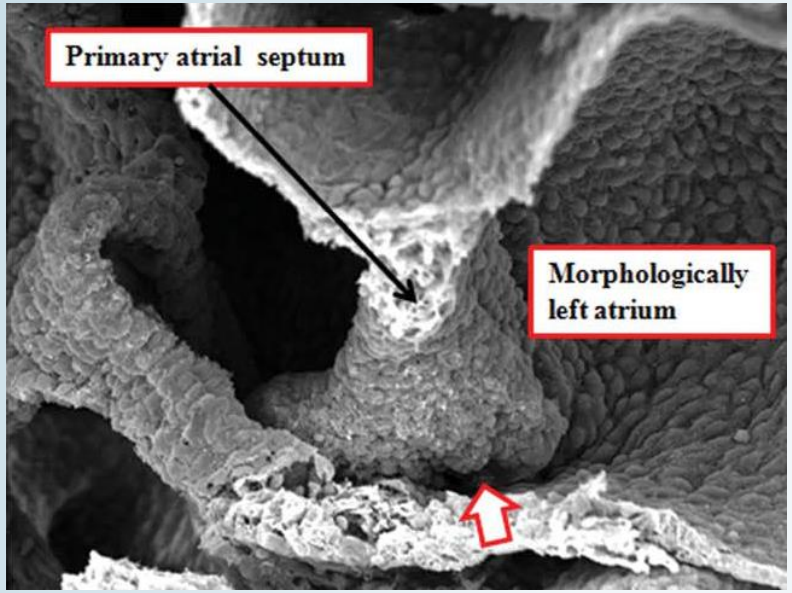


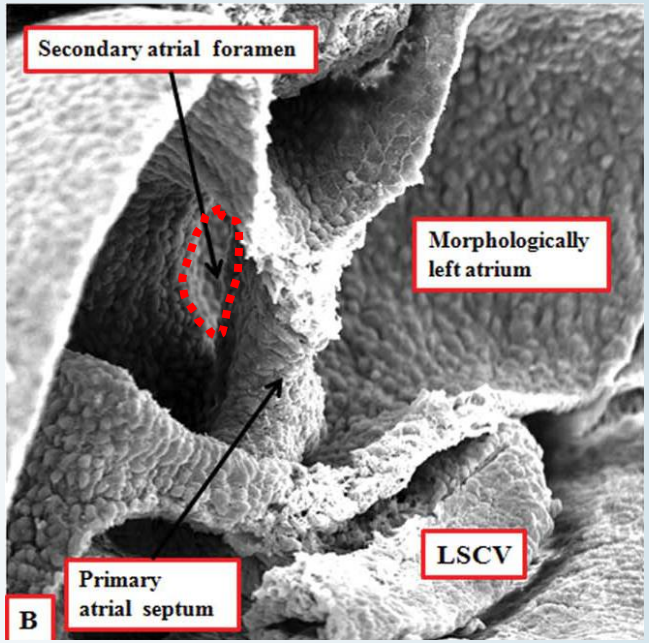


-primary atrial septum fuses with the atrial surface of atrioventricular endocardial cushions
-it is fusion of the mesenchymal tissues with the atrioventricular endocardial cushions that obliterates the primary atrial foramen.
-anchors the primary atrial septum to the atrioventricular cushions

-primary atrial septum grows as a **muscular partition** from the roof of the primary atrium
-this muscular shelf grows into the atrial cavity **between the systemic and pulmonary venous openings**
-originates from the part of the primary atrium that has molecularly **left characteristics**: expression of the *Pitx2* gene

# „SEPTUM SECUNDUM”

-standard textbooks of cardiac development usually illustrate the right atrial margins of the oval foramen as being formed by *downgrowth from the atrial roof of a secondary atrial septum*

**There is no evidence from study of the developing mouse, or human embryonic hearts, to support the notion that such a second septum grows into the atrial cavities from their roof!!!!!**

https://clinicalgate.com/wp-content/uploads/2015/06/B978143772696100005X_f005-002-9781437726961.jpg

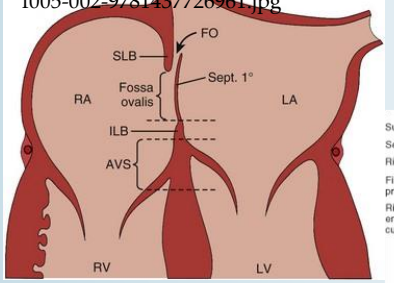


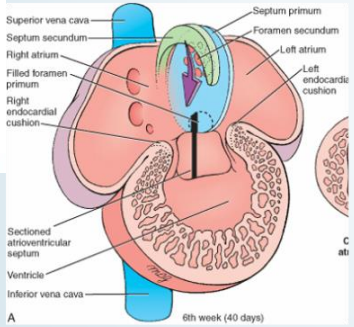


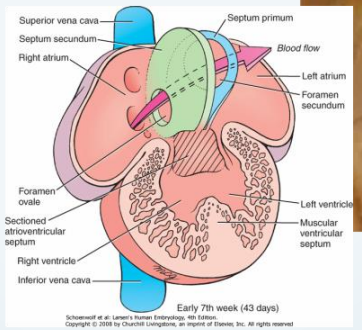


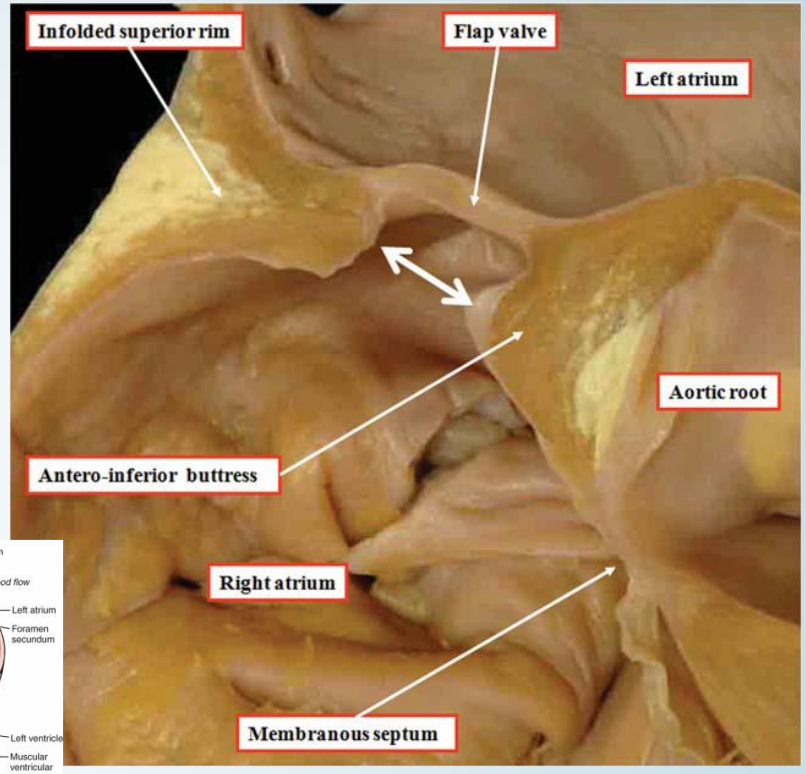


-the newly **muscularised antero-inferior margin** of the oval foramen, derived from the vestibular spine, is anchored to the fibrous skeleton, itself formed from the atrio-ventricular cushions.
- primary atrial septum persists as the flap valve of the oval foramen.
-the **antero-superior rim**, against which the flap valve abuts, and which is usually described as the *"septum secundum"*, is the **infolding** now existing between the junction of the superior caval vein to the right atrium and the right pulmonary veins to the left atrium.

# FORMATION OF INTERATRIAL SEPTUM

Only after septation

-**pulmonary venous component** expand to form the **roof of the left atrium**,

- producing the definitive arrangement with 4 venous orifices

**-morphologically right or left components is under the control of genes such as *Pitx2*, which determine left–right asymmetry**

- systemic venous tributaries are in continuity with the primary atrial component being part

**- with remodelling, “sinus venosus” is shifted to open into the right side of the primary atrium.**

-the atrial chamber is divided by a muscular septum (primary septum) that is formed by **local active proliferation** of the myocardial cell layer

-its free rim is covered with a **mesenchymal cap** that fuses with the atrioventricular cushions and the dorsal mesenchymal protrusion (vestibular spine)

# INTERVENTRICULAR SEPTUM

The **muscular ventricular septum** itself was initially formed concomitant with the process of **ballooning** of the ventricular apical components

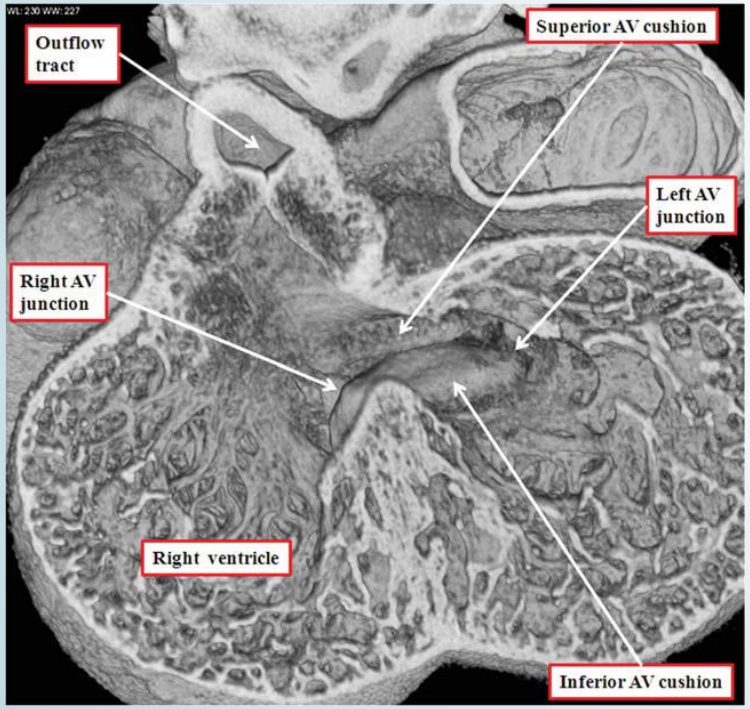


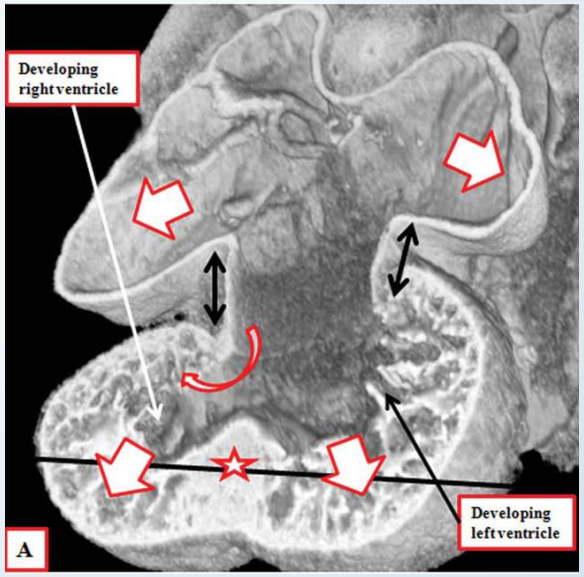

# DEVELOPMENT OF RIGHT VENTRICL

primary ring

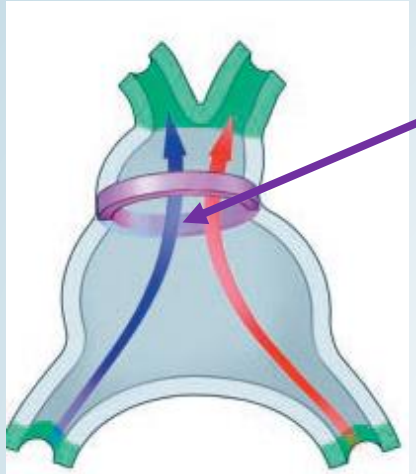

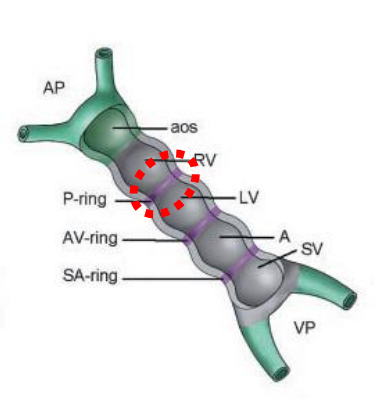


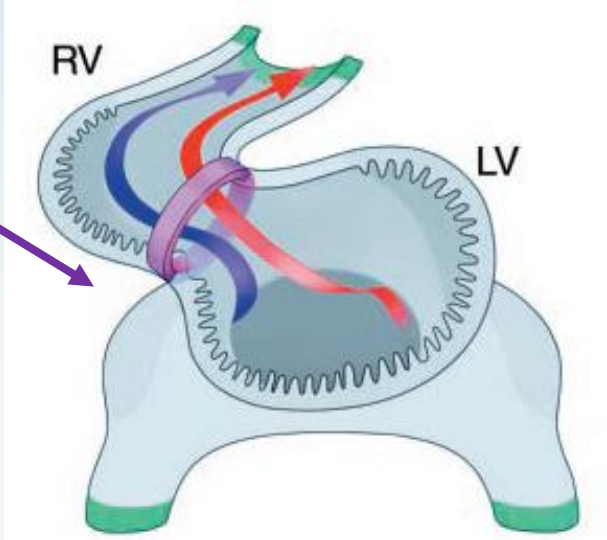


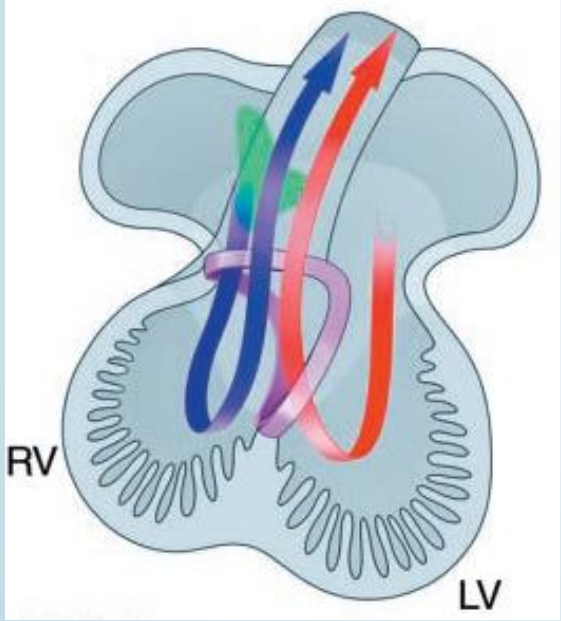


Note that the left and right flows of blood are parallel in all stages!!

PRIMARY RING (interventricular or bulboventricular ring)

-crucial landmark in the development of right ventricle

-comprises the myocardium of primary heart tube at the position where the ventricular septum develops

-in human embryos, the ring is characterized by the expression of a protein epitope called GIN2

- ring become right ventriclar inlet

+

- ring become left ventriclar outlet

# DEVELOPMENT OF RIGHT VENTRICLE

human embryo heart - 35 days

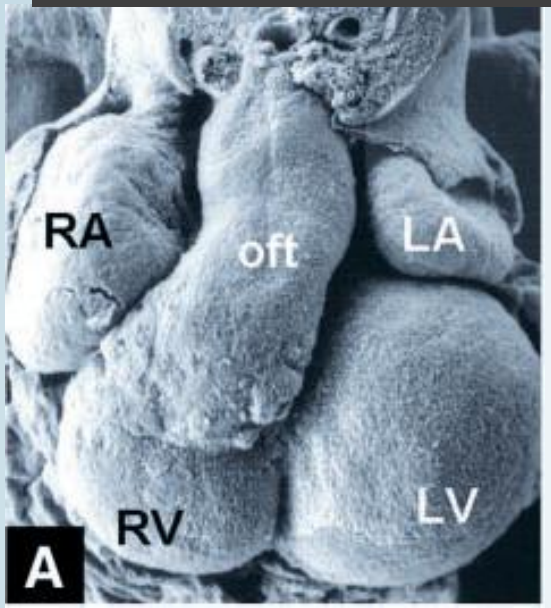


mouse embryo heart – atria removed

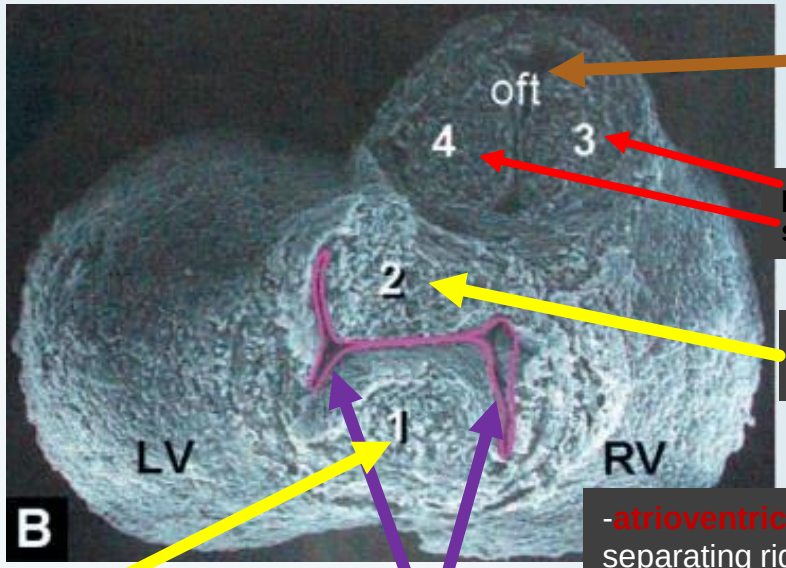


outflow tract

parietal outflow tract ridge
septal outflow tract ridge

ventral atrioventricular cushion

-atrioventricular cushions separating right and left blood flows occupy most of atrioventricular canal

dorsal atrioventricular cushion

atrioventricular canal

**right side** of the atrioventricular canal is directly connected to the right ventricle
**left side** of the atrioventricular canal is directly connected to the left ventricle

most of the right ventricle and arterial trunks are added after the formation of the primitive heart tube

-outflow tract myocardium becomes incorporated into the right ventricle
-right ventricle, (part of) the ventricular septum, the myocardial and smooth muscle cells of the arterial outlets and the atria are all dependent on the ongoing accumulation of differentiating SHF cells

# CASCADE OF HEART DEVELOPMENT

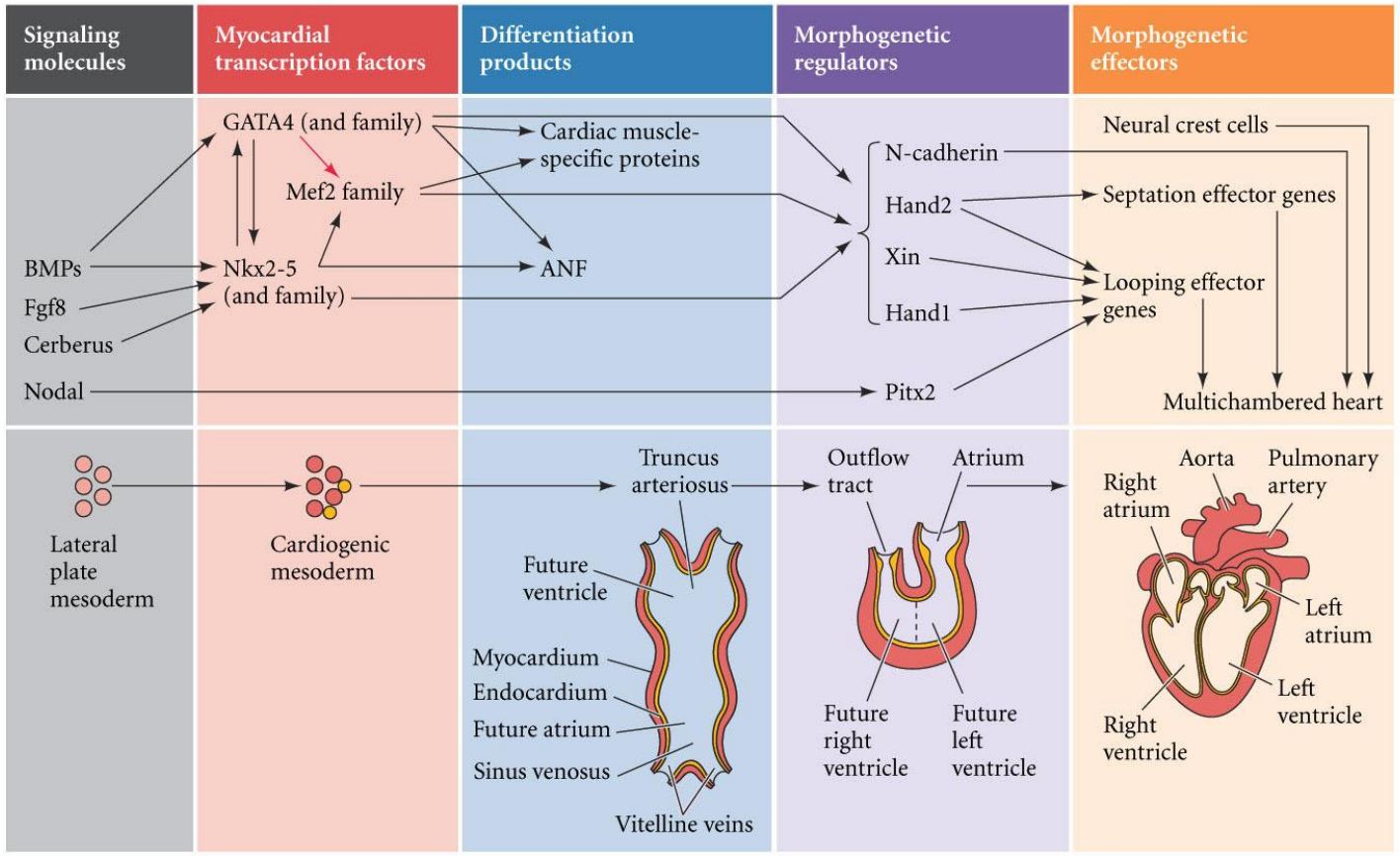


DEVELOPMENTAL BIOLOGY, Eighth Edition, Figure 15.6 © 2006 Sinauer Associates, Inc.

# PARTITIONING OF BULBUS CORDIS AND TRUNCUS ARTERIOSUS

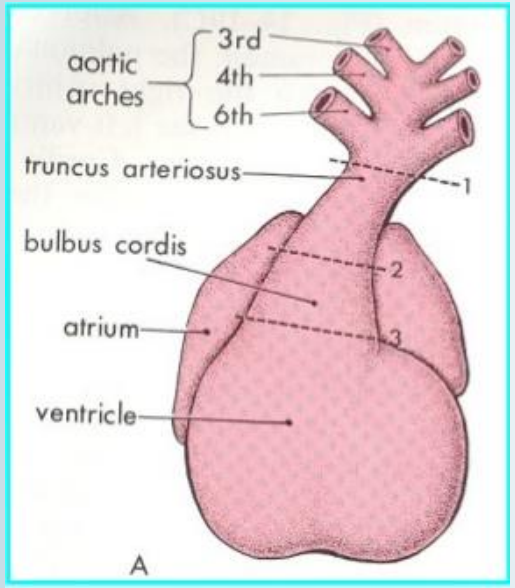


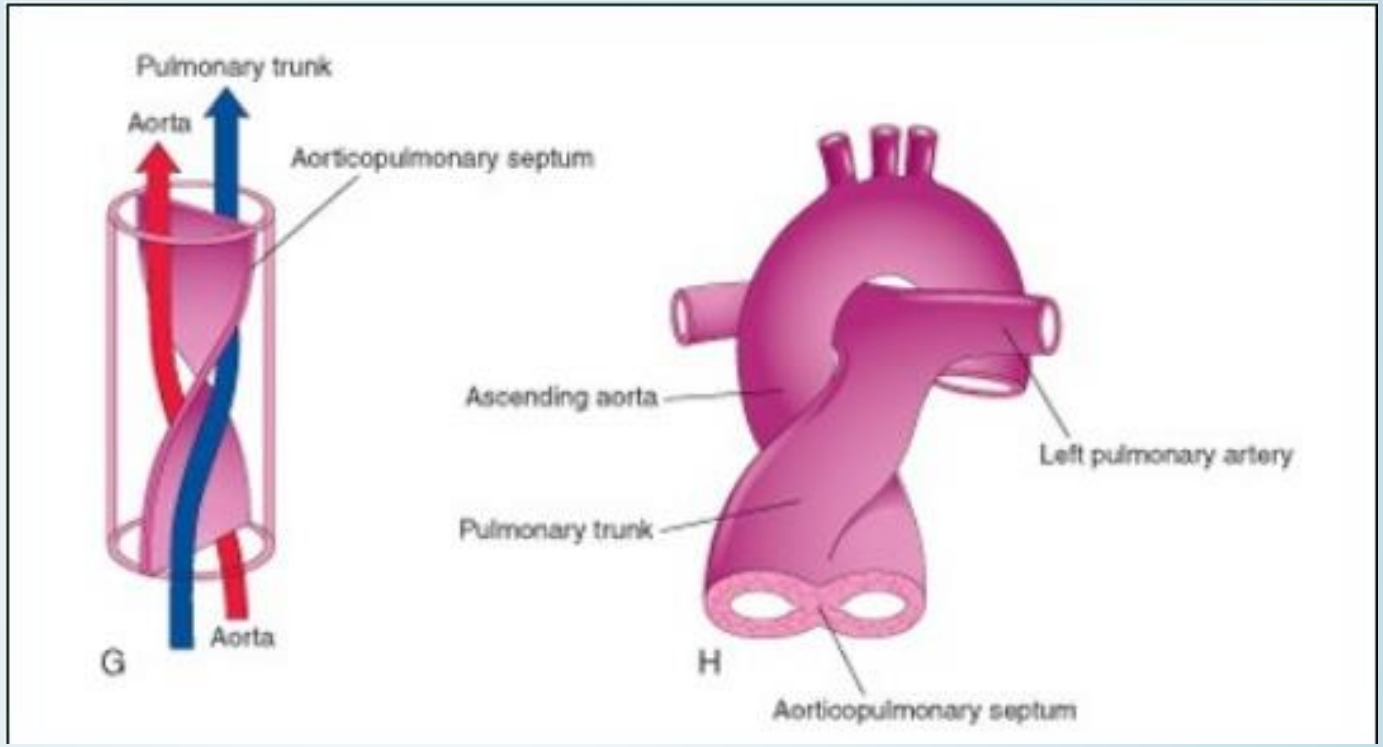


-Shh (protein encded by Shh gene) is involved in maintaining the size of the SHF population and plays important roles during outflow tract septation
- transformation of the myocardial outflow tract into the separated pulmonary trunk and aorta requires the cellular contribution of a distinct precursor pool called the neural crest cells, in addition to SHF cells
-neural crest cells are multipotent migratory cells that delaminate from the lateral margin of the neural plate

https://image.slidesharecdn.com/cvsembryologyparti-a2studentsonly-131230080531-phpapp01/95/cvsembryologyparti-a2studentsonly-32-638.jpg?cb=1388390809

https://image.slidesharecdn.com/cvsembryologyparti-a2studentsonly-131230080531-phpapp01/95/cvsembryologyparti-a2studentsonly-47-638.jpg?cb=1388390809

# DEVELOPMENT OF CARDIAC VALVES

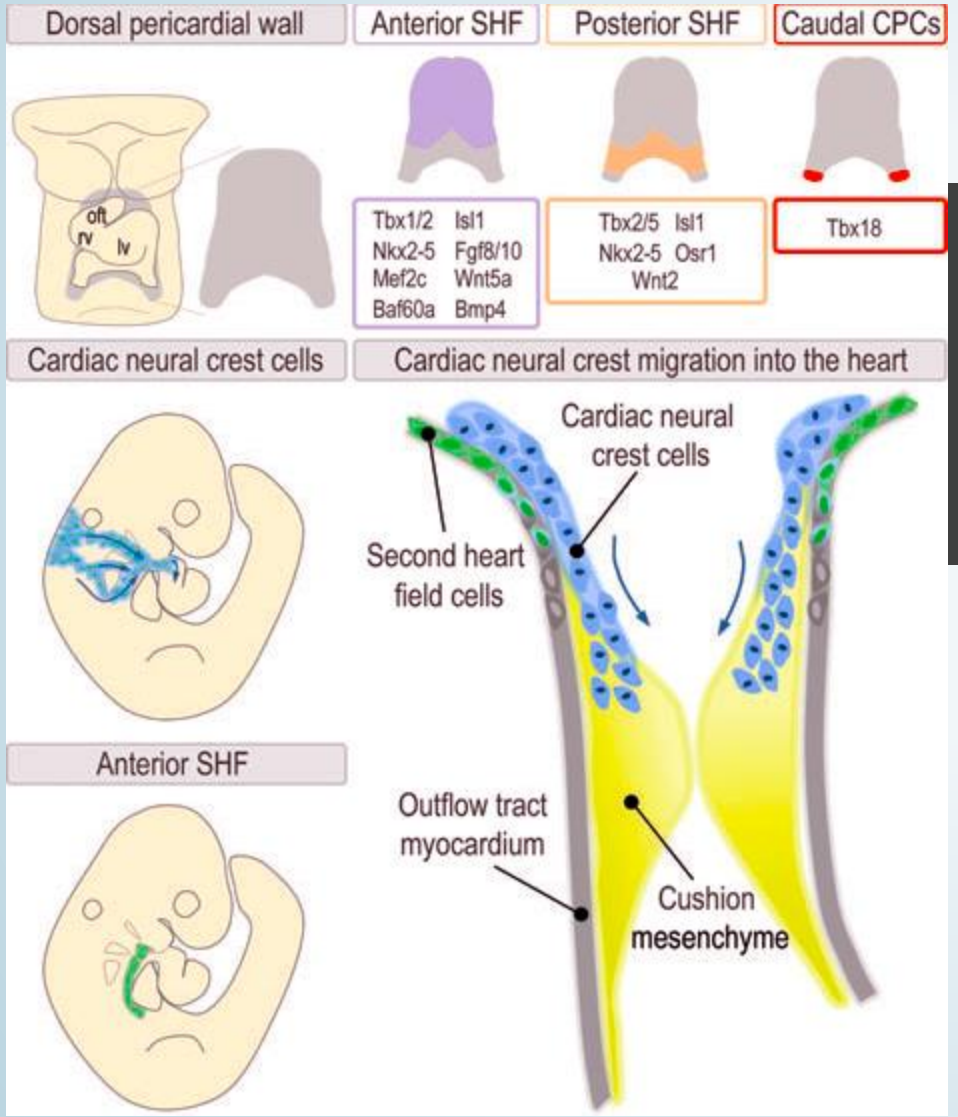


-neural crest cells invade the proximal and distal outflow tract cushions and contribute to the formation:

- -semilunar valves
- -tunica media layer of the smooth muscular wall of the great vessels, aortic arch and the proximal carotids

# DEVELOPMENT OF CARDIAC VALVES - 4 DISTINCT LINEAGES

In addition to **secondary heart field lineage**, cardiac valves appear to be derived from at least **four distinct lineages.**

1. mesenchyme, is derived from the **endocardium**, which has been confirmed by the transformation of endocardial endothelium to mesenchyme (ETM)
   - give rise to components of the major midline cushions and AV valve leaflets,
   - chordae tendineae

2. **epicardium** and epicardial-derived cells (EPDCs)
   - epicardial-contribution not only to the annulus fibrosis and AV sulcus/ groove, but also to the **mural mitral and tricuspid leaflets**

3. **neural crest cells** contributes to the development
   - **AV septal complex** and the **AV valves** POCre/R26R)
   - neural crest cells do, in fact, migrate into the **septal tricuspid leaflet** and the **aortic leaflet of the mitral valve** while sparing the mural leaflets
   - penetrate through the sinus venosus mesocardium and proceed to the AV canal

4. cells of a **bone marrow hematopoietic stem cell** origin are able to contribute to **valvular interstitial cells**

The past fifteen years have been very exciting for cardiac developmental and molecular biologists and have led to significant insights into the developmental origin of the various tissue types that make up the heart.

Current progress has furthermore shed light on the **molecular and transcriptional machineries** that determine cardiac form and function. This knowledge is essential if we want **to understand the developmental origin of congenital cardiac defects** and to devise future molecular, genetic and cell-based therapies.

**More recently, postnatal cardiac or dermal fibroblasts were demonstrated to have the potential to differentiate into myocardium-like cells by adding only Gata4, Tbx5 and Mef2c (Ieda et al. 2010). This combination also induced functional and beating cardiomyocytes from resident non-myocytes in vivo (Qian et al. 2012).**

# FETAL CIRCULATION

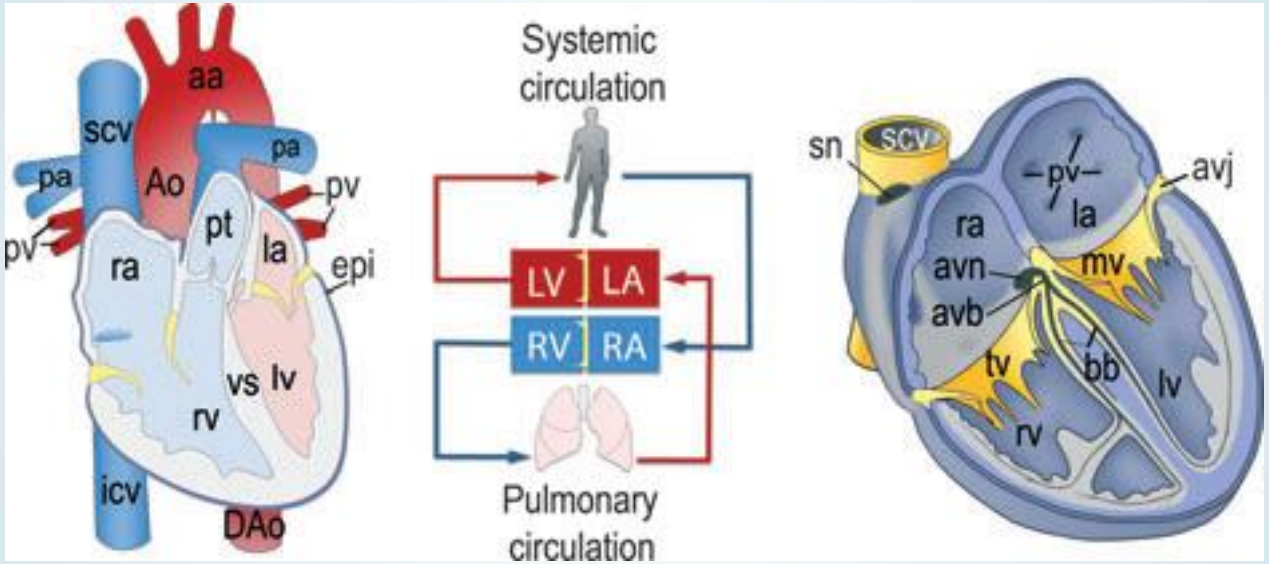

# CIRCULATORY SYSTEM OF A 4-WEEK HUMAN EMBRYO

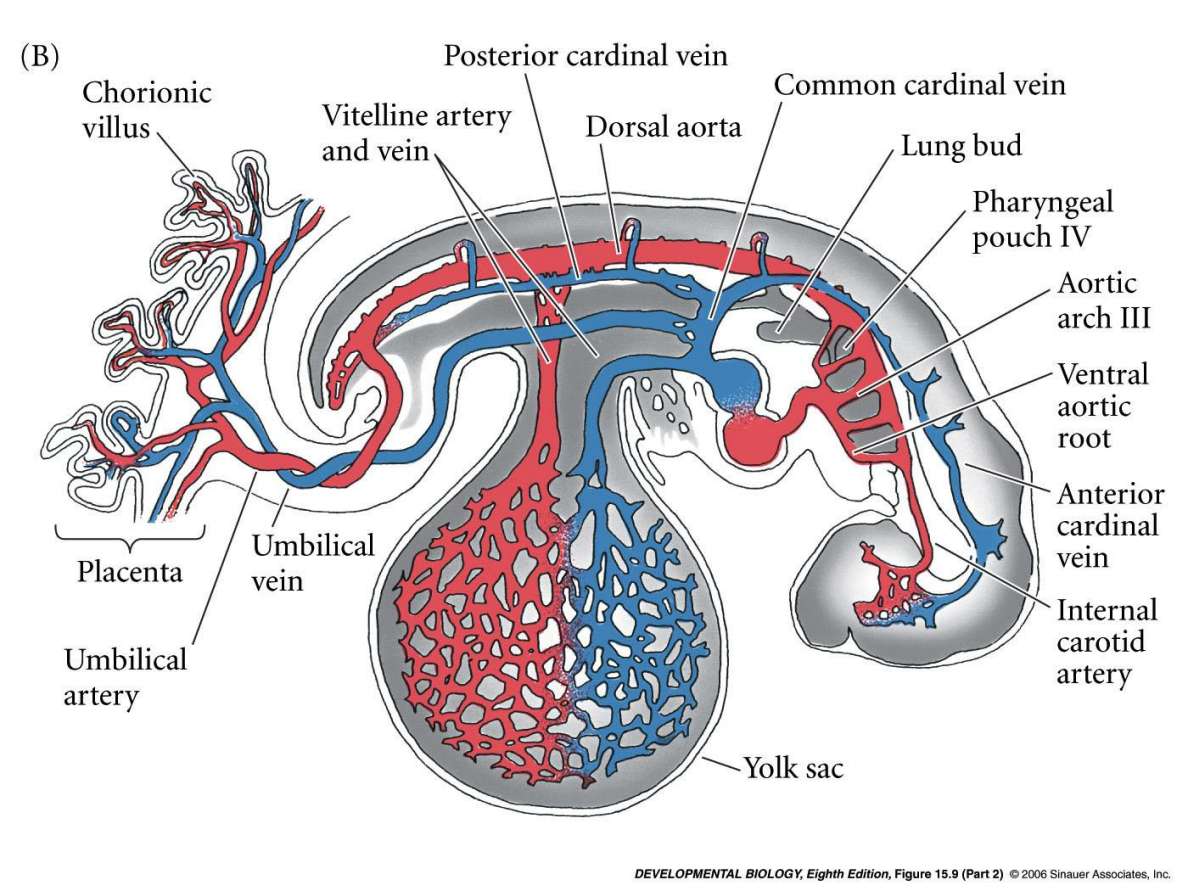


-nutrients are absorbed from the **yolk**, and blood returns through the **vitelline veins** to re-enter the heart through the **sinus venosus**.

-the main supply of food and oxygen comes from the **umbilical vein**, which unites the embryo with the **placenta**

# FETAL CIRCULATION

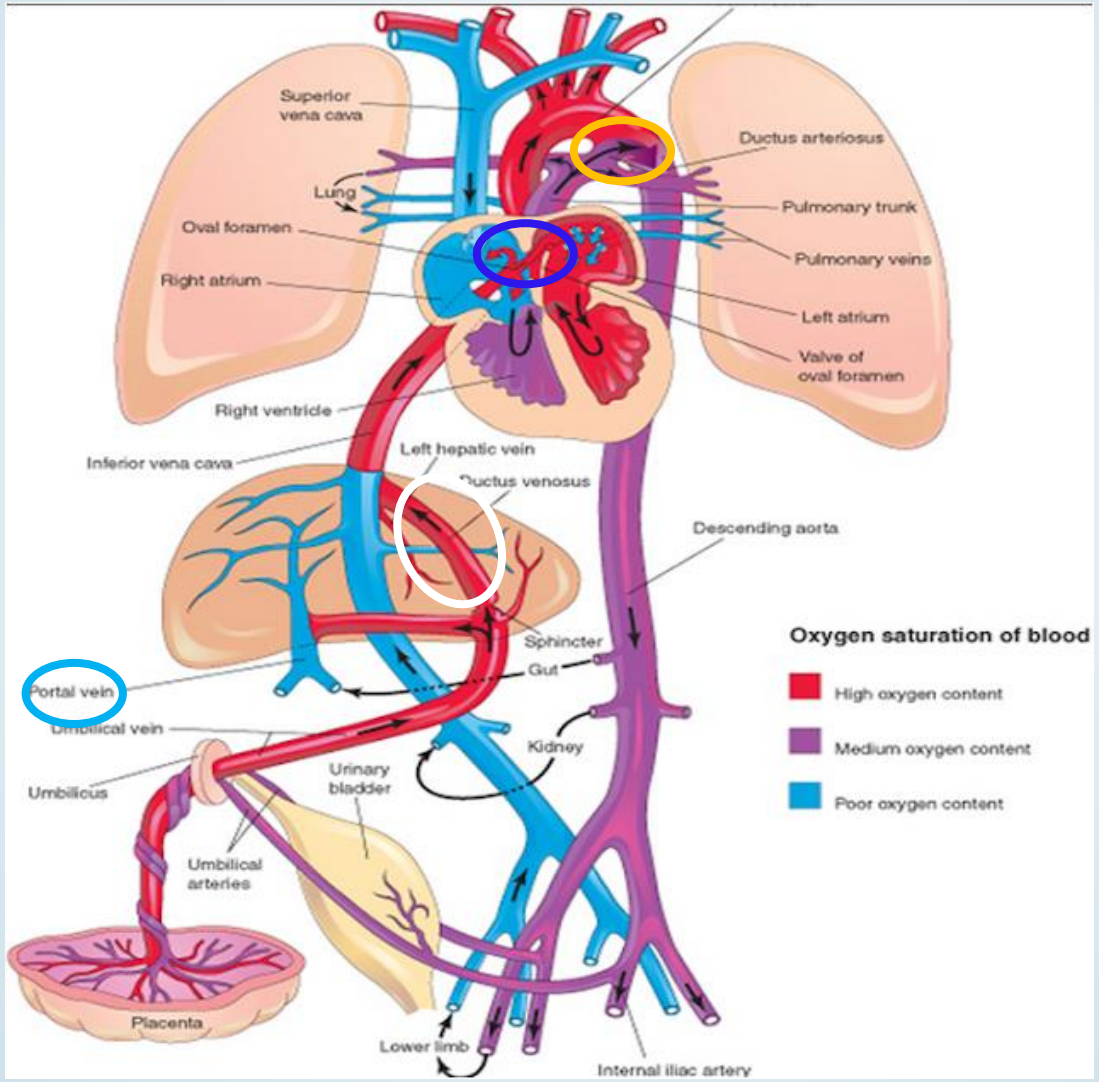

# POSTNATAL CIRCULATION

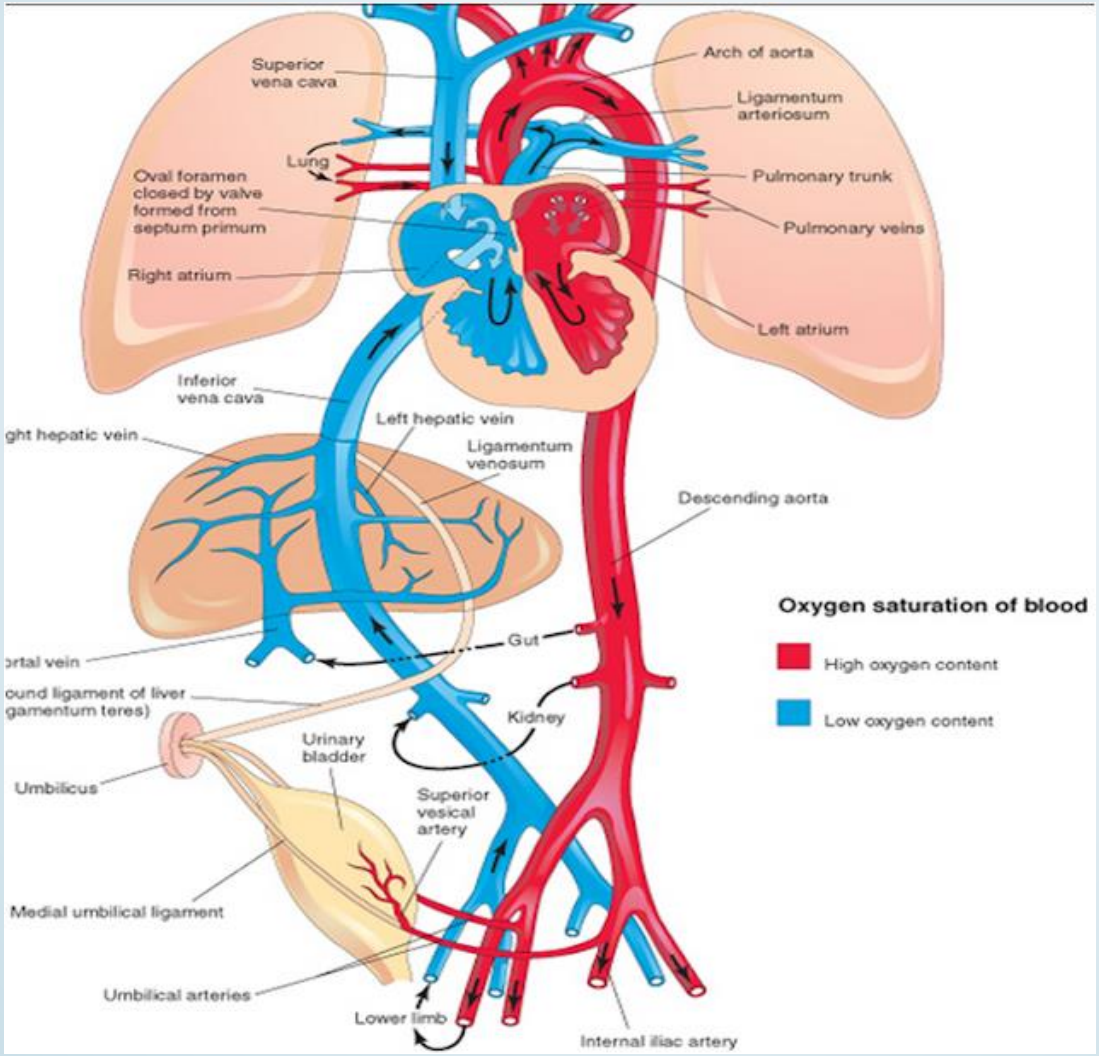


http://2.bp.blogspot.com/-ud88MiLuzGE/UqdazgKprMI/AAAAAAAAKaU/i_64Sj7YlSg/s640/Neonatal+circulation.png

# REFERENCES


REVIEW
A molecular and genetic outline of cardiac morphogenesis
M. S. Rana, V. M. Christoffels and A. F. M. Moorman
Acta Physiol 2013, 207, 588–615

DEVELOPMENT OF THE HEART: (2) SEPTATION OF THE ATRIUMS AND VENTRICLES
Robert H Anderson, Sandra Webb, Nigel A Brown, Wouter Lamers, Antoon Moorman

The Development of Septation in the Four-Chambered Heart
ROBERT H. ANDERSON,1* DIANE E. SPICER,2,3 NIGEL A. BROWN,4 AND TIMOTHY J. MOHUN

Nodal Flow and the Generation of Left-Right Asymmetry
Nobutaka Hirokawa,1,* Yosuke Tanaka,1 Yasushi Okada,1 and Sen Takeda

Heart Fields and Cardiac Morphogenesis
Robert G. Kelly1, Margaret E. Buckingham2, and Antoon F. Moorman

DEVELOPMENT OF THE HEART: (1) FORMATION OF THE CARDIAC CHAMBERS AND ARTERIAL TRUNKS
Antoon Moorman, Sandra Webb, Nigel A Brown, Wouter Lamers, Robert H Anderson

Cardiac Chamber Formation: Development, Genes, and Evolution
ANTOON F. M. MOORMAN AND VINCENT M. CHRISTOFFELS

The contribution of Islet1-expressing splanchnic mesoderm
cells to distinct branchiomeric muscles reveals significant
heterogeneity in head muscle development
Elisha Nathan1, Amir Monovich1, Libbat Tirosh-Finkel1, Zachary Harrelson2, Tal Rousso1, Ariel Rinon1, Itamar Harel1, Sylvia M. Evans2 and Eldad Tzahor

Developmental origin and lineage plasticity of endogenous cardiac stem cells
Maria Paola Santini1, Elvira Forte2,3,4, Richard P. Harvey2,3,4,5,* and Jason C. Kovacic