Angiography and anatomy

Balázs Nemes

Heart and Vascular Center
Semmelweis University

History

- 1927 Egas Moniz
  - First cerebral angiography
- 1929 Werner Forssmann
  - Right heart catheterization (ureter catheter)
- 1953 Seldinger
  - Punction technique
- 1964: Dotter
  - Percutaneous angioplasty – PTA

Seldinger technique

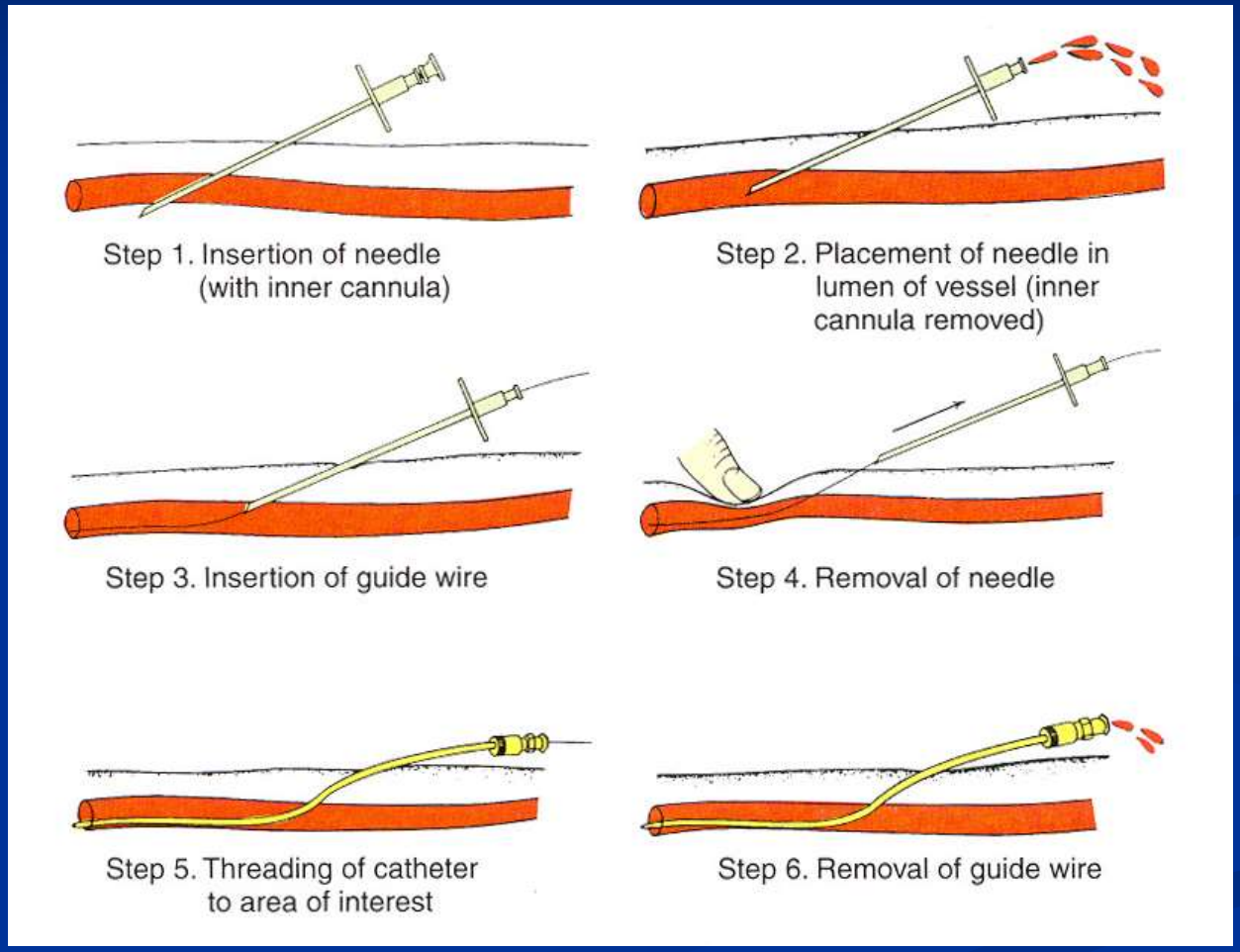

Guidewire



- Teflon or hydrophilic coating
- Diameter (inches): 0.014-0.035

Diagnostic catheters

- Polymer layer – braided wire
- Diameter (French): 1 F = 1/3 mm





Punction site

Easy to palpate and puncture
Safe compression after the procedure

- Femoral
- Radial
- Brachial
- Axillary
- Percutaneous abdominal aortic punction (Dos Santos)

DSA
(digital subtracion angiography)

DSA

- Angiography only depicts the lumen, does not provide information on the surrounding
- Motion artifacts
- Overlapping of the vessels

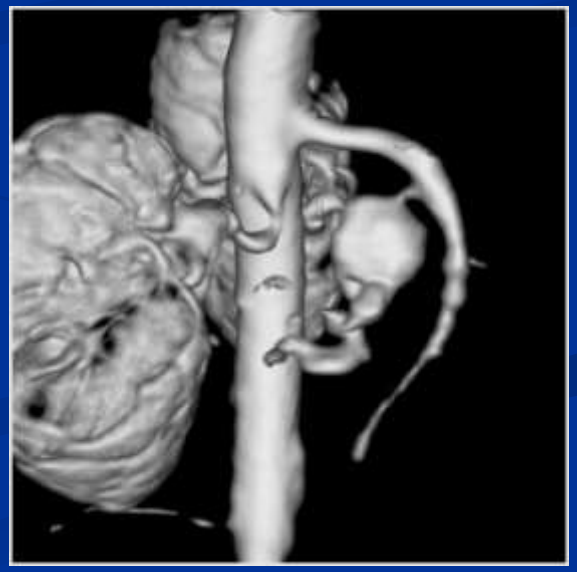

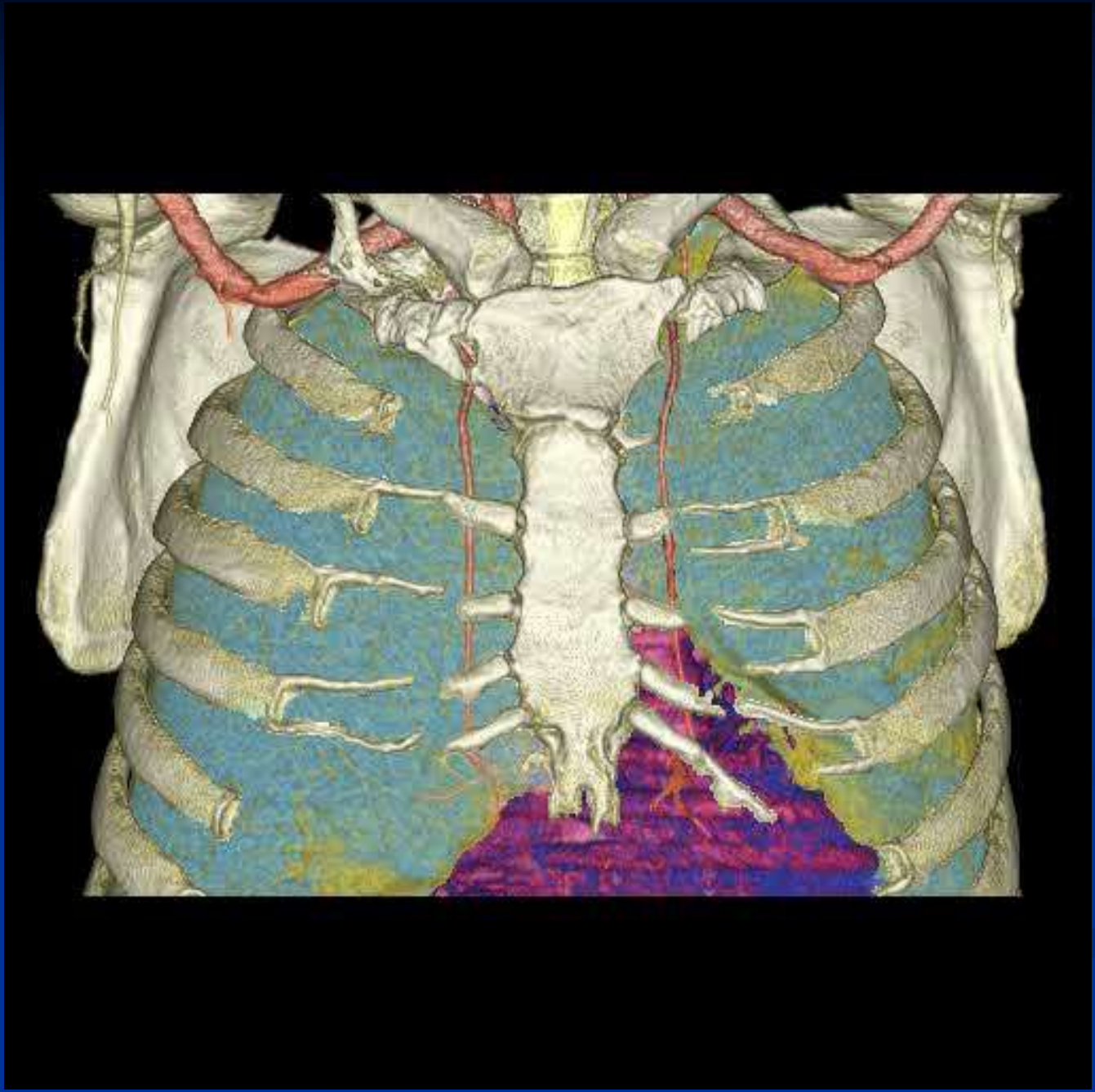

Angiography is replaced by less invasive methods:

- Ultrasound
- CT angiography
- MR angiography

Angiography is mostly used for diagnostics when there is a chance for endovascular (interventional) procedure.

Normal bronchial

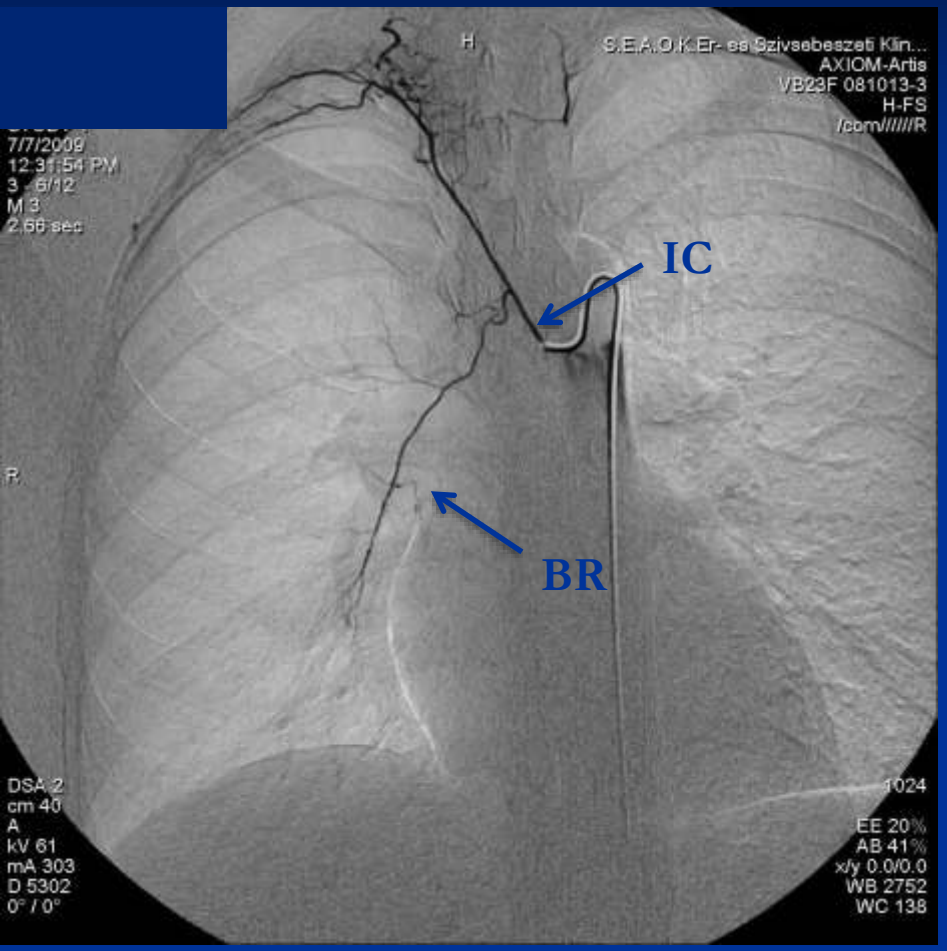

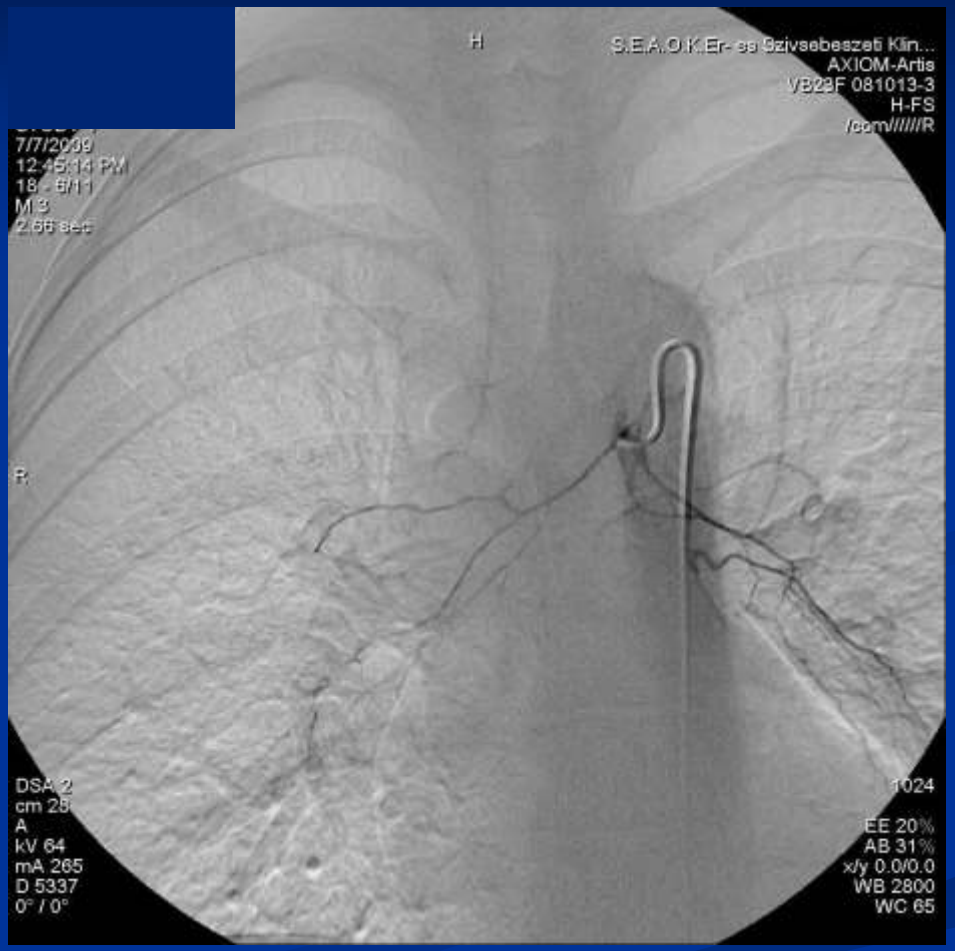

At the level of T5-T6 vertebrae, numerous variations
Maximum diameter: 1,5-2 mm

Bronchial artery

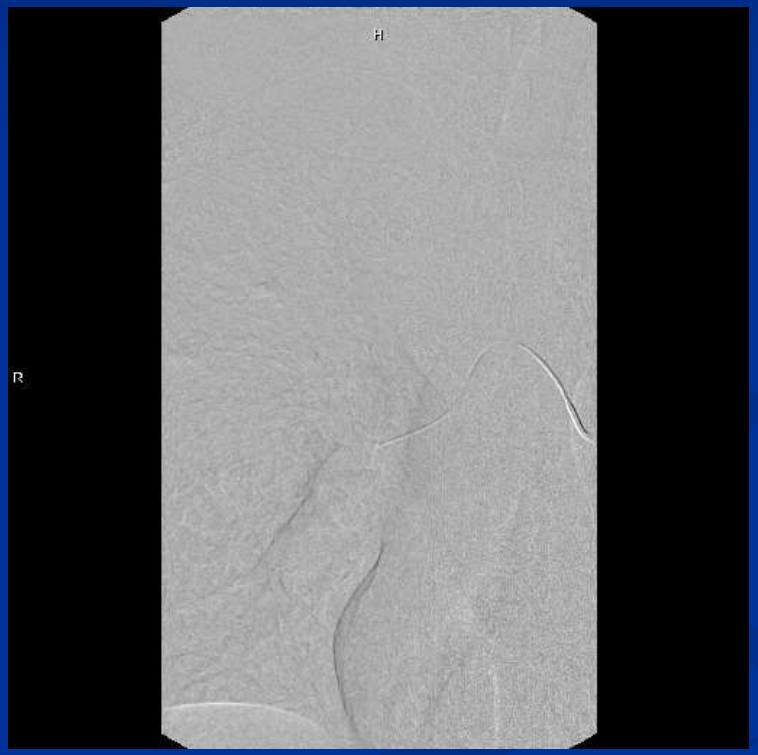

Abdominal CT angiography

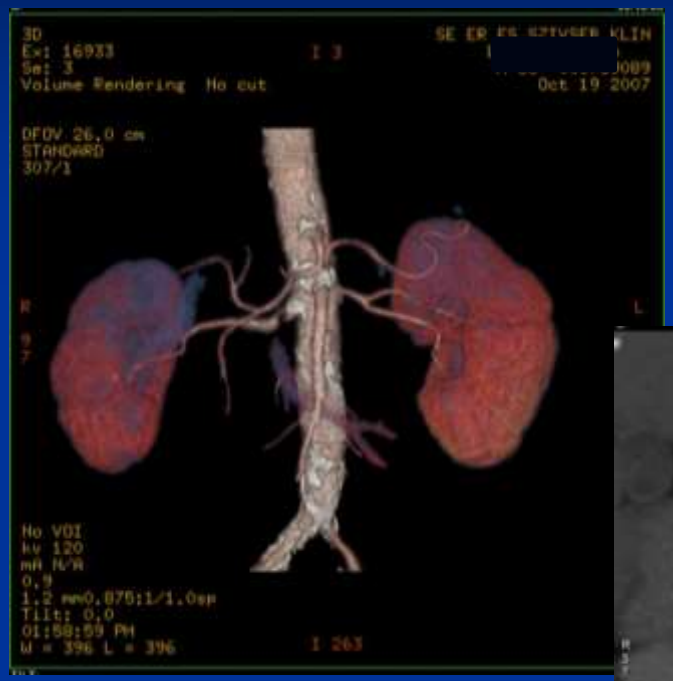

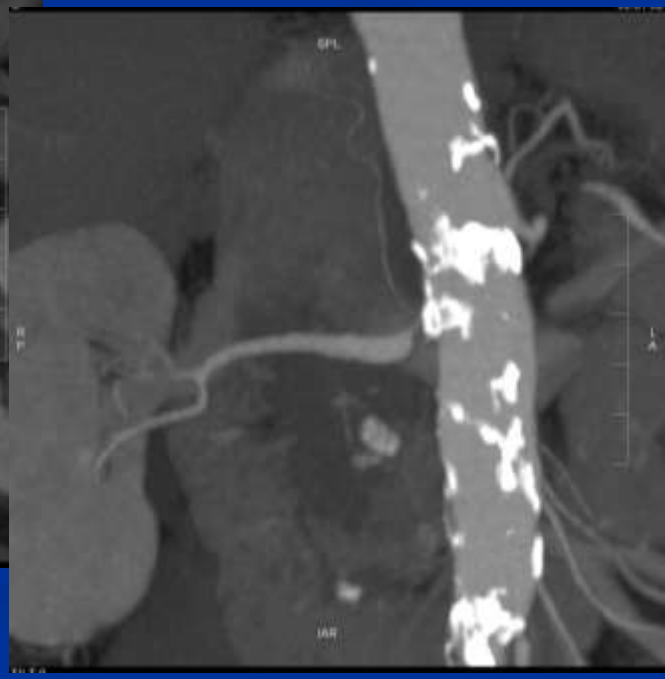

Stenting of the right renal artery

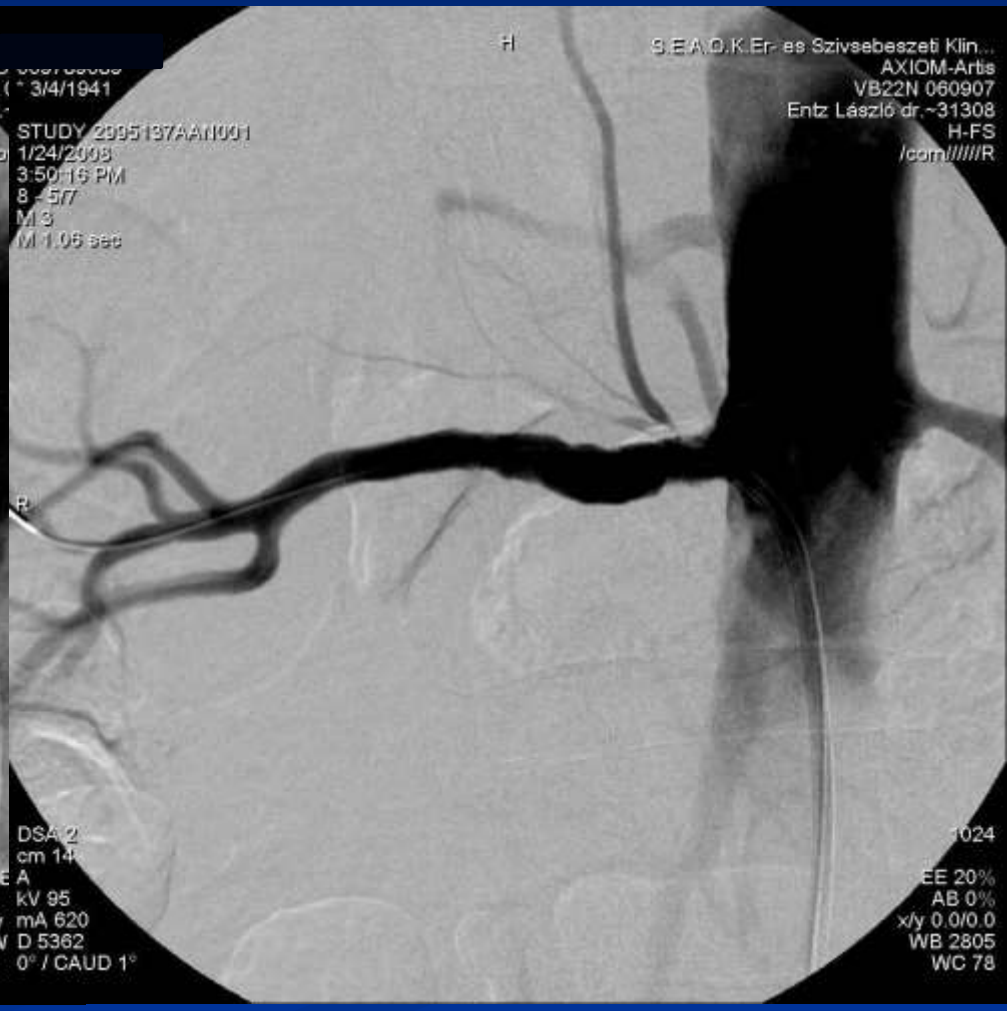

Stent

Self expandable

nitinol (nickel-titanium)

Balloon expandable

stainless steel

Superior vena cava occlusion

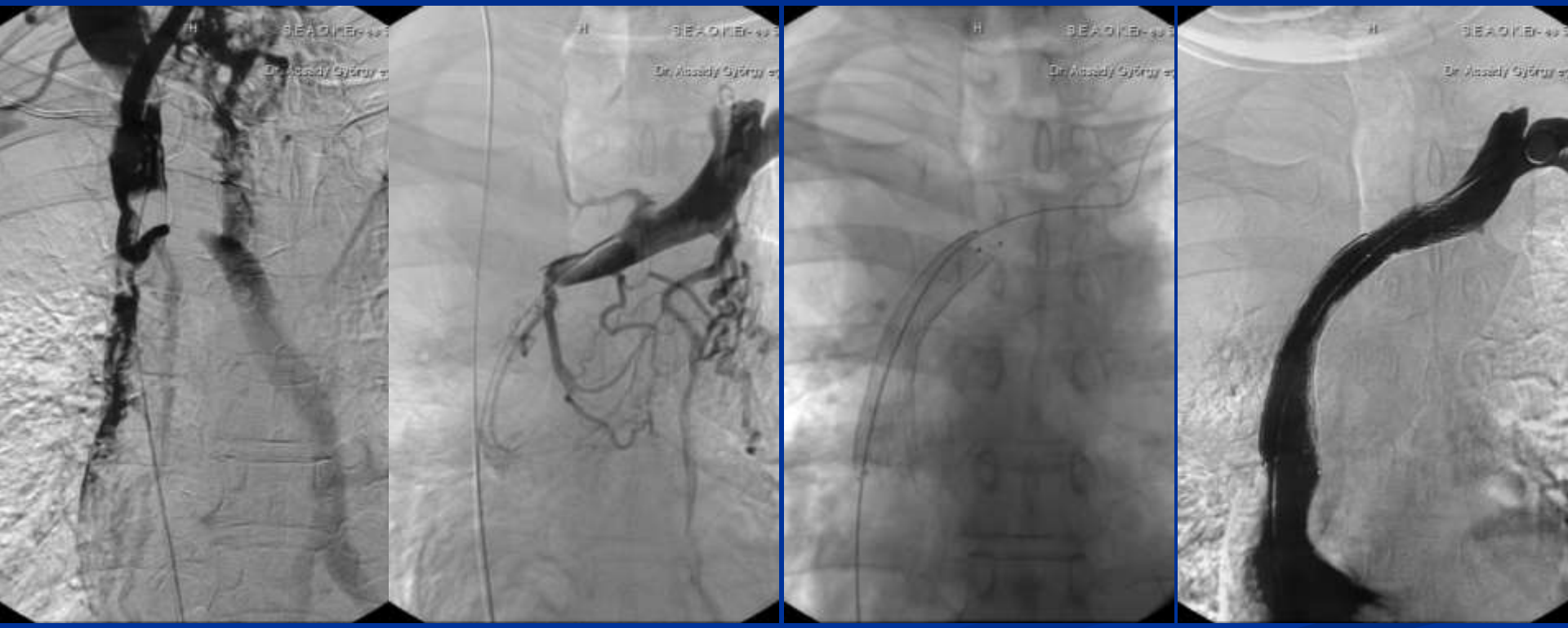

Thoracic Outlet Syndroma

Fractured subclavian vein stent

Stent grafts

- Aneurysm
- Vascular injury

Deceleration trauma of the aortic arch

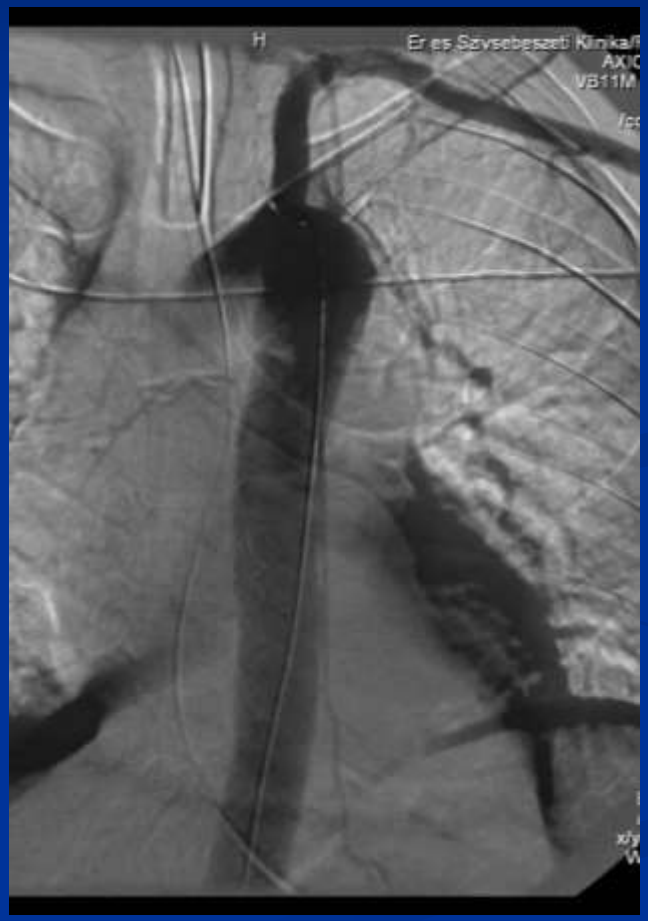

Aortic arch aneurysm

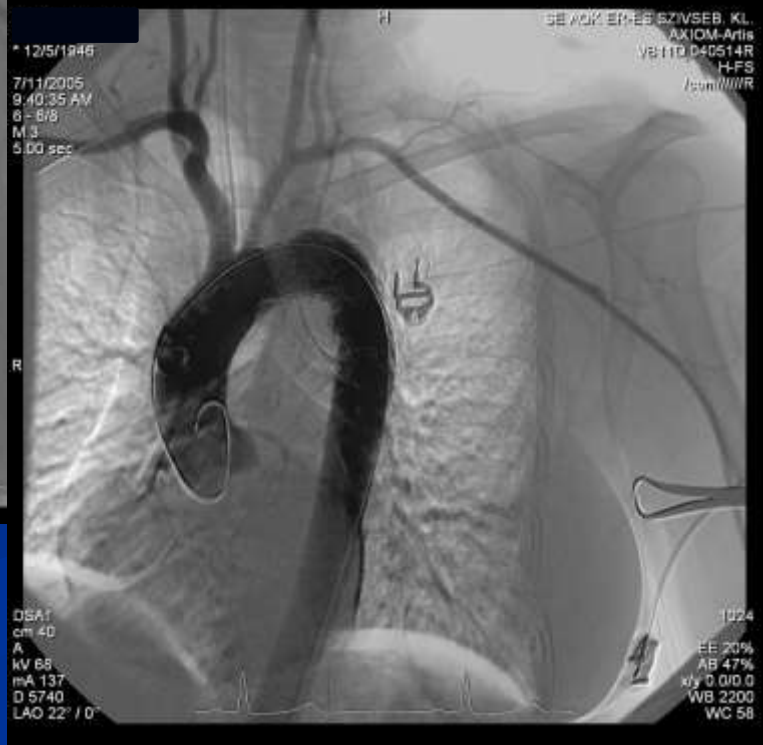

Supraaortic arteries

The knowledge of the collateral routes developing due to obstruction is very important

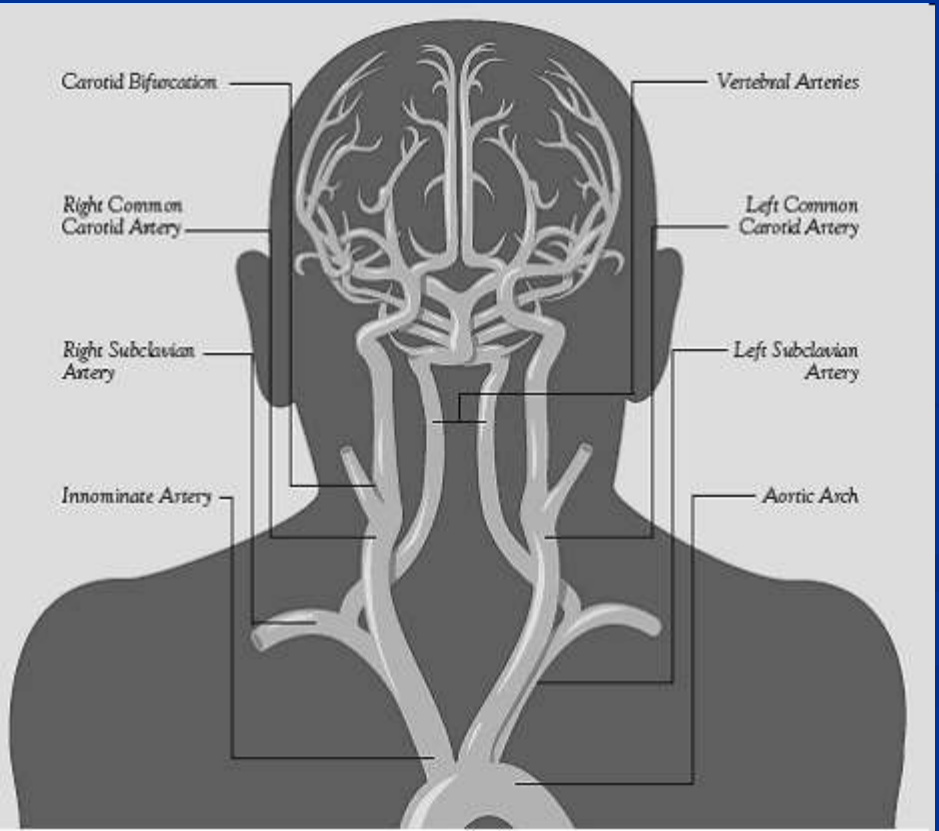

Subclavian steal syndrome

Atypical steal and left subclavian recanalization

Variation in branching of the aortic arch

Pharyngeal arch arteries

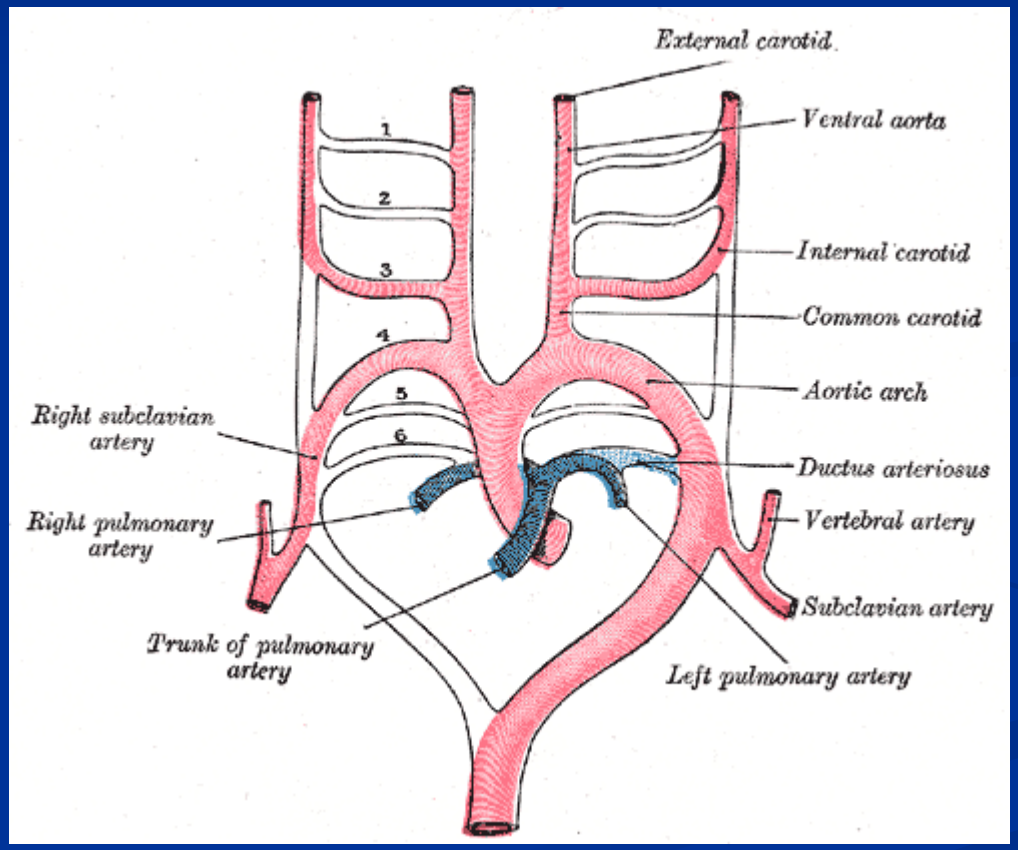

a. lusoria, left sublavian stenting

MRA exam

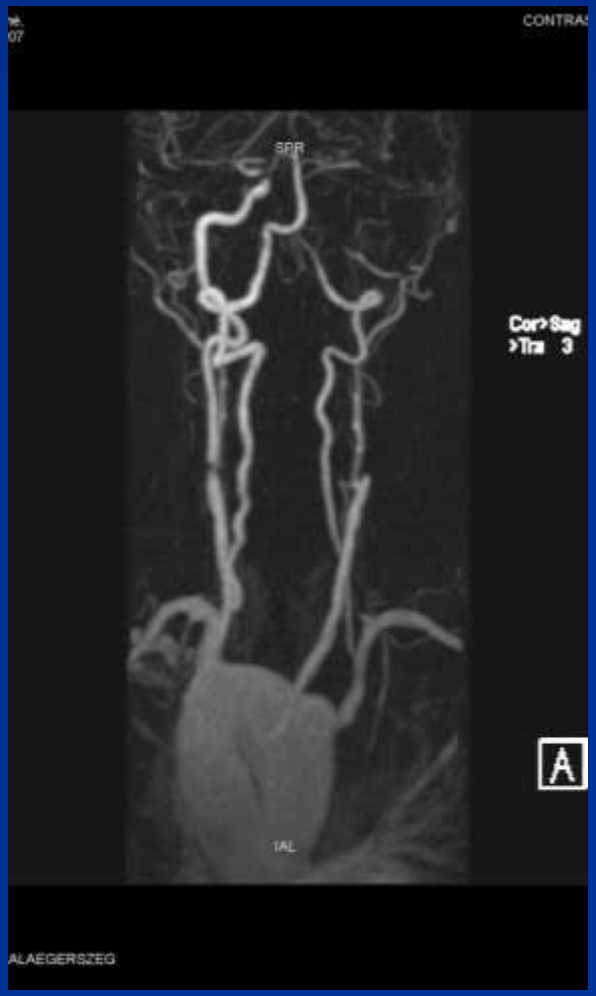
CONTRA
SPR
Cor>Sag
>Tra 3
A
IAL
ALAEGERSZEG

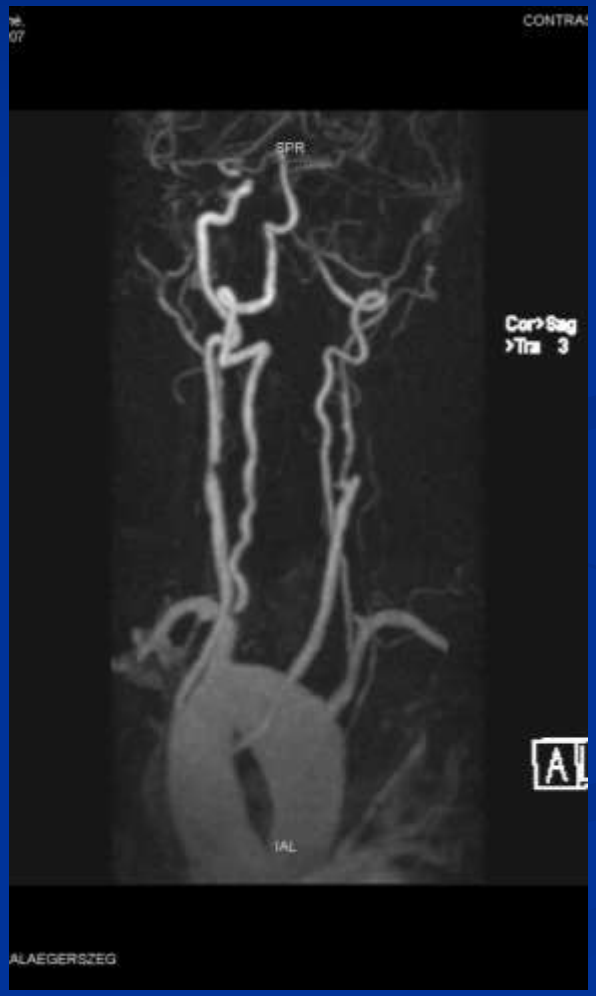
CONTRA
SPR
Cor>Sag
>Tra 3
A
IAL
ALAEGERSZEG

CONTRA
SPR
Cor>Sag
>Tra 2
A
IAL
ALAEGERSZEG

Right internal carotid stenting

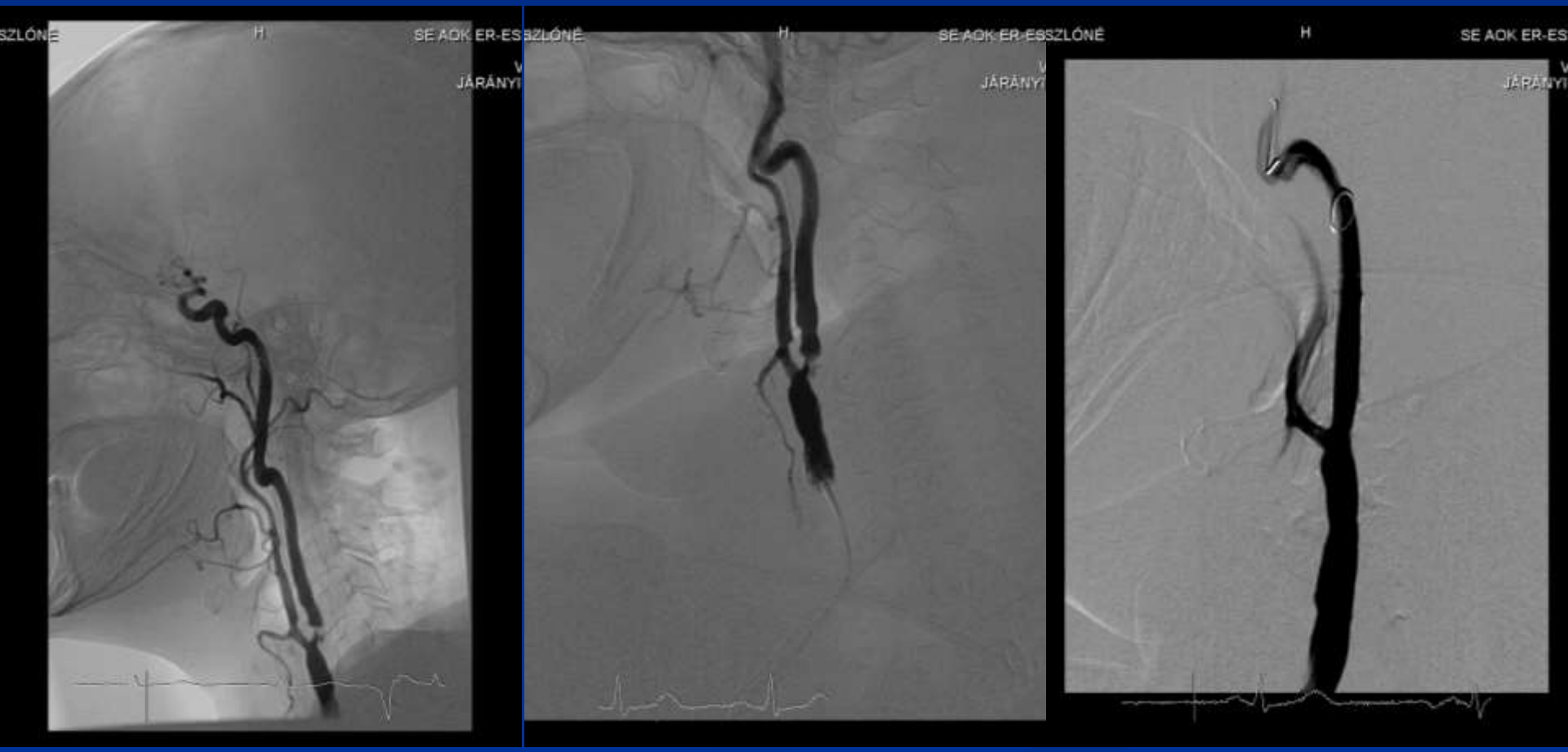

Takayasu sy?

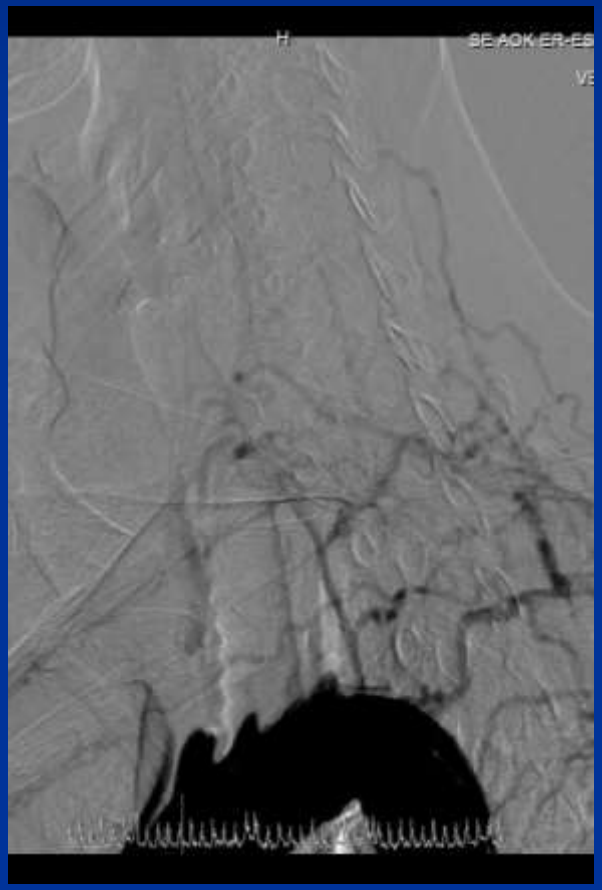

Abdominal collaterals

(Middle aortic syndrome)

Pancreaticoduodenal arcade

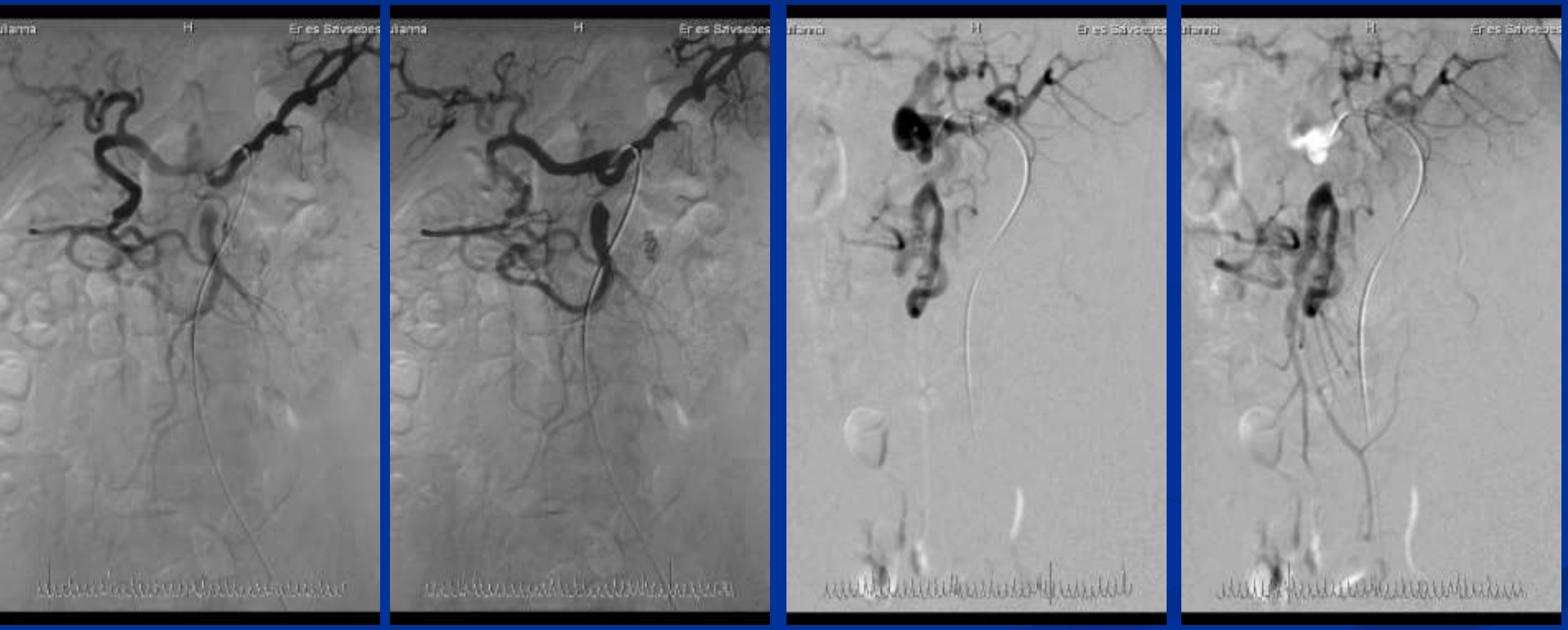

Aortic dissection

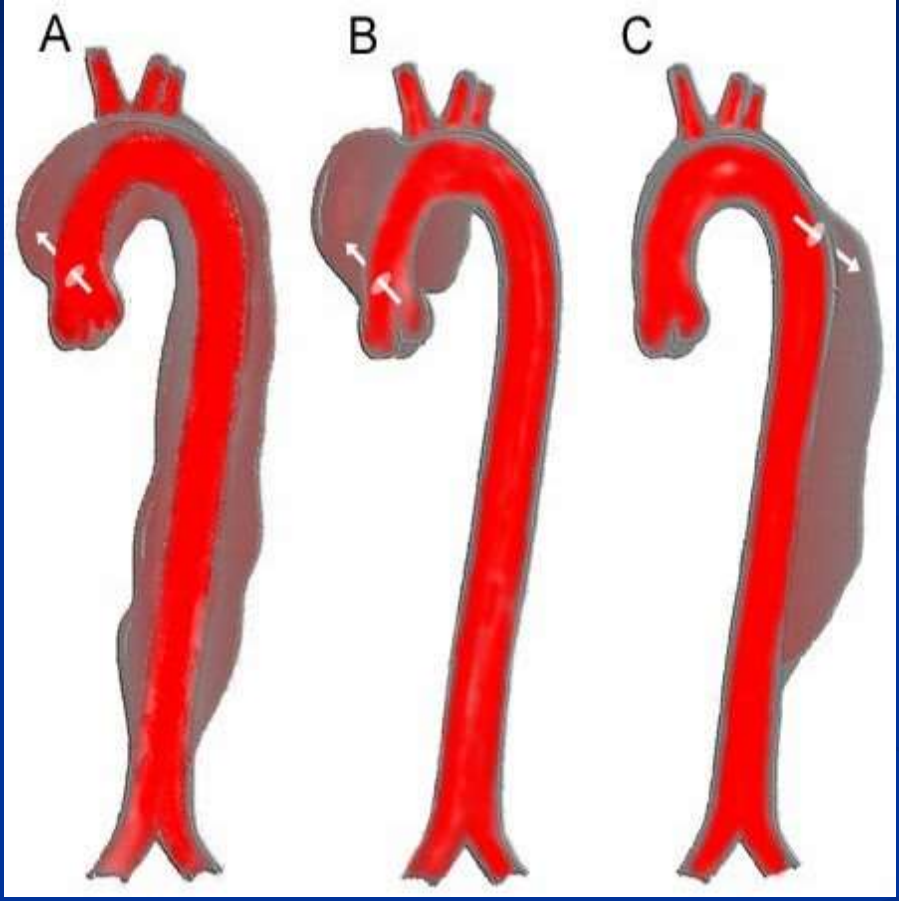

DeBakey I DeBakey II DeBakey III

Stanford A (Proximal)

Stanford B (Distal)

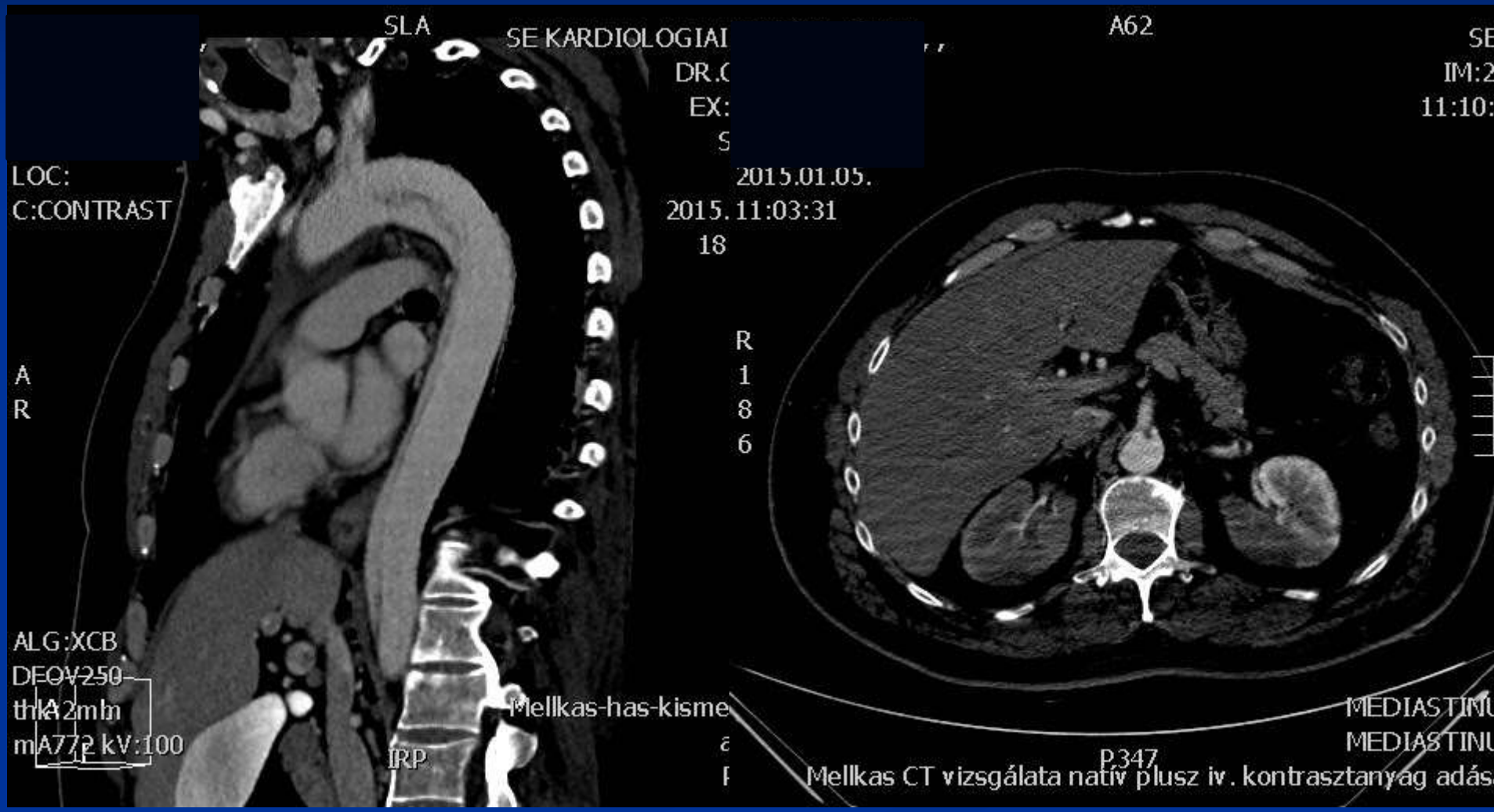
SLA
SE KARDIOLOGIAI
DR.(
EX:
S
LOC:
C:CONTRAST
2015.01.05.
2015. 11:03:31
18
A
R
ALG:XCB
DEOV250
thk2mm
mA772 kV:100
IRP
Mellkas-has-kisme
A62
SE
IM:2
11:10:
R
1
8
6
MEDIASTINU
MEDIASTINU
P347
Mellkas CT vizsgálata natív plusz iv. kontrasztanyag adás

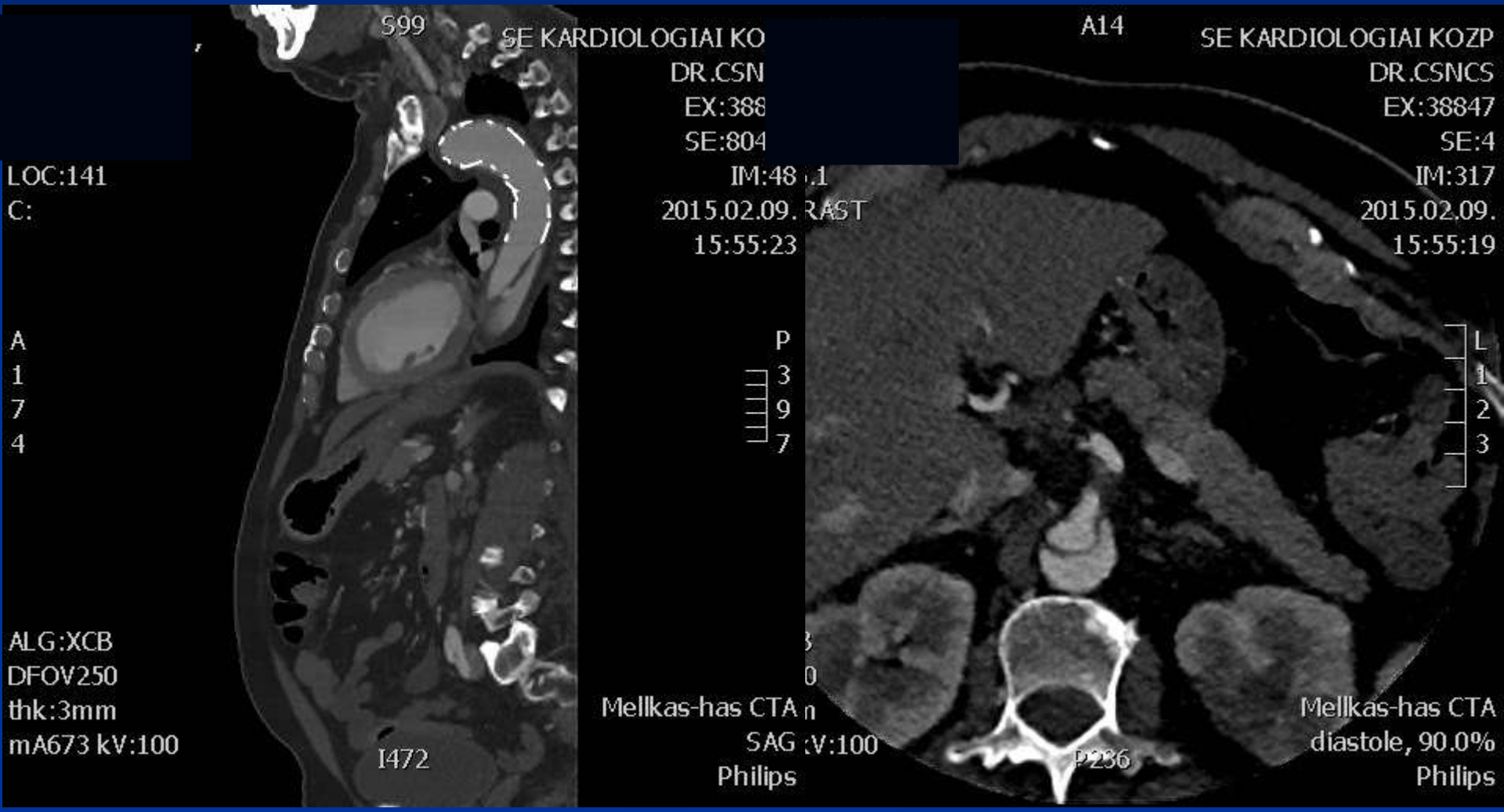
S99
SE KARDIOLOGIAI KO
DR.CSN
EX:388
SE:804
IM:48
2015.02.09.
15:55:23
LOC:141
C:
A
1
7
4
P
3
9
7
ALG:XCB
DFOV250
thk:3mm
mA673 kV:100
I472
Mellkas-has CTA
SAG
Philips
A14
SE KARDIOLOGIAI KOZP
DR.CSNCS
EX:38847
SE:4
IM:317
2015.02.09.
15:55:19
L
1
2
3
P236
Mellkas-has CTA
diastole, 90.0%
Philips

Subintimal angioplasty

Subintimal angioplasty

Femoral artery

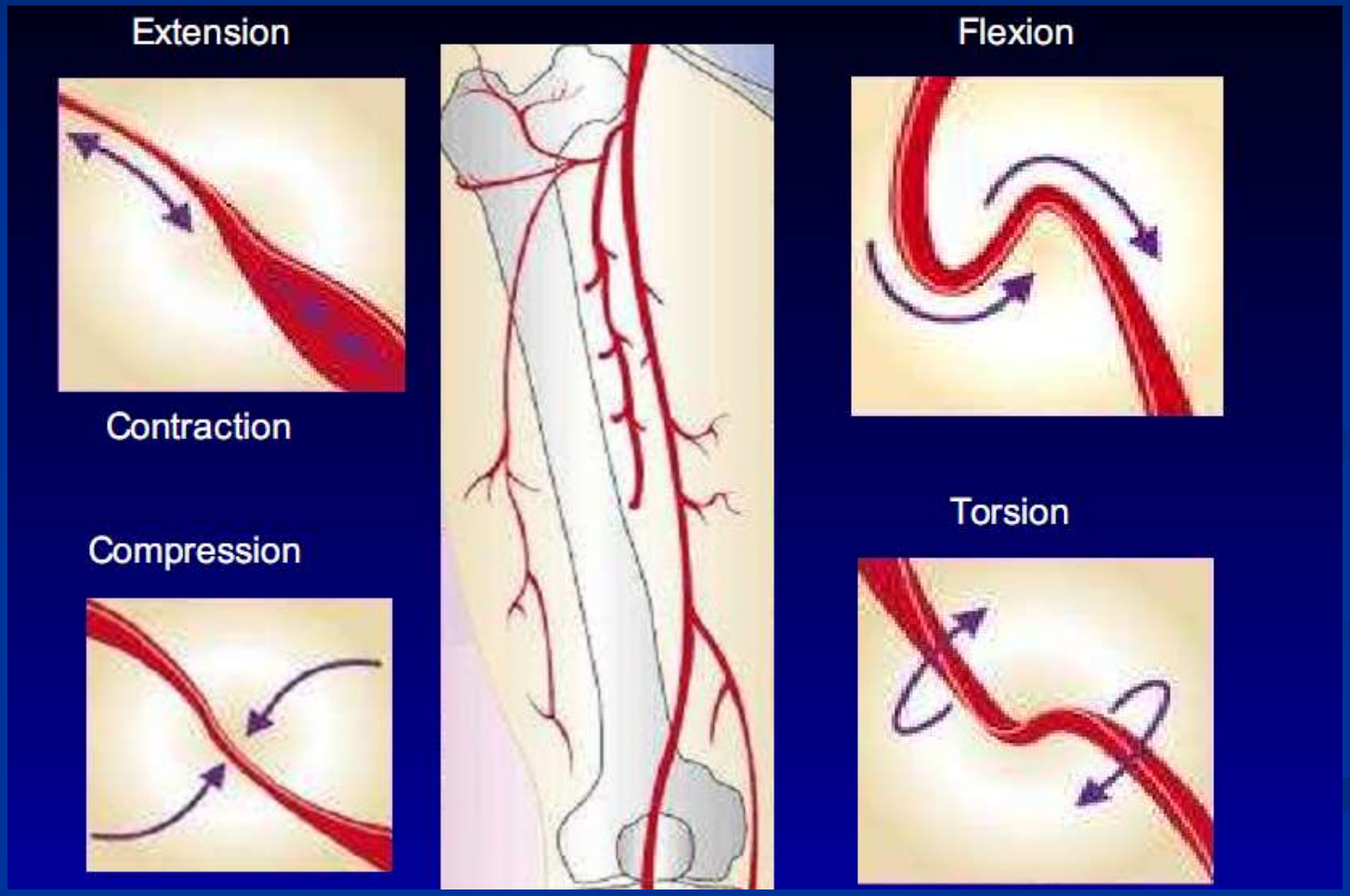

Popliteal stenting

H
R

Lessons

Knowledge of the anatomy of the punture sites is mandatory

- Bony landmarks (palpation may not be enough)
- Possible complications

During catheterization knowledge of vascular anatomy and collateral pathways is required for the accurate diagnosis and for the therapeutic plan

Lessons

- The radiologist must be familiar with the complications and their treatment
- Embolization requires thorough knowledge of the blood supply and collateral circulation of the target area
- Effective analitical thinking

Thank you