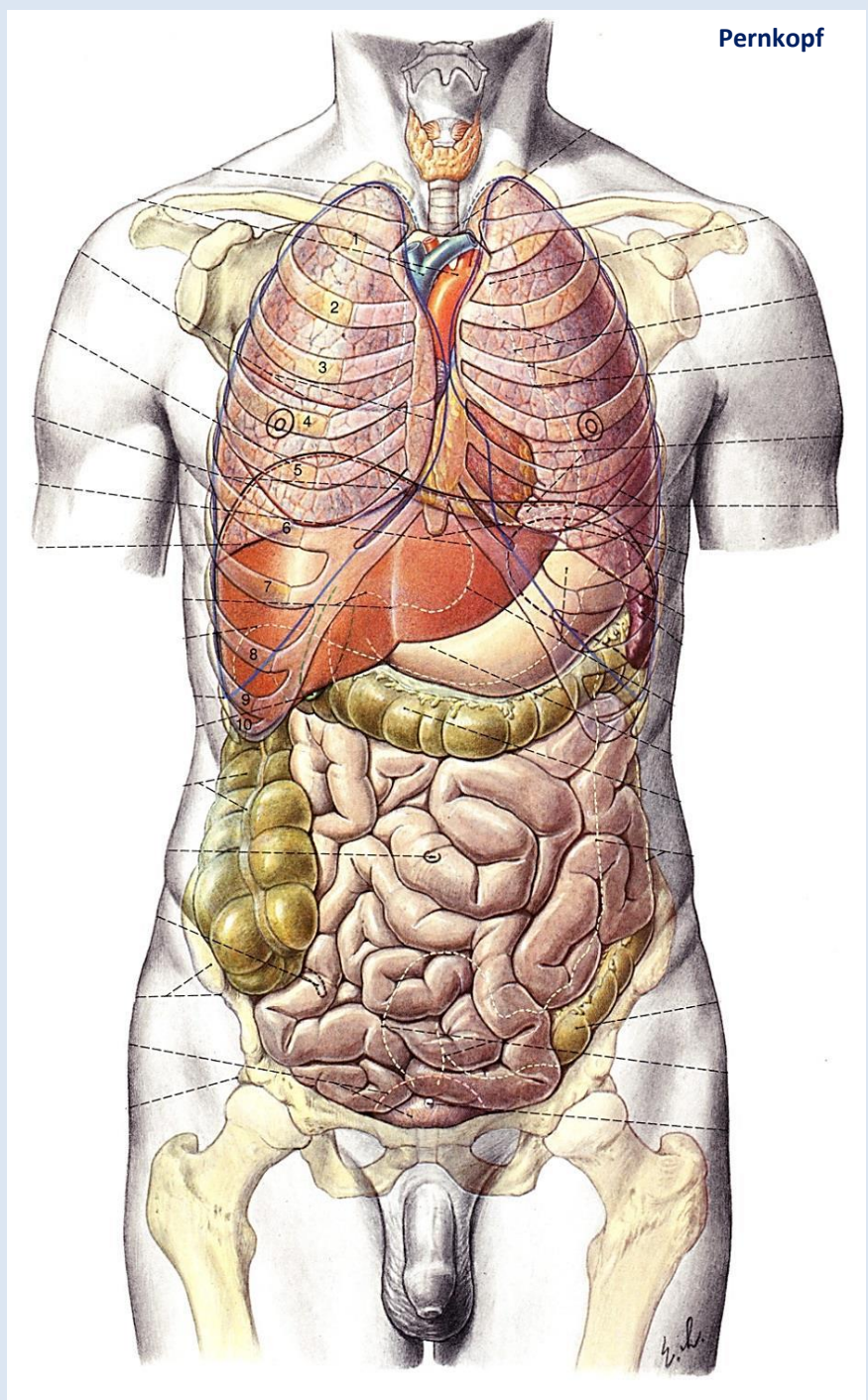
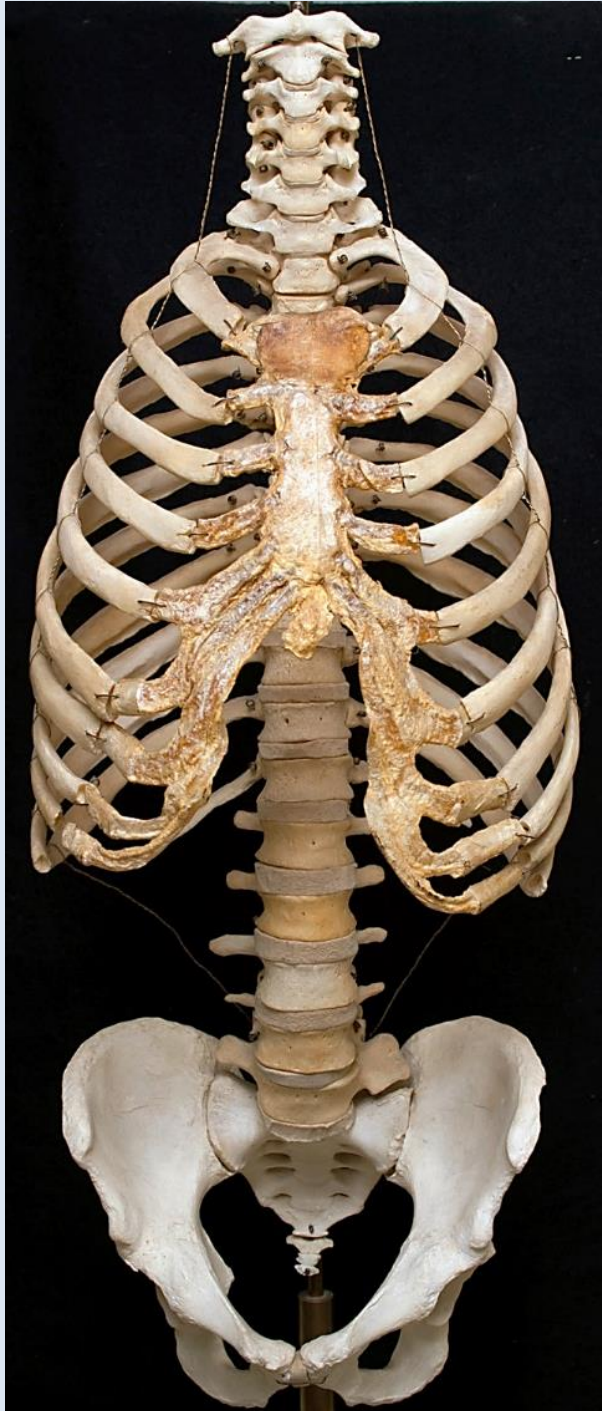
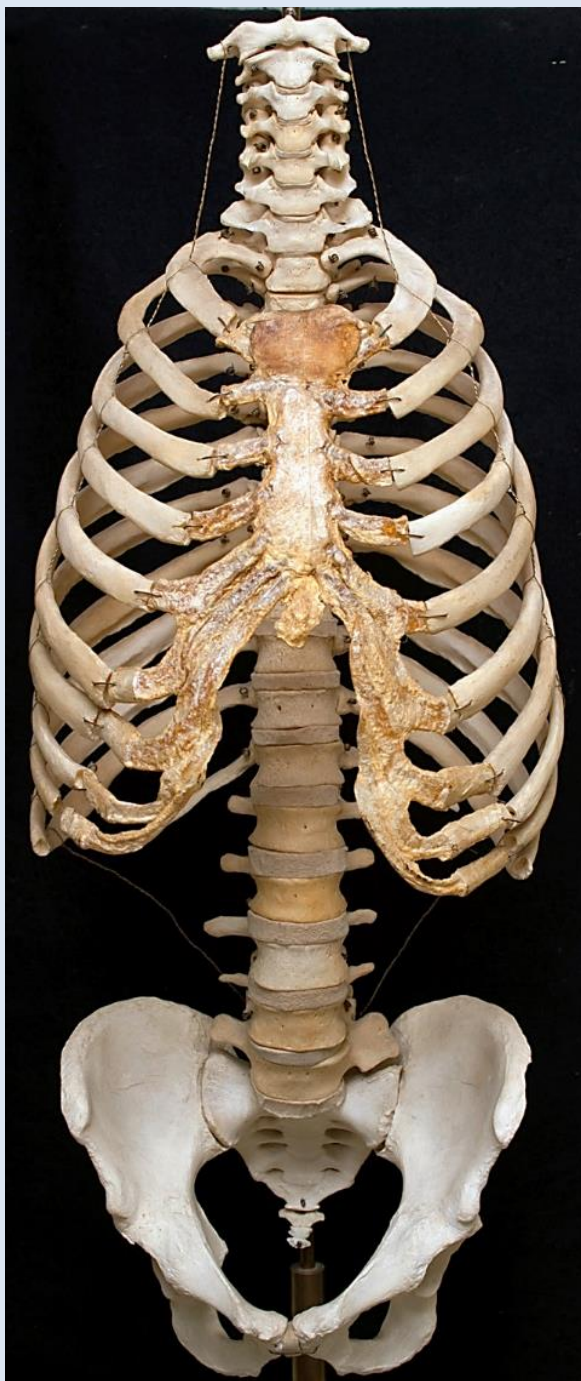


***Topographische und
Querschnittsanatomie des
Thorax bzw. der Organe der
Brusthöhle. Pleura-
und Perikardpunktion.***

**Ph.D Dr. Dávid Lendvai
2019**





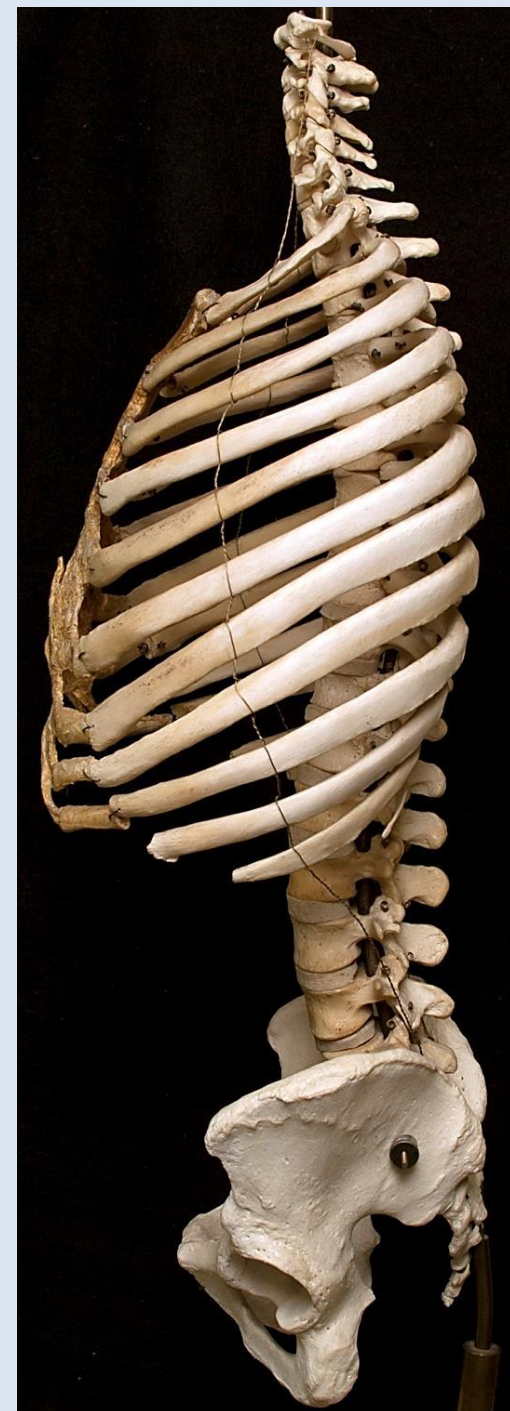Die Aufbauelemente des Brustkorbes

Knocherne Brustkorb:

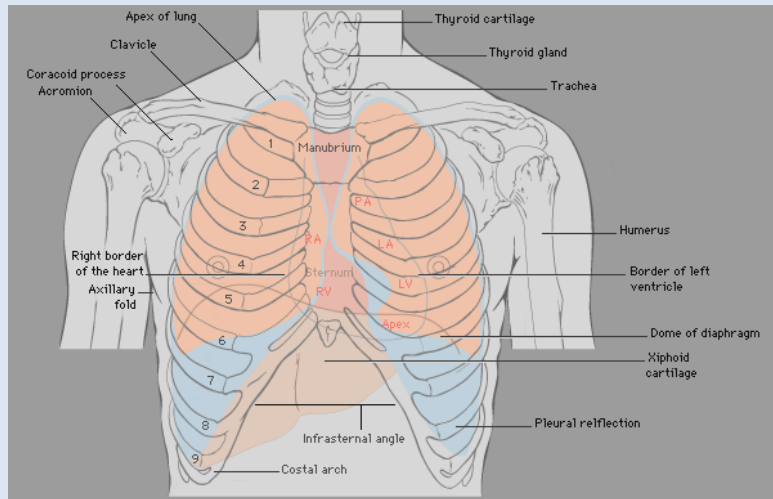
- Sternum
- 12 Paar Rippen
- Wirbelsäule (12 Brustwirbel)

Apertura thoracis superior

Apertura thoracis inferior



DER THORAX



HÖHLE:

- cavum thoracis

-- *apertura thoracis superior*

(*projektion: Th2*)

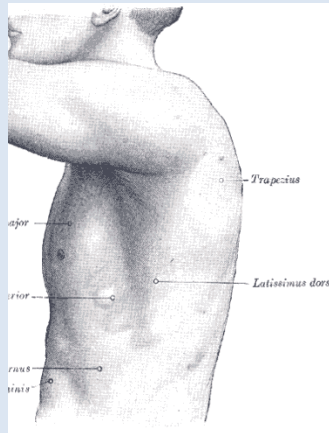
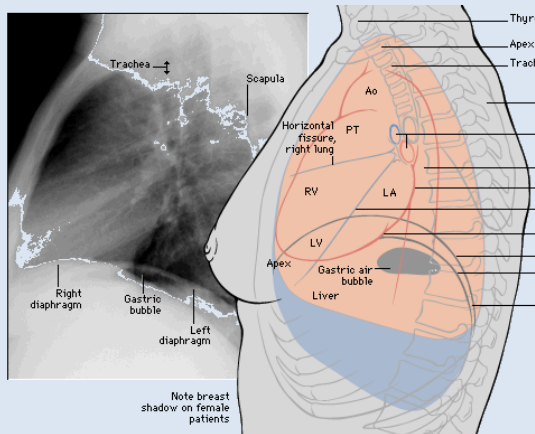
Grenzen: Th1 Wirbel, 1. Rippe, sternum. Seitlich die Pleura, oben „geöffnet“.

-- *apertura thoracis inferior*

(*Projektion: Th10*)

Grenzen: Th12 Wirbel, 11-12.

Rippen, arcus costalis und sternum (processus xiphoideus). Unten geschlossen (diaphragma).

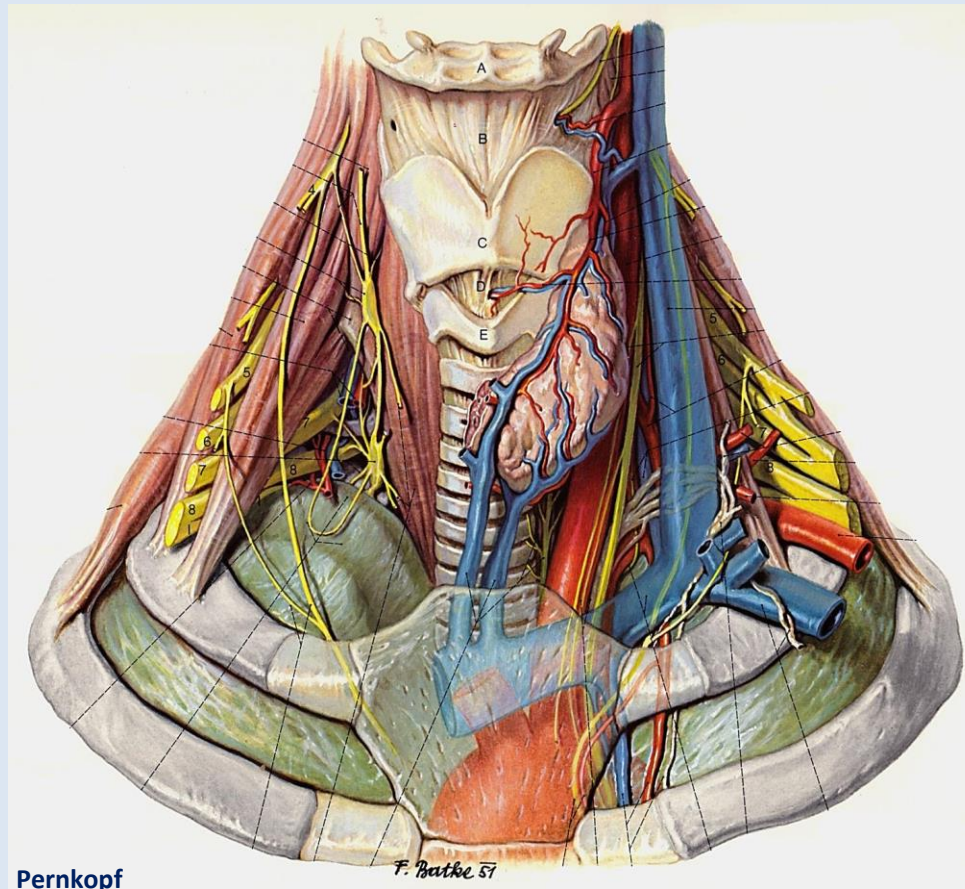


Apertura thoracis superior

1. Rückenwirbel, 1. dem ersten Paar von Rippen und zwischen Manubrium Sterni

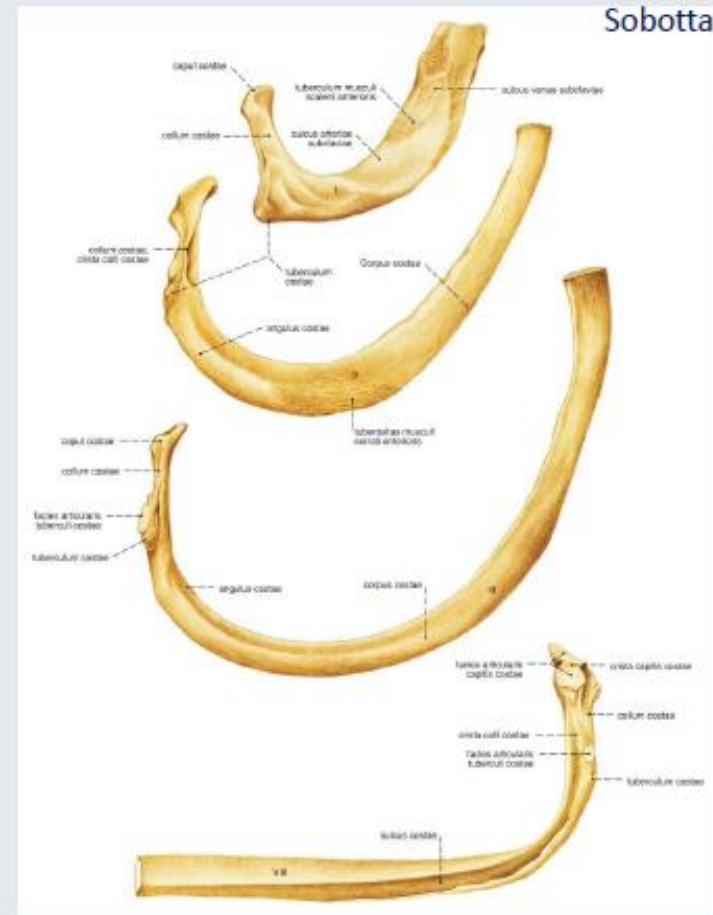
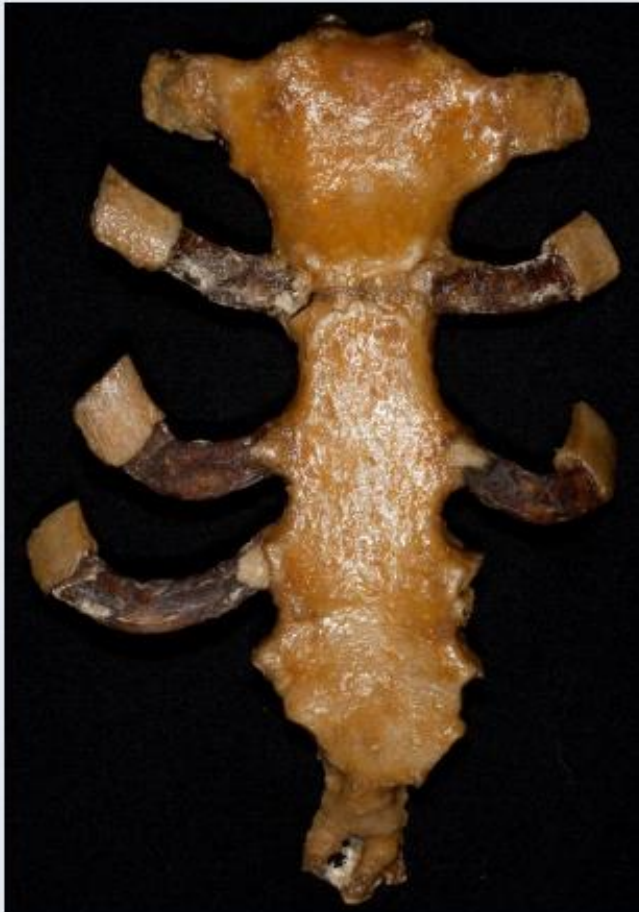Die Lungenspitzen über erweitern

Wichtige Gefäße und Nerven daraufhin



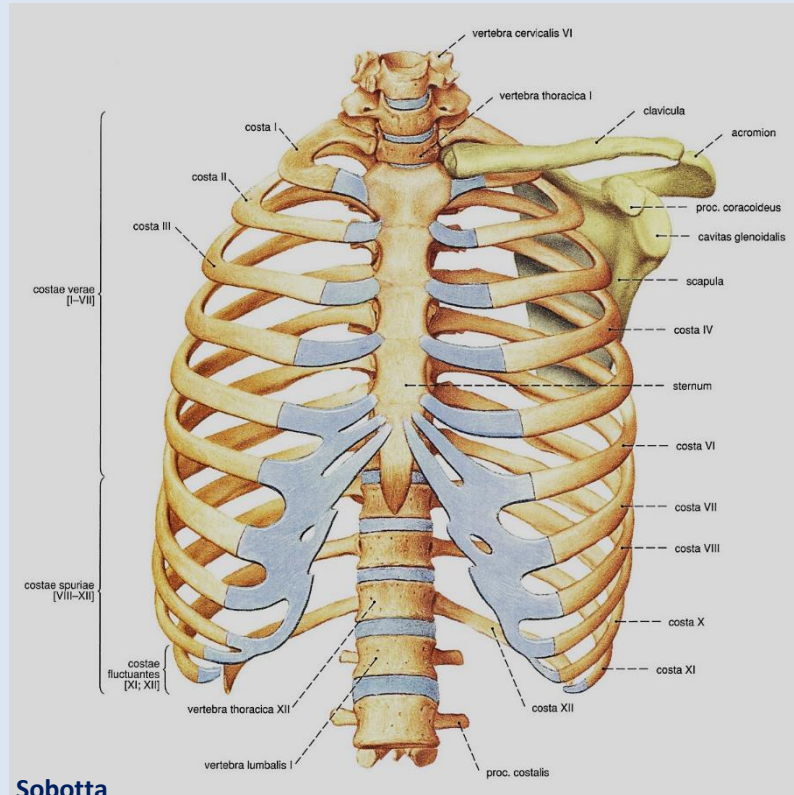
Pernkopf

In der Klinik:
zB. obere Brustkorb Eingangs
Syndromen (Thoracic outlet
syndrom - TOS)



Brustbein = Griff (Manubrium) + Körper (Corpus) + Schwertfortsatz (Proc. xiphoideus)

Costae (Rippen)

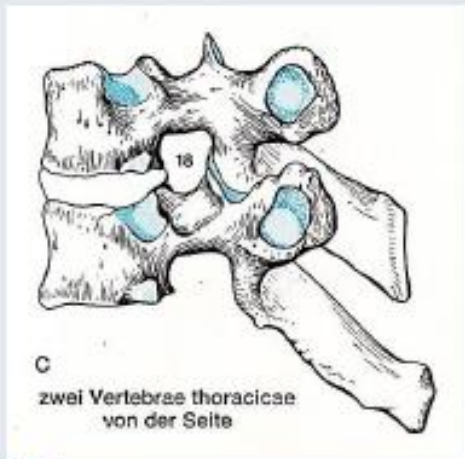
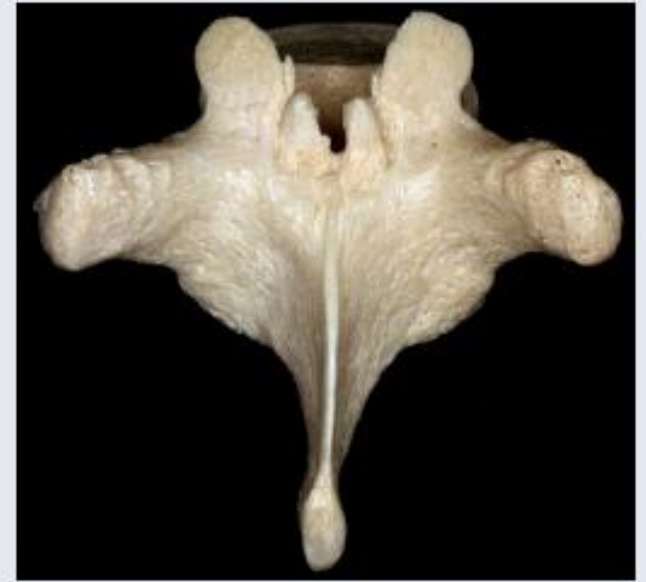
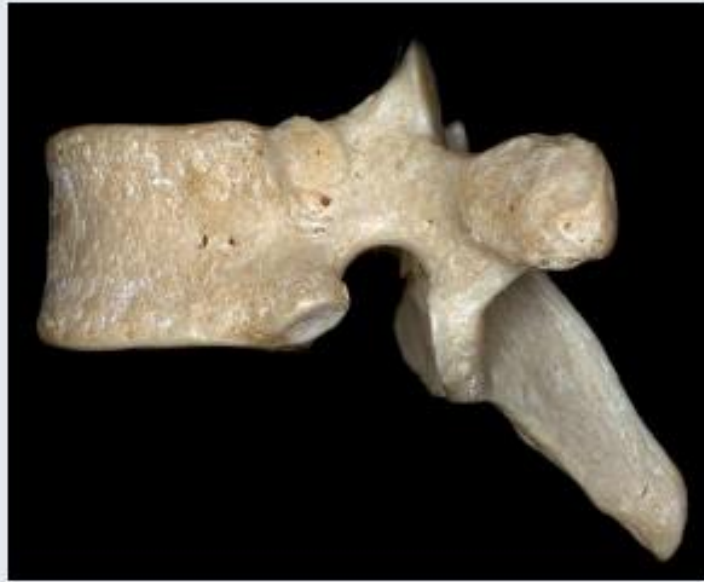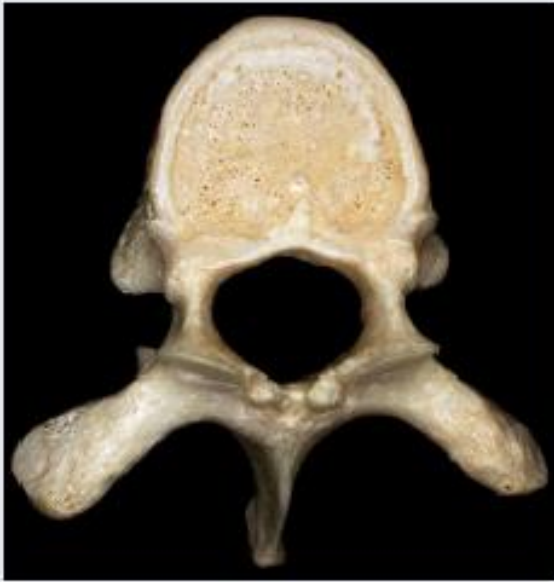Wahre Rippen (I – VII.):
setzen mit dem eigenen Knorpel einzeln
am Sternum an Costae verae

Falsche Rippen (VIII - XII.):
Costae spuriae
...nicht, wie die obigen entweder mit
gemeinsamen Knorpel (VIII – X.)

oder kein Ansatz am Sternum (XI., XII.):
Fliehende Rippen/ Fleischrippen
Costae fluitantes

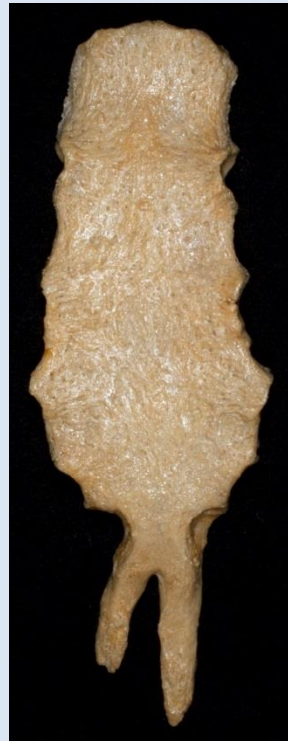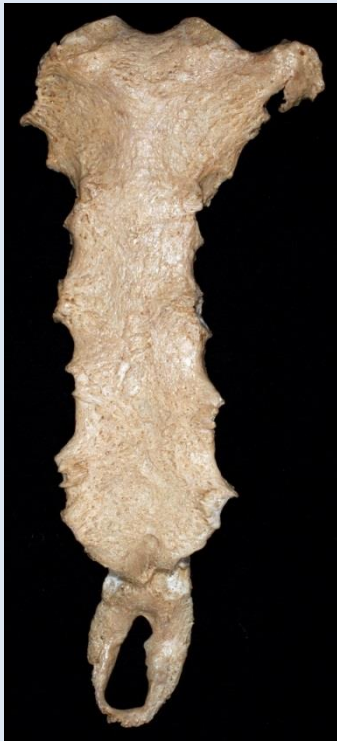Vertebrae thoracales (Brustwirbel)



- „Kartenherzförmiger“ Körper
- Rundes Wirbelloch
- Dornfortsätze immer mehr nach unten zeigend
- Gelenkflächen für die Rippenansätze
- Frontal orientierte Gelenkfortsätze

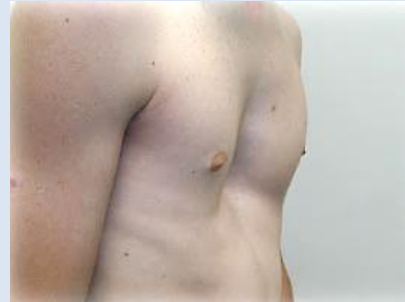

Varianten...



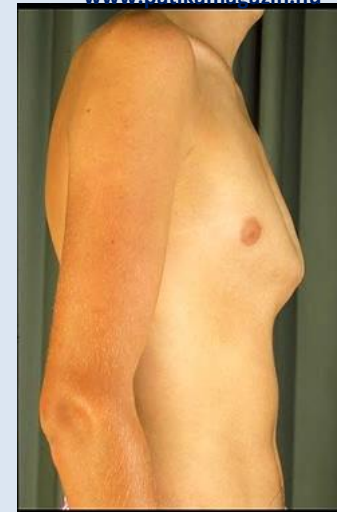Sternumpunkcion!!!

Pectus excavatum



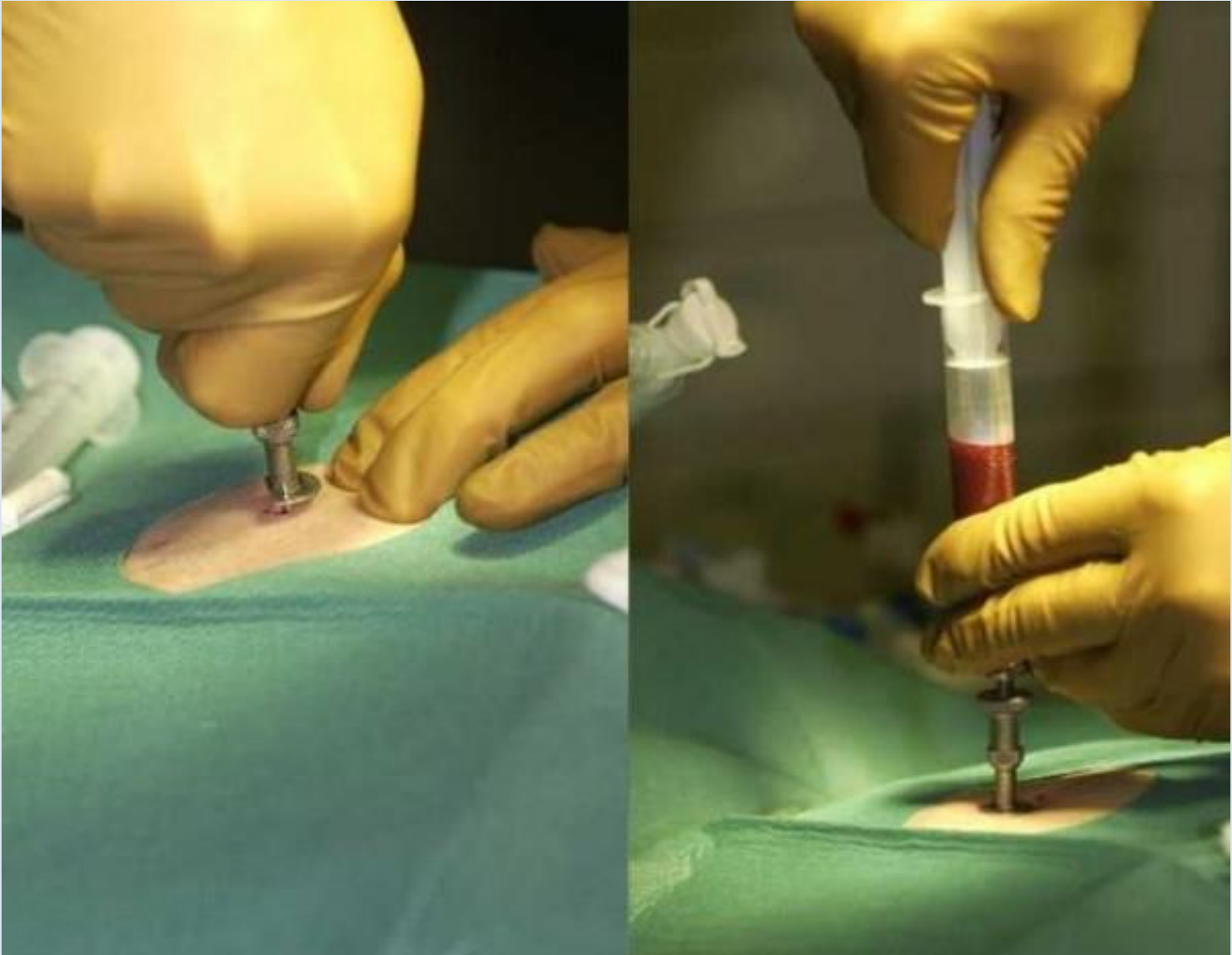
www.pectausexcavatum.atw.hu

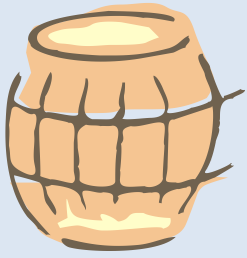
www.patikamagazin.hu



Pectus carinatum

Sternum punktion





2. Rippe

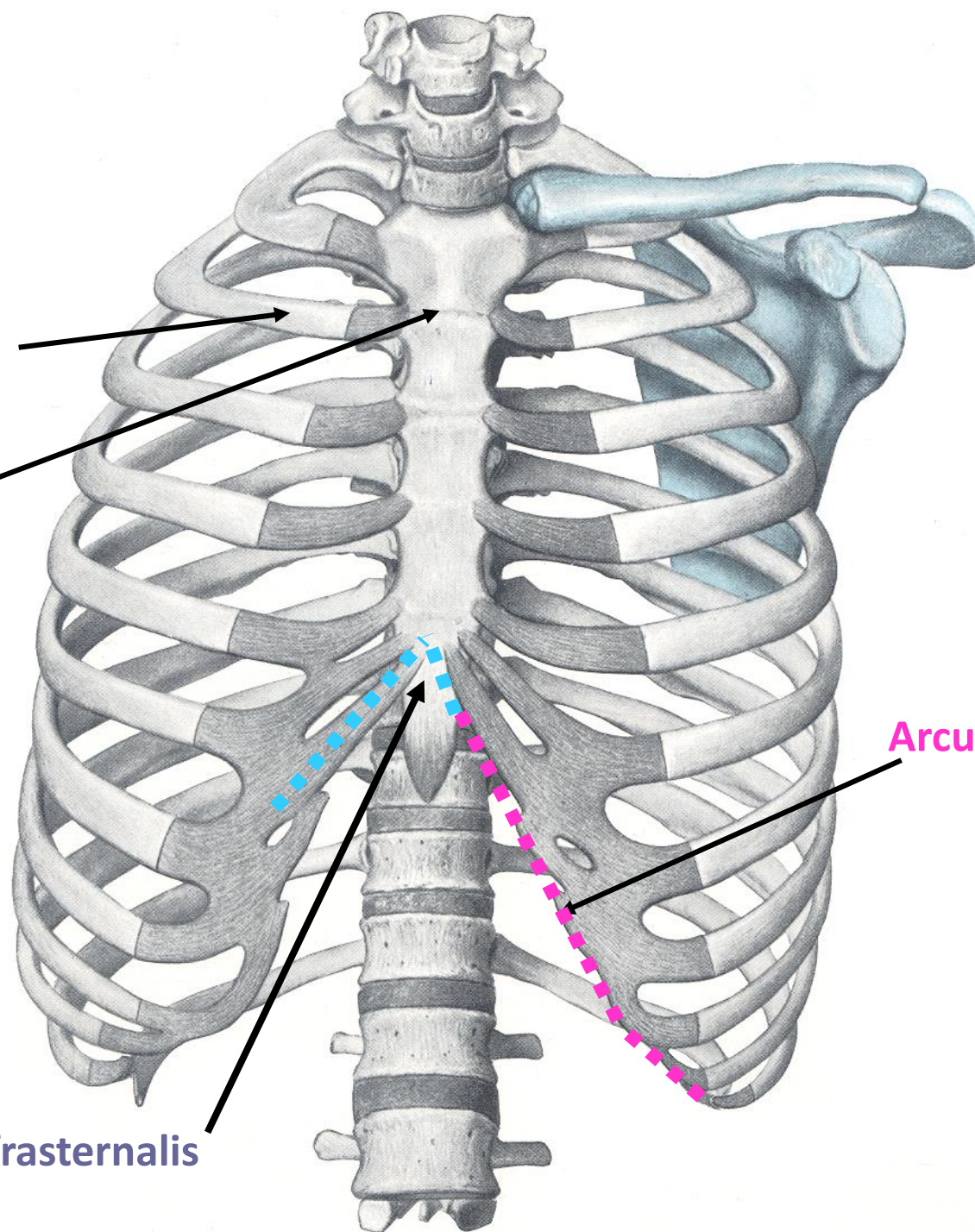
Angulus sterni

Untersuchungen:

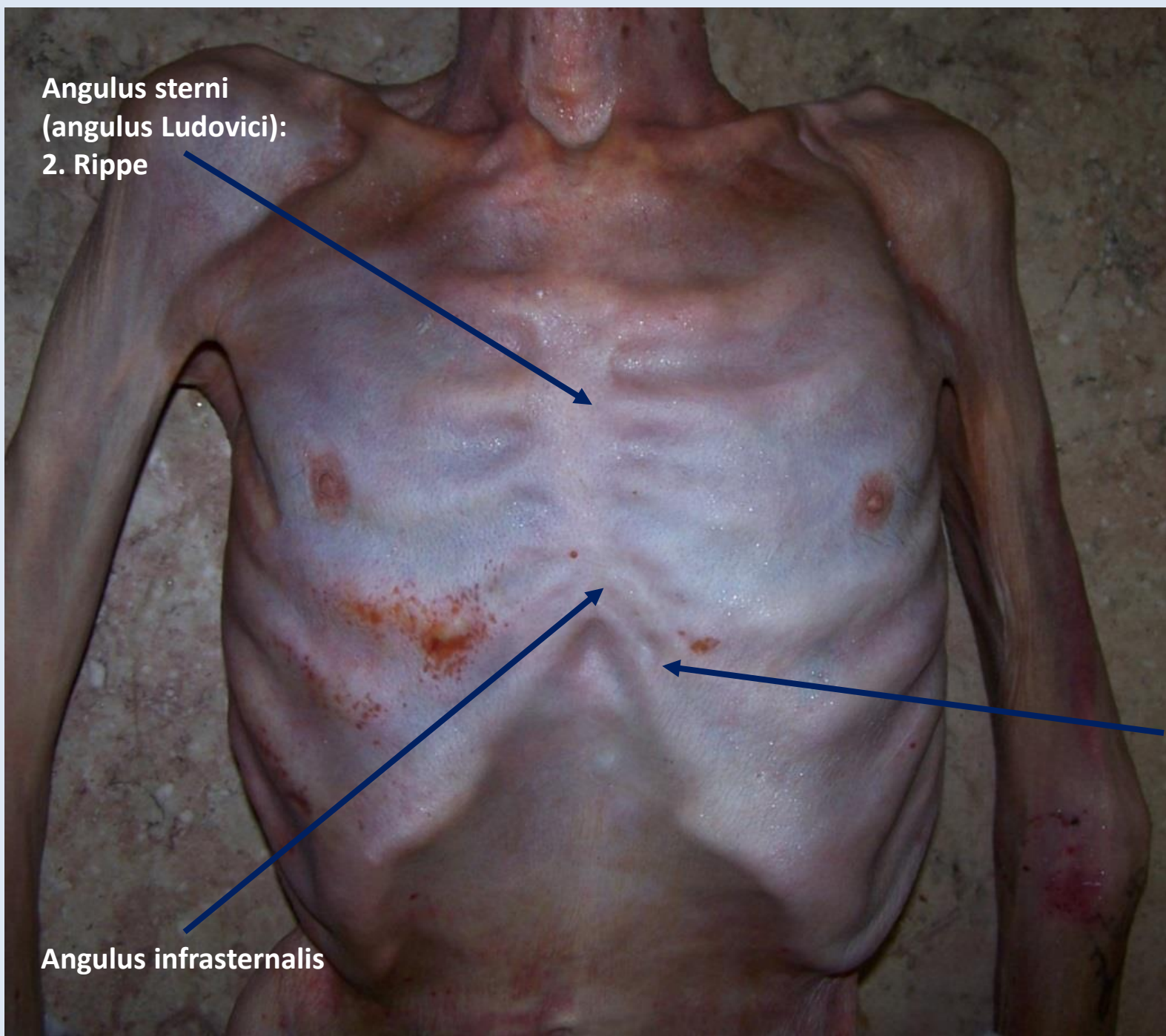
**auscultatio
percussio
palpatio**

Angulus infrasternalis

Arcus costae

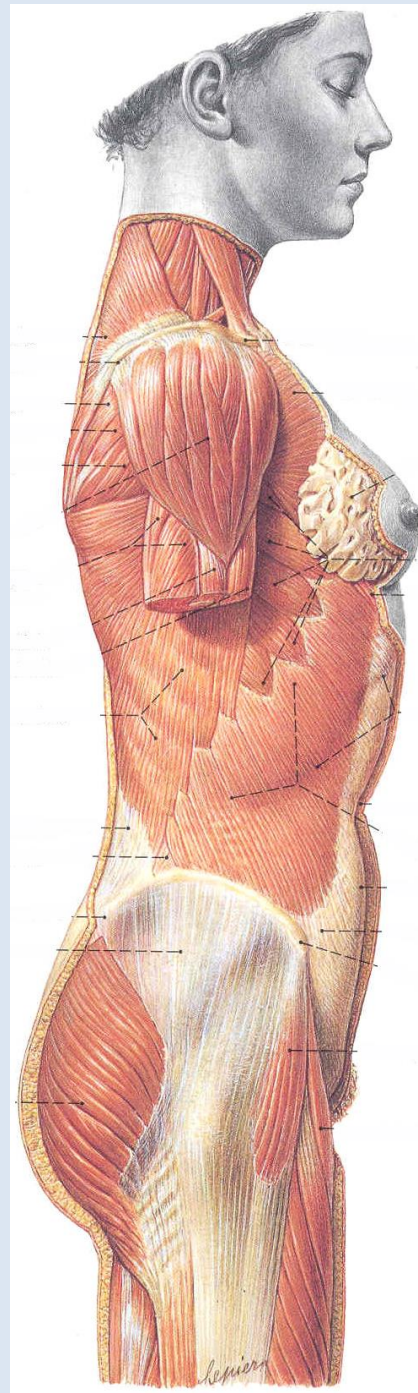
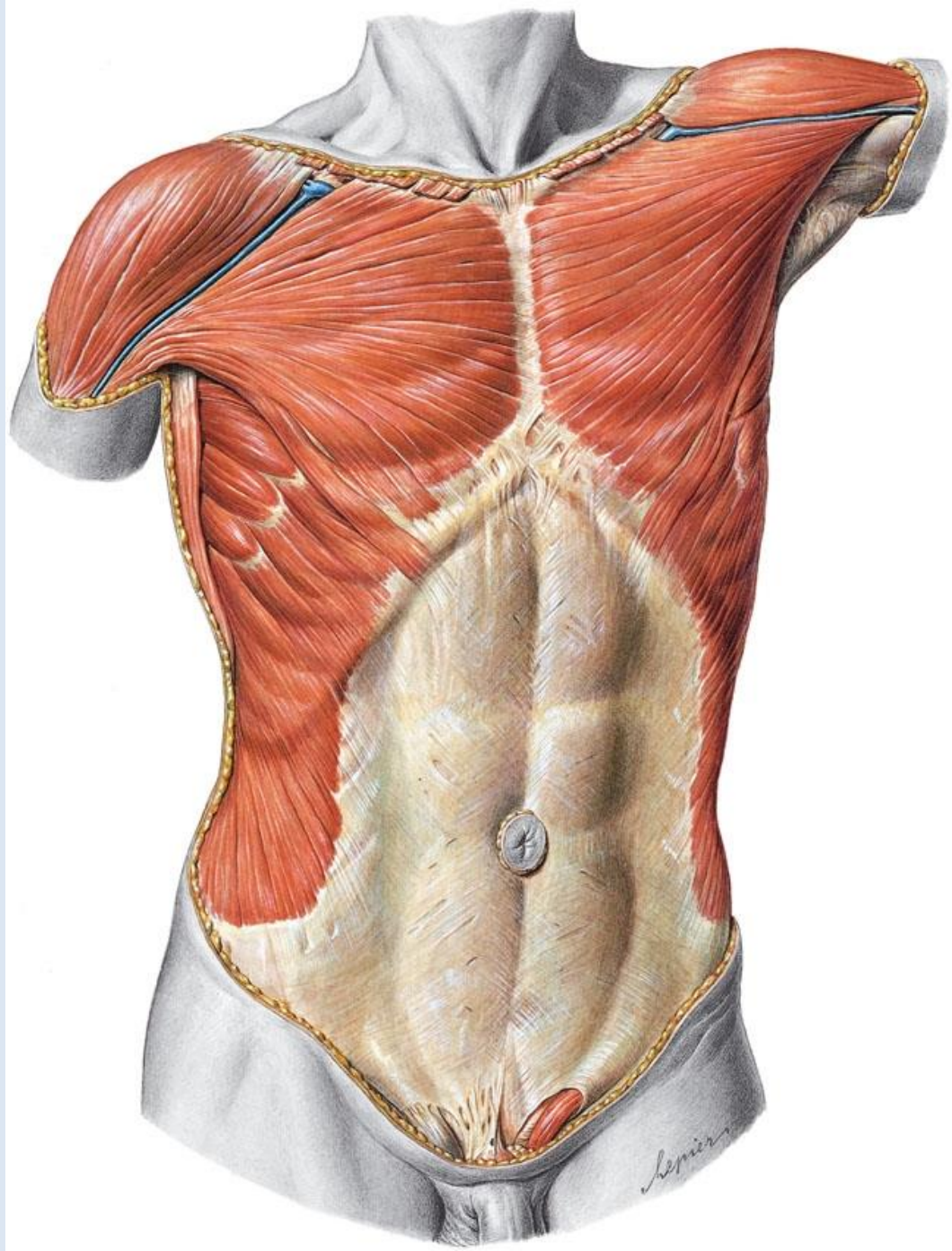


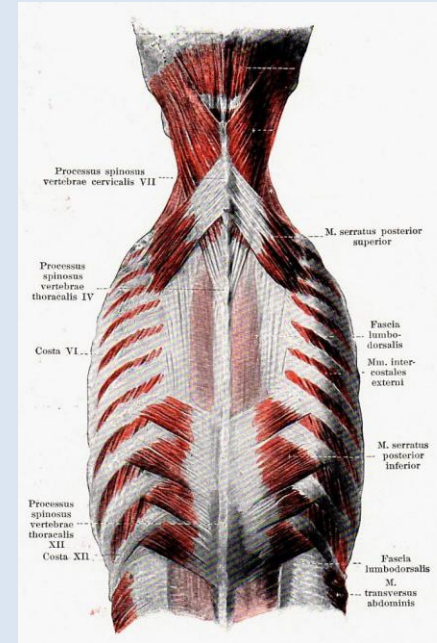
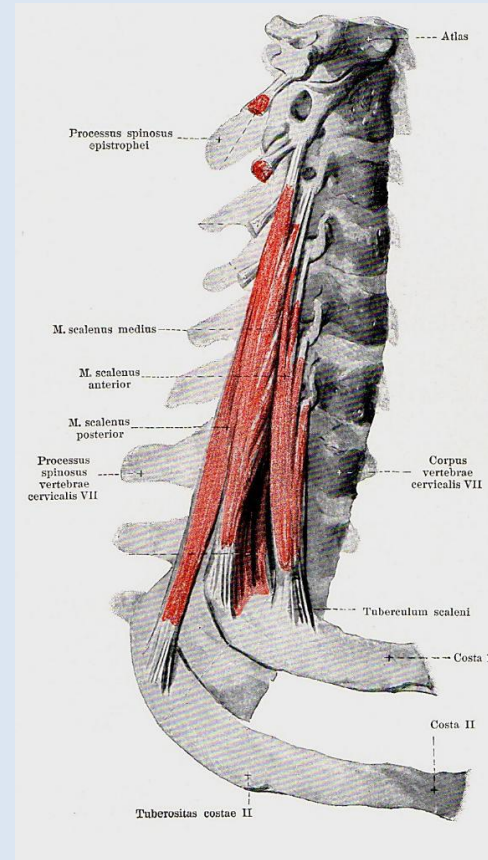
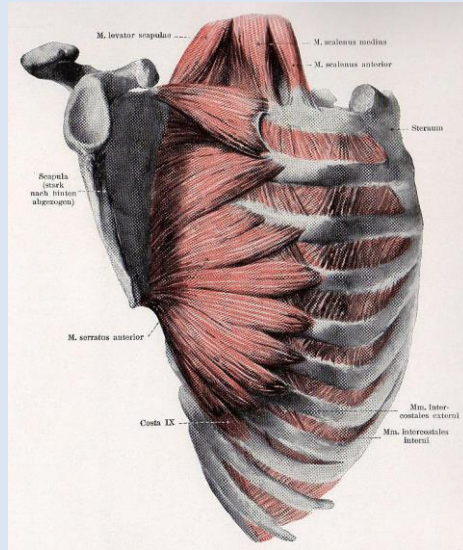
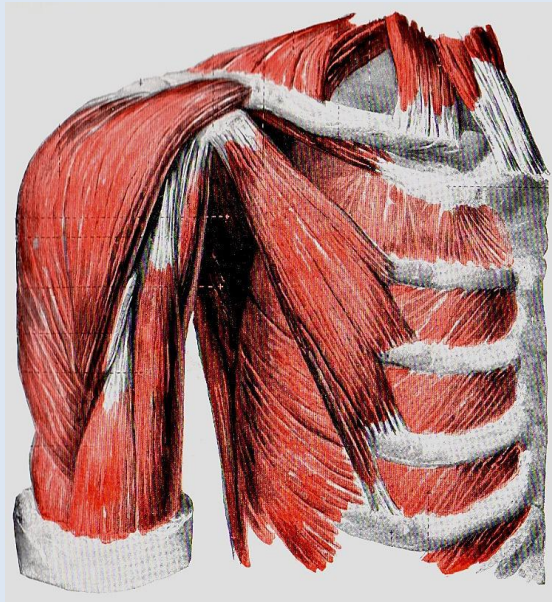
Angulus sterni
(angulus Ludovici):
2. Rippe



Arcus costalis

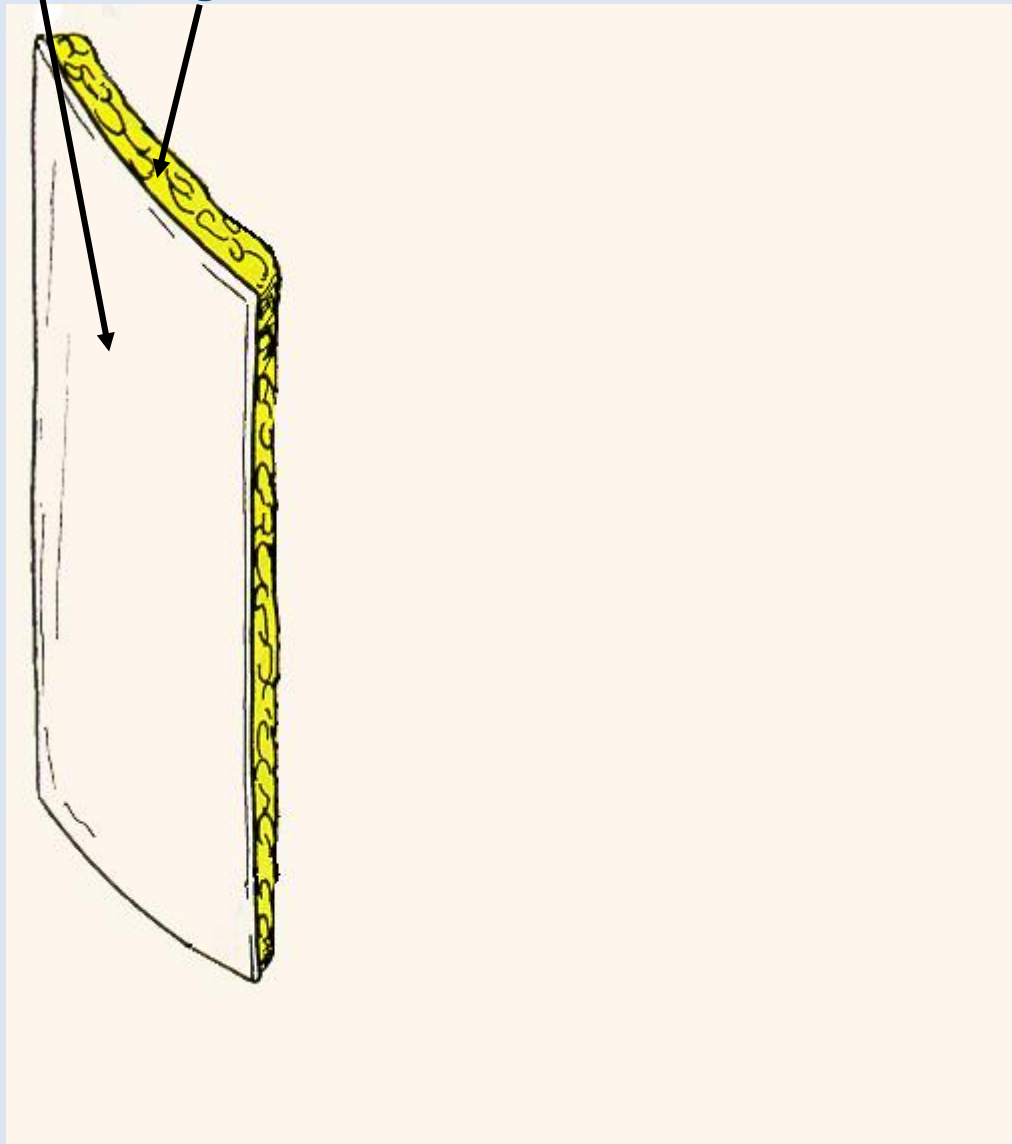
Angulus infrasternalis





BAUELEMENTE DER THORAKALWAND

Haut Bindegewebe

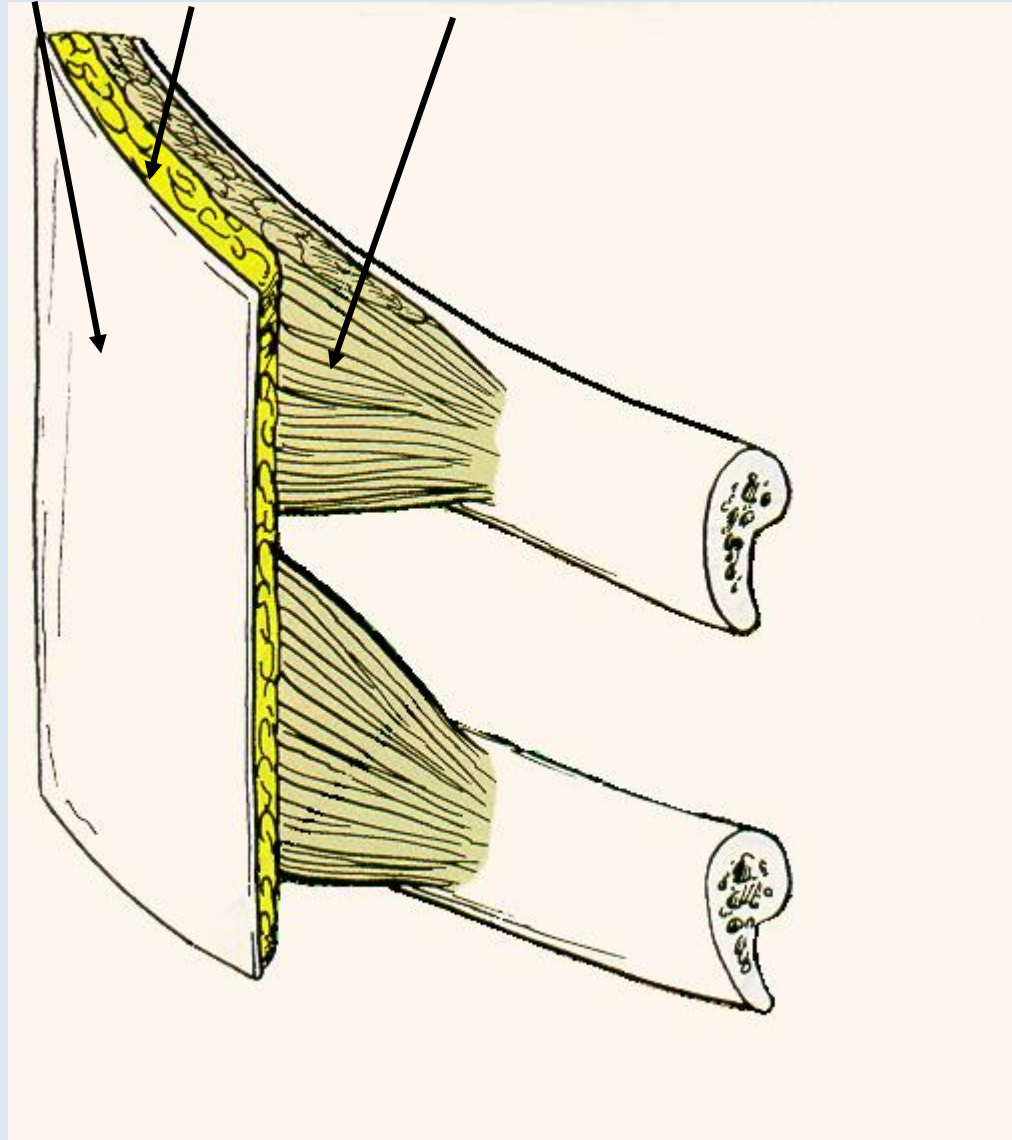


BAUELEMENTE DER THORAKALWAND

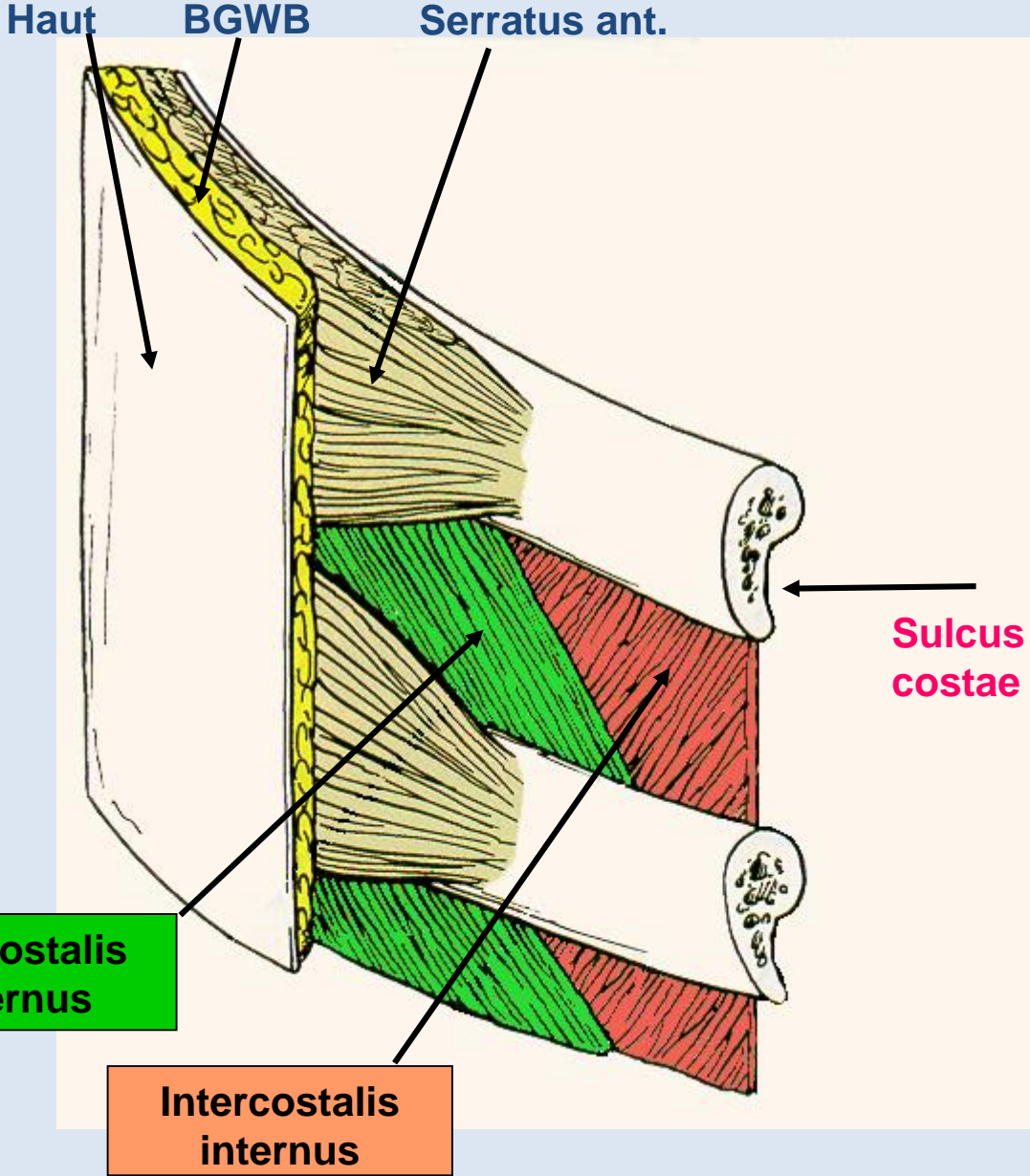
Haut

BGWB.

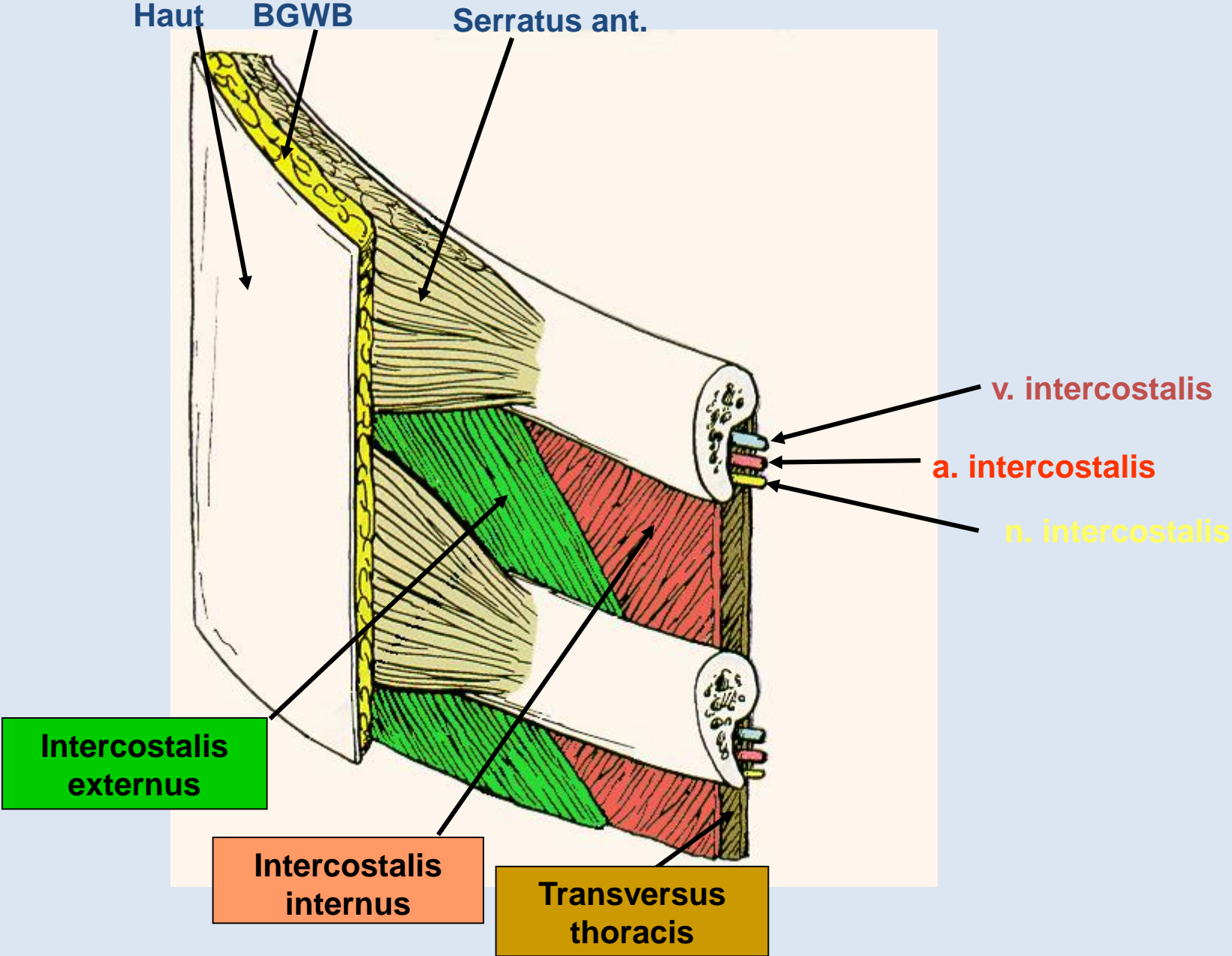
Serratus ant.



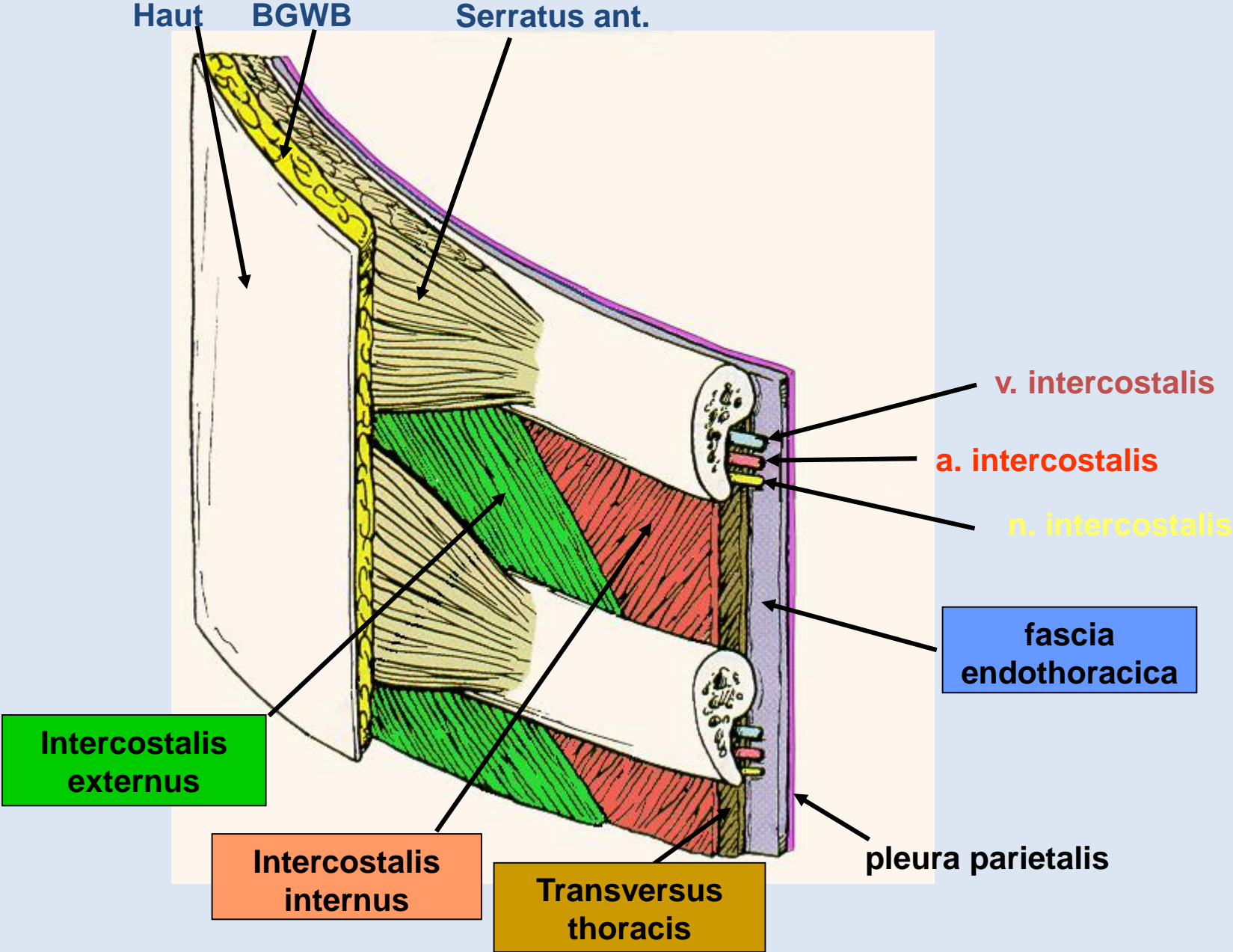
BAUELEMENTE DER THORAKALWAND



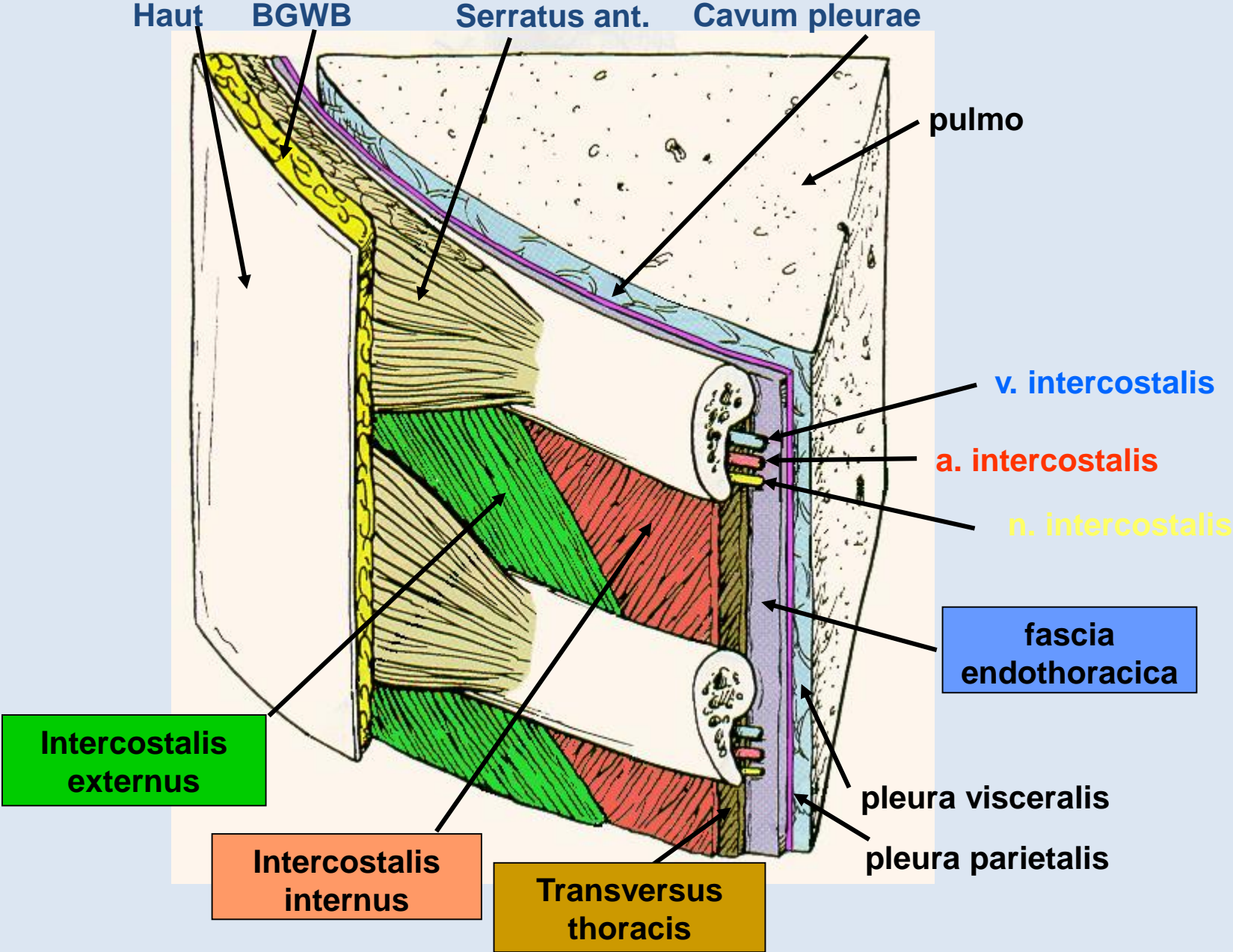
BAUELEMENTE DER THORAKALWAND



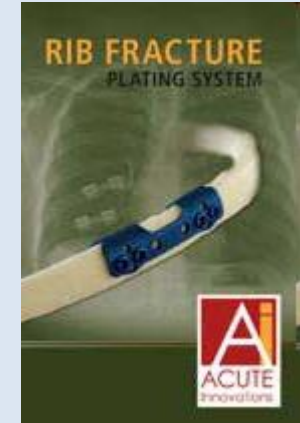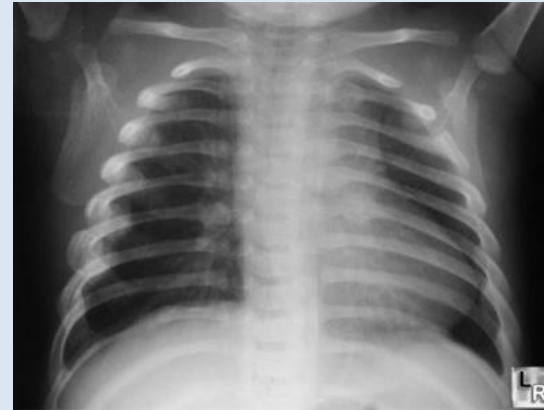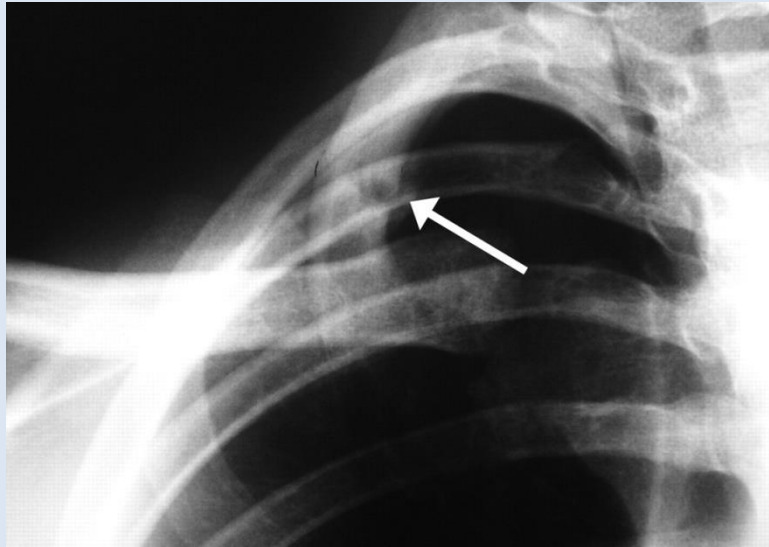
BAUELEMENTE DER THORAKALWAND



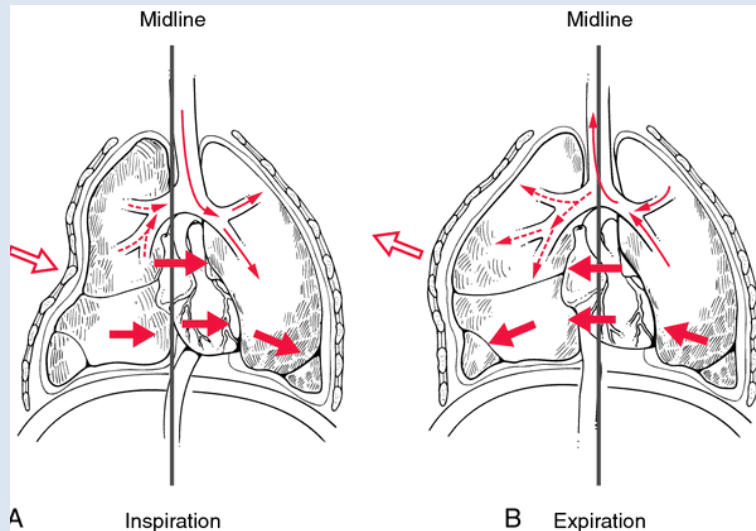
BAUELEMENTE DER THORAKALWAND



KLINISCHE HINWEISE - TRAUMATOLOGIE



Surgical Fixation of Flail Chest with Plating of Ribs



Sample Use Only - Copyrighted

Surgical Fixation of Flail Chest with Plating of Ribs

Incision

Thoracotomy

Multiple flail segments in the chest wall

Pieces of plastic and bone fragments are extracted.

Blood clot and fluid are removed from the thoracic cavity manually and through drains.

The surface of the left lung and parietal pleura was abraded to allow good pleurodesis.

Incision widened on both sides.

Rib Fixation

Five pelvic reconstruction plates and wire are used for a total resection and stabilization of four separate ribs.

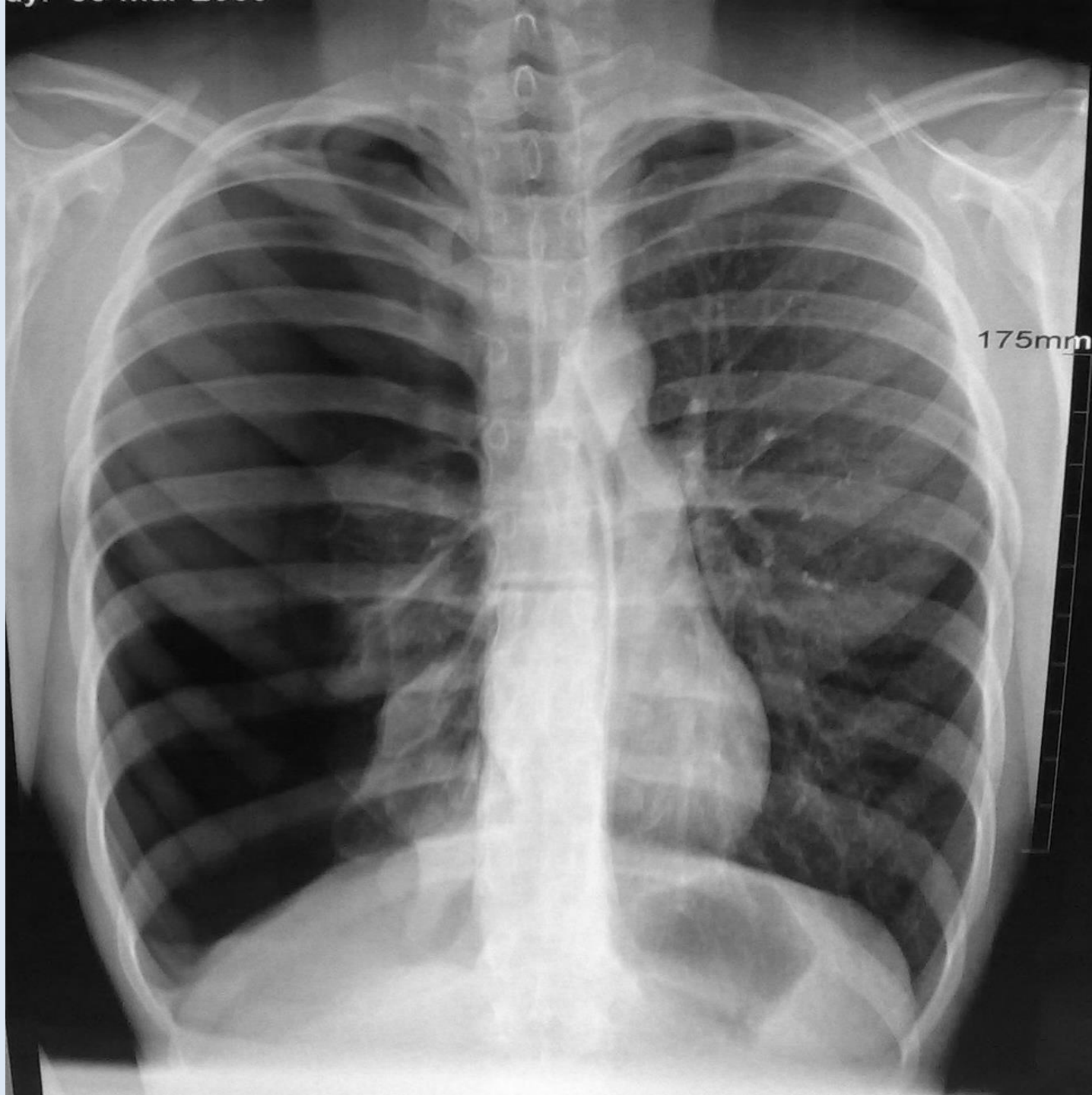Ribs are brought out into normal position and secured to plates using heavy wire.

Post-operative X-ray

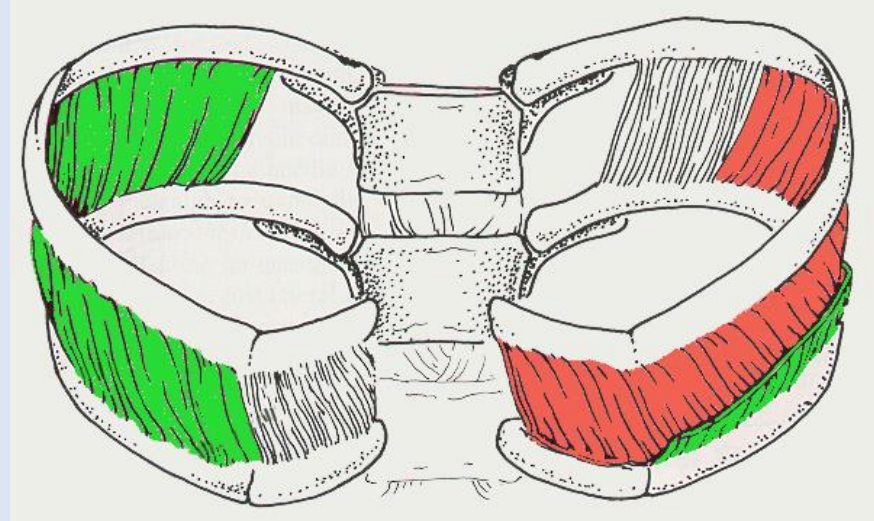
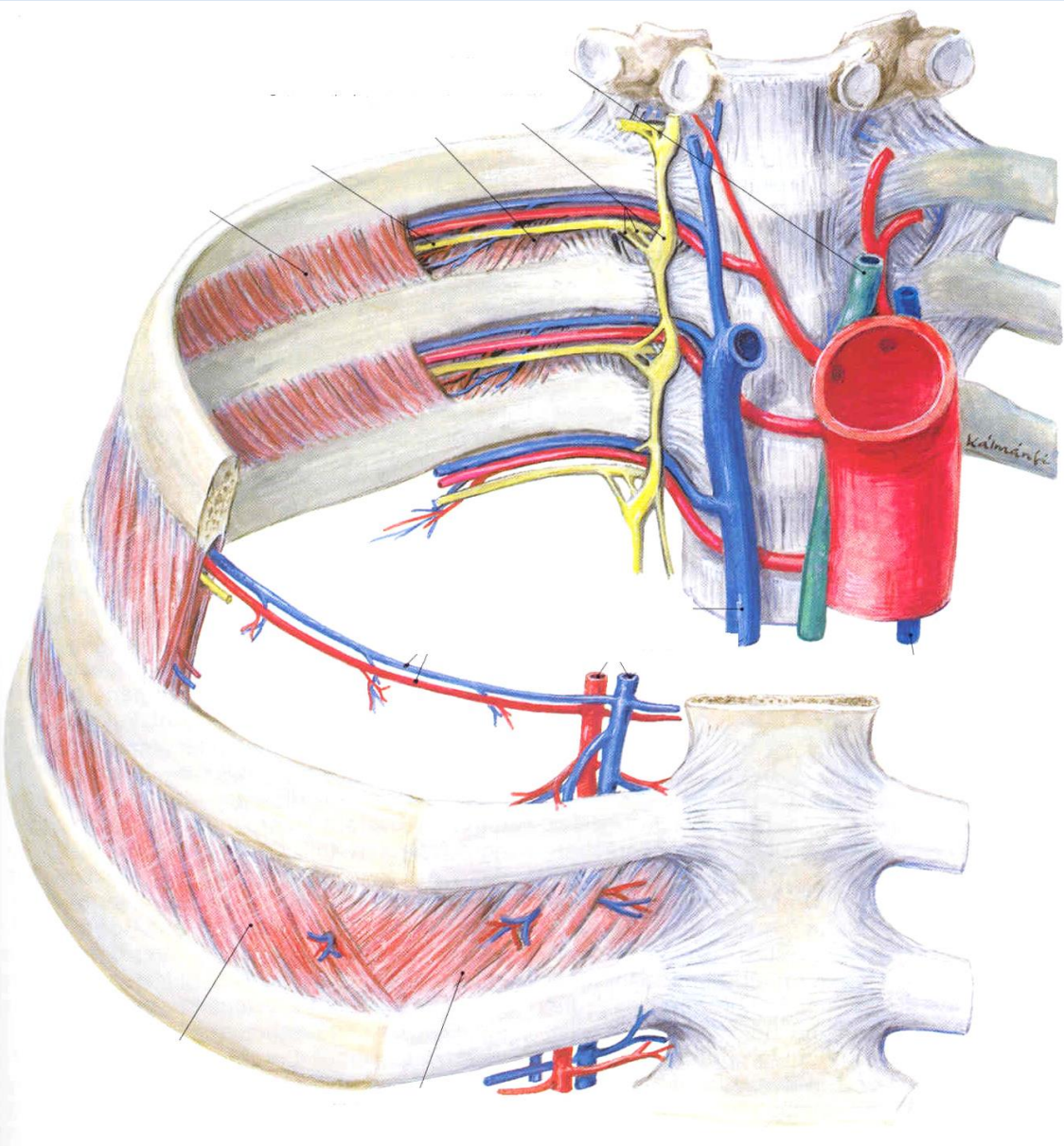
Anterior view

Medical Legal Art

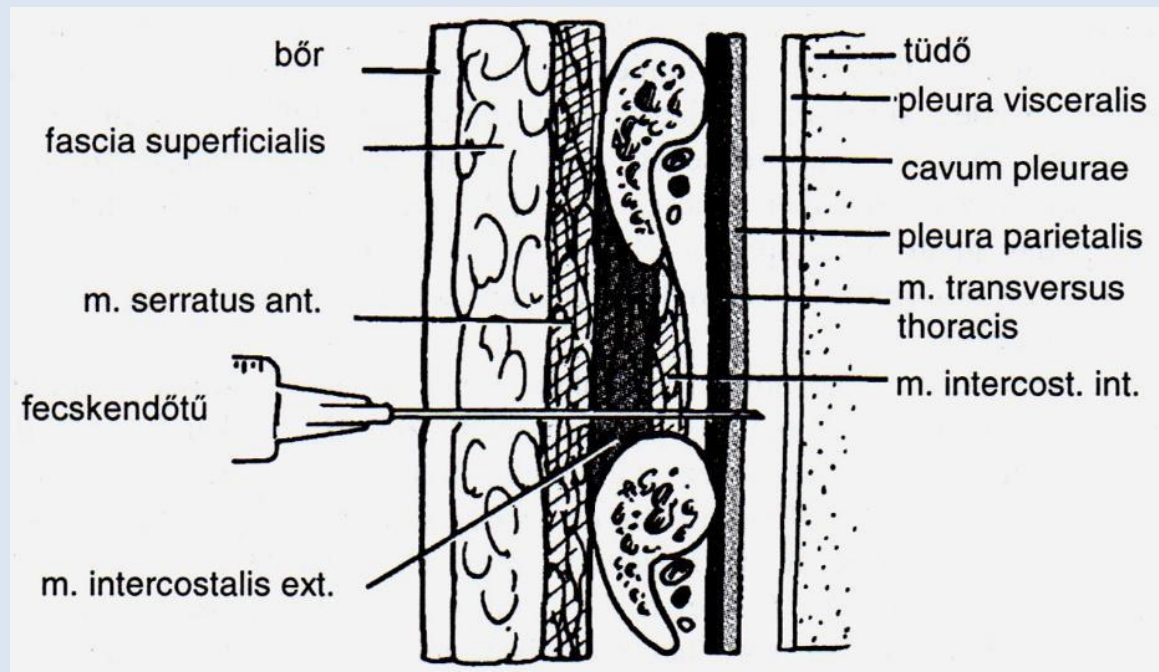
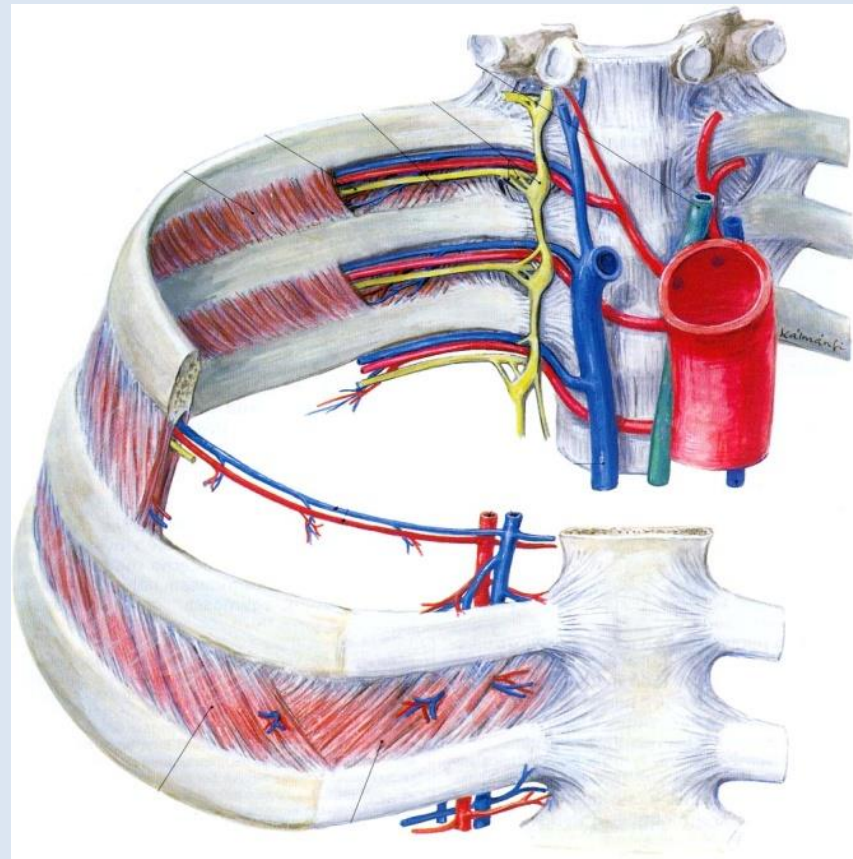
Sample Use Only - Copyrighted

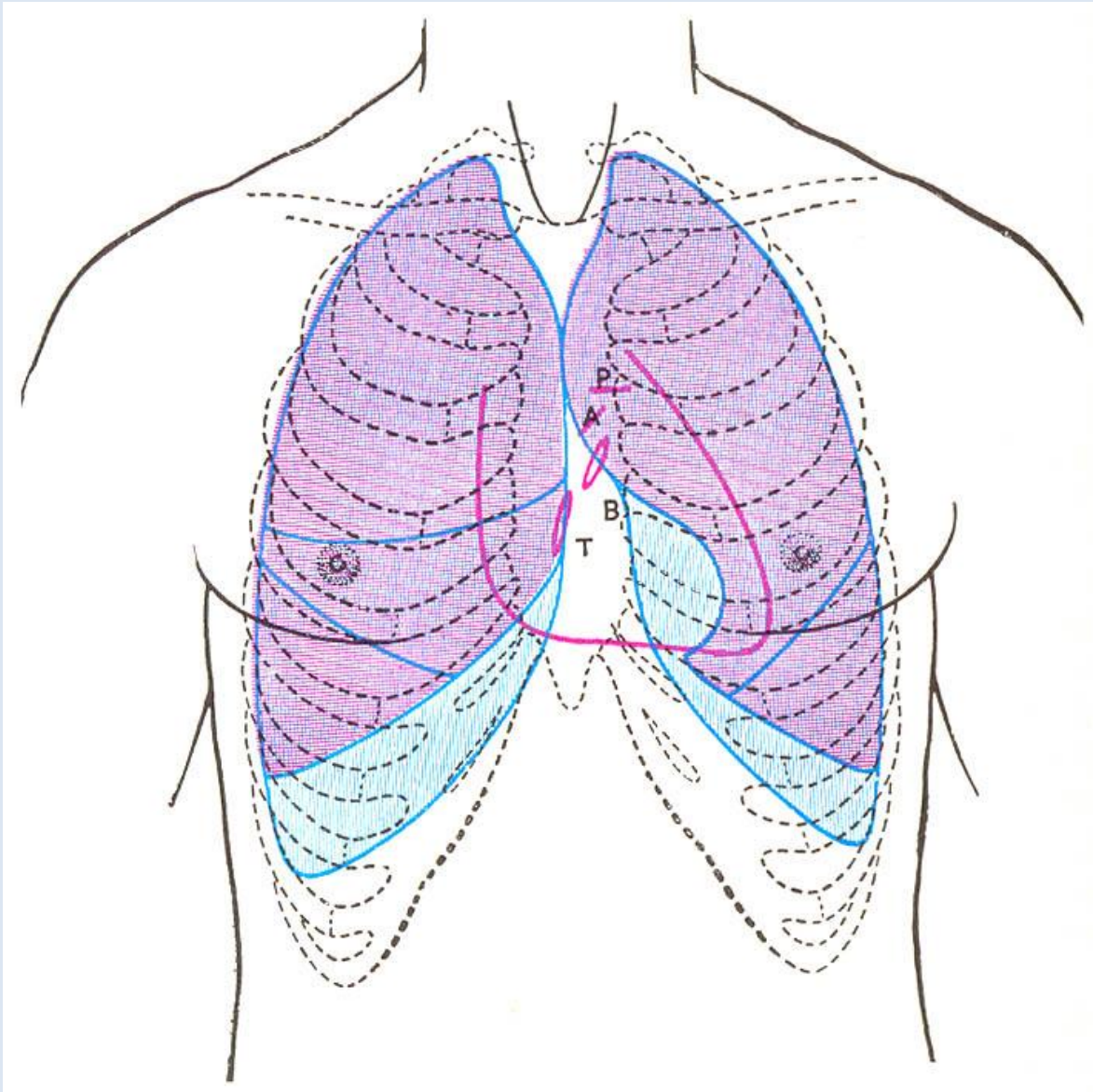


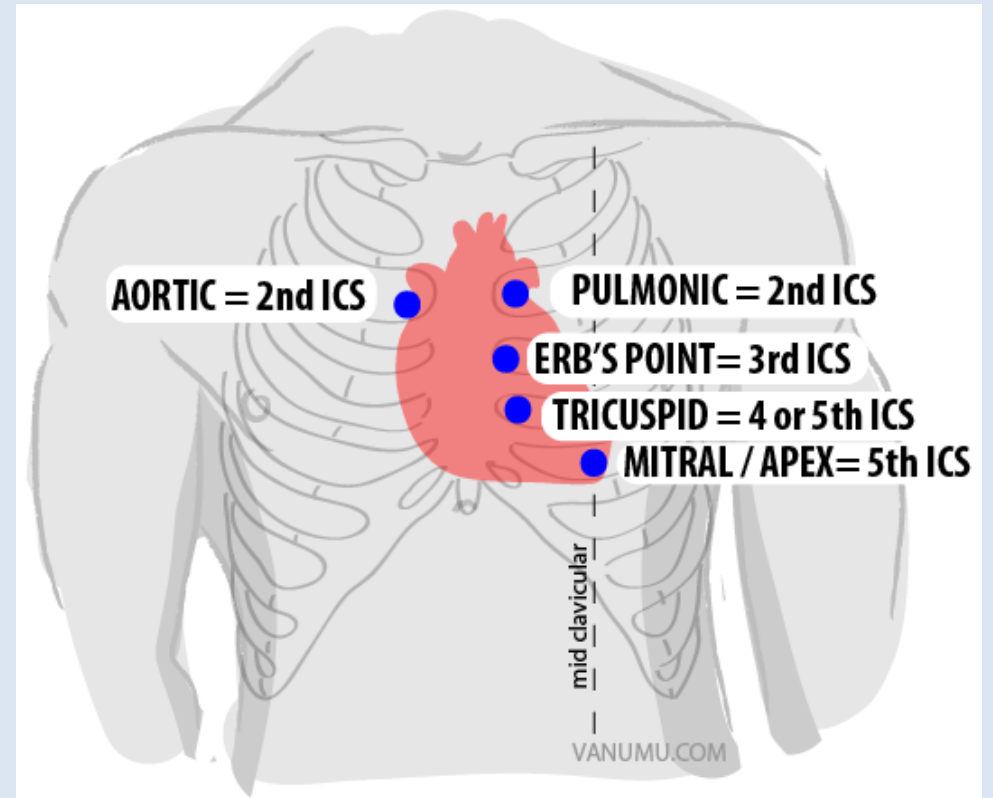
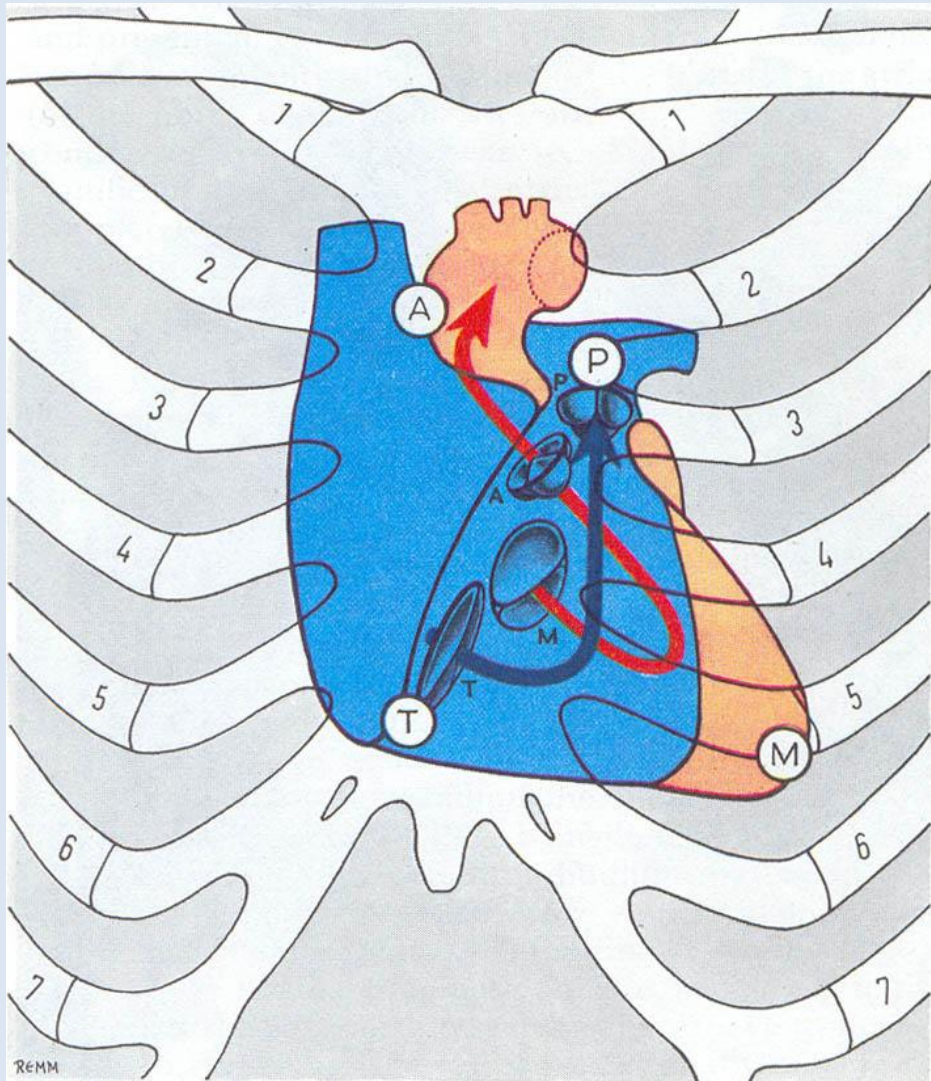
175mm

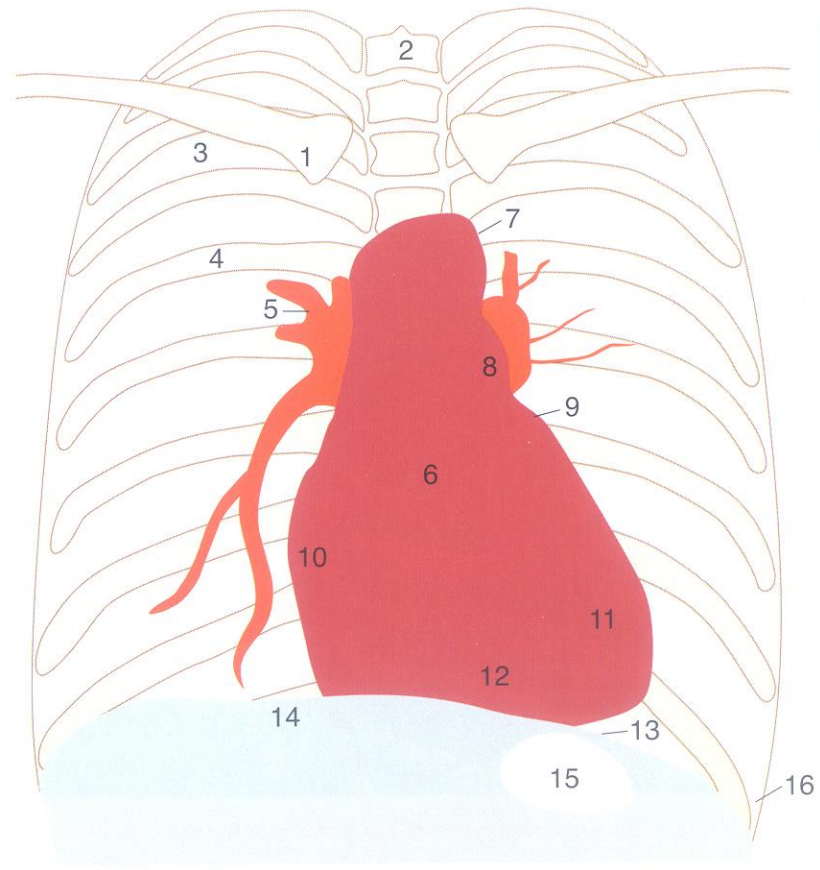
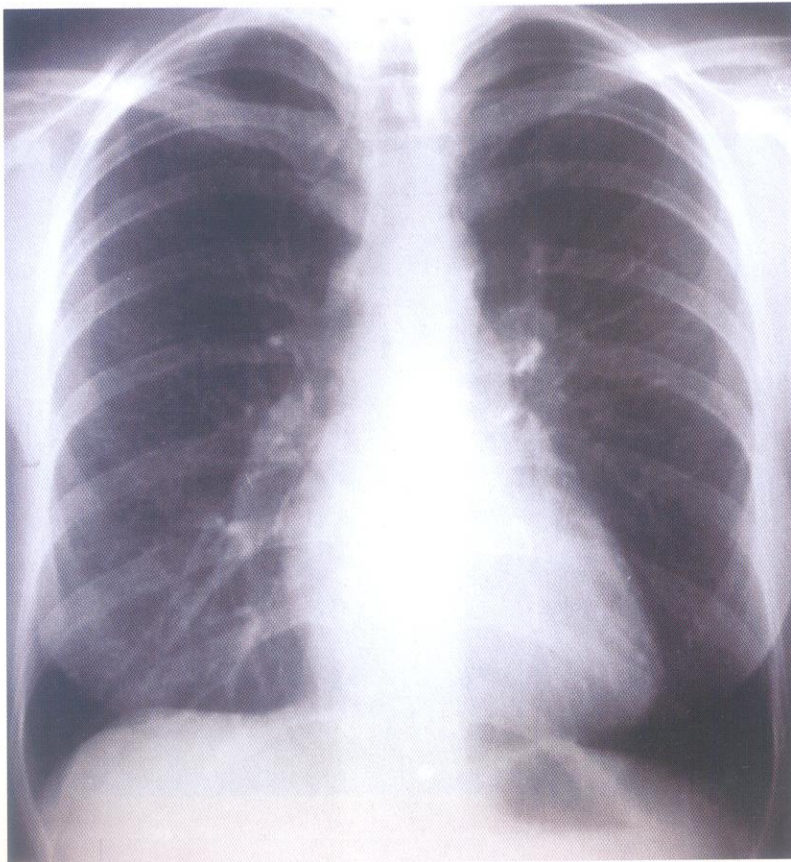
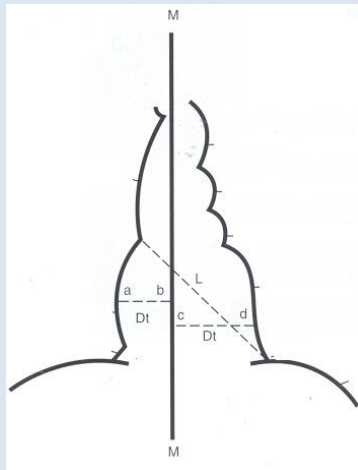


Thorakal Drain (intercostal drain)

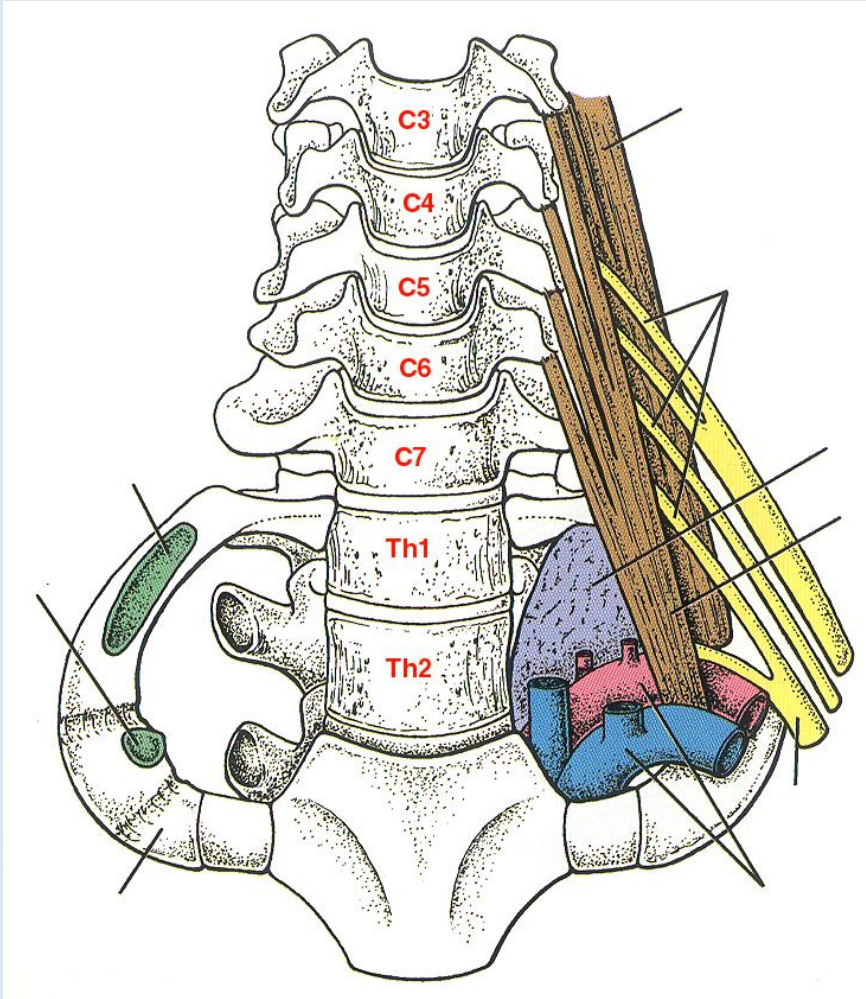
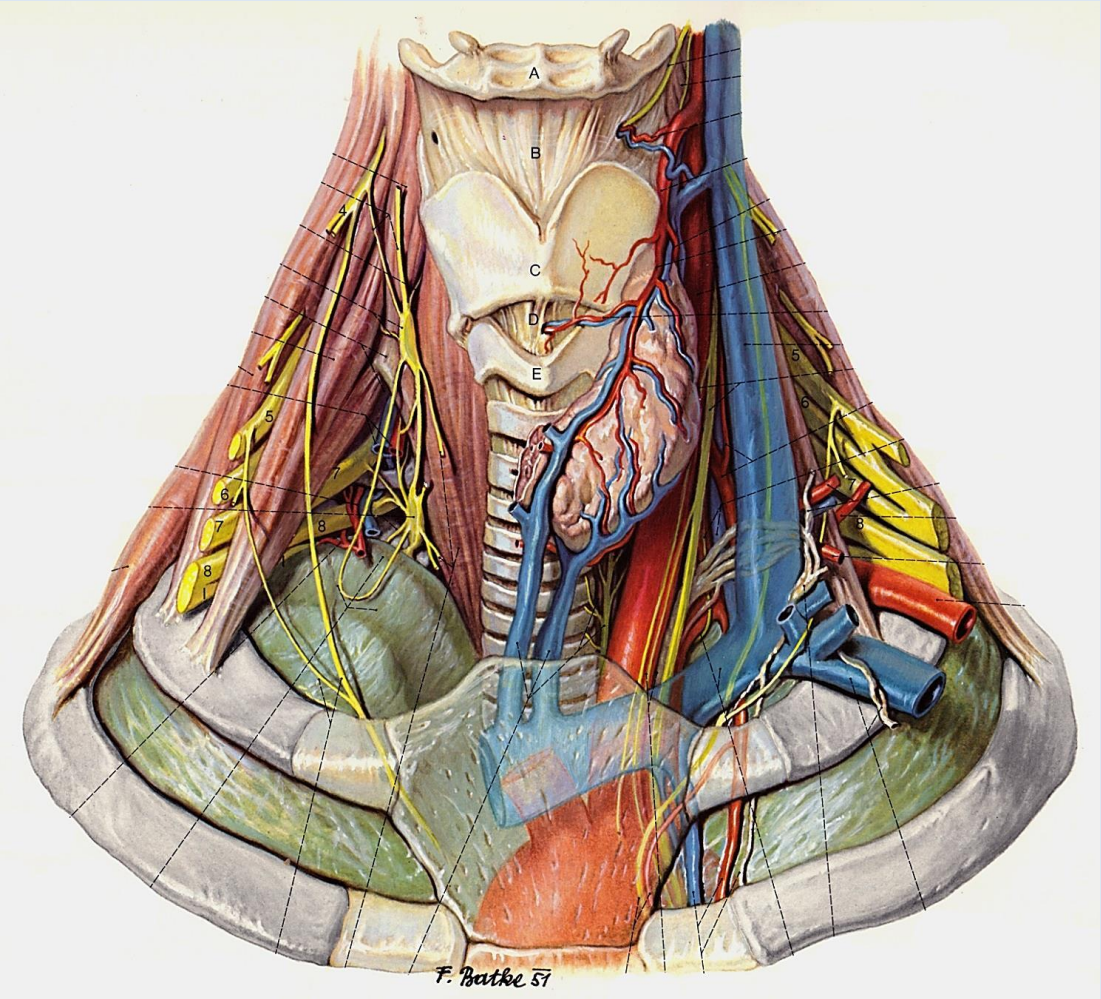








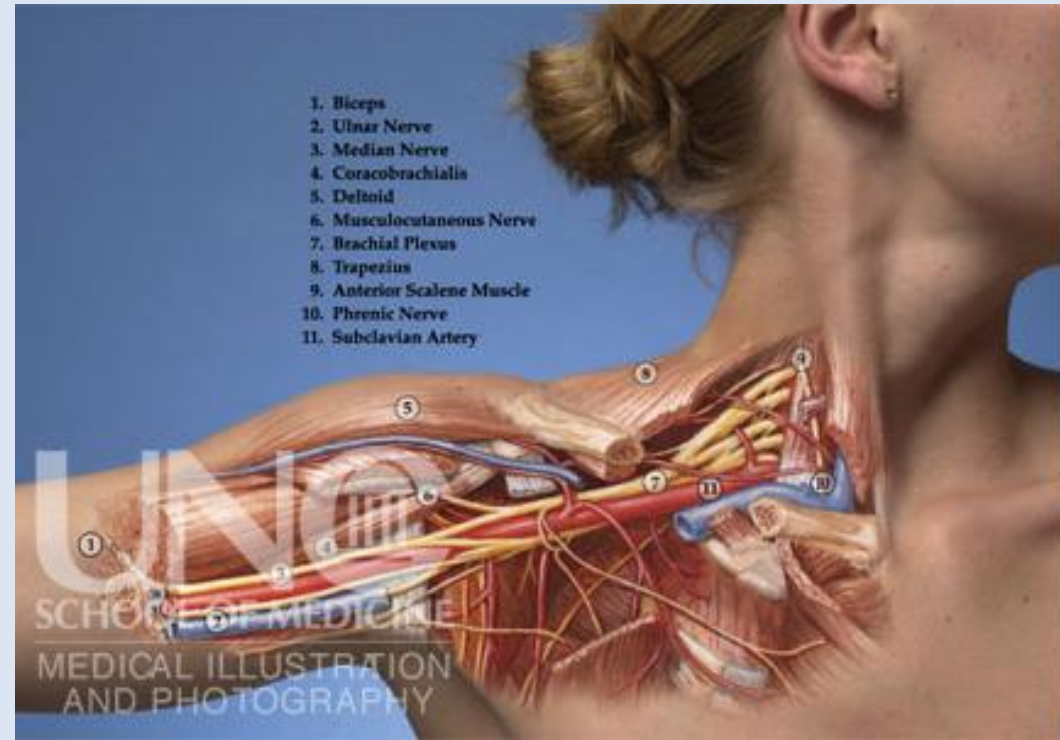
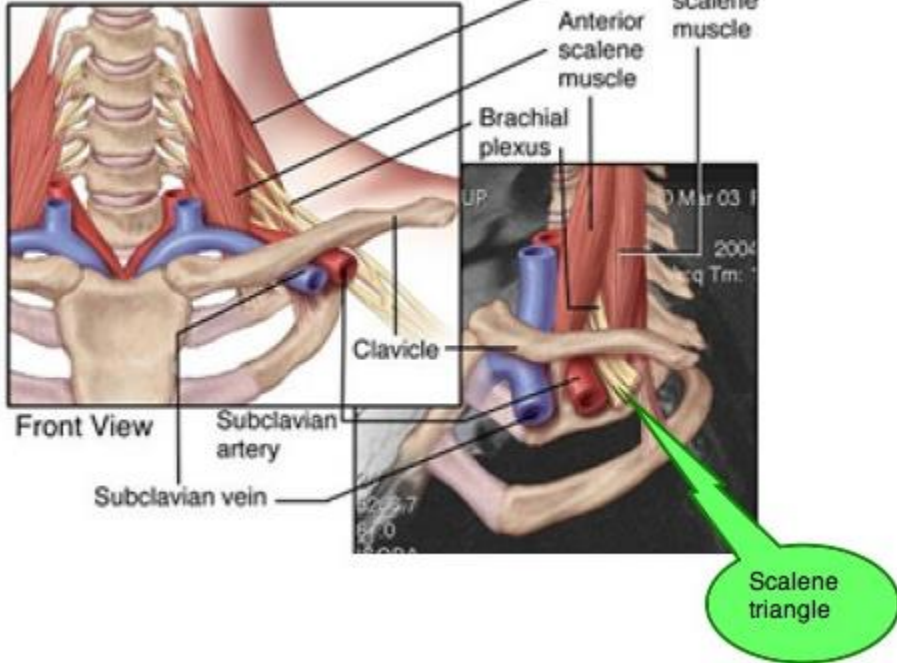
Eingang zur Thorakalhöhle „THORACIC OUTLET“

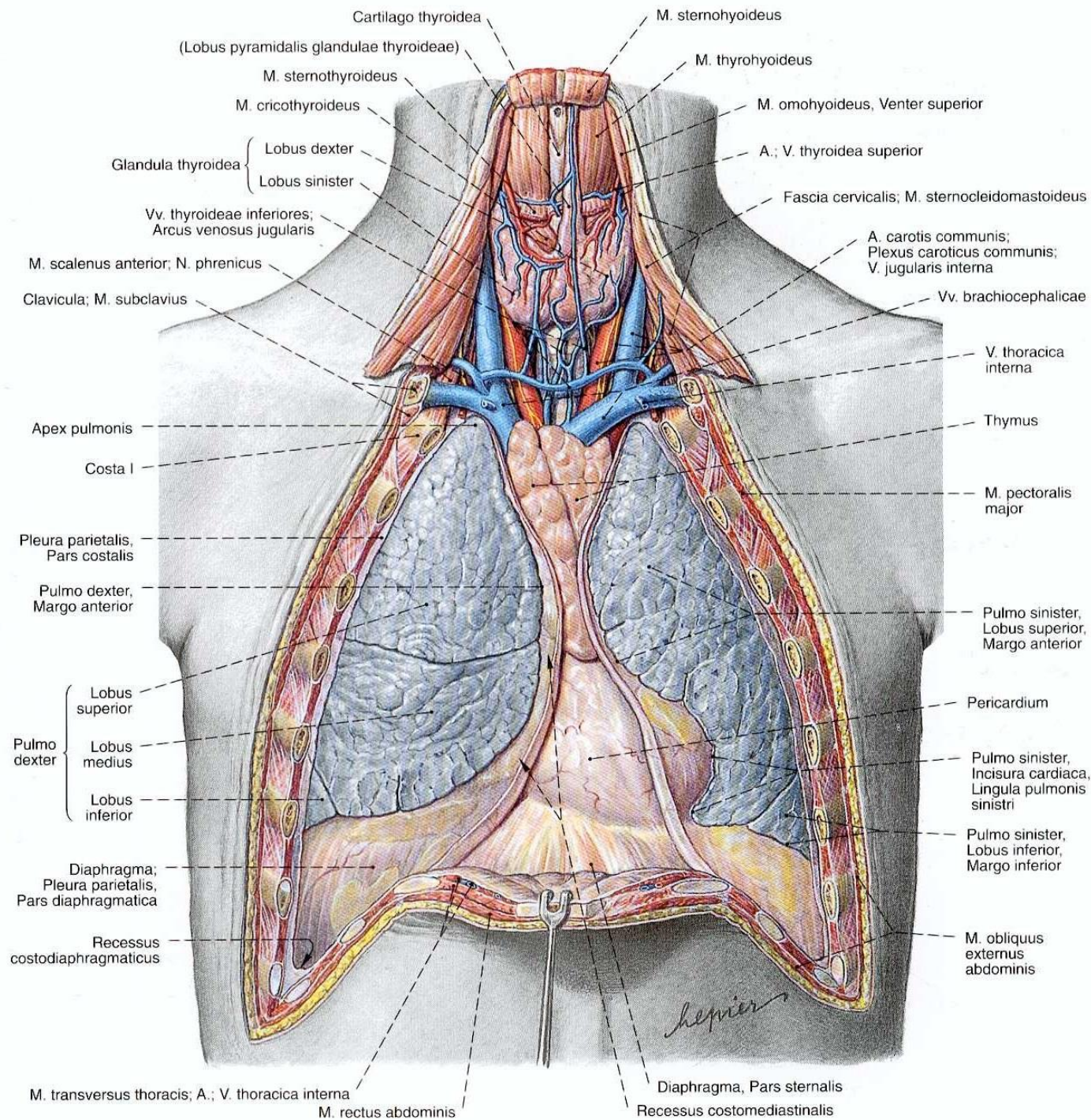


TOS

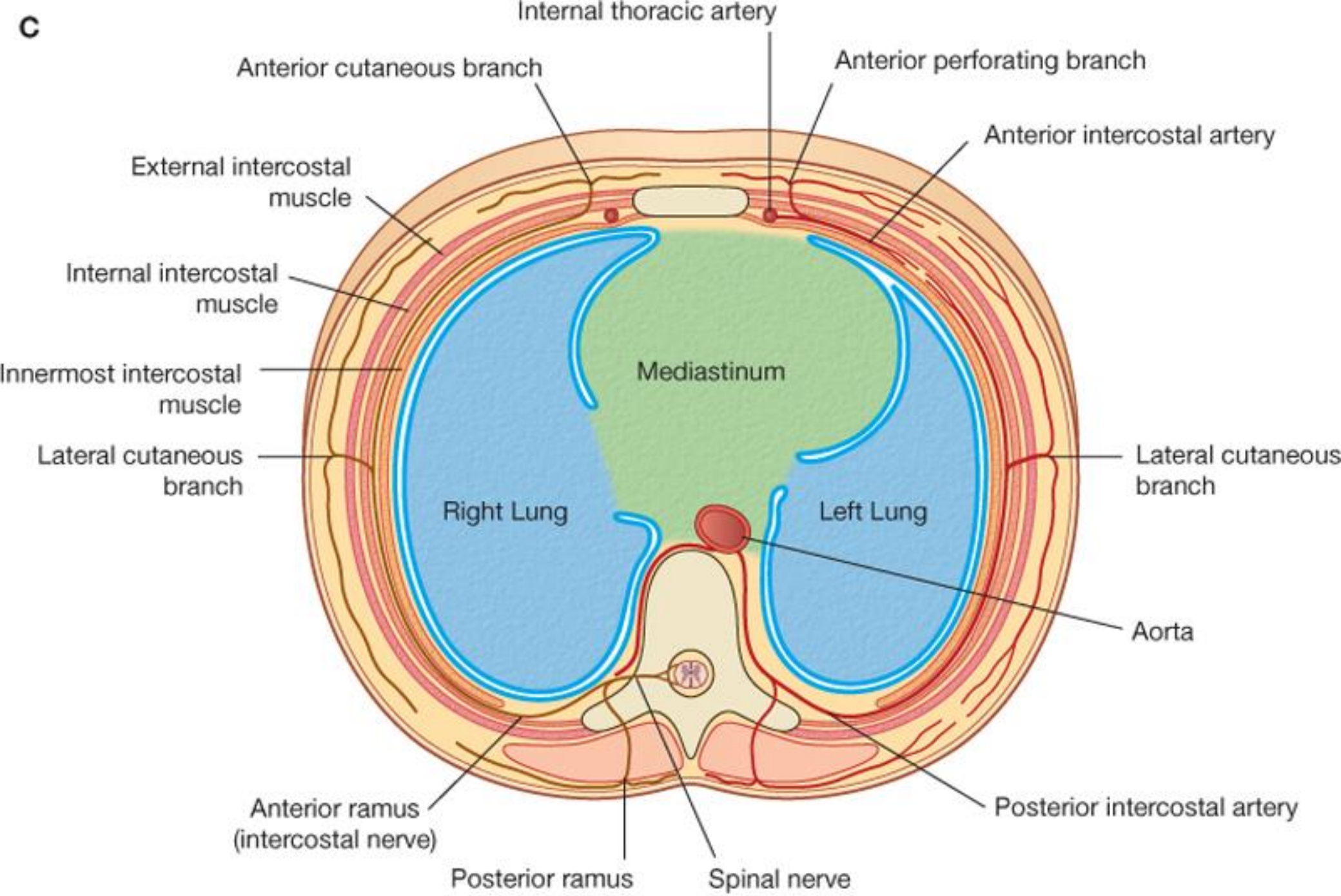
„THORACIC OUTLET SYNDROME“

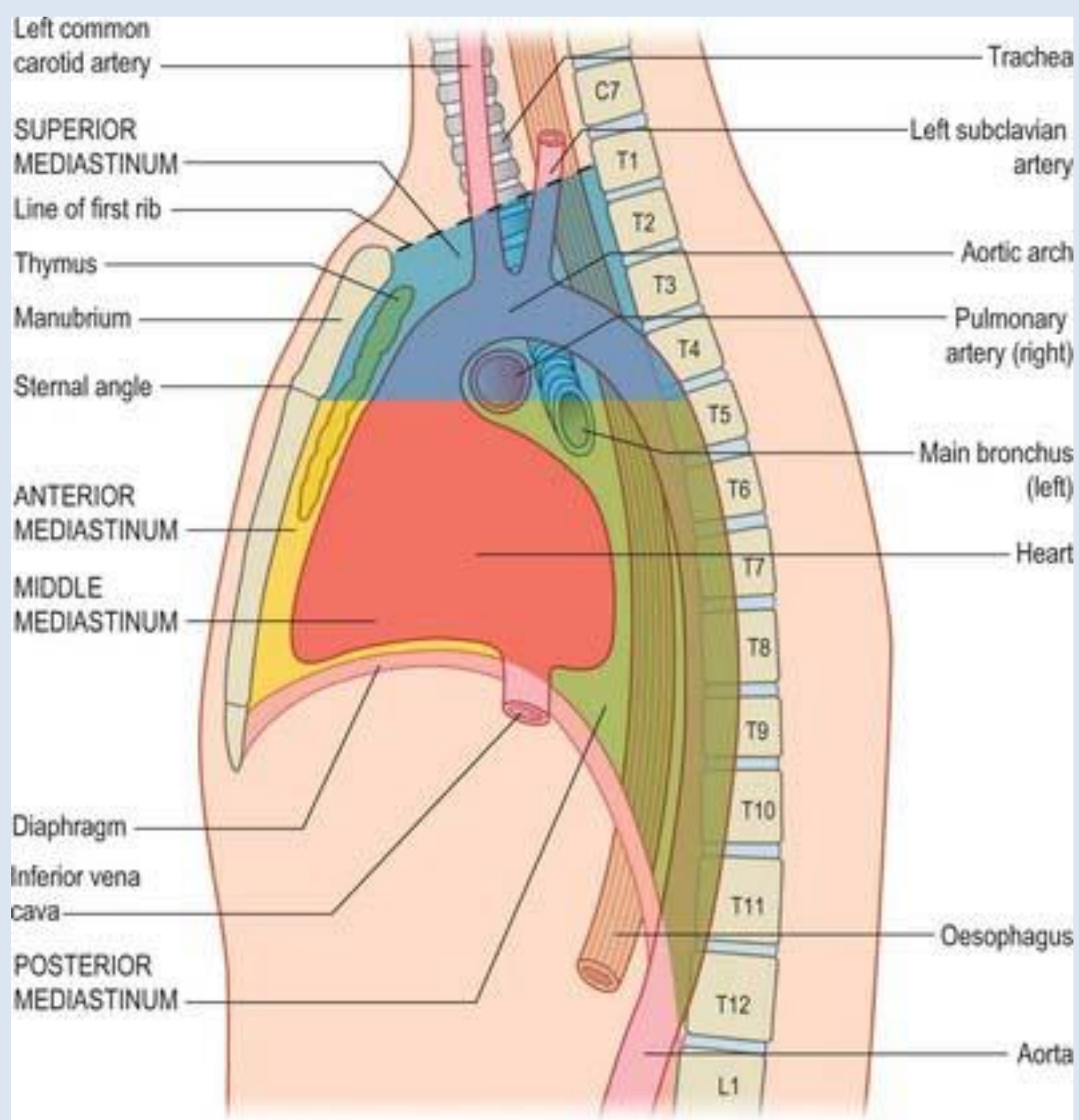
Normal Anatomy

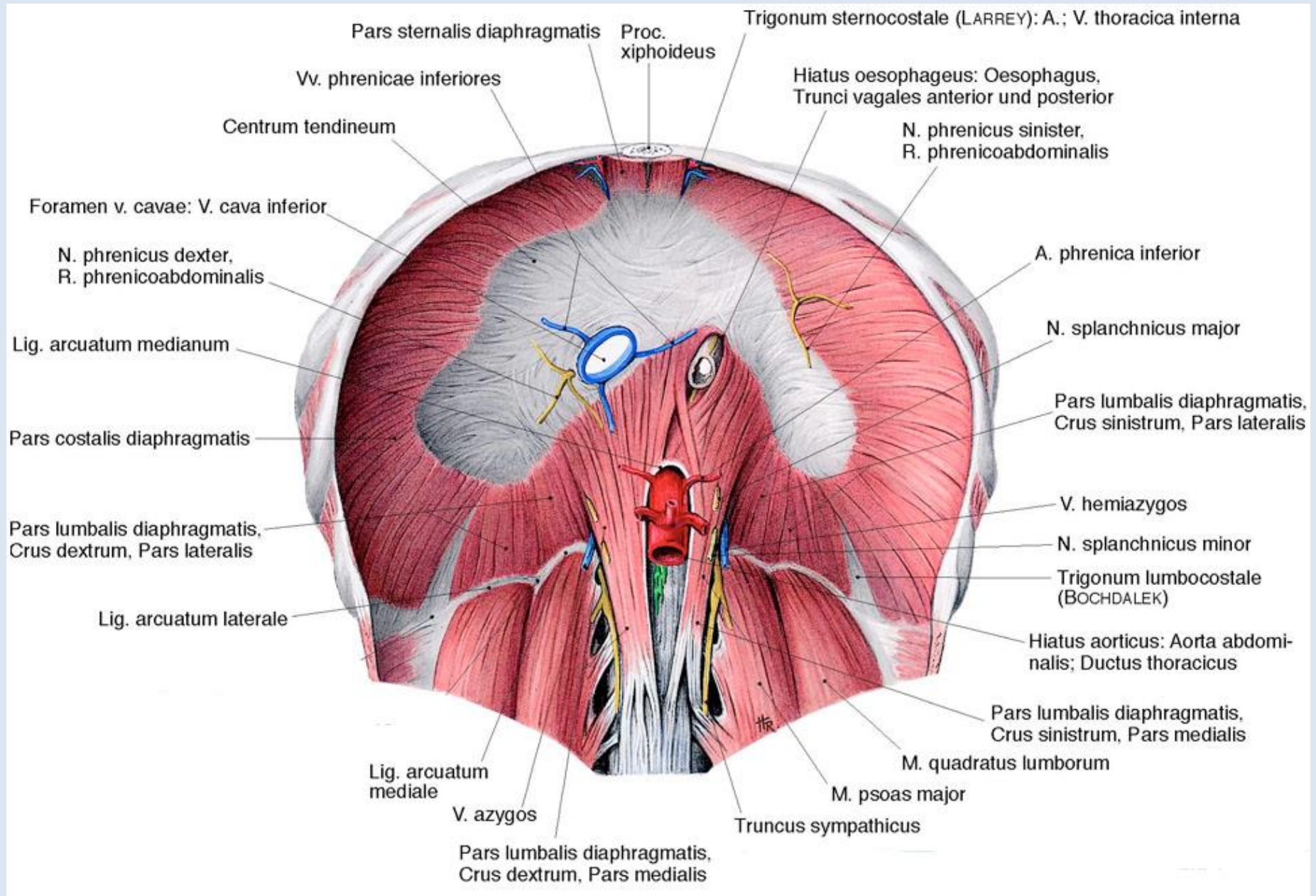


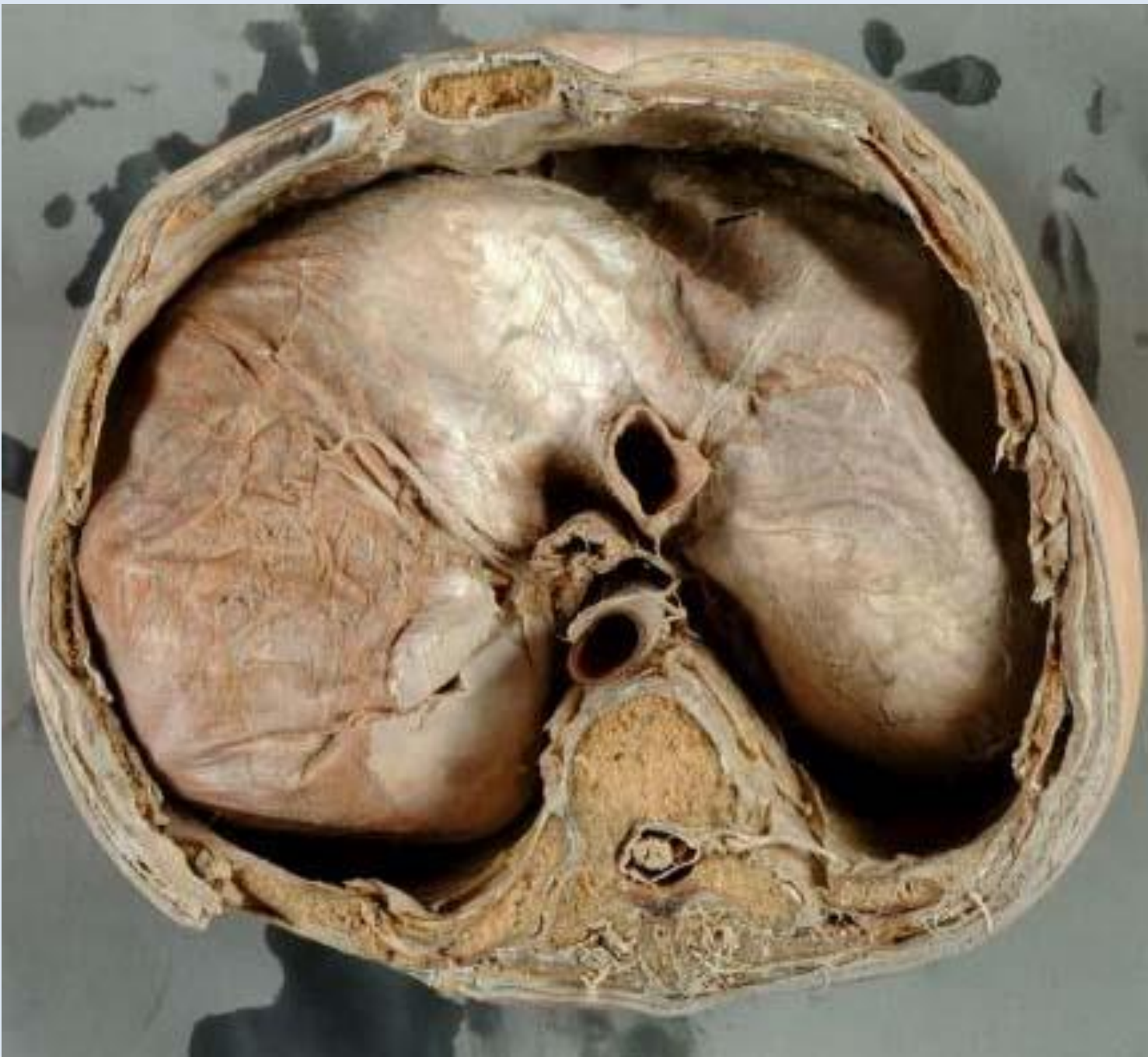


C









Th4 Bifurcation of trachea

Beginning of arch of aorta; **end of arch of aorta** (=beginning of descending aorta)

Azygos vein enters sup. vena cava (at the level of 2nd sternocostal joint)

Th5-6 Hilum of lung

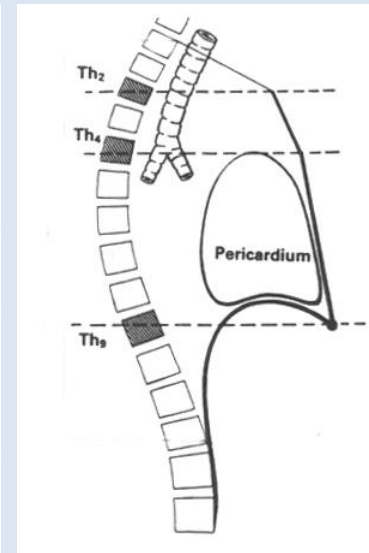
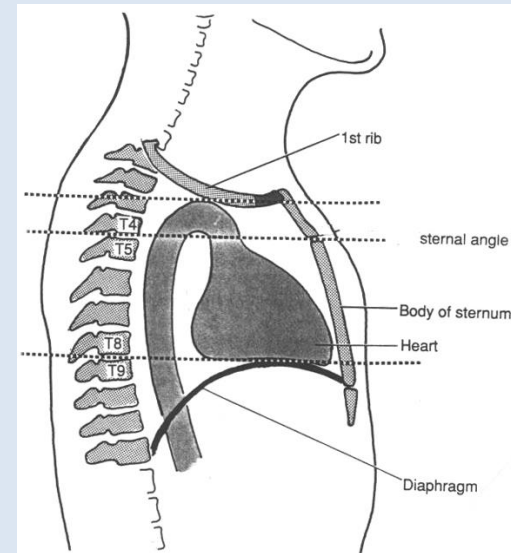
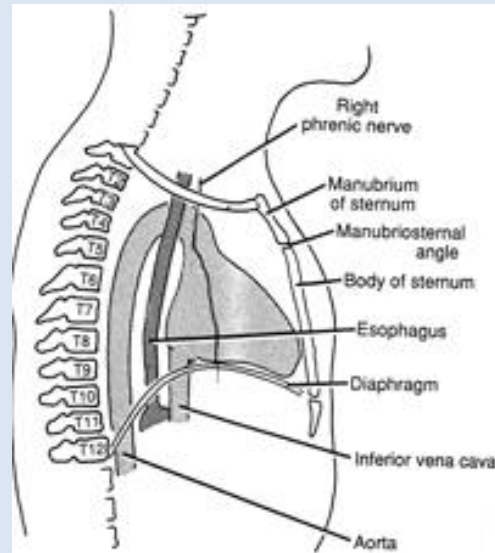
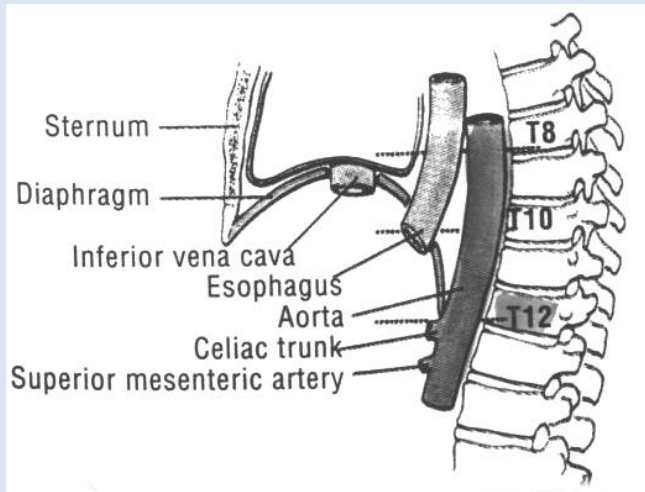
Th8 Foramen of inferior vena cava in the *diaphragm* (IVC+right phrenicoabdominal nerve)

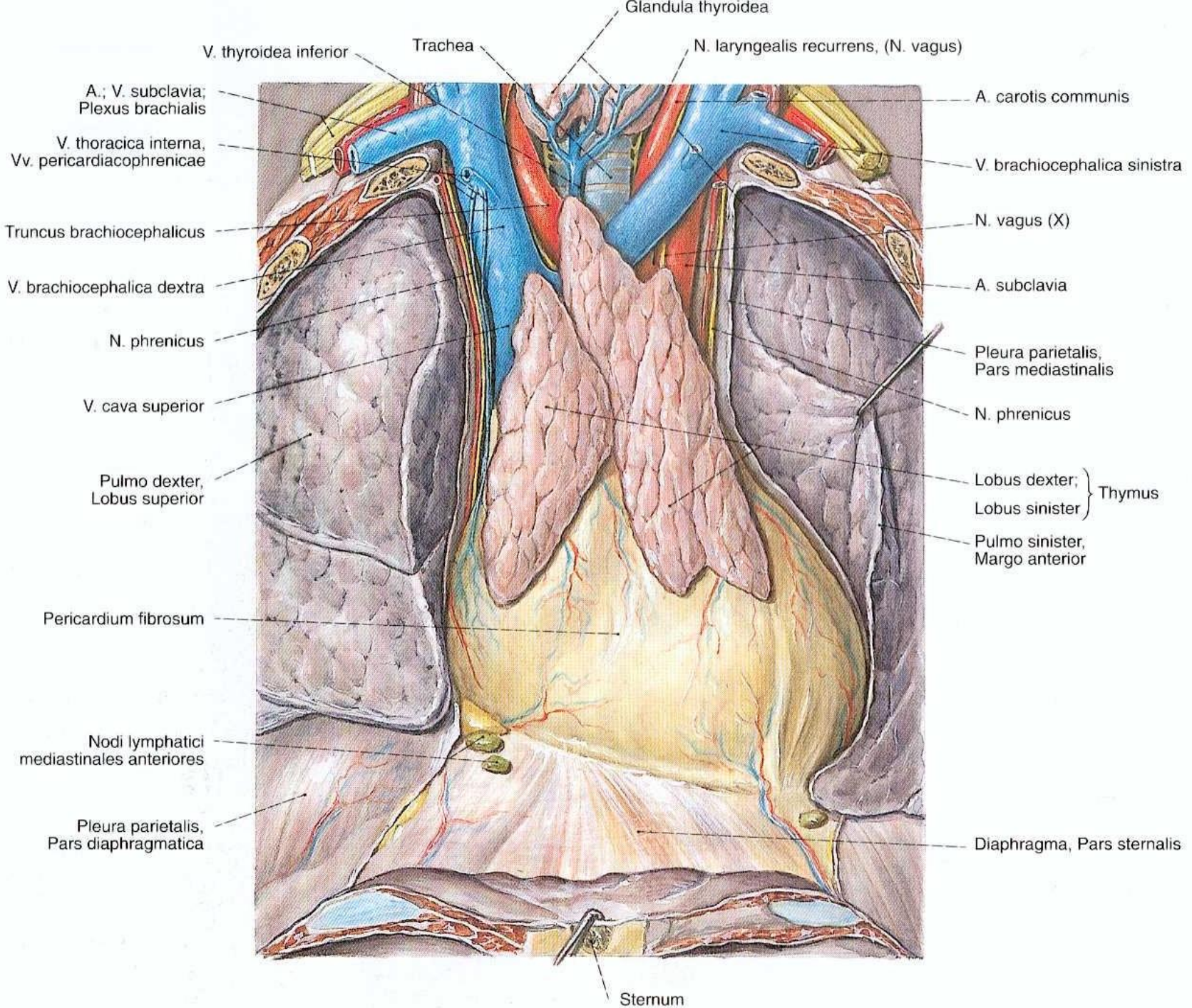
(all the 4 chambers of the heart are visible in cross section)

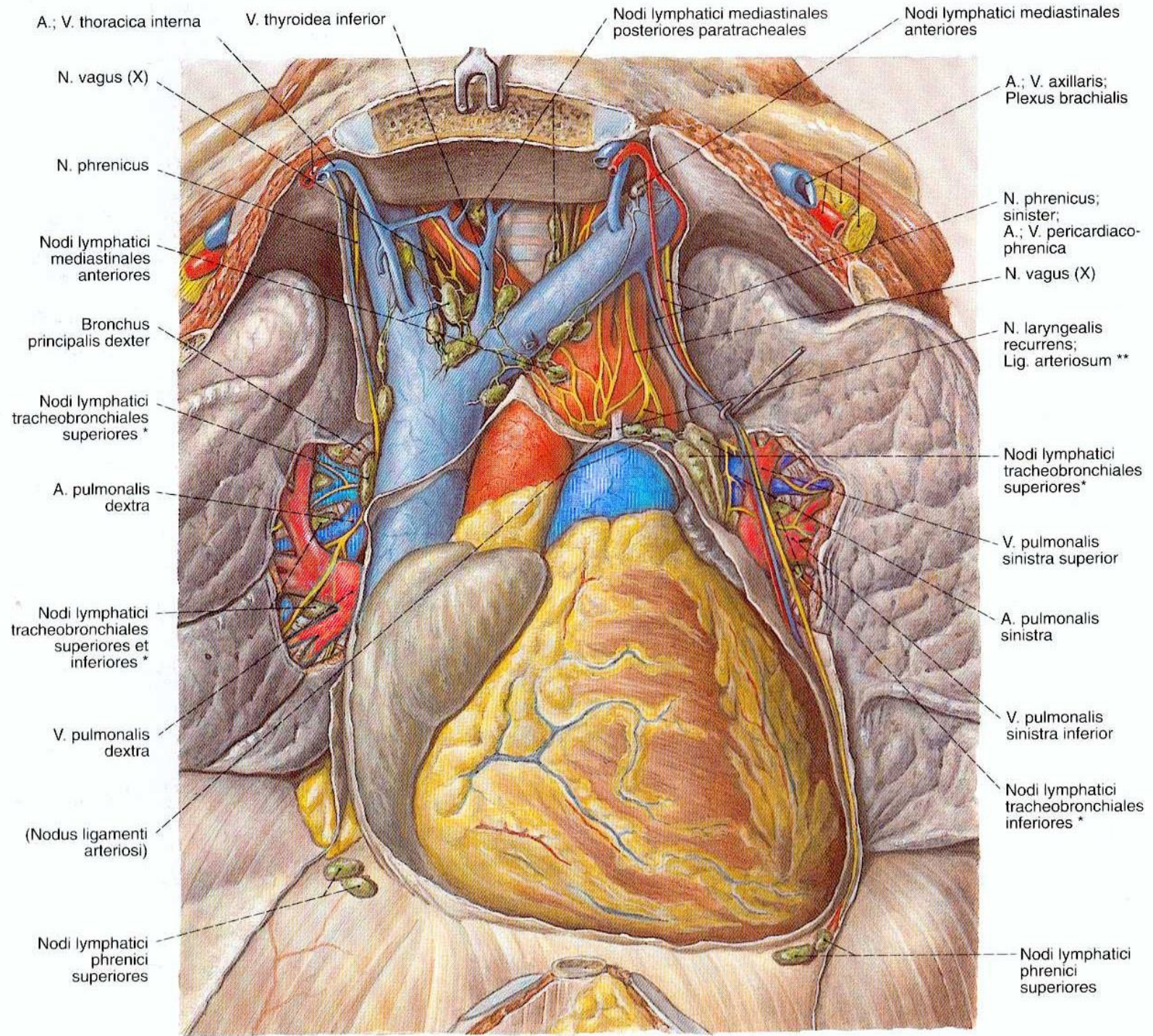
Th10 **Esophageal hiatus of *diaphragm*** (esophagus+vagus nerves+ left phrenicoabdominal nerve)

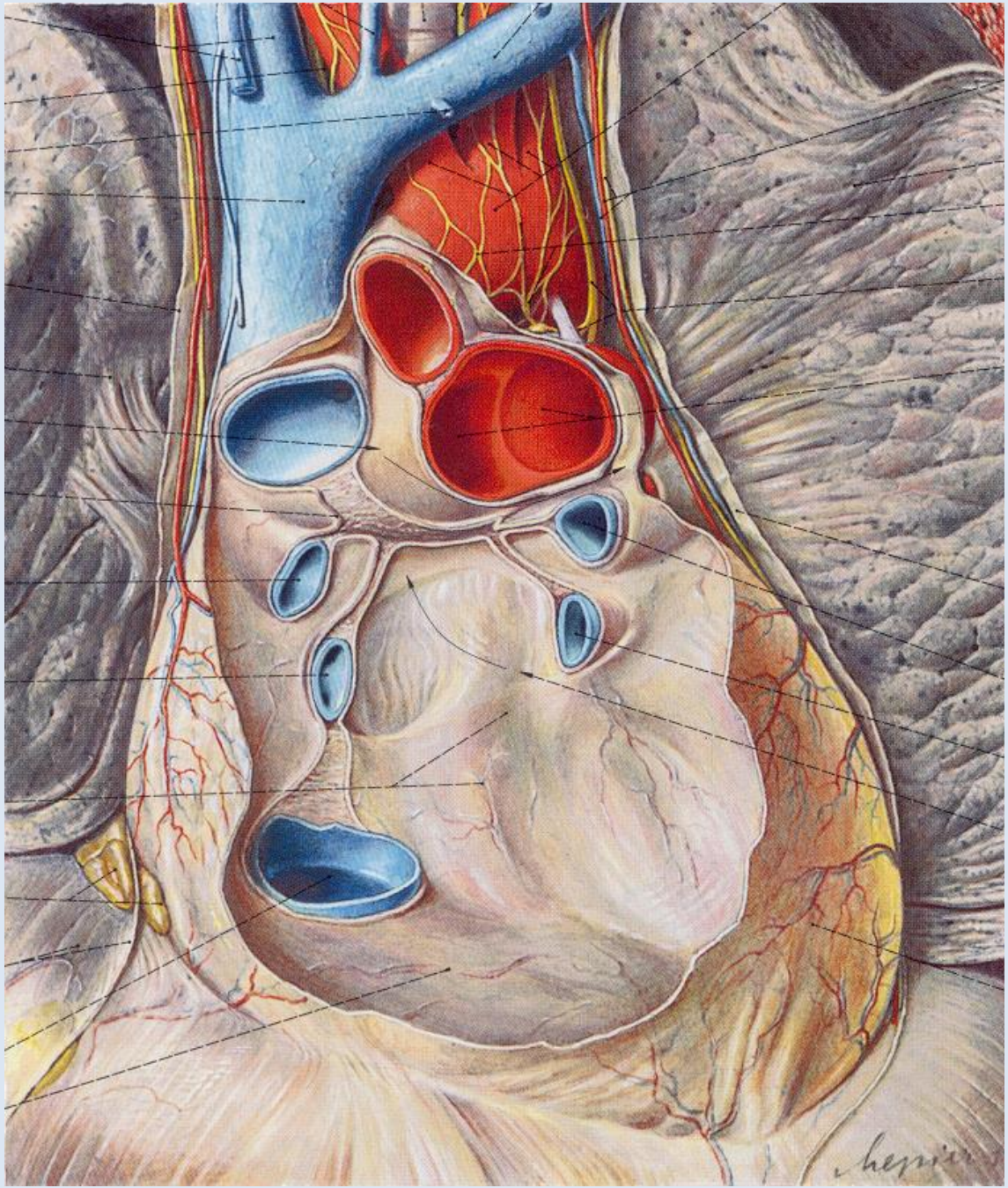
Th11 **Cardia**

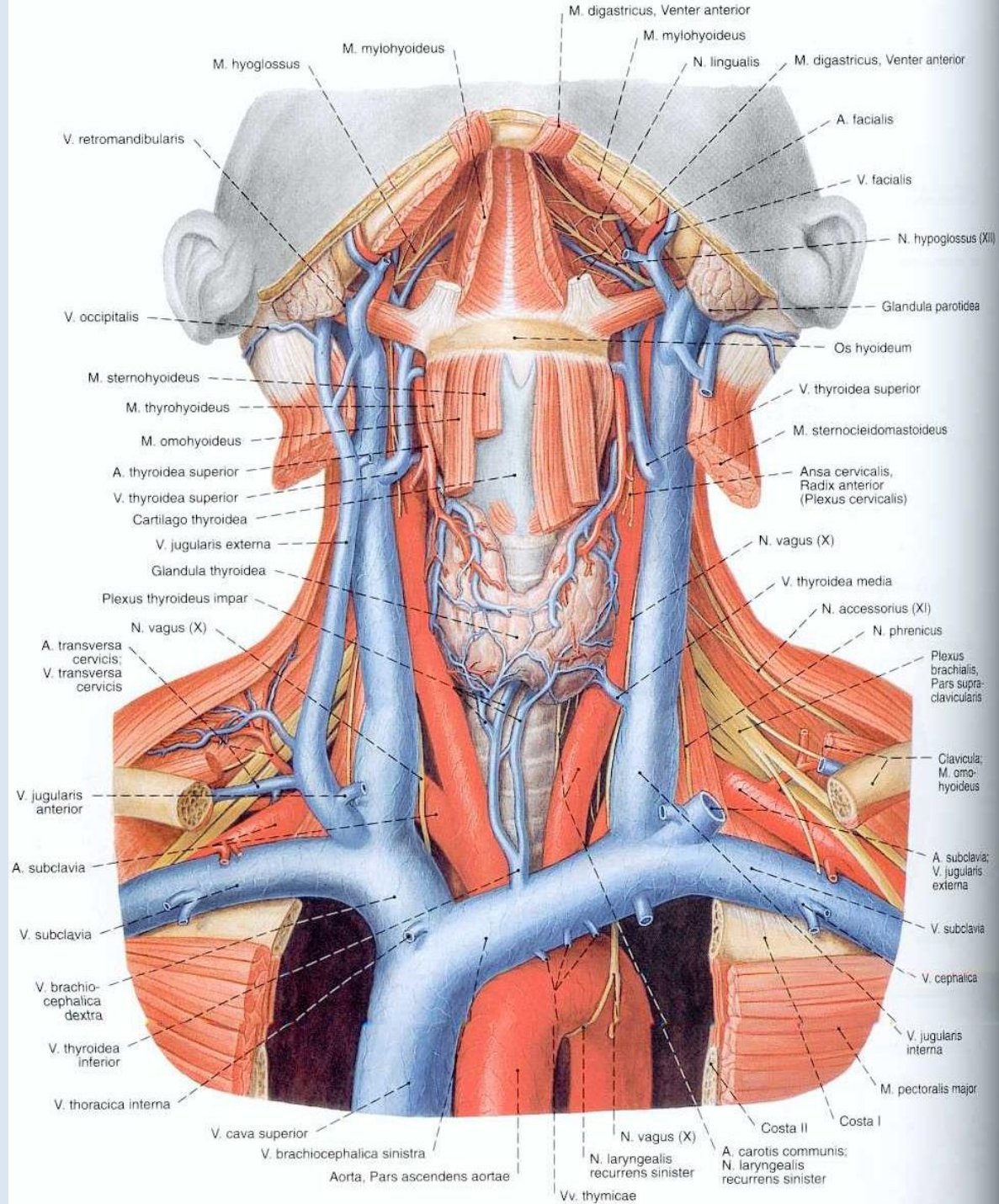
Th12 **Aortic hiatus in *diaphragm*** (aorta+thoracic duct)

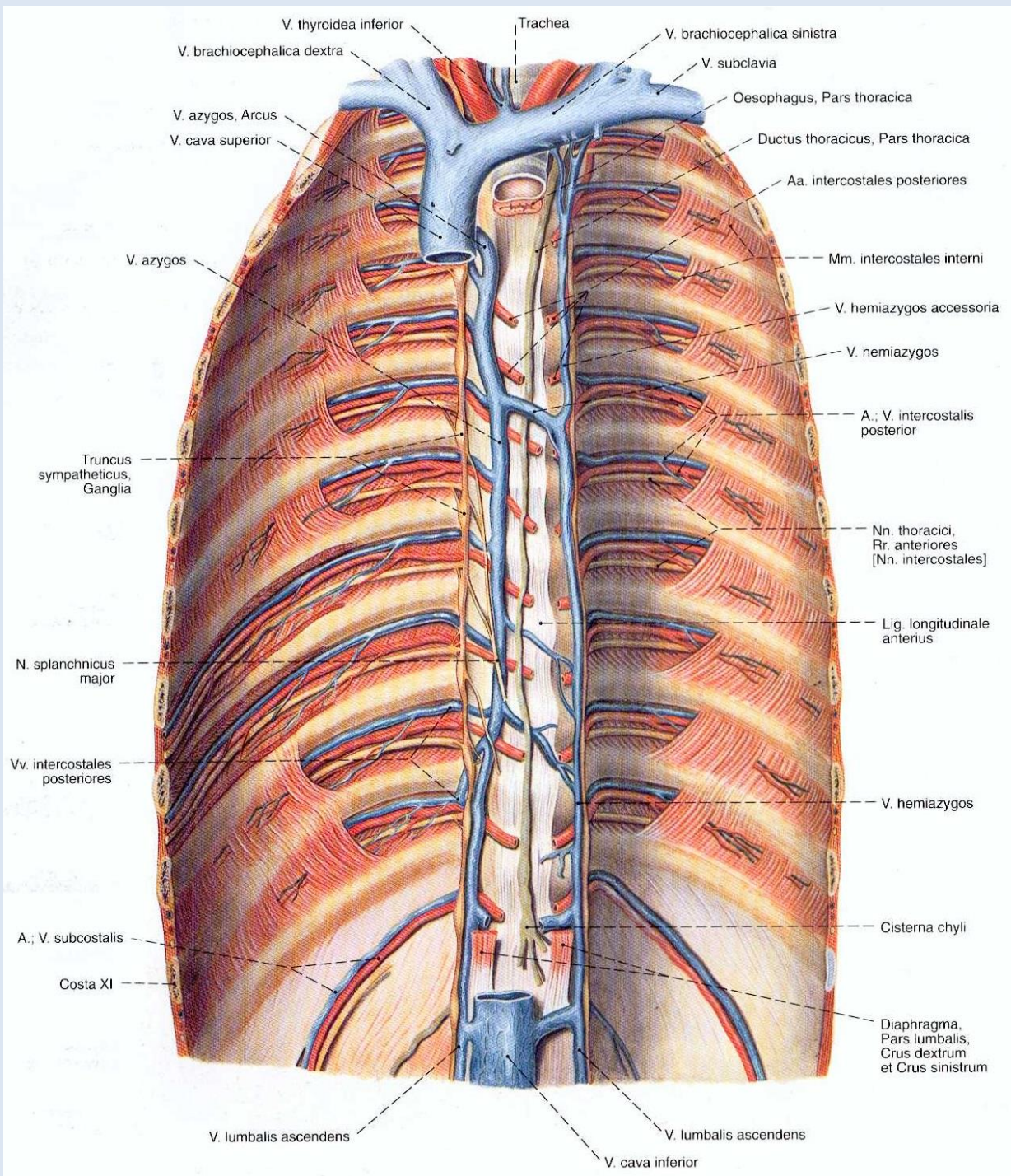


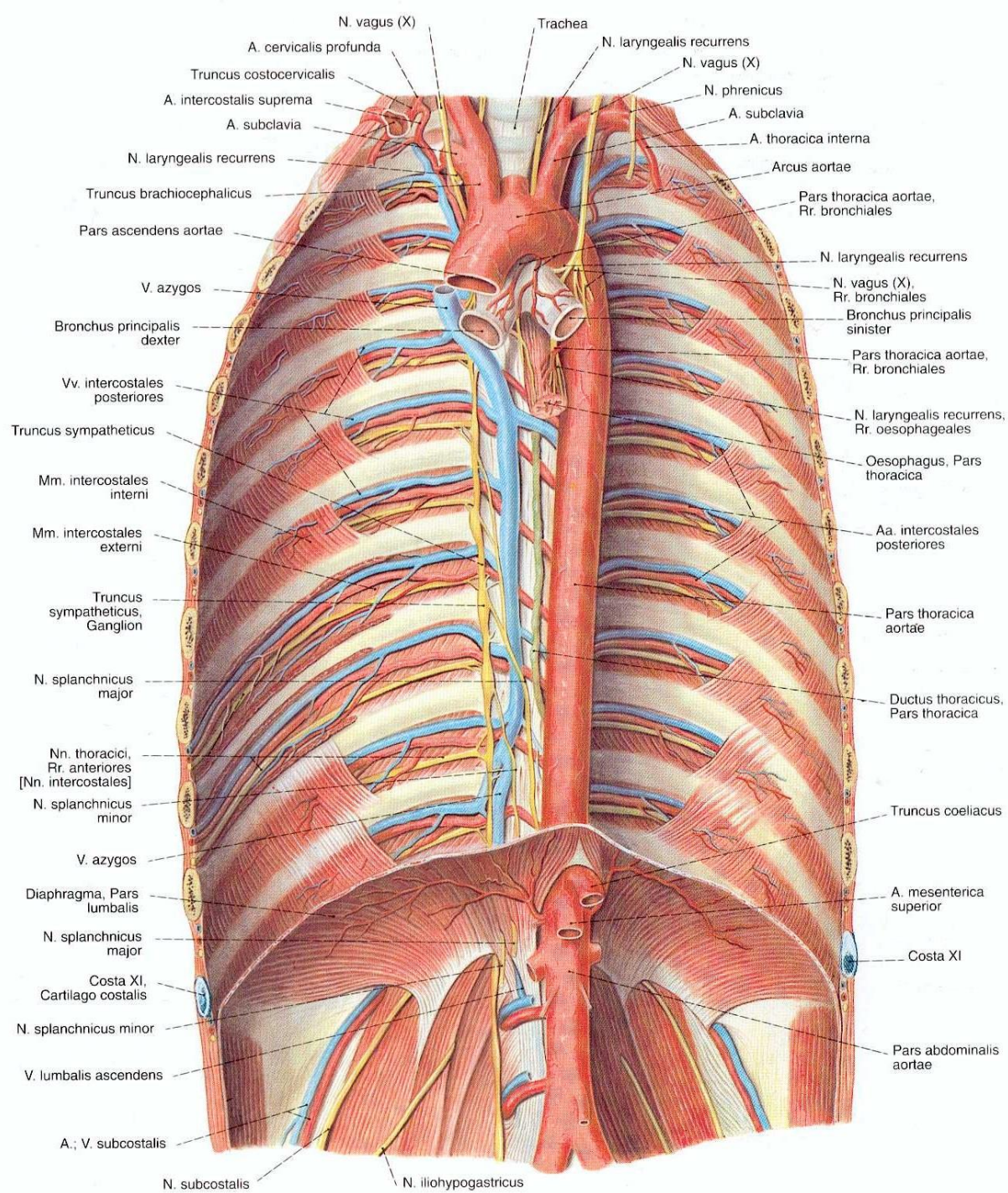


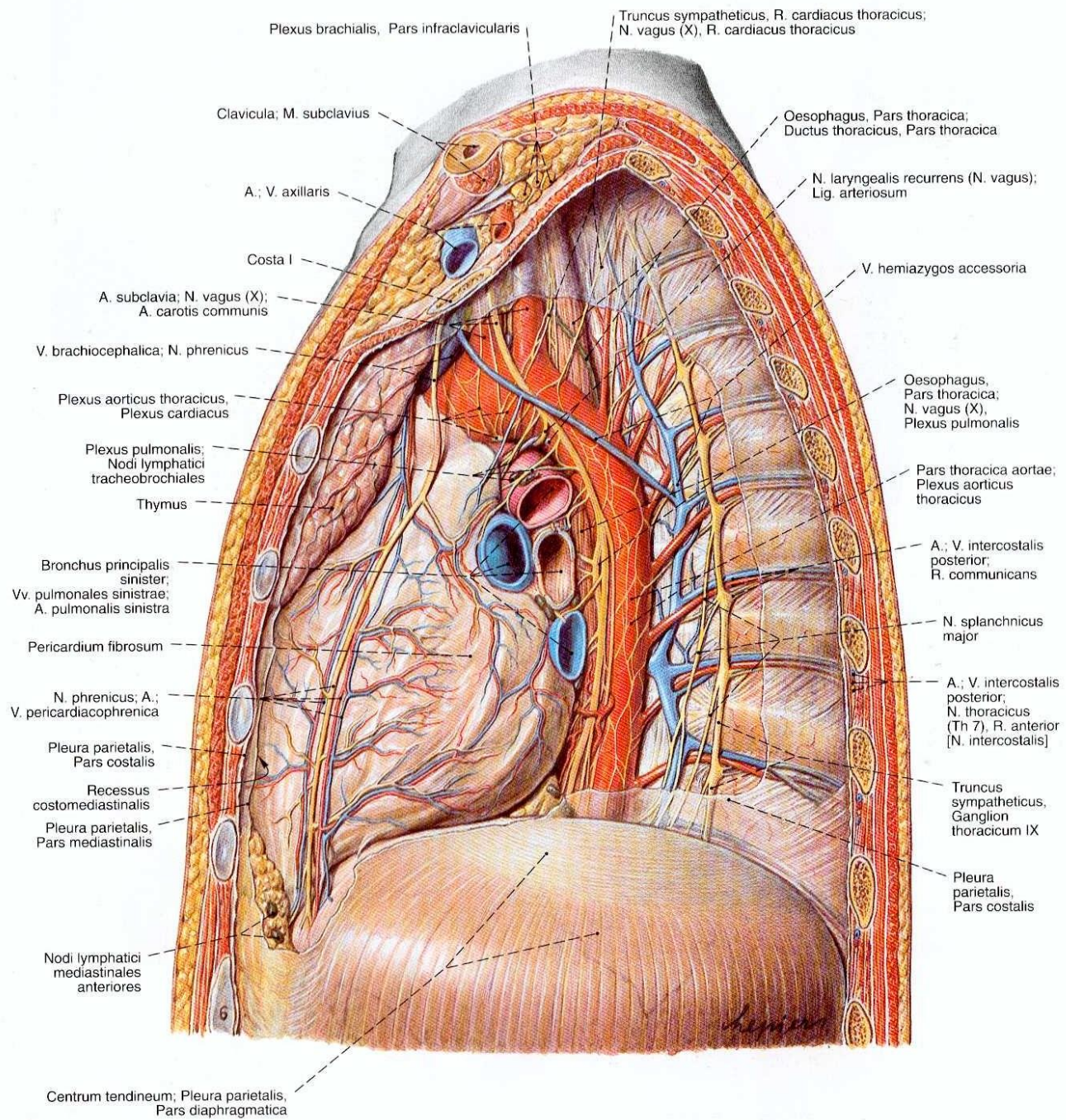


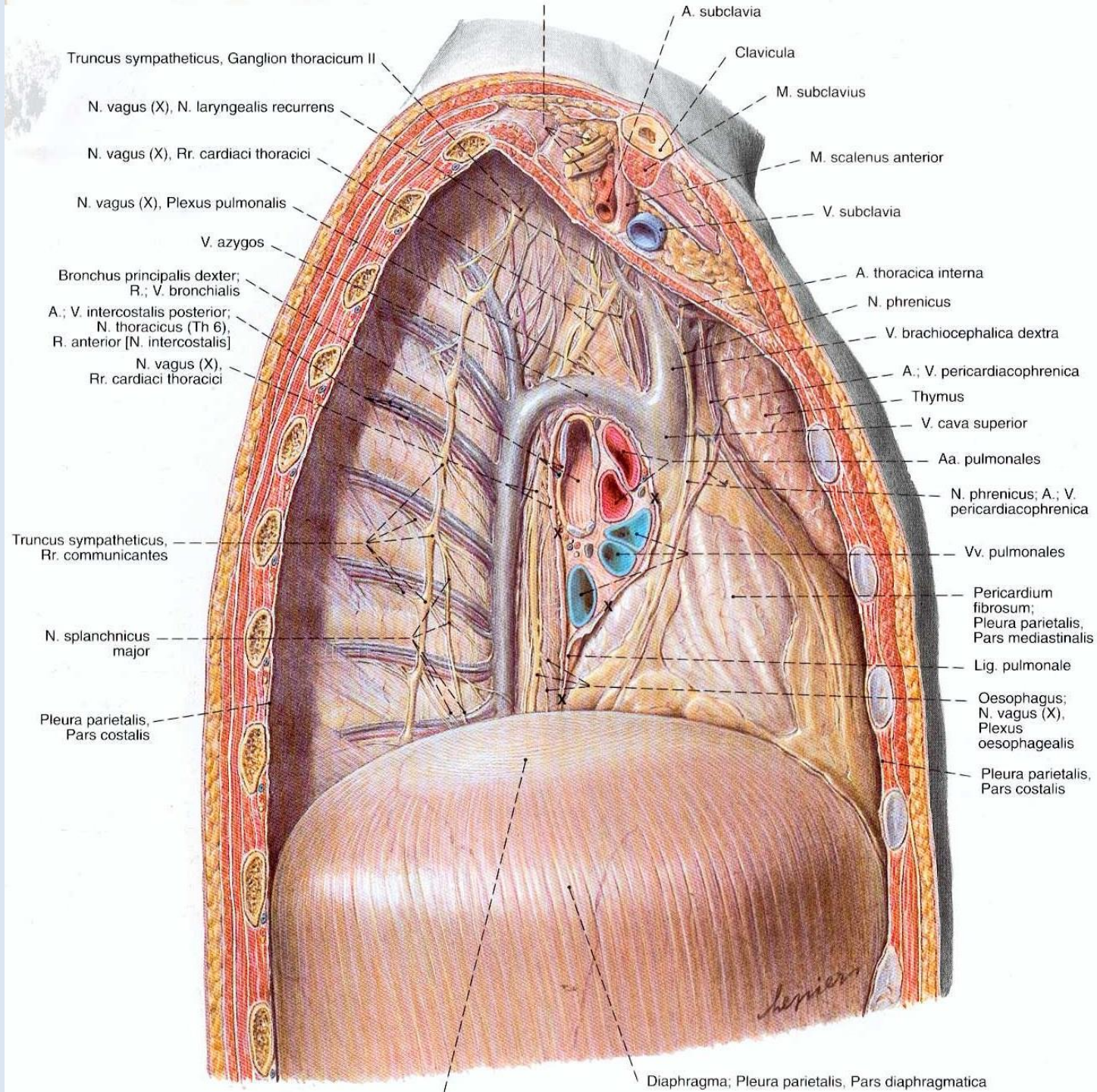


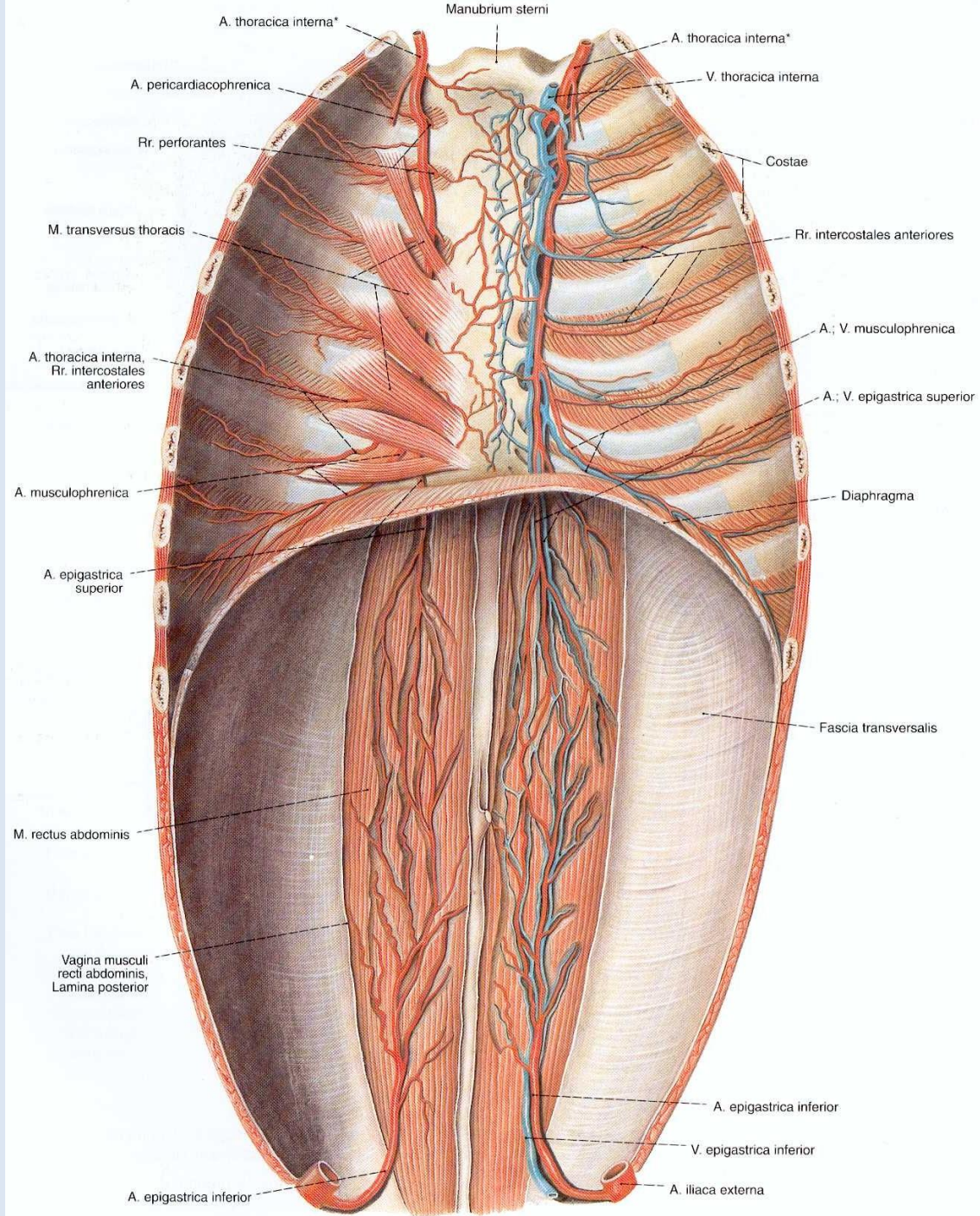


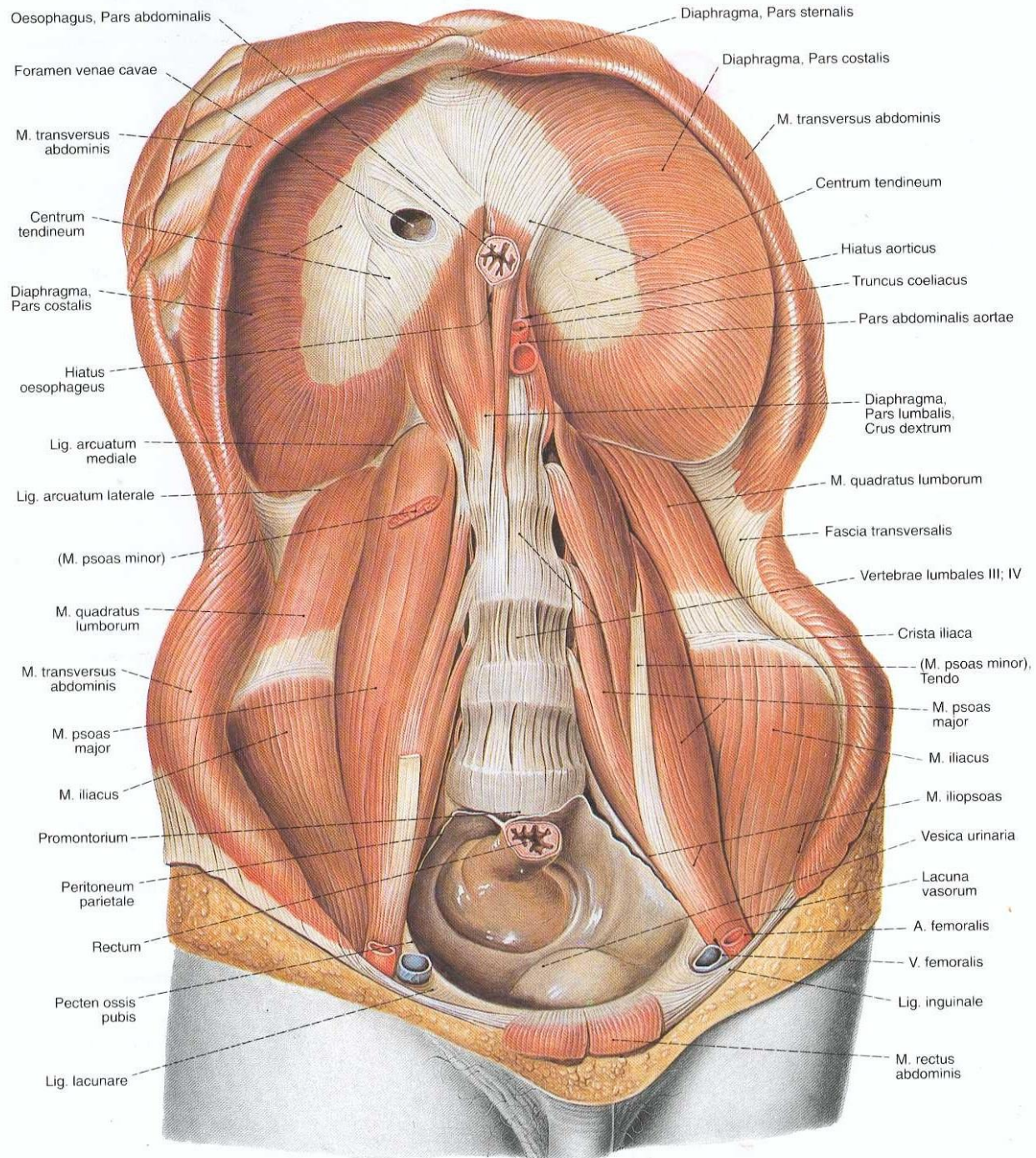


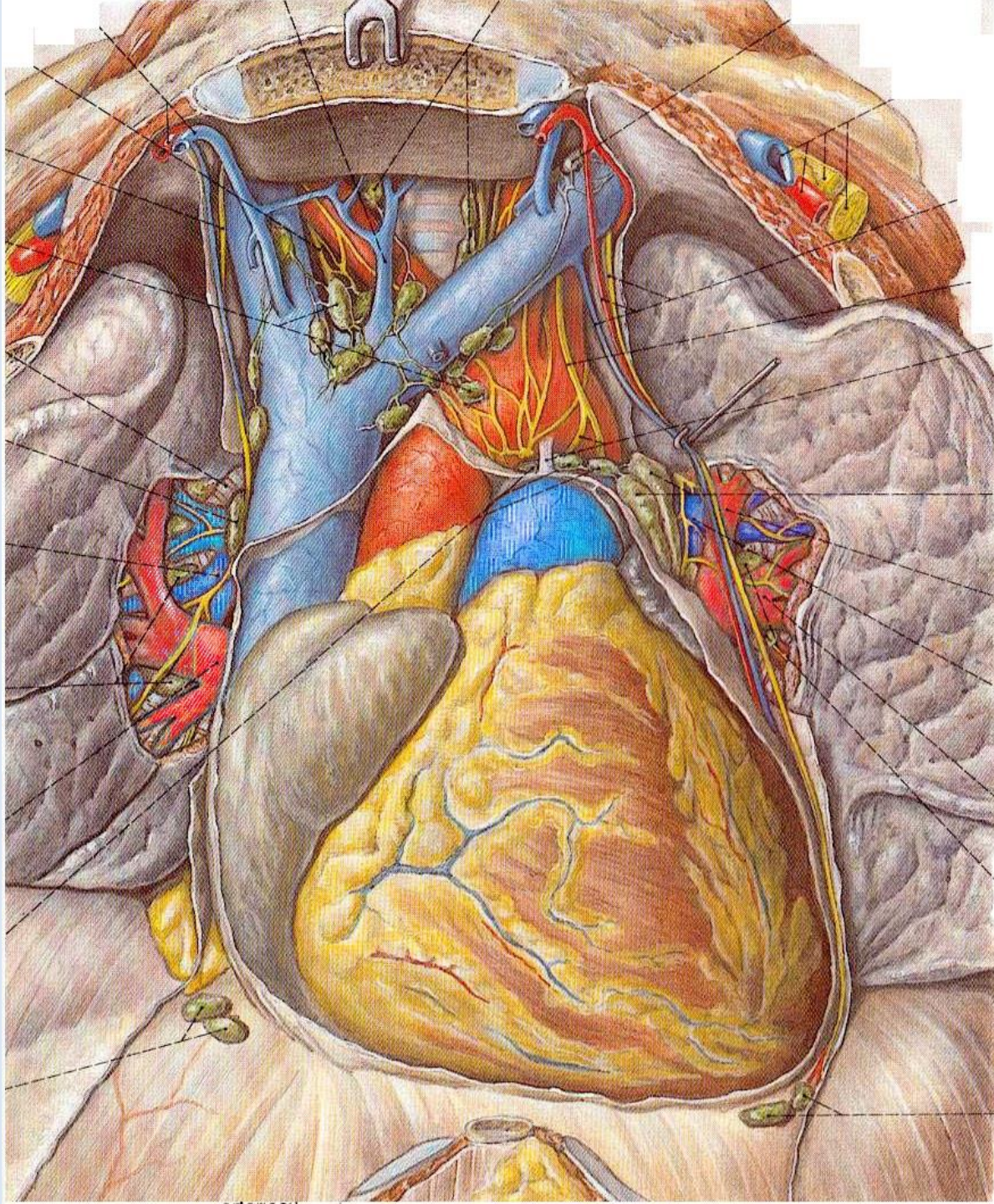


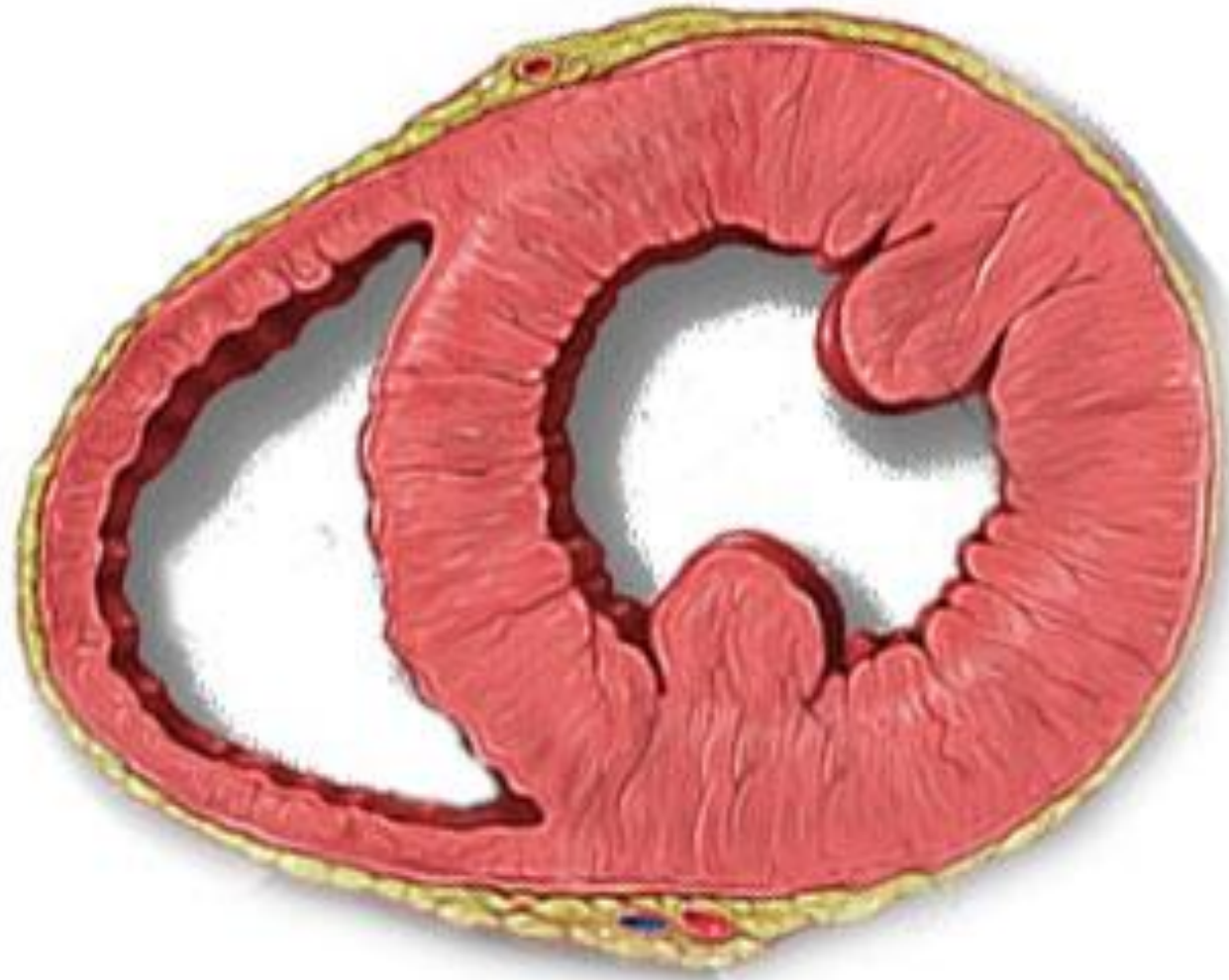

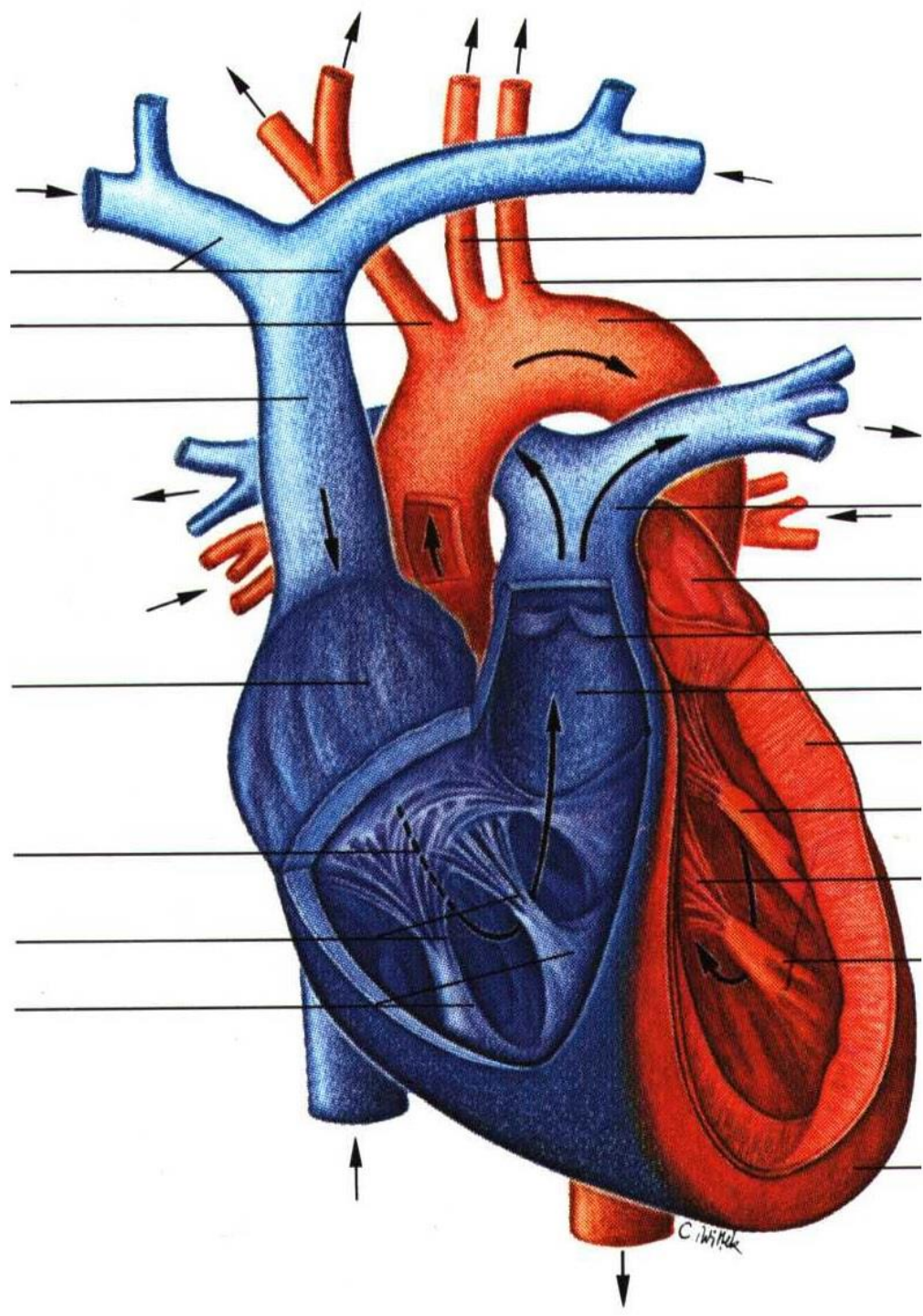


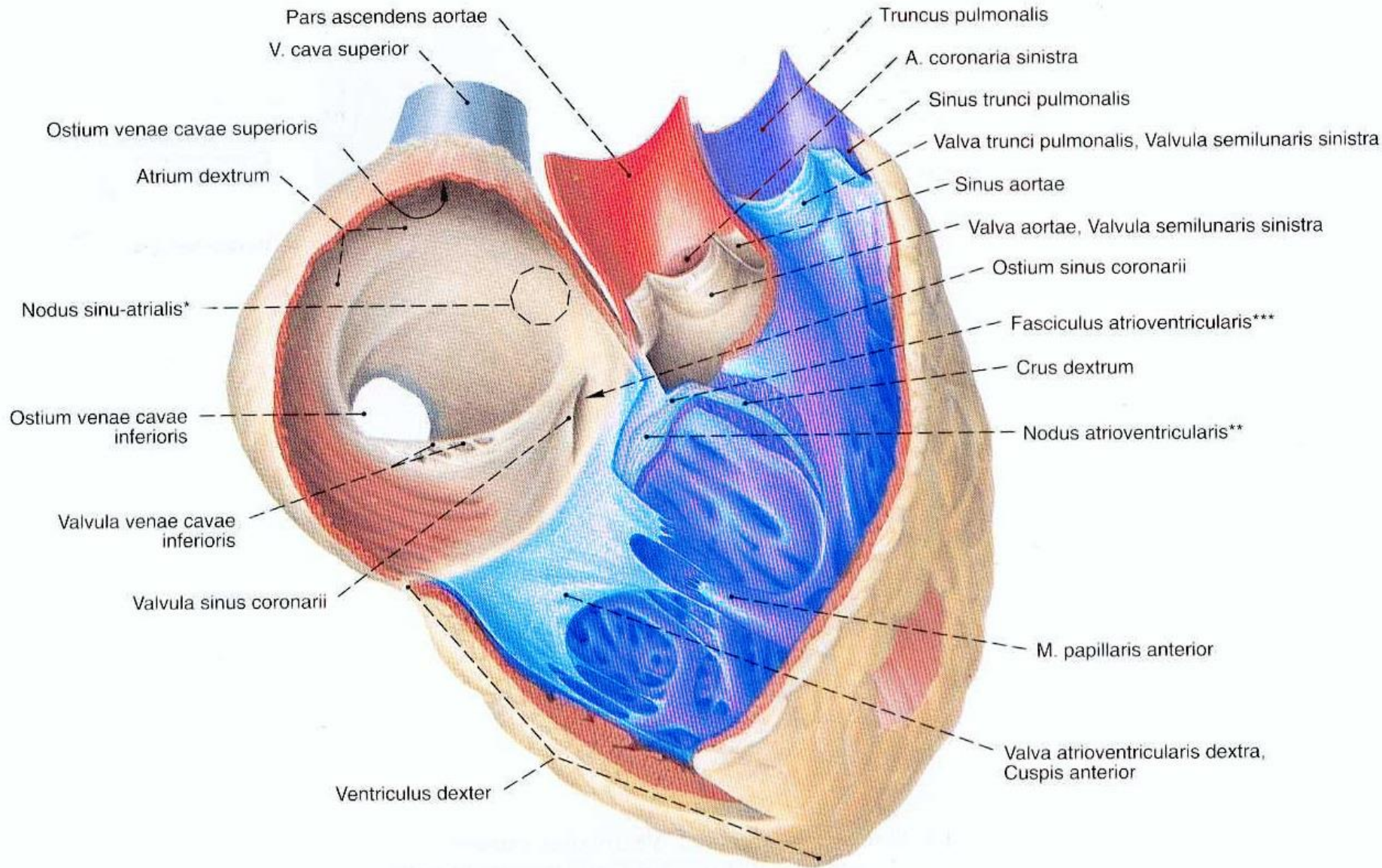






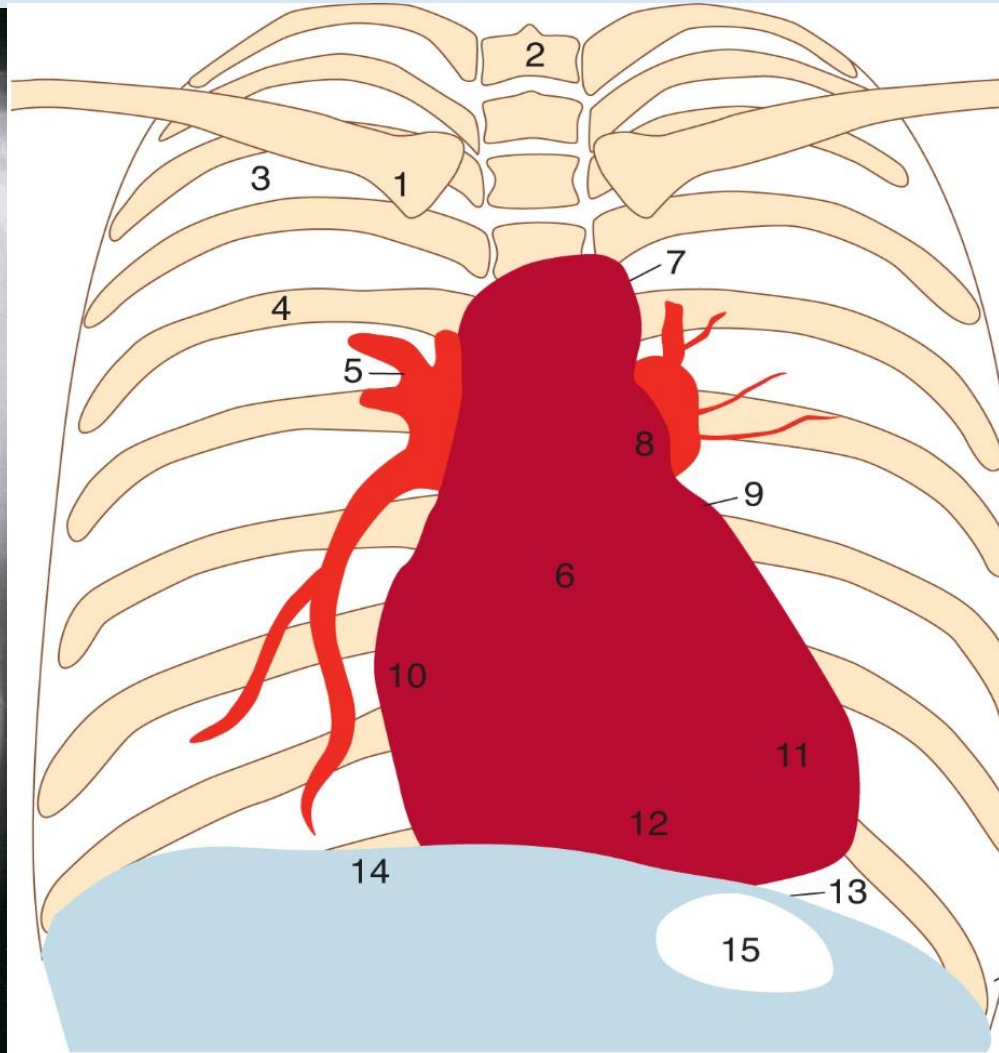
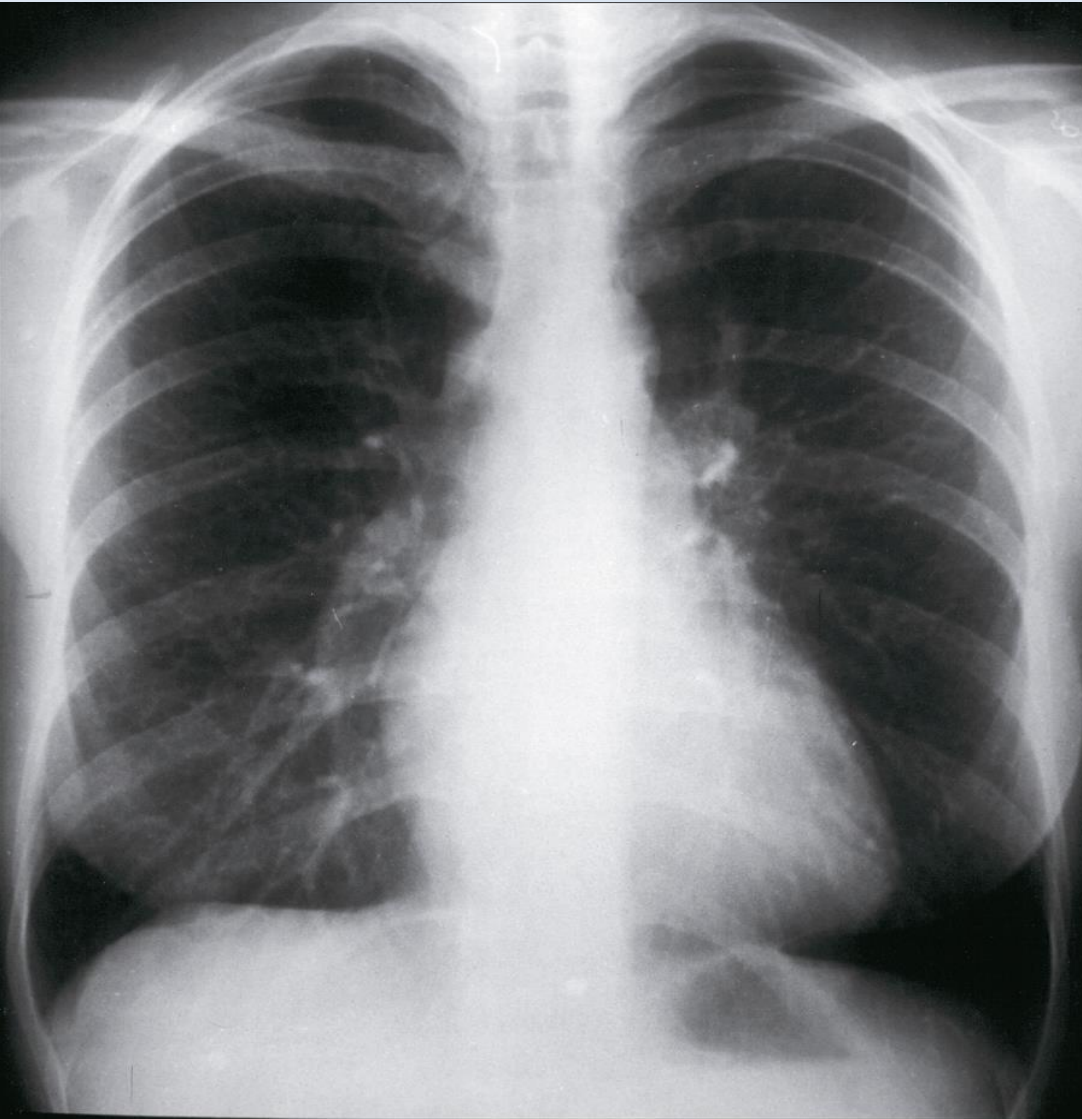




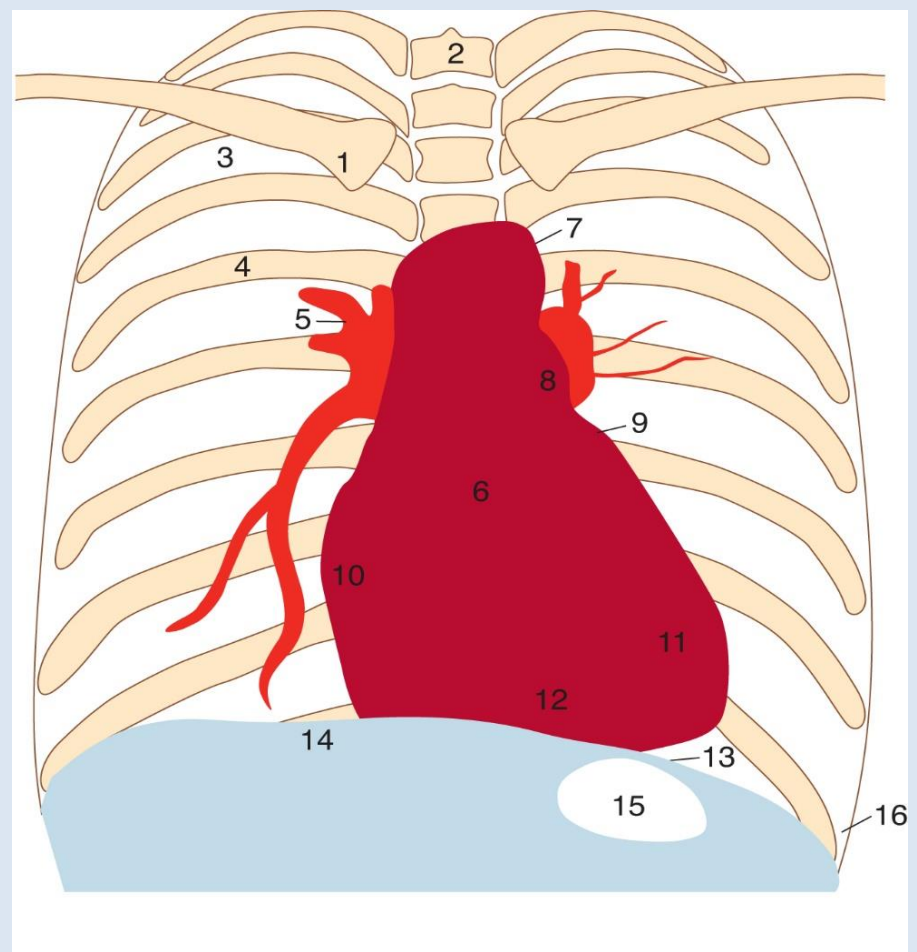
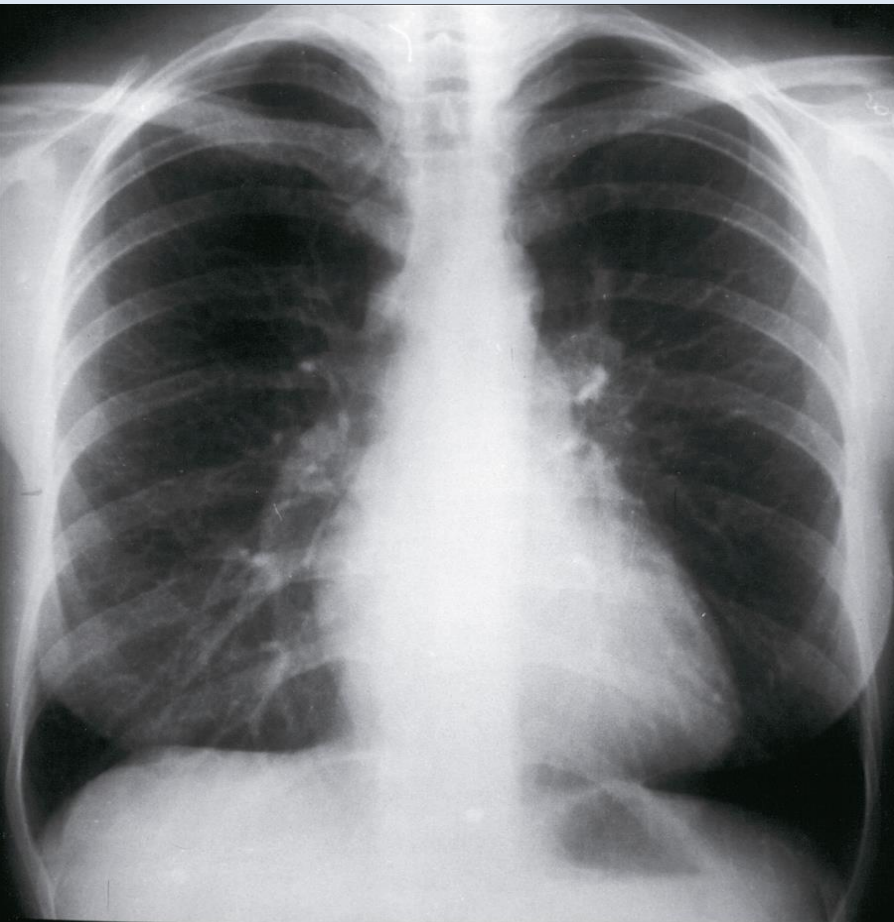


Röntgenbilder der Thorakalhöhle

Thorax, posteroant. aspect

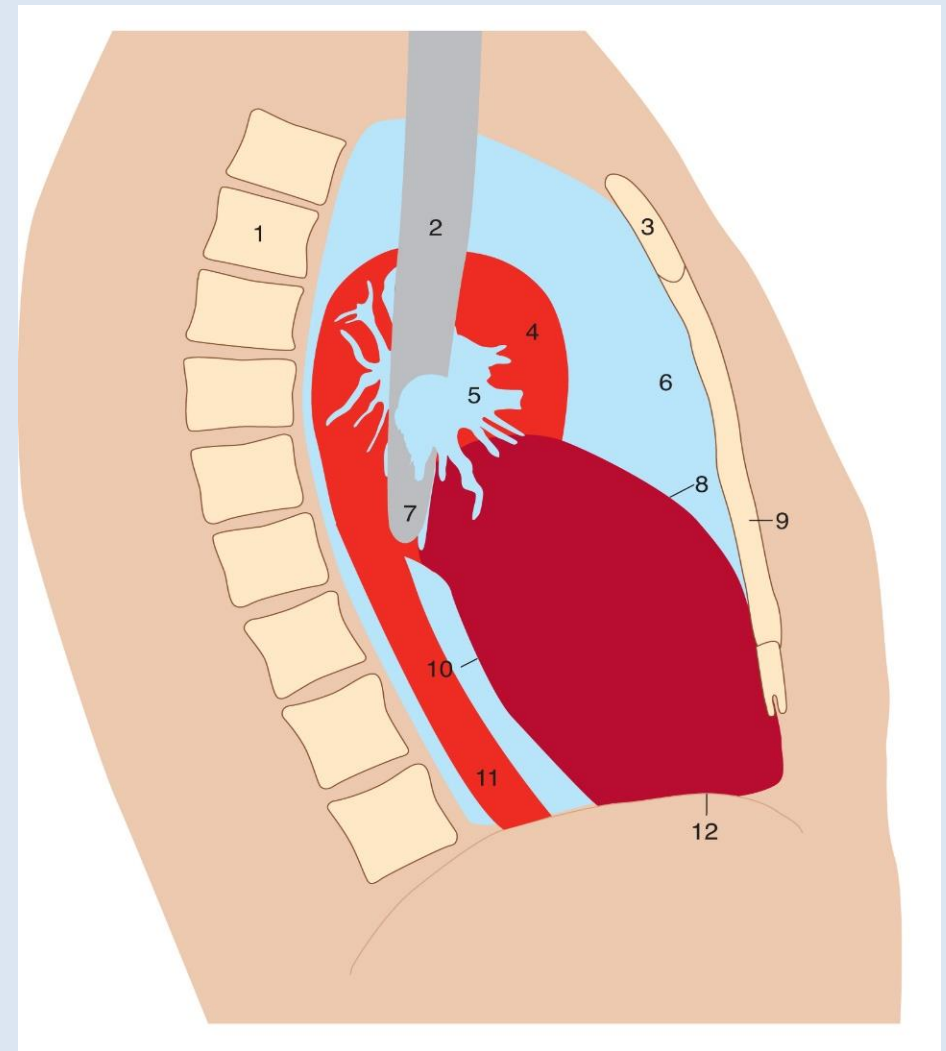
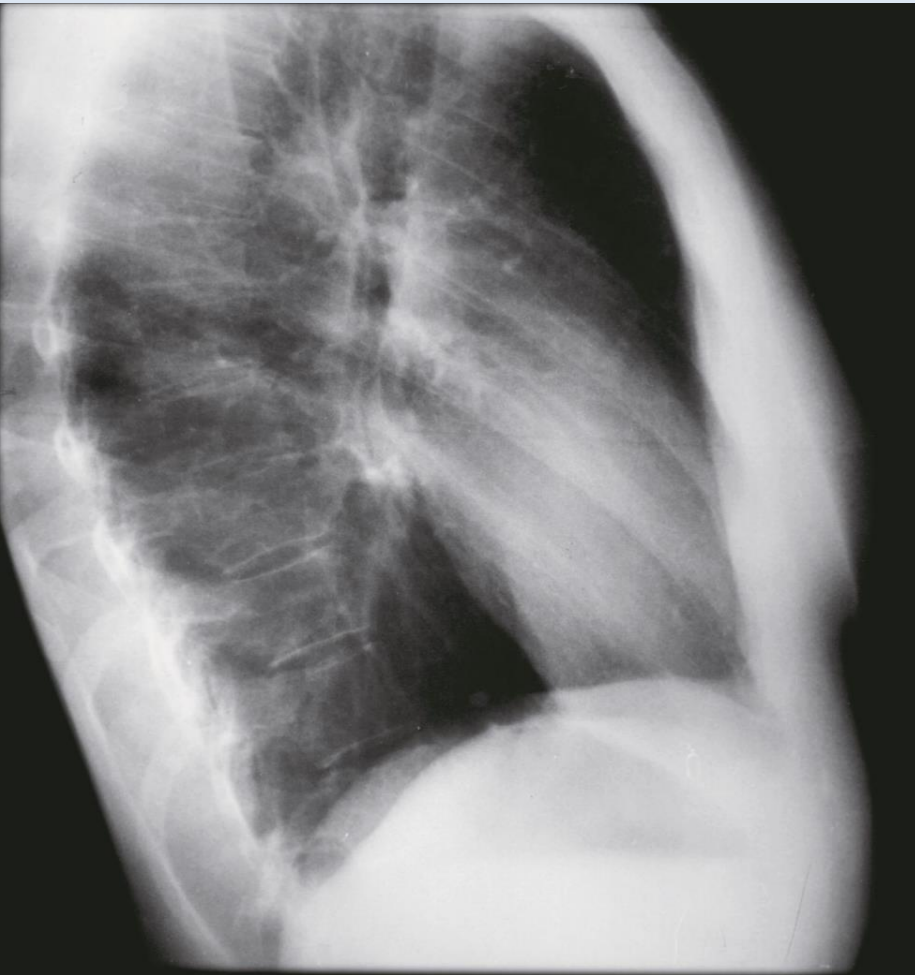

Thorax, posteroant. aspect

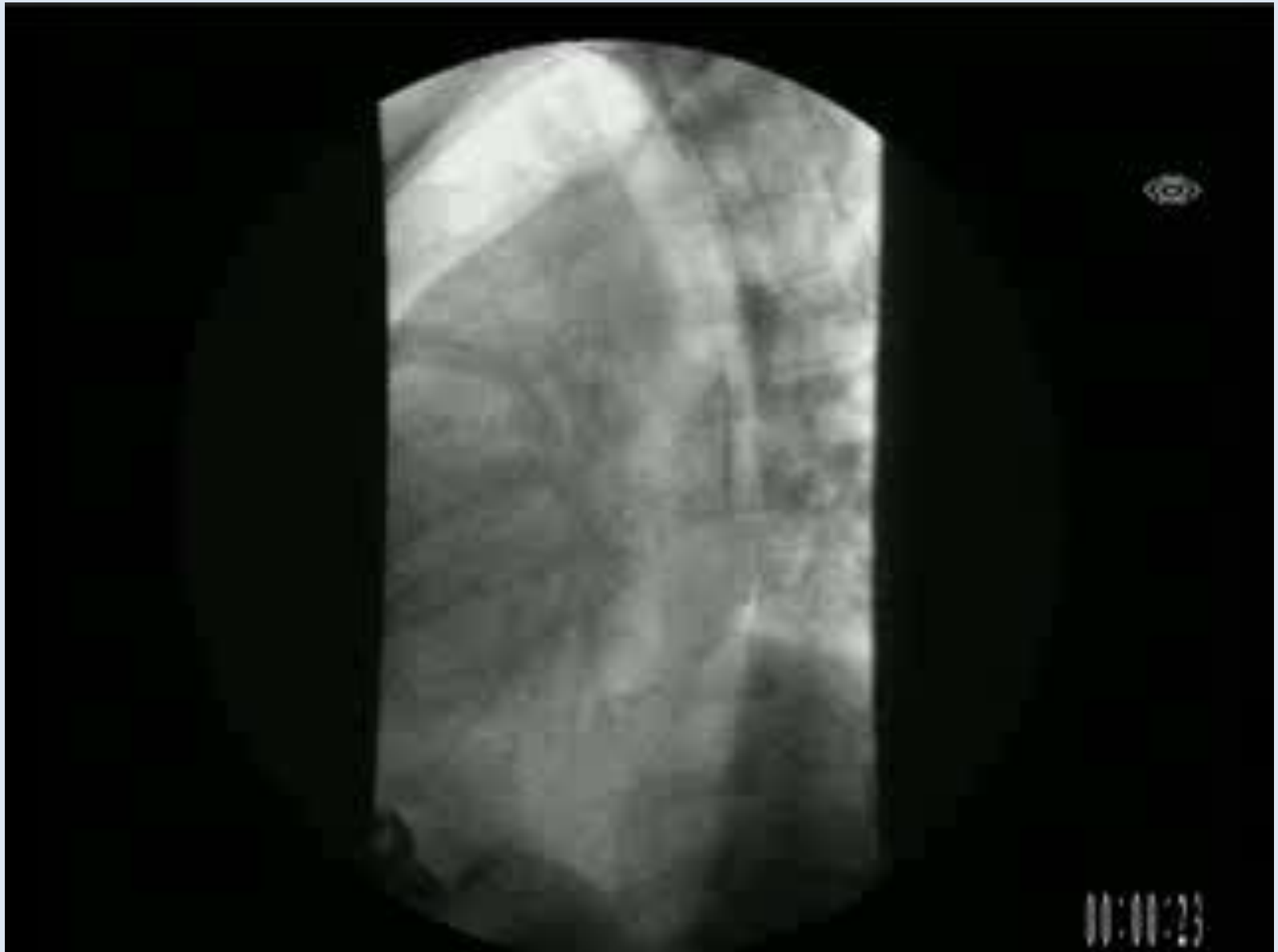


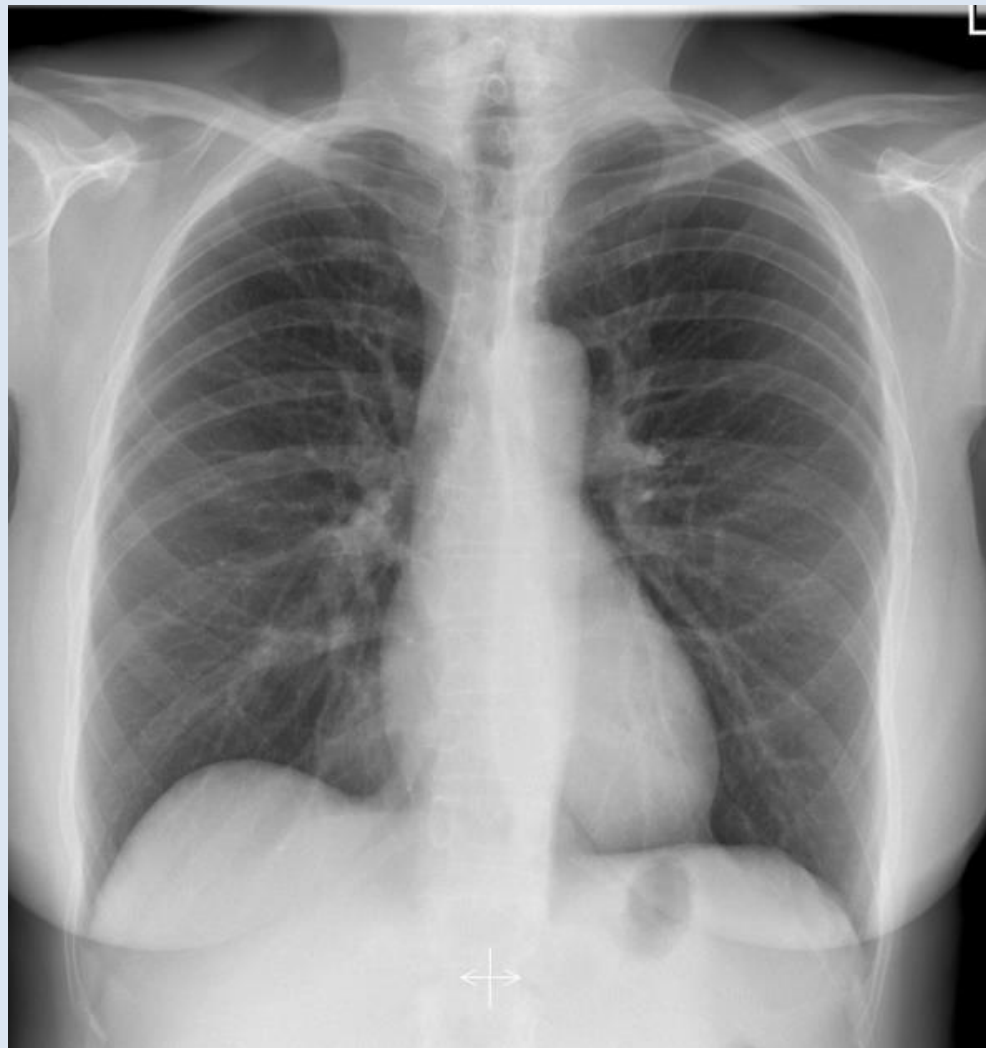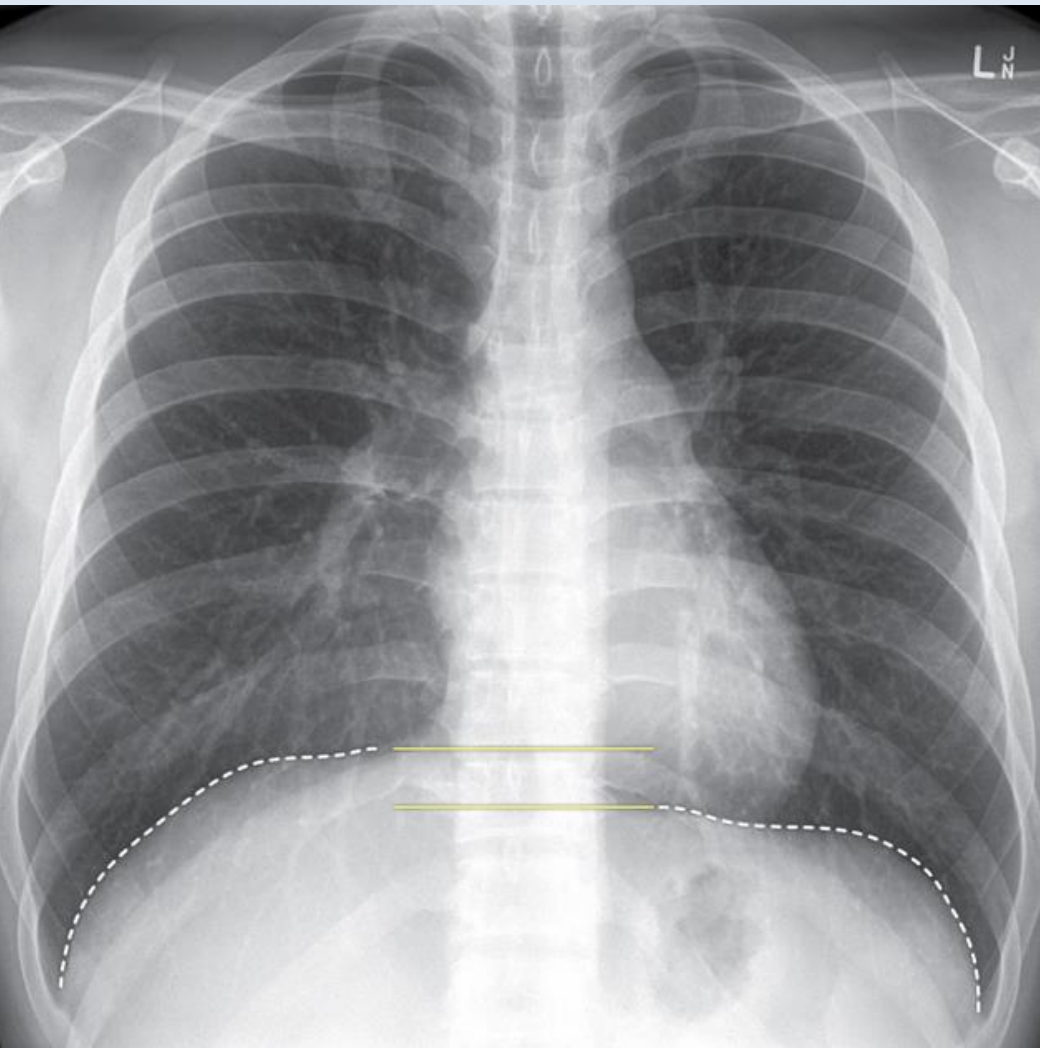
- | | |
|-------------------------|---|
| 1. Clavicula | 10. Atrium dextr. |
| 2. Columna vertebralis | 11. Venticulus sin. |
| 3. Spatium intercostale | 12. Venticulus dext. |
| 4. Costae | 13. Angulus cardiophrenicus sin. |
| 5. Hilus pulmonalis | 14. Diaphragma |
| 6. Atrium sinistrum | 15. Gyomorlégghólyag |
| 7. Aorta gomb | 16. Recessus costodiaphragmaticus
seu sinus phrenicocostalis |
| 8. Truncus pulmonalis | |
| 9. Auricula sin. | |

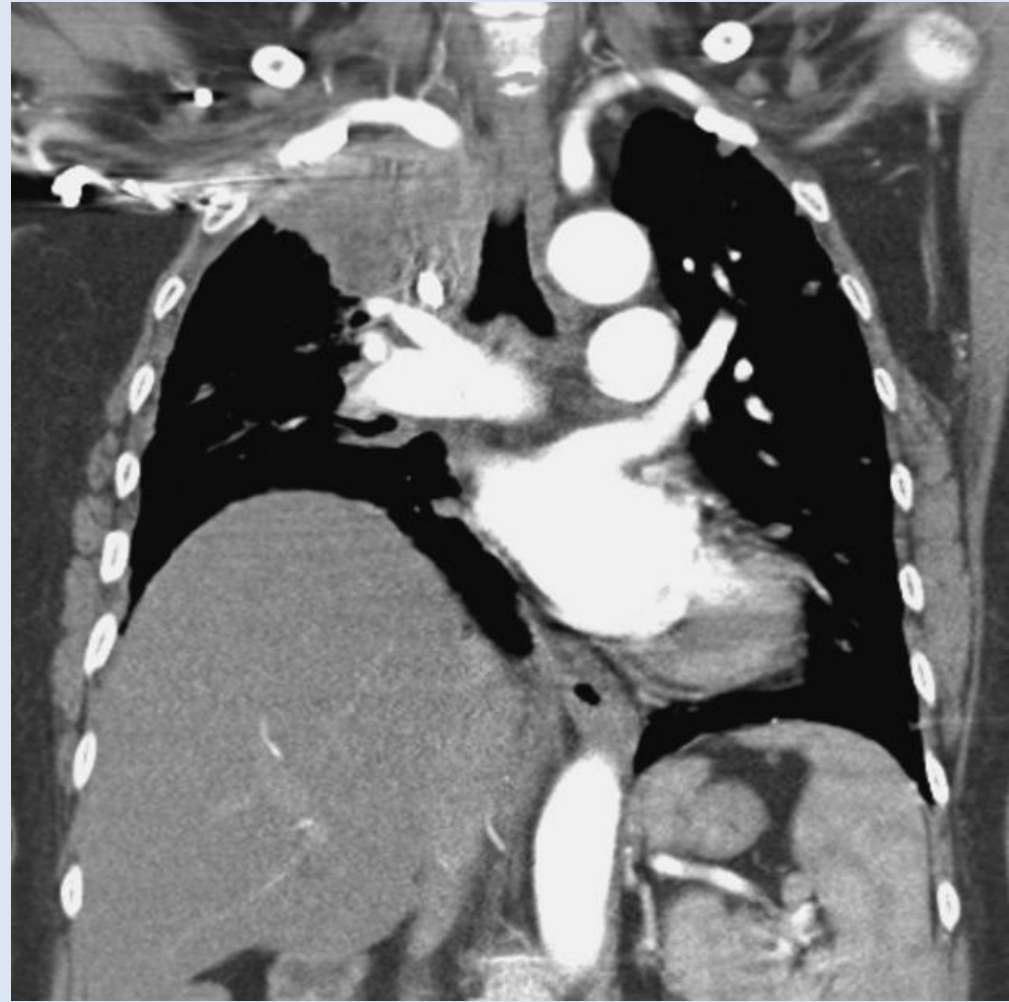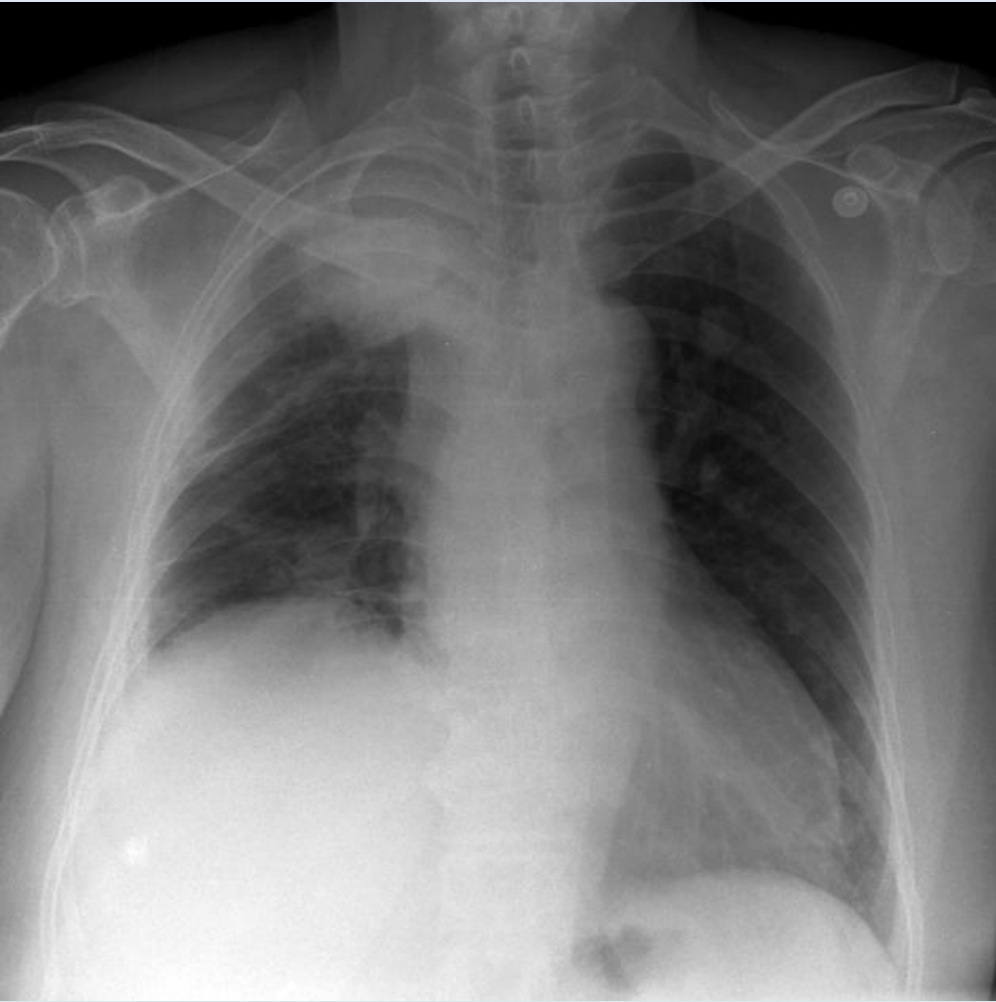
Thorax, lat. aspect

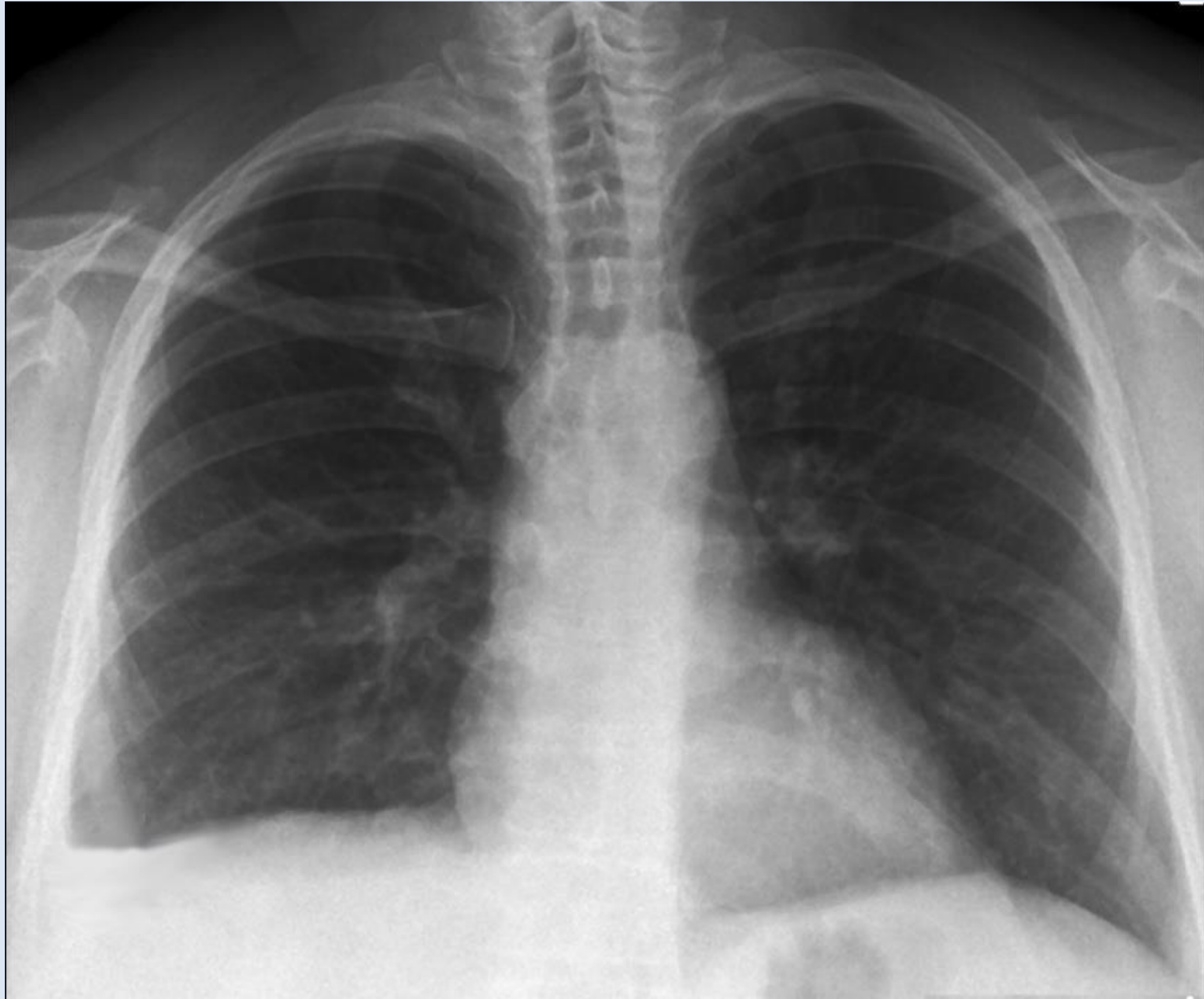


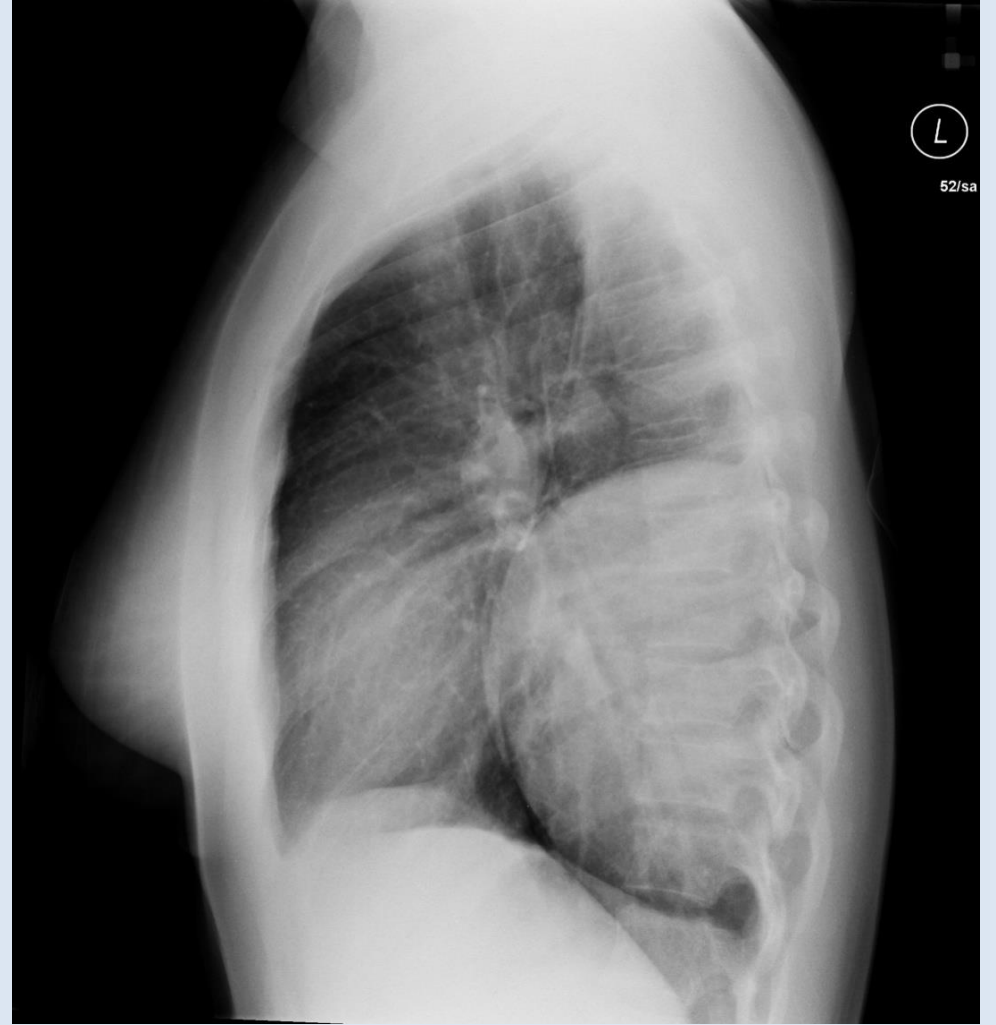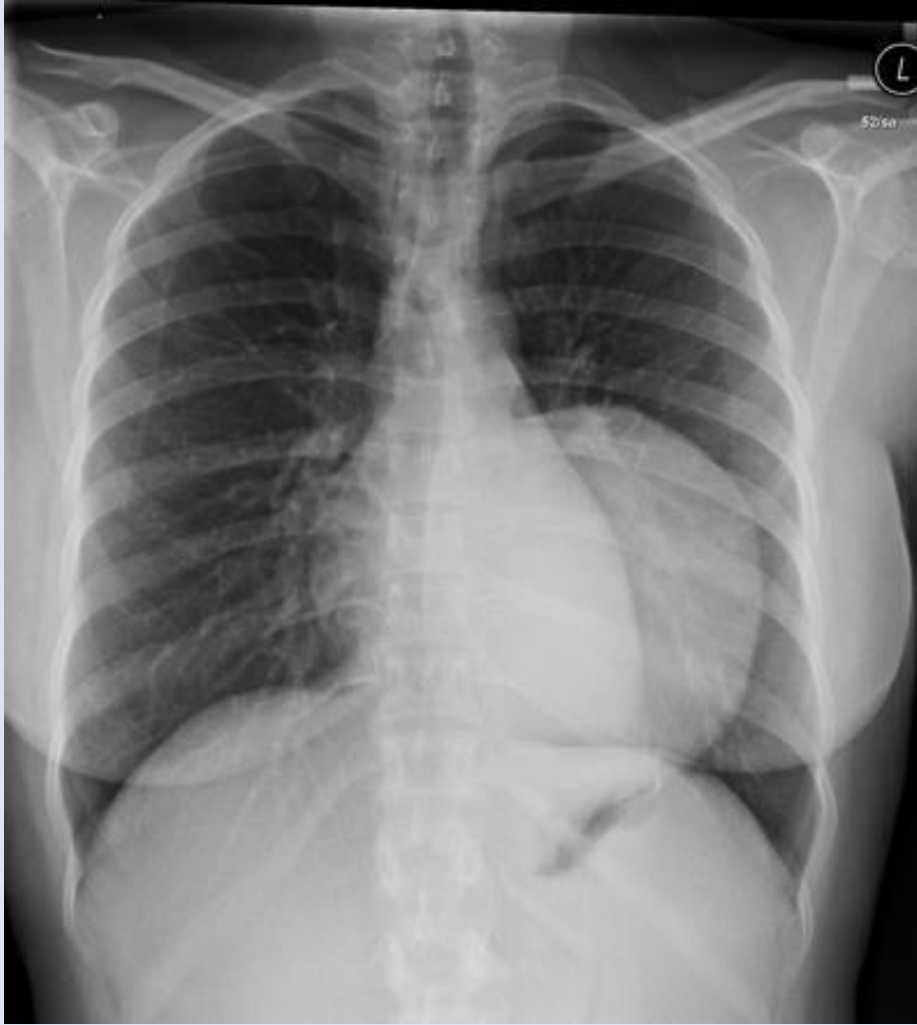
- | | | | |
|----|-----------------------|-----|----------------------------|
| 1. | Columna vertebralis | 8. | Atrium dextrum |
| 2. | Trachea | 9. | Corpus sterni |
| 3. | Manubrium sterni | 10. | Atrium sinistrum |
| 4. | Aorta ascendens | 11. | Aorta thoracica descendens |
| 5. | A. pulmonalis dext. | 12. | Diaphragma |
| 6. | Spatium retrosternale | | |
| 7. | Bronchus principalis | | |





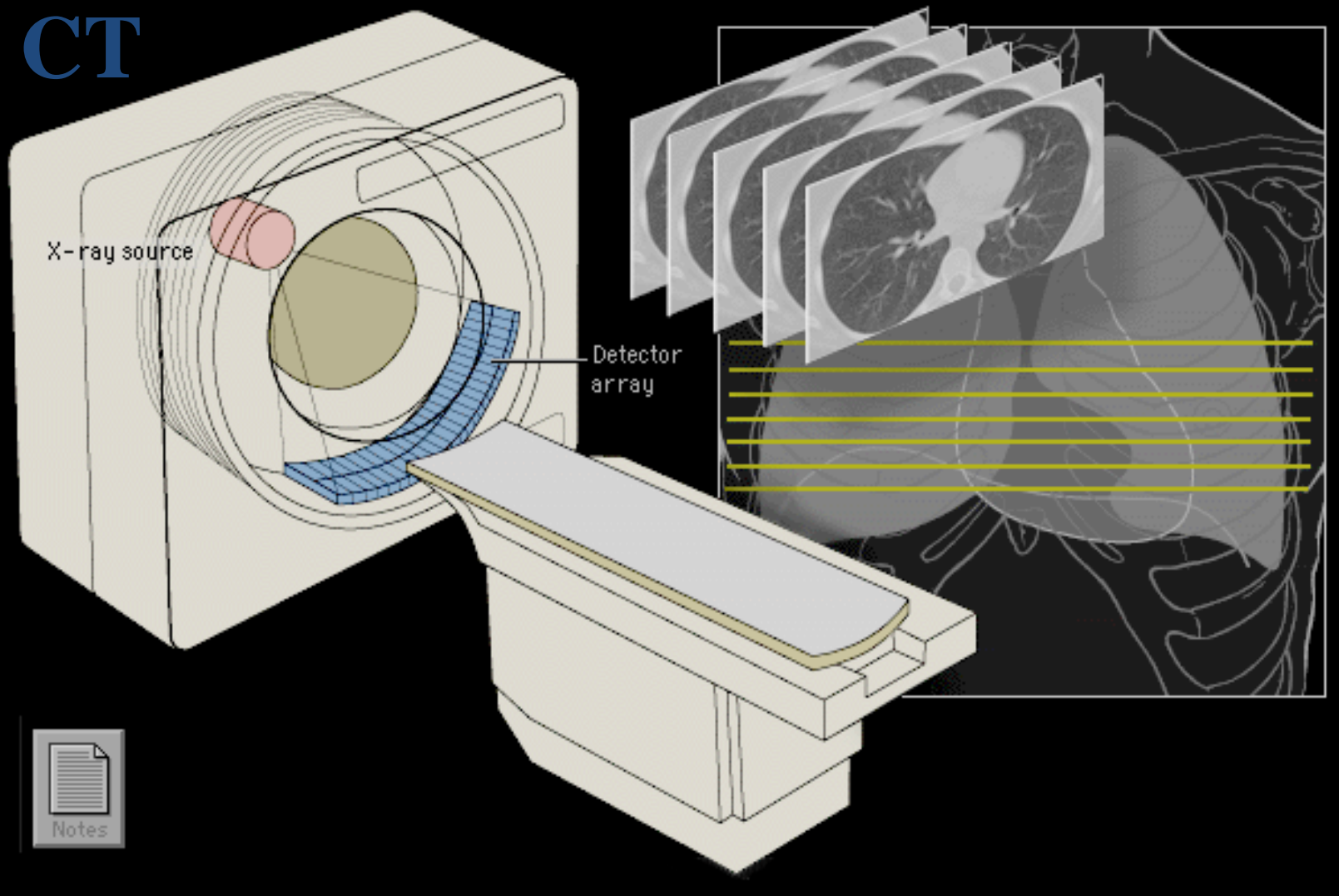


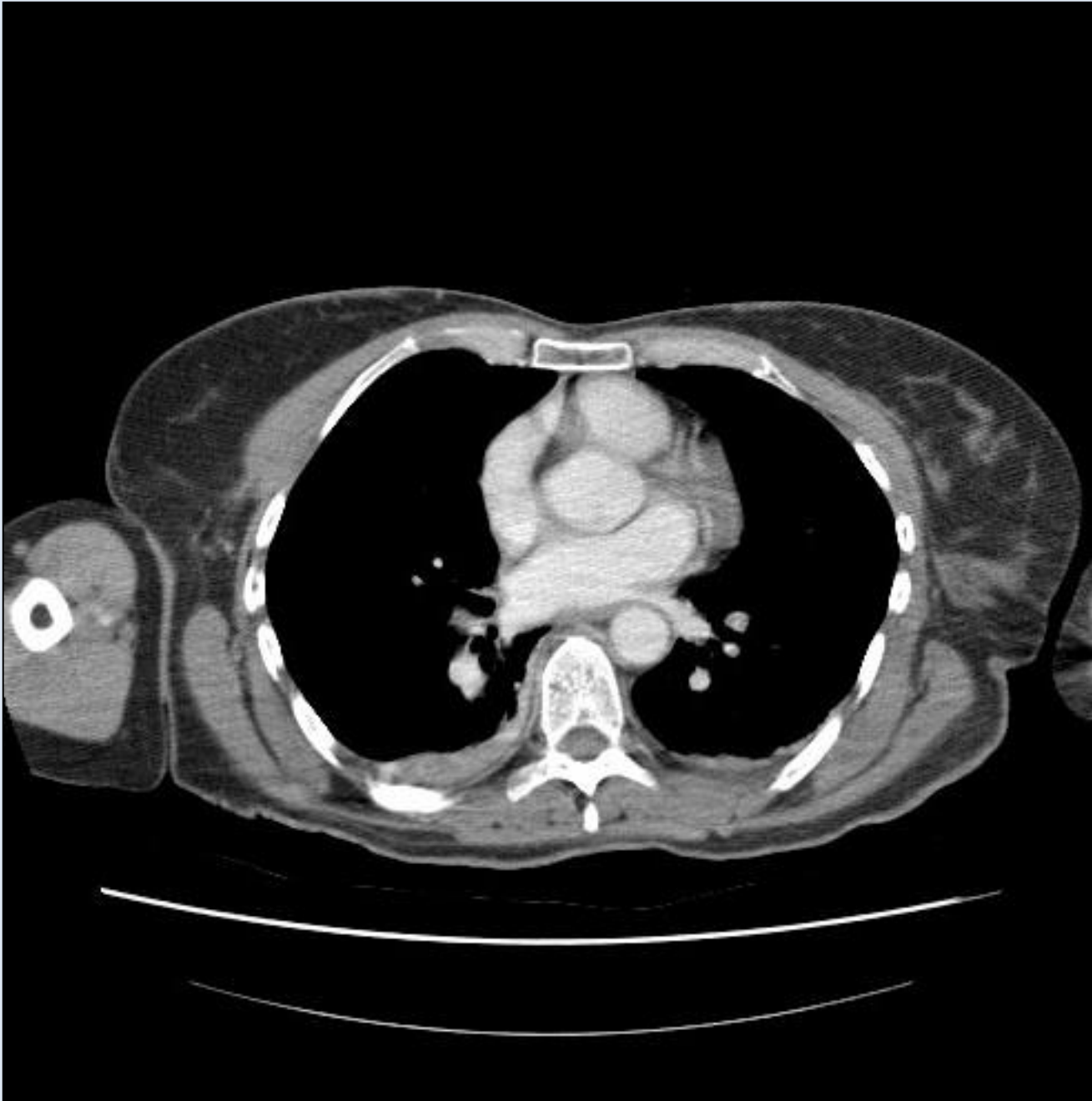


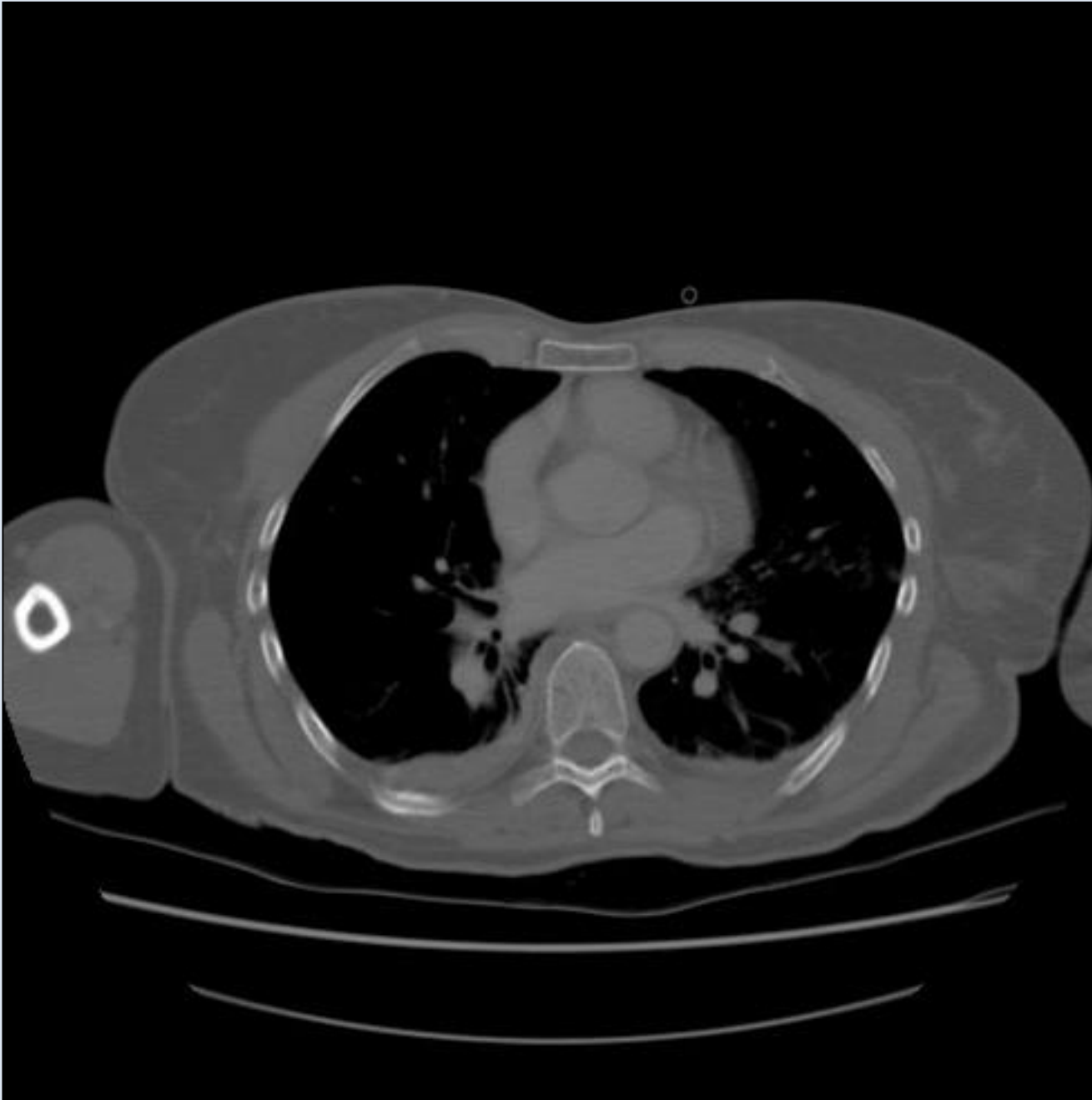
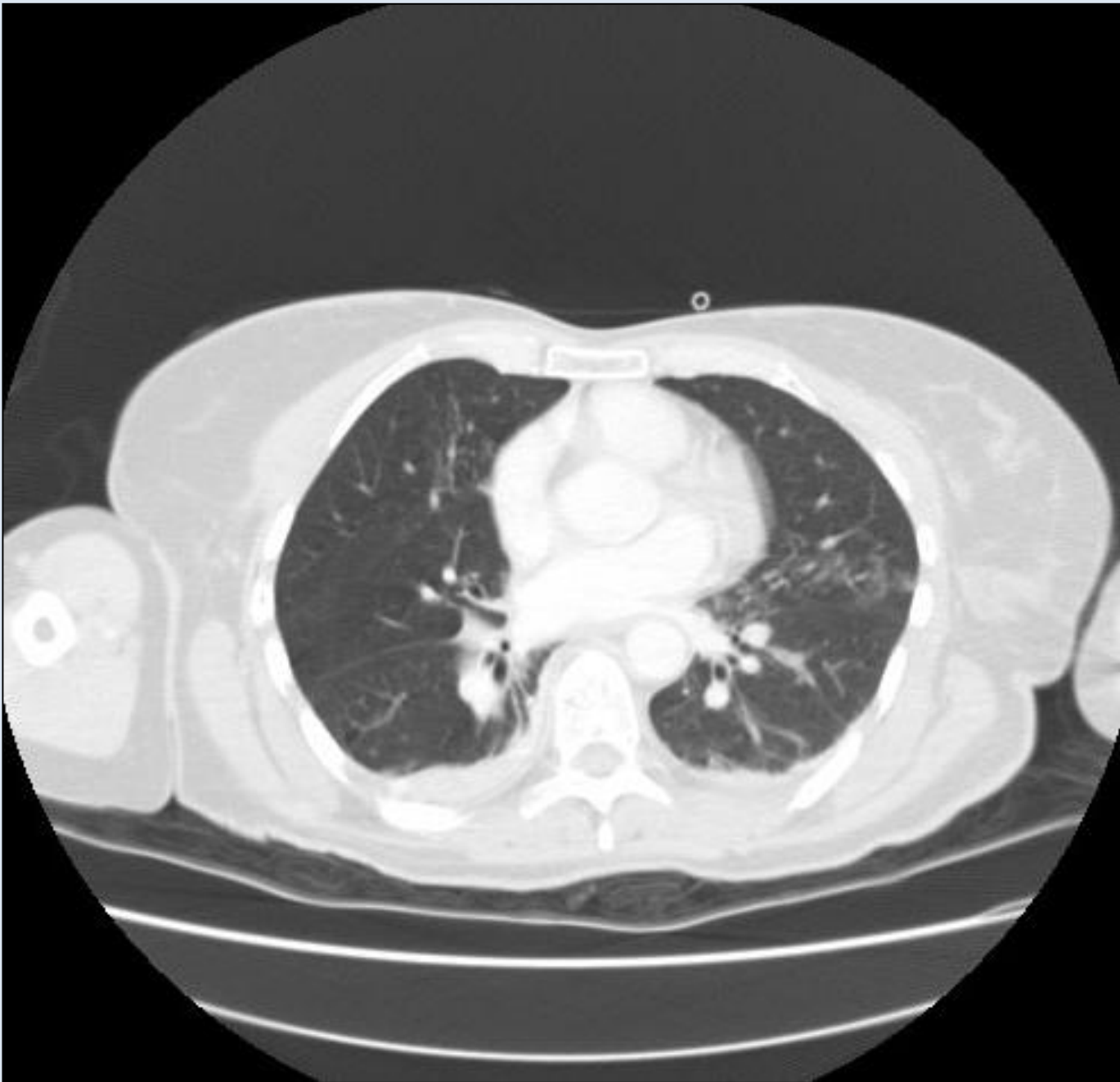
CT-Bilder der Thorakalhöhle

CT

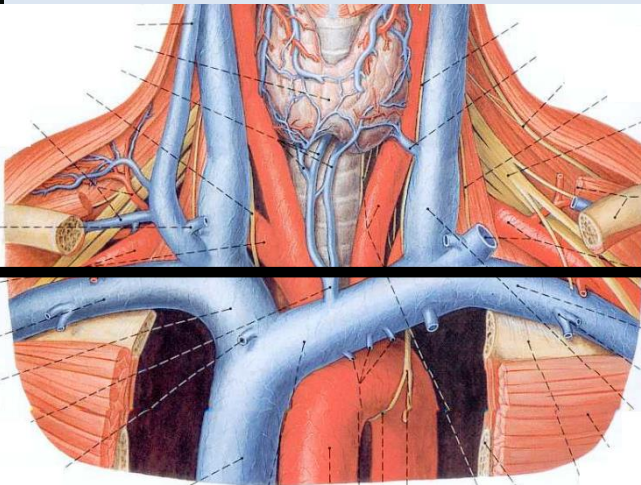
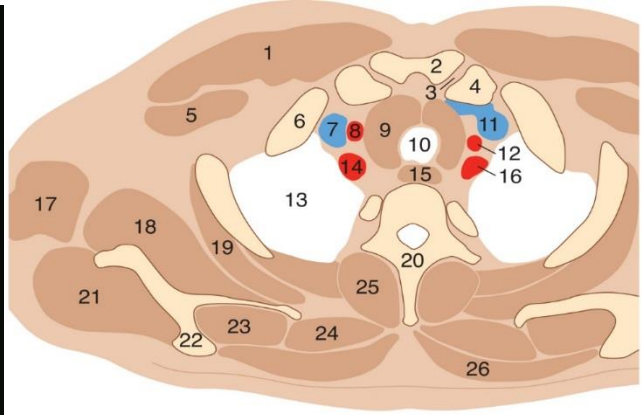
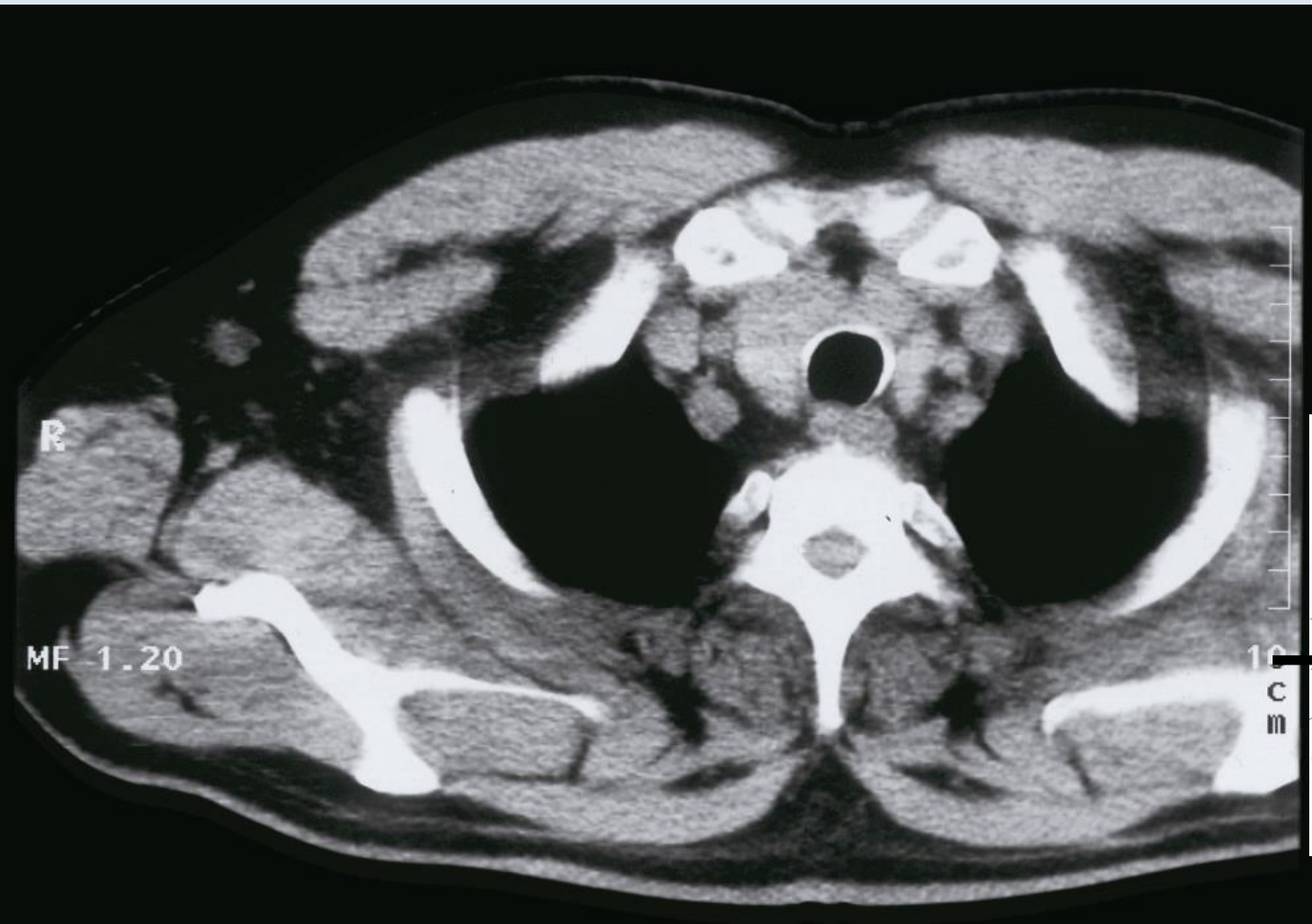

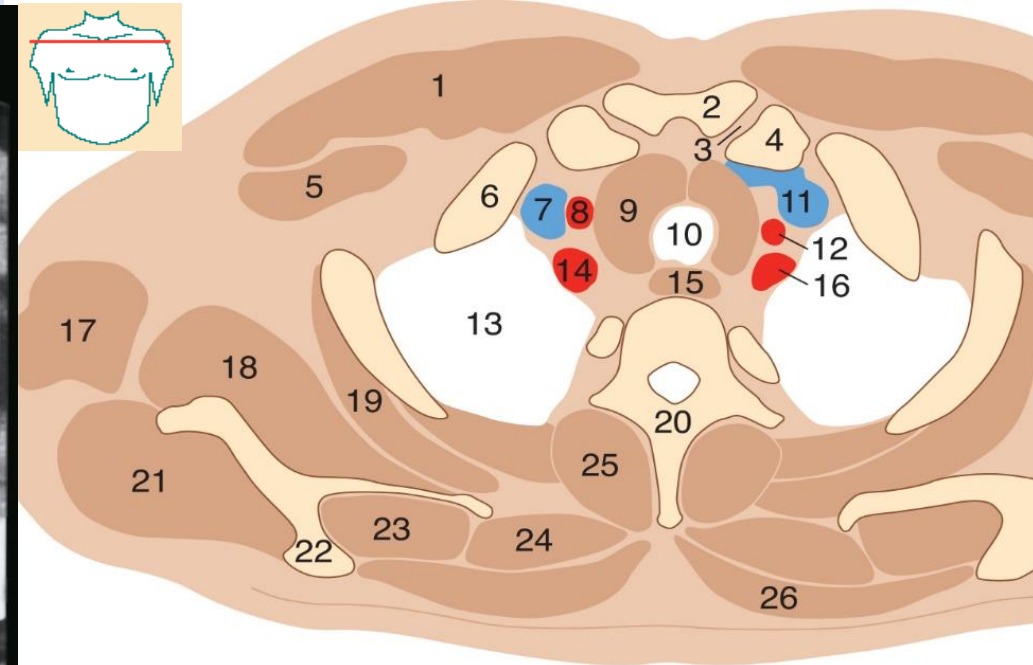
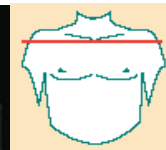

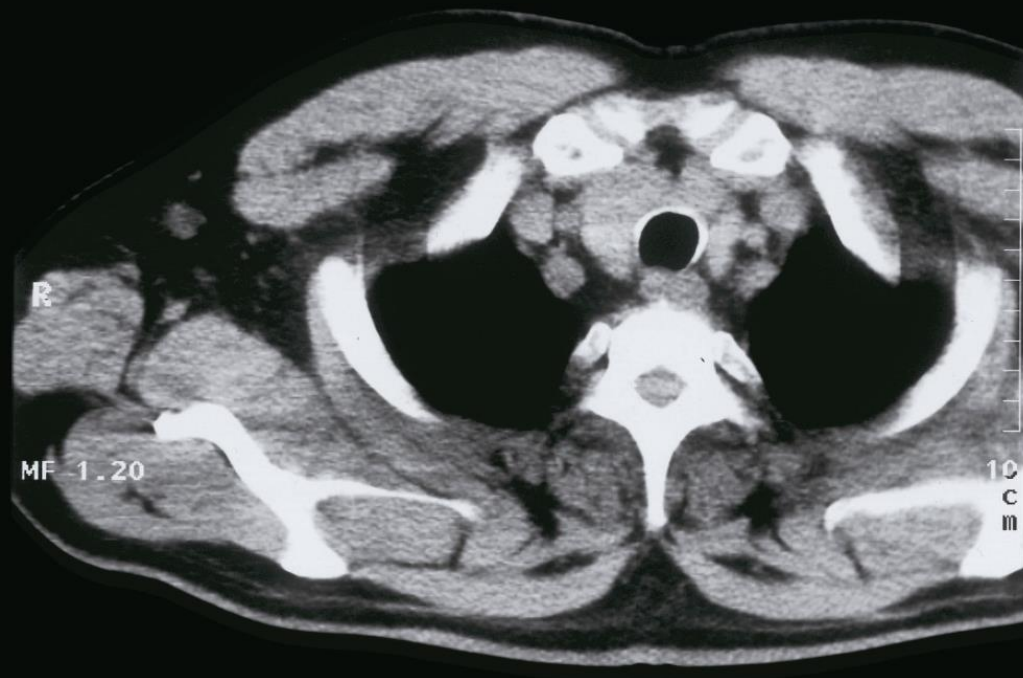


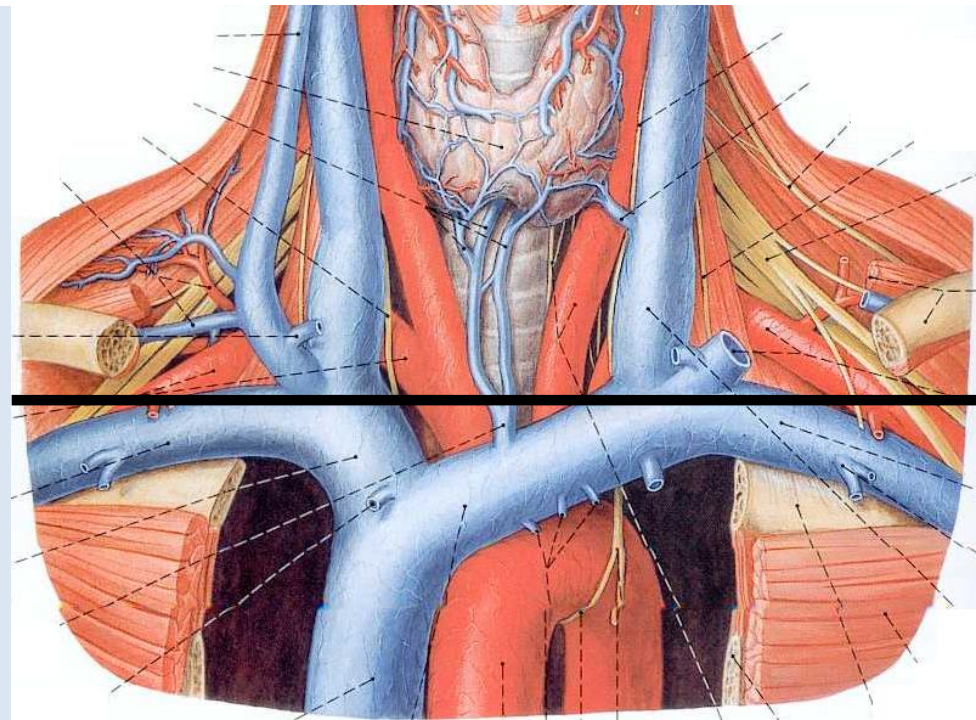


1600/-600

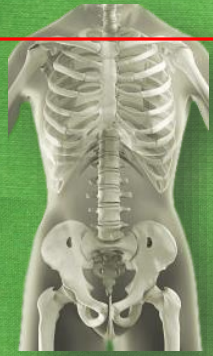



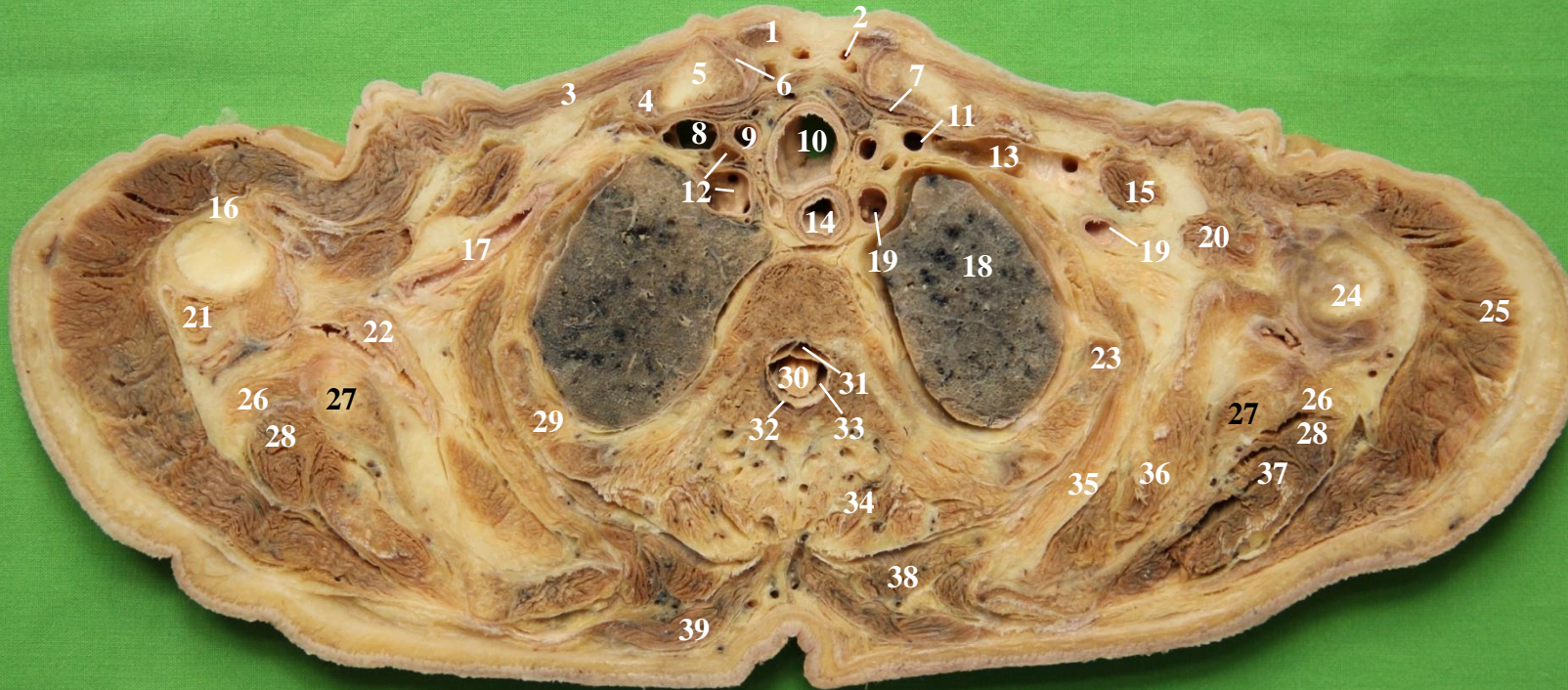
- | | |
|--|-------------------------|
| 1. M. pectoralis major | 15. Oesophagus |
| 2. Sternum | 16. A. subclavia sin. |
| 3. A. sternoclavicularis | 17. M. latissimus dorsi |
| 4. Clavicula | 18. M. subscapularis |
| 5. M. pectoralis minor | 19. M. serratus ant. |
| 6. Costa I | 20. Vertebra thoracica |
| 7. V. brachiocephalica dext./V. jugularis int. | 21. M. infraspinatus |
| 8. A. carotis communis dext. | 22. Spina scapulae |
| 9. Gl. thyroidea (retrosternalisan kiterjedt) | 23. M. supraspinatus |
| 10. Trachea | 24. Mm. rhomboidei |
| 11. V. brachiocephalica sin. | 25. M. erector spinae |
| 12. A. carotis communis sin. | 26. M. trapezius |
| 13. Pulmo | |
| 14. A. subclavia dext. | |



Th2

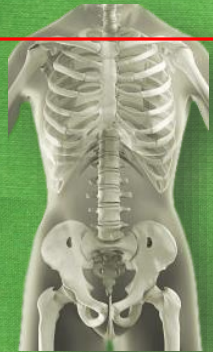

Semmelweis Egyetem
Anatómiai, Szövet- és Fejlődéstani
Intézet

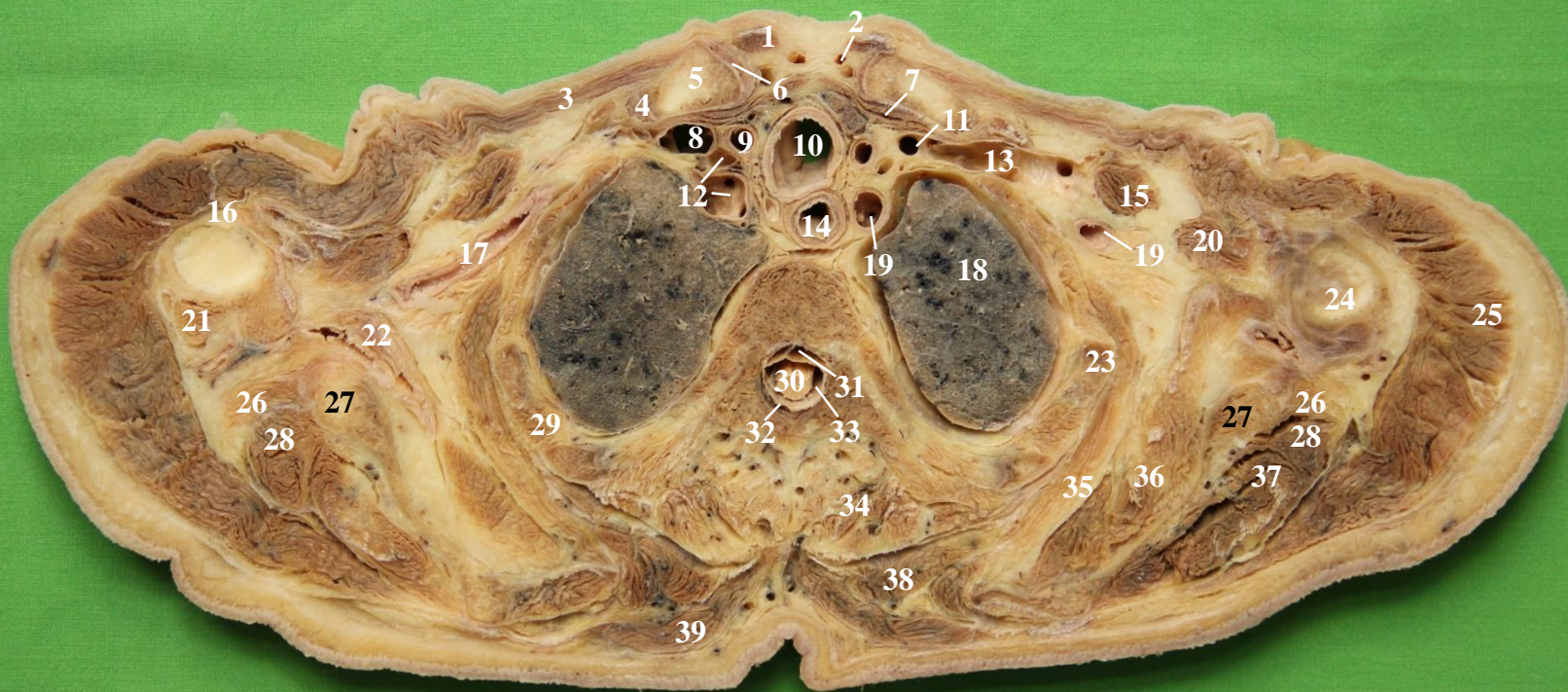


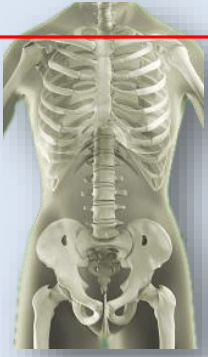1. m. sternocleidomastoideus pars sternalis
2. v. jugularis anterior
3. m. pectoralis major
4. m. subclavius
5. clavicula
6. art. sternoclavicularis
7. mm. infrahyoidei
8. v. brachiocephalica dextra
9. a. carotis communis dextra
10. trachea
11. v. jugularis interna
12. a.v. subclavia dextra
13. v. subclavia sinistra
14. oesophagus
15. m. pectineus minor
16. m. biceps brachii, caput longum in a
17. a. subclavia dextra
18. pulmo sinister, lobus superior
19. a. subclavia sinistra
20. m. biceps brachii, caput berve
21. m. triceps brachii, caput laterale
22. m. subscapularis in a
23. costa
24. humerus
25. m. deltoideus
26. m. triceps brachii, caput longum
27. scapula
28. m. teres minor
29. mm. intercostalis
30. medulla spinalis
31. spatium epidurale
32. durazsák
33. spatium subdurale
34. m. erector spinae
35. m. serratus anterior
36. m. subscapularis
37. m. infraspinatus
38. m. rhomboideus
39. m. trapezius

Th2



Semmelweis Egyetem
Anatómiai, Szövet- és Fejlődéstani
Intézet

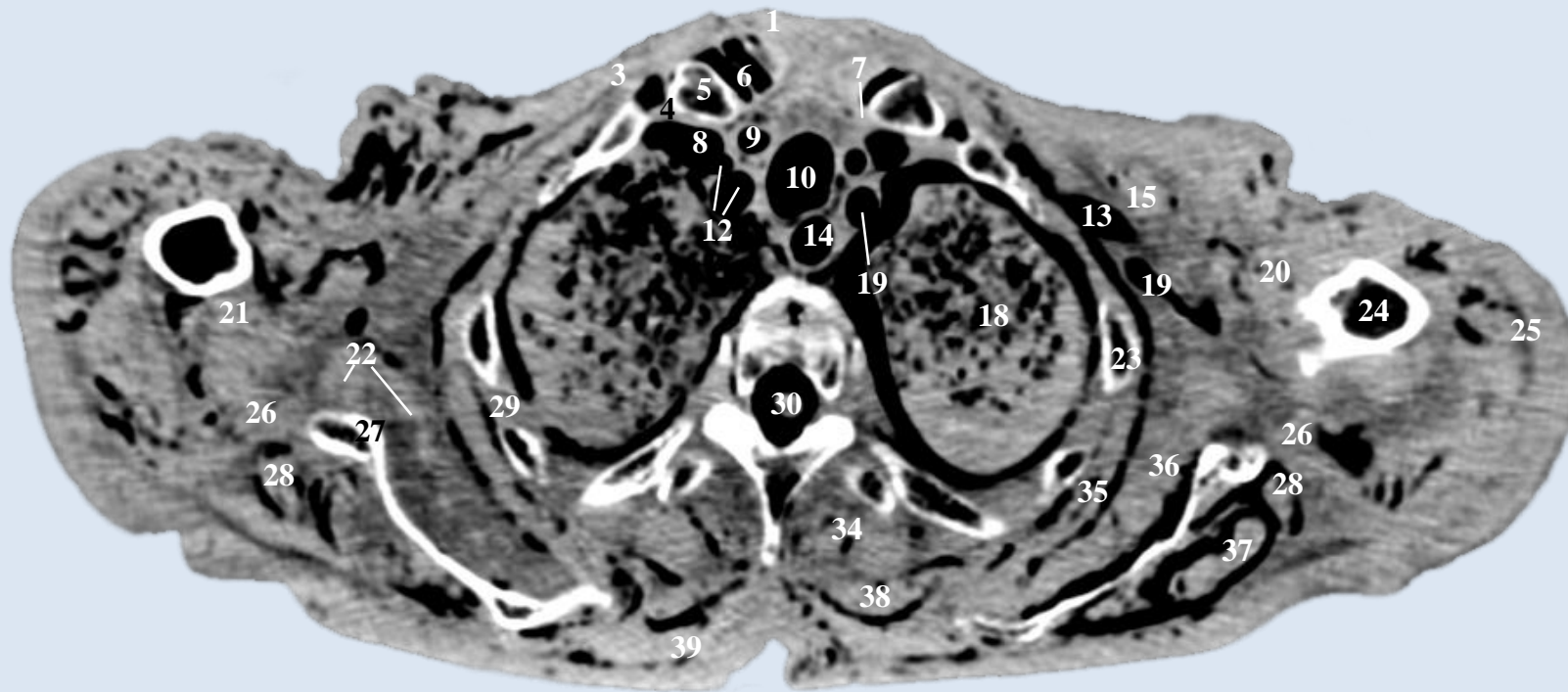




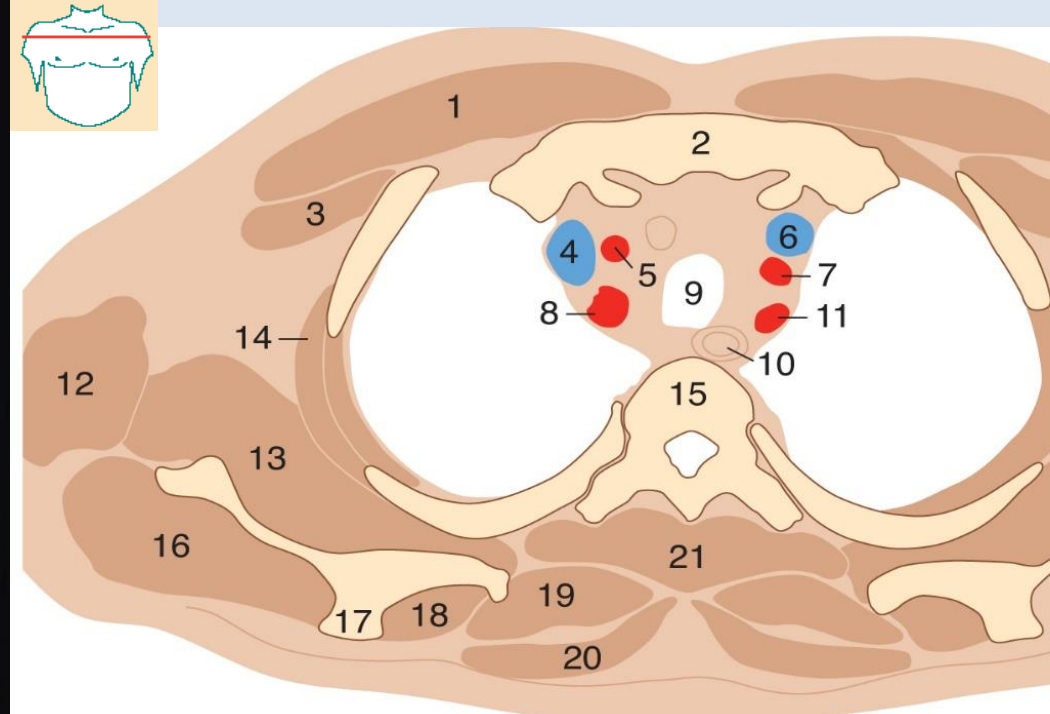
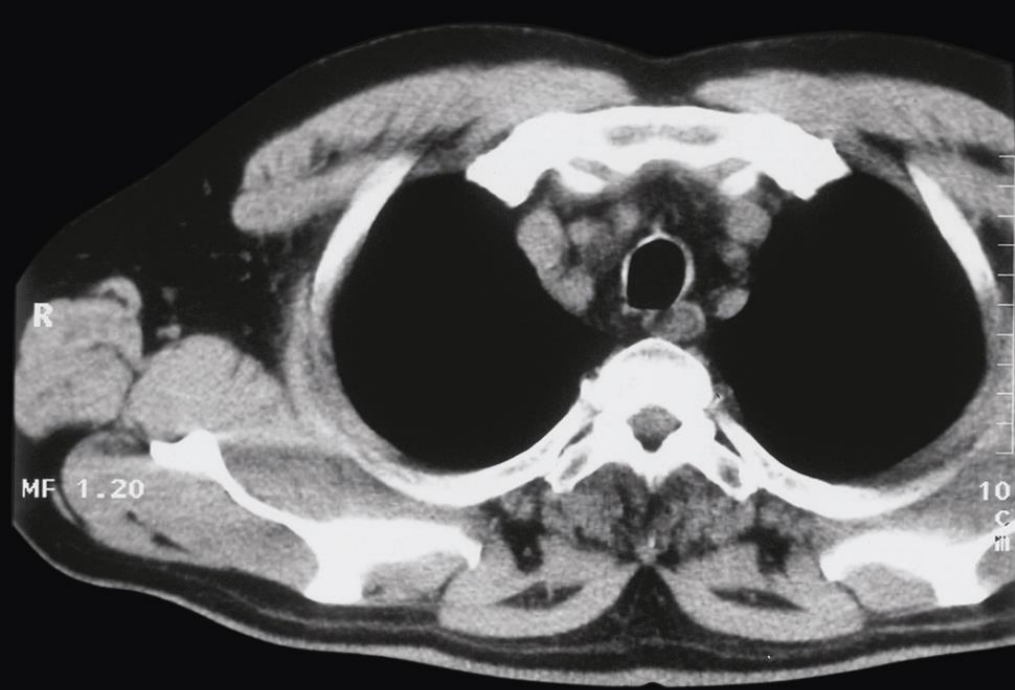Th2



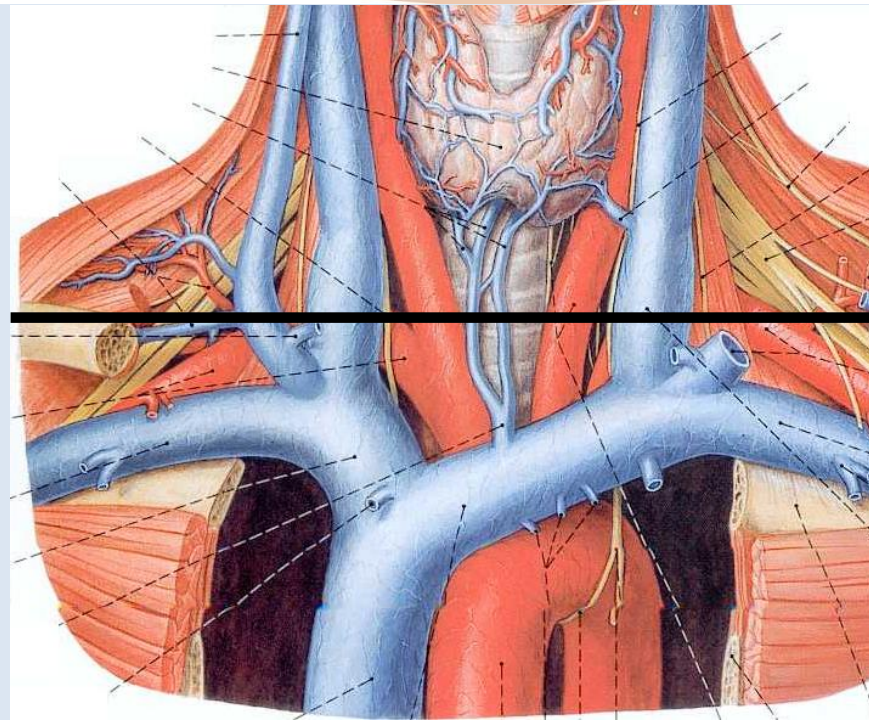
Semmelweis Egyetem
Anatómiai, Szövet- és Fejlődéstani
Intézet

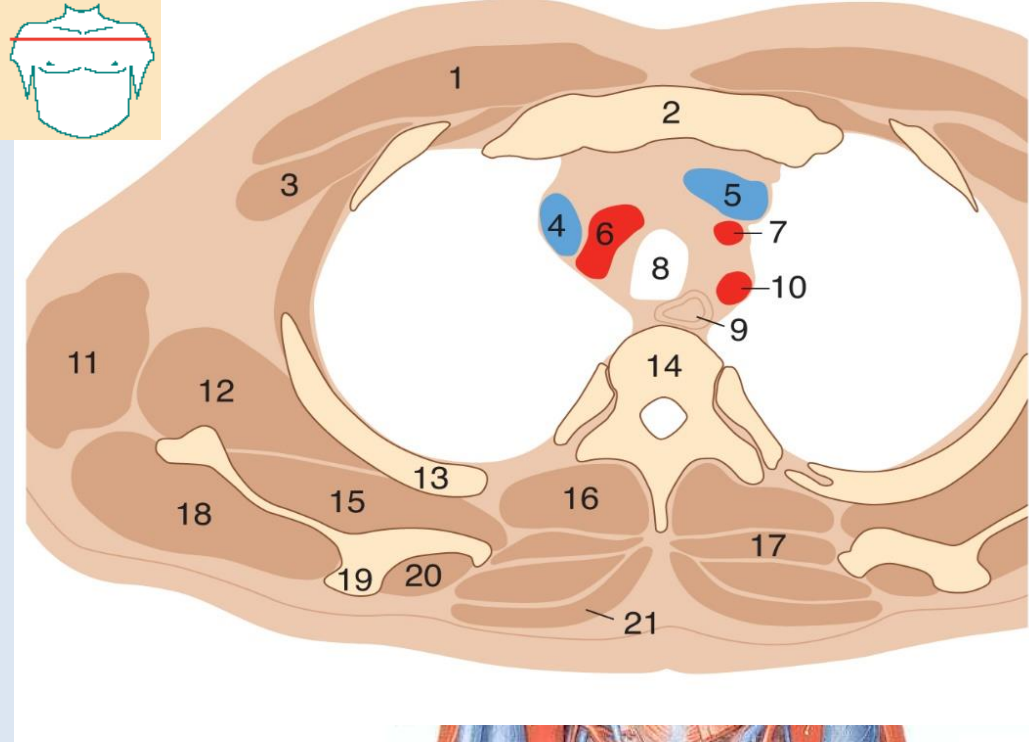
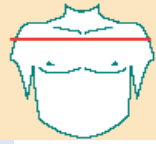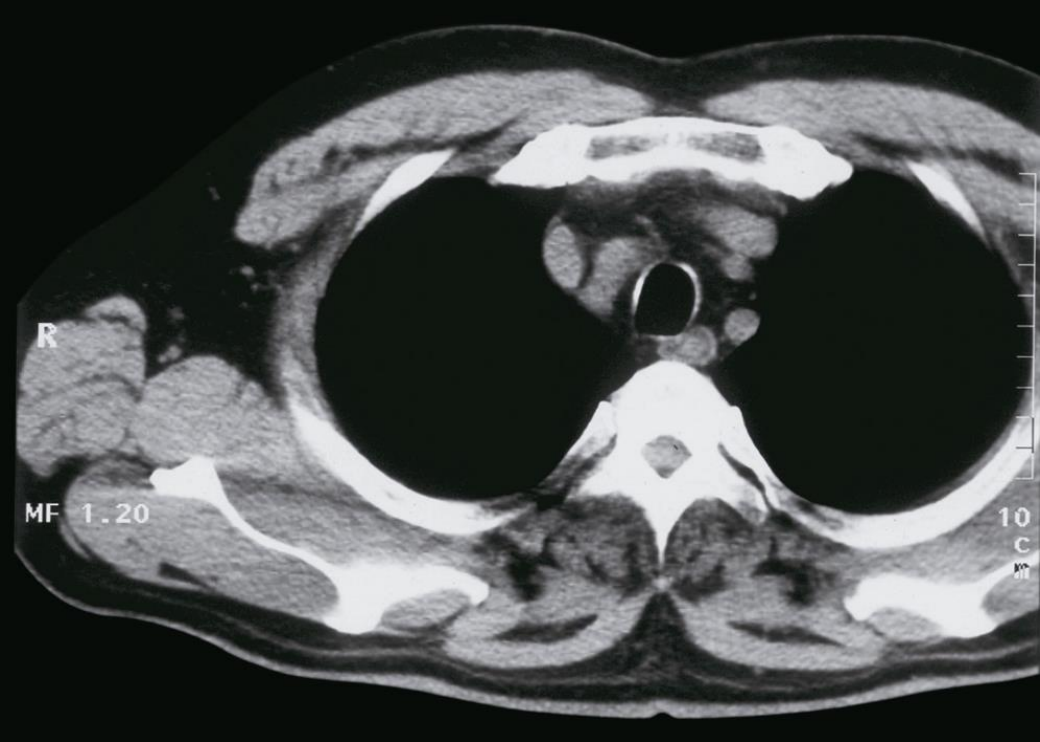


1. m. sternocleidomastoideus pars sternalis
2. -
3. m. pectoralis major
4. m. subclavius
5. clavicula
6. art. sternoclavicularis
7. mm. infrahyoidei
8. v. brachiocephalica dextra
9. a. carotis communis dextra
10. trachea
11. -
12. a.v. subclavia dextra
13. v. subclavia sinistra
14. oesophagus
15. m. pectineus minor
16. -
17. -
18. pulmo sinister, lobus superior
19. a. subclavia sinistra
20. m. biceps brachii, caput berve
21. m. triceps brachii, caput laterale
22. m. subscapularis ina
23. costa
24. humerus
25. m. deltoideus
26. m. triceps brachii, caput longum
27. scapula
28. m. teres minor
29. mm. intercostalis
30. medulla spinalis
31. -
32. -
33. -
34. m. erector spinae
35. m. serratus anterior
36. m. subscapularis
37. m. infraspinatus
38. m. rhomboideus
39. m. trapezius

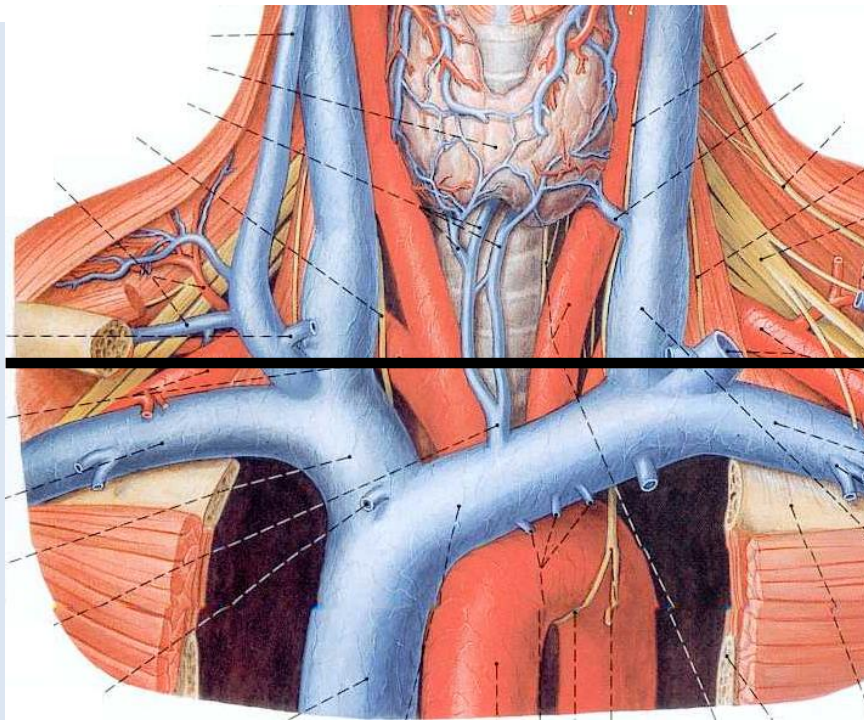


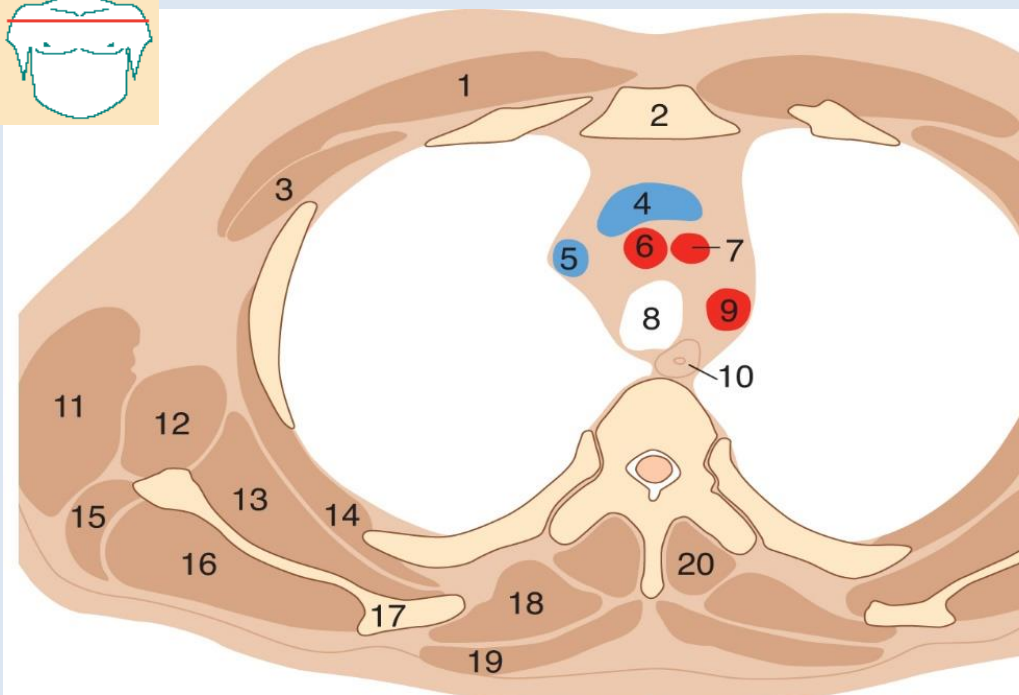
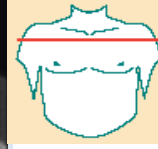
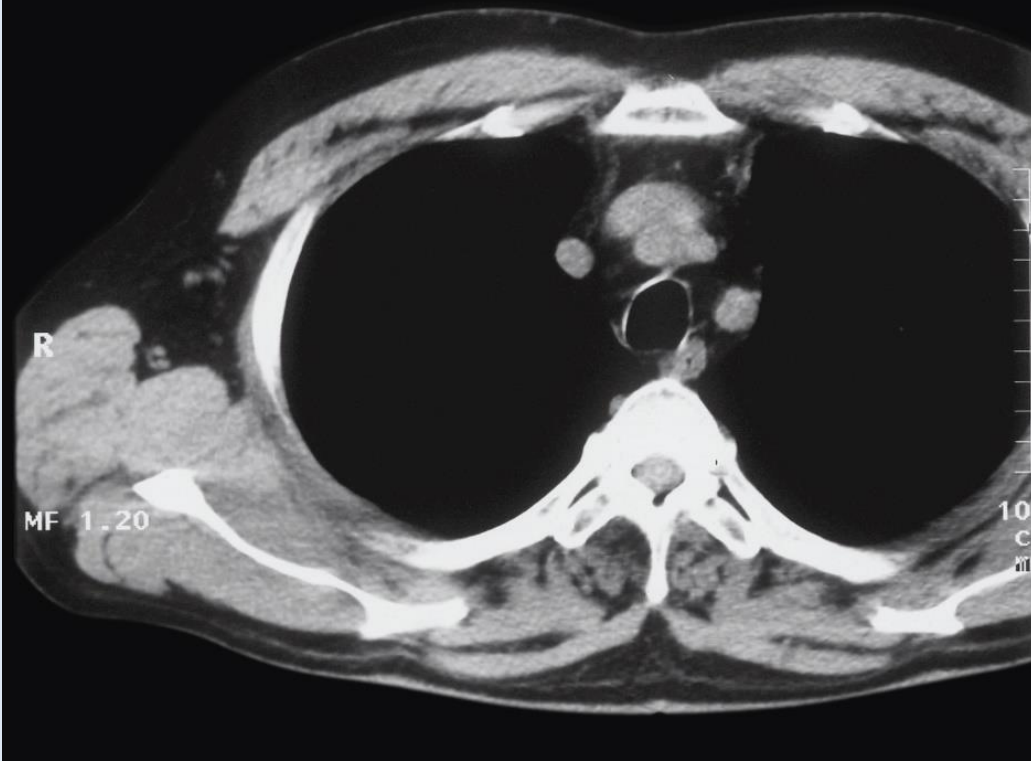
- | | |
|------------------------------|-------------------------|
| 1. M. pectoralis major | 12. M. latissimus dorsi |
| 2. Sternum | 13. M. subscapularis |
| 3. M. pectoralis minor | 14. M. serratus ant. |
| 4. V. brachiocephalica dext. | 15. Vertebra thoracica |
| 5. A. carotis commun. dext. | 16. M. infraspinatus |
| 6. V. brachiocephalica sin. | 17. Spina scapulae |
| 7. A. carotis commun. sin. | 18. M. supraspinatus |
| 8. A. subclavia dext. | 19. Mm. rhomboidei |
| 9. Trachea | 20. M. trapezius |
| 10. Oesophagus | 21. M. erector spinae |
| 11. A. subclavia sin. | |



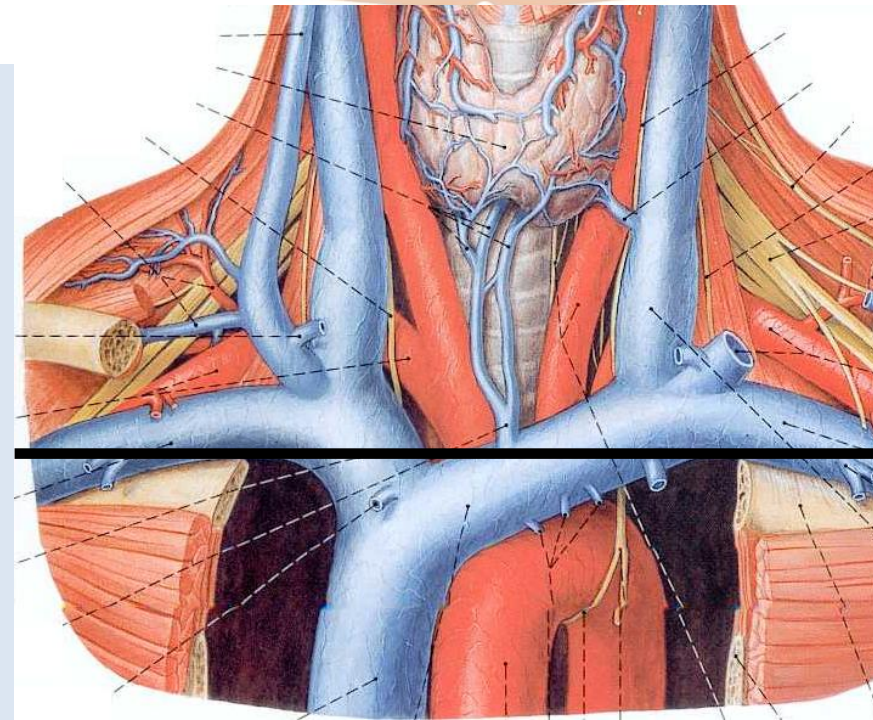


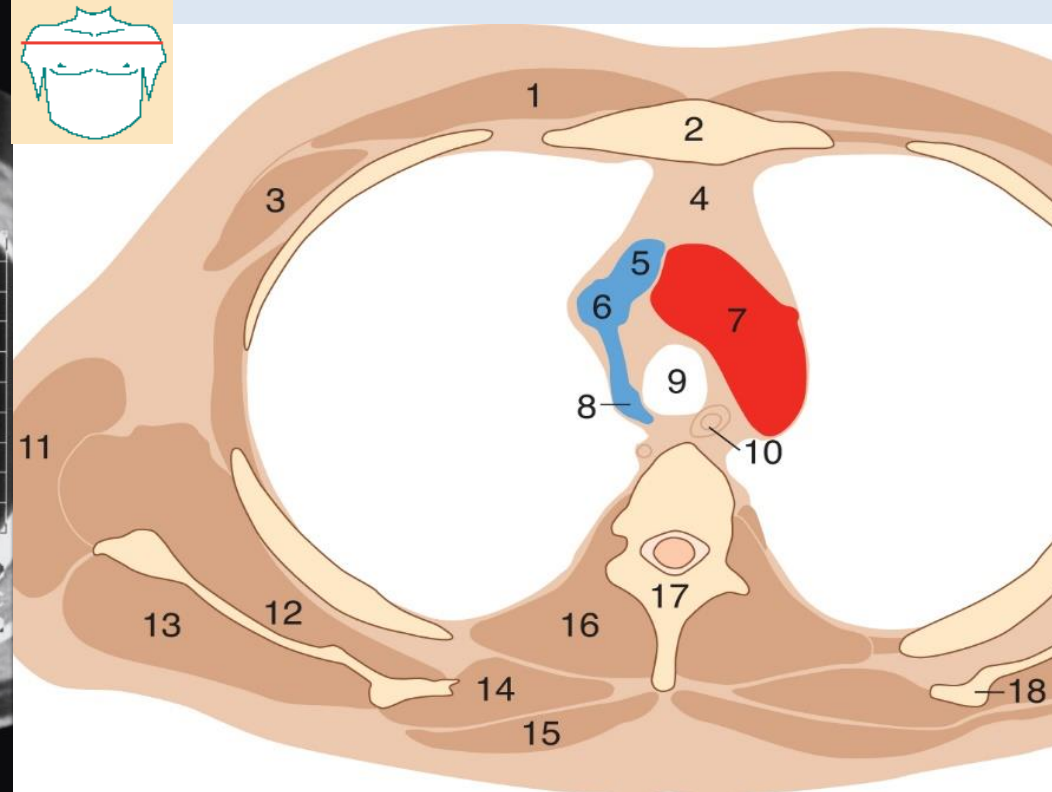
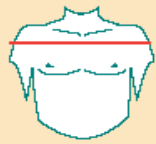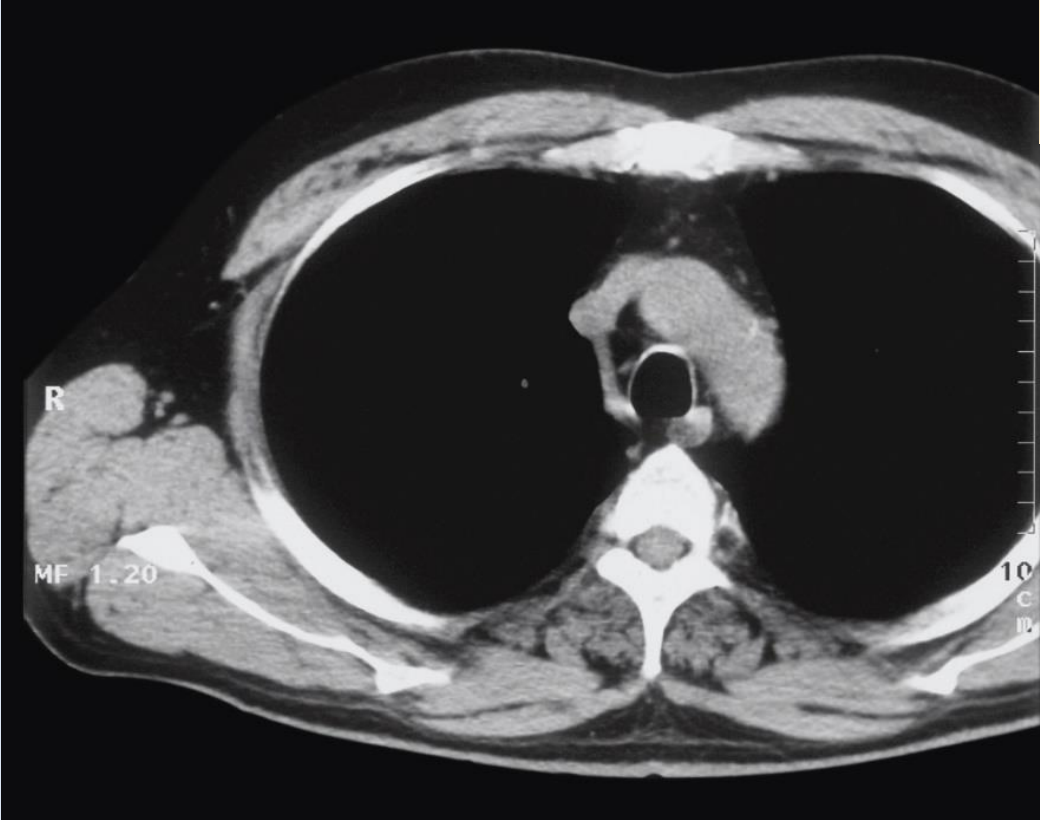
- | | |
|------------------------------|-------------------------|
| 1. M. pectoralis major | 11. M. latissimus dorsi |
| 2. Sternum | 12. M. teres major |
| 3. M. pectoralis minor | 13. Costa |
| 4. V. brachiocephalica dext. | 14. Vertebra thoracica |
| 5. V. brachiocephalica sin. | 15. M. subscapularis |
| 6. A. brachiocephalica | 16. M. erector spinae |
| 7. A. carotis commun. sin. | 17. Mm. rhomboidei |
| 8. Trachea | 18. M. infraspinatus |
| 9. Oesophagus | 19. Spina scapulae |
| 10. A. subclavia sin. | 20. M. supraspinatus |
| | 21. M. trapezius |



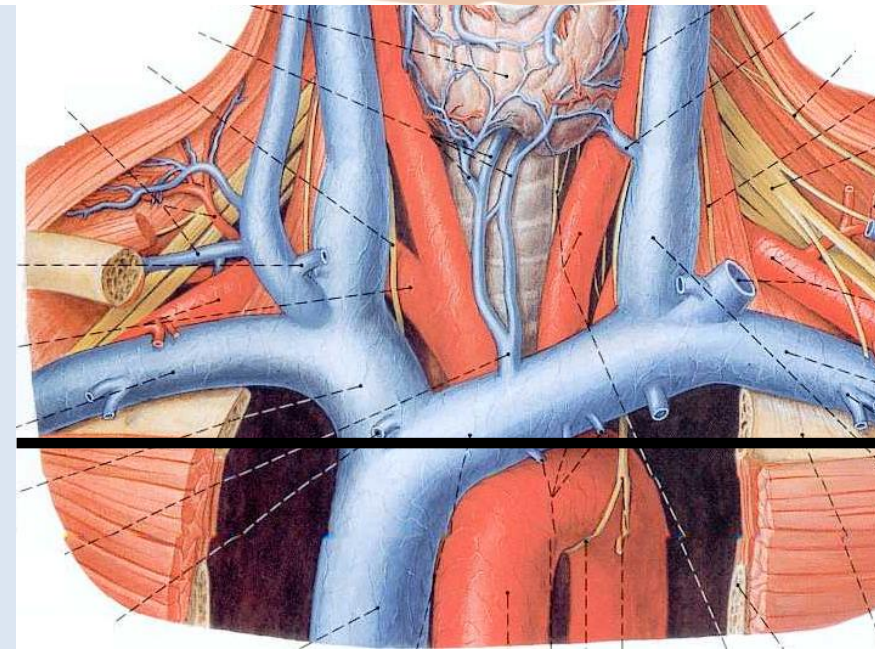


- | | |
|------------------------------|-------------------------|
| 1. M. pectoralis major | 11. M. latissimus dorsi |
| 2. Sternum | 12. M. teres major |
| 3. M. pectoralis minor | 13. M. subscapularis |
| 4. V. brachiocephalica sin. | 14. M. serratus ant. |
| 5. V. brachiocephalica dext. | 15. M. teres minor |
| 6. A. brachiocephalica | 16. M. infraspinatus |
| 7. A. carotis commun. sin. | 17. Scapula |
| 8. Trachea | 18. Mm. rhomboidei |
| 9. A. subclavia sin. | 19. M. trapezius |
| 10. Oesophagus | 20. M. erector spinae |

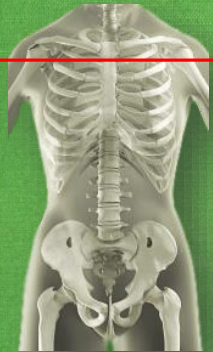



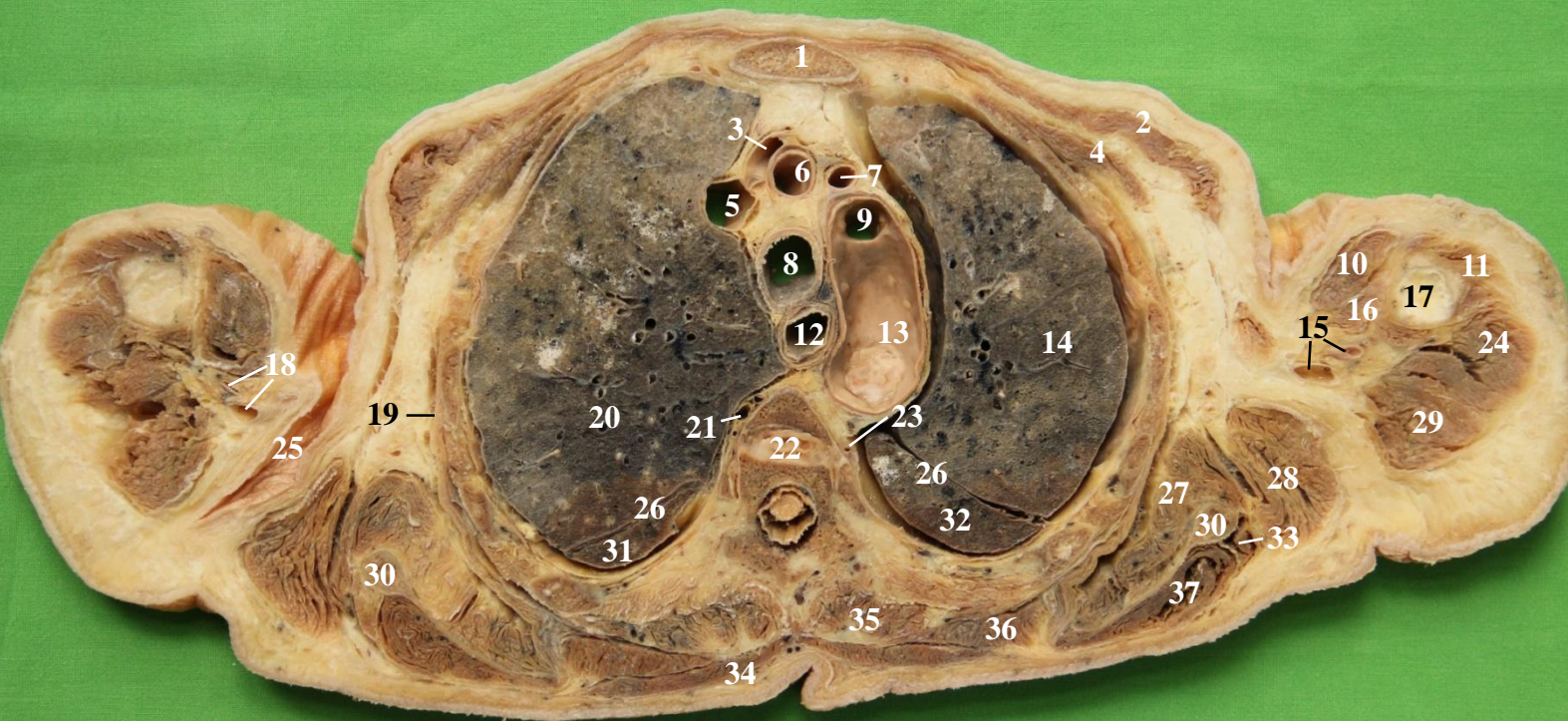
- | | |
|--------------------------------------|-------------------------|
| 1. M. pectoralis major | 11. M. latissimus dorsi |
| 2. Sternum | 12. M. subscapularis |
| 3. M. pectoralis minor | 13. M. infraspinatus |
| 4. Thymus residuum/ mediastinum sup. | 14. Mm. rhomboidei |
| 5. V. brachiocephalica sin. | 15. M. trapezius |
| 6. V. cava sup. | 16. M. erector spinae |
| 7. Arcus aortae | 17. Vertebra thoracica |
| 8. V. azygos | 18. Scapula |
| 9. Trachea | |
| 10. Oesophagus | |



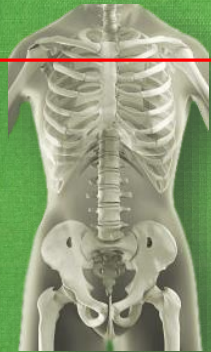Th 3/4



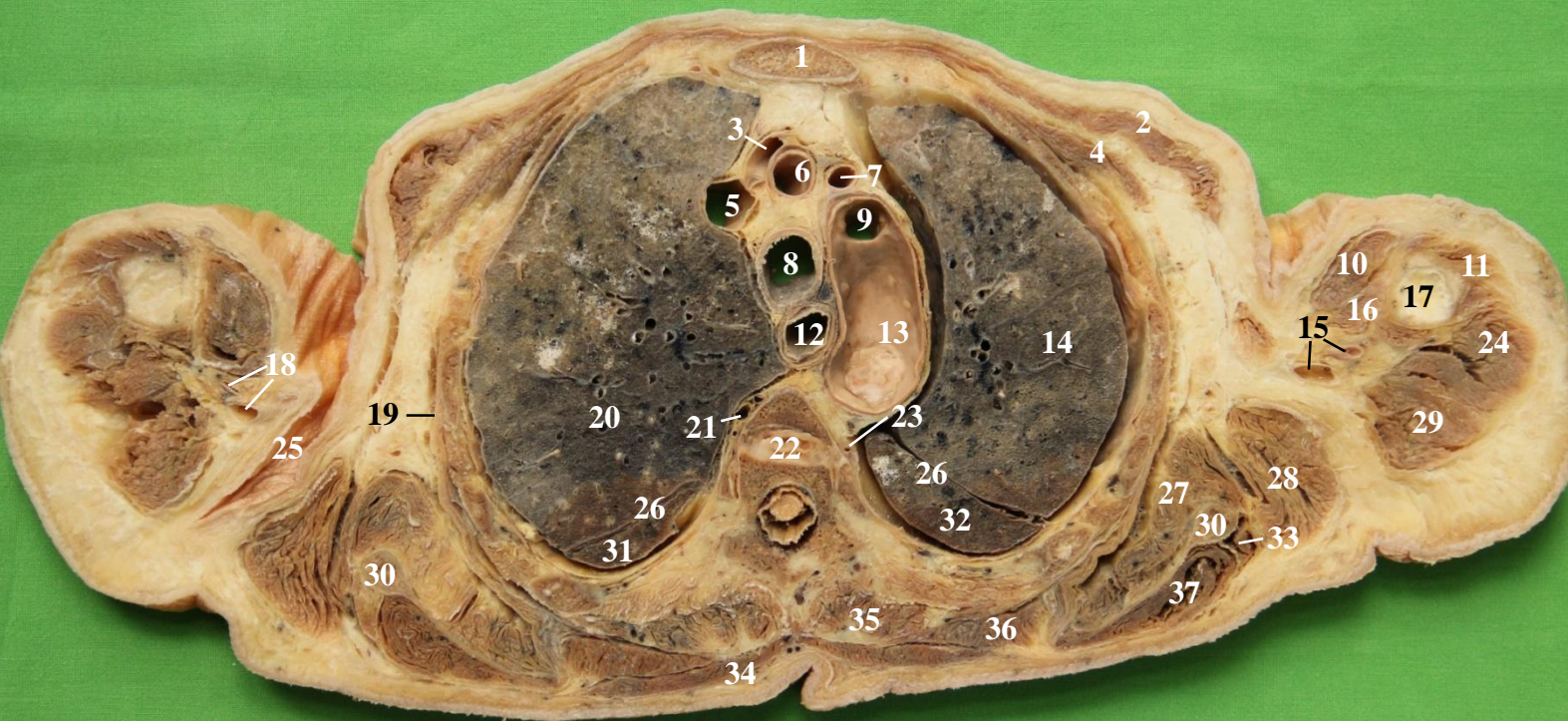
Semmelweis Egyetem
Anatómai, Szövet- és Fejlődéstani
Intézet



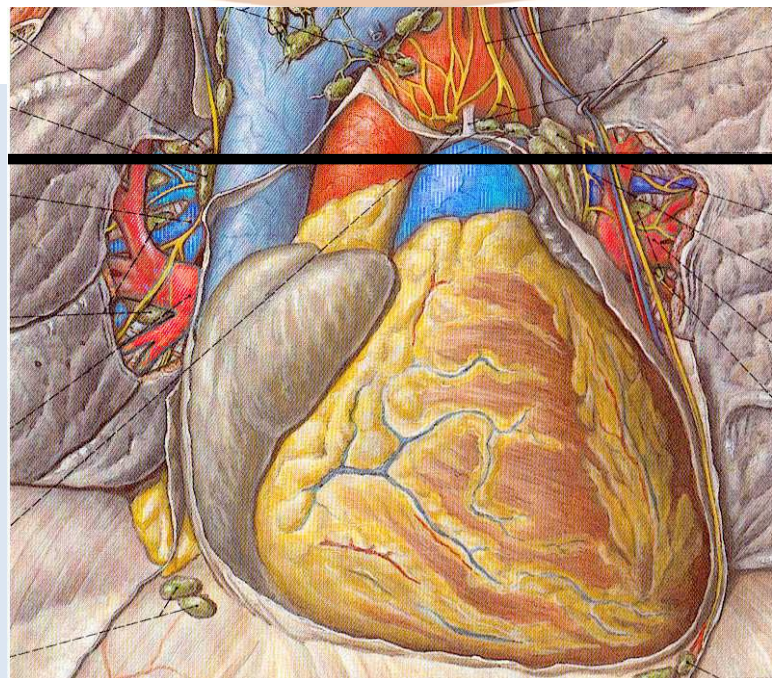
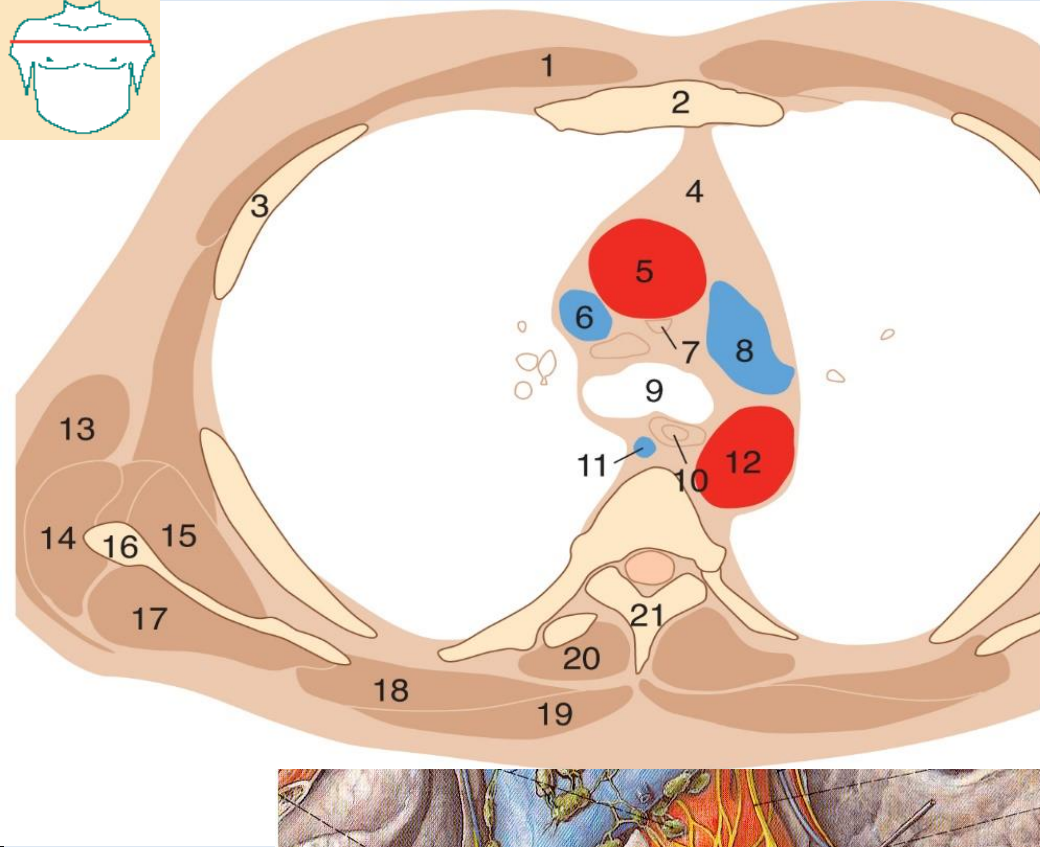
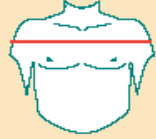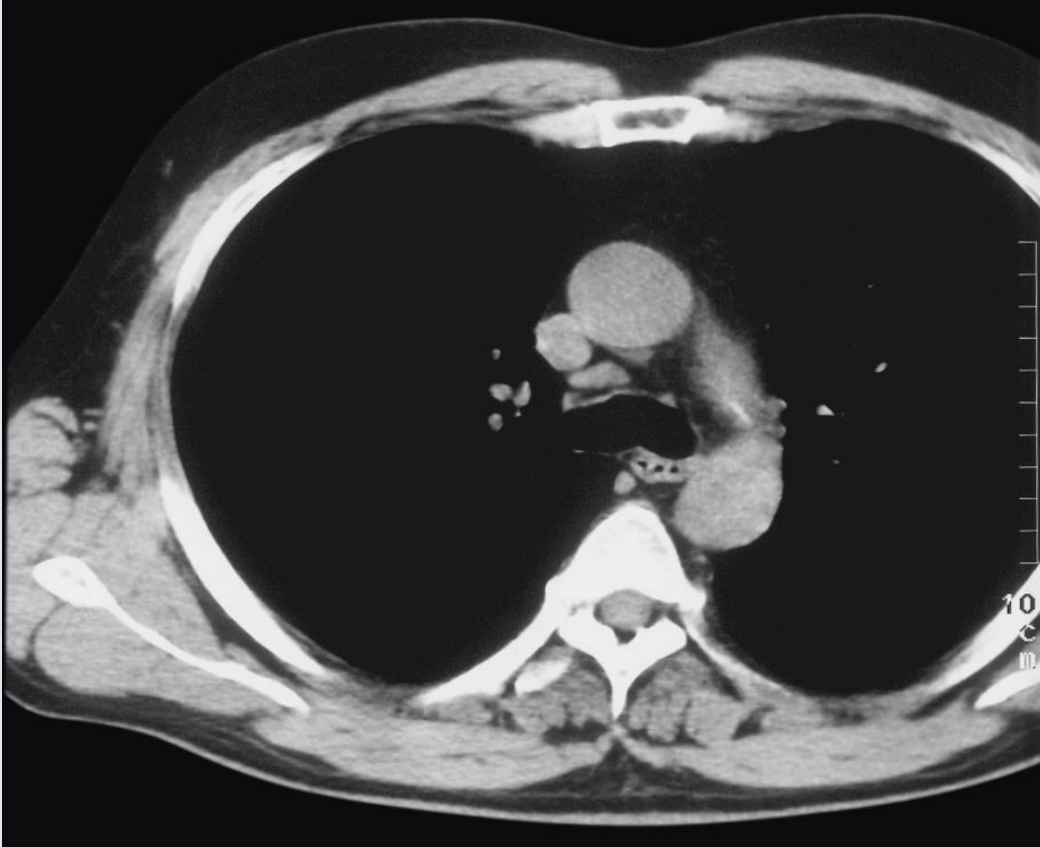
Th 3/4



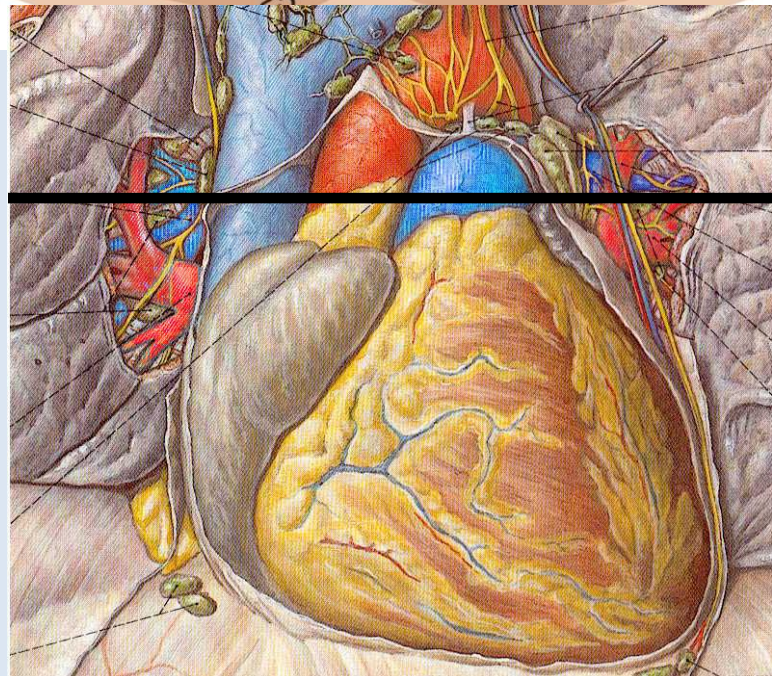
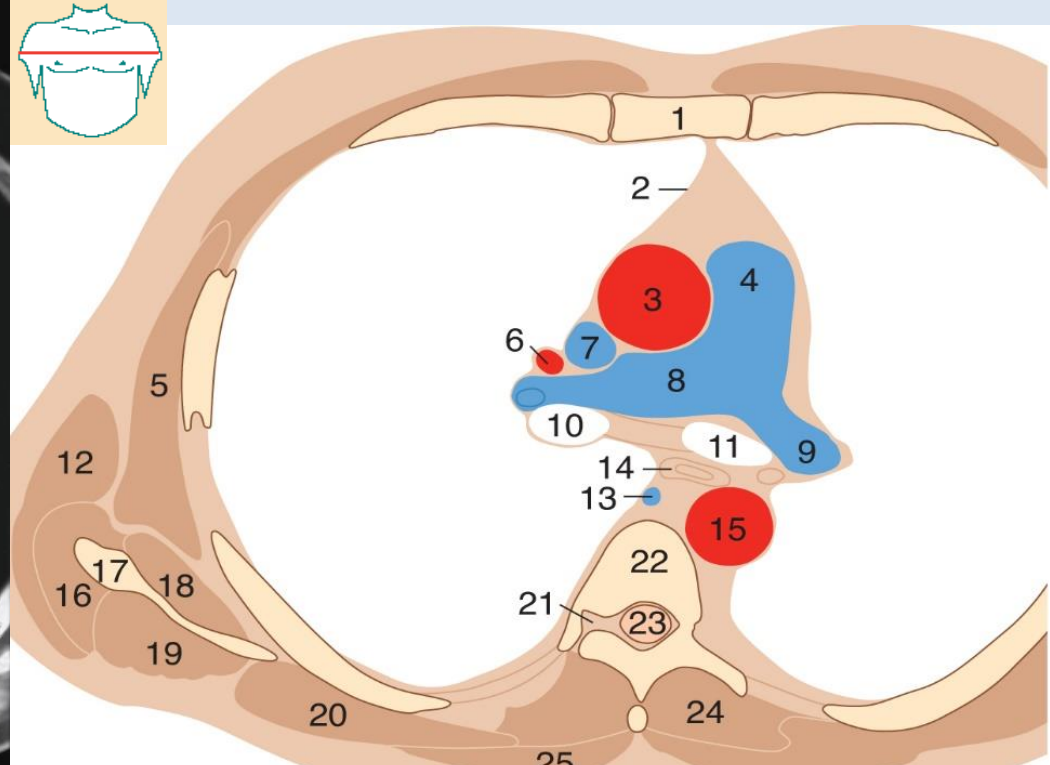
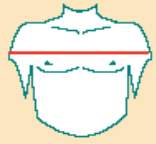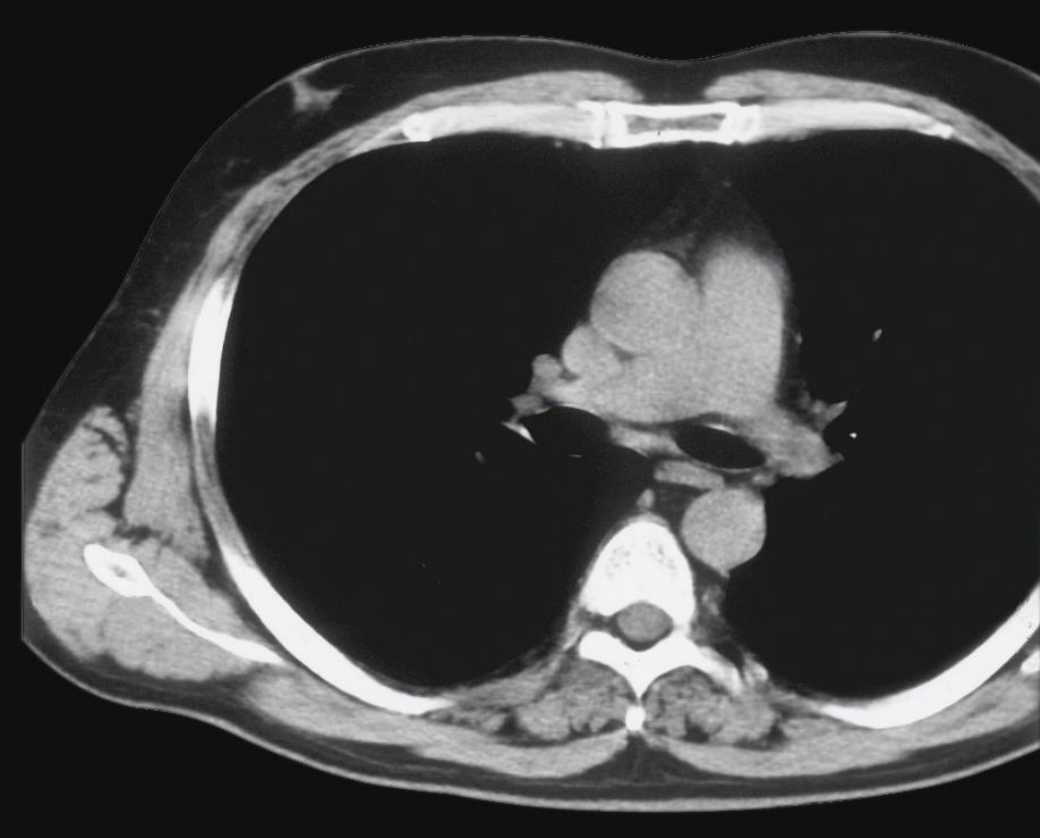
Semmelweis Egyetem
Anatómiai, Szövet- és Fejlődéstani
Intézet



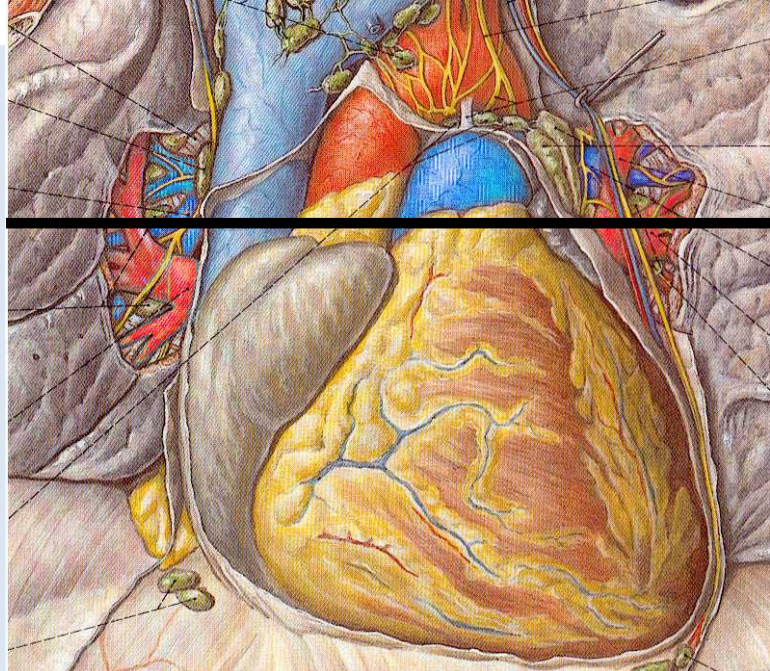
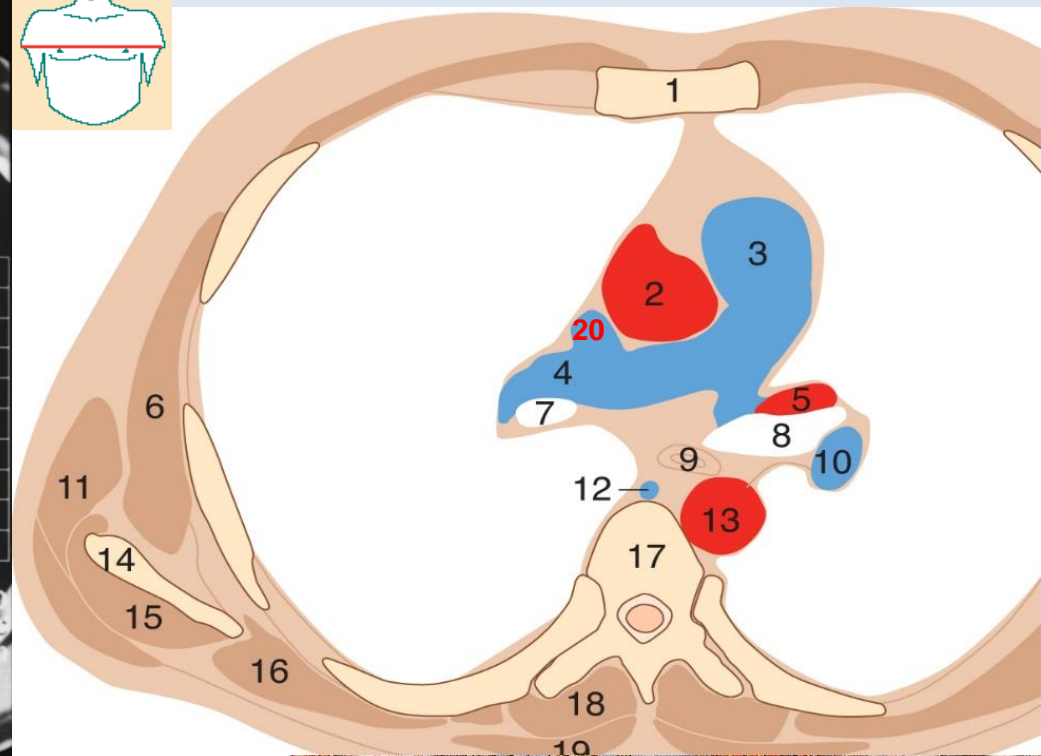
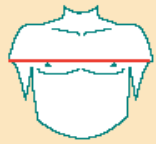
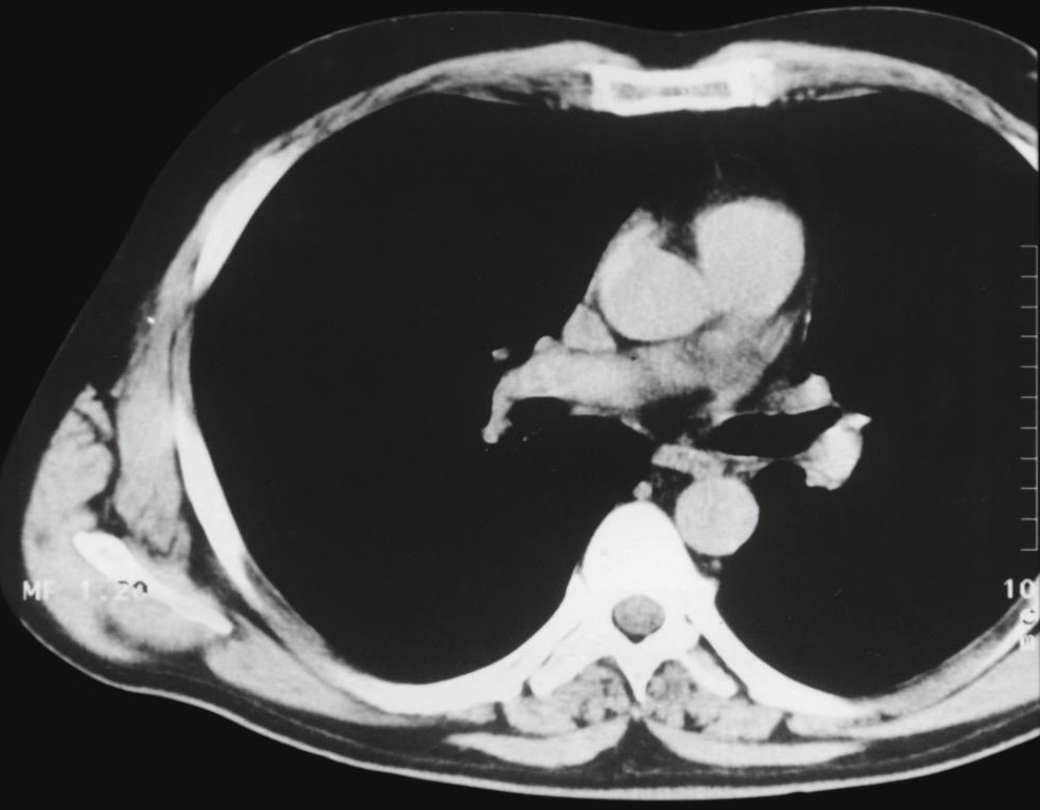
1. sternum
2. m. pectoralis major
- 3.
4. m. pectoralis minor
- 5.
- 6.
- 7.
- 8.
- 9.
10. m. biceps brachii, caput breve
11. m. deltoideus
- 12.
- 13.
14. pulmo sinister, lobus superior
15. a. v. axillaris
16. m. coracobrachialis
17. humerus
18. a.v. axillaris
19. m. serratus anterior
20. pulmo dexter, lobus superior
21. v. intercostalis suprema
22. discus intervertebralis
23. v. hemiazygos accessoria
24. m. triceps brachii, caput laterale
25. hónaljredő
- 26.
27. m. subscapularis
28. m. latissimus dorsi inna és a m. teres major
29. m. triceps brachii, caput longum
30. scapula
- 31.
32. pulmo sinister, lobus inferior
33. m. teres minor
34. m. trapezius
35. m. erector spinae
36. m. rhomboideus
37. m. infraspinatus



- | | |
|--------------------------------------|---------------------------|
| 1. M. pectoralis major | 12. Aorta thoracica desc. |
| 2. Sternum | 13. M. latissimus dorsi |
| 3. Costa | 14. M. teres major |
| 4. Thymus residuum/ mediastinum sup. | 15. M. subscapularis |
| 5. Aorta ascendens | 16. Scapula |
| 6. V. cava sup. | 17. M. infraspinatus |
| 7. Pericardium áthajlás | 18. Mm. rhomboidei |
| 8. A. pulmonalis sin. | 19. M. trapezius |
| 9. Bifurcatio tracheae (carina) | 20. M. erector spinae |
| 10. Oesophagus | 21. Arcus vertebrae |
| 11. V. azygos | |

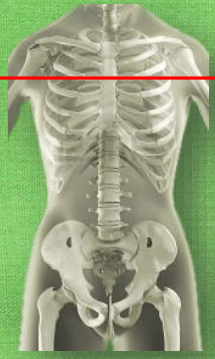

- | | |
|----------------------------------|-----------------------------|
| 1. Sternum | 14. Oesophagus |
| 2. Pleura mediastinalis | 15. Aorta thoracica desc. |
| 3. Aorta ascendens | 16. M. teres major |
| 4. Truncus pulmonalis | 17. Scapula |
| 5. M. serratus ant. | 18. M. subscapularis |
| 6. V. pulmonalis sup. dext. | 19. M. infraspinatus |
| 7. V. cava sup. | 20. Mm. rhomboidei |
| 8. A. pulmonalis dext. | 21. Foramen intervertebrale |
| 9. A. pulmonalis sin. | 22. Vertebra thoracica |
| 10. Bronchus intermedius (dext.) | 23. Medulla spinalis |
| 11. Bronchus principalis sin. | 24. M. erector spinae |
| 12. M. latissimus dorsi | 25. M. trapezius |
| 13. V. azygos | |

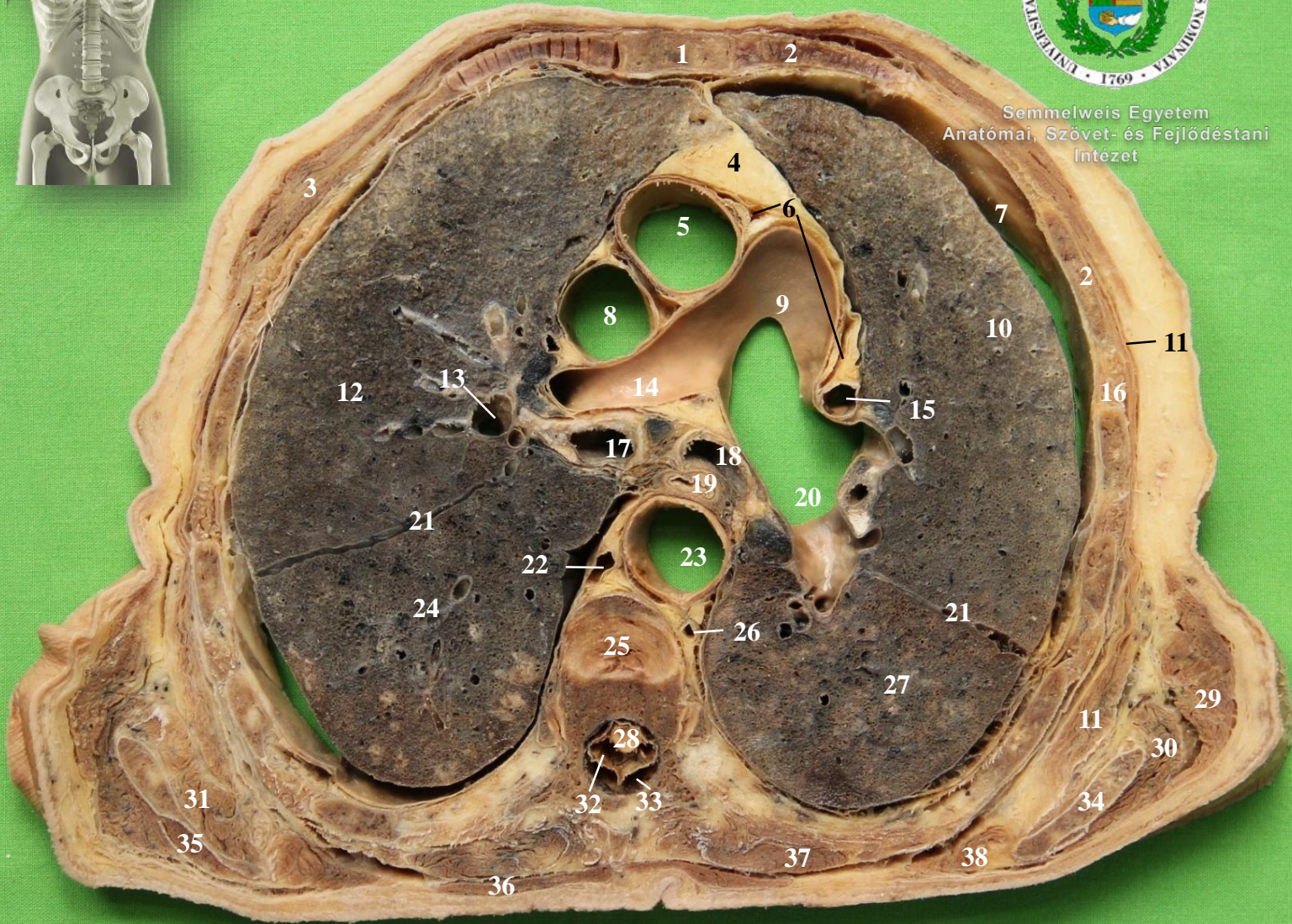


- | | |
|--|--------------------------------------|
| 1. Sternum | 11. M. latissimus dorsi |
| 2. Aorta ascendens | 12. V. azygos |
| 3. Truncus pulmonalis (conus arteriosus) | 13. Aorta thoracica desc. |
| 4. A. pulmonalis dext. | 14. Scapula |
| 5. V. pulmonalis sup. dext. | 15. M. teres major |
| 6. M. serratus ant. | 16. Mm. rhomboidei |
| 7. Bronchus intermedius (dext.) | 17. Vertebra thoracica |
| 8. Bronchus principalis sin. | 18. M. erector spinae |
| 9. Oesophagus | 19. M. trapezius |
| 10. A. pulmonalis sin. | 20. <u>Vena cava superior</u> |

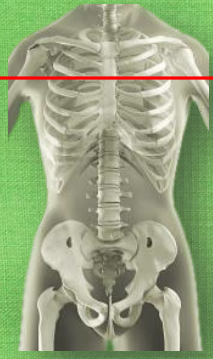Th5/6



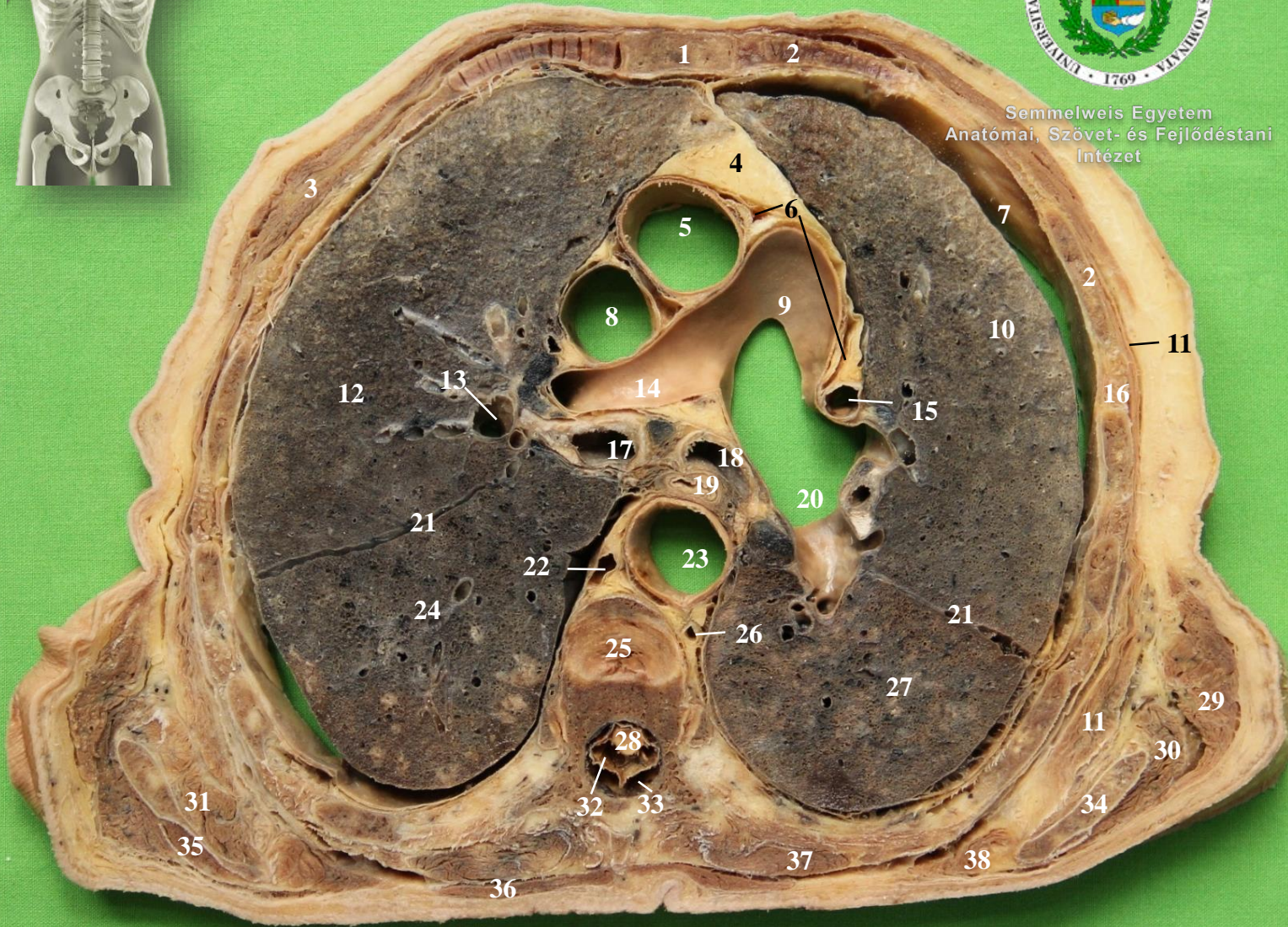
Semmelweis Egyetem
Anatómiai, Szövet- és Fejlődéstani
Intézet



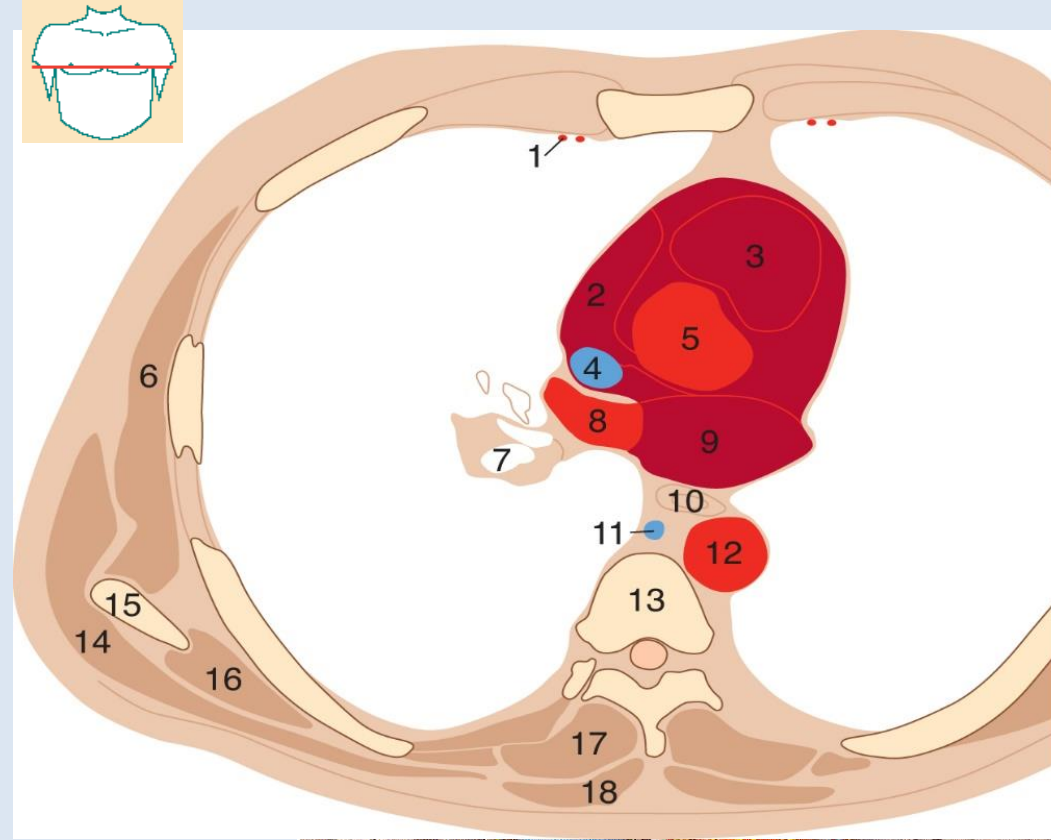
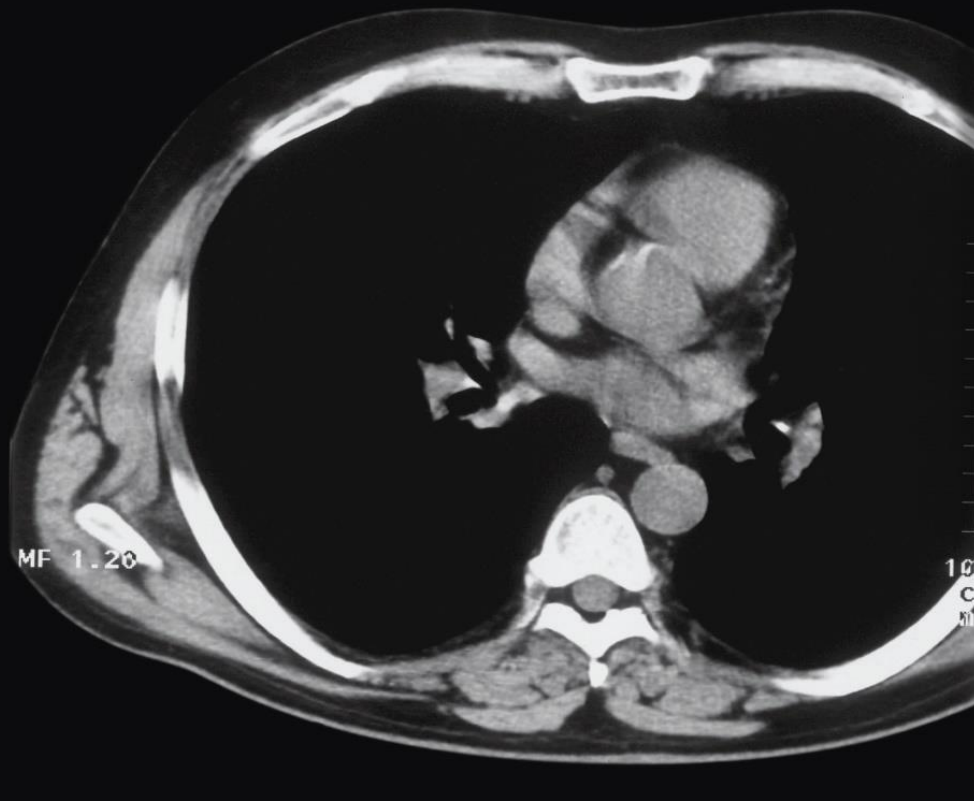
Th5/6



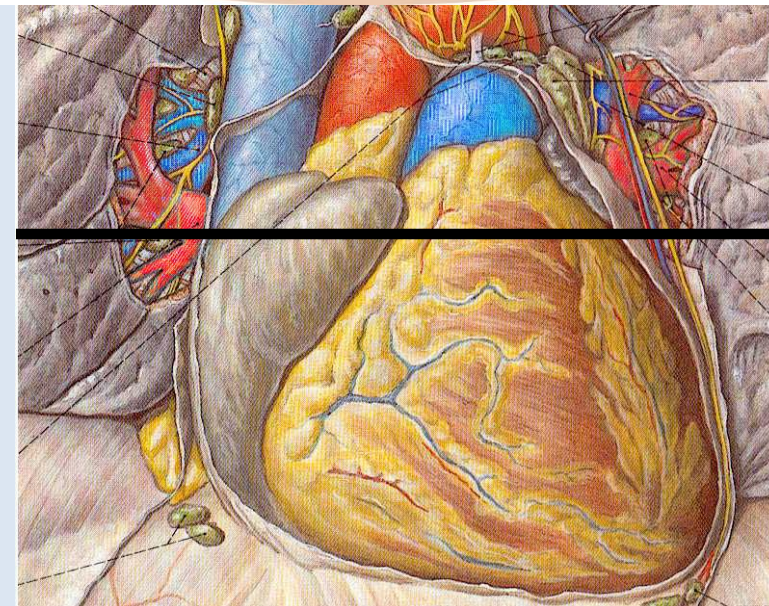
Semmelweis Egyetem
Anatómiai, Szövet- és Fejlődéstani
Intézet

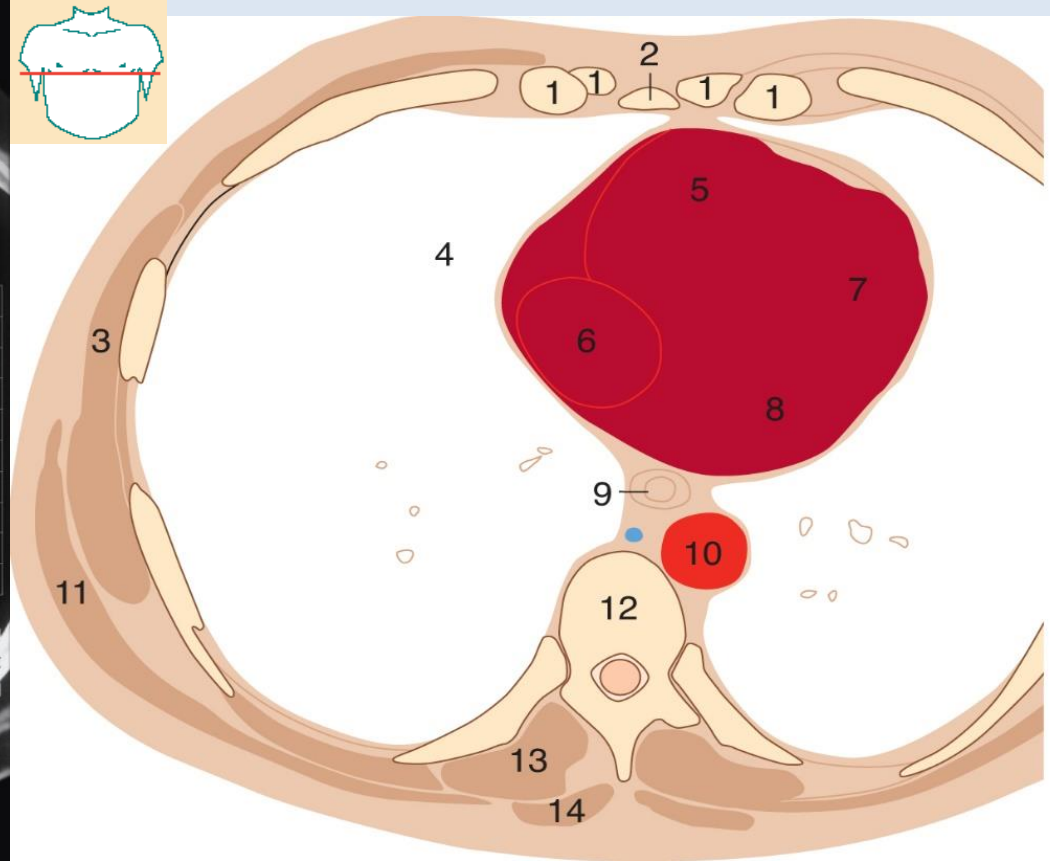
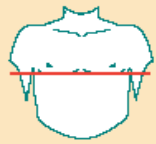
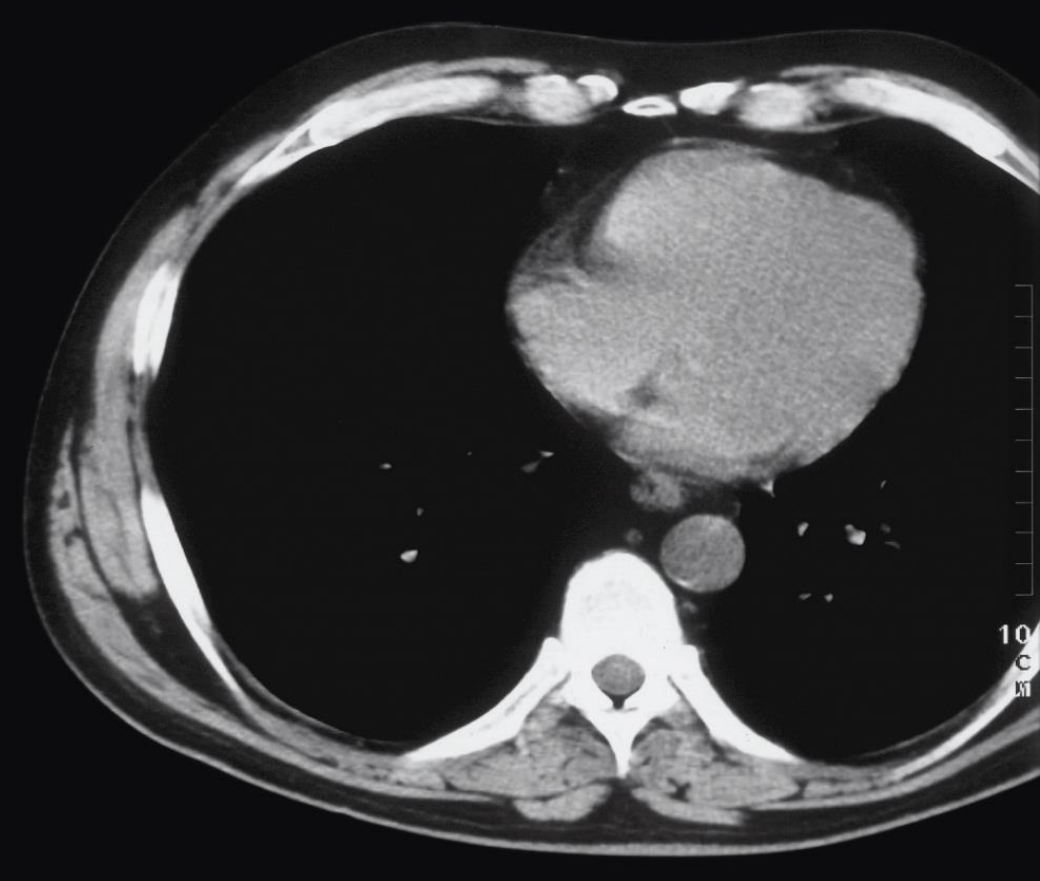


1. sternum
2. costa
3. m. pectoralis major/minor
4. thymus adiposum
5. aorta ascendens
6. cavum pericardii
7. cavum pleurae
8. v. cava superior
9. truncus pulmonalis
10. pulmo dexter, lobus superior
11. m. serratus anterior
12. pulmo sinister, lobus superior
13. v. pulmonalis dextra
14. a. pulmonalis dextra
15. v. pulmonalis sinistra
16. mm. intercostales
17. bronchus principalis dexter
18. bronchus principalis sinister
19. oesophagus
20. a. pulmonalis sinistra
21. fissura obliqua
22. v. azygos
23. aorta descendens
24. pulmo dexter, lobus inferior
25. discus intervertebralis
26. v. hemiazygos accessoria
27. pulmo sinister, lobus inferior
28. spina medullaris
29. m. latissimus dorsi
30. m. teres major
31. m. subscapularis
32. spatium subarachnoideum
33. spatium epidurale
34. scapula
35. m. infraspinatus
36. m. trapezius
37. m. erector spinae
38. m. rhomboideus major

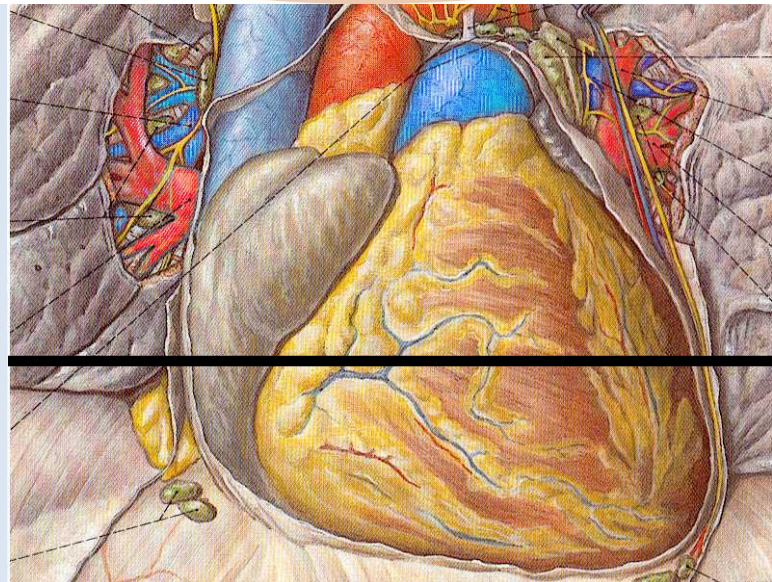


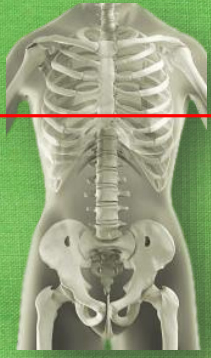
- | | |
|--------------------------------|---------------------------|
| 1. A.et v. thoracica int. | 11. V. azygos |
| 2. Atrium dextrum | 12. Aorta thoracica desc. |
| 3. Jobb kamra, kiáramlási zóna | 13. Vertebra thoracica |
| 4. V. cava sup. | 14. M. latissimus dorsi |
| 5. Aorta ascendens | 15. Scapula |
| 6. M. serratus ant. | 16. Mm. rhomboidei |
| 7. Bronchus lobaris inf. dext. | 17. M. erector spinae |
| 8. V. pulmonalis sup. sin. | 18. M. trapezius |
| 9. Atrium sin. | |
| 10. Oesophagus | |





- | | |
|-------------------------|---------------------------|
| 1. Cartilago costalis | 8. Bal pitvar |
| 2. Processus xiphoideus | 9. Oesophagus |
| 3. M. serratus ant. | 10. Aorta thoracica desc. |
| 4. Pulmo (lobus medius) | 11. M. latissimus dorsi |
| 5. Jobb kamra | 12. Vertebra thoracica |
| 6. Jobb pitvar | 13. M. erector spinae |
| 7. Bal kamra | 14. M. trapezius |





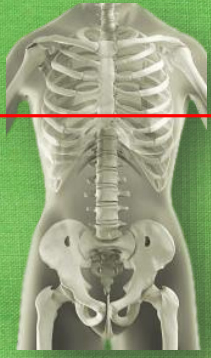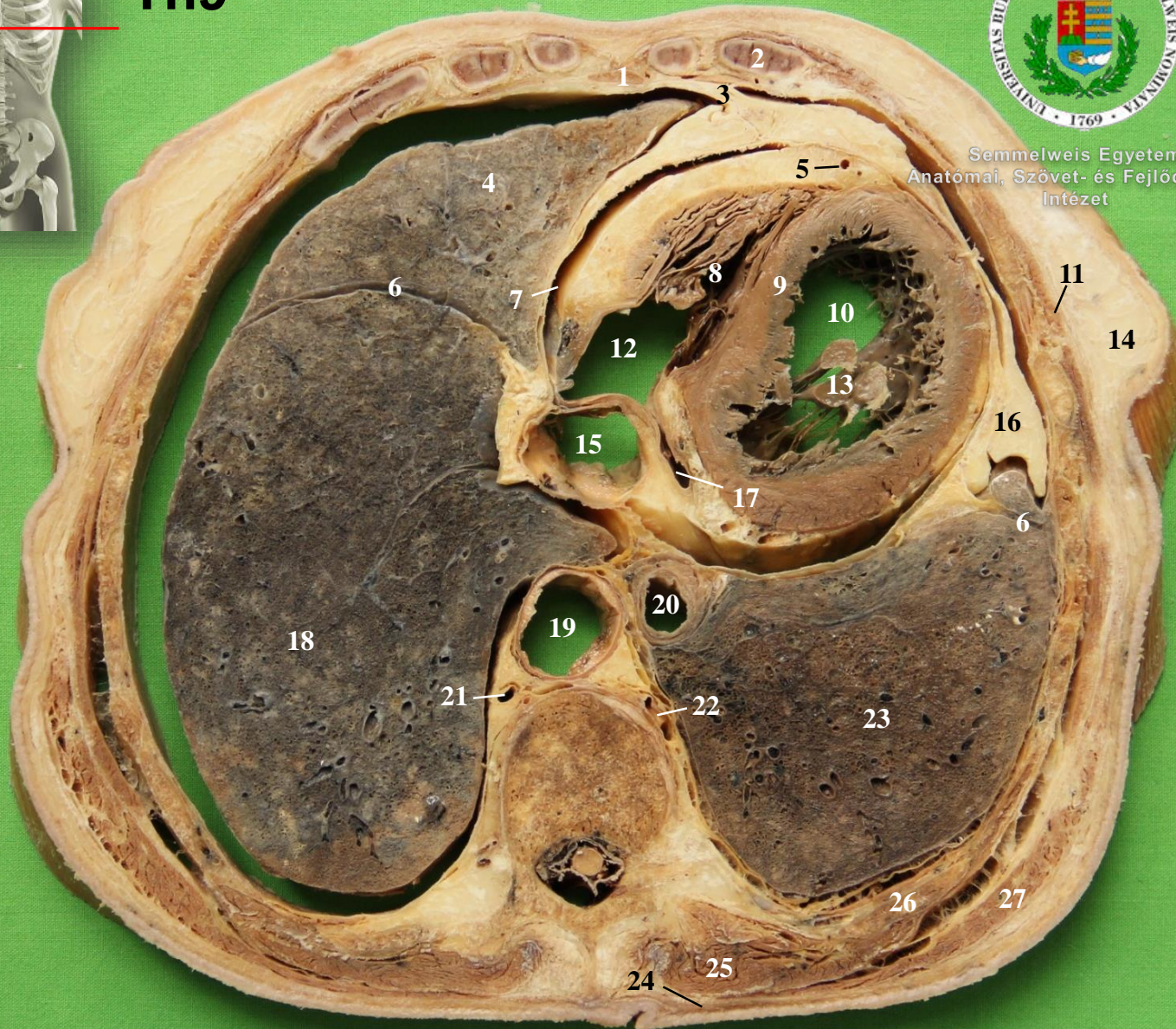
Th9



Semmelweis Egyetem
Anatómiai, Szövet- és Fejlődéstani
Intézet



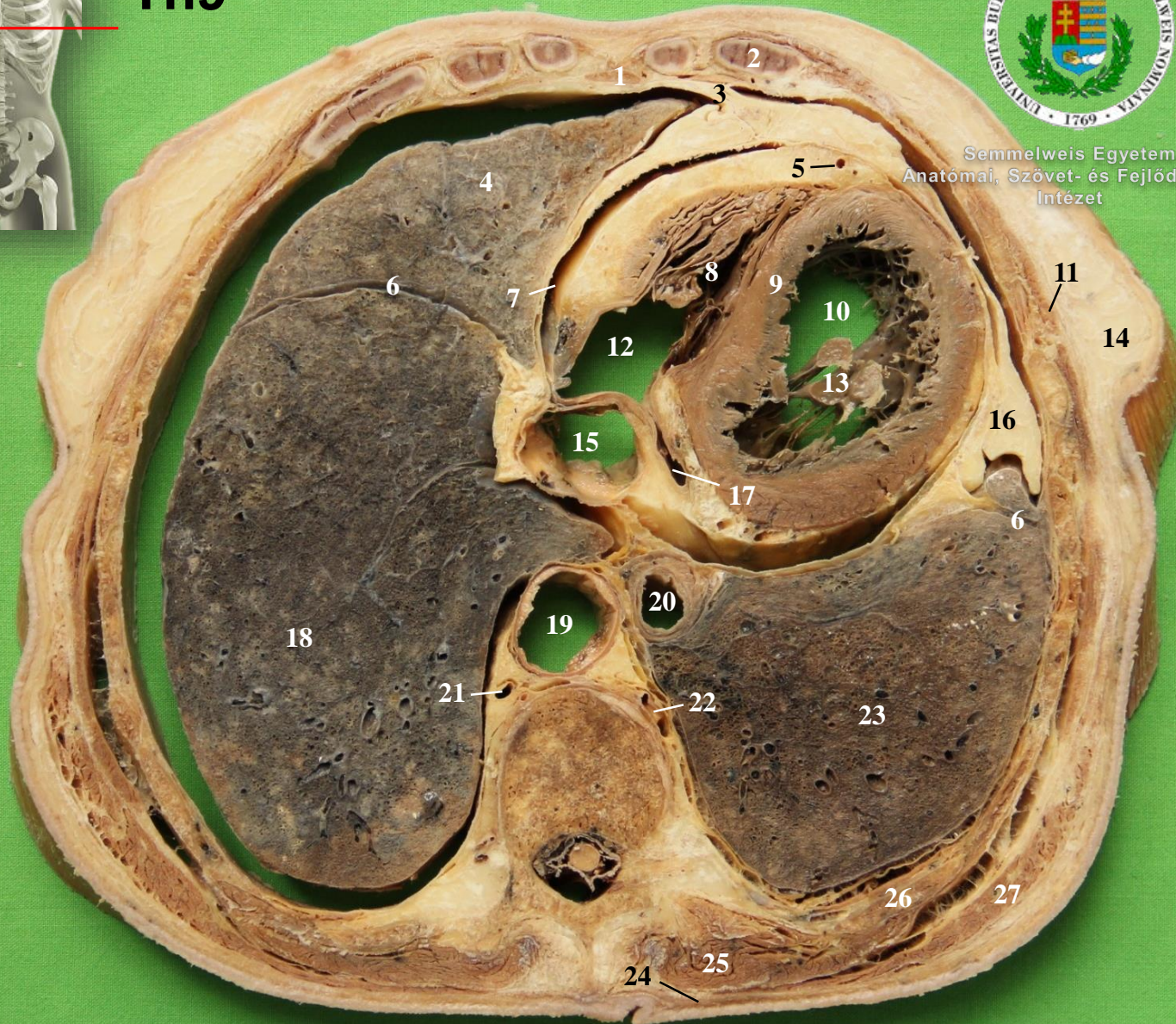1. sternum
2. costa (porc)
3. lig. sternopericardiacum
4. pulmo dexter, lobus medius
5. a. interventricularis anterior
6. fissura obliqua
7. cavum pericardii
8. ventriculus dexter
9. septum interventriculare pars muscularis
10. ventriculus sinister
11. m. serratus anterior
12. atrium dexter
13. m. papillaris anterior
14. mamma
15. vena cava inferior
16. extrapericardialis zsírszövet
17. sinus coronarius
18. pulmo dexter lobus inferior
19. aorta descendens
20. oesophagus
21. v. azygos
22. v. hemiazygos
23. pulmo sinister, lobus inferior
24. m. trapezius
25. m. erector spinae
26. costa (csont)
27. m. latissimus dorsi



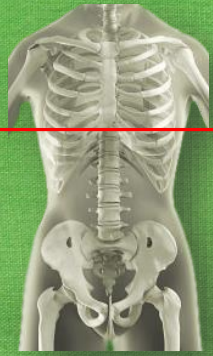
Th9



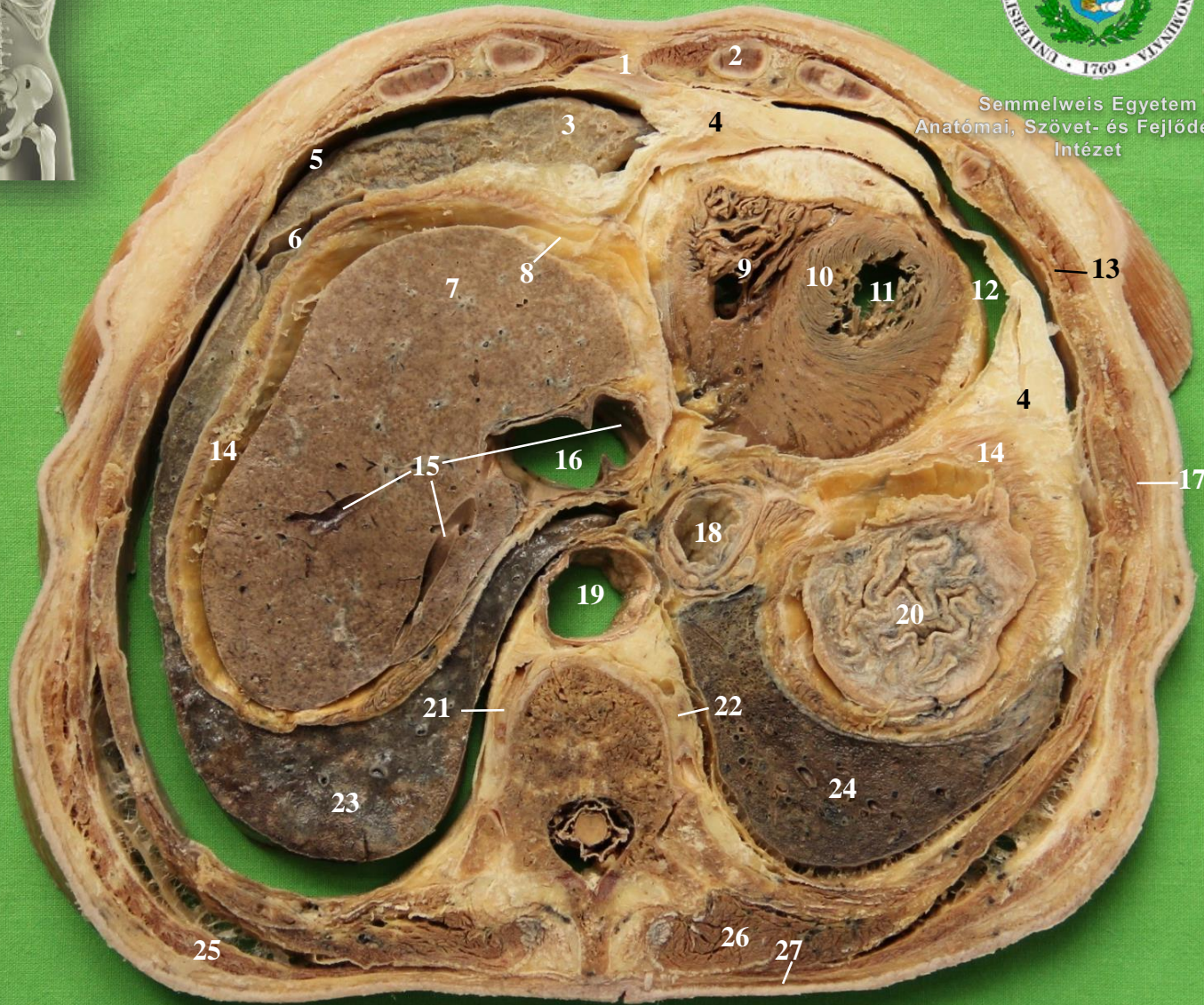
Semmelweis Egyetem
Anatómai, Szövet- és Fejlődéstani
Intézet



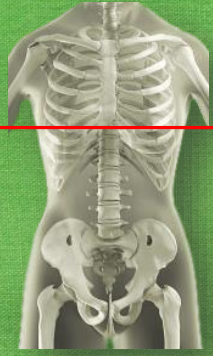
Th10



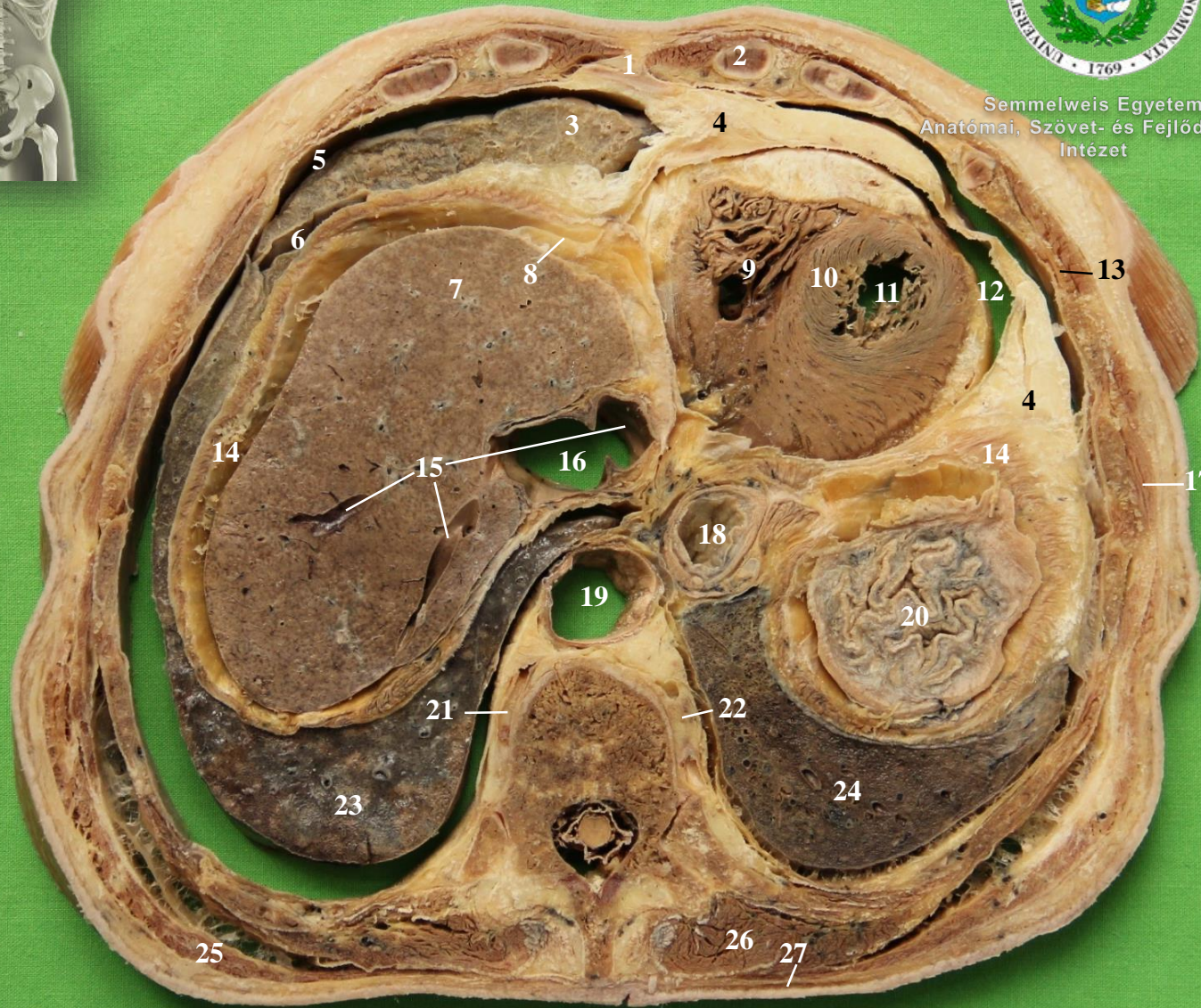
Semmelweis Egyetem
Anatómiai, Szövet- és Fejlődéstani
Intézet



Th10

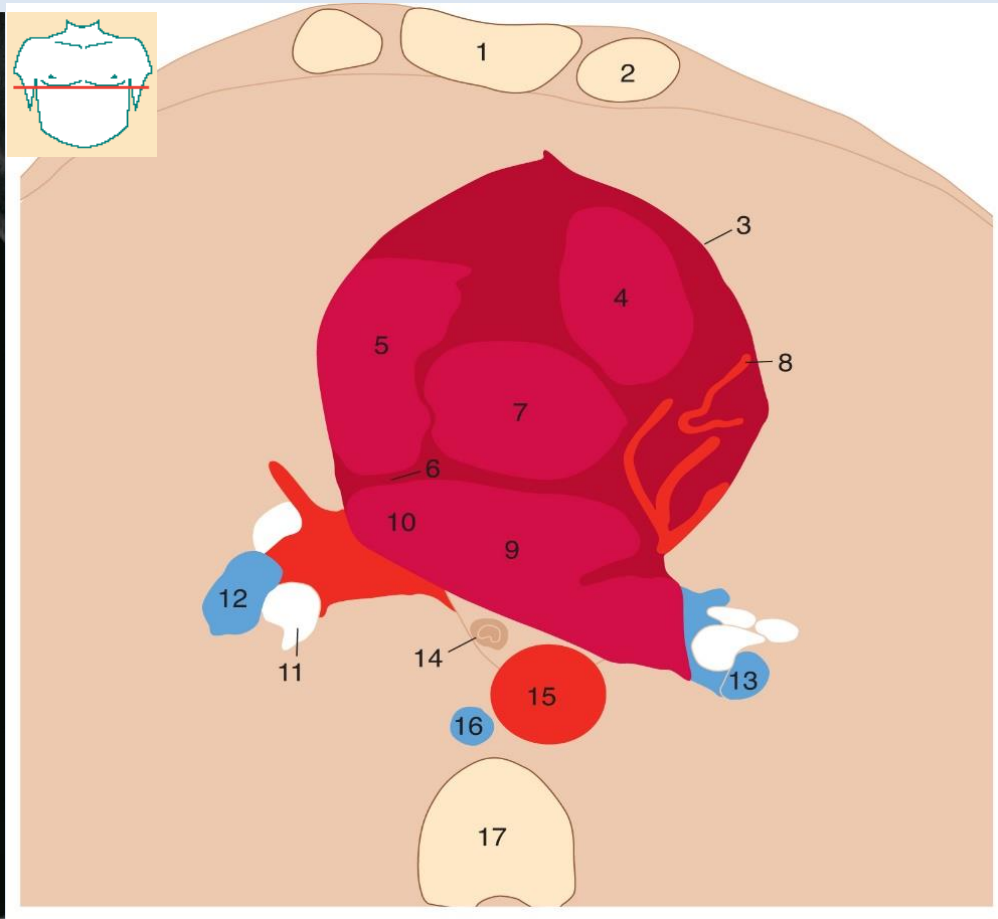
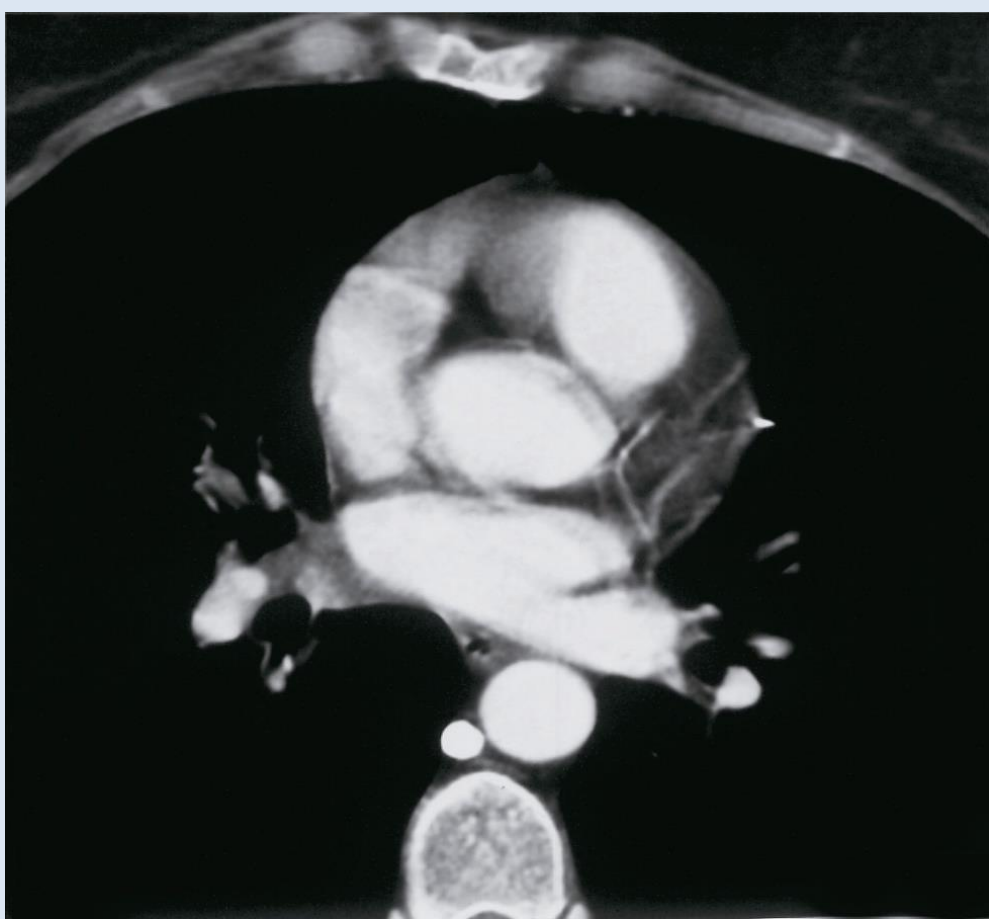


Semmelweis Egyetem
Anatómiai, Szövet- és Fejlődéstani
Intézet

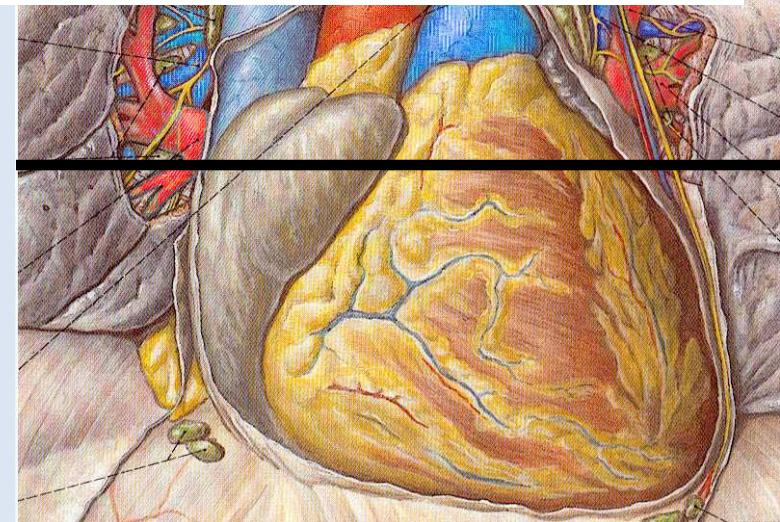


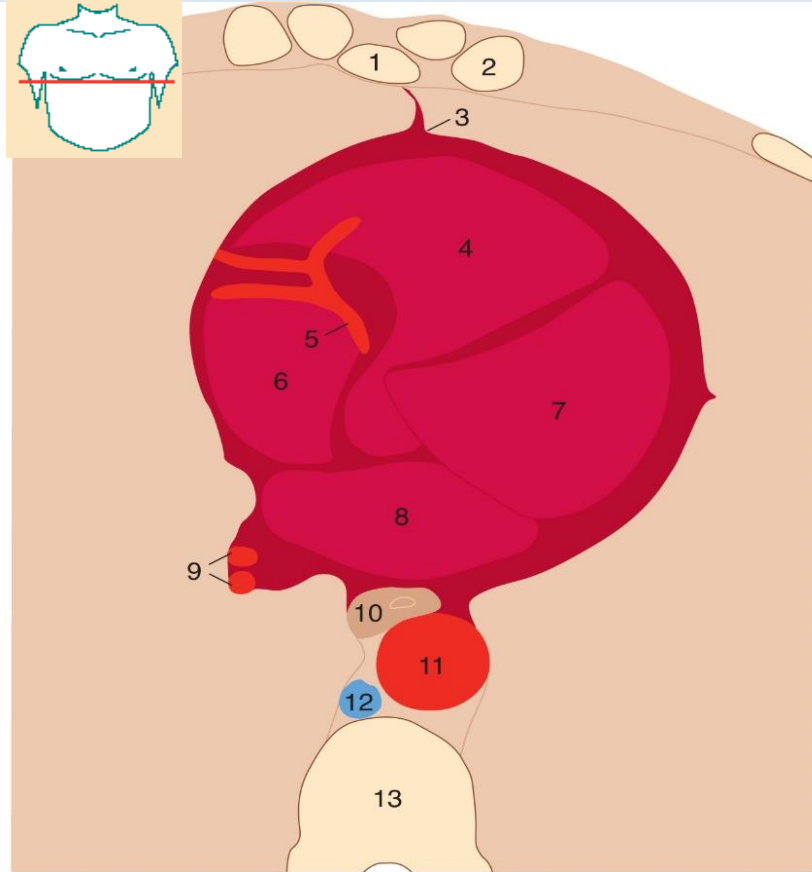
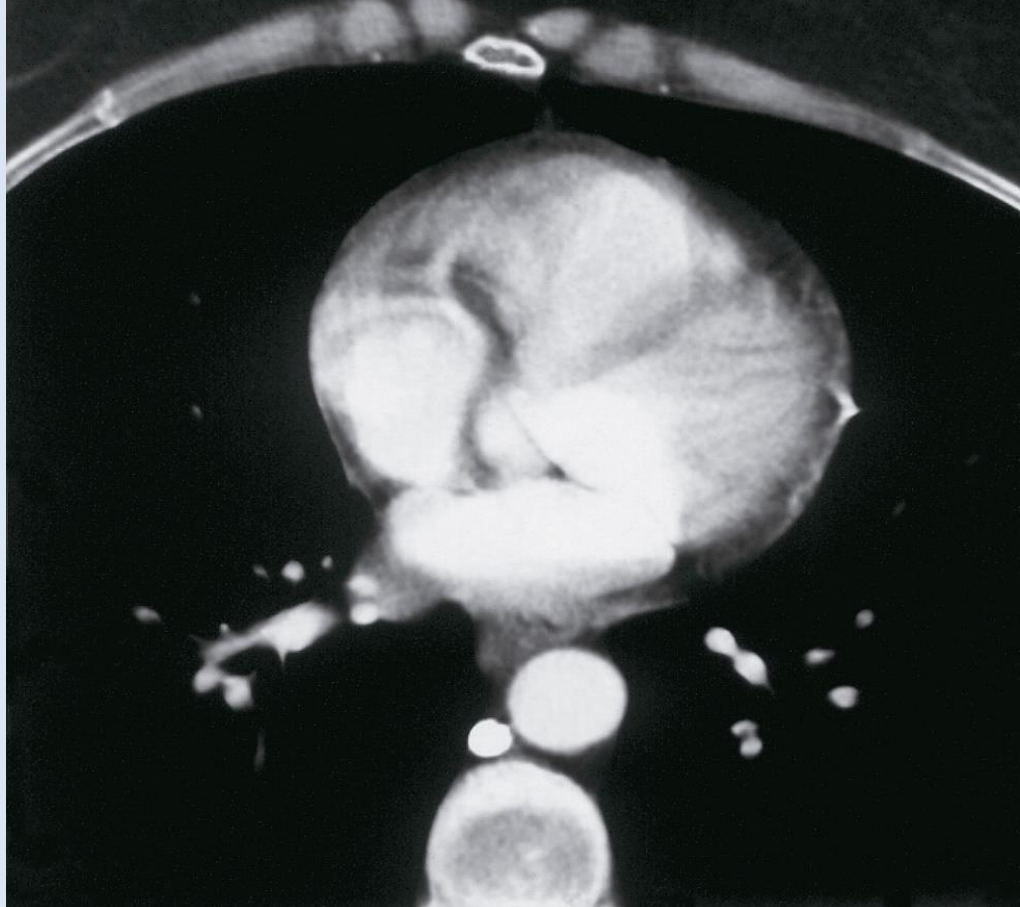
1. processus xiphoideus
2. costa (porc)
3. pulmo dexter, lobus medius
4. extrapericardialis zsírszövet
5. cavum pleurae
6. fissura obliqua
7. hepar
8. lig. falciforme hepatis
9. ventriculus dexter
10. septum interventriculare pars muscularis
11. ventriculus sinister
12. cavum pericardii
13. mm. intercostales
14. diaphragma
15. vv. hepaticae
16. vena cava inferior
17. m. serratus anterior
18. oesophagus-cardia átmenet
19. aorta descendens
20. gaster
21. v. azygosba ömlő v. intercostalis
22. v. hemiazygosba ömlő v. intercostalis
23. pulmo dexter, lobus inferior
24. pulmo sinister, lobus inferior
25. m. latissimus dorsi
26. m. erector spinae
27. m. trapezius

axial CT scans
(Kontrastmittel CT)

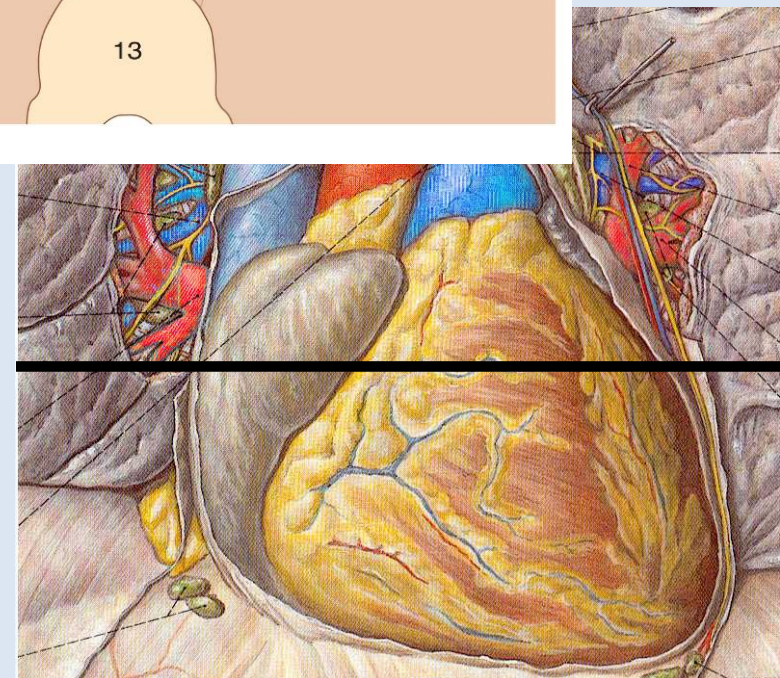


- | | |
|---|---------------------------------|
| 1. Sternum | 10. V. pulmonalis dext. |
| 2. Cartilago costalis | 11. Bronchus lobaris inf. dext. |
| 3. Pericardium | 12. A. pulmonalis dext. |
| 4. Truncus pulmonalis | 13. A. lobaris inf. sin. |
| 5. Jobb pitvar | 14. Oesophagus |
| 6. Septum interatriale | 15. Aorta |
| 7. Aorta ascendens | 16. V. azygos |
| 8. A. coronaria sin. (r. interventr. desc.) | 17. Vertebra |
| 9. Bal pitvar | |

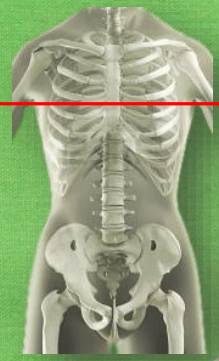




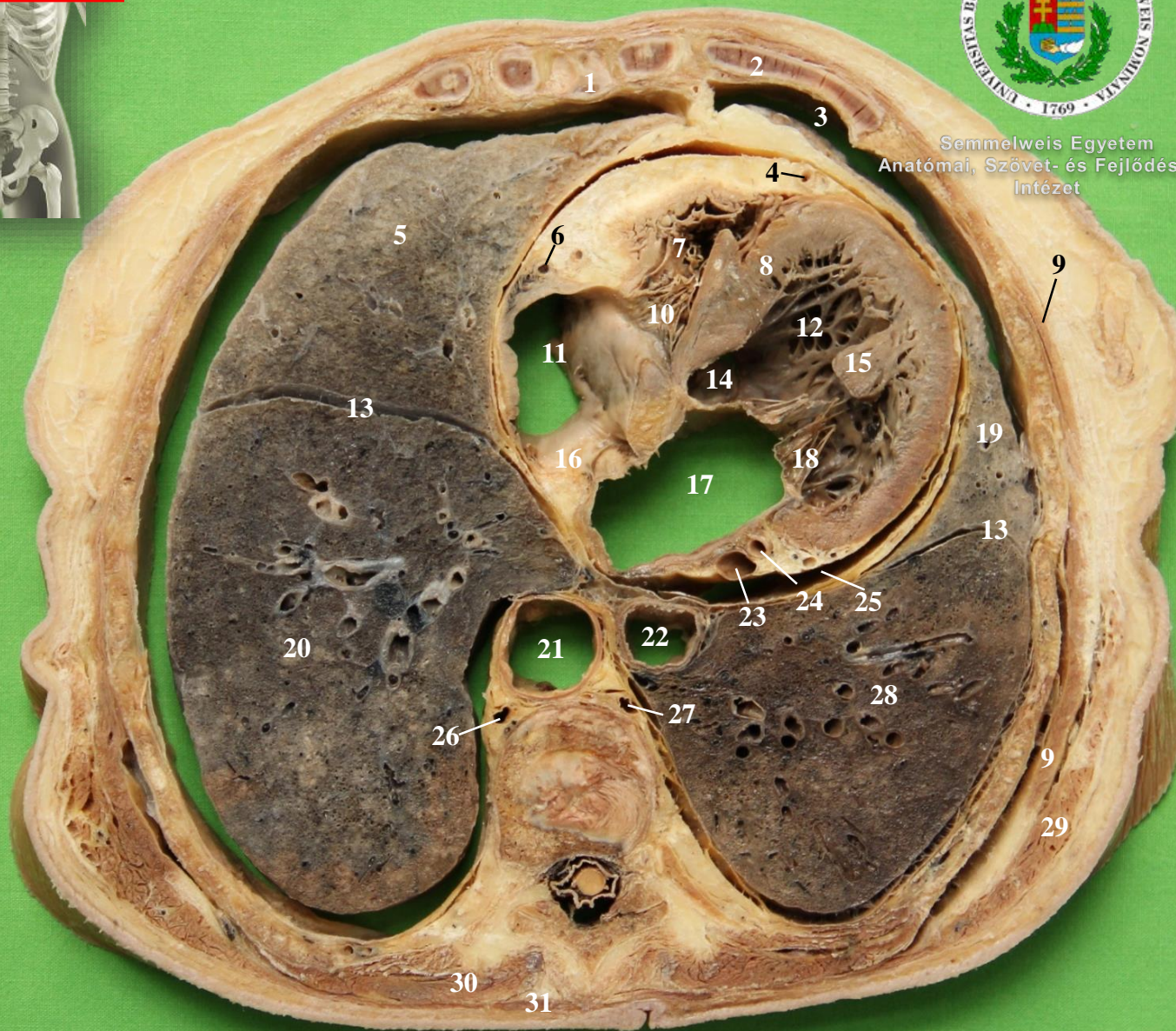- | | |
|-----------------------|---------------------------------|
| 1. Sternum | 8. Bal pitvar |
| 2. Cartilago costalis | 9. Vv. pulmonales dextt. |
| 3. Pericardium | 10. Oesophagus |
| 4. Jobb kamra | 11. Aorta |
| 5. A. coronaria dext. | 12. V. azygos |
| 6. Jobb pitvar | 13. Vertebra |
| 7. Bal kamra | |



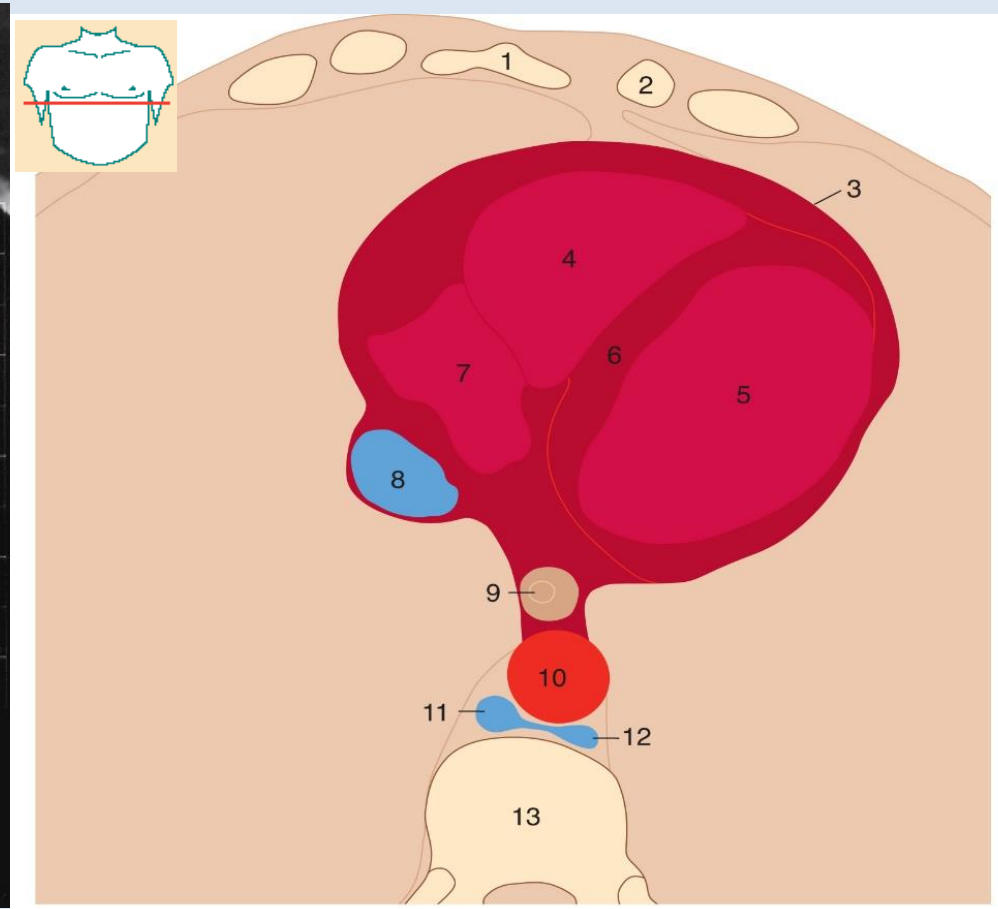
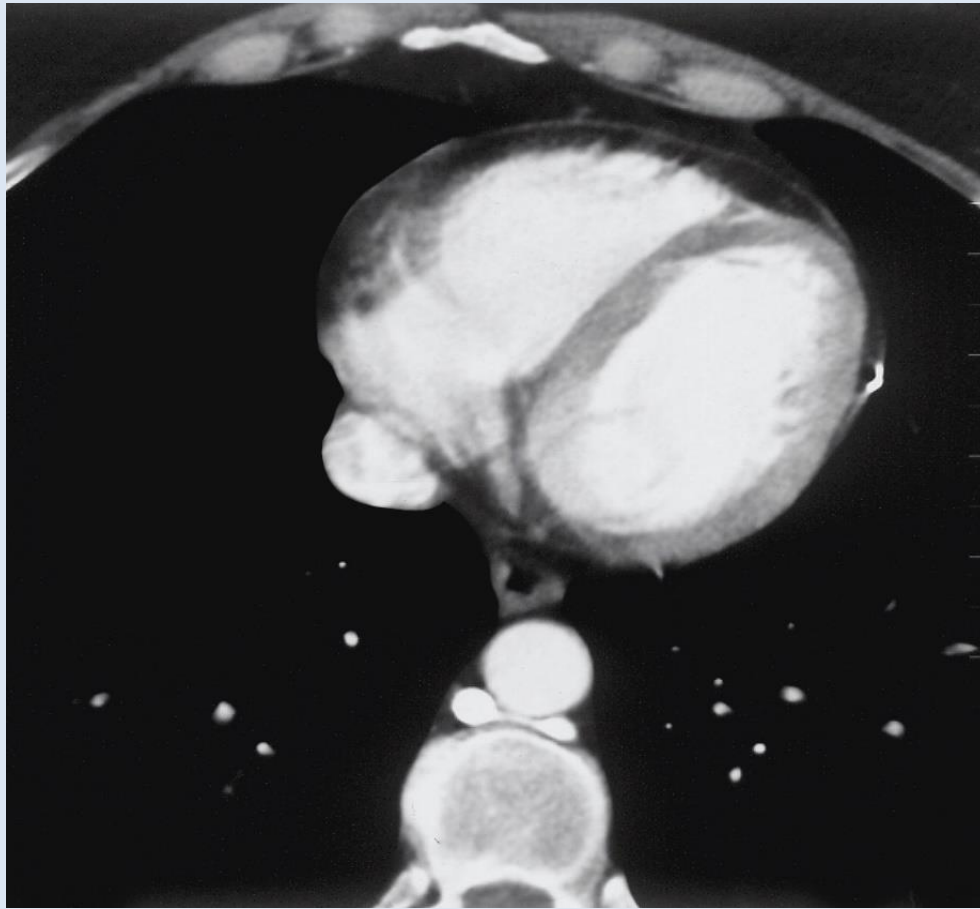
Th8/9



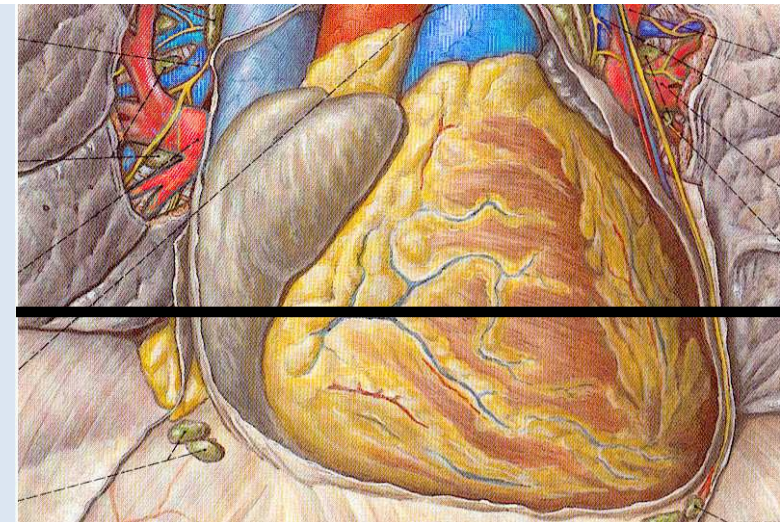
Semmelweis Egyetem
Anatómiai, Szövet- és Fejlődéstani
Intézet

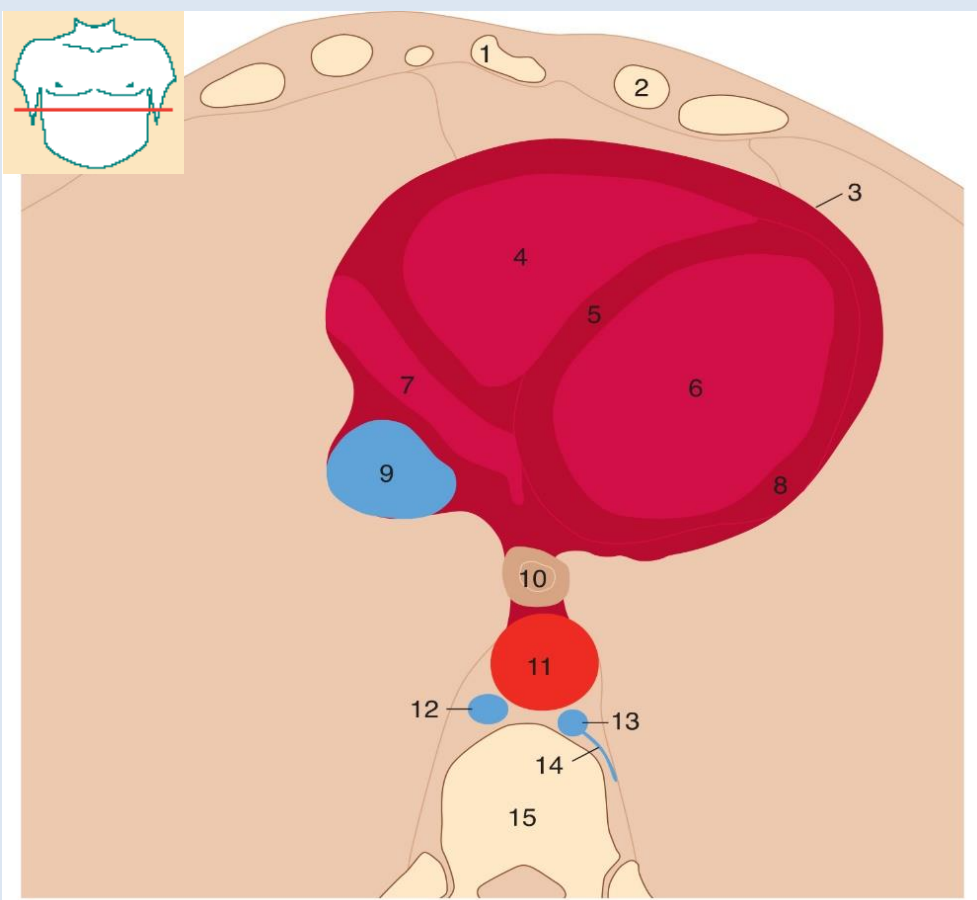
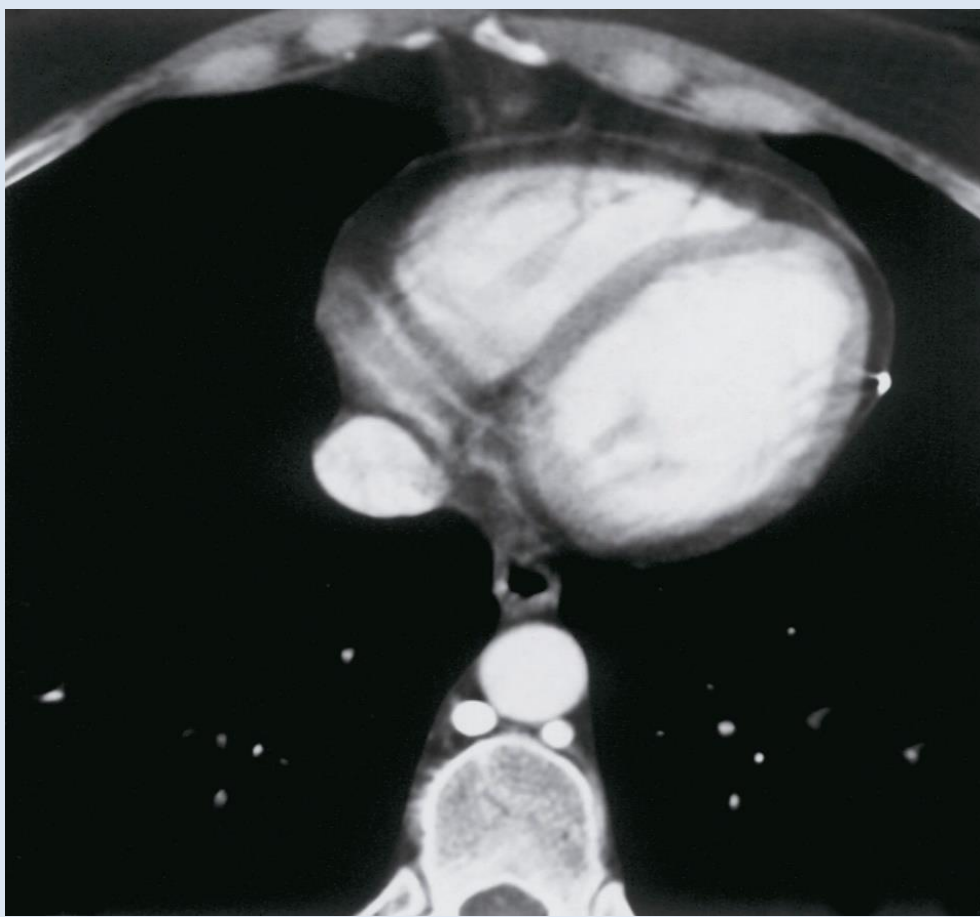


1. sternum
2. costa
3. cavum pleurae
4. a.v. interventricularis anterior
5. pulmo dexter, lobus medius
6. a. coronaria dextra
7. ventriculus dexter
8. septum interventriculare pars muscularis
9. m. serratus anterior
10. valva tricuspidalis, cuspis septalis
11. atrium dextrum
12. ventriculus sinister
13. fissura obliqua
14. ostium aortae
15. m. papillaris anterior
16. septum interatriale
17. atrium sinistrum
18. valva bicuspidalis/mitralis
19. lingula pulmonis
20. pulmo dexter, lobus inferior
21. aorta descendens
22. oesophagus
23. v. cordis magna
24. ramus circumflexus
25. cavum pericardii
26. v. azygos
27. v. hemiazygos
28. pulmo sinister, lobus inferior
29. m. latissimus dorsi
30. m. erector spinae
31. m. trapezius

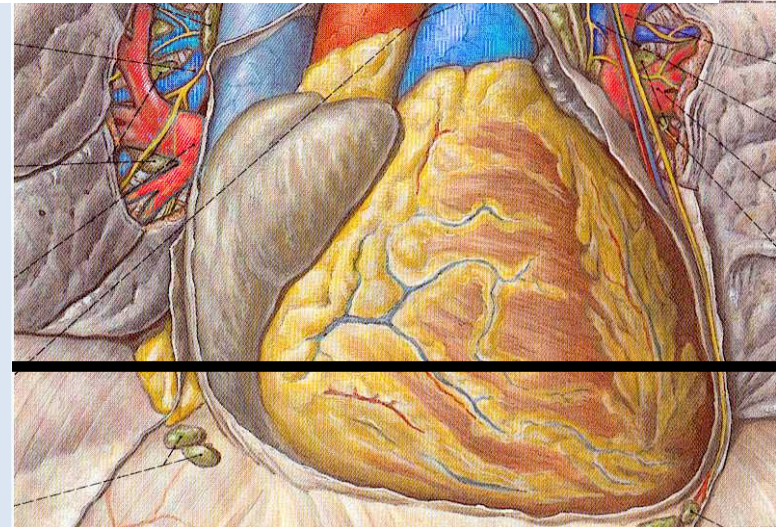


- | | |
|--------------------------------------|-------------------|
| 1. Sternum | 8. V. cava inf. |
| 2. Cartilago costalis | 9. Oesophagus |
| 3. Pericardium | 10. Aorta |
| 4. Jobb kamra ürege | 11. V. azygos |
| 5. Bal kamra ürege | 12. V. hemiazygos |
| 6. Septum interventriculare p. musc. | 13. Vertebra |
| 7. Jobb pitvar | |



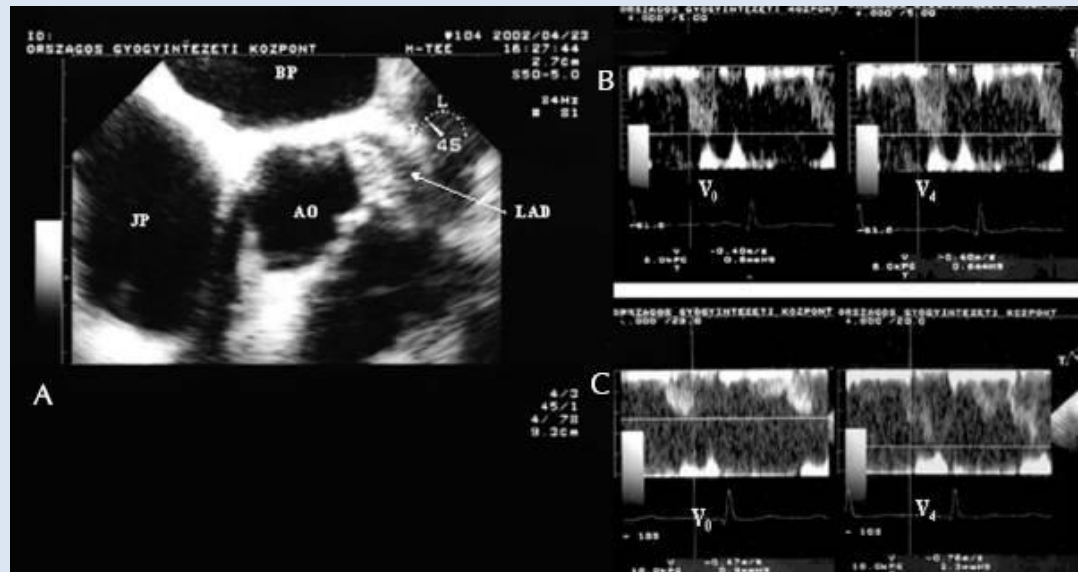
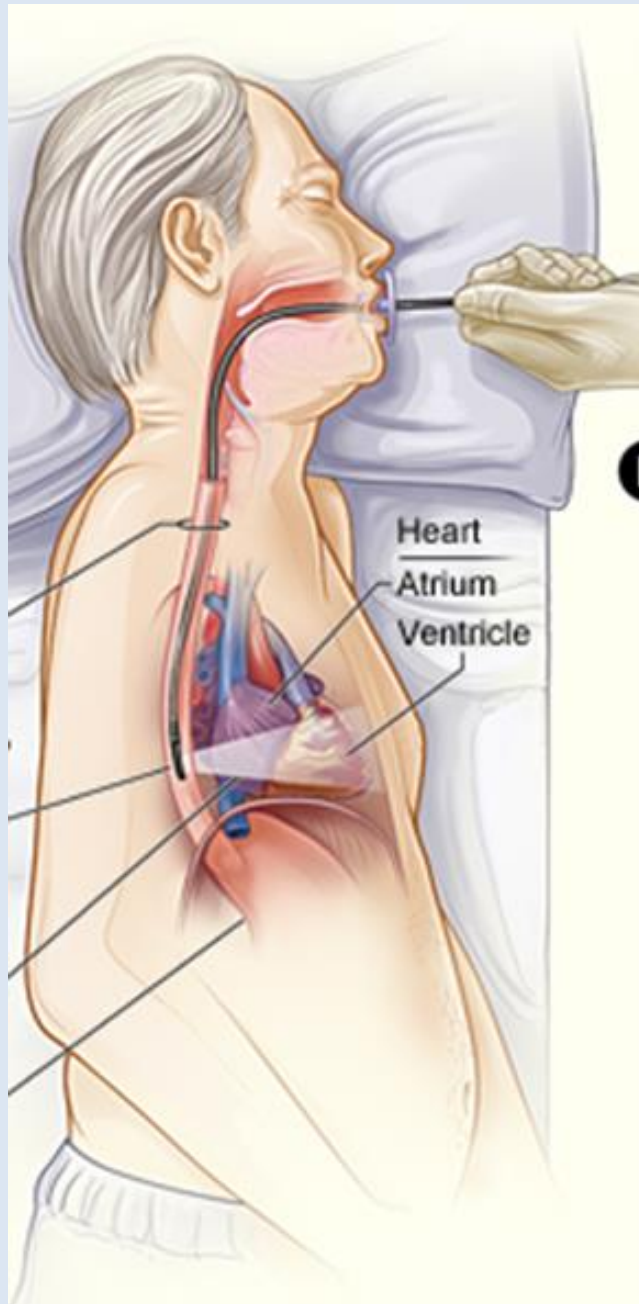


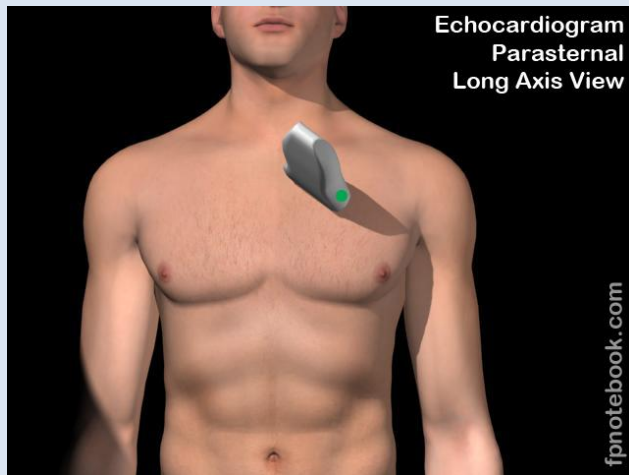
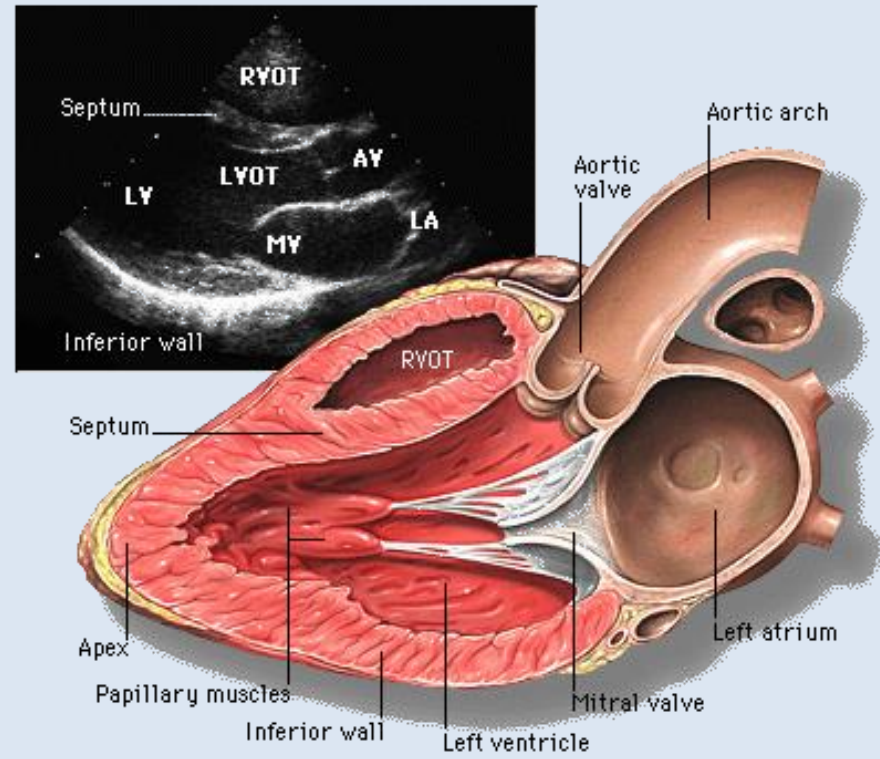
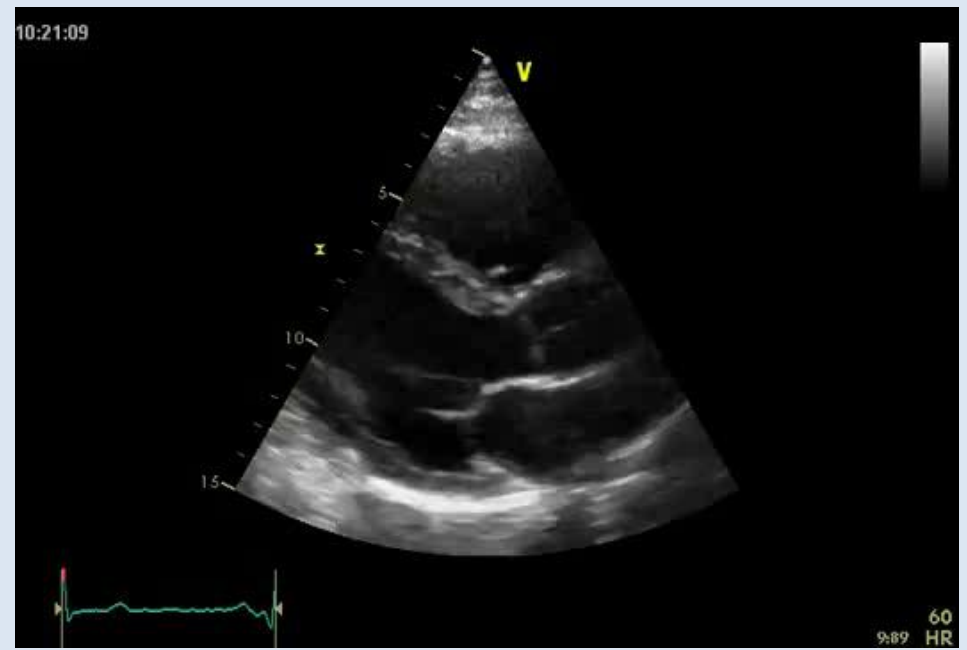
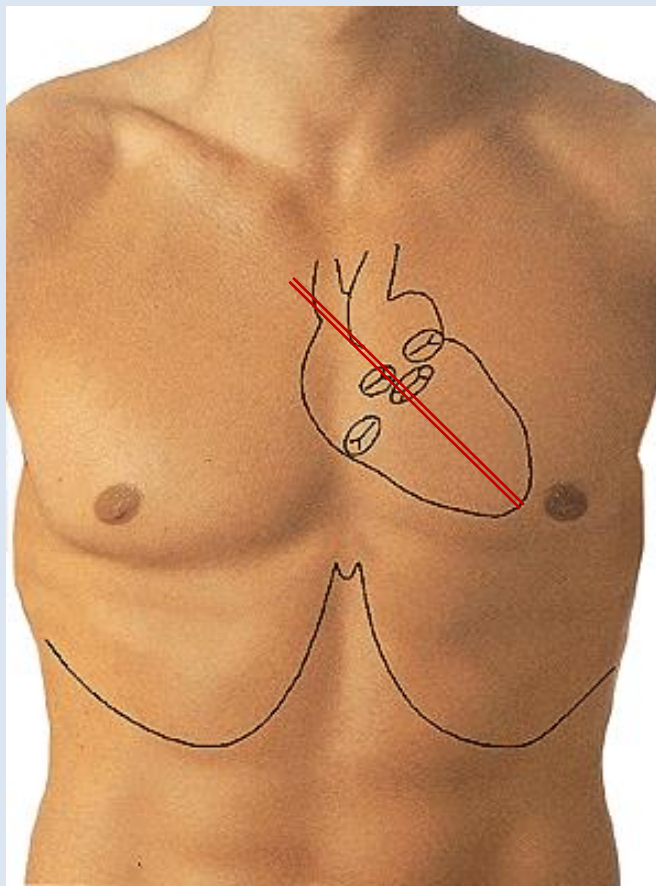
- | | |
|--|----------------------------|
| 1. Sternum | 9. V. cava inf. |
| 2. Cartilago costalis | 10. Oesophagus |
| 3. Pericardium | 11. Aorta |
| 4. Jobb kamra | 12. V. azygos |
| 5. Septum interventriculare, pars muscularis | 13. V. hemiazygos |
| 6. Bal kamra | 14. V. intercostalis post. |
| 7. Jobb pitvar | 15. Vertebra |
| 8. Bal kamra fala | |

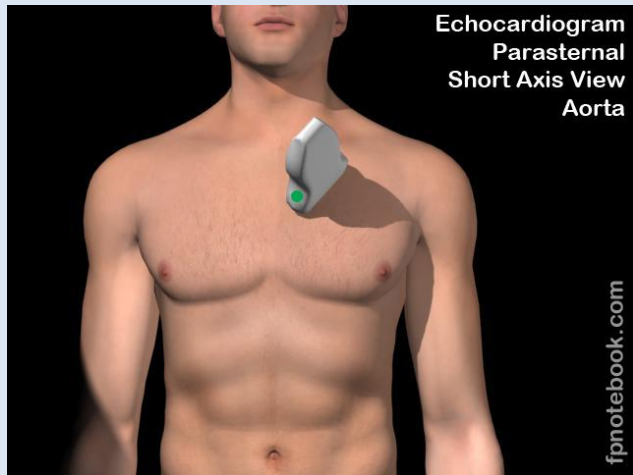
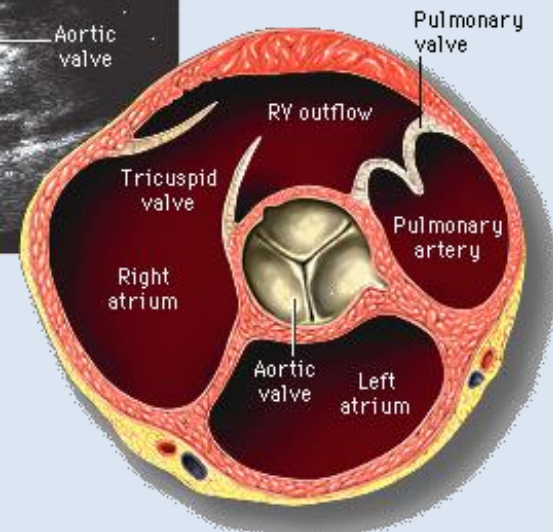
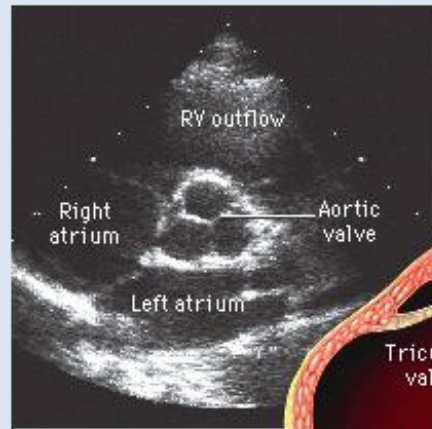
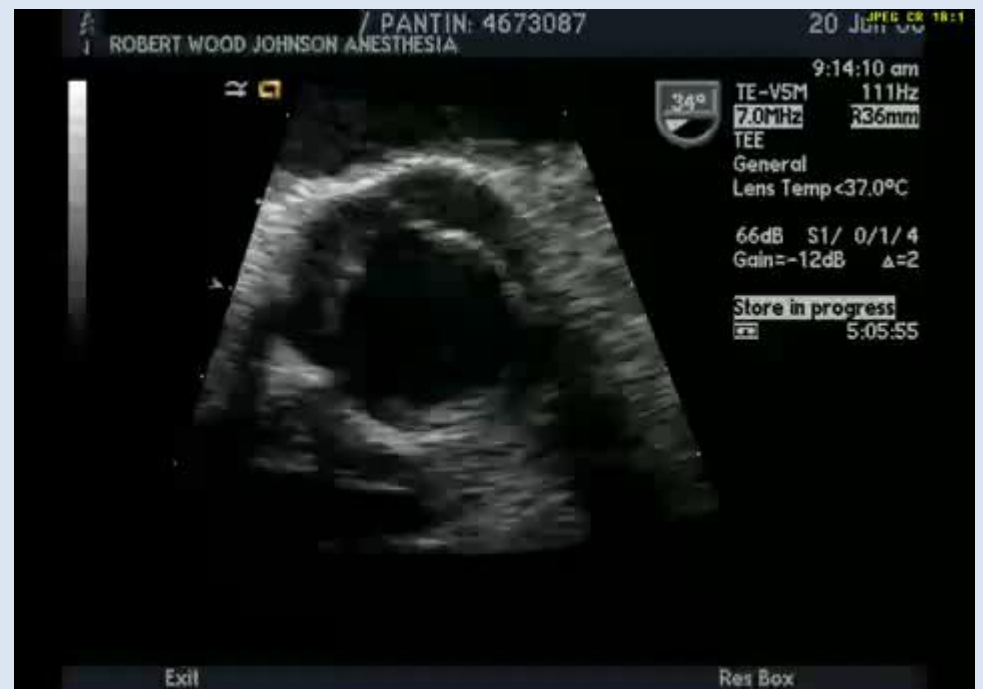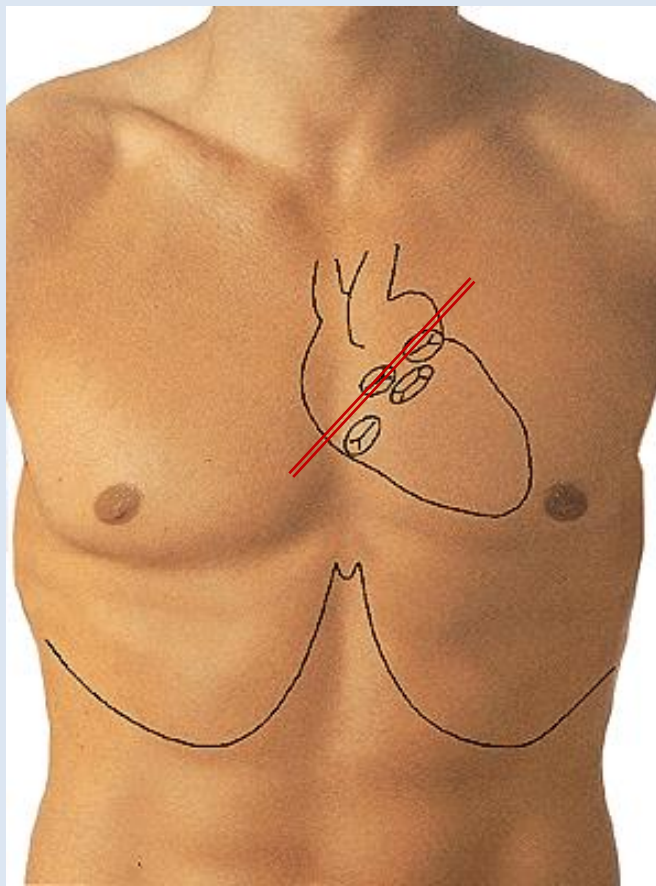


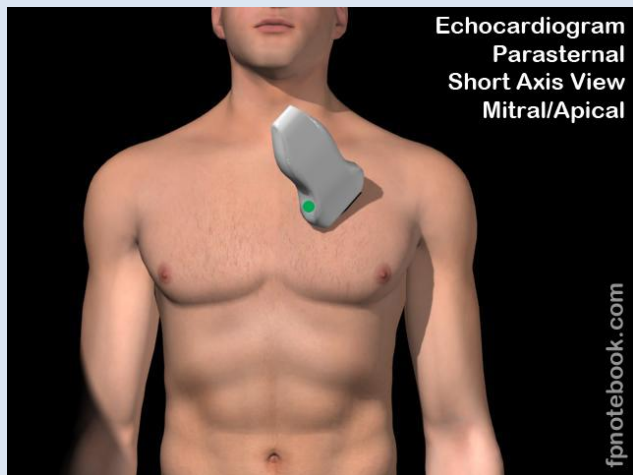
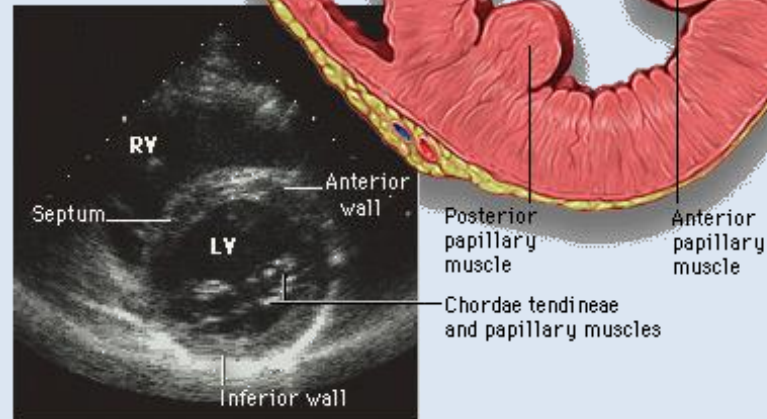
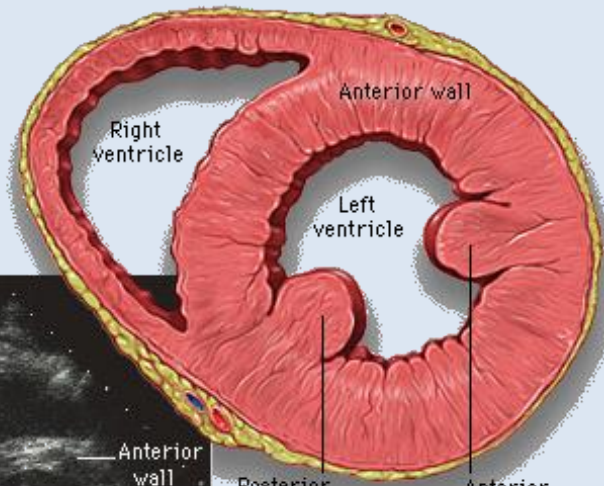
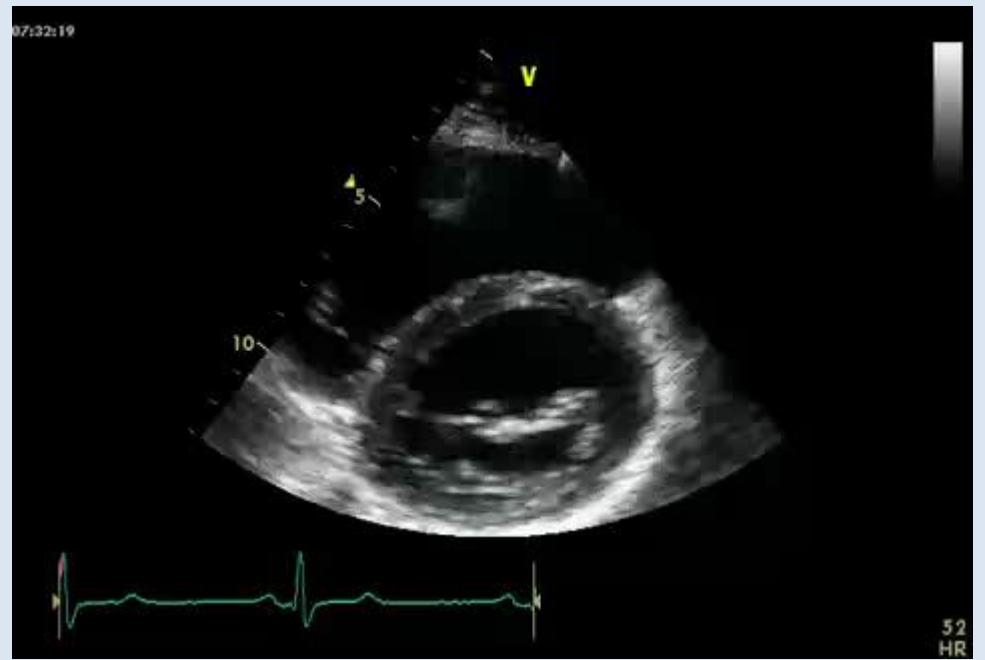
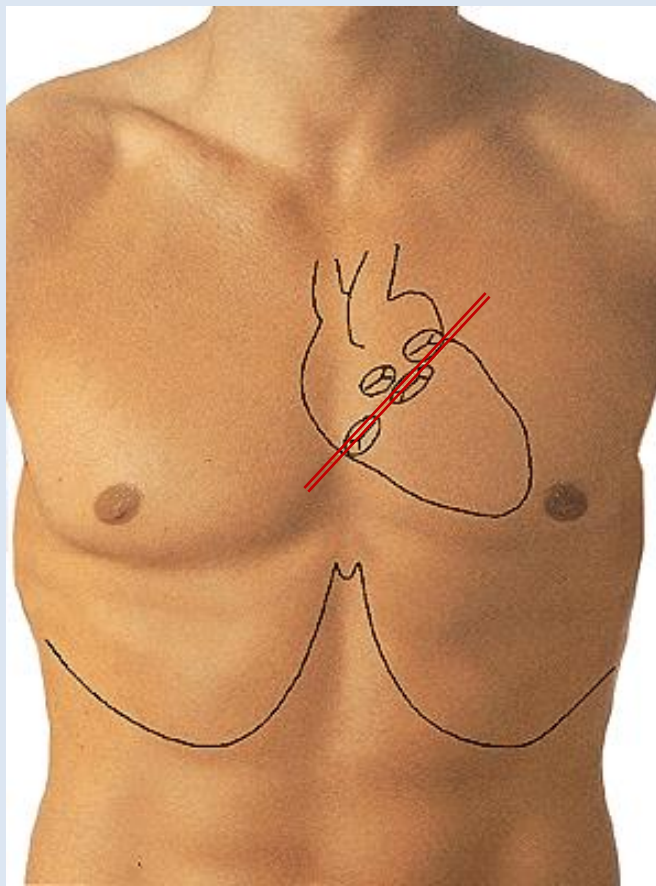
Echokardiographie

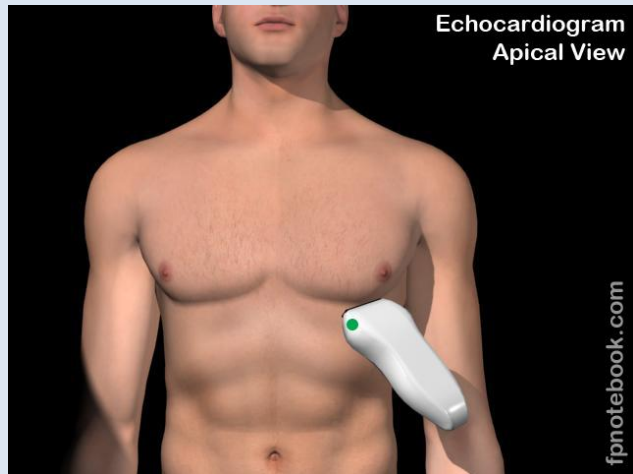
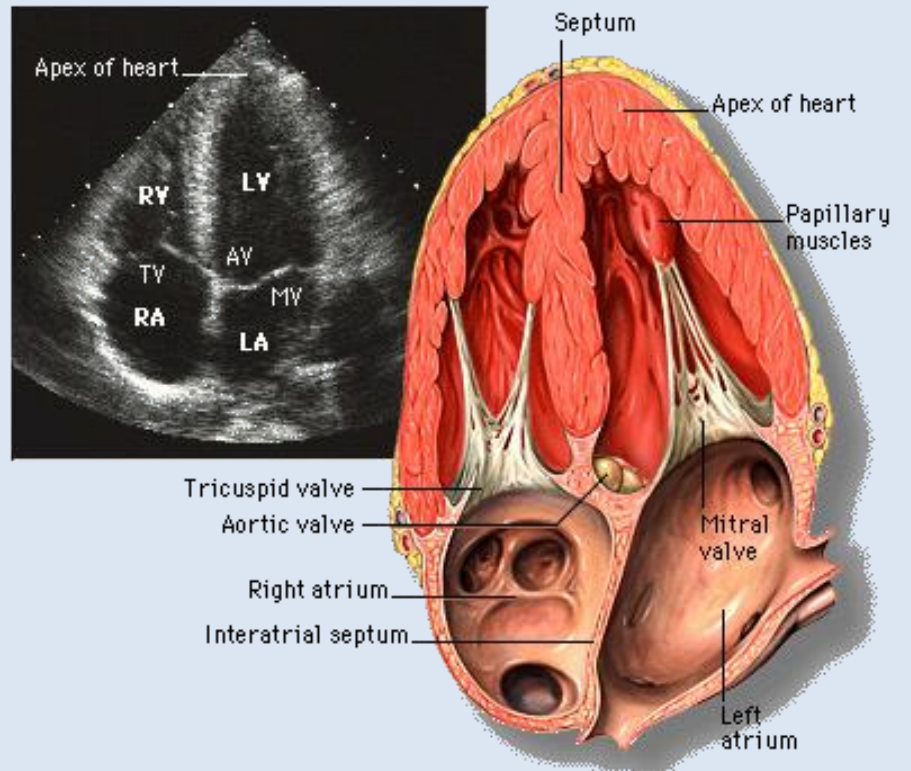
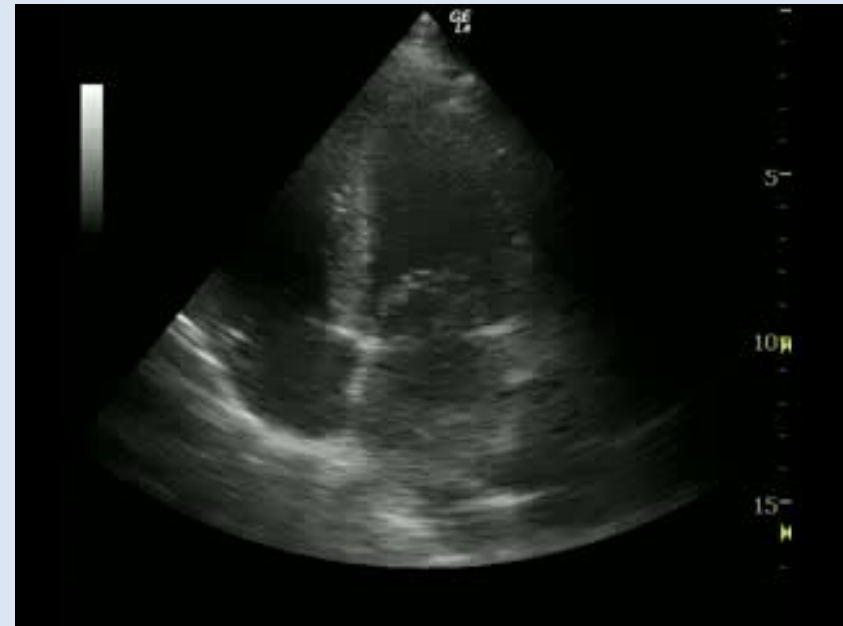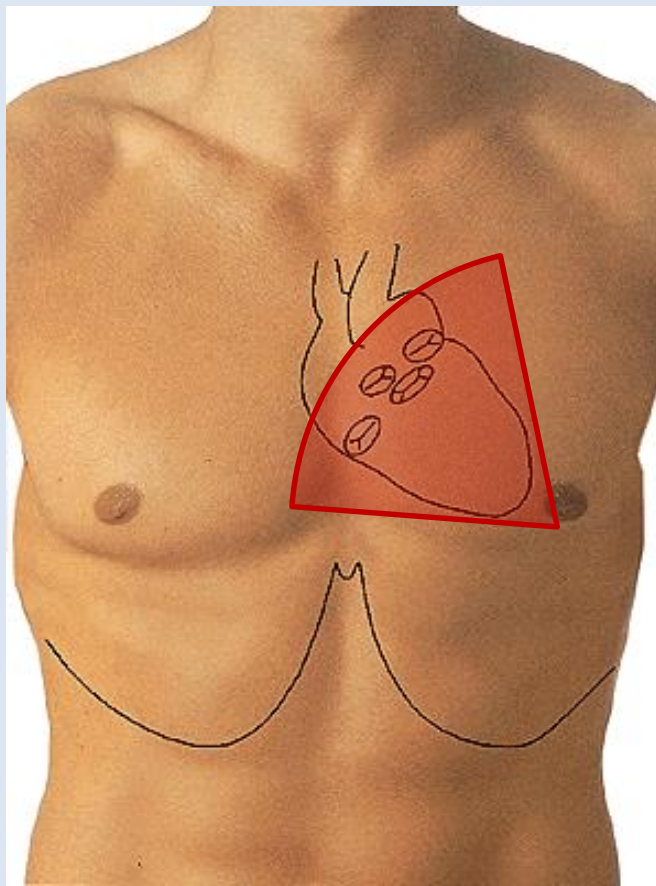
Transesophageal Ultrasound (TUS)





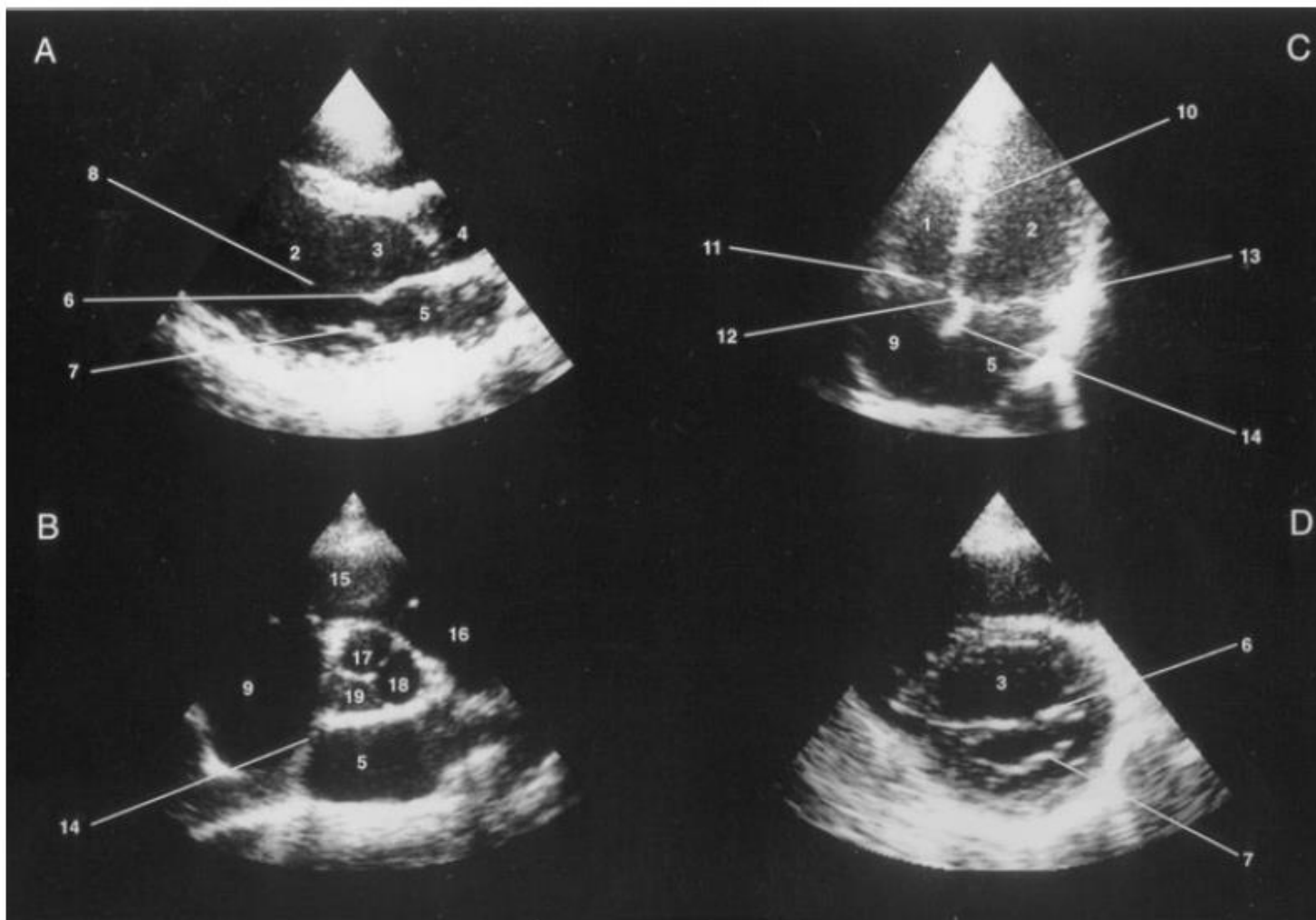






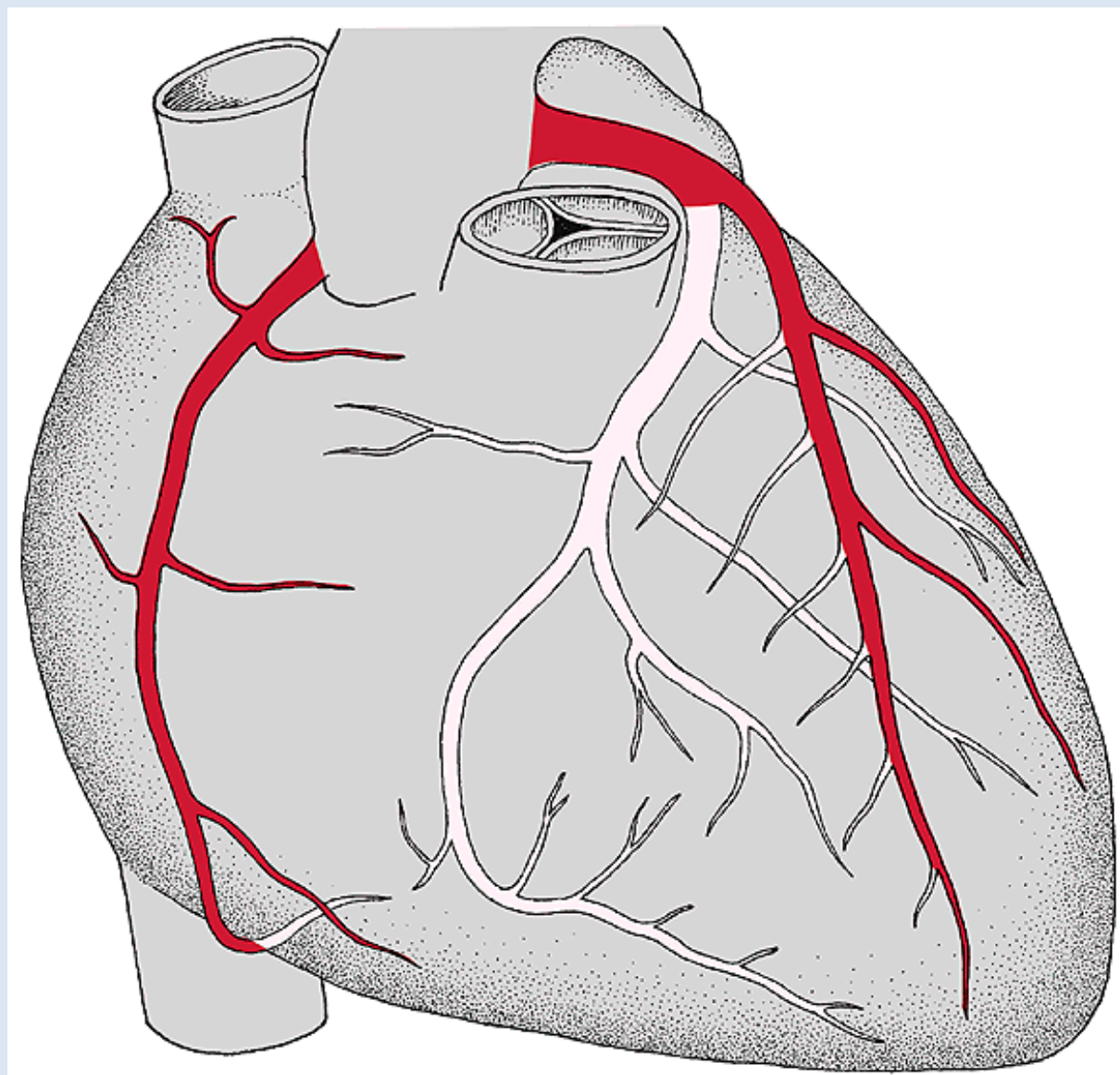
Echocardiográfia


A – hosszú axis felv.; B – aorta billentyű; C – a négy üreg; D – bal parasternalis rövid axis felv.

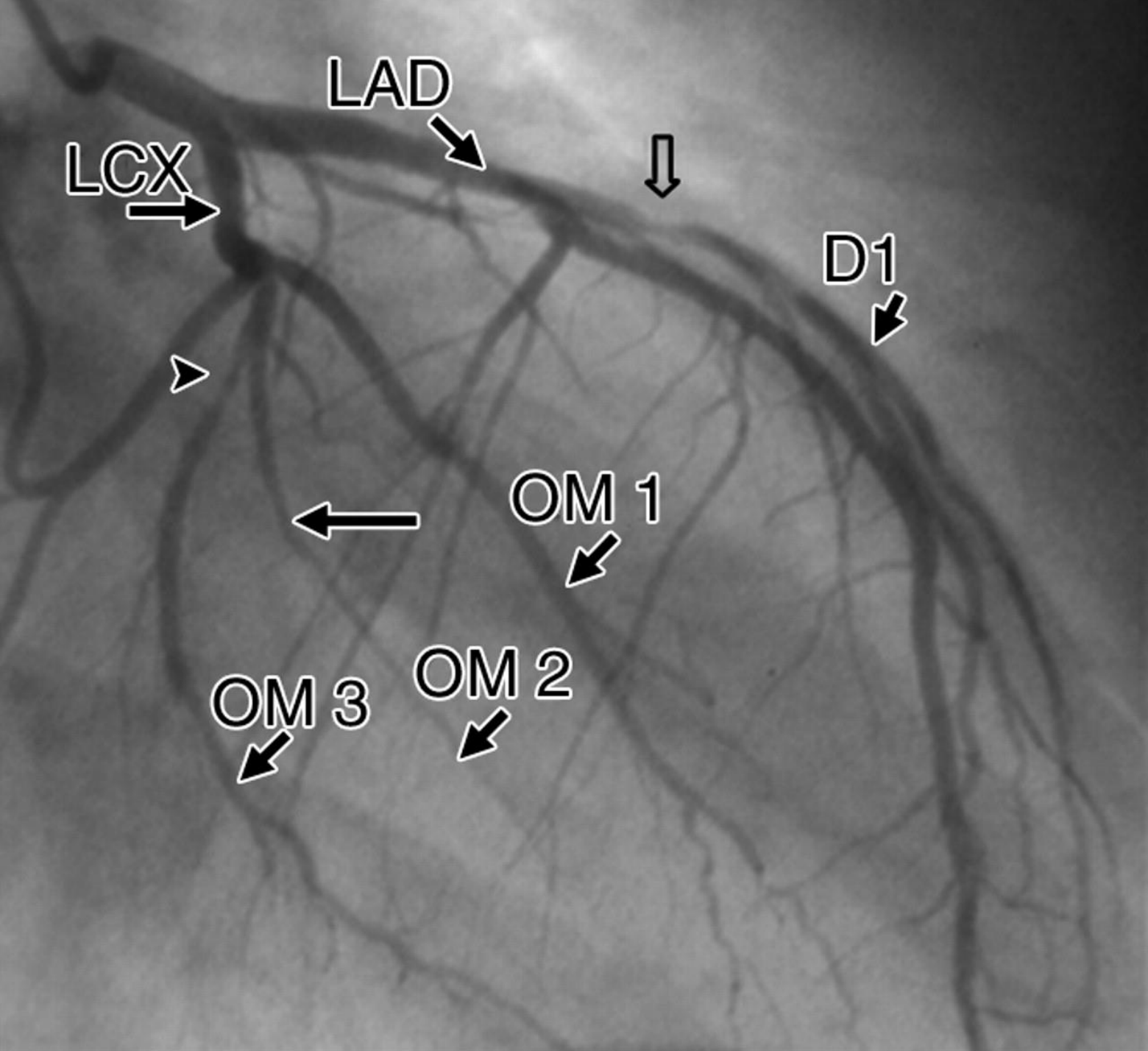


1. Jobb kamra
2. Bal kamra
3. Bal kamra kiáramlási zóna
4. Aorta
5. Bal pitvar
6. Cuspis ant. valvae mitralis
7. Cuspis post. valvae mitralis
8. Chordae tendineae
9. Jobb pitvar
10. Septum interventriculare
11. Valva tricuspidalis
12. Septum atrioventriculare
13. Valva bicuspidalis (mitralis)
14. Septum interatriale
15. Jobb kamra, kiáramlási zóna
16. A. pulmonalis
17. Valvula semilun. dext. aortae
18. Valvula semilun. sin. aortae
19. Valvula semilun. post. aortae

Coronarographie

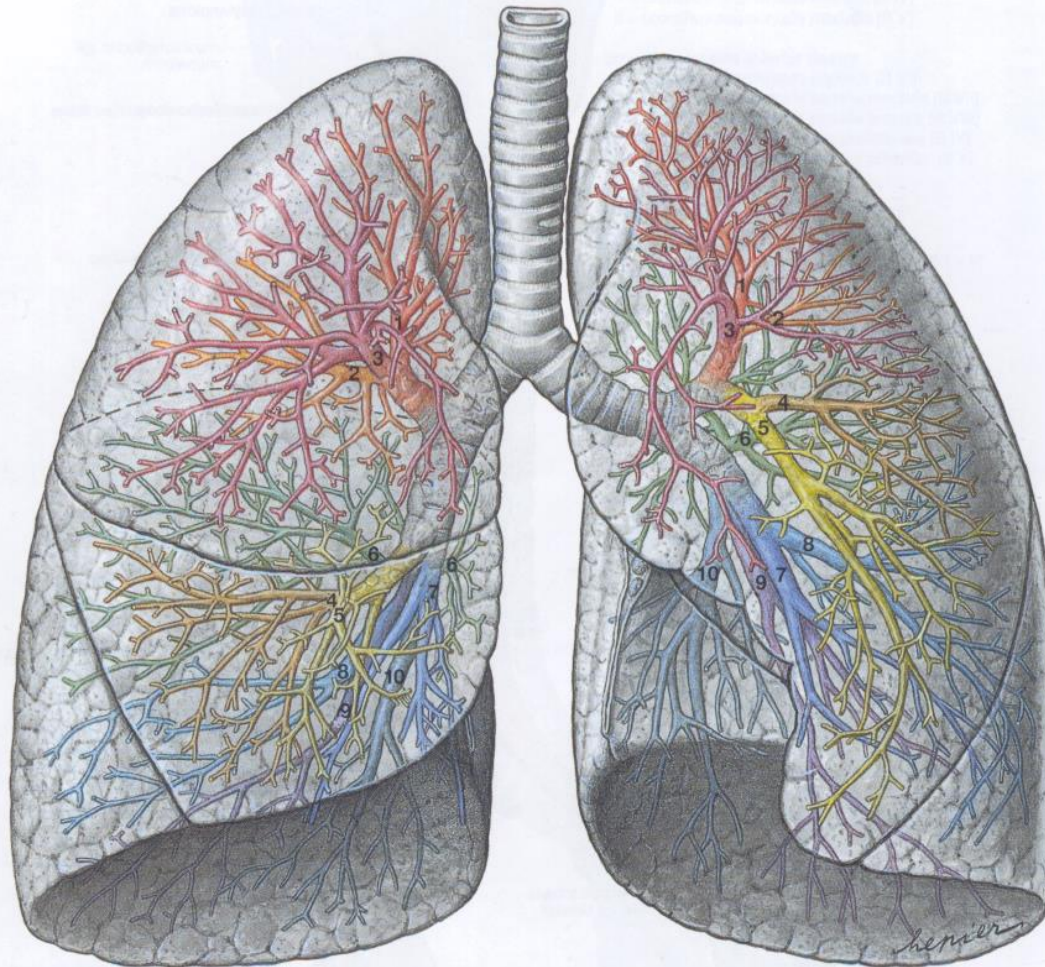






Anatomie der Lunge

Tüdőszegmentumok



bronchus principalis dexter

bronchus lobaris superior dexter

- 1 = bronchus segmentalis apicalis [B I]
- 2 = bronchus segmentalis posterior [B II]
- 3 = bronchus segmentalis anterior [B III]

bronchus lobaris medius dexter

- 4 = bronchus segmentalis lateralis [B IV]
- 5 = bronchus segmentalis medialis [B V]

bronchus lobaris inferior dexter

- 6 = bronchus segmentalis superior [B VI]
- 7 = bronchus segmentalis basalis medialis [B VII]
- 8 = bronchus segmentalis basalis anterior [B VIII]
- 9 = bronchus segmentalis basalis lateralis [B IX]
- 10 = bronchus segmentalis basalis posterior [B X]

bronchus principalis sinister

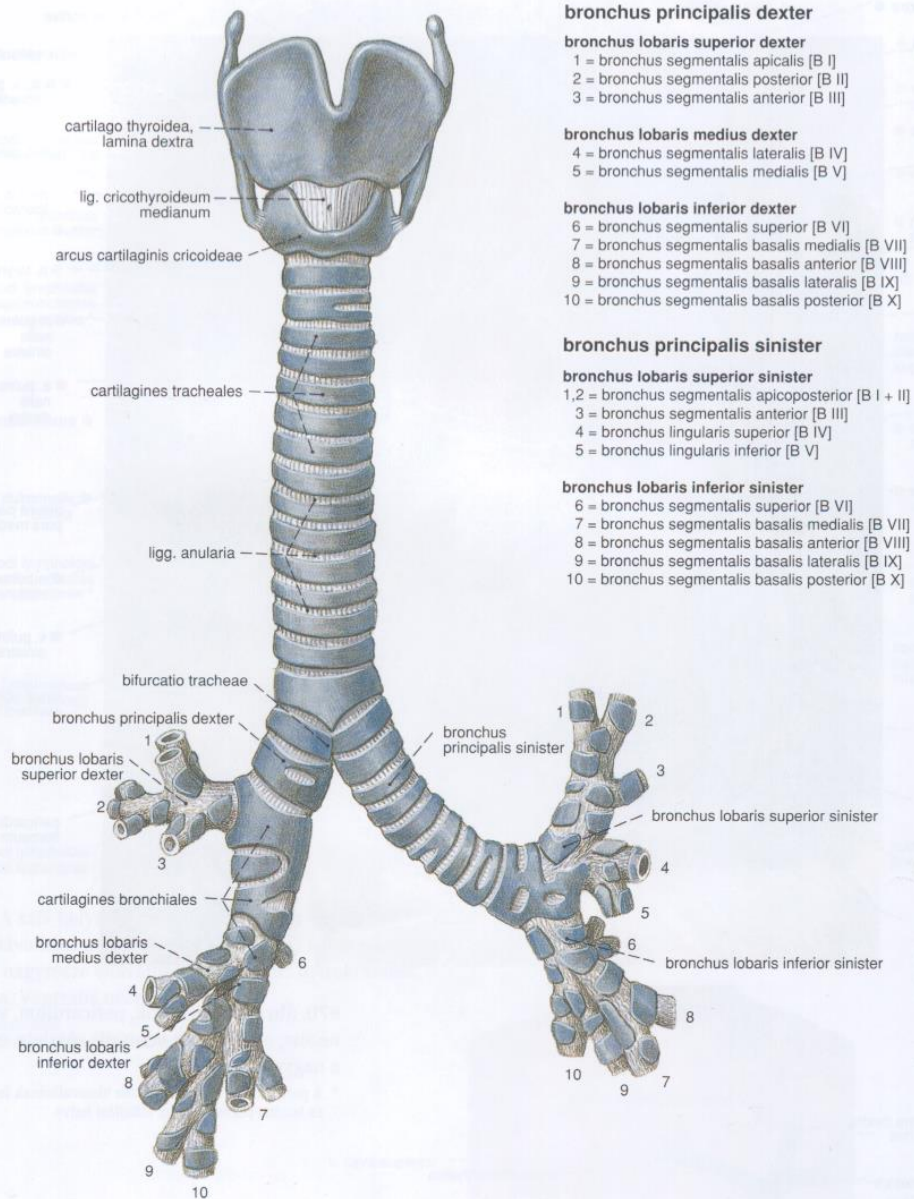
bronchus lobaris superior sinister

- 1,2 = bronchus segmentalis apicoposterior [B I + II]
- 3 = bronchus segmentalis anterior [B III]
- 4 = bronchus lingularis superior [B IV]
- 5 = bronchus lingularis inferior [B V]

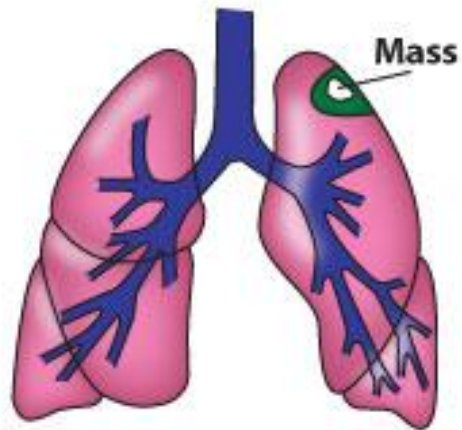
bronchus lobaris inferior sinister

- 6 = bronchus segmentalis superior [B VI]
- 7 = bronchus segmentalis basalis medialis [B VII]
- 8 = bronchus segmentalis basalis anterior [B VIII]
- 9 = bronchus segmentalis basalis lateralis [B IX]
- 10 = bronchus segmentalis basalis posterior [B X]

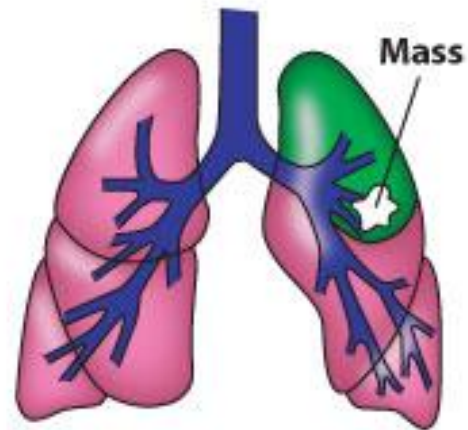
874. ábra A tüdők, pulmones, bronchusok, bronchi, ventralis nézete; a lebeny- és segmentbronchusok különböző színben a tüdő felszínére vetítve. A számok a segmentbronchusokat jelölik (lásd a 92. oldalon). Baloldalt az S I és S II szelvény gyakran közös bronchussal rendelkezik és a mediobasalis S VII szelvény hiányzik



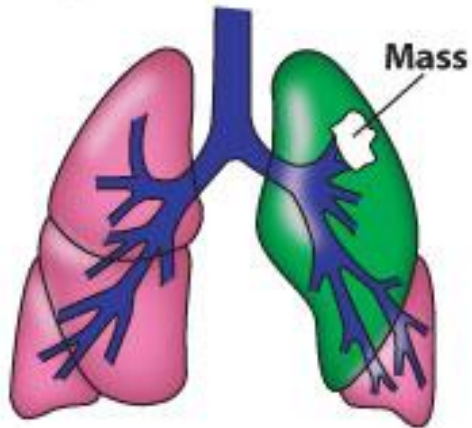
872. ábra A gége, larynx, a légcső, trachea, a bronchusok és bronchiolusok előlnézeti képe. Baloldalt többnyire hiányzik a medialis basalis segment-bronchus [B VII]



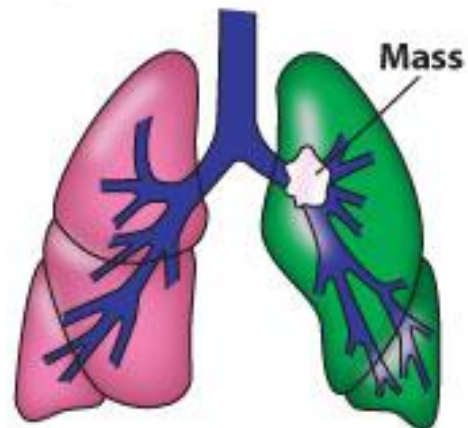
Wedge Resection
removes a small
portion of a lobe.



Segment Resection
removes a larger
portion of a lobe.

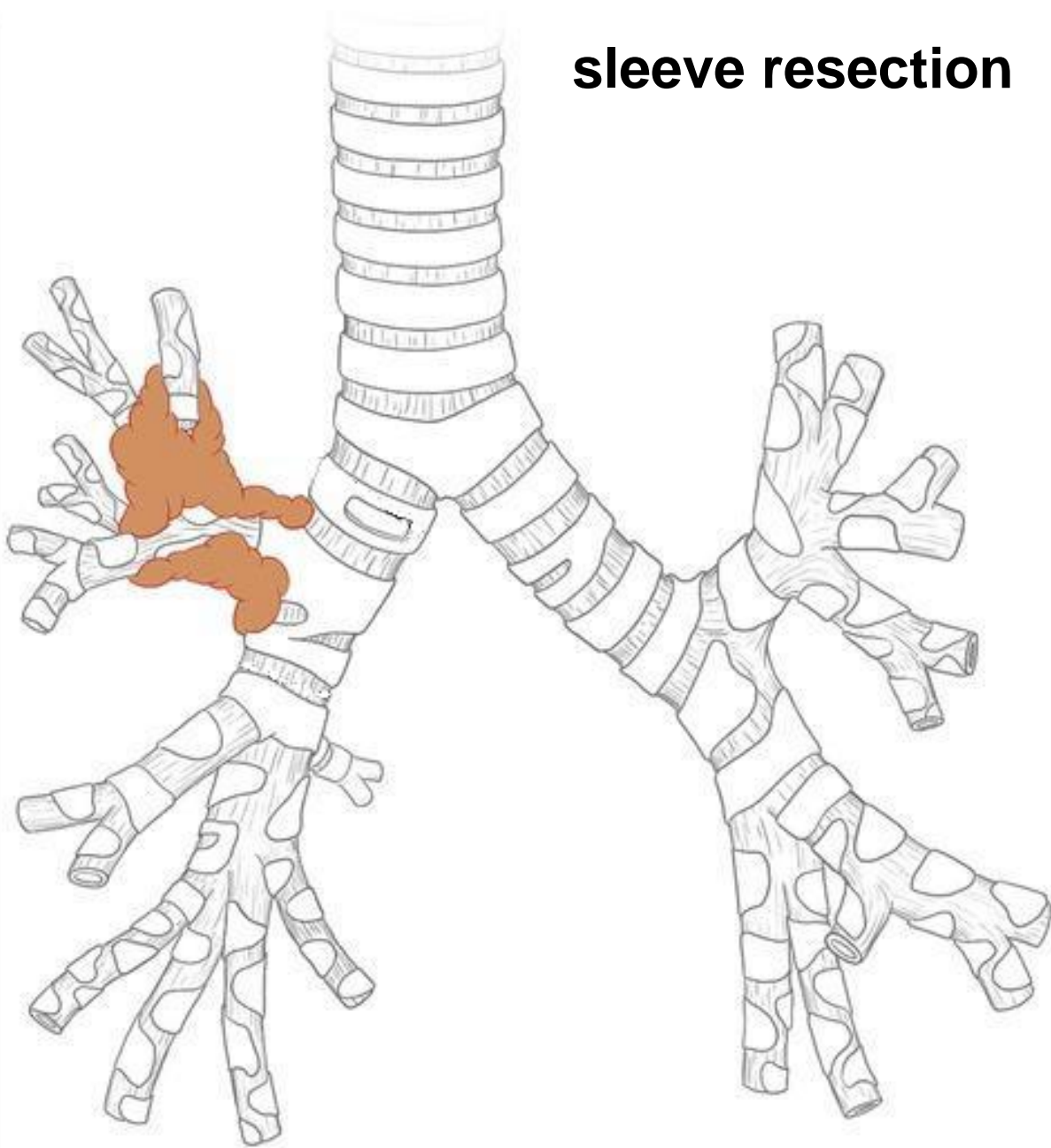


Lobectomy removes
an entire lobe.

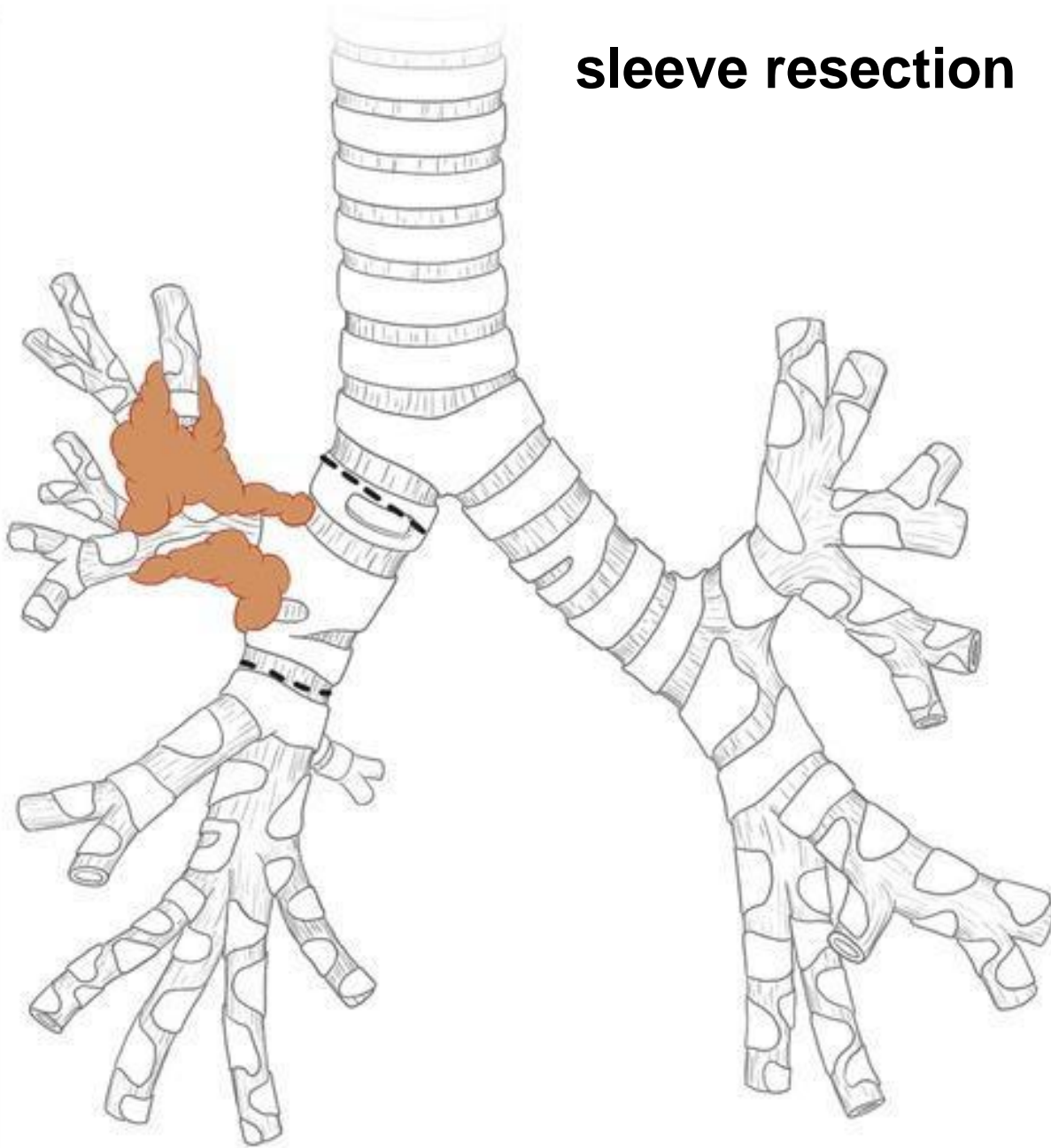


Pneumonectomy
removes the entire lung.

sleeve resection



sleeve resection



sleeve resection

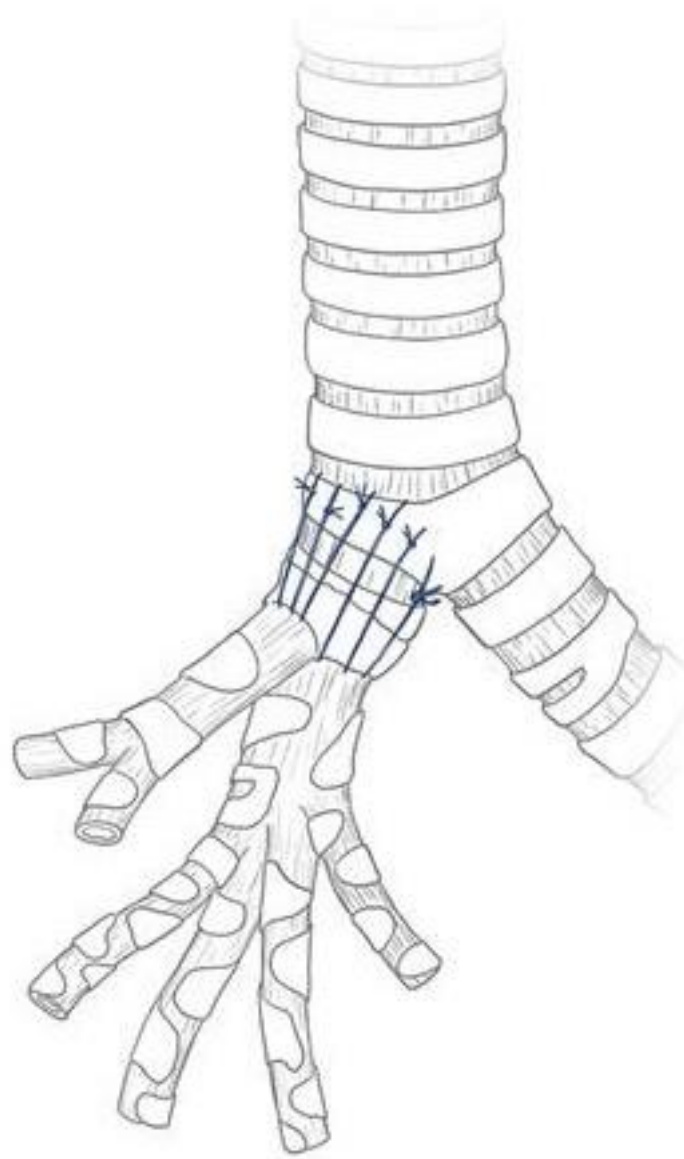
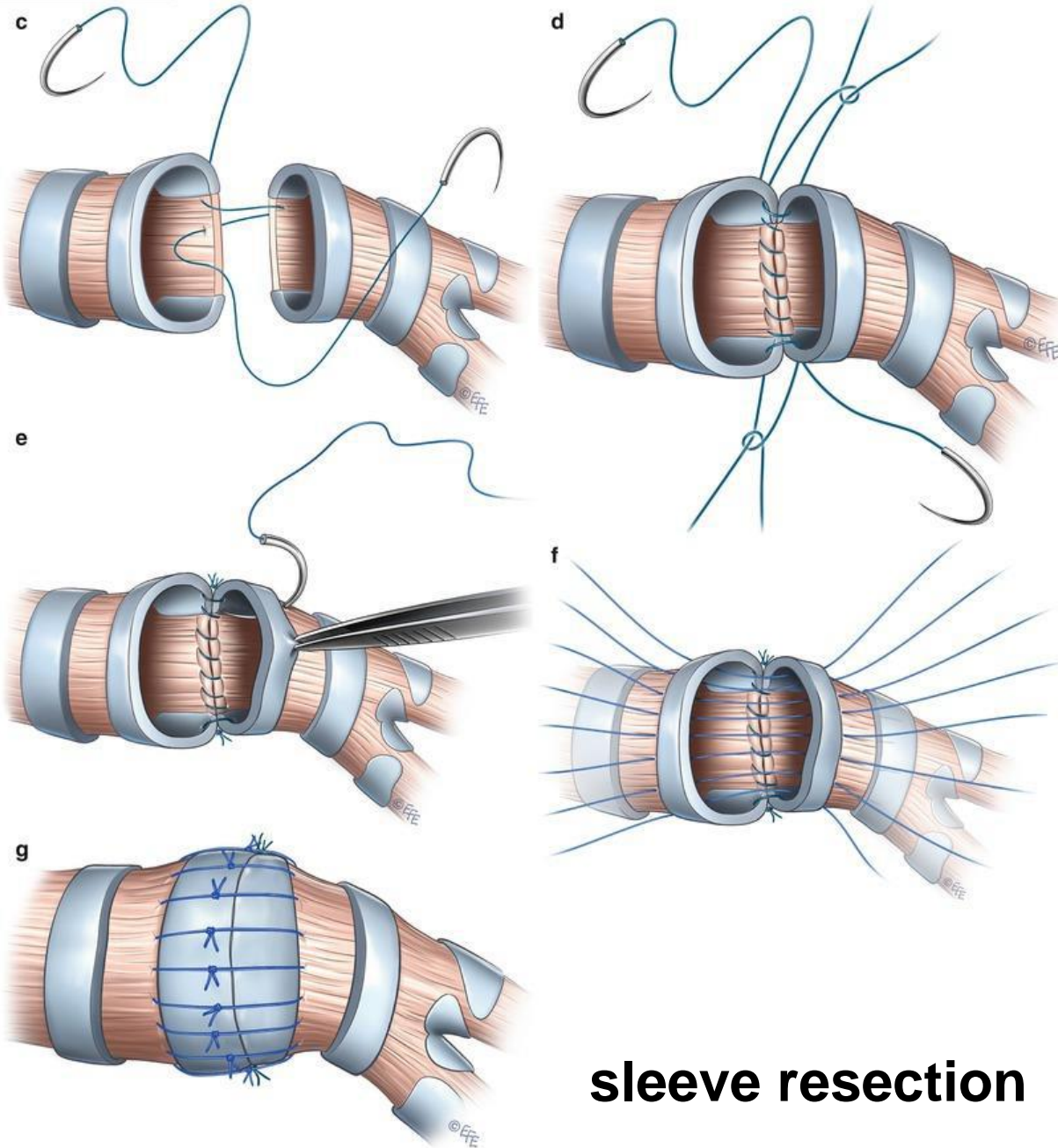
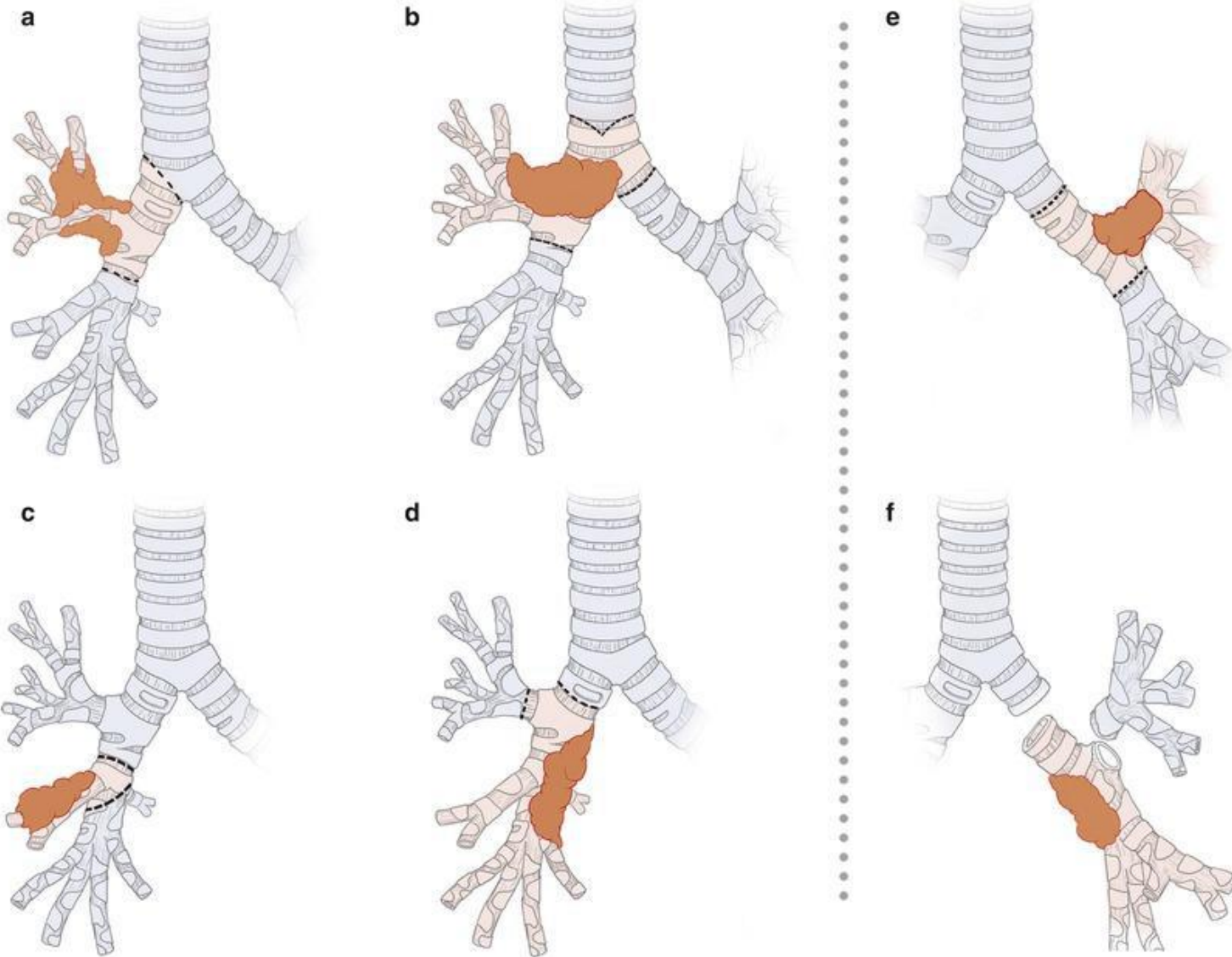


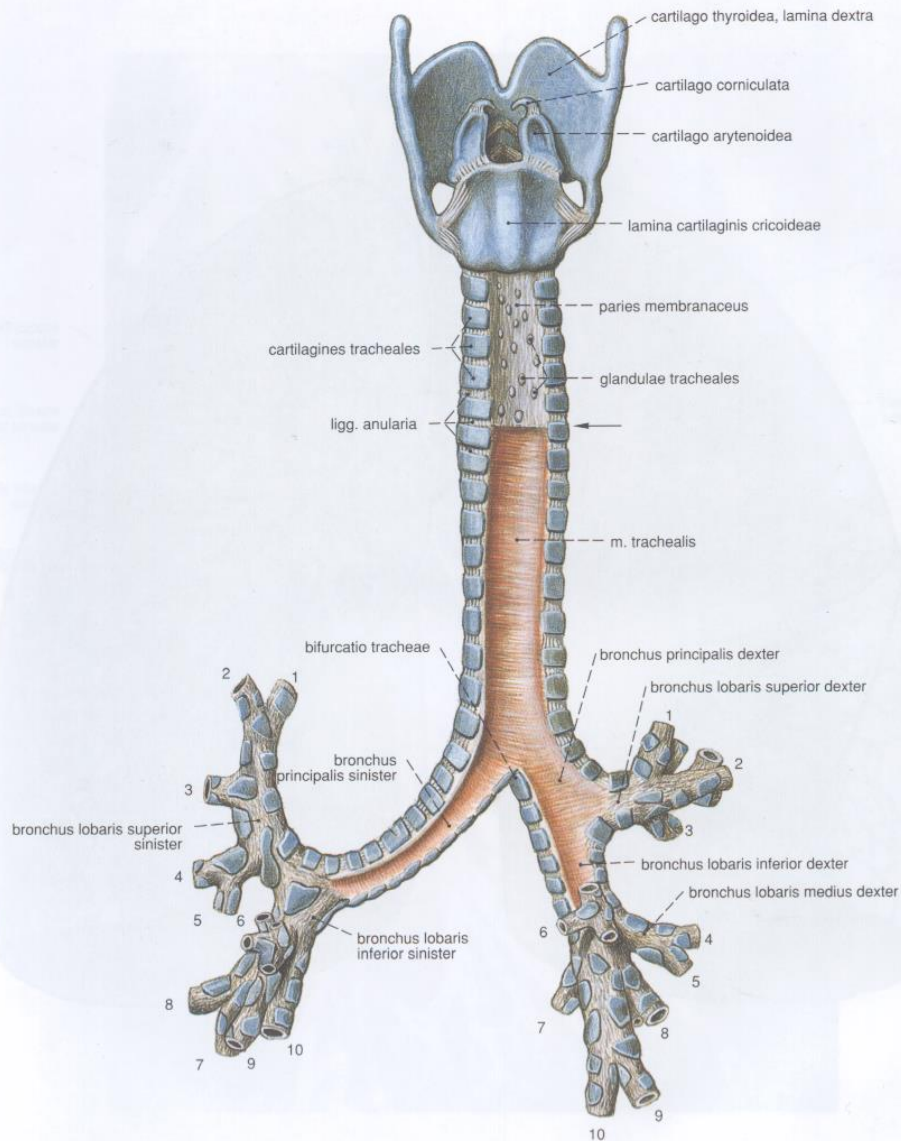
Figure 18.1c–g



sleeve resection

Figure 18.2





873. ábra A gége, larynx, a légső, trachea, a bronchusok és bronchiolusok dorsalis nézete; a nyíl alatti területen a paries membranaceus felszínes rétege eltávolítva a légső izomzatának bemutatására. A számok a segment-bronchusokat jelölik (l. még a 92. oldalon)

pulmo dexter

pulmo dexter, lobus superior

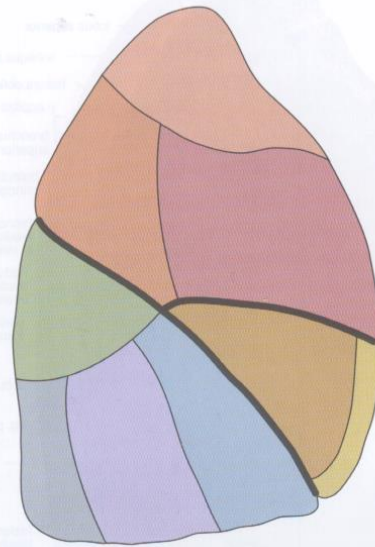
- segmentum apicale [S I]
- segmentum posterius [S II]
- segmentum anterius [S III]

pulmo dexter, lobus medius

- segmentum laterale [S IV]
- segmentum mediale [S V]

pulmo dexter, lobus inferior

- segmentum superius [S VI]
- segmentum basale mediale [cardiacum] [S VII]
- segmentum basale anterius [S VIII]
- segmentum basale laterale [S IX]
- segmentum basale posterius [S X]



880. ábra A jobb tüdő, pulmo dexter, bronchopulmonalis segmentumai, segmenta bronchopulmonalia, oldalnézetben

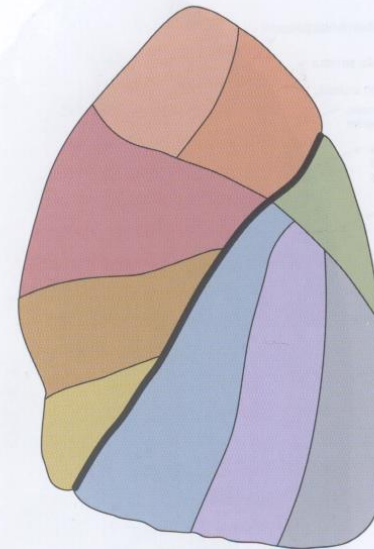
pulmo sinister

pulmo sinister, lobus superior

- segmentum apicoposterius [S I + II]
- segmentum anterius [S III]
- segmentum lingulare superius [S IV]
- segmentum lingulare inferius [S V]

pulmo sinister, lobus inferior

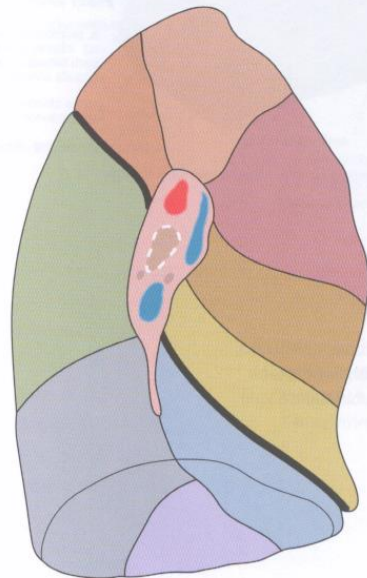
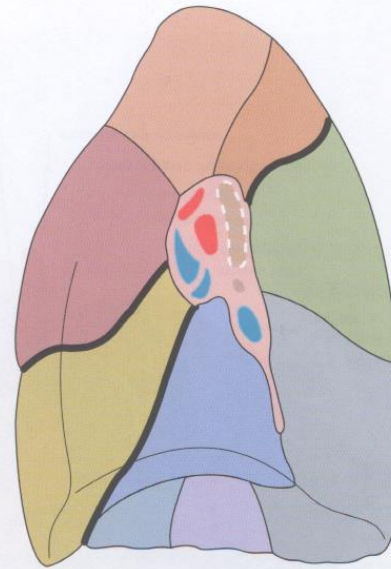
- segmentum superius [S VI]
- segmentum basale mediale [cardiacum] [S VII] *
- segmentum basale anterius [S VIII]
- segmentum basale laterale [S IX]
- segmentum basale posterius [S X]



881. ábra A bal tüdő, pulmo sinister, bronchopulmonalis segmentumai, segmenta bronchopulmonalia, oldalnézetben.

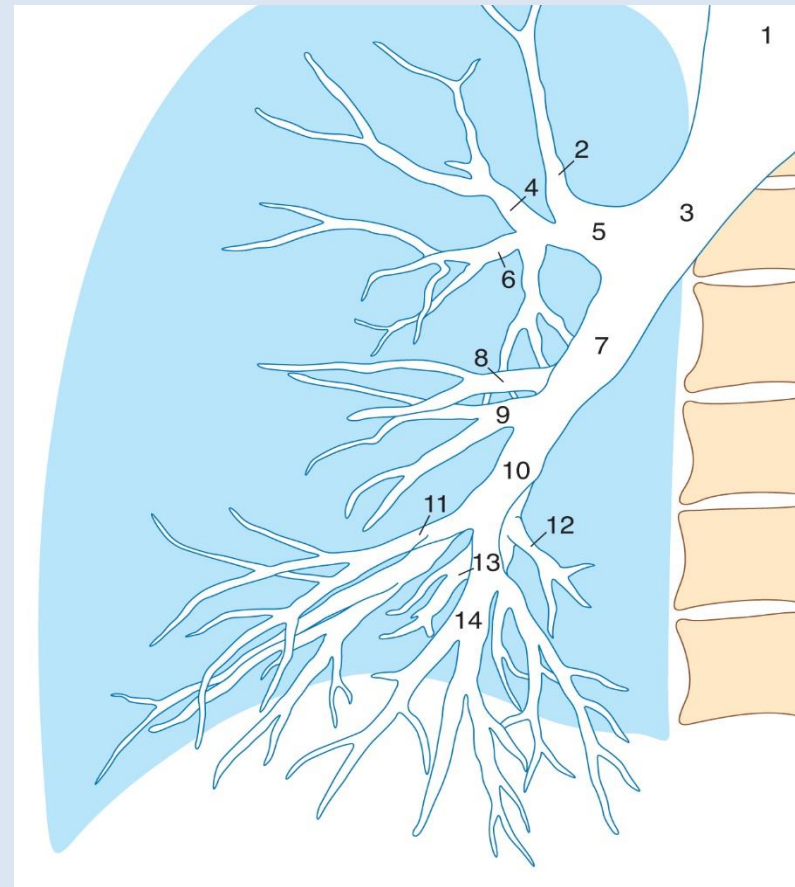
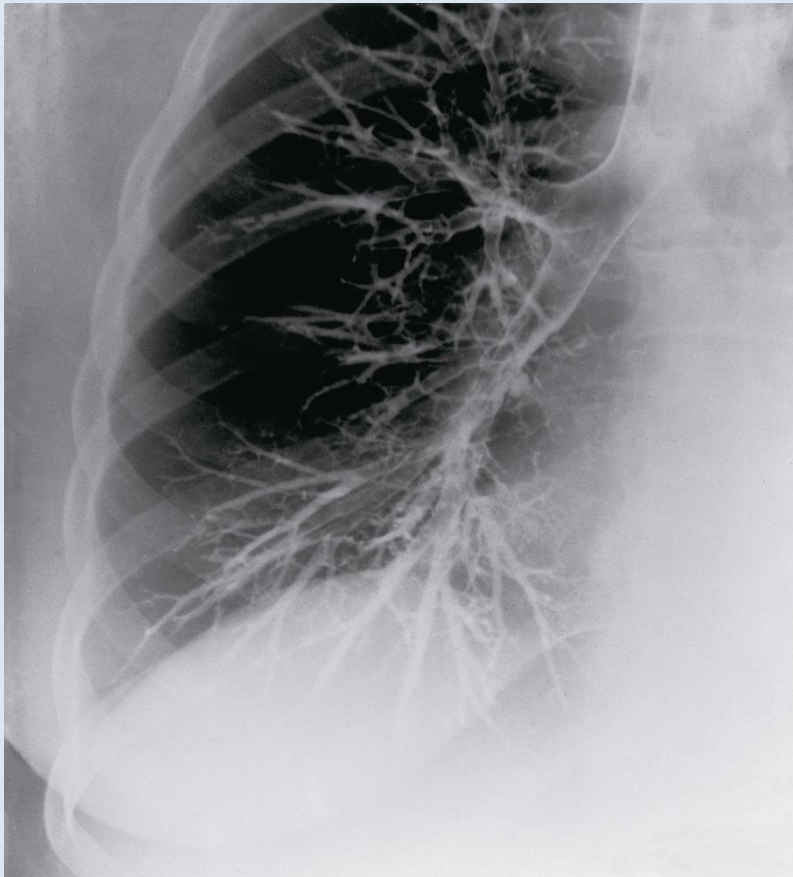* Ez a segmentum többnyire nem önálló, hanem a segmentum basaleval [S VIII] van összeolvadva

882. ábra A jobb tüdő, pulmo dexter, bronchopulmonalis segmentumai, segmenta bronchopulmonalia, medialis nézet (a segmentumok színét és nevét lásd az előző ábrákon)



883. ábra A bal tüdő, pulmo sinister, bronchopulmonalis segmentumai, segmenta bronchopulmonalia, medialis nézet (a segmentumok színét és nevét lásd az előző ábrákon)

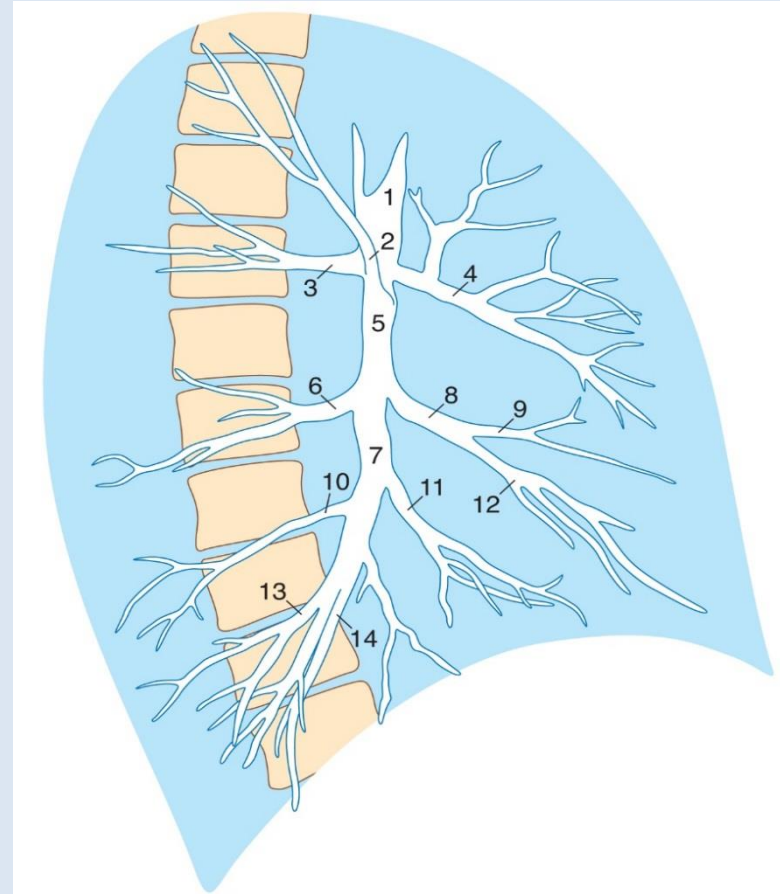
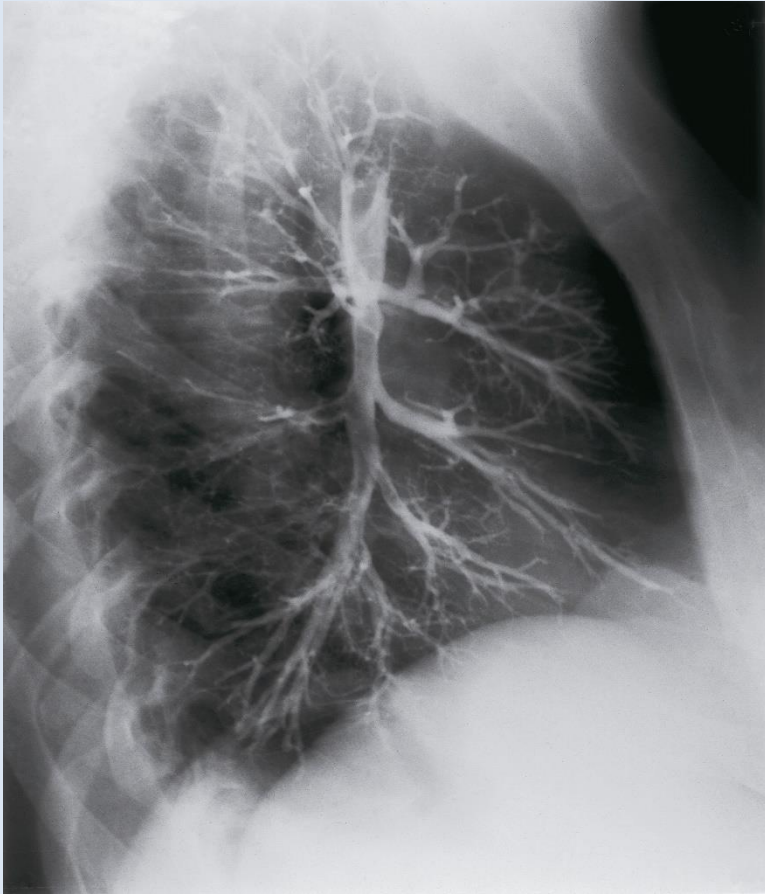
Anteriopost aspect



1. Trachea
2. Bronchus segmentalis apicalis lobi superioris
3. Bronchus principalis dexter
4. Bronchus segmentalis posterior lobi superioris
5. Bronchus lobaris superior
6. Bronchus segmentalis anterior lobi superioris
7. Bronchus intermedius

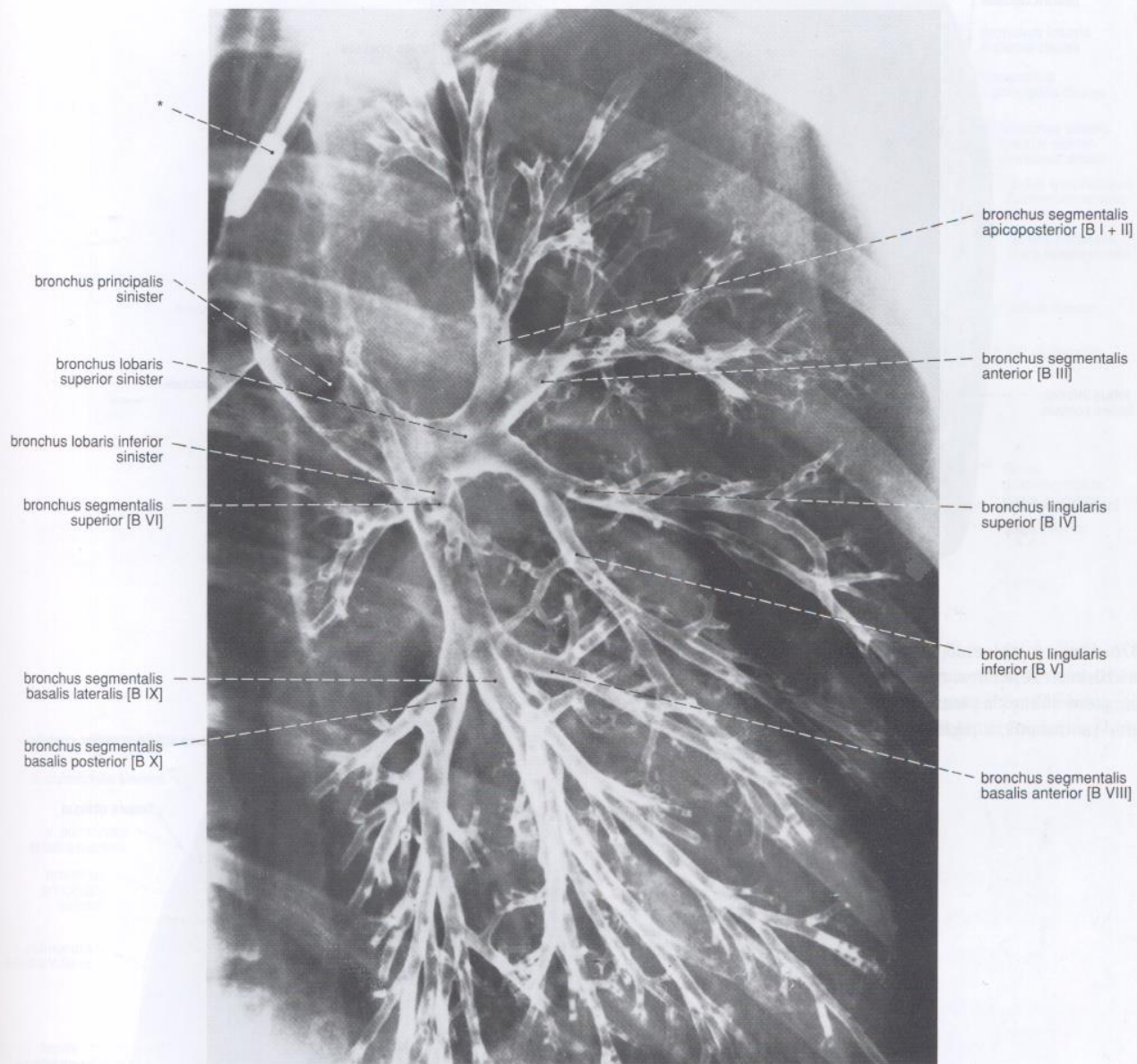
8. Bronchus segmentalis medialis lobi medii
9. Bronchus segmentalis lateralis lobi medii
10. Bronchus lobaris inferior
11. Bronchus segmentalis basalis lateralis lobi inferioris
12. Bronchus segmentalis basalis medialis lobi inferioris
13. Bronchus segmentalis basalis posterior lobi inferioris
14. Bronchus segmentalis basalis anterior lobi inferioris

A jobb tüdő bronchográfiás felvételen, lateralis nézet



1. Bronchus principalis dexter
2. Bronchus segmentalis apicalis lobi superioris
3. Bronchus segmentalis posterior lobi superioris
4. Bronchus segmentalis anterior lobi superioris
5. Bronchus intermedius
6. Bronchus segmentalis apicalis lobi inferioris
7. Bronchus lobaris inferior
8. Bronchus lobaris medius

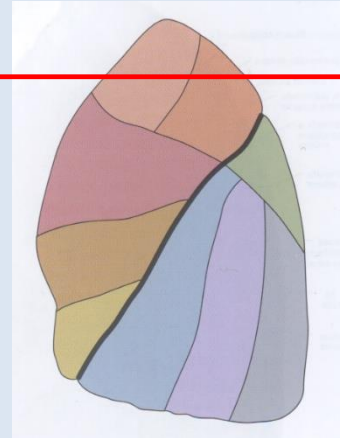
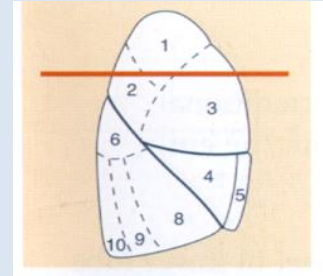
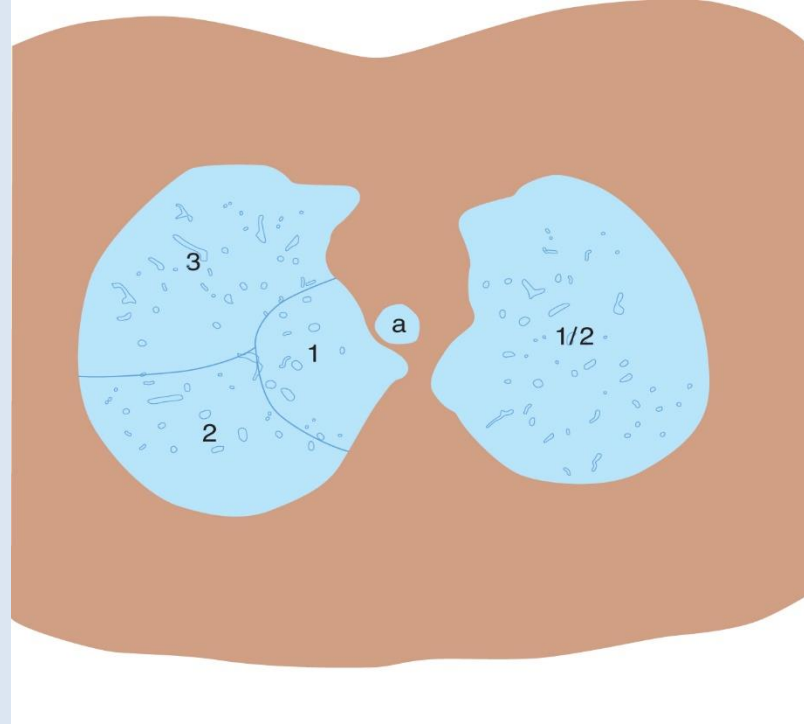
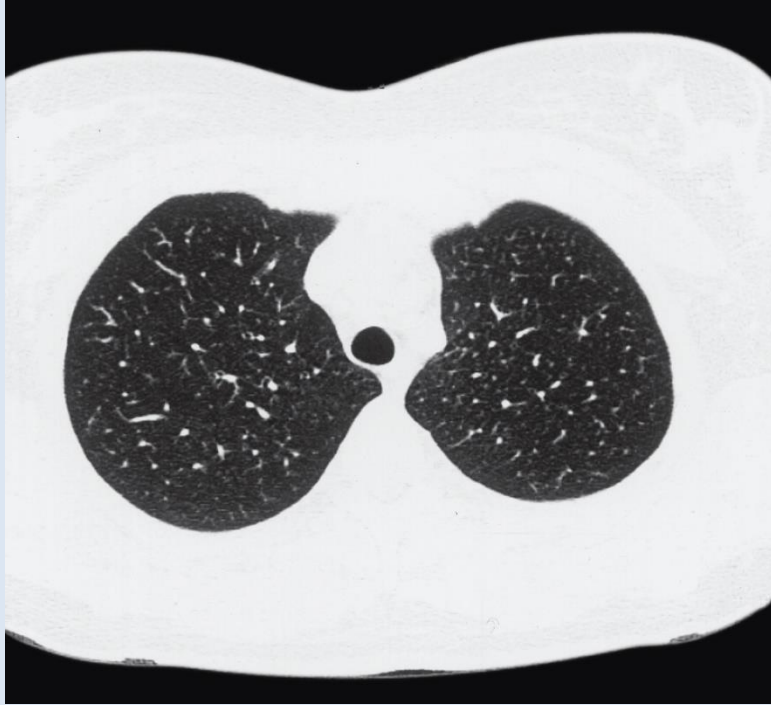
9. Bronchus segmentalis lateralis lobi medii
10. Bronchus segmentalis basalis posterior lobi inferioris
11. Bronchus segmentalis basalis anterior lobi inferioris
12. Bronchus segmentalis medialis lobi medii
13. Bronchus segmentalis basalis lateralis lobi inferioris
14. Bronchus segmentalis basalis medialis lobi inferioris



875. ábra A bal tüdő hörgői, bronchi, bronchographiás ap-röntgenképe (kontrasztanyag-tartalmú por befújása után).

* Bronchographiás katéter a tracheában

Bronchopulmonalis segmentumok, axialis CT felvétel / 1.

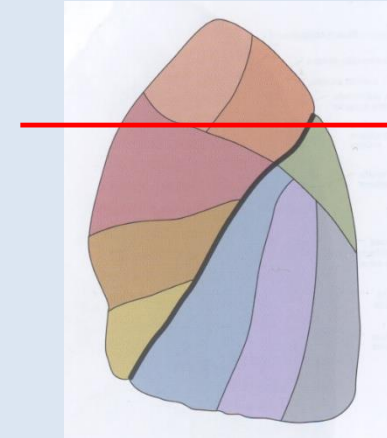
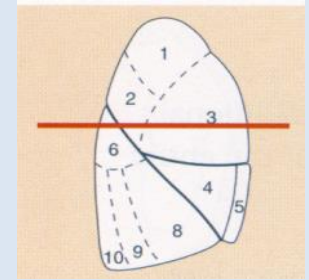
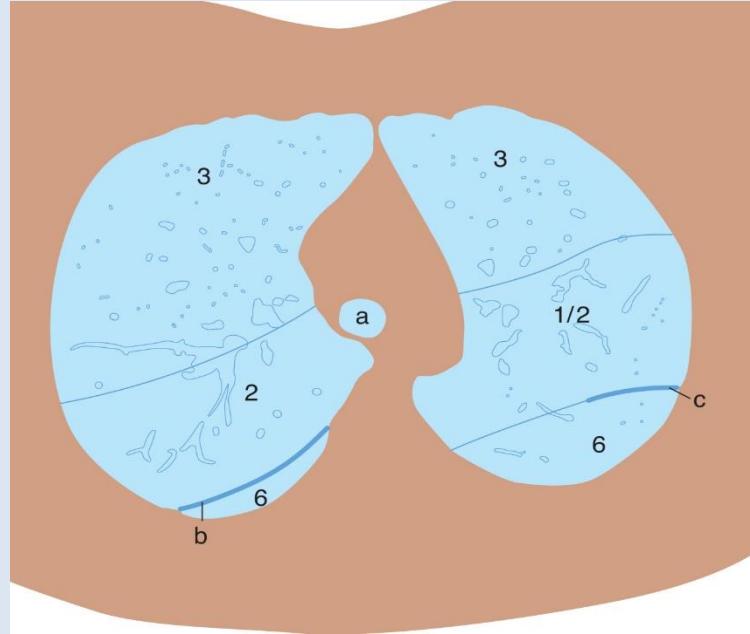
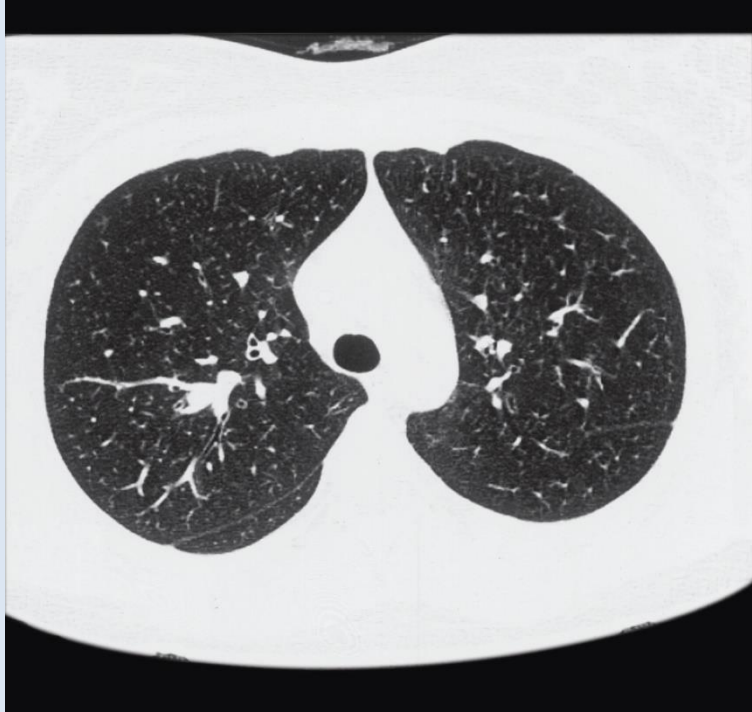

1. Segmentum apicale lobi sup.
2. Segmentum posterius lobi sup.
3. Segmentum anterius lobi sup.
4. Segmentum laterale lobi med. (jobb), lingulare sup. (bal)
5. Segmentum mediale lobi med. (jobb), lingulare inf. (bal)

6. Segmentum apicale lobi inf.
7. Segmentum basale mediale lobi inf. (csak jobb oldalon!)
8. Segmentum basale anterius lobi inf.
9. Segmentum basale laterale lobi inf.
10. Segmentum basale posterius lobi inf.

a = trachea

Bronchopulmonalis segmentumok, axialis CT felvétel / 2.



1. Segmentum apicale lobi sup.
2. Segmentum posterius lobi sup.
3. Segmentum anterius lobi sup.
4. Segmentum laterale lobi med. (jobb), lingulare sup. (bal)
5. Segmentum mediale lobi med. (jobb), lingulare inf. (bal)
6. Segmentum apicale lobi inf.

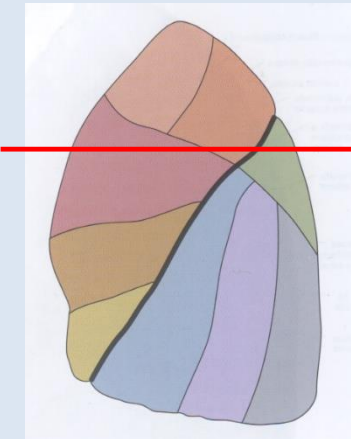
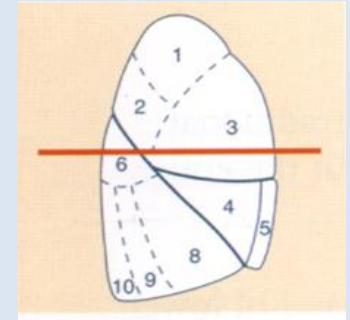
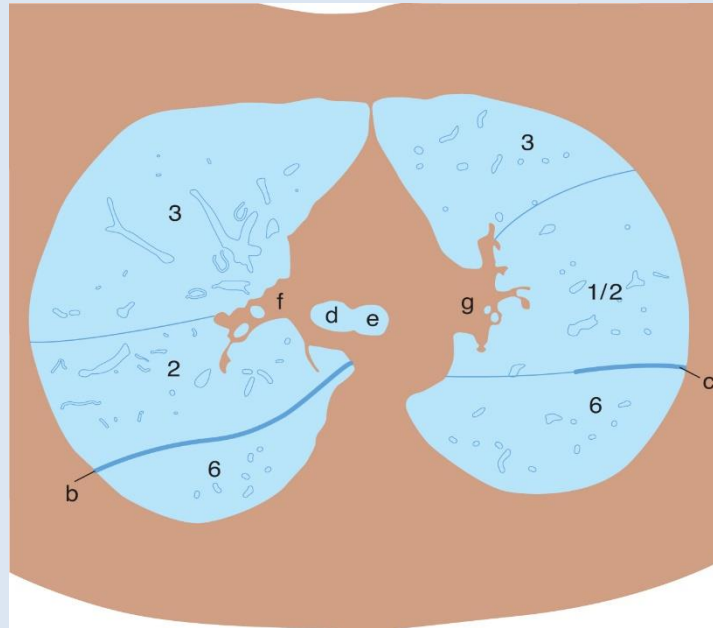
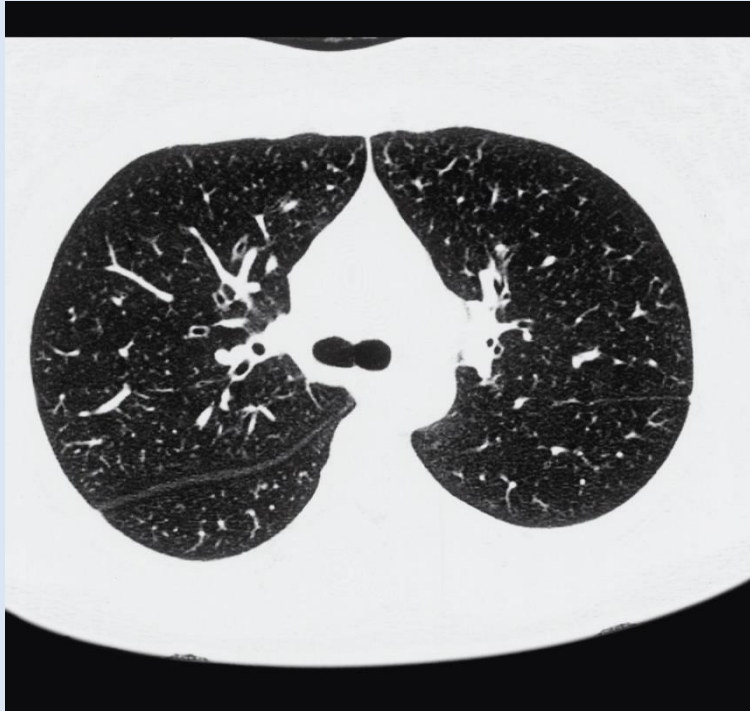7. Segmentum basale mediale lobi inf., (csak jobb oldalon!)
8. Segmentum basale anterius lobi inf.
9. Segmentum basale laterale lobi inf.
10. Segmentum basale posterius lobi inf.

a = trachea

b = fissura obliqua pulm. dext.

c = fissura obliqua pulm. sin.

Bronchopulmonalis segmentumok, axialis CT felvétel / 3.



1. Segmentum apicale lobi sup.
2. Segmentum posterius lobi sup.
3. Segmentum anterius lobi sup.
4. Segmentum laterale lobi med. (jobb), lingulare sup. (bal)
5. Segmentum mediale lobi med. (jobb), lingulare inf. (bal)
6. Segmentum apicale lobi inf.
7. Segmentum basale mediale lobi inf. (csak jobb oldalon)

8. Segmentum basale anterius lobi inf.
9. Segmentum basale laterale lobi inf.
10. Segmentum basale posterius lobi inf.

b = fissura obliqua pulm. dext.

c = fissura obliqua pulm. sin.

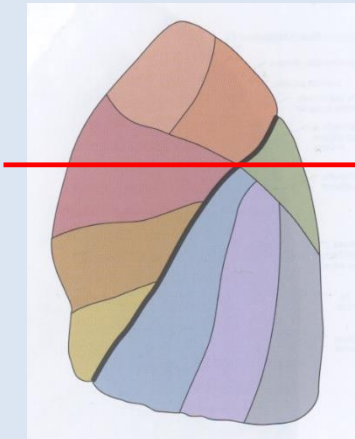
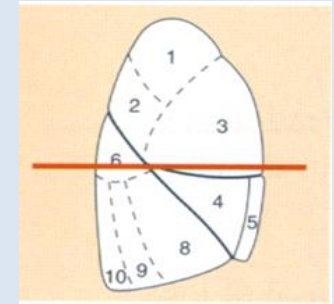
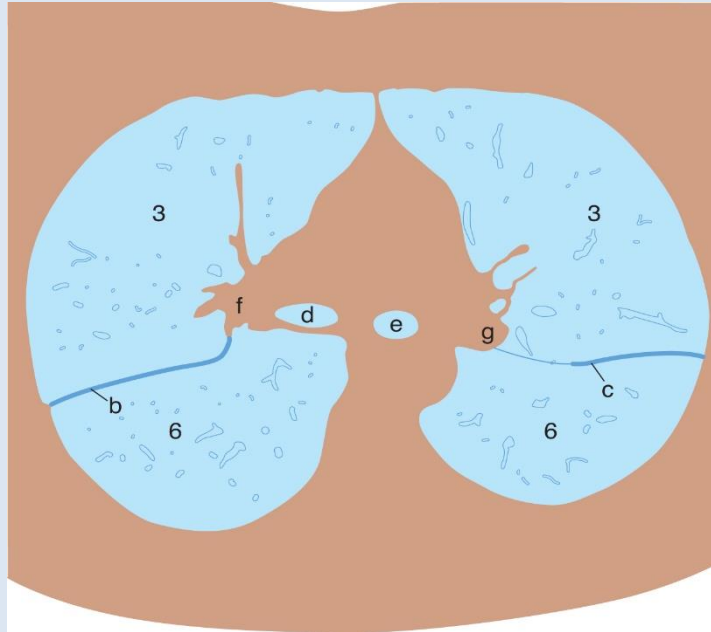
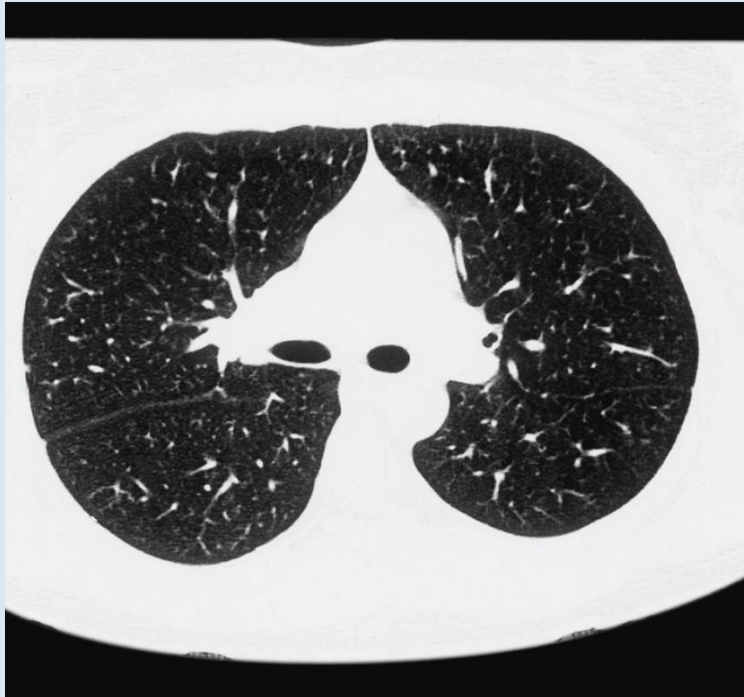d = bronchus principalis dext.

e = bronchus principalis sin.

f = hilus pulm. dext.

g = hilus pulm. sin.

Bronchopulmonalis segmentumok, axialis CT felvétel / 4.



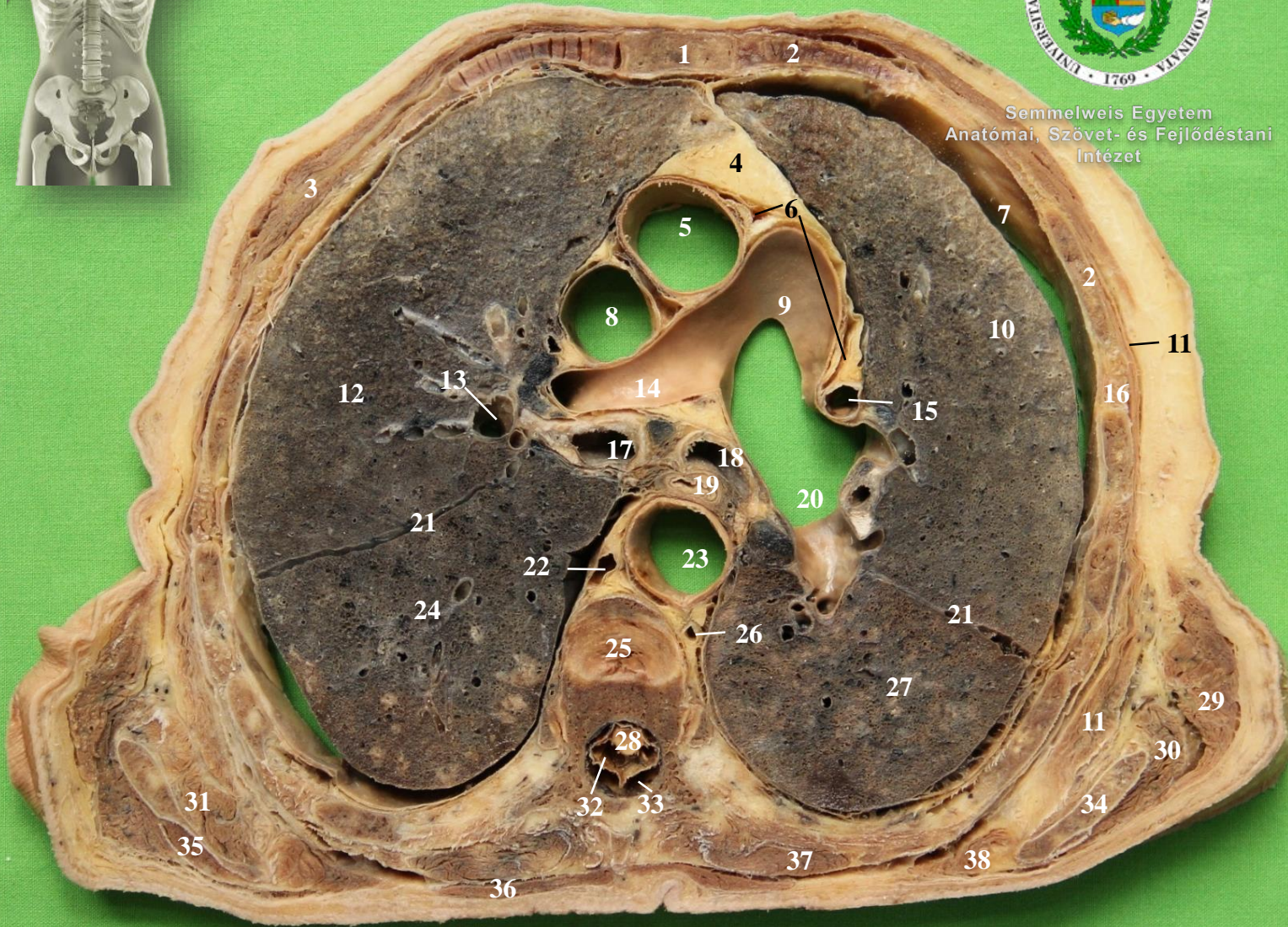
1. Segmentum apicale lobi sup.
2. Segmentum posterius lobi sup.
3. Segmentum anterius lobi sup.
4. Segmentum laterale lobi med. (jobb), lingulare sup. (bal)
5. Segmentum mediale lobi med. (jobb), lingulare inf. (bal)
6. Segmentum apicale lobi inf.
7. Segmentum basale mediale lobi inf. (csak jobb oldalon)

8. Segmentum basale anterius lobi inf.
 9. Segmentum basale laterale lobi inf.
 10. Segmentum basale posterius lobi inf.
- b = fissura obliqua pulm. dext.**
c = fissura obliqua pulm. sin.
d = bronchus principalis dext.
e = bronchus principalis sin.
f = hilus pulm. dext.
g = hilus pulm. sin.

Th5/6

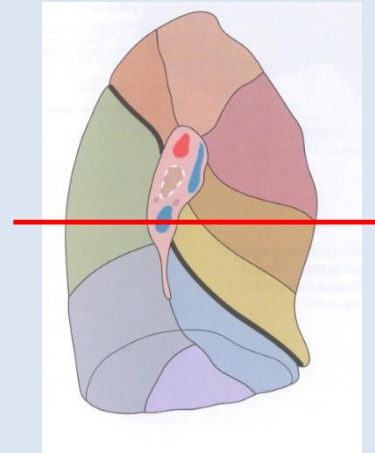
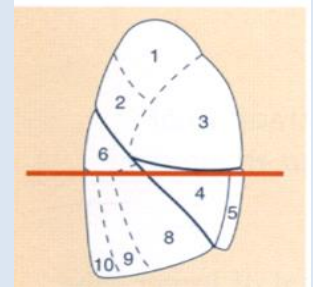
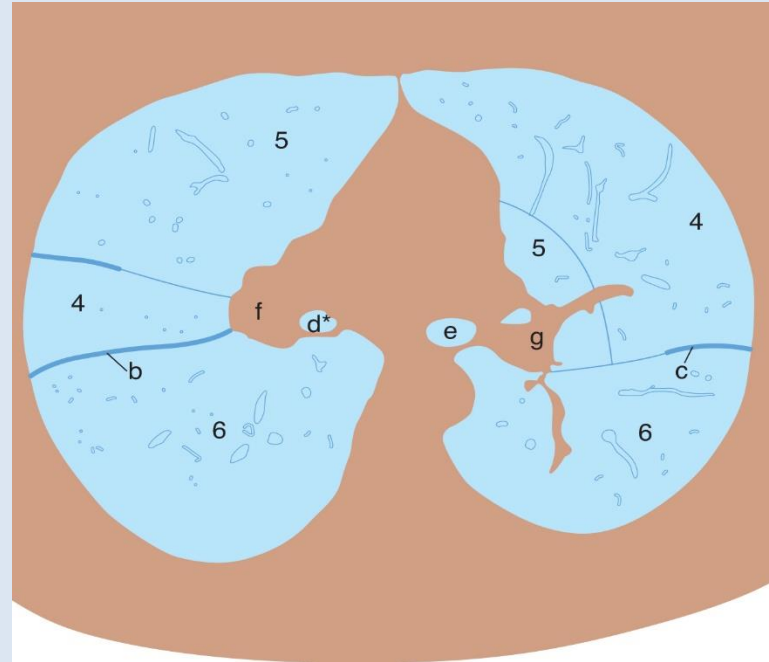
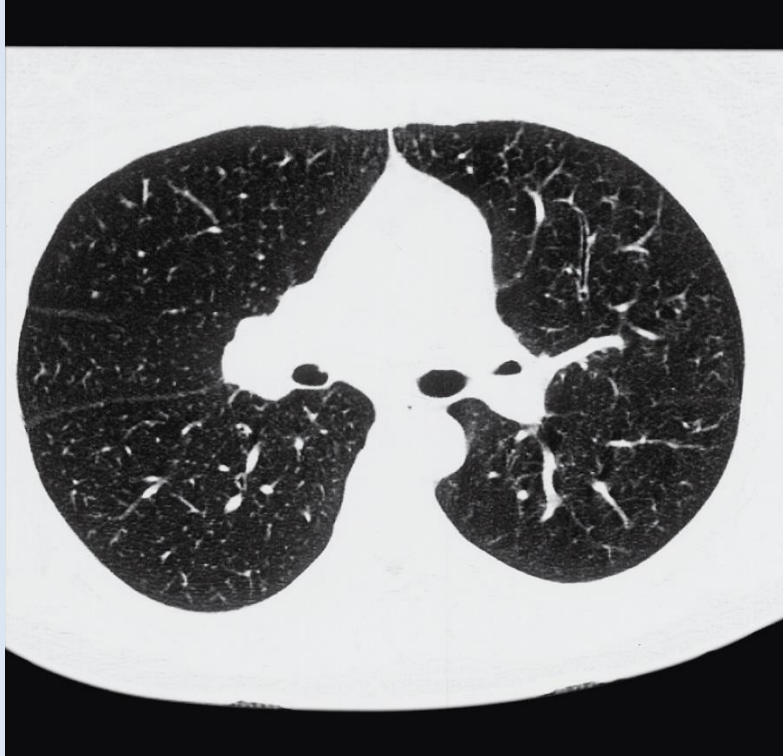


Semmelweis Egyetem
Anatómiai, Szövet- és Fejlődéstani
Intézet



1. sternum
2. costa
3. m.pectoralis major/minor
4. thymus adiposum
5. aorta ascendens
6. cavum pericardii
7. cavum pleurae
8. v. cava superior
9. truncus pulmonalis
10. pulmo dexter, lobus superior
11. m. serratus anterior
12. pulmo sinister, lobus superior
13. v. pulmonalis dextra
14. a. pulmonalis dextra
15. v. pulmonalis sinistra
16. mm. intercostales
17. bronchus principalis dexter
18. bronchus principalis sinister
19. oesophagus
20. a. pulmonalis sinistra
21. fissura obliqua
22. v. azygos
23. aorta descendens
24. pulmo dexter, lobus inferior
25. discus intervertebralis
26. v. hemiazygos accessoria
27. pulmo sinister, lobus inferior
28. spina medullaris
29. m. latissimus dorsi
30. m. teres major
31. m. subscapularis
32. spatium subarachnoideum
33. spatium epidurale
34. scapula
35. m. infraspinatus
36. m. trapezius
37. m. erector spinae
38. m. rhomboideus major

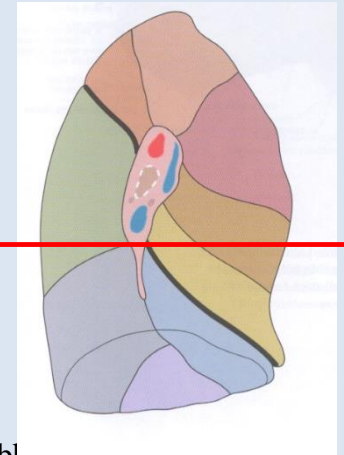
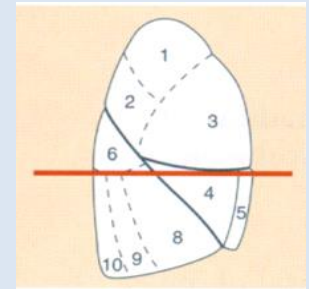
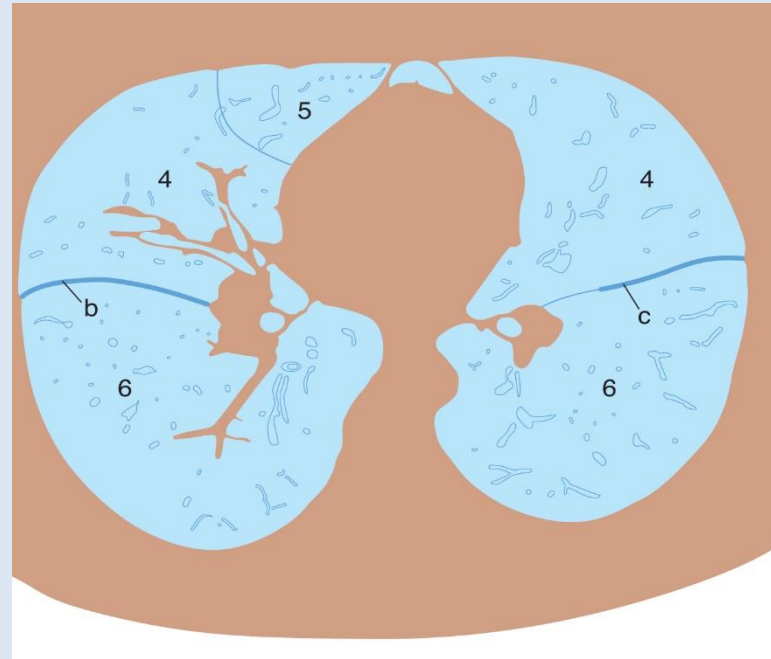
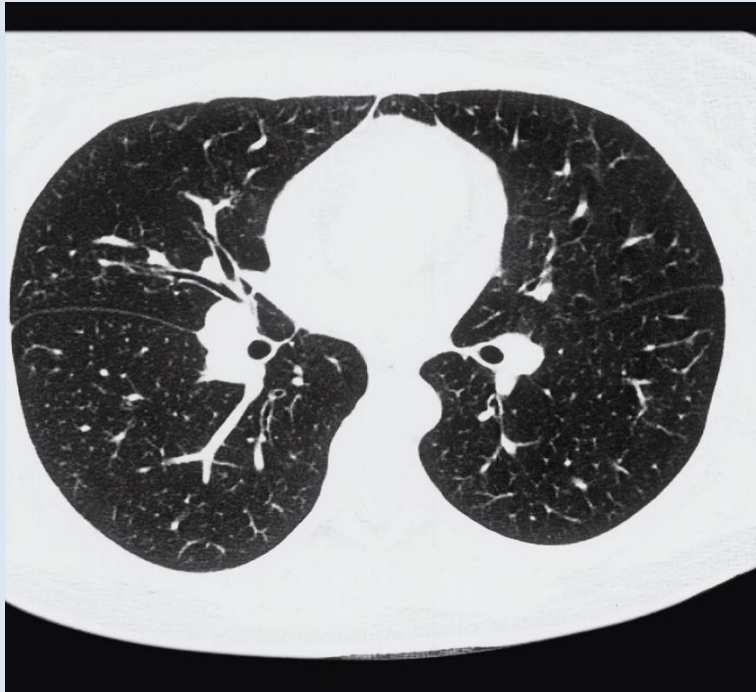Bronchopulmonalis segmentumok, axialis CT felvétel / 5.



1. Segmentum apicale lobi sup.
2. Segmentum posterius lobi sup.
3. Segmentum anterius lobi sup.
4. Segmentum laterale lobi med. (jobb), lingulare sup. (bal)
5. Segmentum mediale lobi med. (jobb), lingulare inf. (bal)
6. Segmentum apicale lobi inf.
7. Segmentum basale mediale lobi inf. (csak jobb oldalon)

8. Segmentum basale anterius lobi inf.
 9. Segmentum basale laterale lobi inf.
 10. Segmentum basale posterius lobi inf.
- b = fissura obliqua pulm. dext.**
c = fissura obliqua pulm. sin.
d = bronchus principalis dext.
e = bronchus principalis sin.
f = hilus pulm. dext.
g = hilus pulm. sin.

Bronchopulmonalis segmentumok, axialis CT felvétel / 6.



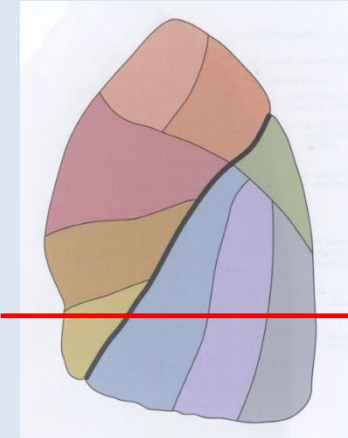
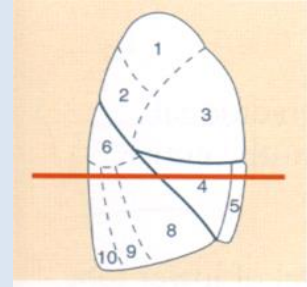
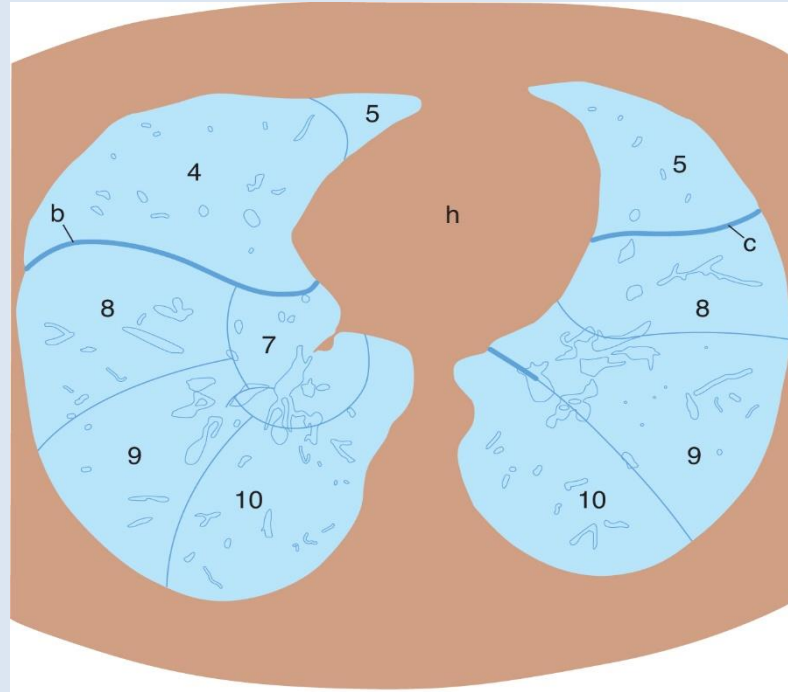
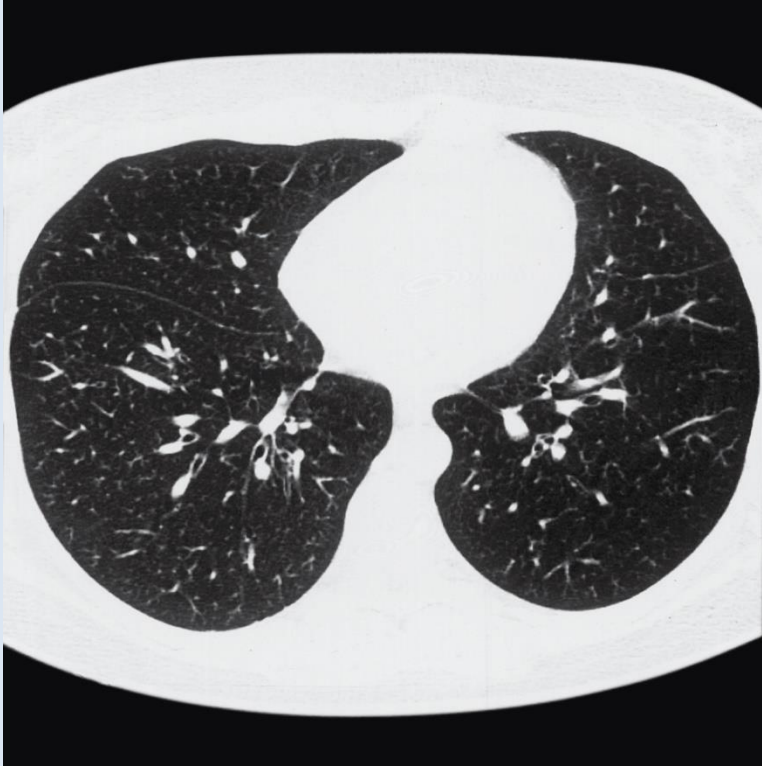1. Segmentum apicale lobi sup.
2. Segmentum posterius lobi sup.
3. Segmentum anterius lobi sup.
4. Segmentum laterale lobi med. (jobb), lingulare sup. (bal)
5. Segmentum mediale lobi med. (jobb), lingulare inf. (bal)
6. Segmentum apicale lobi inf.

7. Segmentum basale mediale lobi inf. (csak jobb oldalán)
8. Segmentum basale anterius lobi inf.
9. Segmentum basale laterale lobi inf.
10. Segmentum basale posterius lobi inf.

b = fissura obliqua pulm. dext.

c = fissura obliqua pulm. sin.

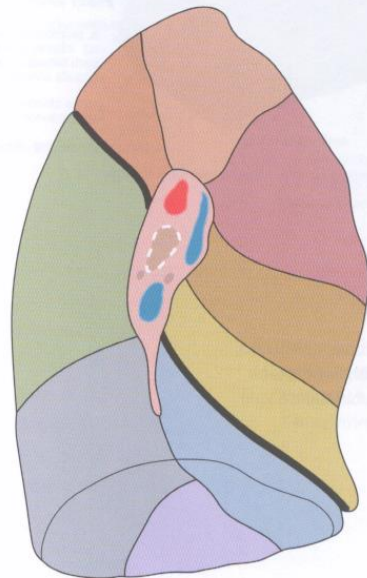
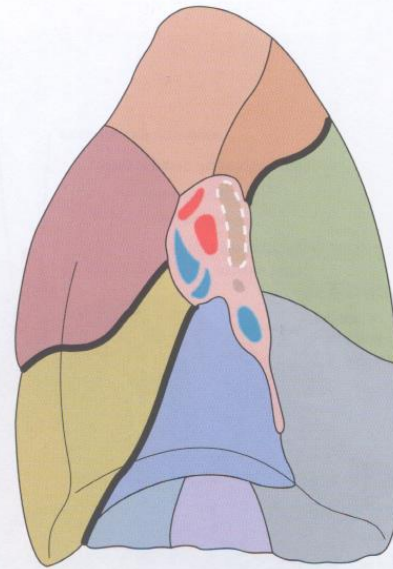
Bronchopulmonalis segmentumok, axialis CT felvétel / 7.



1. Segmentum apicale lobi sup.
2. Segmentum posterius lobi sup.
3. Segmentum anterius lobi sup.
4. Segmentum laterale lobi med. (jobb), lingulare sup. (bal)
5. Segmentum mediale lobi med. (jobb), lingulare inf. (bal)
6. Segmentum apicale lobi inf.

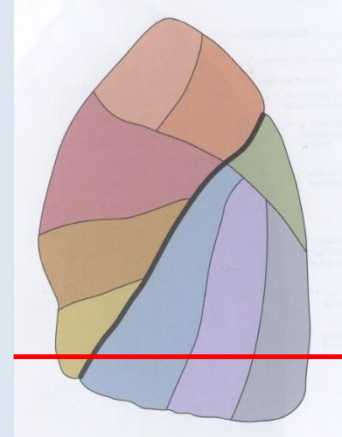
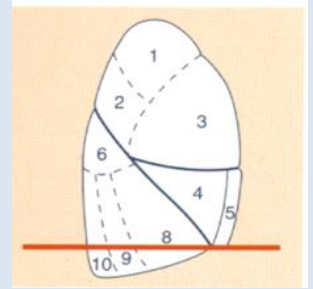
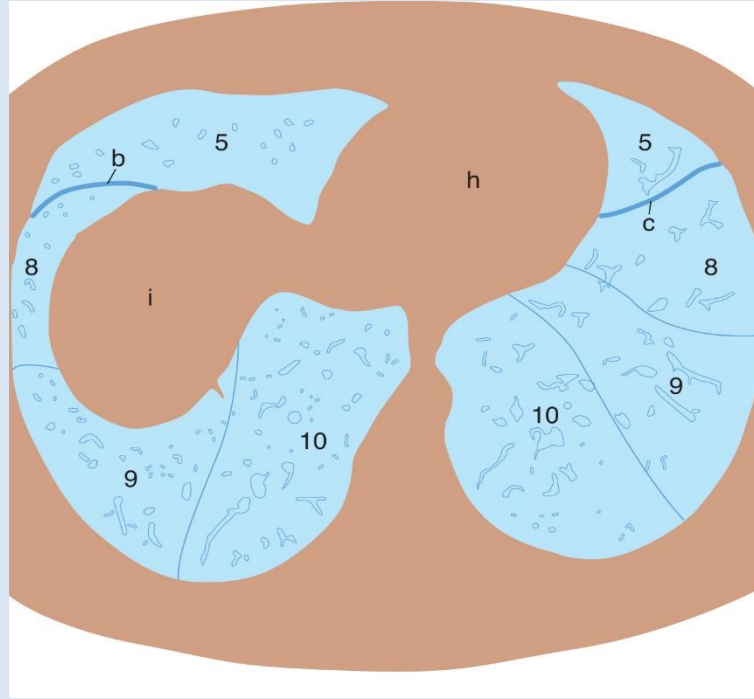
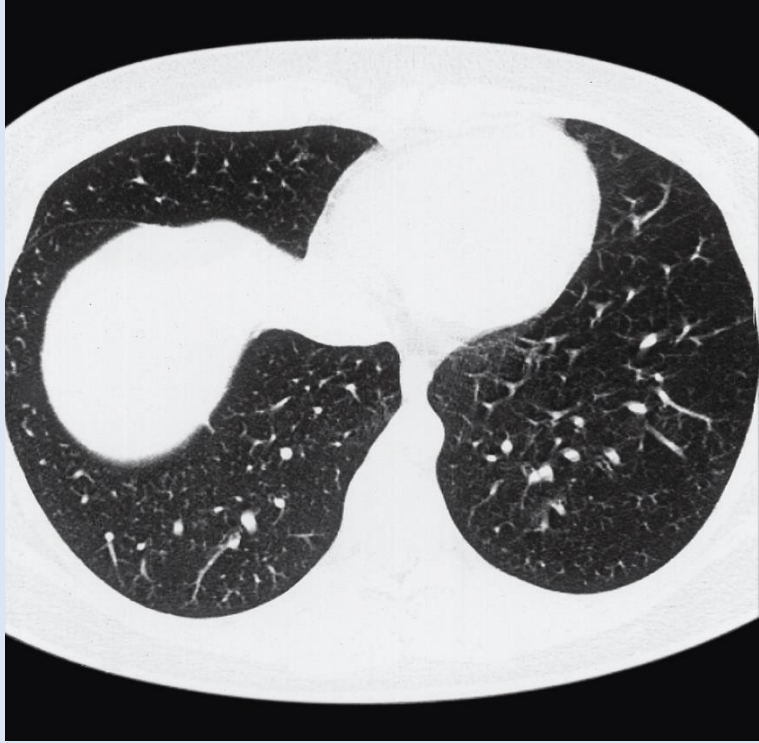7. Segmentum basale mediale lobi inf., (csak jobb oldalon!)
 8. Segmentum basale anterius lobi inf.
 9. Segmentum basale laterale lobi inf.
 10. Segmentum basale posterius lobi inf.
- b = fissura obliqua pulm. dext.**
c = fissura obliqua pulm. sin.
h = cor

882. ábra A jobb tüdő, pulmo dexter, bronchopulmonalis segmentumai, segmenta bronchopulmonalia, medialis nézet (a segmentumok színét és nevét lásd az előző ábrákon)



883. ábra A bal tüdő, pulmo sinister, bronchopulmonalis segmentumai, segmenta bronchopulmonalia, medialis nézet (a segmentumok színét és nevét lásd az előző ábrákon)

Bronchopulmonalis segmentumok, axialis CT felvétel / 8.



1. Segmentum apicale lobi sup.
2. Segmentum posterius lobi sup.
3. Segmentum anterius lobi sup.
4. Segmentum laterale lobi med. (jobb), lingulare sup. (bal)
5. Segmentum mediale lobi med. (jobb), lingulare inf. (bal)
6. Segmentum apicale lobi inf.

7. Segmentum basale mediale lobi inf, (csak jobb oldalon!)
8. Segmentum basale anterius lobi inf.
9. Segmentum basale laterale lobi inf.
10. Segmentum basale posterius lobi inf.

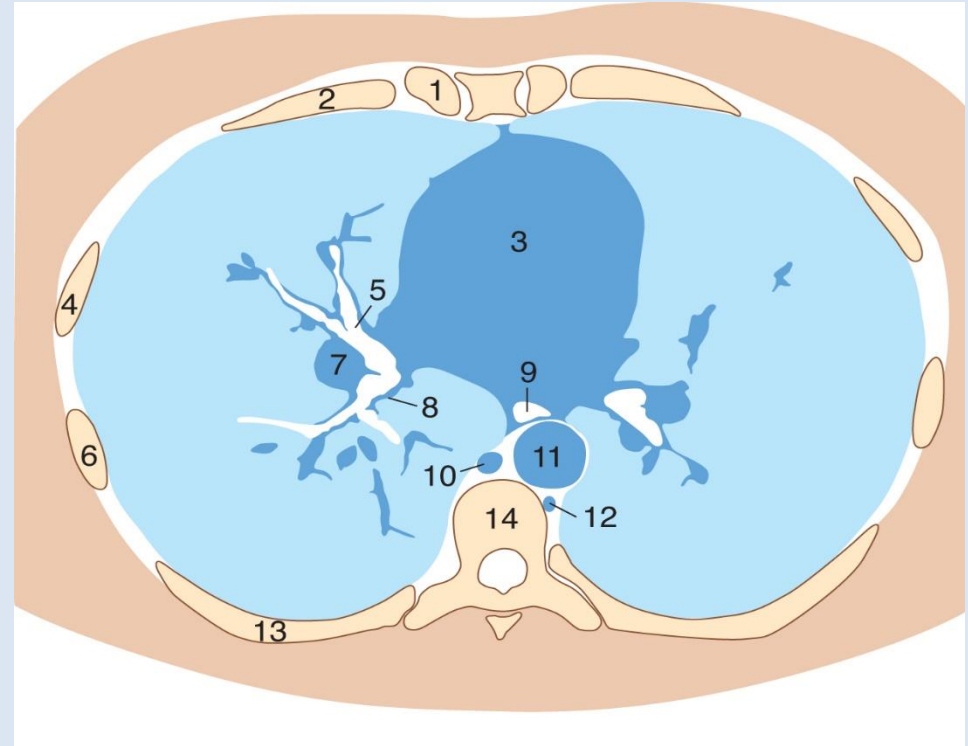
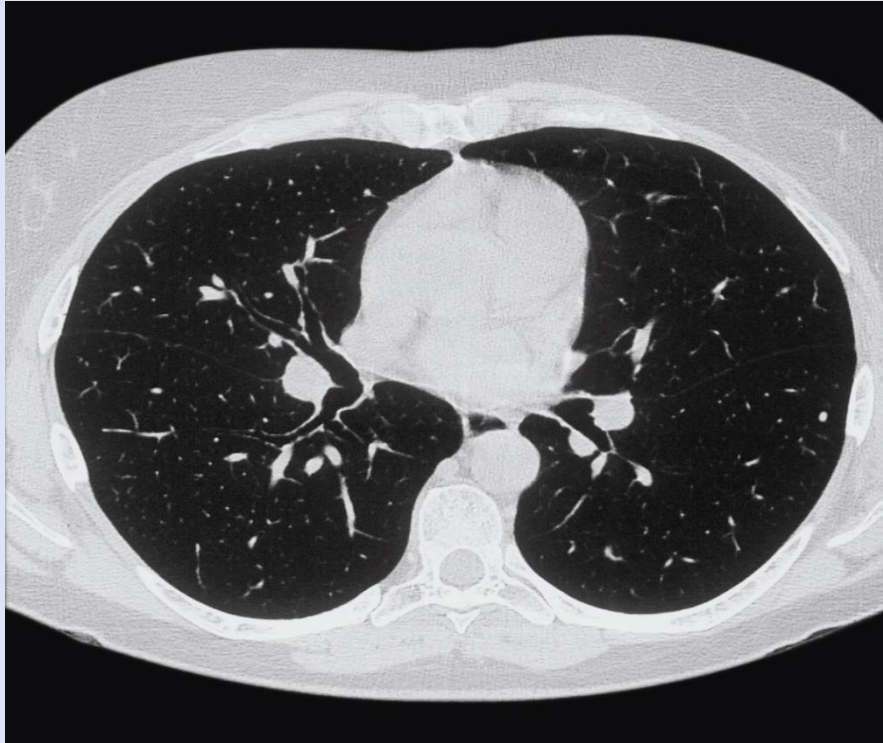
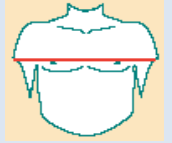b = fissura obliqua pulm. dext.

c = fissura obliqua pulm. sin.

h = cor

i = diaphragma

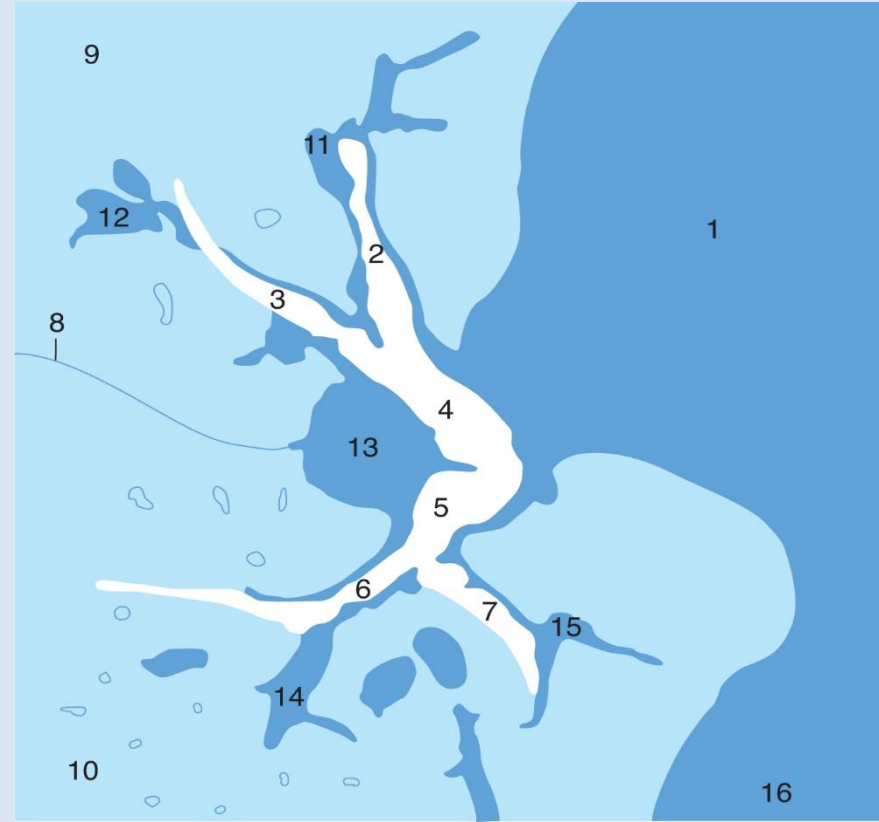
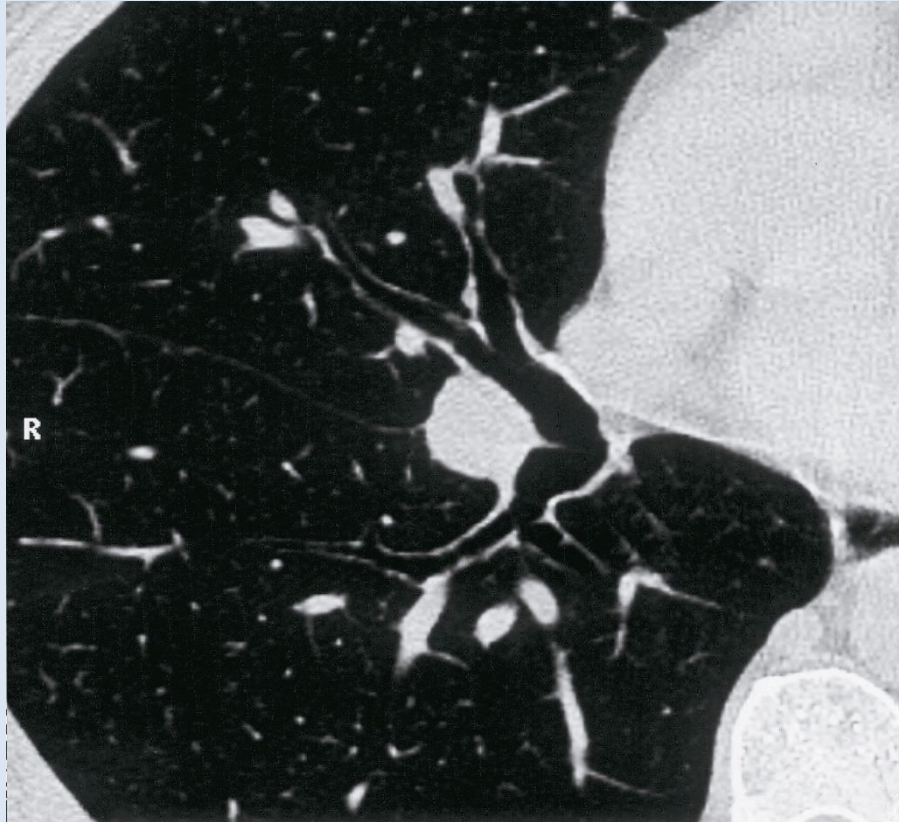
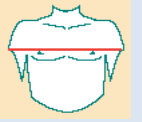
high-resolution CT



1. Cartilago costalis IV.
2. Costa V.
3. Szív és pericardium
4. Costa IV.
5. Bronchus et arteria lobares med.
6. Costa VII.
7. A. pulmonalis

8. Brochus et arteria lobares inf.
9. Oesophagus
10. Vena azygos
11. Aorta
12. Vena hemiazygos
13. Costa VIII.
14. Vertebra thoracica VIII.

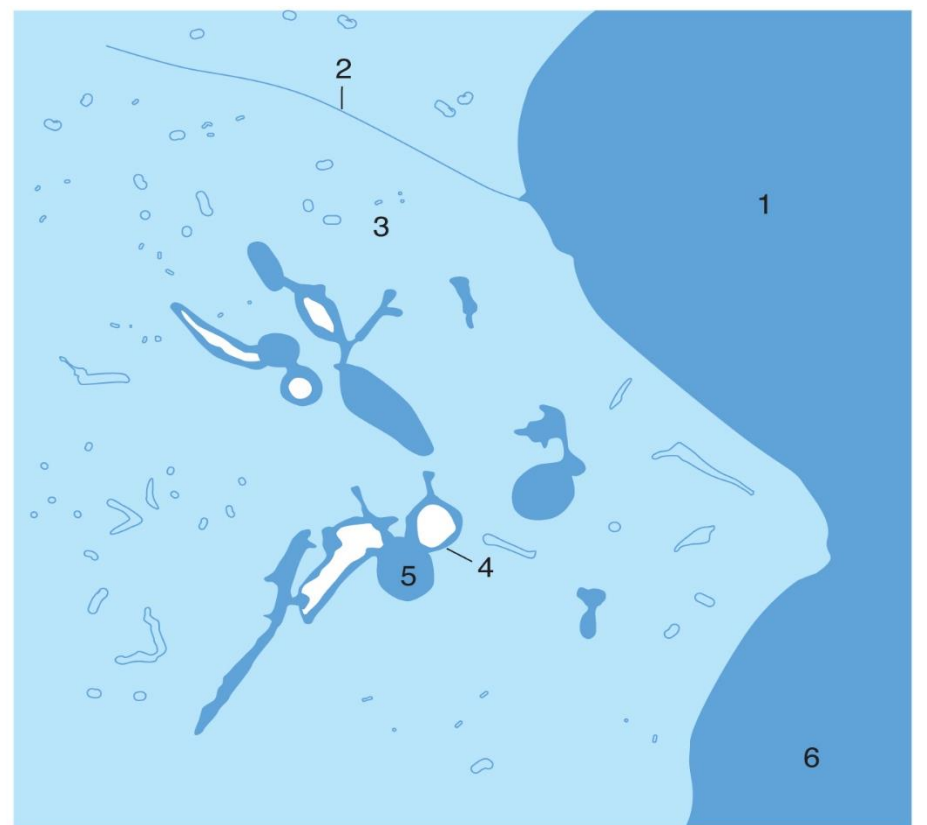
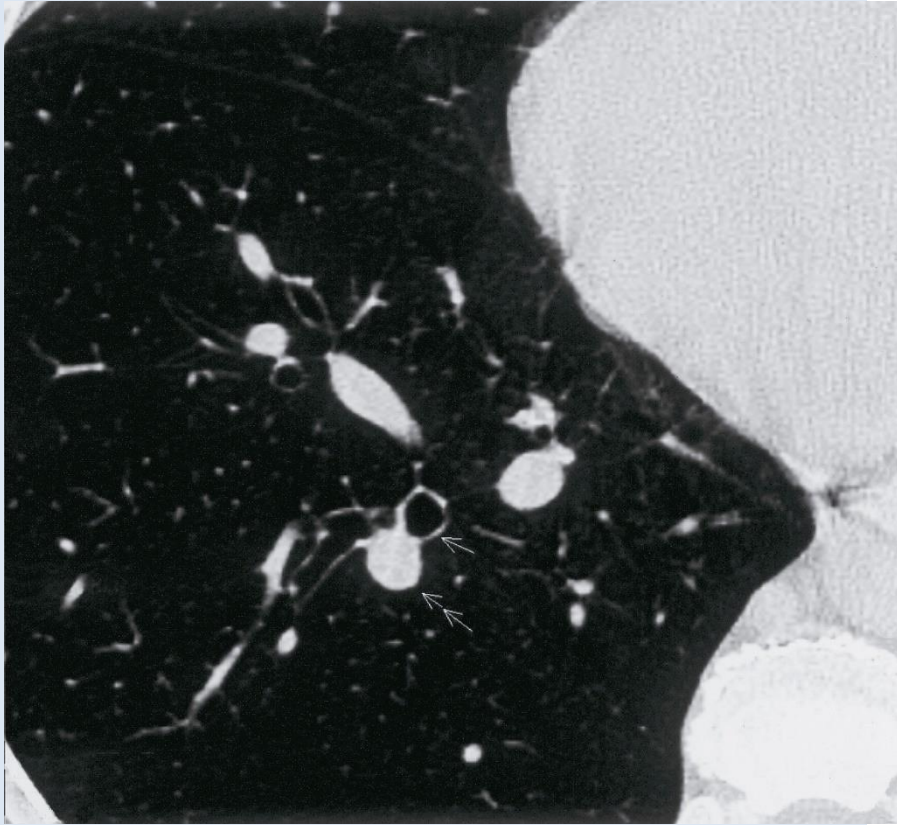
Hilus pulmonis dext. - high-resolution CT



1. Szív
2. Bronchus segmentalis medialis lobi medii
3. Bronchus segmentalis lateralis lobi medii
4. Bronchus lobaris medius
5. Bronchus lobaris inferior
6. Bronchus segmentalis anterobasalis lobi inferioris
7. Bronchus segmentalis mediobasalis lobi inferioris
8. Fissura obliqua

9. Lobus medius
10. Lobus inferior
11. A. segmentalis medialis lobi medii
12. A. segmentalis lateralis lobi medii
13. A. pulmonalis
14. A. segmentalis anterobasalis lobi inferioris
15. A. segmentalis mediobasalis lobi inferioris
16. Columna vertebralis

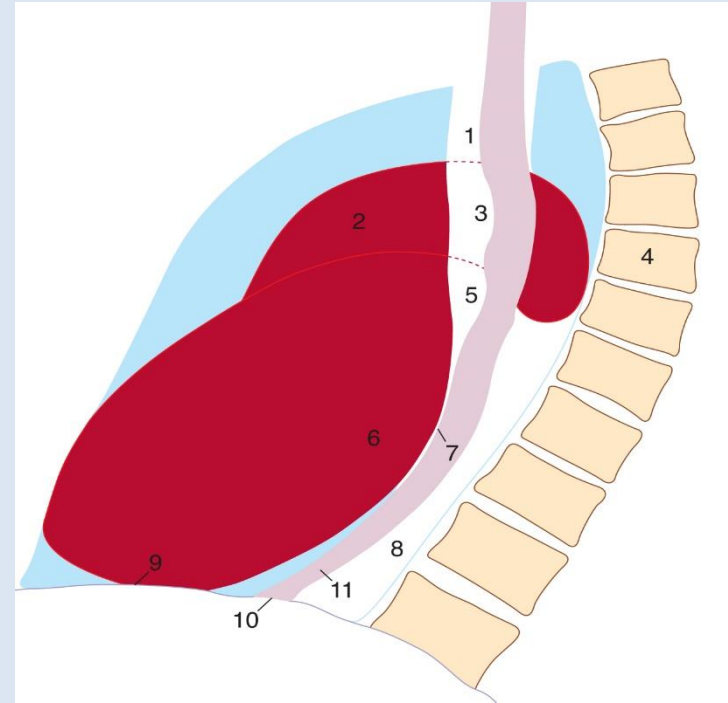
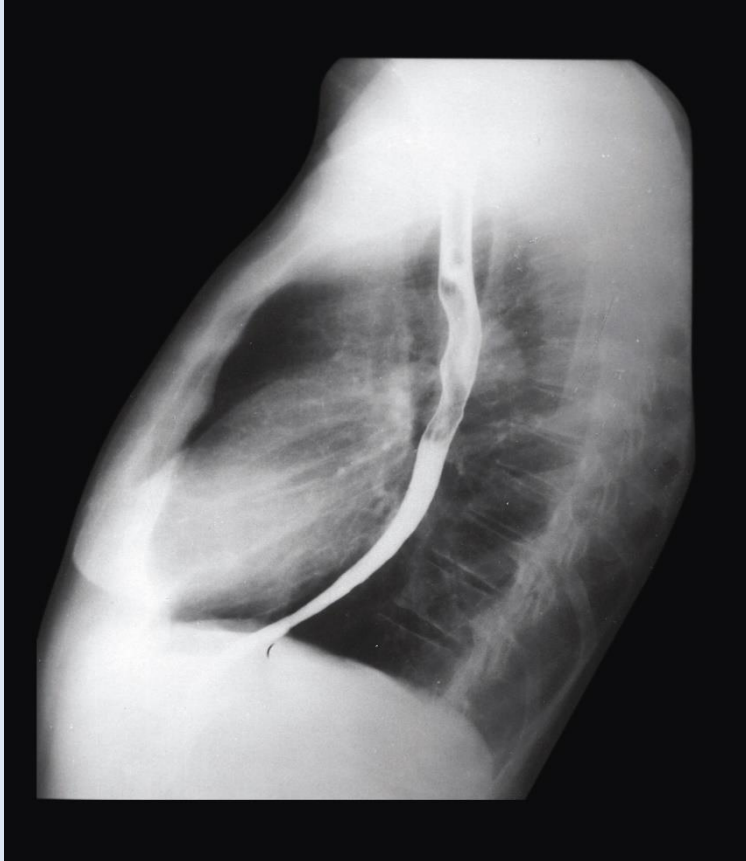
Tüdőparenchyma - high-resolution CT



1. Szív
2. Fissura obliqua
3. Tüdőparenchyma
4. Bronchus lobaris (keresztmetszet)
5. A. lobaris (keresztmetszet)
6. Columna vertebralis

Röntgenbild mit Kontrastmittel

Nyelőcső barium kontrasztanyag RTG képe – lateralis nézet

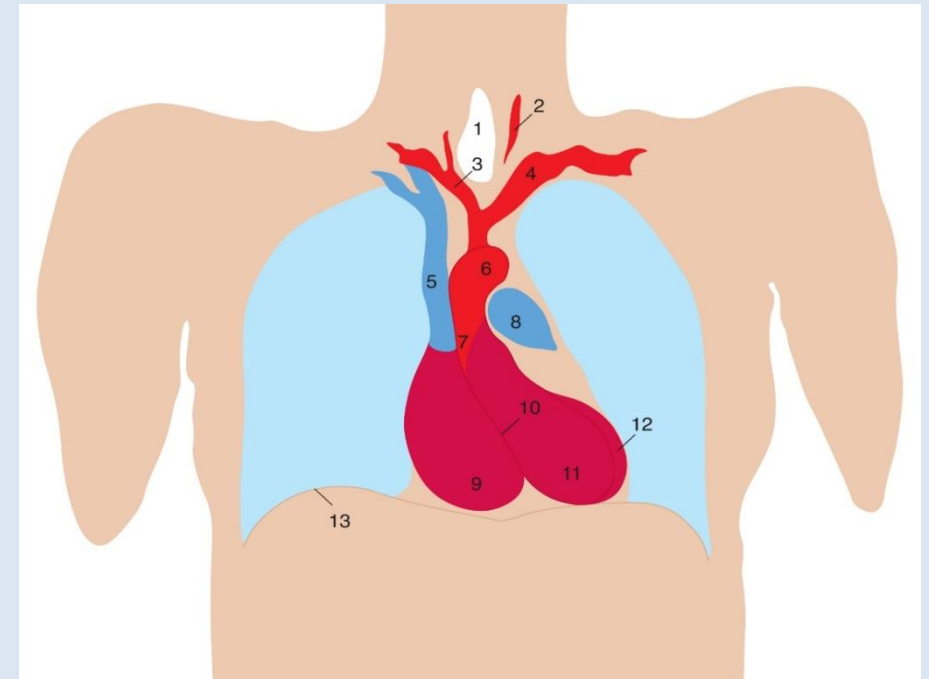
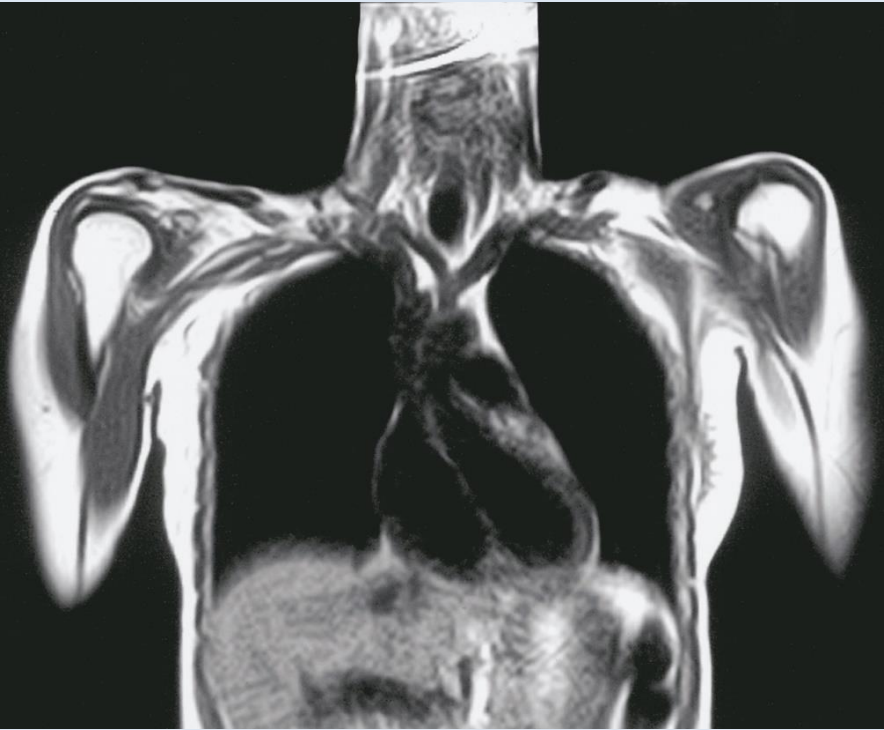

1. Trachea
2. Aorta ascendens
3. Impressio aortica
4. Columna vertebralis
5. Bal főhörgő benyomata
6. Bal pitvar

7. Impressio cardiaca
8. Spatium retrocardiacum
9. Diaphragma
10. Hiatus oesophageus (oesophago-gastricus átmenet)
11. Kontrasztanyag a nyelőcsőben

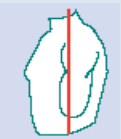
MRT

Coronalis MRI felvétel

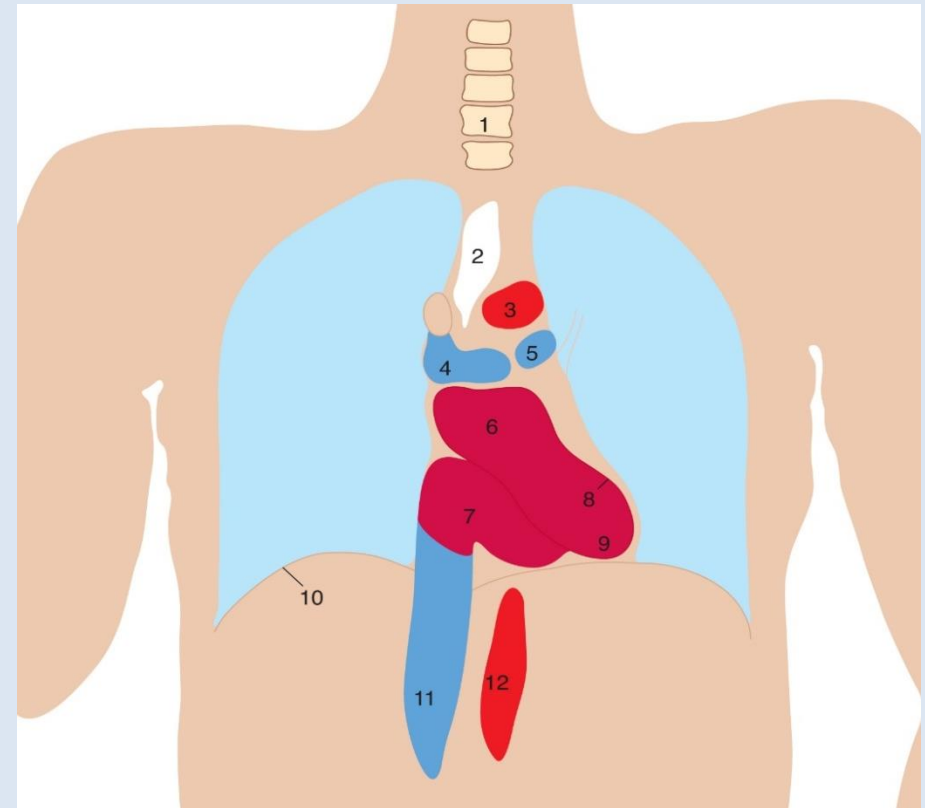
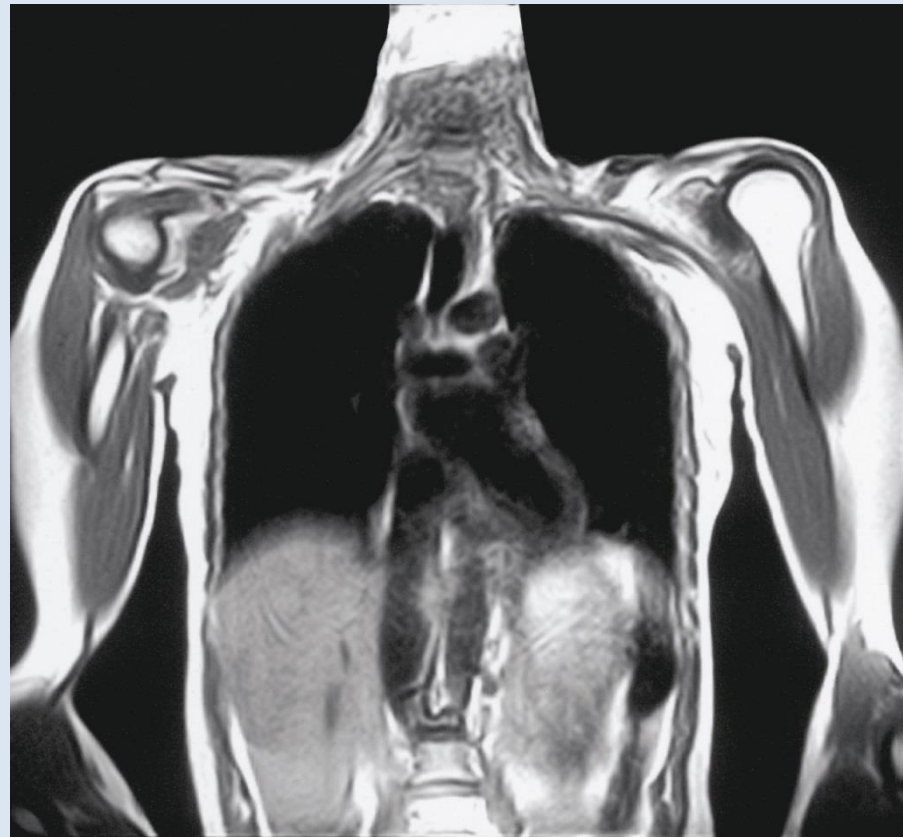

1. Trachea
2. A. carotis commun. sin.
3. Truncus brachiocephalicus
4. A. subclavia sin.
5. V. cava sup.
6. Aorta 'gomb'
7. Aorta ascendens

8. Truncus pulmonalis
9. Jobb kamra
10. Septum interventriculare, pars muscularis
11. Bal kamra ürege
12. Bal kamra fala
13. Diaphragma

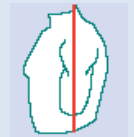


Coronalis MRI felvétel

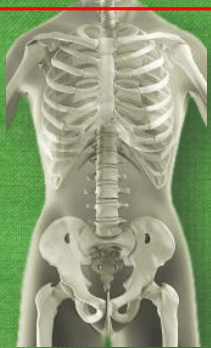

1. Vertebrae cervicales
2. Trachea
3. Aorta gomb
4. A. pulmonalis dext.
5. A. pulmonalis sin.
6. Bal pitvar

7. Jobb pitvar
8. Bal kamra fala
9. Bal kamra ürege
10. Diaphragma
11. V. cava inf.
12. Aorta desc.



Querschnittsanatomie des Thorax

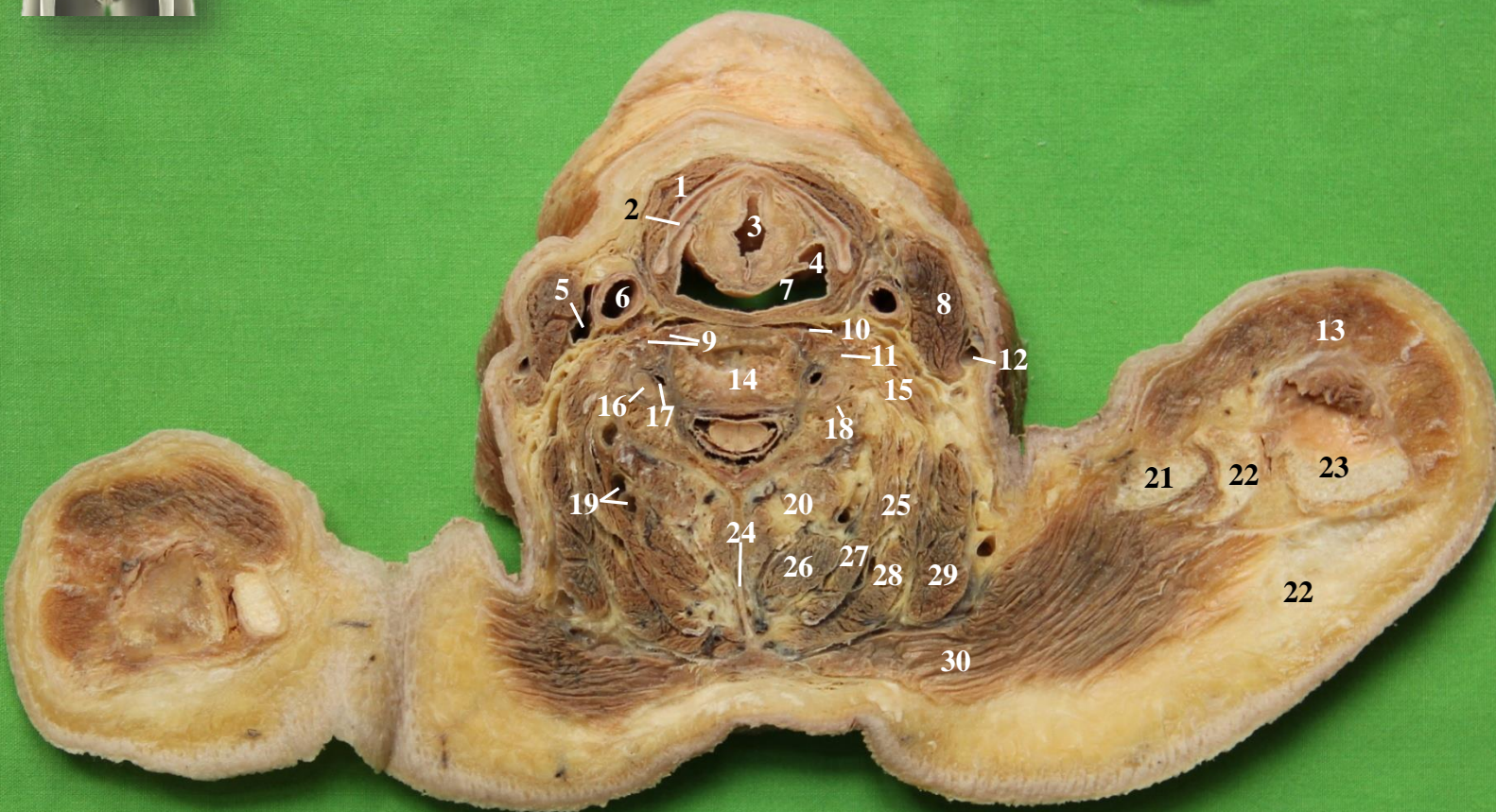


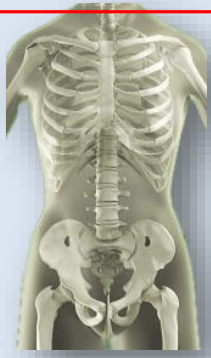C5



Semmelweis Egyetem
Anatómai, Szövet- és Fejlődéstani
Intézet

1. mm. infrahyoidei
2. cornu major ossis hyoidei
3. vestibulum laryngis
4. recessus piriformis
5. v. jugularis interna
6. a. carotis communis
7. laryngopharynx
8. m. sternocleidomastoideus
9. mm. prevertebrales (m. longus colli/capitis)
10. spatium retropharyngeum
11. m. scalenus anterior
12. v. jugularis externa
13. m. deltoideus
14. corpus vertebrae
15. m. scalenus medius
16. n. spinalis
17. a. vertebralis
18. art. intervertebralis (art. zygapophysealis)
19. vv. cervicales profundae
20. m. multifidus
21. clavicula
22. scapula
23. humerus
24. lig. nuchae
25. m. longissimus capitis
26. m. semispinalis cervicis
27. m. semispinalis capitis
28. m. splenius capitis
29. m. levator scapulae
30. m. trapezius



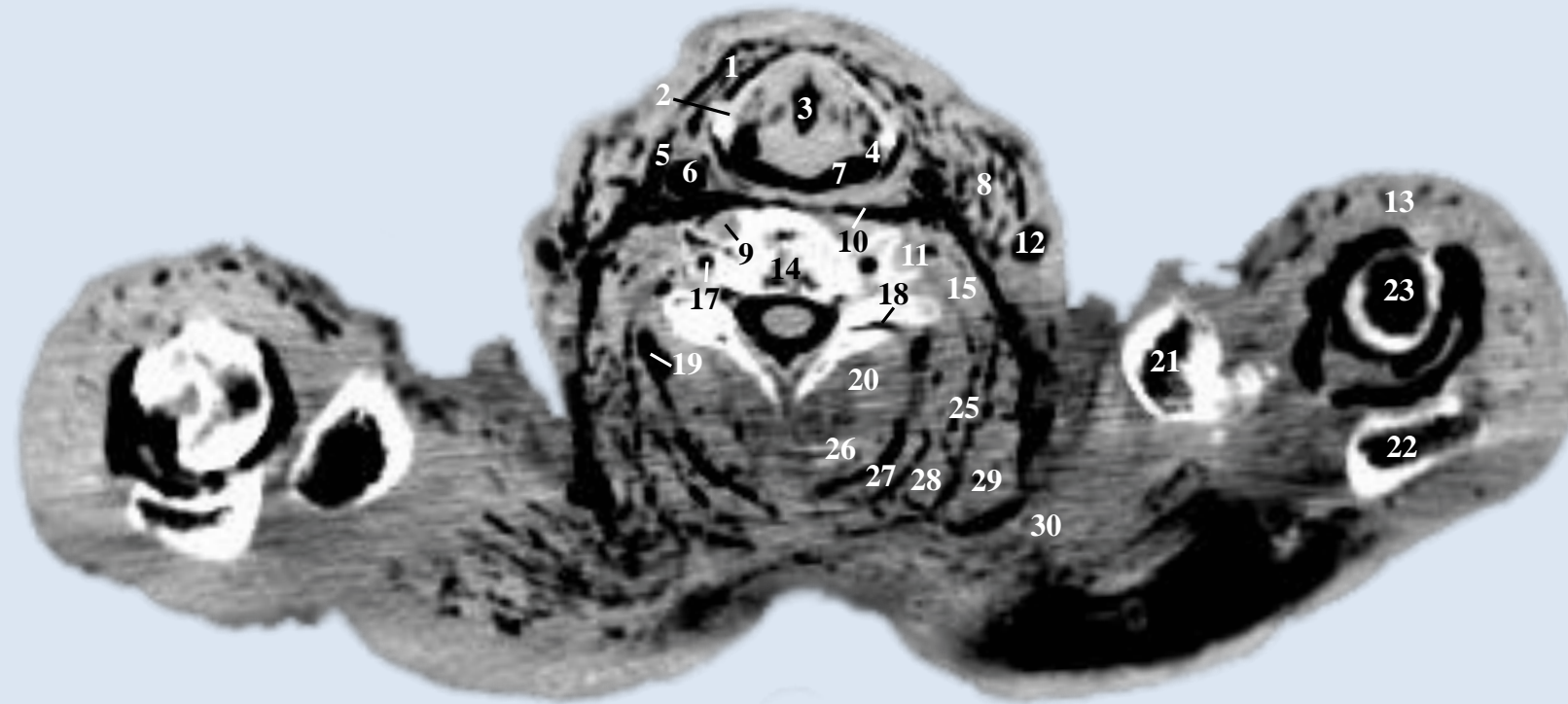


C5

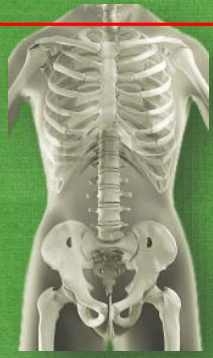

Semmelweis Egyetem
Anatómiai, Szövet- és Fejlődéstani
Intézet

1. mm. infrahyoidei
2. cornu major ossis hyoidei
3. vestibulum laryngis,
4. recessus piriformis
5. v. jugularis interna
6. a. carotis communis
7. laryngopharynx
8. m. sternocleidomastoideus
9. mm. prevertebrales (m. longus colli/capitis)
10. spatium retropharyngeum
11. m. scalenus anterior
12. v. jugularis externa
13. m. deltoideus
14. corpus vertebrae
15. m. scalenus medius
16. -
17. a. vertebralis
18. art. intervertebralis (art. zygapophysealis)
19. vv. cervicales profundae
20. m. multifidus
21. clavicula
22. scapula
23. humerus
24. -
25. m. longissimus capitis
26. m. semispinalis cervicis
27. m. semispinalis capitis
28. m. splenius capitis
29. m. levator scapulae
30. m. trapezius

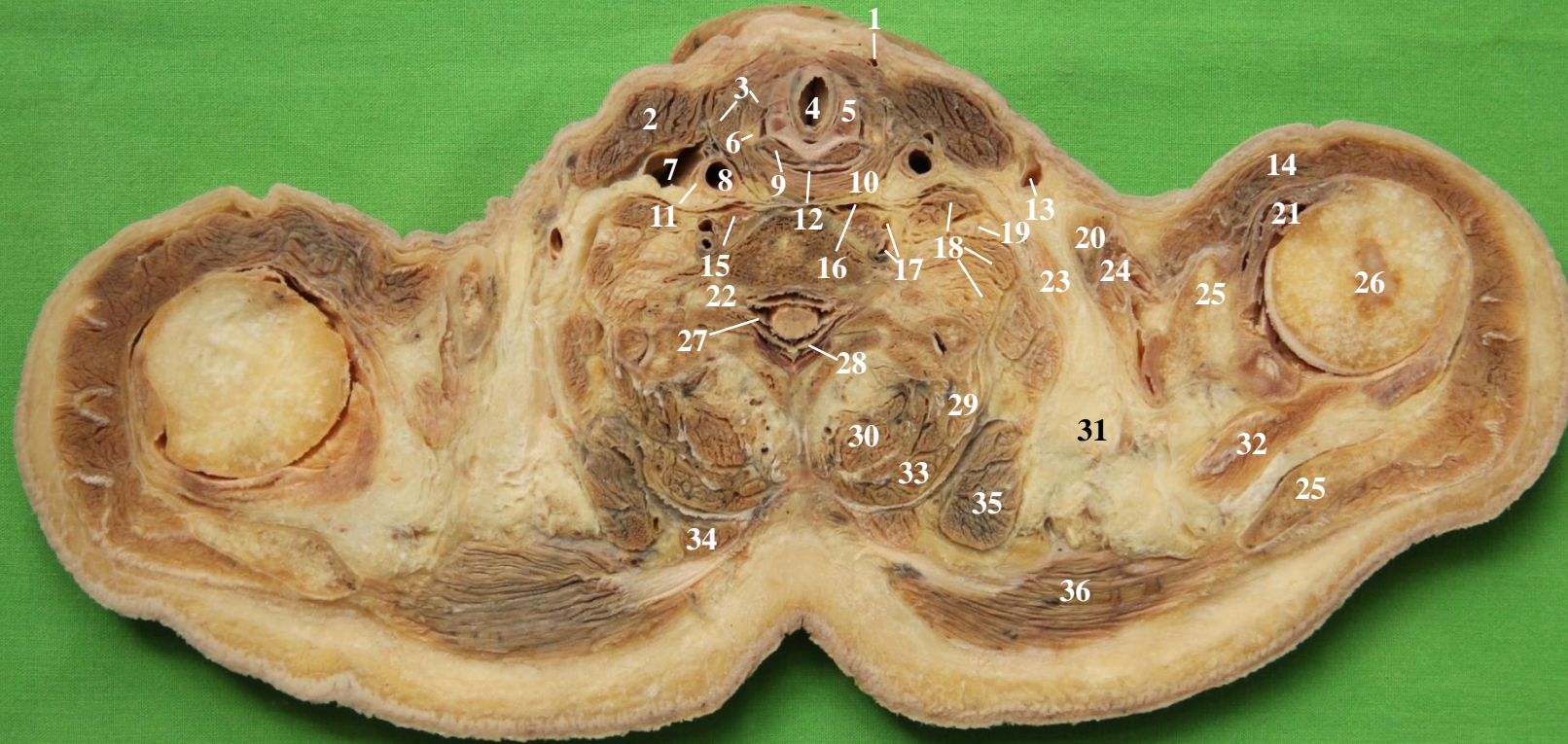


C6

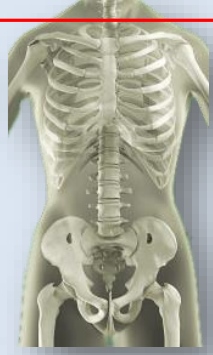

Semmelweis Egyetem
Anatómai, Szövet- és Fejlődéstani
Intézet

1. v. jugularis anterior
2. m. sternocleidomastoideus
3. mm. infrahyoidei
4. cavum subglotticum
5. cartilago cricoidea
6. cartilago thyroidea, cornu inferius
7. v. jugularis interna
8. a. carotis communis
9. m. cricoarytenoideus posterior
10. m. constrictor pharyngis inferior
11. n. vagus
12. laryngopharynx
13. v. jugularis externa
14. m. deltoideus
15. m. longus colli/capitis)
16. spatium retropharyngeum
17. a. v. vertebralis
18. mm. scaleni
19. plexus brachialis a hiatus scaleni-ben
20. clavicula
21. m. biceps brachii ina
22. foramen intervertebrale
23. m. omohyoideus
24. m. subclavius
25. scapula
26. humerus
27. lig. denticulatum
28. saccus duralis
29. m. longissimus capitis
30. m. semispinalis
31. fossa axillaris
32. m. supraspinatus
33. m. splenius capitis
34. m. rhomboideus minor
35. m. levator scapulae
36. m. trapezius

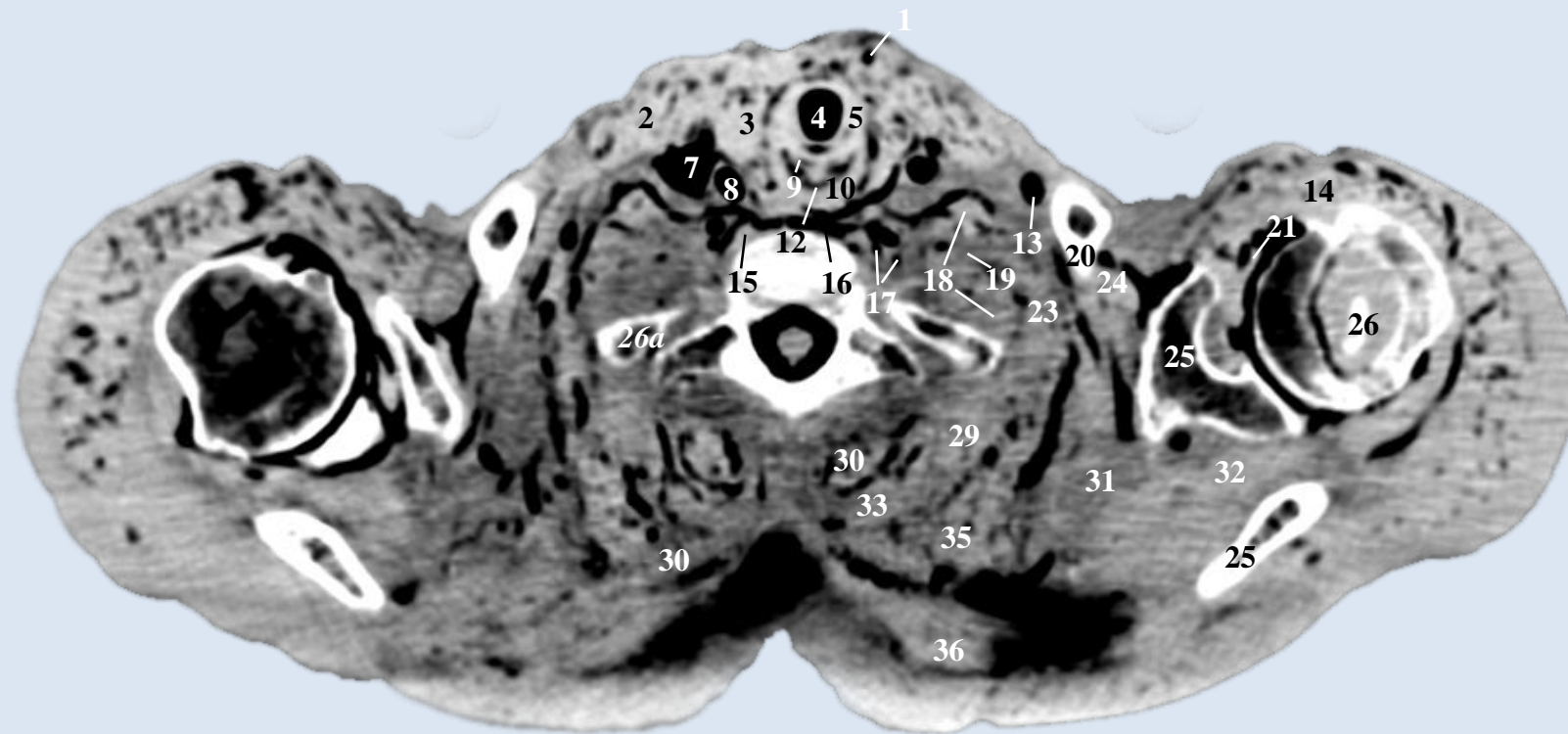


C6

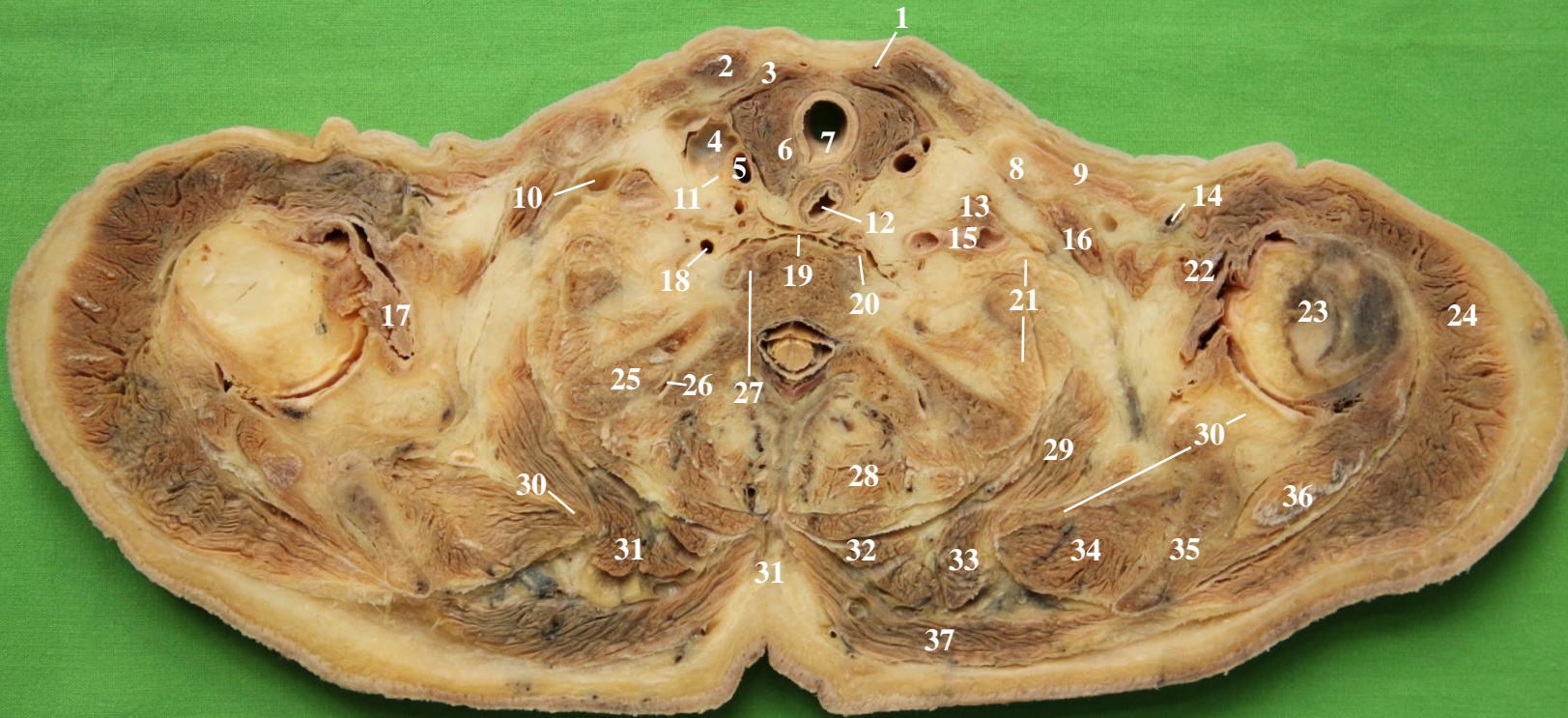
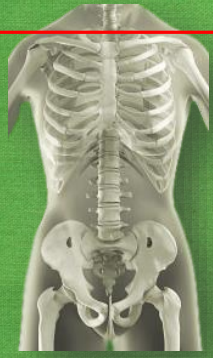

Semmelweis Egyetem
Anatómiai, Szövet- és Fejlődéstan
Intézet

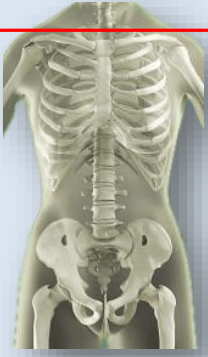1. v. jugularis anterior
2. m. sternocleidomastoideus
3. mm. infrahyoidei
4. cavum subglotticum
5. cartilago cricoidea
6. -
7. v. jugularis interna
8. a. carotis communis
9. m. cricoarytenoideus posterior
10. m. constrictor pharyngis inferior
11. n. vagus
12. laryngopharynx
13. v. jugularis externa
14. m. deltoideus
15. m. longus colli/capitis)
16. spatium retropharyngeum
17. a. v. vertebralis
18. mm. scaleni
19. plexus brachialis a hiatus scaleni-ben
20. clavicula
21. m. biceps brachii ina
22. -
23. m. m. omohyoideus
24. m. subclavius
25. scapula
26. humerus
- 26a. *costa,*
art. costotransversaria
27. -
28. -
29. m. longissimus capitis
30. m. semispinalis
31. fossa axillaris
32. m. supraspinatus
33. m. splenius capitis
34. m. rhomboideus minor
35. m. levator scapulae
36. m. trapezius



Th1



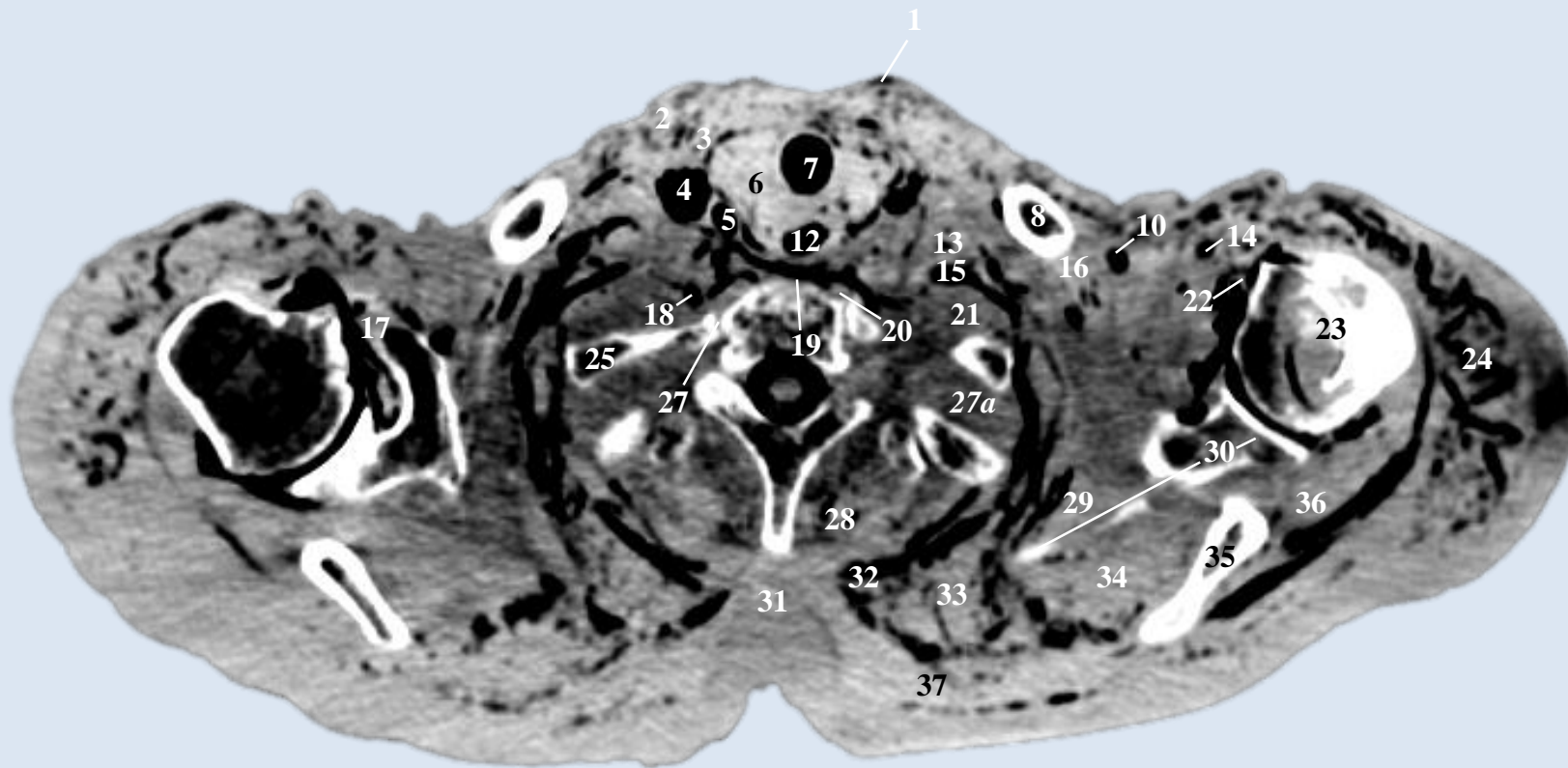
1. v. jugularis anterior
2. m. sternocleidomastoideus
3. mm. infrahyoidei
4. v. jugularis interna
5. a. carotis communis
6. gl. thyroidea
7. trachea
8. clavicula
9. m. pectoralis major
10. v. subclavia
11. n. vagus
12. oesophagus
13. m. scalenus anterior
14. v. cephalica
15. a. subclavia a hiatus scaleni-ben
16. m. subclavius
17. m. subscapularis ina
18. a. vertebralis
19. spatium retropharyngeum
20. m. longus colli
21. m. scalenus medius és m. scalenus posterior
22. m. biceps brachii, caput breve ina
23. humerus
24. m. deltoideus
25. costa
26. art. costotransversaria
27. art. capitis costae
28. m. erector spinae
29. m. serratus anterior
30. scapula
31. lig. nuchae
32. m. serratus posterior superior
33. m. rhomboideus major
34. m. supraspinatus
35. spina scapulae
36. m. infraspinatus
37. m. trapezius



Th1



Semmelweis Egyetem
Anatómiai, Szövet- és Fejlődéstani
Intézet

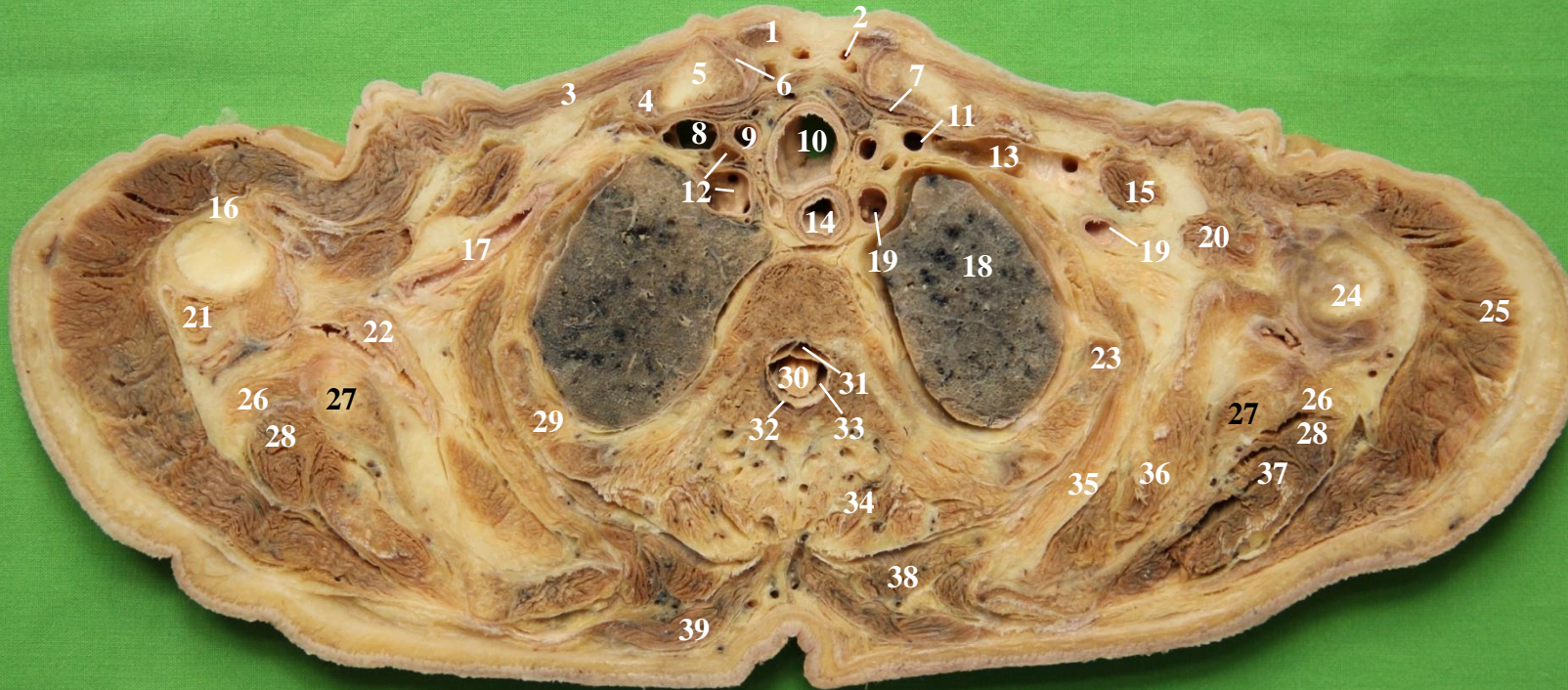


1. v. jugularis anterior
2. m. sternocleidomastoideus
3. mm. infrahyoidei
4. v. jugularis interna
5. a. carotis communis
6. gl. thyroidea
7. trachea
8. clavicula
9. -
10. v. subclavia
11. -
12. oesophagus
13. m. scalenus anterior
14. v. cephalica
15. a. subclavia a hiatus
scaleni-ben
16. m. subclavius
17. m. subscapularis ina
18. a. vertebralis
19. spatium retropharyngeum
20. m. longus colli
21. m. scalenus medius
22. m. biceps brachii, caput
breve ina
23. humerus
24. m. deltoideus
25. costa
26. -
27. art. capitis costae
- 27a. m. scalenus posterior
28. m. erector spinae
29. m. serratus anterior
30. scapula
31. lig. nuchae
32. m. serratus posterior
superior
33. m. rhomboideus major
34. m. supraspinatus
35. spina scapulae
36. m. infraspinatus
37. m. trapezius

Th2



Semmelweis Egyetem
Anatómiai, Szövet- és Fejlődéstani
Intézet



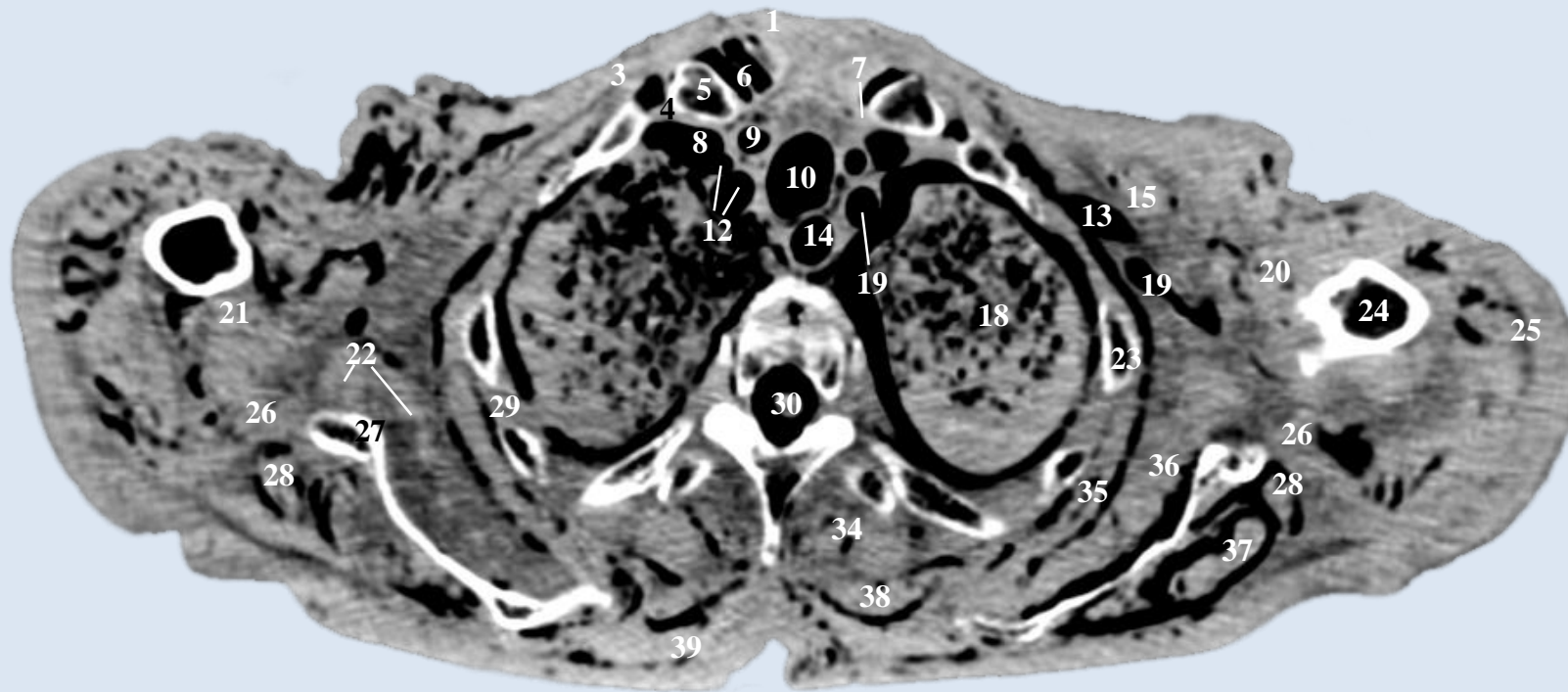
1. m. sternocleidomastoideus pars sternalis
2. v. jugularis anterior
3. m. pectoralis major
4. m. subclavius
5. clavicula
6. art. sternoclavicularis
7. mm. infrahyoidei
8. v. brachiocephalica dextra
9. a. carotis communis dextra
10. trachea
11. v. jugularis interna
12. a.v. subclavia dextra
13. v. subclavia sinistra
14. oesophagus
15. m. pectineus minor
16. m. biceps brachii, caput longum in a
17. a. subclavia dextra
18. pulmo sinister, lobus superior
19. a. subclavia sinistra
20. m. biceps brachii, caput berve
21. m. triceps brachii, caput laterale
22. m. subscapularis in a
23. costa
24. humerus
25. m. deltoideus
26. m. triceps brachii, caput longum
27. scapula
28. m. teres minor
29. mm. intercostalis
30. medulla spinalis
31. spatium epidurale
32. durazsák
33. spatium subdurale
34. m. erector spinae
35. m. serratus anterior
36. m. subscapularis
37. m. infraspinatus
38. m. rhomboideus
39. m. trapezius



Th2

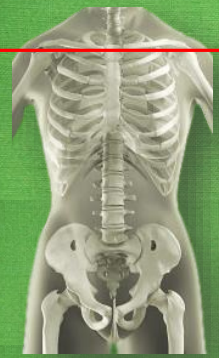

Semmelweis Egyetem
Anatómiai, Szövet- és Fejlődéstani
Intézet

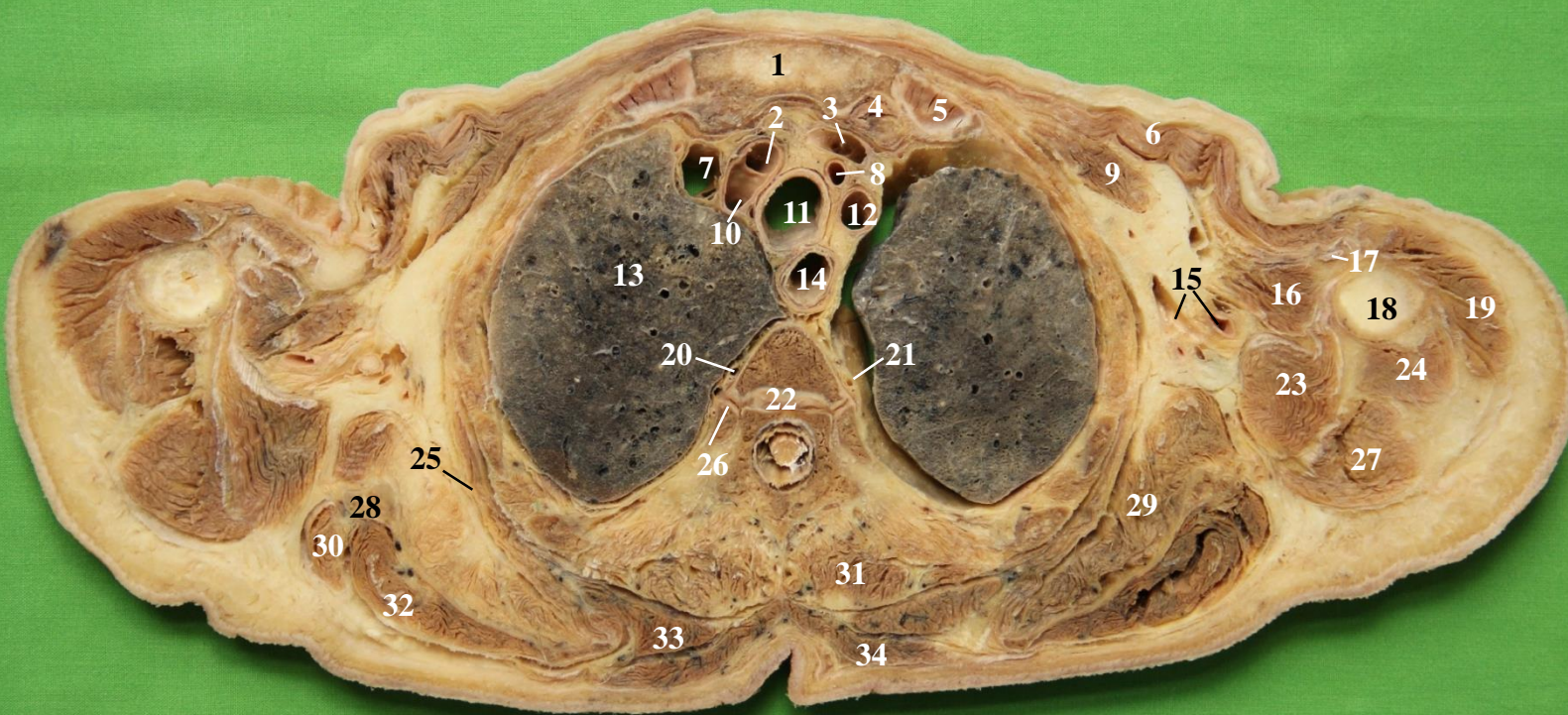


1. m. sternocleidomastoideus pars sternalis
2. -
3. m. pectoralis major
4. m. subclavius
5. clavicula
6. art. sternoclavicularis
7. mm. infrahyoidei
8. v. brachiocephalica dextra
9. a. carotis communis dextra
10. trachea
11. -
12. a.v. subclavia dextra
13. v. subclavia sinistra
14. oesophagus
15. m. pectineus minor
16. -
17. -
18. pulmo sinister, lobus superior
19. a. subclavia sinistra
20. m. biceps brachii, caput berve
21. m. triceps brachii, caput laterale
22. m. subscapularis ina
23. costa
24. humerus
25. m. deltoideus
26. m. triceps brachii, caput longum
27. scapula
28. m. teres minor
29. mm. intercostalis
30. medulla spinalis
31. -
32. -
33. -
34. m. erector spinae
35. m. serratus anterior
36. m. subscapularis
37. m. infraspinatus
38. m. rhomboideus
39. m. trapezius

Th 2/3

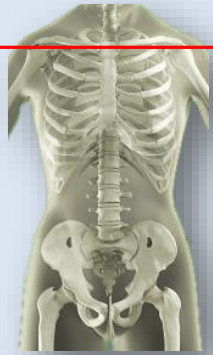

Semmelweis Egyetem
Anatómiai, Szövet- és Fejlődéstani
Intézet

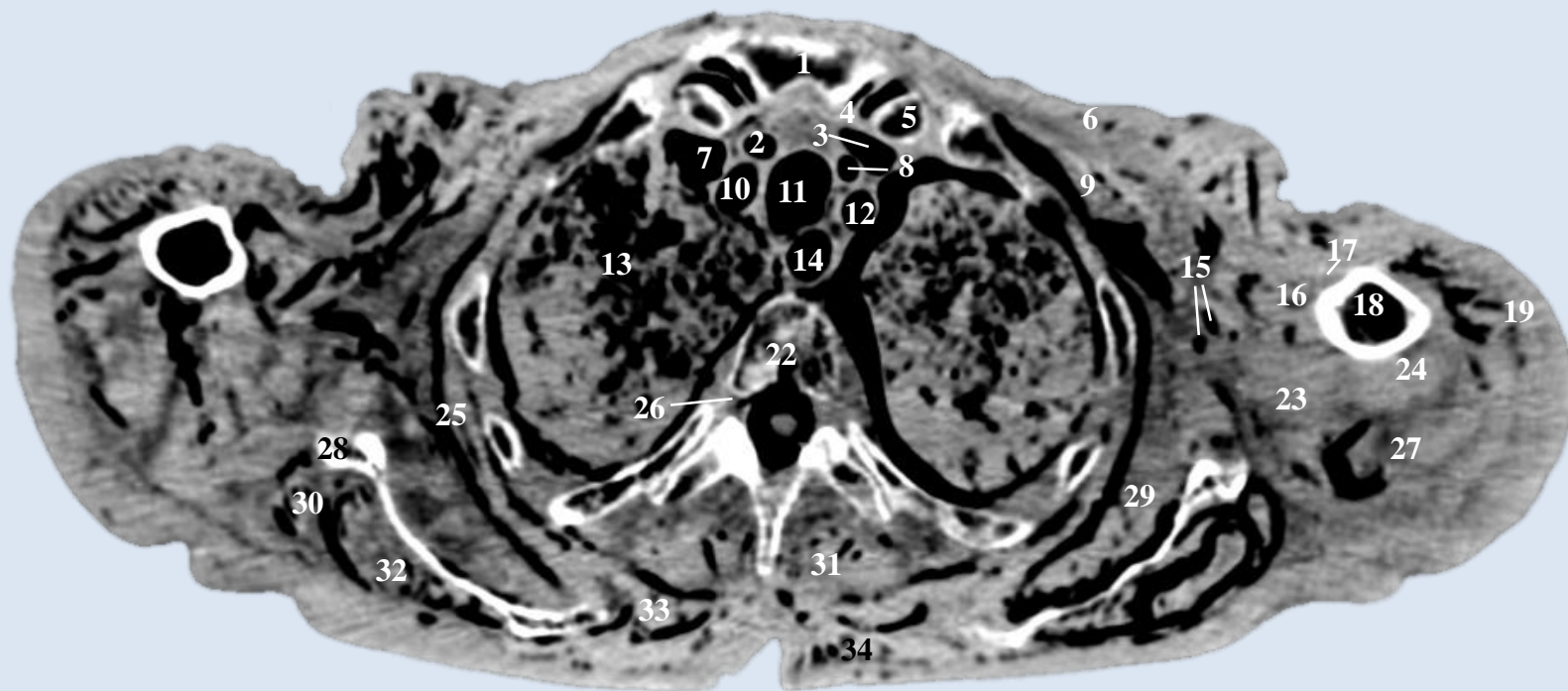


1. sternum
2. a. carotis communis dextra
3. v. brachiocephalica sinistra
4. mm. infrahyoidei
5. costa (porc)
6. m.pectoralis major
7. v. brachiocephalica dextra
8. a. carotis communis sinistra
9. m.pectoralis minor
10. a. subclavia dextra
11. trachea
12. a. subclavia sinistra
13. pulmo dexter, lobus superior
14. oesophagus
15. a. v. axillaris
16. m. biceps brachii, caput breve
17. m. biceps brachii, caput longum
18. humerus
19. m. deltoideus
20. a. intercostalis suprema
21. a. hemiazygos accessoria
22. discus intervertebralis
23. m. teres major
24. m. triceps brachii, caput laterale
25. m. serratus anterior
26. art. capitis costae
27. m. triceps brachii, caput longum
28. scapula
29. m. subscapularis
30. m. teres minor
31. m. erector spinae
32. m. infraspinatus
33. m. rhomboideus major
34. m. trapezius

Th 2/3



Semmelweis Egyetem
Anatómiai, Szövet- és Fejlődéstani
Intézet

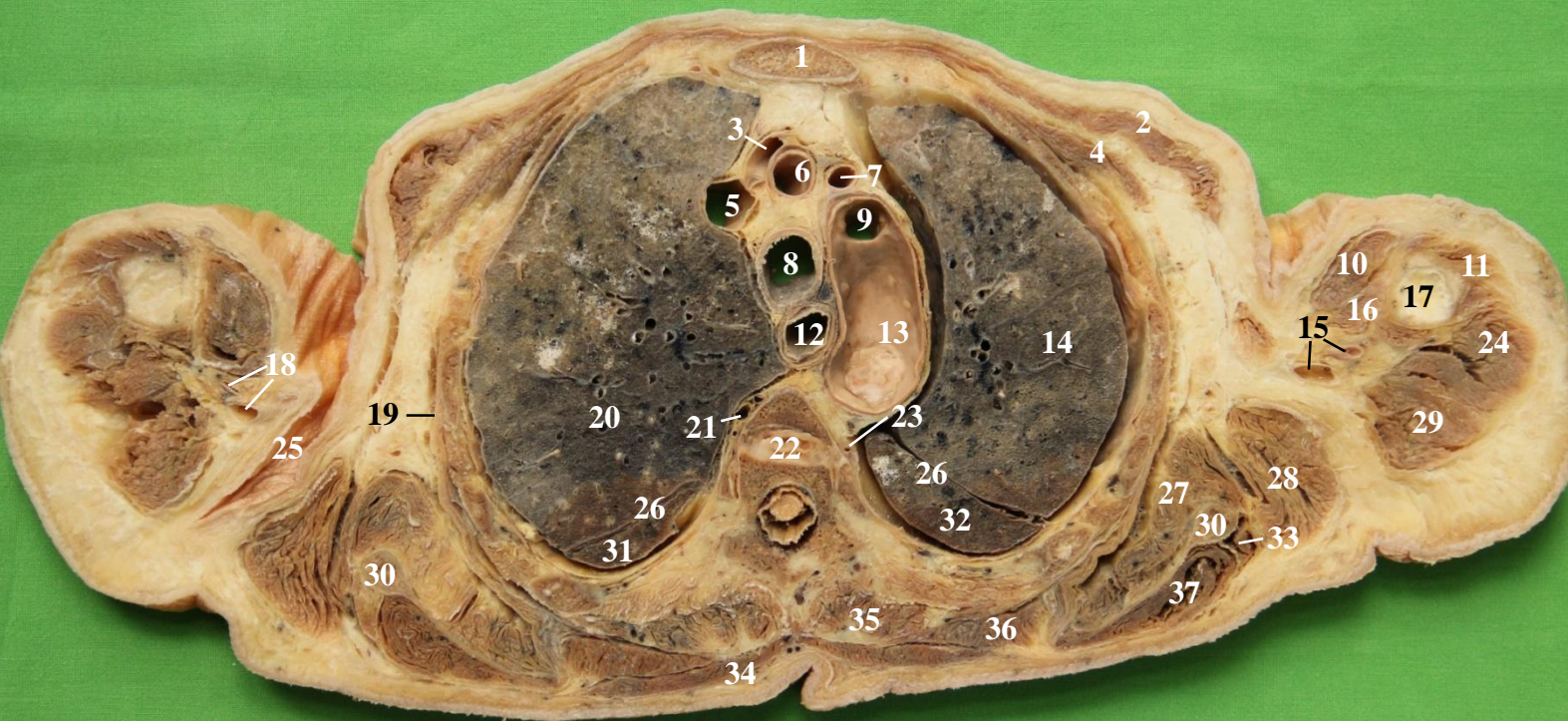


1. sternum
2. a. carotis communis dextra
3. v. brachiocephalica sinistra
4. mm. infrahyoidei
5. costa (porc)
6. m.pectoralis major
7. v. brachiocephalica dextra
8. a. carotis communis sinistra
9. m.pectoralis minor
10. a. subclavia dextra
11. trachea
12. a. subclavia sinistra
13. pulmo dexter, lobus superior
14. oesophagus
15. a. v. axillaris
16. m. biceps brachii, caput breve
17. m. biceps brachii, caput longum in a
18. humerus
19. m. deltoideus
20. -
21. -
22. discus intervertebralis
23. m. teres major
24. m. triceps brachii, caput laterale
25. m. serratus anterior
26. art. capitis costae
27. m. triceps brachii, caput longum
28. scapula
29. m. subscapularis
30. m. teres minor
31. m. erector spinae
32. m. infraspinatus
33. m. rhomboideus major
34. m. trapezius

Th 3/4

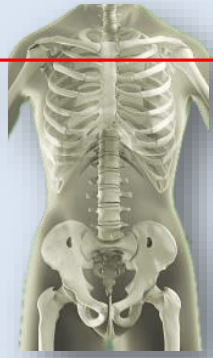

Semmelweis Egyetem
Anatómiai, Szövet- és Fejlődéstani
Intézet



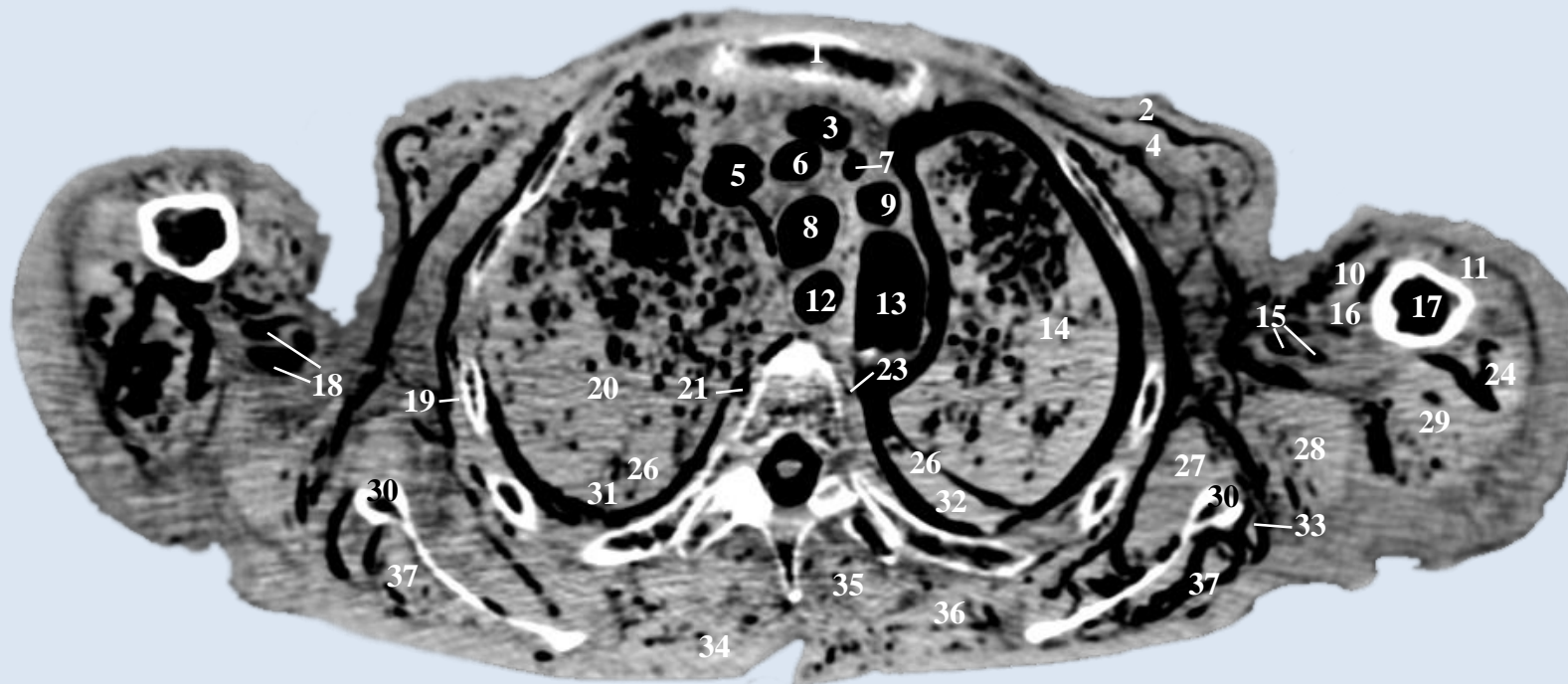
1. sternum
2. m. pectoralis major
3. v. brachiocephalica sinistra
4. m. pectoralis minor
5. v. brachiocephalica dextra
6. tr. brachiocephalicus
7. a. carotis communis sinistra
8. trachea
9. a. subclavia sinistra
10. m. biceps brachii, caput breve
11. m. deltoideus
12. oesophagus
13. arcus aortae
14. pulmo sinister, lobus superior
15. a. v. axillaris
16. m. coracobrachialis
17. humerus
18. a. v. axillaris
19. m. serratus anterior
20. pulmo dexter, lobus superior
21. v. intercostalis suprema
22. discus intervertebralis
23. v. hemiazygos accessoria
24. m. triceps brachii, caput laterale
25. hónaljredő
26. fissura obliqua
27. m. subscapularis
28. m. latissimus dorsi inna és a m. teres major
29. m. triceps brachii, caput longum
30. scapula
31. pulmo dexter, lobus inferior
32. pulmo sinister, lobus inferior
33. m. teres minor
34. m. trapezius
35. m. erector spinae
36. m. rhomboideus
37. m. infraspinatus

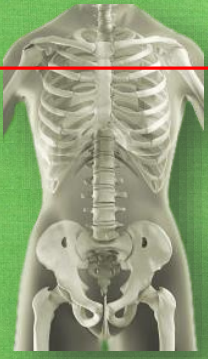Th 3/4



Semmelweis Egyetem
Anatómiai, Szövet- és Fejlődéstan
Intézet

1. sternum
2. m.pectoralis major
3. v. brachiocephalica sinistra
4. m. pectoralis minor
5. v. brachiocephalica dextra
6. tr. brachiocephalicus
7. a. carotis communis sinistra
8. trachea
9. a. subclavia sinistra
10. m. biceps brachii, caput breve
11. m. deltoideus
12. oesophagus
13. arcus aortae
14. pulmo sinister, lobus superior
15. a. v. axillaris
16. m. coracobrachialis
17. humerus
18. a.v. axillaris
19. m. serratus anterior
20. pulmo dexter, lobus superior
21. v. intercostalis suprema
22. -
23. v. hemiazygos accessoria
24. m. triceps brachii, caput laterale
25. -
26. fissura obliqua
27. m. subscapularis
28. m. latissimus dorsi ina és a m. teres major
29. m. triceps brachii, caput longum
30. scapula
31. pulmo dexter, lobus inferior
32. pulmo sinister, lobus inferior
33. m. teres minor
34. m. trapezius
35. m. erector spinae
36. m. rhomboideus
37. m. infrapinatus

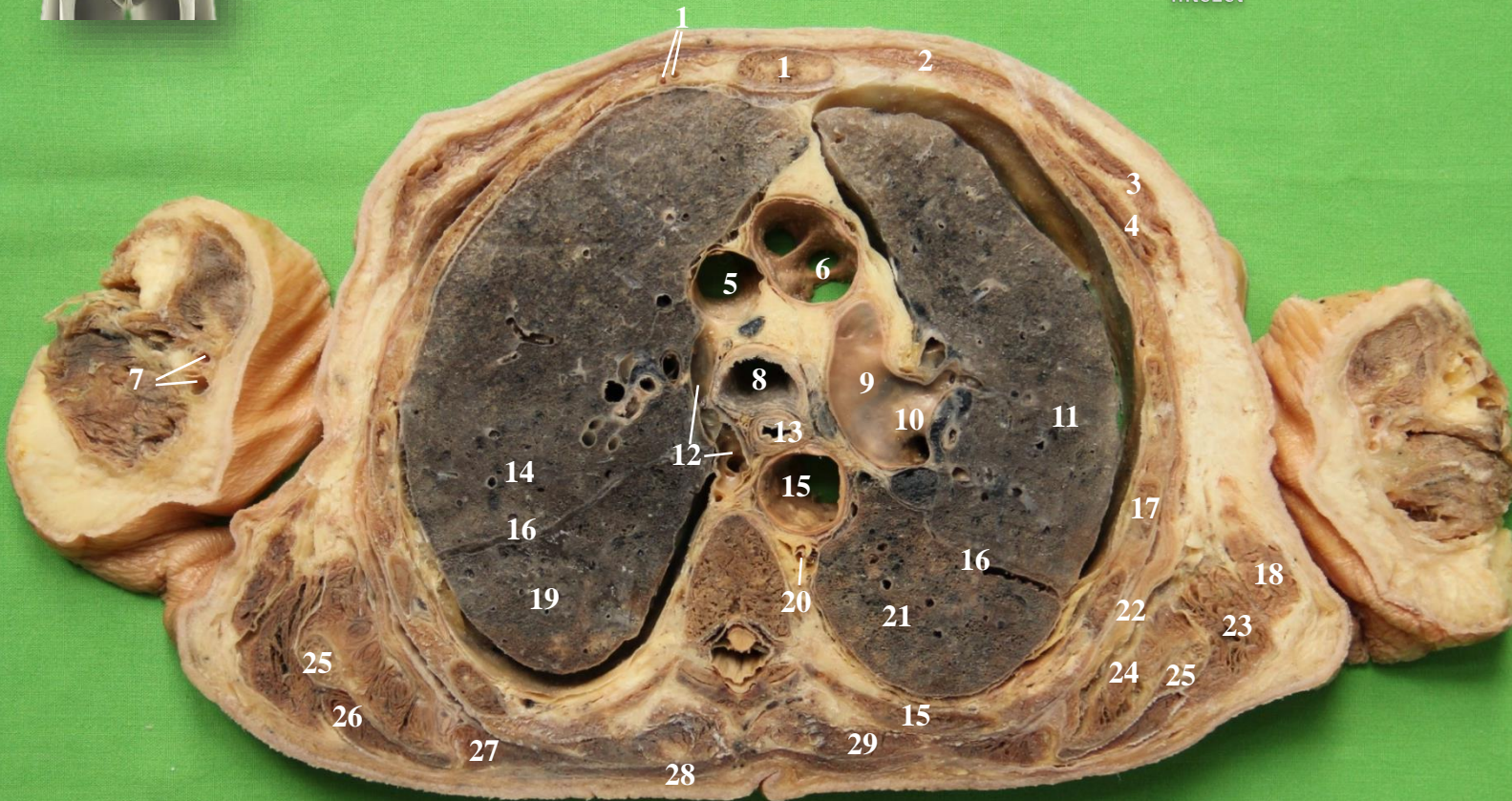




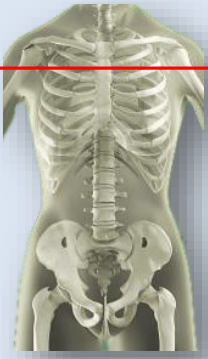Th5



Semmelweis Egyetem
Anatómiai, Szövet- és Fejlődéstani
Intézet



1. a.v. thoracica interna
2. sternum
3. m. pectoralis major
4. m. pectoralis minor
5. v. cava superior
6. aorta ascendens
7. a.v. brachialis
8. trachea
9. truncus pulmonalis
10. a. pulmonalis sinistra
11. pulmo sinister, lobus superior
12. v. azygos
13. oesophagus
14. pulmo dexter, lobus superior
15. aorta descendens
16. fissura obliqua
17. costa
18. m. latissimus dorsi
19. pulmo dexter, lobus inferior
20. v. hemiazygos accessoria
21. pulmo sinister, lobus inferior
22. m. serratus anerior
23. m. teres major
24. m. subscapularis
25. scapula
26. m. infraspinatus
27. m. rhomboideus
28. m. trapezius
29. m. erector spinae

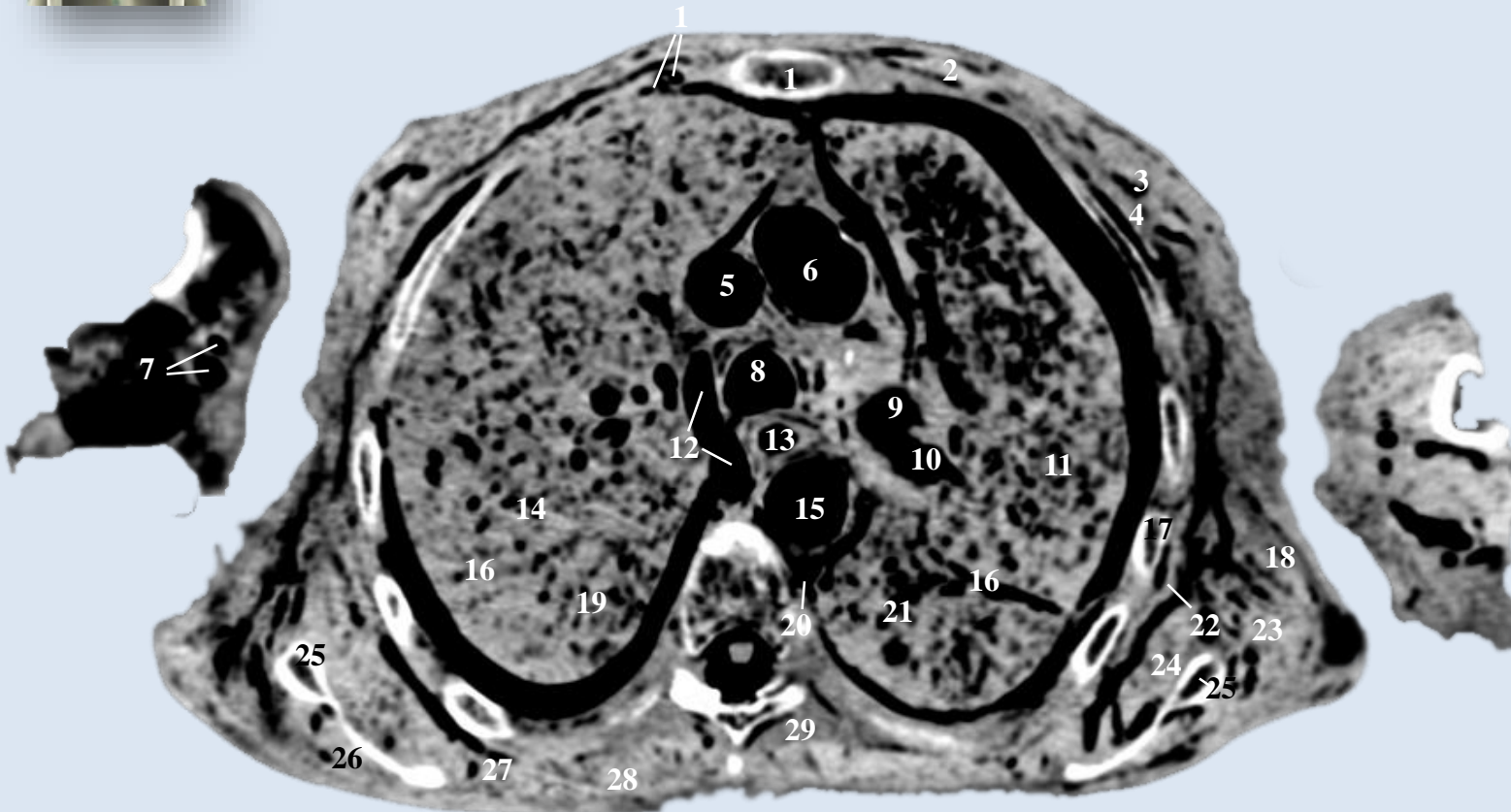


Th5



Semmelweis Egyetem
Anatómiai, Szövet- és Fejlődéstani
Intézet

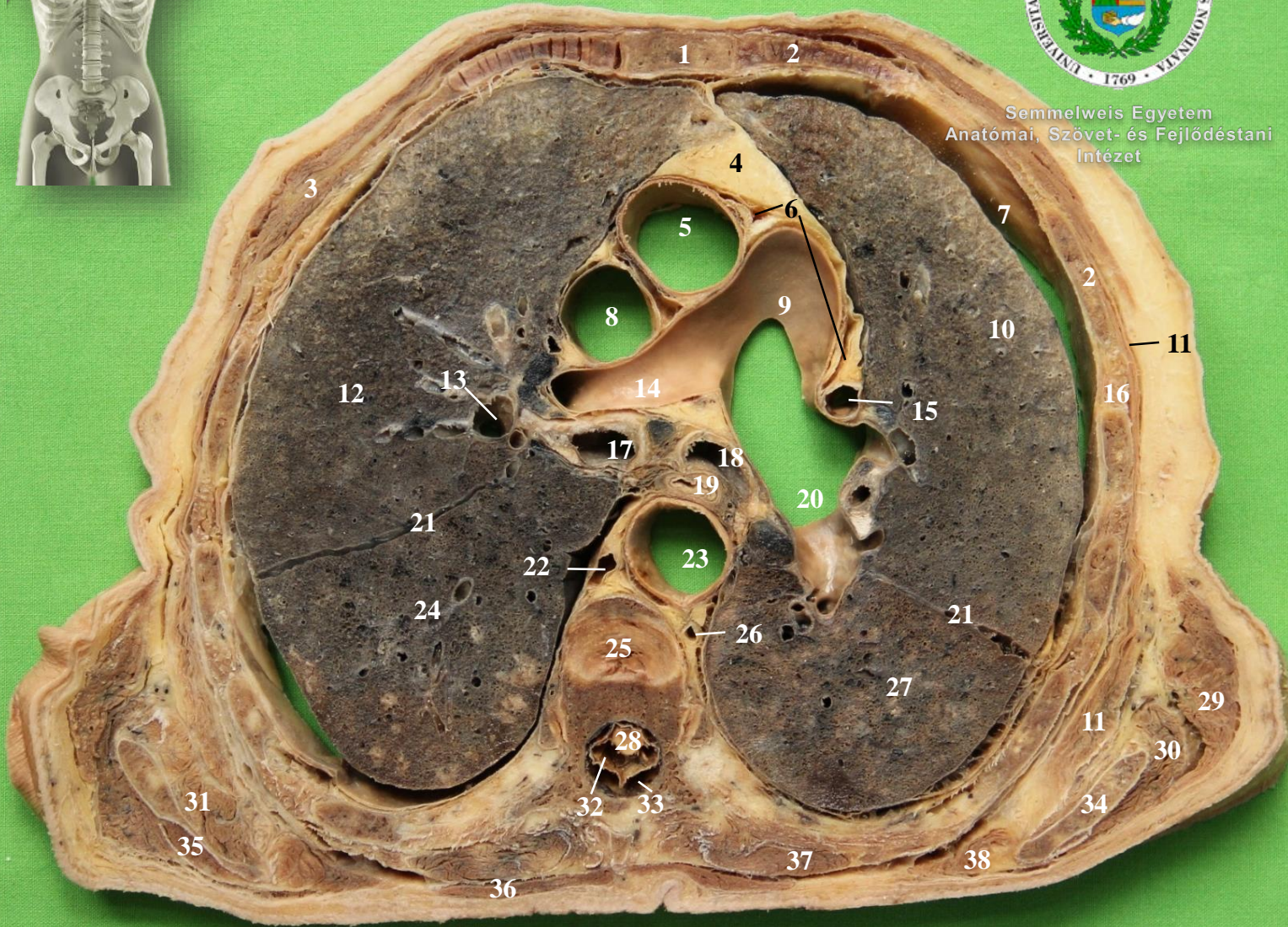
1. a.v. thoracica interna
2. sternum
3. m. pectoralis major
4. m. pectoralis minor
5. v. cava superior
6. aorta ascendens
7. a.v. brachialis
8. trachea
9. truncus pulmonalis
10. a. pulmonalis sinistra
11. pulmo sinister, lobus superior
12. v. azygos
13. oesophagus
14. pulmo dexter, lobus superior
15. aorta descendens
16. fissura obliqua
17. costa
18. m. latissimus dorsi
19. pulmo dexter, lobus inferior
20. v. hemiazygos accessoria
21. pulmo sinister, lobus inferior
22. m. serratus anerior
23. m. teres major
24. m. subscapularis
25. scapula
26. m. infraspinatus
27. m. rhomboideus
28. m. trapezius
29. m. erector spinae



Th5/6

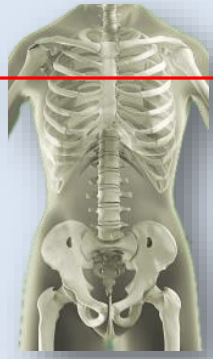

Semmelweis Egyetem
Anatómiai, Szövet- és Fejlődéstani
Intézet

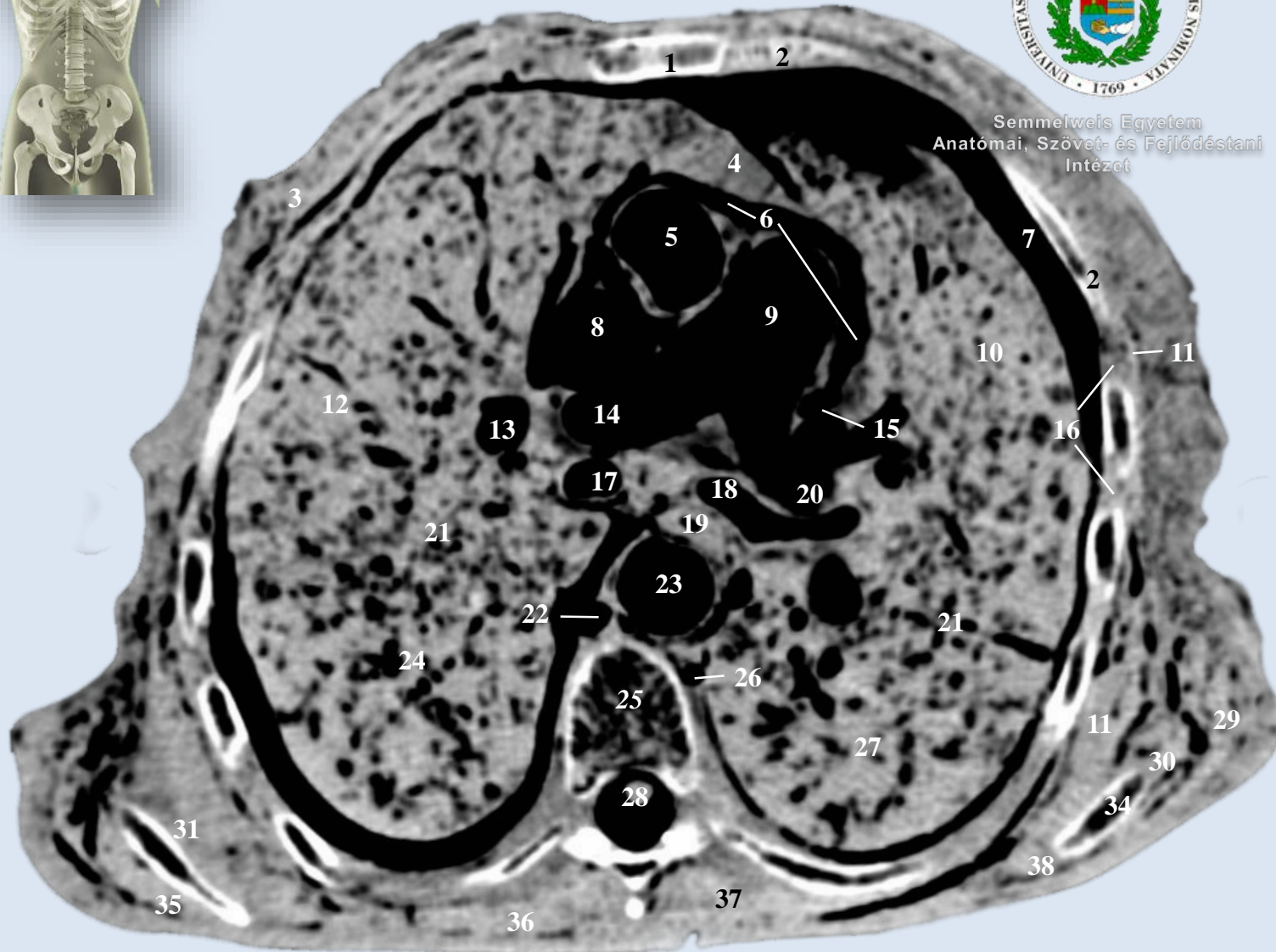


1. sternum
2. costa
3. m. pectoralis major/minor
4. thymus adiposum
5. aorta ascendens
6. cavum pericardii
7. cavum pleurae
8. v. cava superior
9. truncus pulmonalis
10. pulmo dexter, lobus superior
11. m. serratus anterior
12. pulmo sinister, lobus superior
13. v. pulmonalis dextra
14. a. pulmonalis dextra
15. v. pulmonalis sinistra
16. mm. intercostales
17. bronchus principalis dexter
18. bronchus principalis sinister
19. oesophagus
20. a. pulmonalis sinistra
21. fissura obliqua
22. v. azygos
23. aorta descendens
24. pulmo dexter, lobus inferior
25. discus intervertebralis
26. v. hemiazygos accessoria
27. pulmo sinister, lobus inferior
28. spina medullaris
29. m. latissimus dorsi
30. m. teres major
31. m. subscapularis
32. spatium subarachnoideum
33. spatium epidurale
34. scapula
35. m. infraspinatus
36. m. trapezius
37. m. erector spinae
38. m. rhomboideus major

Th5/6

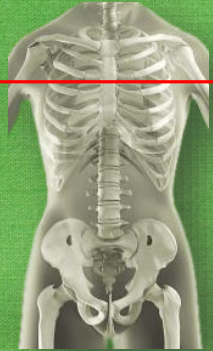

Semmelweis Egyetem
Anatómiai, Szövet- és Fejlődéstan Intézet



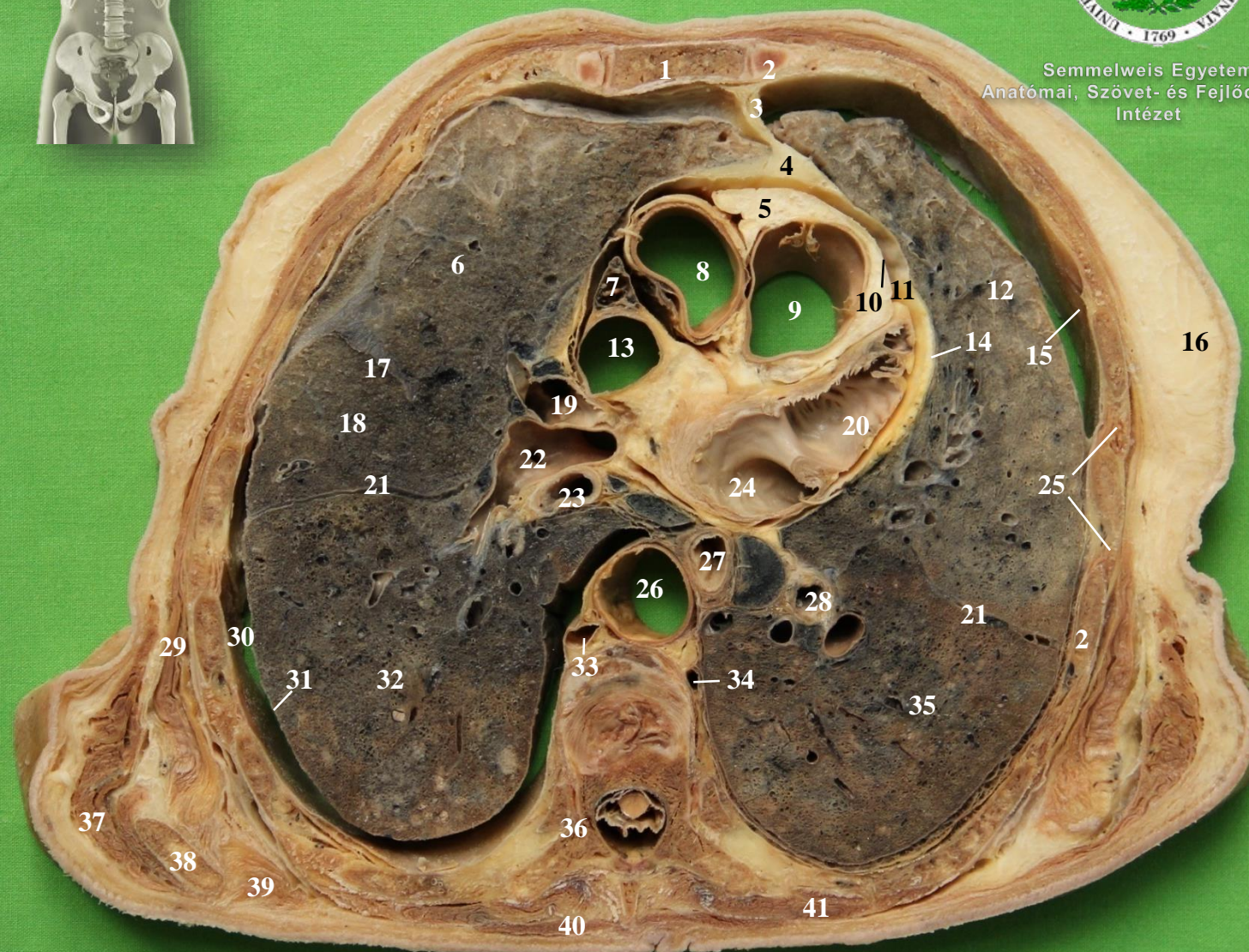
1. sternum
2. costa
3. m.pectoralis major/minor
4. thymus adiposum
5. aorta ascendens
6. cavum pericardii
7. cavum pleurae
8. v. cava superior
9. truncus pulmonalis
10. pulmo dexter, lobus superior
11. m. serratus anterior
12. pulmo sinister, lobus superior
13. v. pulmonalis dextra
14. a. pulmonalis dextra
15. v. pulmonalis sinistra
16. mm. intercostales
17. bronchus principalis dexter
18. bronchus principalis sinister
19. oesophagus
20. a. pulmonalis sinistra
21. fissura obliqua
22. v. azygos
23. aorta descendens
24. pulmo dexter, lobus inferior
25. corpus vertebrae
26. v. hemiazygos accessoria
27. pulmo sinister, lobus inferior
28. spina medullaris
29. m. latissimus dorsi
30. m. teres major
31. m. subscapularis
32. -
33. -
34. scapula
35. m. infraspinatus
36. m. trapezius
37. m. errector spinae
38. m. rhomboideus major

Th 6/7

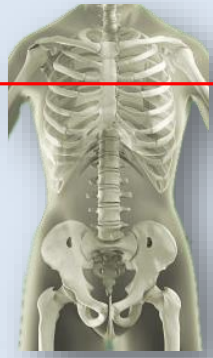

Semmelweis Egyetem
Anatómiai, Szövet- és Fejlődéstani
Intézet

1. sternum
2. costa
3. lig. sternopericardiacum
4. thymus adiposum
5. subpericardiális zsírszövet
6. pulmo dexter, lobus superior
7. auricula dextra
8. aorta ascendens
9. truncus pulmonalis
10. pericardium viscerale
11. cavum pericardii
12. pulmo sinister, lobus superior
13. v. cava superior
14. pericardium parietale
15. pleura parietale
16. mamma
17. fissura transversa
18. pulmo dexter, lobus medius
19. v. pulmonalis dextra
20. auricula sinistra
21. fissura obliqua
22. a. pulmonalis dextra
23. bronchus principalis dexter
24. atrium sinistrum
25. mm. intercostales
26. aorta descendens
27. oesophagus
28. bronchus principalis sinister
29. m. serratus anterior
30. cavum pleurae
31. pleura viscerale
32. pulmo dexter, lobus inferior
33. v. azygos
34. v. hemiazygos
35. pulmo sinister, lobus inferior
36. art. costovertebralis
37. m. latissimus dorsi
38. scapula
39. m. rhomboideus major
40. m. trapezius
41. m. erector spinae

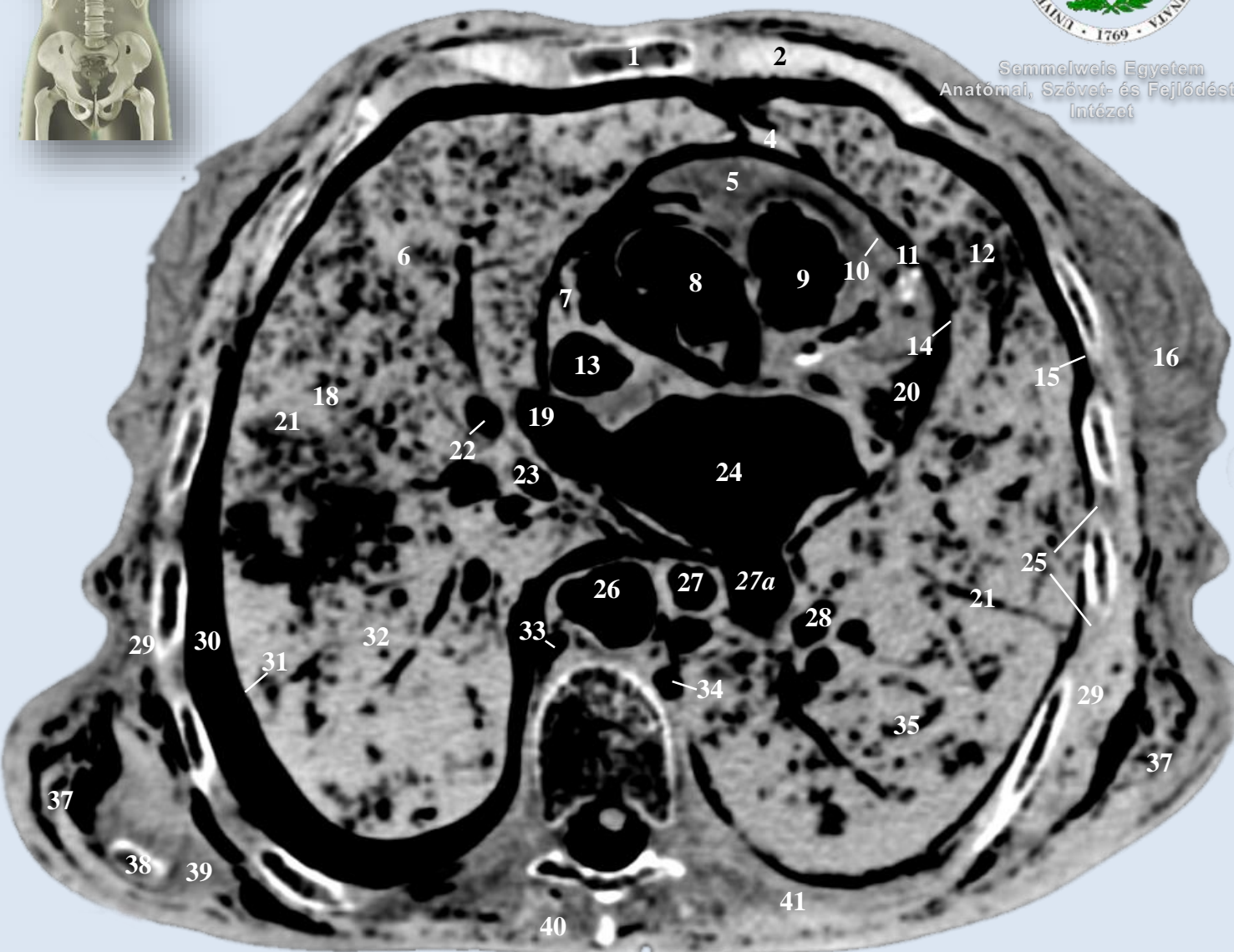


Th 6/7

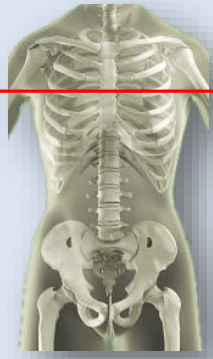

Semmelweis Egyetem
Anatómiai, Szövet- és Fejlődéstani
Intézet

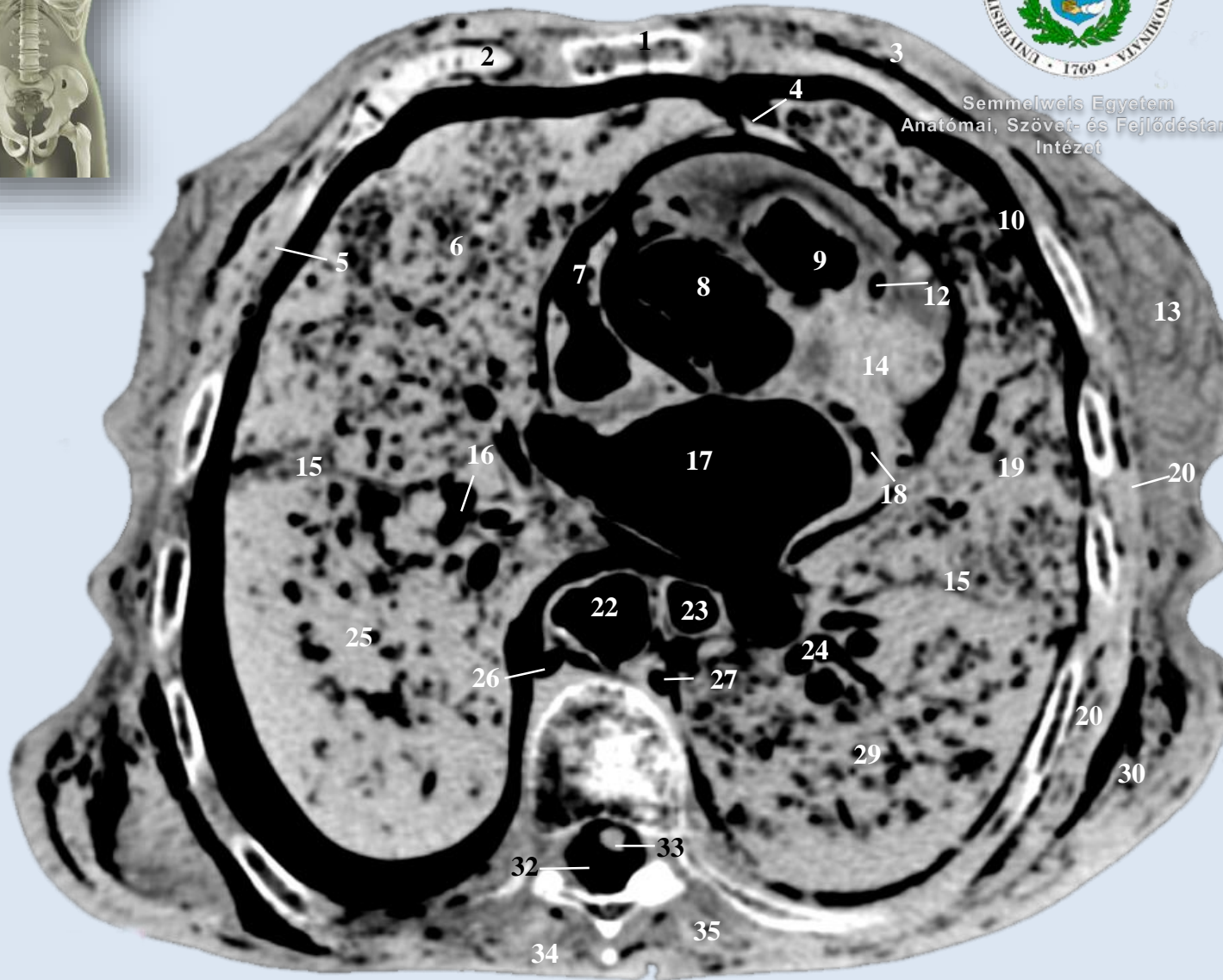
1. sternum
2. costa
3. -
4. thymus adiposum
5. subpericardiális zsírszövet
6. pulmo dexter, lobus superior
7. auricula dextra
8. aorta ascendens
9. truncus pulmonalis
10. pericardium viscerale
11. cavum pericardii
12. pulmo sinister, lobus superior
13. v. cava superior
14. pericardium parietale
15. pleura parietale
16. mamma
17. -
18. pulmo dexter, lobus medius
19. v. pulmonalis dextra
20. auricula sinistra
21. fissura obliqua
22. a. pulmonalis dextra
23. bronchus principalis dexter
24. atrium sinistrum
25. mm. intercostales
26. aorta descendens
27. oesophagus
- 27a. v. pulmonalis sinistra
28. bronchus principalis sinister
29. m. serratus anterior
30. cavum pleurae
31. pleura viscerale
32. pulmo dexter, lobus inferior
33. v. azygos
34. v. hemiazygos
35. pulmo sinister, lobus inferior
36. -
37. m. latissimus dorsi
38. scapula
39. m. rhomboideus major
40. m. trapezius
41. m. erector spinae



Th7/8

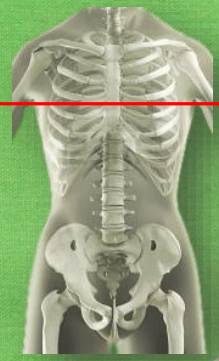


Semmelweis Egyetem
Anatómiai, Szövet- és Fejlődéstani
Intézet

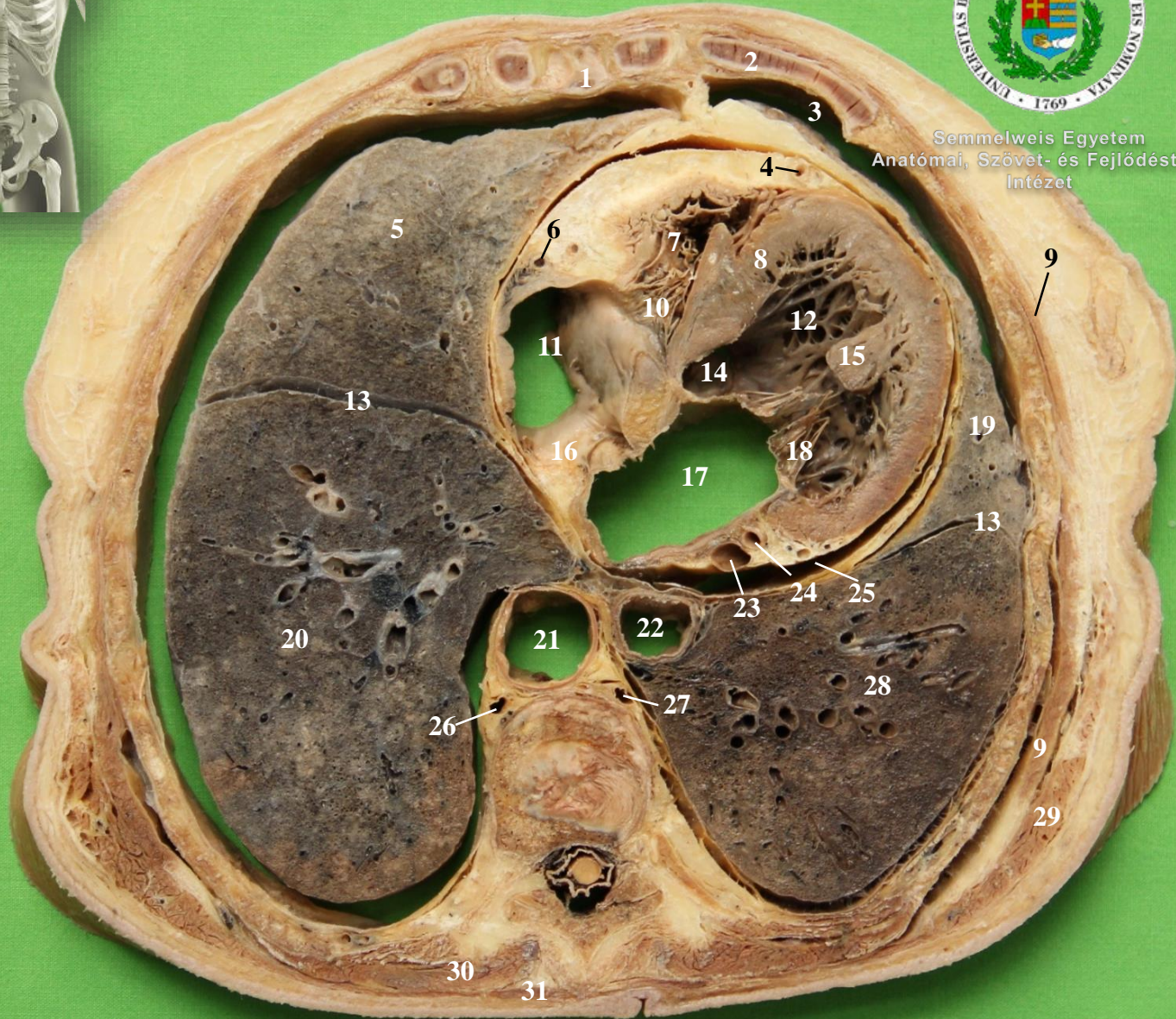

1. sternum
2. costa
3. m. pectoralis major
4. lig. sternopericardiacum
5. mm. intercostales
6. pulmo dexter, lobus medius
7. auricula dextra
8. aorta ascendens
9. ventriculus dexter
10. cavum pleurae
11. -
12. ramus interventricularis anterior
13. mamma
14. ventriculus sinister
15. fissura obliqua
16. bronchus
17. atrium sinister
18. ramus circumflexus
19. pulmo sinister, lobus superior
20. m. serratus anterior
21. -
22. aorta descendens
23. oesophagus
24. bronchus
25. pulmo dexter, lobus inferior
26. v. azygos
27. v. hemiazygos
28. -
29. pulmo sinister, lobus inferior
30. m. latissimus dorsi
31. -
32. spatium epidurale
33. medulla spinalis
34. m. trapezius
35. m. erector spinae

Th8/9

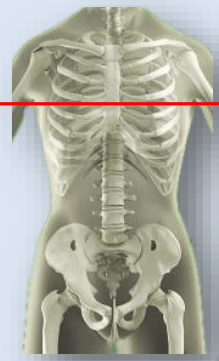

Semmelweis Egyetem
Anatómiai, Szövet- és Fejlődéstani
Intézet

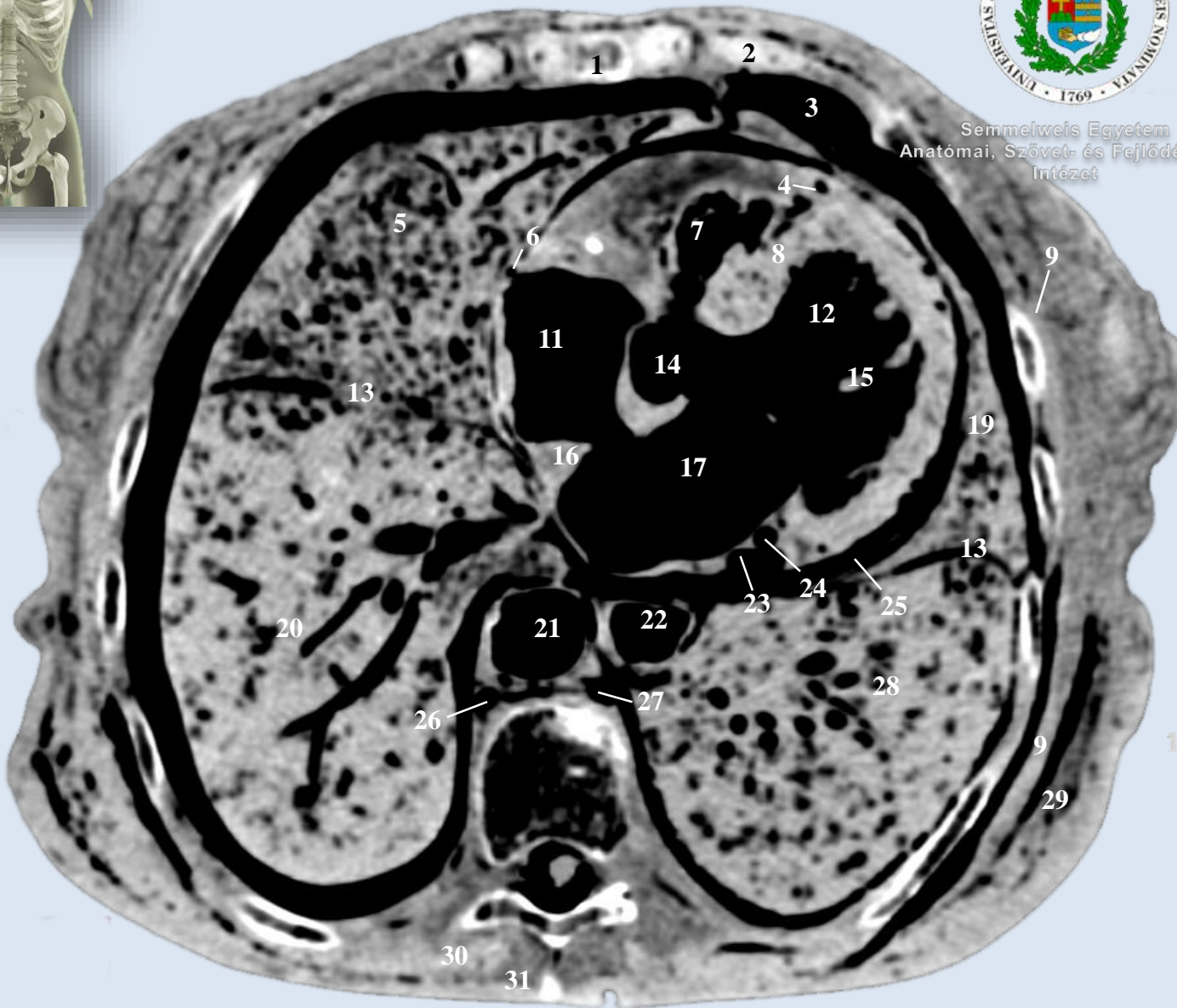


1. sternum
2. costa
3. cavum pleurae
4. a.v. interventricularis anterior
5. pulmo dexter, lobus medius
6. a. coronaria dextra
7. ventriculus dexter
8. septum interventriculare pars muscularis
9. m. serratus anterior
10. valva tricuspidalis, cuspis septalis
11. atrium dextrum
12. ventriculus sinister
13. fissura obliqua
14. ostium aortae
15. m. papillaris anterior
16. septum interatriale
17. atrium sinistrum
18. valva bicuspidalis/mitralis
19. lingula pulmonis
20. pulmo dexter, lobus inferior
21. aorta descendens
22. oesophagus
23. v. cordis magna
24. ramus circumflexus
25. cavum pericardii
26. v. azygos
27. v. hemiazygos
28. pulmo sinister, lobus inferior
29. m. latissimus dorsi
30. m. erector spinae
31. m. trapezius

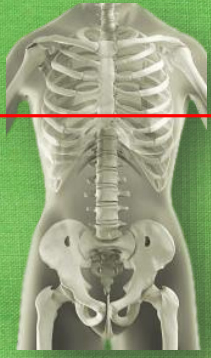
Th8/9



Semmelweis Egyetem
Anatómiai, Szövet- és Fejlődéstani
Intézet



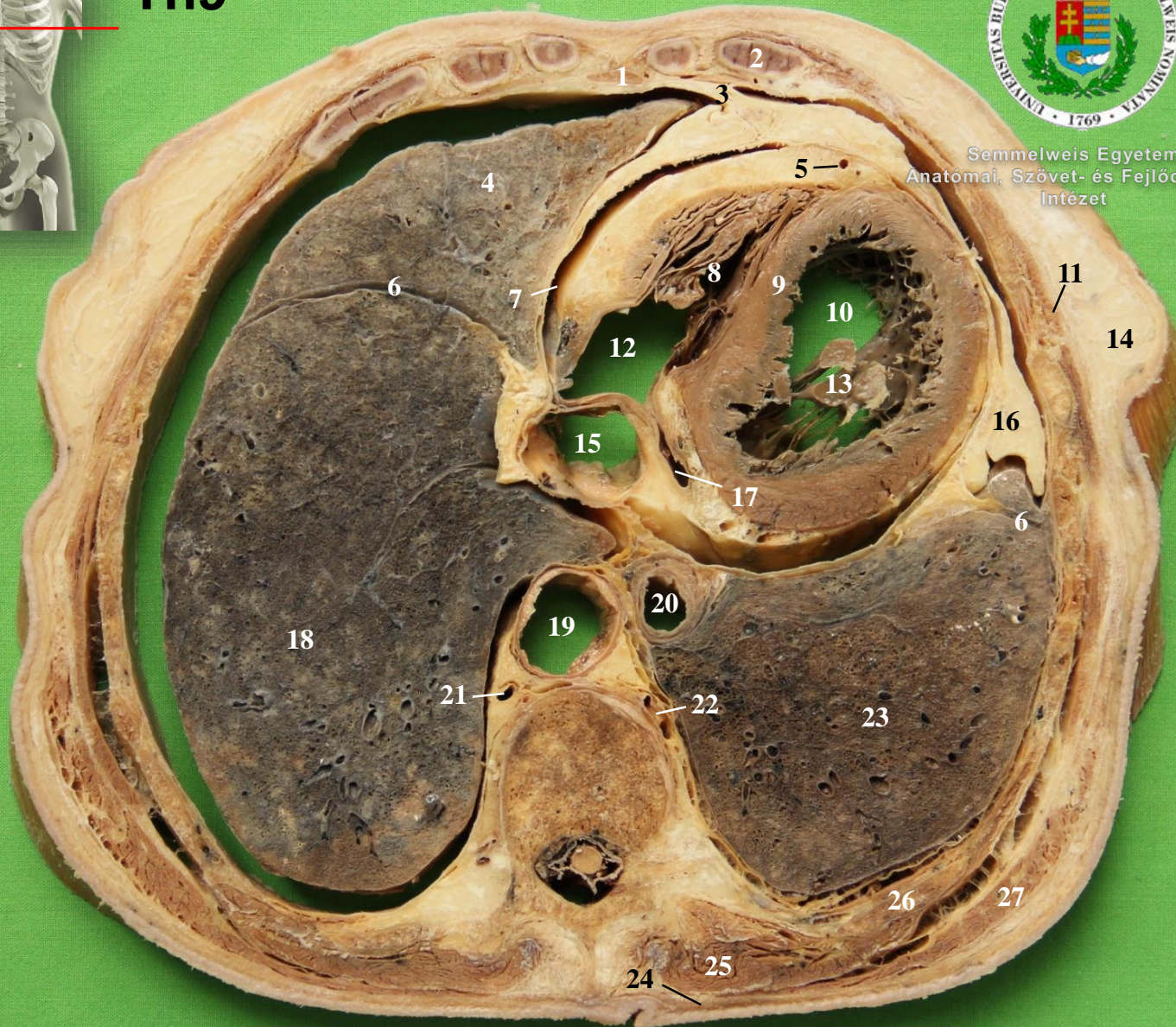1. sternum
2. costa
3. cavum pleurae
4. a.v. interventricularis anterior
5. pulmo dexter, lobus medius
6. a. coronaria dextra
7. ventriculus dexter
8. septum interventriculare pars muscularis
9. m. serratus anterior
10. valva tricuspidalis, cuspis septalis
11. atrium dextrum
12. ventriculus sinister
13. fissura obliqua
14. ostium aortae
15. m. papillaris anterior
16. septum interatriale
17. atrium sinistrum
18. valva bicuspidalis/mitralis
19. lingula pulmonis
20. pulmo dexter, lobus inferior
21. aorta descendens
22. oesophagus
23. v. cordis magna
24. ramus circumflexus
25. cavum pericardii
26. v. azygos
27. v. hemiazygos
28. pulmo sinister, lobus inferior
29. m. latissimus dorsi
30. m. erector spinae
31. m. trapezius



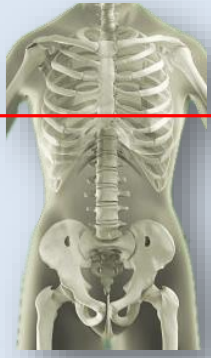
Th9



Semmelweis Egyetem
Anatómiai, Szövet- és Fejlődéstani
Intézet



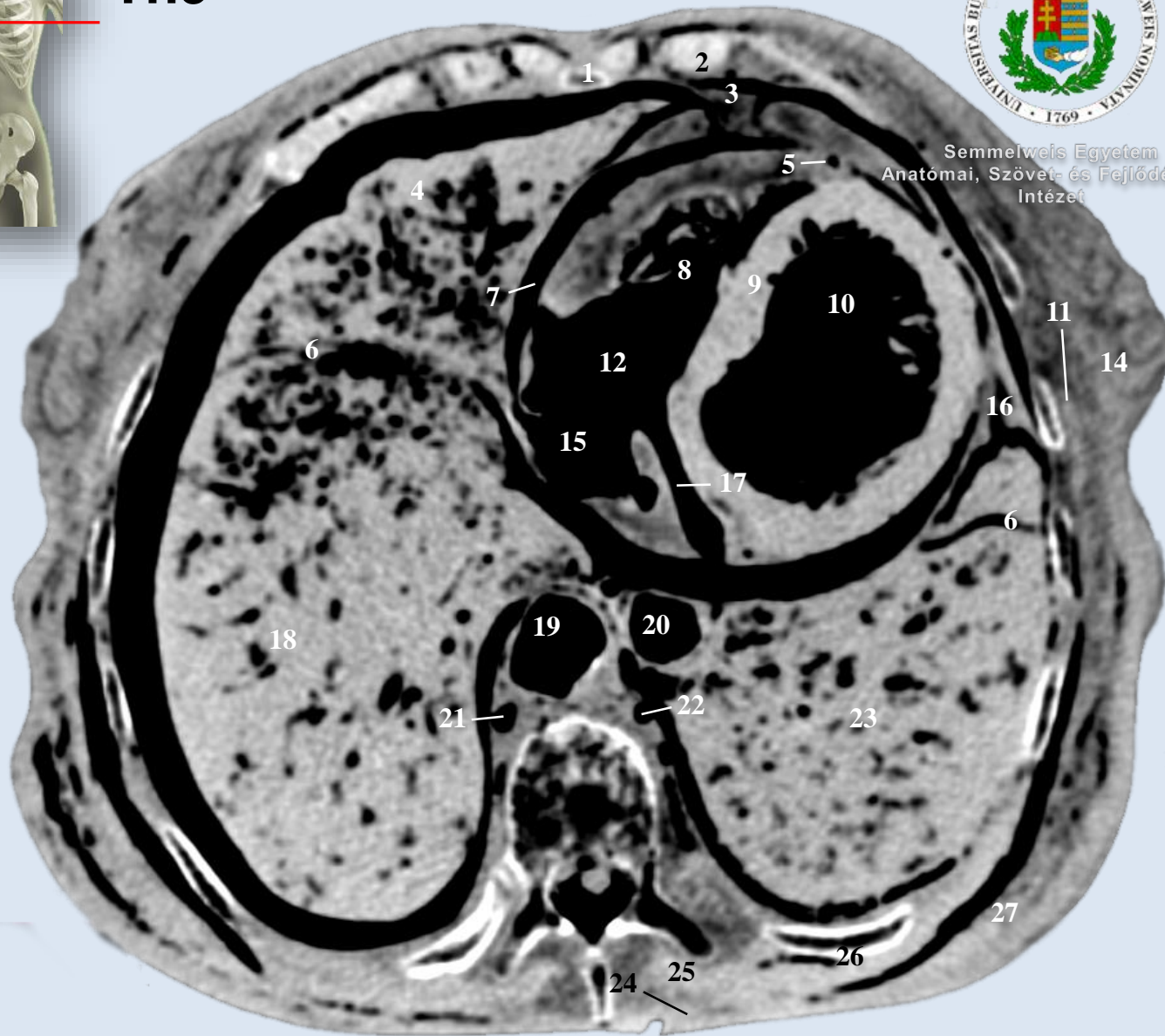
1. sternum
2. costa (porc)
3. lig. sternopericardiacum
4. pulmo dexter, lobus medius
5. a. interventricularis anterior
6. fissura obliqua
7. cavum pericardii
8. ventriculus dexter
9. septum interventriculare pars muscularis
10. ventriculus sinister
11. m. serratus anterior
12. atrium dexter
13. m. papillaris anterior
14. mamma
15. vena cava inferior
16. extrapericardialis zsírszövet
17. sinus coronarius
18. pulmo dexter lobus inferior
19. aorta descendens
20. oesophagus
21. v. azygos
22. v. hemiazygos
23. pulmo sinister, lobus inferior
24. m. trapezius
25. m. erector spinae
26. costa (csont)
27. m. latissimus dorsi



Th9

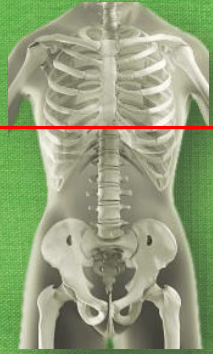


Semmelweis Egyetem
Anatómiai, Szövet- és Fejlődéstani
Intézet

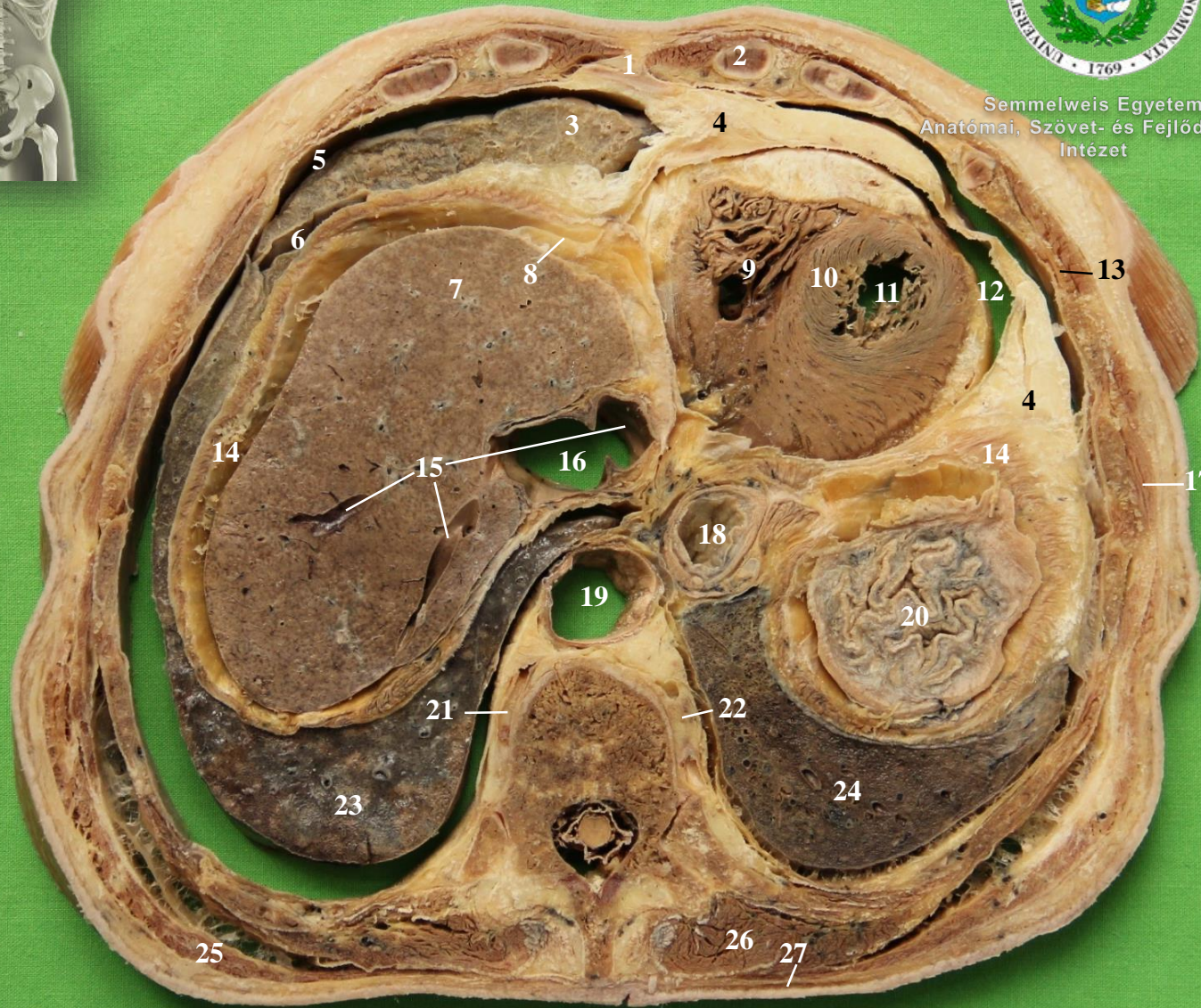


1. sternum
2. costa (porc)
3. lig. sternopericardiacum
4. pulmo dexter, lobus medius
5. a. interventricularis anterior
6. fissura obliqua
7. cavum pericardii
8. ventriculus dexter
9. septum interventriculare pars muscularis
10. ventriculus sinister
11. m. serratus anterior
12. atrium dexter
13. -
14. mamma
15. vena cava inferior
16. extrapericardialis zsírszövet
17. sinus coronarius
18. pulmo dexter lobus inferior
19. aorta descendens
20. oesophagus
21. v. azygos
22. v. hemiazygos
23. pulmo sinister, lobus inferior
24. m. trapezius
25. m. erector spinae
26. costa (csont)
27. m. latissimus dorsi

Th10

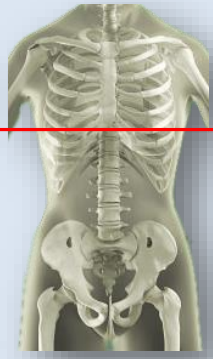


Semmelweis Egyetem
Anatómiai, Szövet- és Fejlődéstan
Intézet

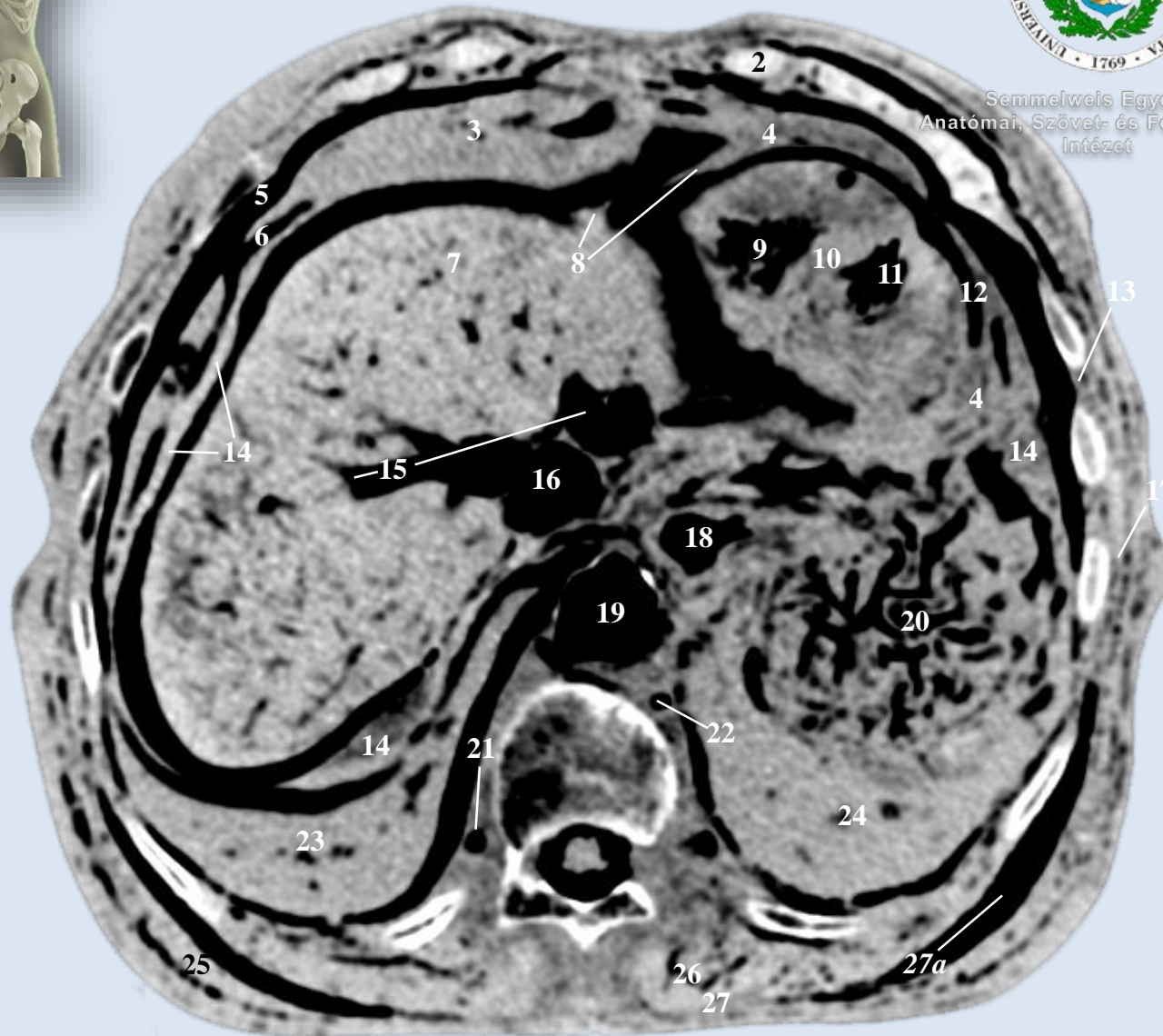


1. processus xiphoideus
2. costa (porc)
3. pulmo dexter, lobus medius
4. extrapericardialis zsírszövet
5. cavum pleurae
6. fissura obliqua
7. hepar
8. lig. falciforme hepatis
9. ventriculus dexter
10. septum interventriculare pars muscularis
11. ventriculus sinister
12. cavum pericardii
13. mm. intercostales
14. diaphragma
15. vv. hepaticae
16. vena cava inferior
17. m. serratus anterior
18. oesophagus-cardia átmenet
19. aorta descendens
20. gaster
21. v. azygosba ömlő v. intercostalis
22. v. hemiazygosba ömlő v. intercostalis
23. pulmo dexter, lobus inferior
24. pulmo sinister, lobus inferior
25. m. latissimus dorsi
26. m. erector spinae
27. m. trapezius

Th10



Semmelweis Egyetem
Anatómiai, Szövet- és Fejlődéstani
Intézet



1. -
2. costa (porc)
3. pulmo dexter, lobus medius
4. extrapericardialis zsírszövet
5. cavum pleurae
6. fissura obliqua
7. hepar
8. lig. falciforme hepatis
9. ventriculus dexter
10. septum interventriculare
pars muscularis
11. ventriculus sinister
12. cavum pericardii
13. mm. intercostales
14. diaphragma
15. vv. hepaticae
16. vena cava inferior
17. m. serratus anterior
18. oesophagus-cardia átmenet
19. aorta descendens
20. gaster
21. v. intercostalis
22. v. hemiazygos
23. pulmo dexter, lobus inferior
24. pulmo sinister, lobus inferior
25. m. latissimus dorsi
26. m. erector spinae
27. m. trapezius
- 27a. műtermék