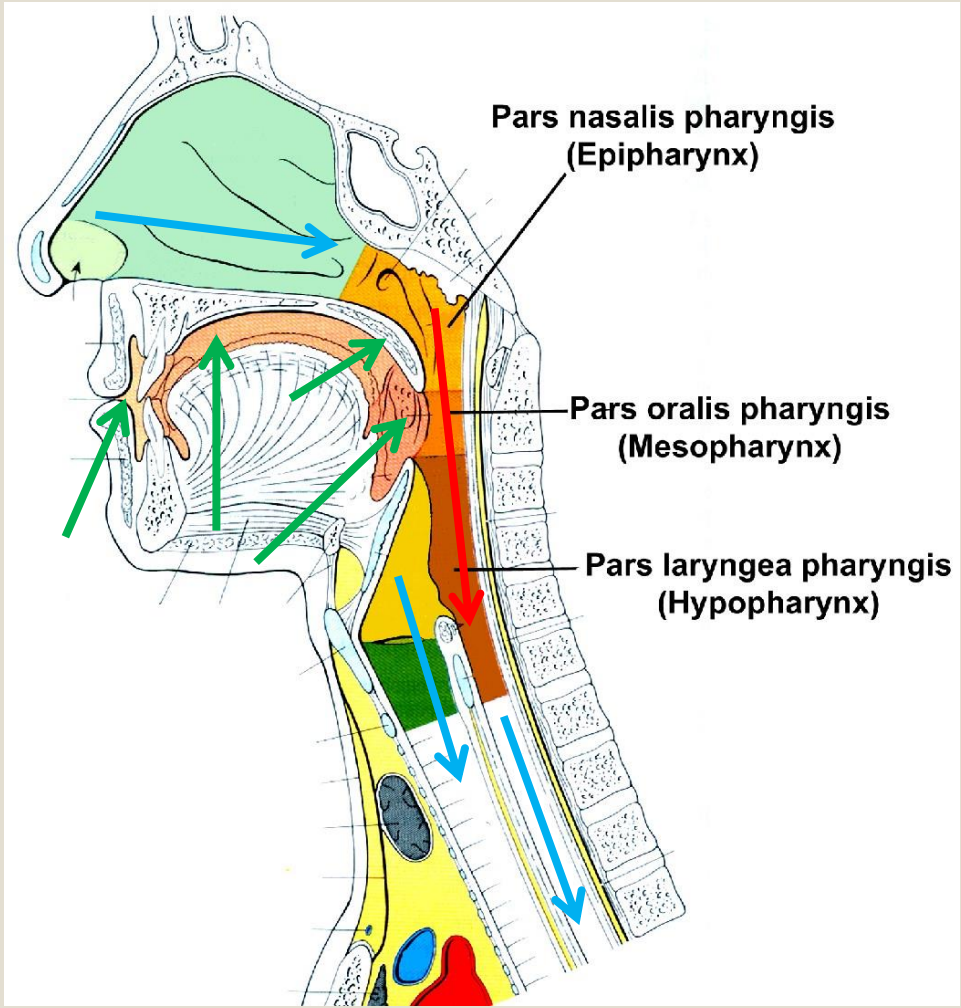


Pharynx and pharyngeal spaces.

János Hanics M.D.

Previous – Present – Next lectures

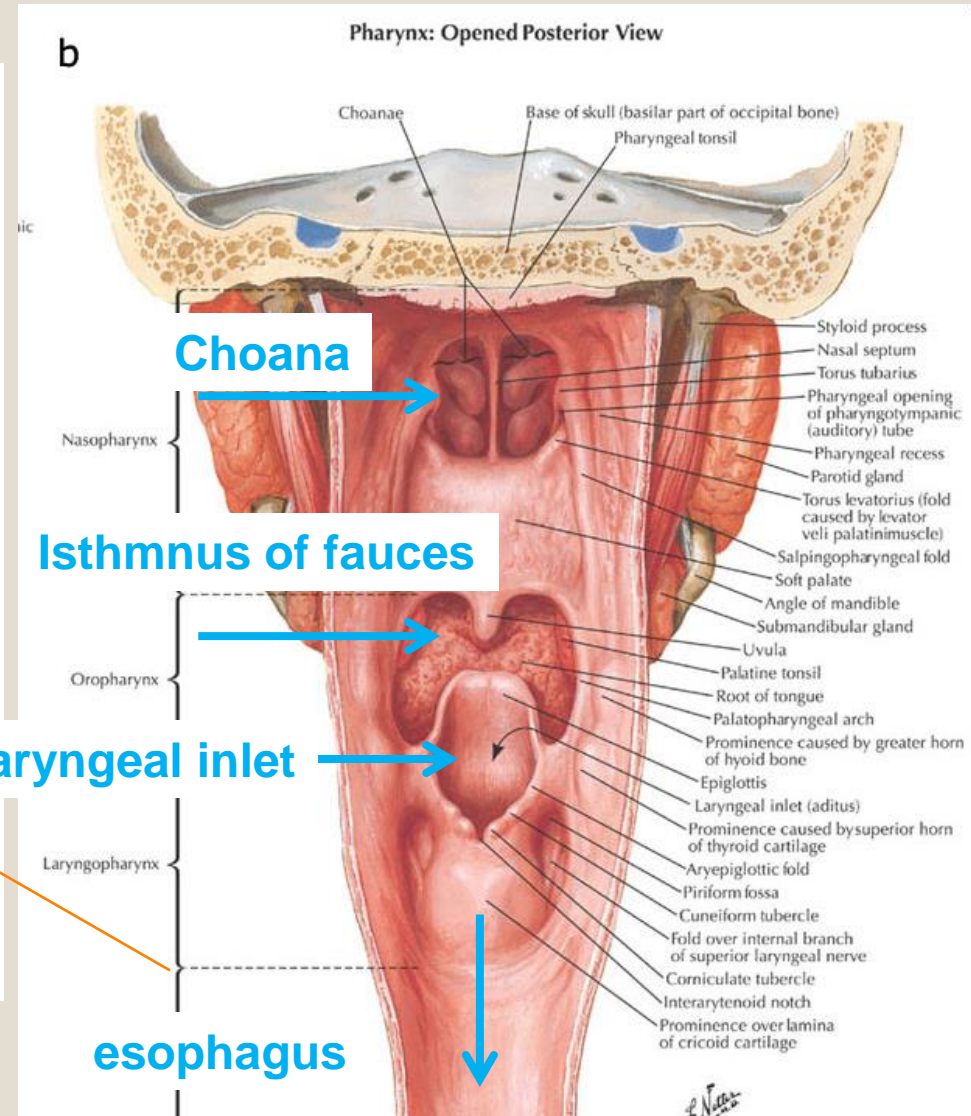
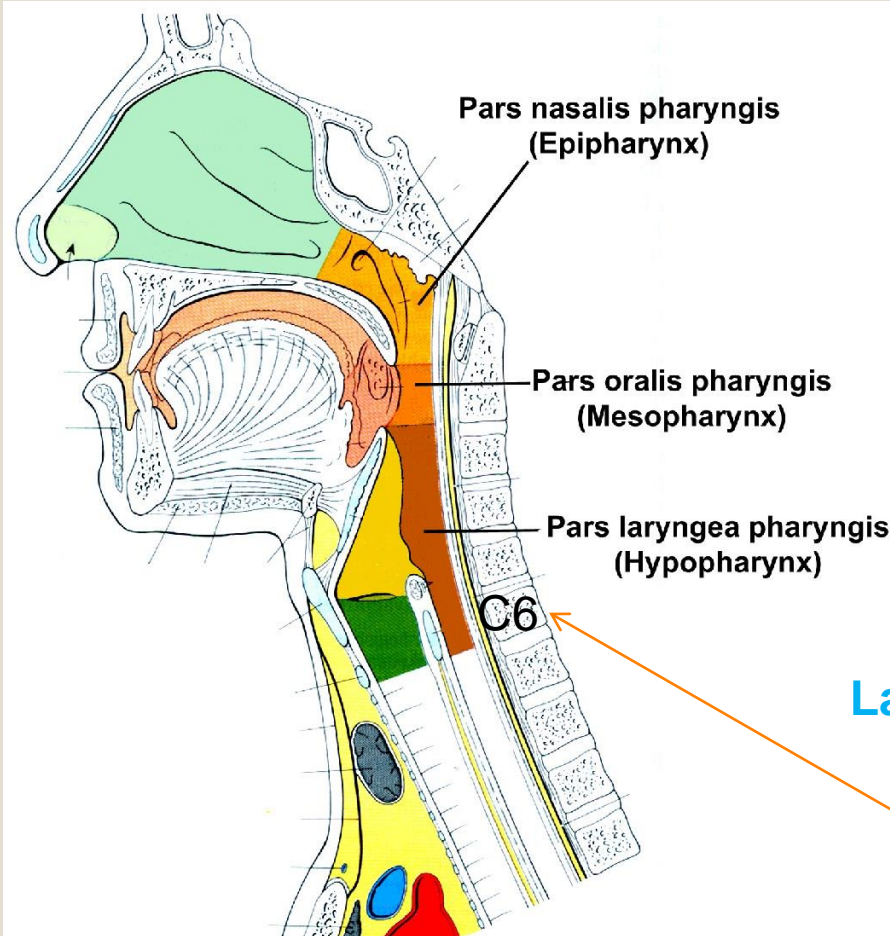


- Oral cavity:
 - Vestibulum oris
 - Cavum oris proprium
 - Soft palate (velum palatinum)
 - Isthmus of fauces
- Pharynx
- Nasal cavity
- Larynx
- Esophagus

Pharynx

3 openings represent the anterior wall of pharynx and it is continuous with the esophagus

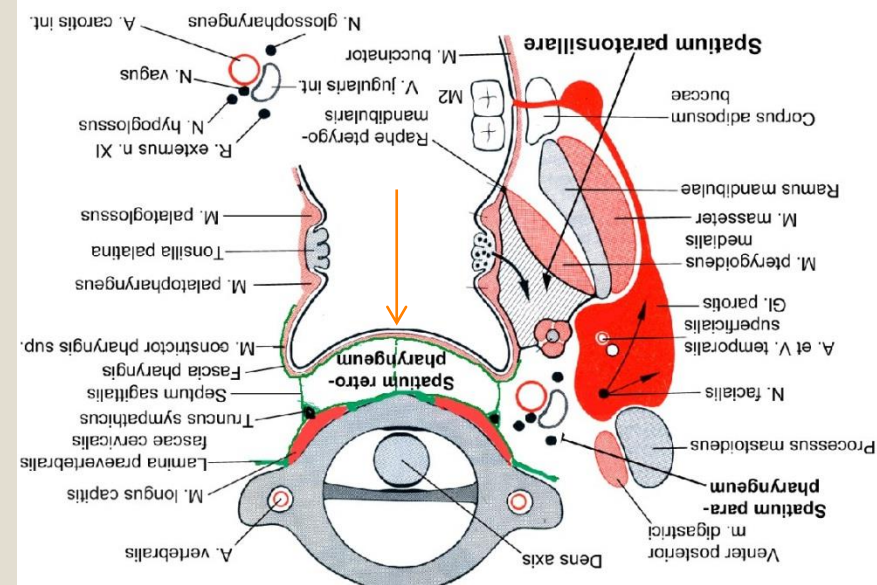
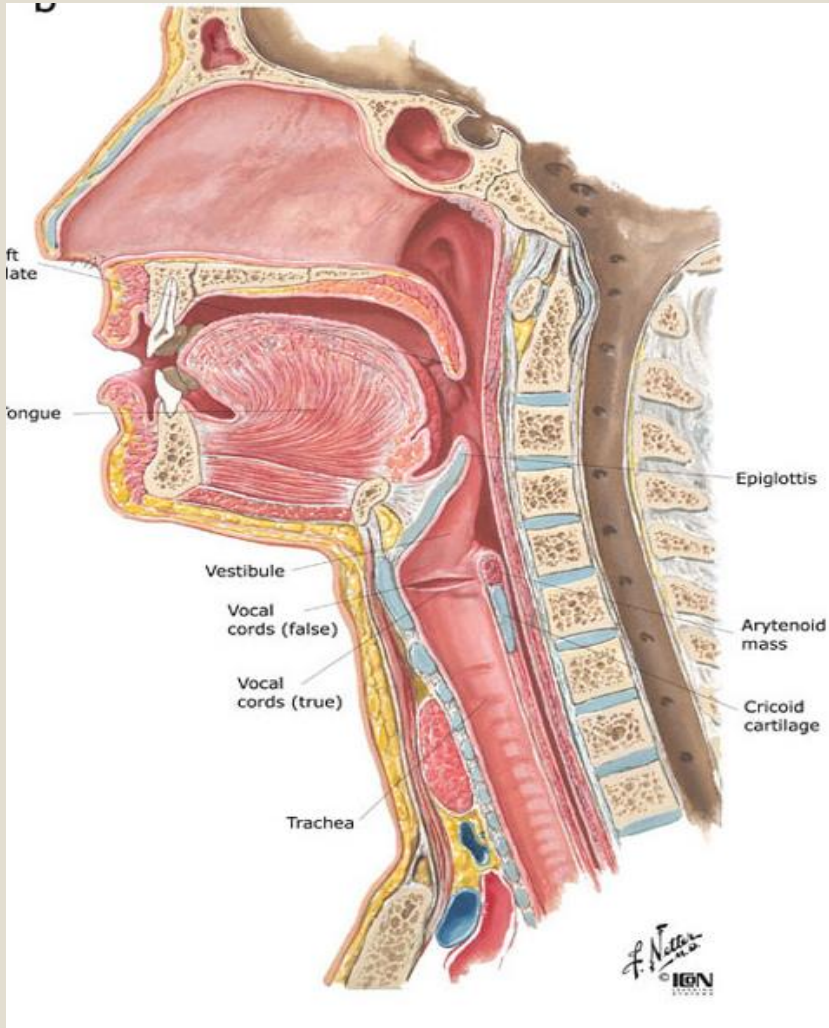
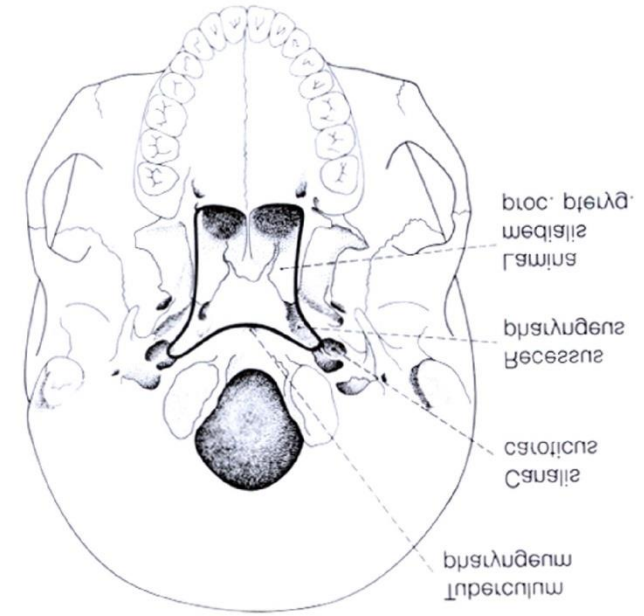
It has 3 level:



Pharynx

- 1) Tunica mucosa
- 2) Tunica fibrosa
- 3) Tunica muscularis (striated muscles)
- 4) Tunica adventitia

Origin on the base of the skull:



Muscles of the pharynx

**Constrictor muscles of the pharynx
(3 groups)**

Levator muscles of the pharynx

Raphe pharyngis

Constrictor muscles of the pharynx

M. constrictor pharyngis superior:

1. pars pterygopalatina,
2. pars buccopharyngea,
3. pars mylopharyngea,
4. pars glossopharyngea;

n. IX

M. constrictor pharyngis medius:

1. pars chondropharyngea,
2. pars ceratopharyngea;

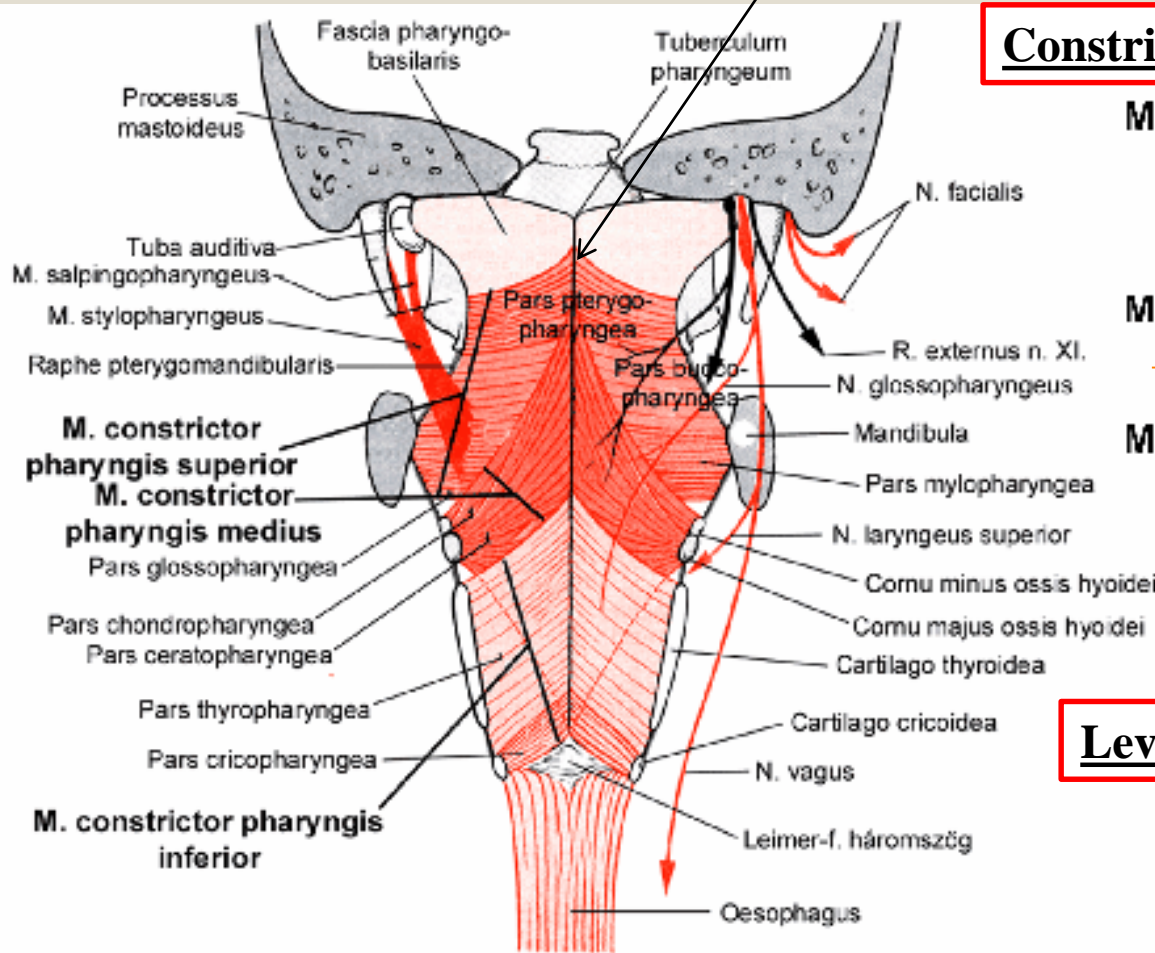
M. constrictor pharyngis inferior:

1. pars thyropharyngea,
2. pars cricopharyngea.

n. X

Levator muscles of the pharynx

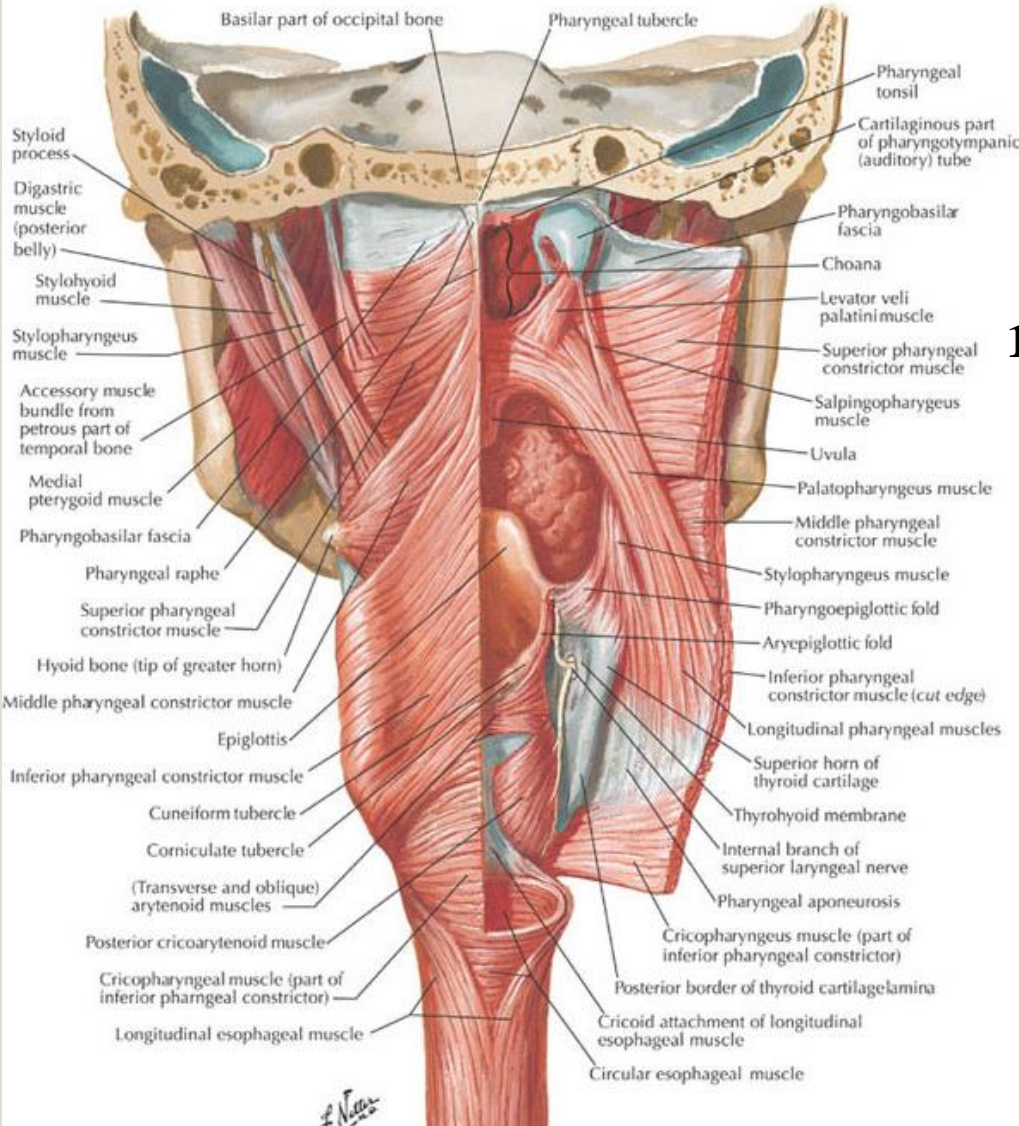
1. M. stylopharyngeus,
2. M. salpingopharyngeus,
3. M. palatopharyngeus



Levator muscles of the pharynx

a

Muscles of Pharynx: Partially Opened Posterior View

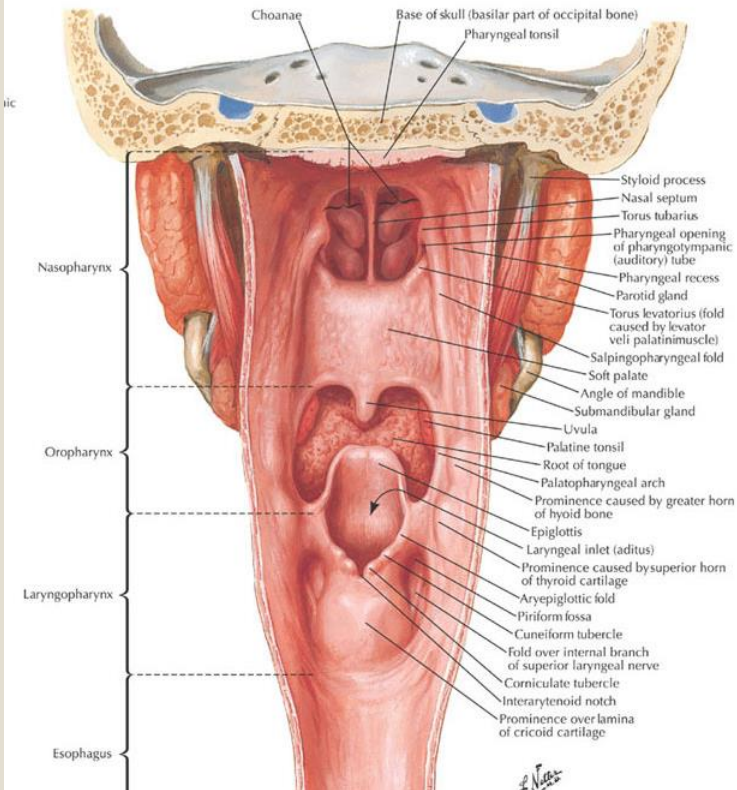


Stylopharyngeus m. – Styloid proc. (temporal bone)

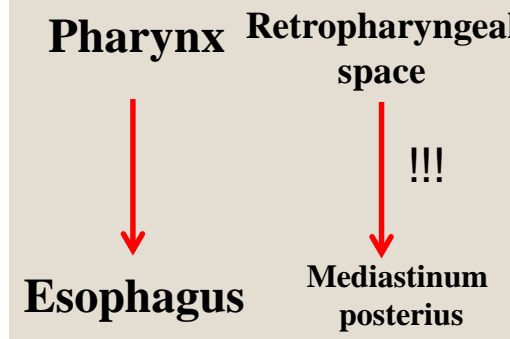
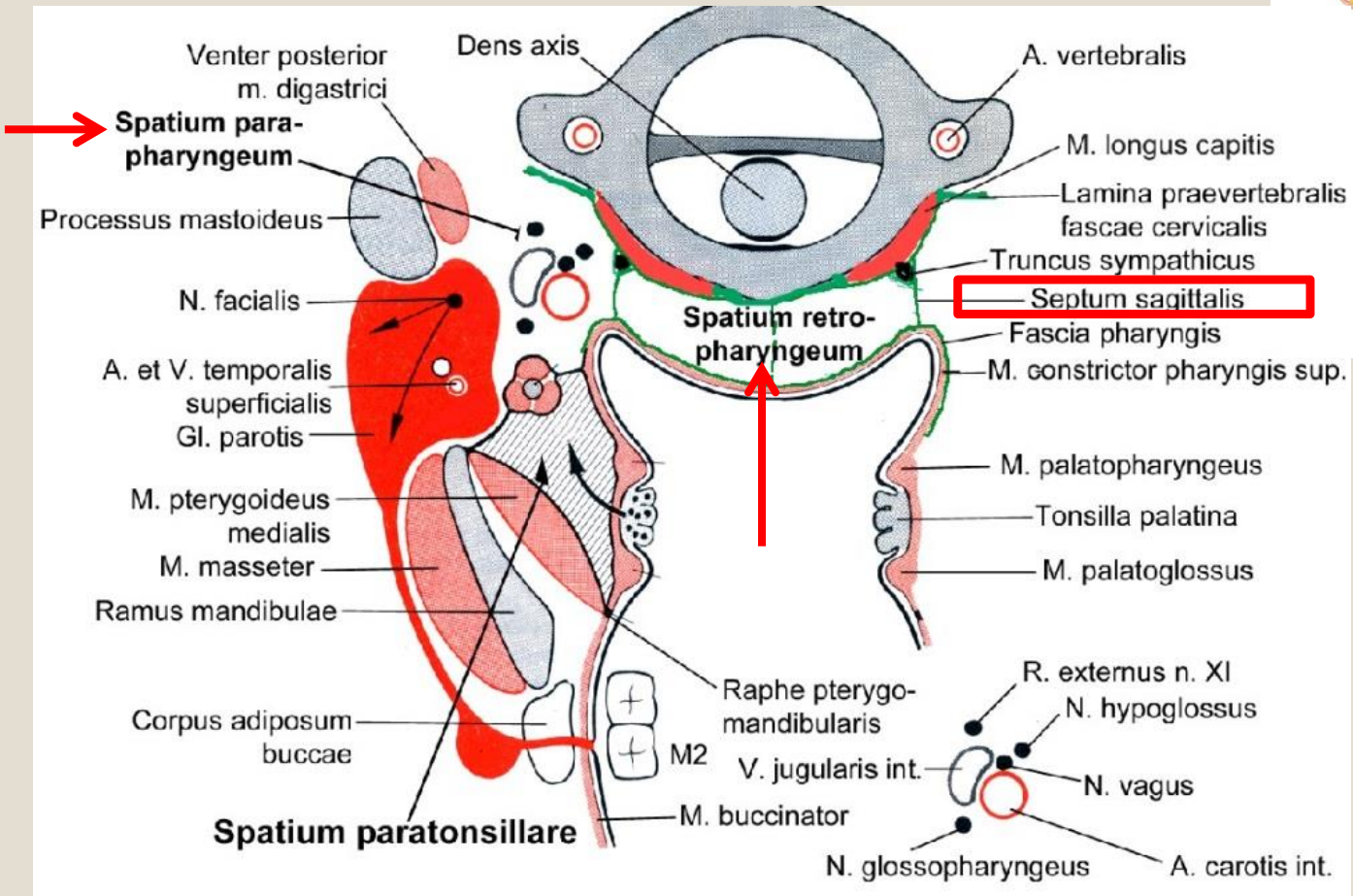
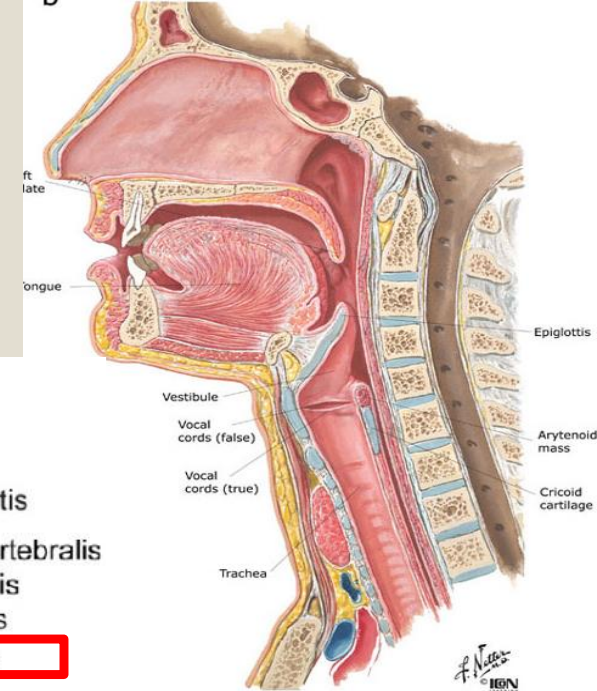
Salpingopharyngeus m. – cartilaginous part of the auditive tube and medial lamina of the pterygoid proc.

Palatopharyngeus m. – soft palate

1 external + 2 internal (fold) ew



→ Pharyngeal spaces (spatium)



Arteries of the head and neck

Vertebral aa.

ICA – intracranial division

ECA:

Au – post. auricular a.

Oc – occipital a.

StyM – stylomastoid a.

Te – temporal superfic. a.

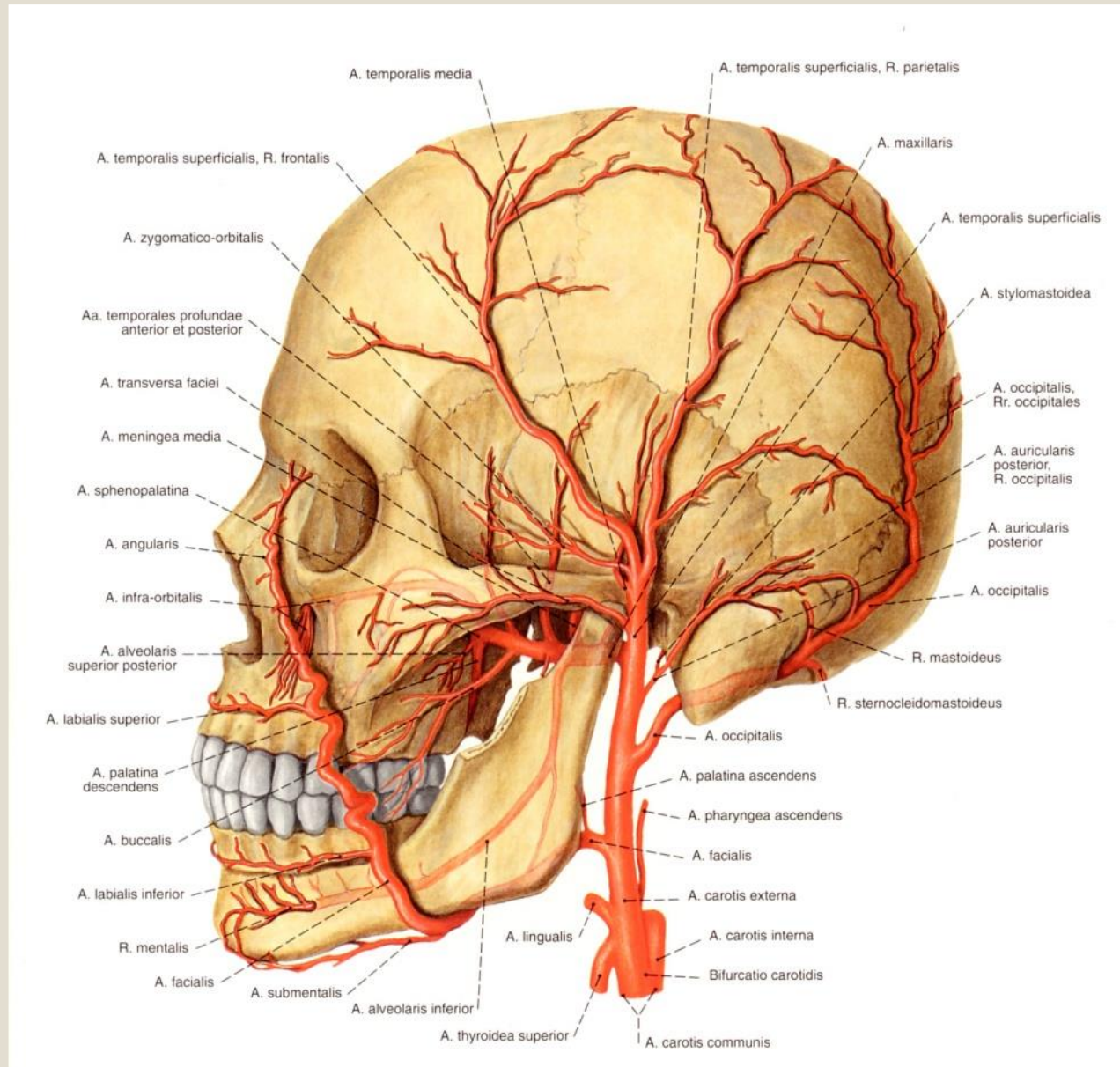
Ma – maxillary a.

Fa – facial a.

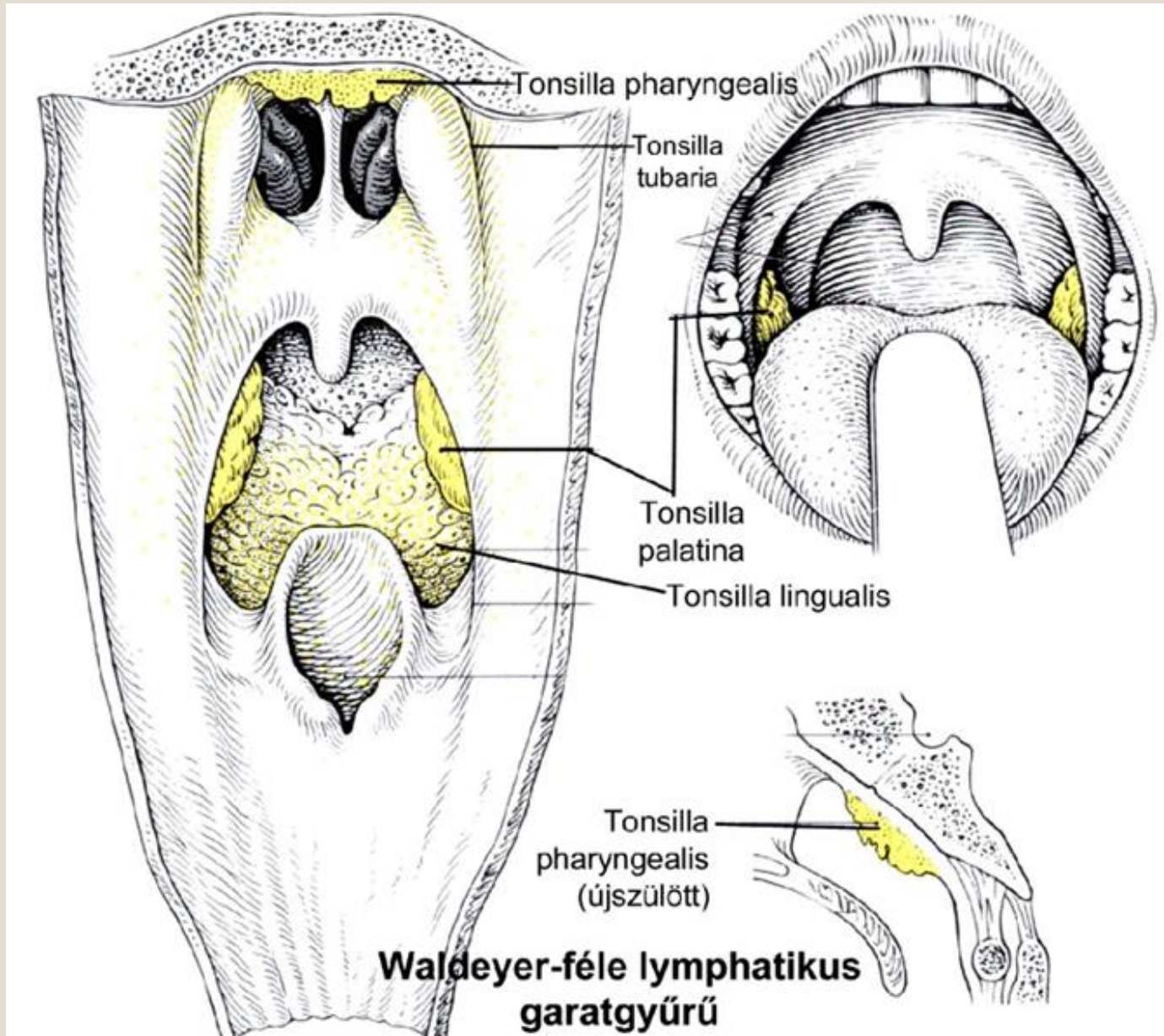
Pha – asc. pharyngeal a.

Ly – lingual a.

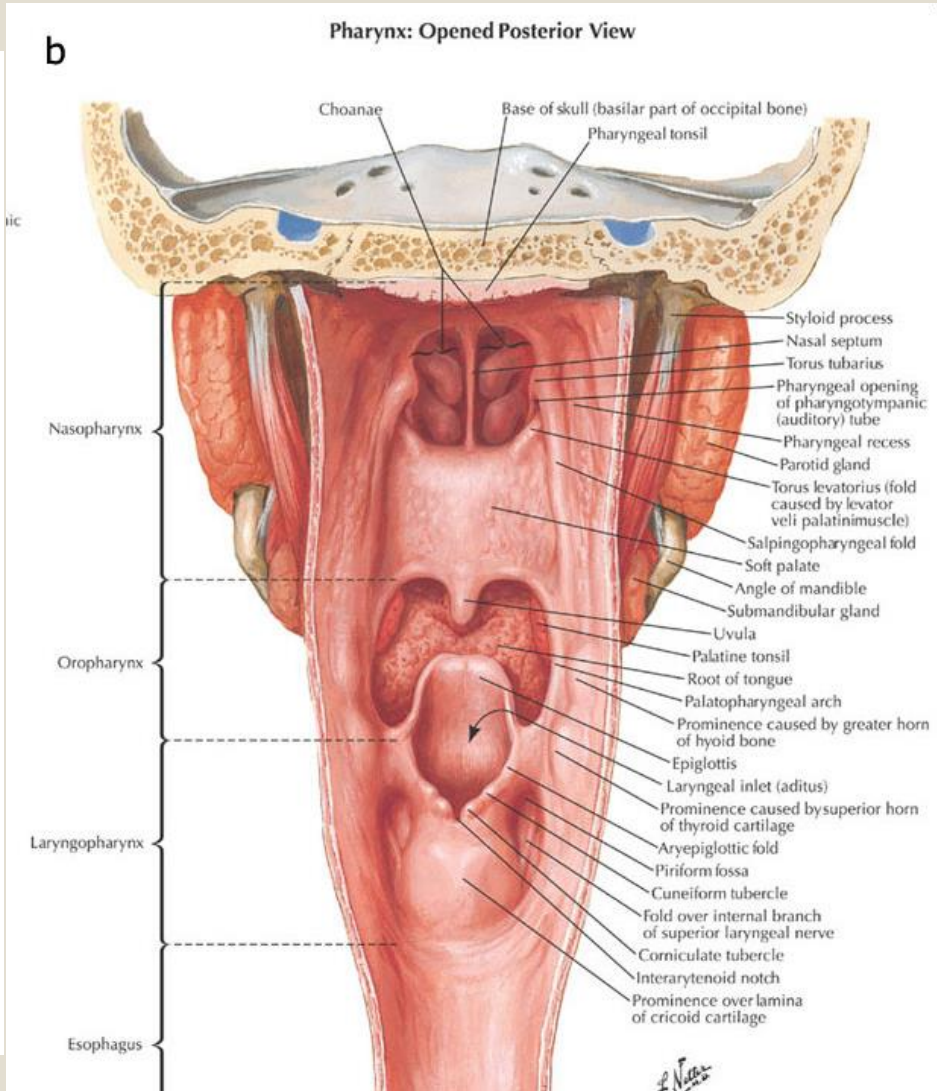
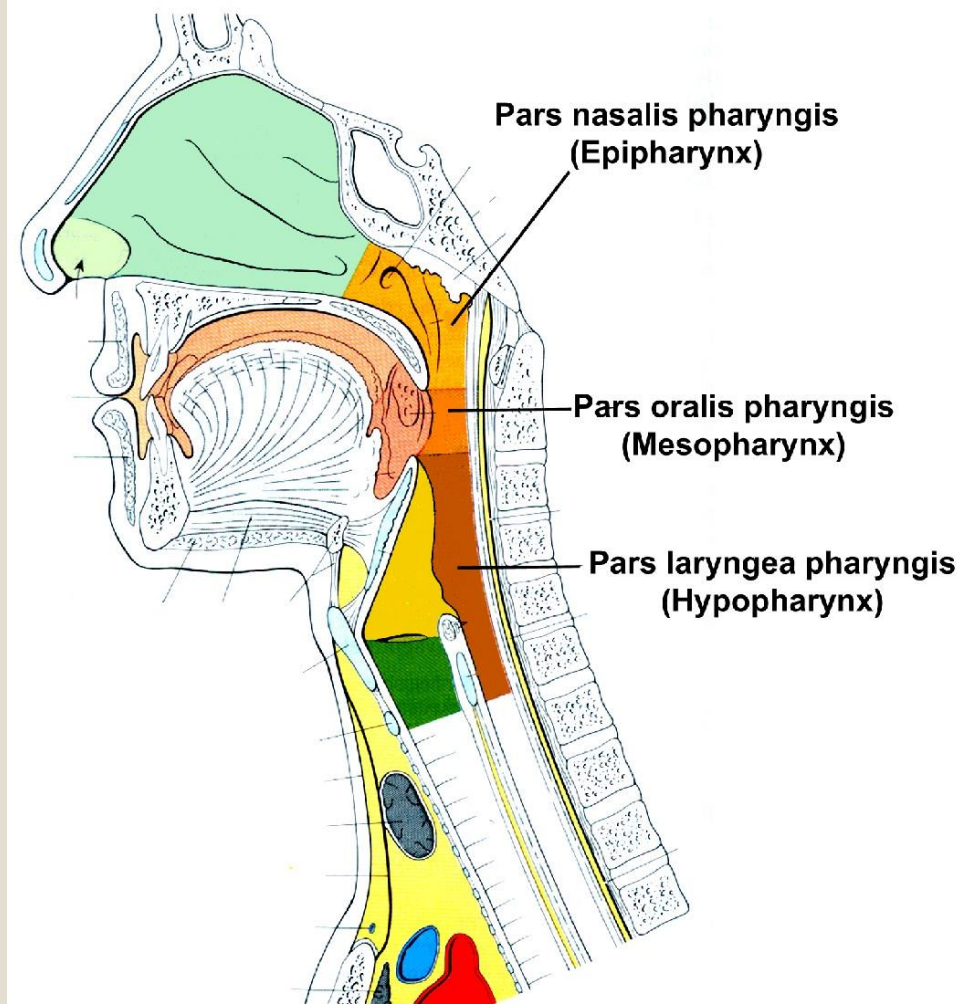
Thy – sup. thyroid a.



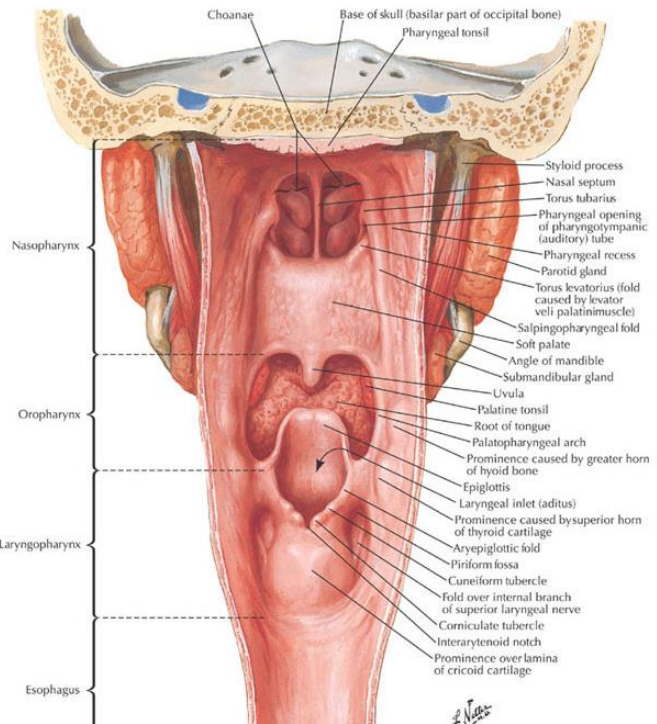
Cavity of the pharynx – Lymphatic ring of Waldeyer



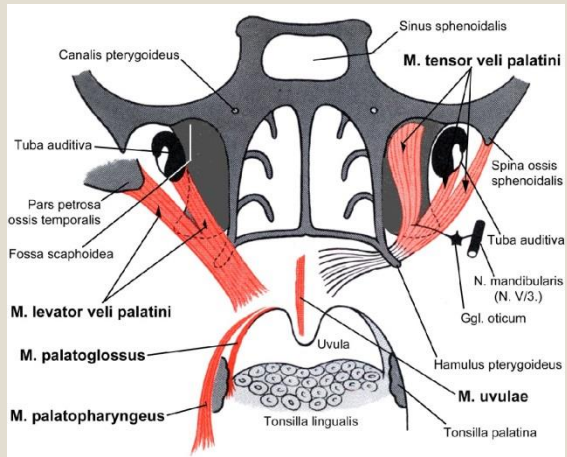
Cavity of the pharynx



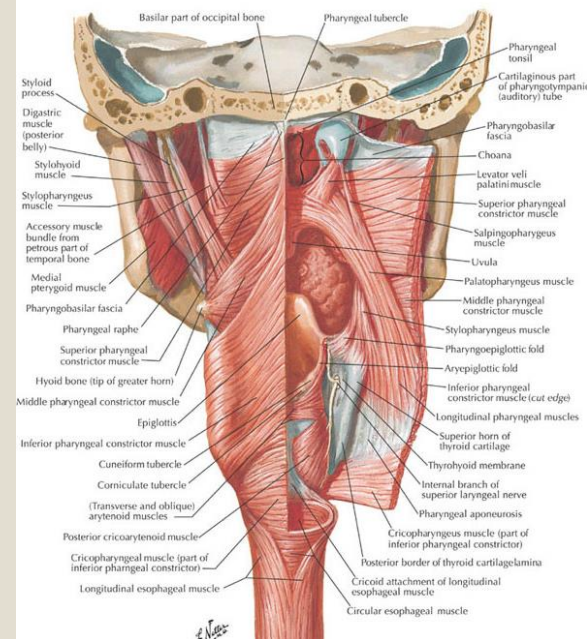
b Pharynx: Opened Posterior View



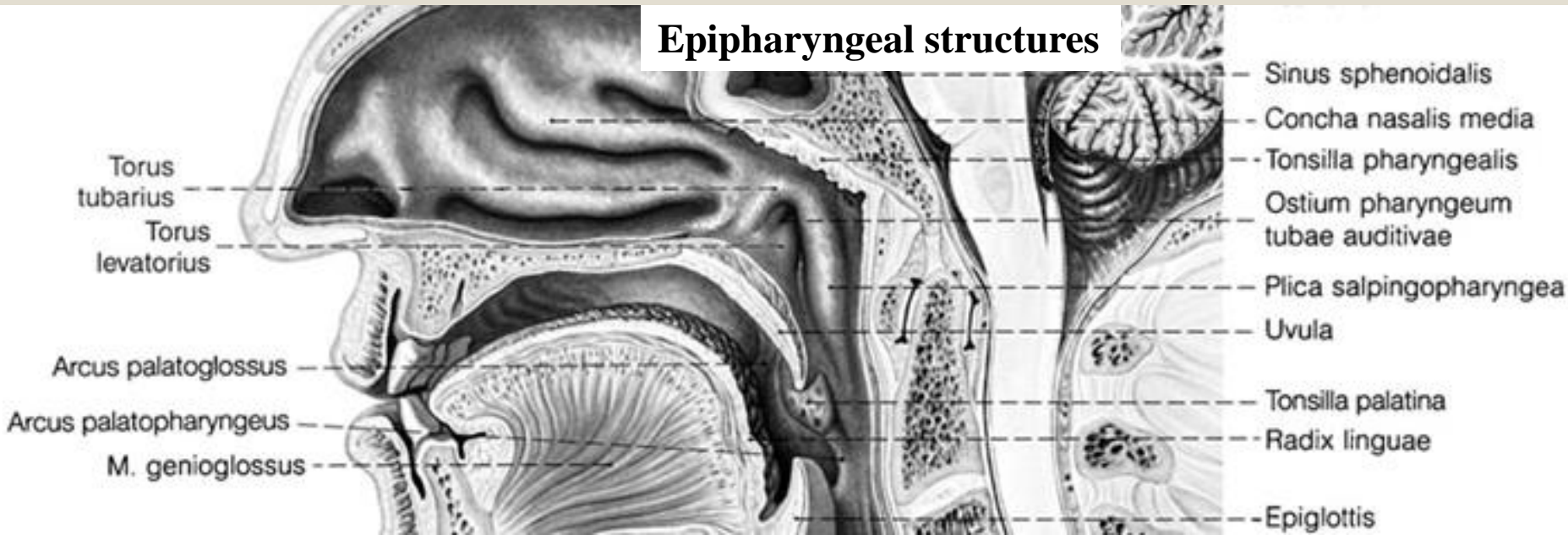
Cavity of the pharynx - epipharynx



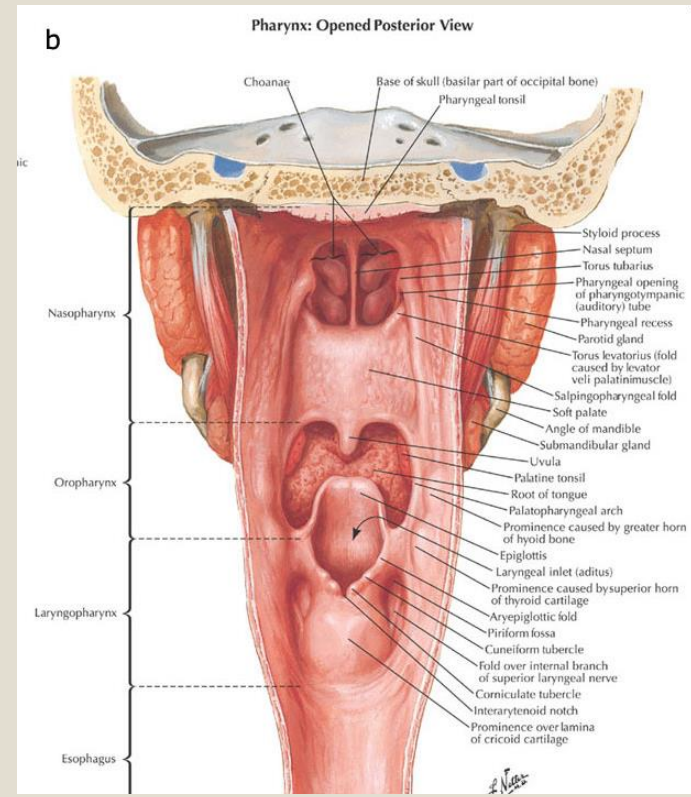
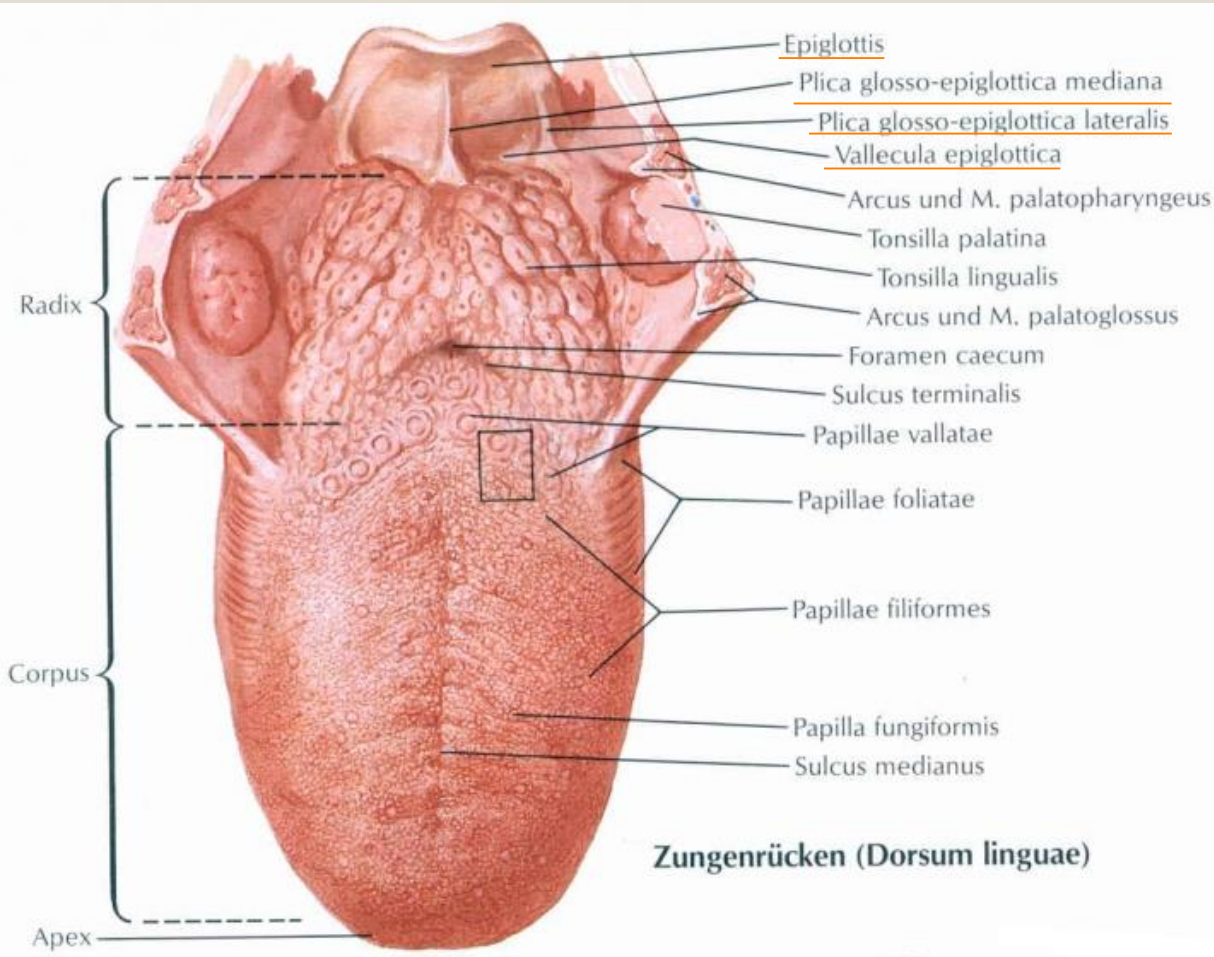
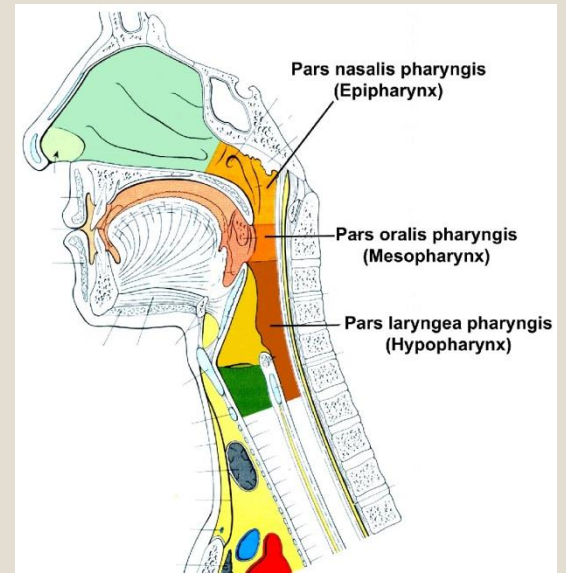
a Muscles of Pharynx: Partially Opened Posterior View



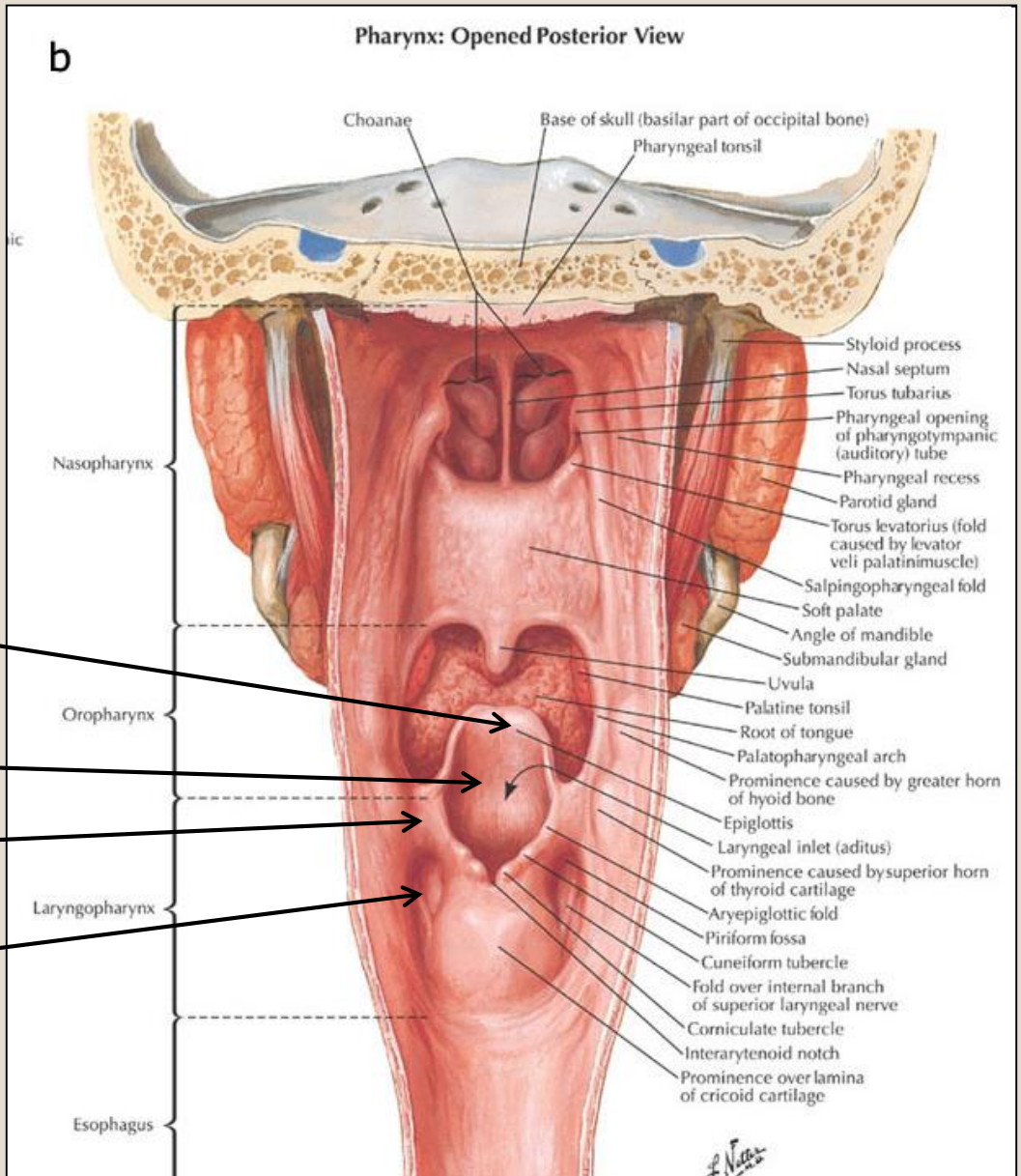
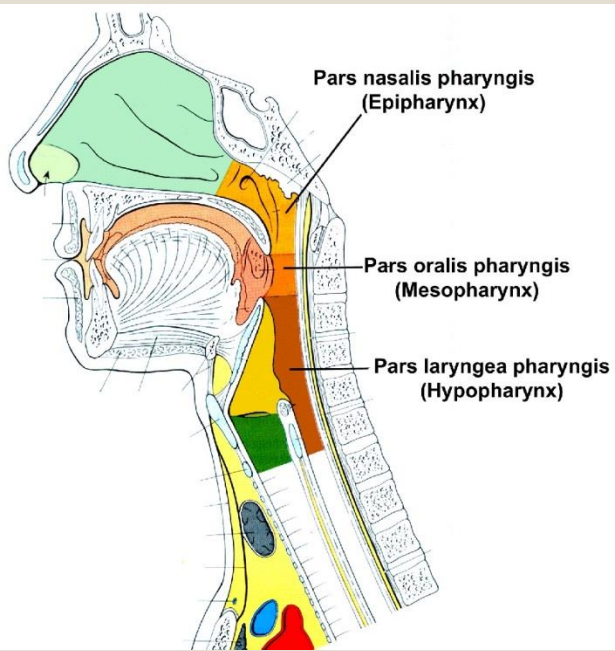
Epipharyngeal structures



Cavity of the pharynx - mesopharynx



Cavity of the pharynx - hypopharynx



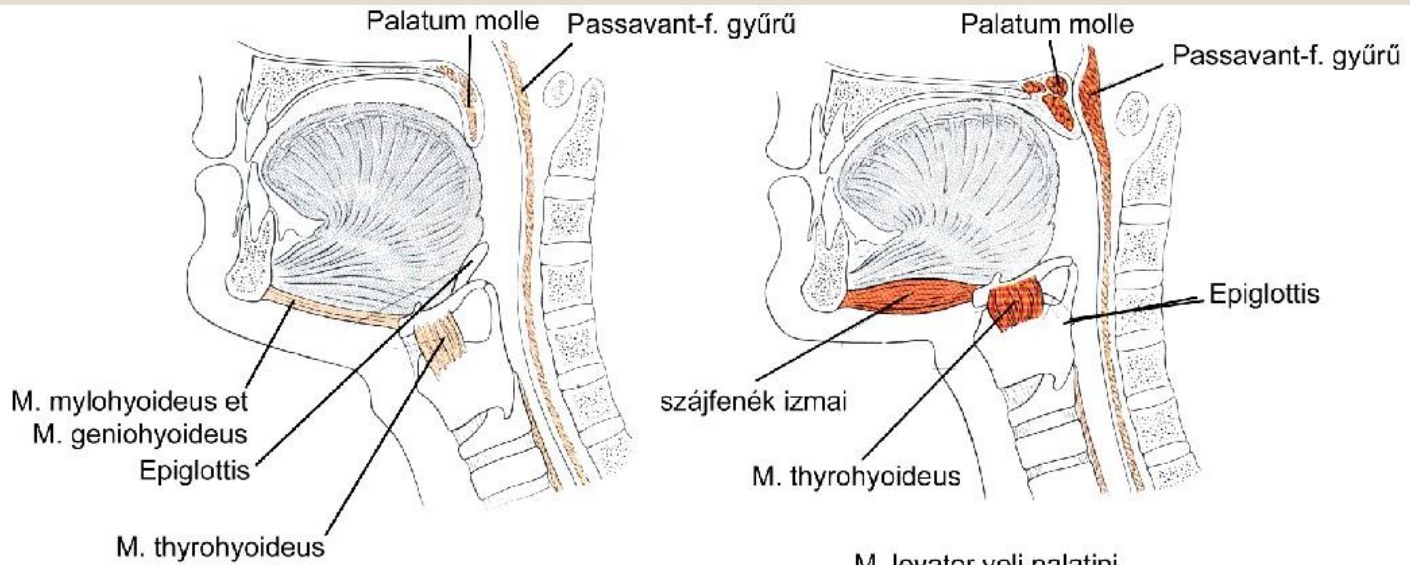
Epiglottis

Aditus laryngis

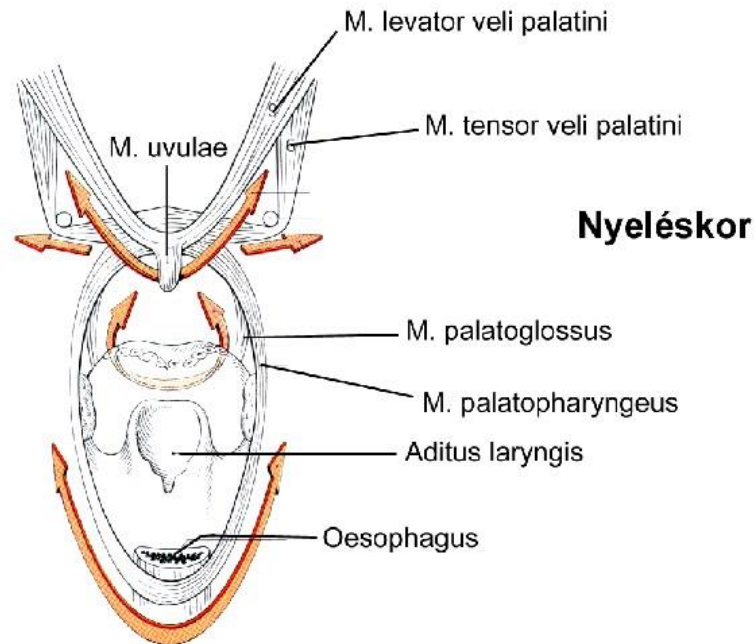
Aryepiglottic fold

Piriform recess

The process of swallowing



Légzéskor



Nyeléskor

Thank you for your kind attention!!!

