

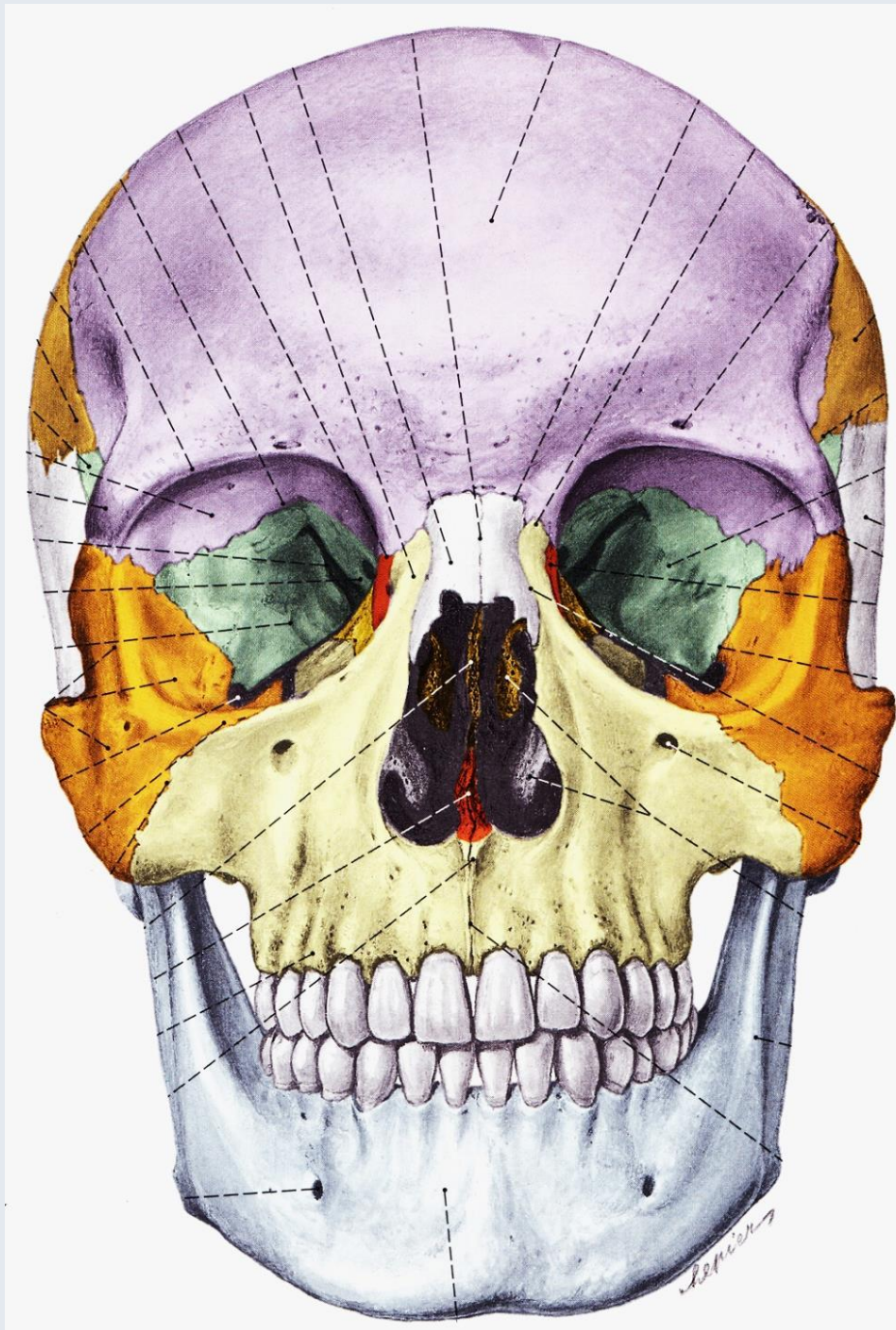
Maxillofaziale Aspekte von



Dr. Dávid Lendvai

Anatomisches, Histologisches- und Embryologisches Institut

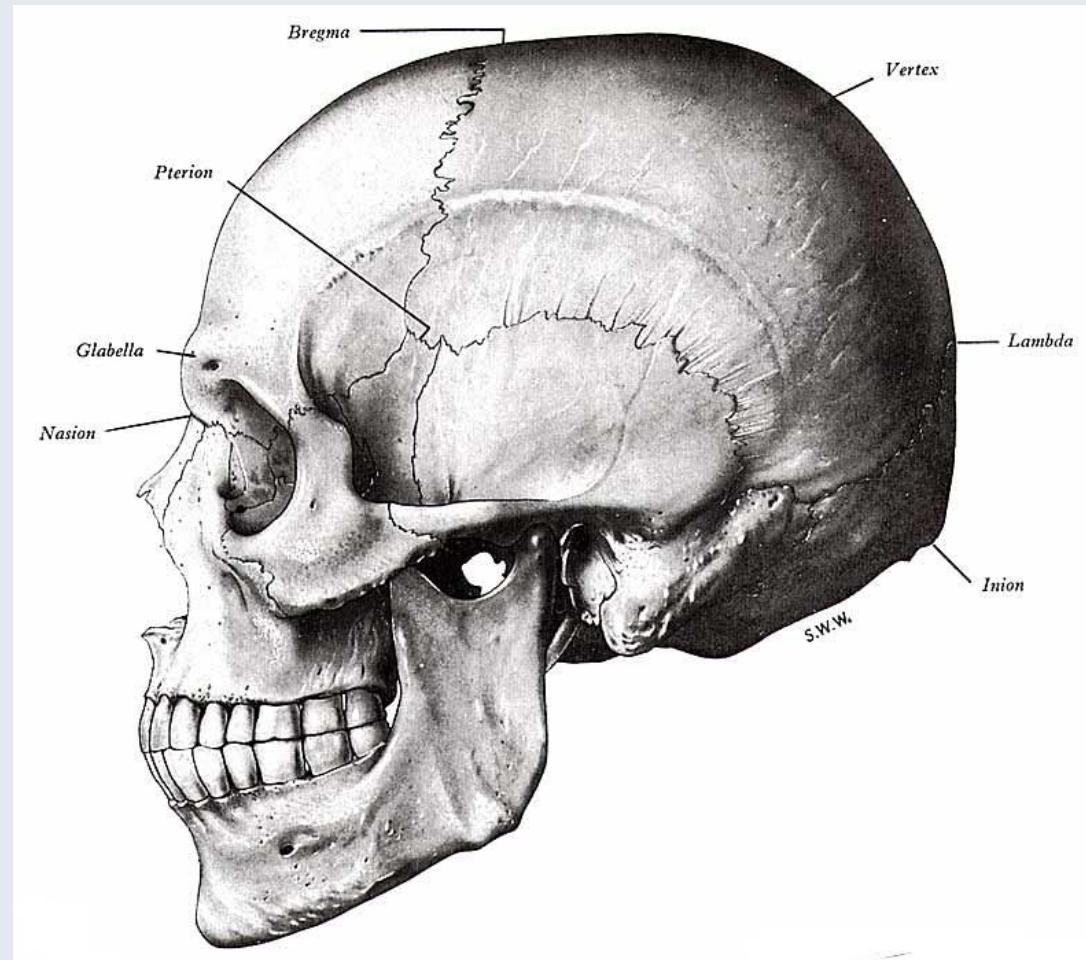
2019.



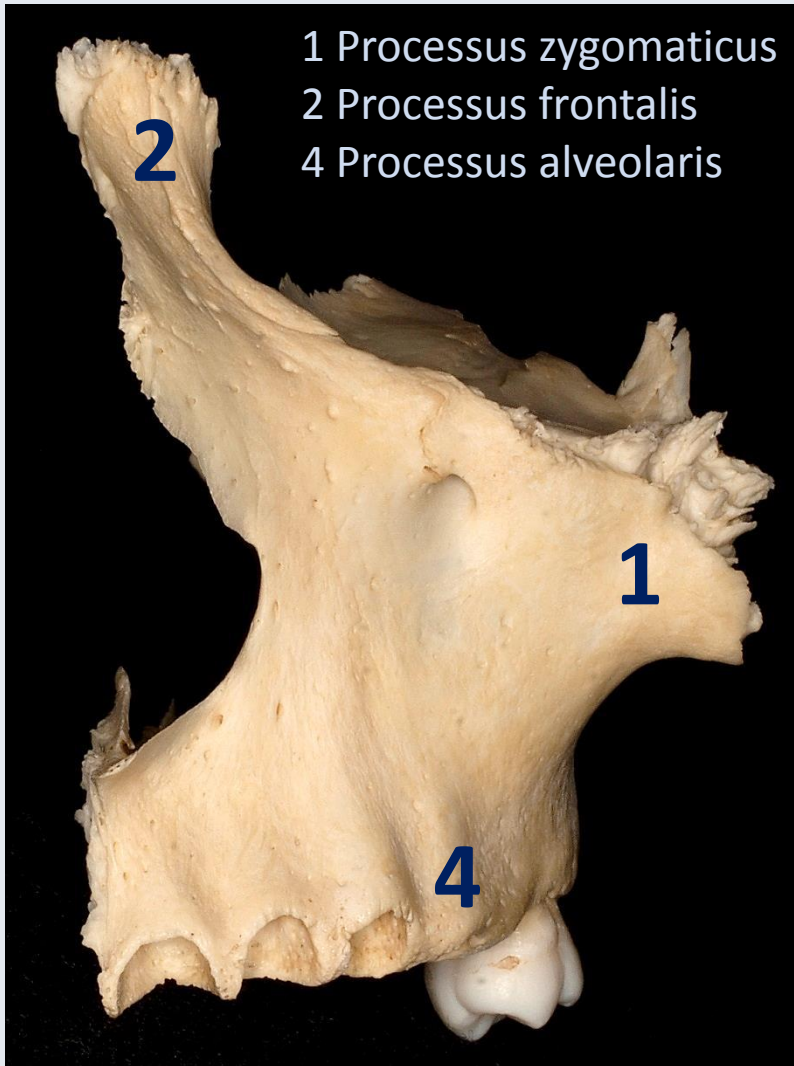
Cranium cerebrale

1. calvaria
2. Skull base:
 - Basis cranii int.
 - Basis cranii ext.

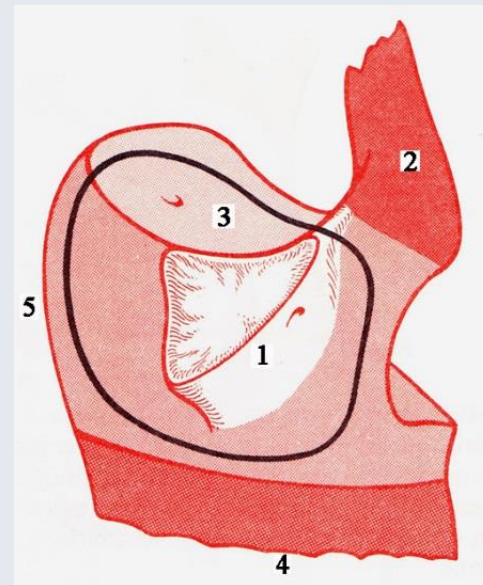
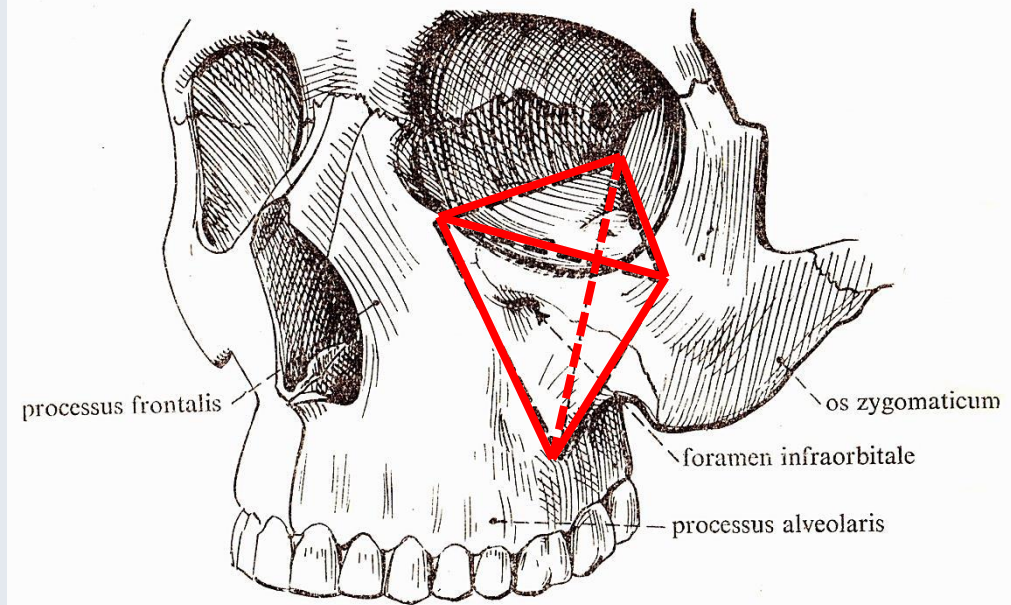
Protub. occip. ext. → linea nuchae sup. → beginning of the linea temp. → zygomatic arch → infratemp. crest → ala major → zygomatic process → supraorbital margin → nasofrontalis suture



Aspectus anterior



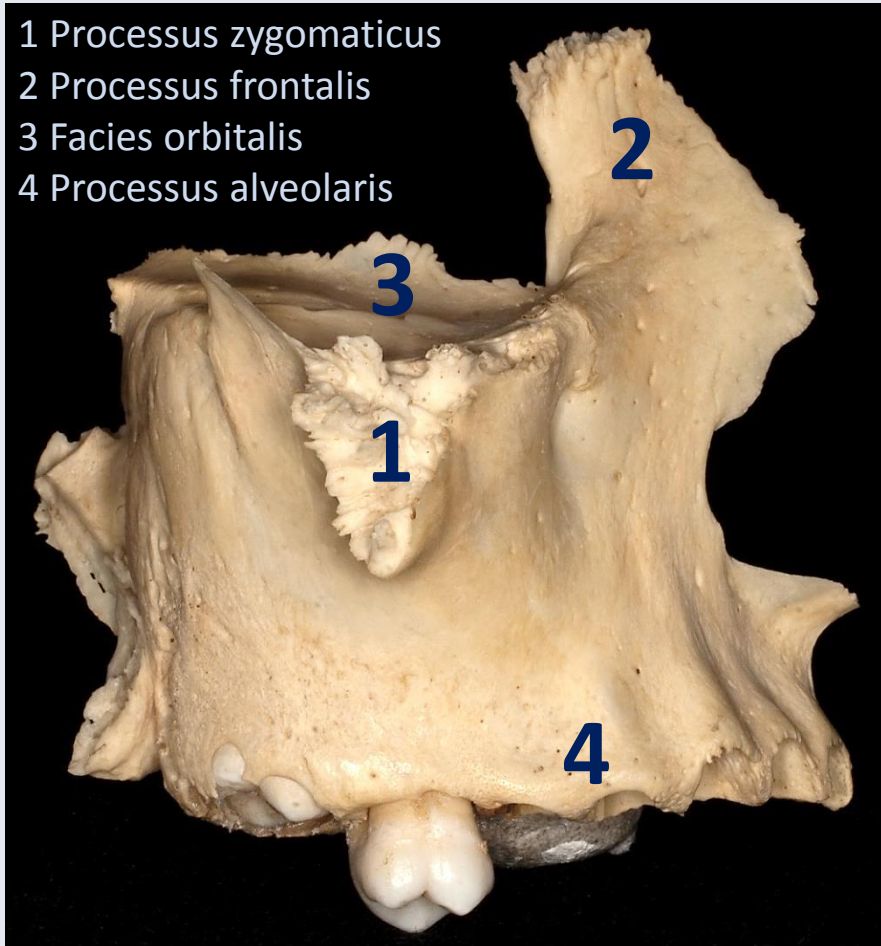
(linke Seite)



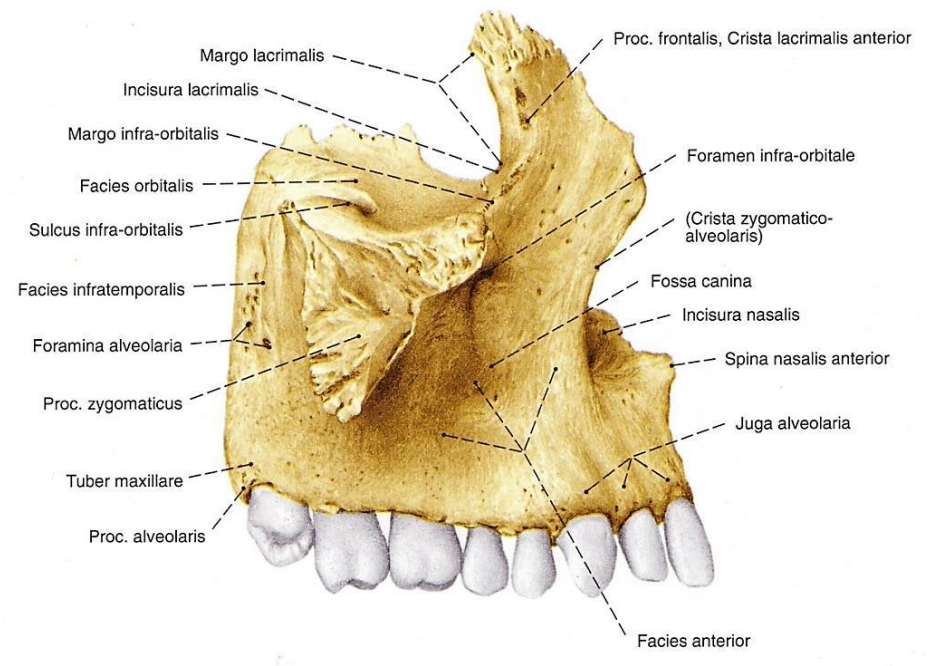
Faller

Aspectus lateralis

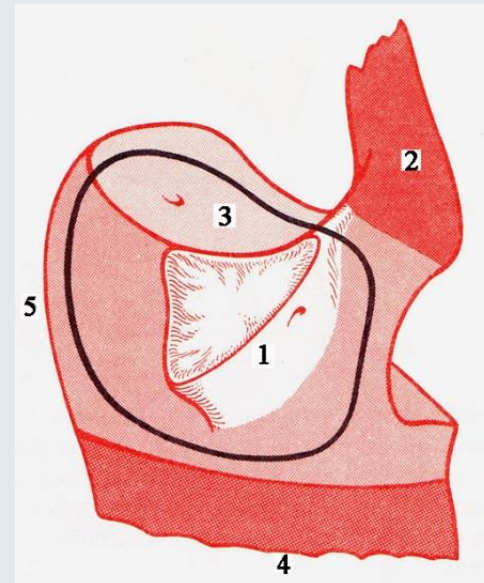
- 1 Processus zygomaticus
- 2 Processus frontalis
- 3 Facies orbitalis
- 4 Processus alveolaris



(rechte Seite)

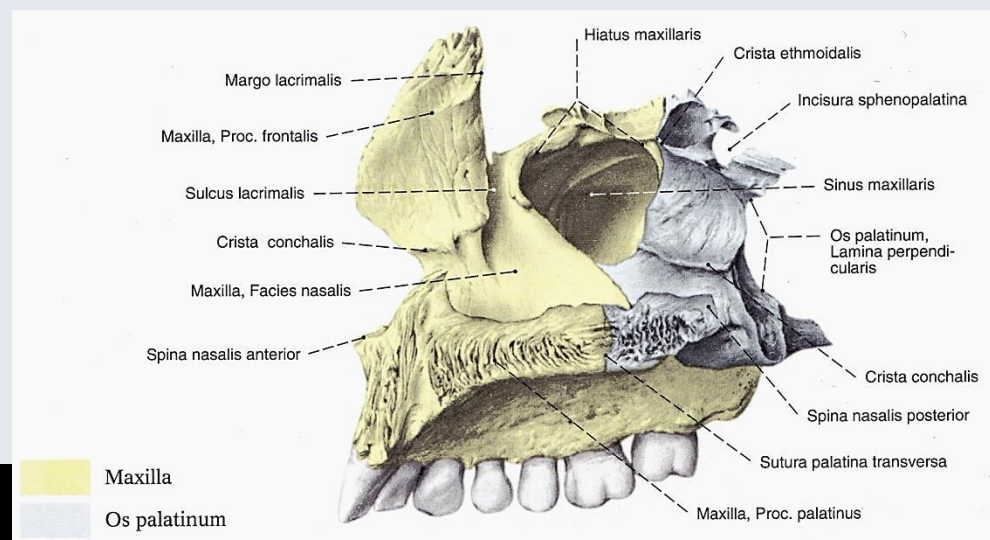
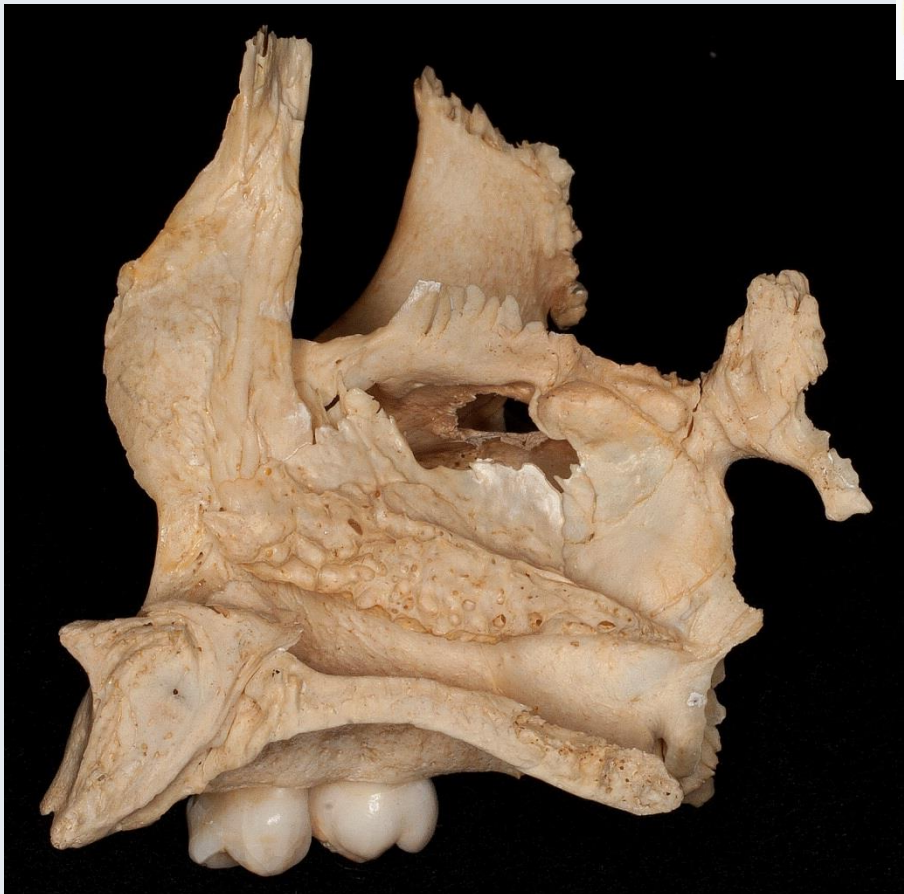

Sobotta

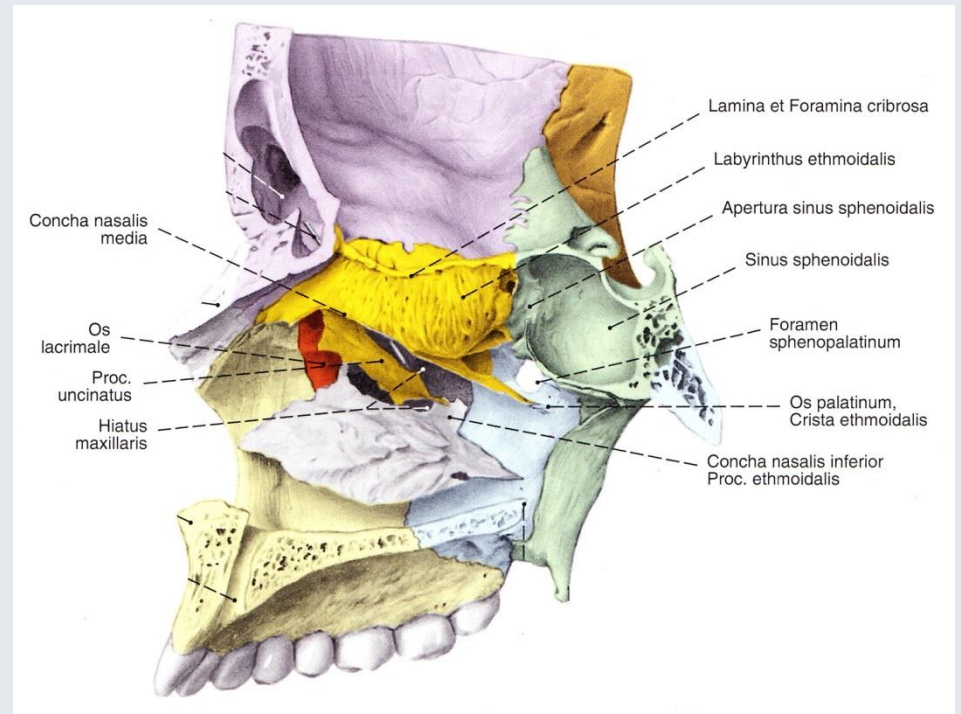


Faller

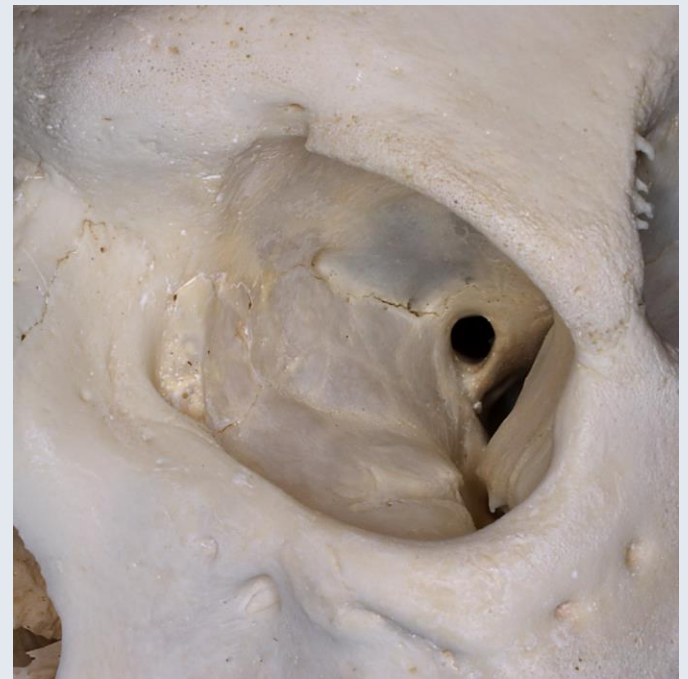
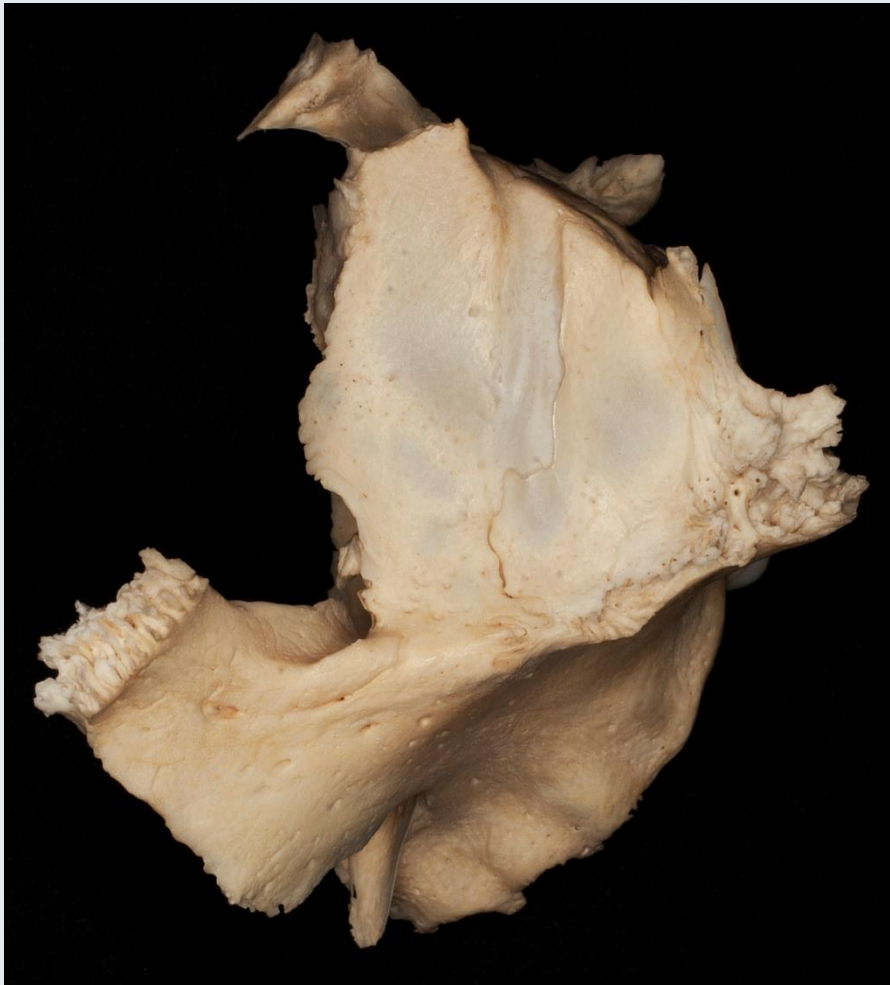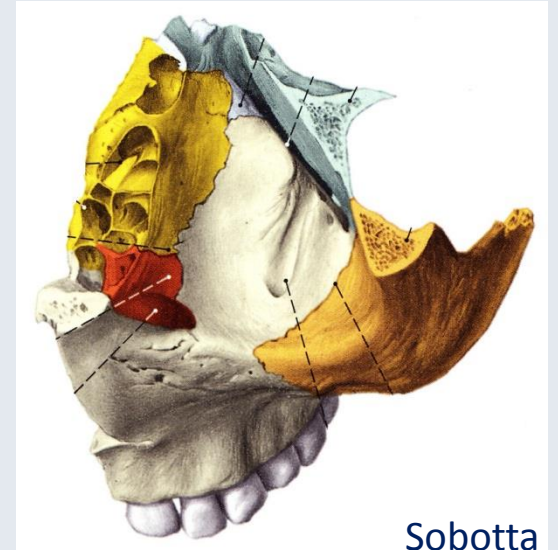
Aspectus medialis

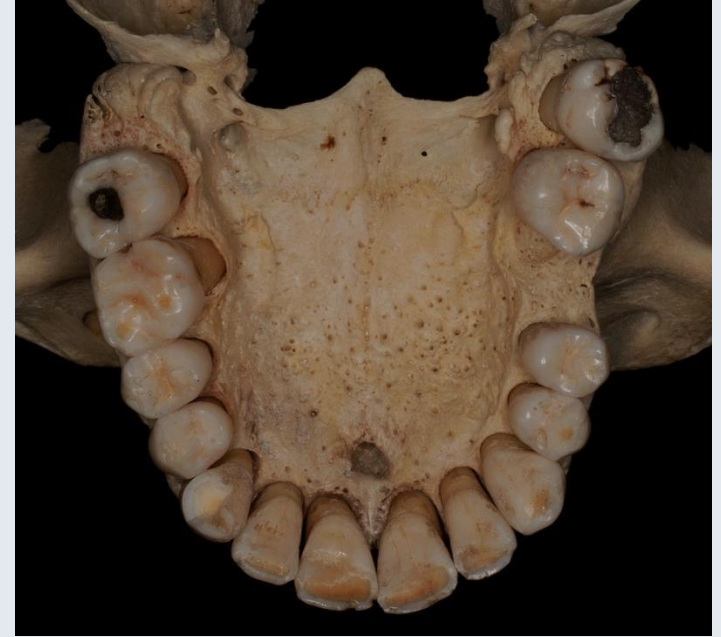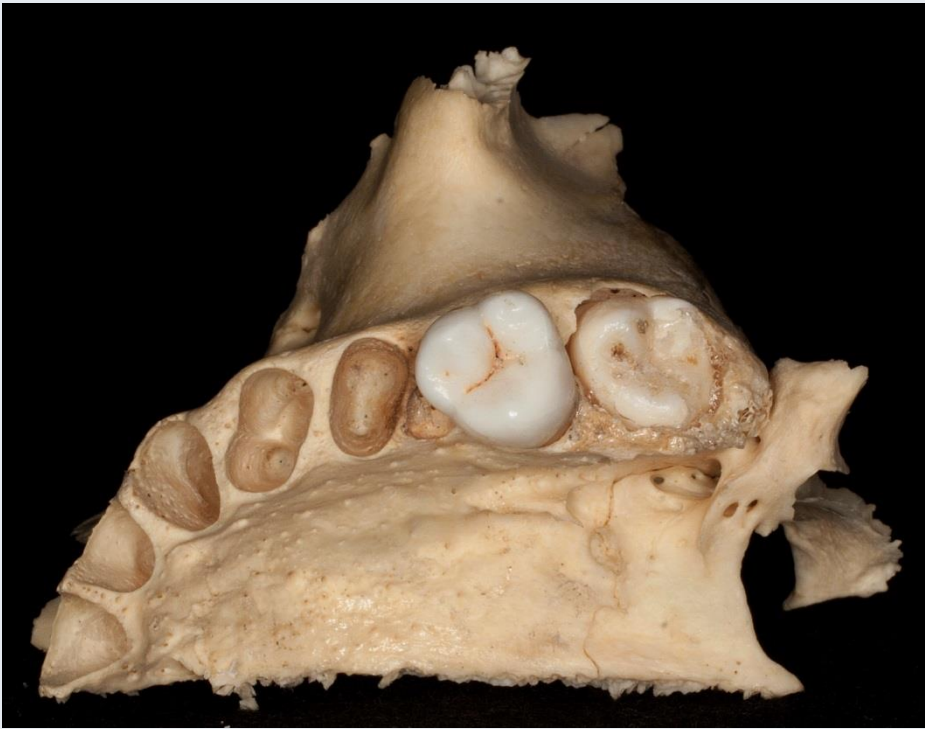


Sobotta

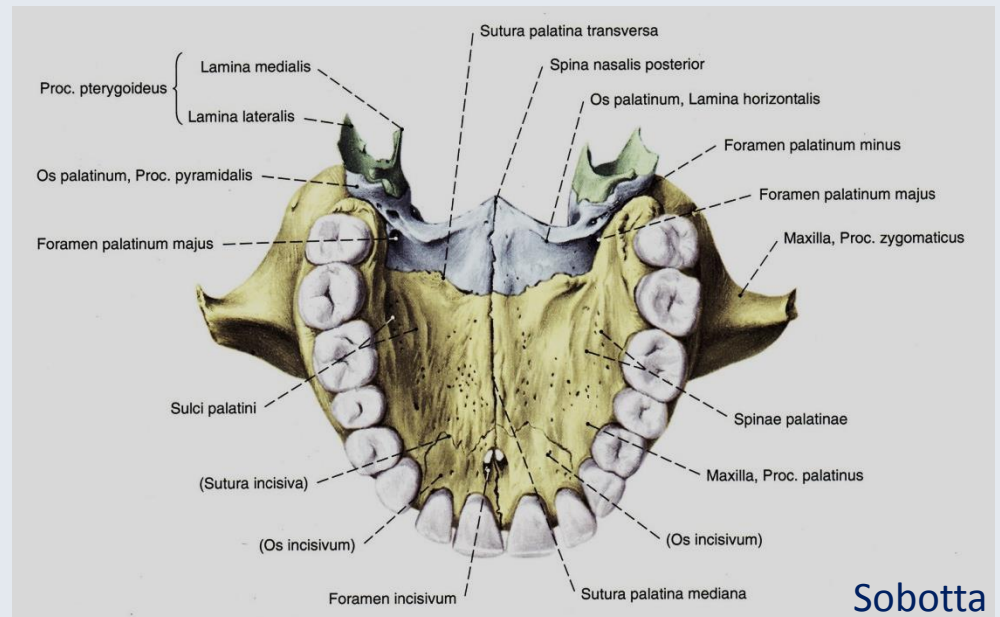


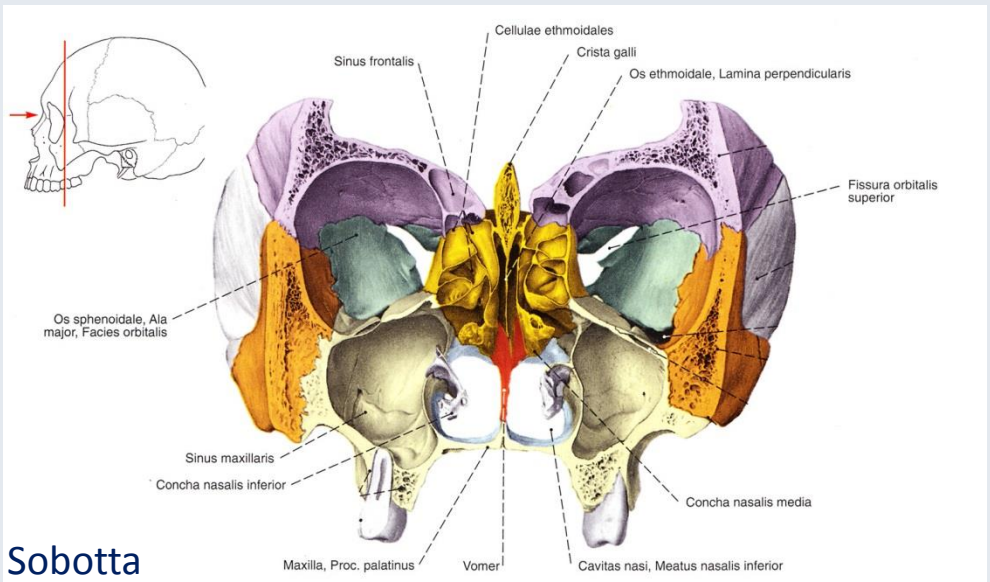
Aspectus superior



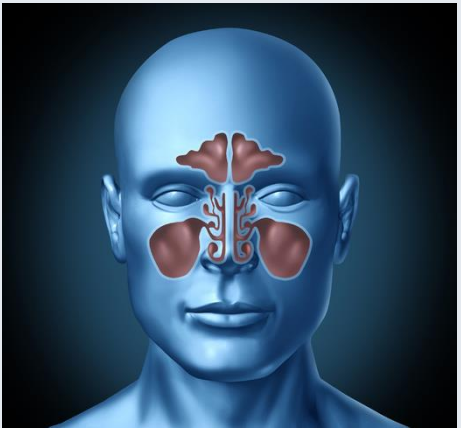


Aspectus inferior

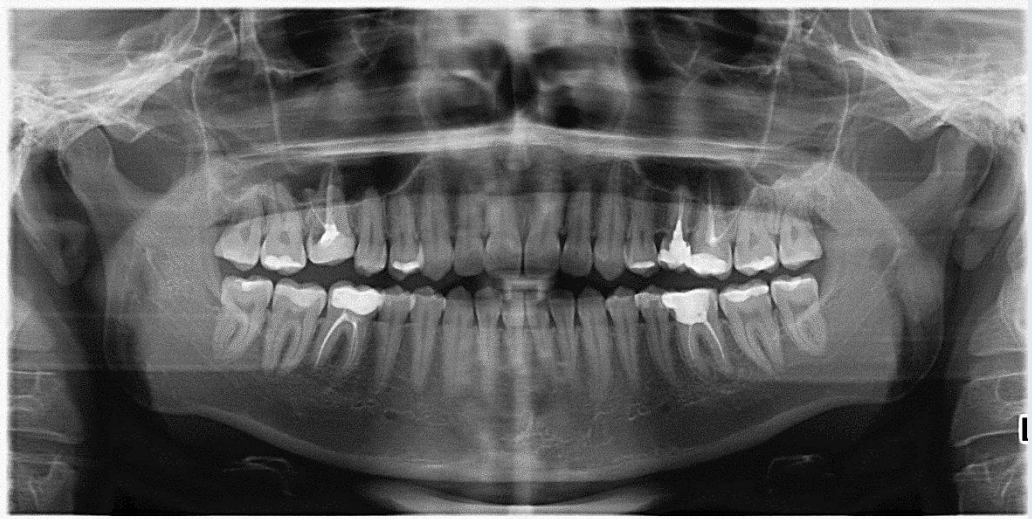




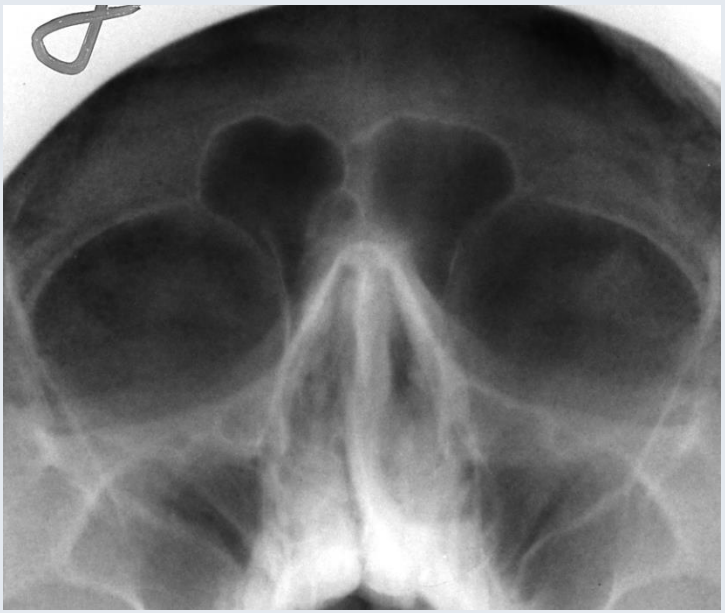Sobotta

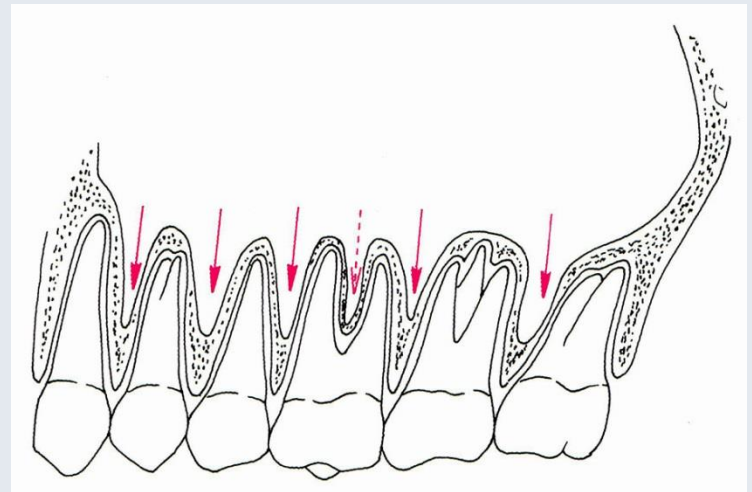
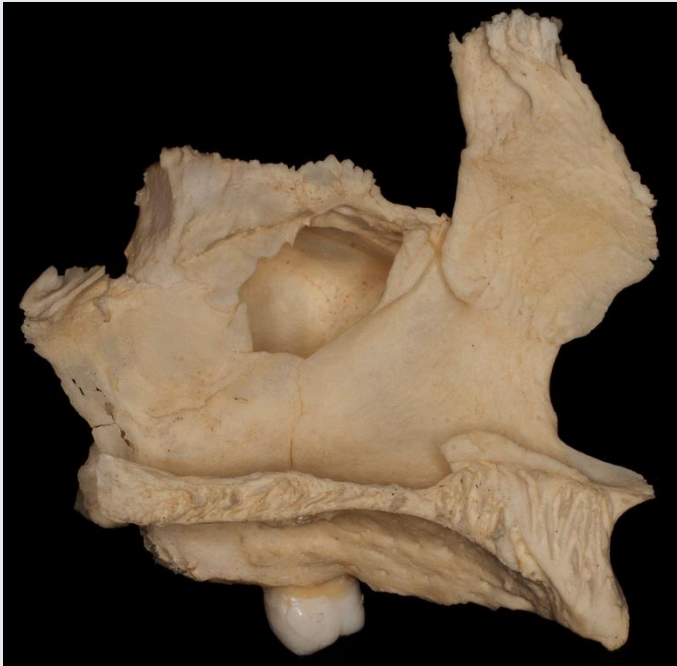
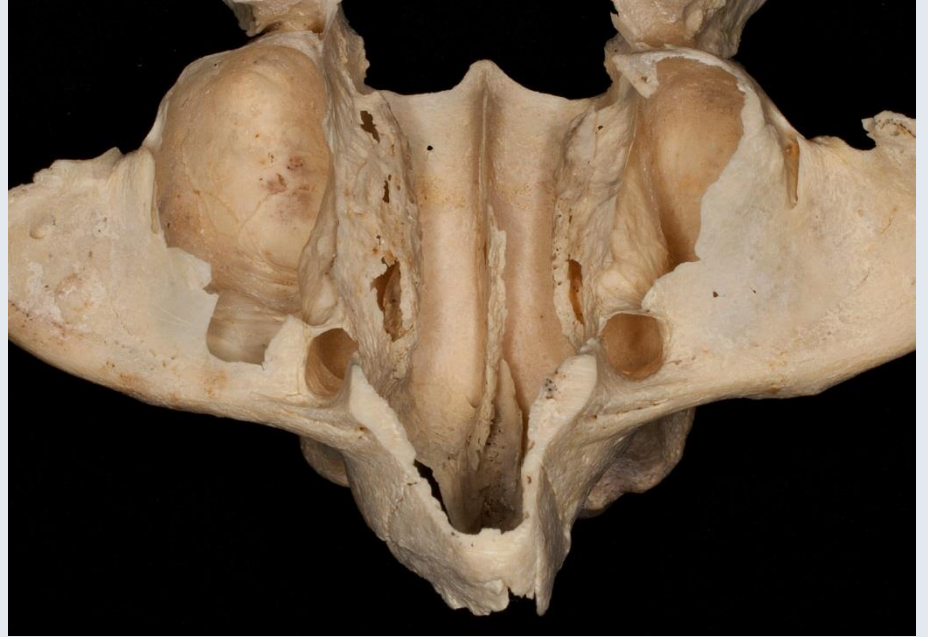
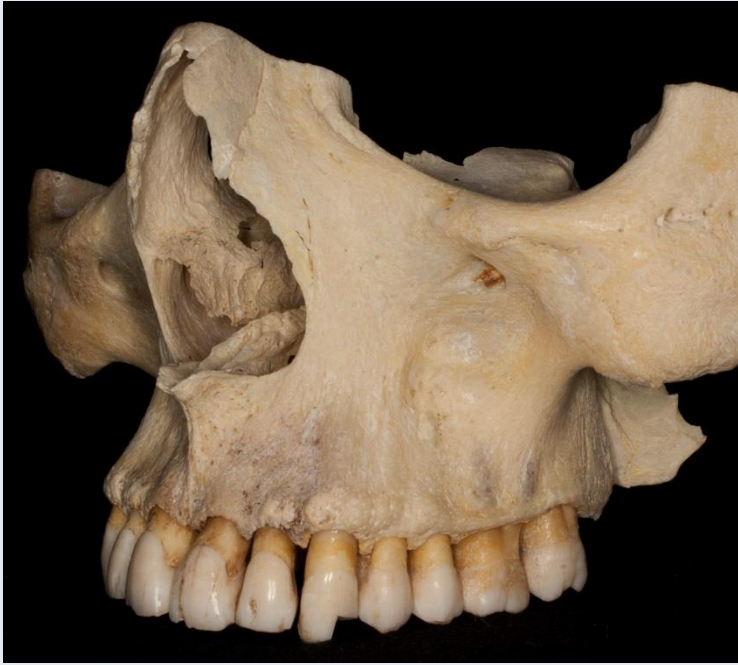<http://www.almanahmedical.eu>



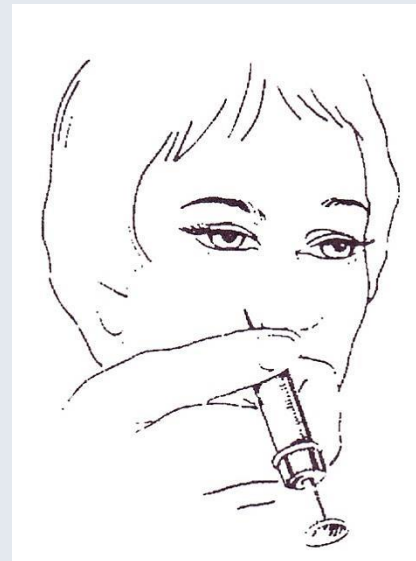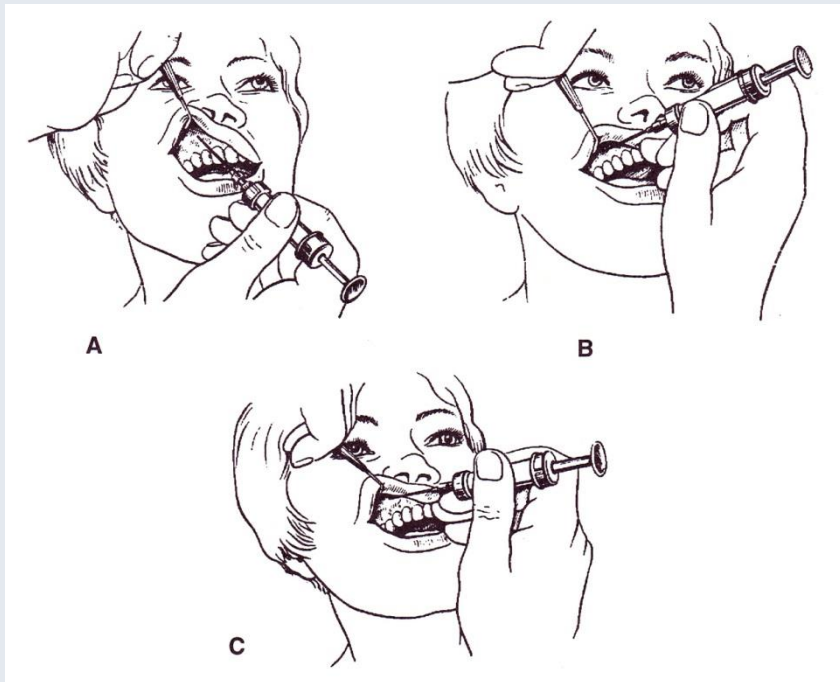
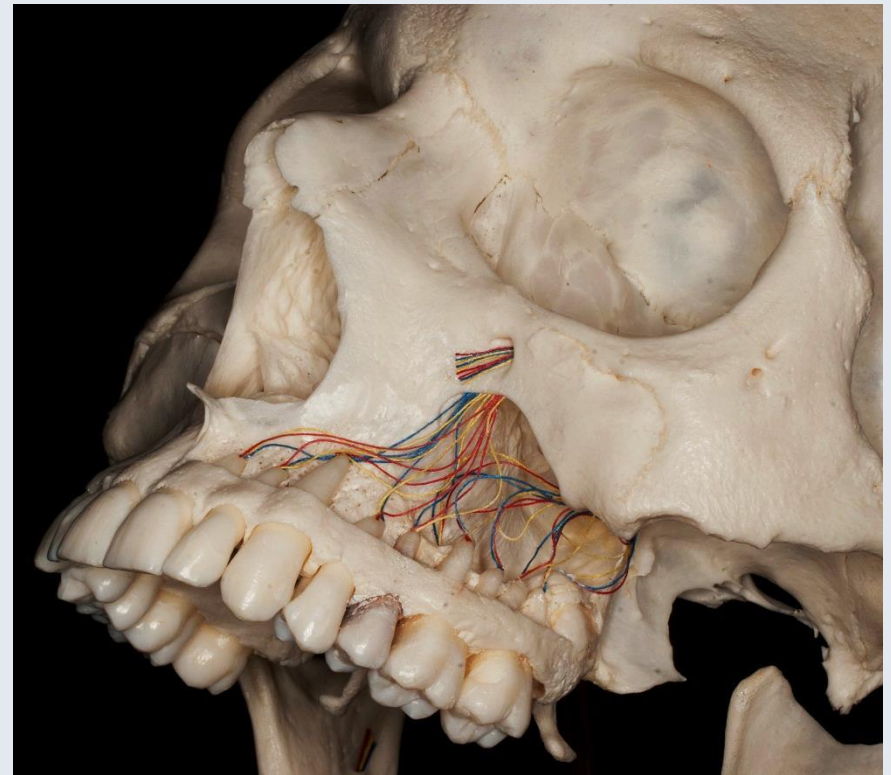
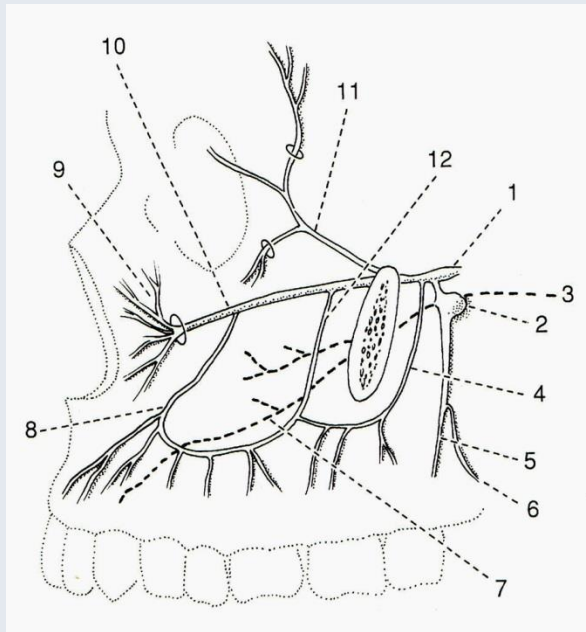
Florian Dental – Dr. S. Kováčh





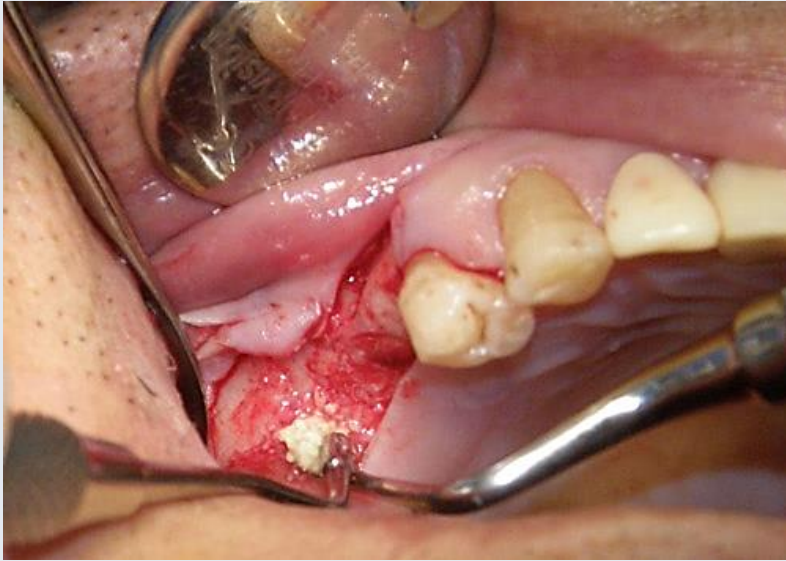Fehér

Fehér

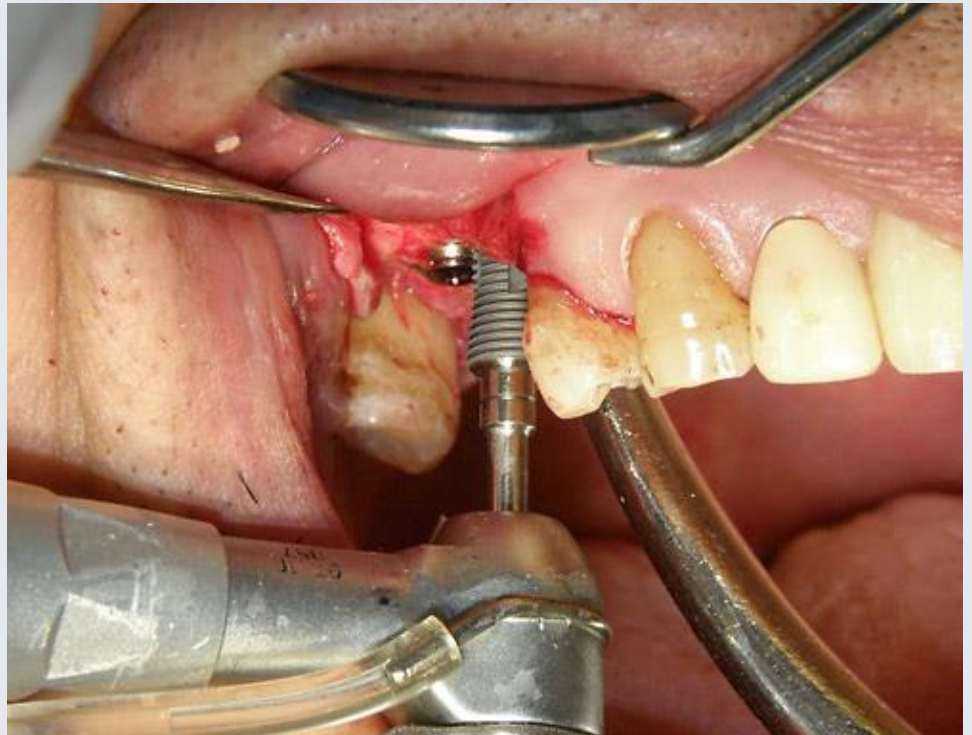


Szél

Szél

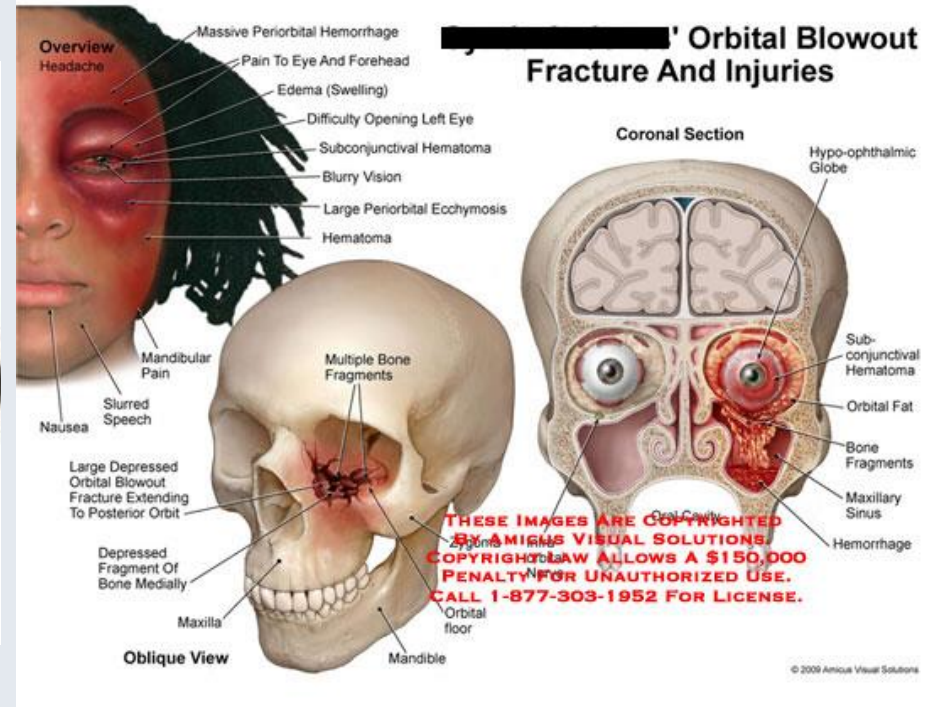
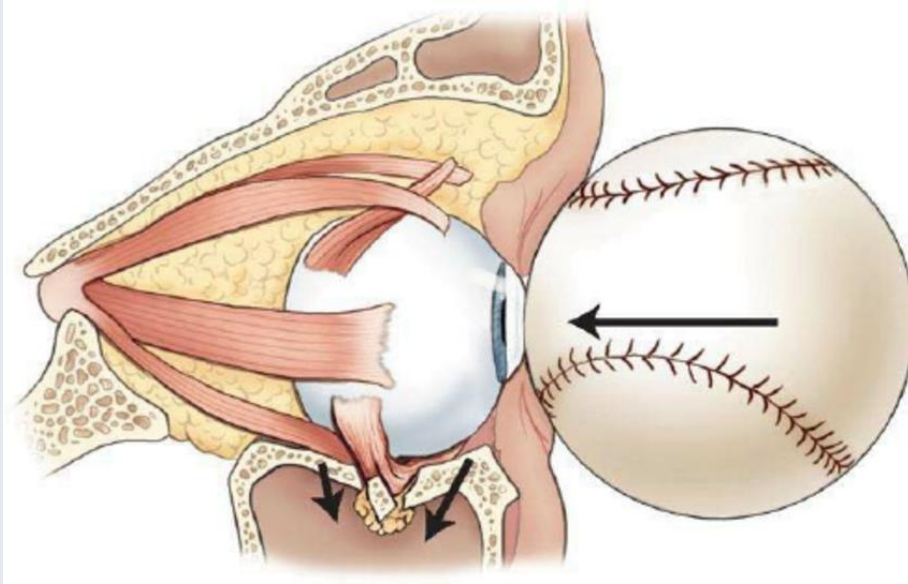


<http://www.hc-bios.com>

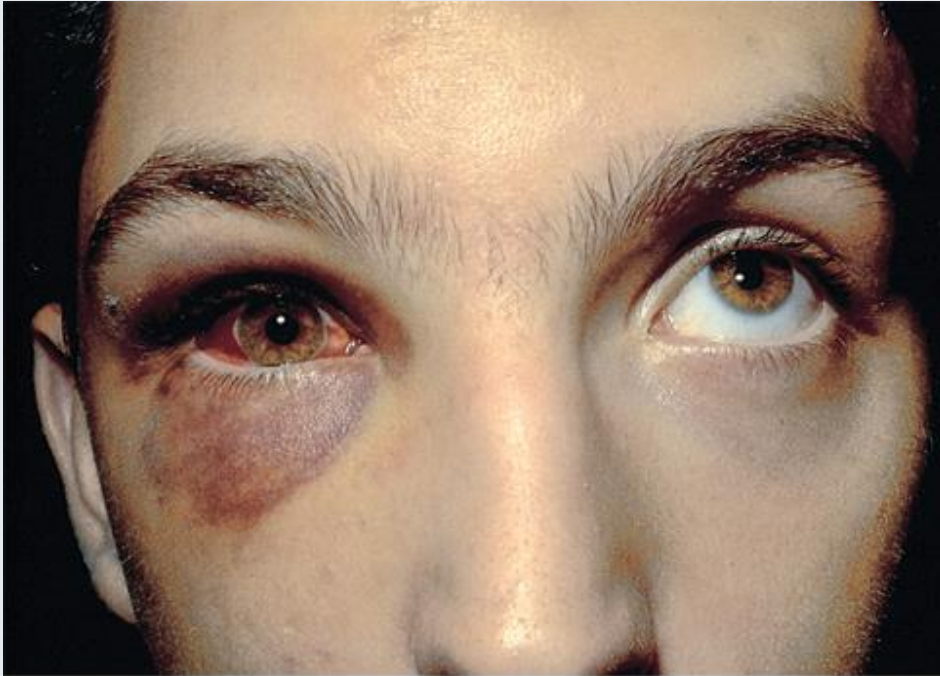

Orbit

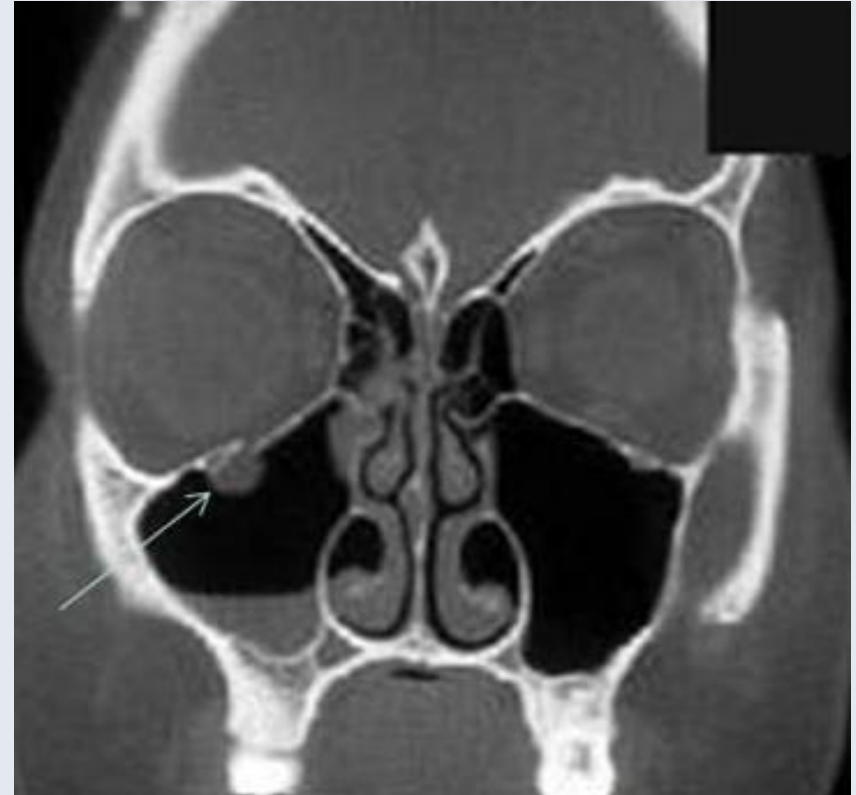Blowout Fractur



Blowout Fractur

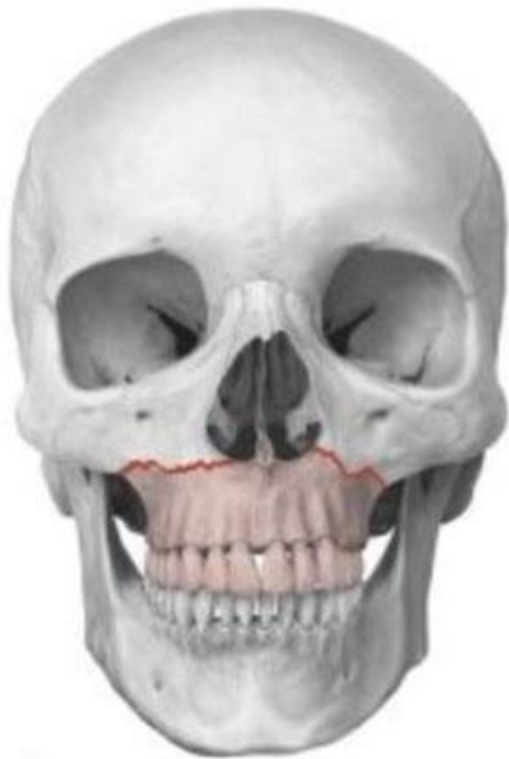

Source: K.J. Knoop, L.B. Stack, A.B. Storrow, R.J. Thurman:
The Atlas of Emergency Medicine, 4th Edition,
www.accessemergencymedicine
Copyright © McGraw-Hill Education. All rights reserved.

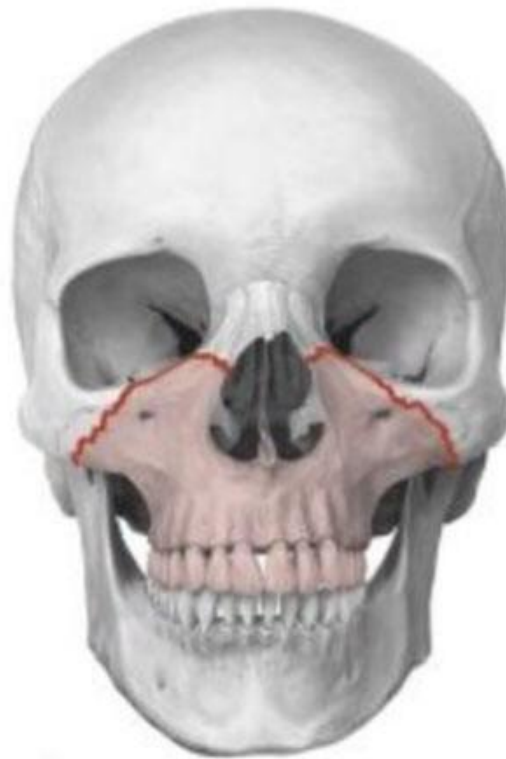

Viscerocranium

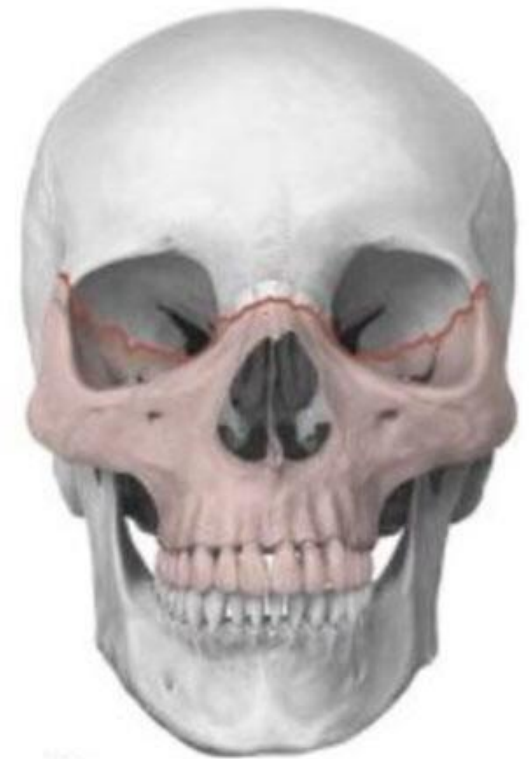A **Le Fort fracture of the skull** is a classic transfacial fracture of the mid face, involving the maxillary bone and surrounding structures in either a horizontal, pyramidal or transverse direction.



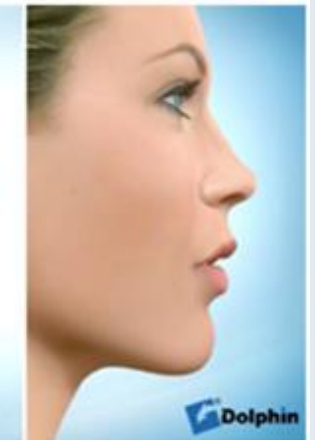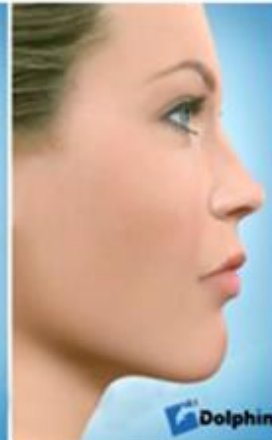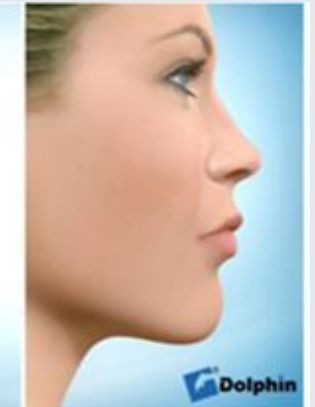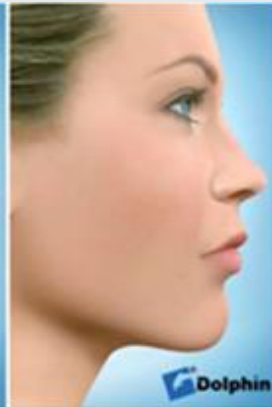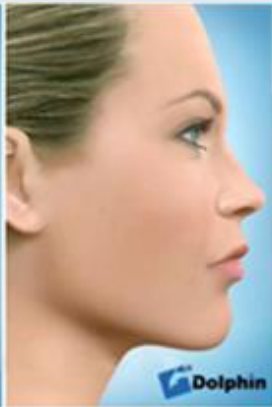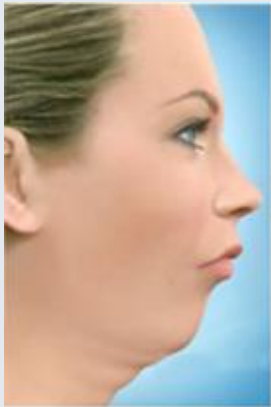Le Fort I

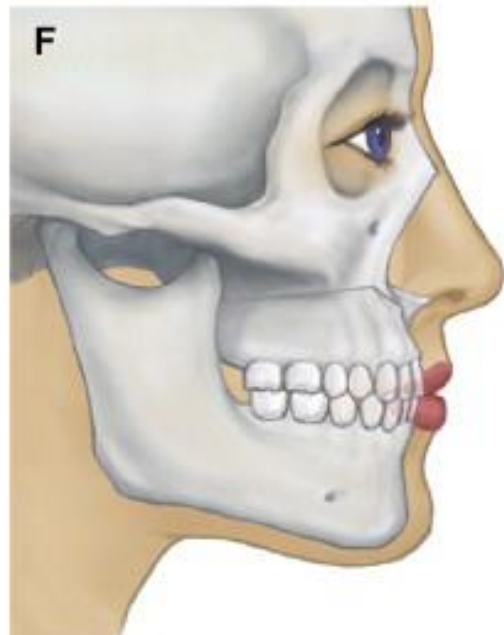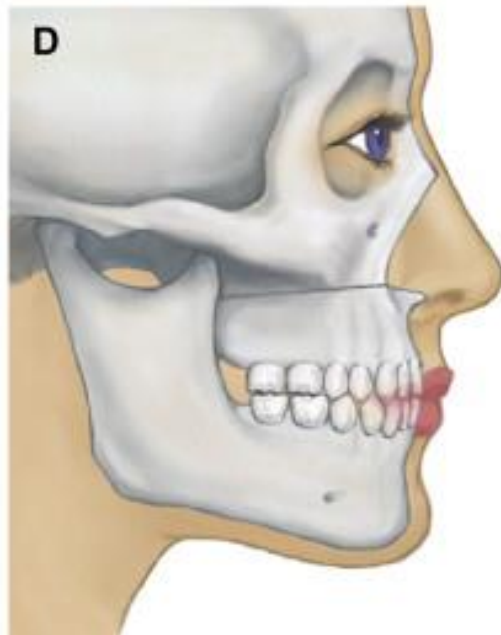
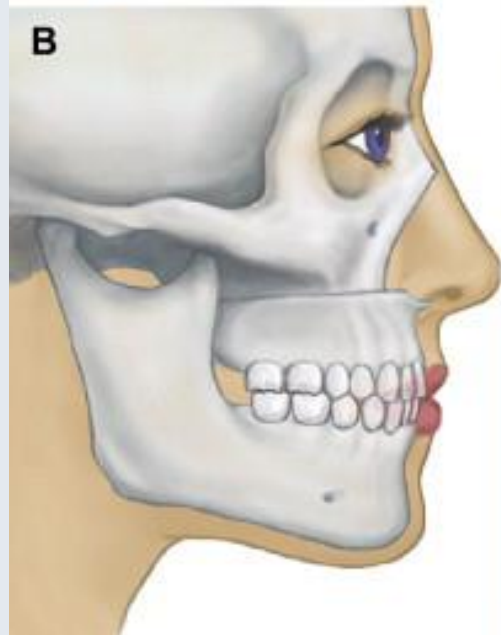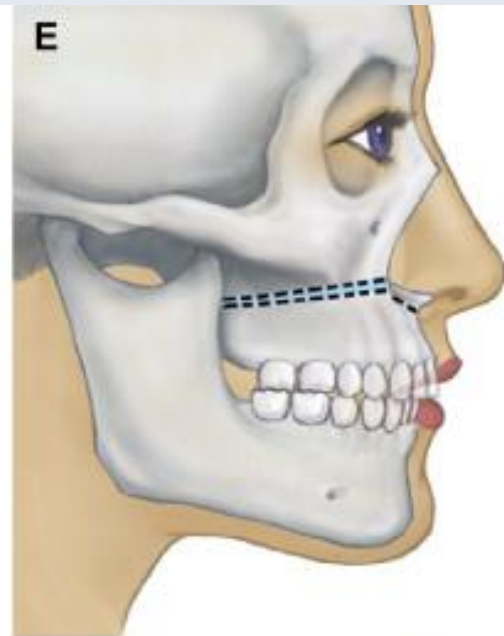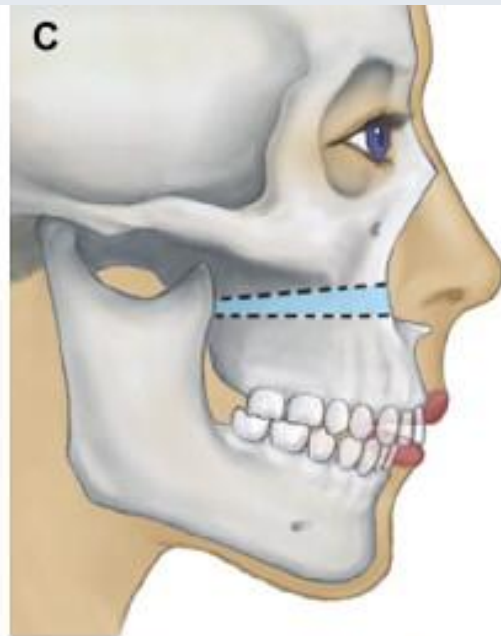
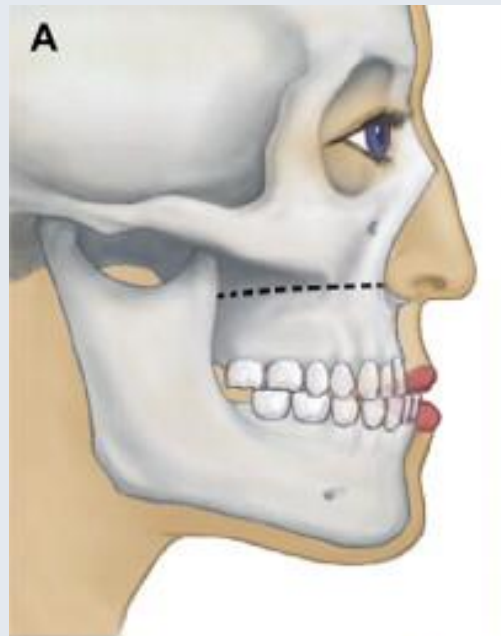


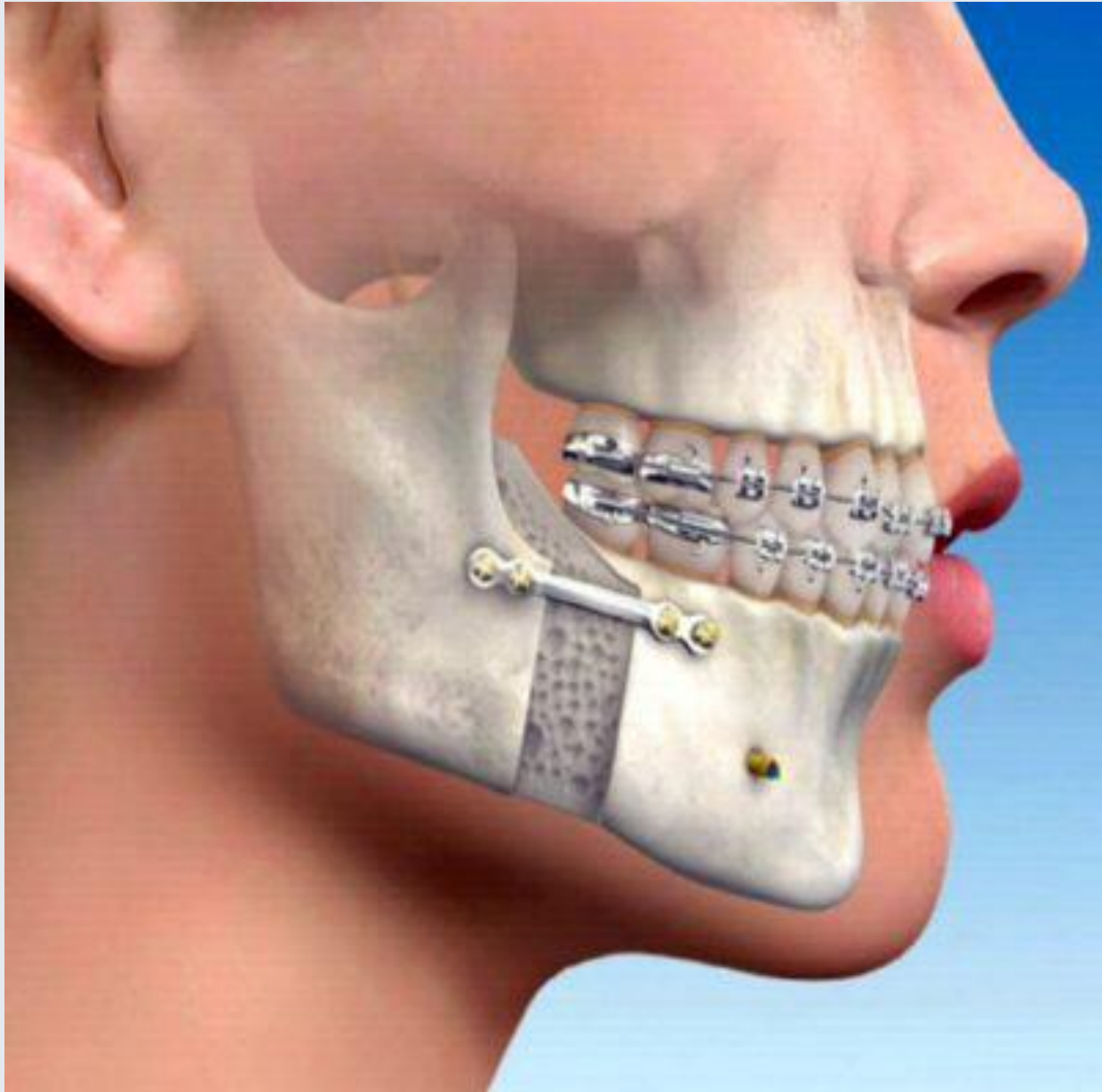
Le Fort II

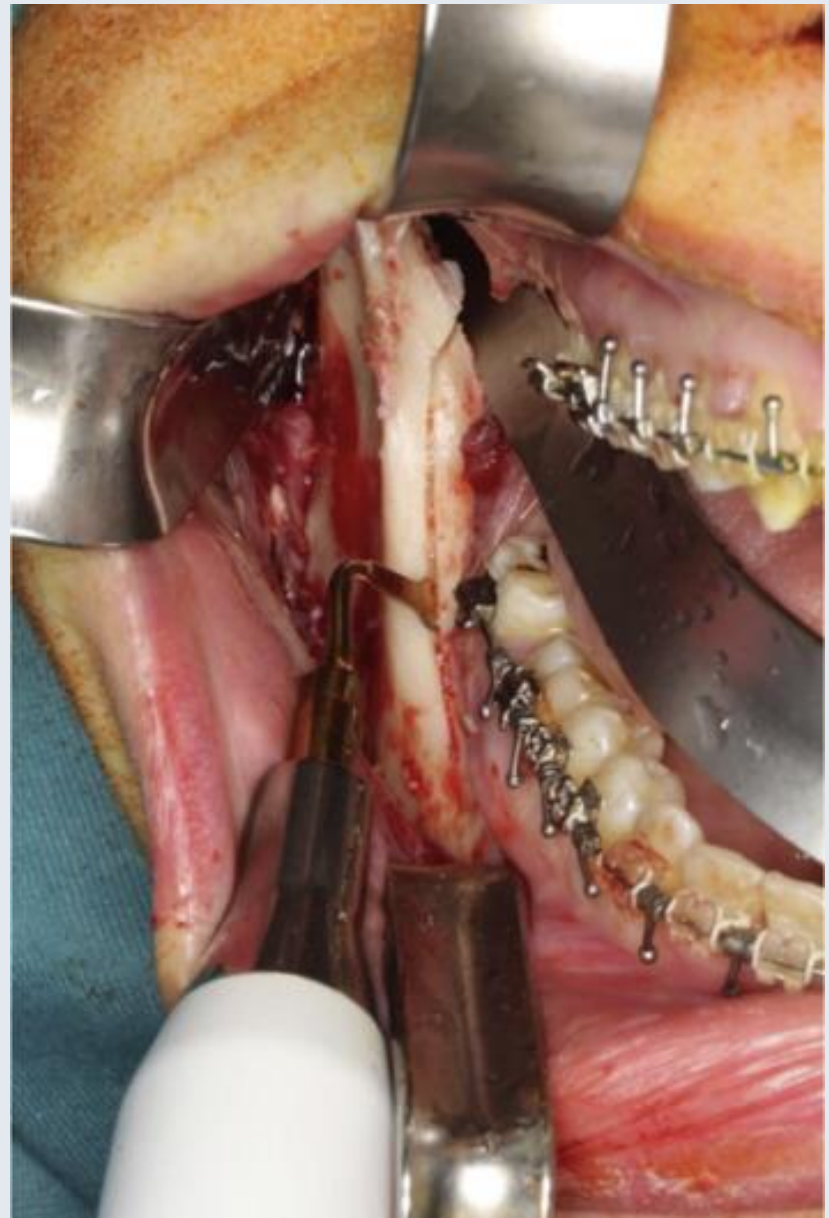
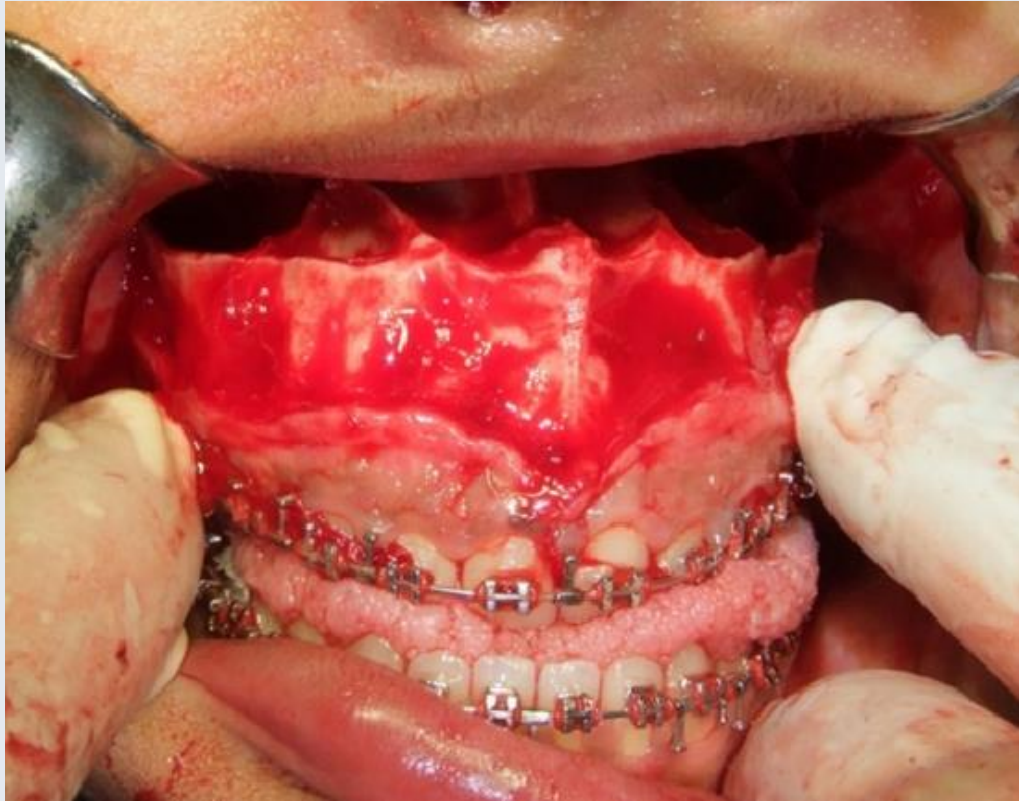
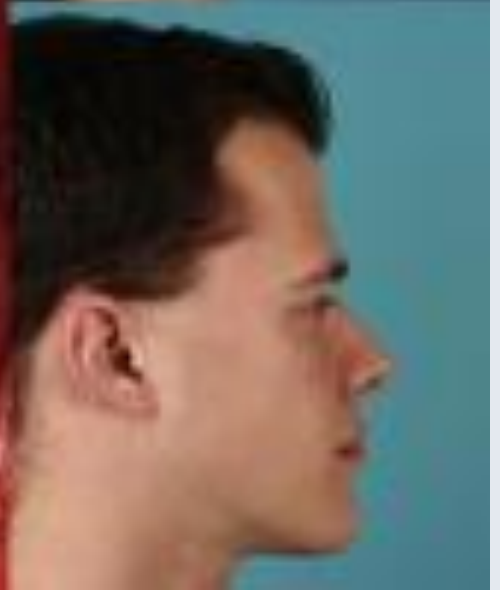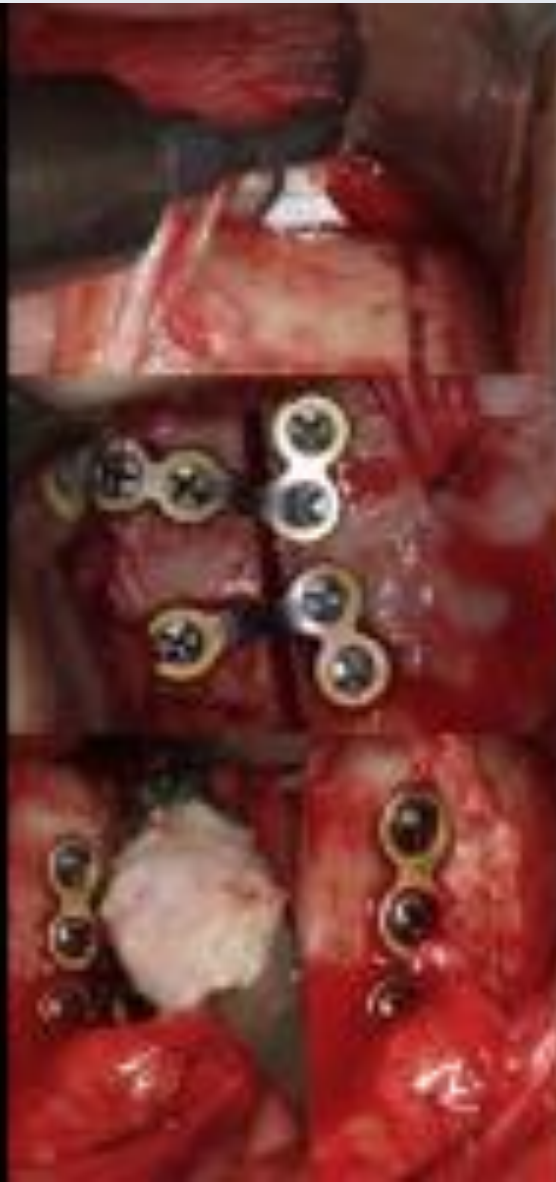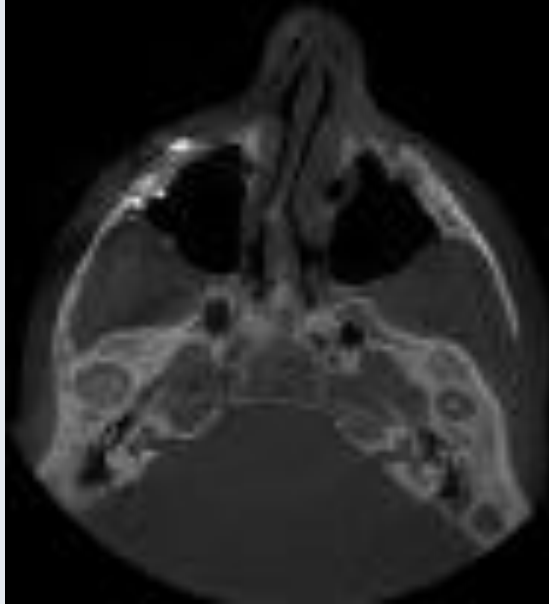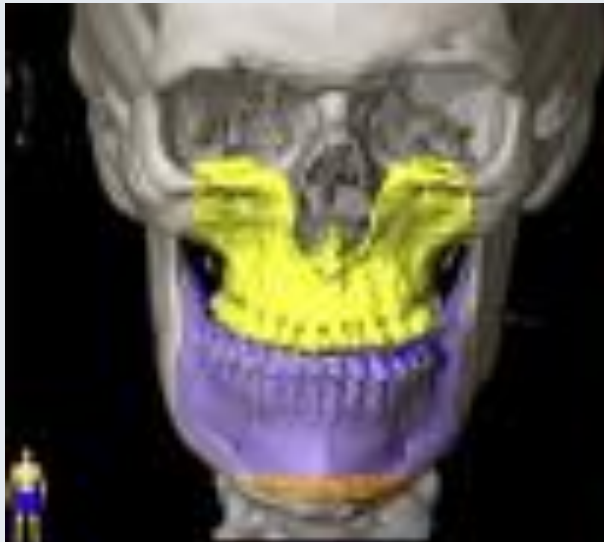
Le Fort III











https://www.youtube.com/watch?v=Ewg0_Bct1Yk

<https://www.youtube.com/watch?v=Td9Hx6N1YiY>

Literatur und Danksagung

Faller: Anatomie in Stichworten – Ein Arbeitsbuch für Medizinstudente und praktische Ärzte (Ferdinand Enke Verlag 1980.)

Fehér: Maxillofaciális anatómia (Medicina Kiadó 2001.)

Pernkopf: Topographische Anatomie des Menschen. Lehrbuch und Atlas der regionär-stratigraphischen Präparation. (Urban & Schwarzenberg 1952.)

Sobotta: Az ember anatómiájának atlasza (Semmelweis Kiadó 1994.)

Szél: Klinikai anatómia (SOTE Képzéskutató 1999.)

Szentágothai – Réthelyi: Funkcionális anatómia (Medicina Kiadó - Semmelweis Kiadó 1996.)

www.almanahmedical.eu

www.hc-bios.com

www.mng.hu

Knochenpräparate in der Vorlesung: Dr. Lajos Patonay

Panoramaaufnahmen: Florian Dental – Dr. Sándor Kovách