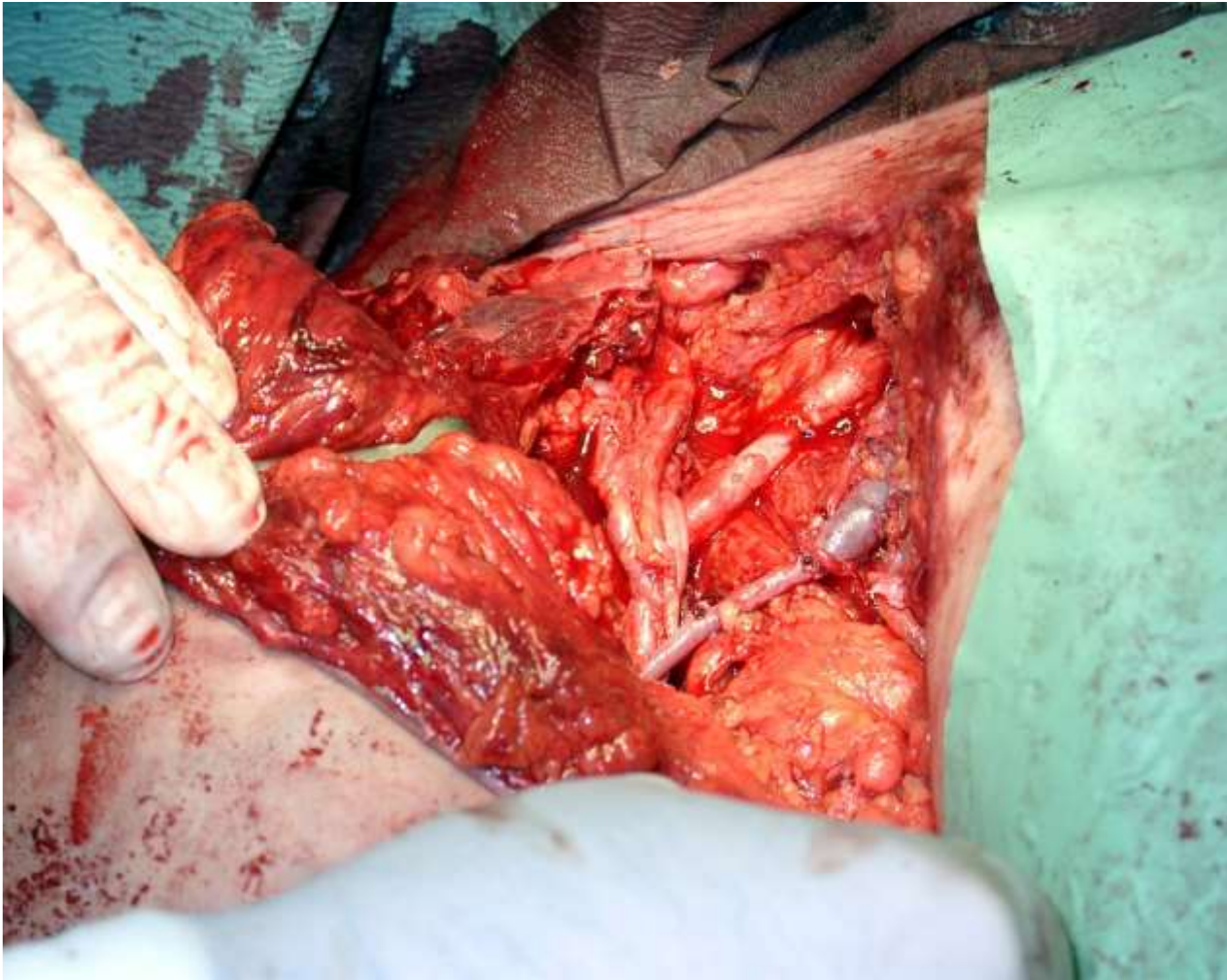


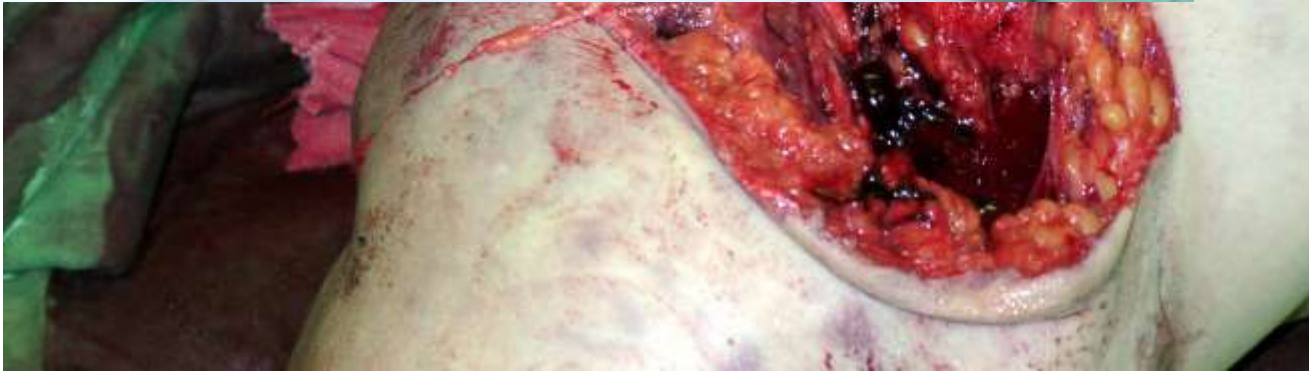Sebészeti Anatomia-
Surgical Anatomy,
Traumatologia-
Traumatology

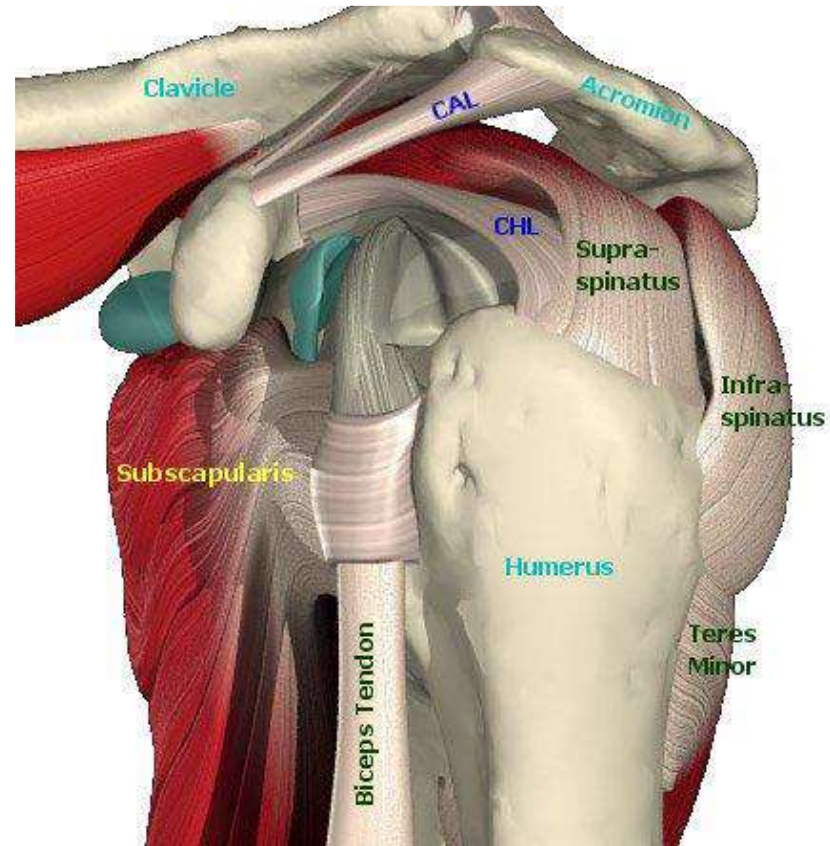
Detre Zoltán

Szt. JÁNOS KórházBUDAPESTTraumatologiai és Kézsebészeti
Osztály, Budai Trauma Centrum

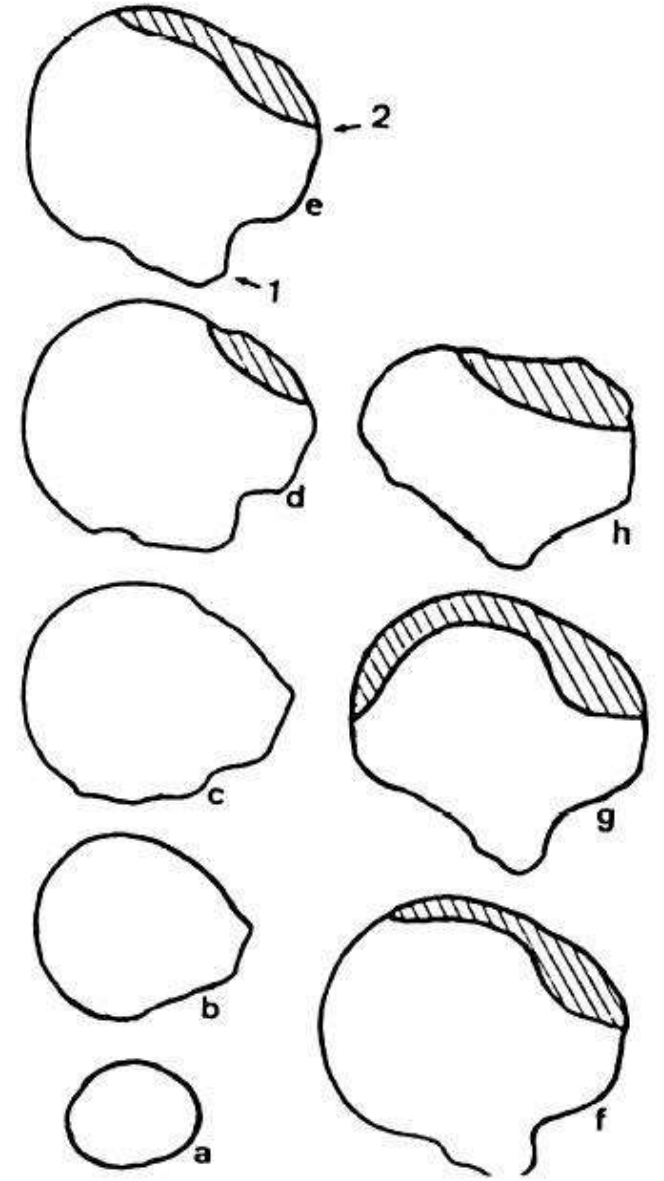
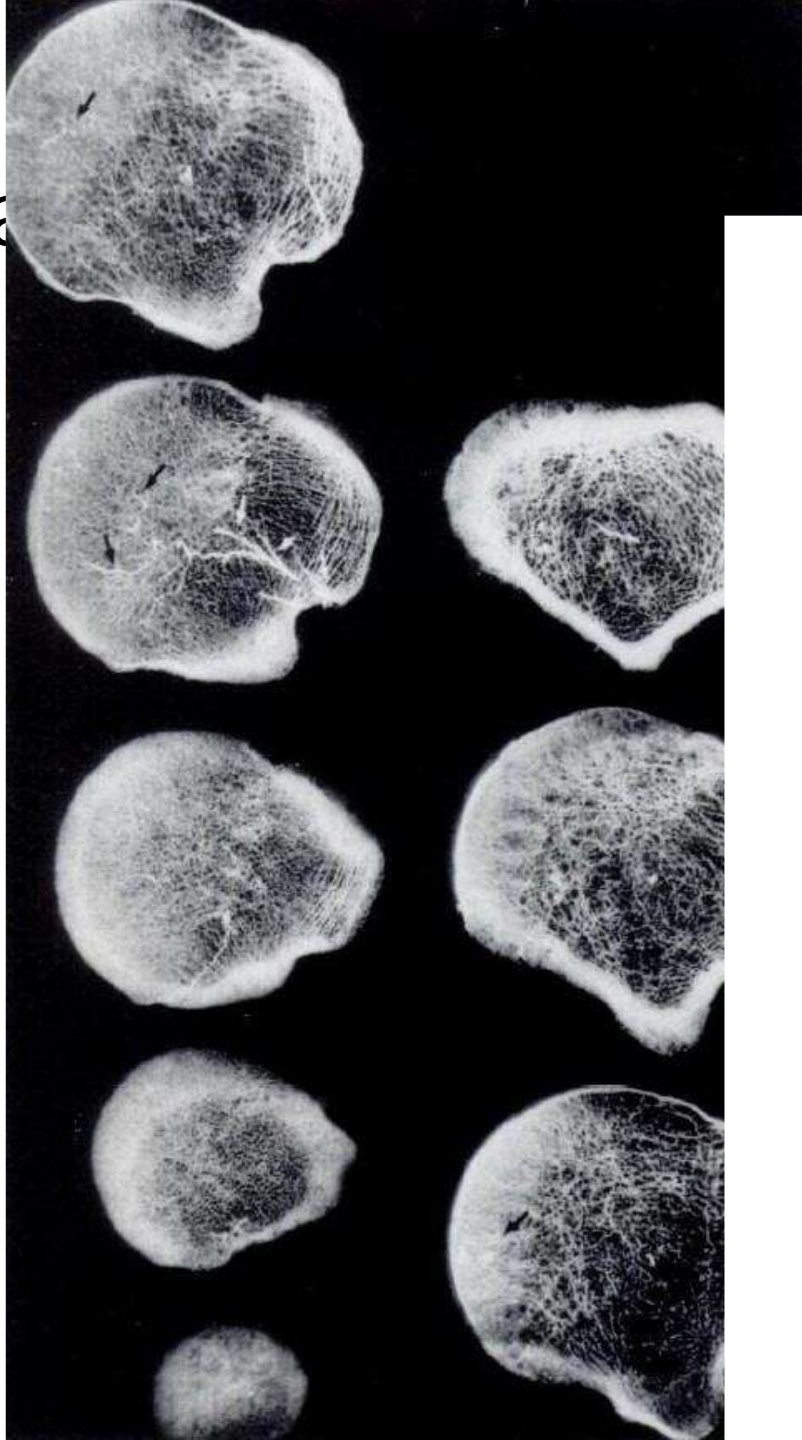
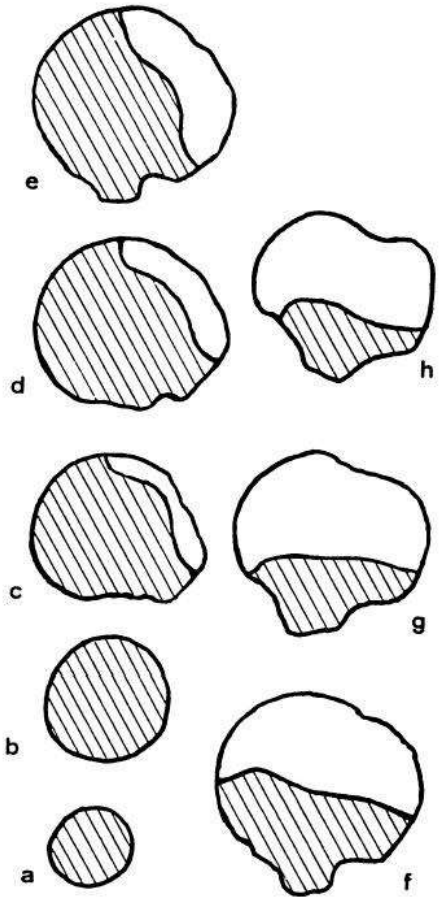


- Arterial and venous bypass and axillary plexus adaptation were performed





Ant. circumflex a
Post. circumflex



Fibula OT

