

A gége izmai és működése. A gége  
kötőszövetes váza és nyálkahártyája.

Dr. Ádám Ágota  
Egyetemi adjunktus  
2019.

# A GÉGE ALKOTÓRÉSZEI

Váz  
Izmok  
Szalagok

+

Fibroelasztikus membránok  
Nyálkahártya  
Idegek, erek, nyirokerek

## FŐBB PORCOK:

*Cartilago thyroidea* (pajzsporc)

*Cartilago cricoidea* (gyűrűporc)

*Epiglottis* (gégefedő)

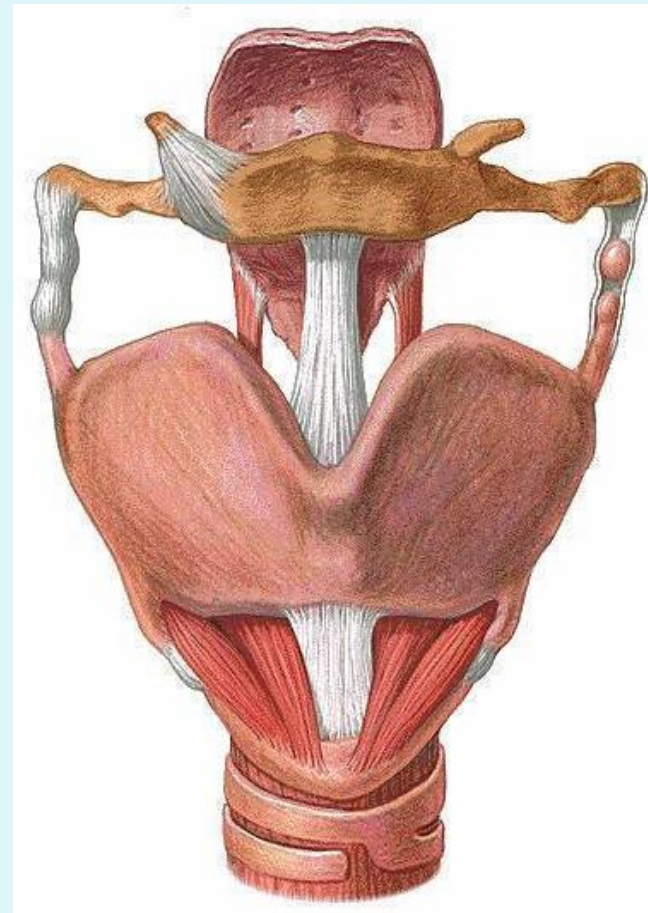
*Cartilago arytenoidea* (kannaporc)

## KISEBB PORCOK:

*Cartilago corniculata* (Santorini)

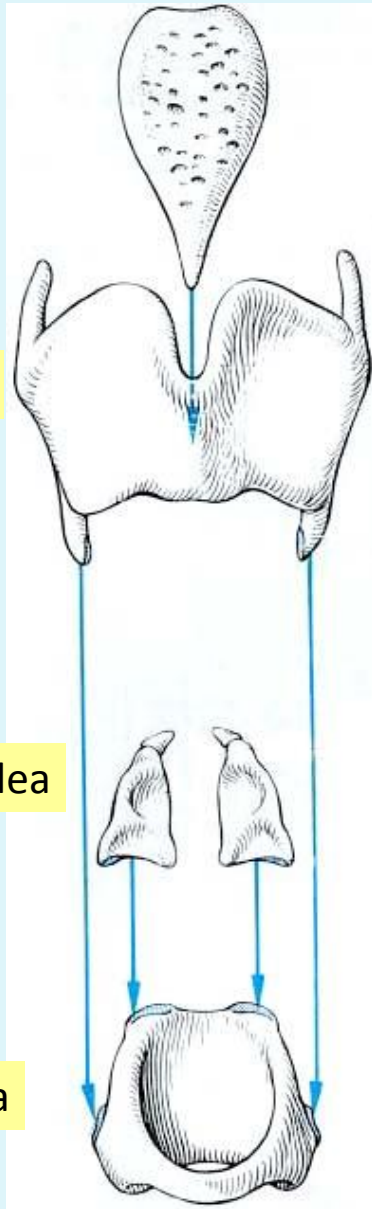
*Cartilago cuneiforme* (Wrisberg)

*Cartilago triticea*



# A GÉGE VÁZA (ismétlés)

Epiglottis



Cart. thyroidea

Cart. arytenoidea

Cart. cricoidea

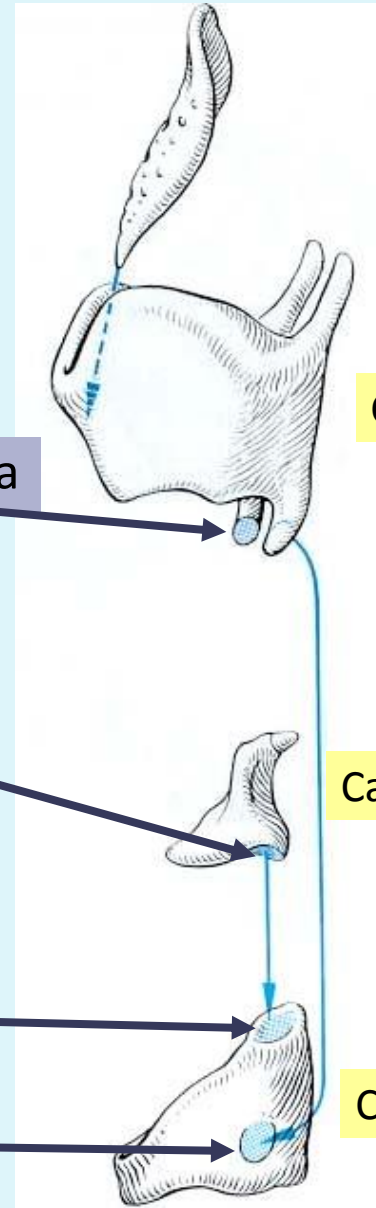
Petiolus epiglottidis

Fac. articularis cricoidea

Basis; facies articularis cricoidea

Fac. articularis arytenoidea

Fac. articularis thyroidea



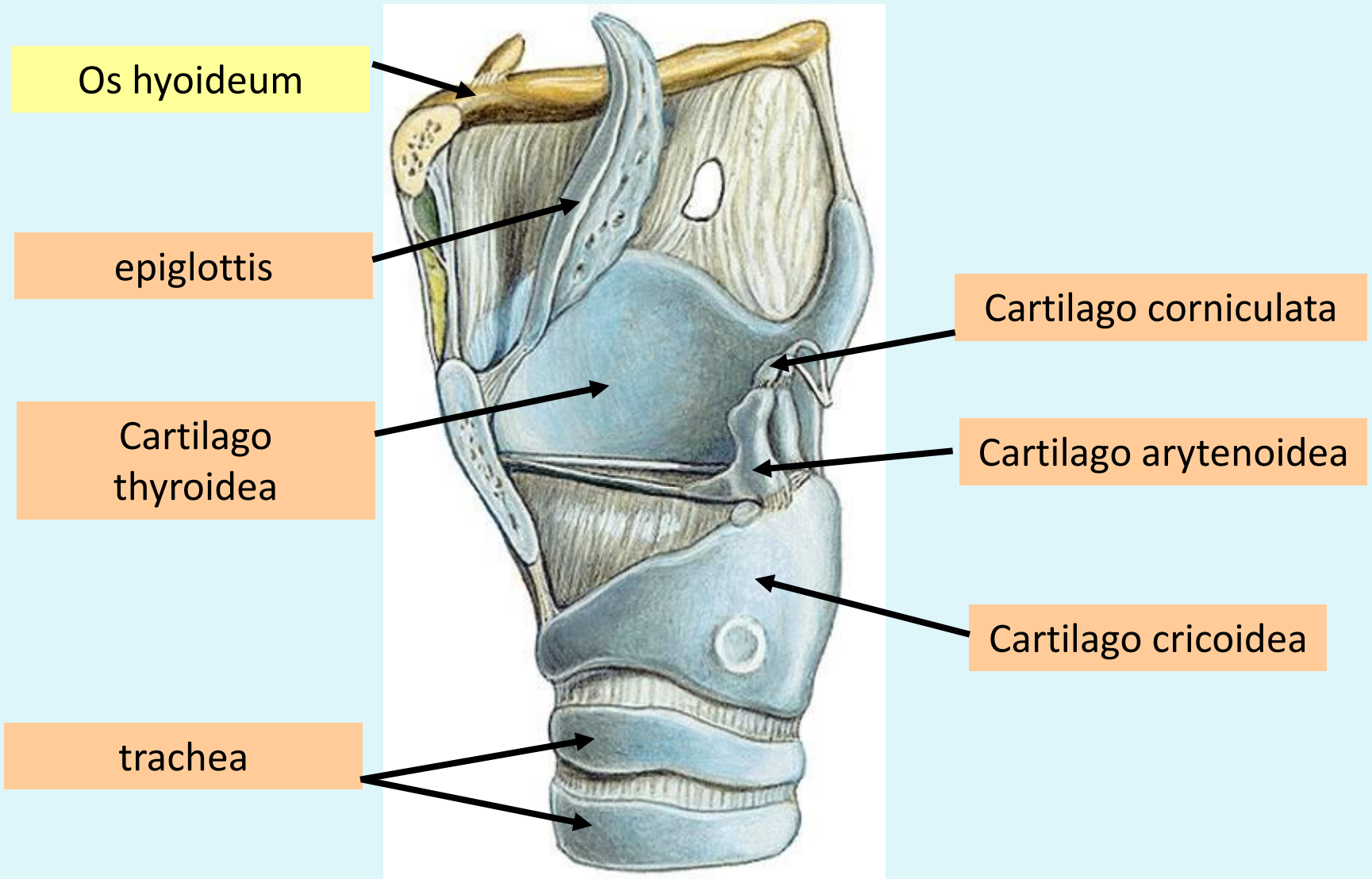
Epiglottis

Cart. thyroidea

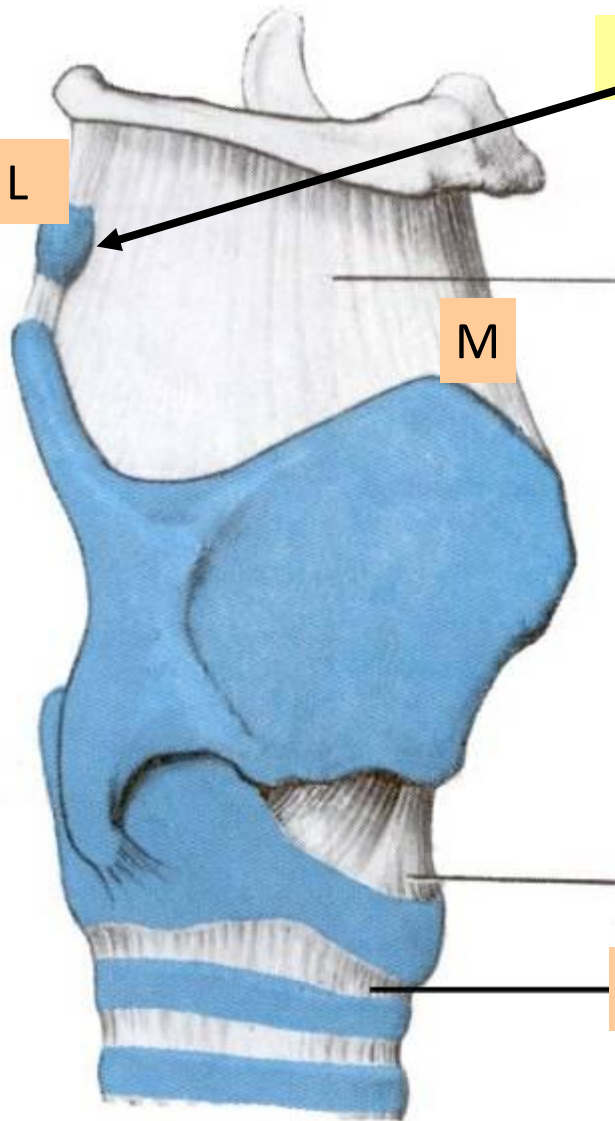
Cart. arytenoidea

Cart. cricoidea

# A GÉGE VÁZA



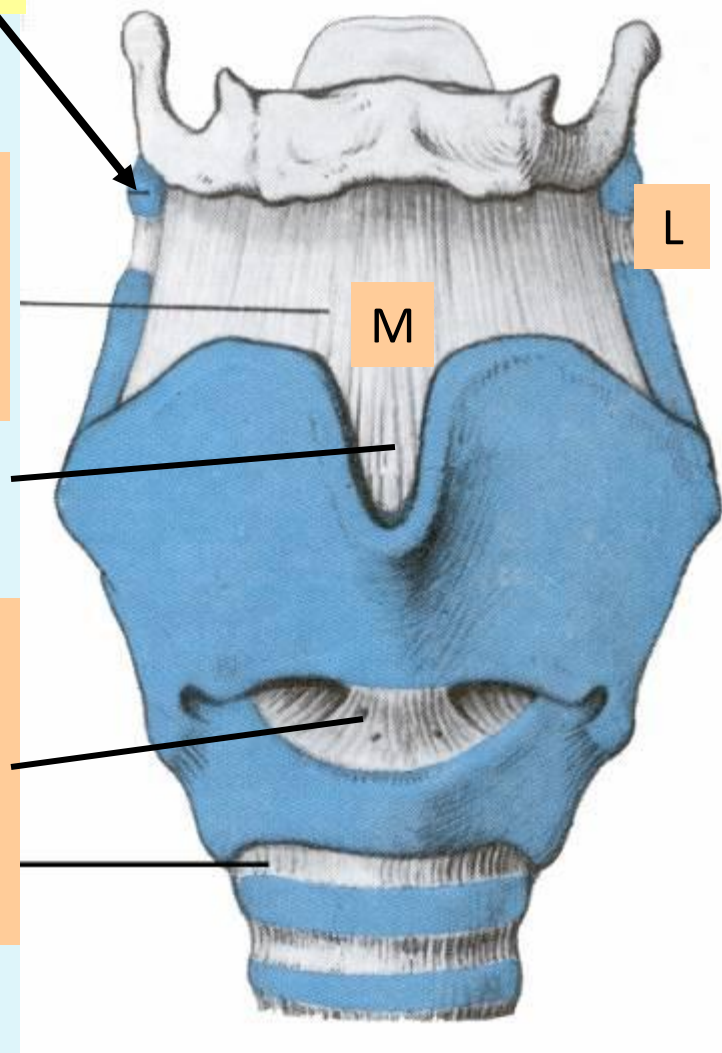
# A GÉGE SZALAGJAI



Cartilago triticea

Membrana thyrohyoidea  
+ lig. thyrohyoidea med. és lat.

Lig. cricothyroideum medianum  
(*lig. conicum*)  
**Conicotomia**  
Lig. cricotracheale



# BELSŐ SZALAGOK

RAJZ!

Membrana  
thyrohyoidea  
+

Lig. thyrohyoideum  
med. és lat.

Lig. thyroepiglotticum

Lig. conicum

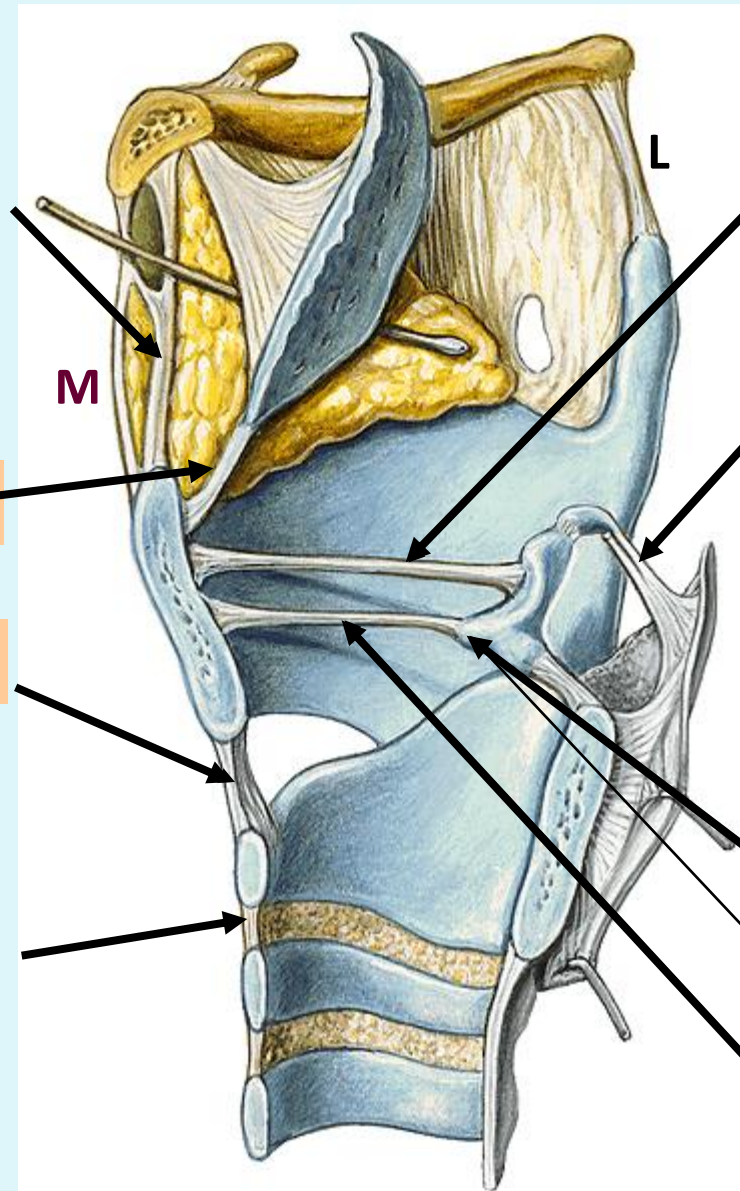
Lig. cricotracheale

Lig. vestibulare

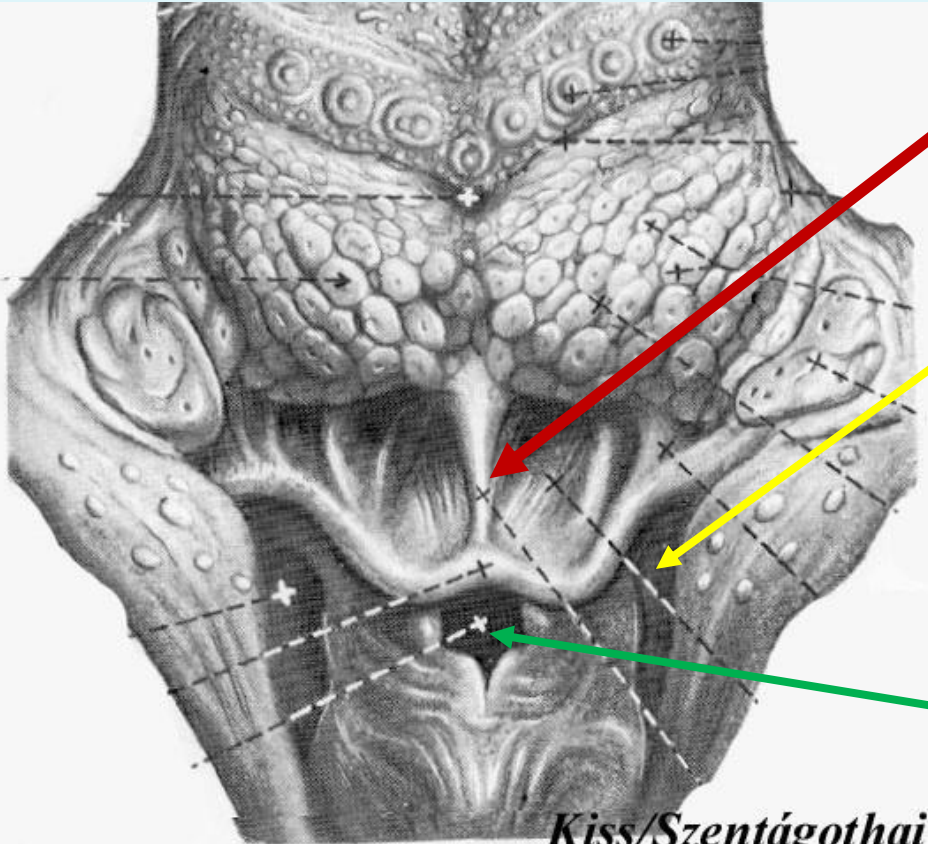
Lig. cornicopharyngeale

Proc. vocalis

Lig. vocale



# A GÉGEBEMENET



## EPIGLOTTIS

*Plica glossoepiglottica*  
*Vallecula epiglottica*

## RECESSUS PIRIFORMIS

*Plica n. laryngei sup.*

## ADITUS LARYNGIS HATÁRAI:

*Plica aryepiglottica*  
*Tuberculum cuneiforme*  
*Tuberculum corniculatum*  
*Incisura interarytenoidea*

Hámátmenet! - Több. el nem szarusodó laphám vs. légzőhám

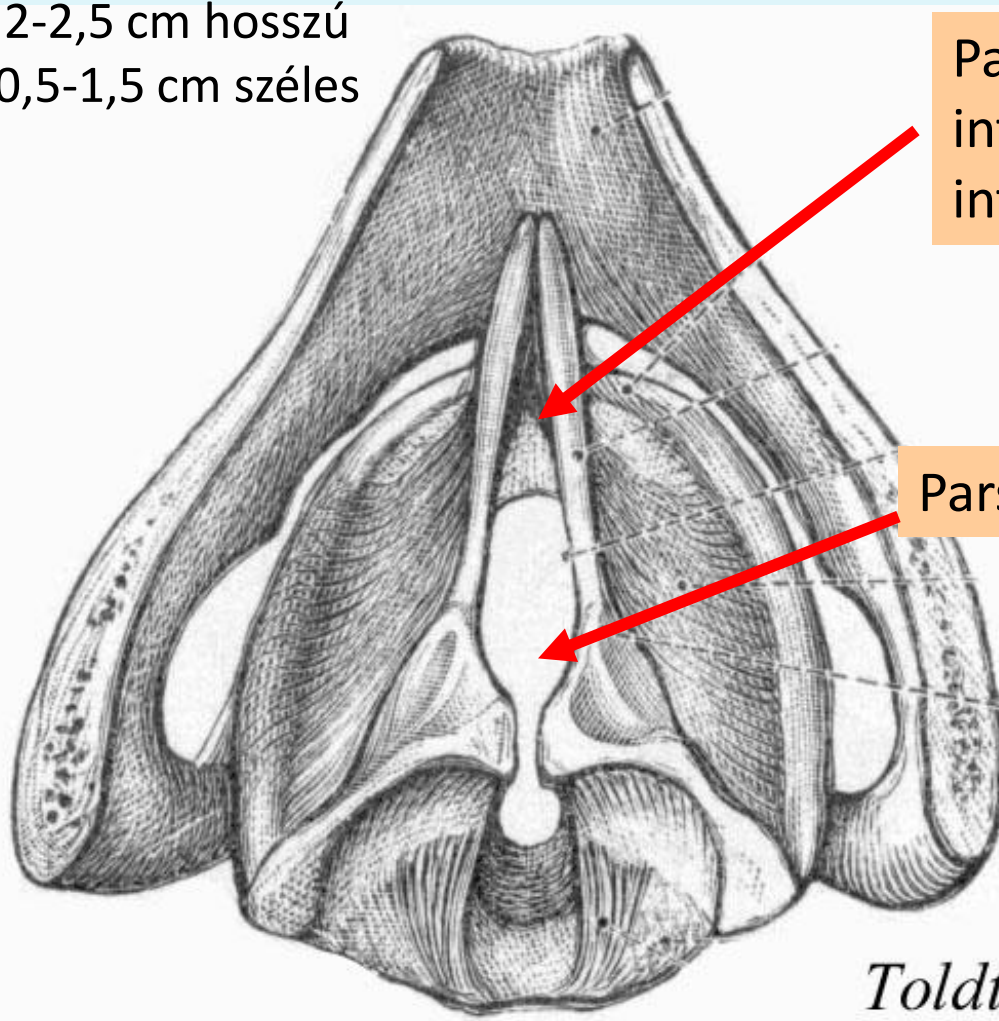
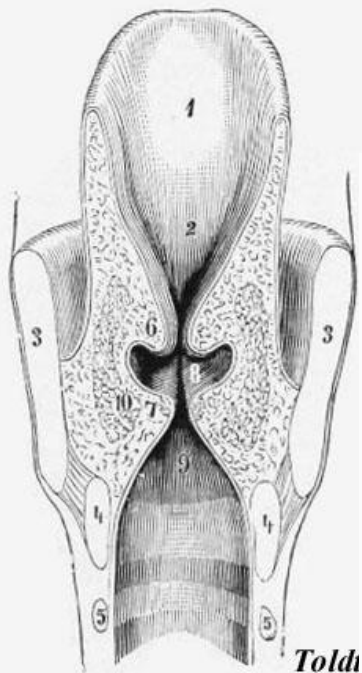
# HANGRÉS (RIMA GLOTTIDIS)

## RIMA GLOTTIDIS RÉSZEI ÉS HATÁRAI

**RAJZ!**

Rima glottidis

2-2,5 cm hosszú  
0,5-1,5 cm széles



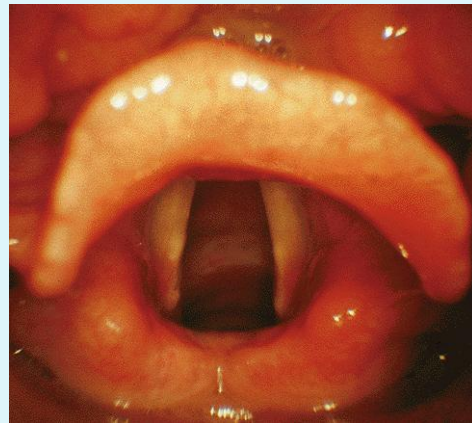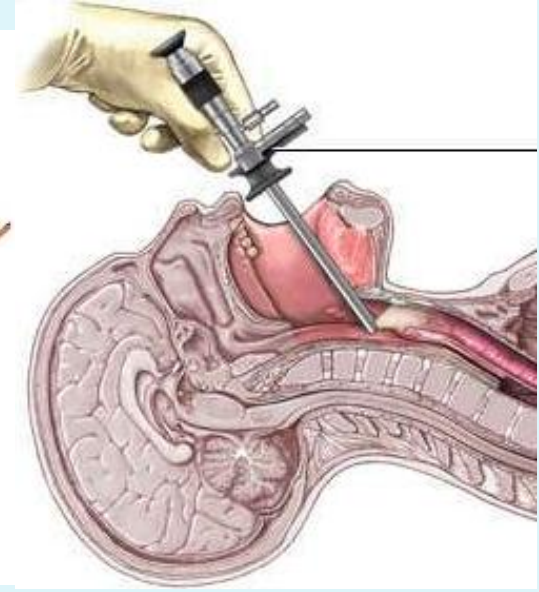
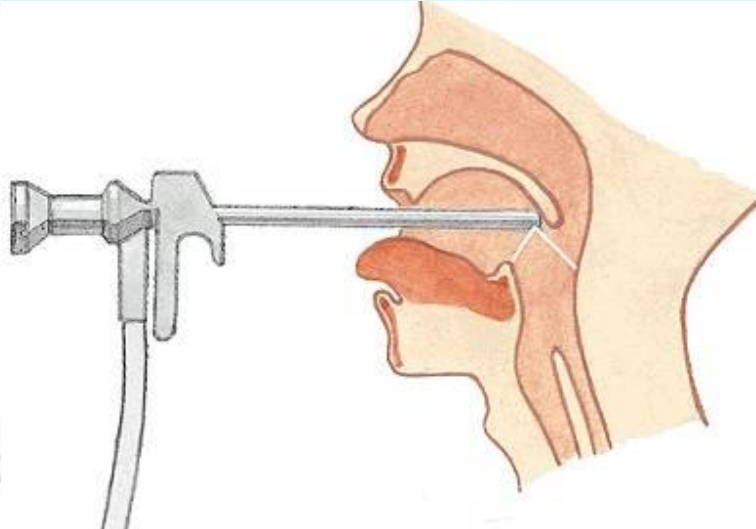
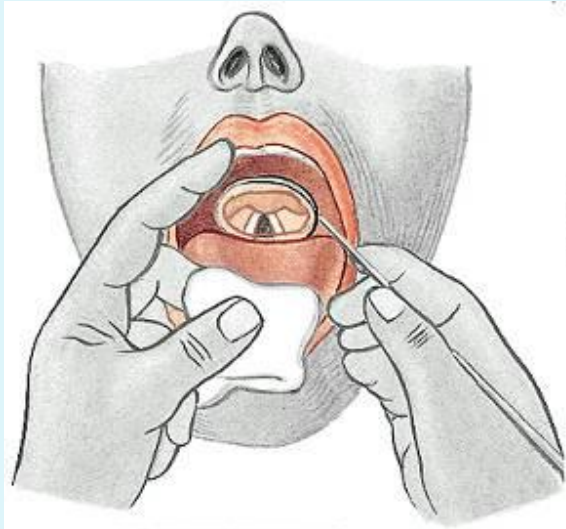
Pars  
intermembranacea/  
interligamentosa

Pars intercartilaginea

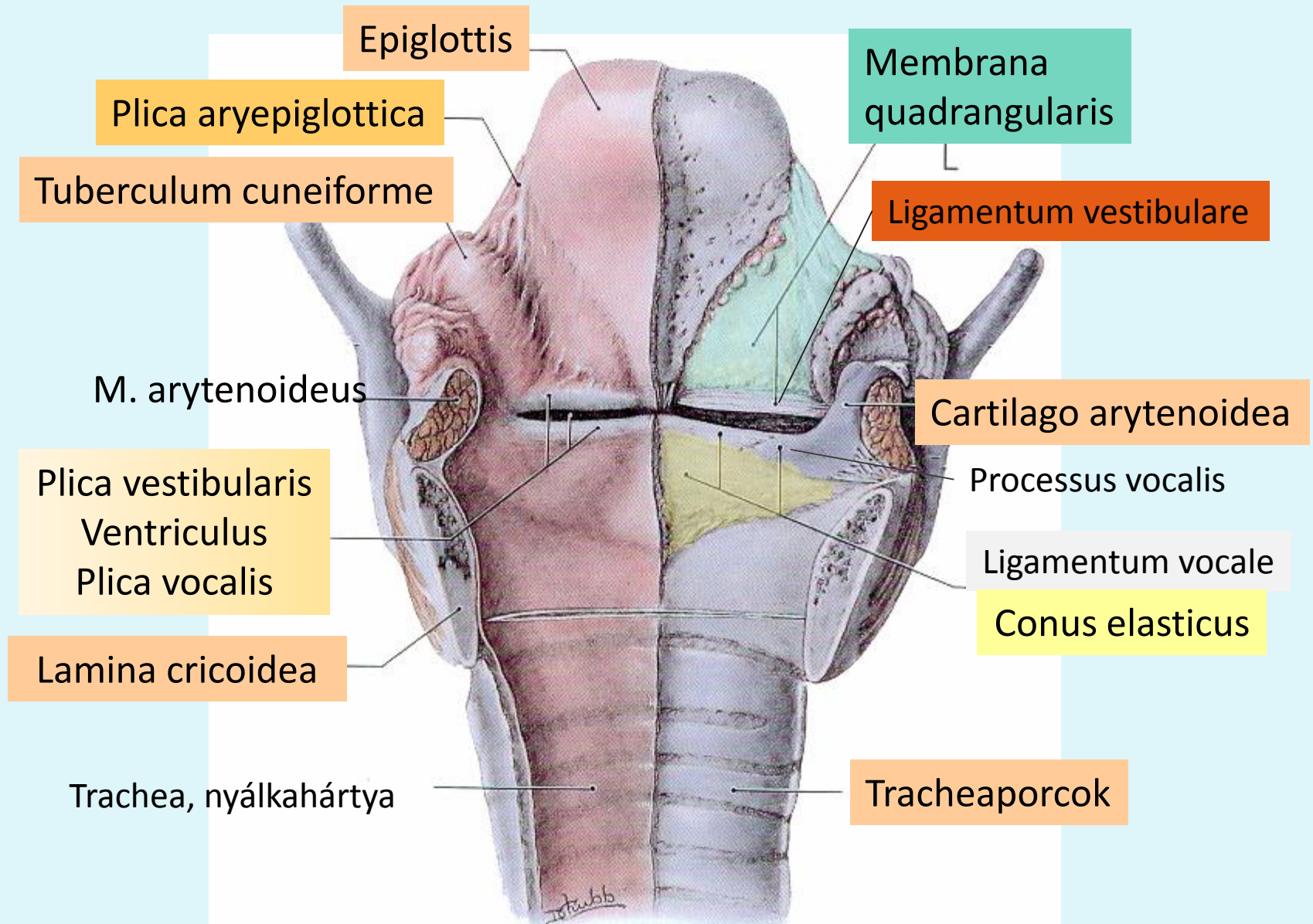
Toldt



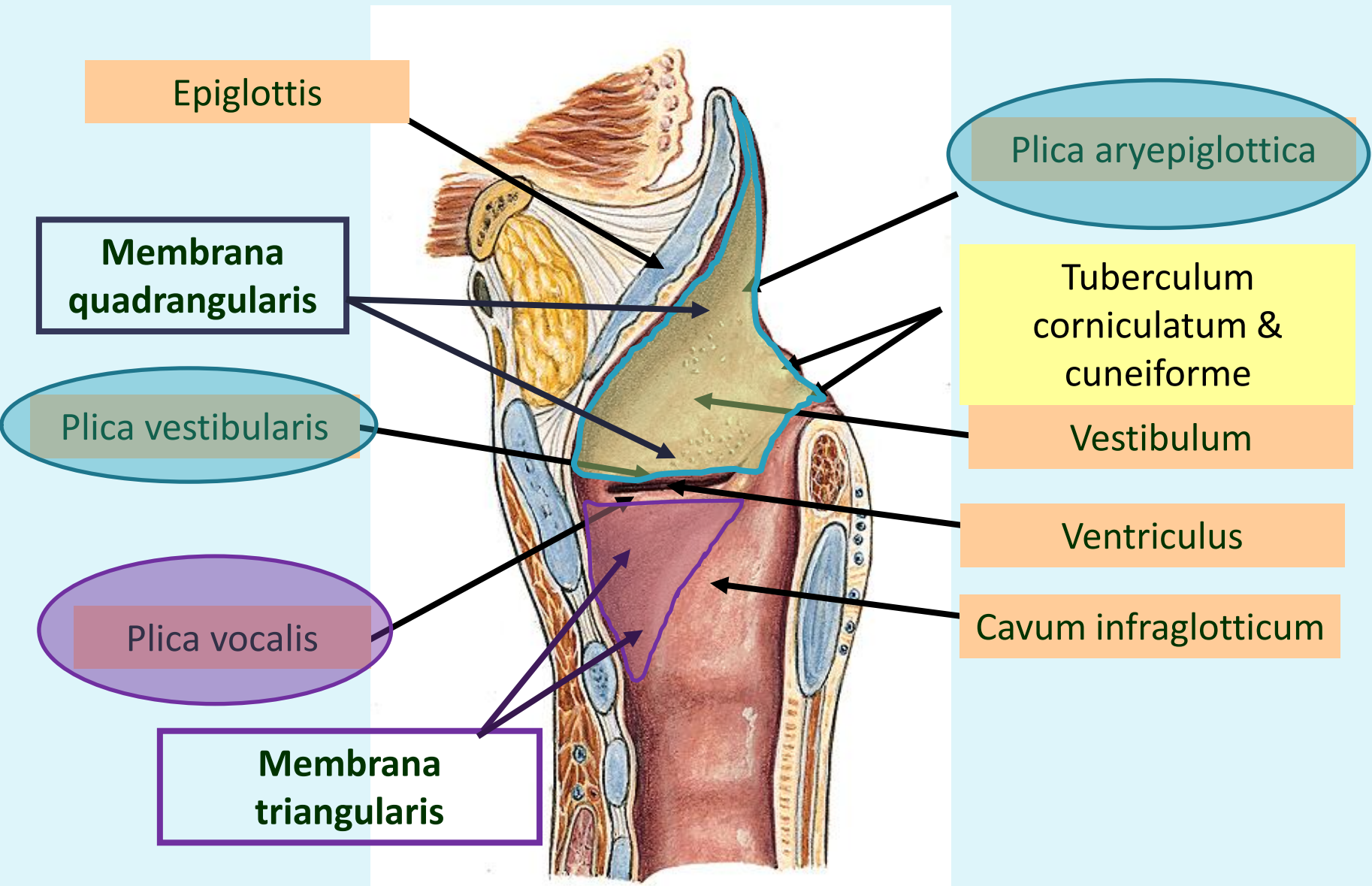
# LARYNGOSKOPIA



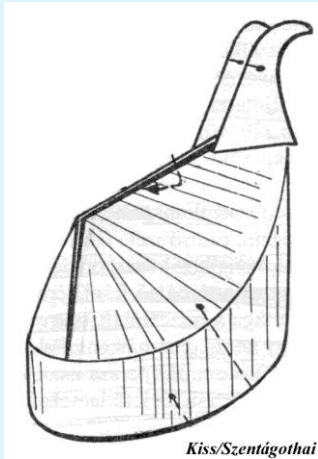
# A GÉGE FIBROELASTICUS MEMBRÁNRENDSZERE



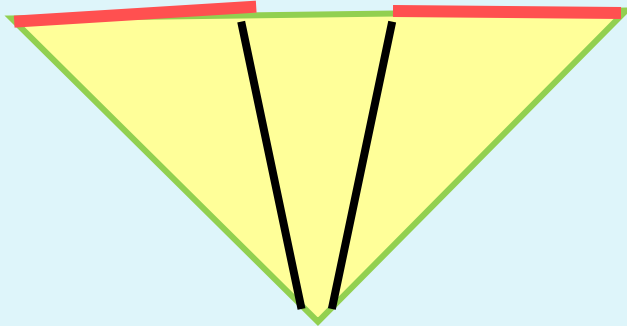
# A GÉGE FIBROELASTICUS MEMBRÁNRENDSZERE



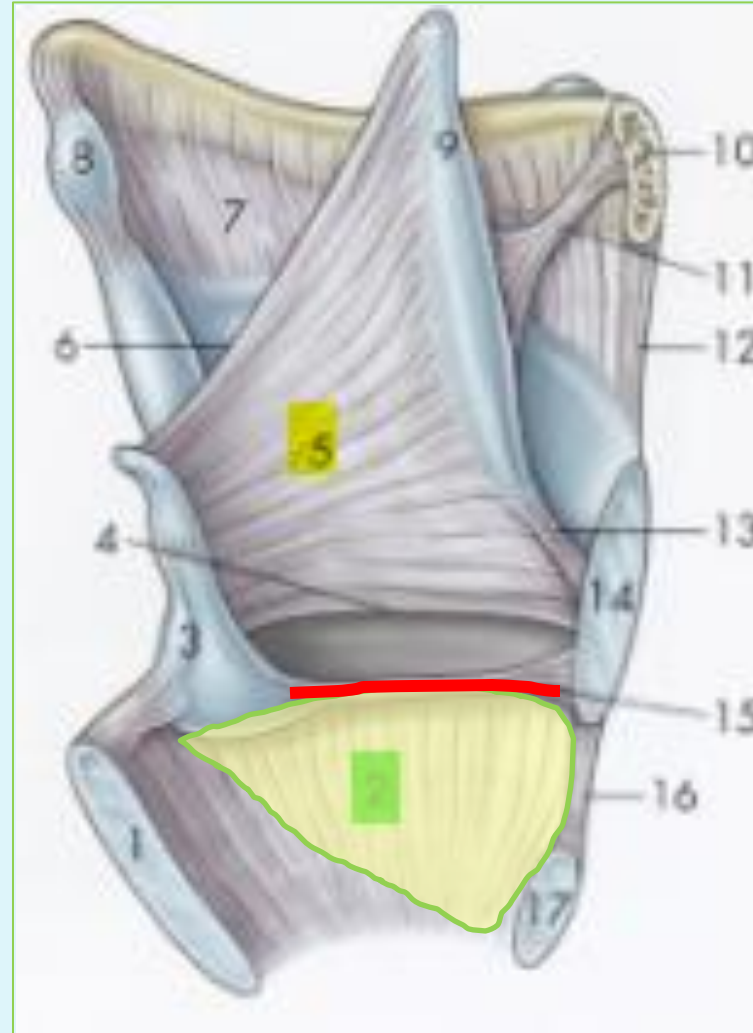# CONUS ELASTICUS



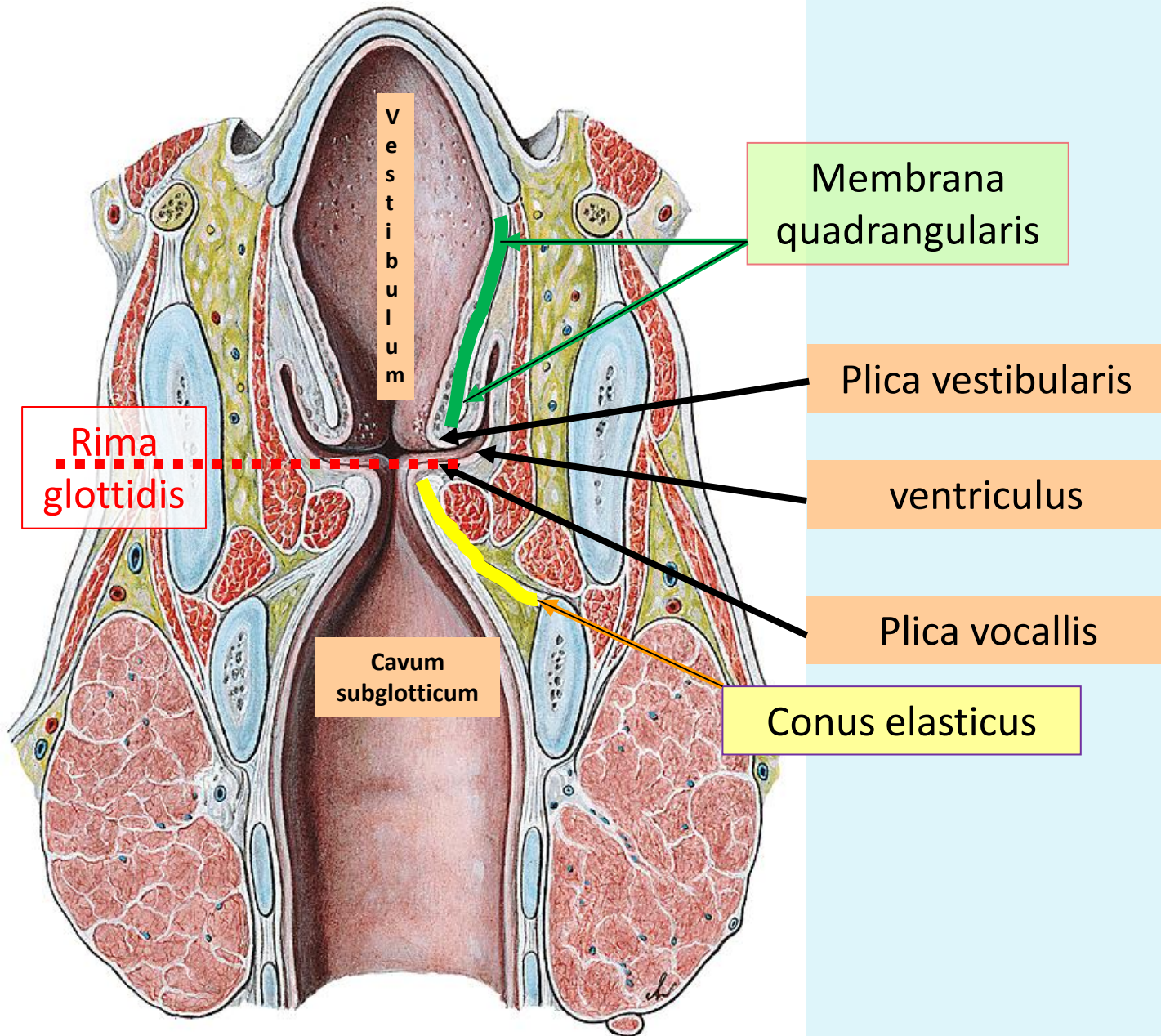
Ligamentum vocale



Membrana triangularis



# A GÉGE NYÁLKAHÁRTYÁJA



# A GÉGE SZÖVETTANA

## Vestibulum laryngis

### PLICA VESTIBULARIS

#### *légzőhám*

Laza ksz. (! *Glottis oedema* !)

Kevert mirigyek

Membrana quadrangularis

*MALT vagy elszórtan nyiroktüszők*

### PLICA VOCALIS

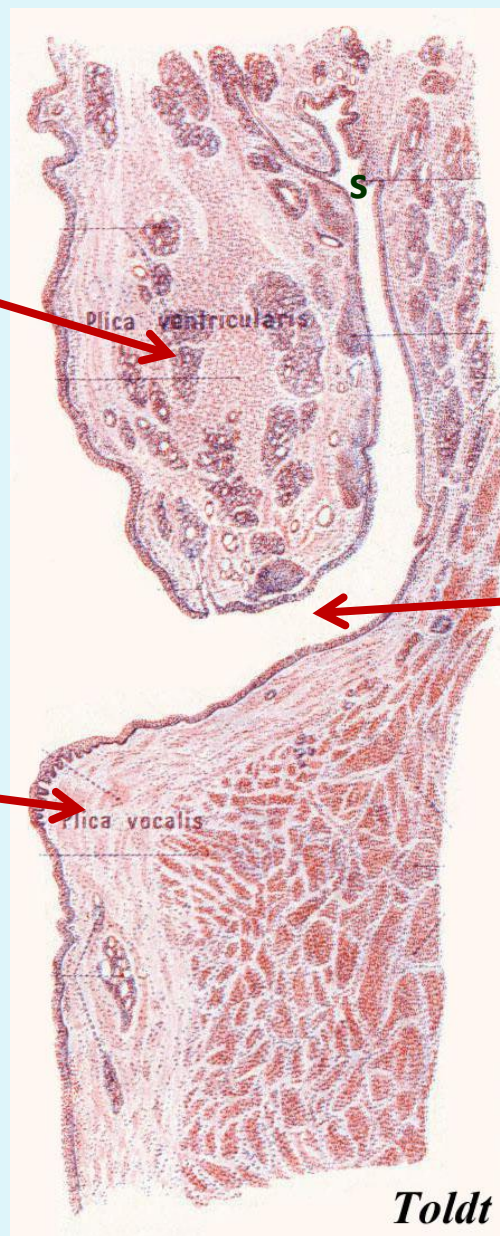
#### *Többrétegű el nem szarusodó laphám*

A hám szorosan kapcsolódik a plica vocalishoz

Mirigyek nincsenek

Benne nagy h.csíktolt izom (m. vocalis)

Membrana triangularis



### Sacculus

A ventriculus kiöblösödése  
(hangképzésben szerep)

### VENTRICULUS

*Toldt*

# BEIDEGZÉS ÉS VÉRELLÁTÁS

## N. Laryngeus sup. (N. X.)

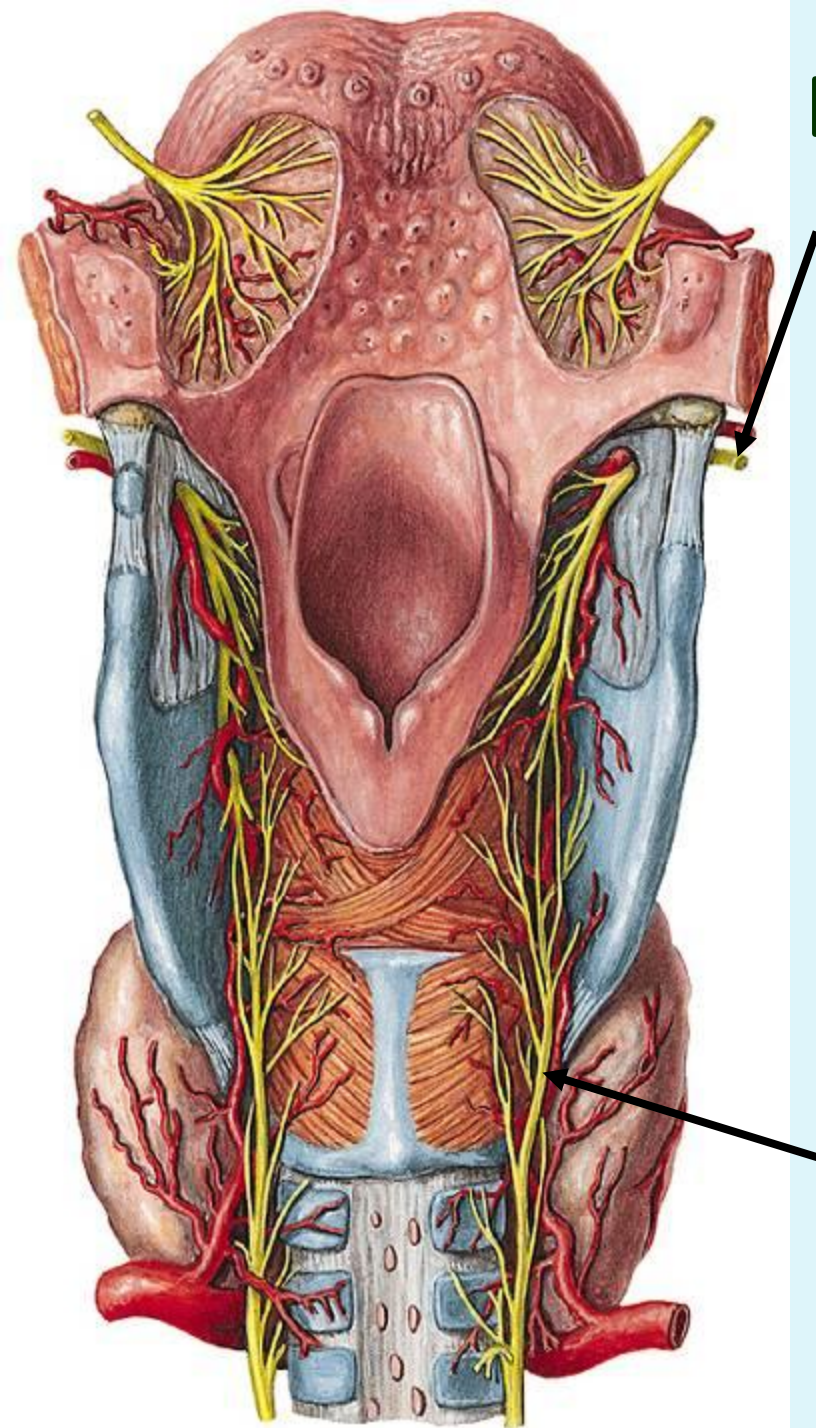
- m. cricothyroideus (mozgató)
- vestibulum nyh.-ja (érző)

a. laryngea sup.      **A. carotis ext.-ből**  
(a. thyroidea sup. ága)

a. laryngea inf.      **A. subclaviából**  
(a. thyroidea inf. ága)

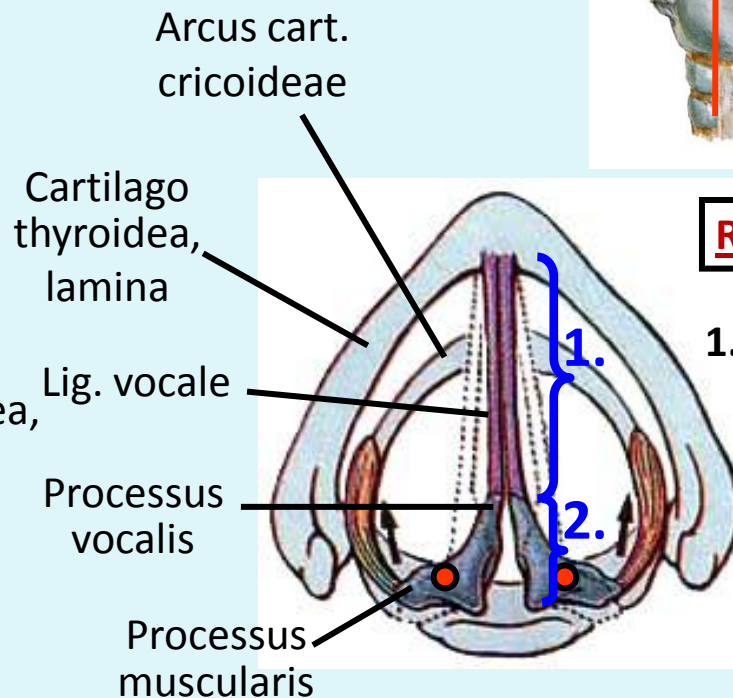
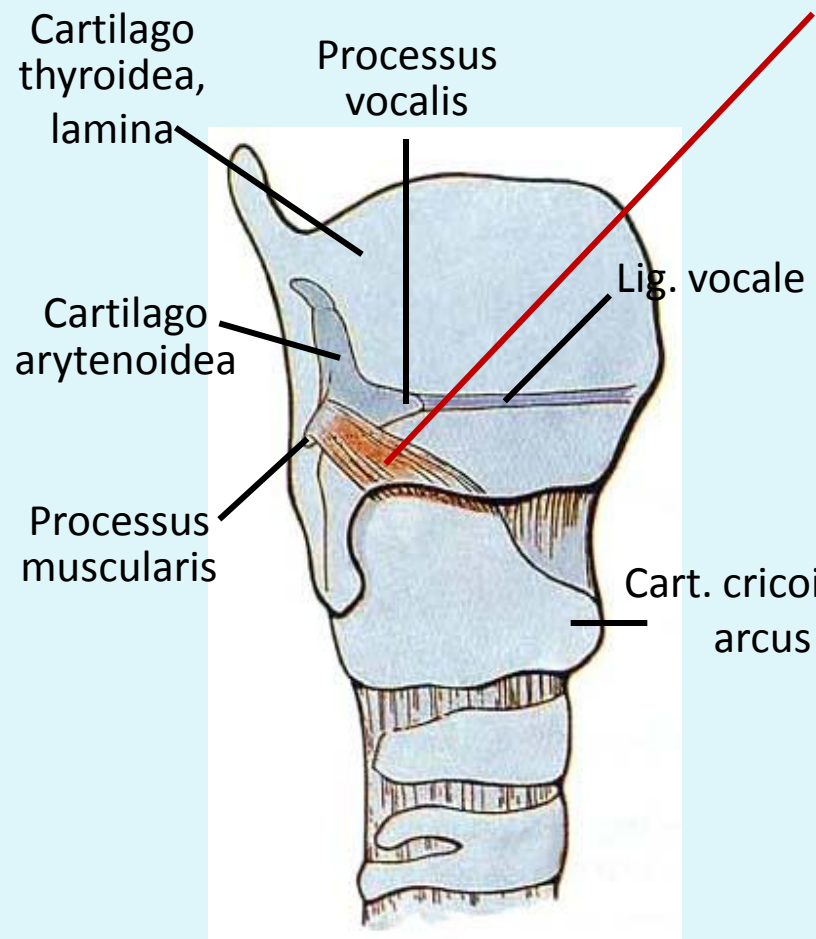
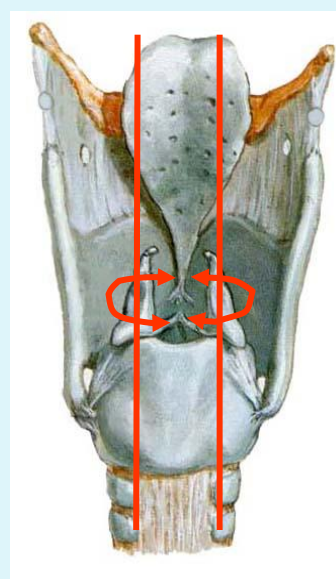
## n. laryngeus recurrens (N.X.)

- összes belső gégeizom (mozgató)
- nyh. a rima glottidis alatt (érző)



# GÉGEIZMOK

## M. CRICOARYTENOIDEUS LAT.



**Rima glottidis**

- 1. Pars intermembranacea
- 2. Pars intercartilaginea

**EREDÉS:** cart. cricoidea, arcus (felső oldalsó szél)

**TAPADÁS:** cart. arytenoidea, proc. muscularis

**ZÁRJA A RIMA GLOTTIDIS-T  
(a pars intermembranaceat)**

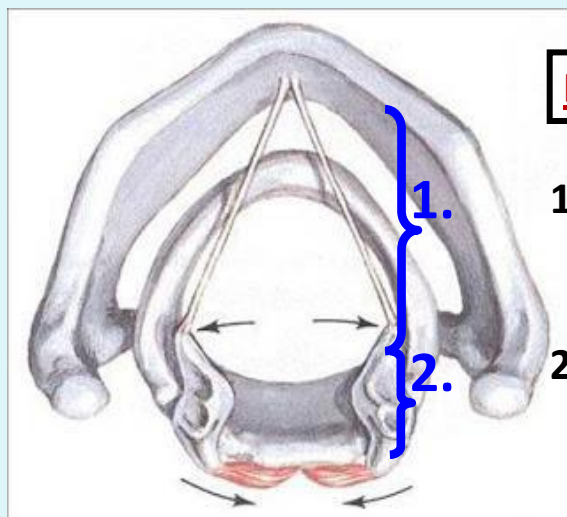
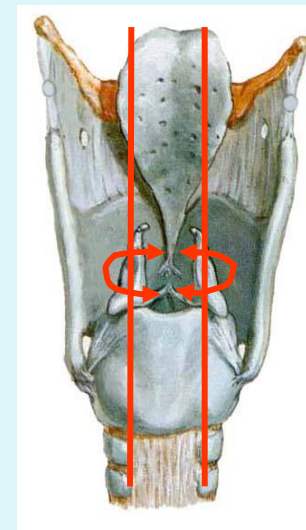
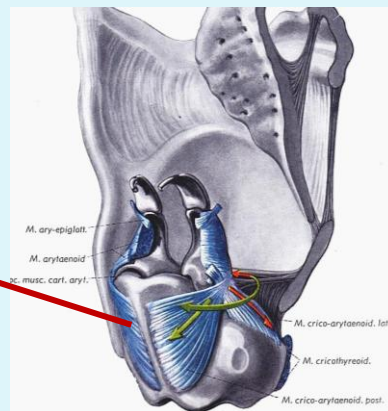


# GÉGEIZMOK

## M. CRICOARYTENOIDEUS POSTERIOR „POSTICUS”

**EREDÉS** cart. cricoidea, lamina

**TAPADÁS** cart. arytenoidea, proc. muscularis

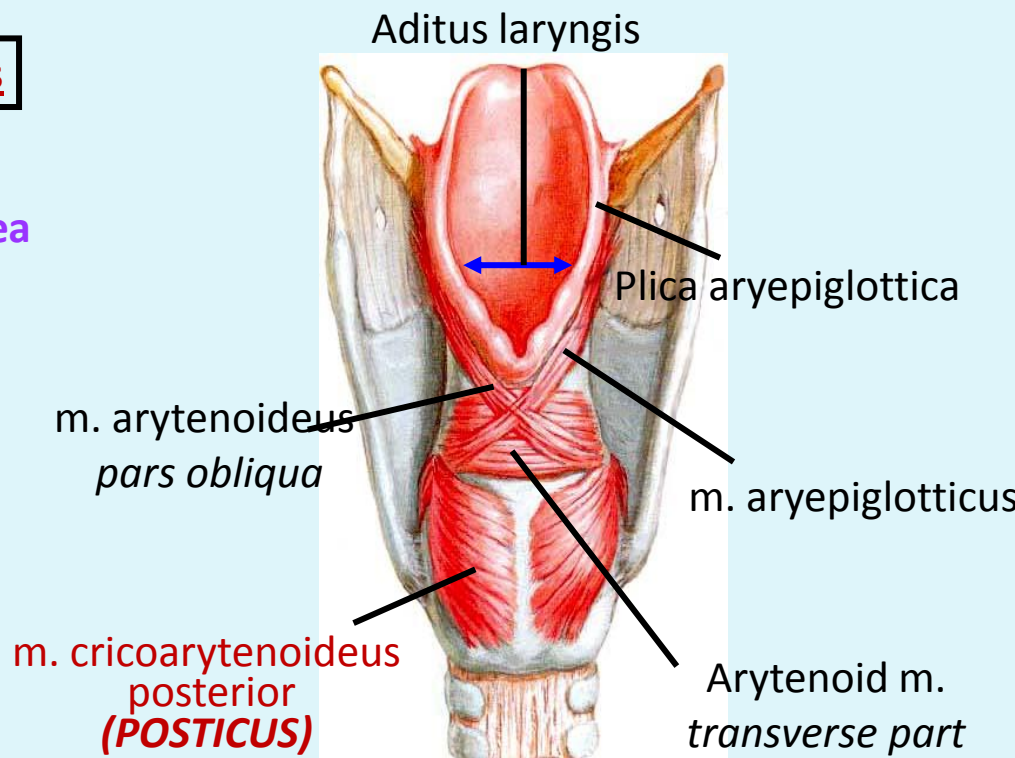


### Rima glottidis

1. Pars intermembranacea

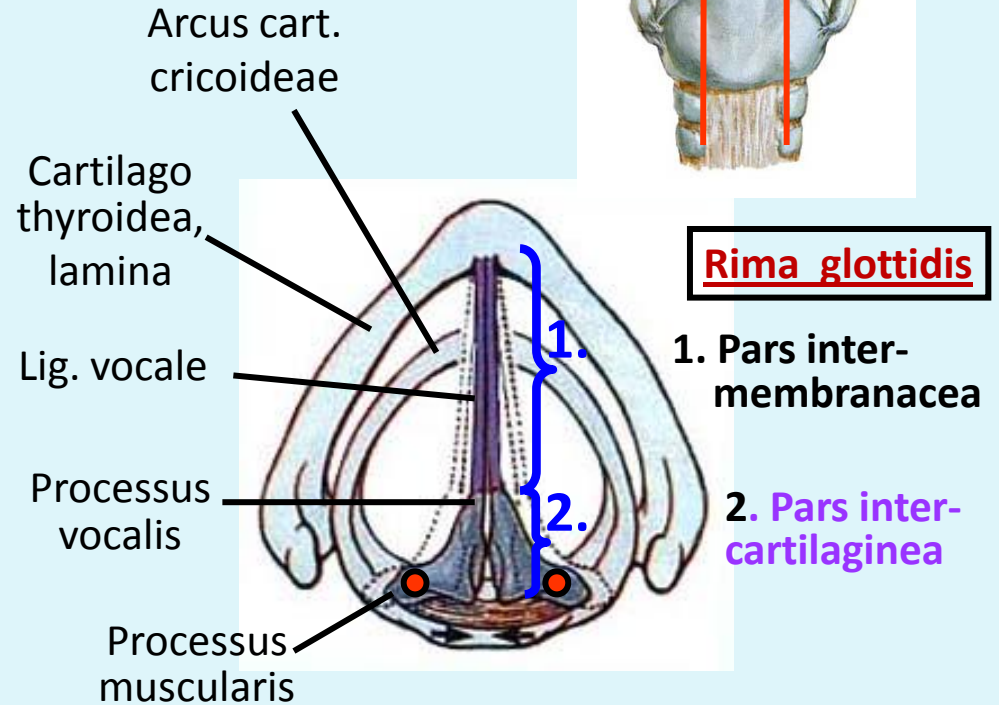
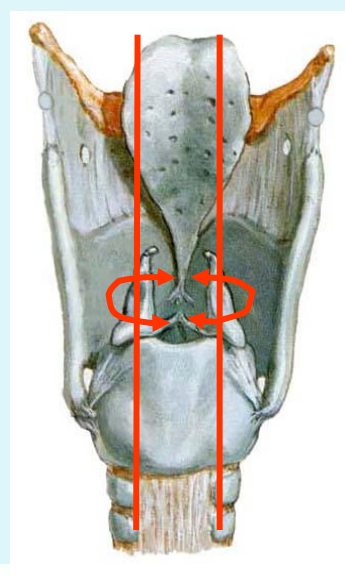
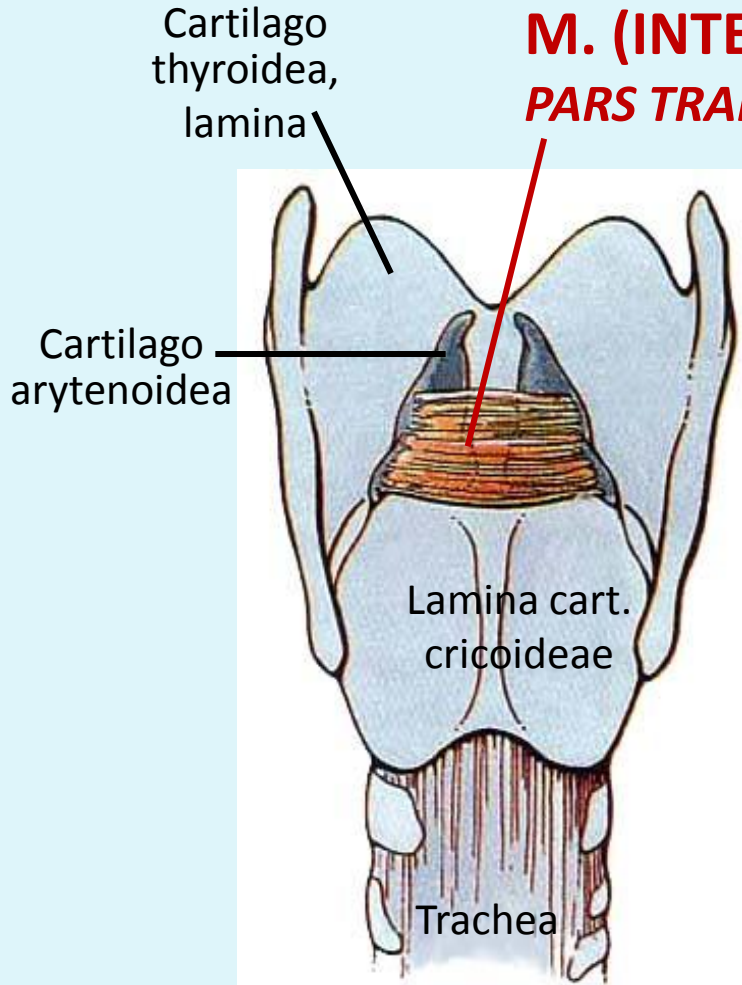
2. Pars intercartilaginea

**A RIMA GLOTTIDIS  
EGYETLEN NYITÓJA!**



# GÉGEIZMOK

## M. (INTER)ARYTENOIDEUS PARS TRANSVERSA

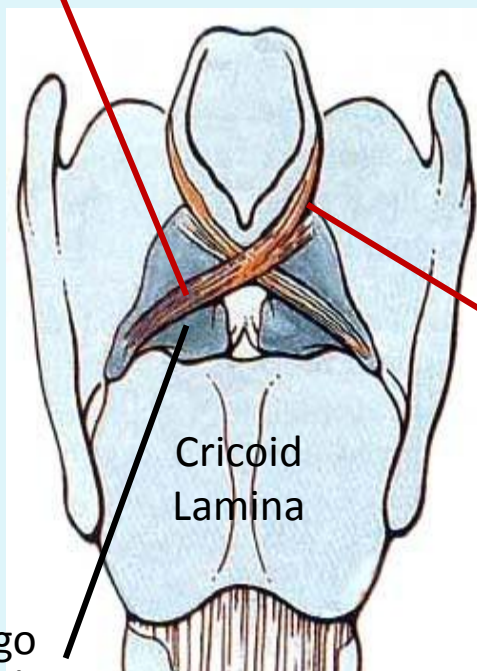


**EREDÉS:** }  
**TAPADÁS:** } Cart. arytenoidea post. részén

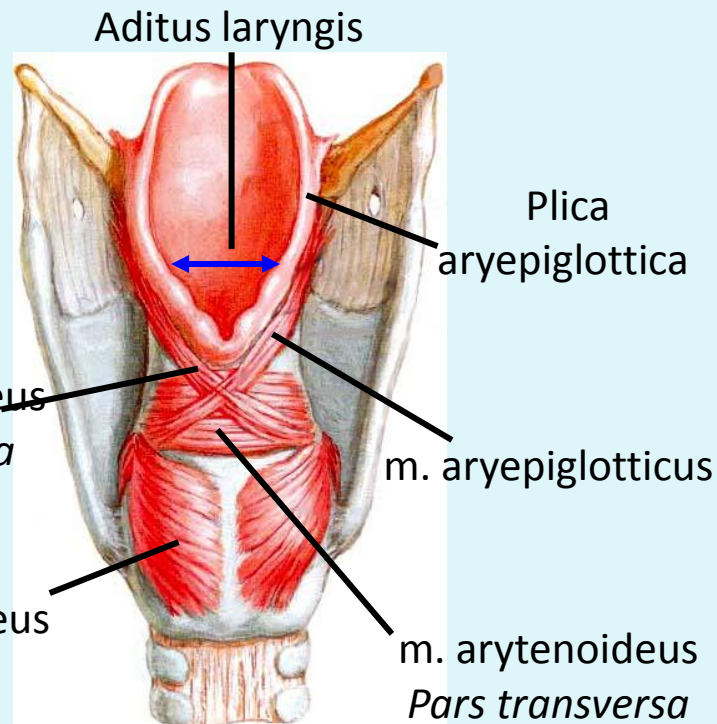
**ZÁRJA A RIMA GLOTTIDIS-T  
(A pars intercartilaginea-t)**

# GÉGEIZMOK

## M. (INTER)ARYTENOIDEUS PARS OBLIQUA



**ZÁRJA A RIMA GLOTTIDIS-T  
(A pars intercartilaginea-t)**



## M. ARYEPIGLOTTICUS

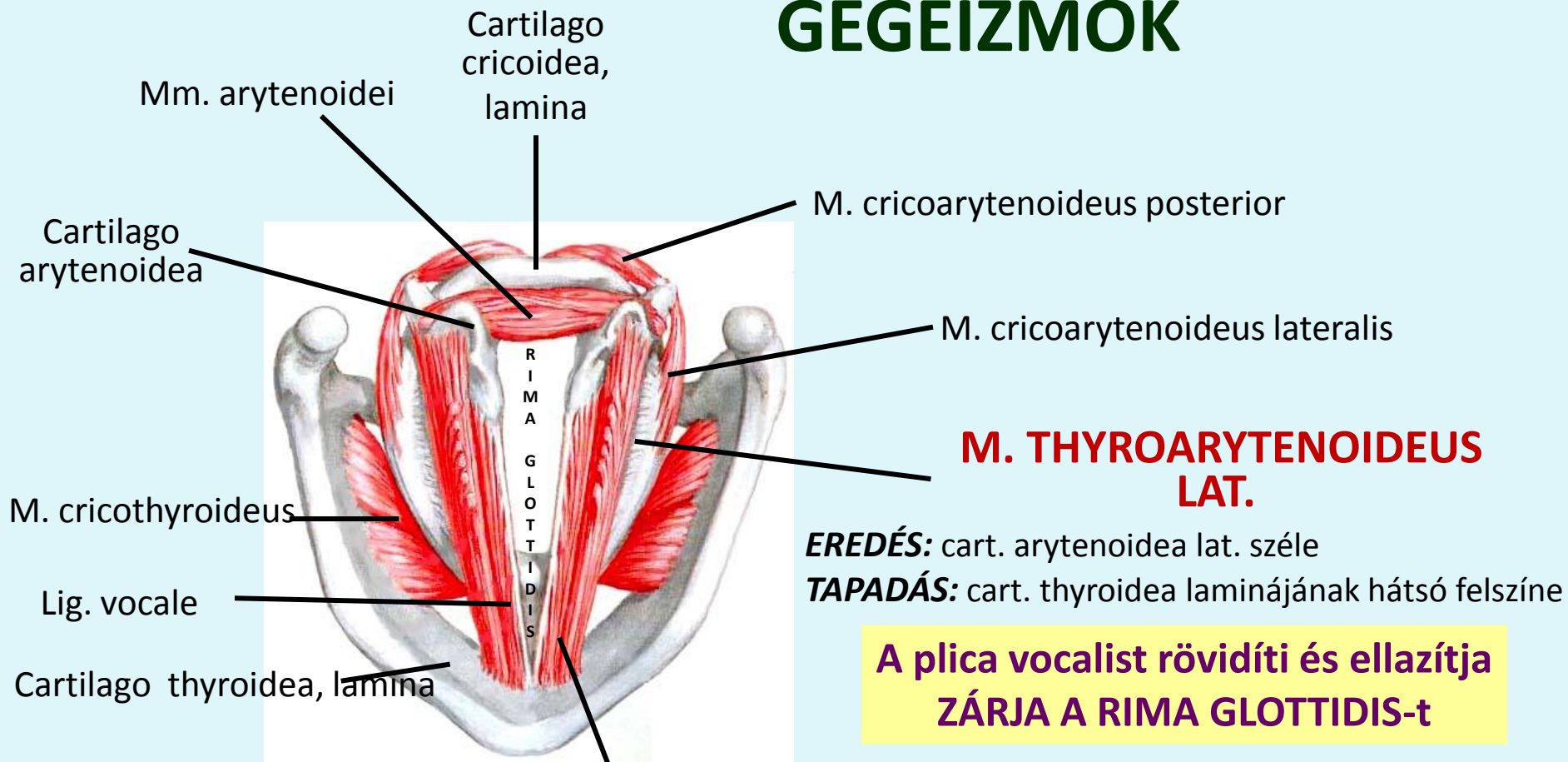
**EREDÉS:** a m. arytenoideus obl. folytatása

**TAPADÁS:** plica aryepiglottica



**Lefele húzza az epiglottist,  
szűkíti a gégét**

# GÉGEIZMOK



## M. VOCALIS

(MM THYROARYTENOIDEUS MED.)

**EREDÉS:** cartilago arytenoidea anterolat. felszíne

**INSERTION:** lamina cartilaginis thyroideae, hátsó felszín

**Kitölti a plica vocalist**

**Összehúzódva a plica vocalis megfeszül és a hangszalag jobban rezeg**

## M. THYROARYTENOIDEUS LAT.

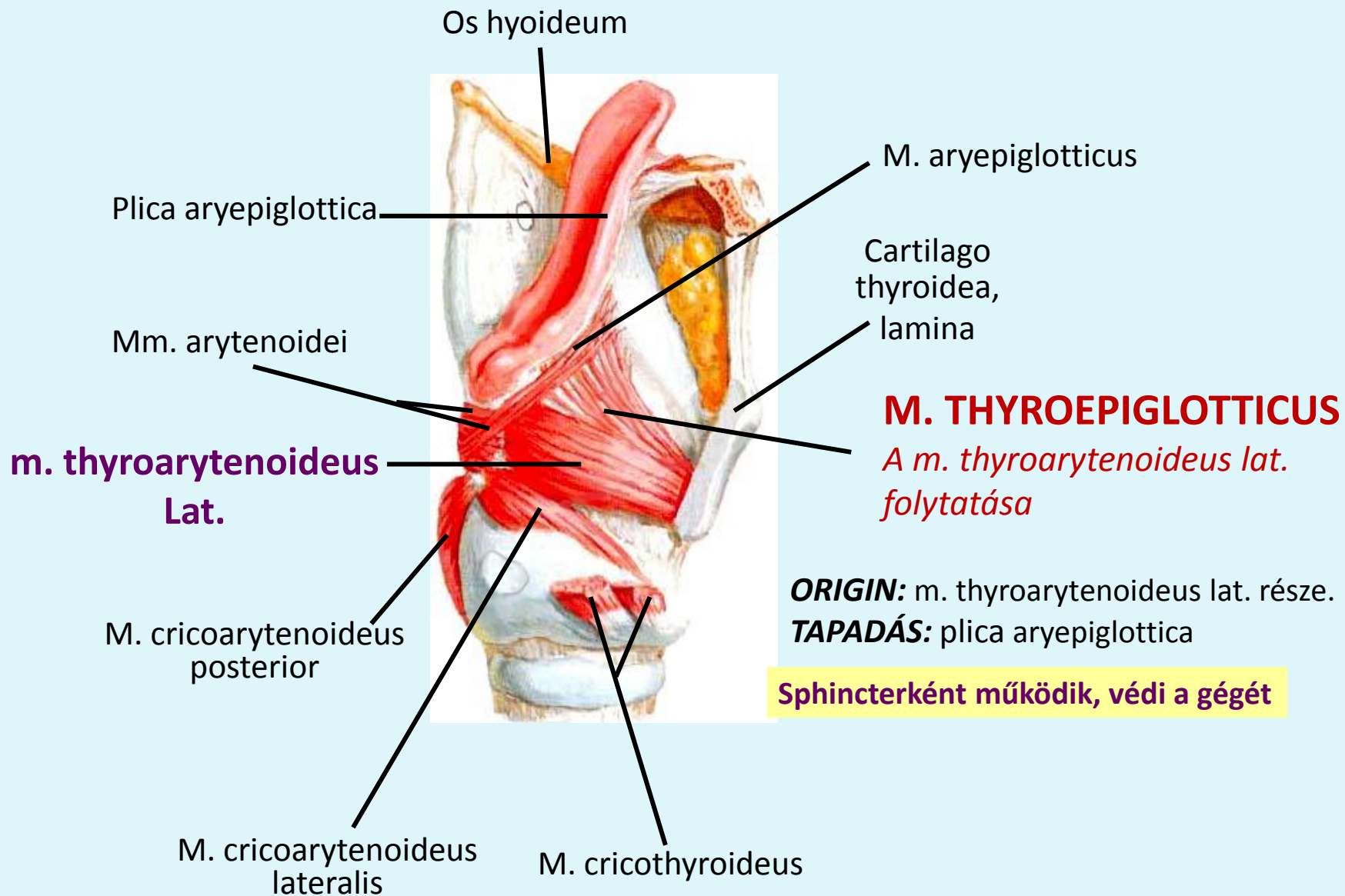
**EREDÉS:** cart. arytenoidea lat. széle

**TAPADÁS:** cart. thyroidea laminájának hátsó felszíne

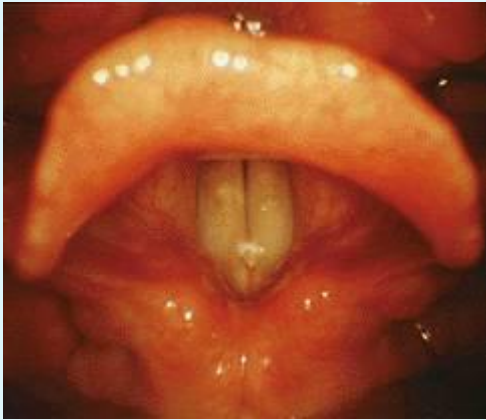
**A plica vocalist rövidíti és ellazítja  
ZÁRJA A RIMA GLOTTIDIS-t**

**ZÁRJA A RIMA GLOTTIDIS-t  
(A pars intermembranacea-t)**

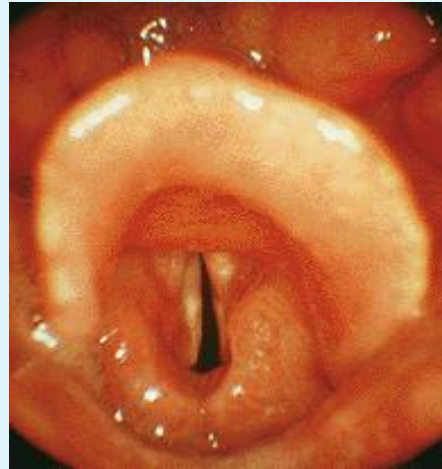
# GÉGEIZMOK



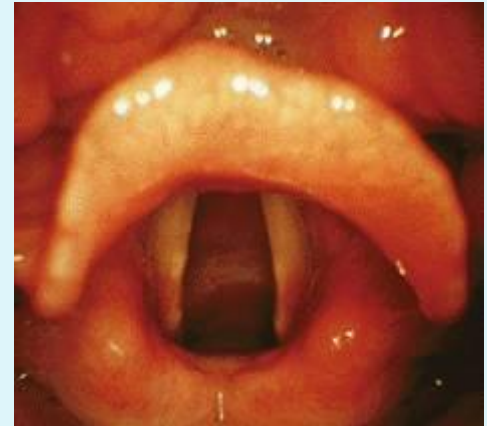# LARYNGOSCOPIA



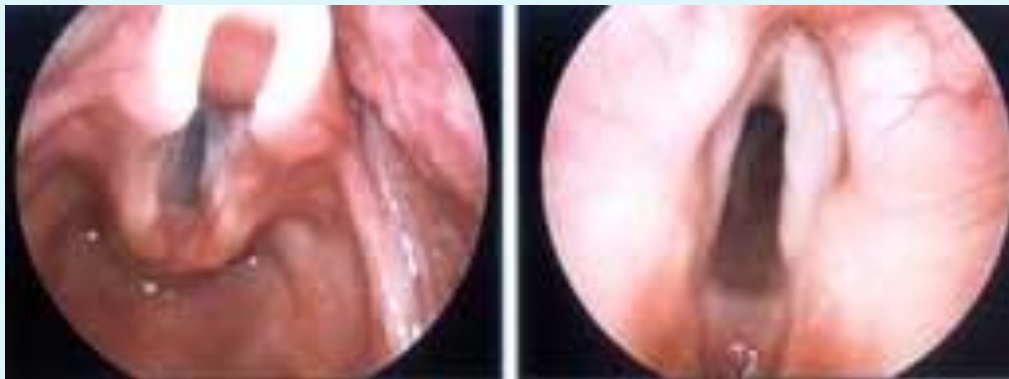Normál beszéd  
*rima glottidis* zárva



suttogás

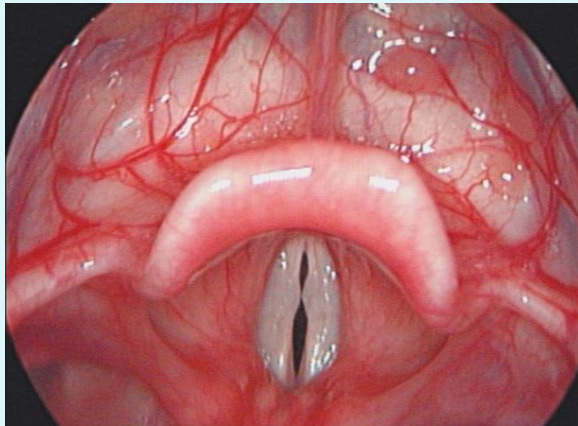


Maximum belégzés  
*rima glottidis* nyitva

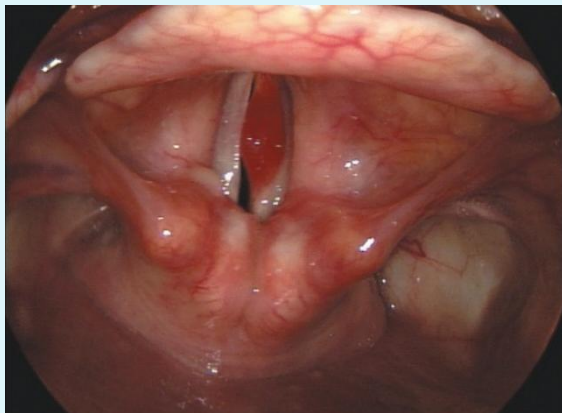
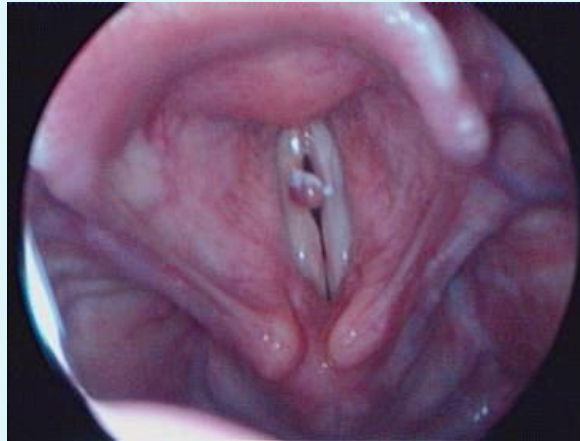

Phonation position

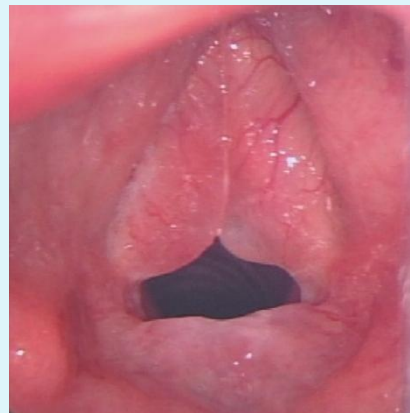# PATOLÓGIÁS ELVÁLTOZÁSOK



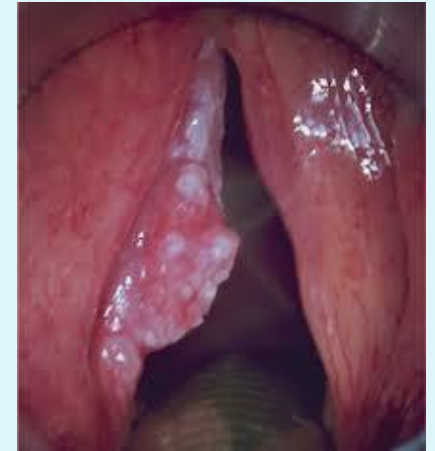hangszalag-csomó = Fibroma



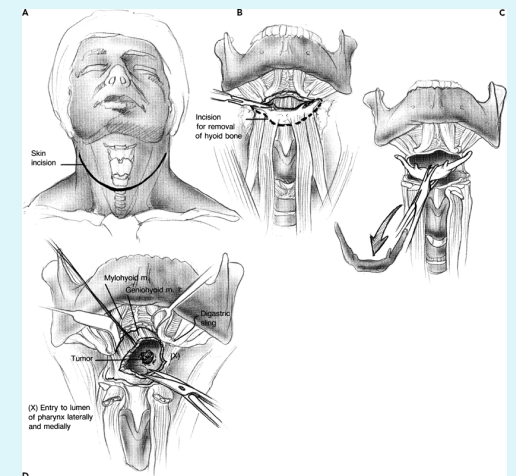
Polypus



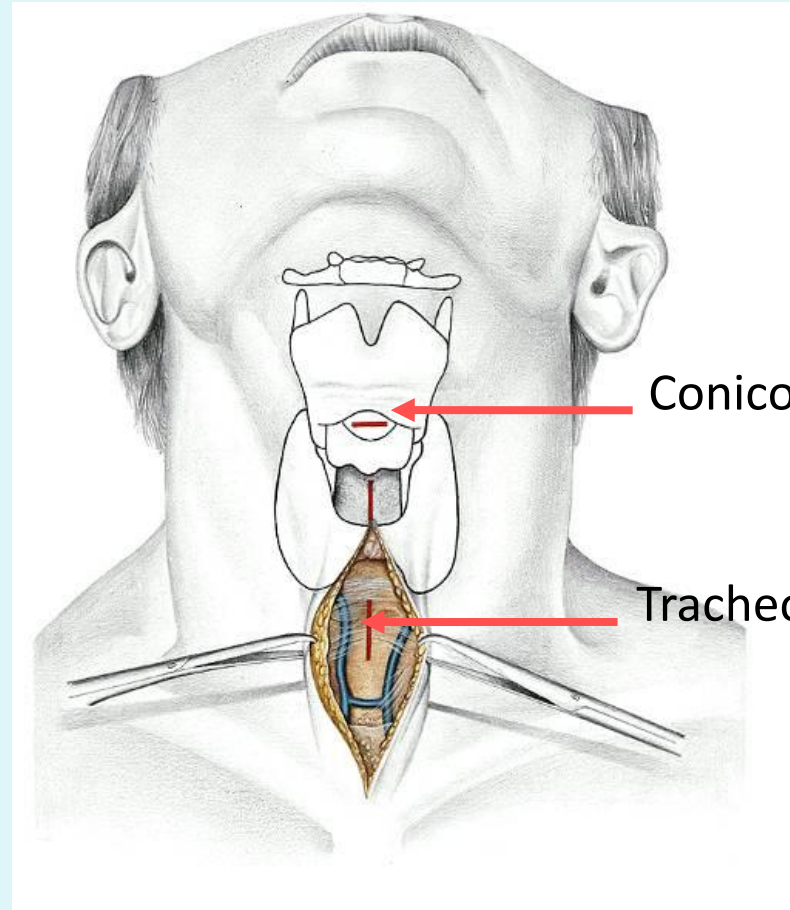
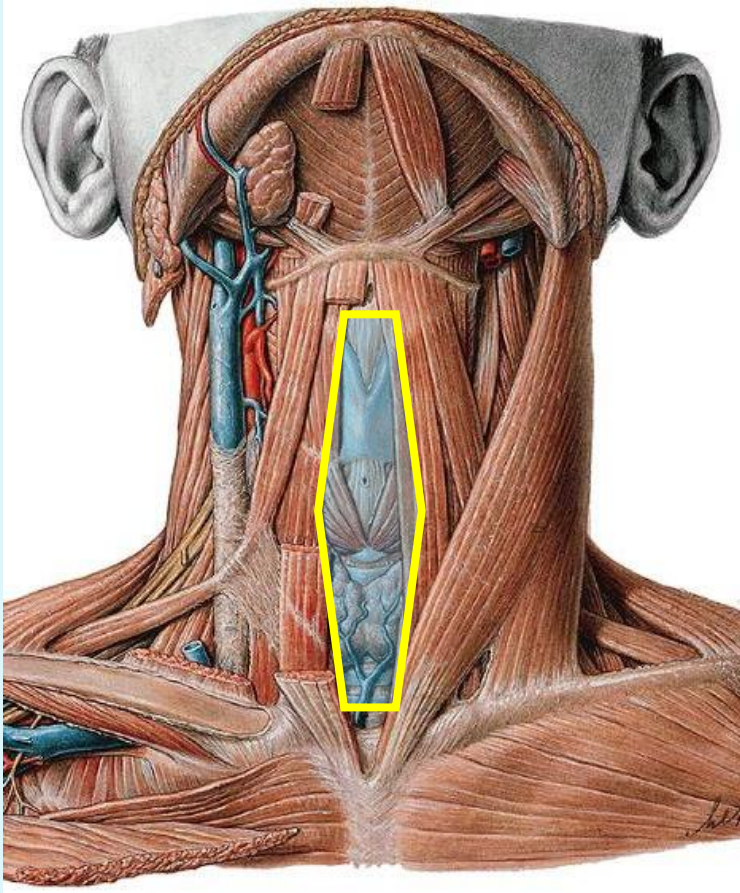
Reinke ödéma  
(krónikus gyulladás)



gégerák

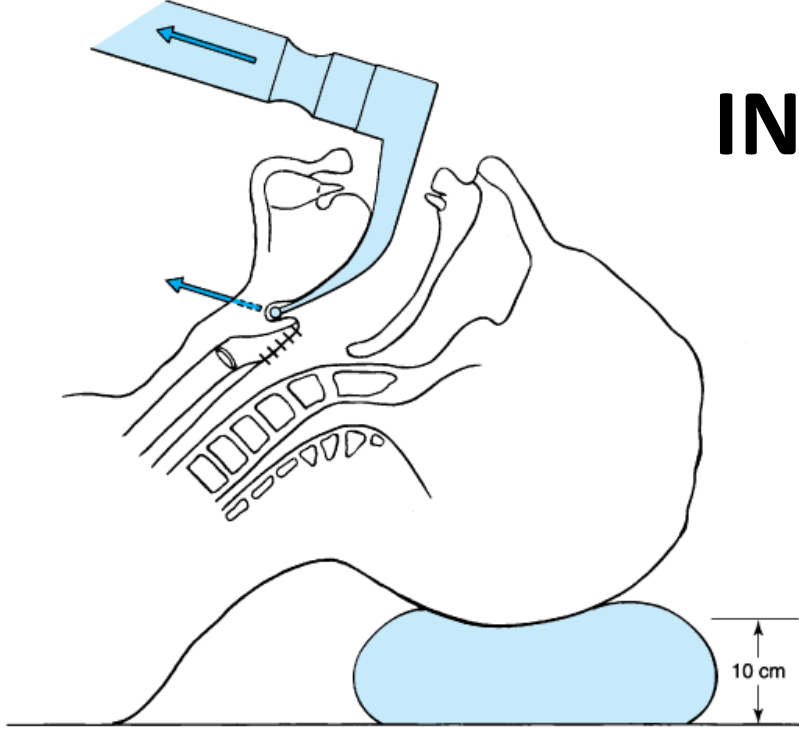


# REGIO COLLI MEDIANA

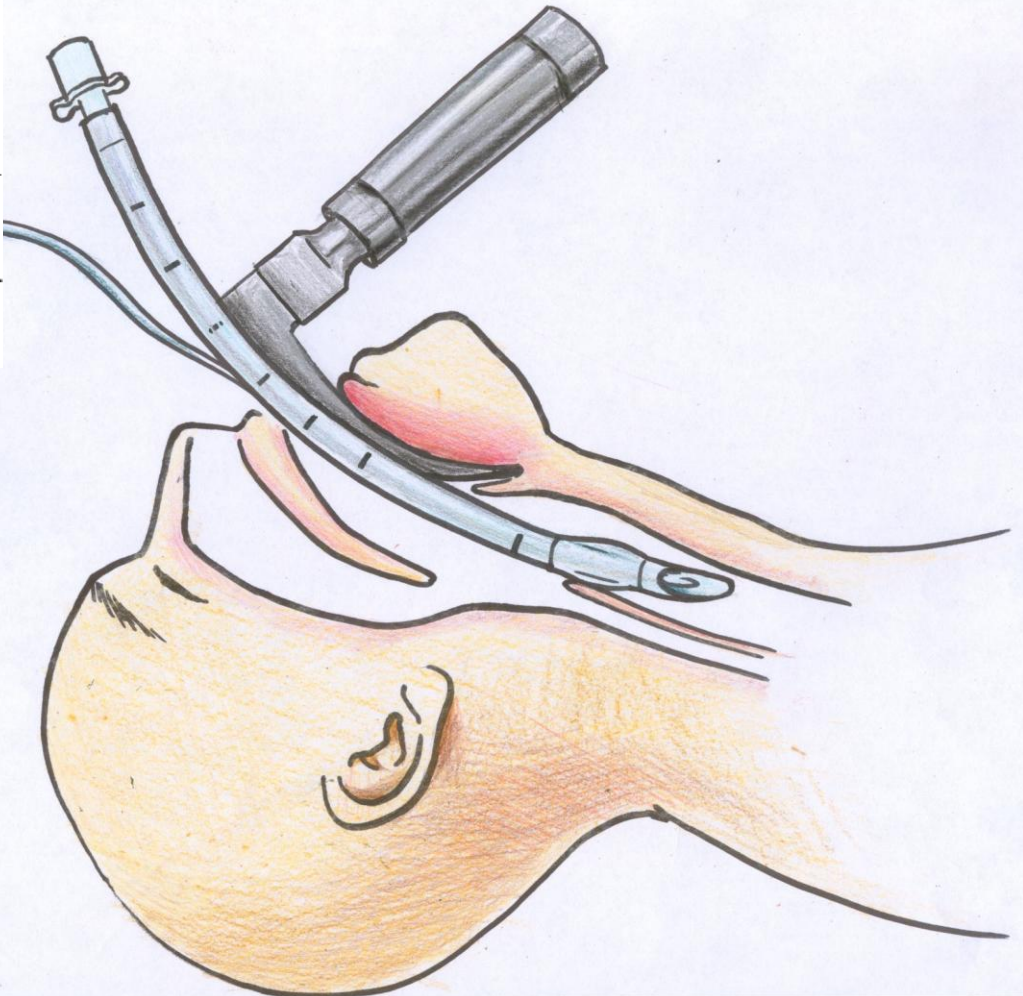




# INTUBATIO



Copyright ©2006 by The McGraw-Hill Companies, Inc.  
All rights reserved.



***Köszönöm a figyelmet!***

<https://www.youtube.com/watch?v=-XGds2GAvGQ>