



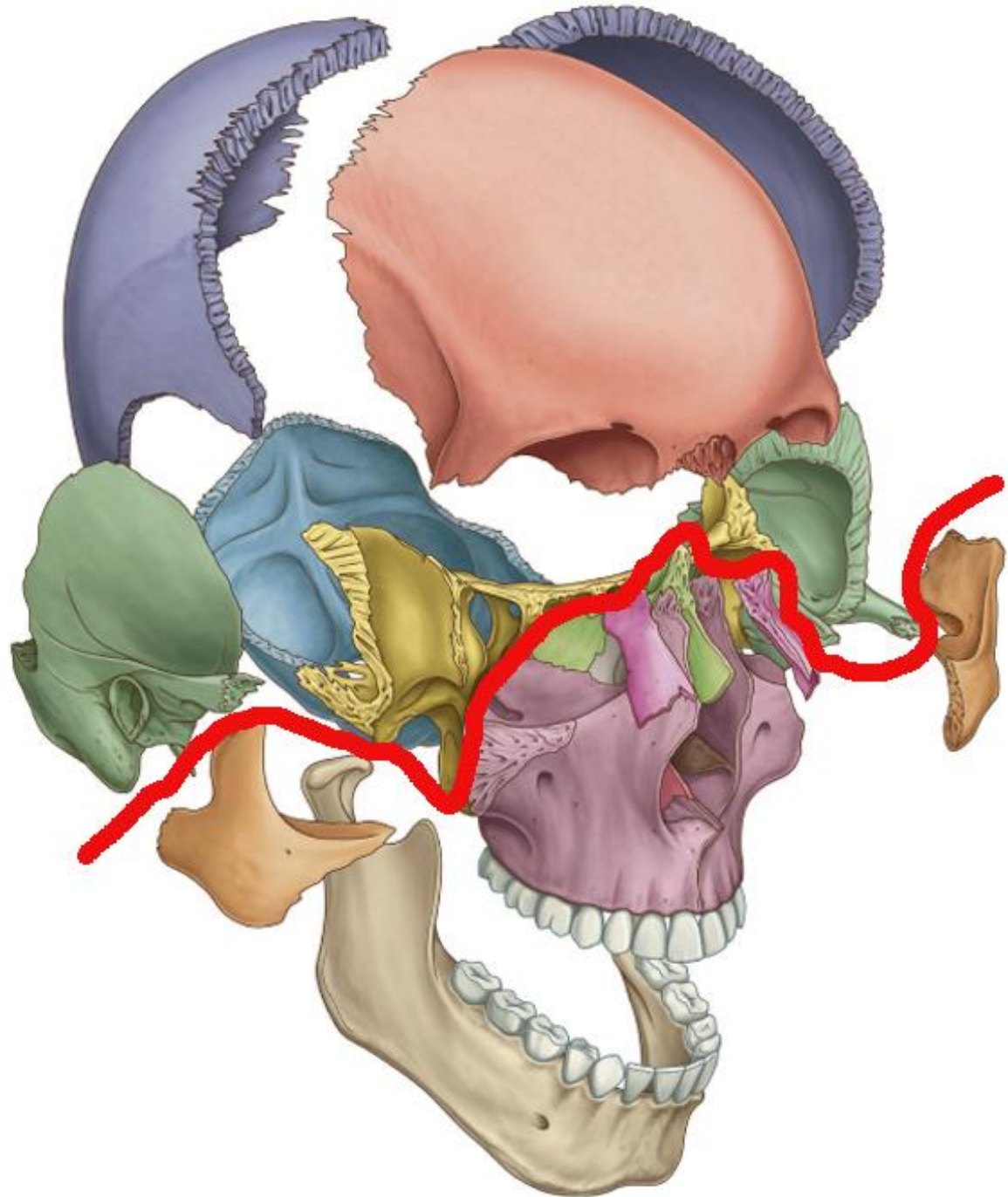
Viscerocranium és térségei az a. carotis
externa és n. trigeminus ágaiival

Dr. Katz Sándor Ph.D.

A

Viscerocranium

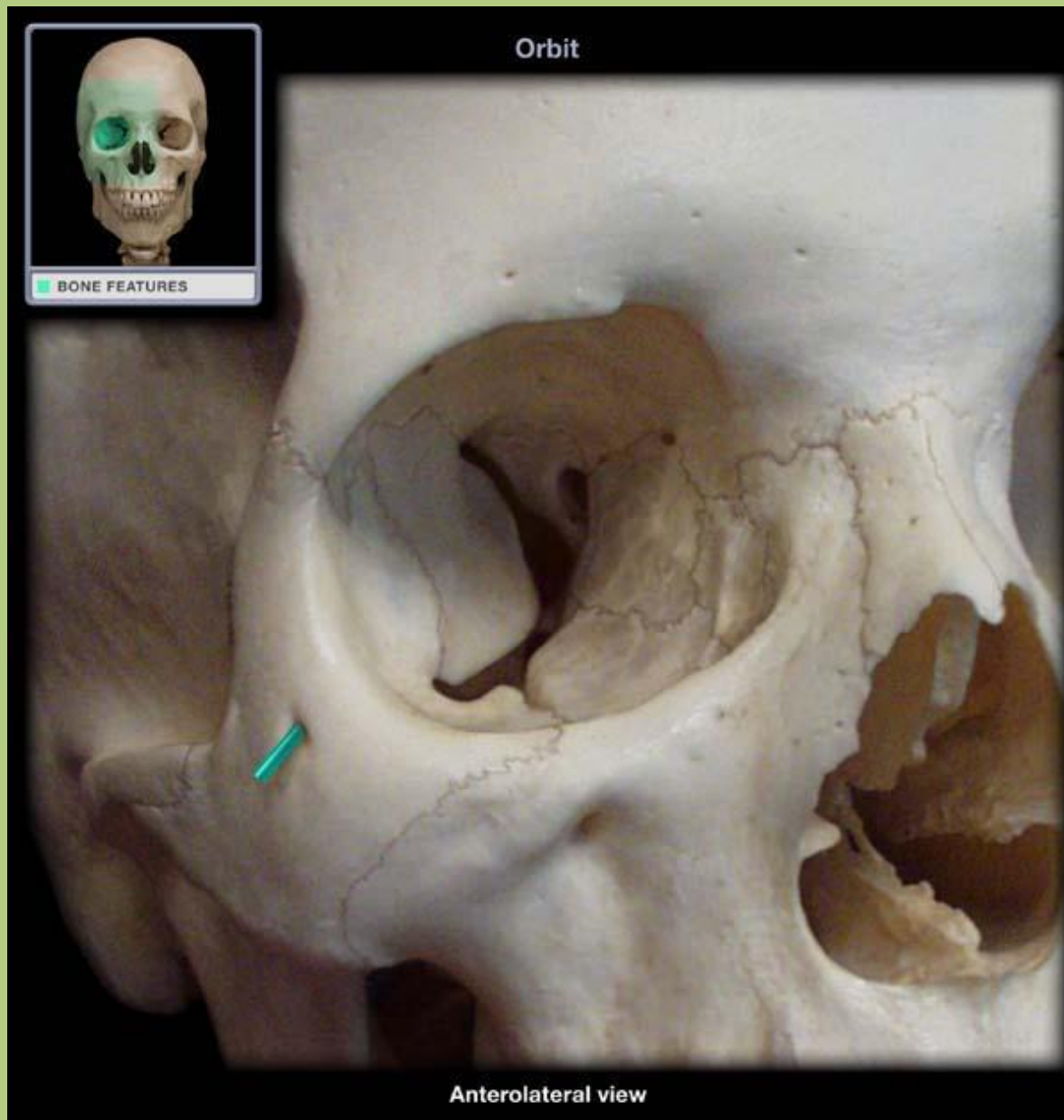- Os nasale
- Os lacrimale
- Os ethmoidale
- Maxilla
- Mandibula
- Os zygomaticum
- Vomer
- Os palatinum
- Concha nasalis inferior
- Os hyoideum



Orbita

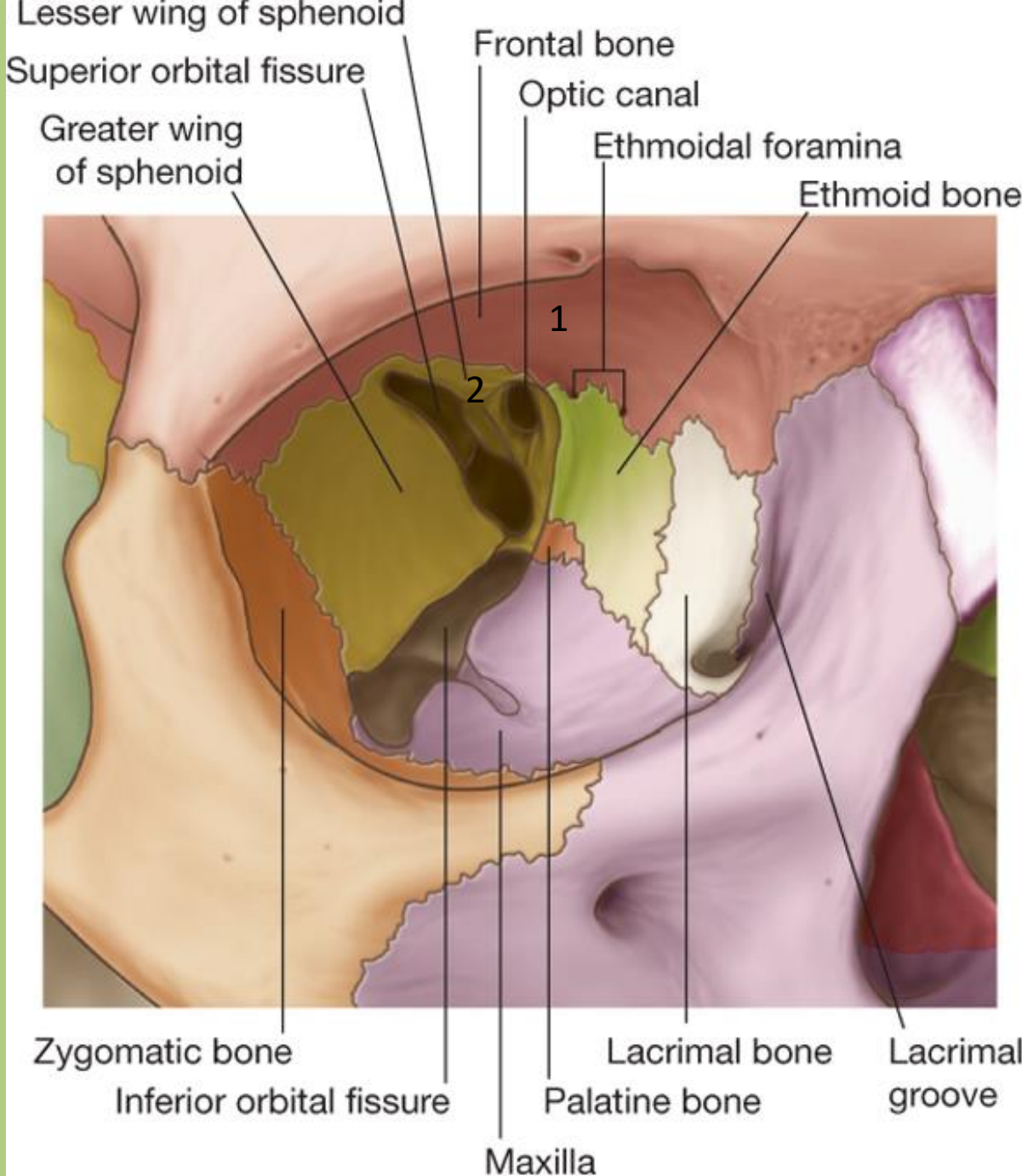
- piramis alakú csontos üreg
- bázisa anterolaterálisan helyezkedik
- csúcsa posteromediálisan helyezkedik

Tartalma: szemgolyó, külső szemizmok, idegek, erek, könnykészülék.



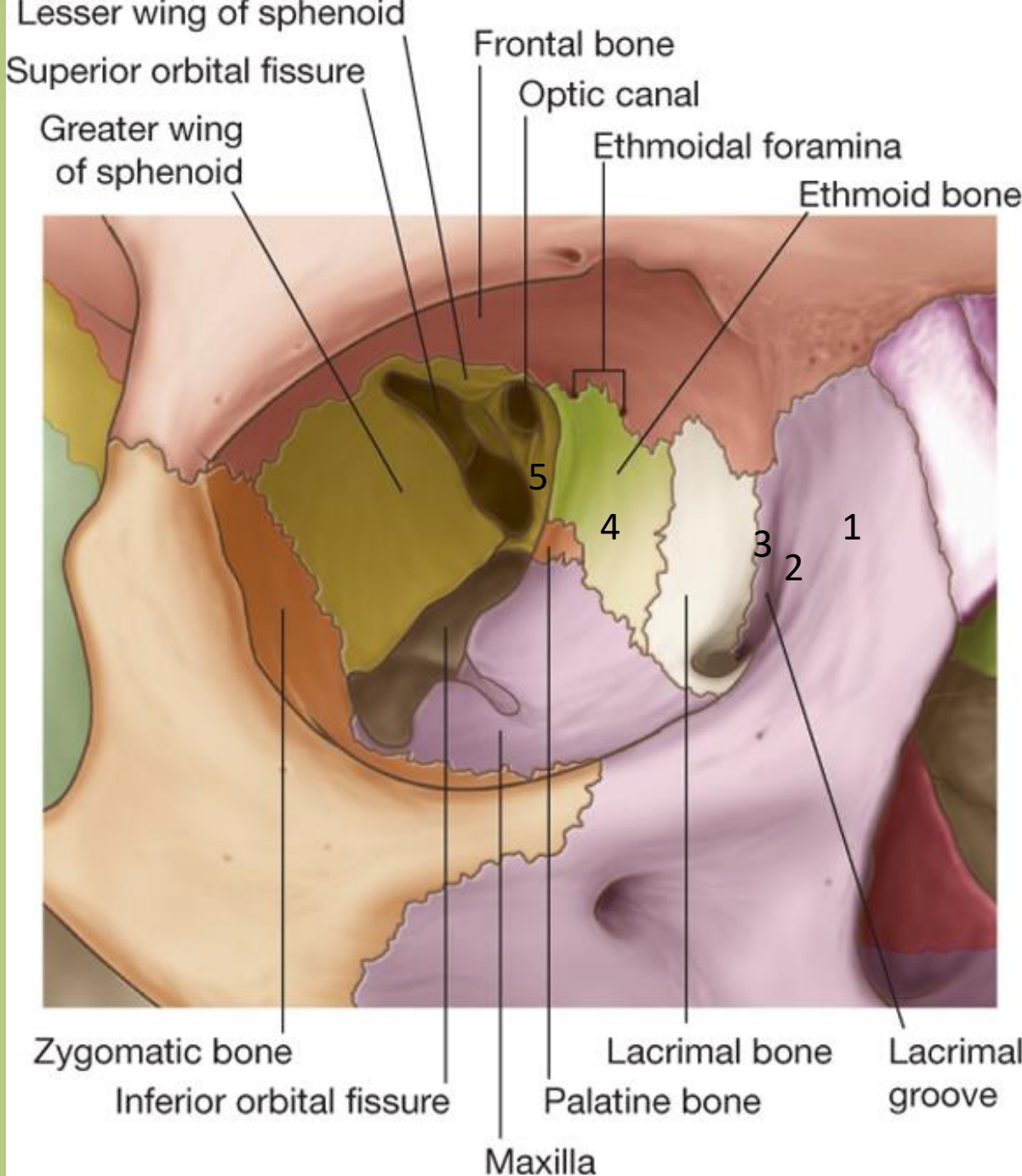
ORBITA:
SUPERIOR FAL

- pars orbitalis ossis frontalis (1)
- ala minor ossis sphenoidalis (2)
- fissura orbitalis superior
- canalis opticus



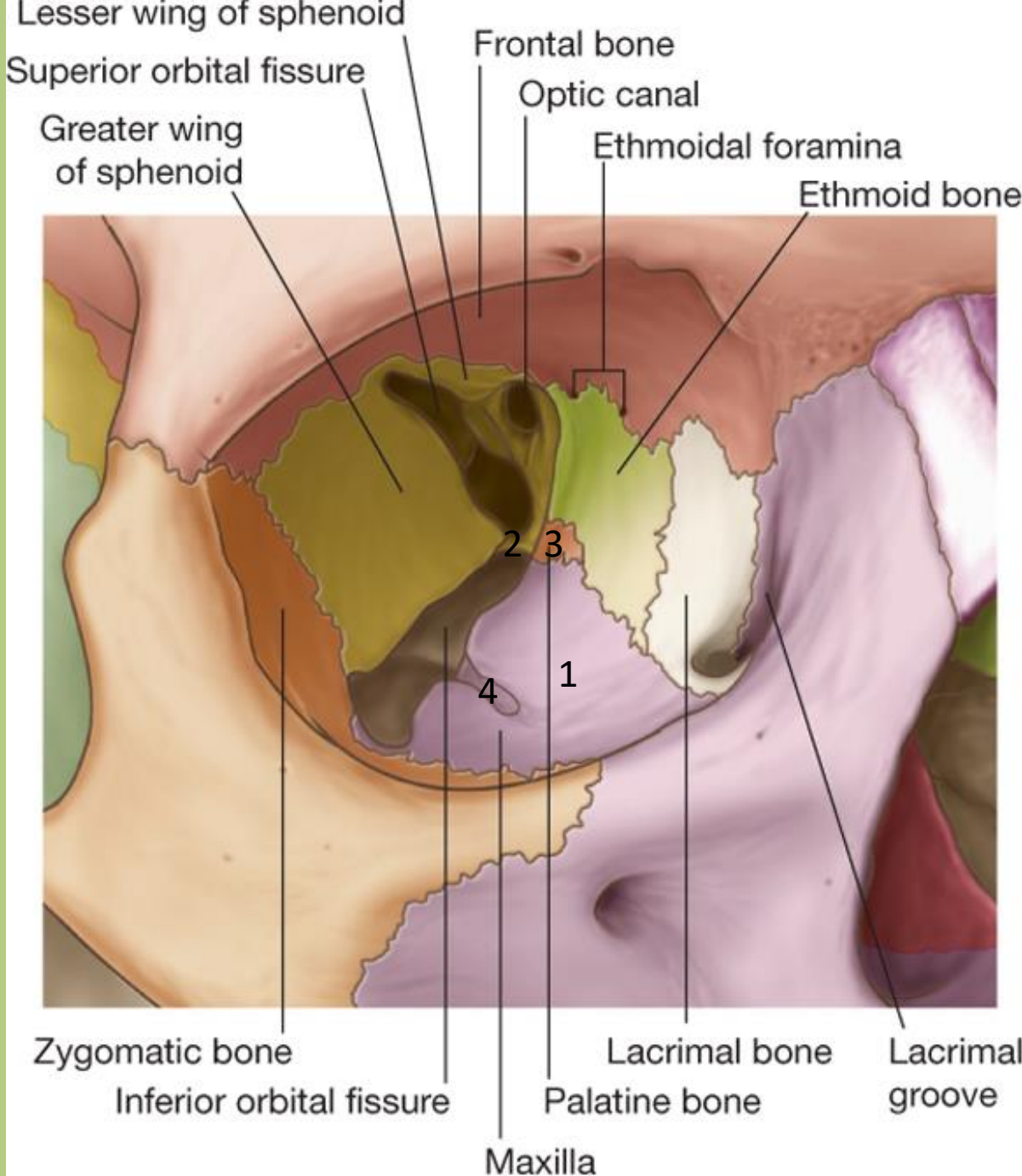
**ORBITA:
MEDIALIS FAL**

- processus frontales maxillae (1)
- crista lacrimalis anterior (2)
- os lacrimale
- crista lacrimalis posterior (3)
- saccus lacrimalis
- canalis nasolacrimalis
- lamina orbitalis ossis ethmoidalis (4)
- anterior et posterior foramina ethmoidalia
- corpus ossis sphenoidalis (5)



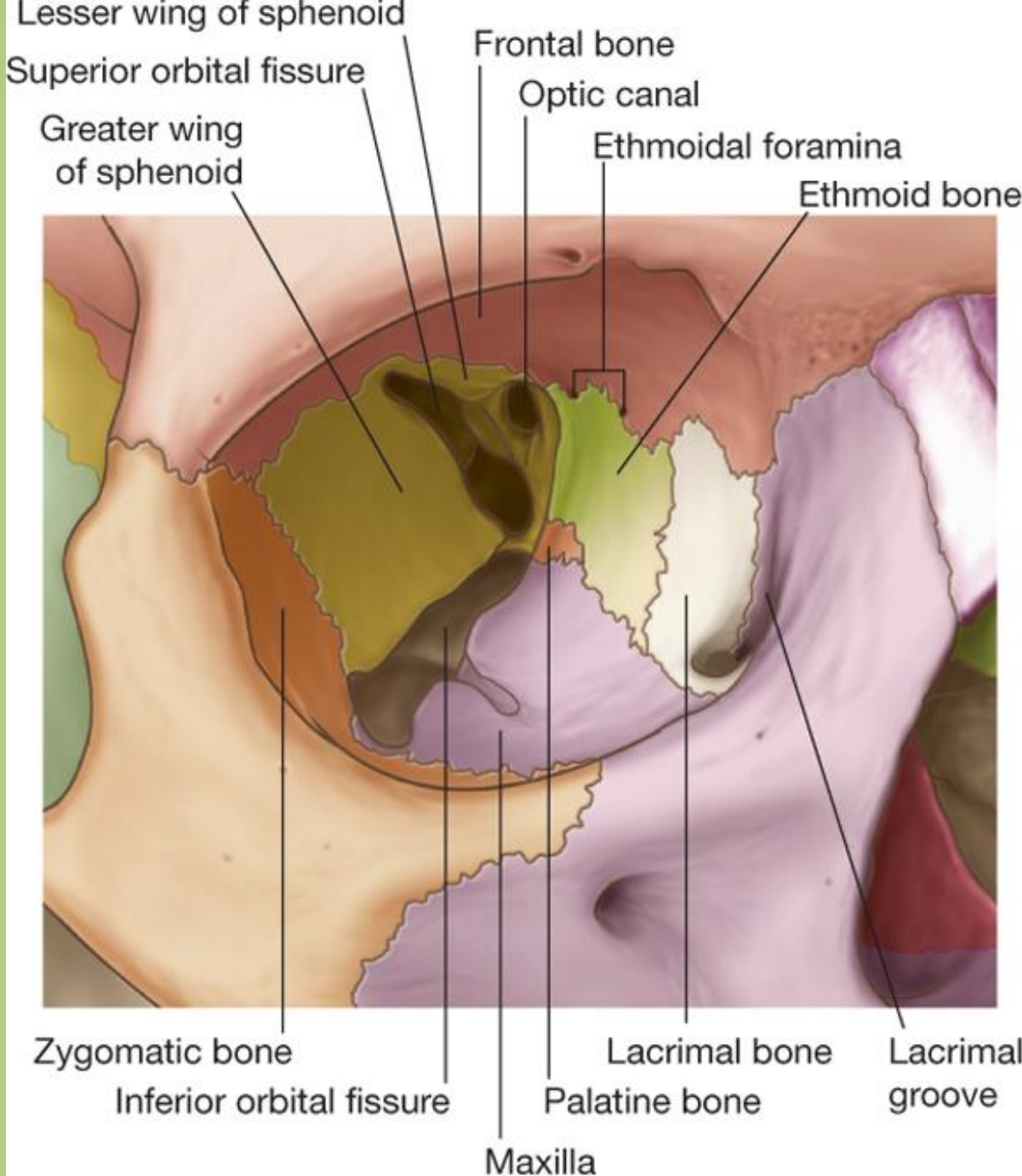
ORBITA:
INFERIOR FAL

- corpus maxillae (1)
- corpus ossis sphenoidalis (2)
- lamina perpendicularis ossis palatini (3)
- fissura orbitalis inferior (4)
- sulcus infraorbitalis (4)
- canalis infraorbitalis

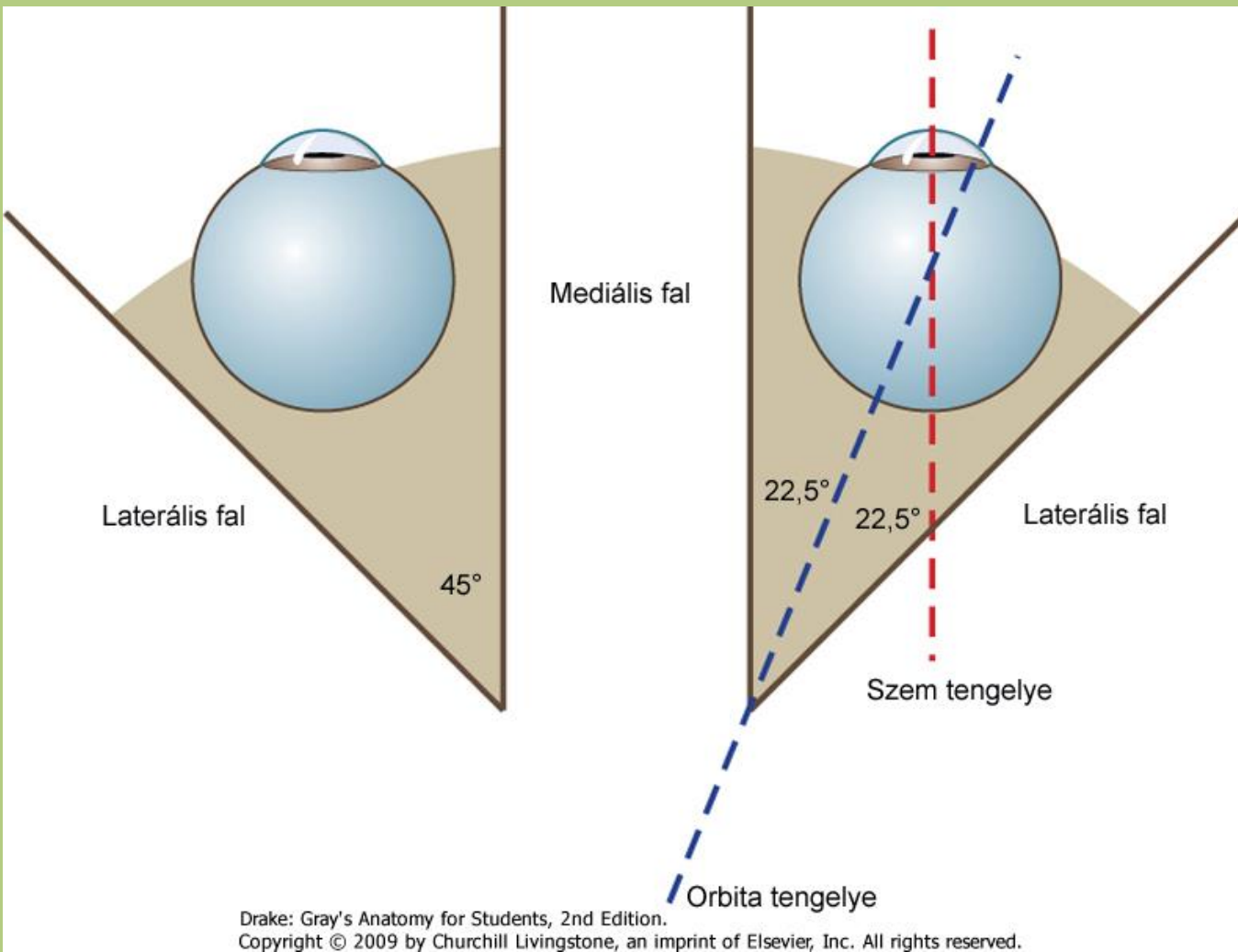


ORBITA:
LATERALIS FAL

- ala major ossis sphenoidalis
- os zygomaticum

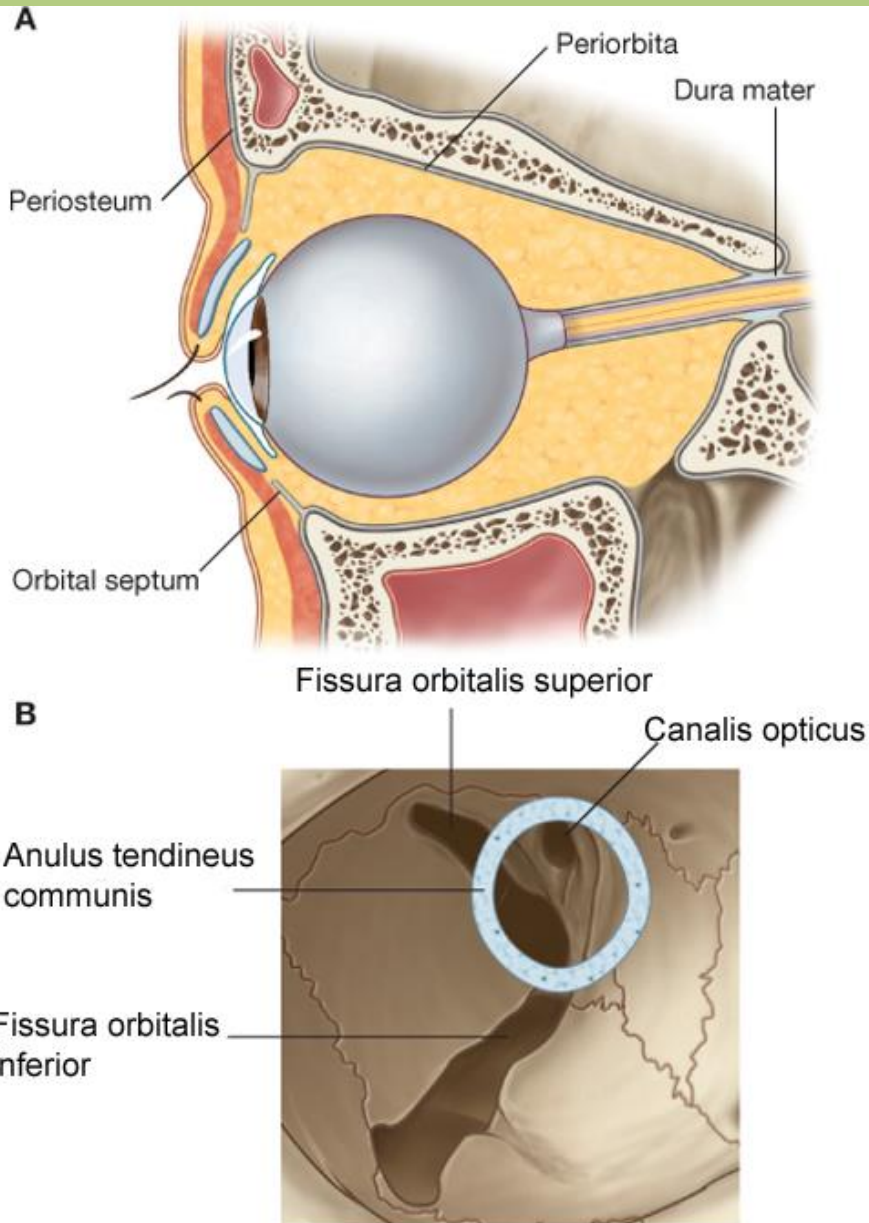


Szem vs. Orbita



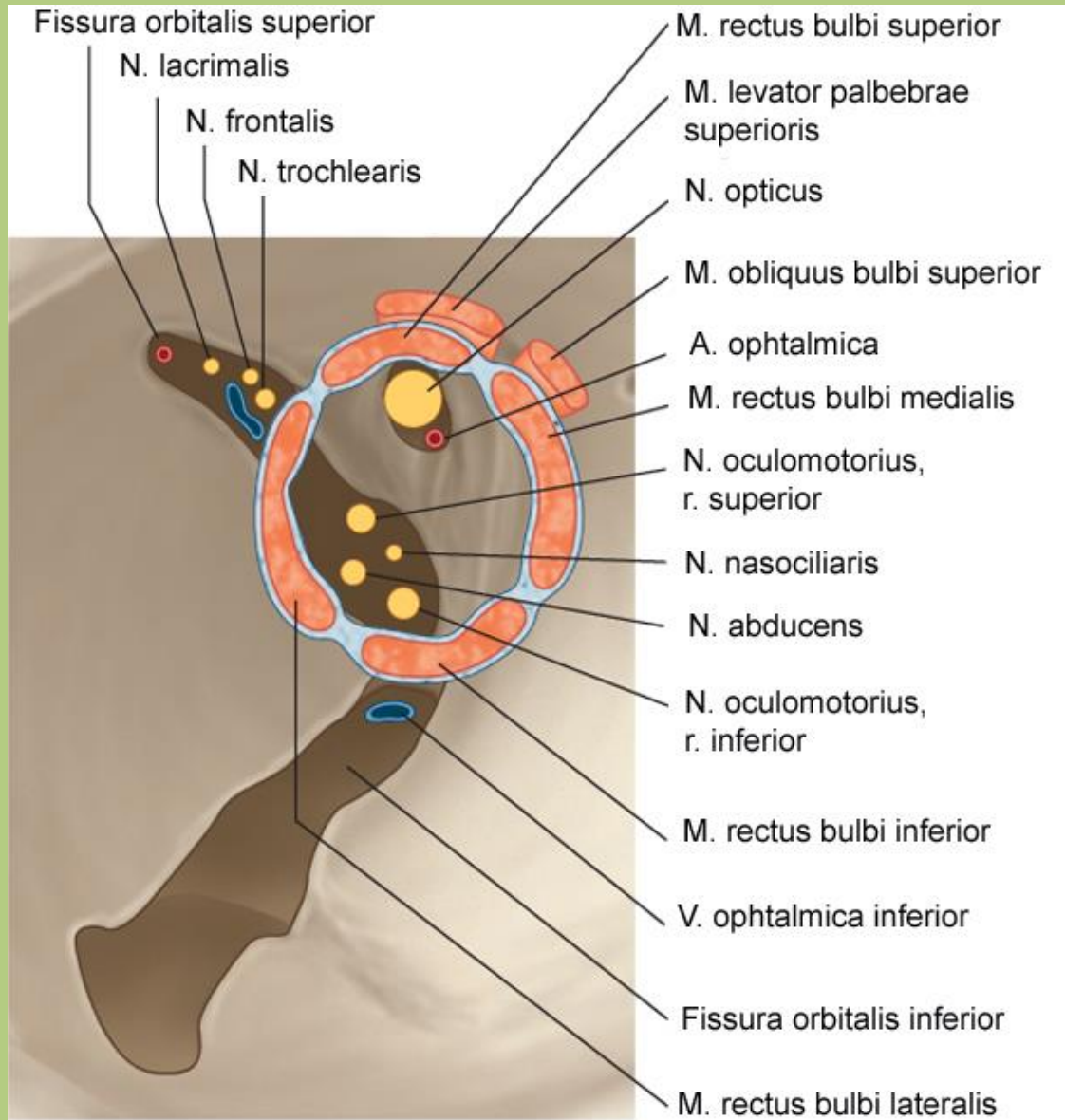
- A mediális fal párhuzamos a mediánsagittális síkkal.
- A laterális fal ettől 45°-kal eltér.
- A szem AP (antero-posterior) tengelye a sagittális síkkal párhuzamos.

Orbita



A szemüreg zsírszövetének tokjában kötőszöveti lemezekkel rögzített szemgolyó a ***spatium episcleraléban*** minden irányban elmozdulhat az itt elhelyezkedő hat izomnak köszönhetően. A négy rectus izom eredő inai tölcsérszerű gyűrűt képeznek a canalis opticus körül: **anulus tendineus communis**.

Orbita



Fissura orbitalis superior

N. lacrimalis

N. frontalis

N. trochlearis

M. rectus bulbi superior

M. levator palpebrae superioris

N. opticus

M. obliquus bulbi superior

A. ophtalmica

M. rectus bulbi medialis

N. oculomotorius, r. superior

N. nasociliaris

N. abducens

N. oculomotorius, r. inferior

M. rectus bulbi inferior

V. ophtalmica inferior

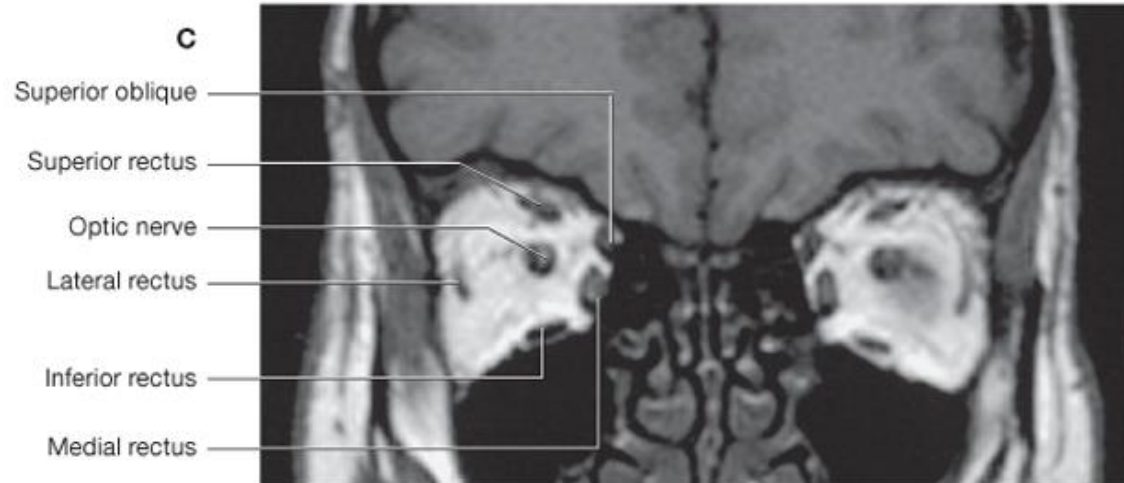
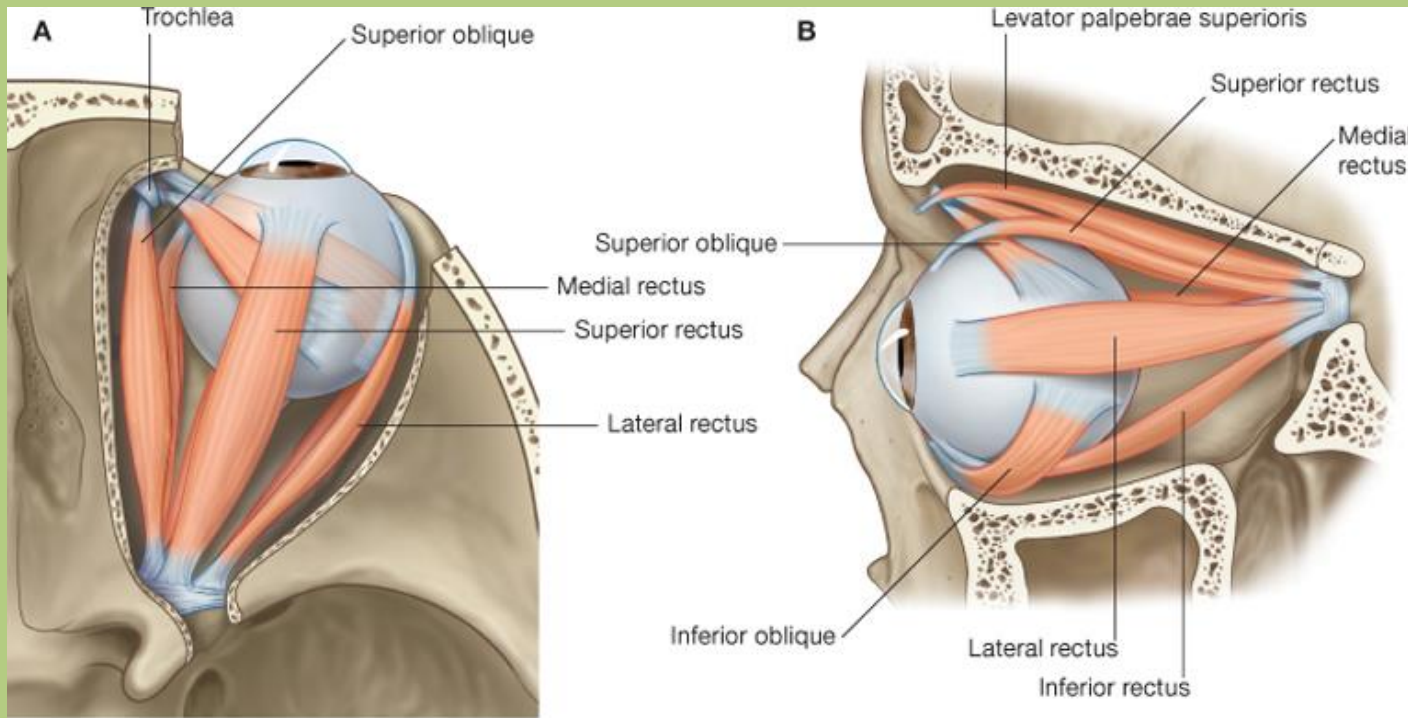
Fissura orbitalis inferior

M. rectus bulbi lateralis

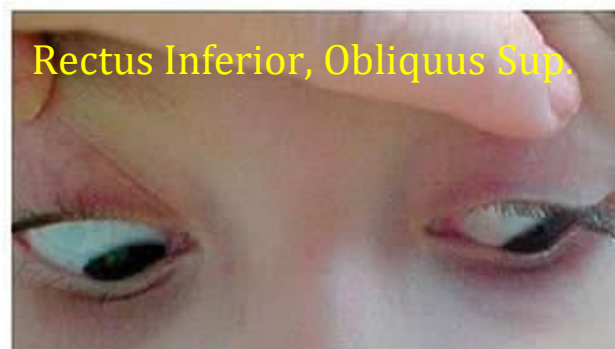
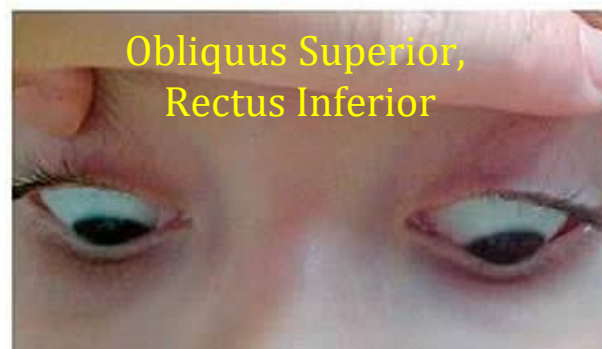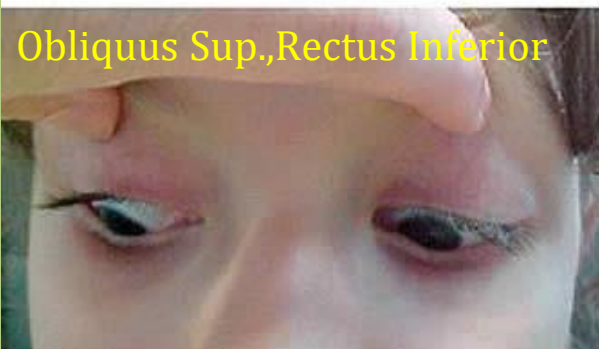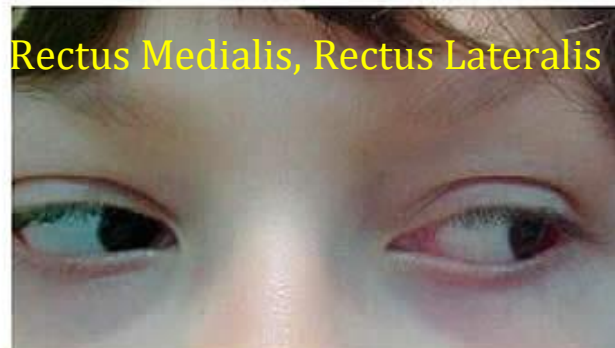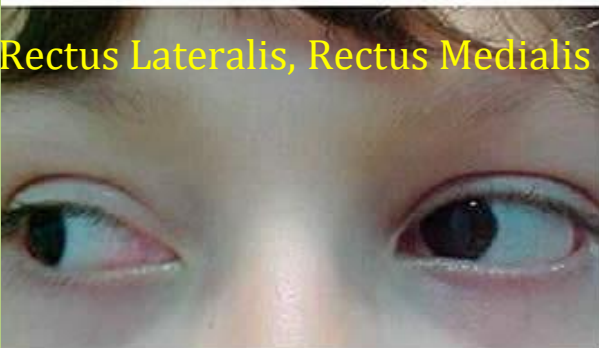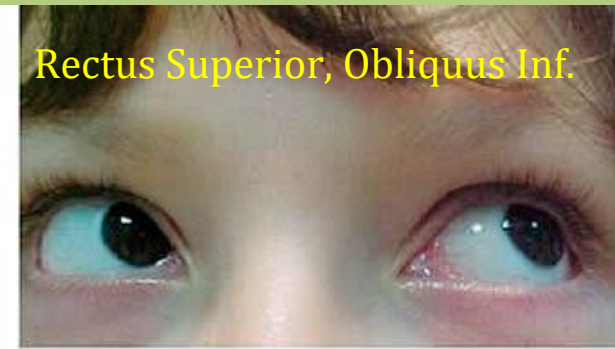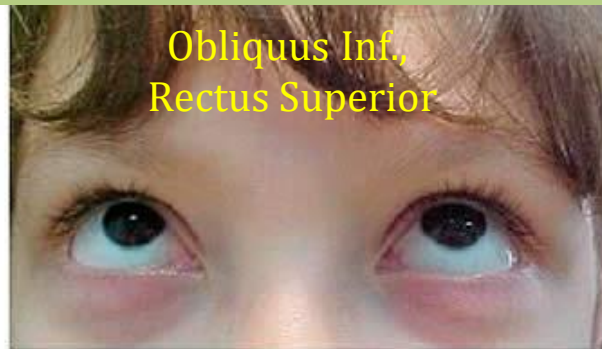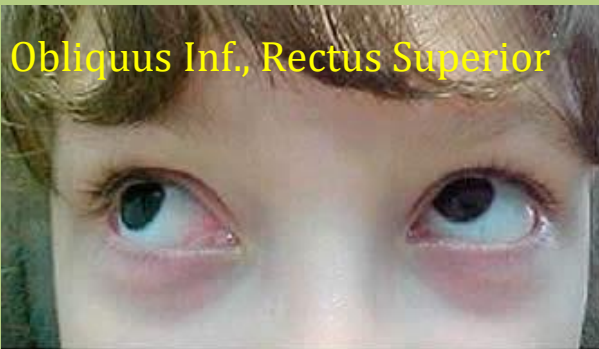Lateral

Medial

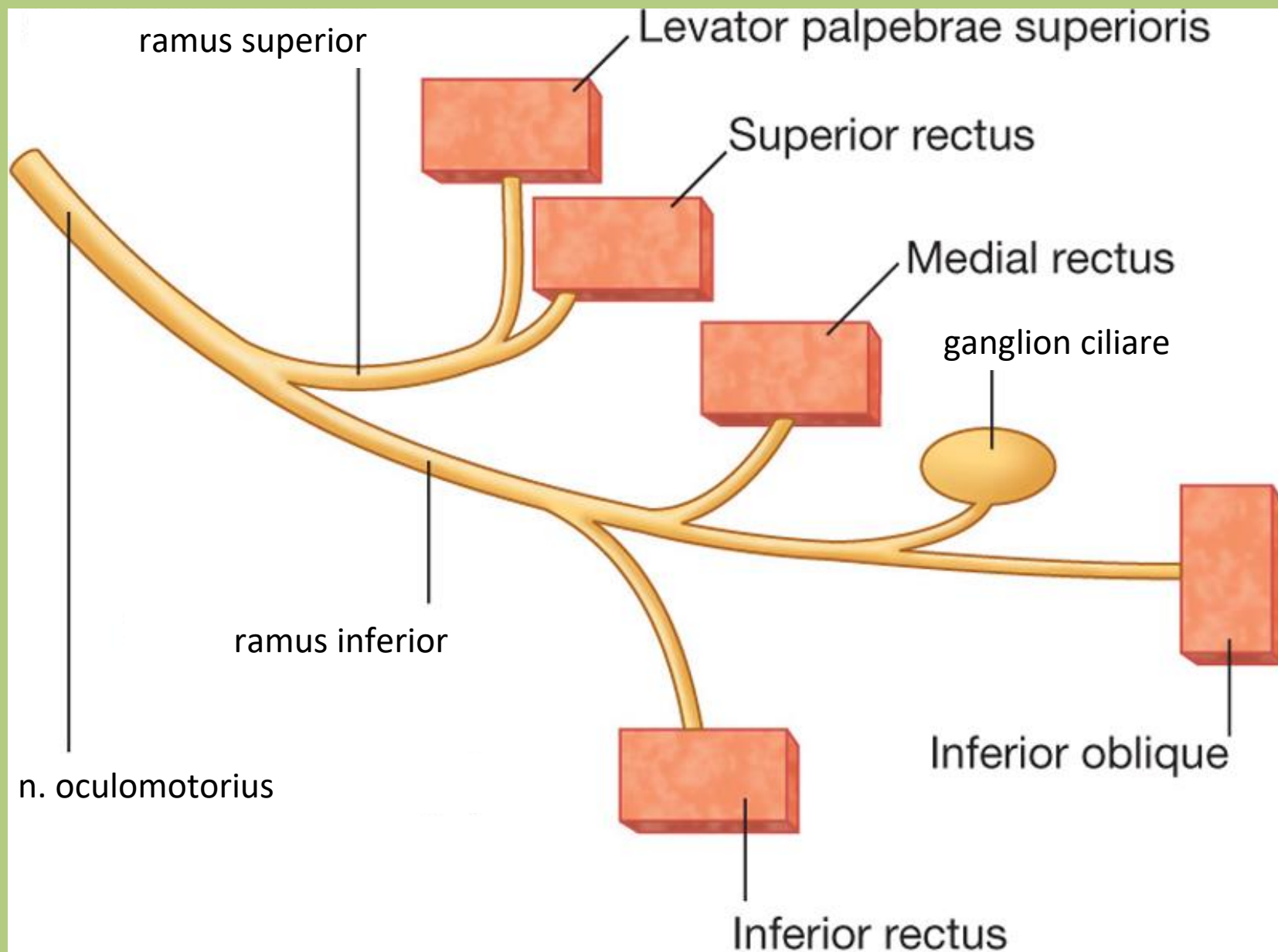
Extraoculáris izmok



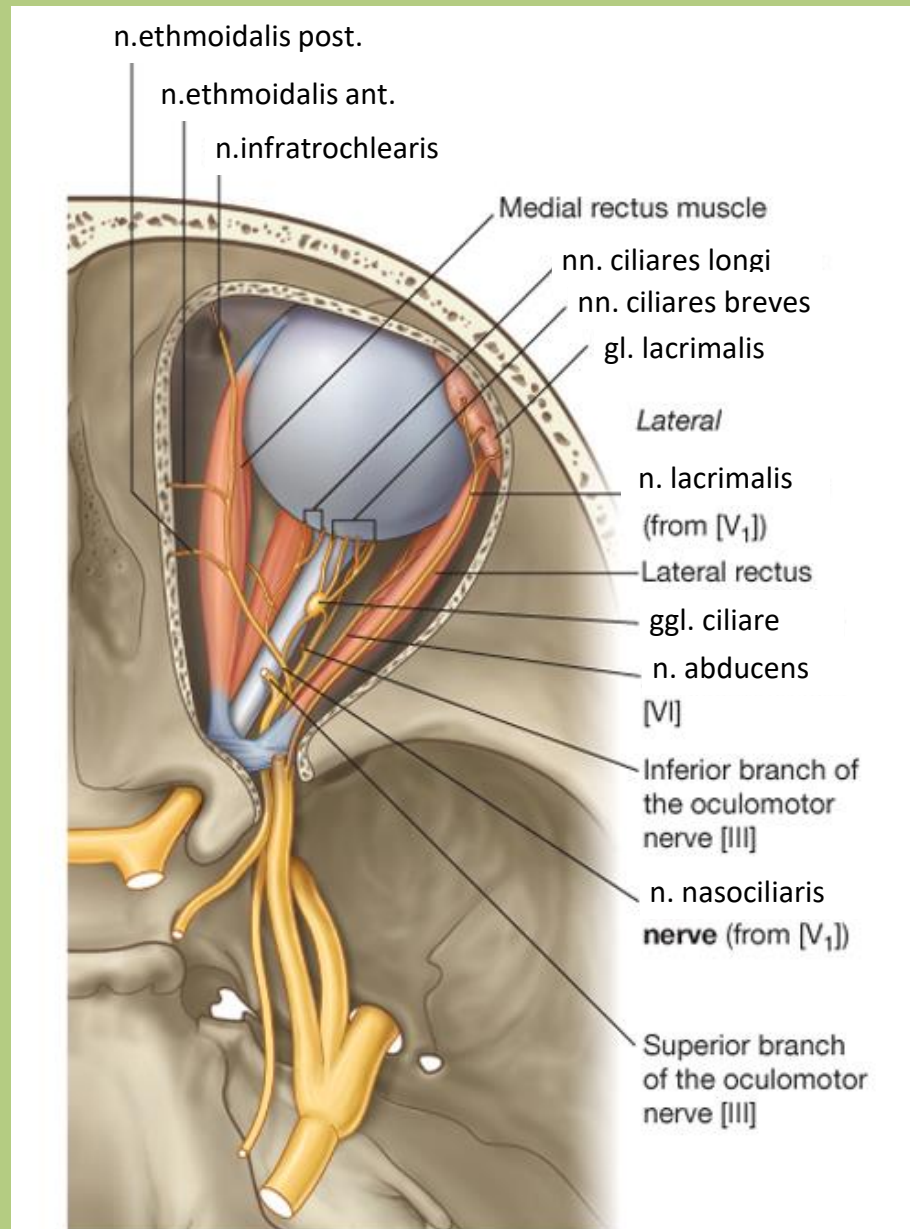
Binoculáris mozgások



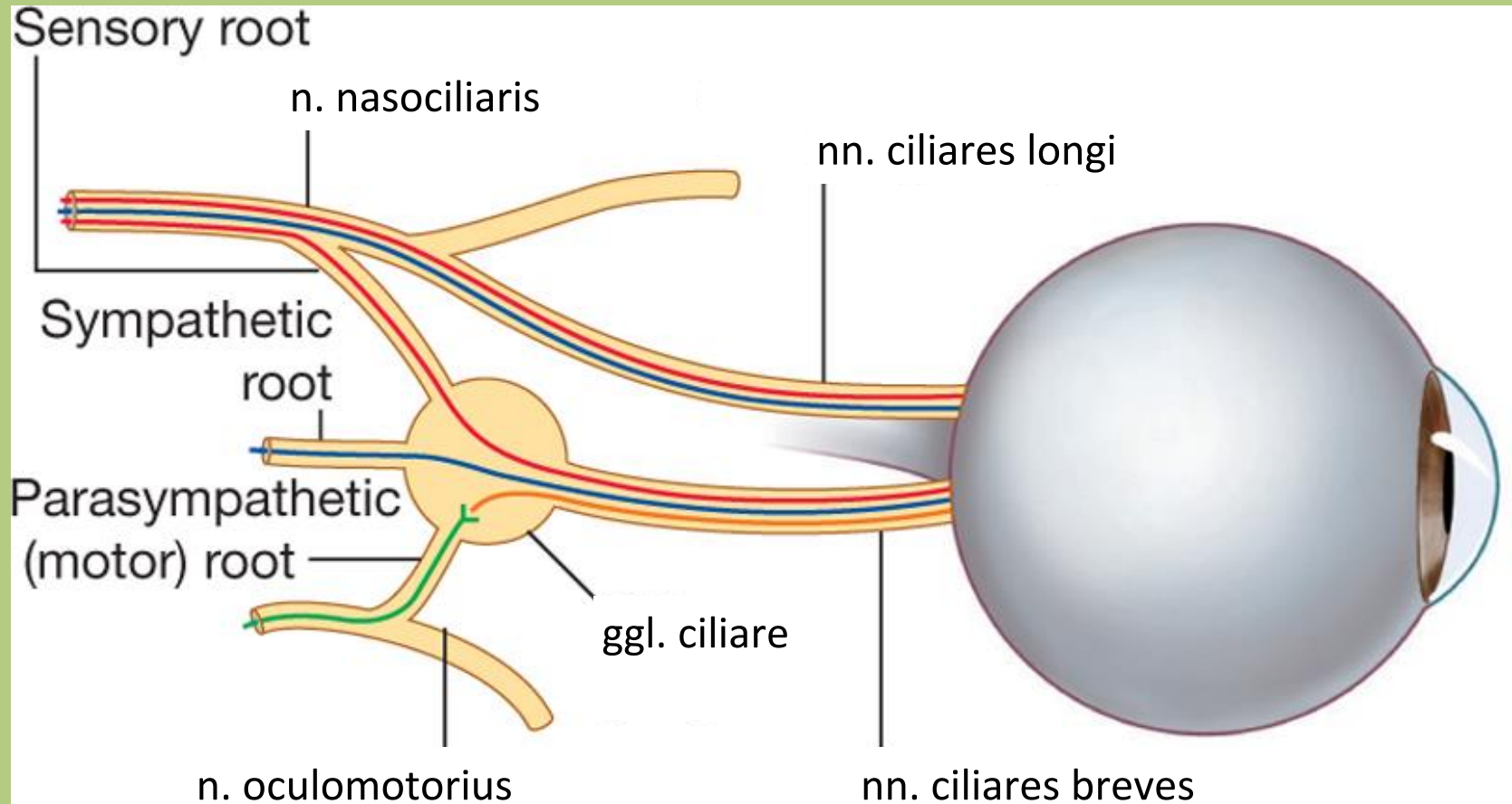
A n. oculomotorius által beidegzett extraoculáris izmok



Extraoculáris izmok



Ggl. ciliare

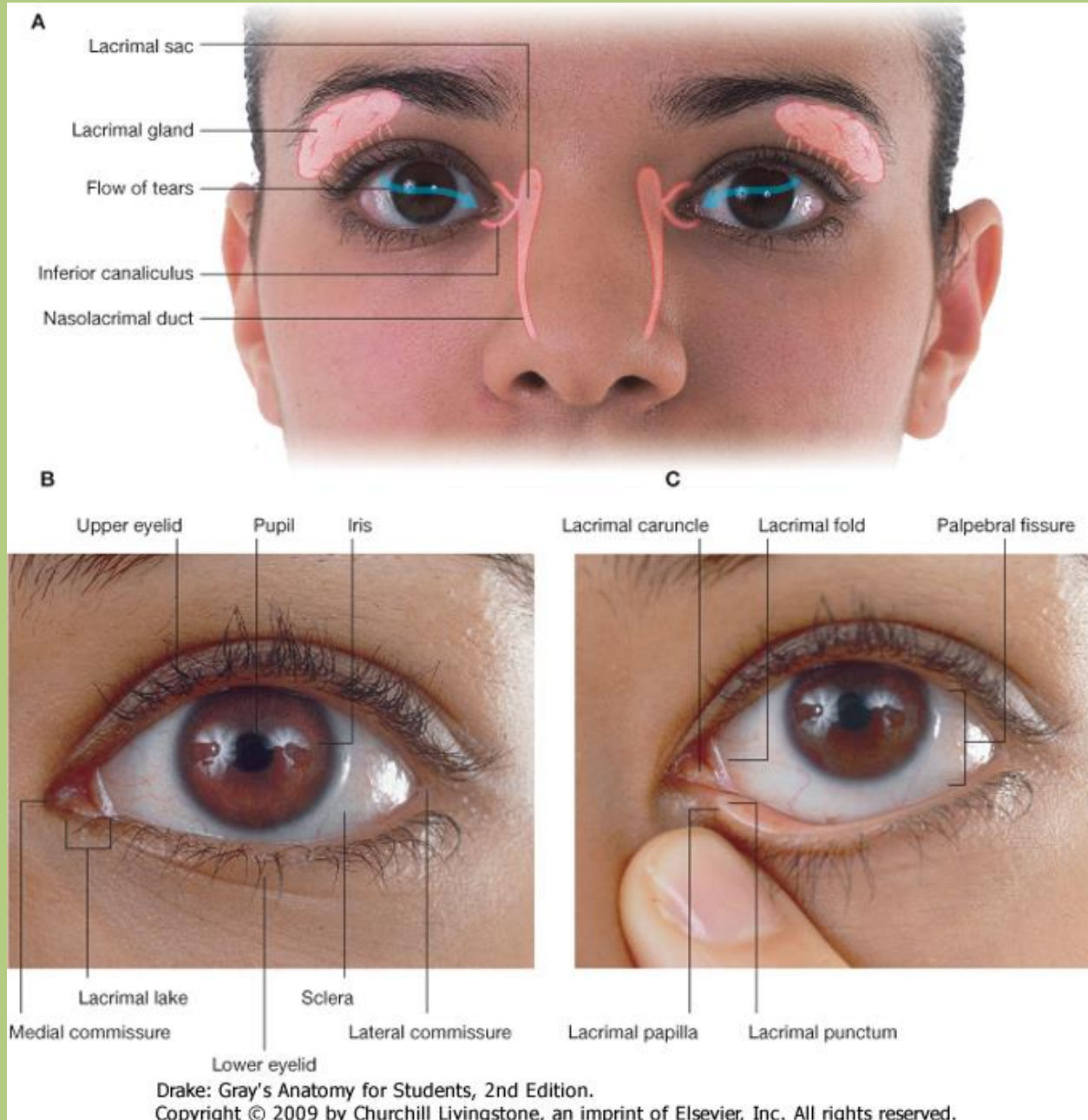


- Sensory fibers
- Sympathetic fibers
- Parasympathetic preganglionic fibers
- Parasympathetic postganglionic fibers

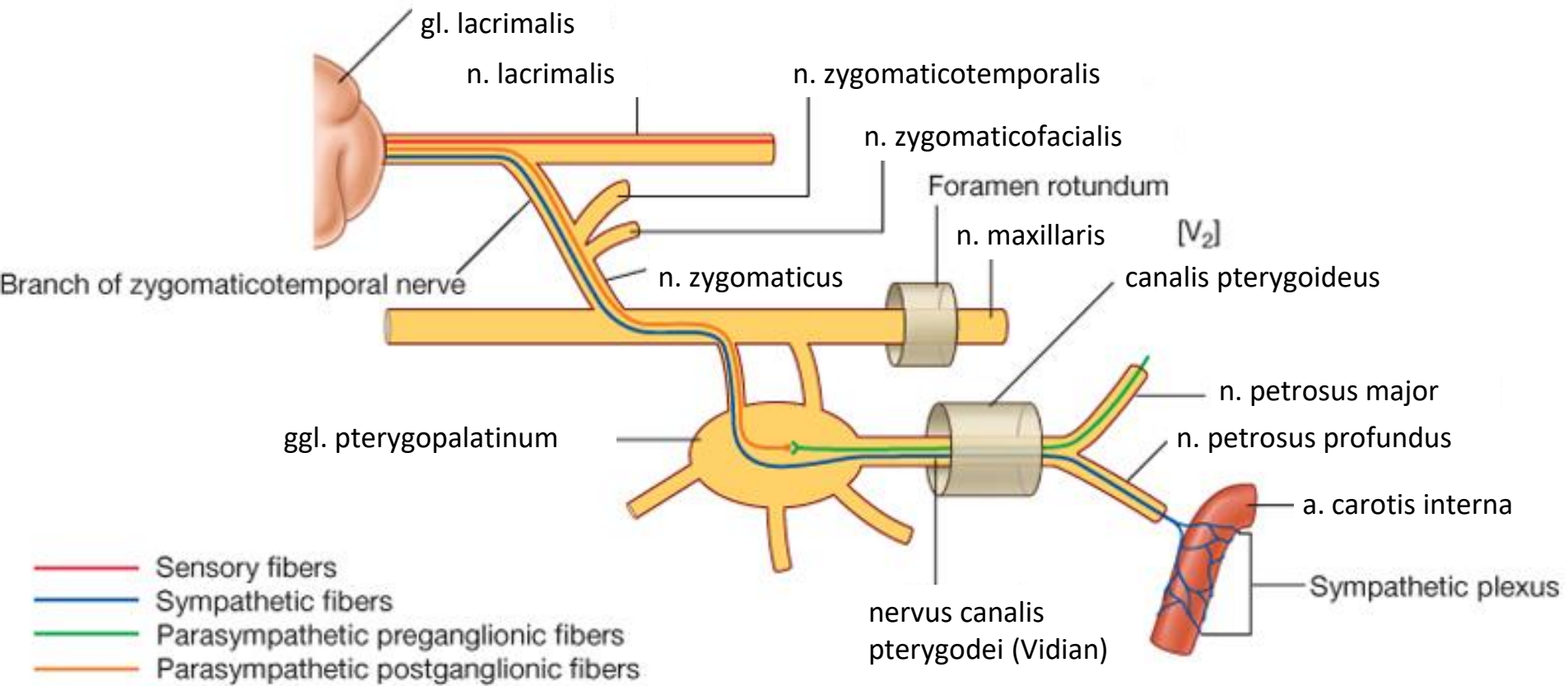
Drake: Gray's Anatomy for Students, 2nd Edition.

Copyright © 2009 by Churchill Livingstone, an imprint of Elsevier, Inc. All rights reserved.

Könnykészülék



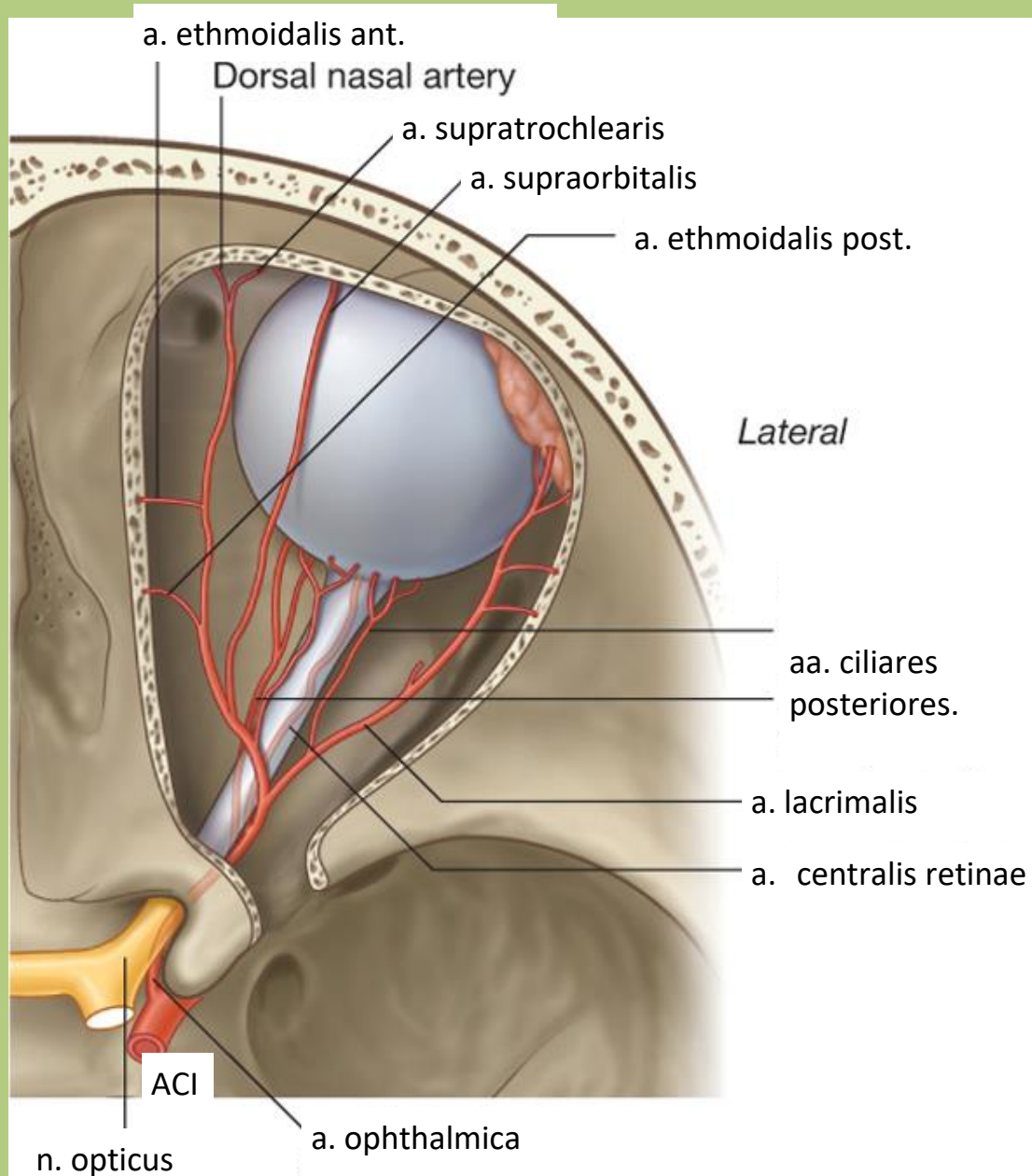
Ggl. pterygopalatinum



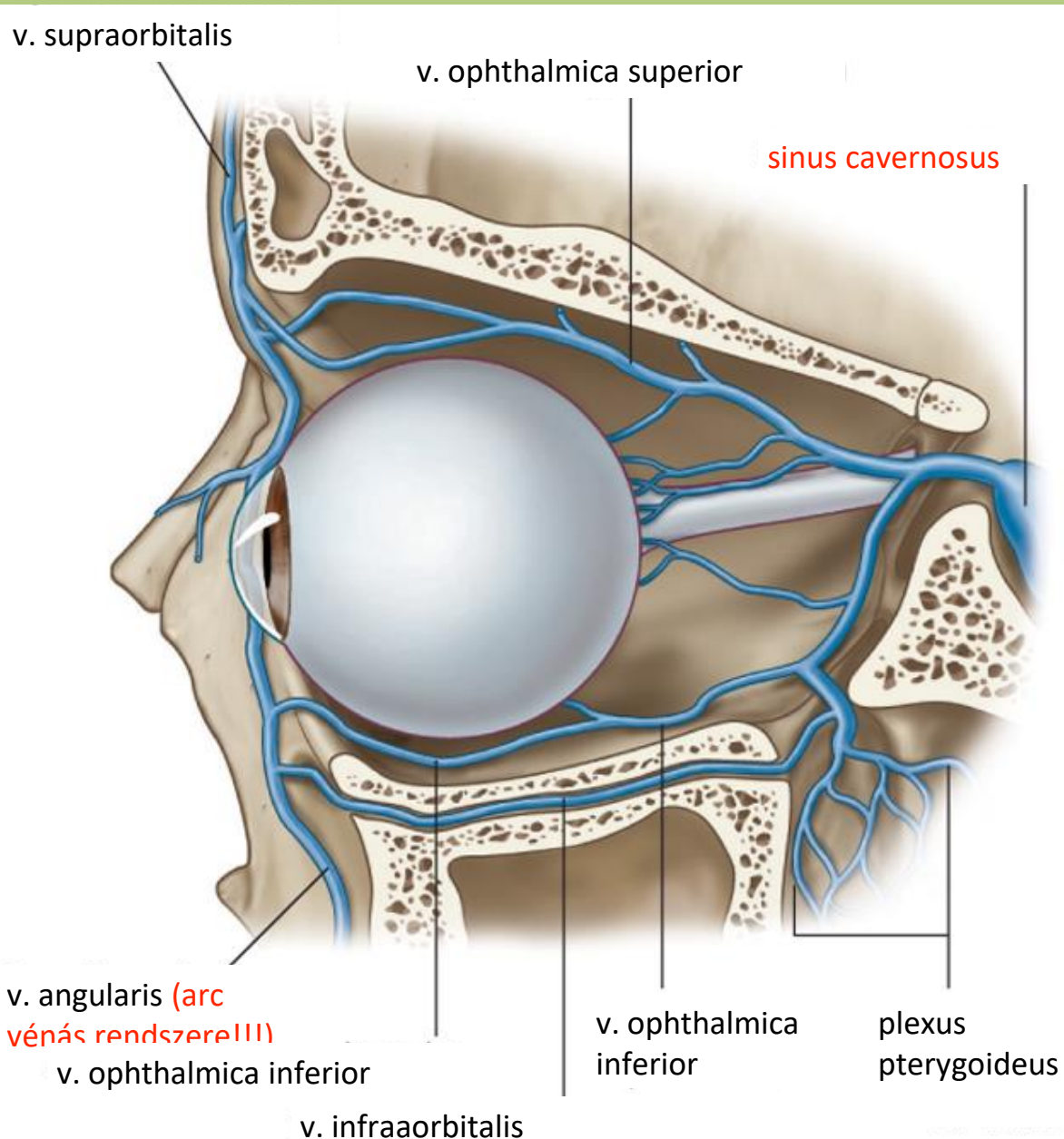
Drake: Gray's Anatomy for Students, 2nd Edition.

Copyright © 2009 by Churchill Livingstone, an imprint of Elsevier, Inc. All rights reserved.

Vérellátás

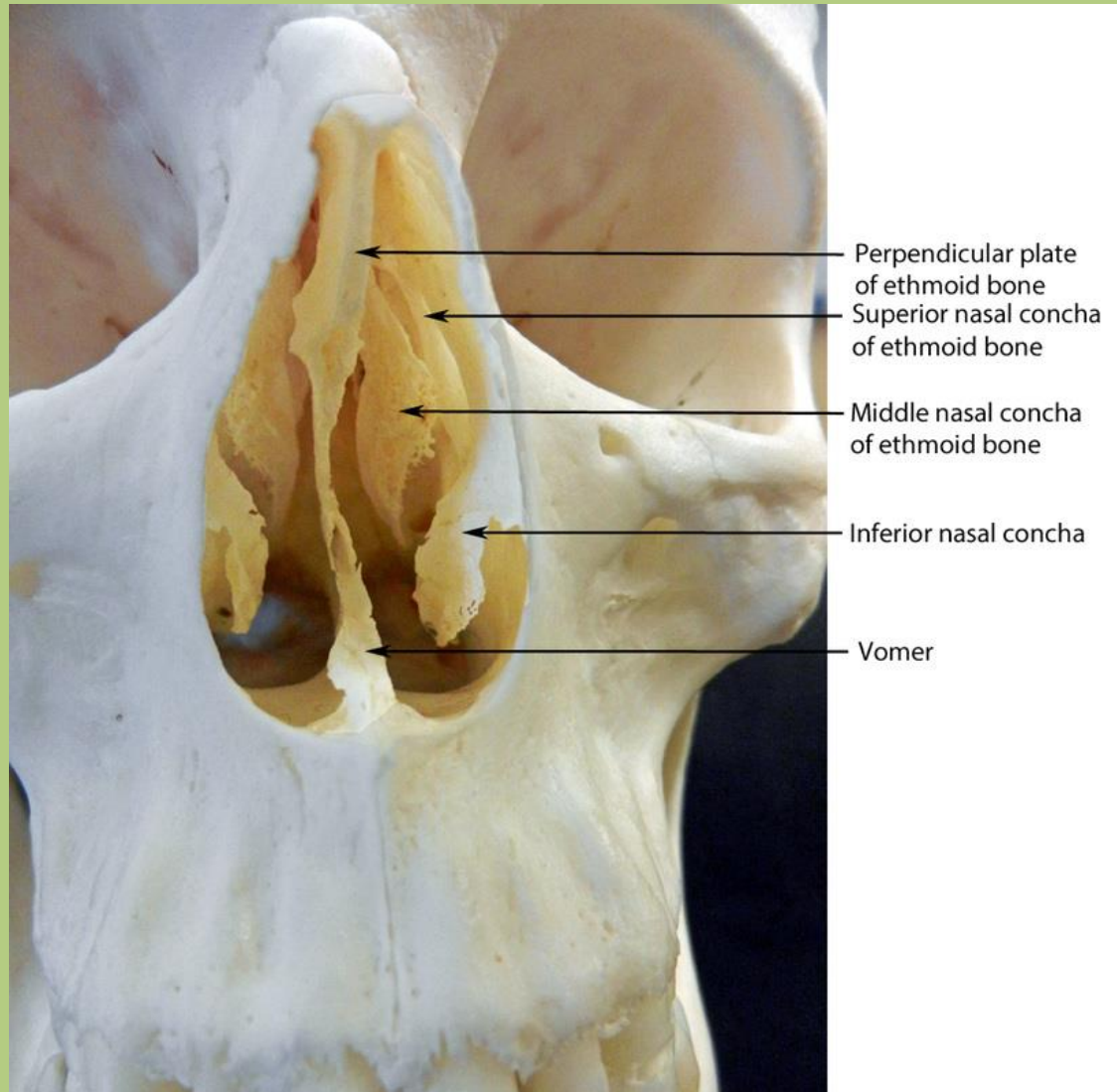


Vérellátás



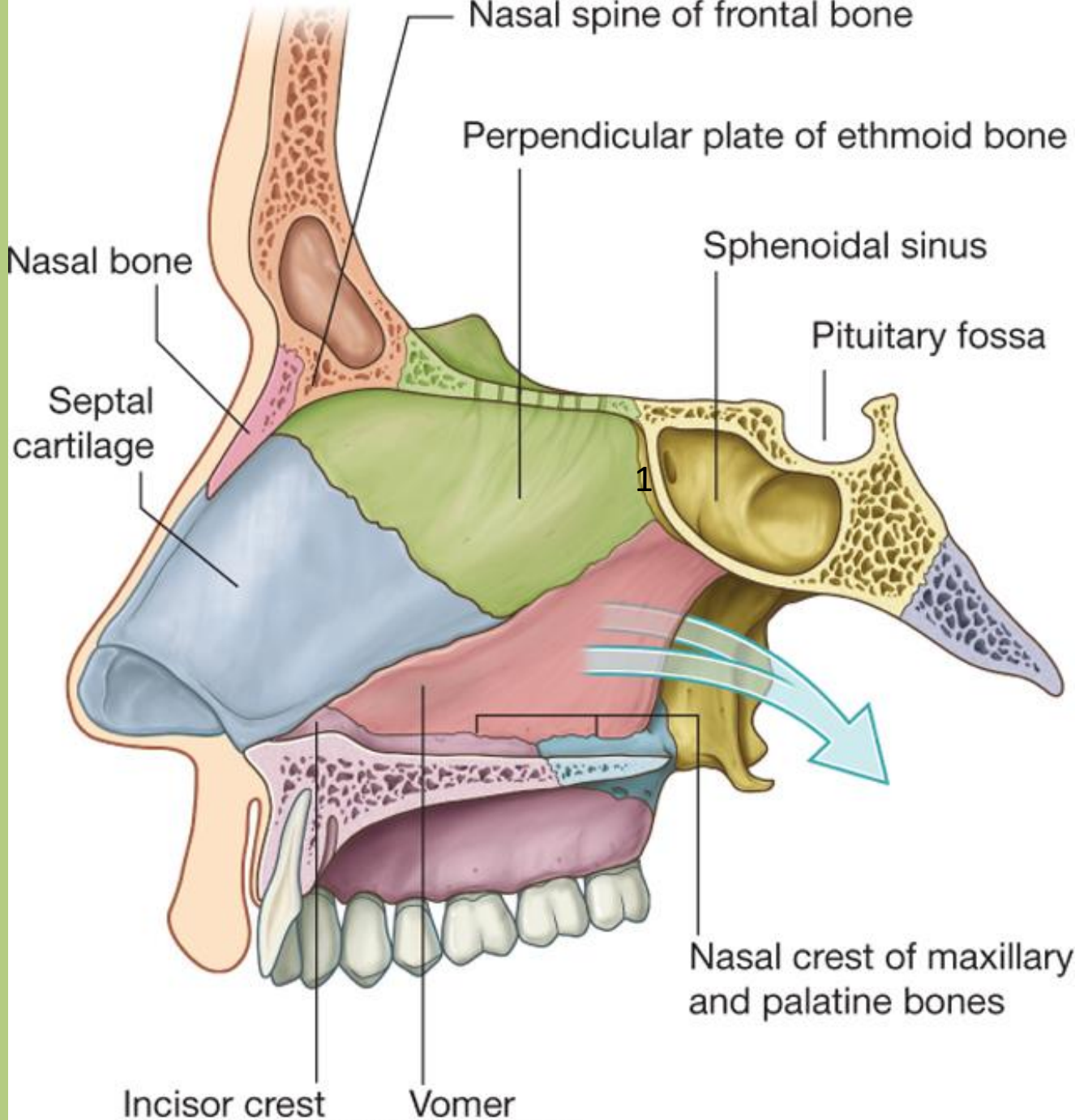
Cavum nasi

- a septum nasi két részre osztja
- nyílásai: apertura piriformis és choanae
- nyálkahártya béleli
- felső részében regio olfactoria
- kapcsolat a sinus paranasalel



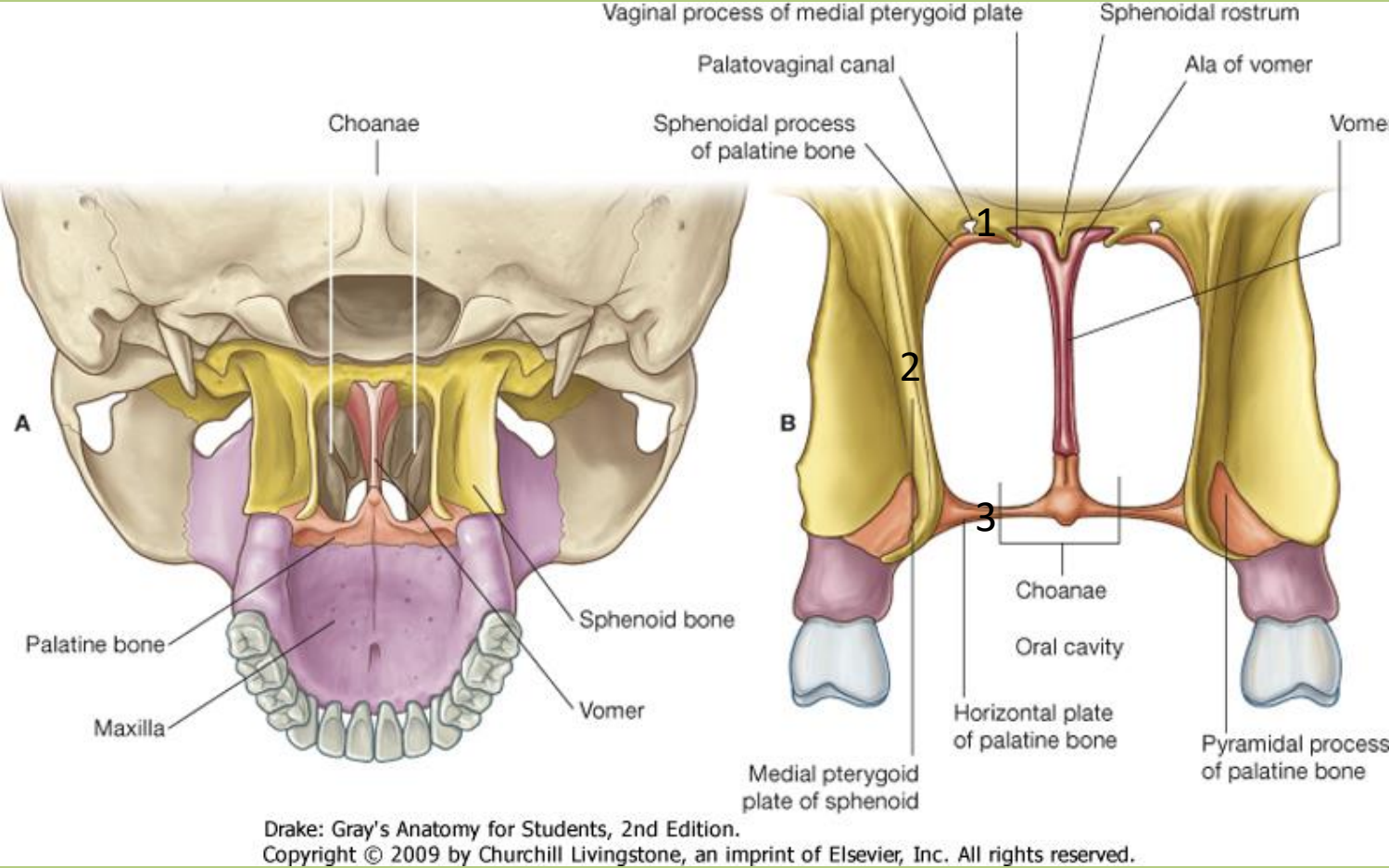
CAVUM NASI:
MEDIALIS FAL

- septum nasi osseum:
lamina perpendicularis
ossis ethmoidalis,
crista sphenoidalis (1)
és
vomer



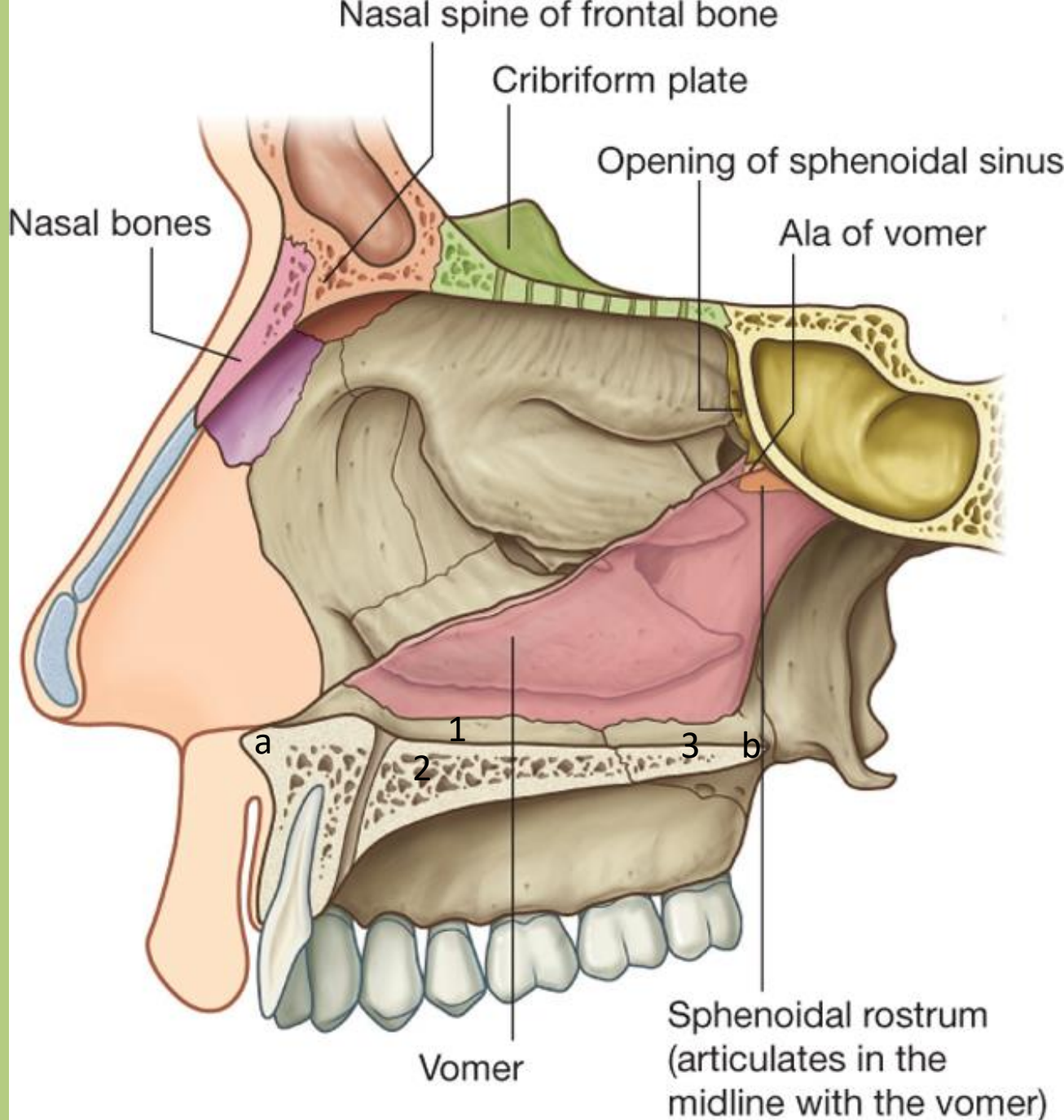
CAVUM NASI:
MEDIALIS FAL

- choanae:
corpus ossis
sphenoidalis (1),
lamina medialis
processus
pterygoidei (2),
lamina
horizontalis ossis
palatini (3)



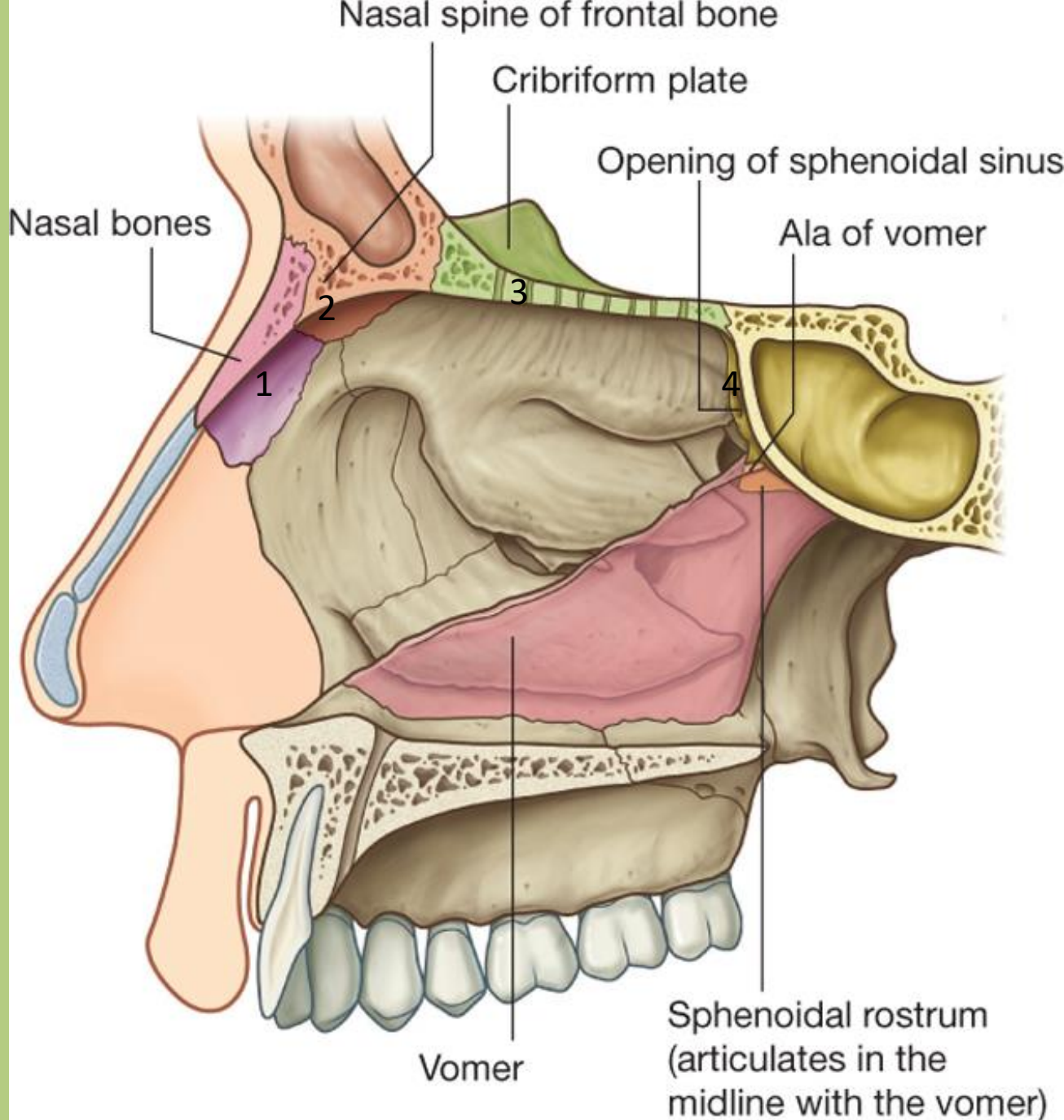
CAVUM NASI:
INFERIOR FAL

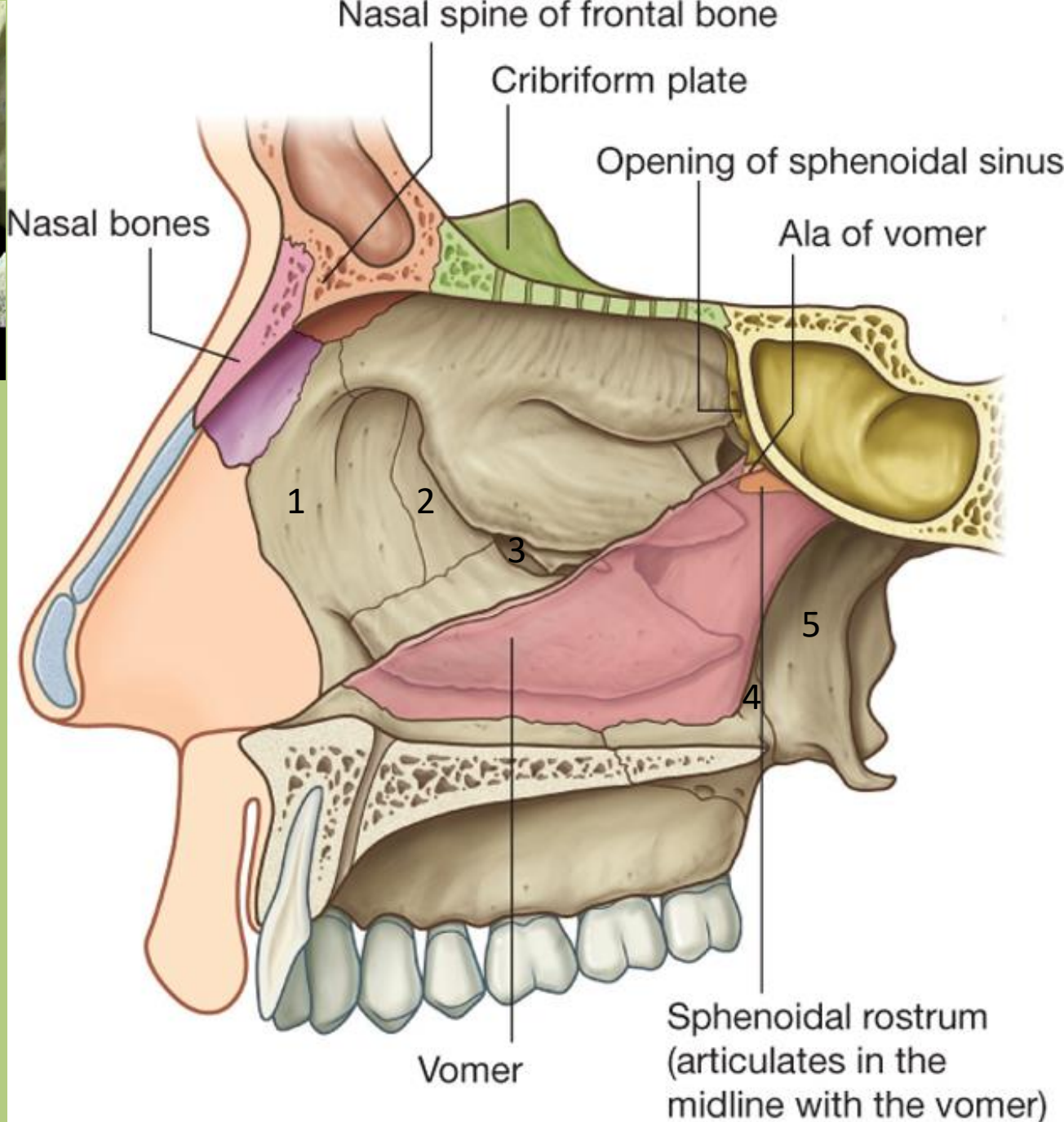
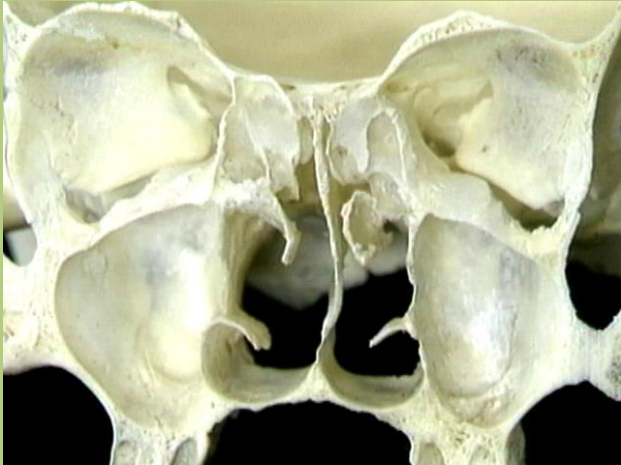
- crista nasalis (1)
- spina nasalis anterior (a)
- spina nasalis posterior (b)
- processus platinus maxillae (2)
- lamina horizontalis ossis palatini (3)



CAVUM NASI:
SUPERIOR FAL

- os nasale (1)
- pars nasalis ossis frontalis (2)
- lamina cribrosa (3)
- recessus sphenothmoidalis (4)

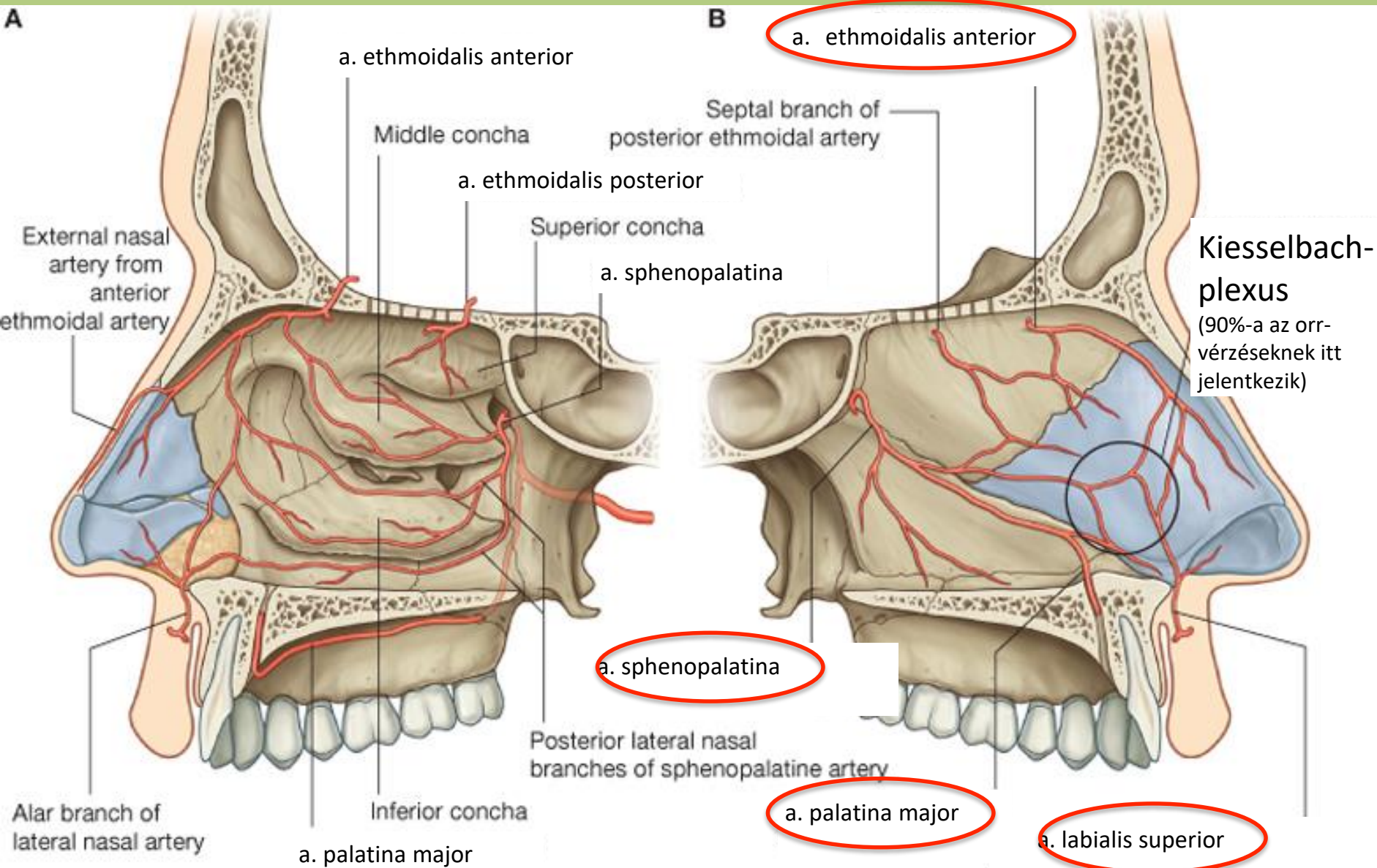




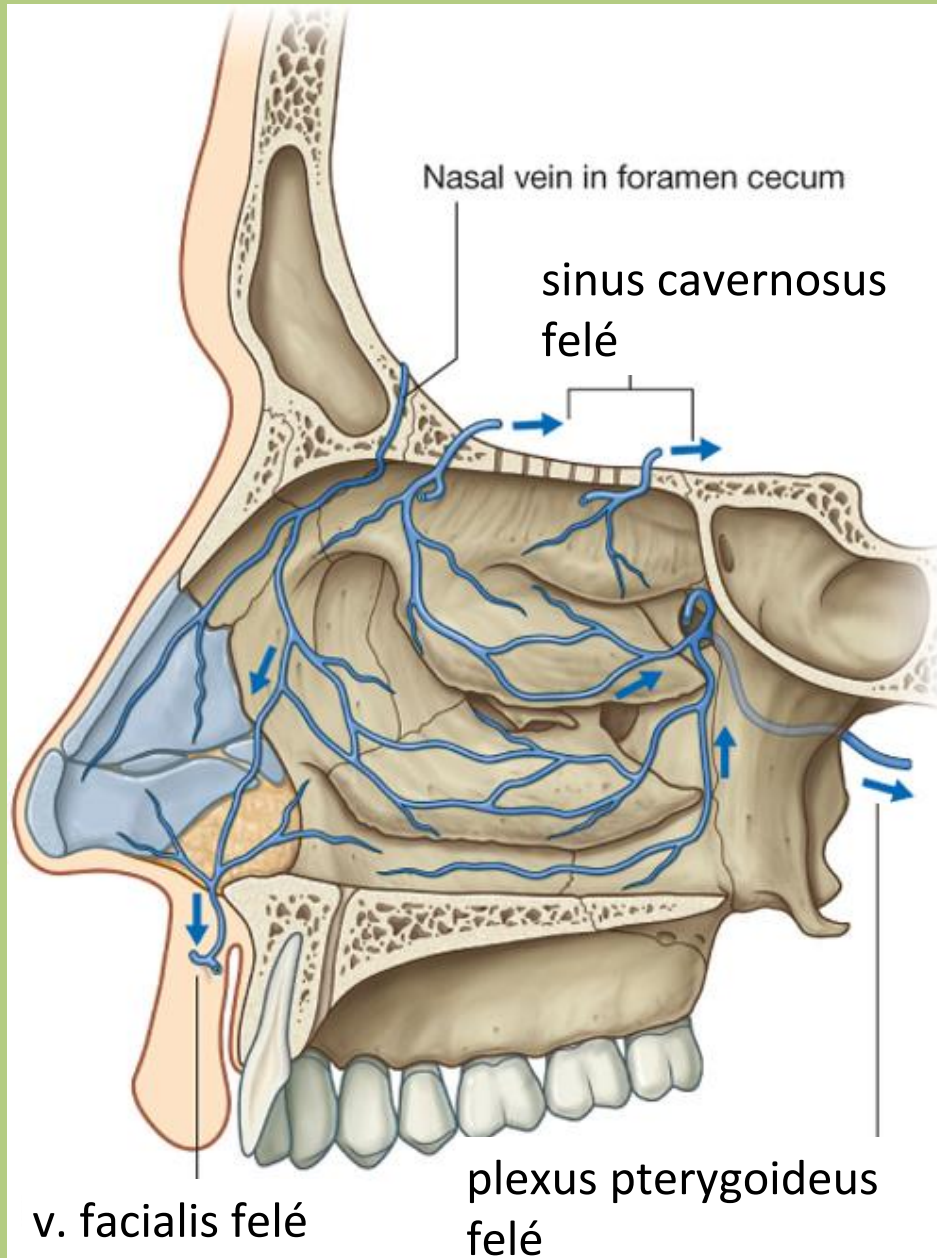
**CAVUM NASI:
LATERALIS
FAL**

- processus frontales maxillae (1)
- os ethmoidale (2)
- conchae nasales
- bulla ethmoidalis
- processus uncinatus
- hiatus semilunaris (3)
- os sphenoidale
- corpus maxillae
- lamina perpendicularis ossis palatini (4)
- lamina medialis processus pterygoidei (5)
- foramen sphenopalatinum
- ductus nasolacrimalis

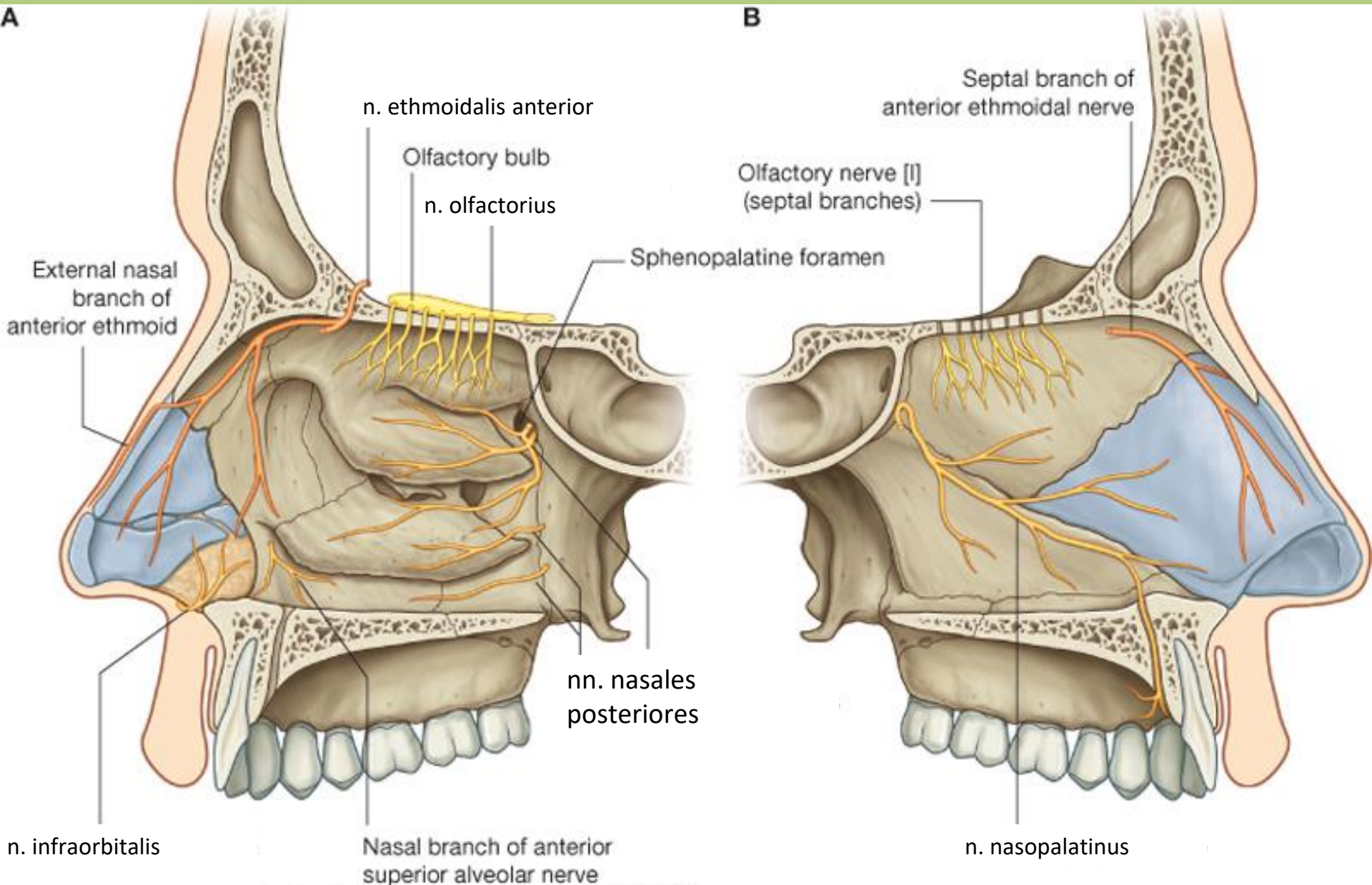
Vérellátás



Vérellátás



Beidegzés

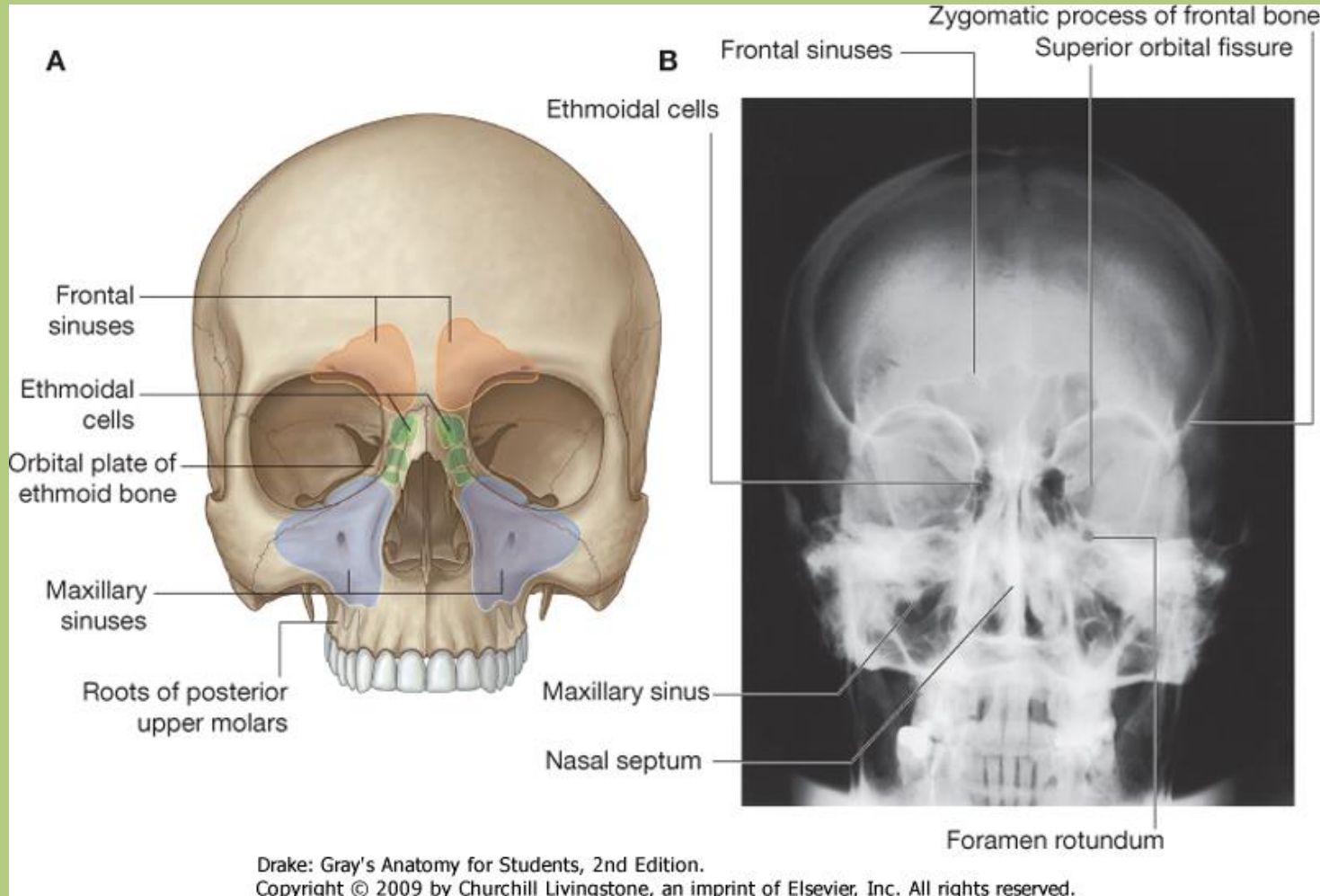


Drake: Gray's Anatomy for Students, 2nd Edition.

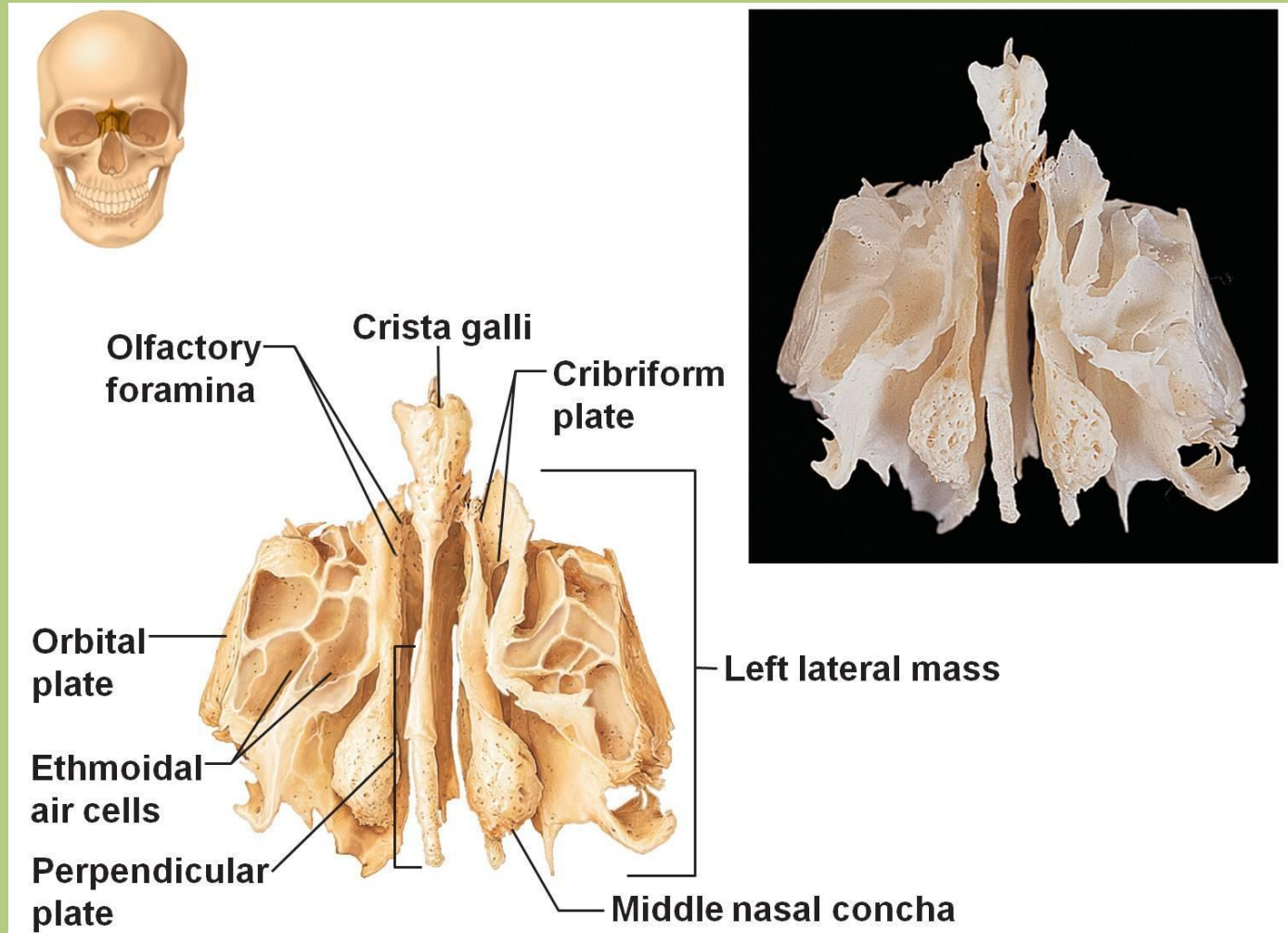
Copyright © 2009 by Churchill Livingstone, an imprint of Elsevier, Inc. All rights reserved.

Sinus paranasales

- kapcsolat a cavum nasival
- könnyítik a koponya súlyát
- többmagsoros csillószőrös hengerhám béleli
- melegítik és párásítják a levegőt
- rezonátorként működnek

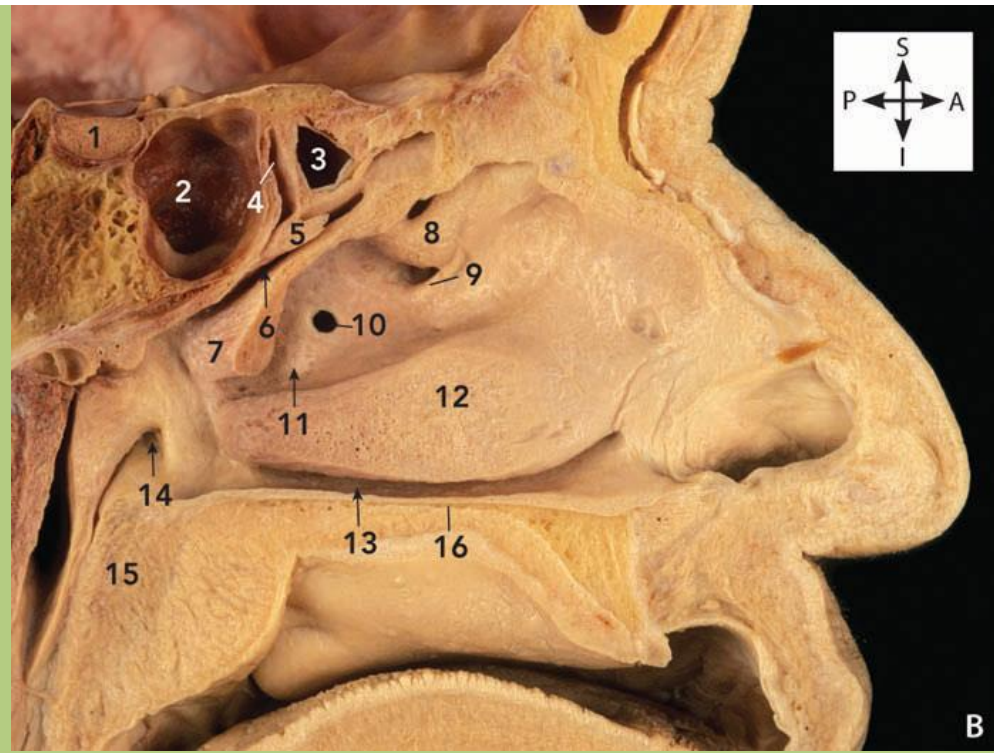
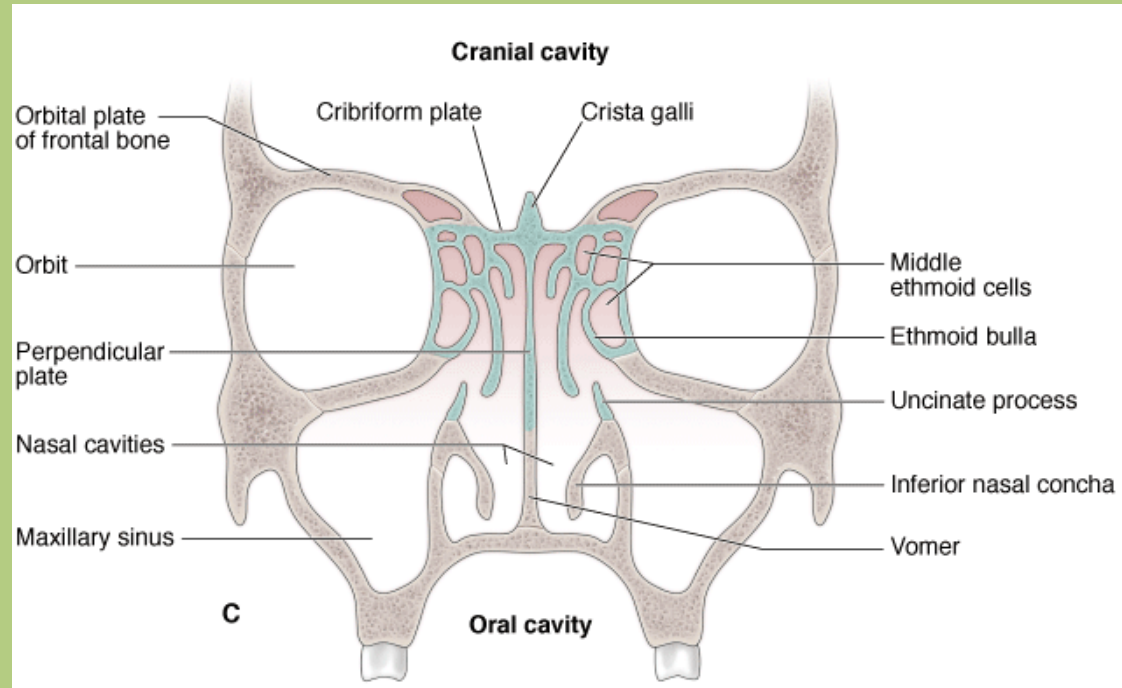


Cellulae ethmoidales

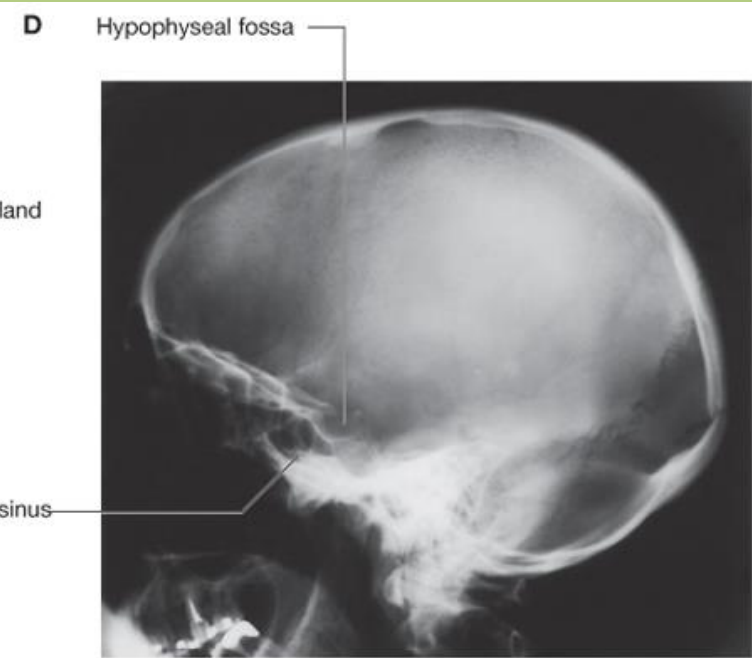
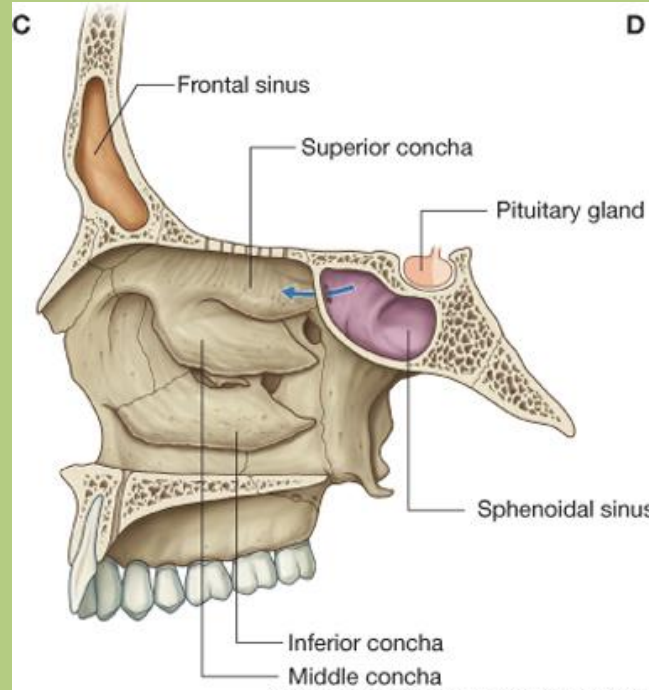


Cellulae ethmoidales

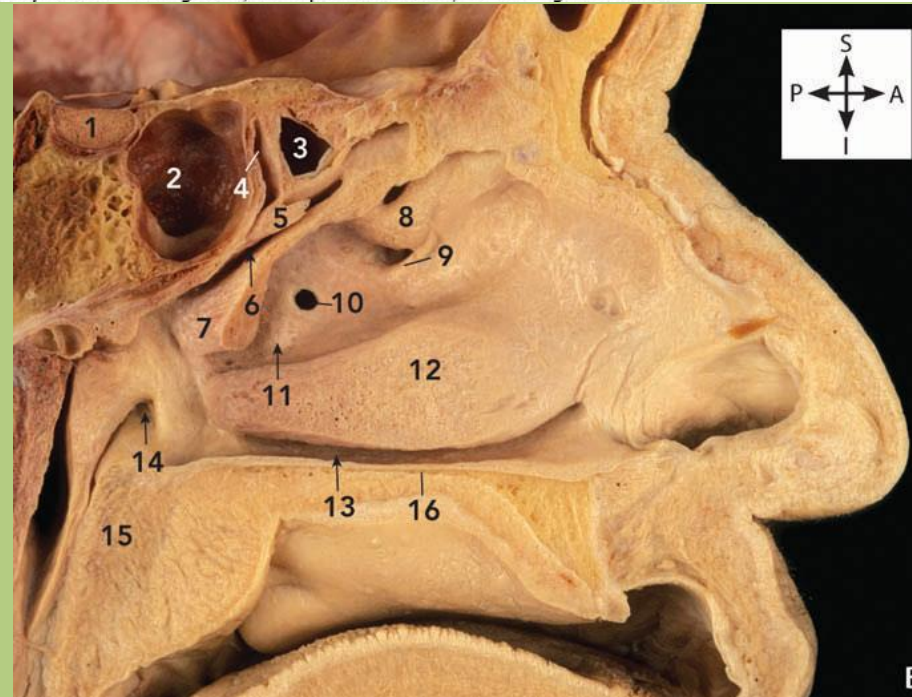
- bulla ethmoidalis (8)

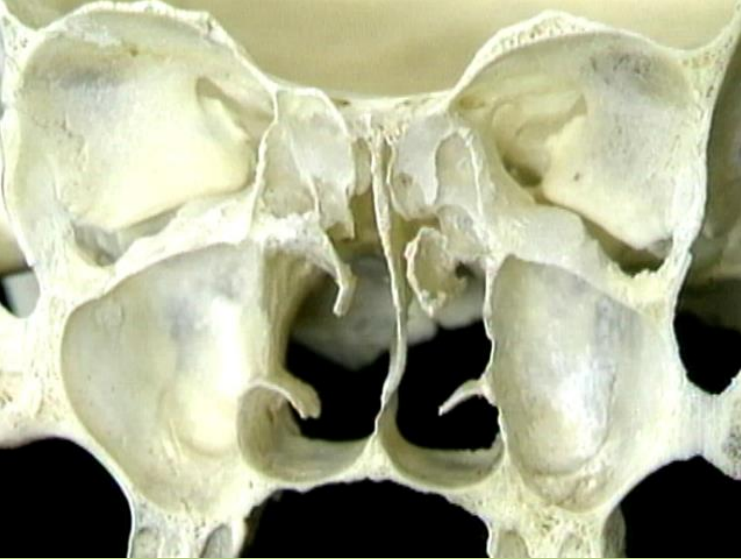

Sinus sphenoidalis (2)

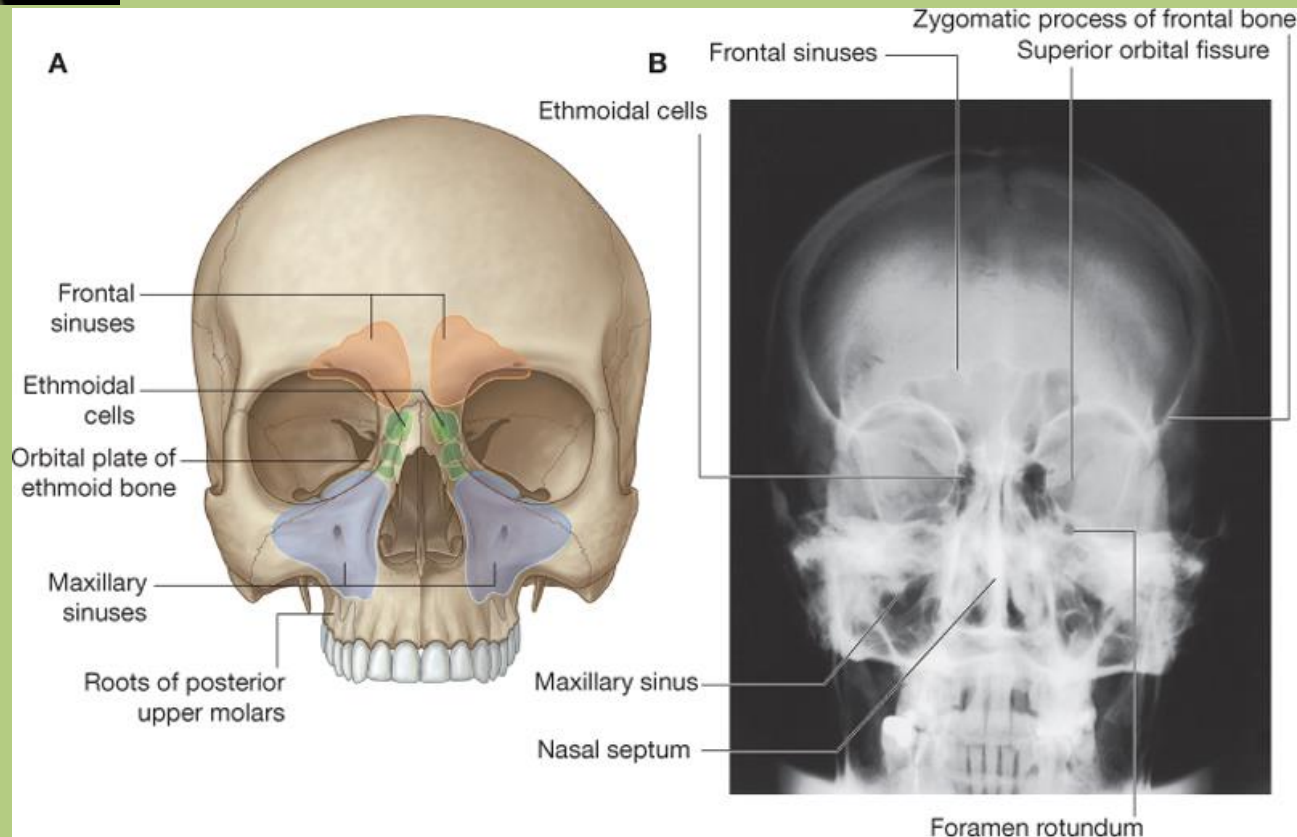


Drake: Gray's Anatomy for Students, 2nd Edition.
Copyright © 2009 by Churchill Livingstone, an imprint of Elsevier, Inc. All rights reserved.

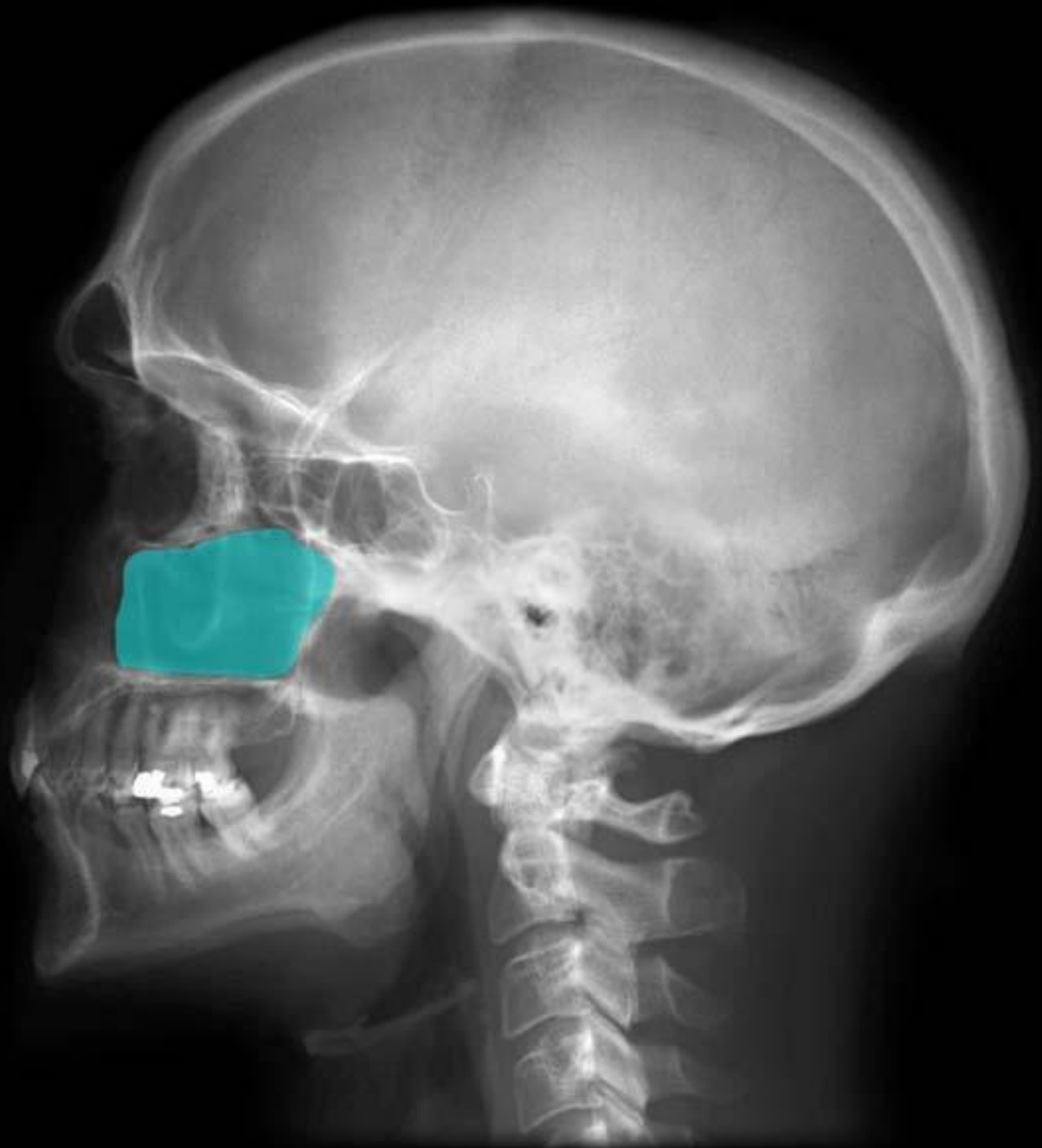




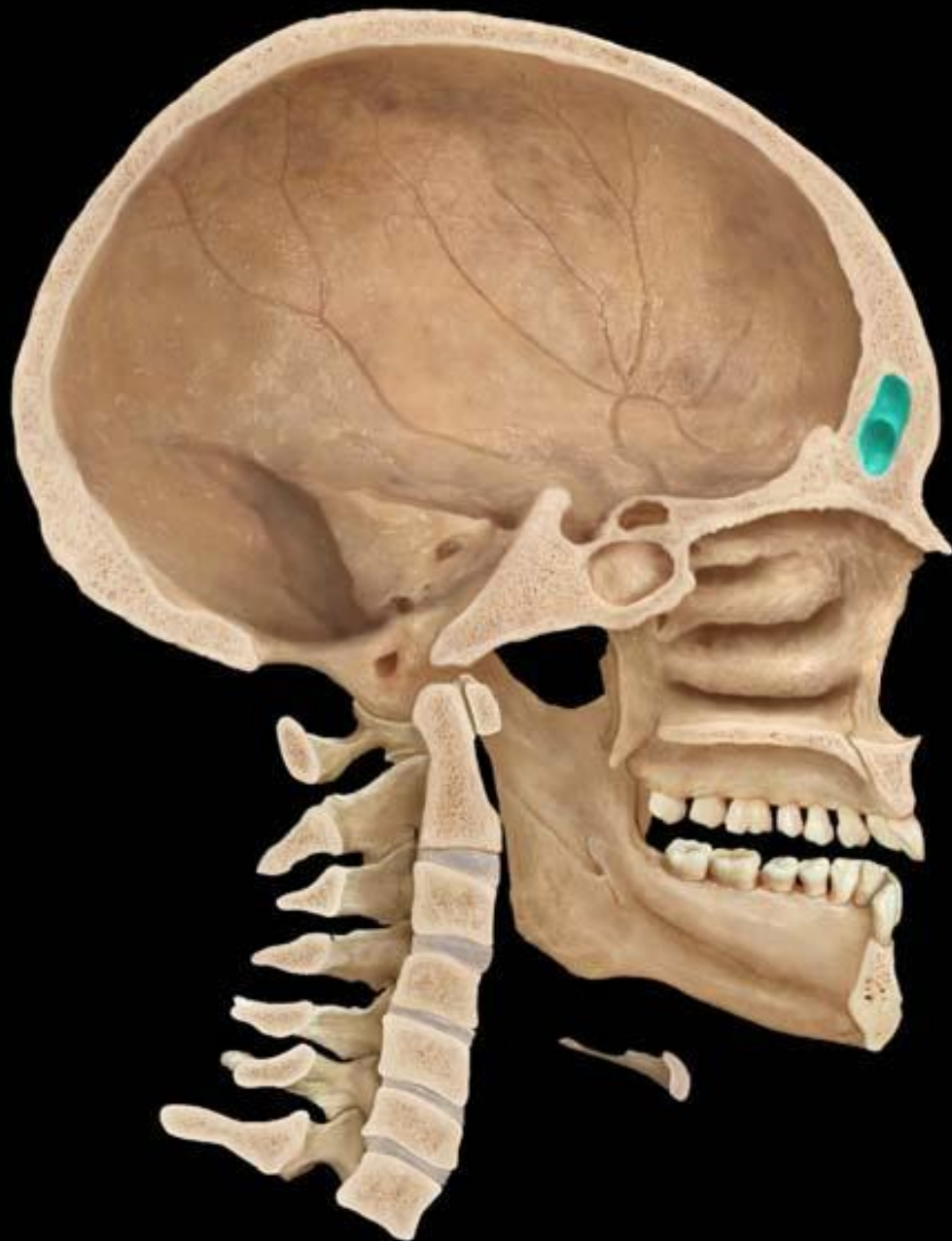Sinus maxillaris=
Highmore-féle öböl:

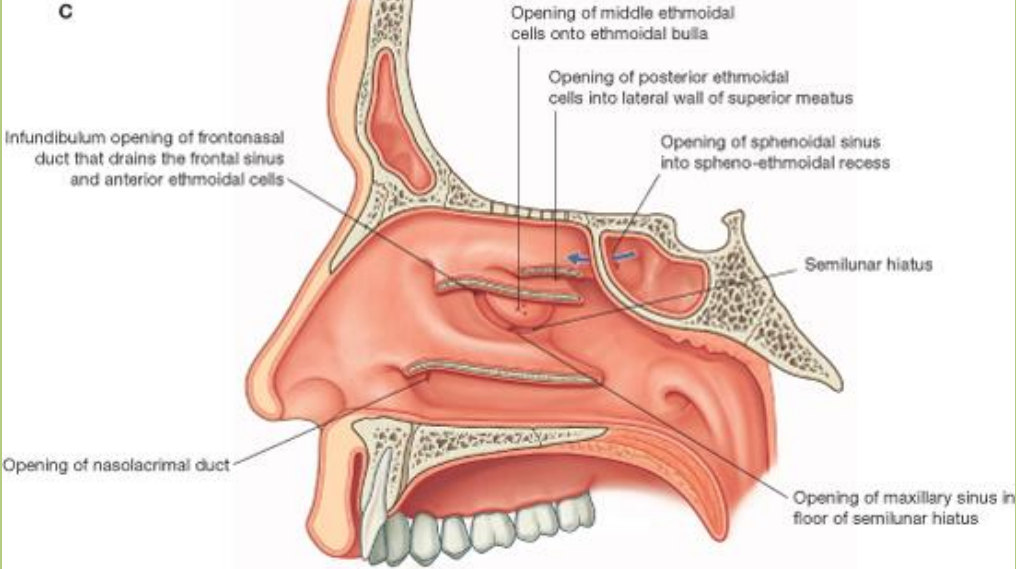


Sinus maxillaris=
Highmore-féle öböl:



Sinus frontalis

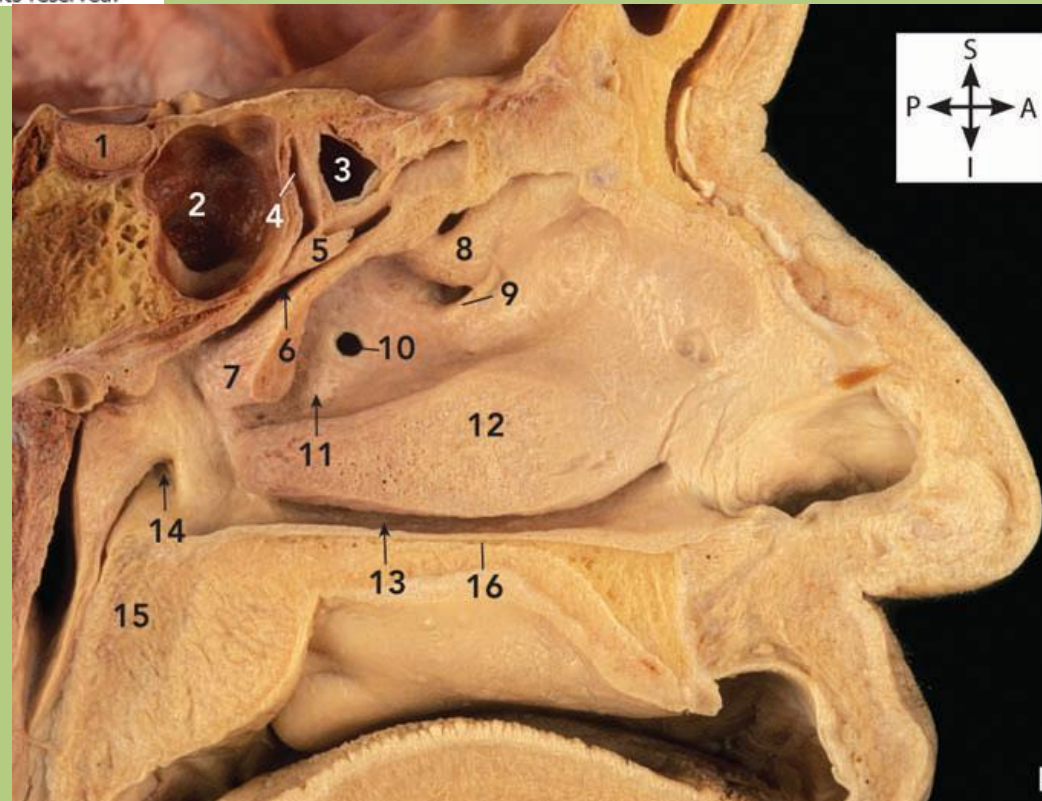




Drake: Gray's Anatomy for Students, 2nd Edition.
Copyright © 2009 by Churchill Livingstone, an imprint of Elsevier, Inc. All rights reserved.

Sinus paranasales nyílásai

1. hypophysis
2. sinus sphenoidalis
3. cellulae ethmoidales post.
4. recessus sphenoethmoidalis
5. concha nasalis superior
6. meatus nasi sup.
7. concha nasalis media
8. bulla ethmoidalis
9. hiatus semilunaris
10. sinus maxillaris nyílása
11. meatus nasi med.
12. concha nasalis inferior
13. meatus nasi inf.
14. ostium tubae auditivae
15. palatum molle
16. palatum durum



HEALTHY SINUS

SINUSITIS

Frontal Sinus

Inflamed Sinus Lining

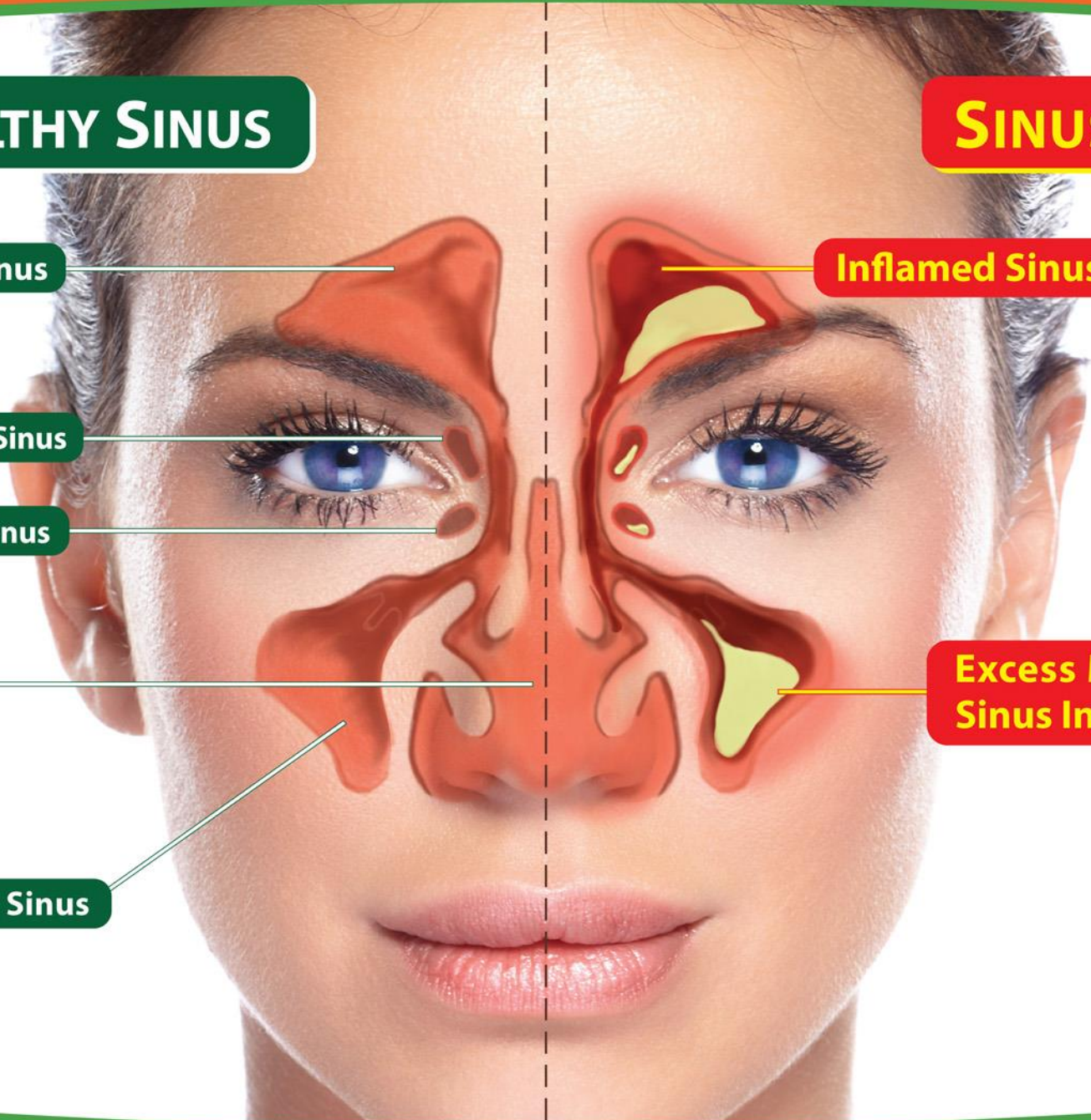
Sphenoid Sinus

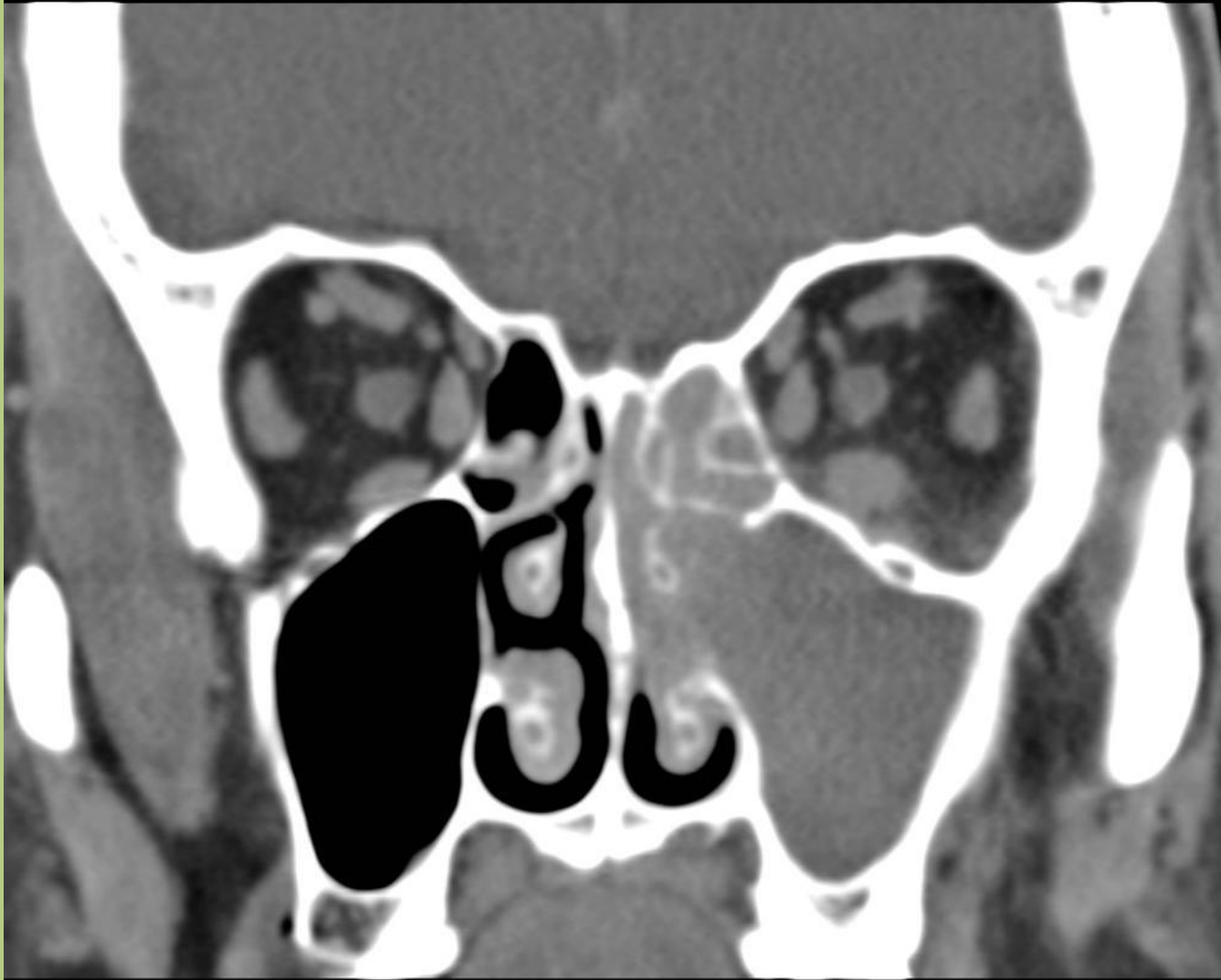
Ethmoid Sinus

Septum

Excess Mucus/
Sinus Infection

Maxillary Sinus

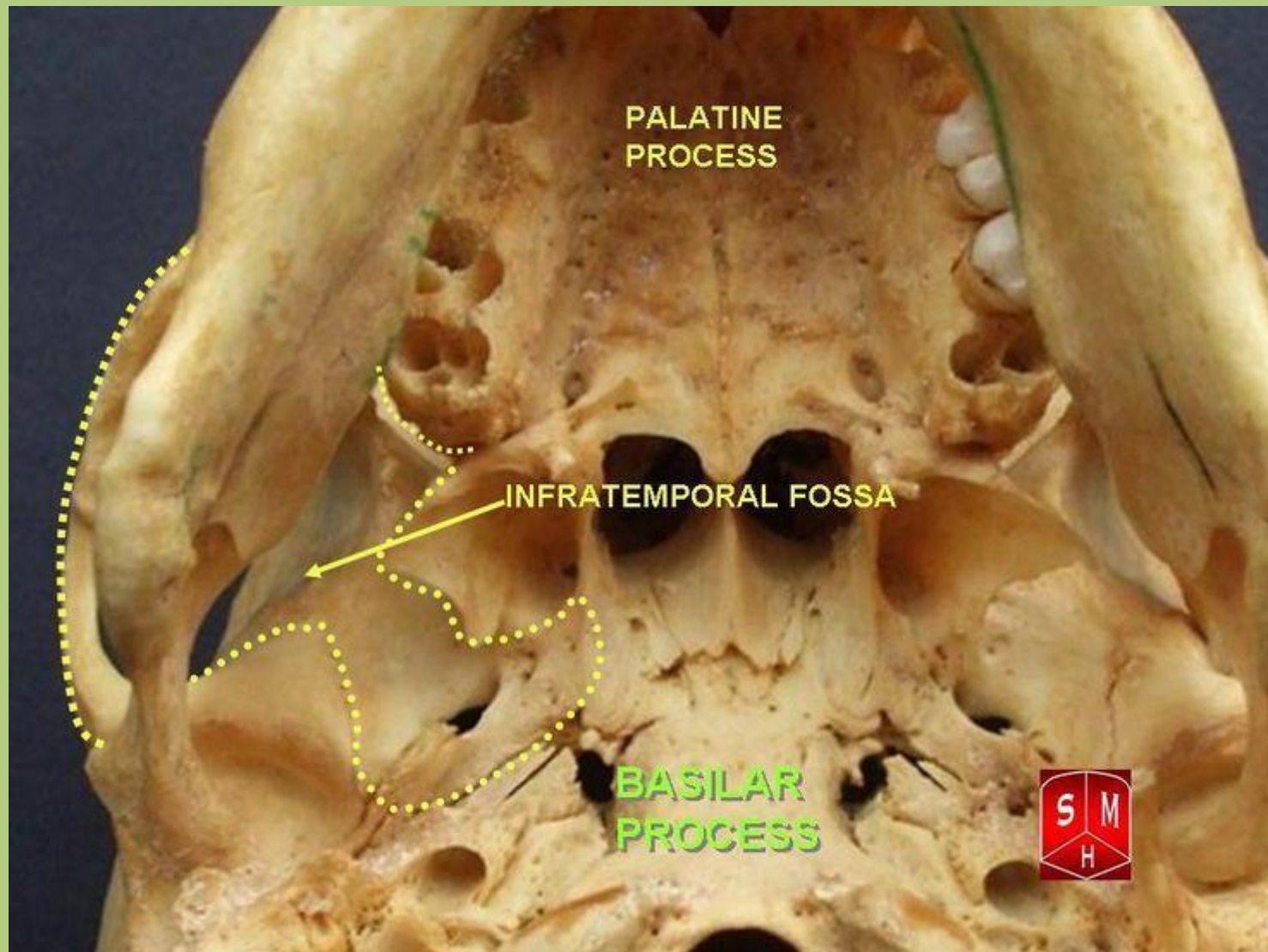




W 693 : L 114

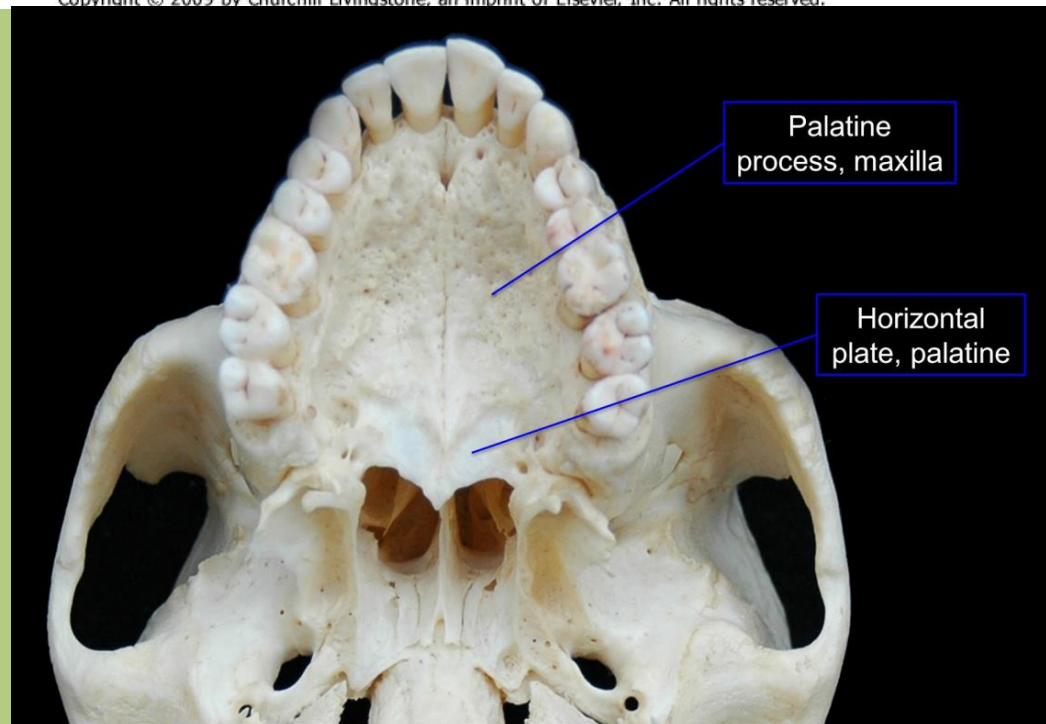
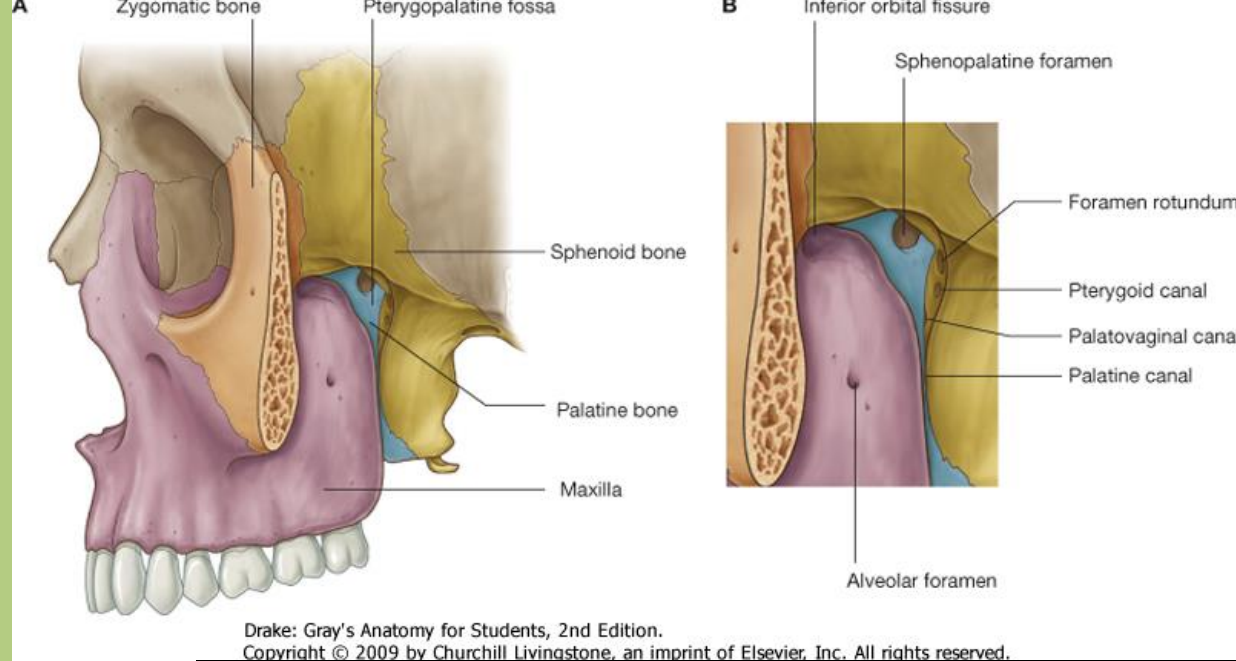
Fossa infratemporalis

- **anterior fal:**
corpus maxillae
- **medialis fal:**
lamina lateralis
processus
pterygoidei
- **superior fal:** ala
major ossis
sphenoidealis
- **posterior fal:**
art.
temporomandibularis

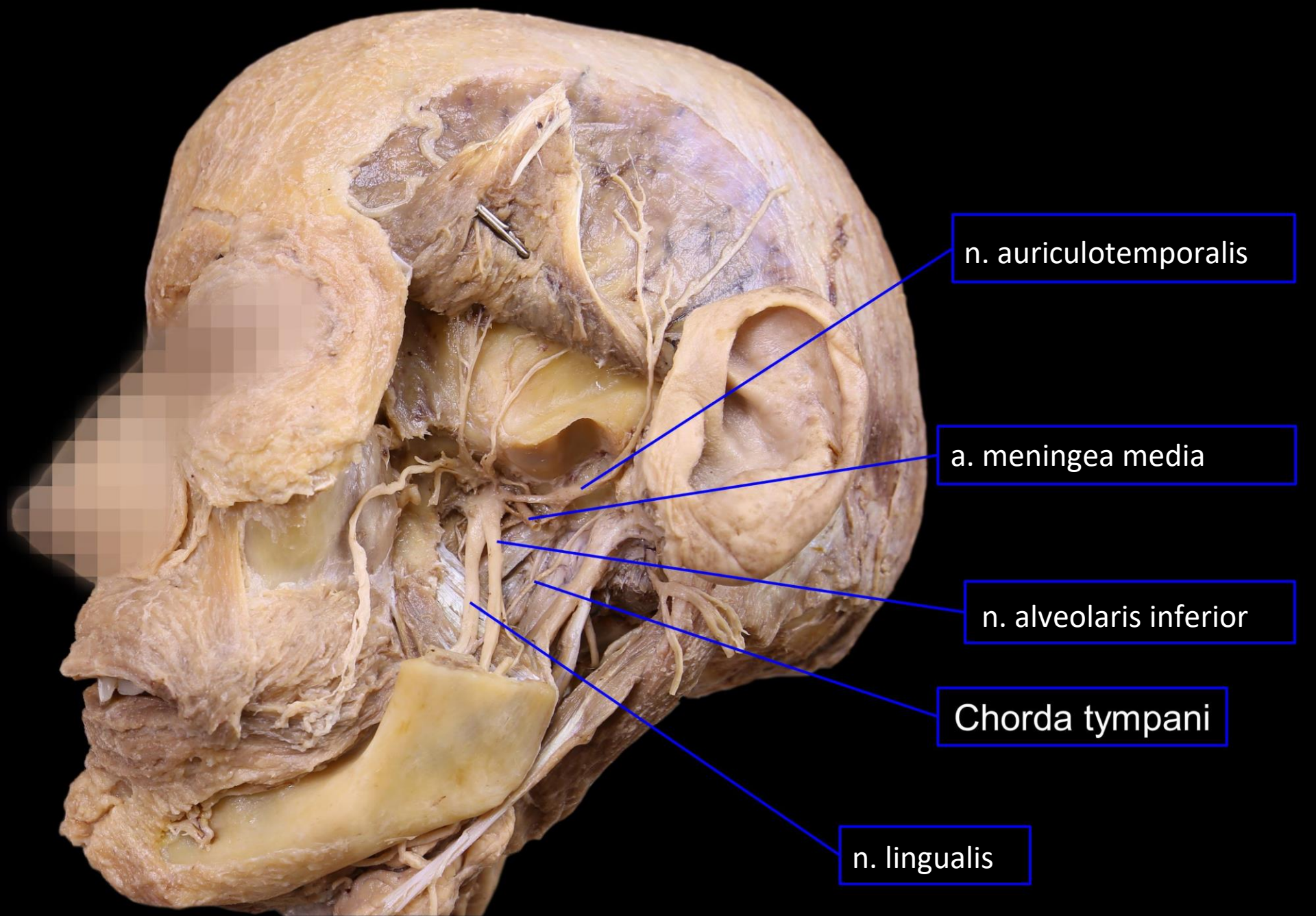


Fossa infratemporalis

- fissura orbitalis inferior (*n. zygomaticus, n/a/v. infraorbitalis, v. ophthalmica inf.*)
- fissura pterygomaxillaris (*a. maxillaris, nn. alveolares supp. postt.*)
- foramen ovale (*V/3*)
- foramen spinosum (*a. meningea media, r. meningeus nervi mandibulares*)



Hard palate, inferior



n. auriculotemporalis

a. meningea media

n. alveolaris inferior

Chorda tympani

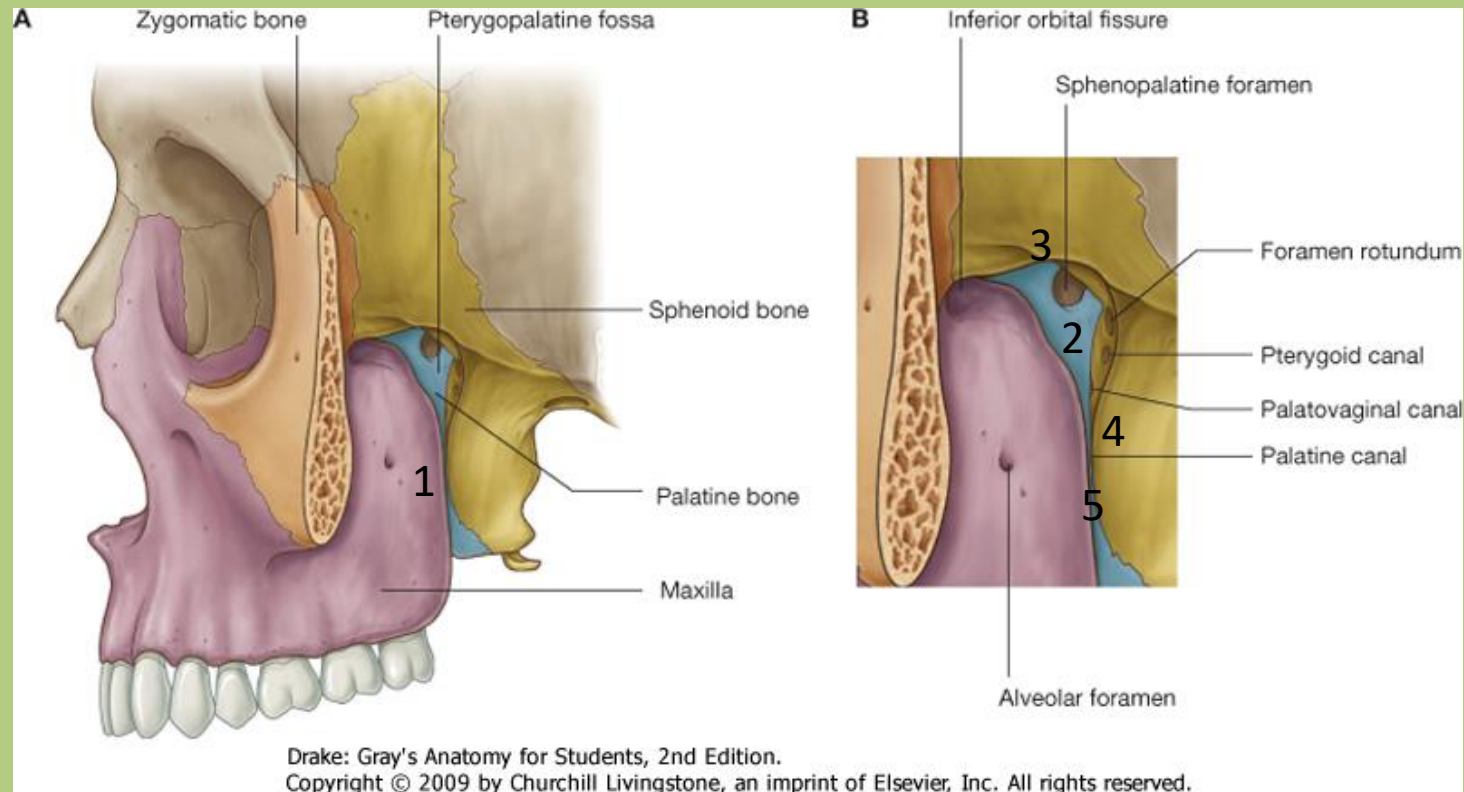
n. lingualis

Infratemporal fossa, lateral



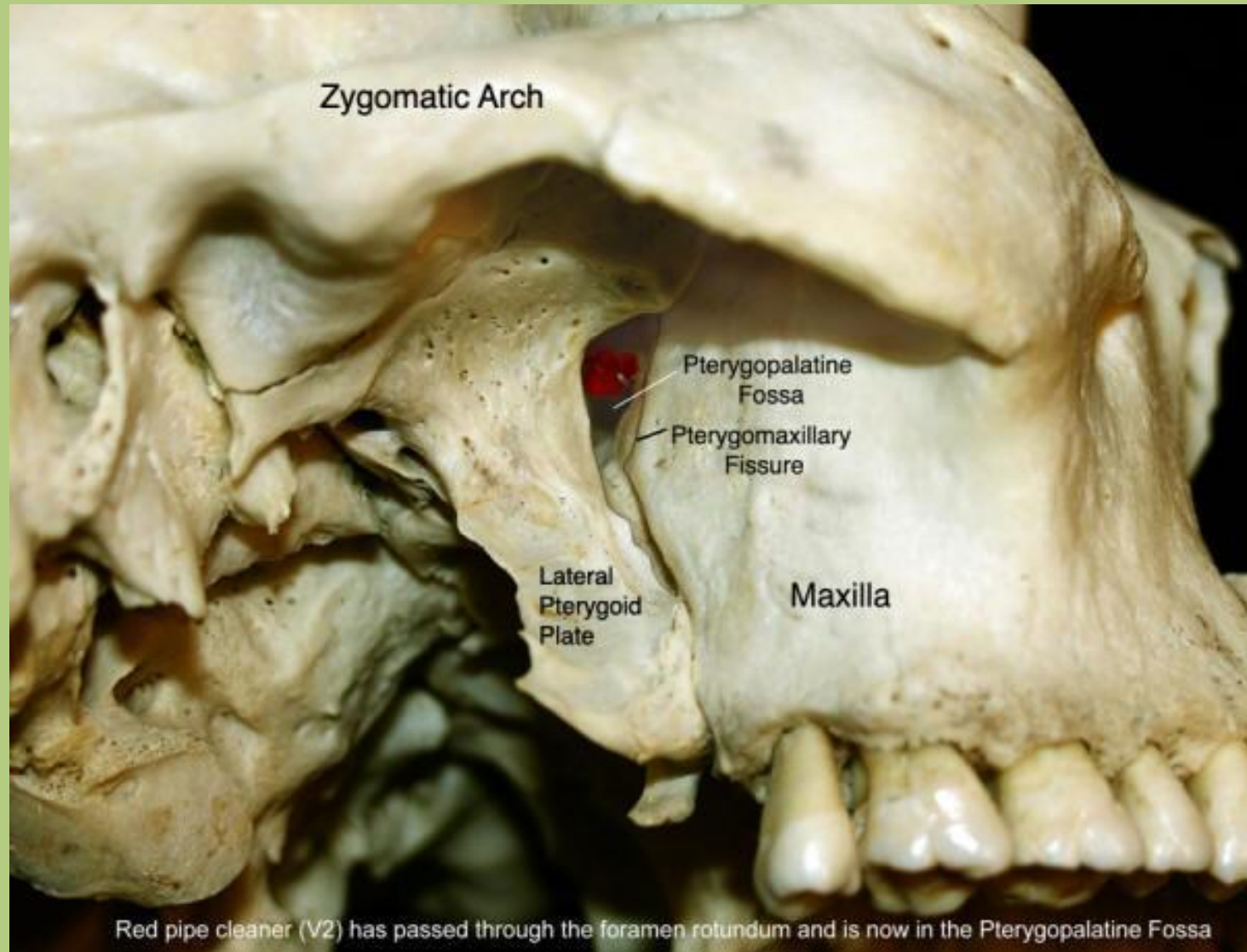
Fossa pterygopalatina

- **anterior fal:** tuber maxillae (1)
- **medialis fal:** lamina perpendicularis ossis palatini (2)
- **superior fal:** ala major ossis sphenoidalis (3)
- **posterior fal:** processus pterygoideus (4)
- **lateralis fal:** a fissura pterygomaxillaris on keresztül a fossa infratemporalis (5)



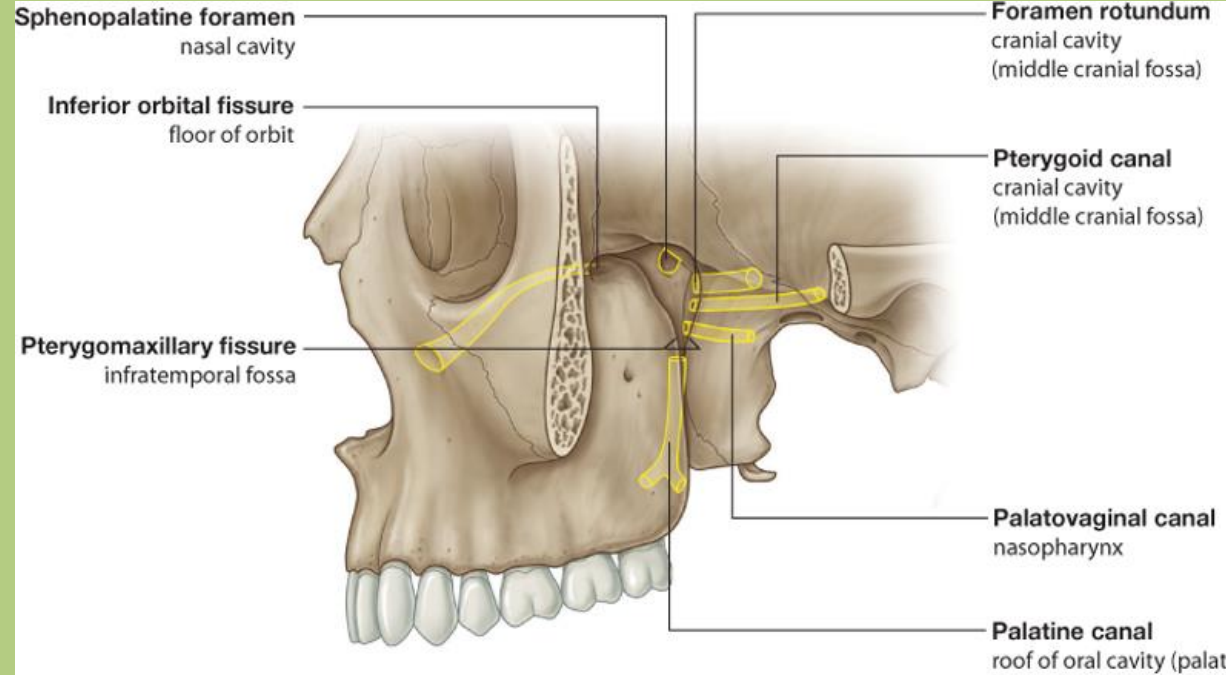
Fossa pterygopalatin a

- **anterior fal:**
tuber maxillae
- **medialis fal:**
lamina
perpendicularis
ossis palatini
- **superior fal:**
ala major ossis
sphenoidalis
- **posterior fal:**
processus
pterygoideus
- **lateralis fal:** a
fissura
pterygomaxillar
ison keresztül a
fossa
infratemporalis

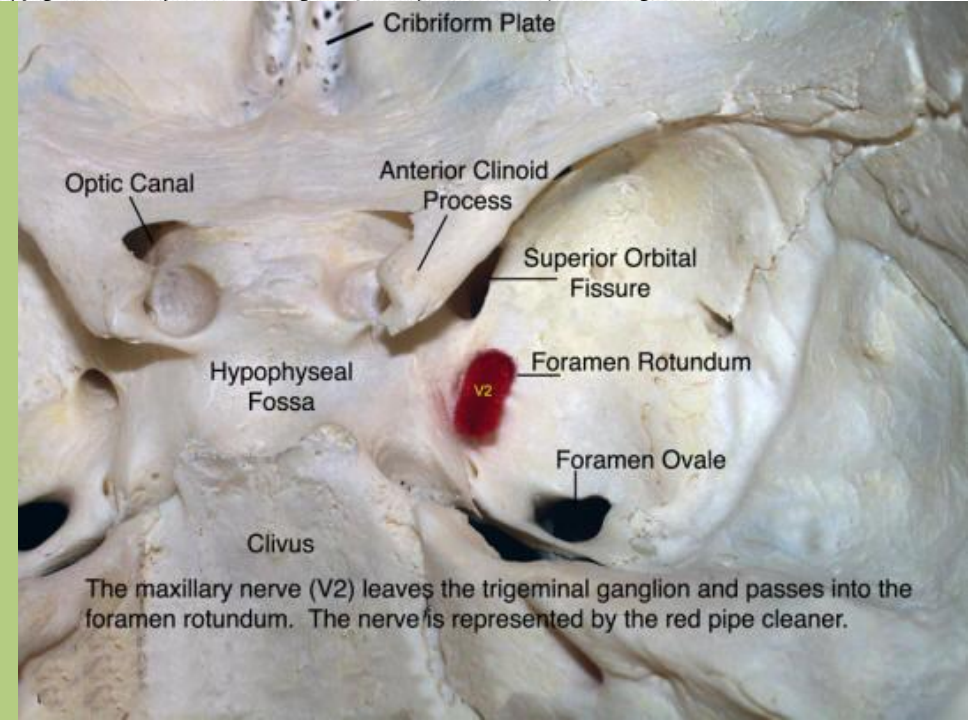


A fossa pterygopalatina összeköttetései:

- **foramen rotundum** a fossa cranii mediából. Tartalma: *n. maxillaris*.



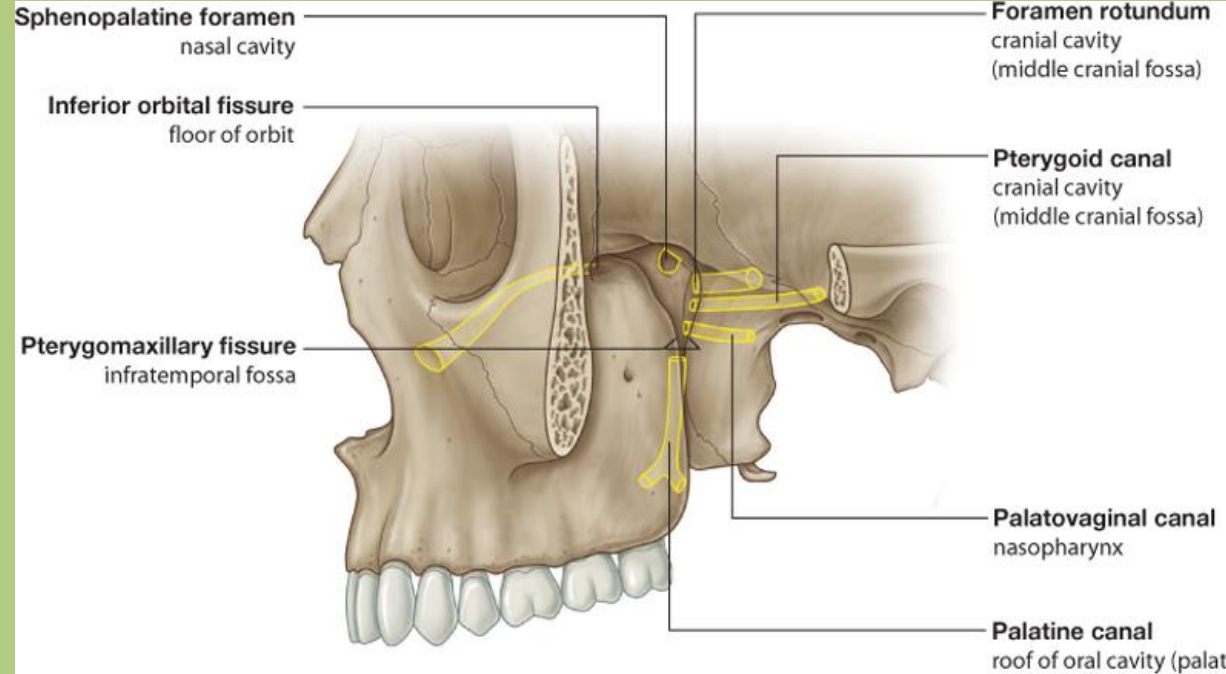
Drake: Gray's Anatomy for Students, 2nd Edition.
Copyright © 2009 by Churchill Livingstone, an imprint of Elsevier, Inc. All rights reserved.



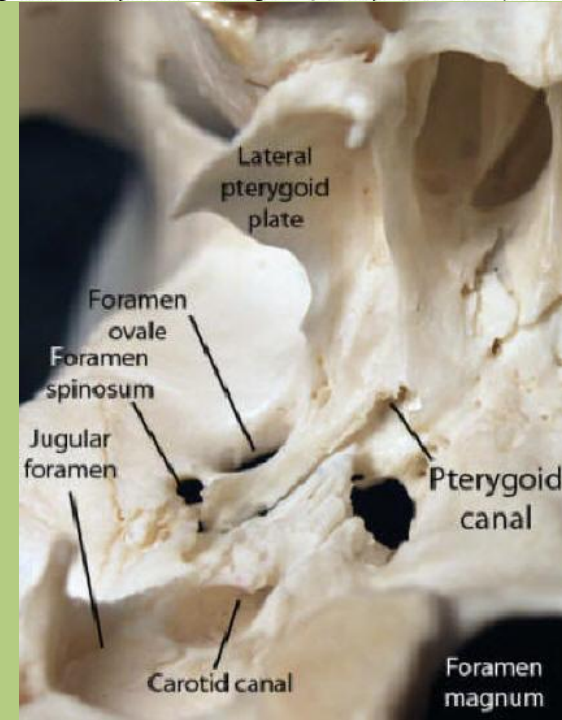
The maxillary nerve (V2) leaves the trigeminal ganglion and passes into the foramen rotundum. The nerve is represented by the red pipe cleaner.

**A fossa
pterygopalatina
összeköttetései:**

- **canalis pterygoideus (Vidian):** a külső koponyalapról. Tartalma: *n. petrosus major et n. petrosus profundus, erek.*

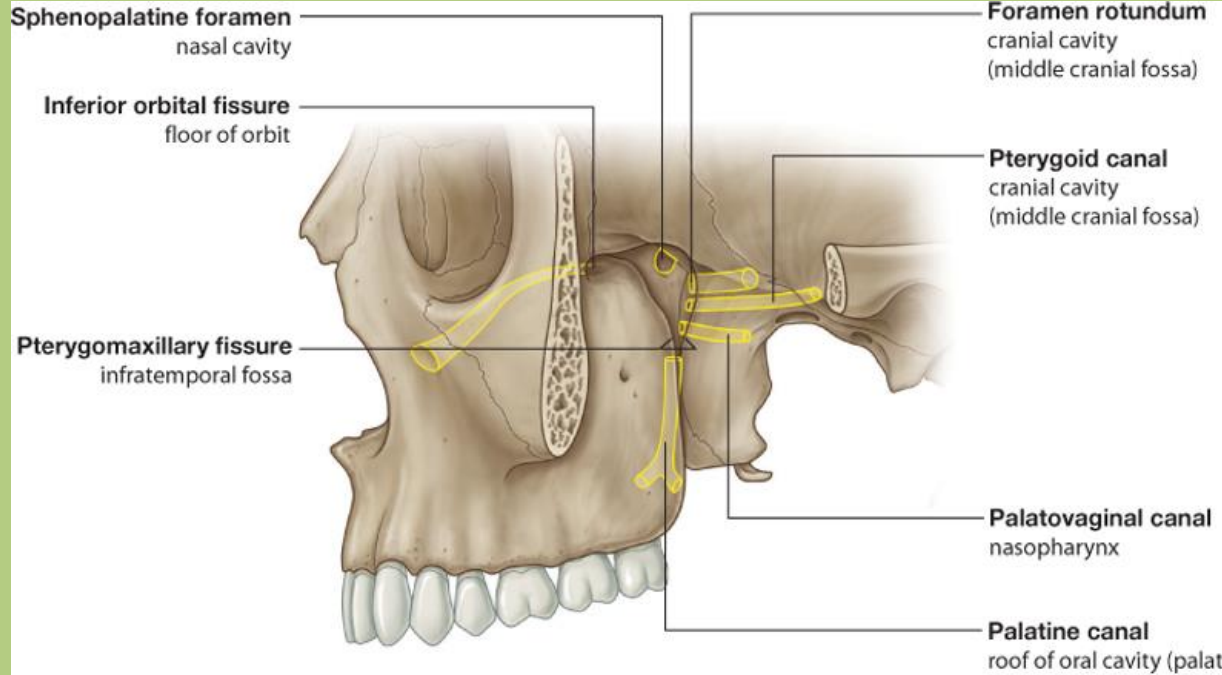


Drake: Gray's Anatomy for Students, 2nd Edition.
Copyright © 2009 by Churchill Livingstone, an imprint of Elsevier, Inc. All rights reserved.

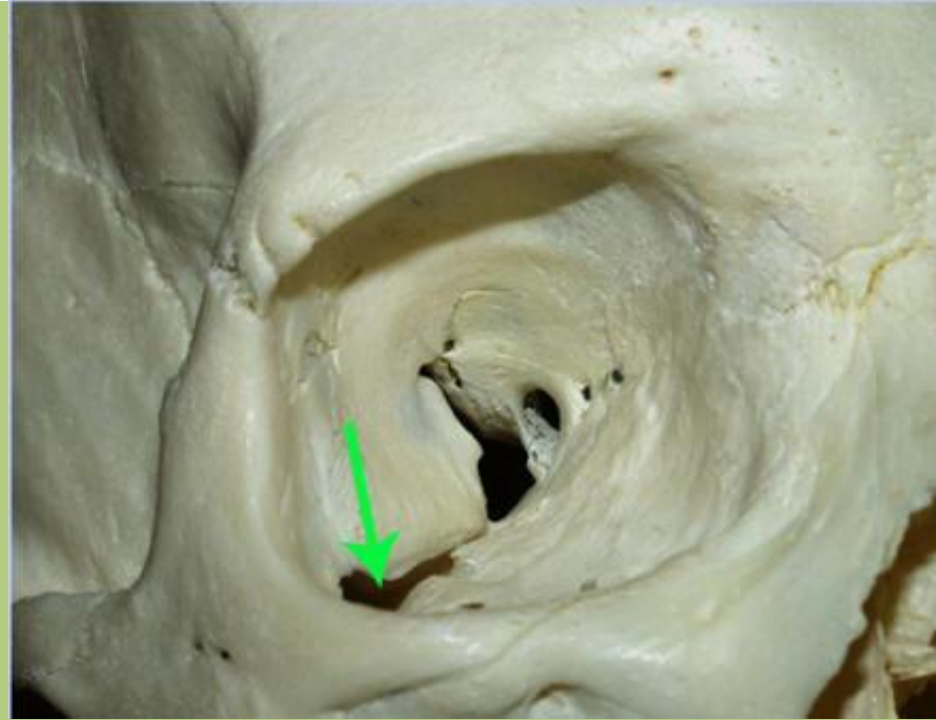


**A fossa
pterygopalatina
összeköttetései:**

- **fissura orbitalis inferior** az orbitával teremt kapcsolatot. Tartalma: *n. infraorbitalis*, *n. zygomaticus*, *a./v. infraorbitalis*, *v. ophthalmica inferior*.

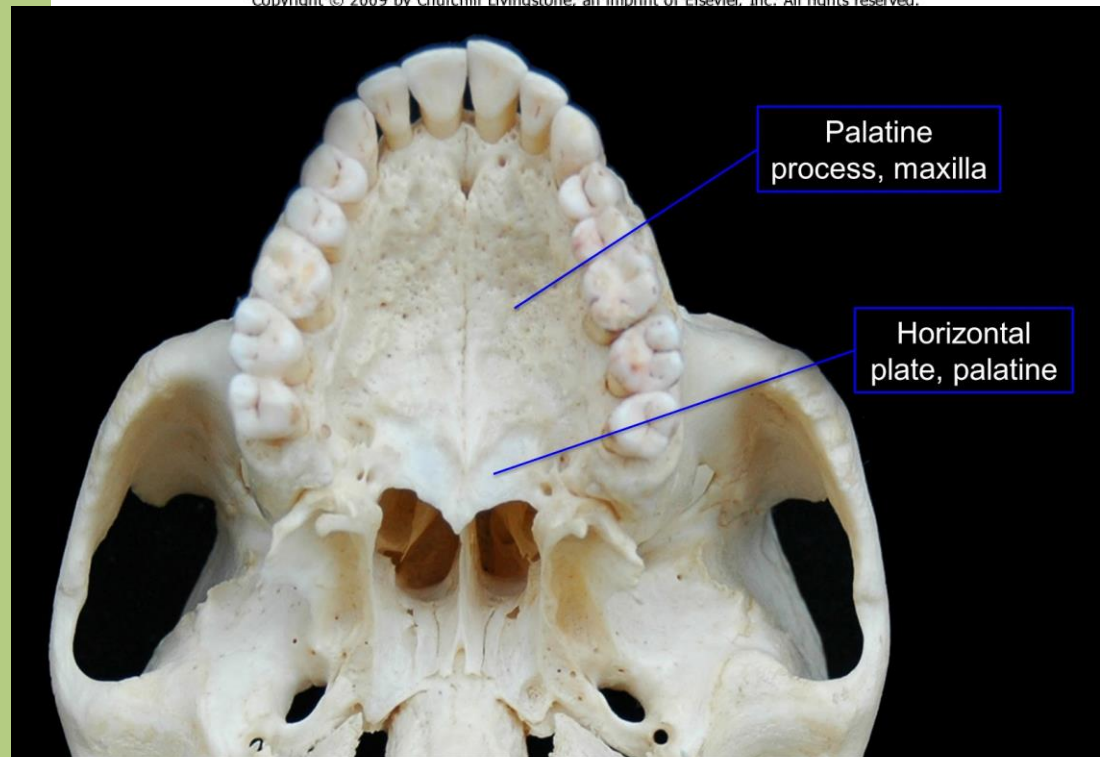
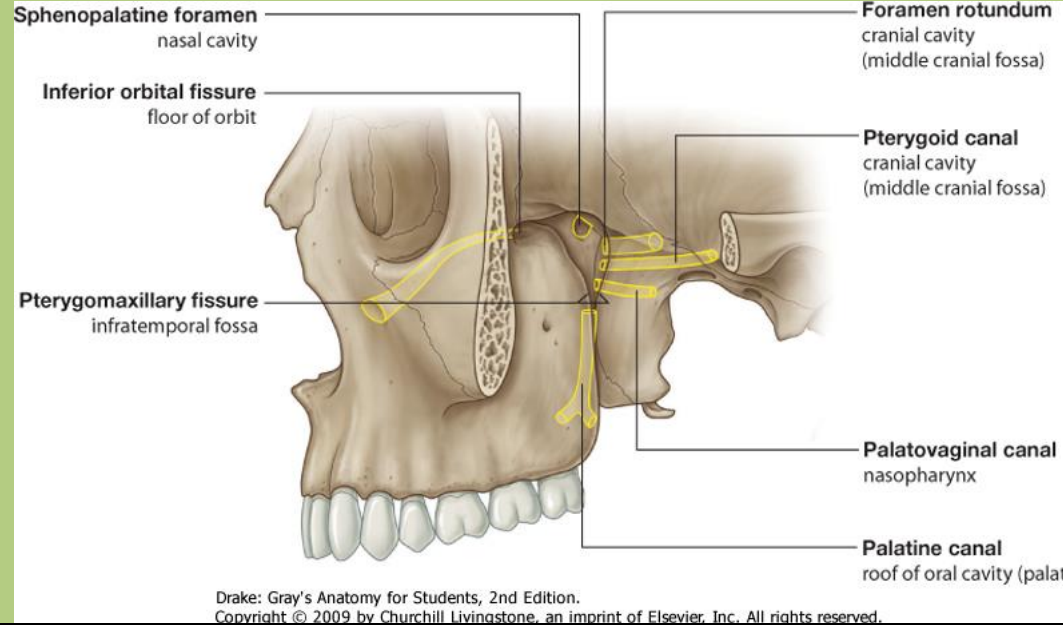


Drake: Gray's Anatomy for Students, 2nd Edition.
Copyright © 2009 by Churchill Livingstone, an imprint of Elsevier, Inc. All rights reserved.



A fossa
pterygopalatina
összeköttetései:

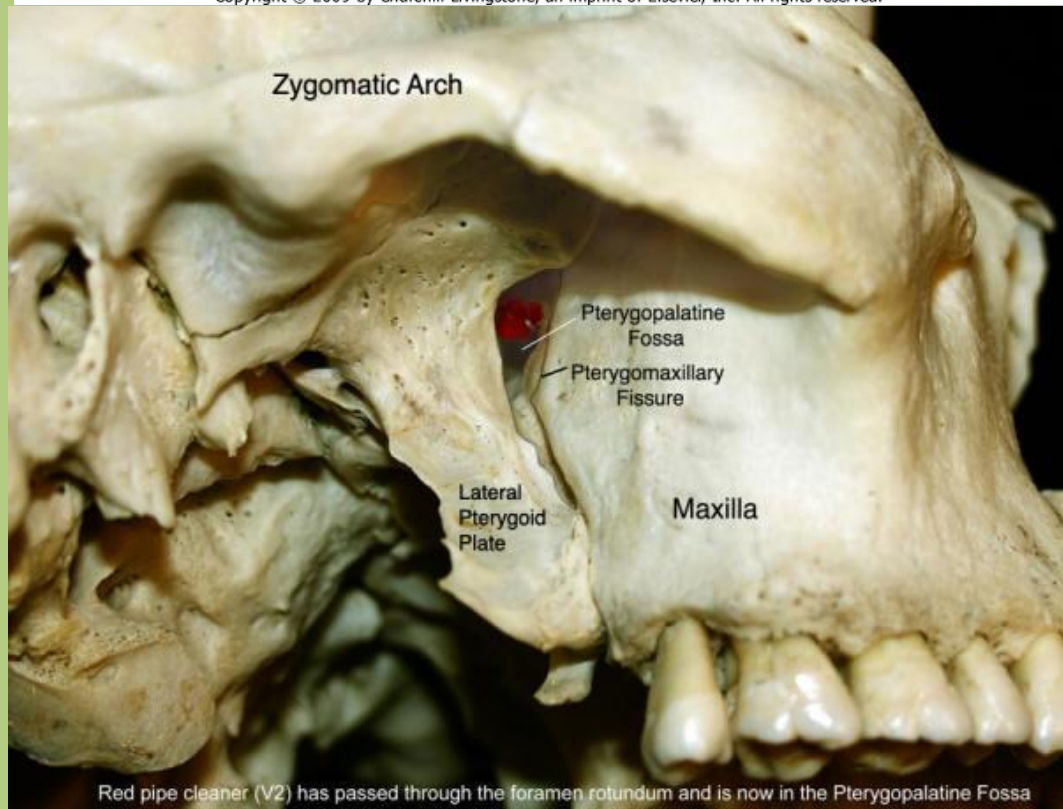
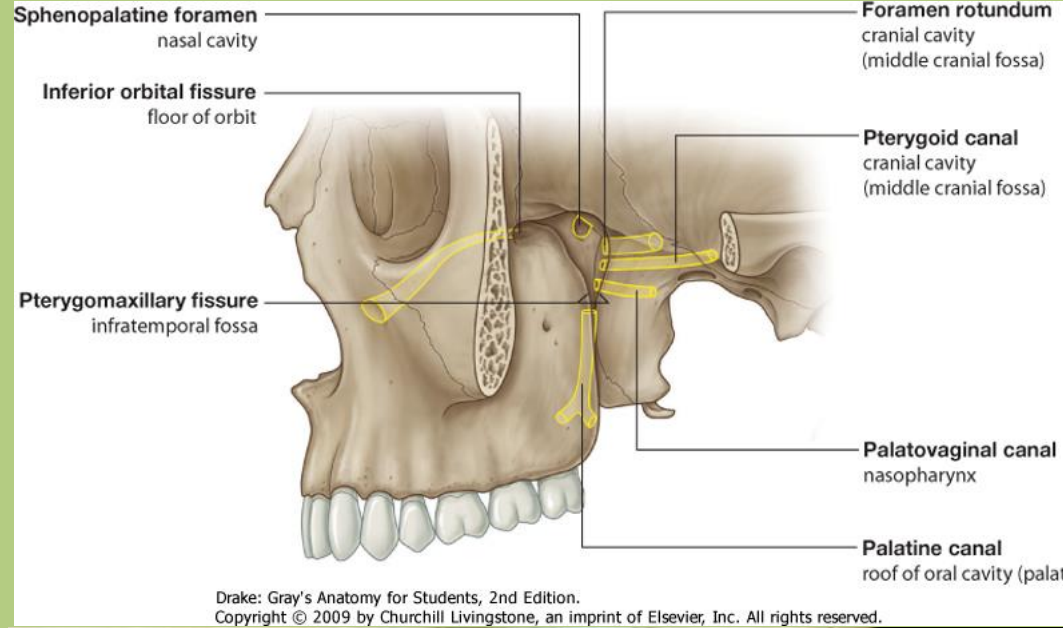
- **canales palatini majores et minores** a szájüreggel teremtkapcsolatot. Tartalma: *n. palatinus major, nn. palatini minores, aa. palatini majores et minores, a. palatina descendens.*



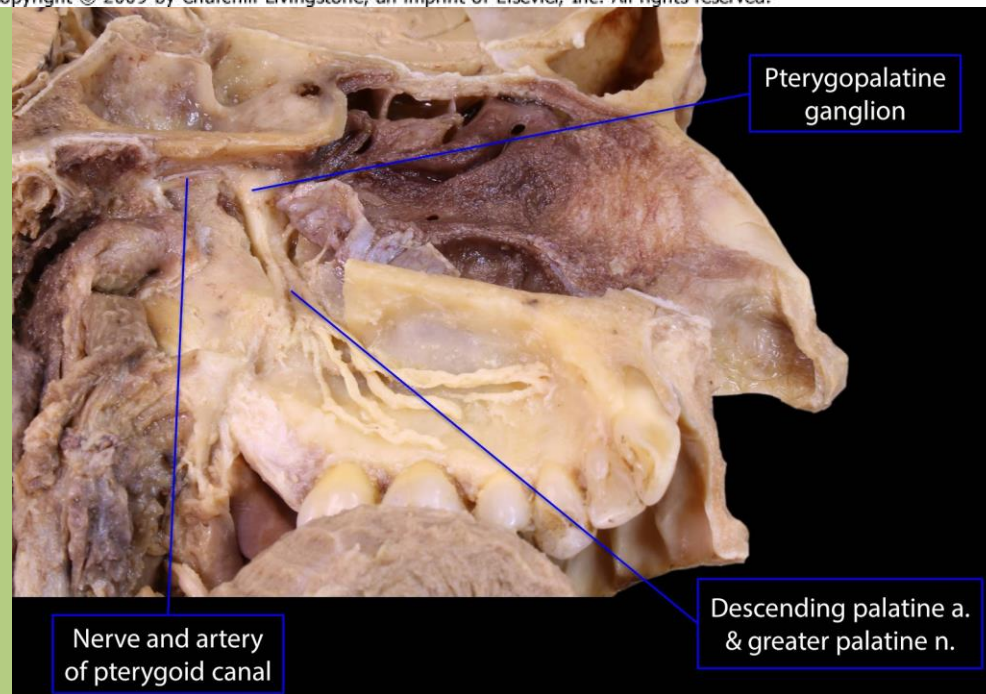
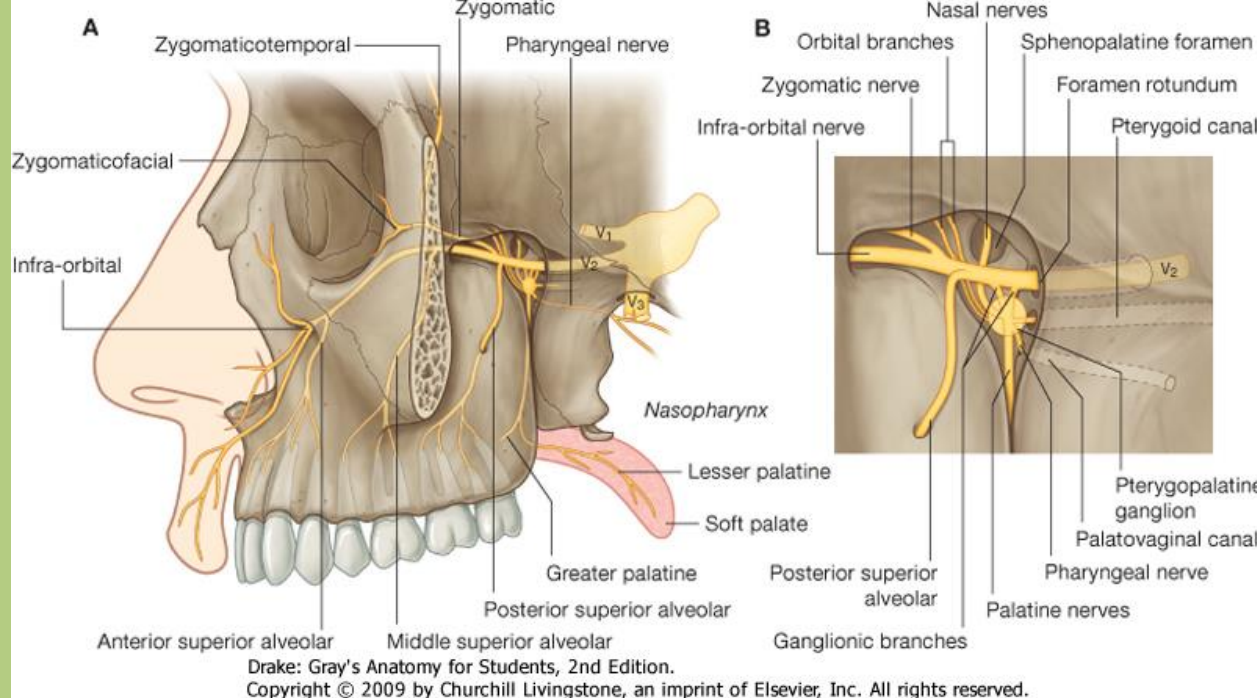
Hard palate, inferior

A fossa pterygopalatina összeköttetései:

- **foramen sphenopalatinu**m a cavum nasival teremt kapcsolatot. Tartalom: *a. sphenopalatina, nn. nasales postt. supp., n. nasopalatinus.*

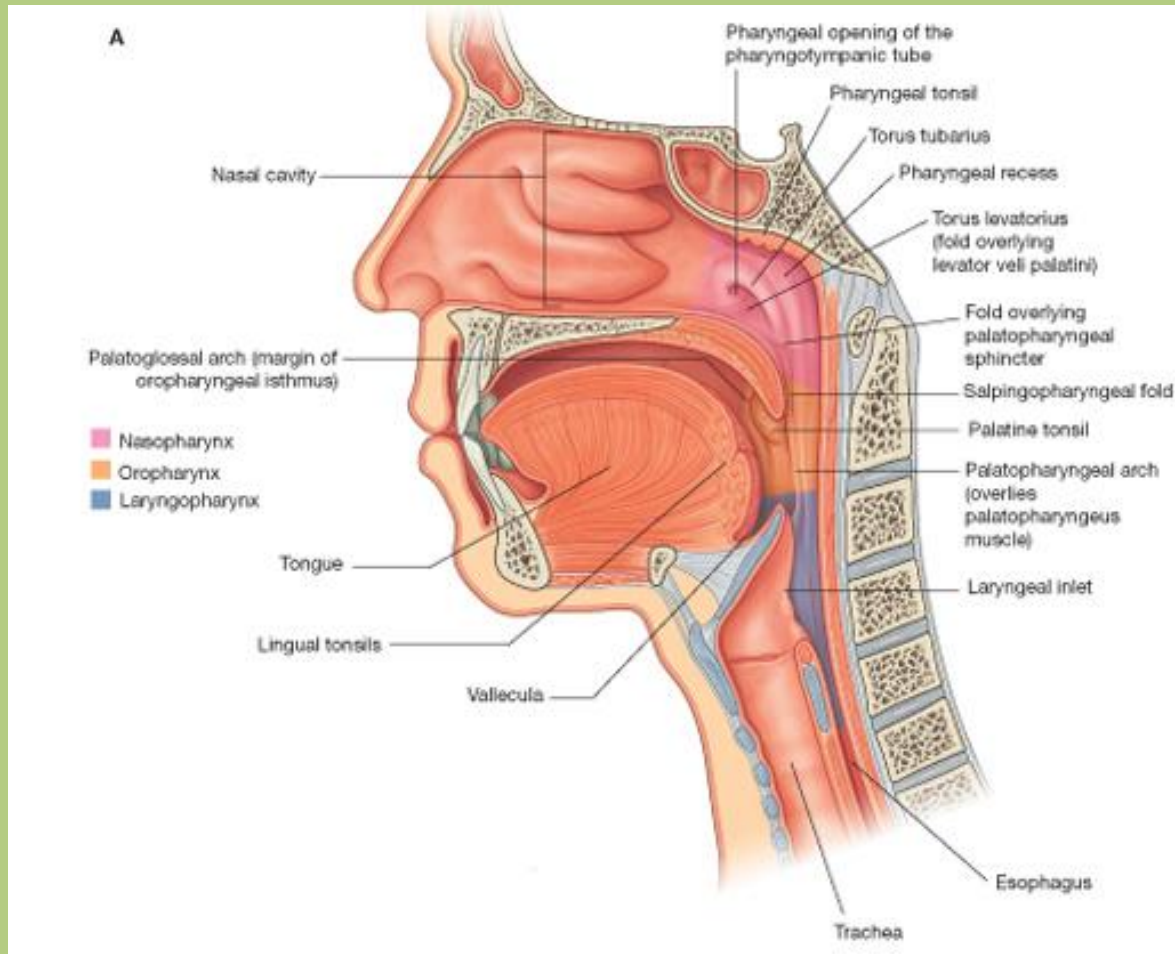


Ganglion pterygopalatinu m



Pterygopalatine fossa, inferomedial

Cavum oris



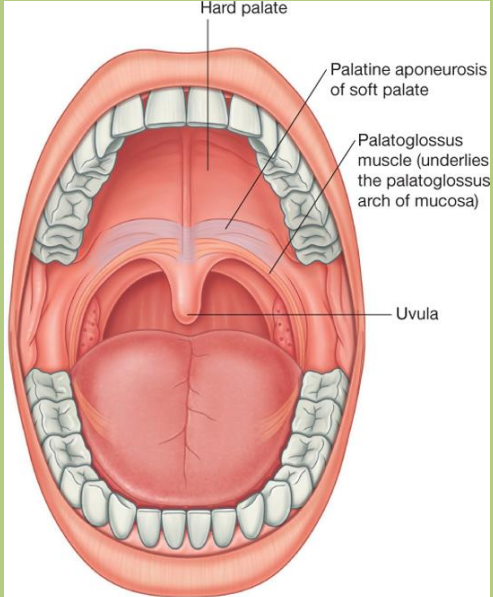
Határai:

- Anterior fal: ajkak
- Superior fal: palatum durum, palatum molle
- Inferior fal: m. mylohyoideus
- Lateral fal: pofa (m. buccinator)

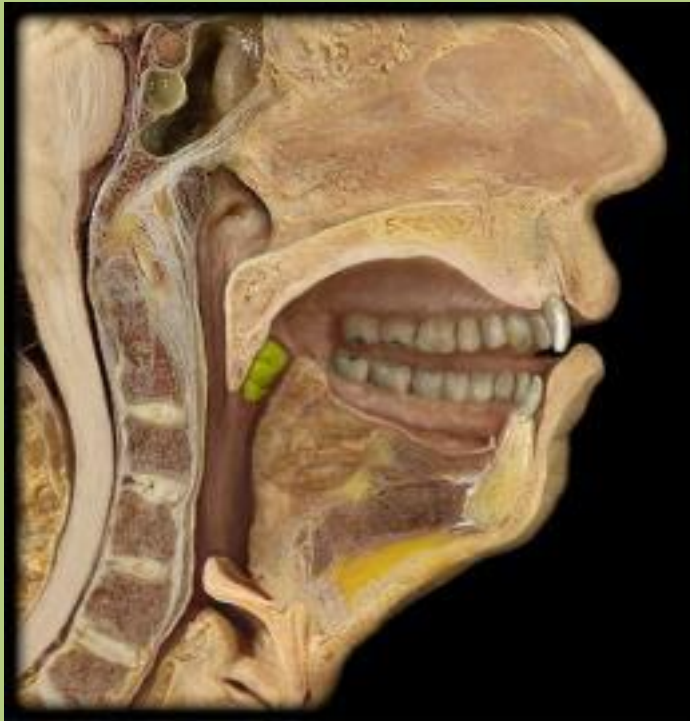Részei:

- vestibulum oris
- cavum oris proprium
- isthmus faucium

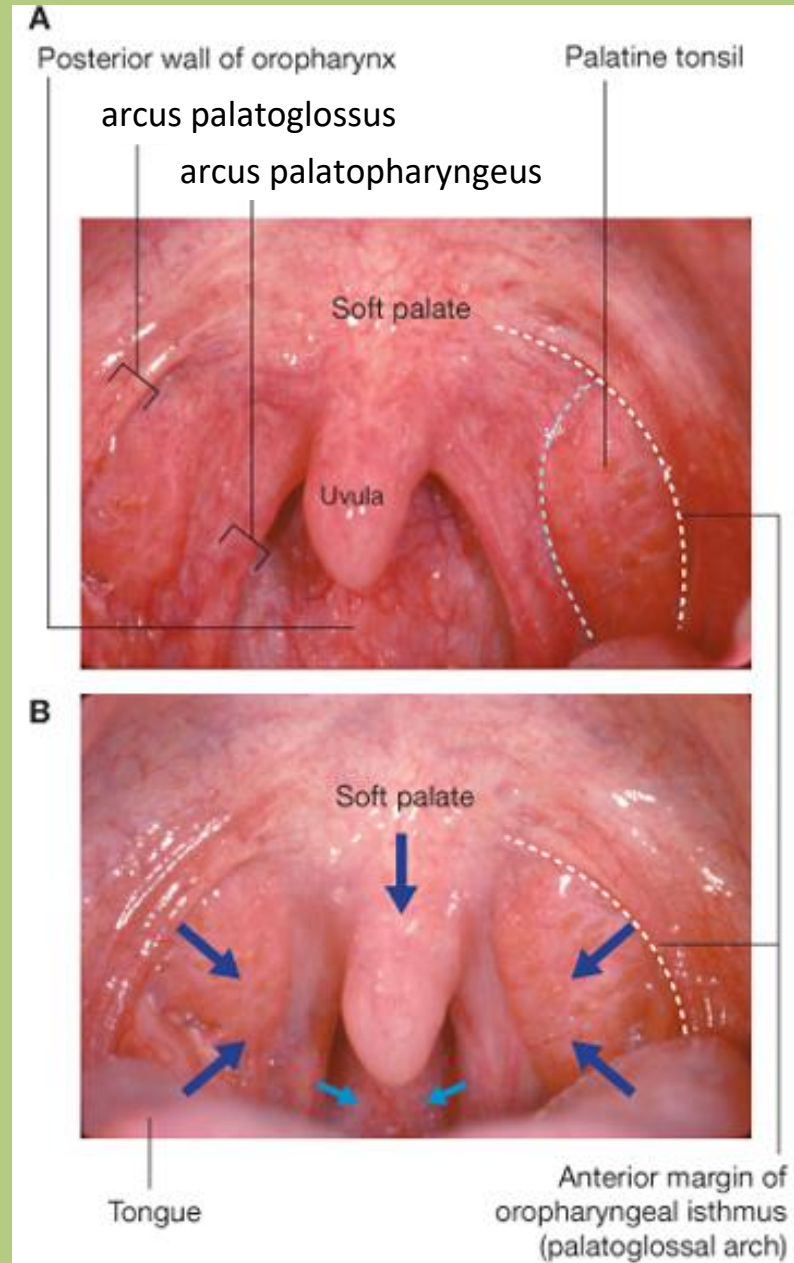
Isthmus faucium



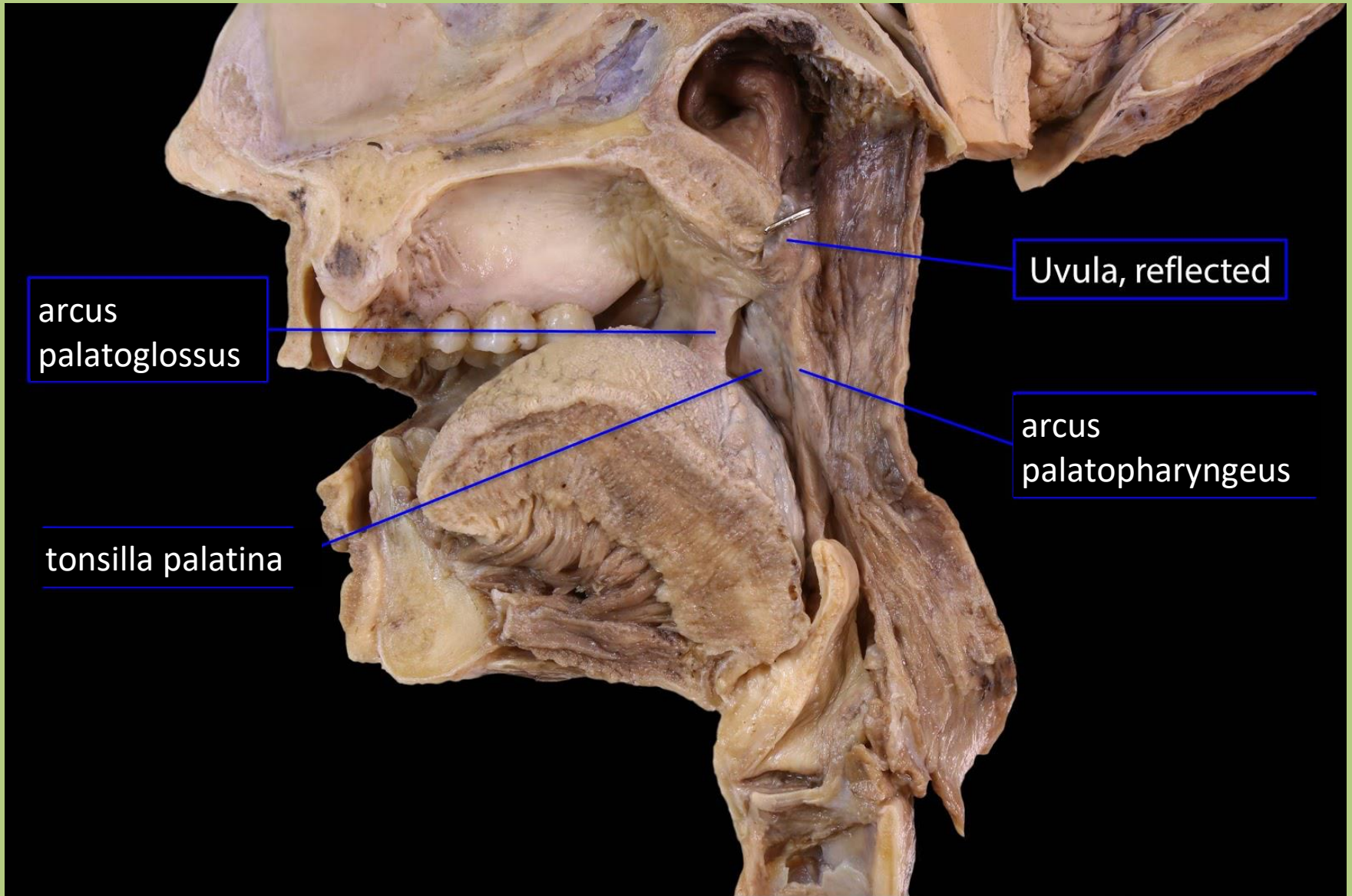
Drake: Gray's Anatomy for Students, 2nd Edition.
Copyright © 2009 by Churchill Livingstone, an imprint of Elsevier, Inc. All rights reserved.



tonsilla palatina



Isthmus faucium



arcus
palatoglossus

Uvula, reflected

tonsilla palatina

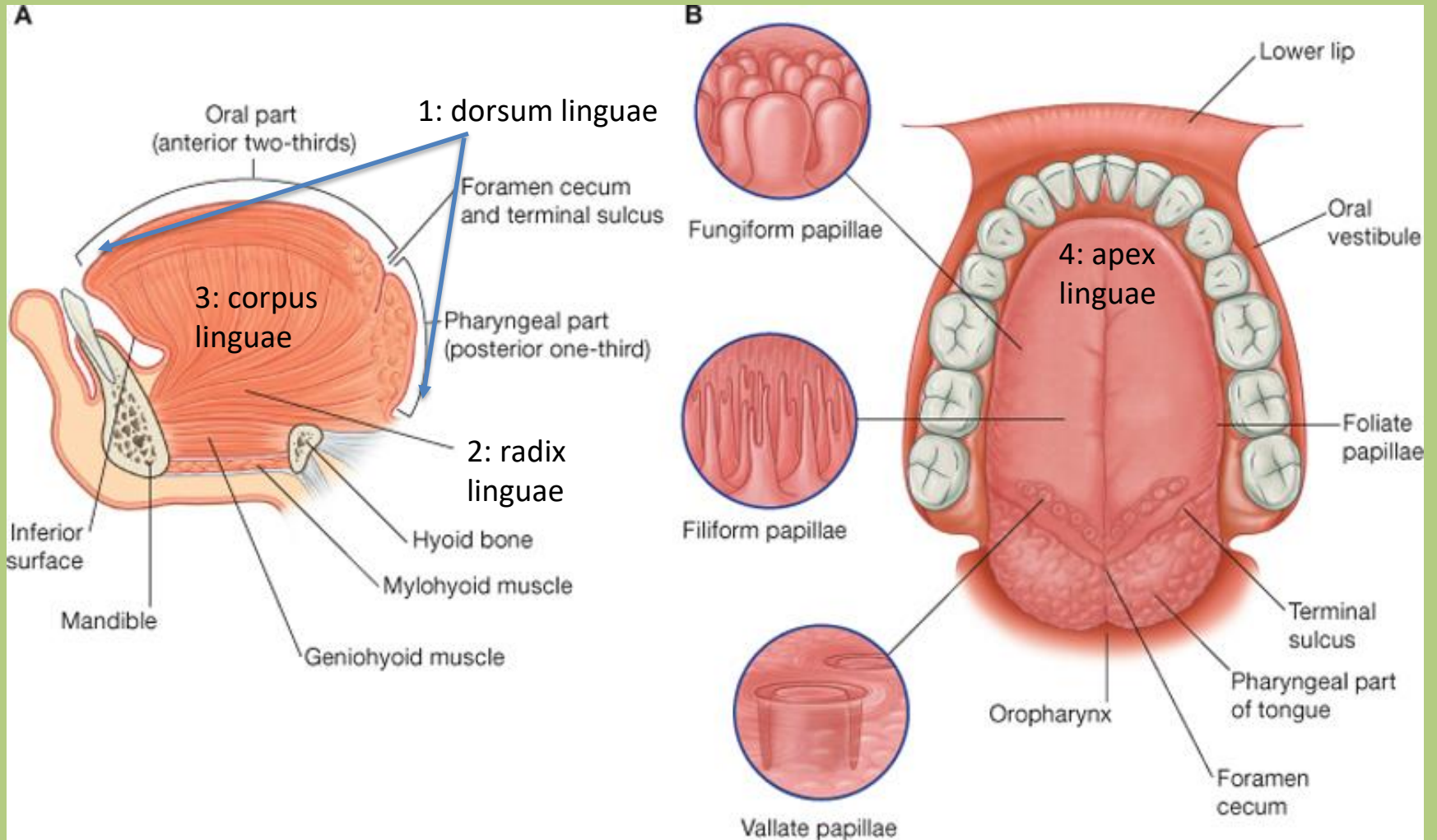
arcus
palatopharyngeus

Hemisected head, medial

BlueLink

© B. Kathleen Alsup & Glenn M. Fox

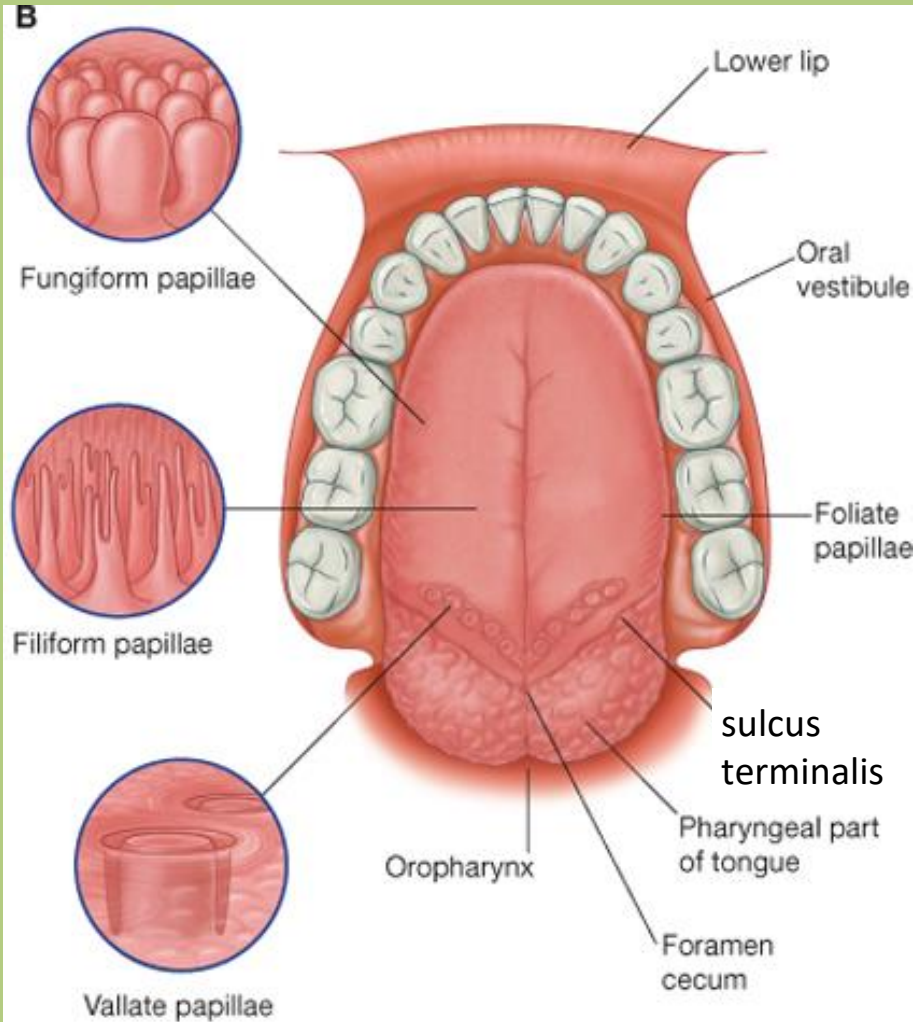
Lingua



Drake: Gray's Anatomy for Students, 2nd Edition.

Copyright © 2009 by Churchill Livingstone, an imprint of Elsevier, Inc. All rights reserved.

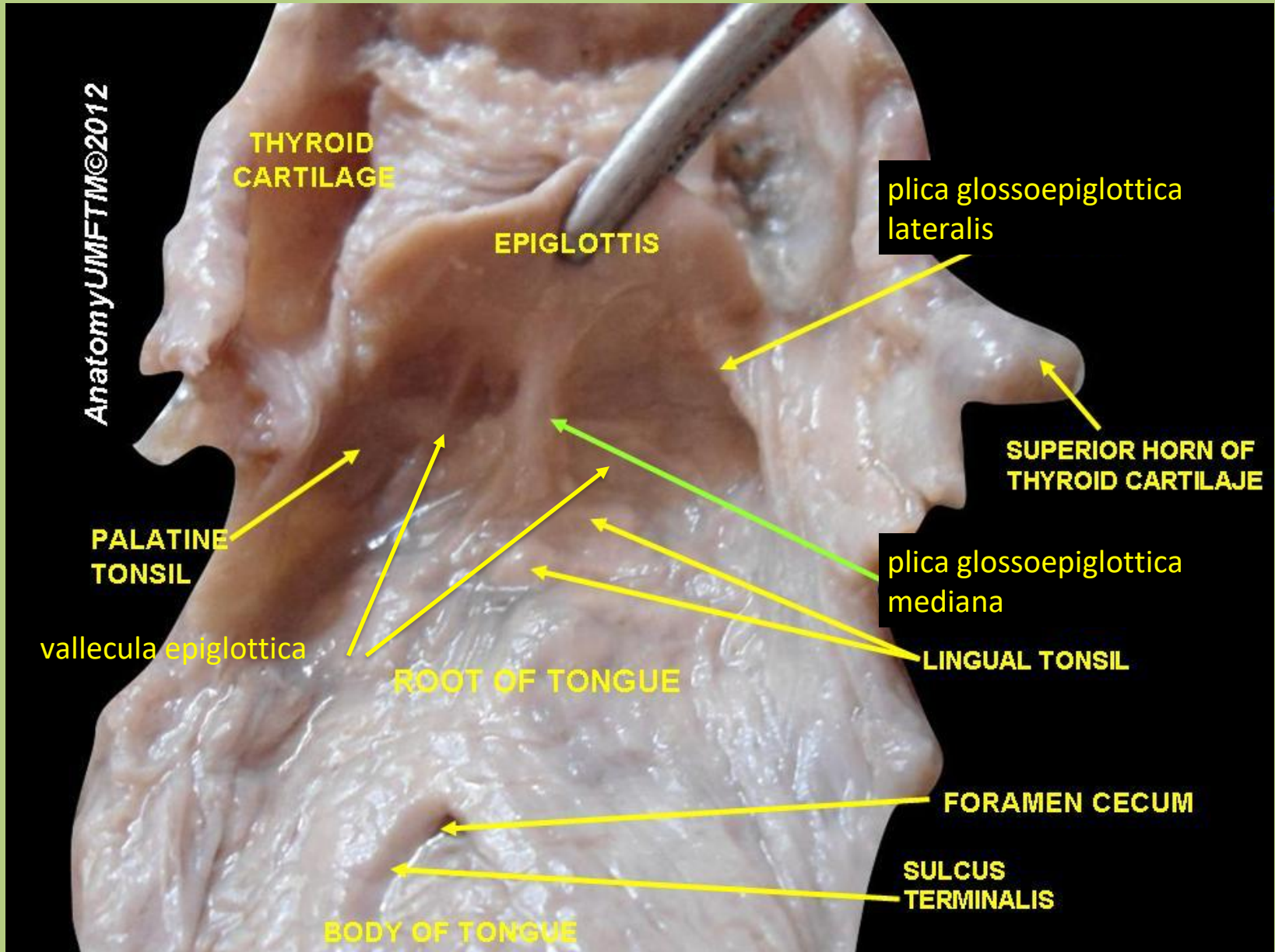
Lingua



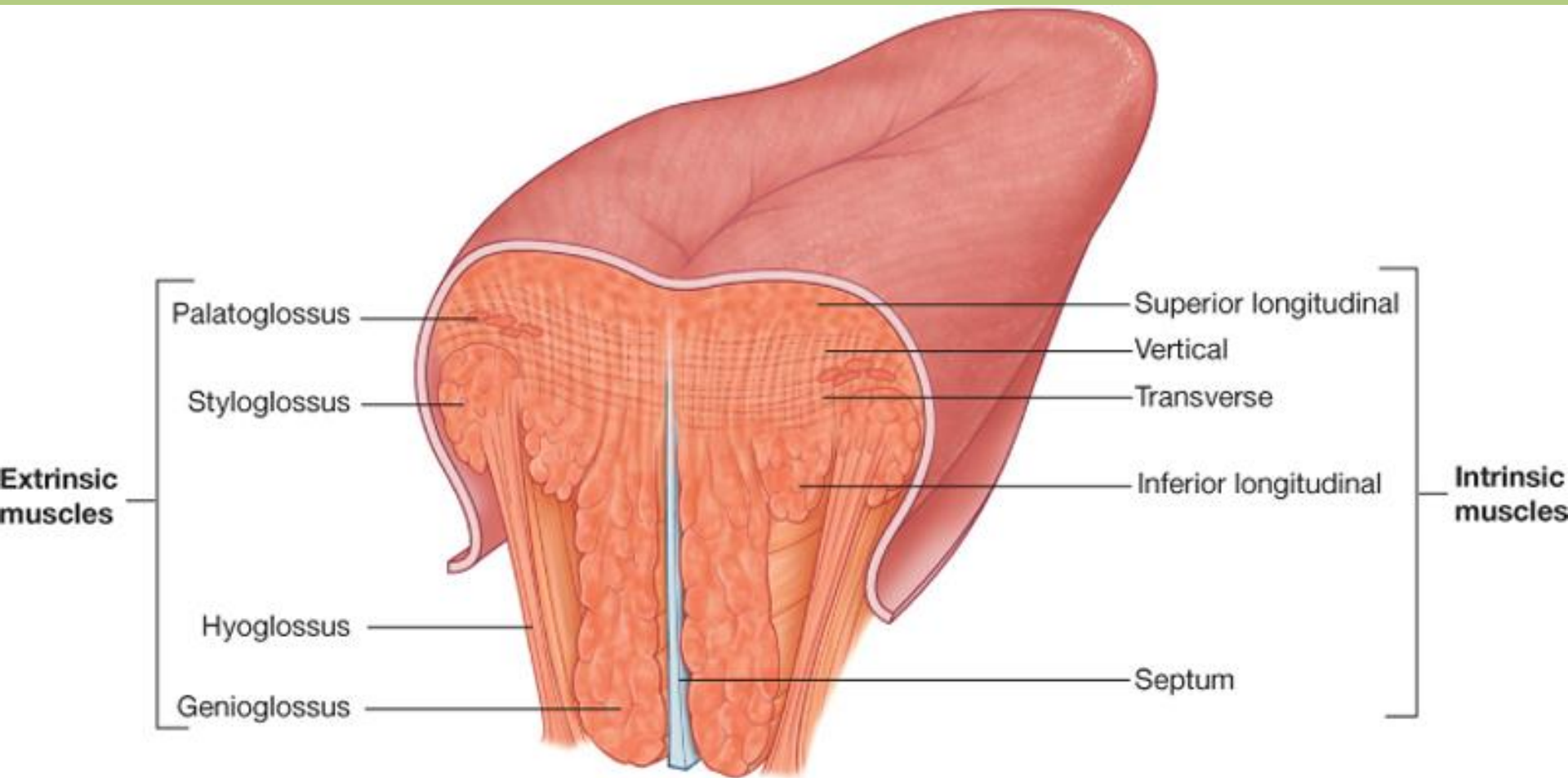
Foramen cecum:

Embriológiai maradványa a ***ductus thyroglossus***nak (pajzsmirigy nyak területére való leszállásához).

Lingua



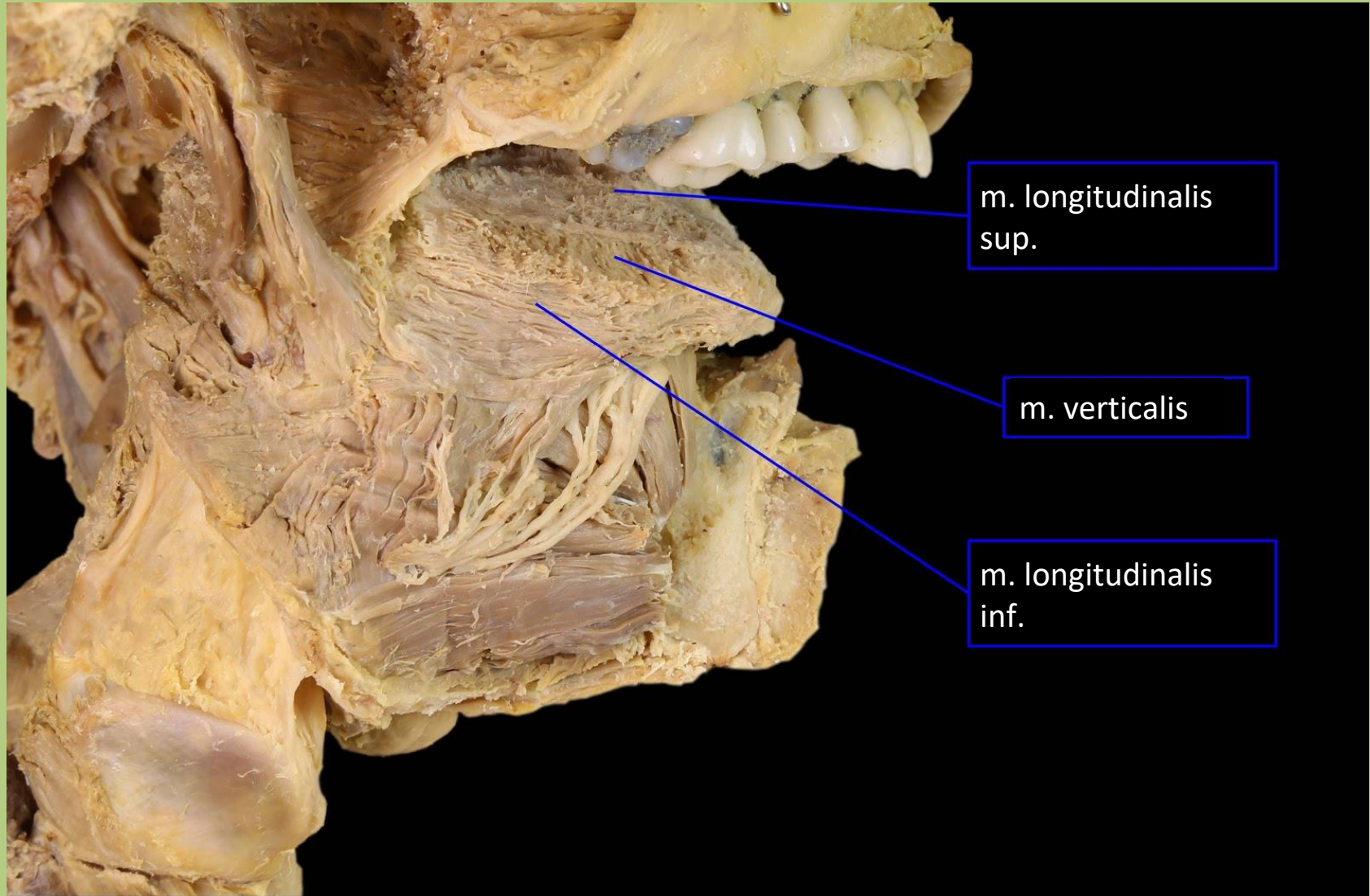
Lingua - izmok (zsigeri harántcsíkolt)



Drake: Gray's Anatomy for Students, 2nd Edition.

Copyright © 2009 by Churchill Livingstone, an imprint of Elsevier, Inc. All rights reserved.

Lingua - izmok

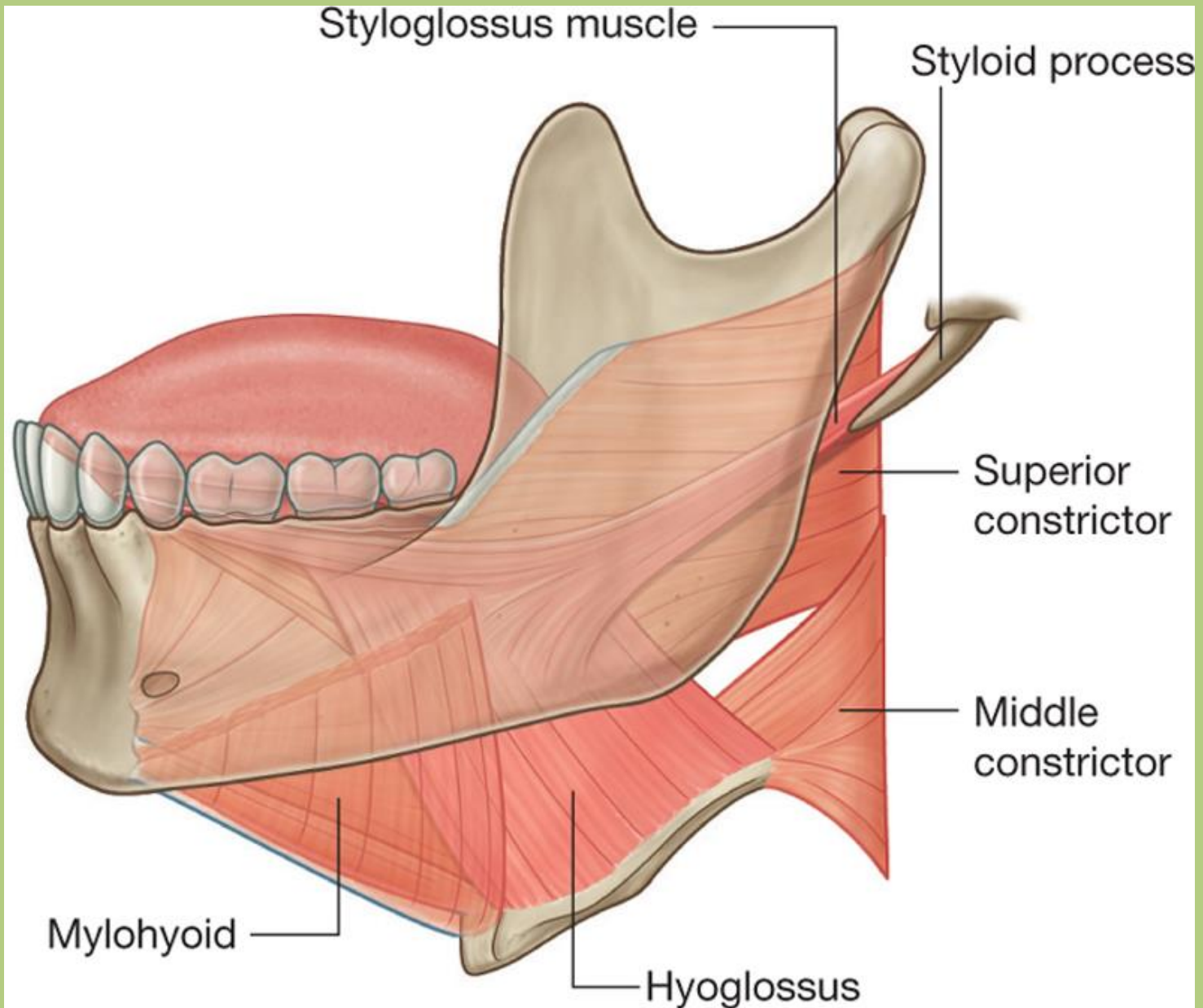


m. longitudinalis
sup.

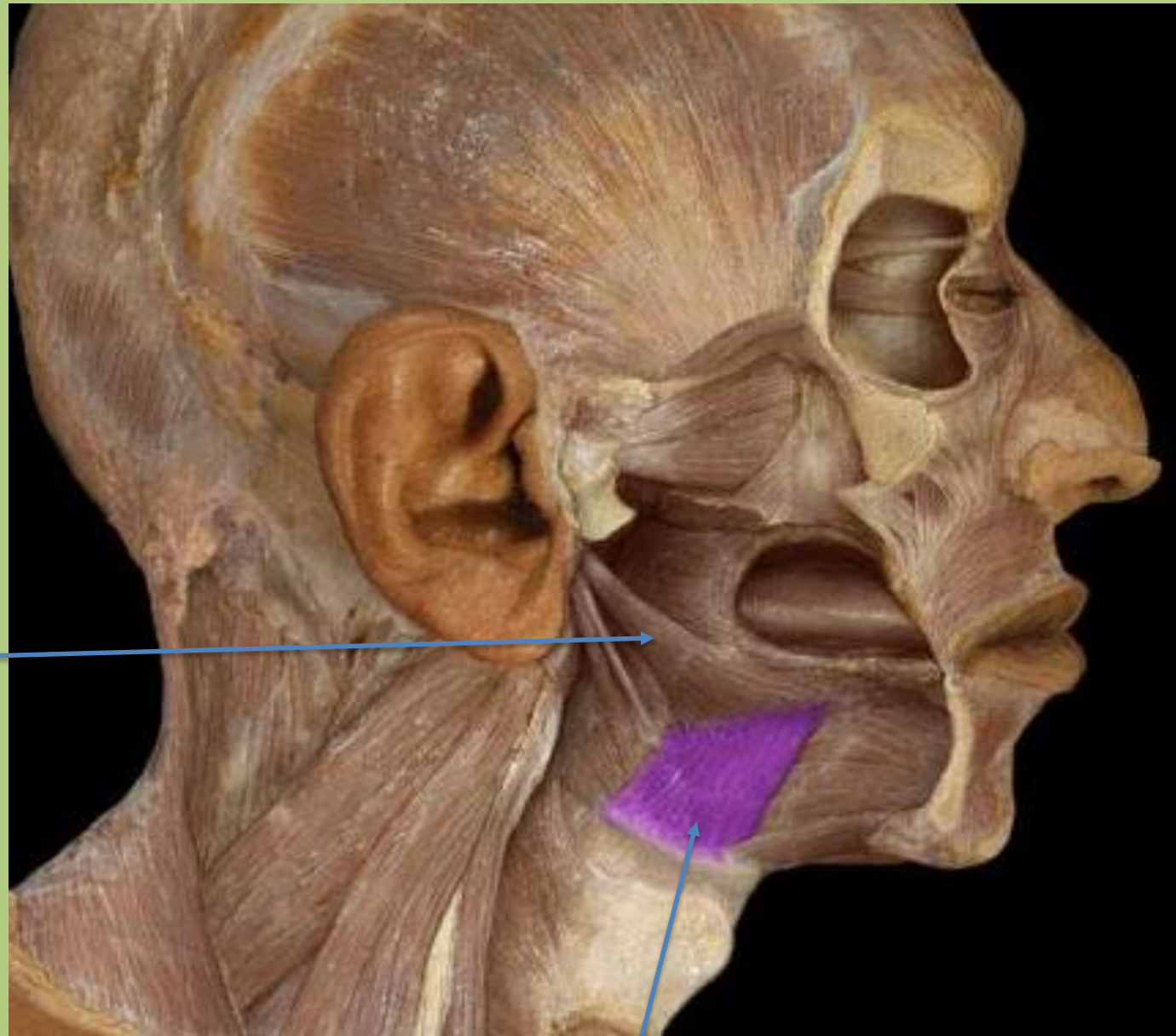
m. verticalis

m. longitudinalis
inf.

Lingua - izmok



Lingua - izmok

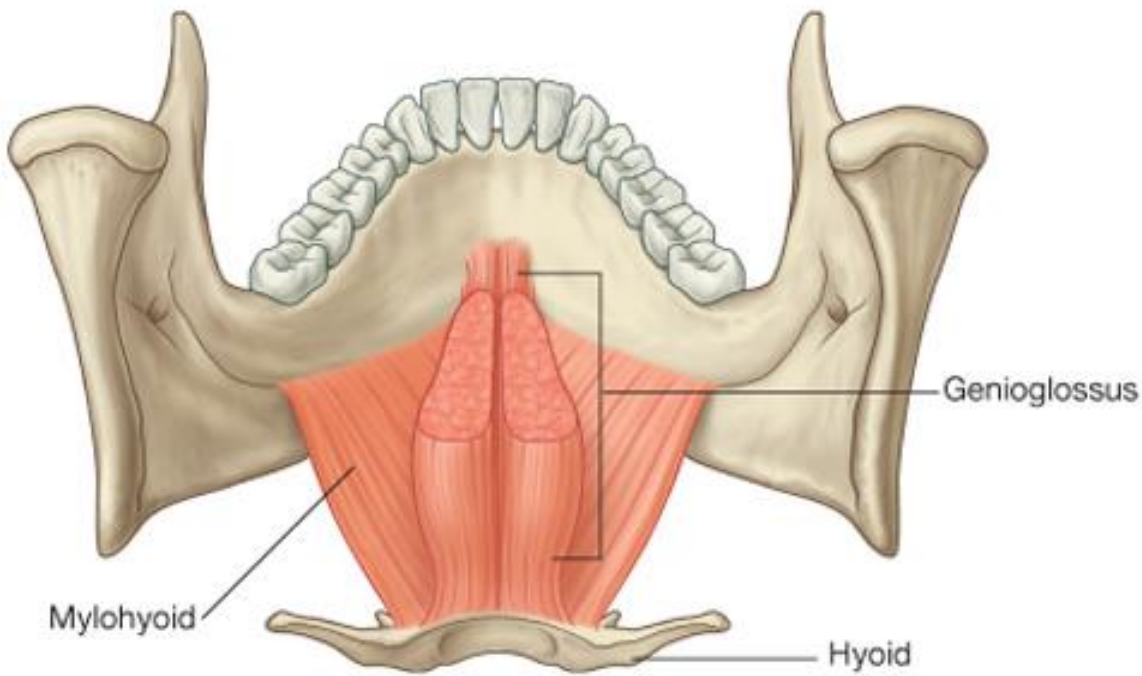


m. styloglossus

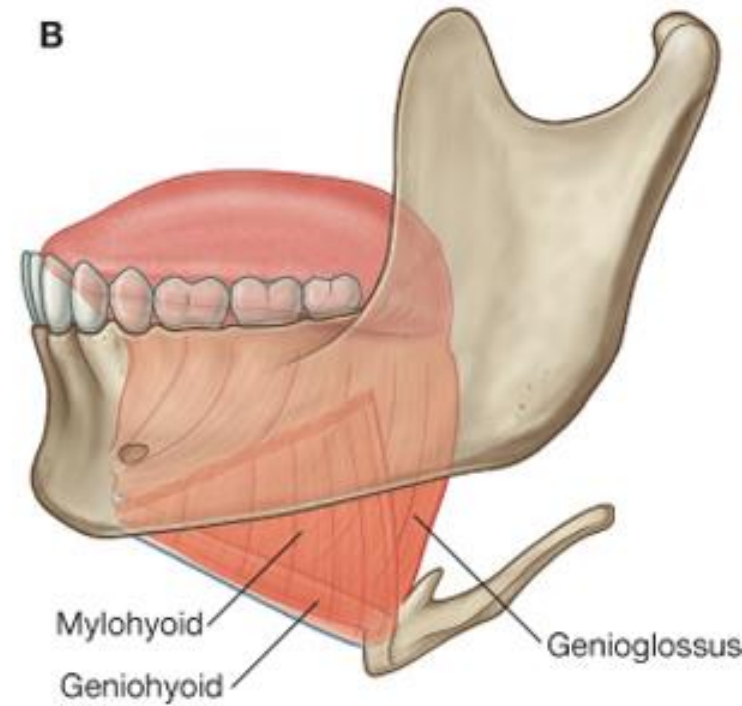
m. hyoglossus

Lingua - izmok

A



B



Drake: Gray's Anatomy for Students, 2nd Edition.

Copyright © 2009 by Churchill Livingstone, an imprint of Elsevier, Inc. All rights reserved.

Lingua - izmok

Intrinsic mm. of tongue

m. genioglossus

m. geniohyoideus

m. mylohyoideus

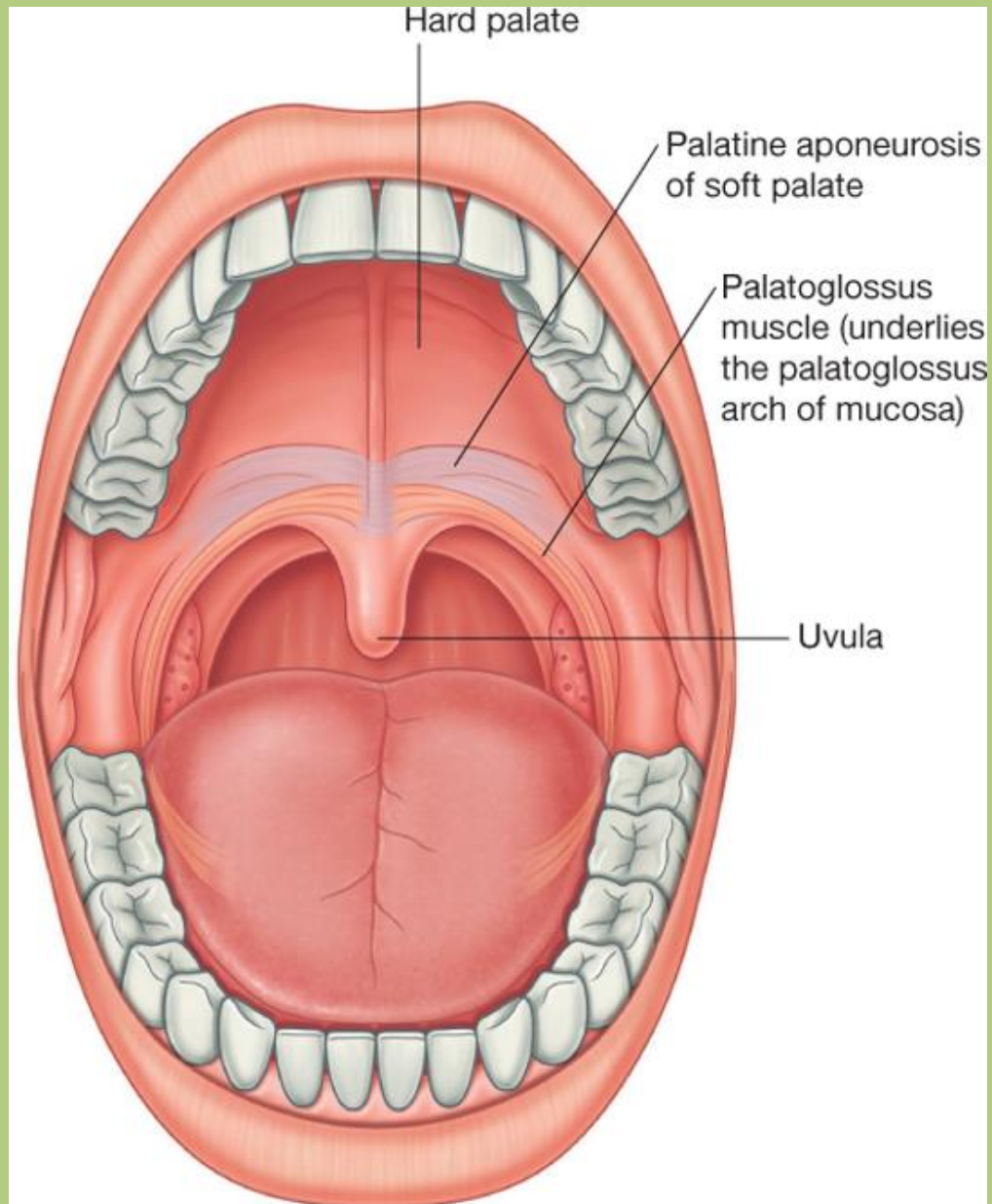
m. digastricus, venter anterior

Hemisected oral cavity, medial

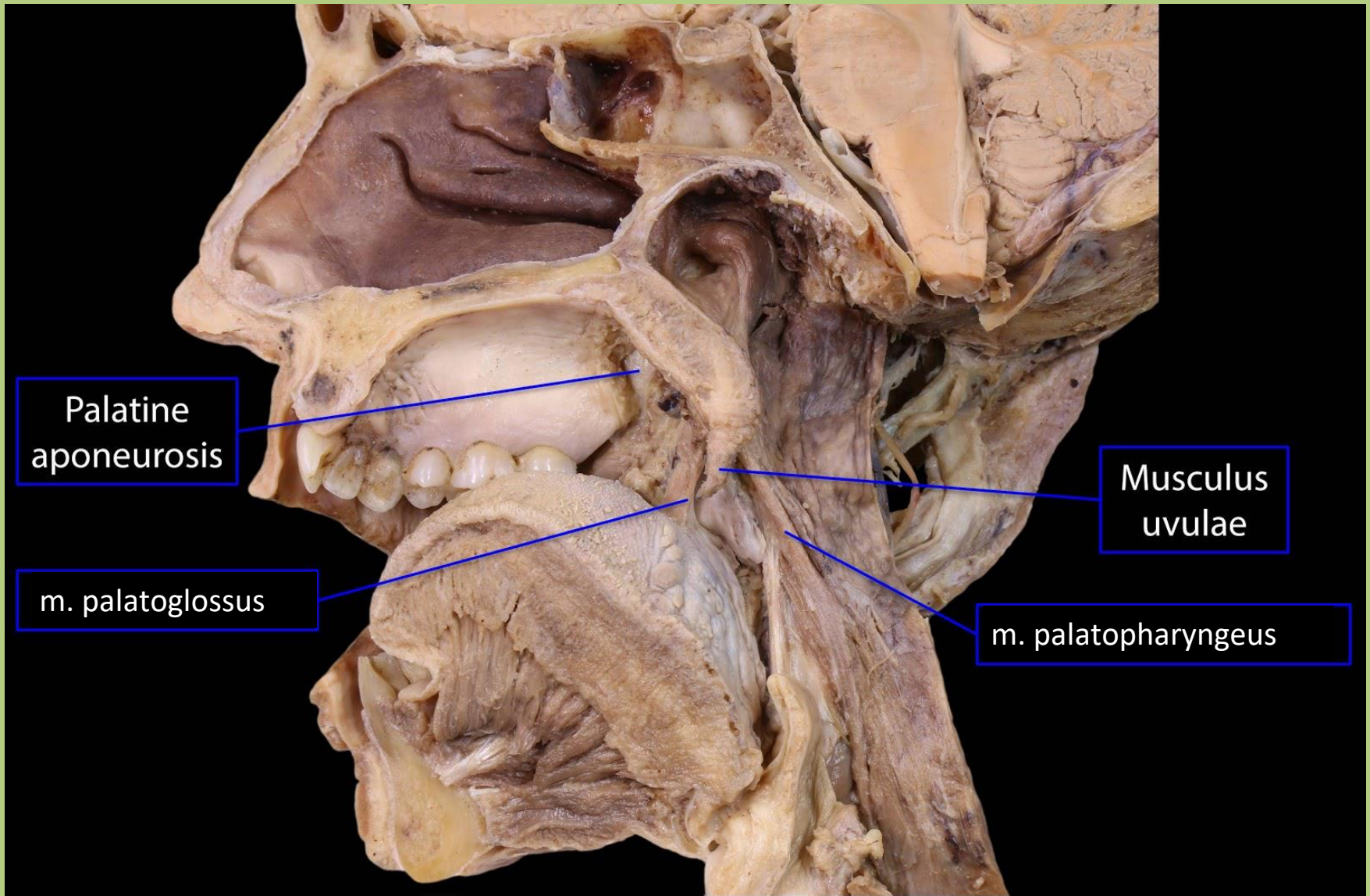
BlueLink

© B. Kathleen Alsup & Glenn M. Fox

Lingua - izmok



Lingua - izmok



Hemisected head, medial

Lingua - motoros beidegzés

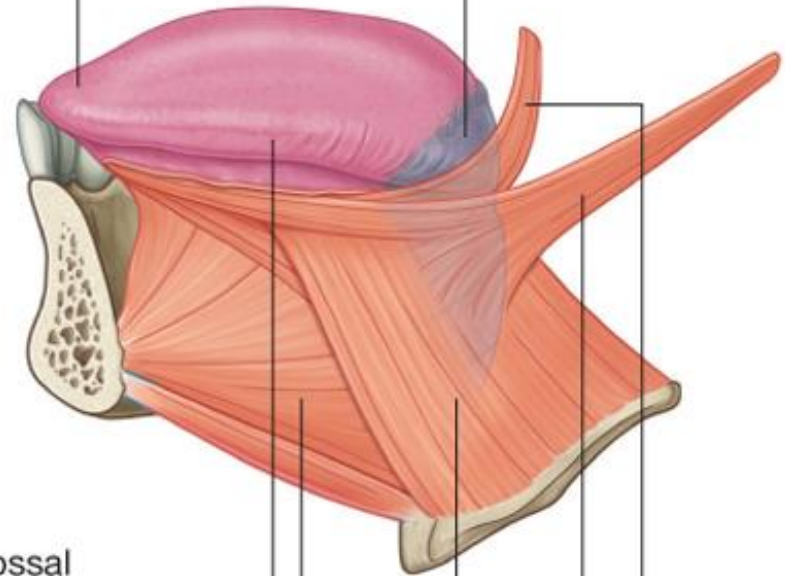
Sensory

Anterior two-thirds (oral)

- general sensation
mandibular nerve [V₃]
via lingual nerve
- special sensation (taste)
facial nerve [VII] via
chorda tympani

Posterior one-third (pharyngeal)

- general and special
(taste) sensation via
glossopharyngeal nerve [IX]



Motor

Hypoglossal
nerve [XII]

Intrinsic muscle

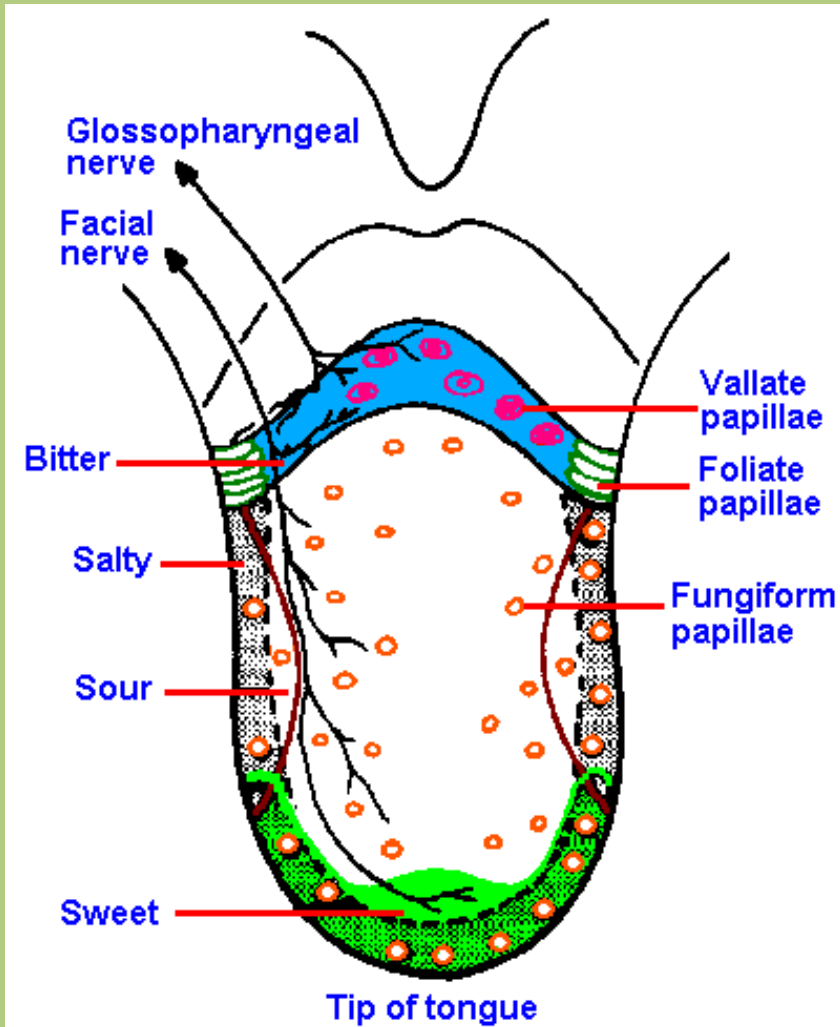
Genioglossus

Hyoglossus

Styloglossus

Palatoglossus – vagus nerve [X]

Lingua - szenzoros beidegzés



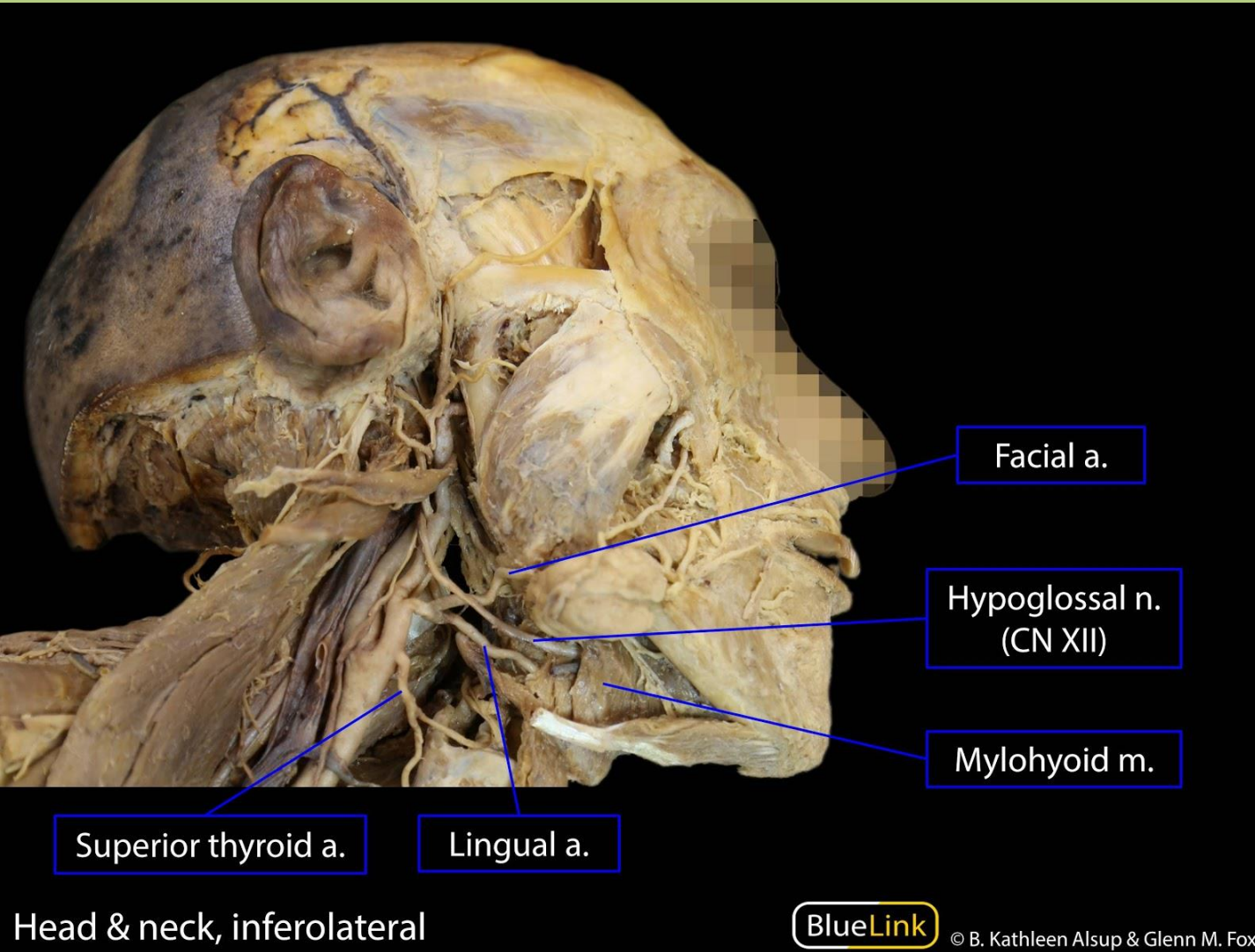
Általános érzés:

- Anterior 2/3: n. lingualis
- Posterior 1/3: n. glossopharyngeus

Ízérzés:

- Anterior 2/3: chorda tympani (n. facialis)
- Posterior 1/3: n. glossopharyngeus

Lingua - vérellátás



a. lingualis:

- *a. lingualis profunda*
- *a. sublingualis*

v. lingualis →

v. lingualis profunda,
v. retromandibularis,
v. jugularis interna

Pirogov-féle háromszög

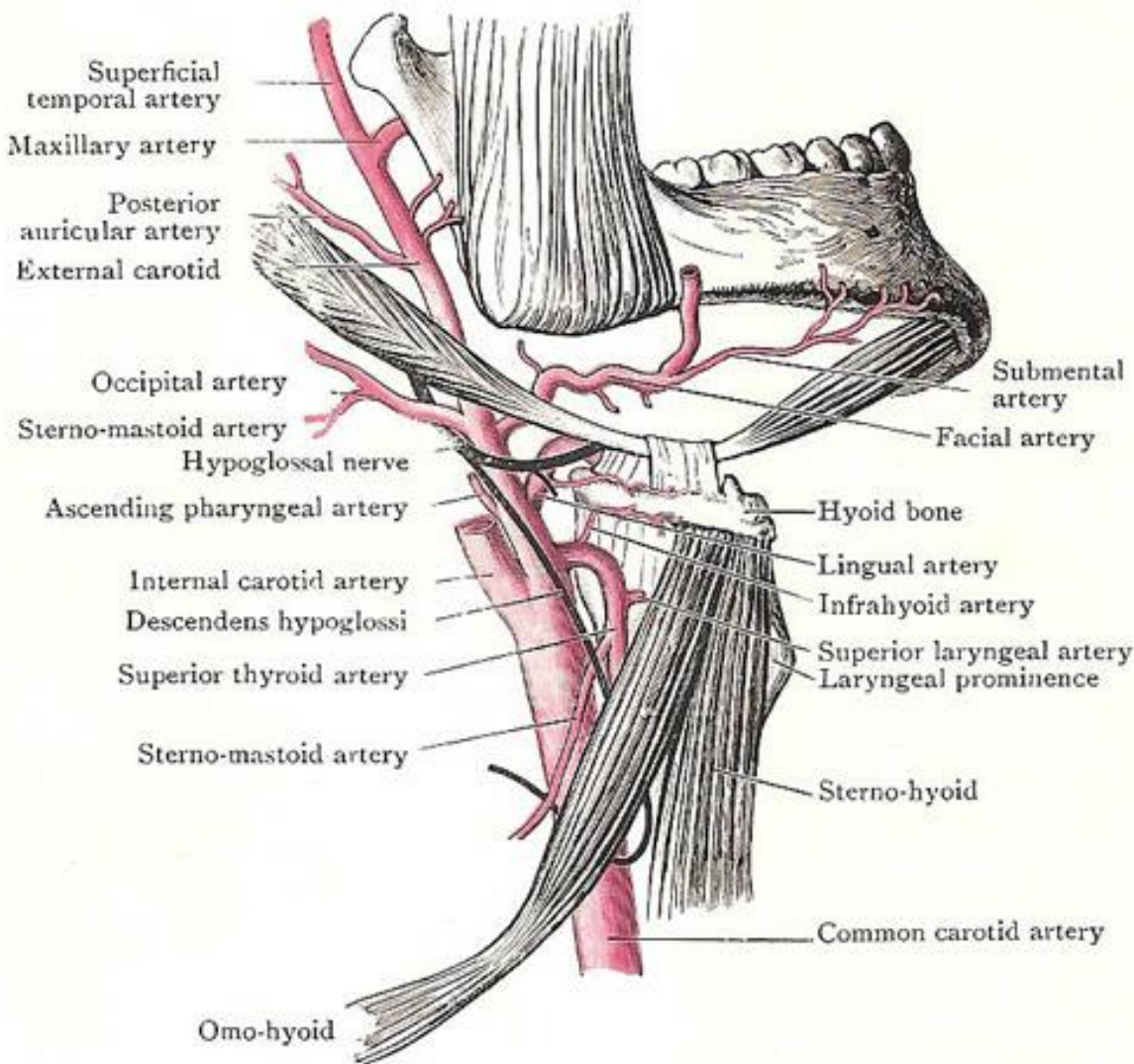
(tökéletes hely az *a. lingualis* lekötéséhez)



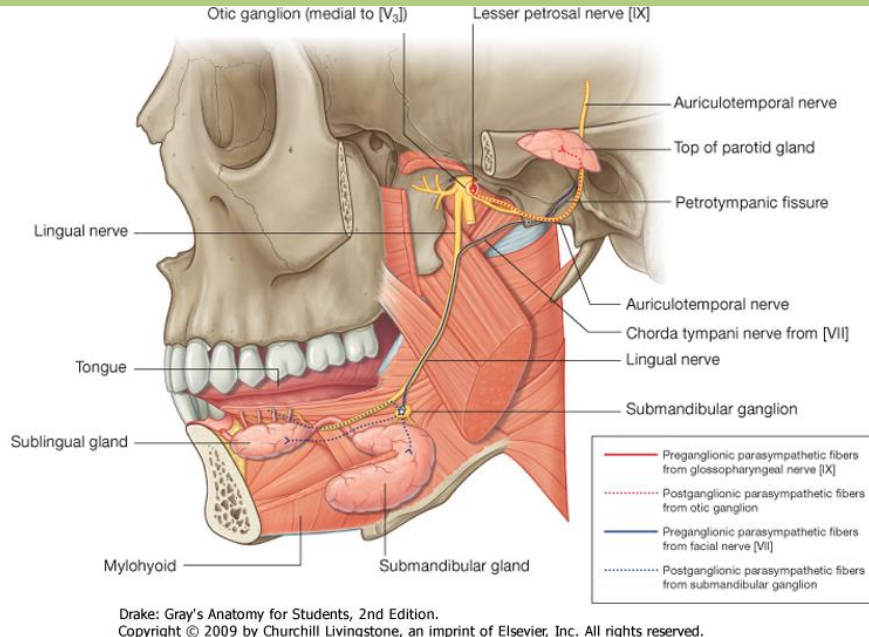
Határai:

- *m. mylohyoideus* hátsó széle
- *m. digastricus, venter post.*
- *n. hypoglossus*

Tartalma:
a. lingualis



Nyálmirigyek

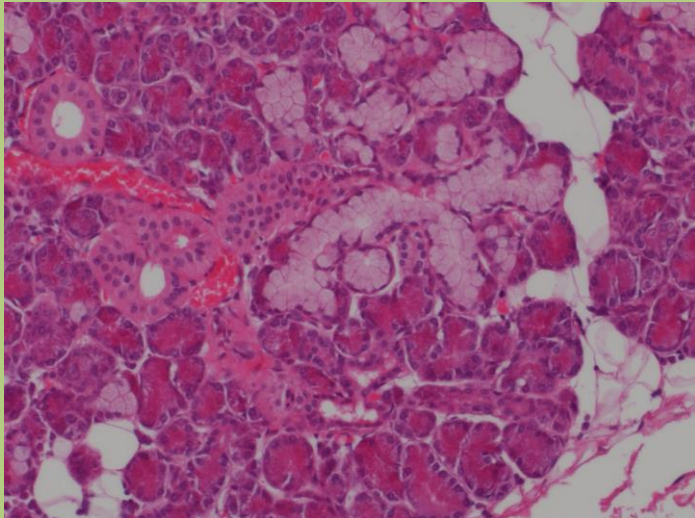


Nagy nyálmirigyek:

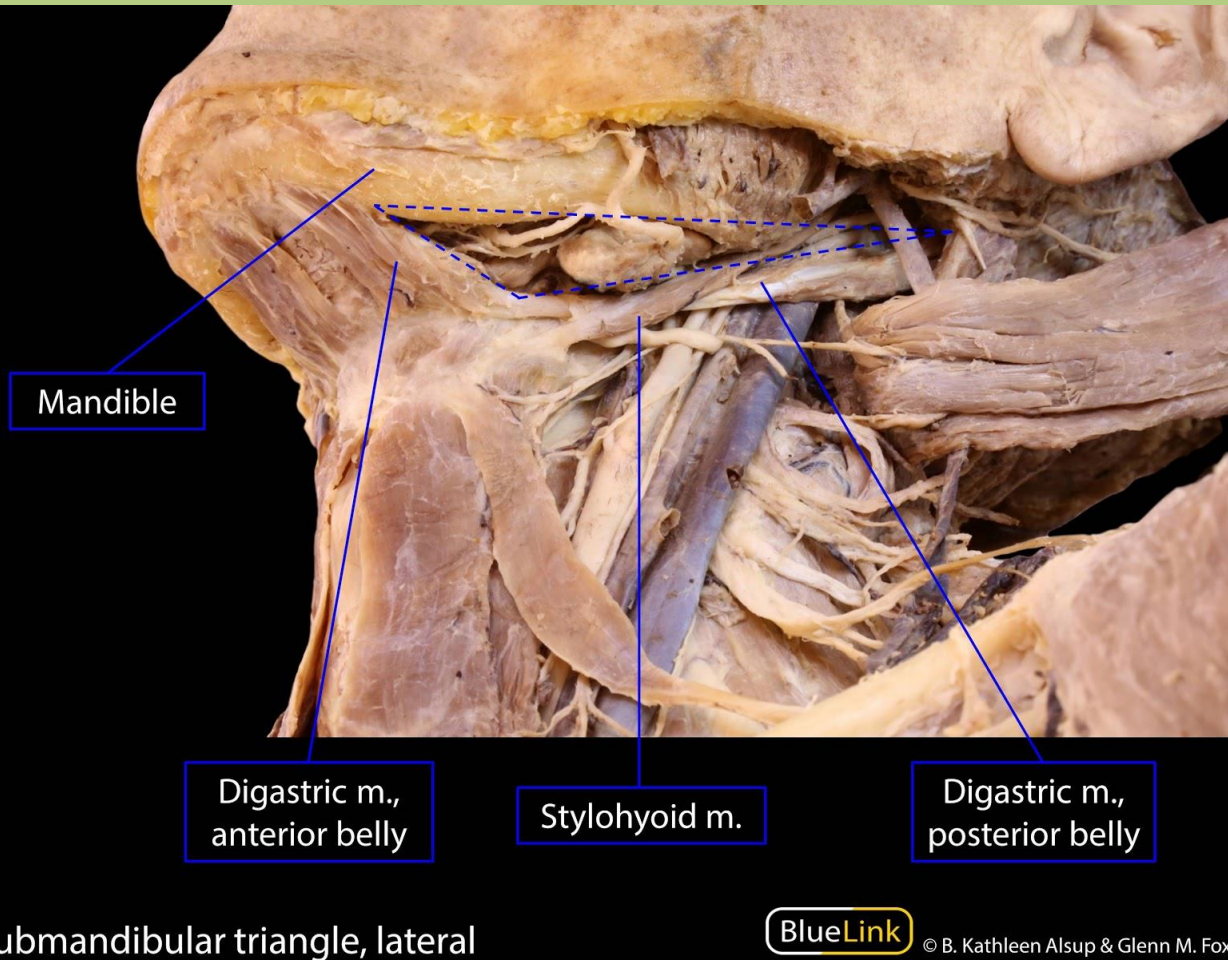
- Gl. parotis
- Gl. submandibularis
- Gl. sublingualis

Kis nyálmirigyek:

800-1000 apró mirigy a submucosában az egész szájürgben.

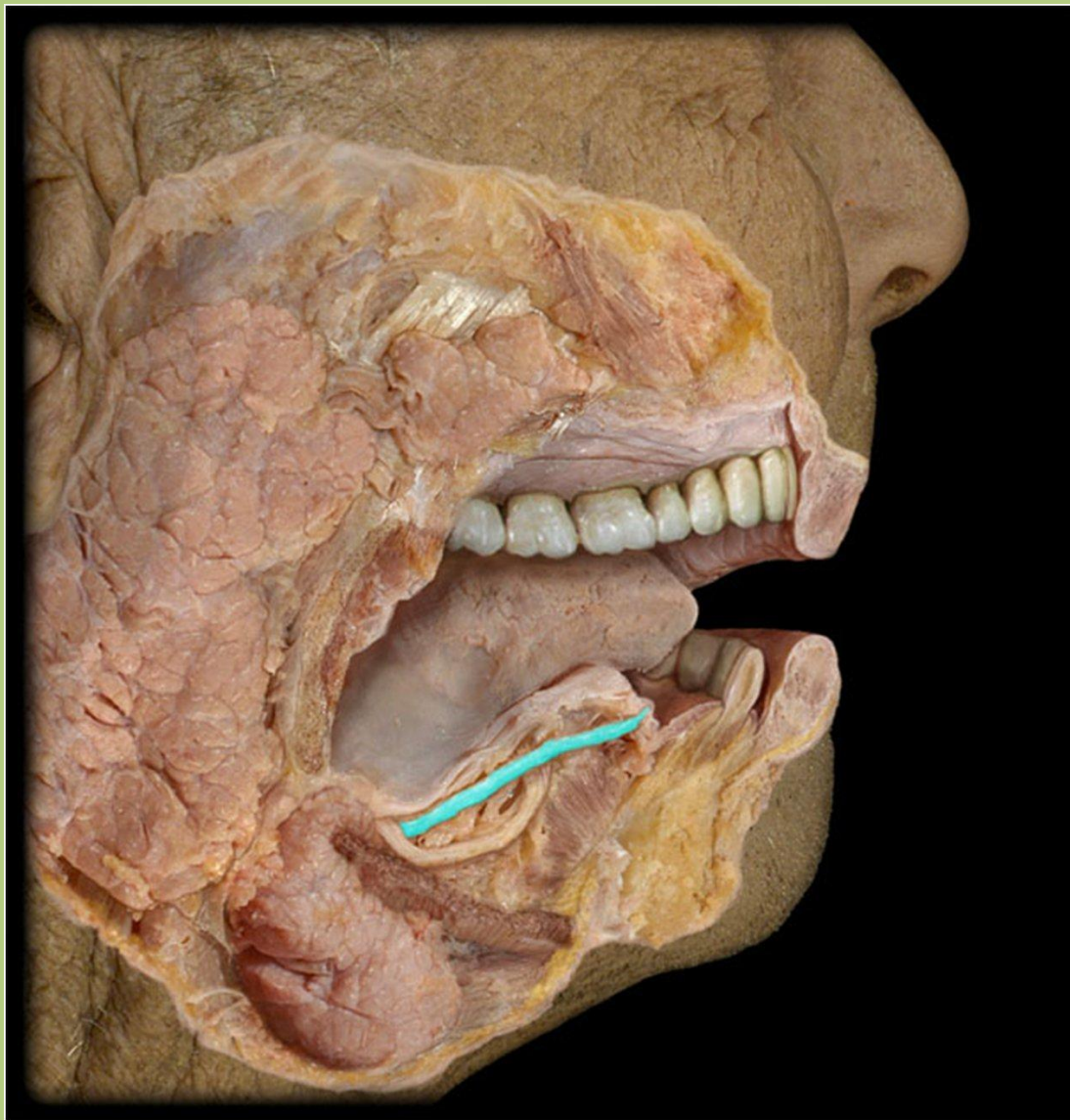


Gl. submandibularis



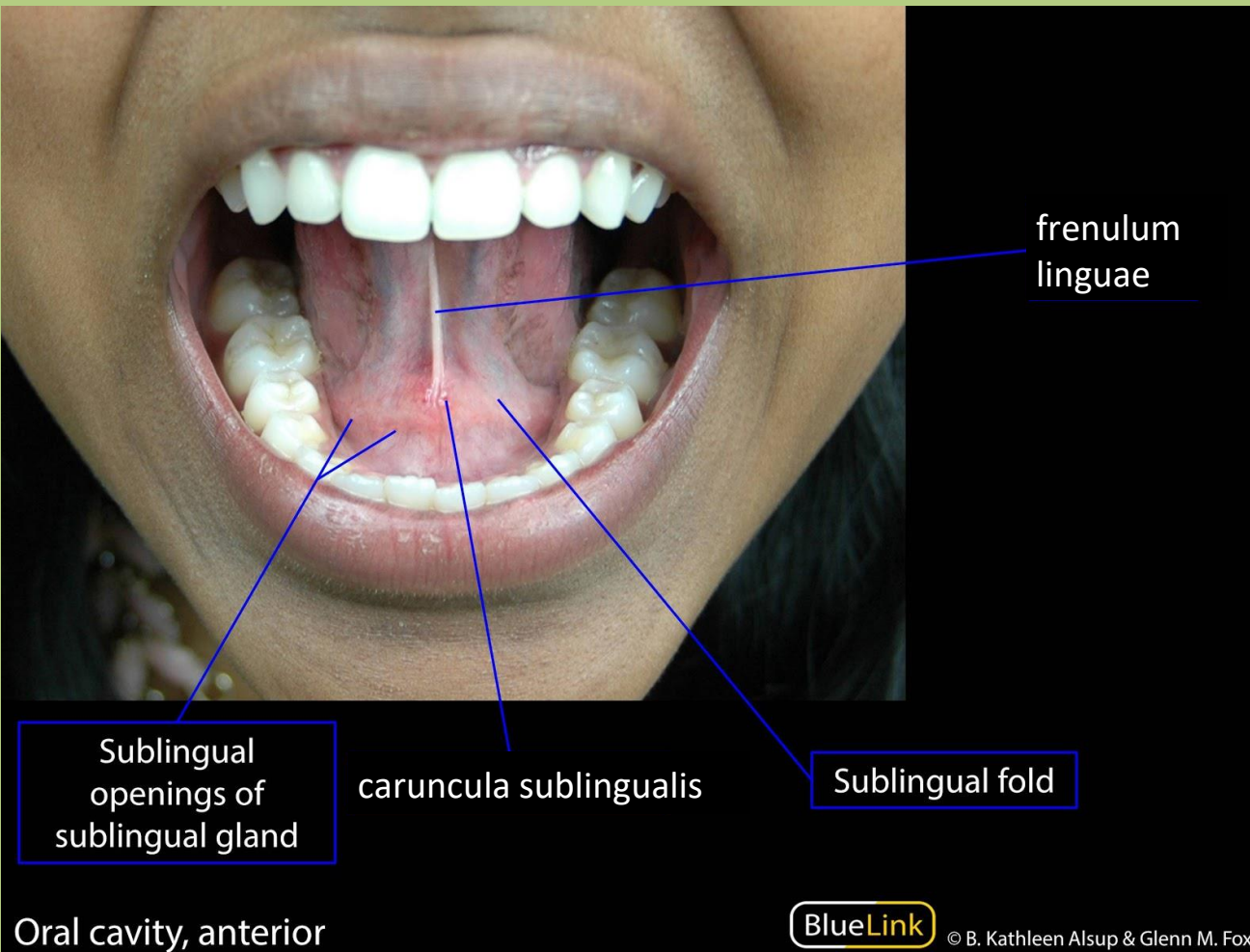
- ***trigonum submandibulare***
- ***a. facialis*** beágyazódott a belső/mediális felszínébe
- ***v. facialis*** a külső felszínével érintkezik
- ***n. lingual*** a felső felszínénél található
- Vérellátása: a. lingualis.
- Beidegzése: ggl. submandibulare a n. lingualison keresztül.

Gl. submandibularis



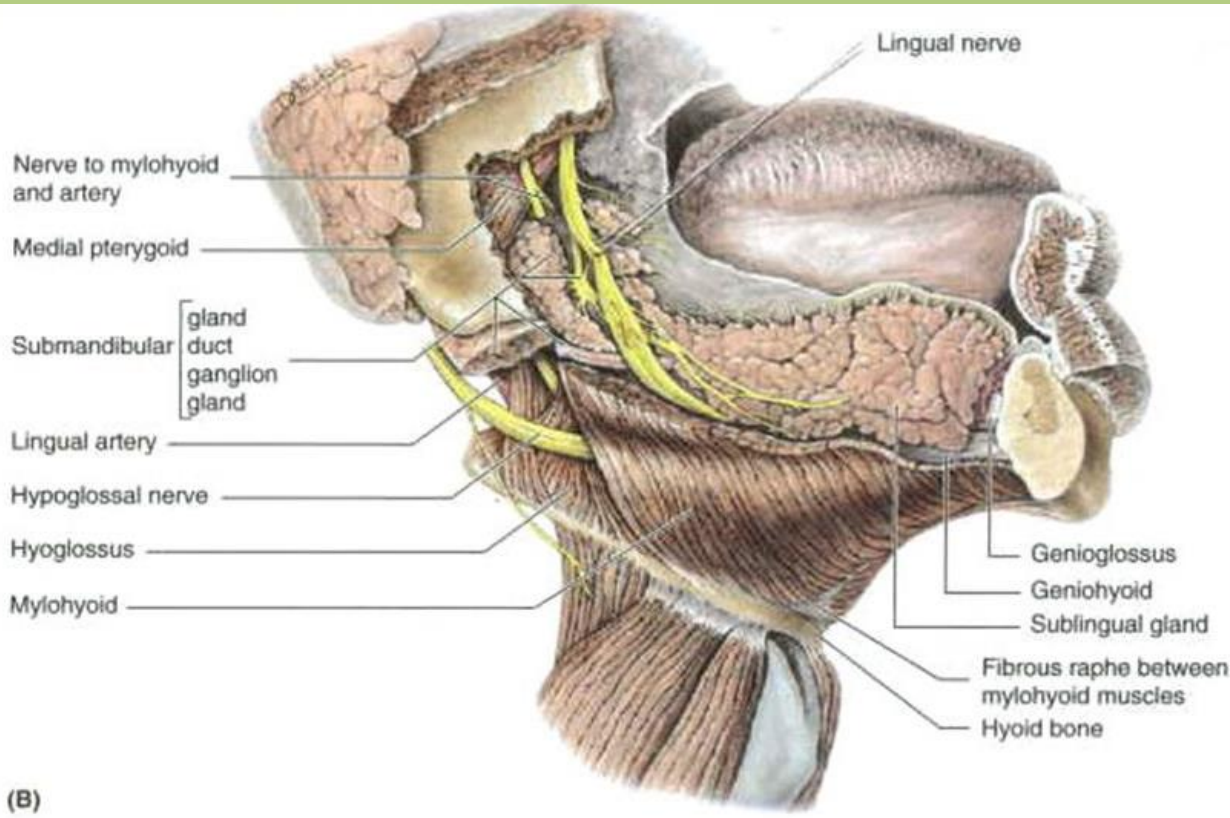
- *ductus submandibularis* a mirigy mediális felszínén ered és belép a *sulcus lateralis linguae*be

Gl. submandibularis



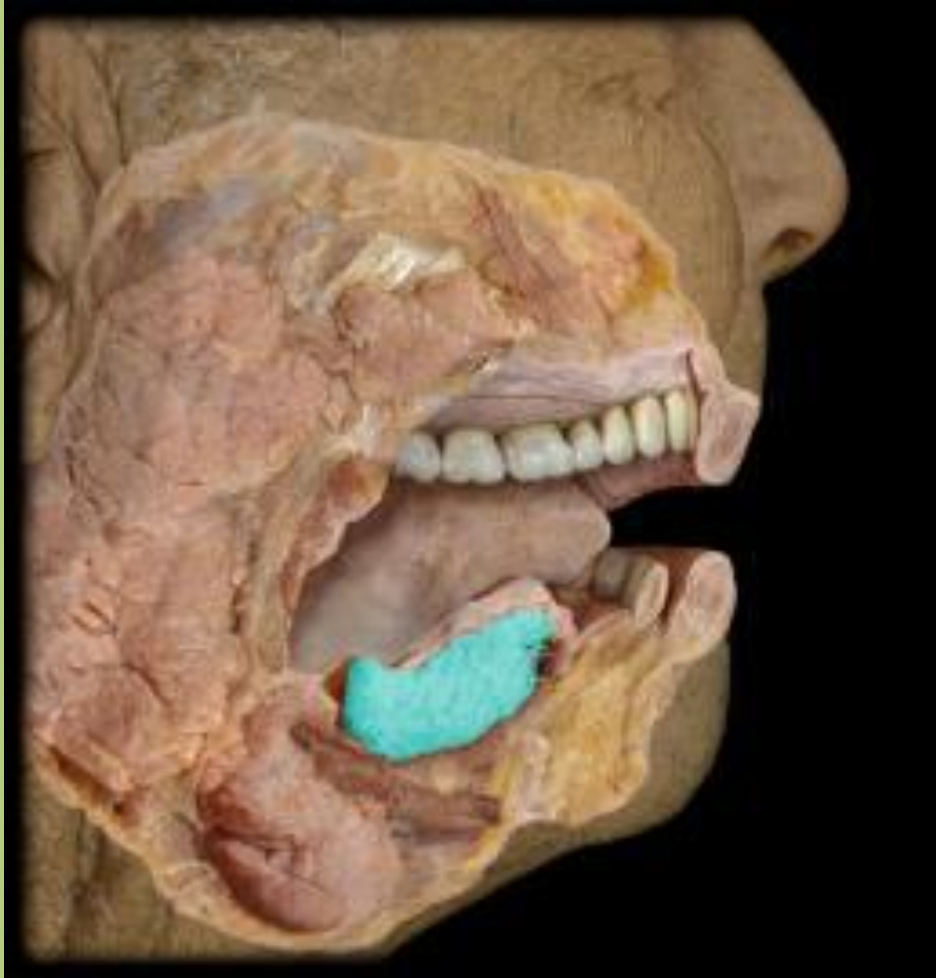
- a *ductus submandibularis* a *caruncula sublingualis* felszínén nyílik a frenulum linguae két oldalán

Sulcus lateralis linguae



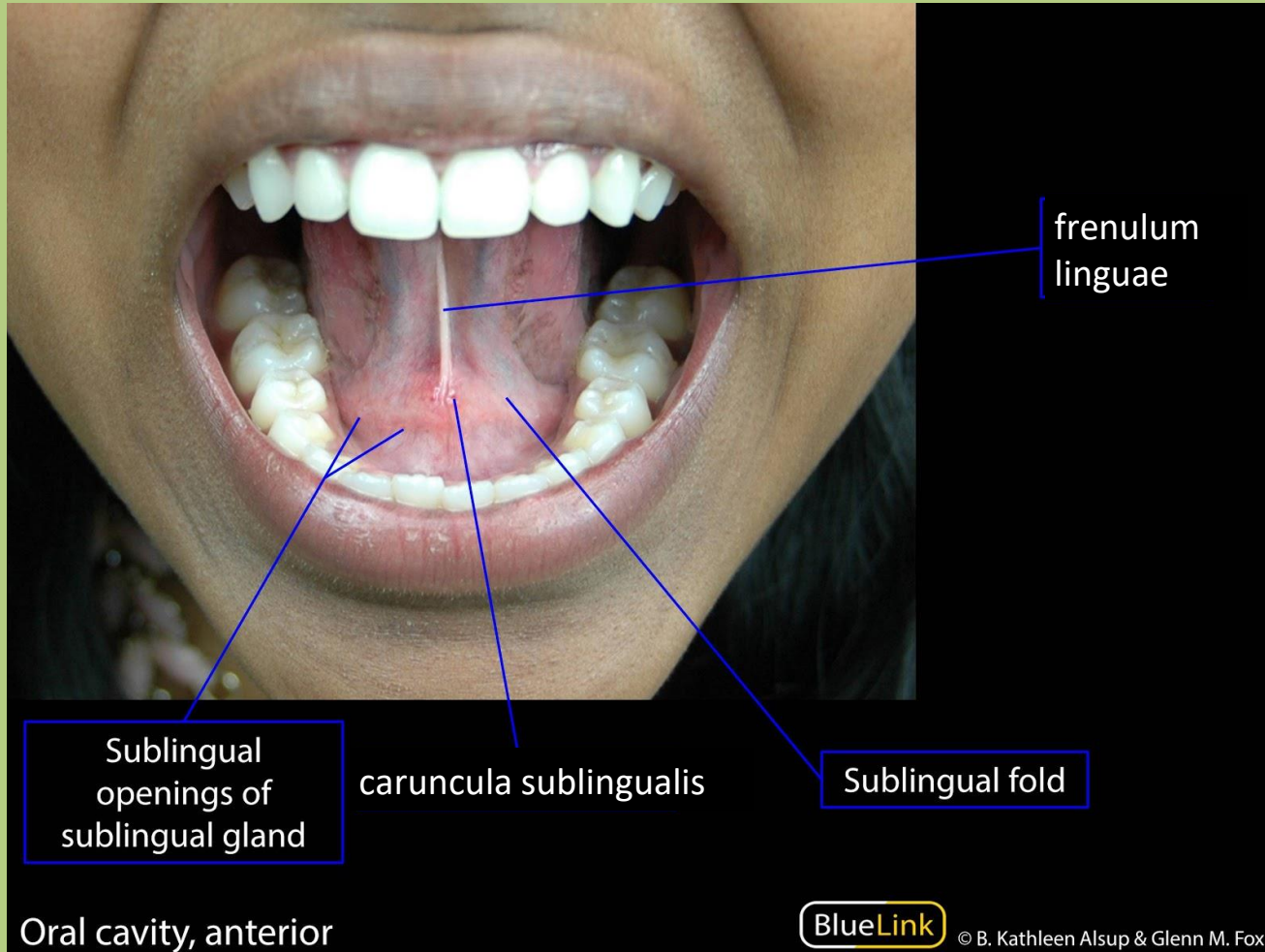
- V-alakú
- medialis fal: m. hyoglossus
- lateralis fal: m. mylohyoideus
- tartalma fentről lefelé: ***n. lingualis, ductus submandibularis, n. hypoglossus***

Gl. sublingualis

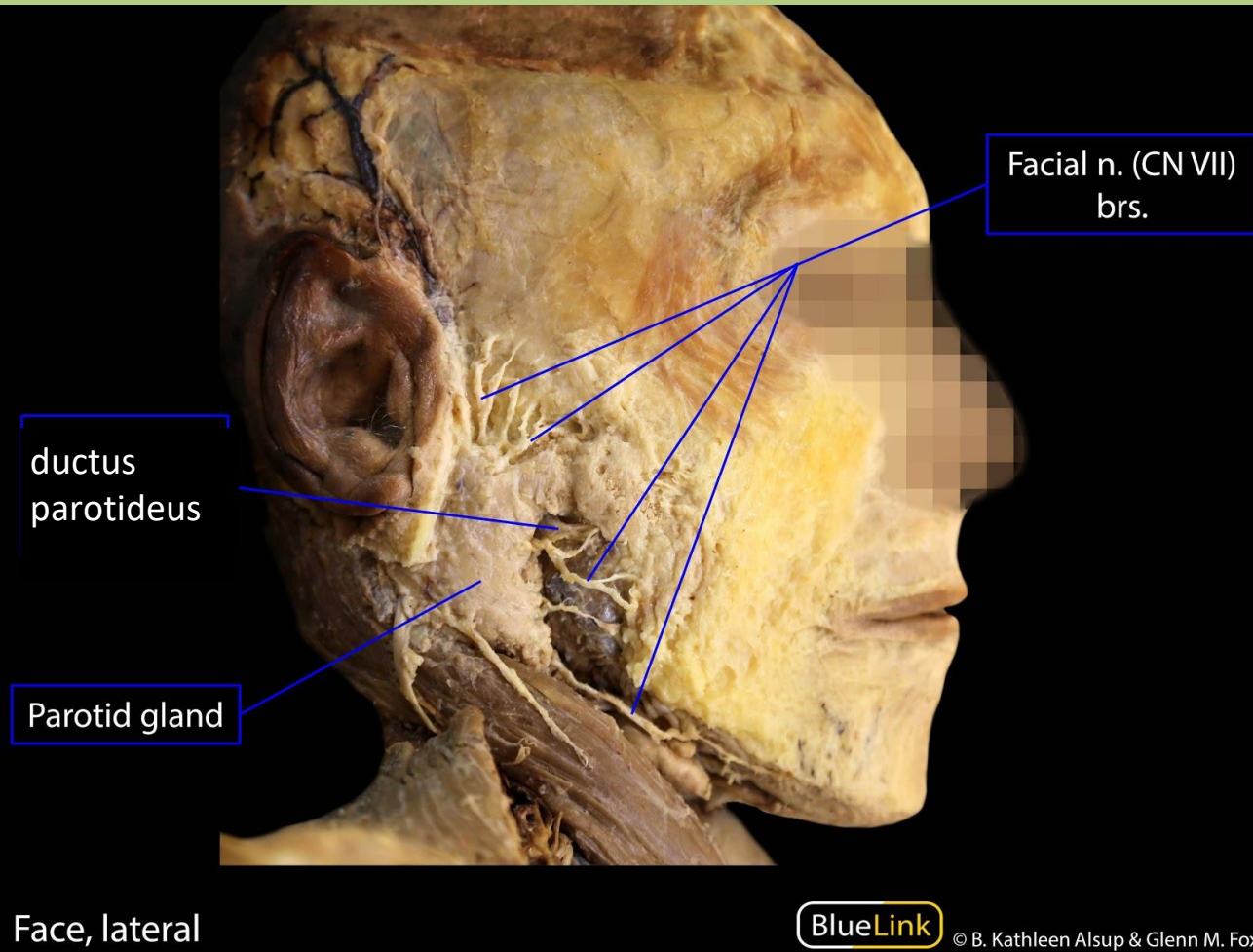


- a *m. mylohyoideus*on ül a *gl. submandibularis* előtt
- több apró ductus nyílik a ductus submandubularisba vary közvetlenül a szájüreg alapjára
- vérellátás: a. sublingualis
- beidegzés: ggl. submandibulare a n. lingualison keresztül

Gl. sublingualis

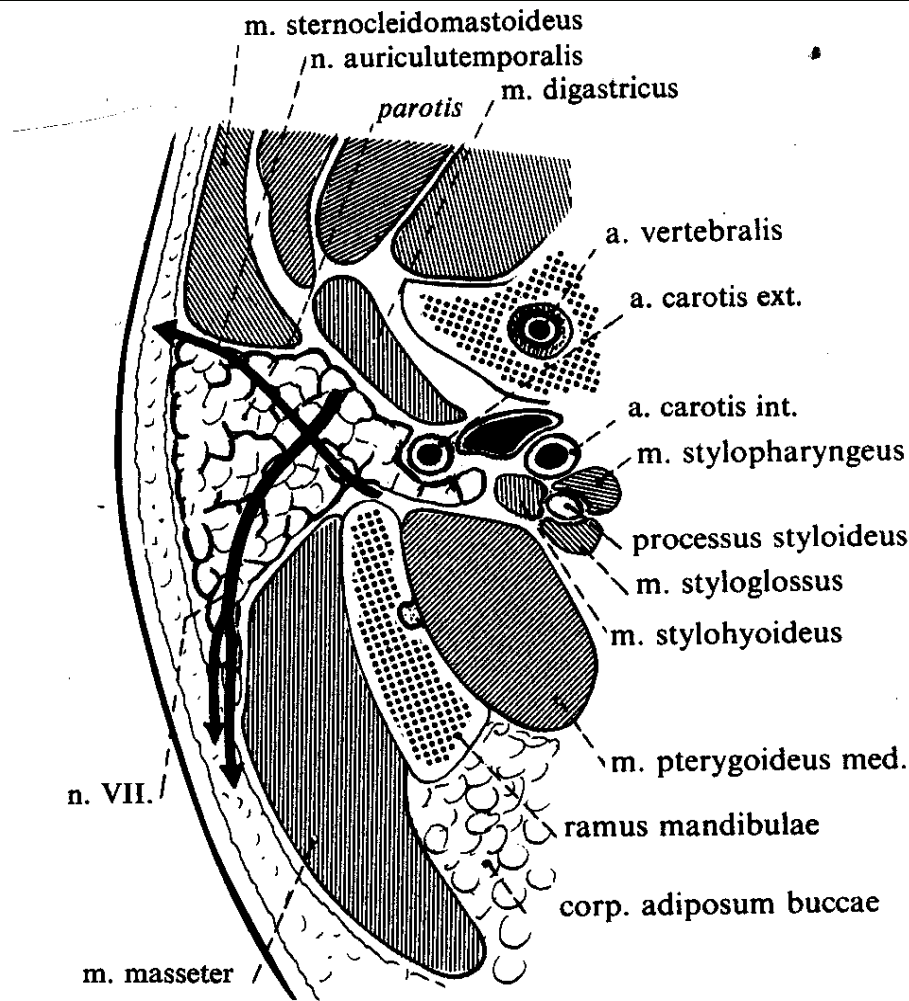


Gl. parotis



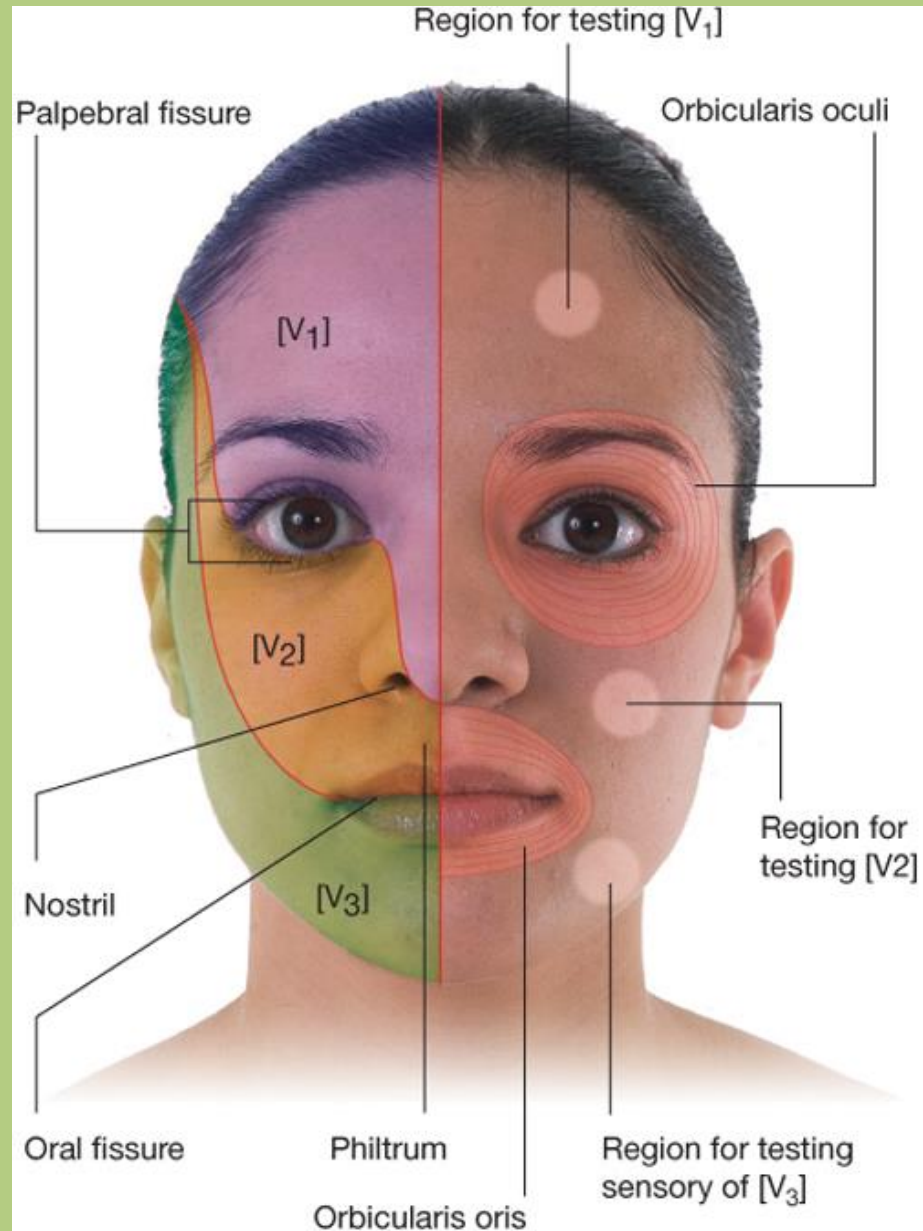
- *nidus parotideus*
- fascia parotide borítja
- a *ductus parotideus* az arcus zygomaticus alatt halad és a m. masseter elülső élénél mediálisan fordul, majd átfúrja a m. buccinatort és a *vestibulum orisban nyílik* a második moláris szintjében

Nidus parotideus

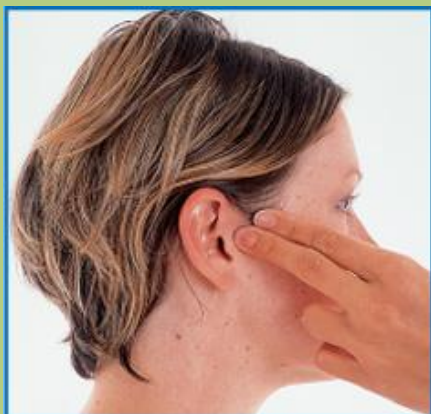

- **vérellátás: a. carotis externa és v. jugularis externa**
- **a n. facialis és n. auriculotemporalis fúrja át**
- **a n. auriculotemporalis biztosítja a szekretomotoros (paraszimpatikus) beidegzését**

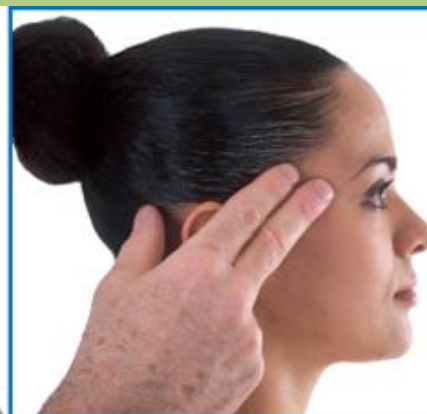
N. trigeminus - bőrbeidegzés



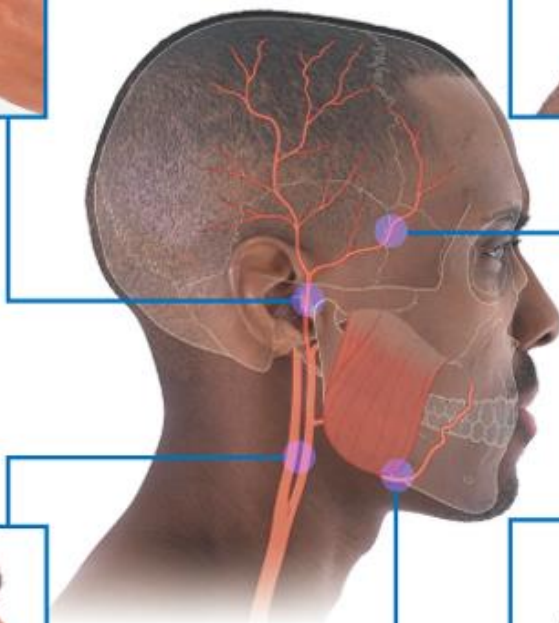
Pulzus tapintása



Temporal pulse
(superficial temporal artery)

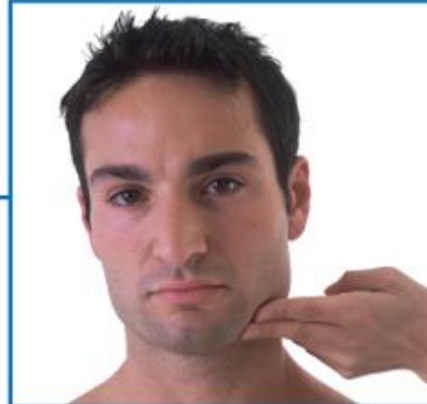
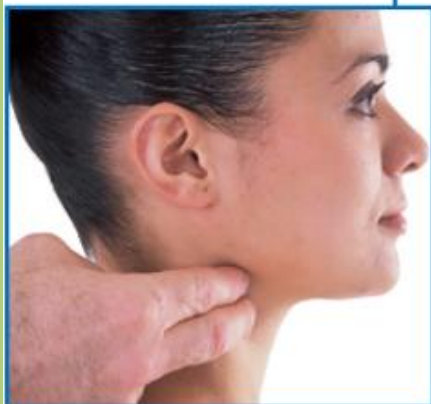
Temporal pulse
(anterior branch of
superficial temporal artery)



Carotid pulse

Facial pulse



PLAN YOUR TREATMENT PROTOCOL



"Nurse, get on the internet, go to SURGERY.COM, scroll down and click on the 'Are you totally lost?' icon."

Köszönöm a figyelmet!

References: Drake: Gray's Anatomy for Students, 2nd ed.
Standring: Gray's Anatomy, 39th ed.
Radiopaedia.org
Thieme Atlas of Anatomy, General Anatomy and Musculoskeletal System, Head and Neuroanatomy 2nd ed.