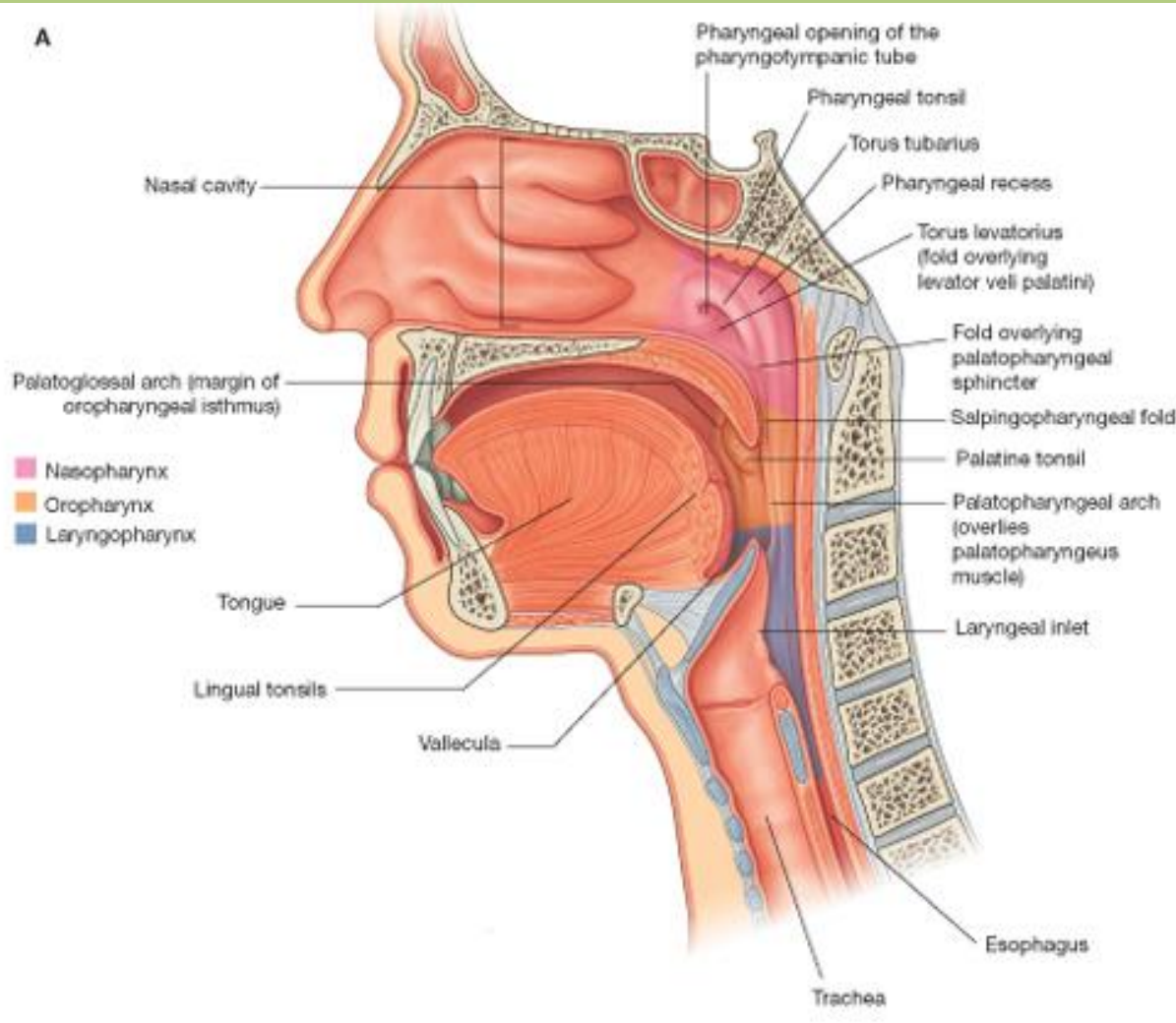




Torokszoros, lágyszájpad, garat és a garat körüli térségek

Dr. Katz Sándor Ph.D.

Cavum oris



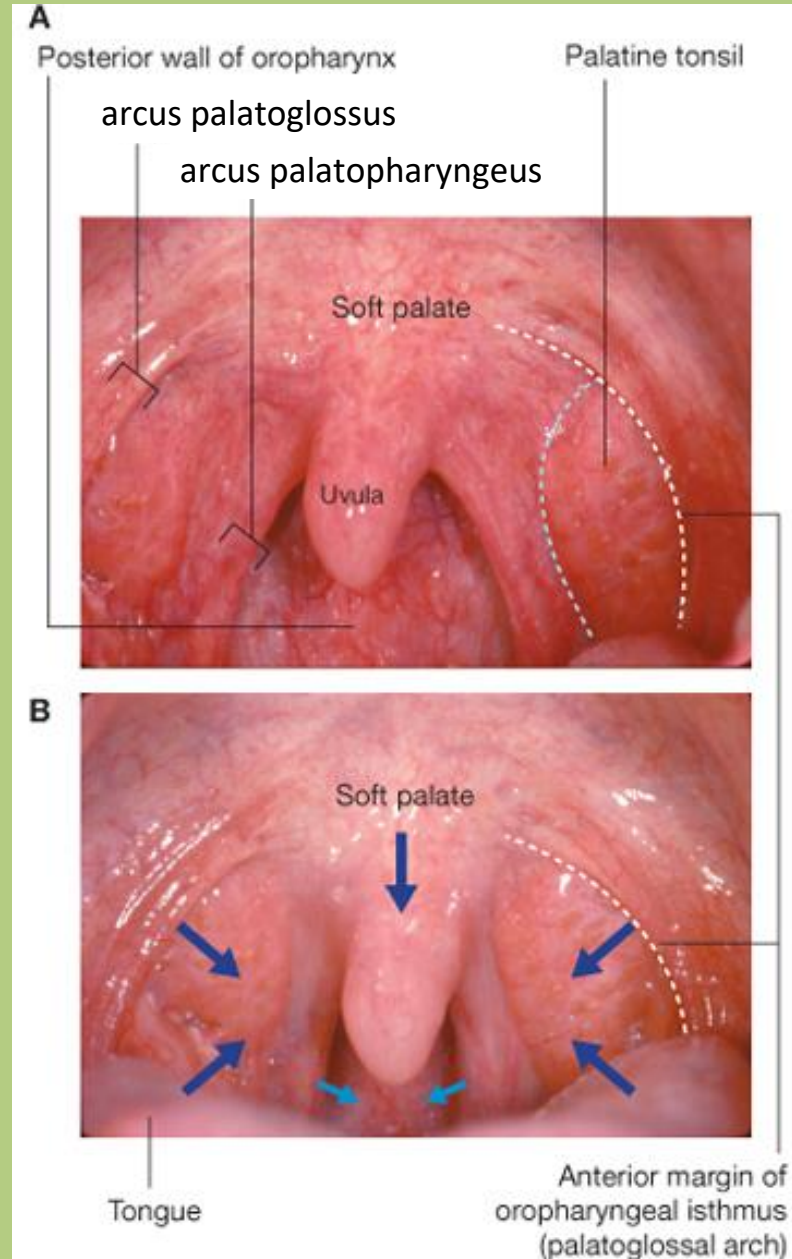
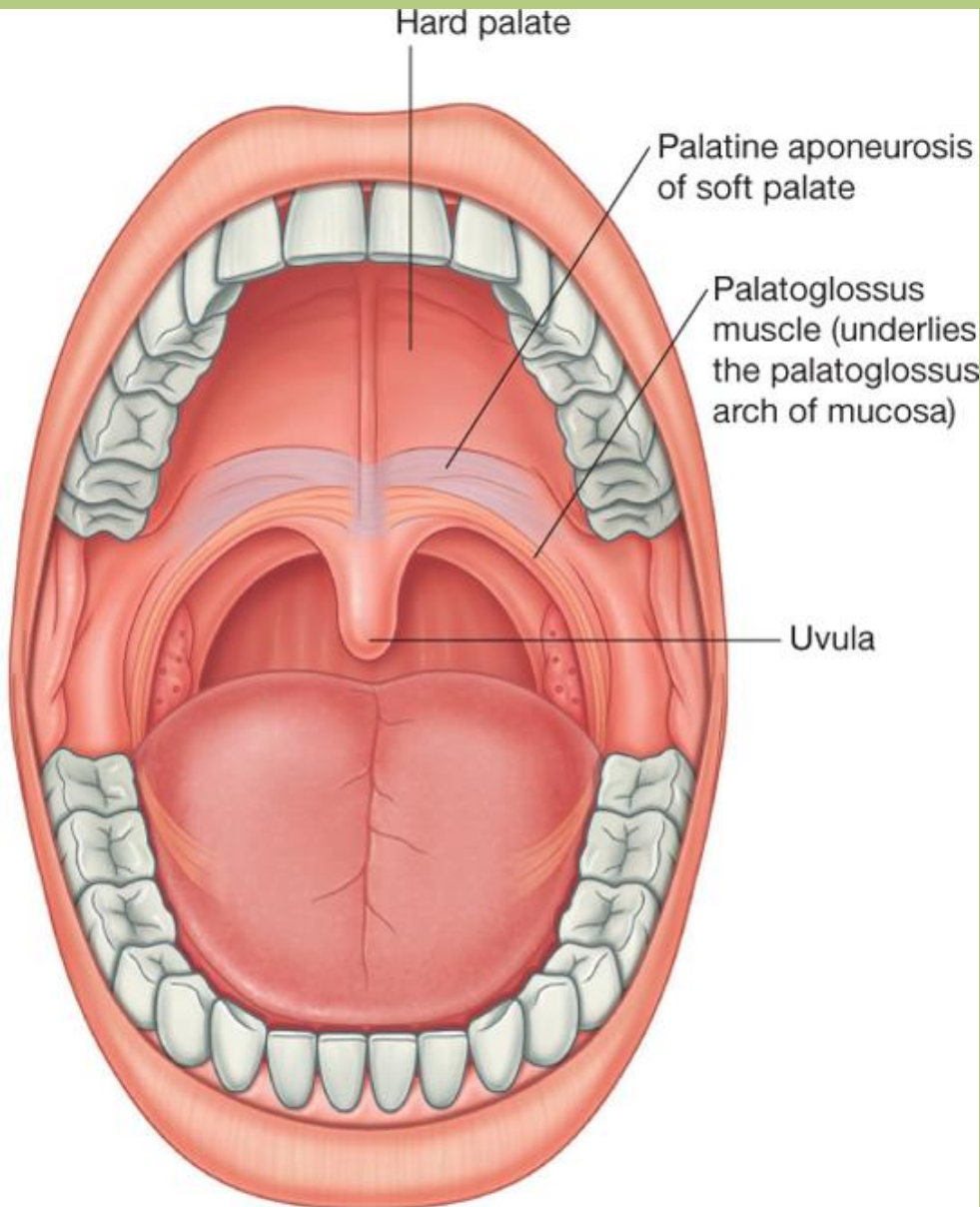
Határai:

- Anterior fal: ajkak
- Superior fal: palatum durum, palatum molle
- Inferior fal: m. mylohyoideus
- Lateral fal: pofa (m. buccinator)

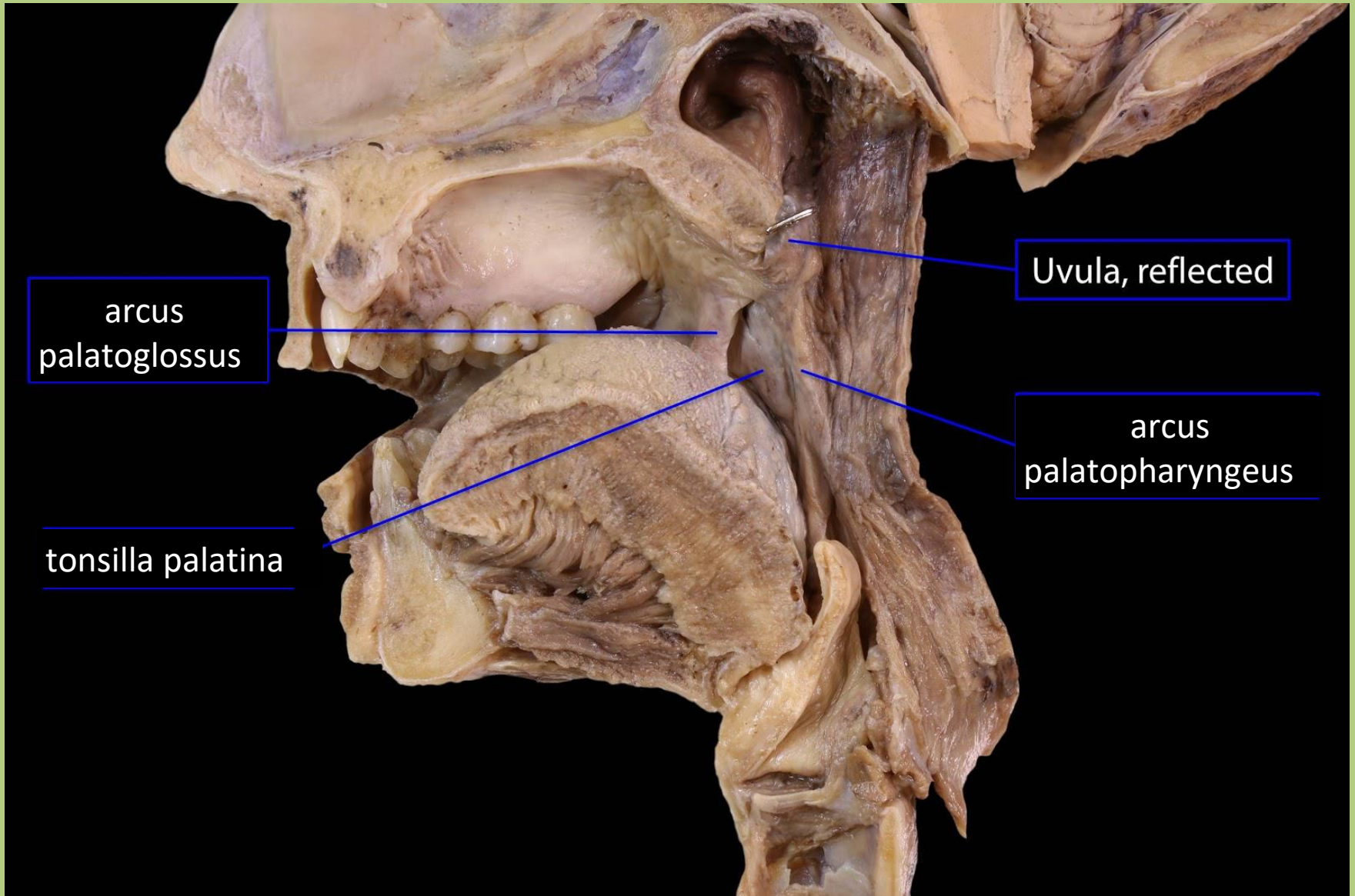
Részei:

- vestibulum oris
- cavum oris proprium
- isthmus faucium

Isthmus faucium



Isthmus faucium



arcus
palatoglossus

Uvula, reflected

tonsilla palatina

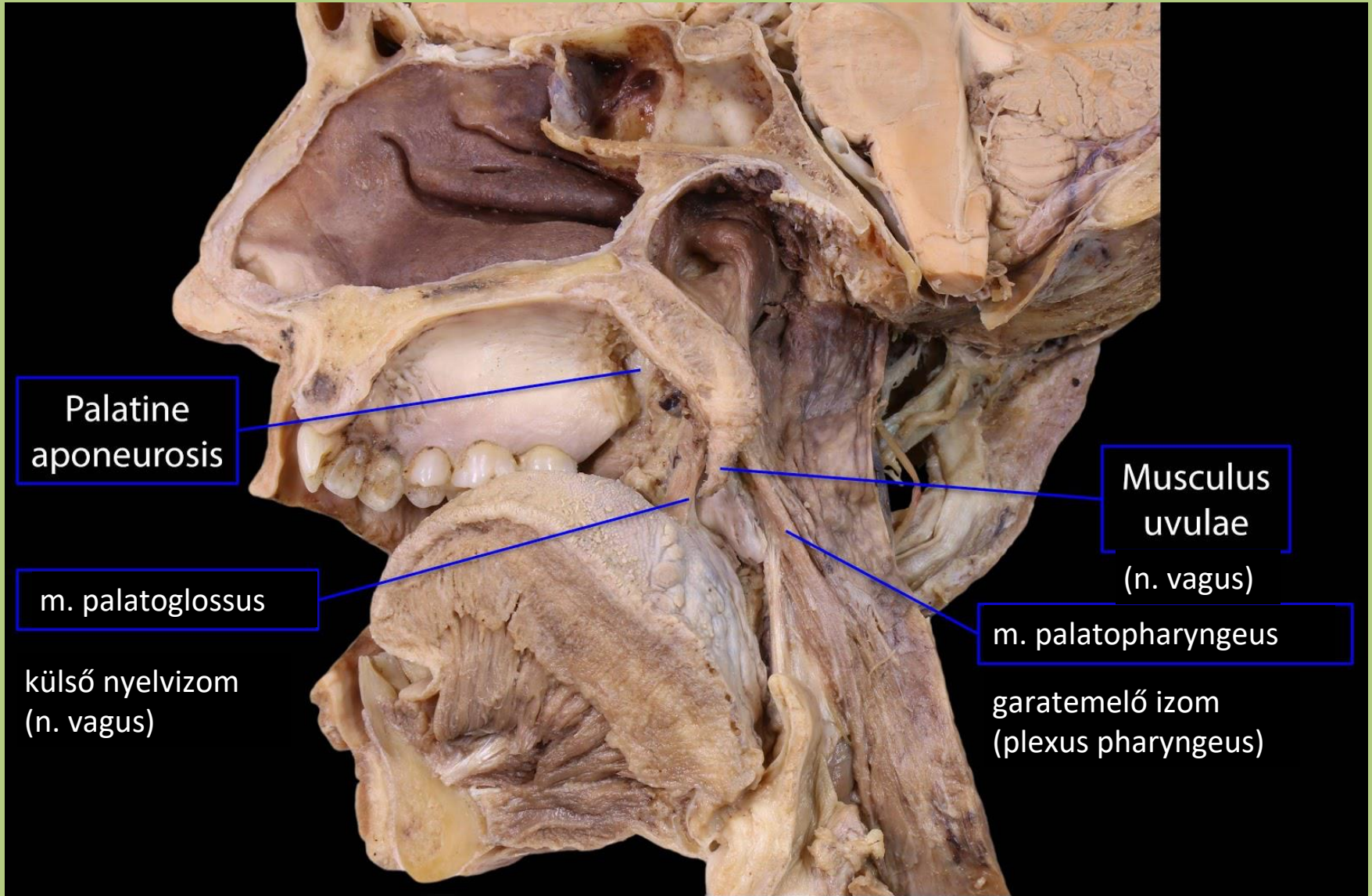
arcus
palatopharyngeus

Hemisected head, medial

BlueLink

© B. Kathleen Alsup & Glenn M. Fox

Isthmus faucium



Palatine
aponeurosis

m. palatoglossus

külső nyelvizom
(n. vagus)

Musculus
uvulae

(n. vagus)

m. palatopharyngeus

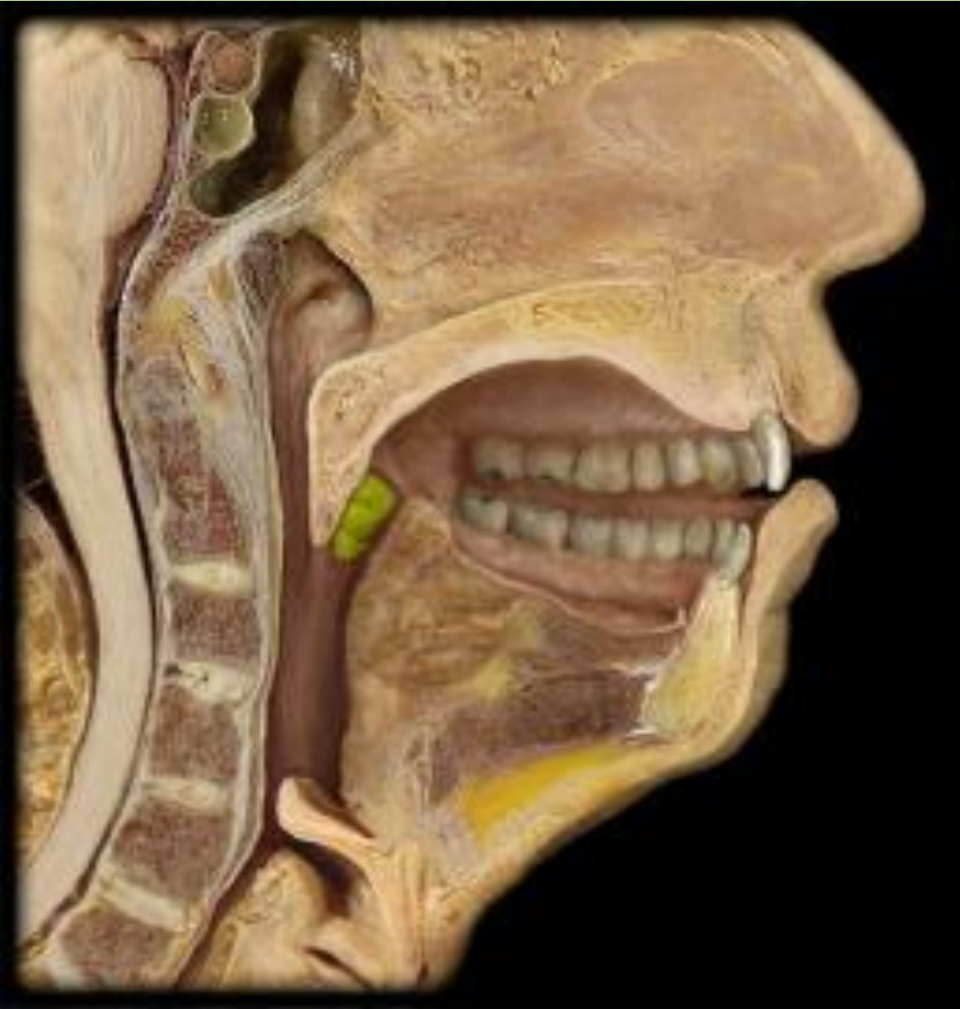garatemelő izom
(plexus pharyngeus)

Hemisected head, medial

BlueLink

© B. Kathleen Alsup & Glenn M. Fox

Tonsilla palatina



tonsilla palatina a fossa tonsillaribusban

Vérellátása:

1. a. palatina ascendens (a. facialis)
2. a. lingualis (a. carotis ext.)
3. a. palatina descendens (a. maxillaris)
4. a. pharyngea ascendens (a. carotis ext.)

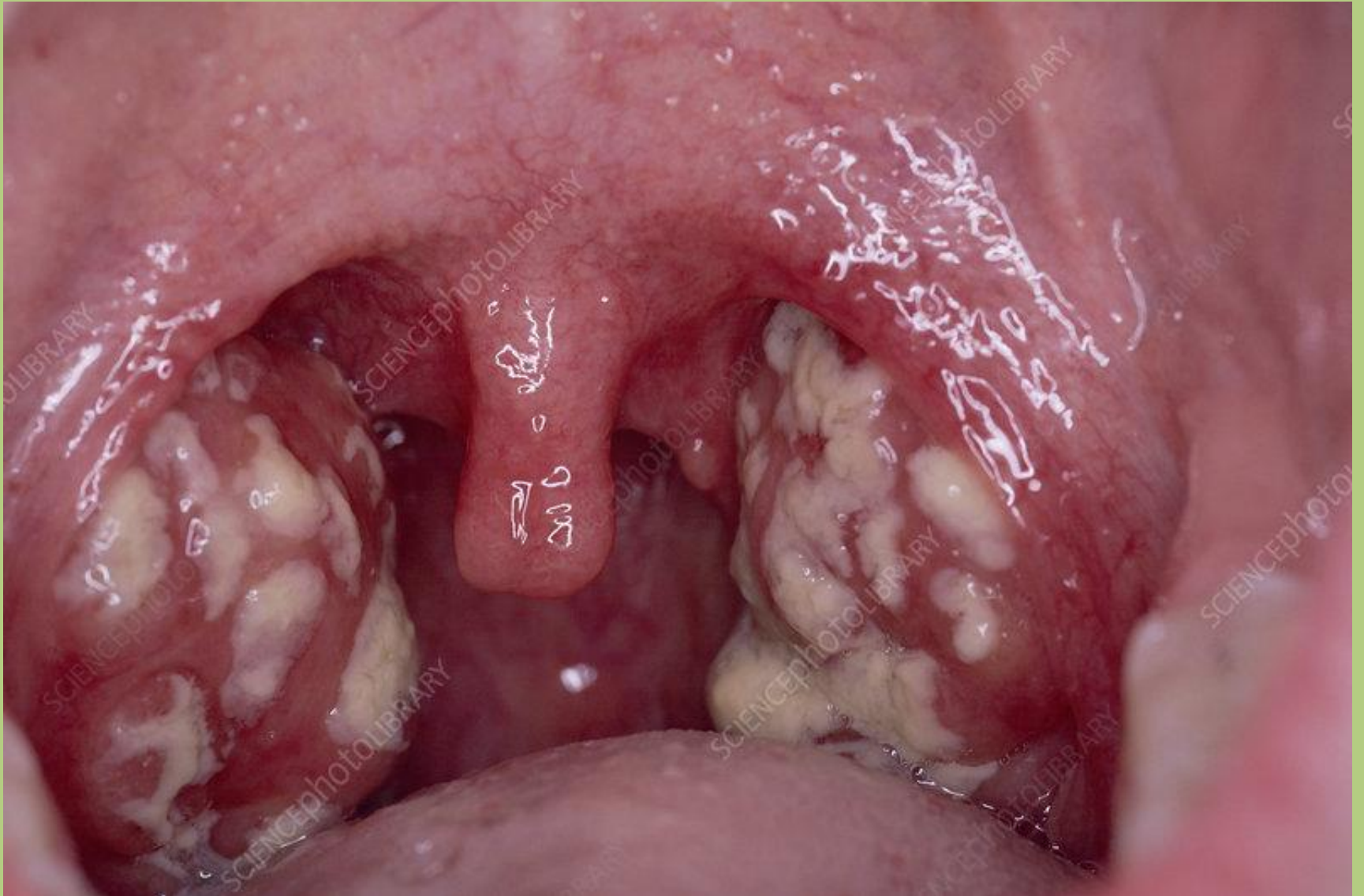Vénás elvezetés:

plexus peritonsillaris -
lingualis- és pharyngealis vénák - v. jugularis
interna

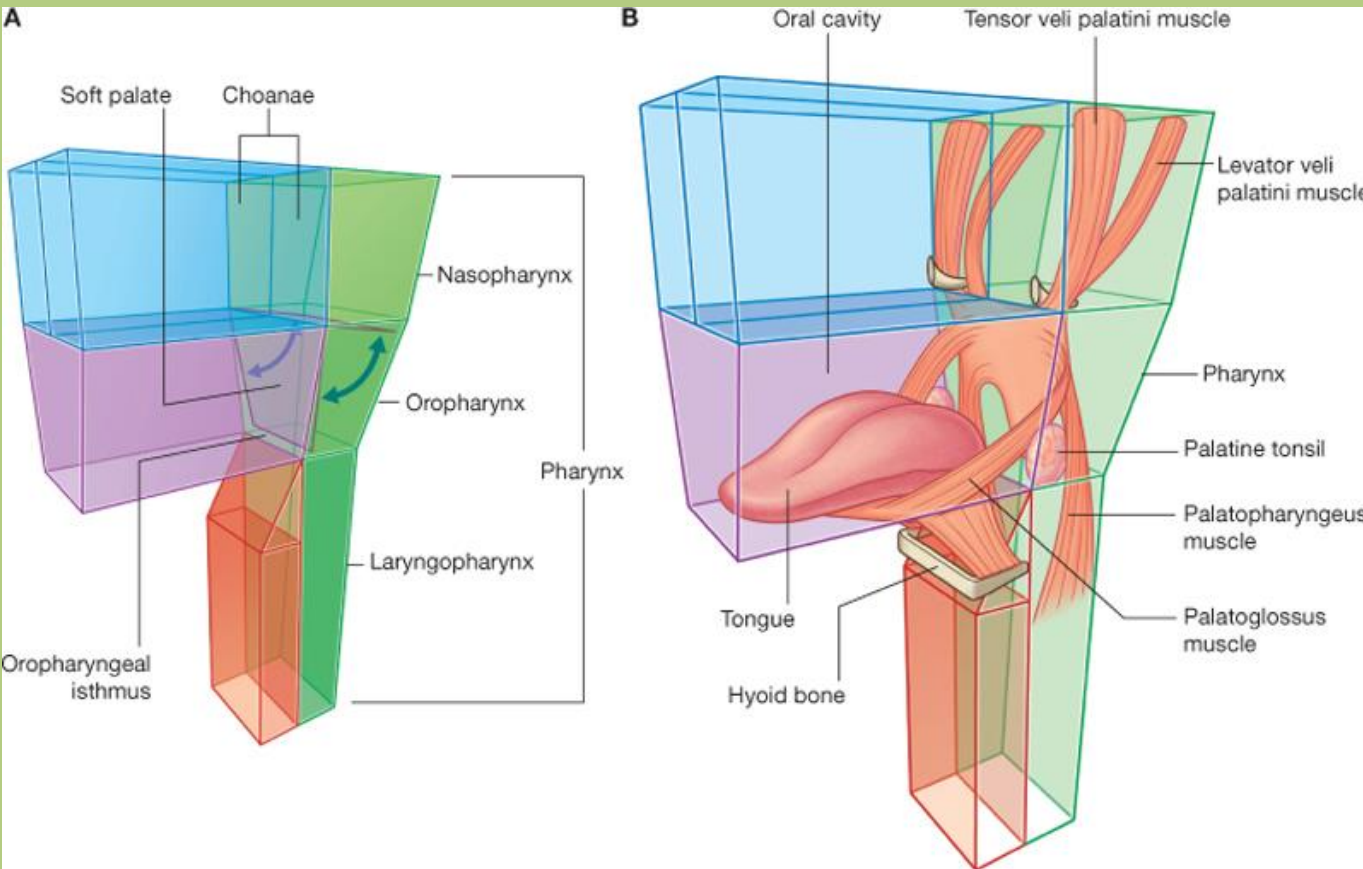
Beidegzés:

V/2 (r. pharyngeus)
n. glossopharyngeus (rr. tonsillares)

Tonsillitis



Palatum molle



Drake: Gray's Anatomy for Students, 2nd Edition.
Copyright © 2009 by Churchill Livingstone, an imprint of Elsevier, Inc. All rights reserved.

Szájpadizmok:

m. levator veli palatini

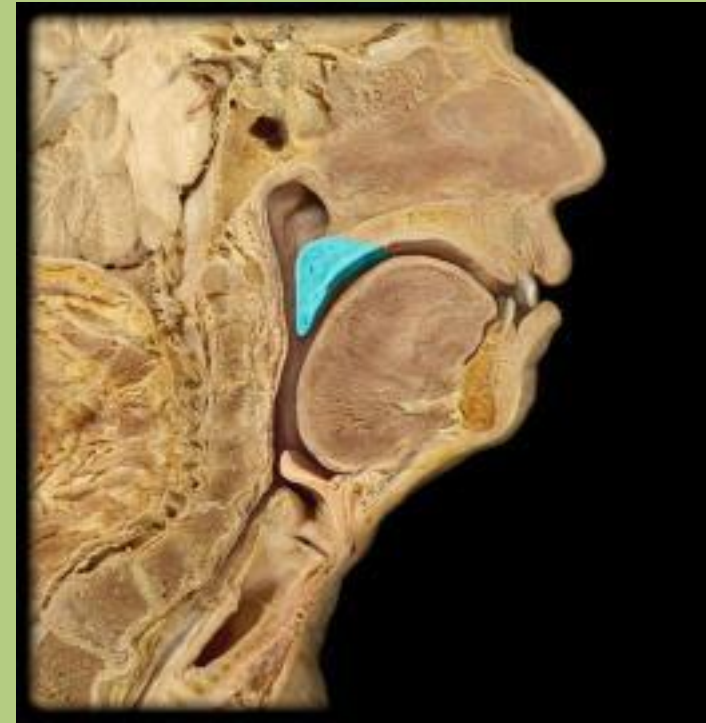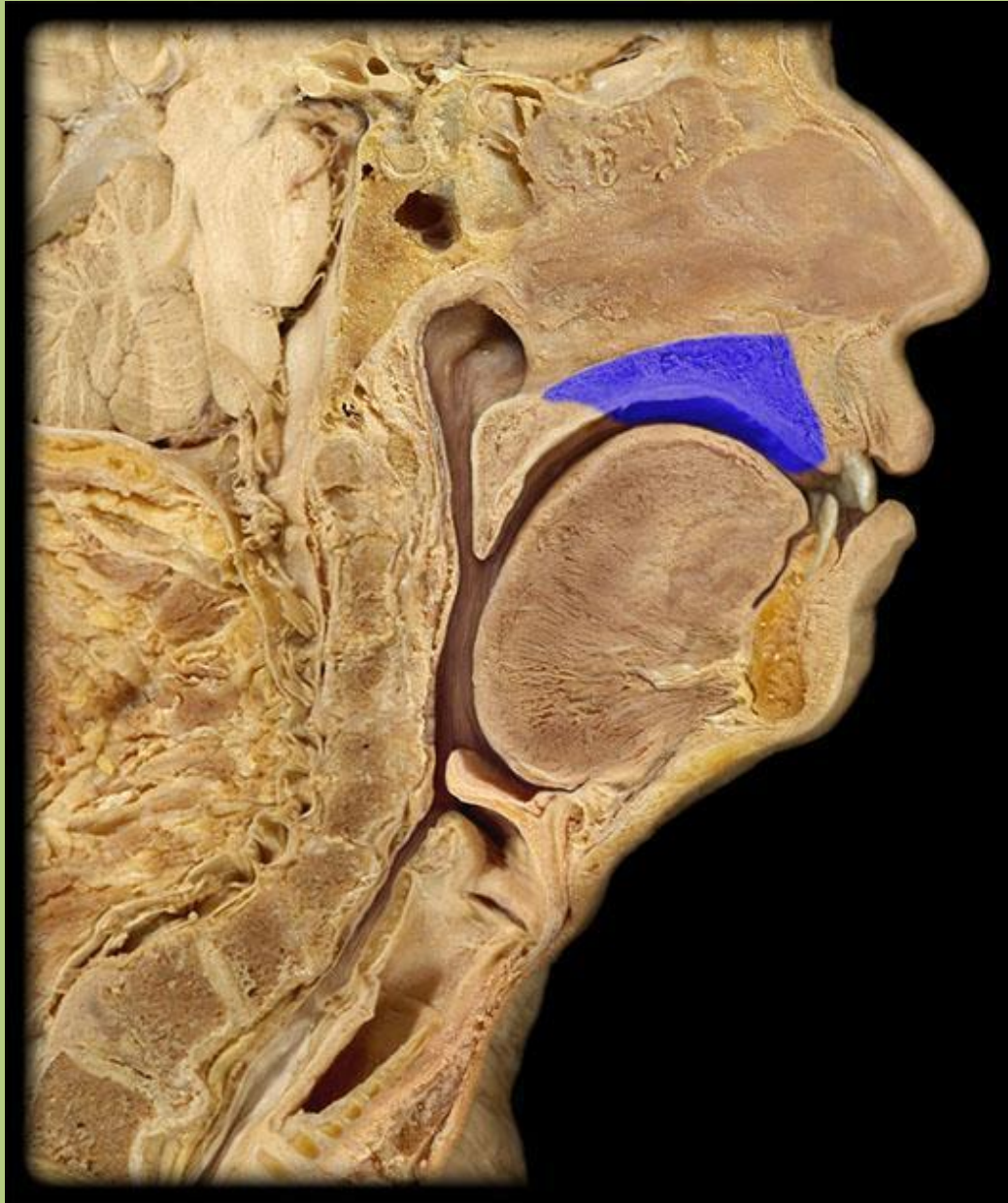
m. tensor veli palatini

m. palatoglossus

m. palatopharyngeus

(m. uvulae)

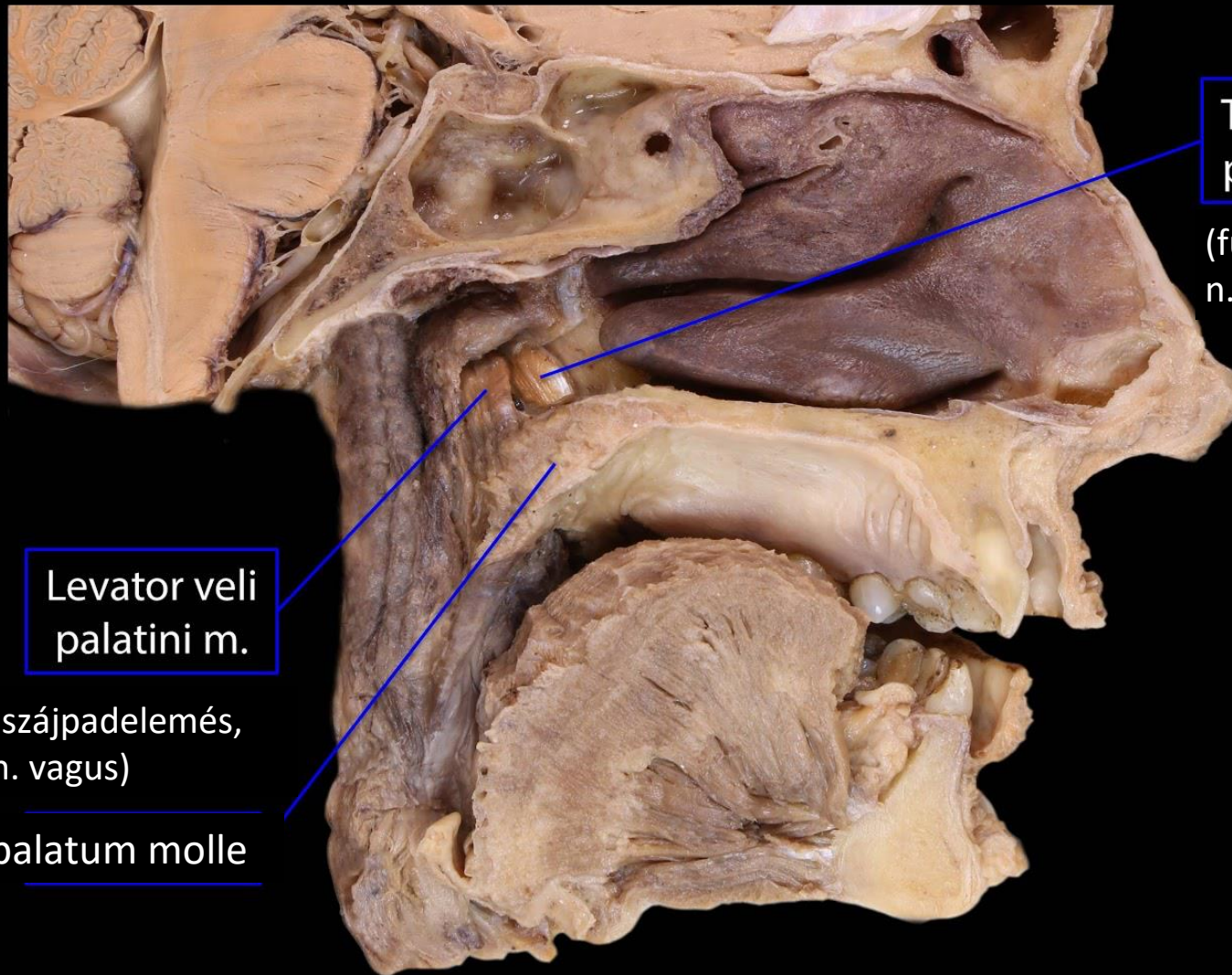
Palatum durum et molle



palatum molle

palatum durum

Levator et tensor veli palatini



Tensor veli palatini m.

(fülkürt nyitása,
n. mandibularis)

Levator veli palatini m.

(szájpadelemés,
n. vagus)

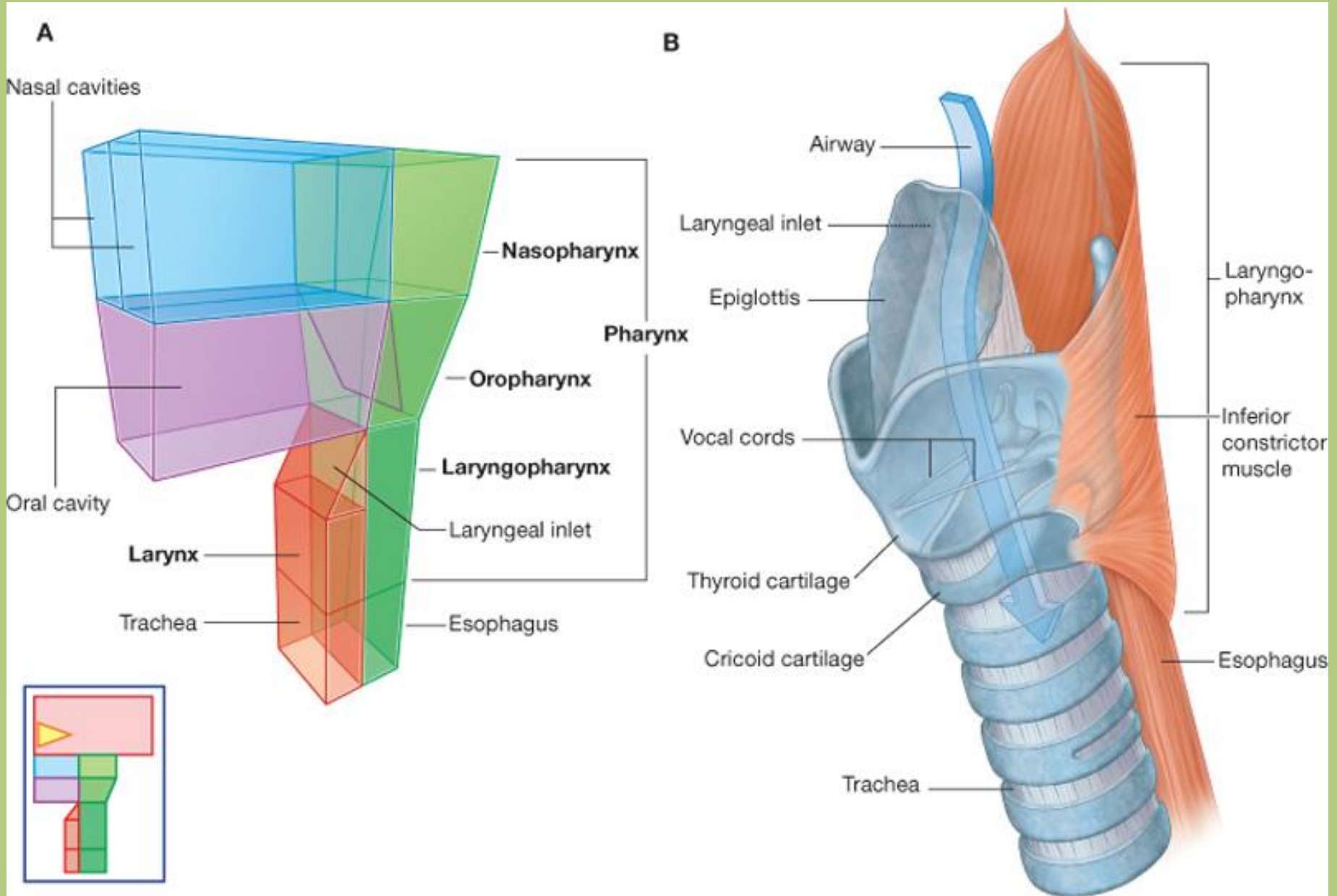
palatum molle

Left hemisected head, medial

BlueLink

© B. Kathleen Alsup & Glenn M. Fox

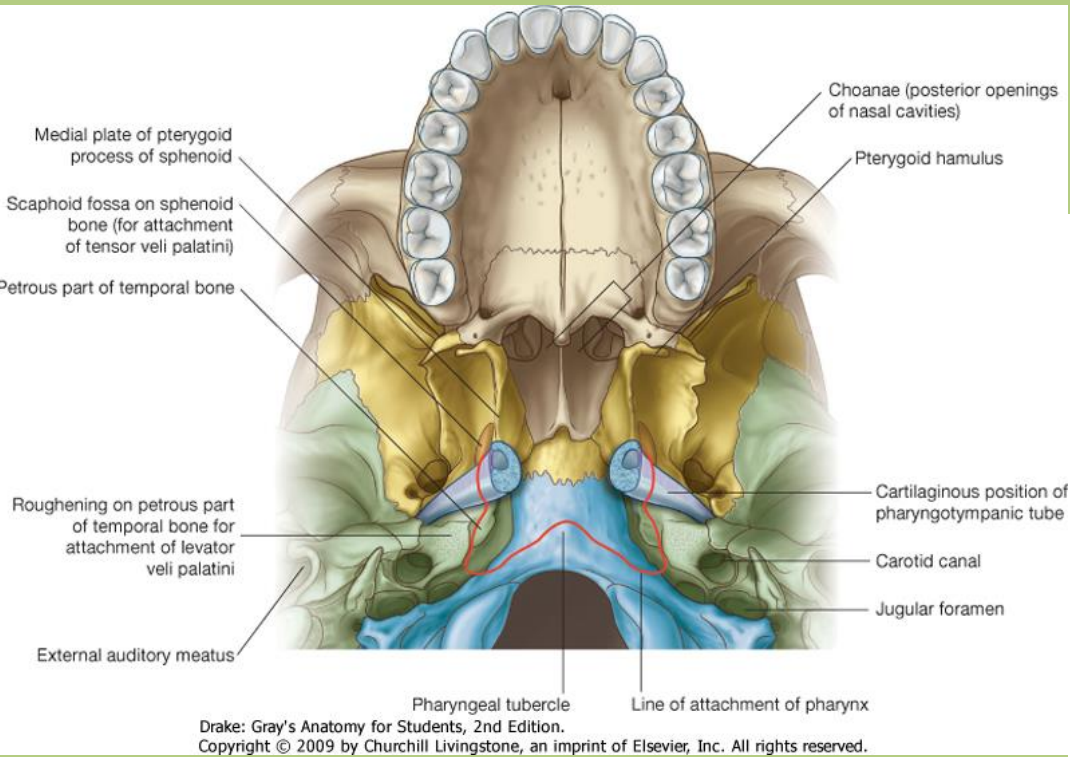
Pharynx



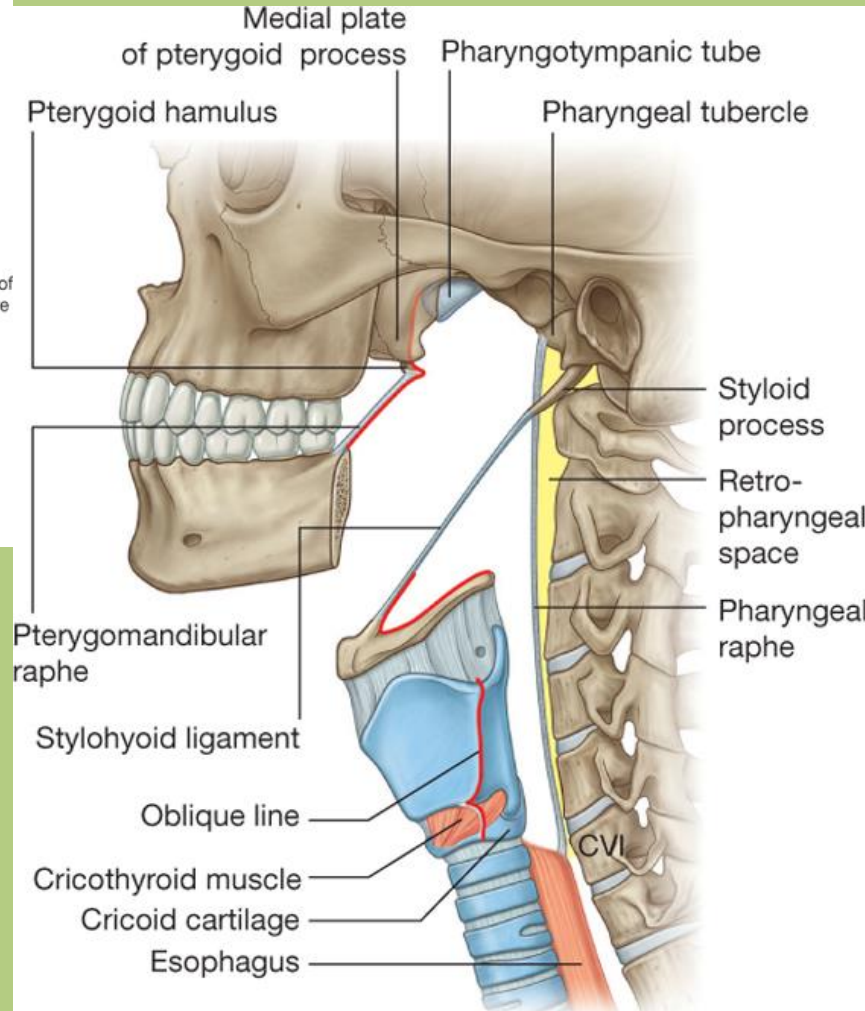
Drake: Gray's Anatomy for Students, 2nd Edition.

Copyright © 2009 by Churchill Livingstone, an imprint of Elsevier, Inc. All rights reserved.

Pharynx - izomgarnitúra eredése



A garat egy izommentes kötőszövetes megerősődéssel ered a koponyaalapról: *fascia pharyngobasilaris*.



Pharynx

I. Nasopharynx (epipharynx):

ant.: choanae

sup.: fornix pharyngis

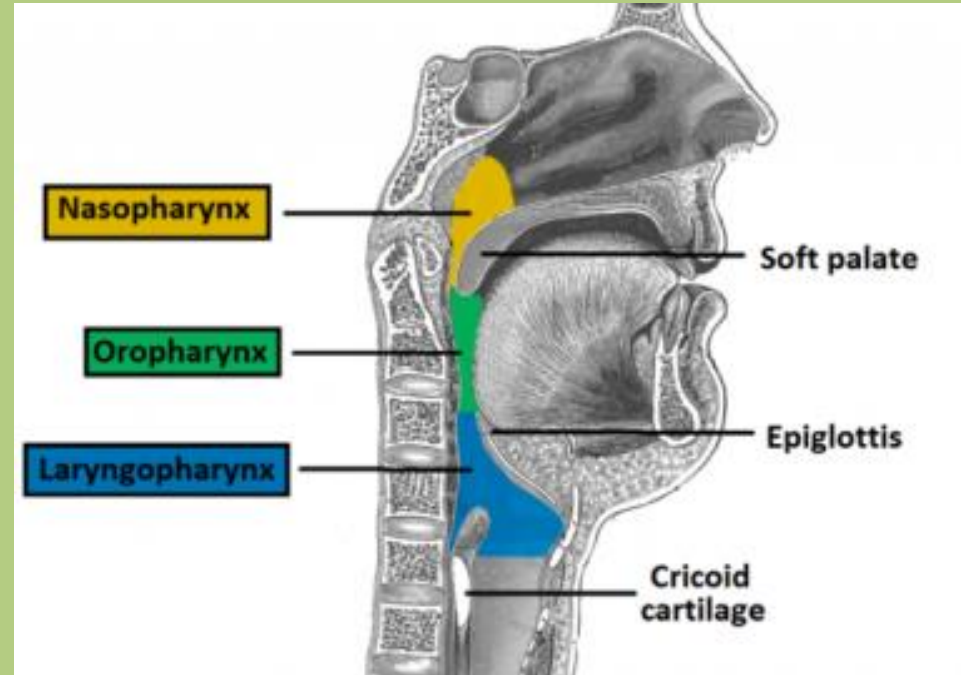
II. Oropharynx (mesopharynx):

ant.: isthmus faucium

sup.: palatum molle

III. Laryngopharynx (hypopharynx):

ant./sup.: epiglottis



Pharynx

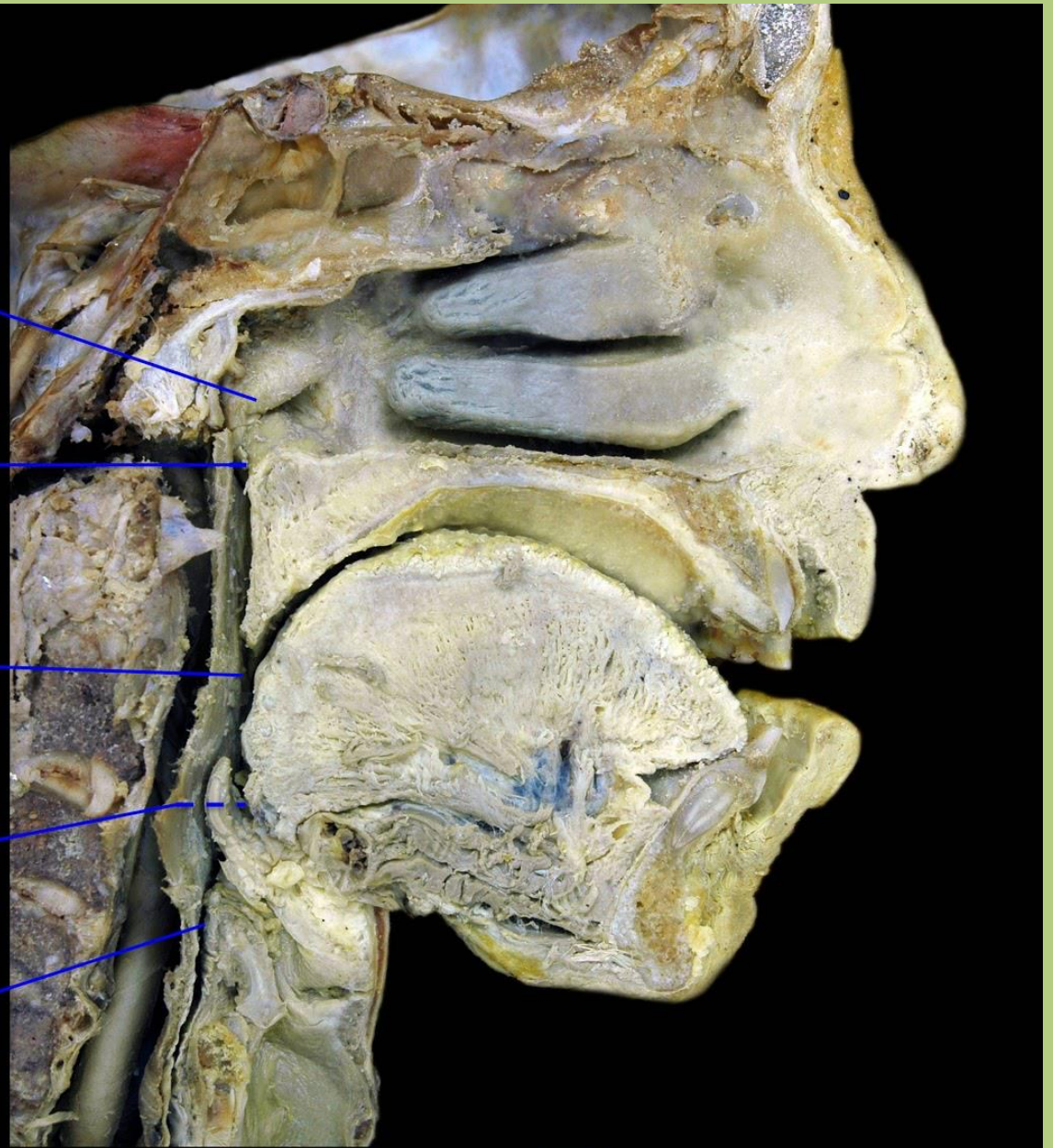
I. **Nasopharynx**
(epipharynx)

Boundary at
soft palate

II. **Oropharynx**
(mesopharynx)

Boundary at pharyngo-
epiglottic fold

III. **Laryngopharynx**
(hypopharynx)

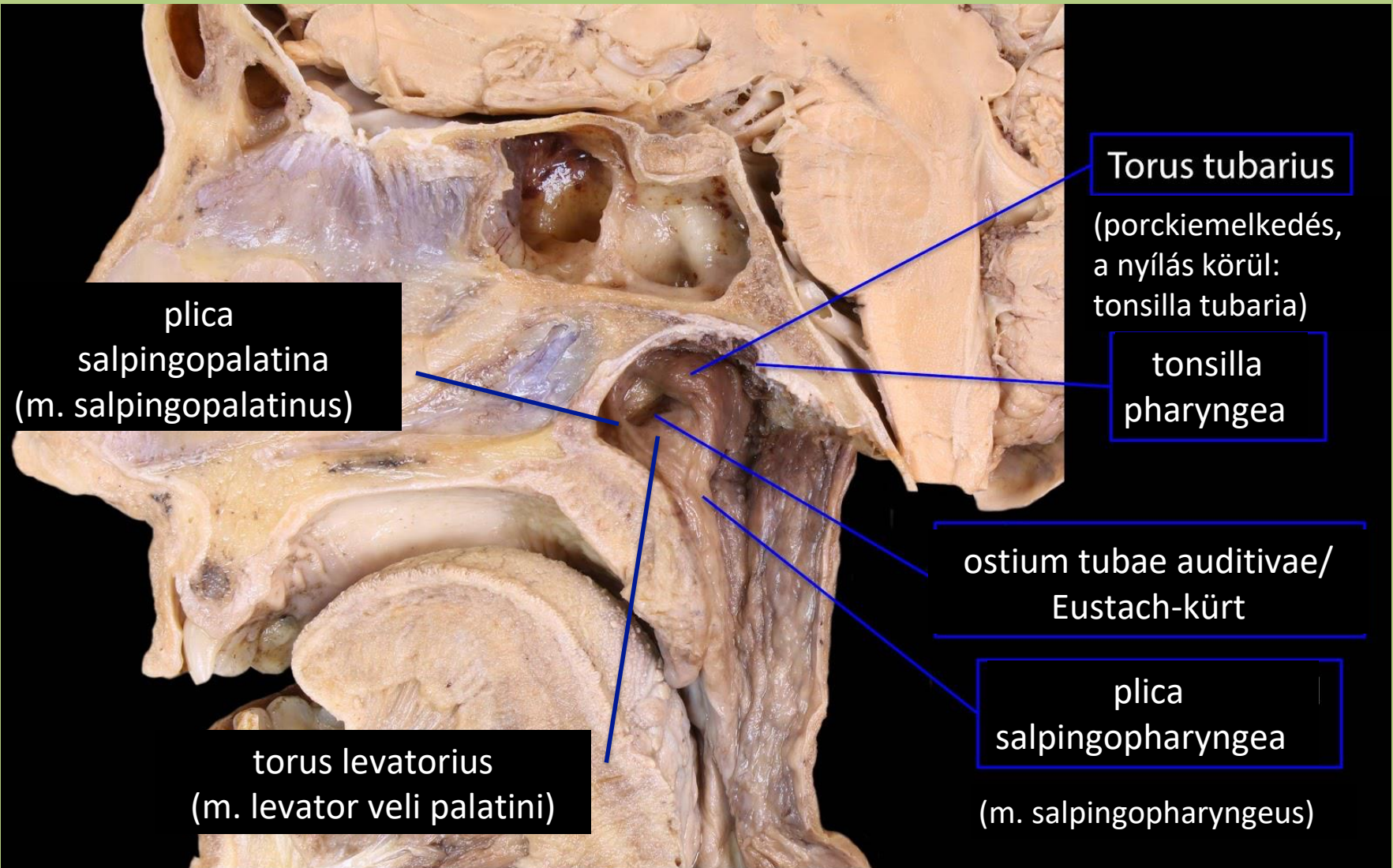


Left hemisected head, medial

BlueLink

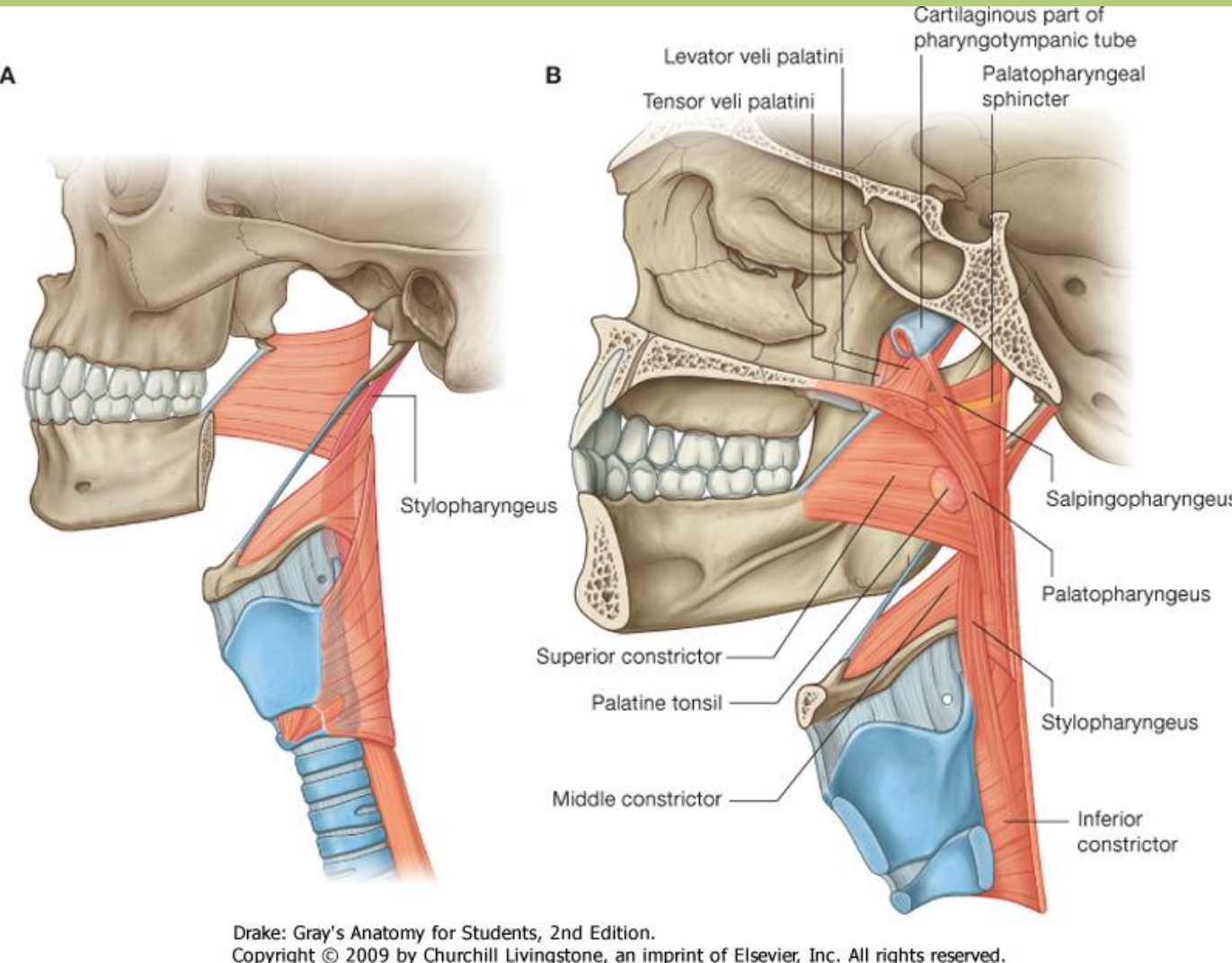
© B. Kathleen Alsup & Glenn M. Fox

Nasopharynx



Hemisected head, medial

Pharynx - mm. levatores pharyngis



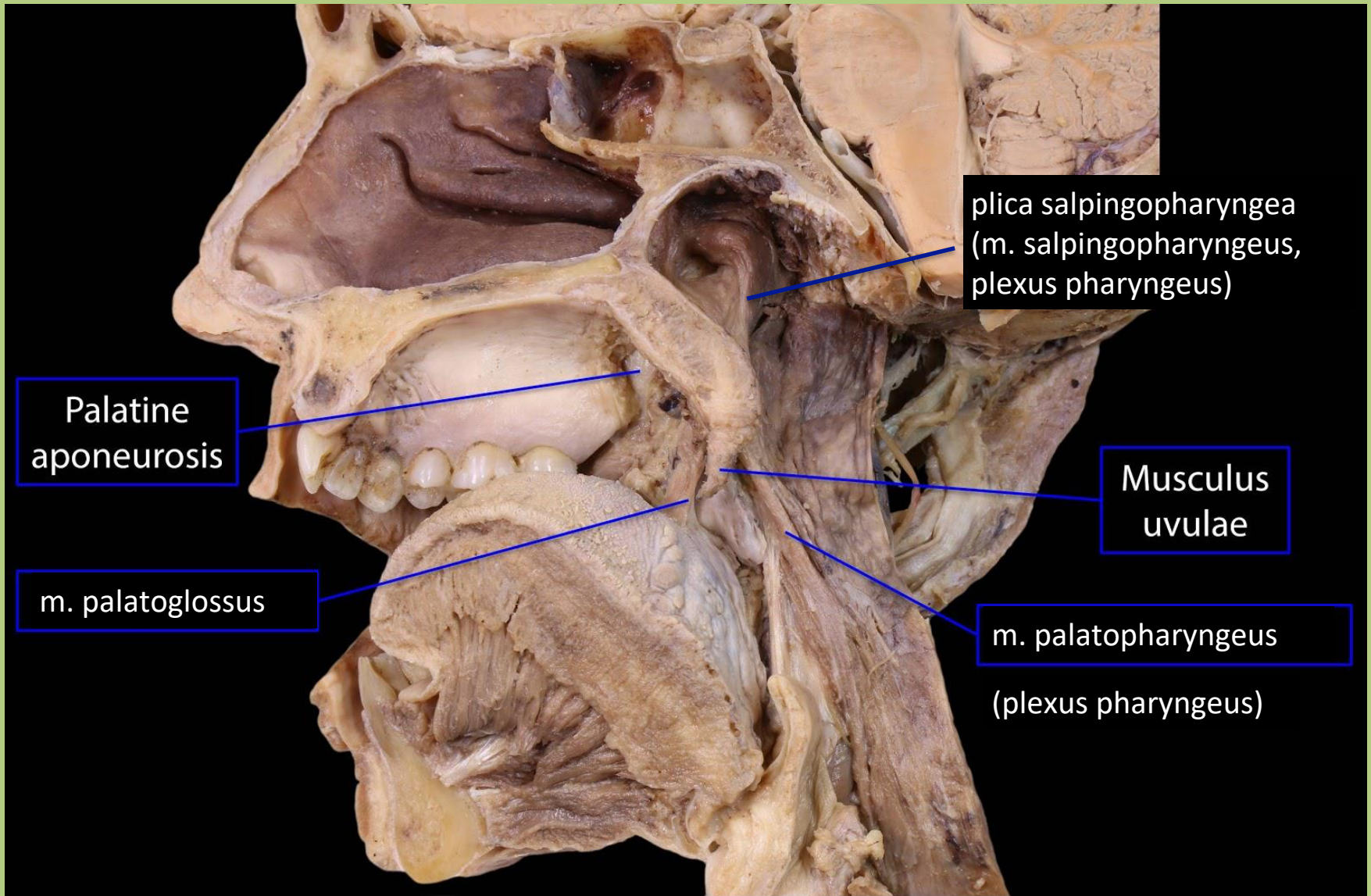
m. salpingopharyngeus:
e.: fülkürt porca, hamulus pterygoideus

m. palatopharyngeus:
e.: aponeurosis palatina, palatum durum

m. stylopharyngeus:
e.: proc.styloideus

tapadás: garatfal

Mm. levatores pharyngis



Palatine aponeurosis

plica salpingopharyngea
(m. salpingopharyngeus,
plexus pharyngeus)

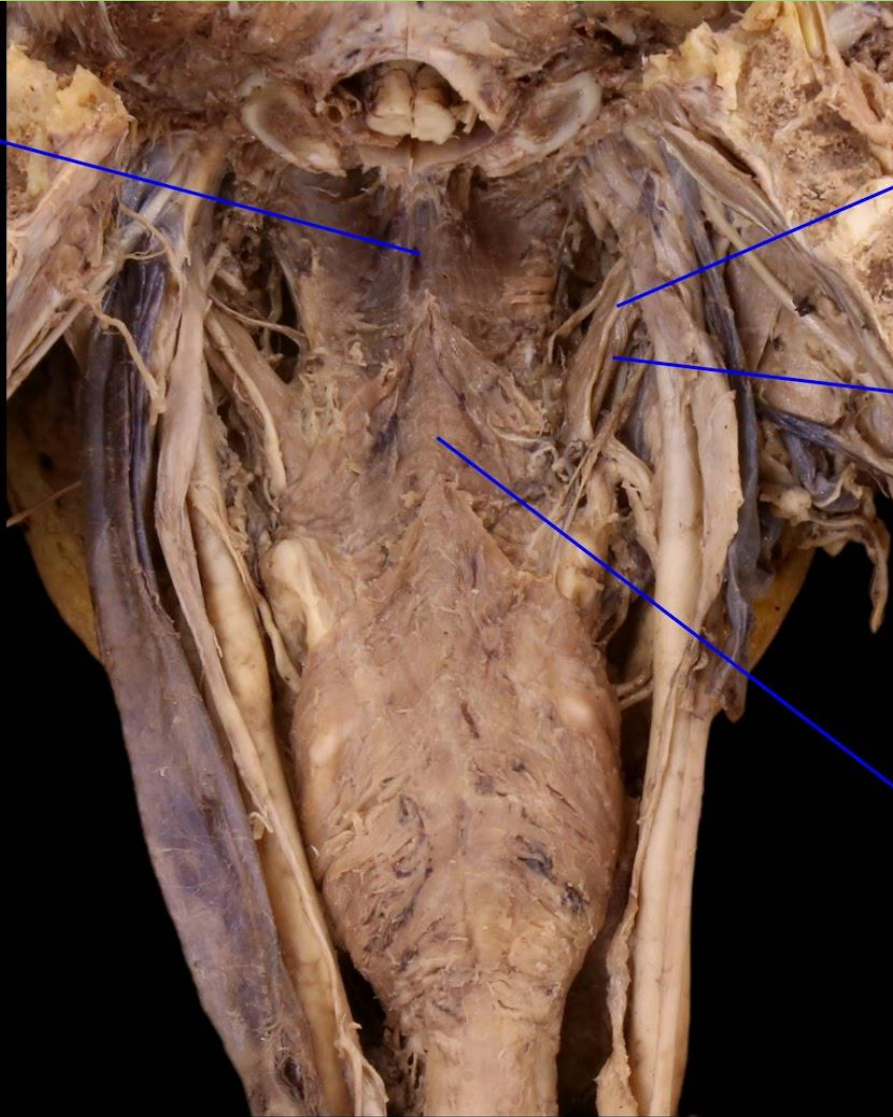
m. palatoglossus

Musculus uvulae

m. palatopharyngeus
(plexus pharyngeus)

Mm. levatores pharyngis

Superior
pharyngeal
constrictor m.

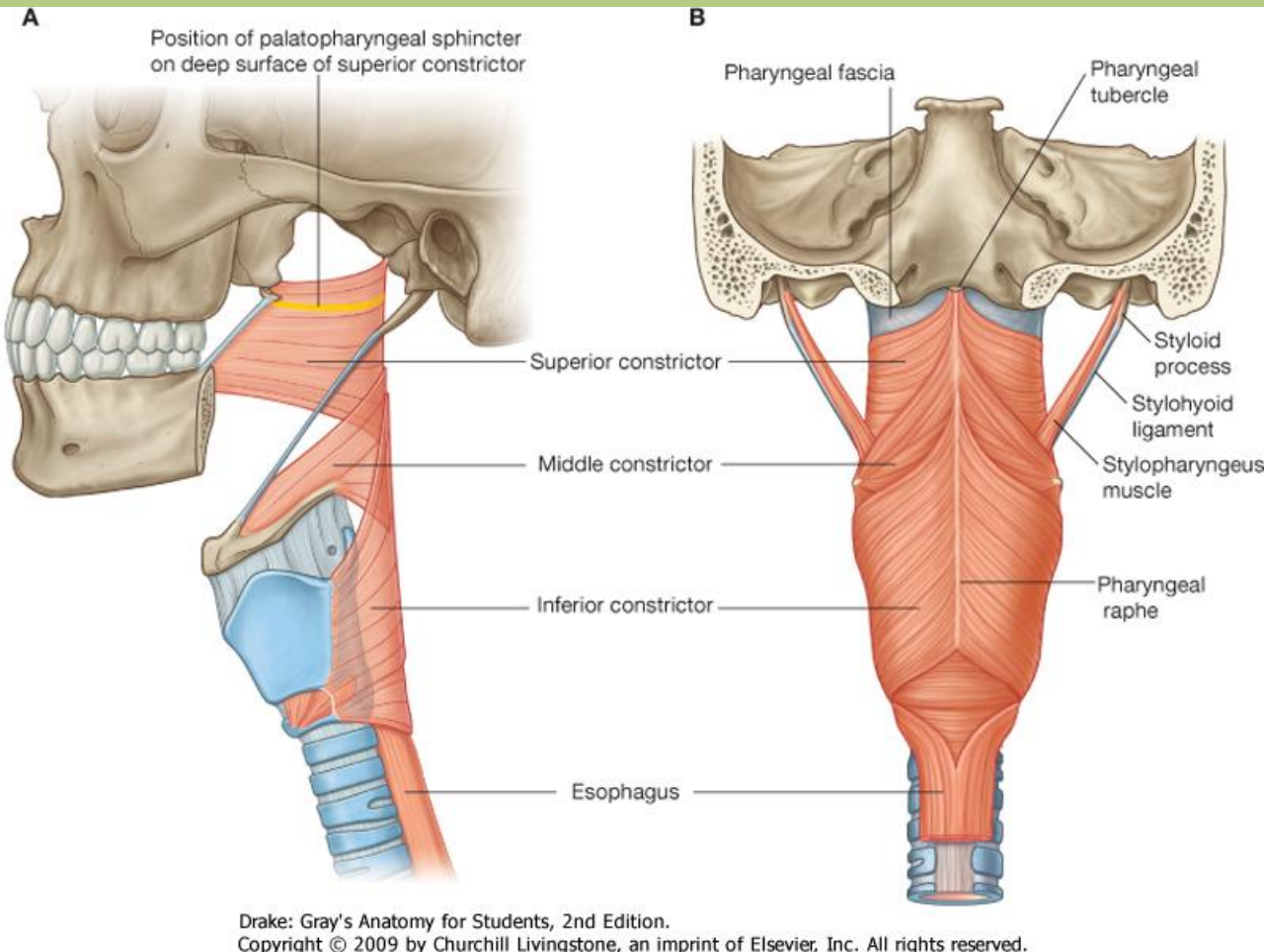


Glossopharyngeal n.
(CN IX)

Stylopharyngeus m.
(n. glossopharyngeus)

Middle
pharyngeal
constrictor m.

Pharynx - mm. constrictores pharyngis



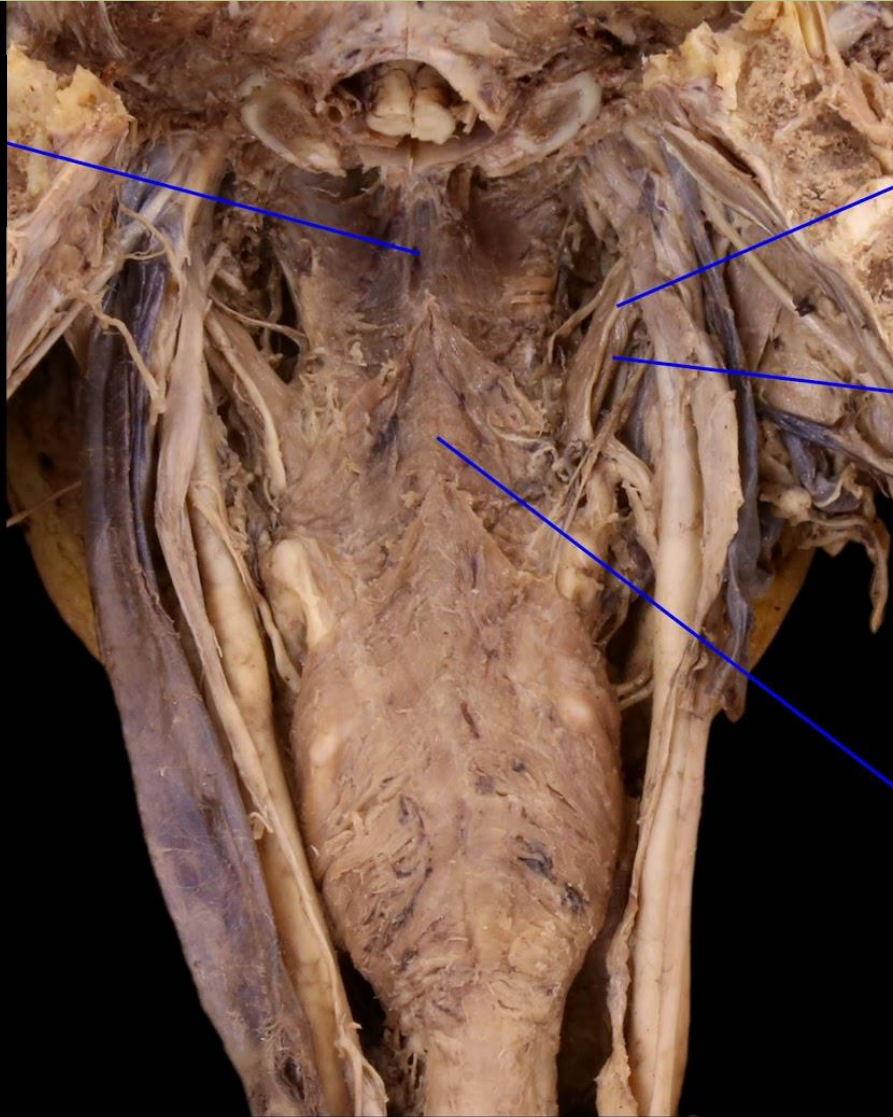
m. constrictor pharyngis superior:

1. **pars pterygopharyngea** (e.: lamina medialis processus pterygoidei)
2. **pars buccopharyngea** (e.: raphe pterygomandibularis)
3. **pars mylopharyngea** (e.: linea mylohyoidea)
4. **pars glossopharyngea** (e.: radix linguae)

tapadás: raphe pharyngis

Pharynx - mm. constrictores pharyngis

m. constrictor
pharyngis
superior



Glossopharyngeal n.
(CN IX)

Stylopharyngeus m.

Middle
pharyngeal
constrictor m.

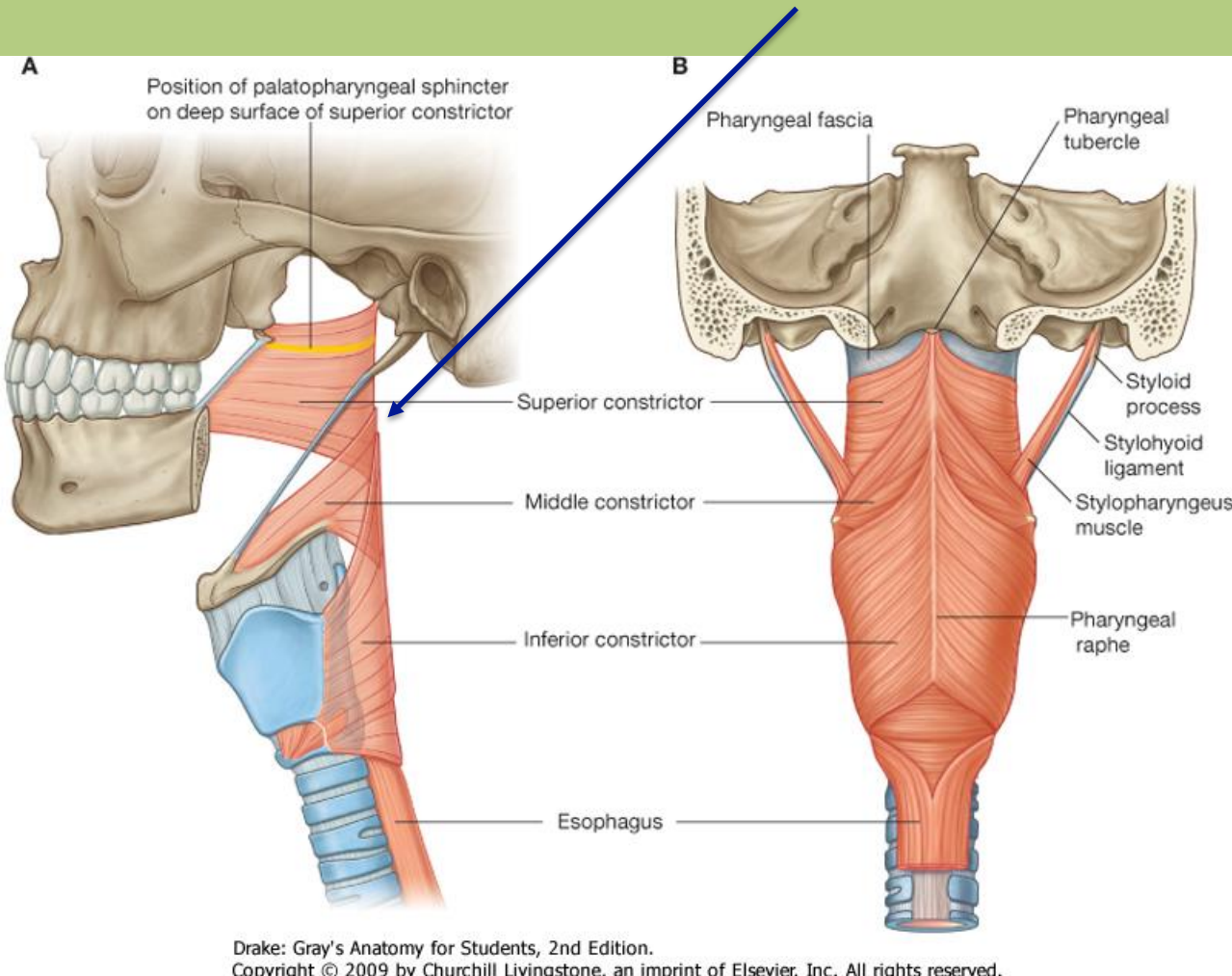
Pharynx, posterior

BlueLink

© B. Kathleen Alsup & Glenn M. Fox

Pharynx - mm. constrictores pharyngis

AZ ALSÓ RÉSZEK TAKARJÁK A FELETTE LÉVŐKET!



m. constrictor pharyngis medius:

1. pars chondropharyngea
(e.: os hyoideum, cornu minus)

2. pars ceratopharyngea (e.: os hyoideum, cornu majus)

m. constrictor pharyngis inferior:

1. pars thyropharyngea (e.: cartilago thyroidea)

2. pars cricopharyngea (e.: cartilago cricoidea)

tapadás: raphe pharyngis

Pharynx - mm. constrictores pharyngis

m. constrictor
pharyngis
superior

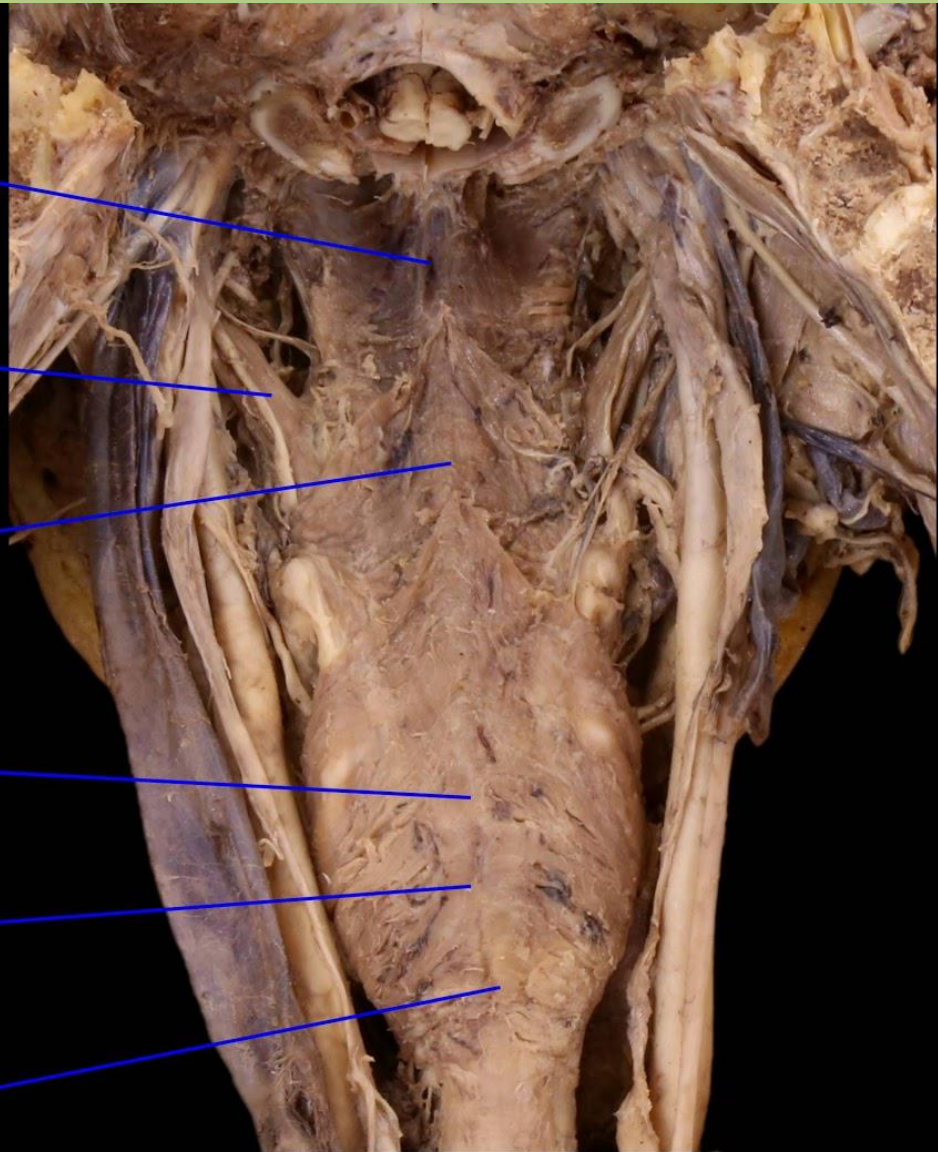
Stylopharyngeus m.

m. constrictor
pharyngis
medius

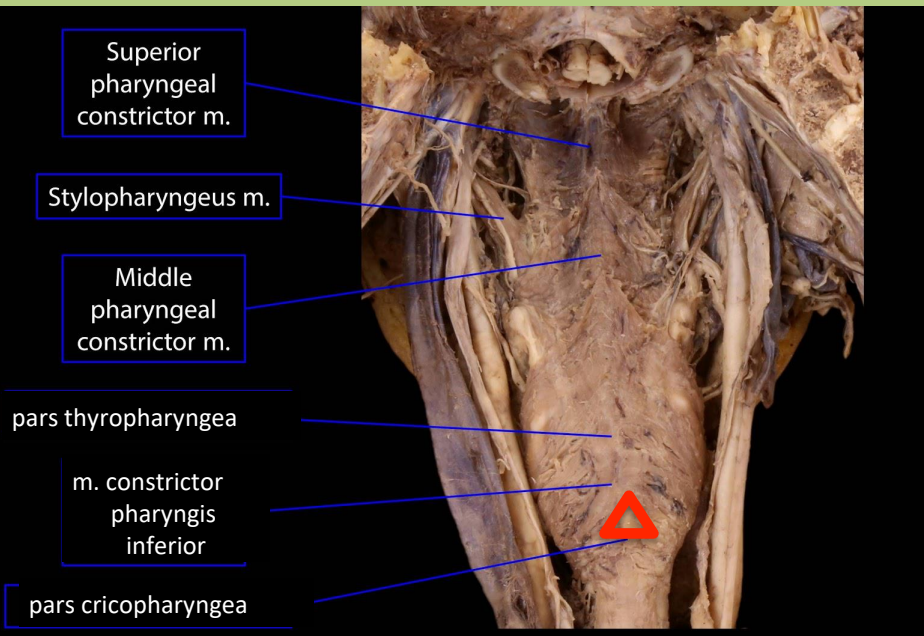
pars thyropharyngea

m. constrictor
pharyngis
inferior

pars cricopharyngea



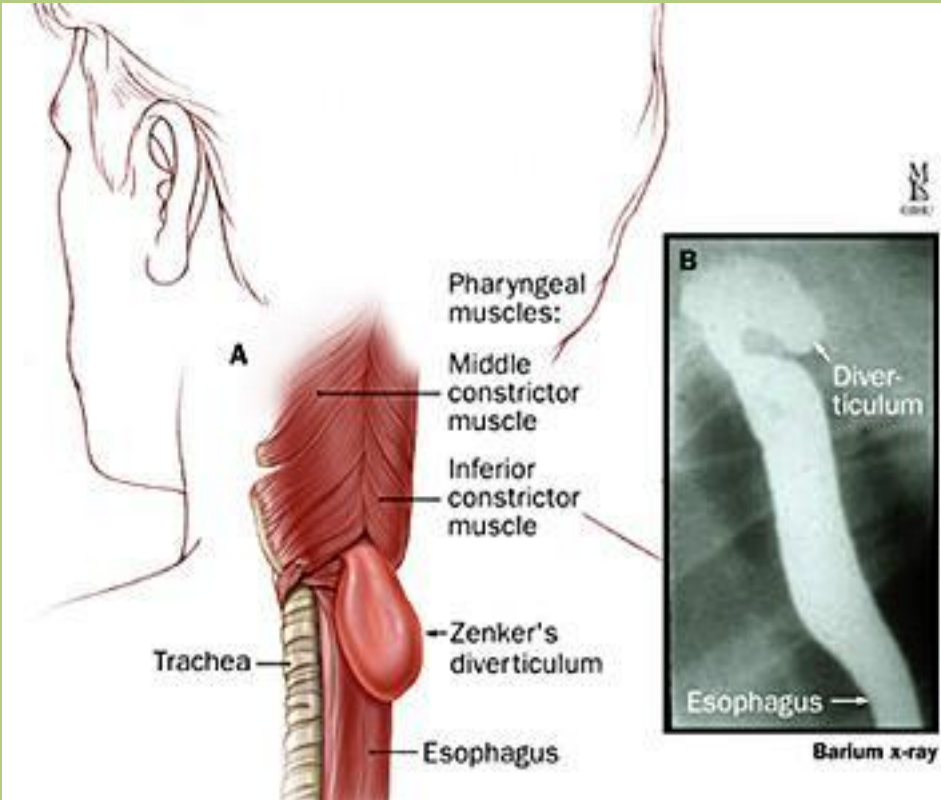
Killian-háromszög



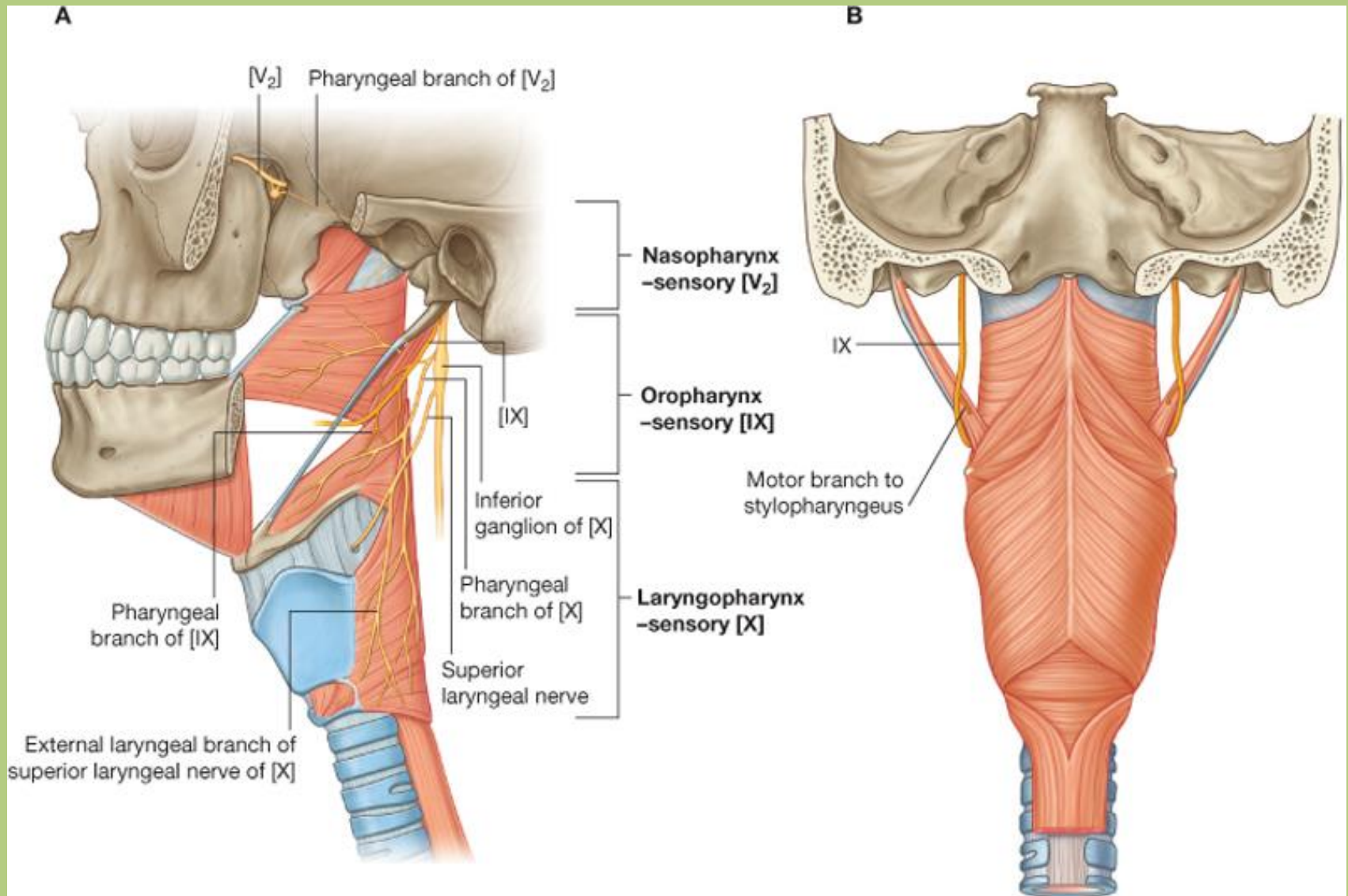
Pharynx, posterior

BlueLink © B. Kathleen Alsup & Glenn M. Fox

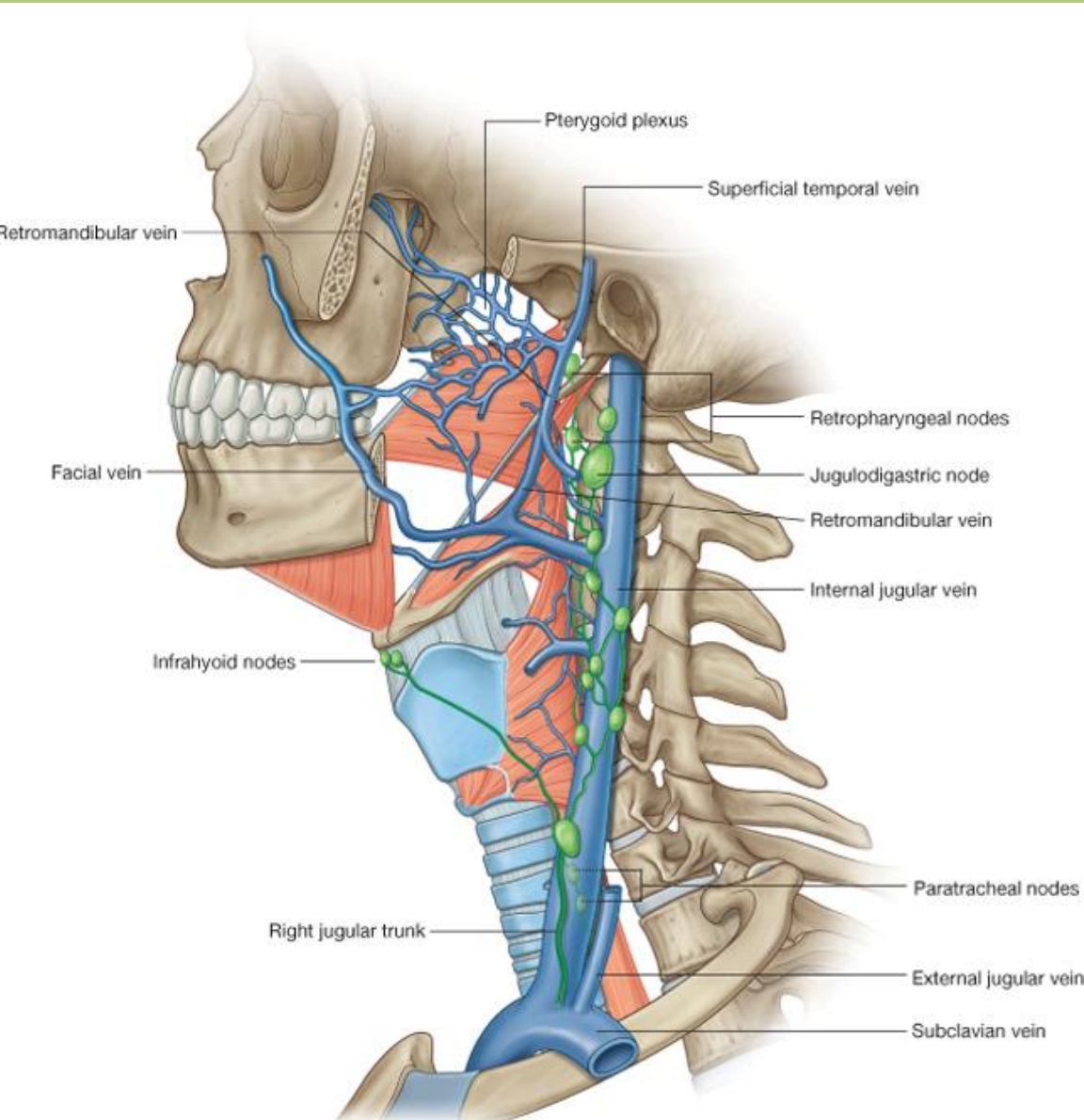
A ***pars cricopharyngea*** két része közötti izomgyenge pont, ahol a mucosa kibolthozhat hátrafelé (***Zenker-divertikulum***), ételpangást okozva. Általában középkorban/időskorban fordul elő.



Pharynx - érző beidegzés



Pharynx - vérellátás



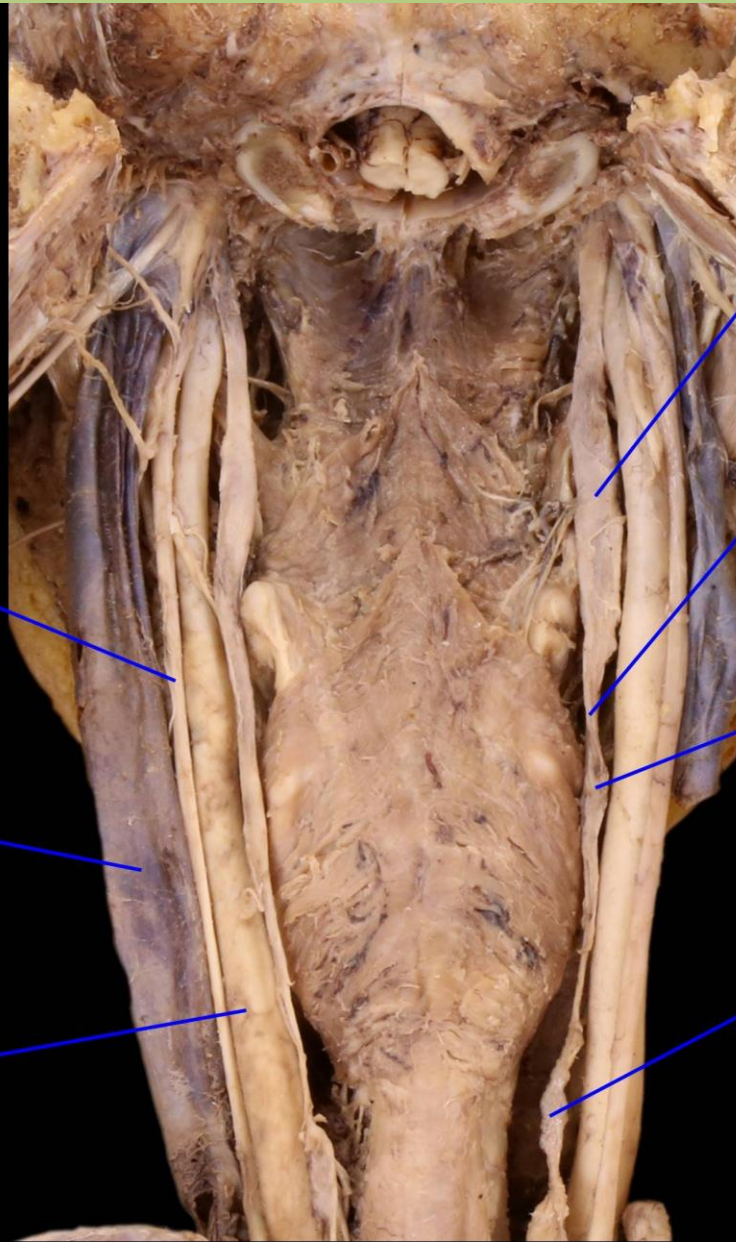
Vénás elvezetés:

plexus venosus pharyngis - v.
jugularis interna

Nyirokelvezetés:

retropharyngeális nyirokcsomók
- truncus jugularis

Pharynx



ganglion cervicale
superius

truncus
sympathicus

ganglion cervicale
medius

ganglion cervicale
inferius

n. vagus

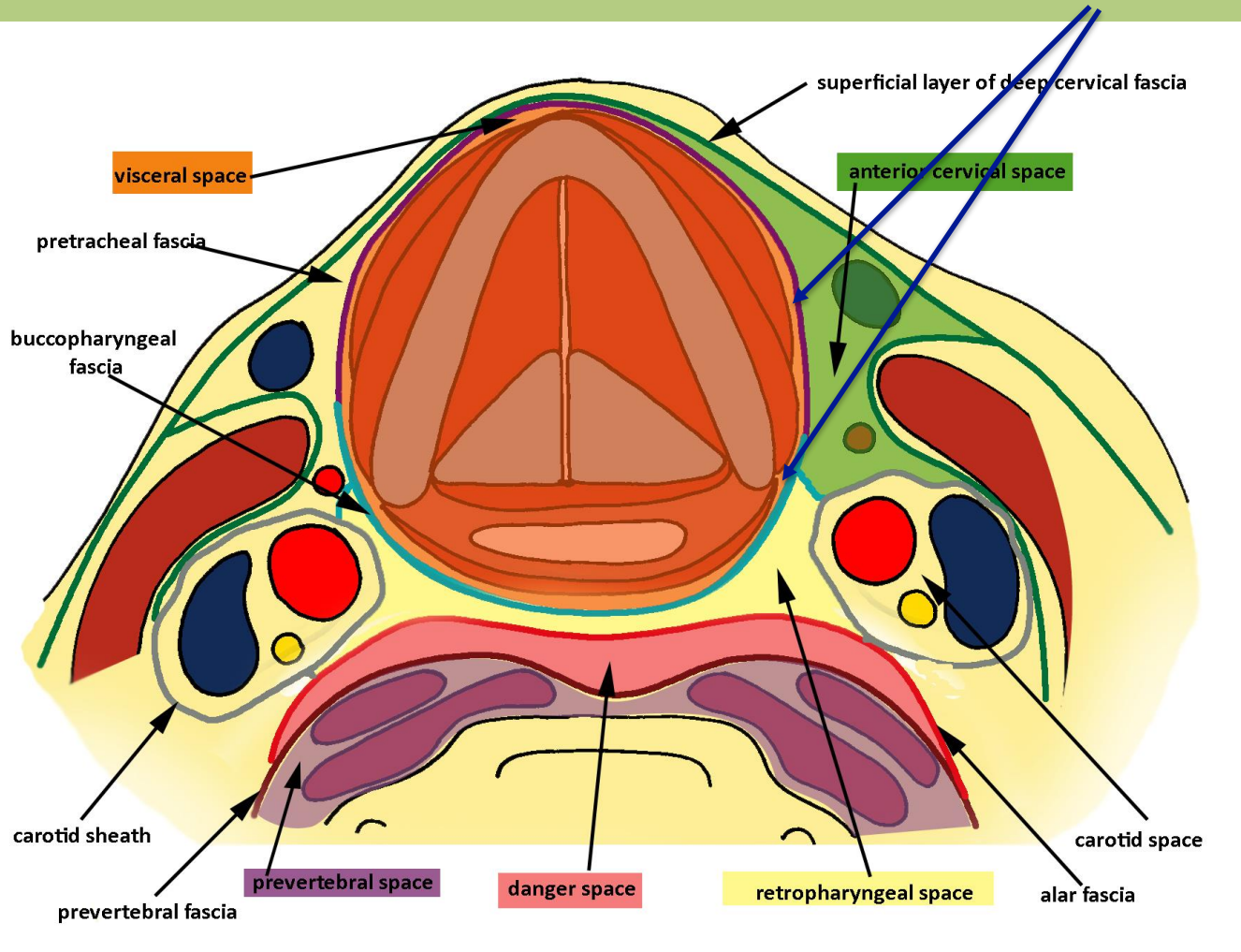
v. jugularis interna

a. carotis communis

Deep neck, posterior

Garat körüli térségek

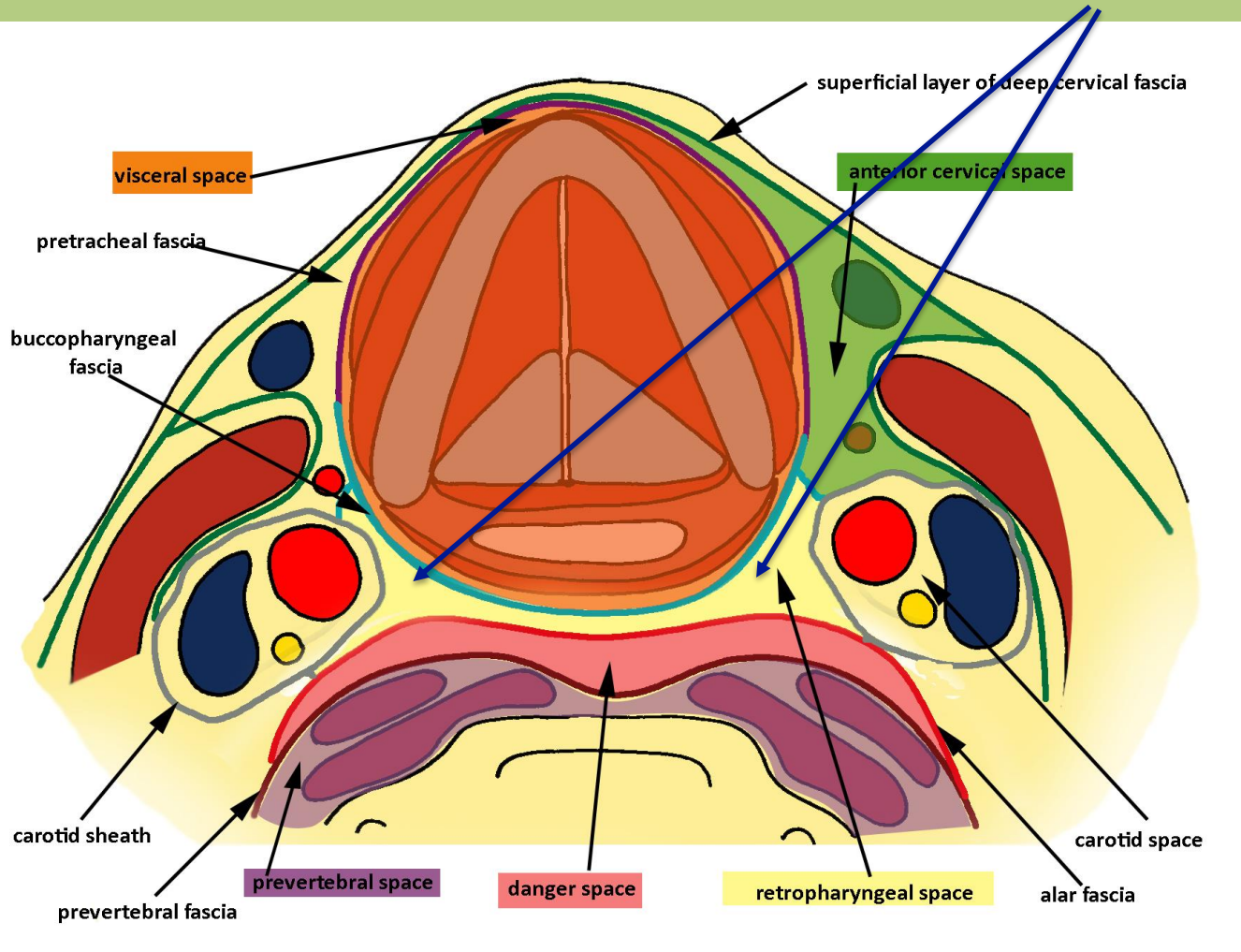
spatium parapharyngeum



A garat mellett és a processus styloideusról eredő izmok előtt helyezkedik el és a *trigonum submandibulare*ba vezet.

Garat körüli térségek

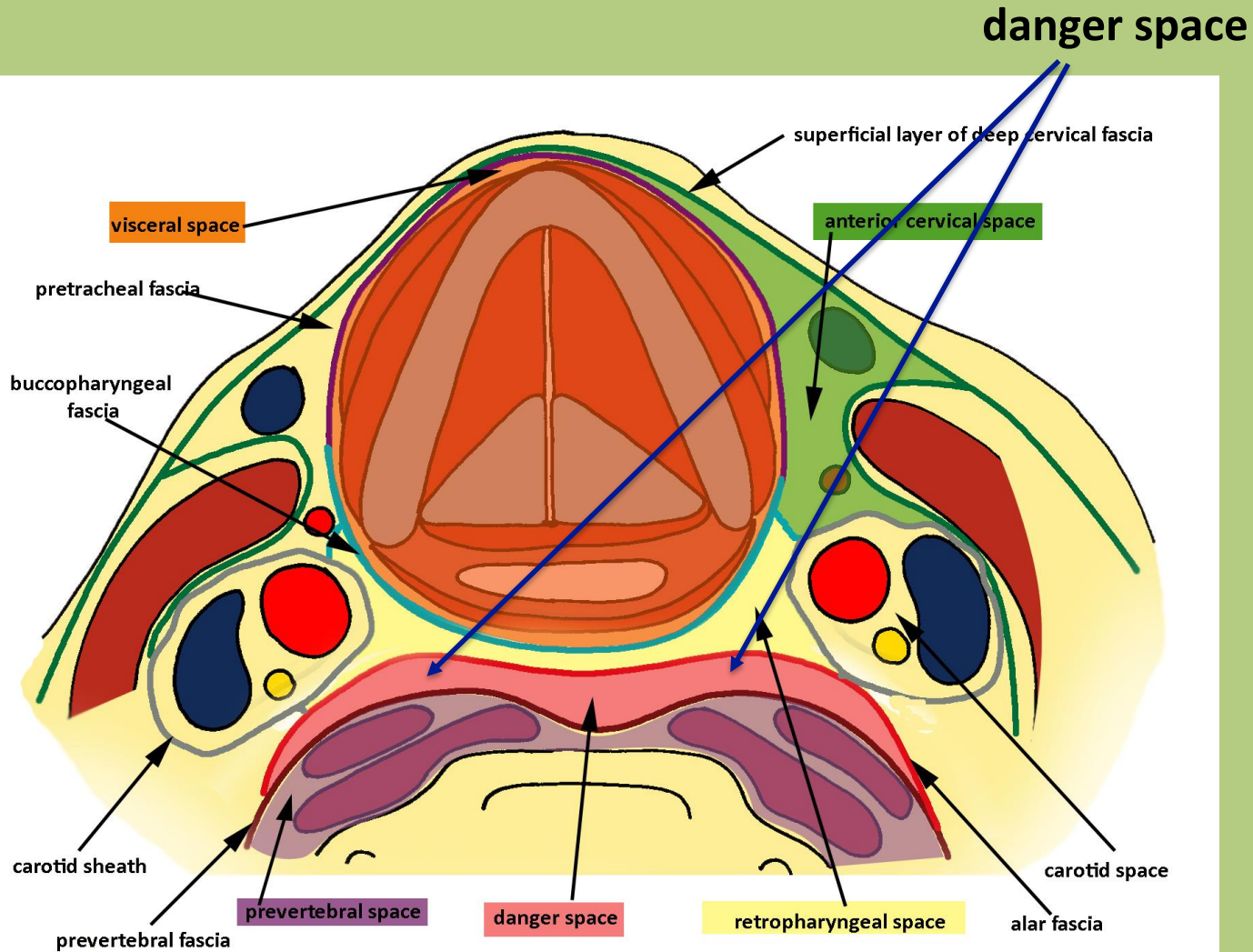
spatium retropharyngeum



A fascia **buccopharyngea** (lamina pretrachealis) és a **fascia alaris** között elhelyezkedő potenciális térség retropharyngealis nyirokcsomókkal.

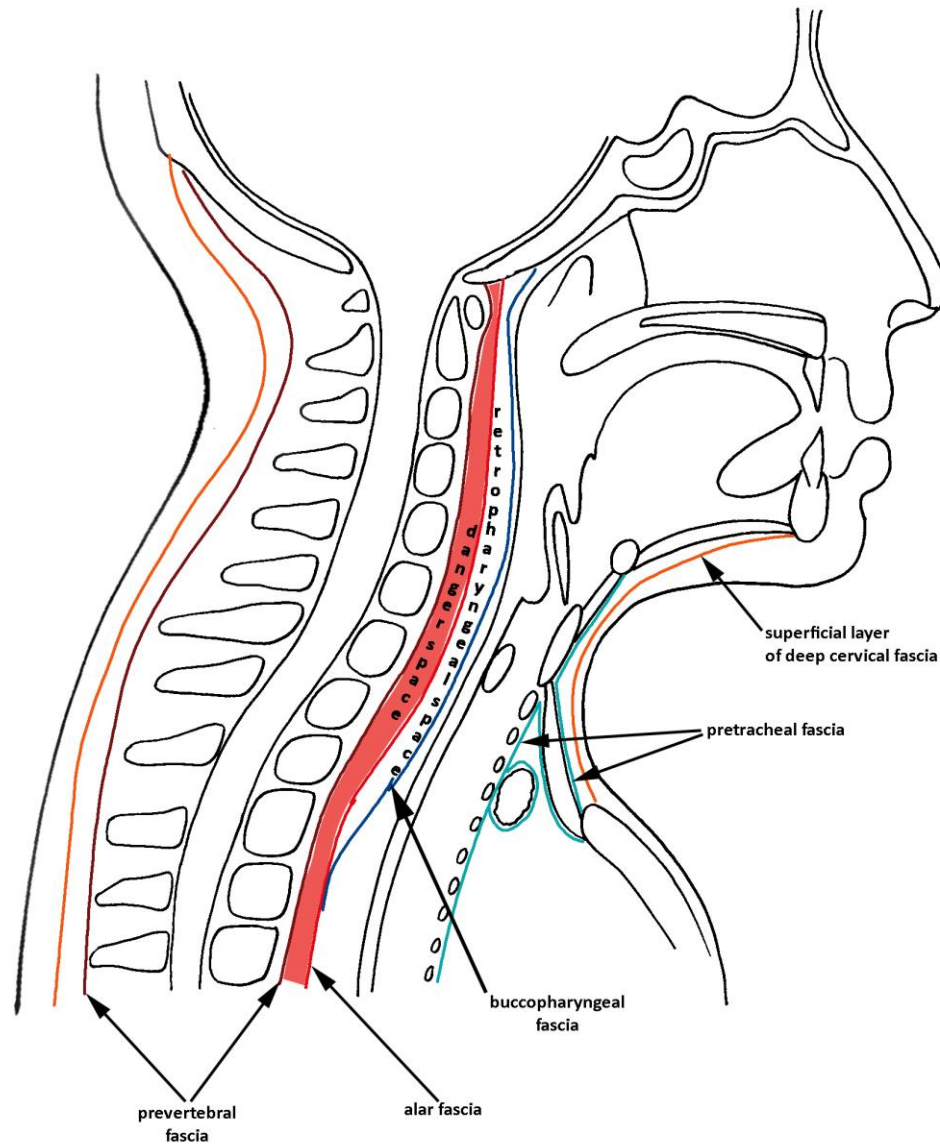
A két lemez Th4 magasságában összenő.

Garat körüli térségek



A fascia alaris és a lamina prevertebralis között elhelyezkedő térség, amely a *mediastinum posteriusba* vezet.

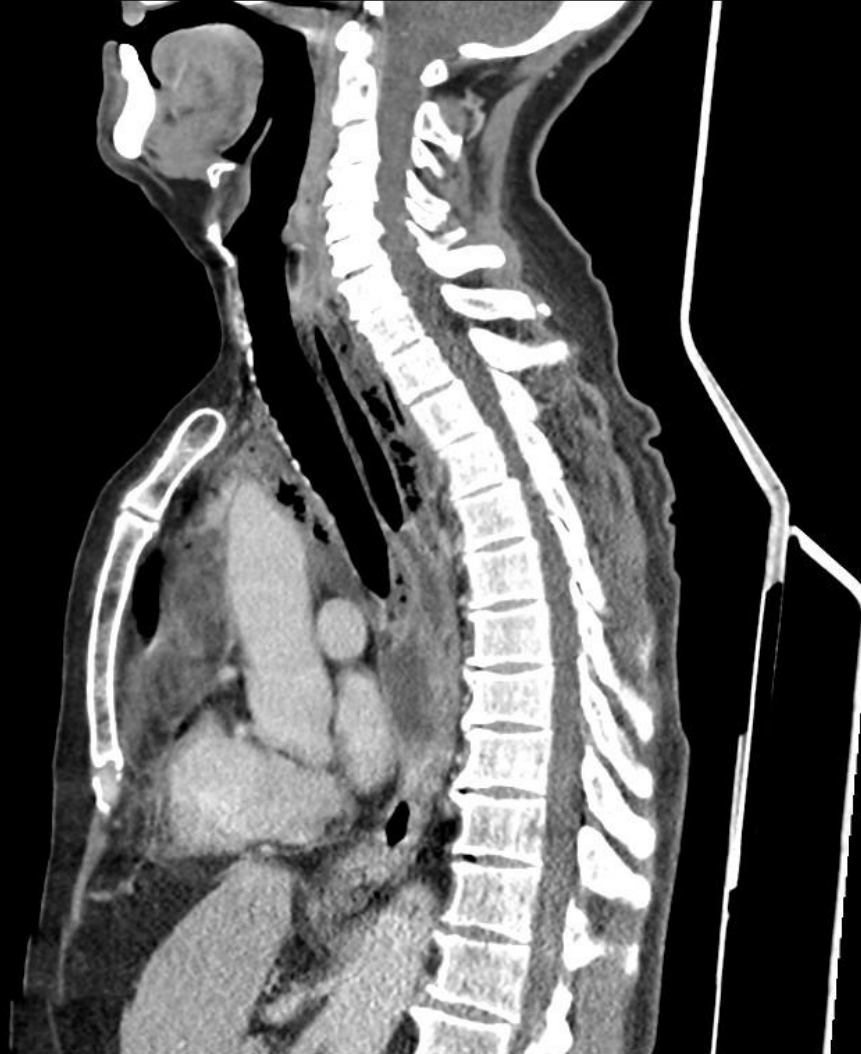Garat körüli térségek



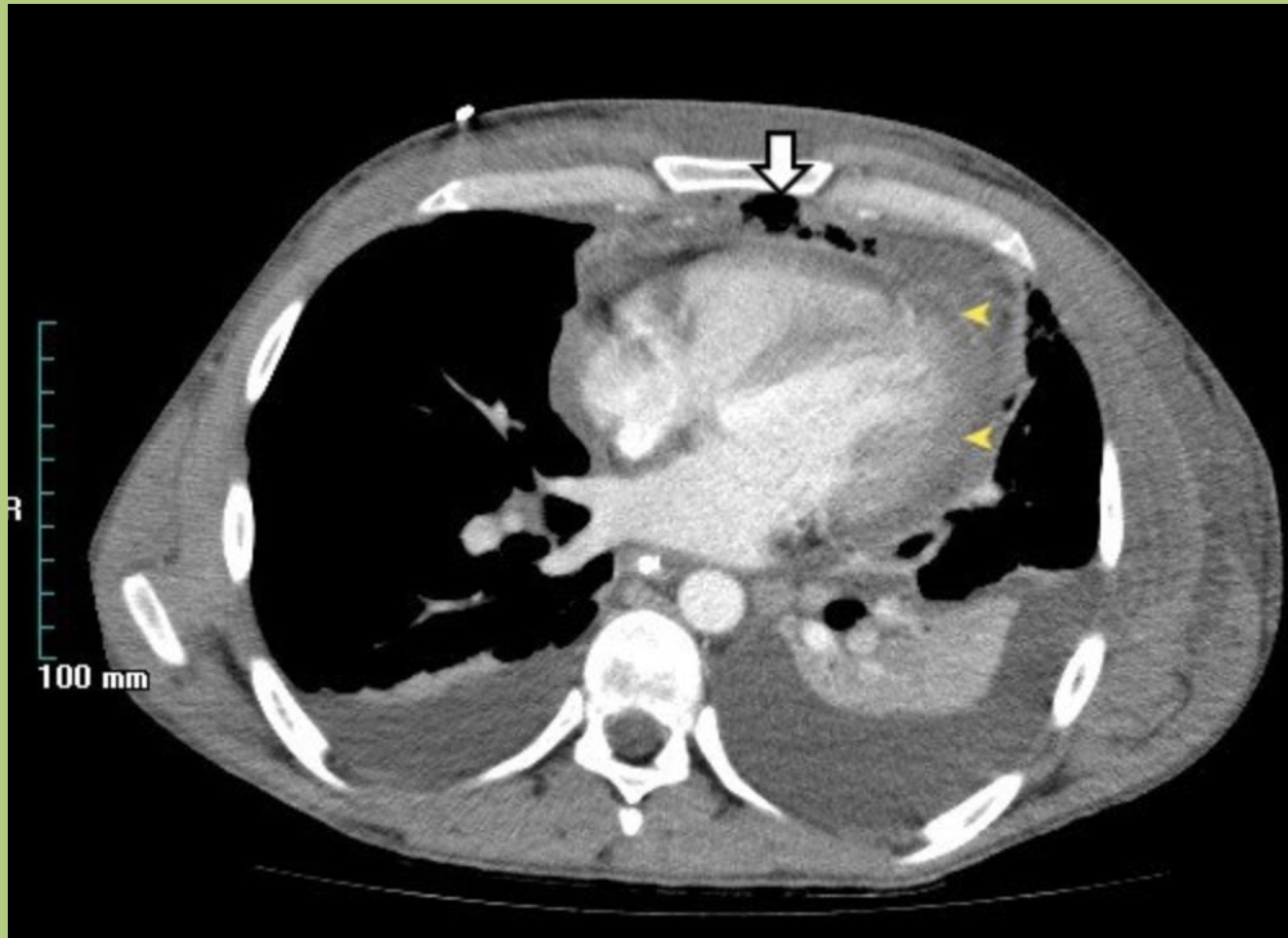
The prevertebral fascia consists two layers: prevertebral and alar fascia

The alar fascia fuses with the buccopharyngeal fascia at level of the 4th thoracic vertebra.

Descendáló mediastinitis



Descendáló mediastinitis





You only get your tonsils out once.

Köszönöm a figyelmet!

- References:
- Drake: Gray's Anatomy for Students, 2nd ed.
 - Standring: Gray's Anatomy, 39th ed.
 - Radiopaedia.org
 - Thieme Atlas of Anatomy, Head, Neck and Neuroanatomy, 2nd ed.
 - dr. Halász Vanda rajzolt képei a nyaki térségekről
 - studyblue.com
 - BlueLink.com