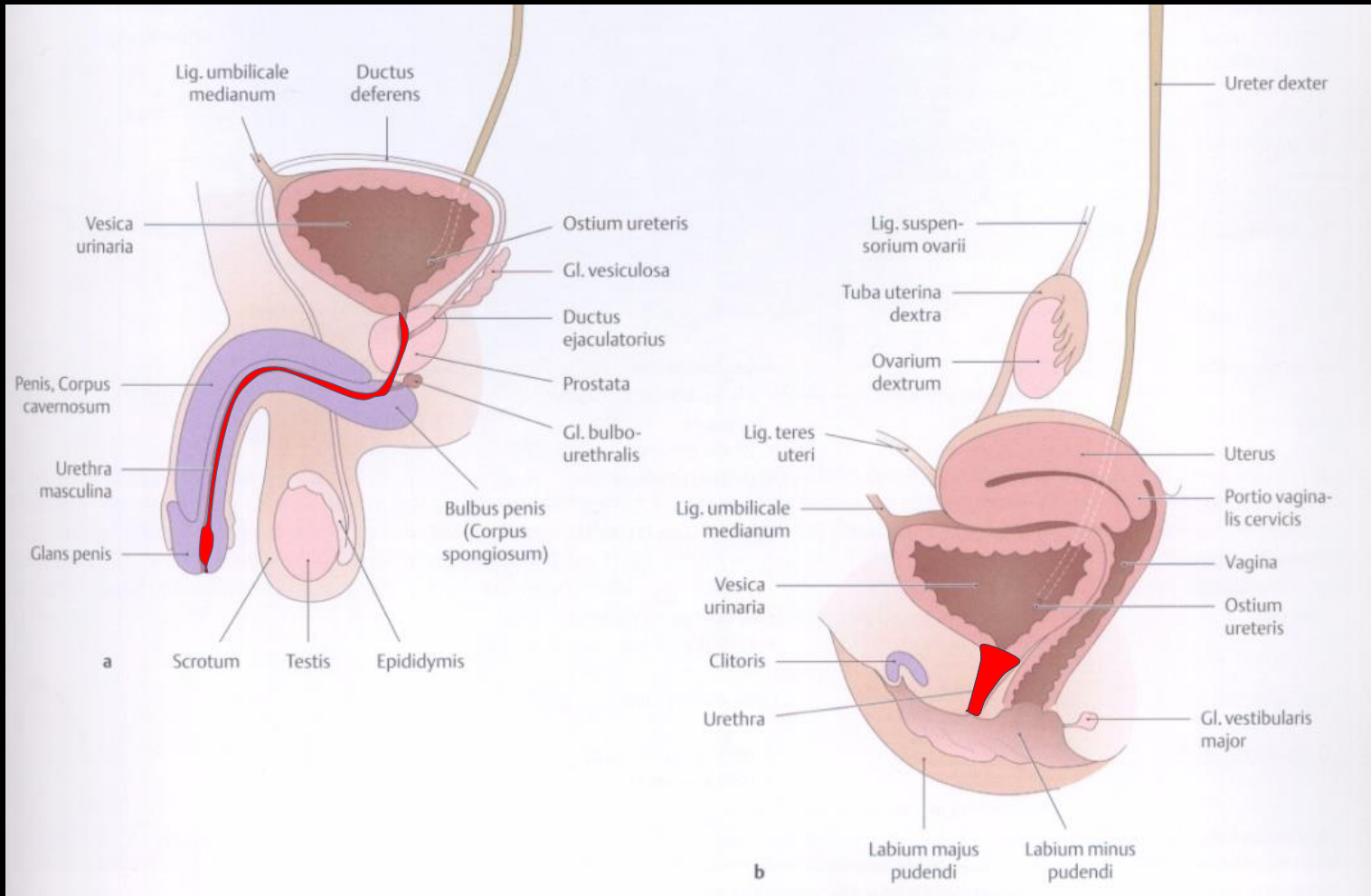
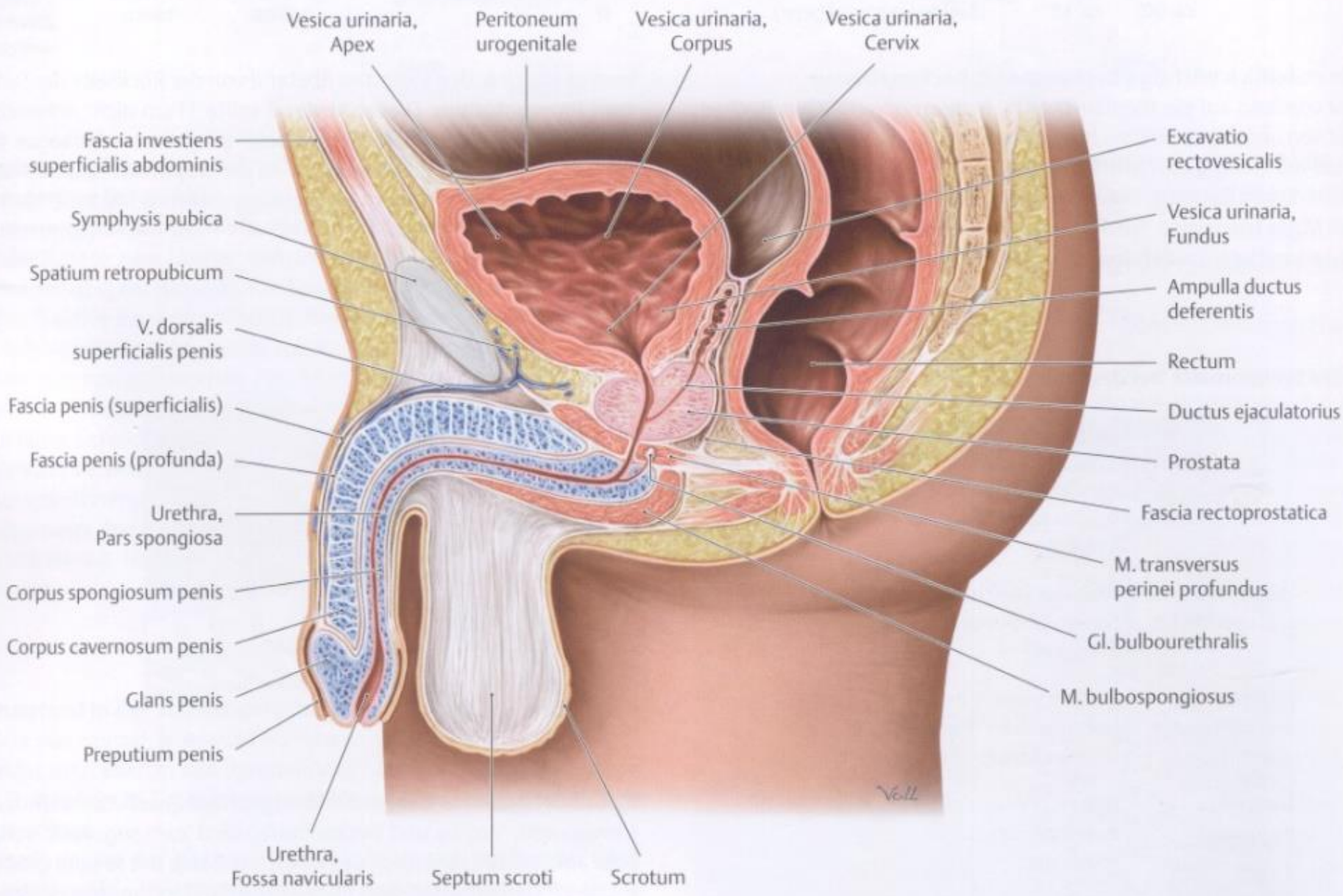


Penis és a férfi húgycső

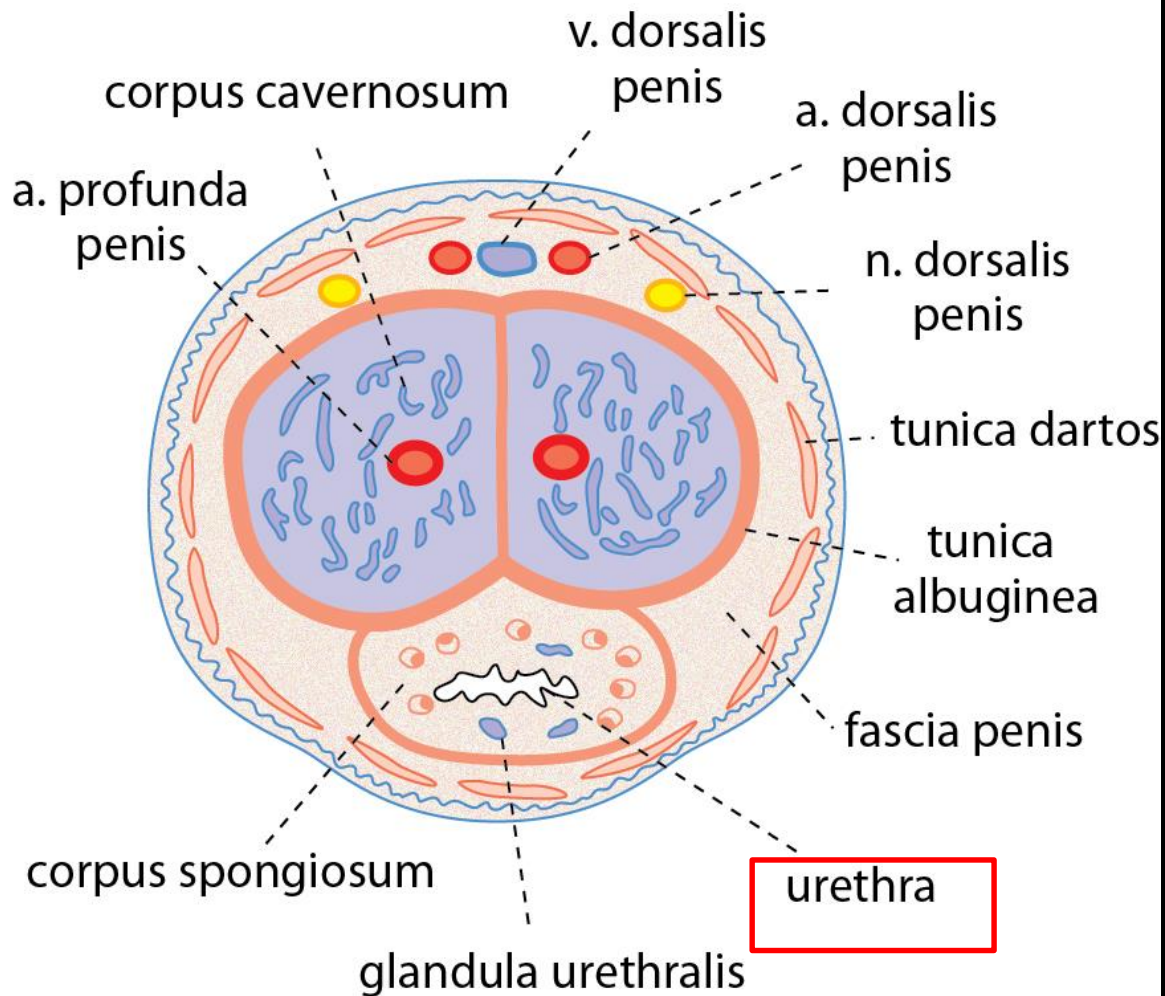
Barna János

Urethra

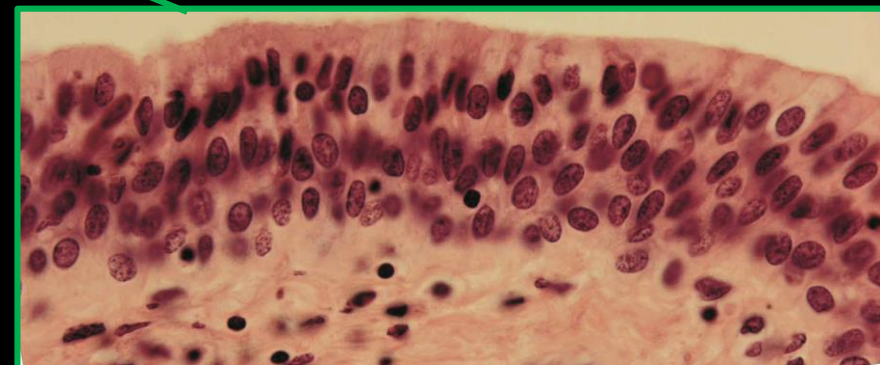
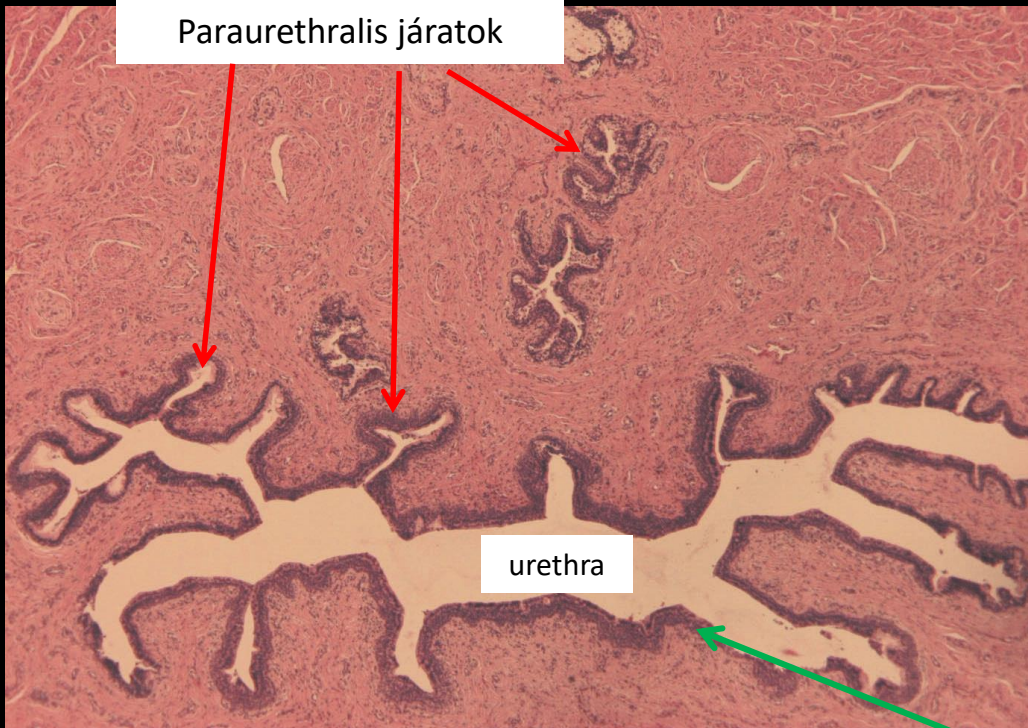




Pars spongiosa urethrae

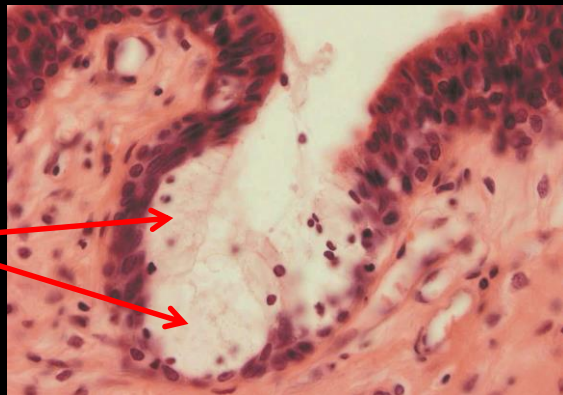

Pars spongiosa urethrae

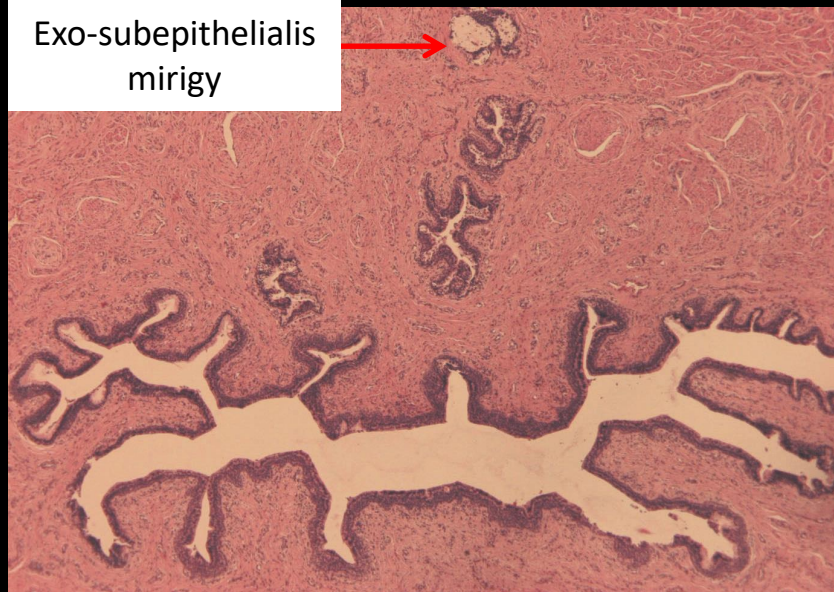


A húgycső endoepithelialis és exoepithelialis (paraurethralis - Littré) mirigyei

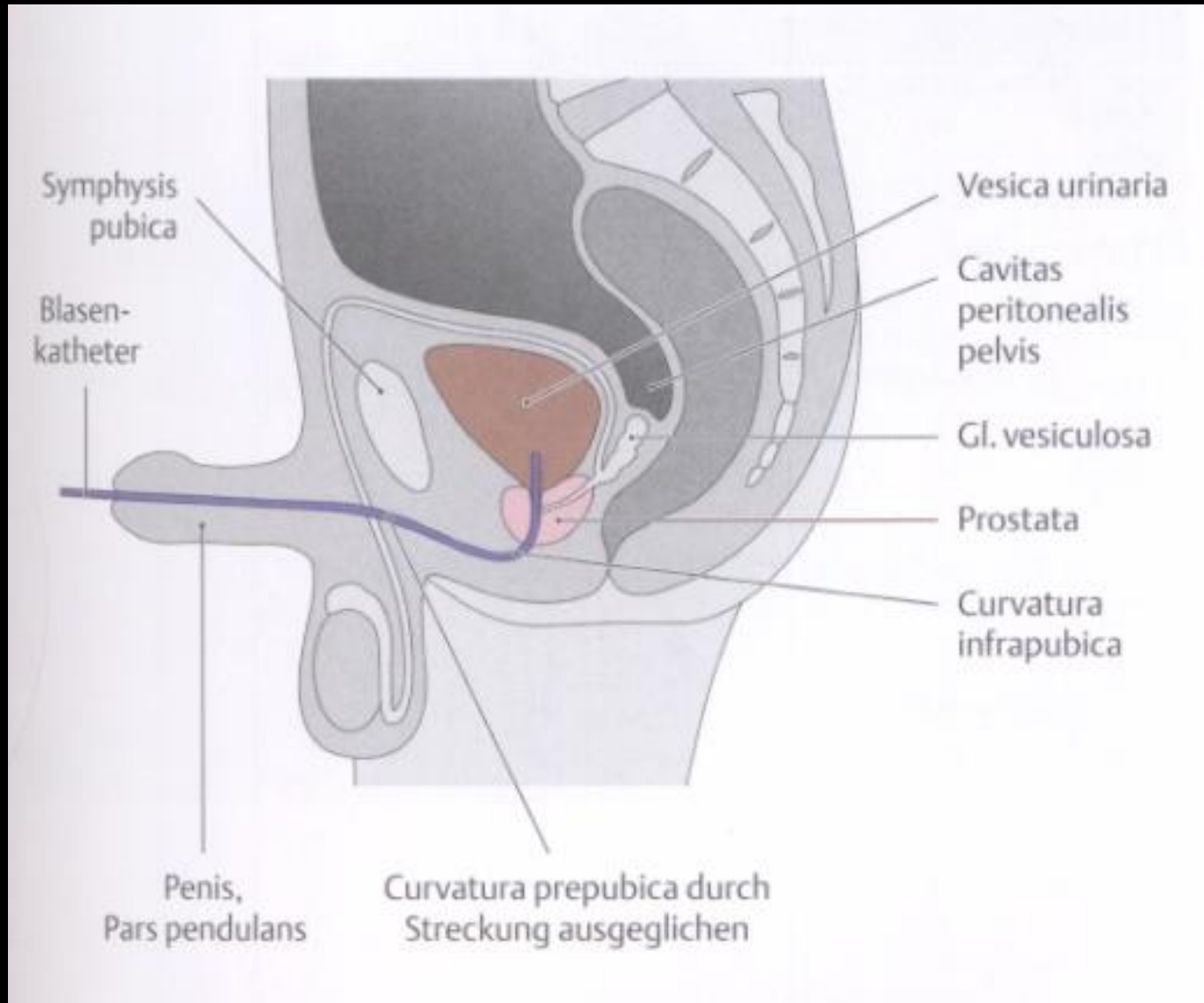
Endo/intraepithelialis mirigyek



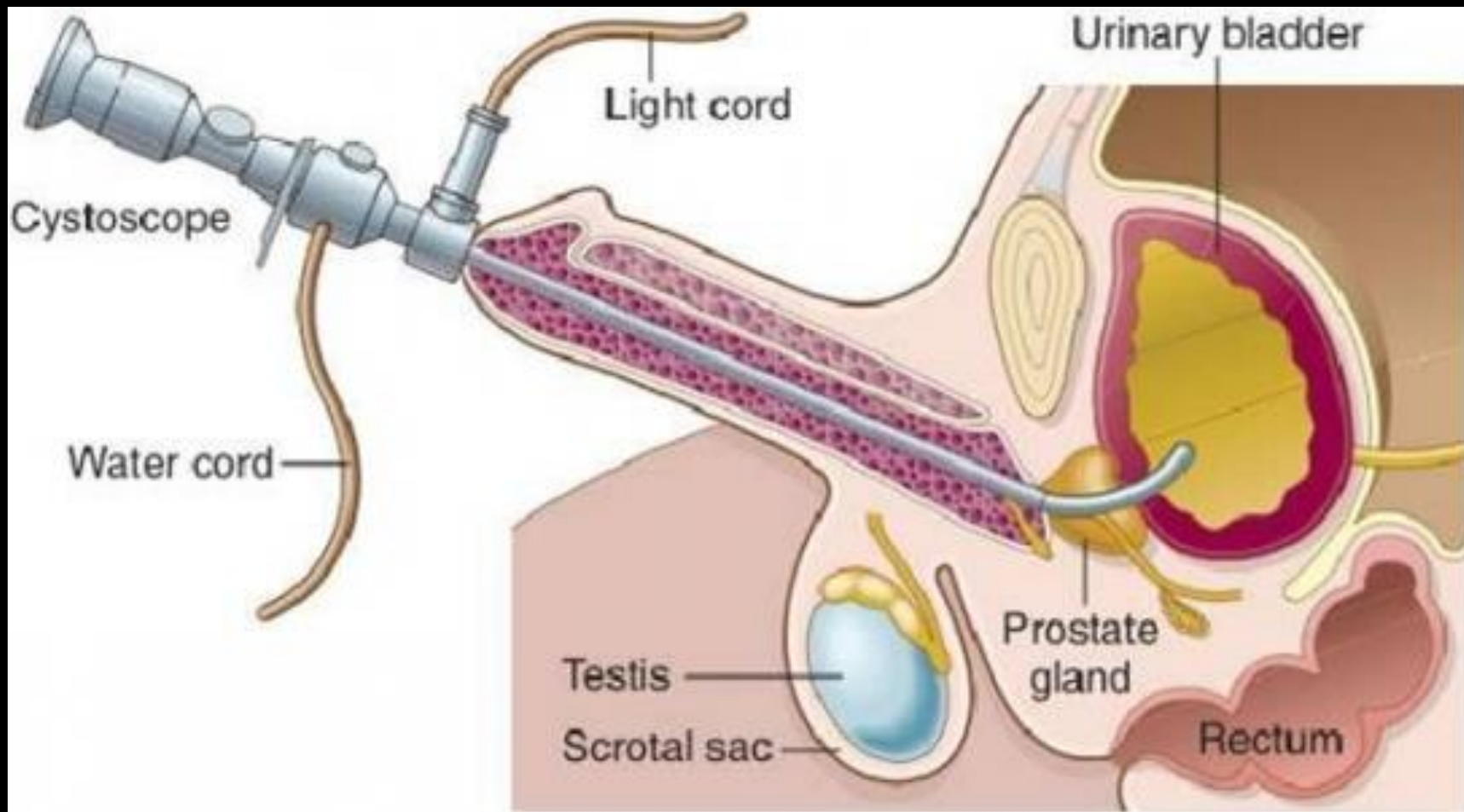
Exo-subepithelialis mirigy



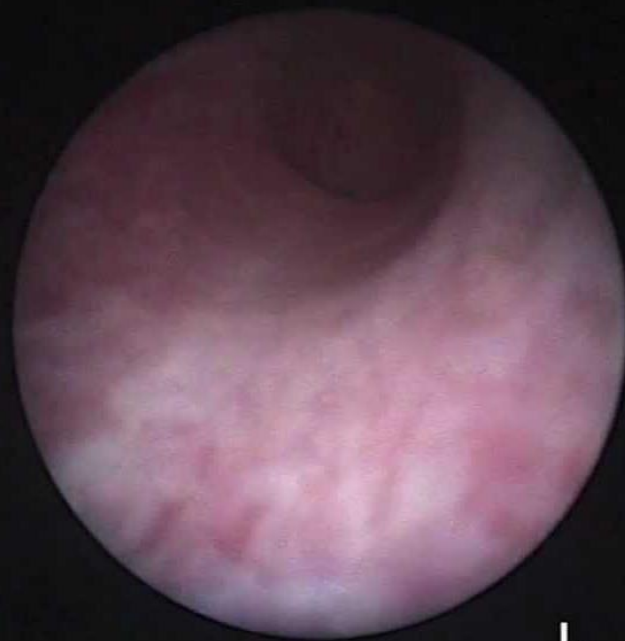Hólyagkatéterezés



Citoszkópia (hólyagtükrözés)

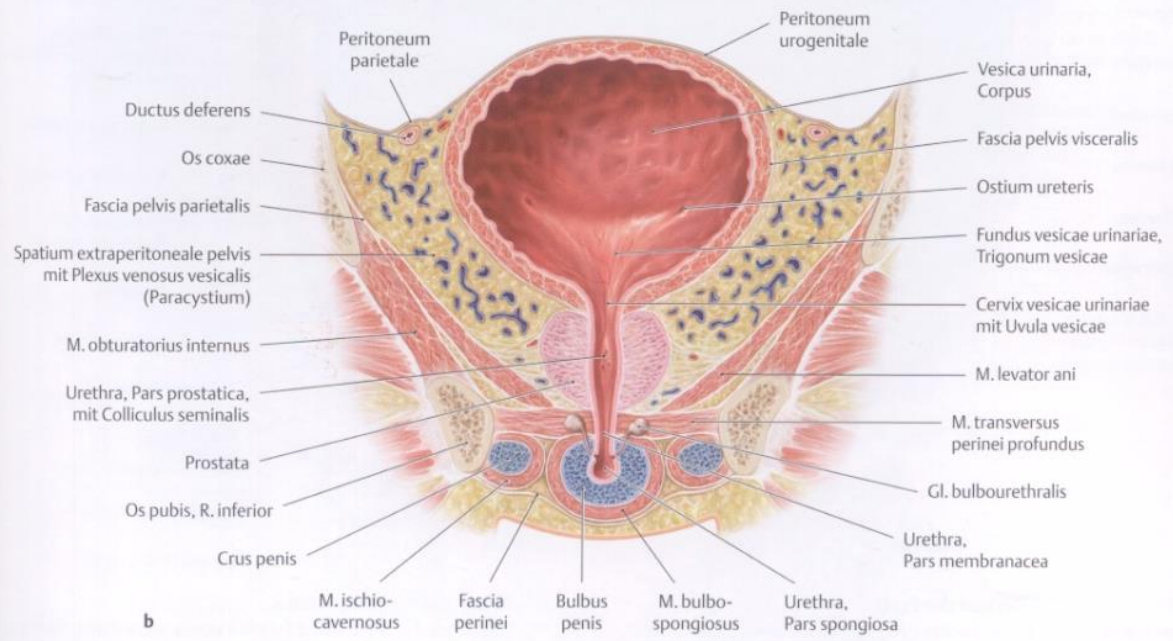
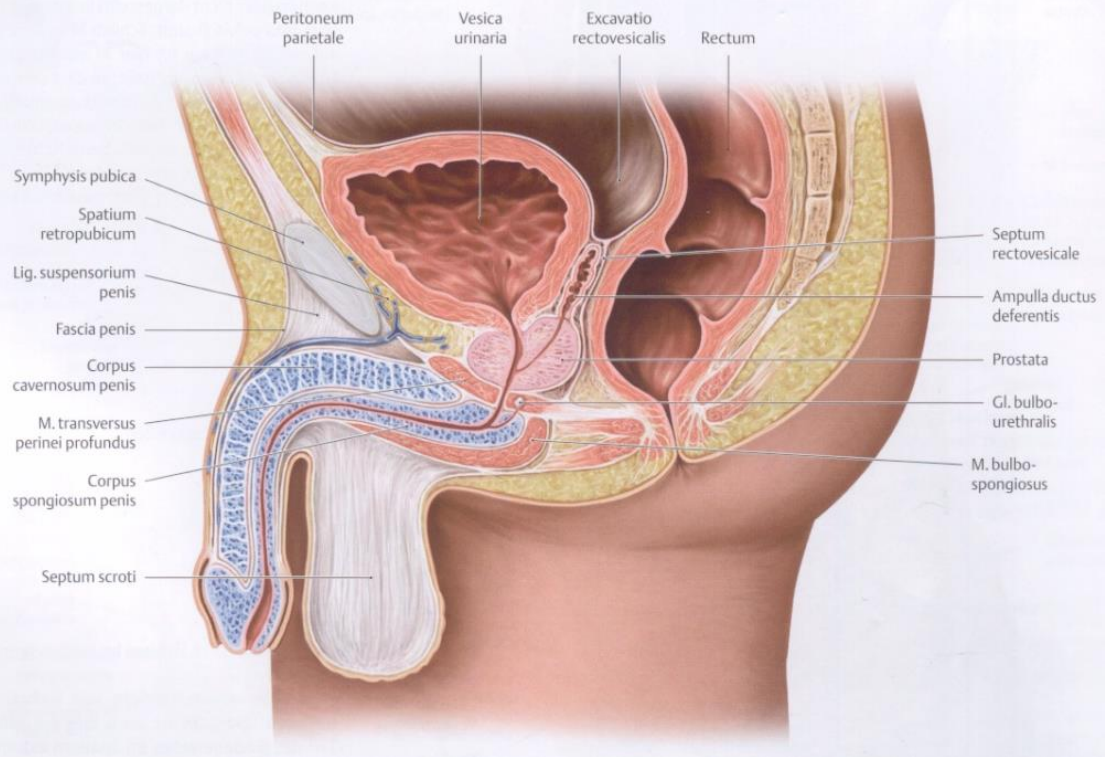


Hólyagkövek

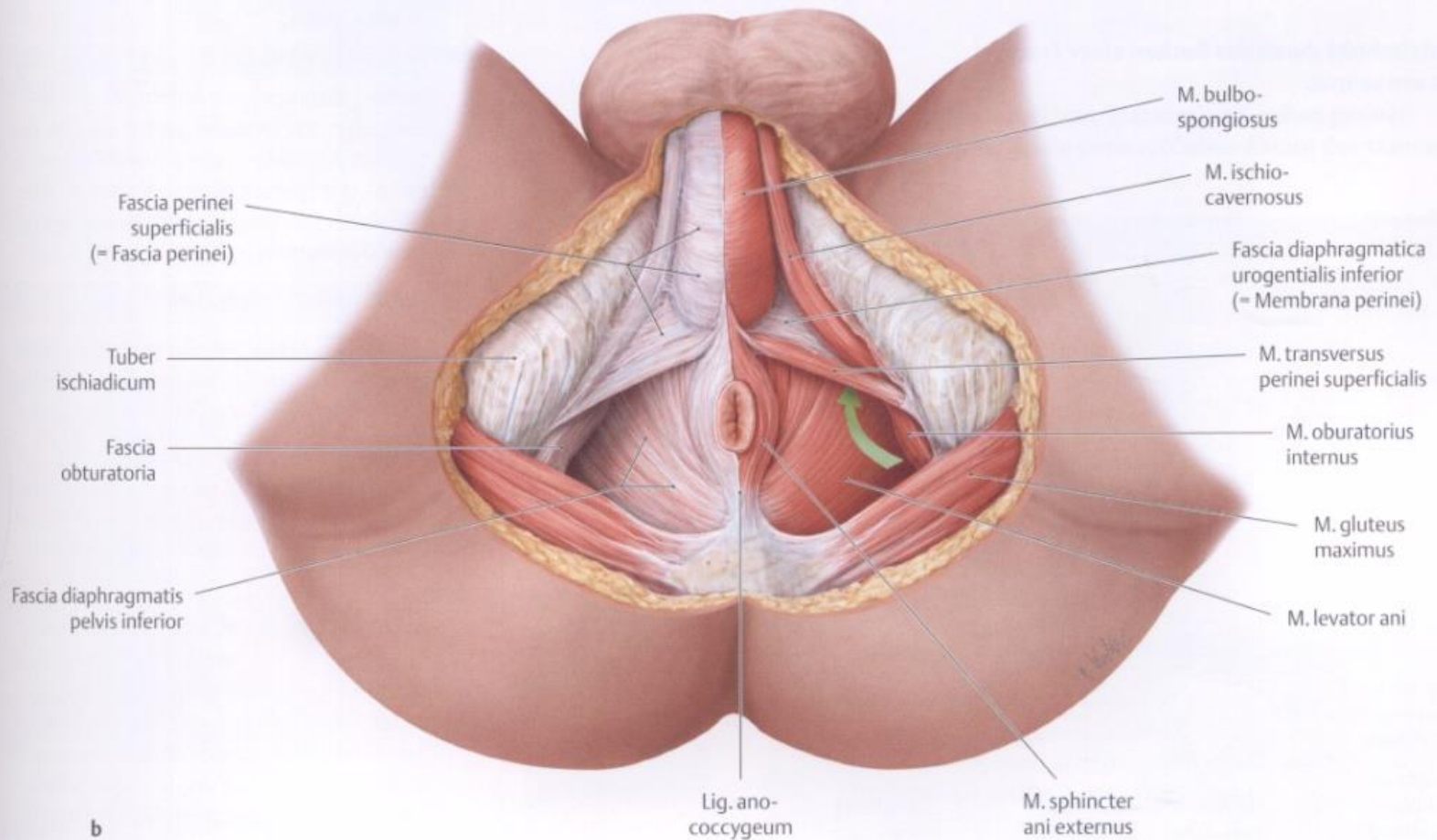


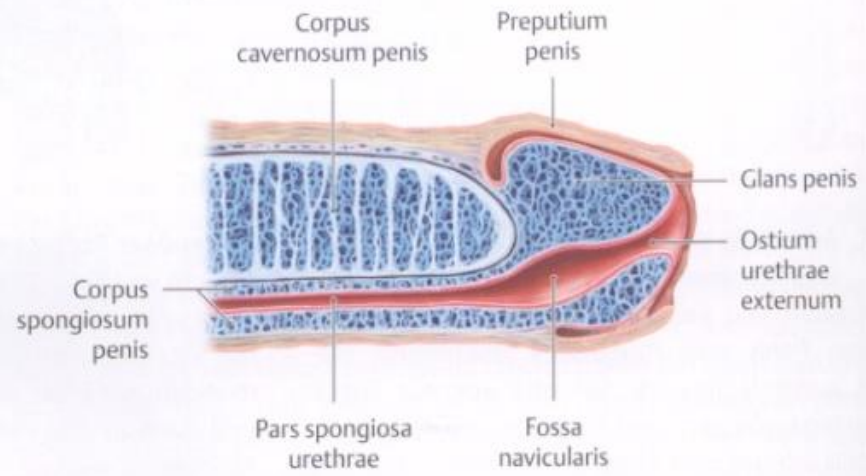
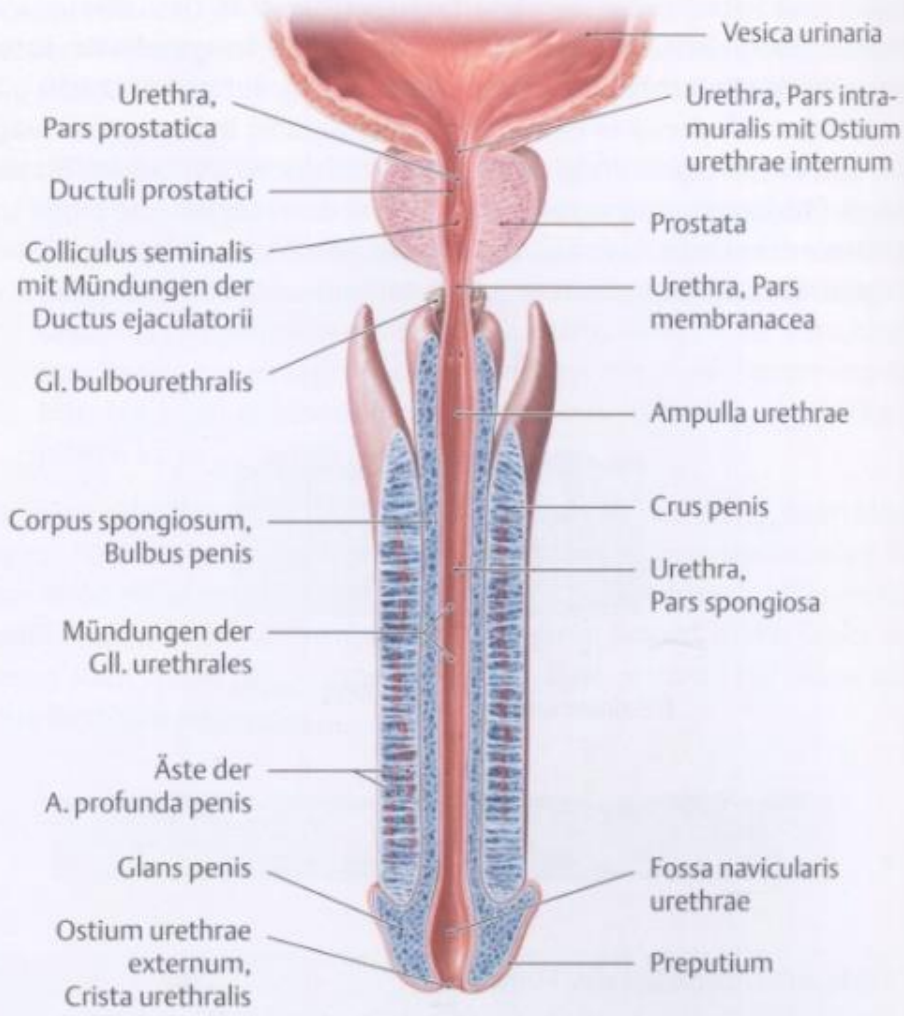
L

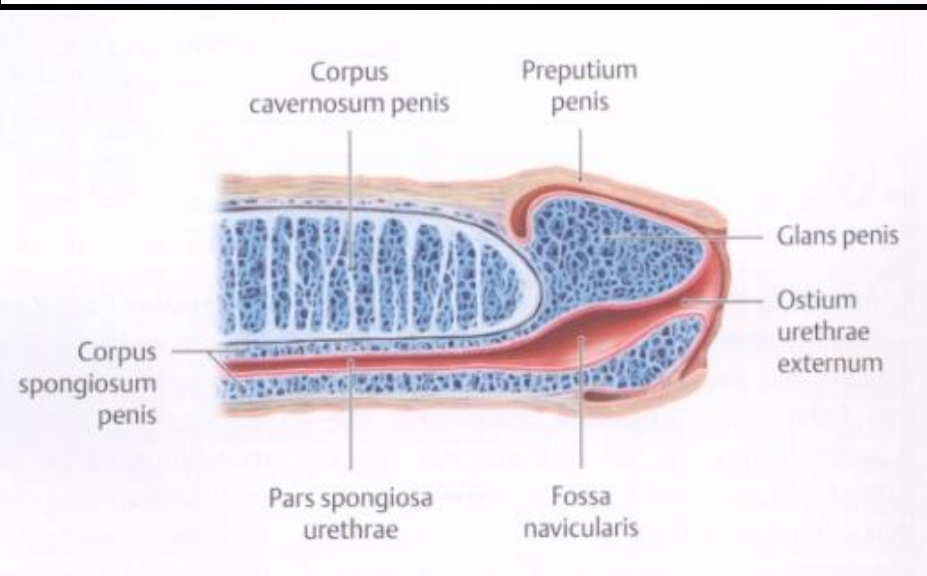
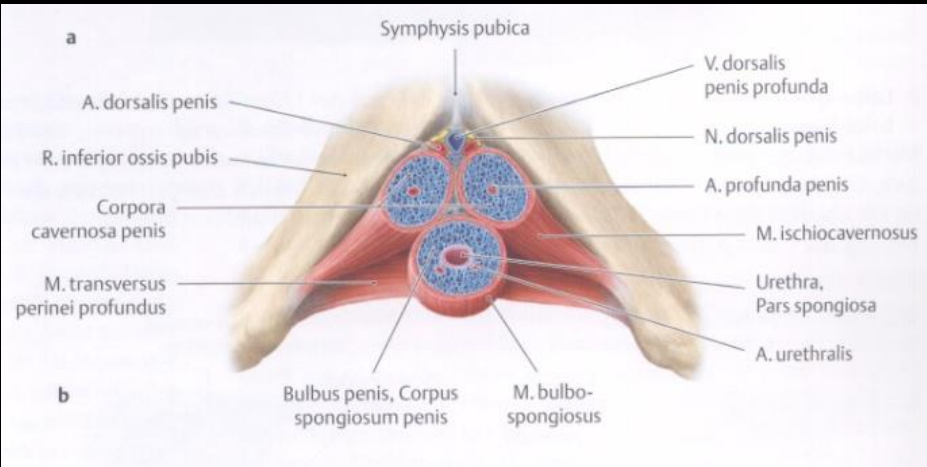
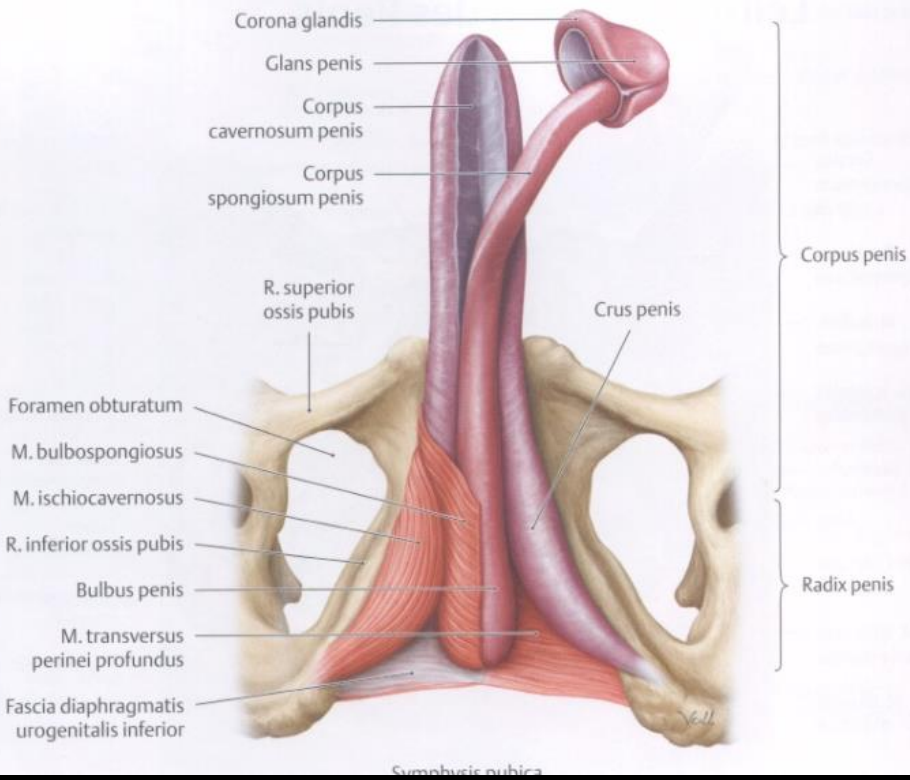


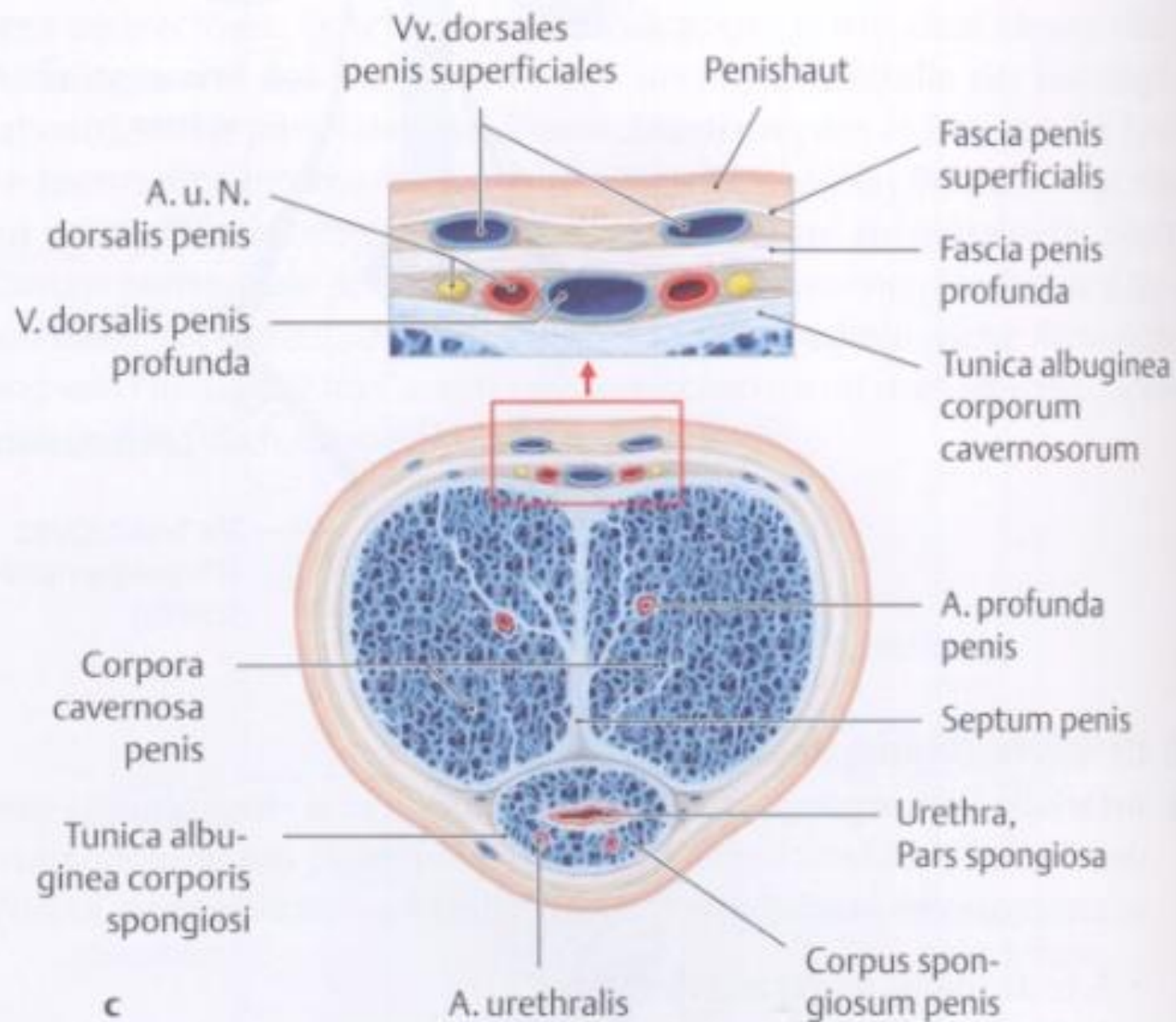


Radix penis



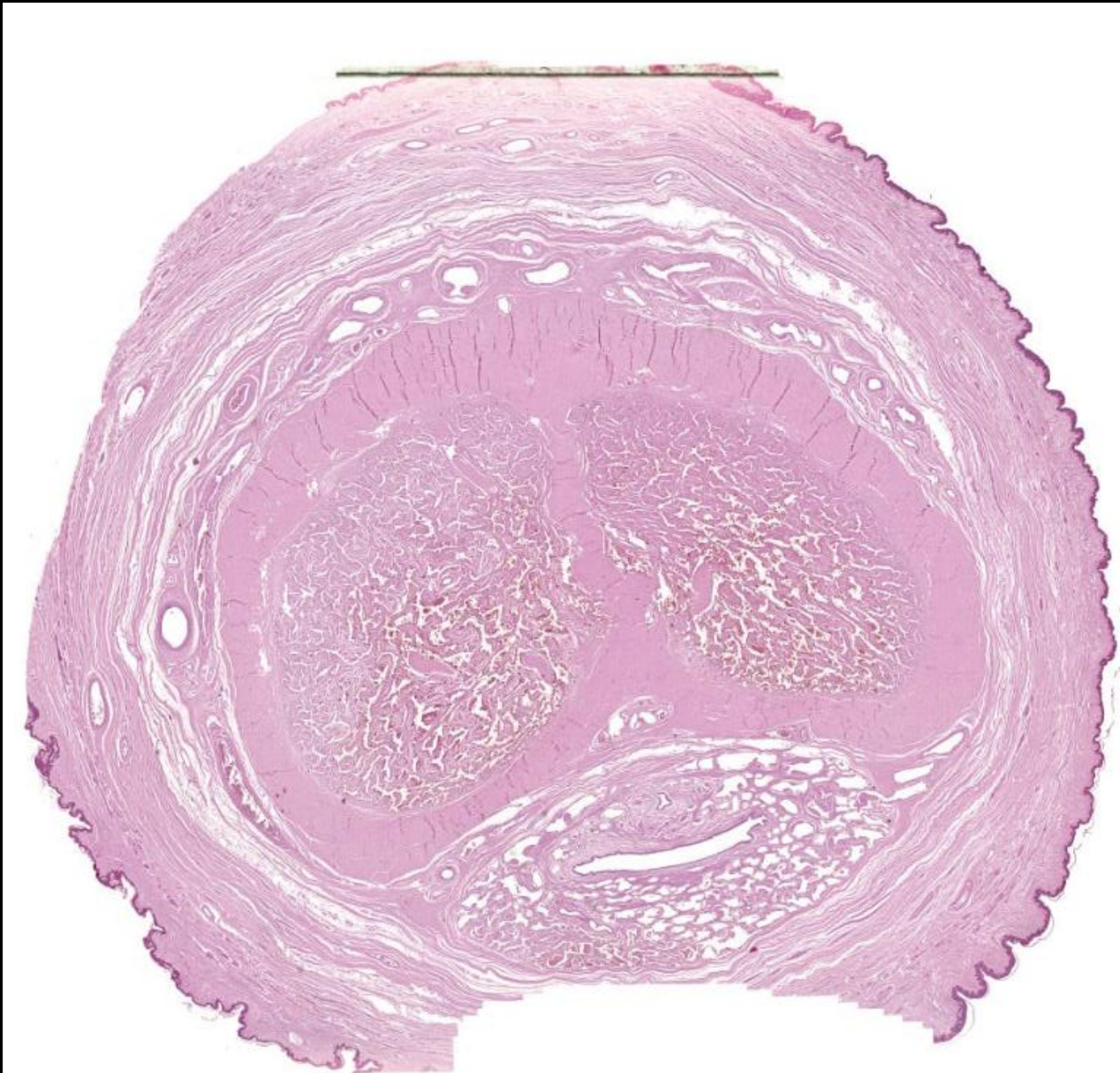



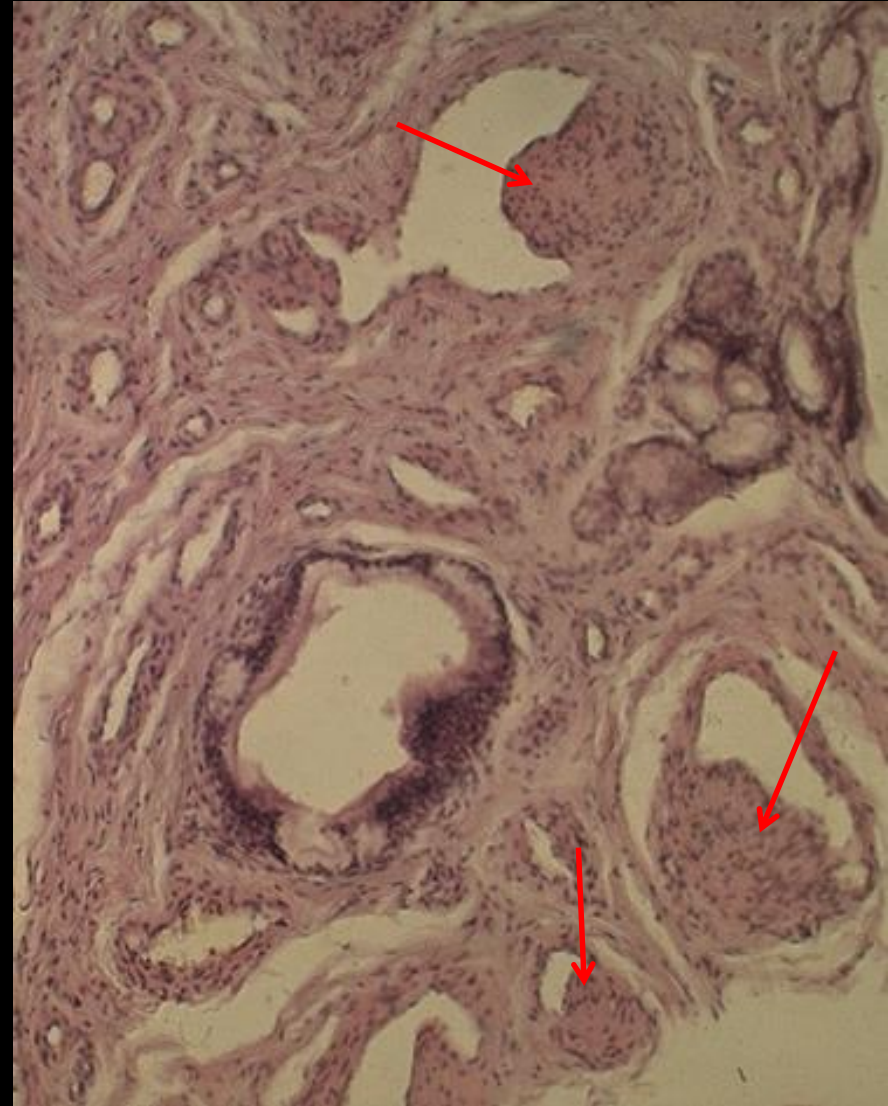
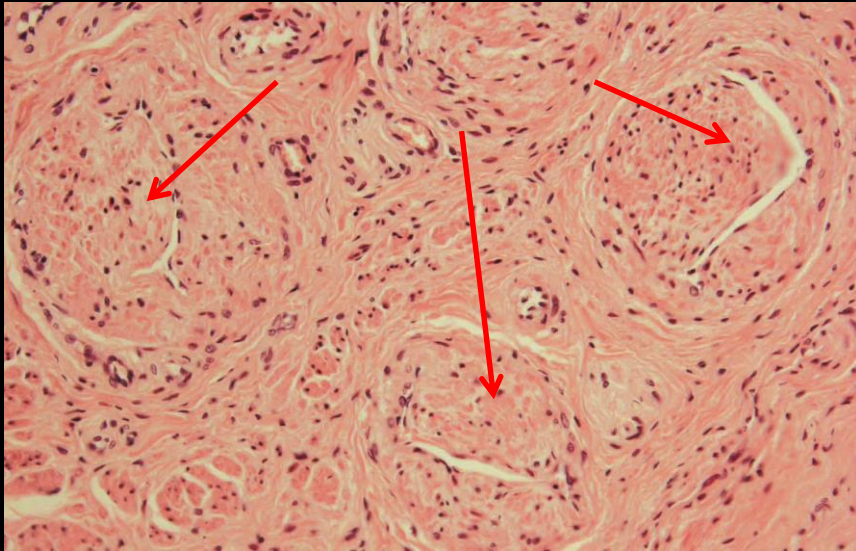


c

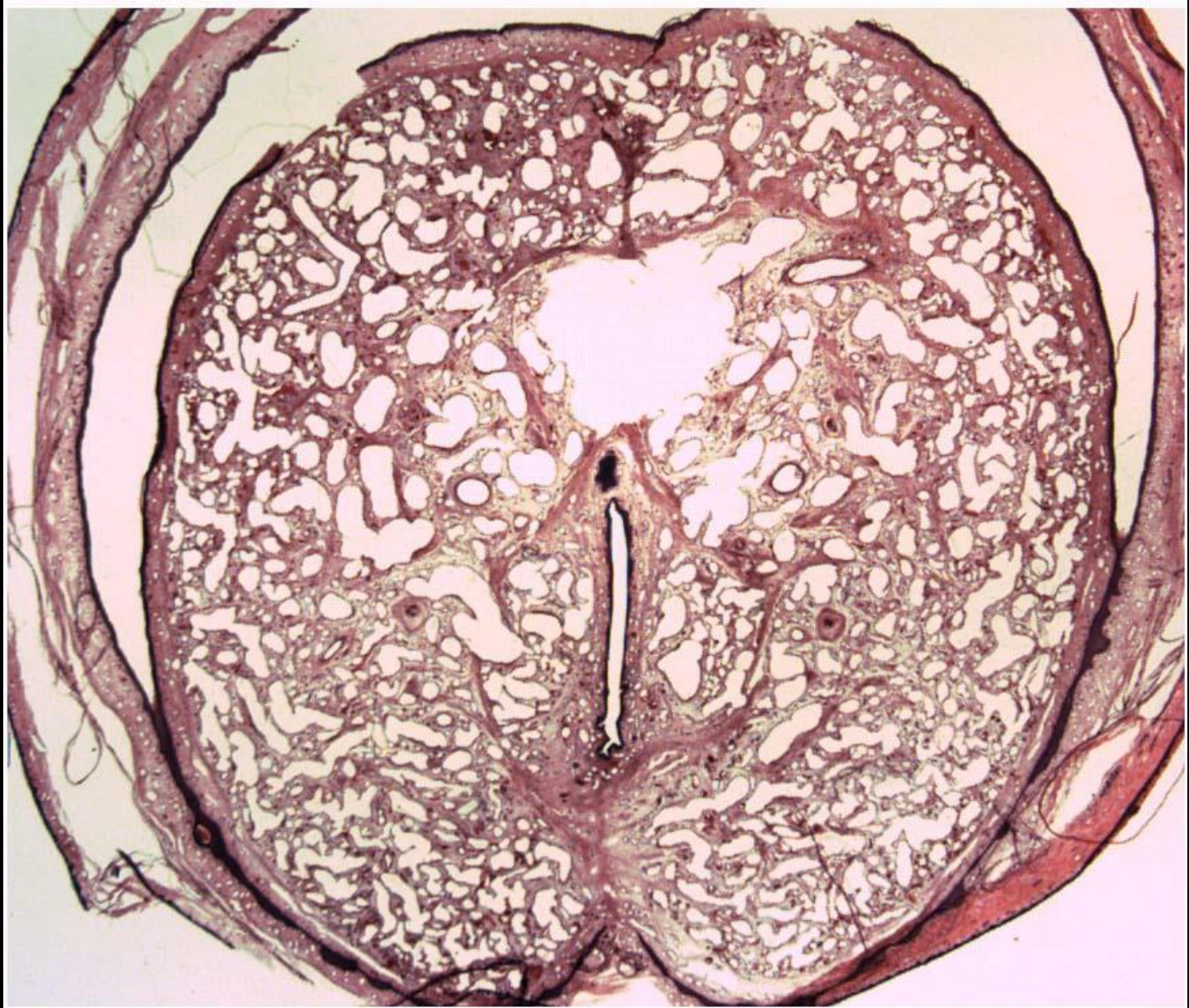
Corpus penis

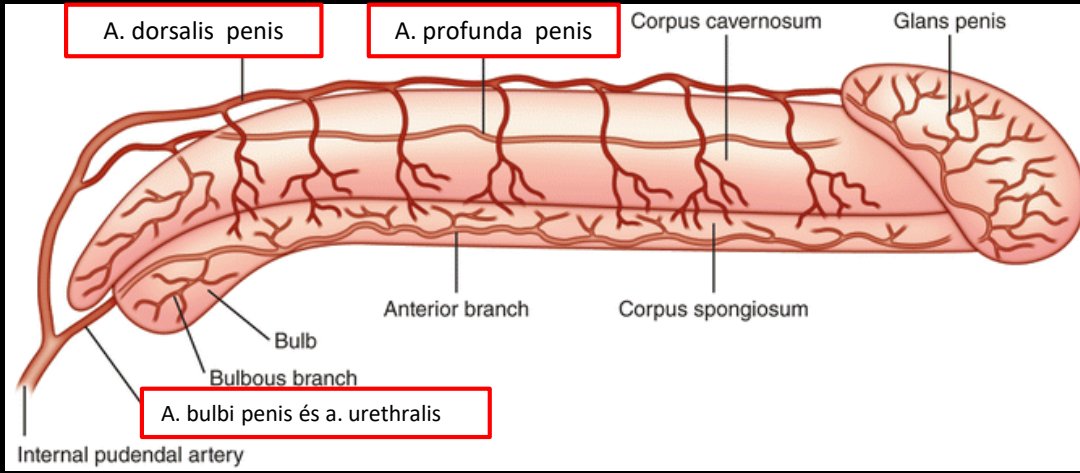


Ebner –féle intimapárnák

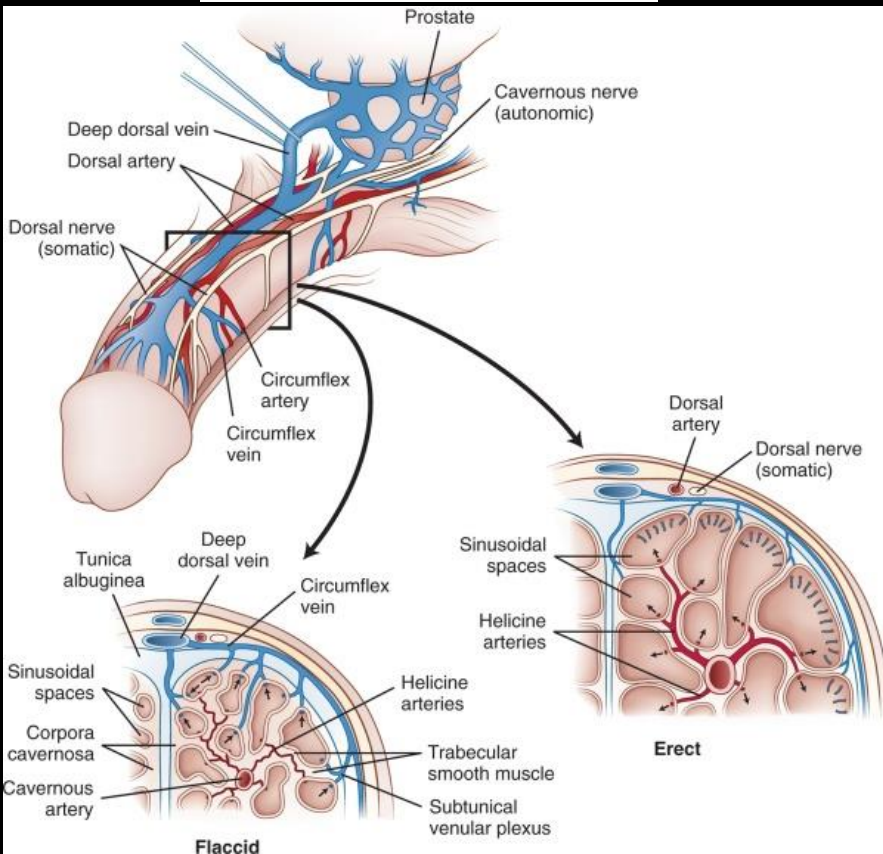


Glans penis

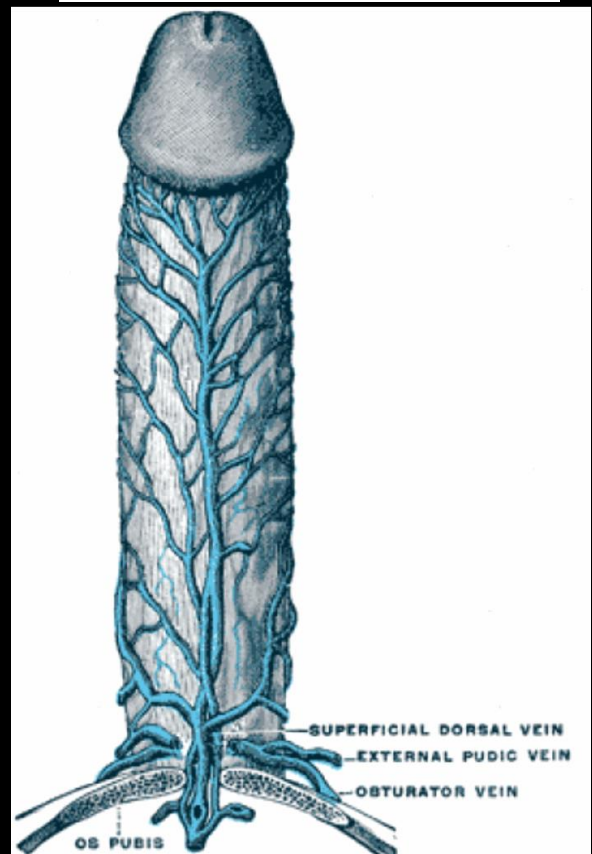




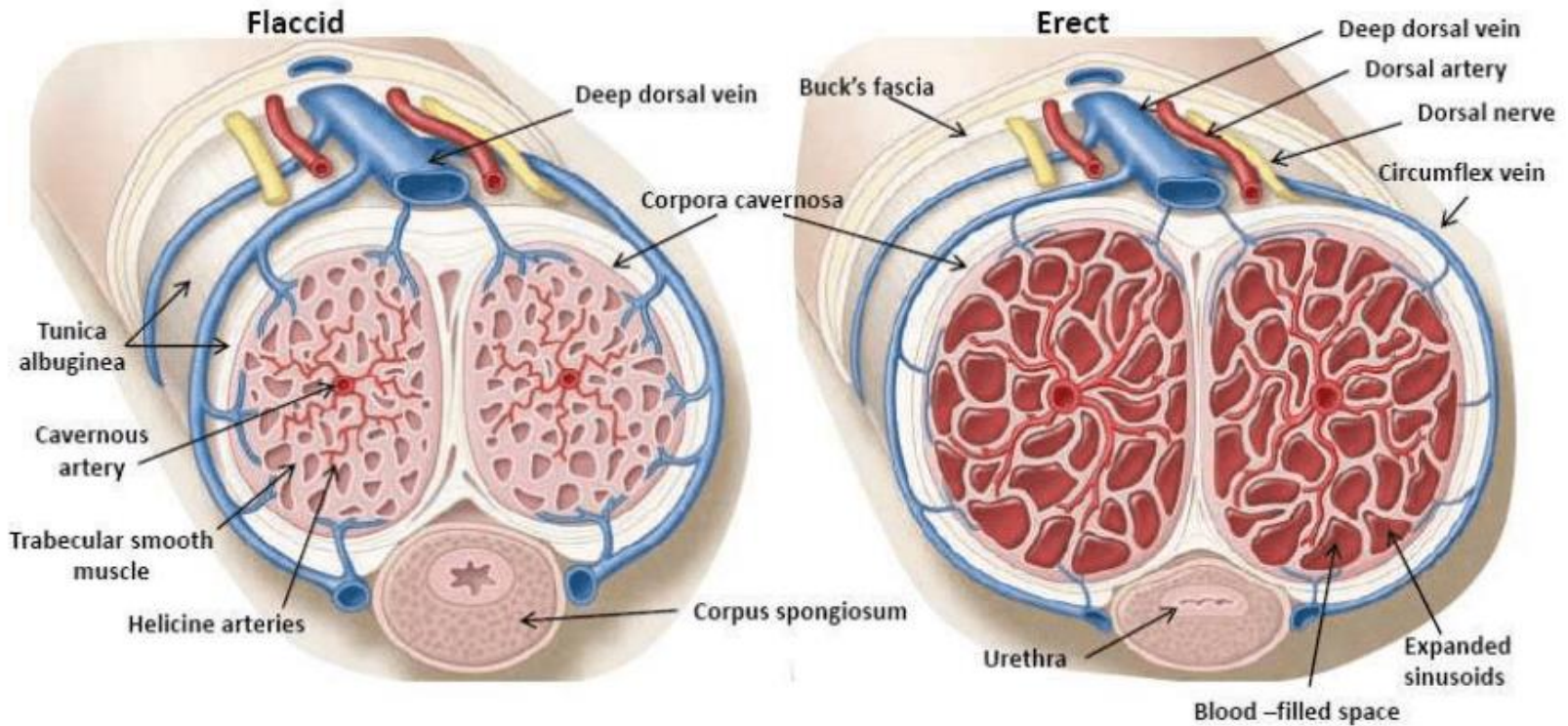
V. dorsalis profunda penis



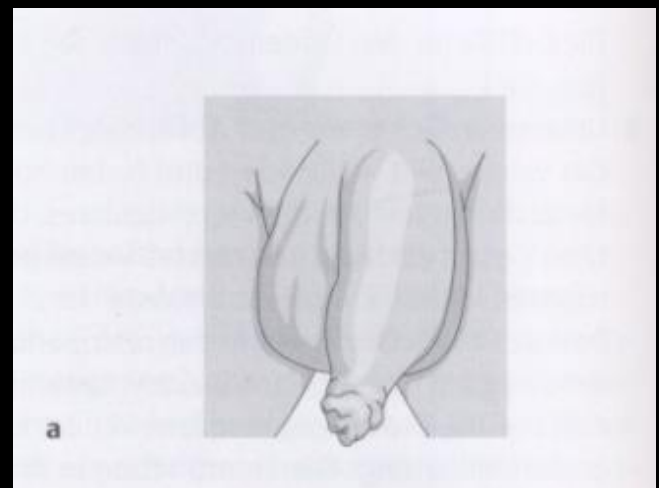
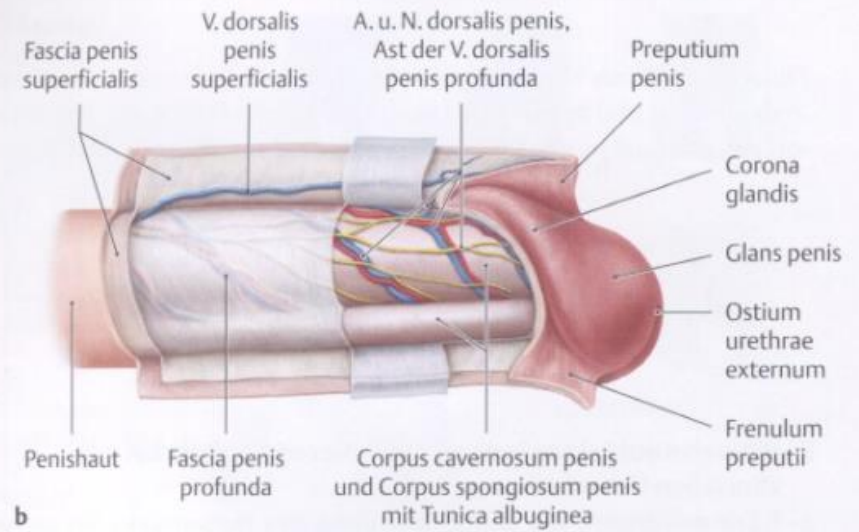
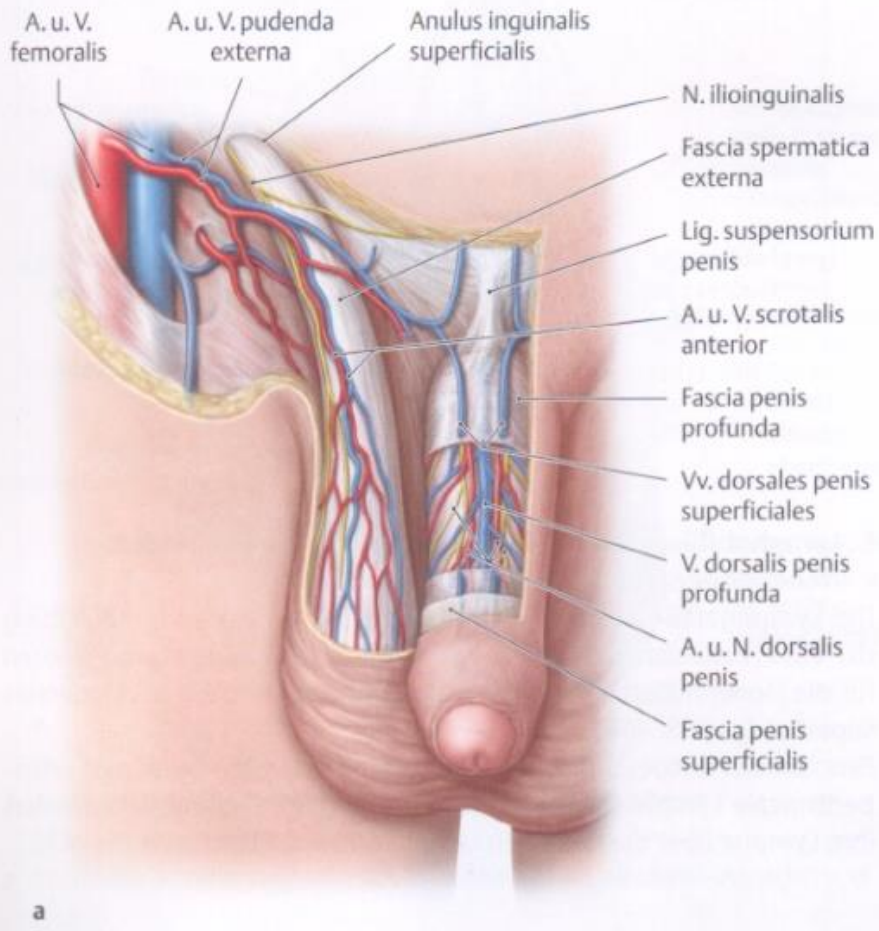
V. dorsalis superficialis penis



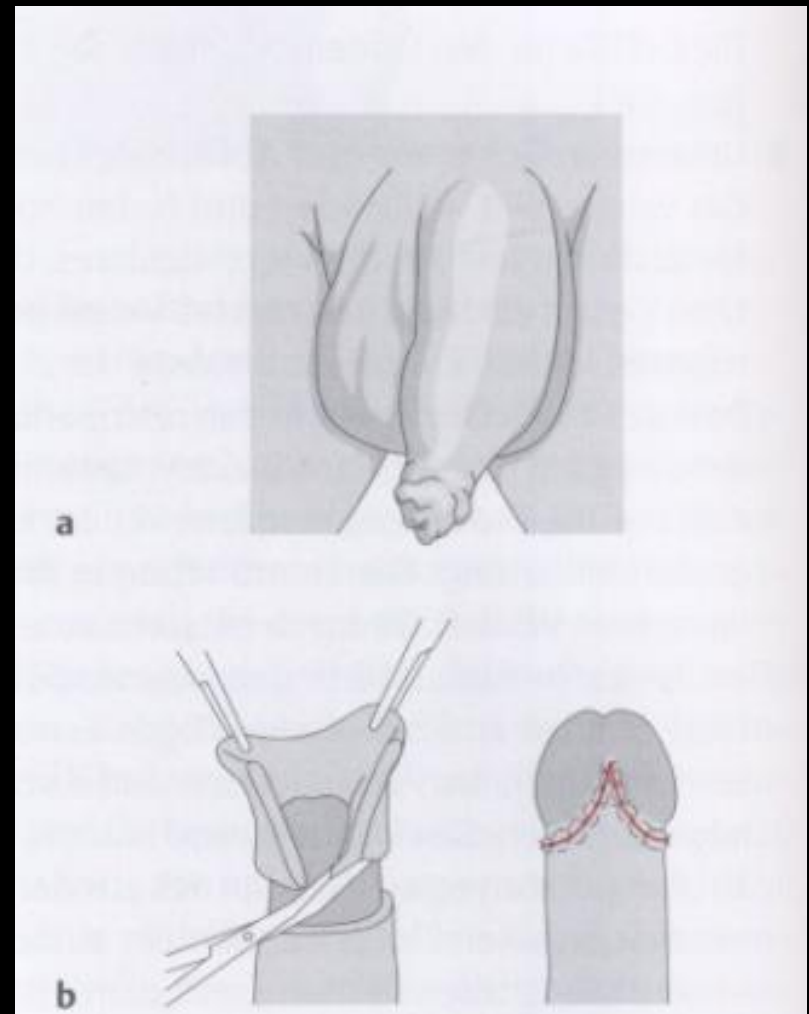
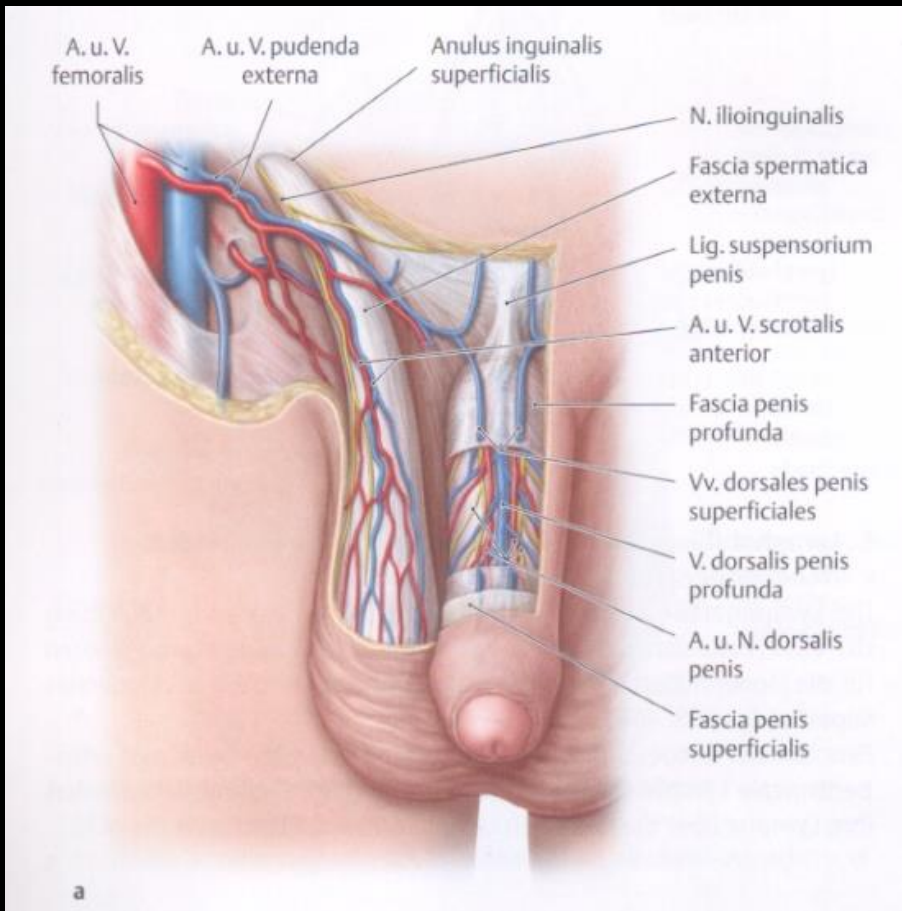
Merevedés (erekció)



Előbőr – fityma (preputium)



Körülmetélés (circumcisio)



Férfi medencefenék és gátizmok

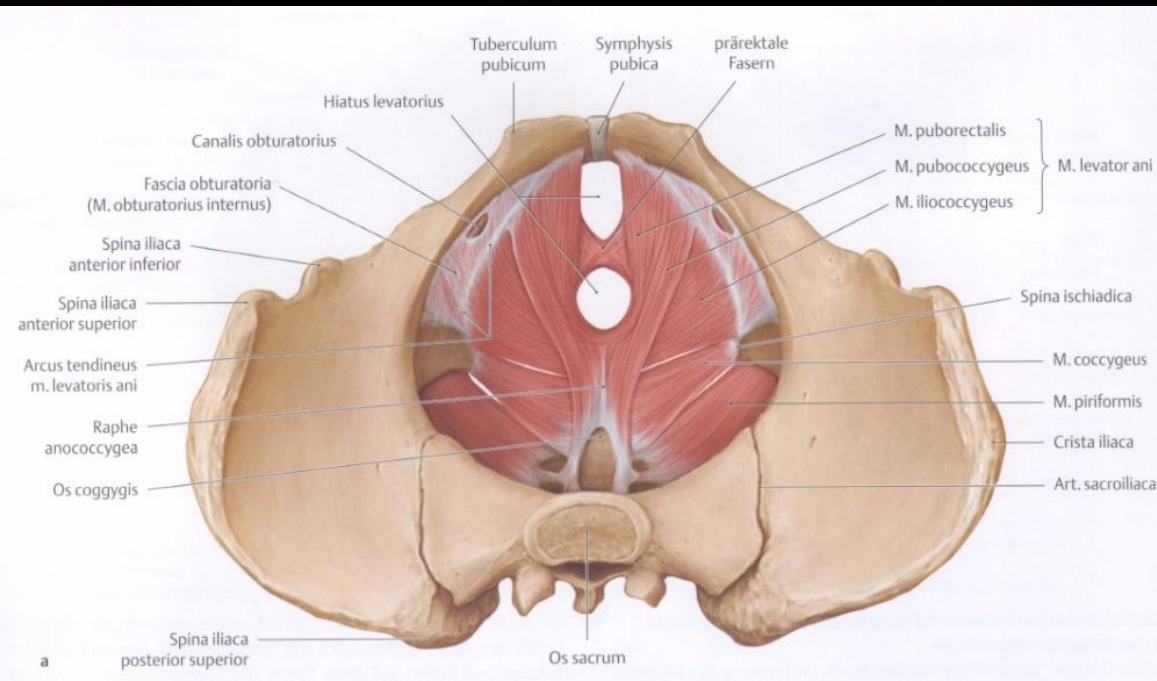
A medencefenék izmai

diaphragma pelvis

m. coccygeus

m. piriformis

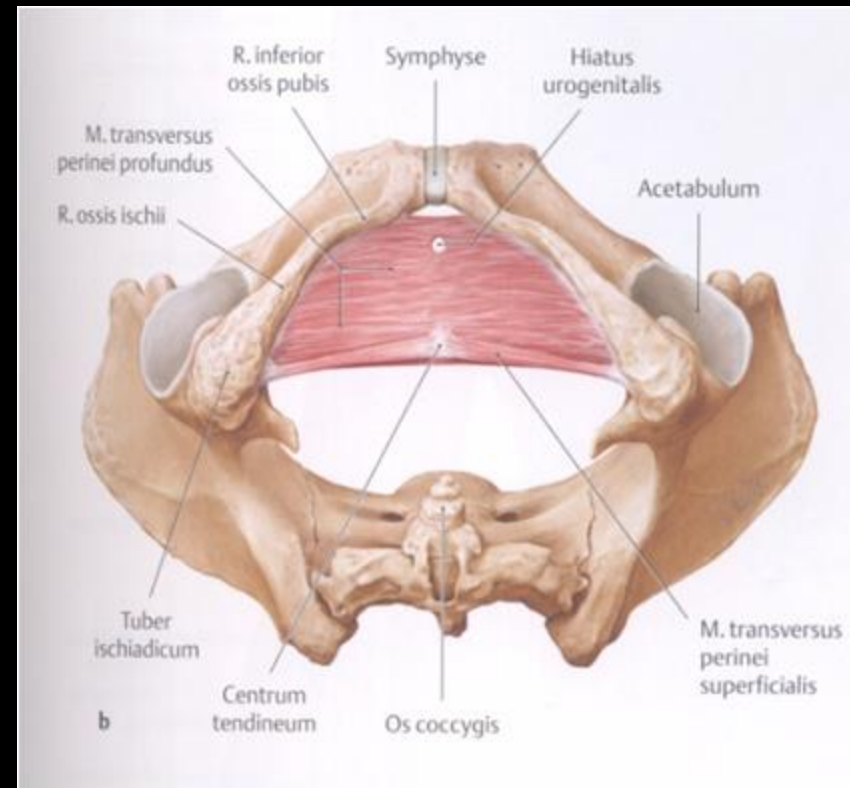
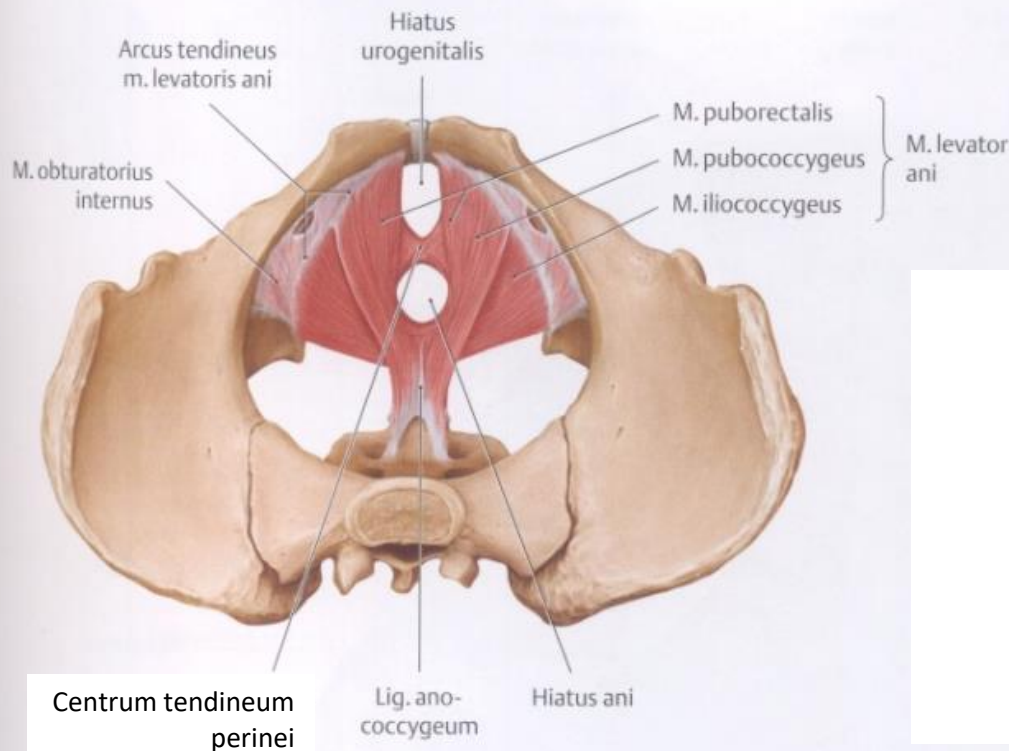
m. obturator internus



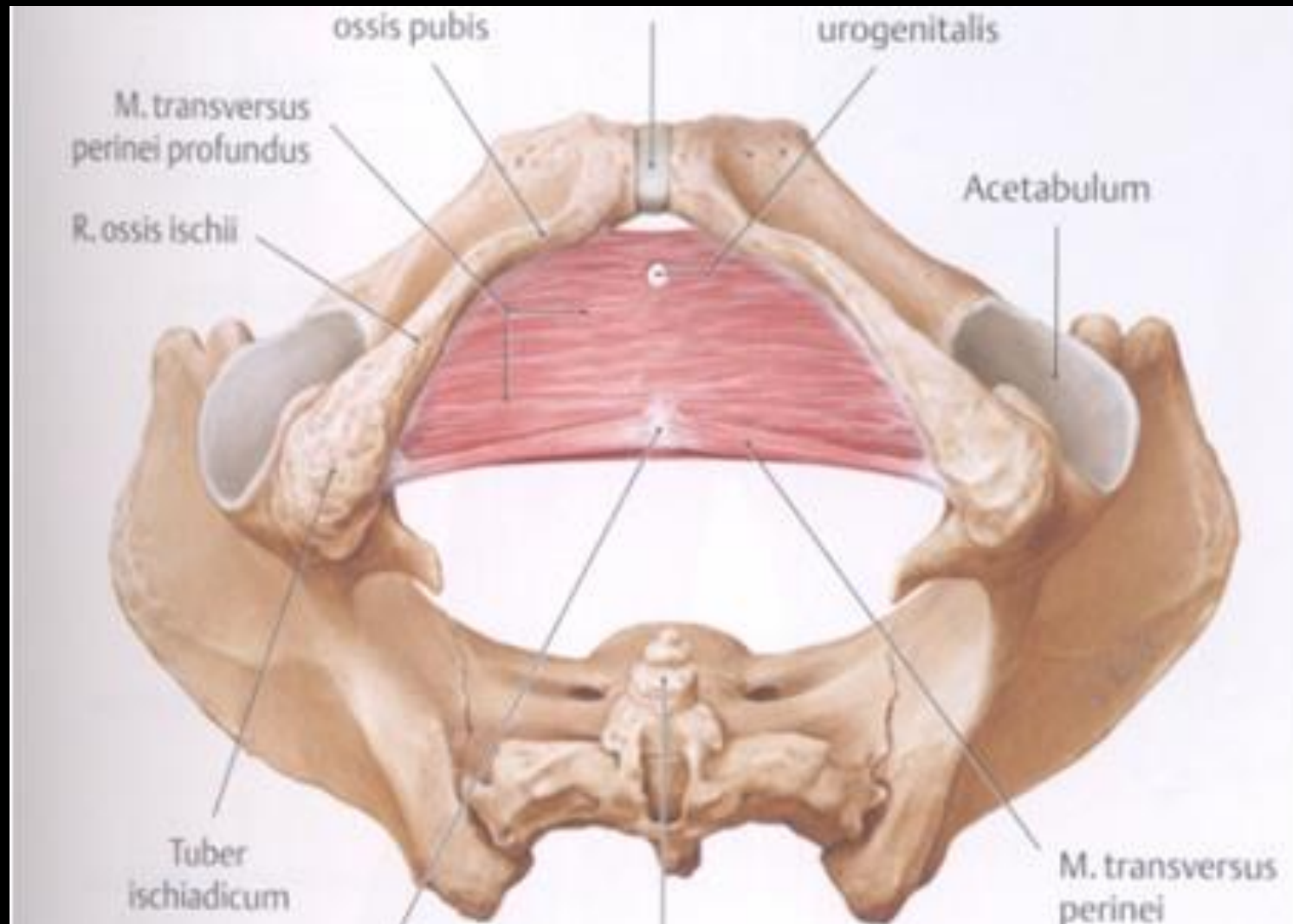
A medencefenék és gátizmok

diaphragma pelvis

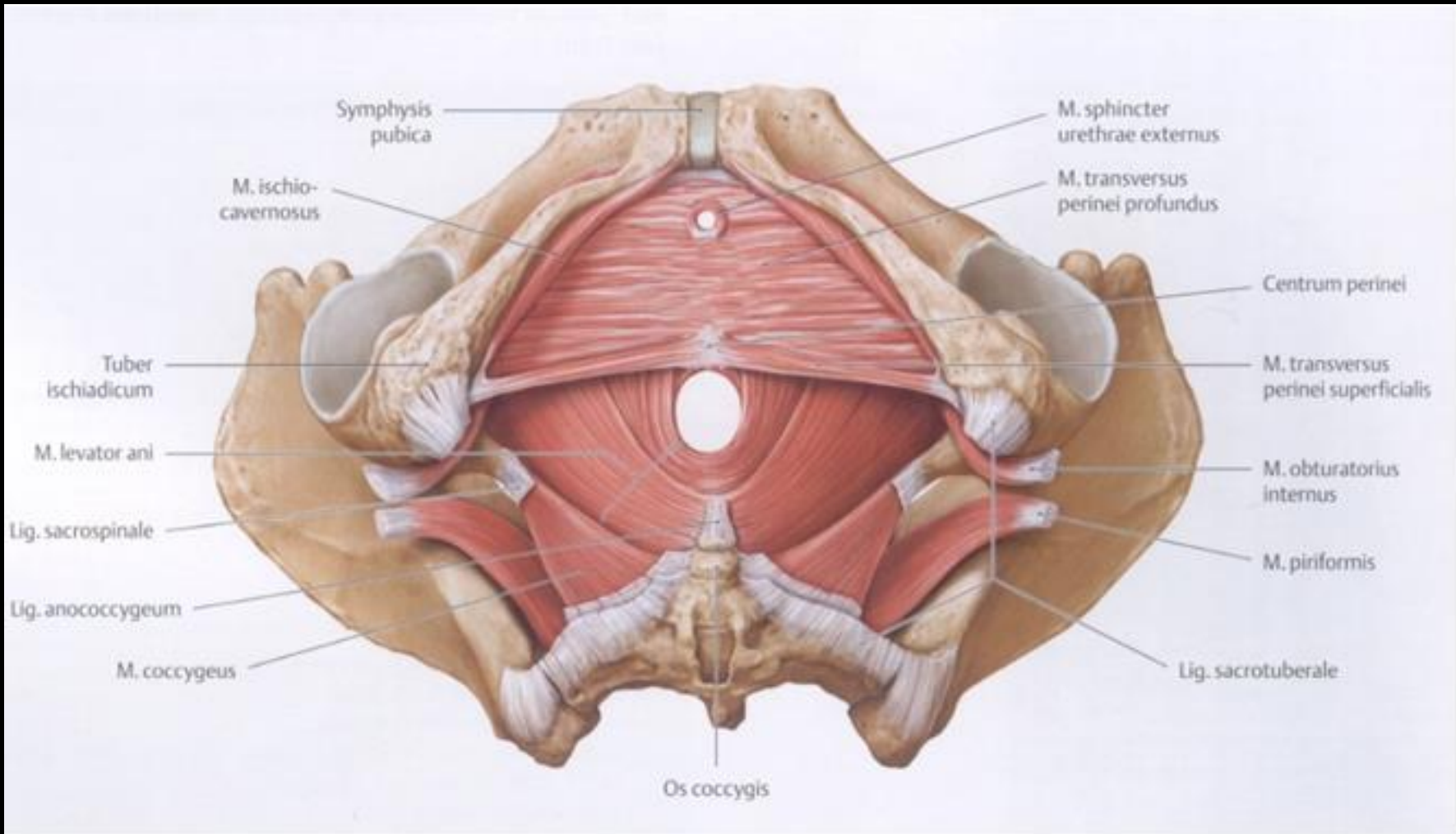
diaphragma urogenitale



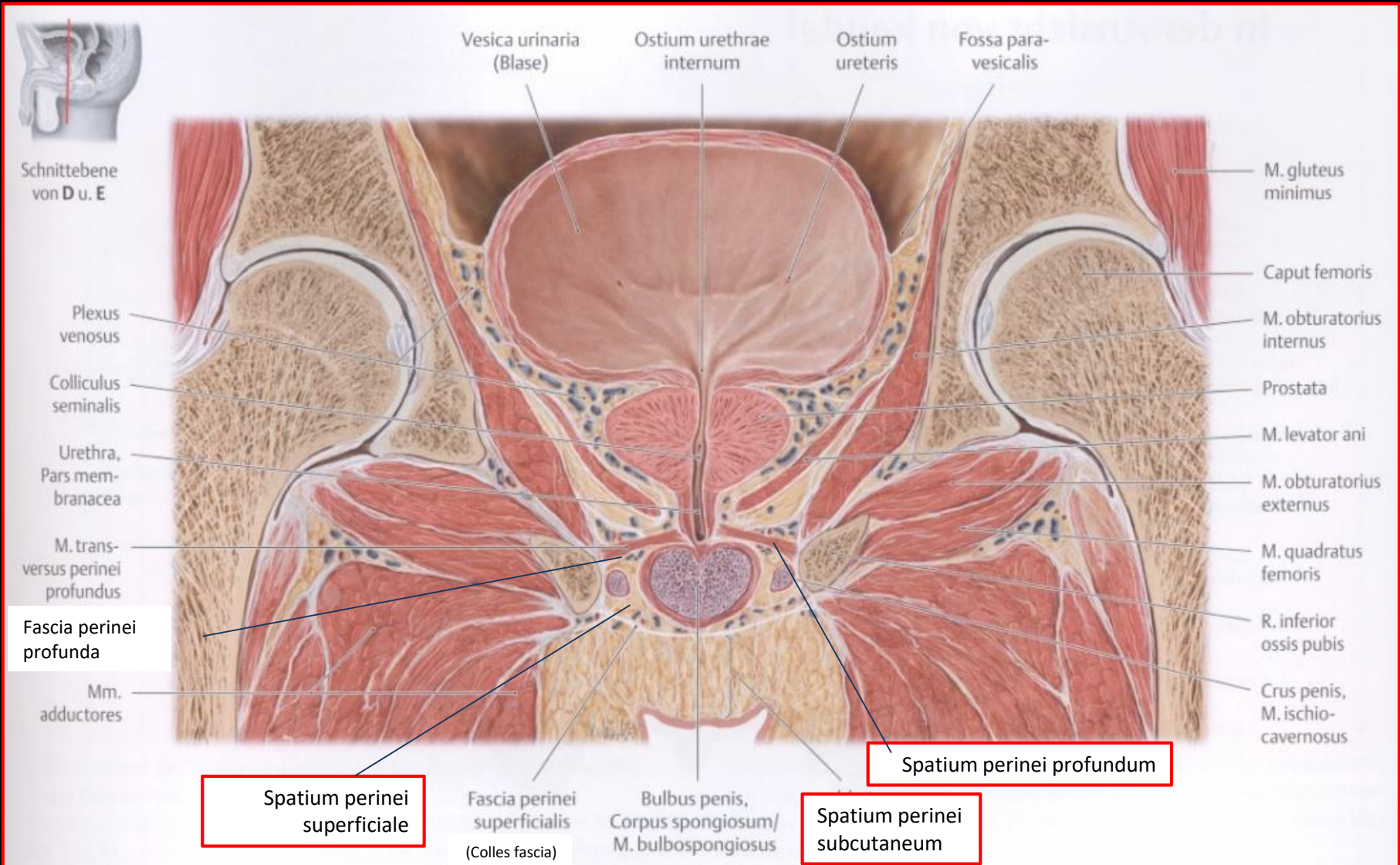
A gát területe (regio perinealis)



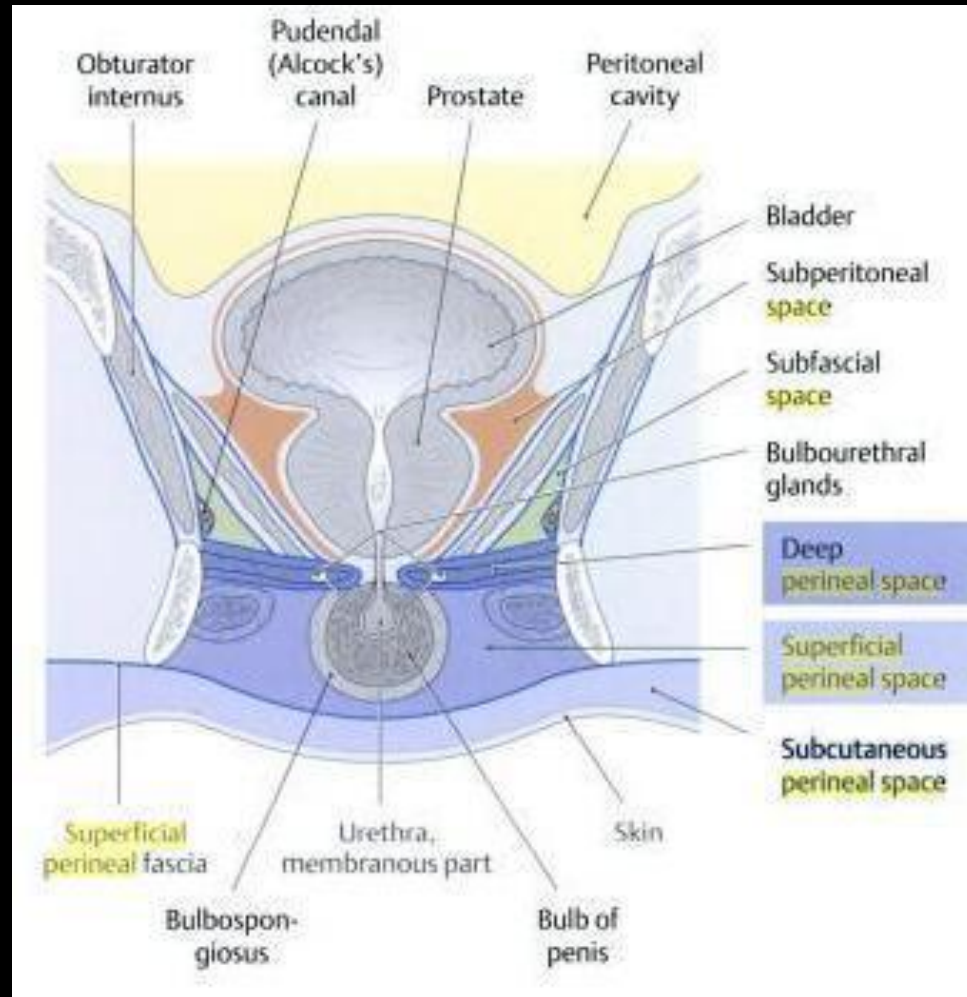
A gát területe (regio perinealis)



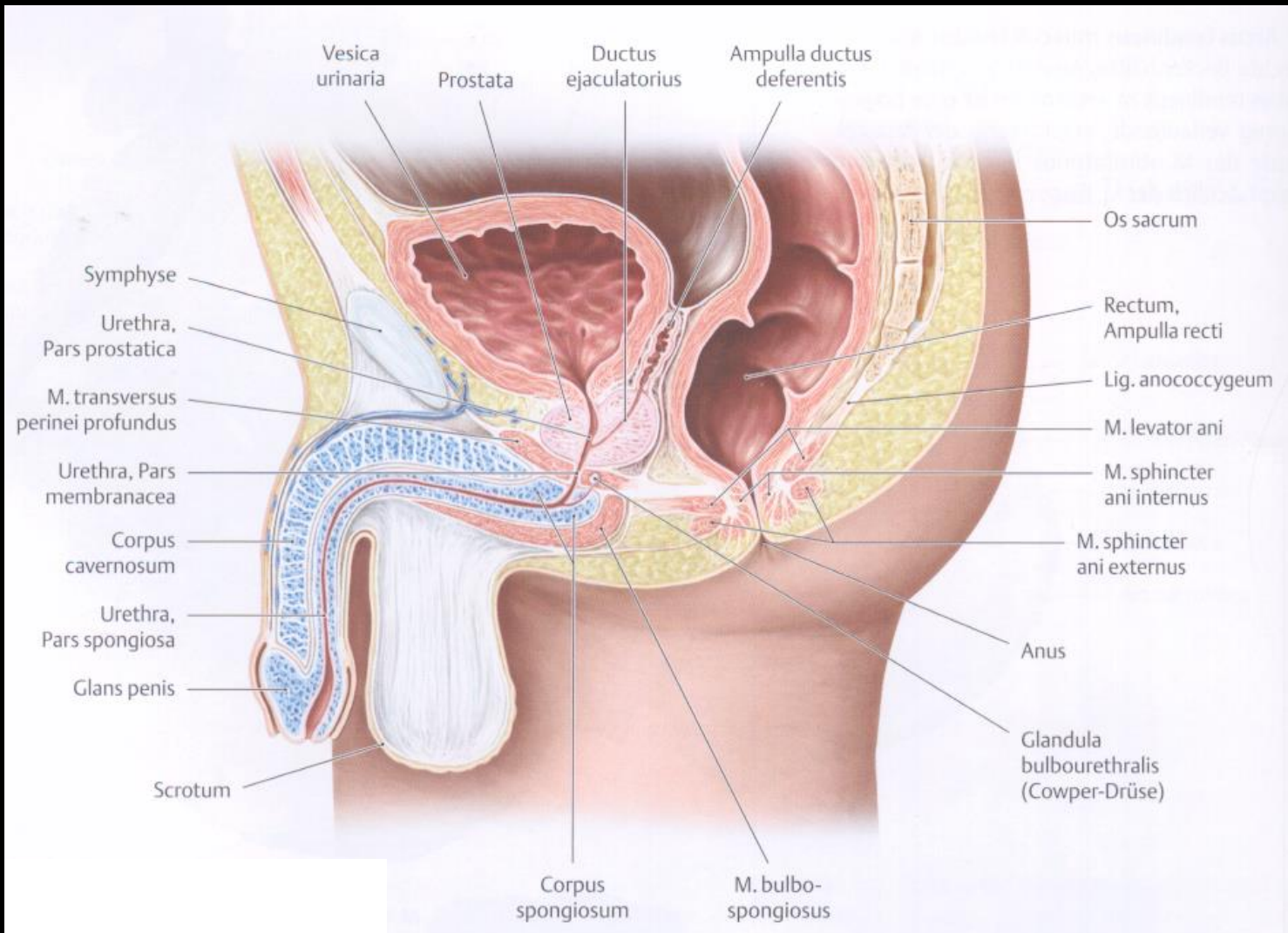
A medencefenék, a gátizmok és a **gát** szövetei



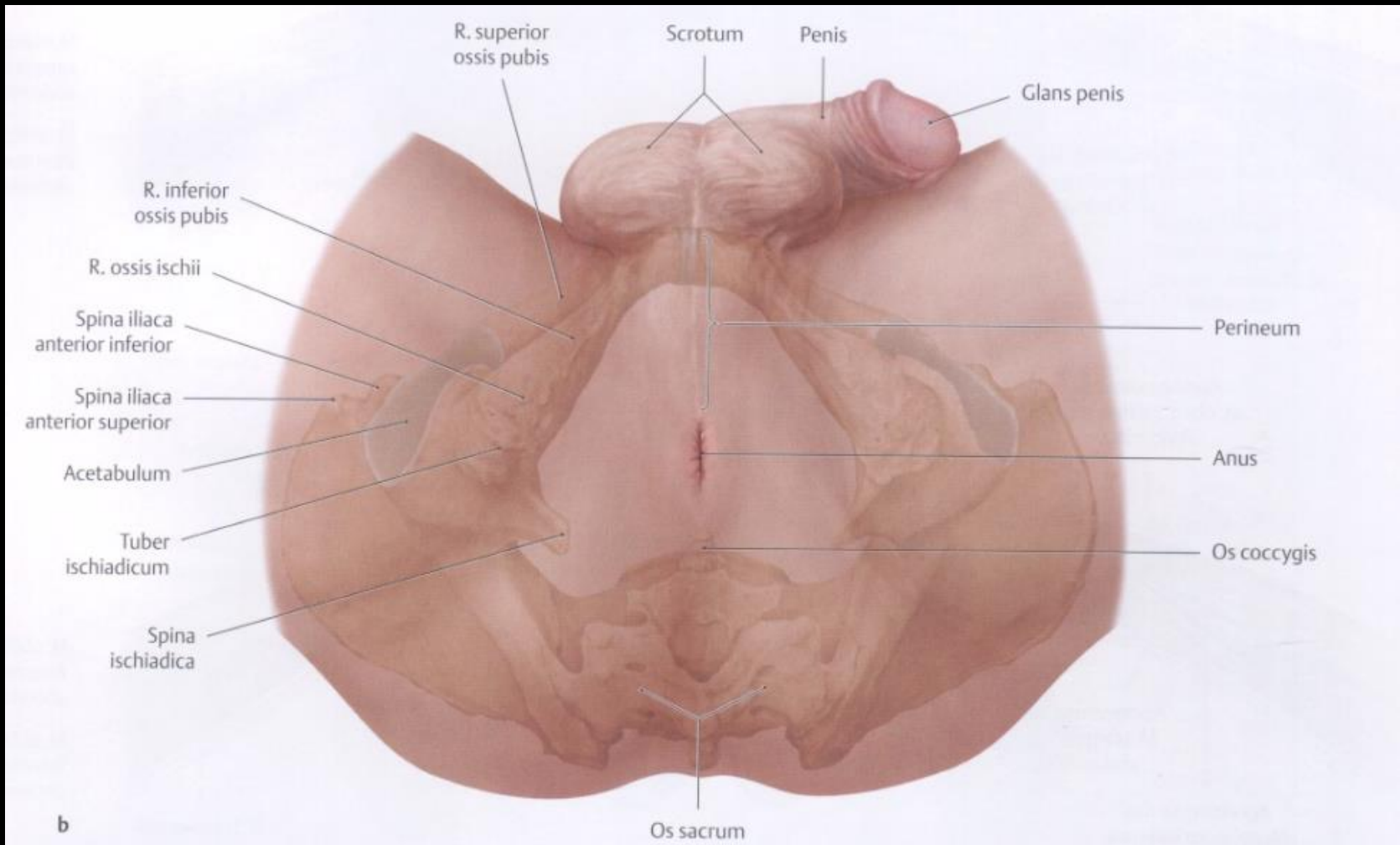
A medencefenék, a gátizmok és a gát szövetterei



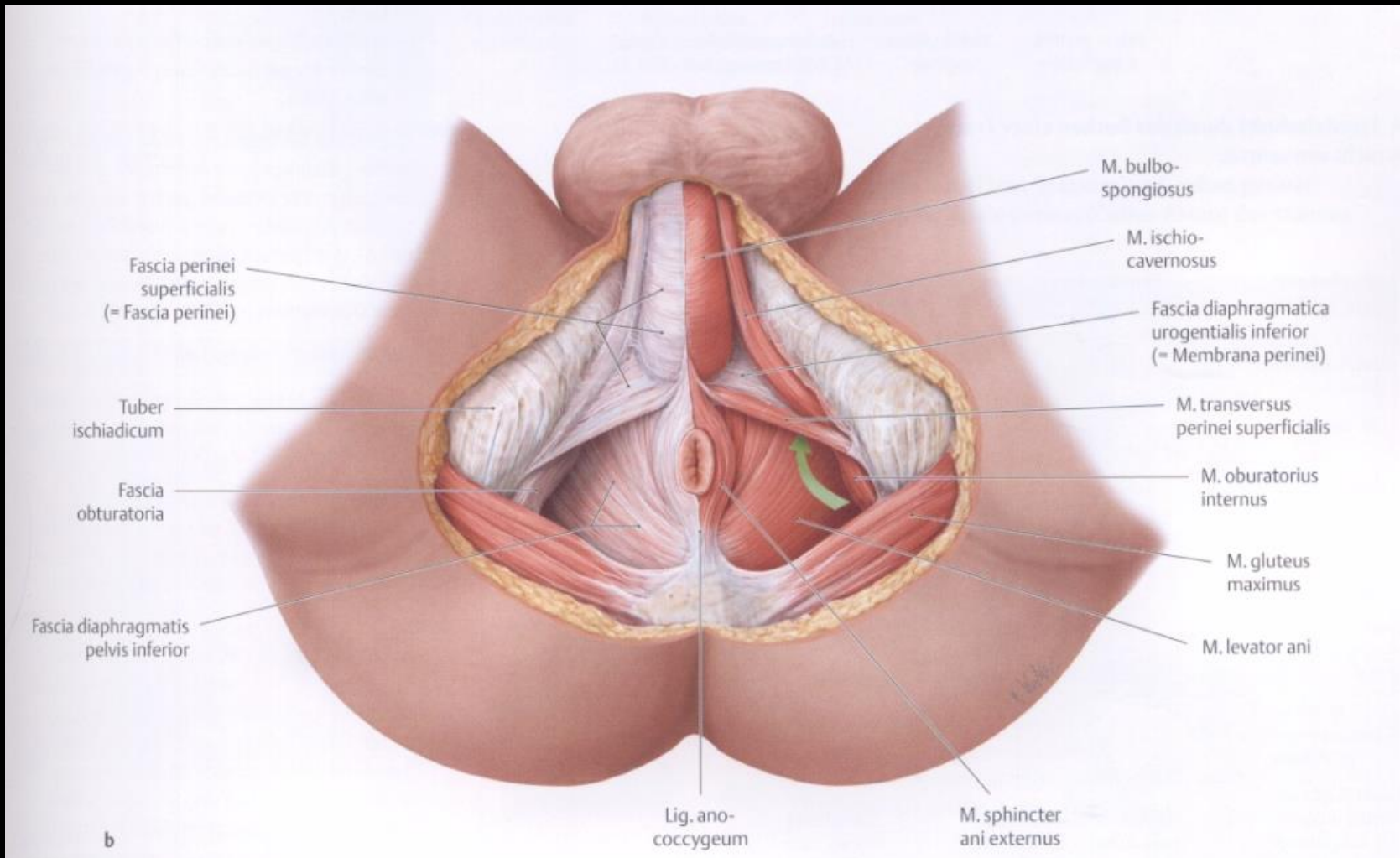
A medencefenék és gátizmok



A gát területe (regio perinealis)



A gát területe (regio perinealis)



A gát területe (regio perinealis)

