

A NYIROKRENDSZER

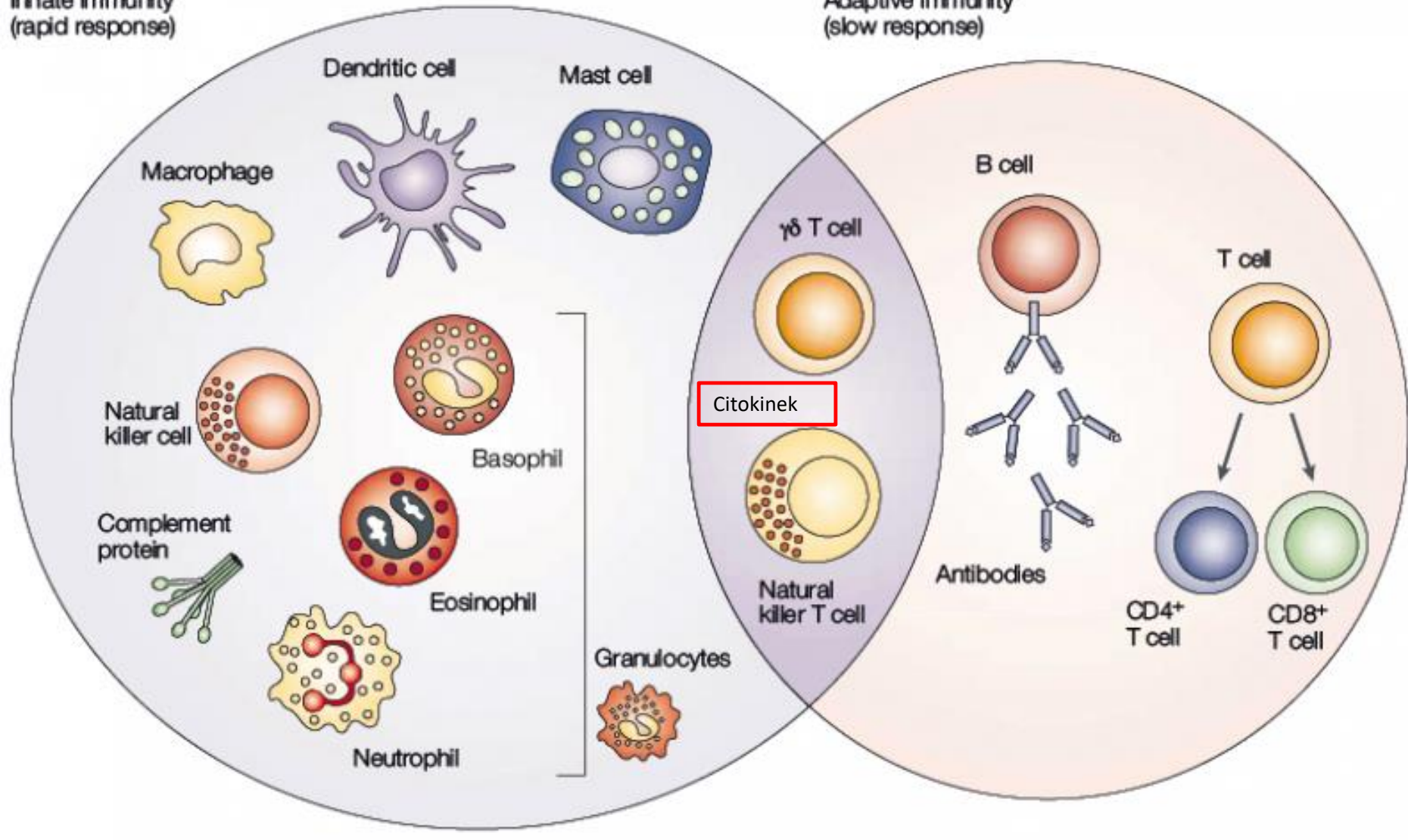
Barna János

Veleszületett/természetes immunitás

Adaptív/szerzett immunitás

Innate immunity
(rapid response)

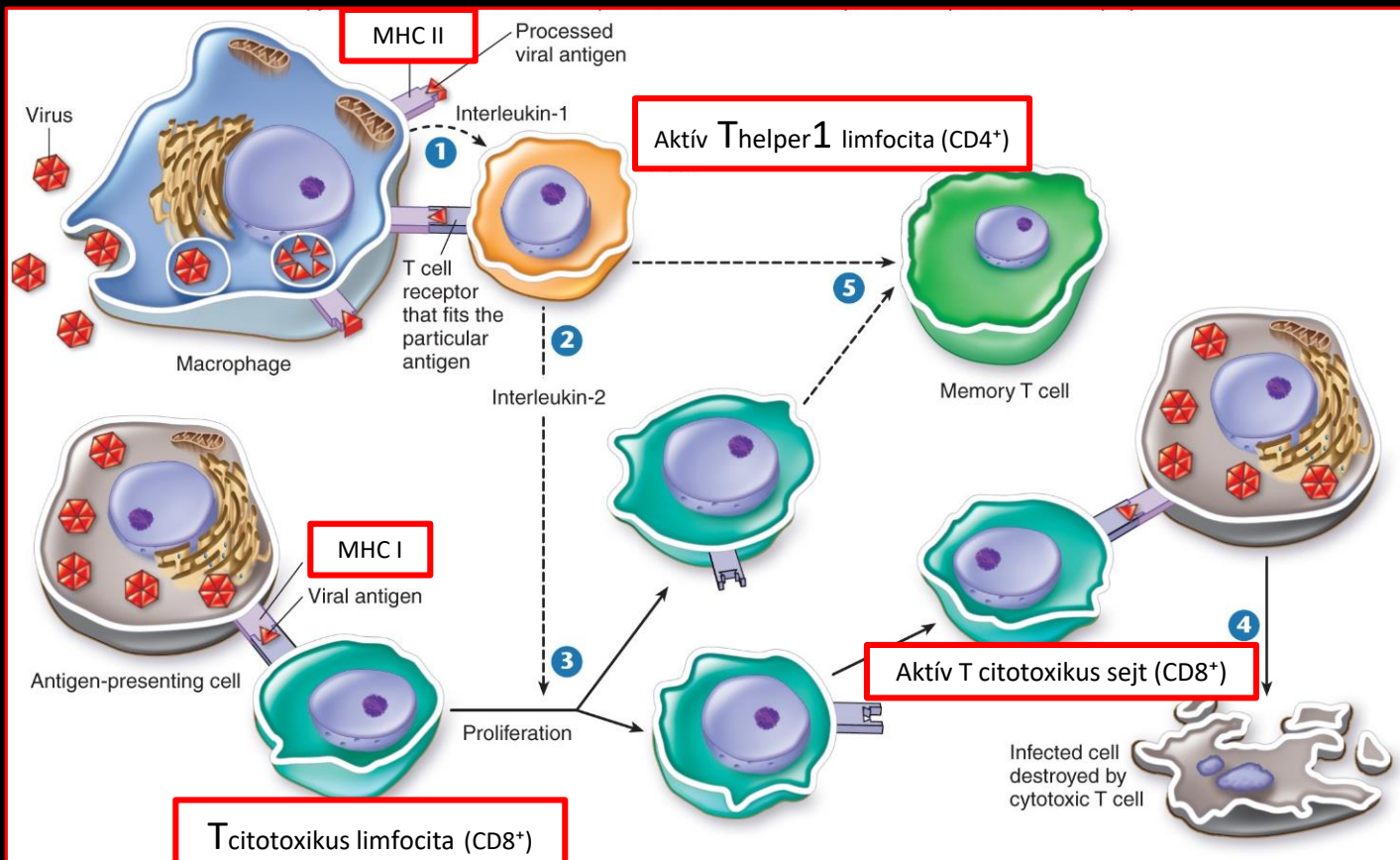
Adaptive immunity
(slow response)



Adaptív/szerzett immunitás

Celluláris immunválasz

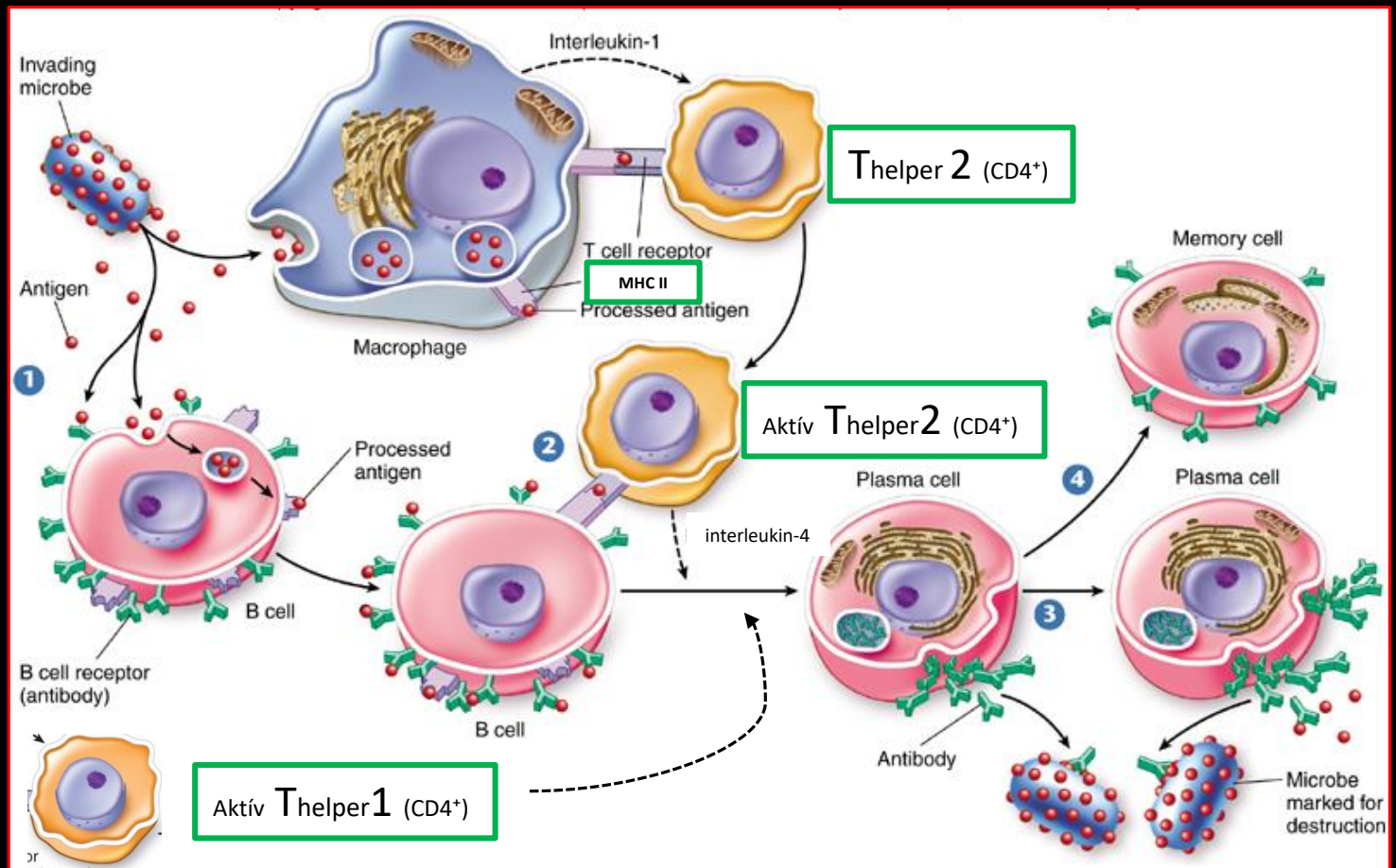
Humorális immunválasz



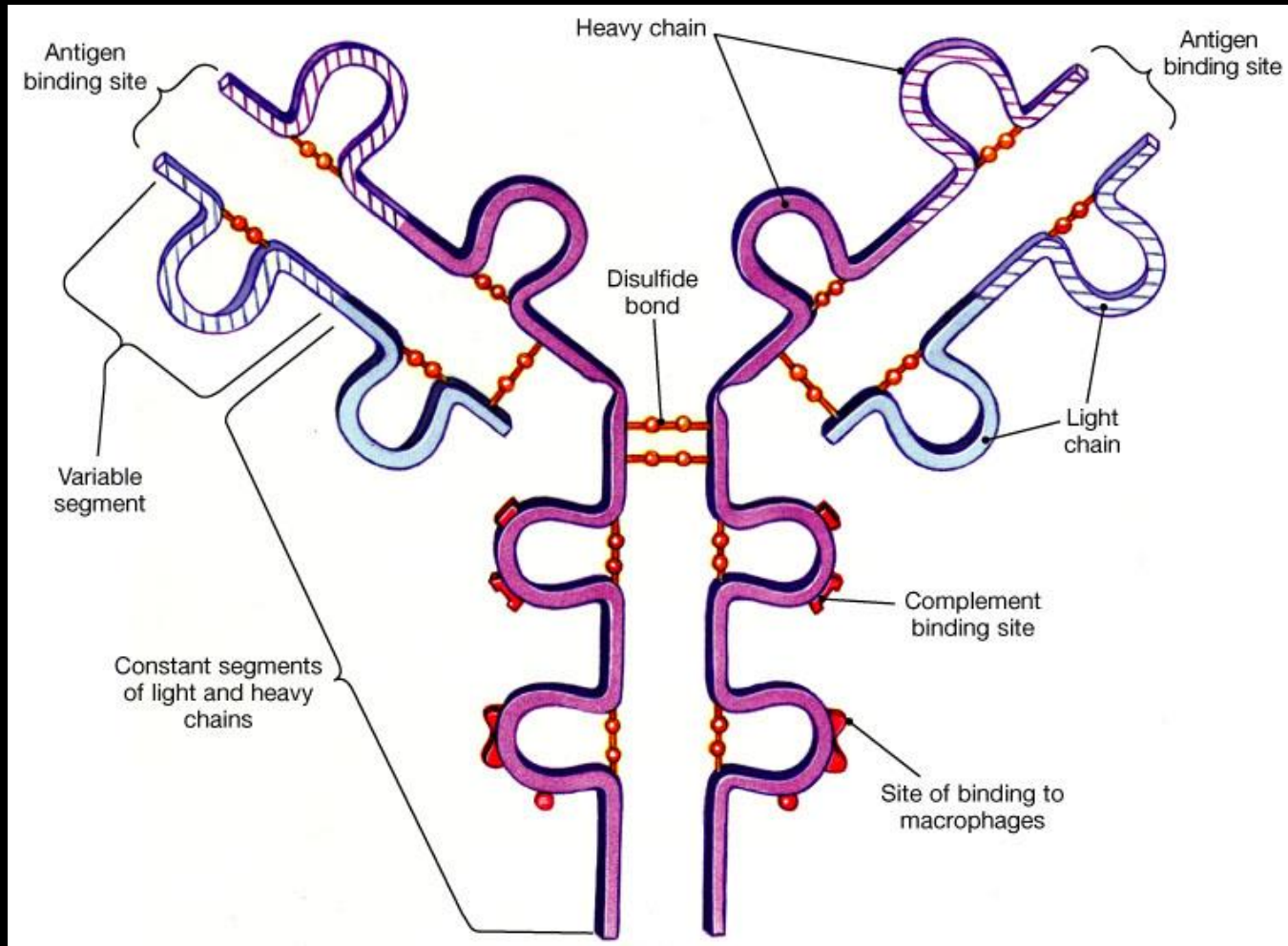
Adaptív/szerzett immunitás

Celluláris immunválasz

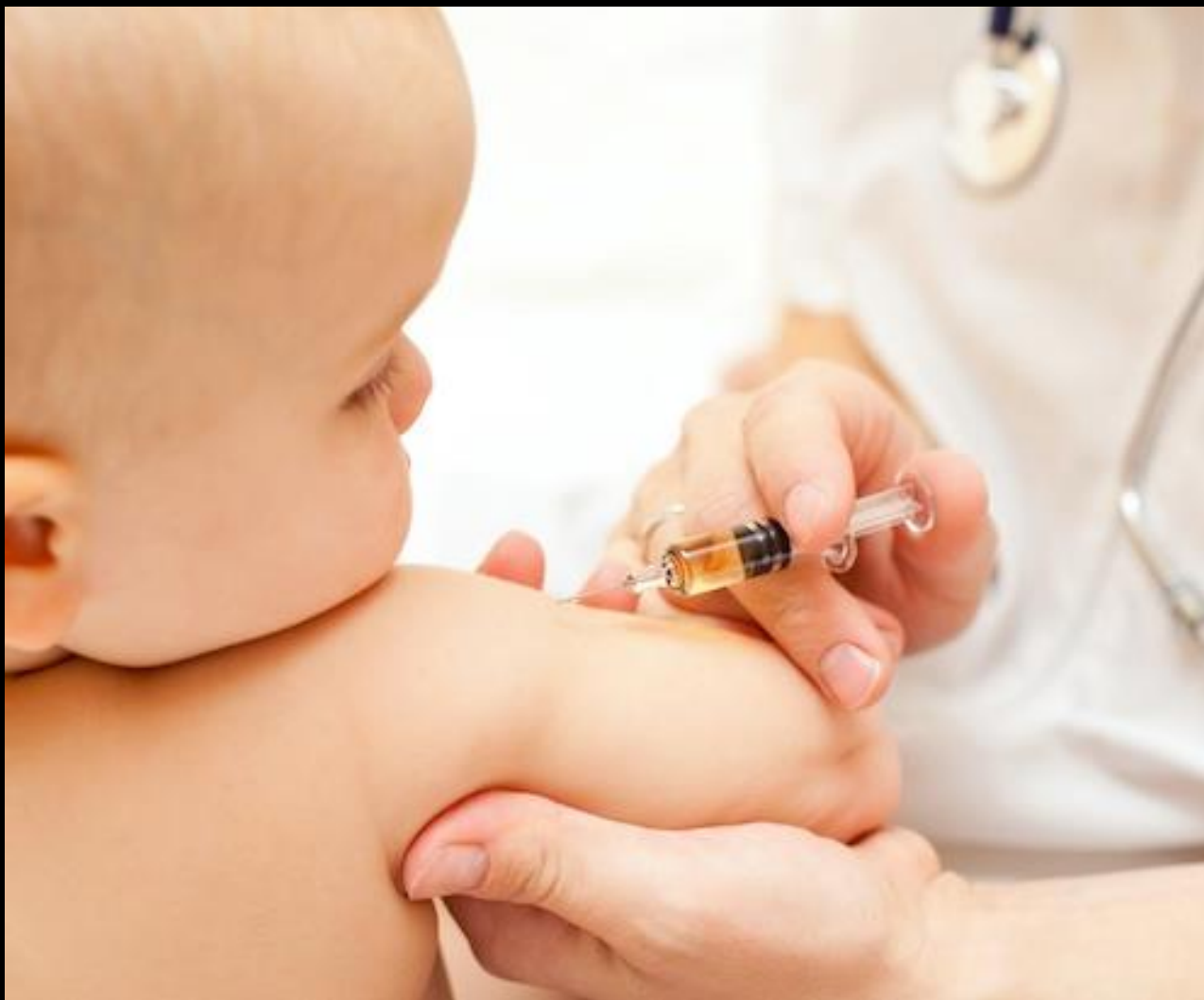Humorális immunválasz



Immunglobulin (antitest)

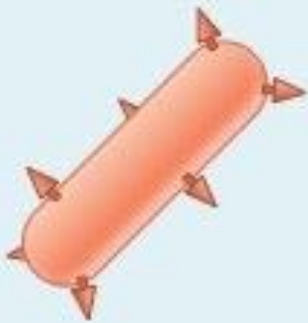


PASSZÍV versus AKTÍV IMMUNITÁS



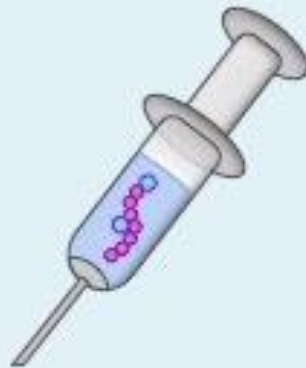Aktív immunitás

természetes



Infection

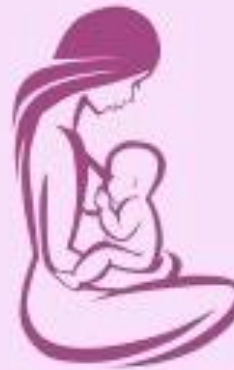mesterséges



Vaccination

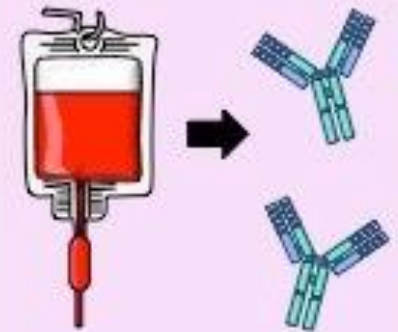
Passzív immunitás

természetes



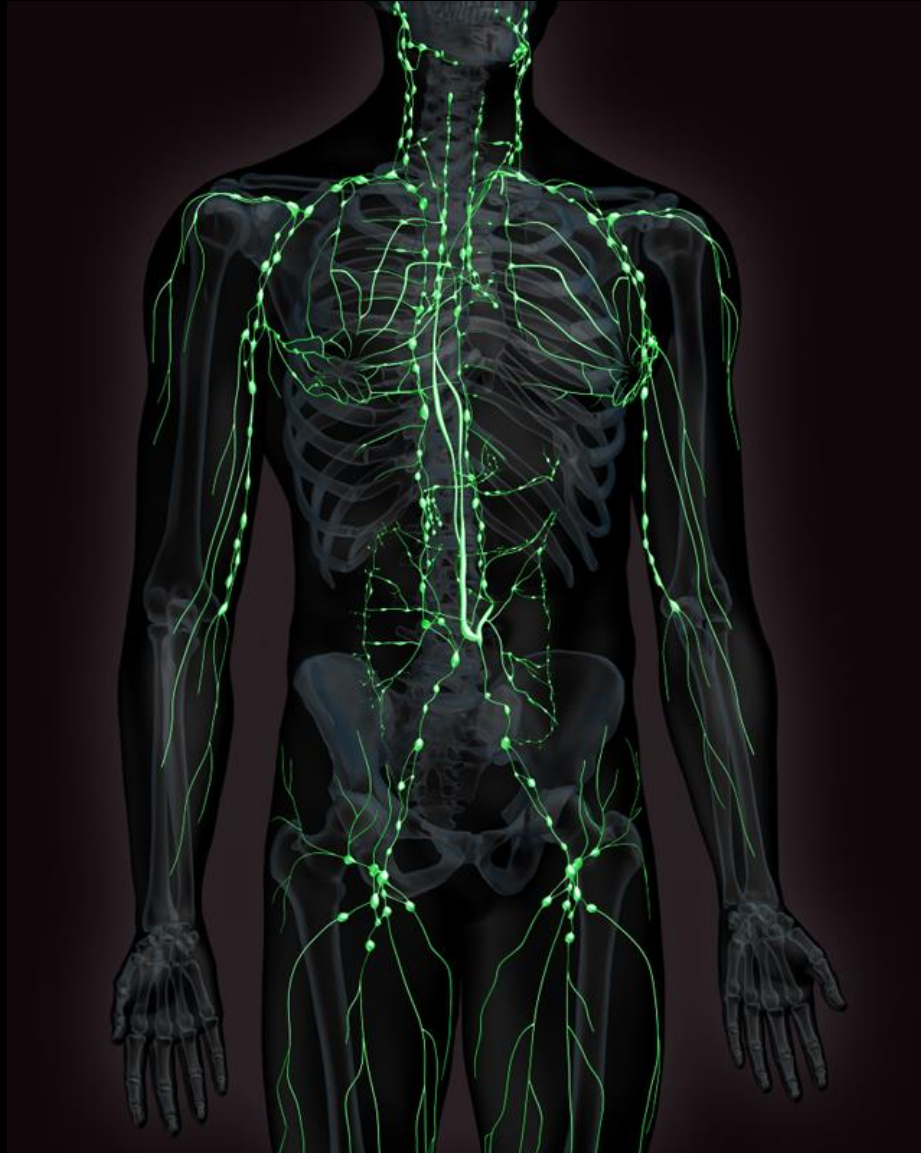
Maternal
antibodies

mesterséges

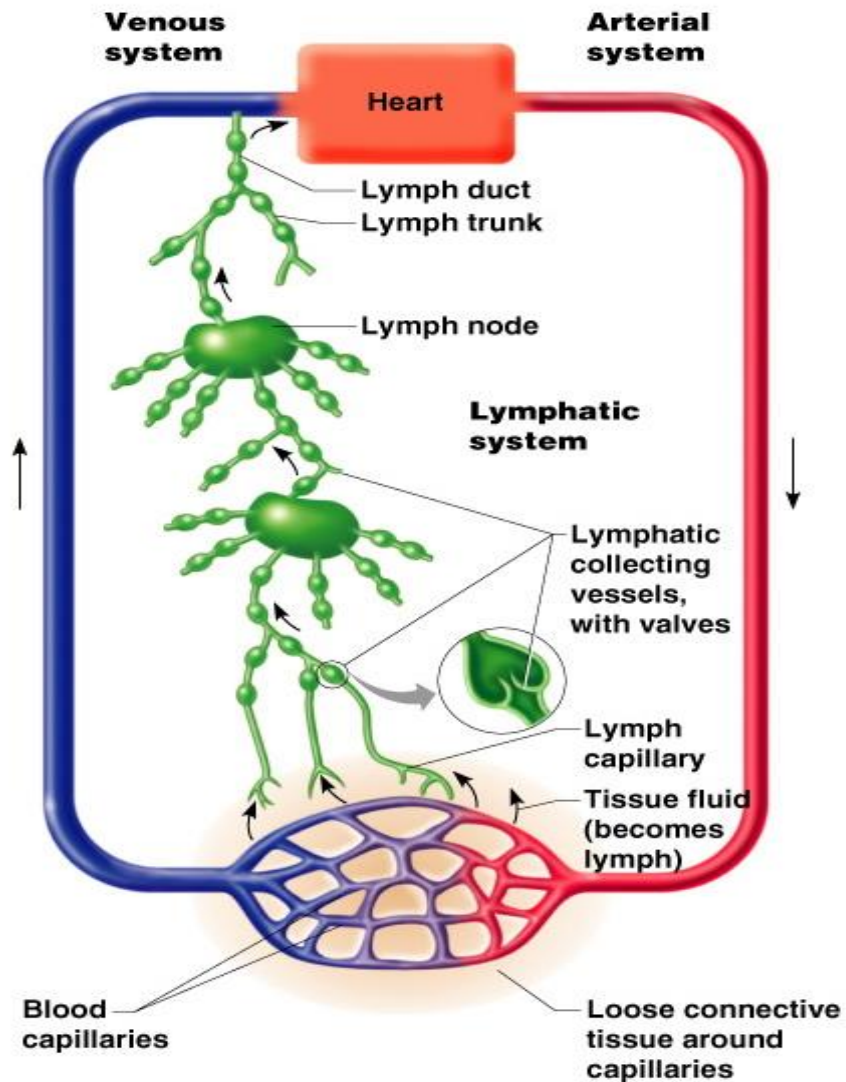


Monoclonal
antibodies

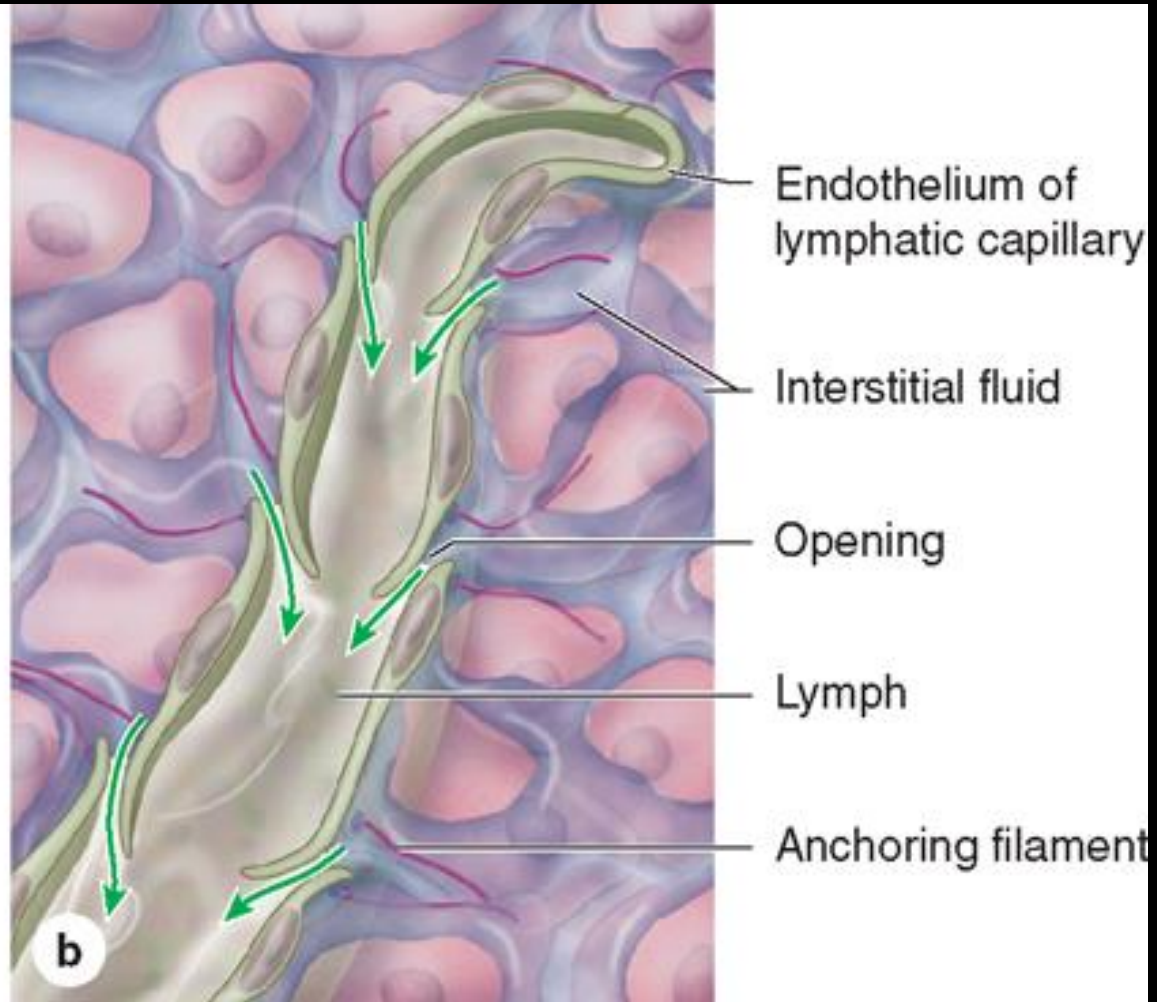
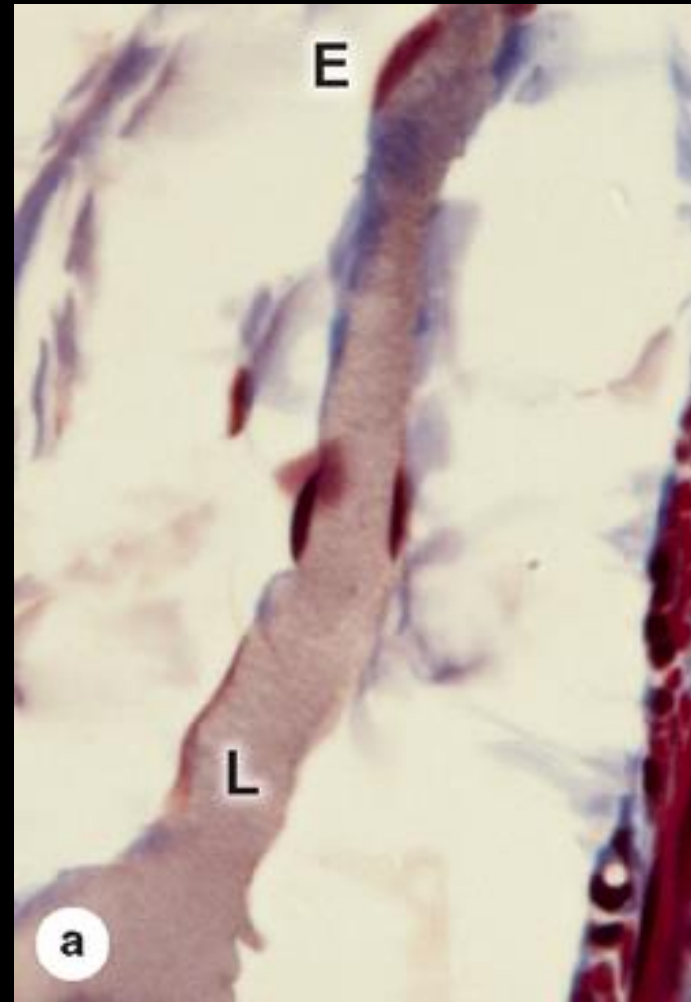
A nyirokerek

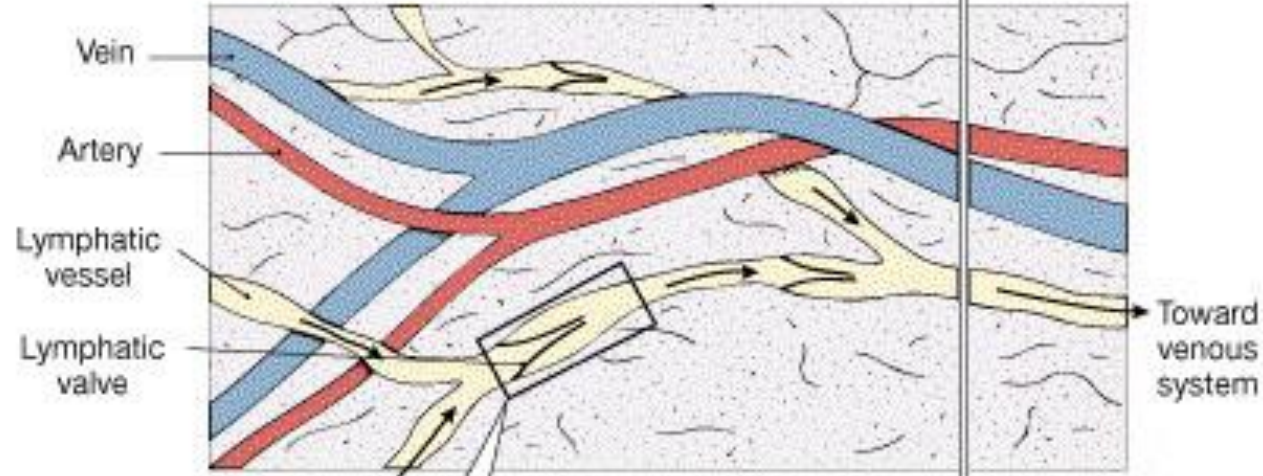


Nyirokkeringés




Nyirokkapilláris

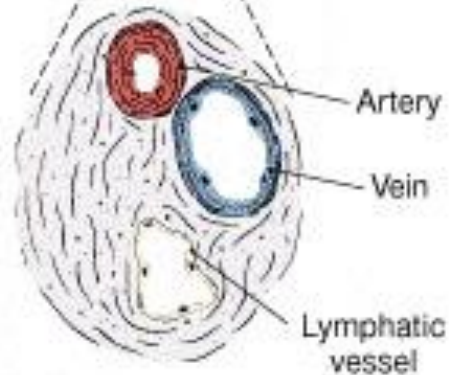




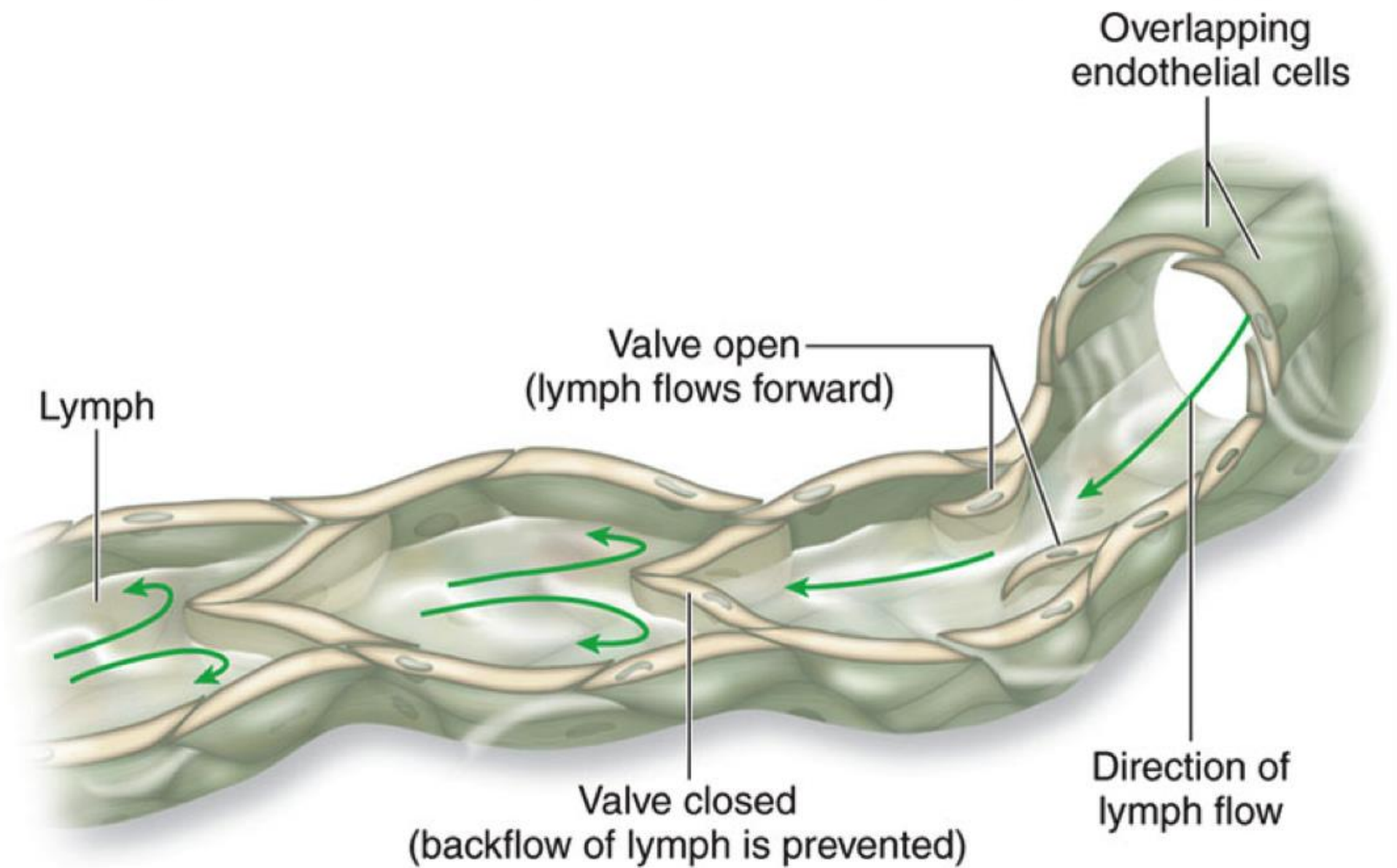
(a) Lymphatic vessels showing arrangement of valves



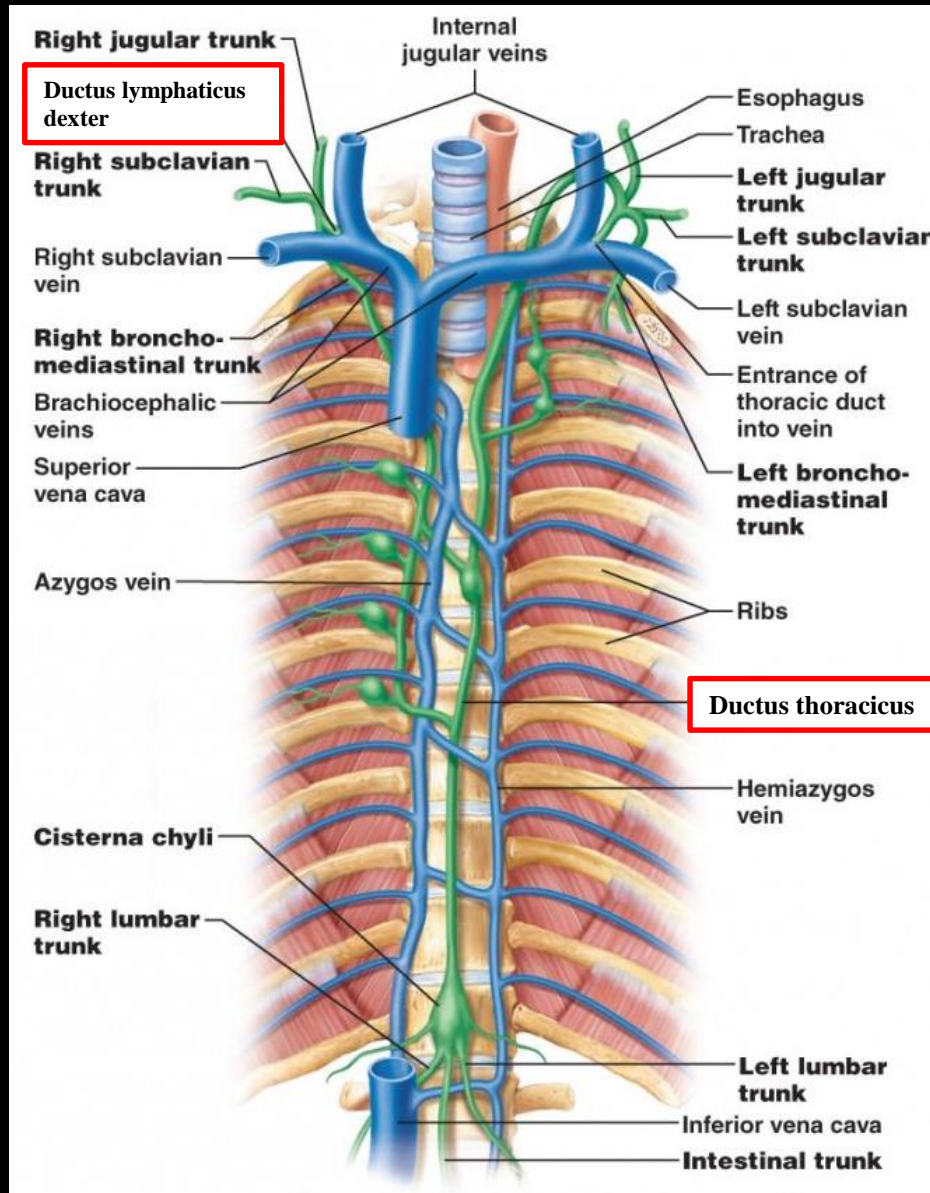
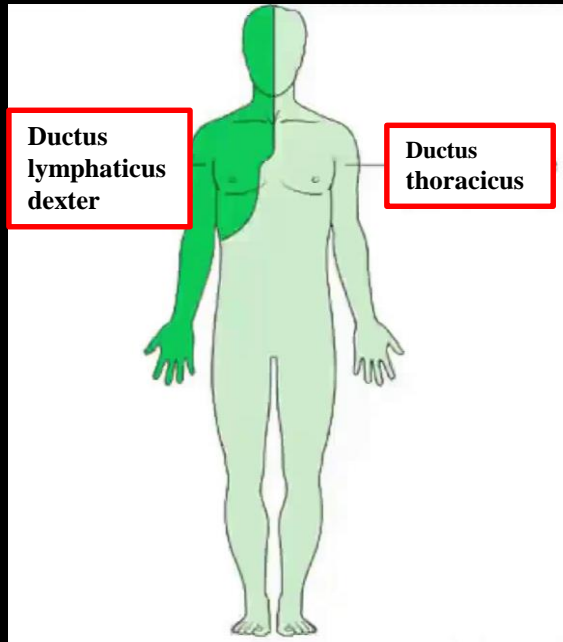
(b) Whole mount of lymphatic vessel with valve (LM × 63)



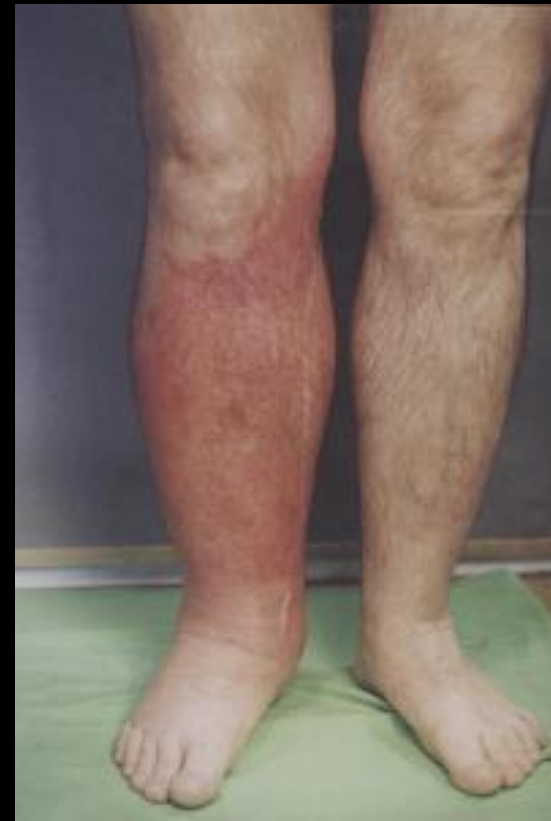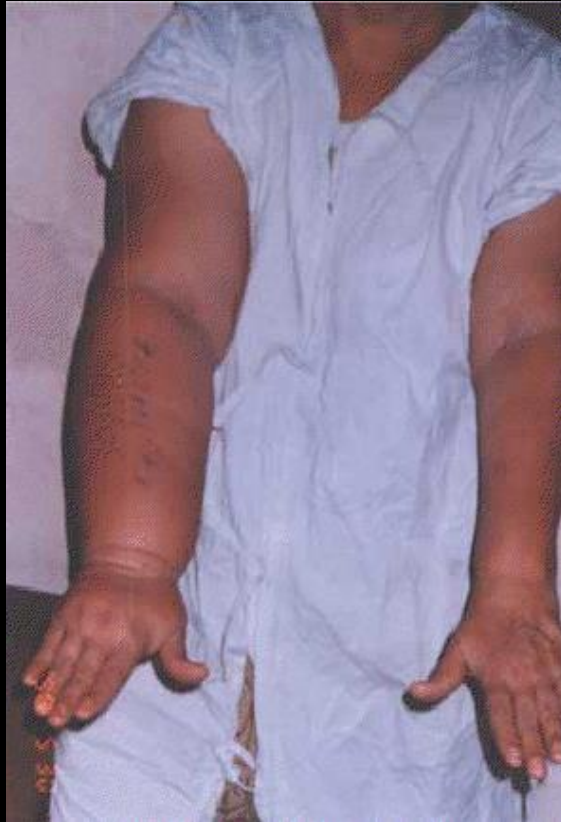(c) Sectional view



A nyirokerek

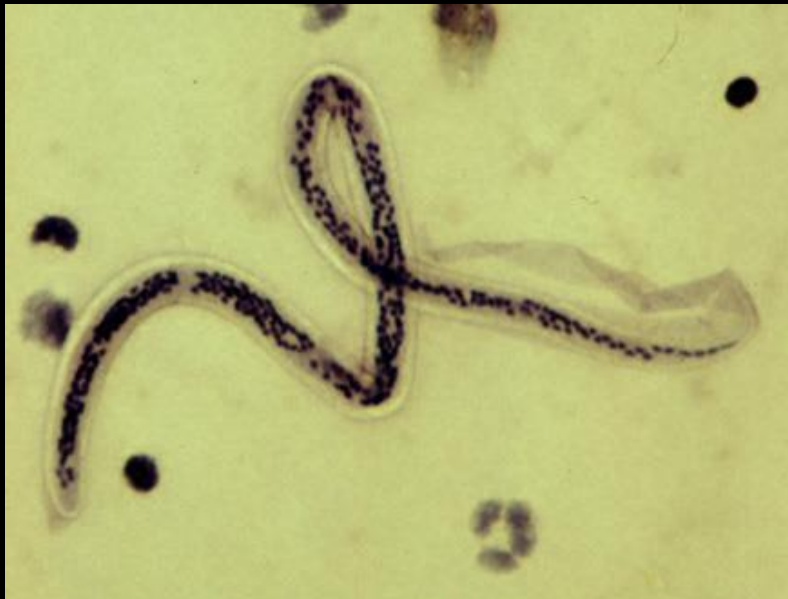

oedema



Elefántkór/elefántiázis

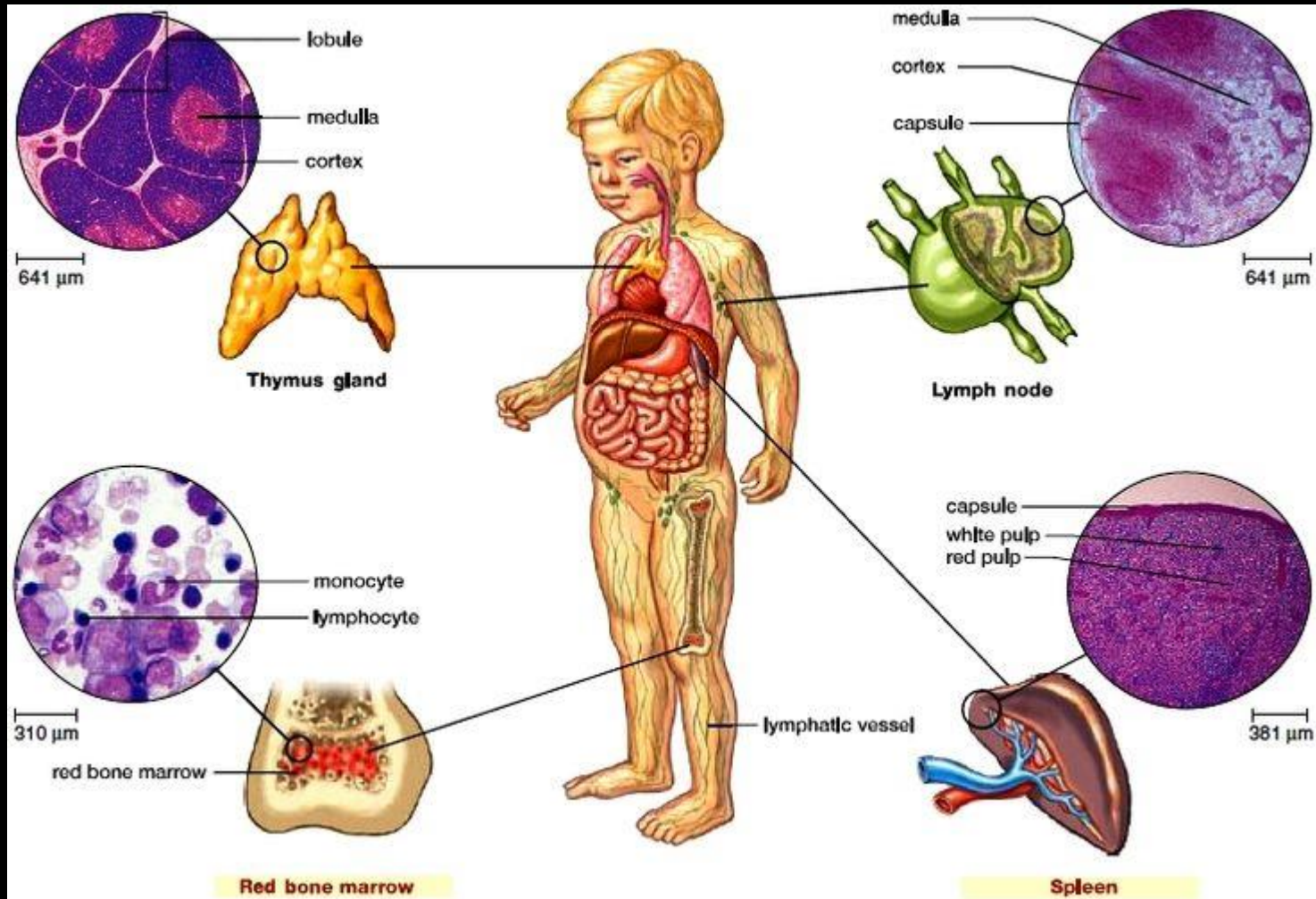
Wuchereria bancrofti



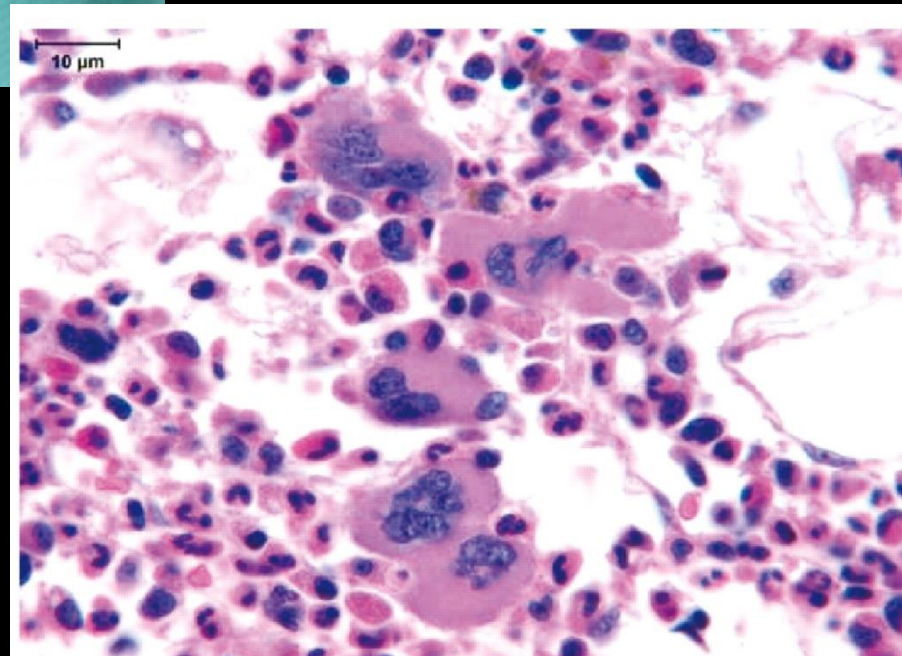
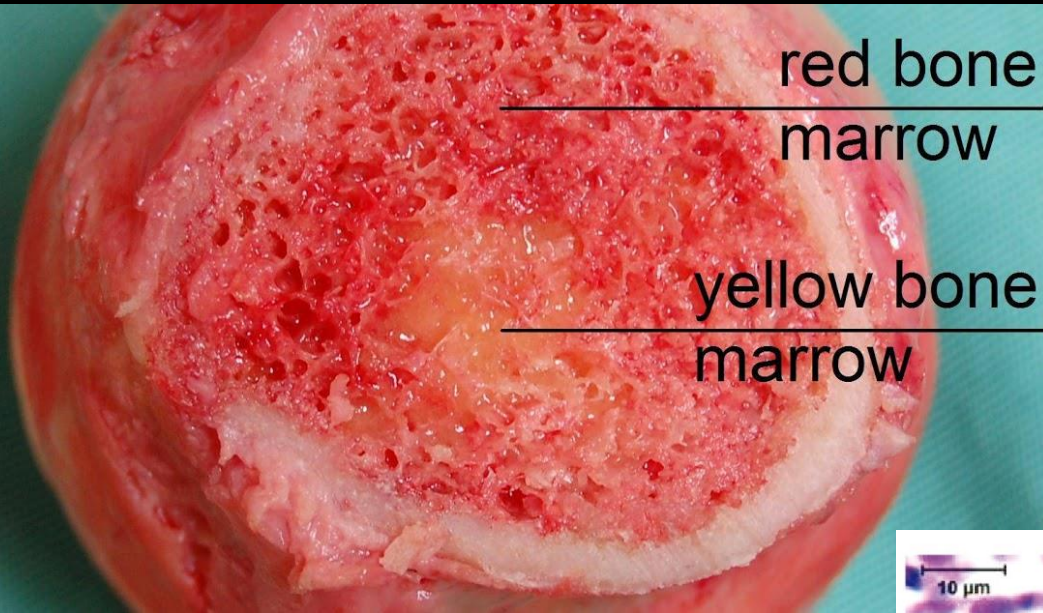
Nyirokszervek

Centralis/primer nyirokszervek

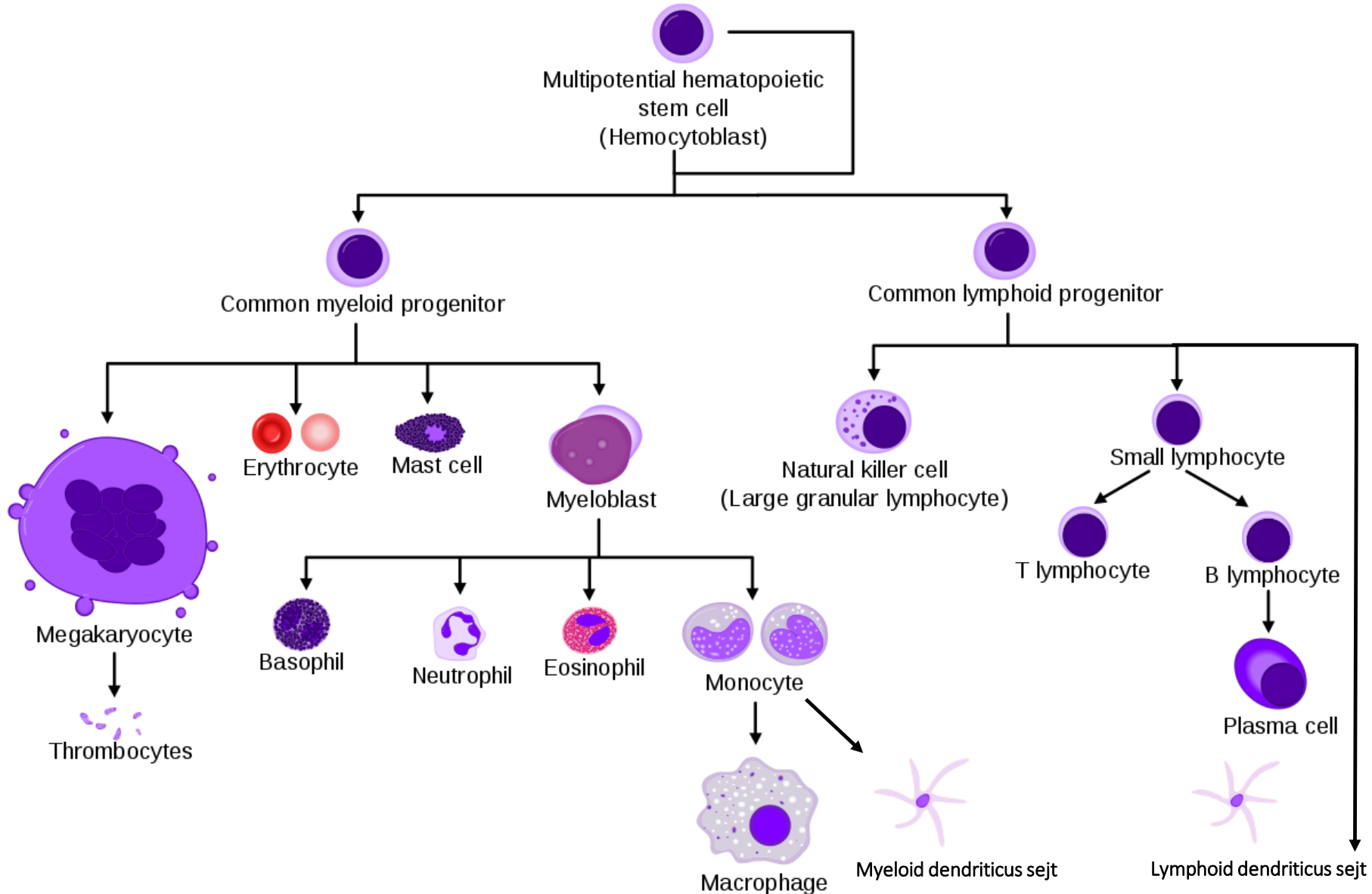
Perifériás/secunder nyirokszervek



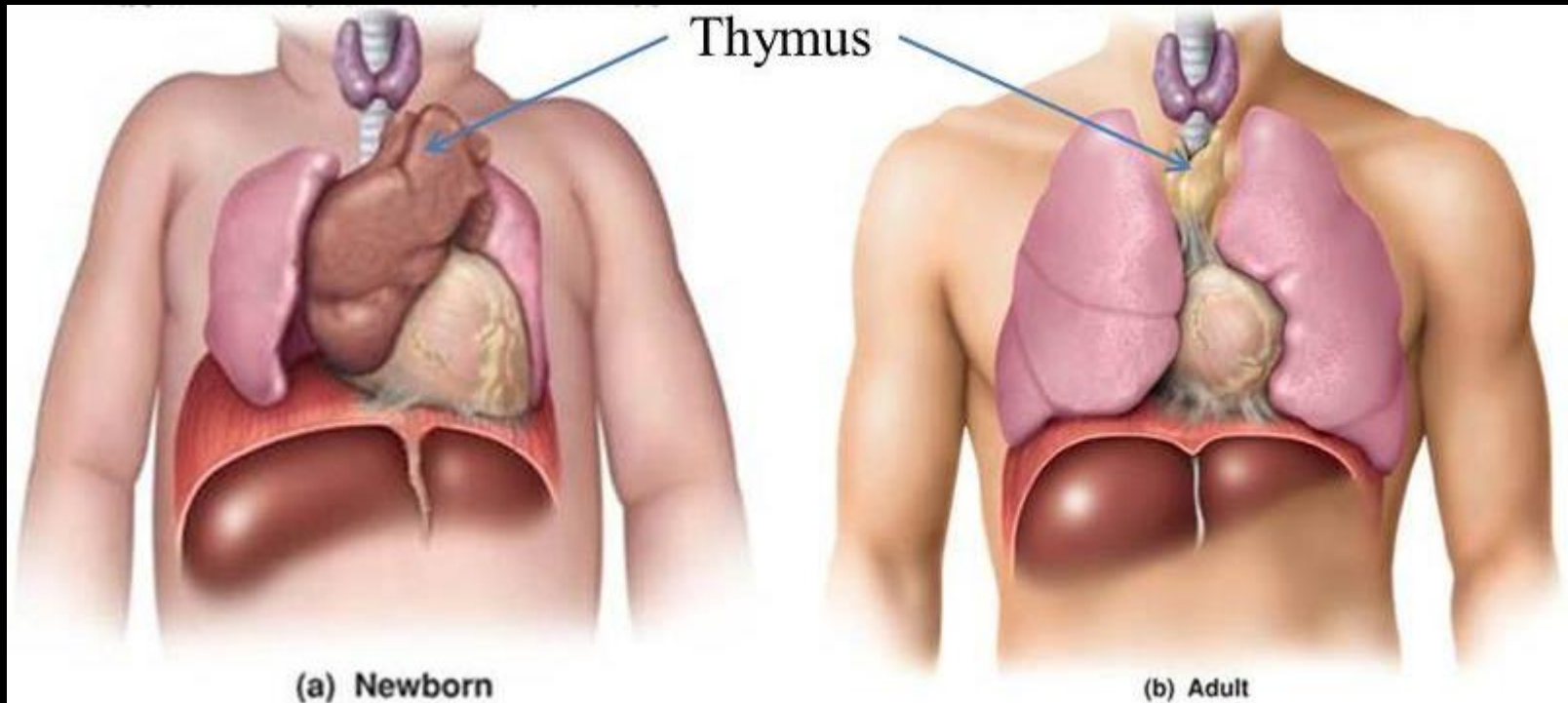
Vöröscsontvelő

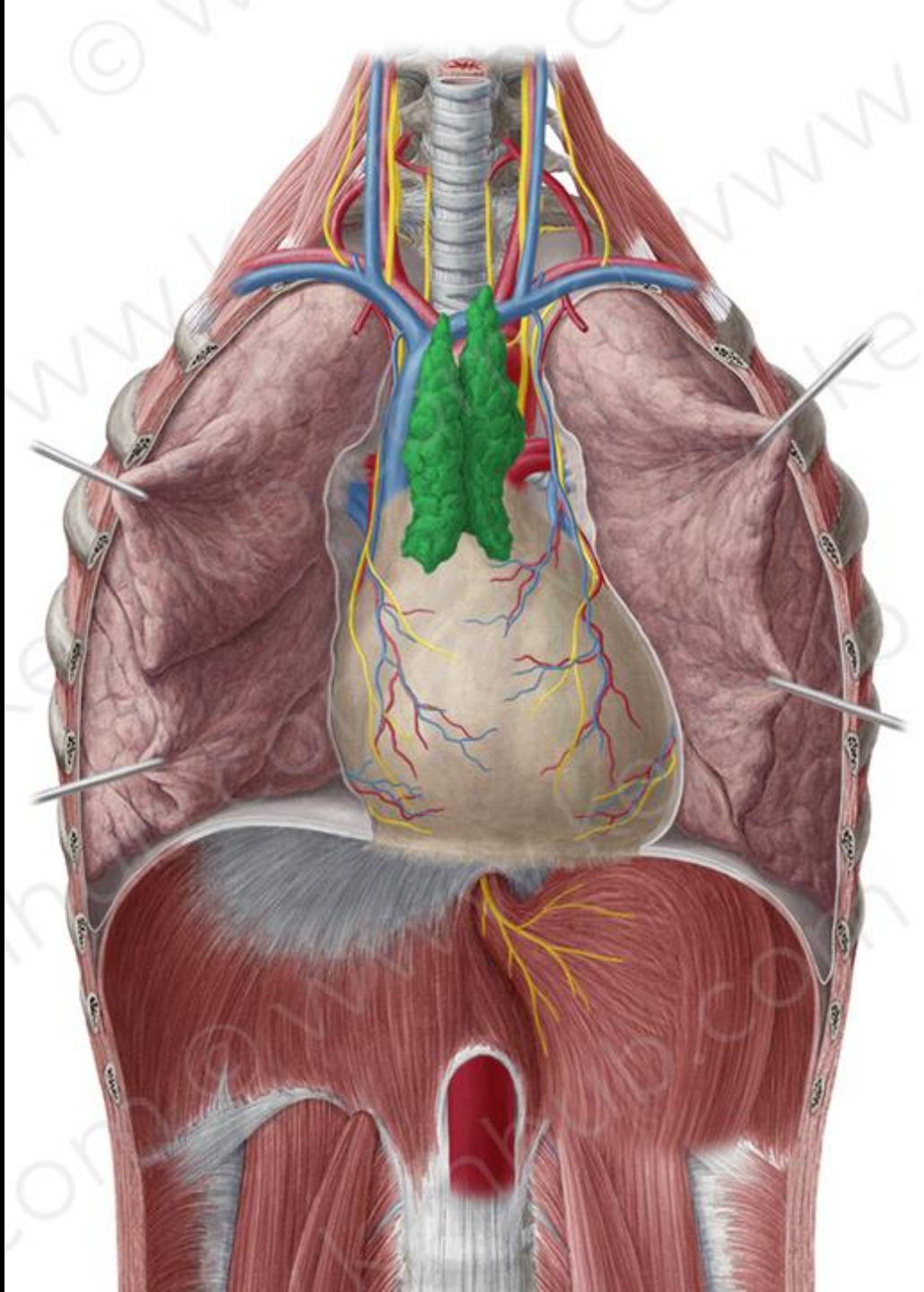


Vöröscsontvelő

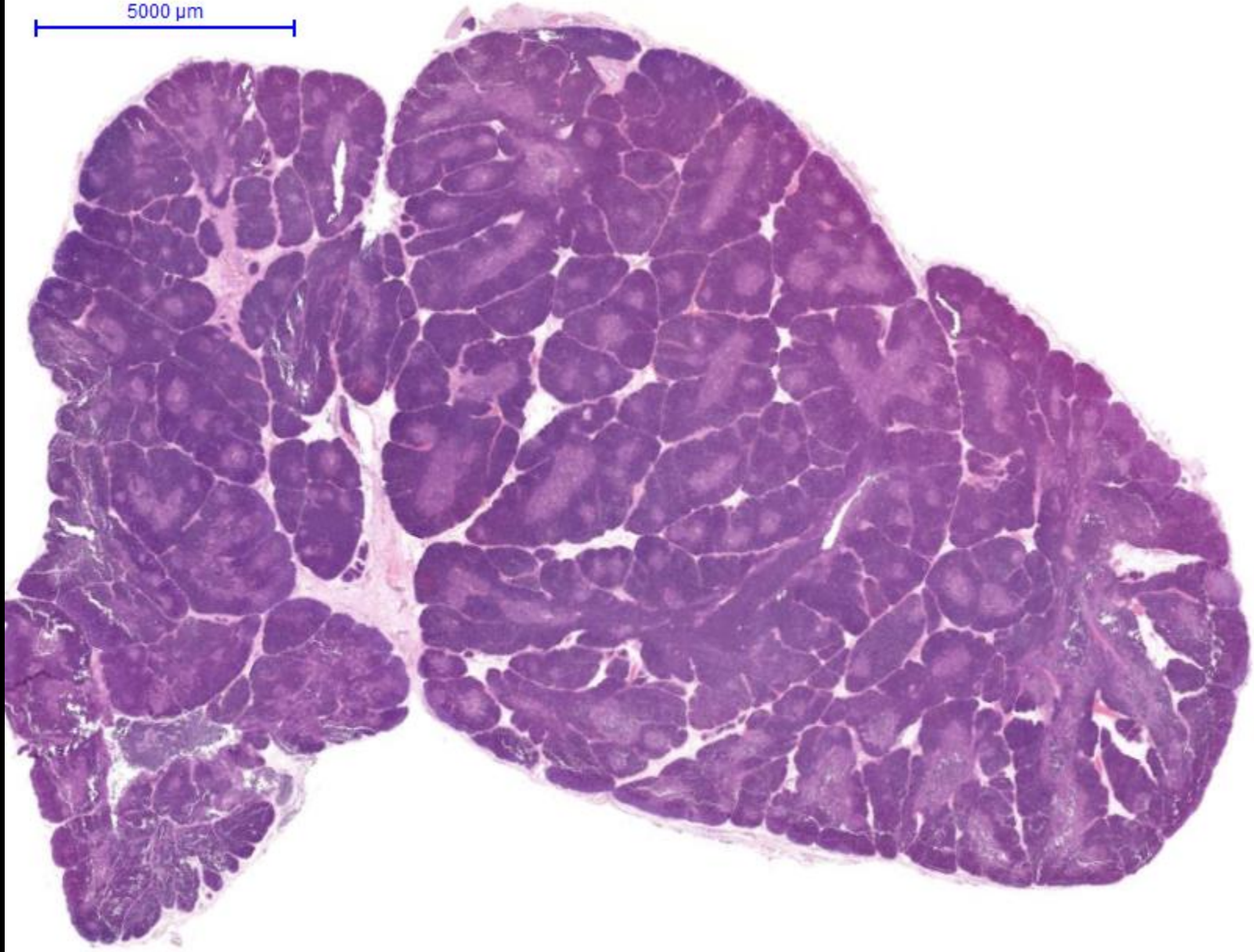


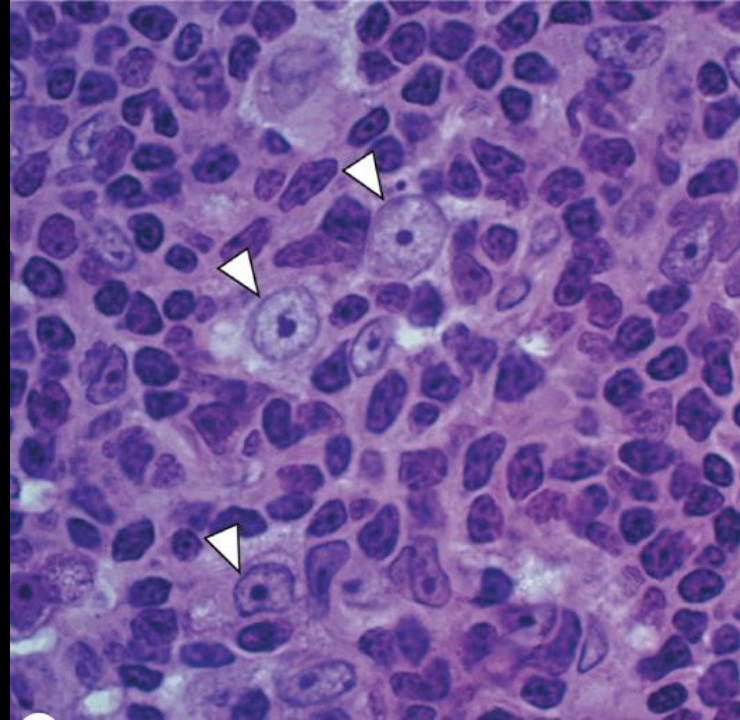
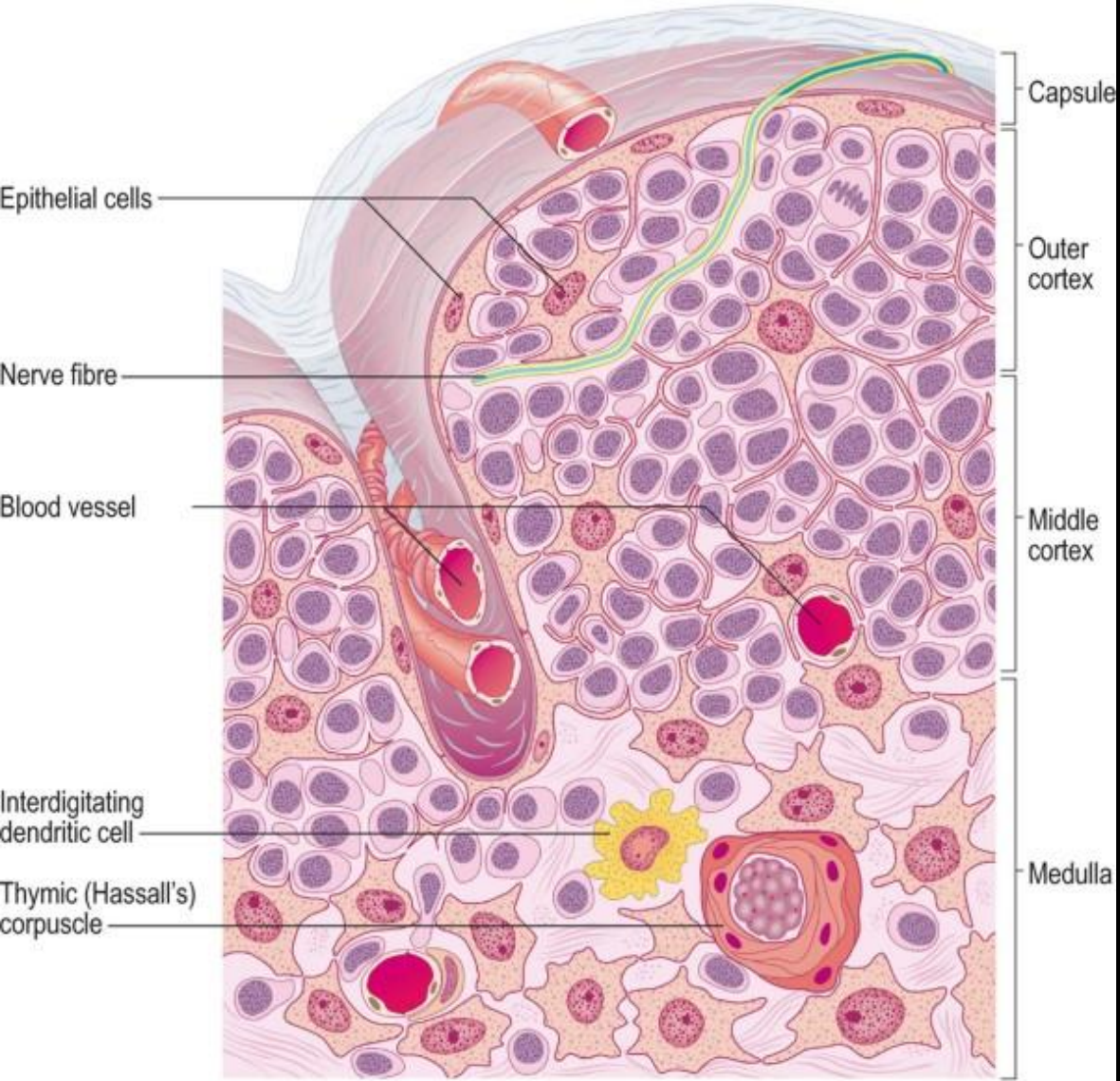
Thymus



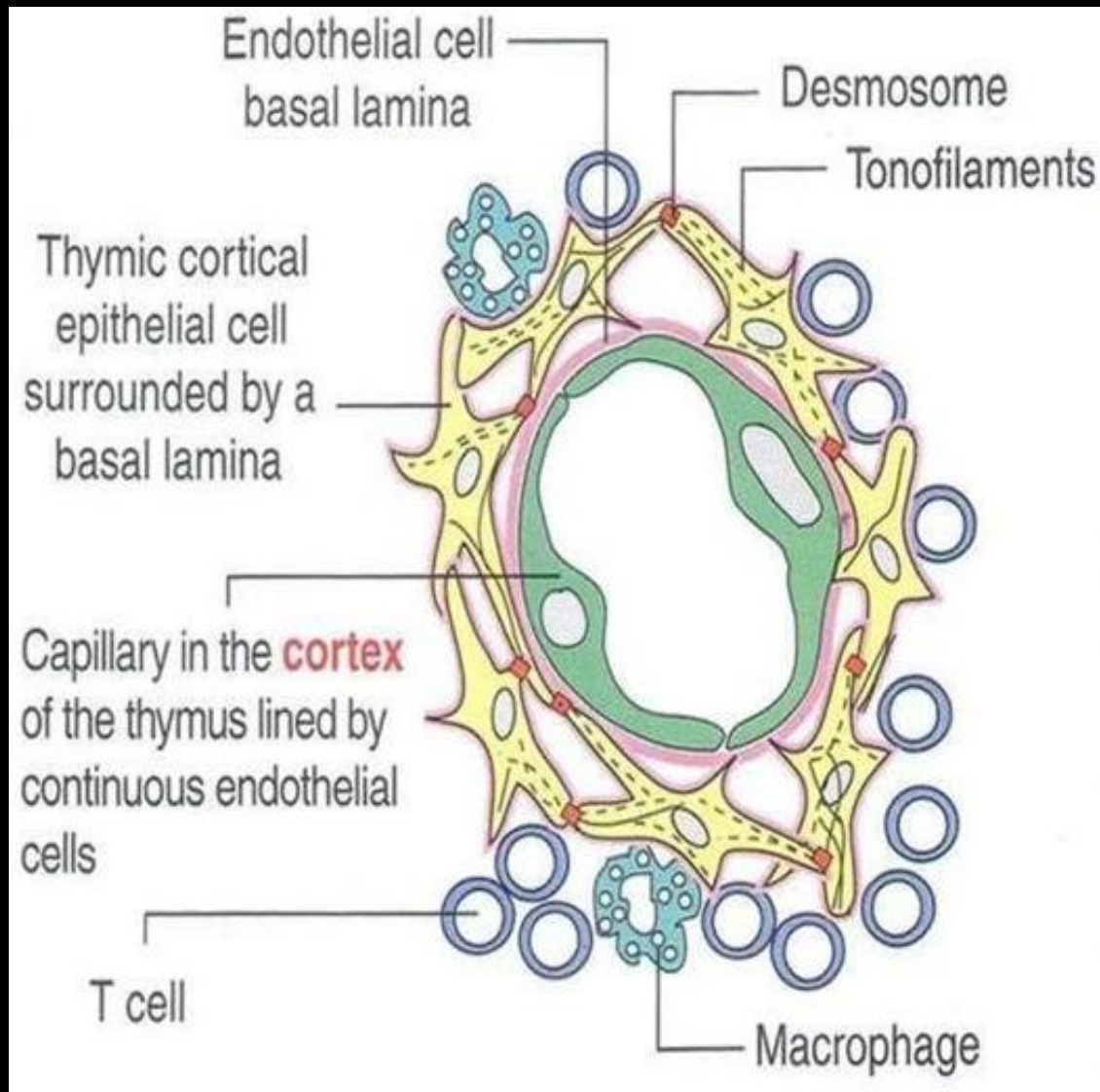


5000 μm

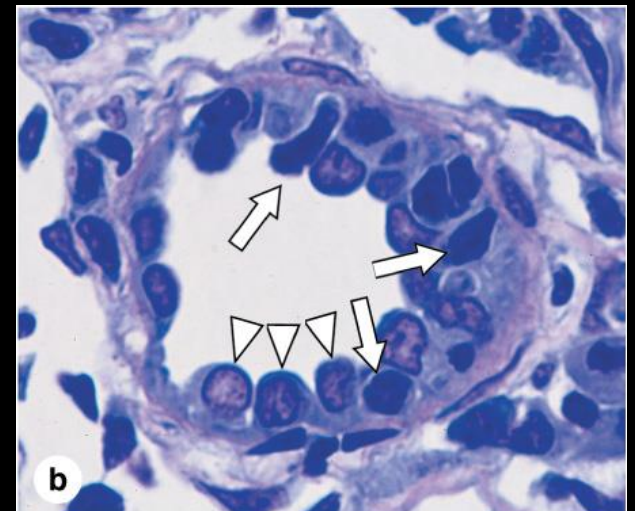
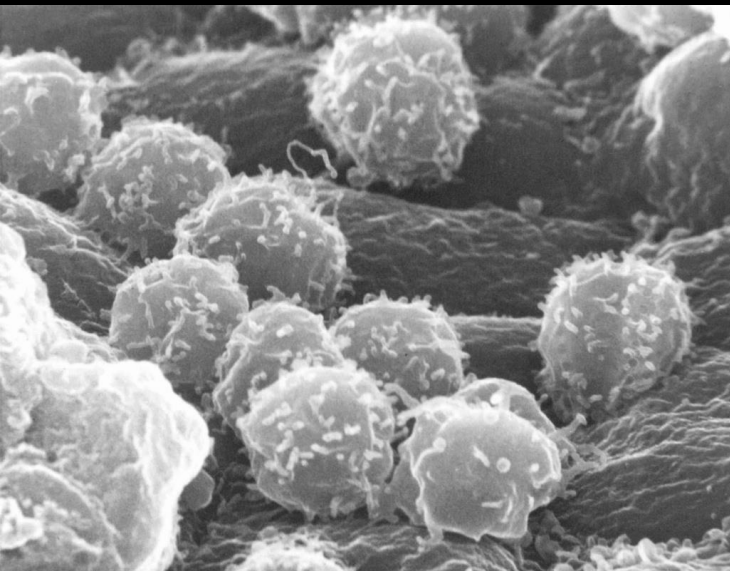
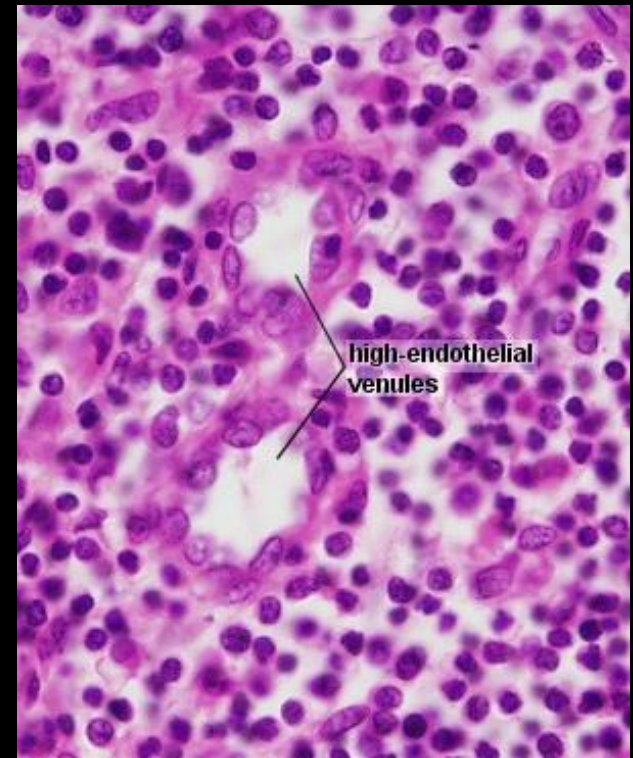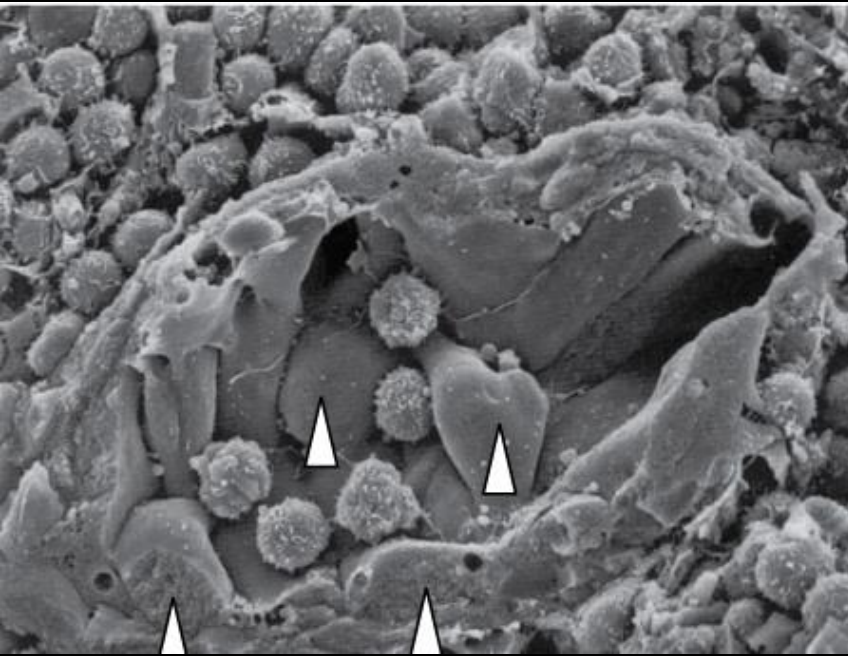




Vér-Thymus barrier

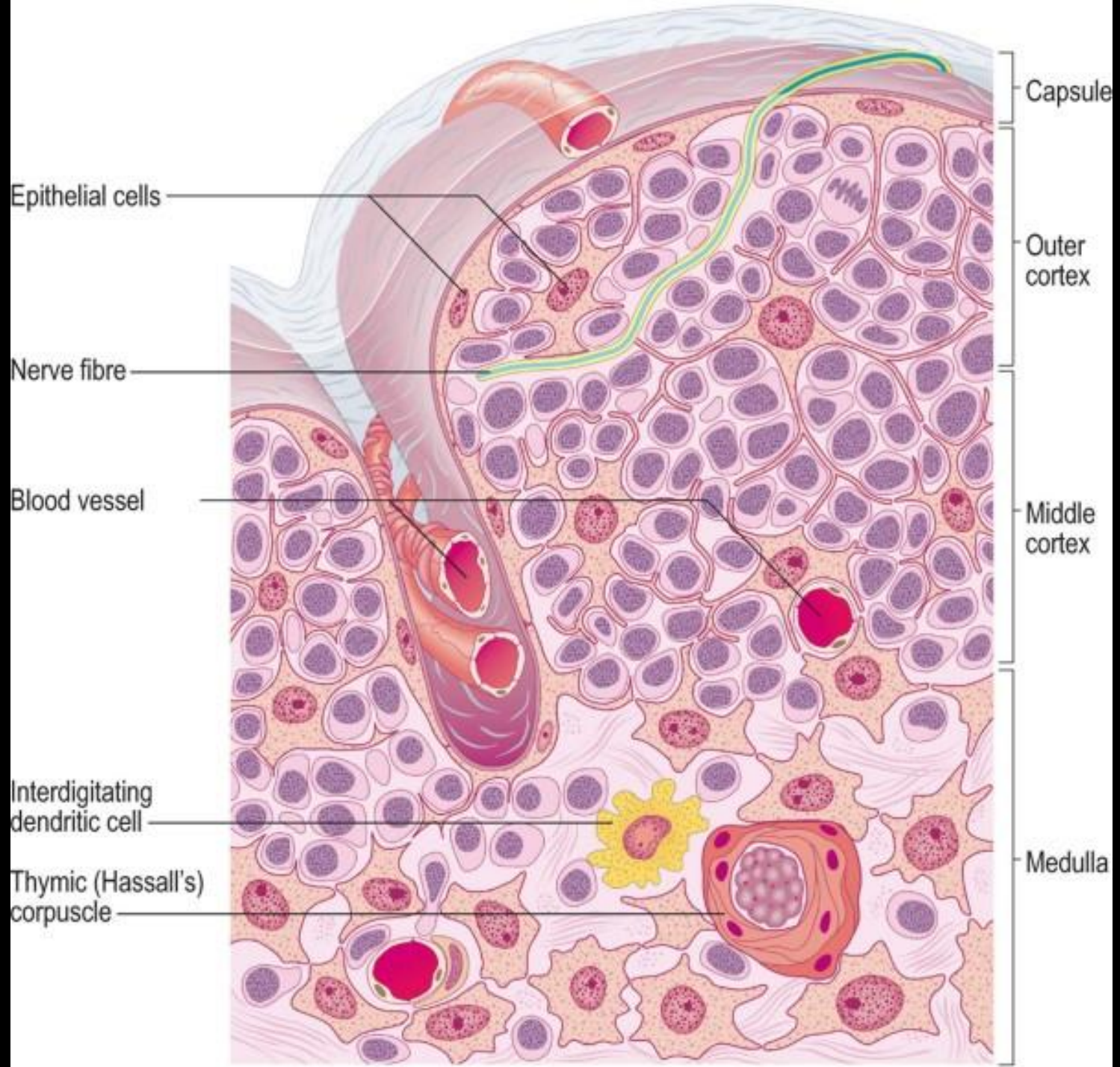


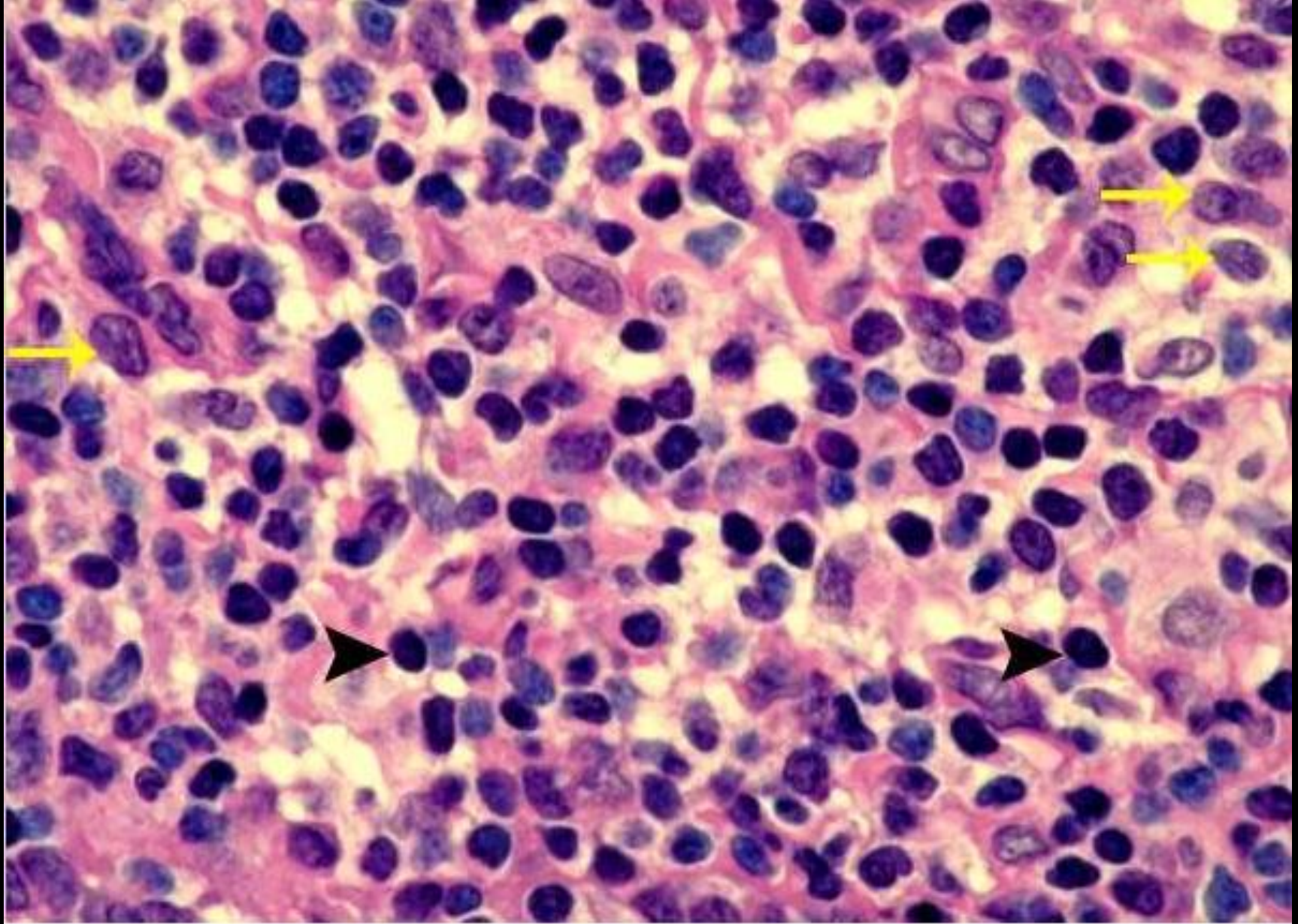
Magas endothelű venulák (HEV)



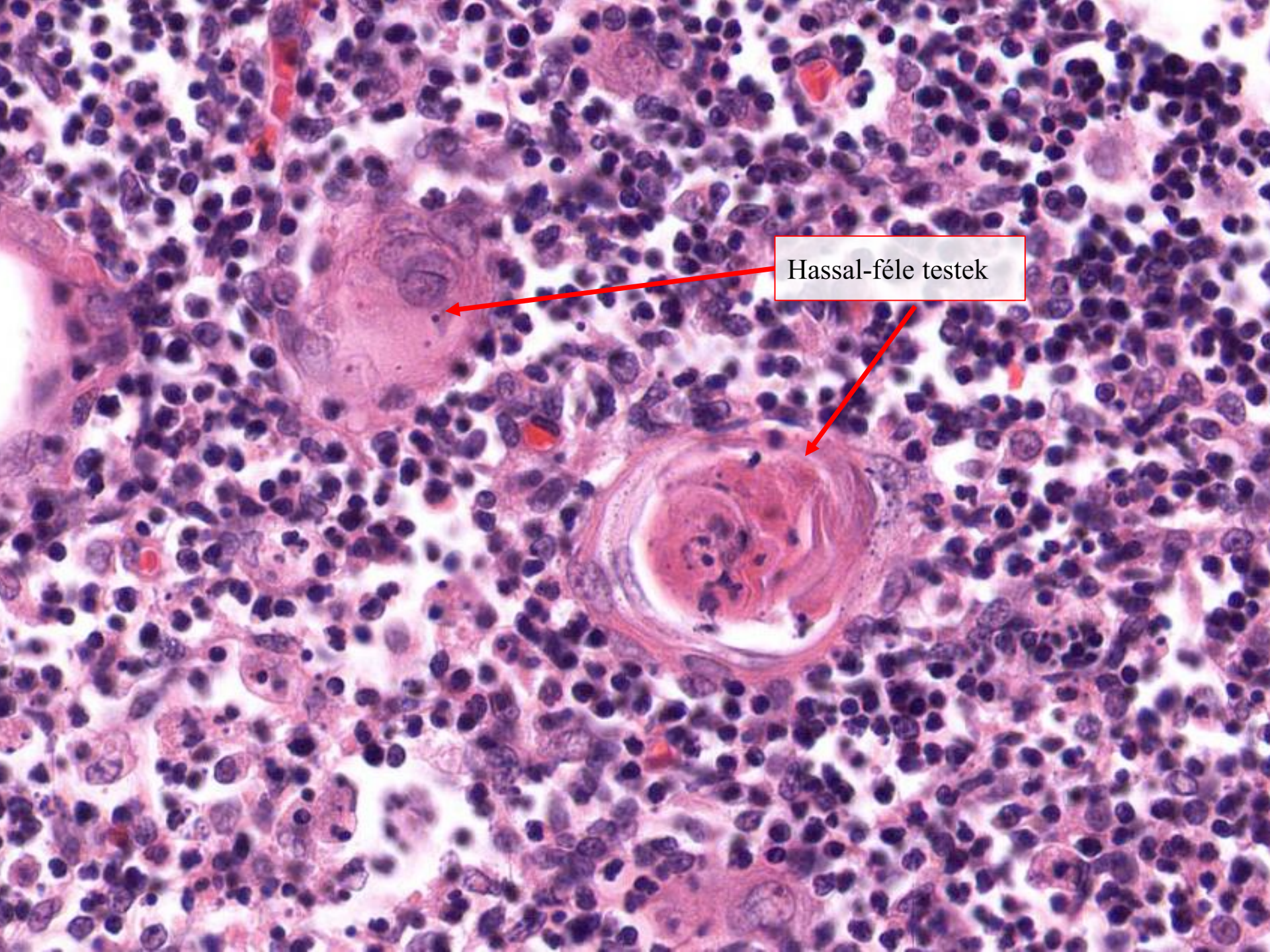
Source: Mescher AL: *Junqueira's Basic Histology: Text and Atlas, 12th Edition*: <http://www.accessmedicine.com>

Copyright © The McGraw-Hill Companies, Inc. All rights reserved.

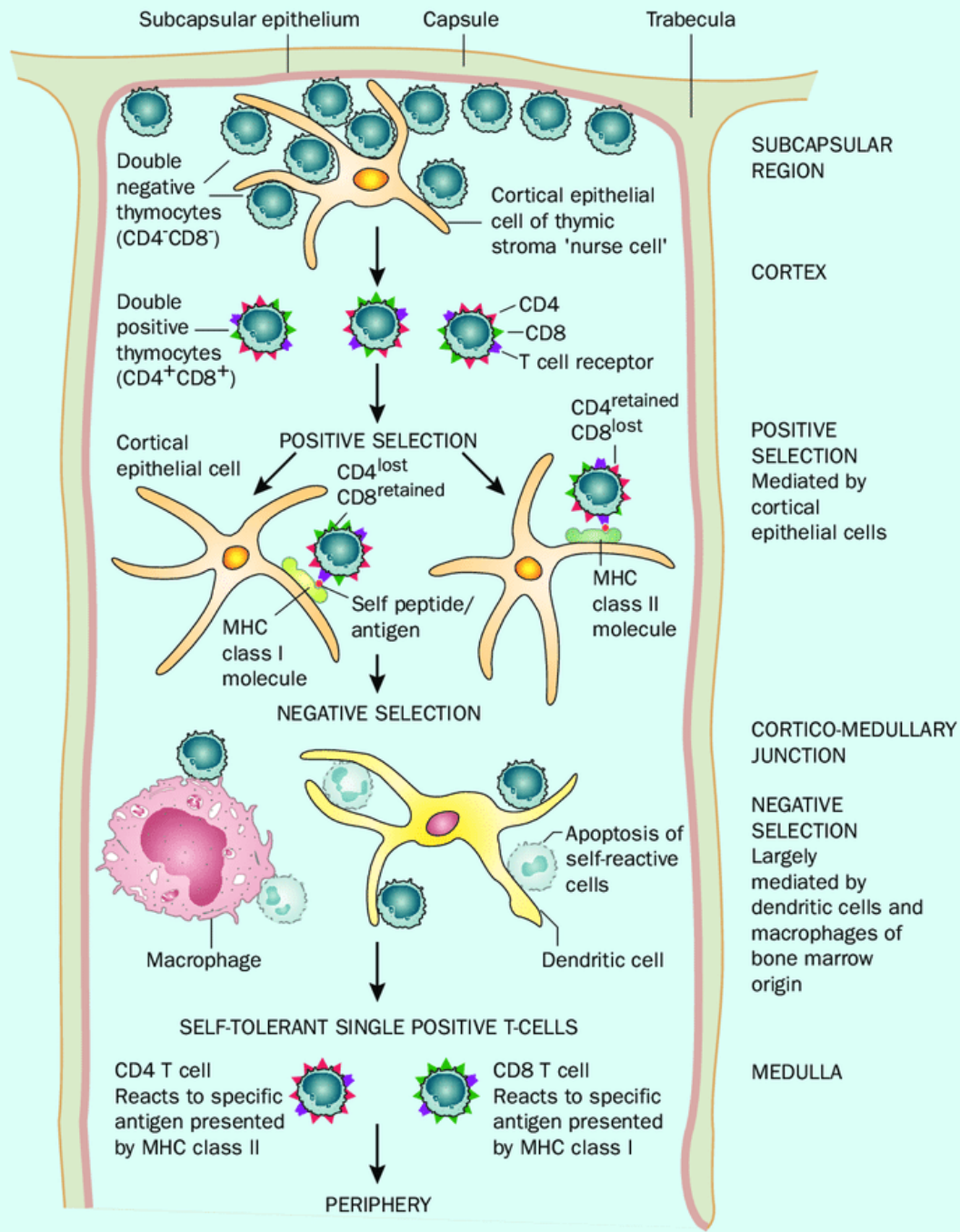




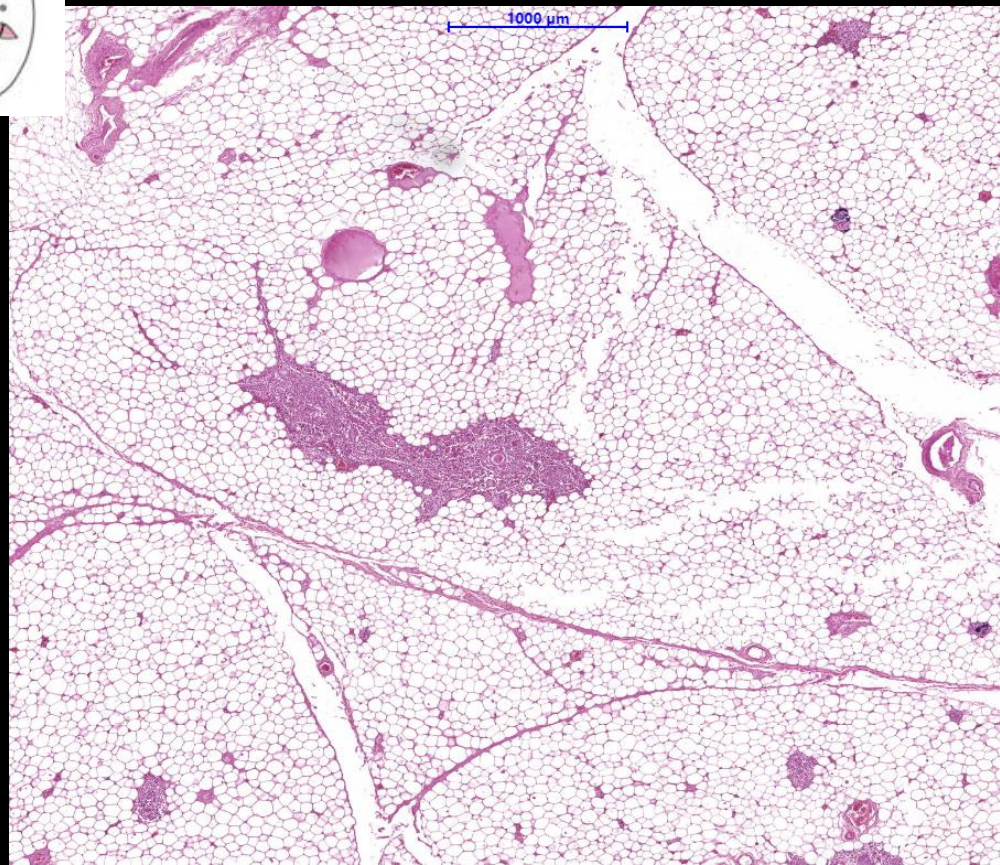
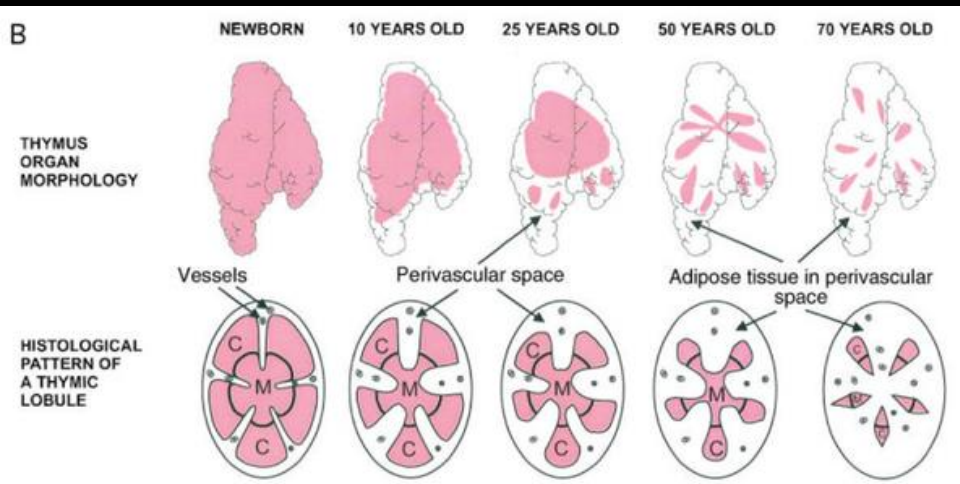
[THYMUS HISTOLOGY]. The thymic medulla contains fewer thymocytes than the cortex (arrowheads). The thymocytes here are either CD4+ or CD8+ and do not express CD1. The thymic epithelial cells are larger cells with pale cytoplasm and round to oval nuclei (arrows).



Hassal-féle testek

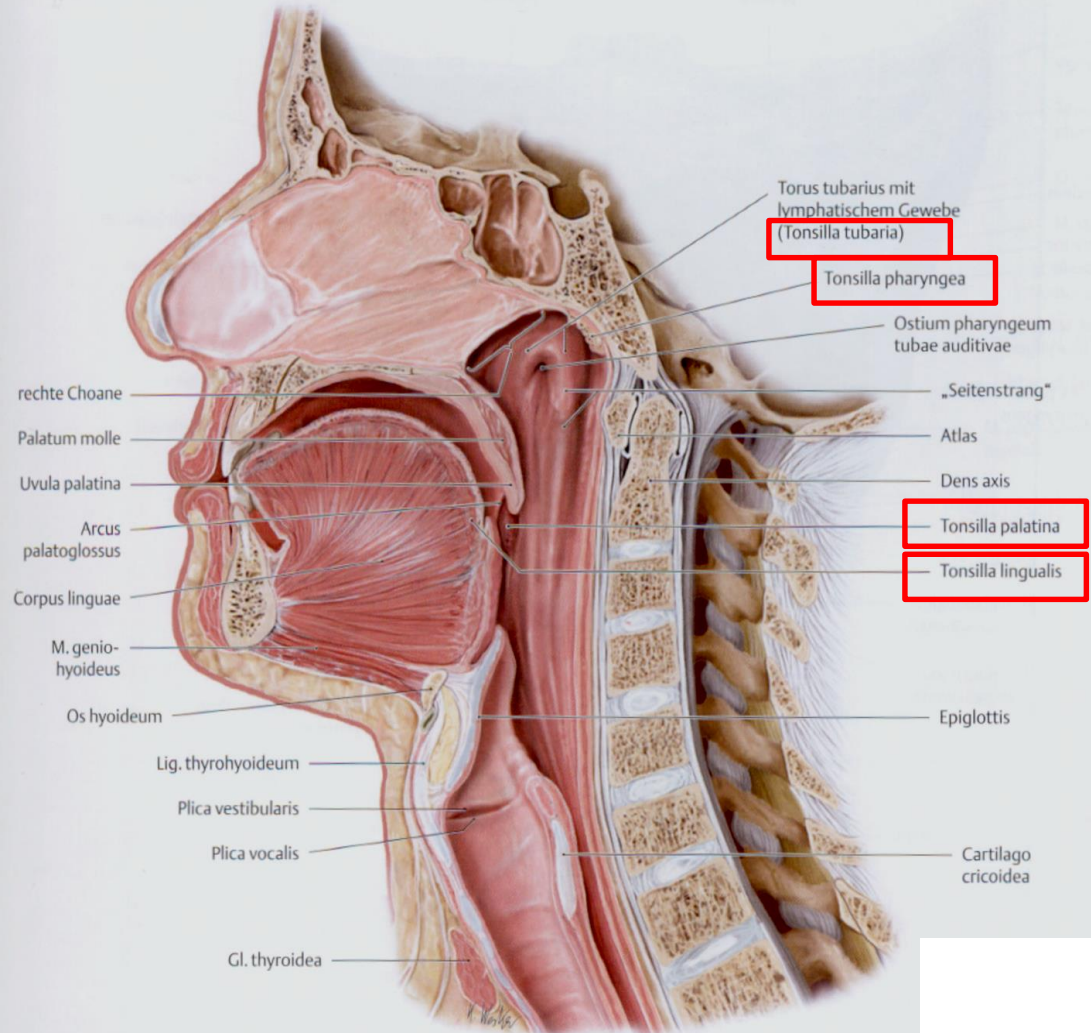


Thymus adiposus

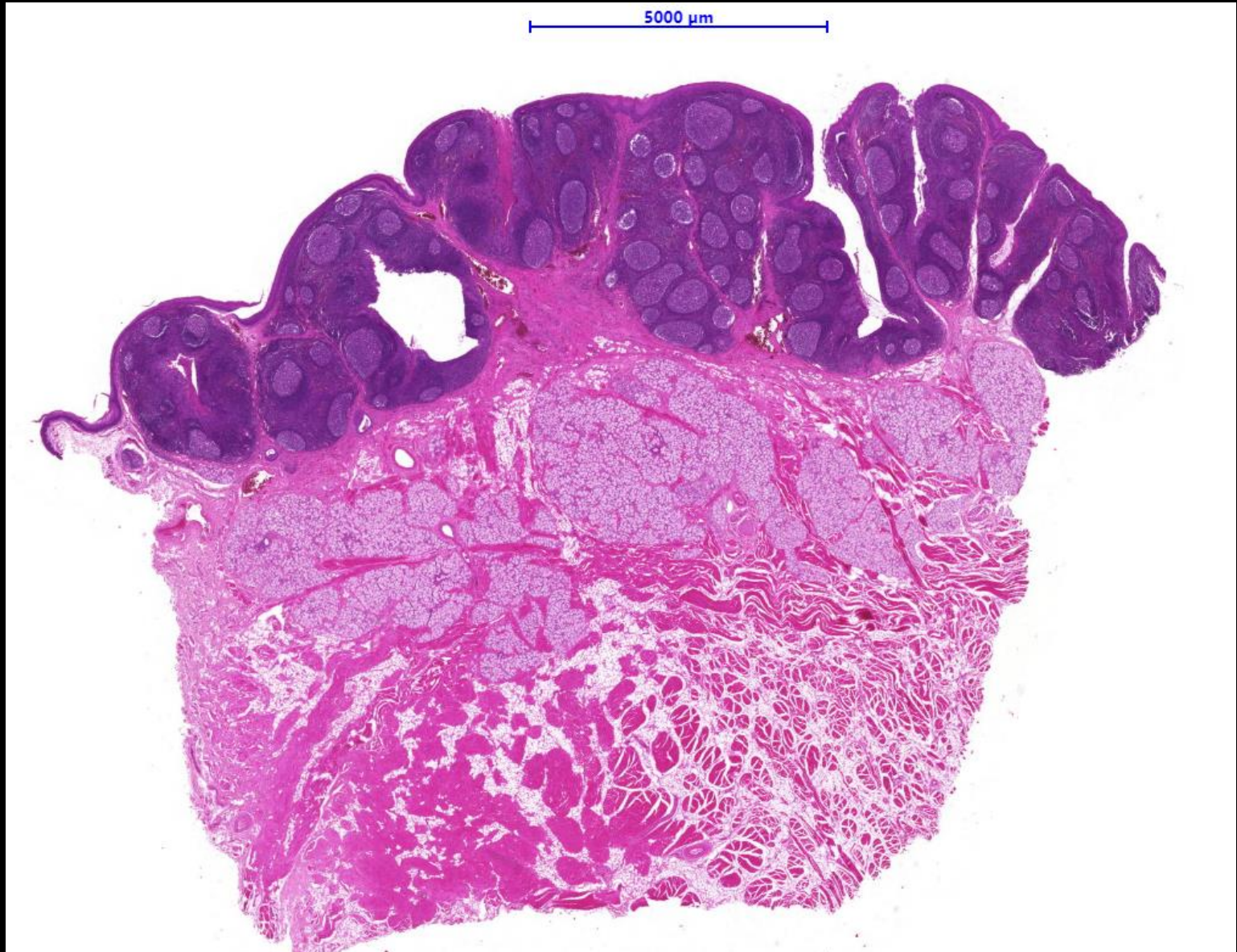


GALT (bélrendszerhez asszociált nyirokszövet)

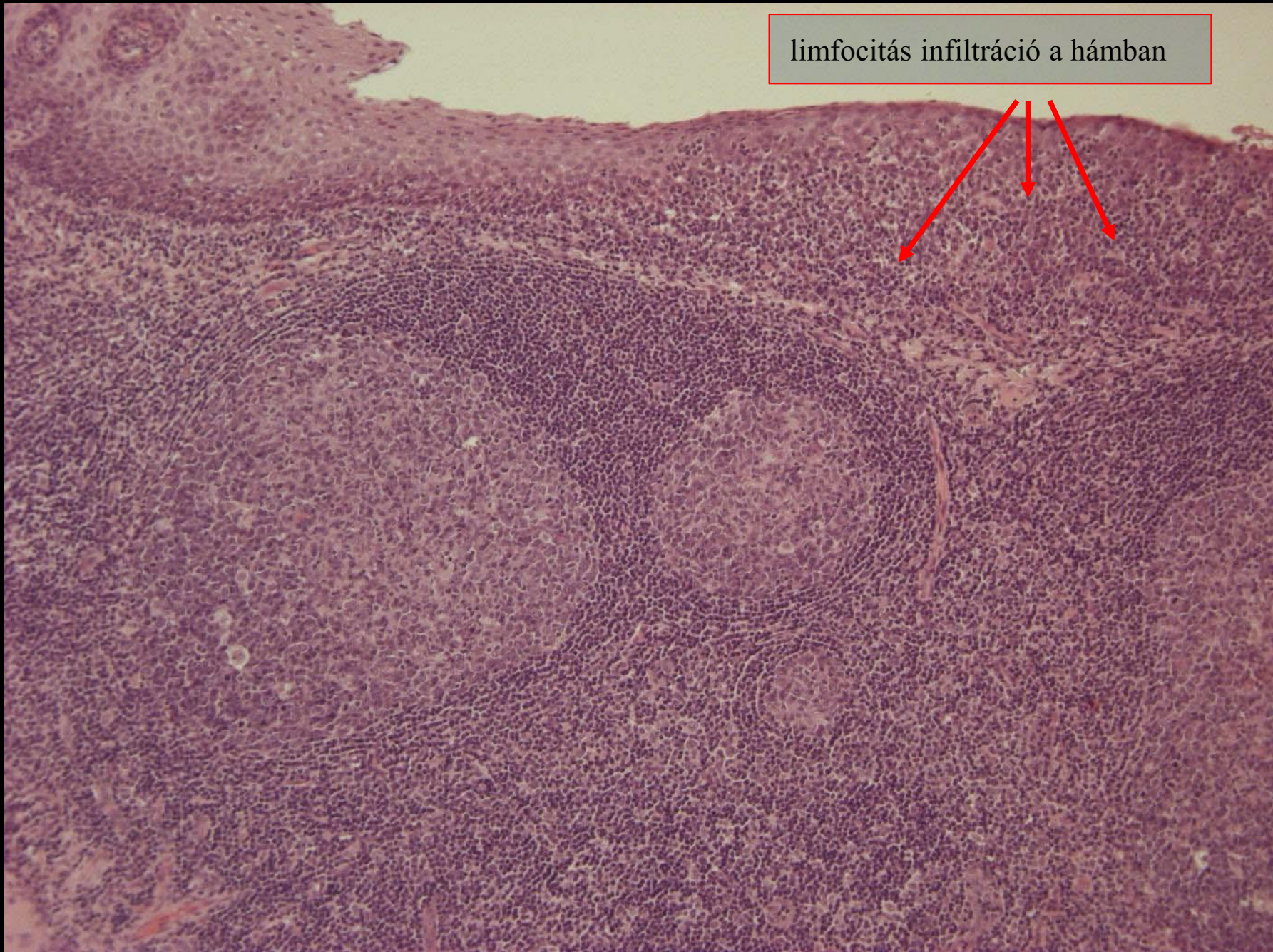
Tonsillák (mandulák)



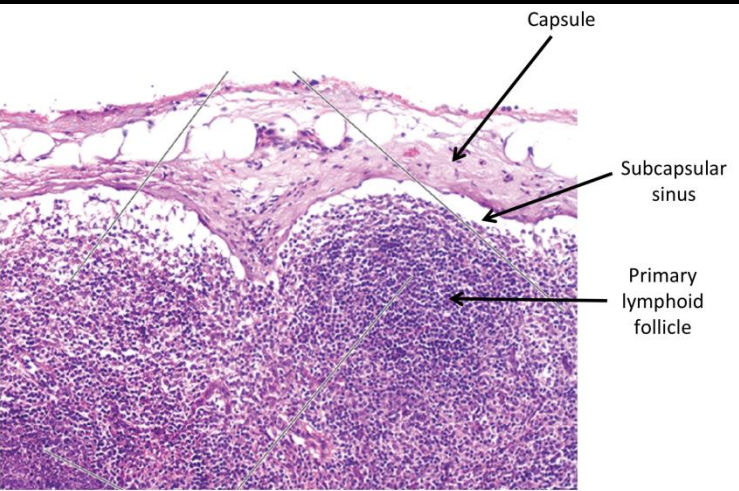
Tonsilla lingualis



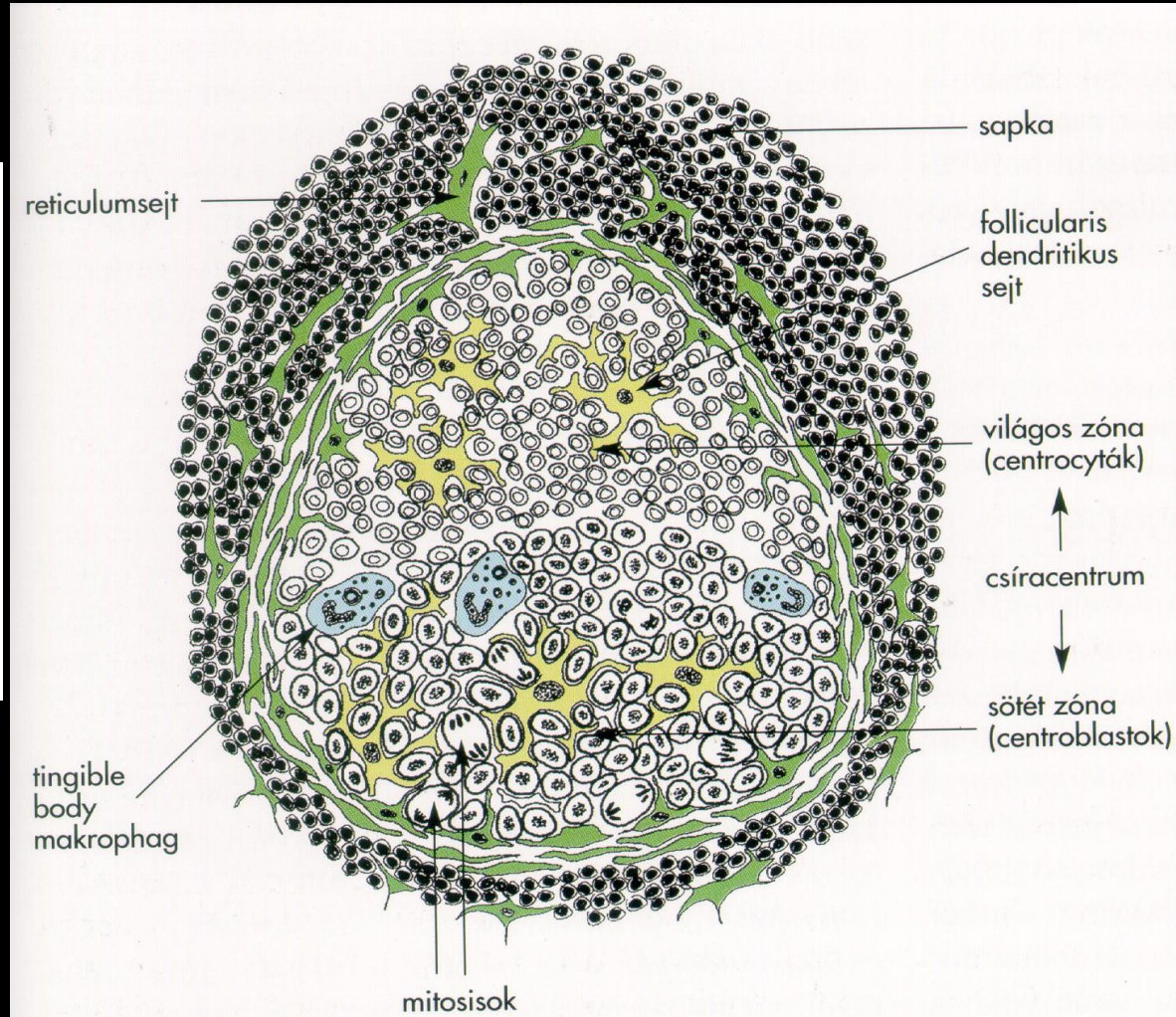
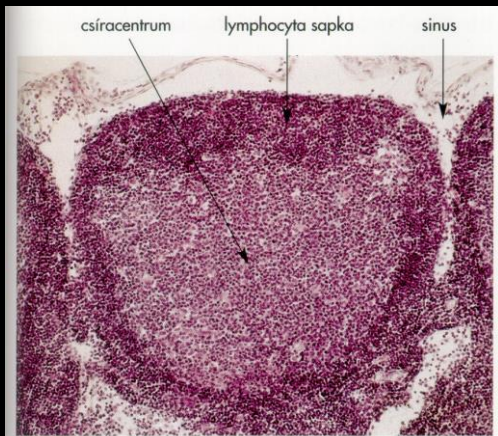
limfocitás infiltráció a hámban



Folliculus lymphaticus

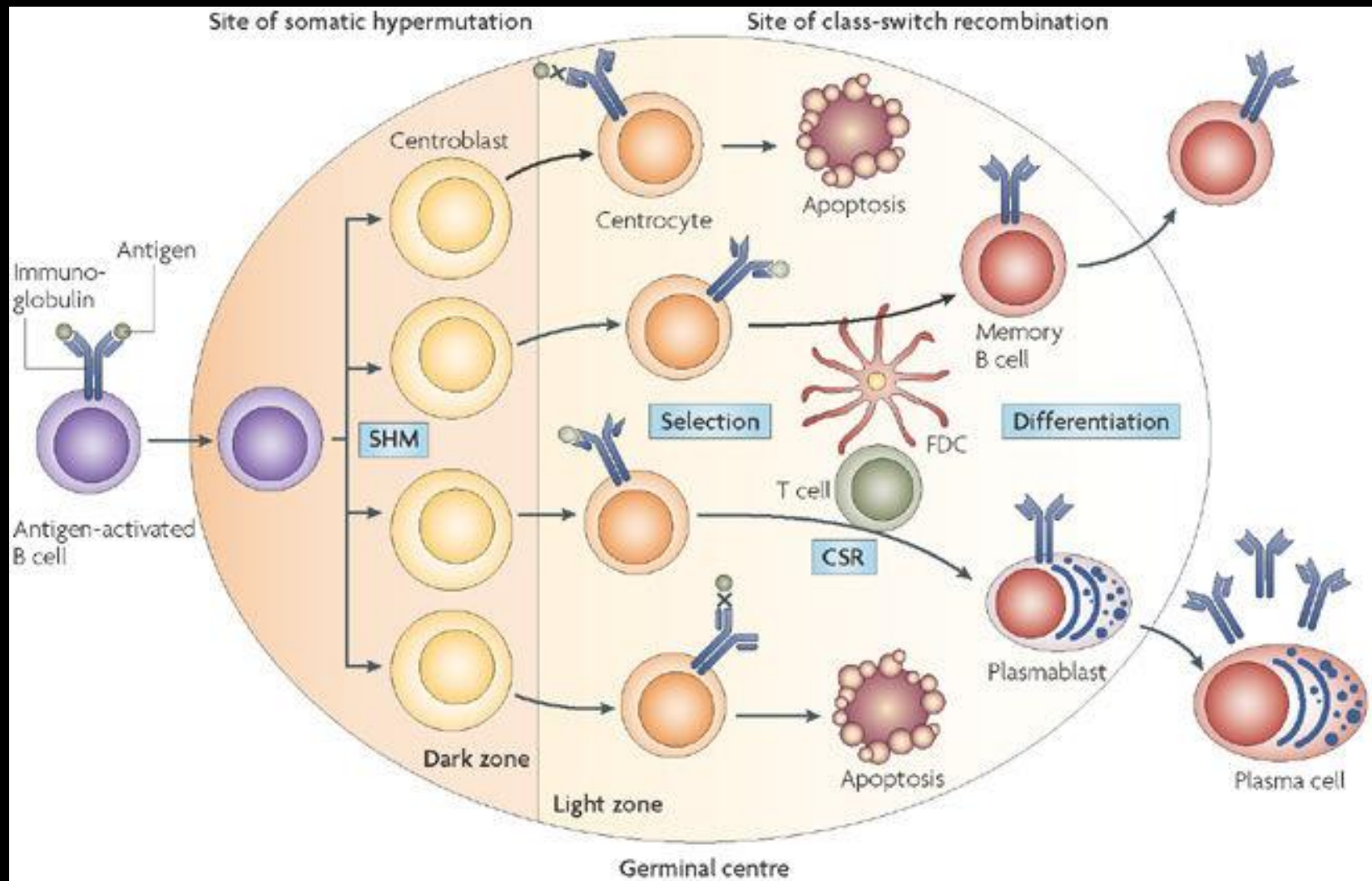


Lymph node: primary follicles



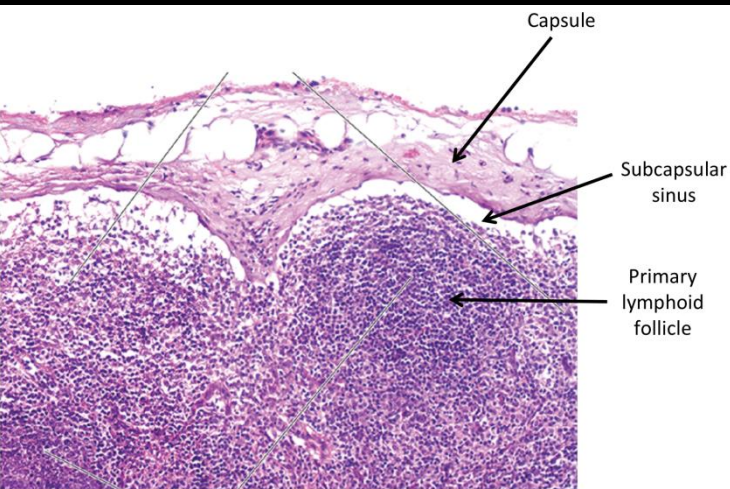
secunder nyiroktüsző

Csíracentrum-reakció

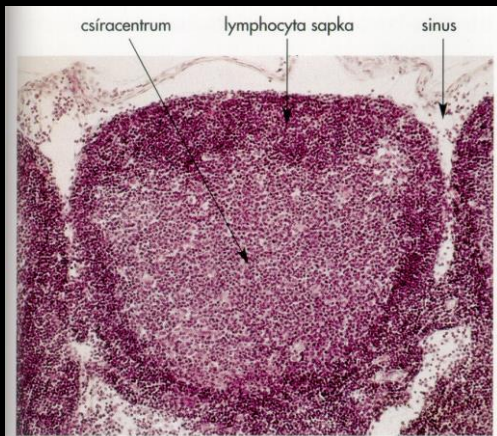


Folliculus lymphaticus

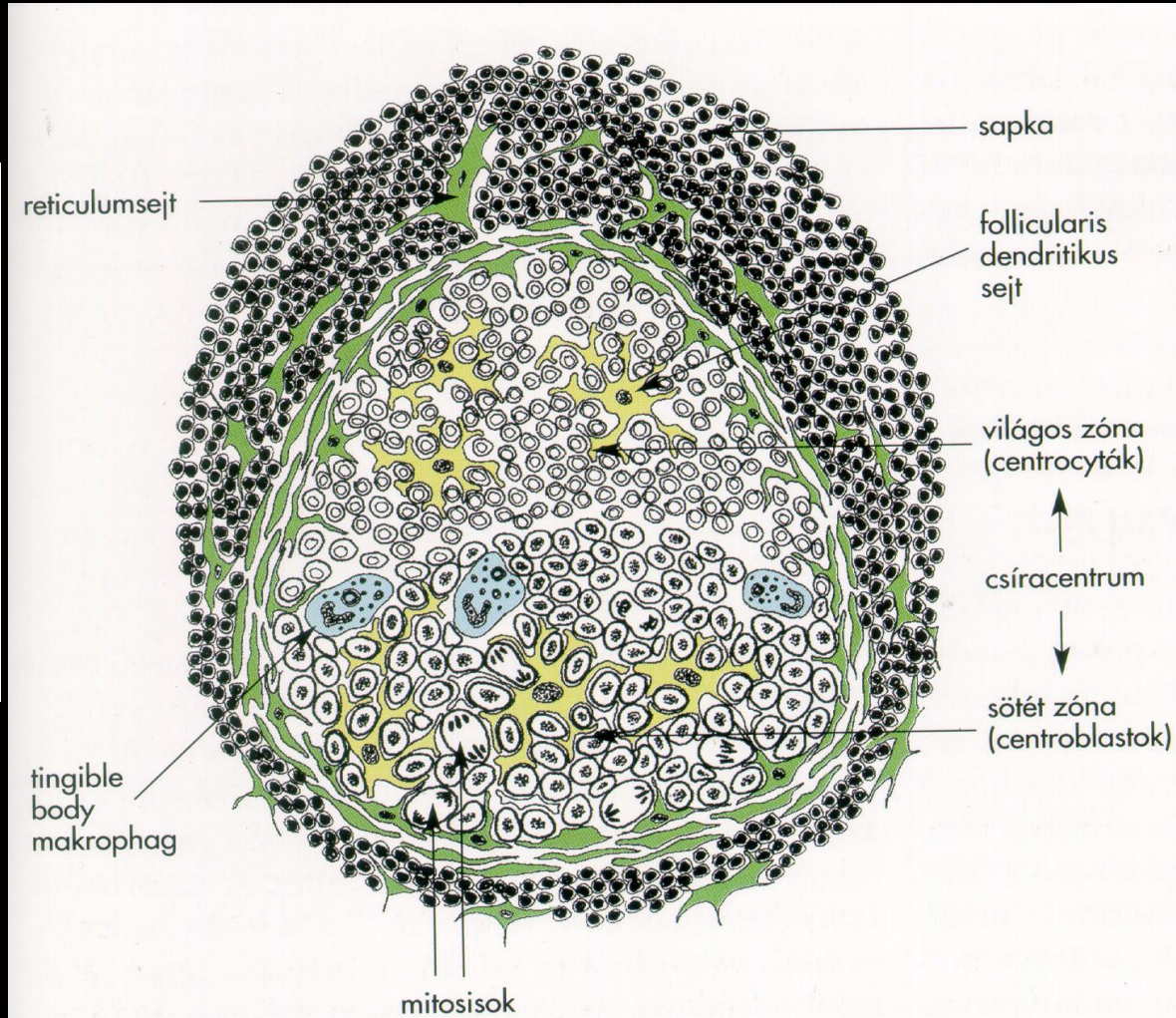
primér nyiroktüsző

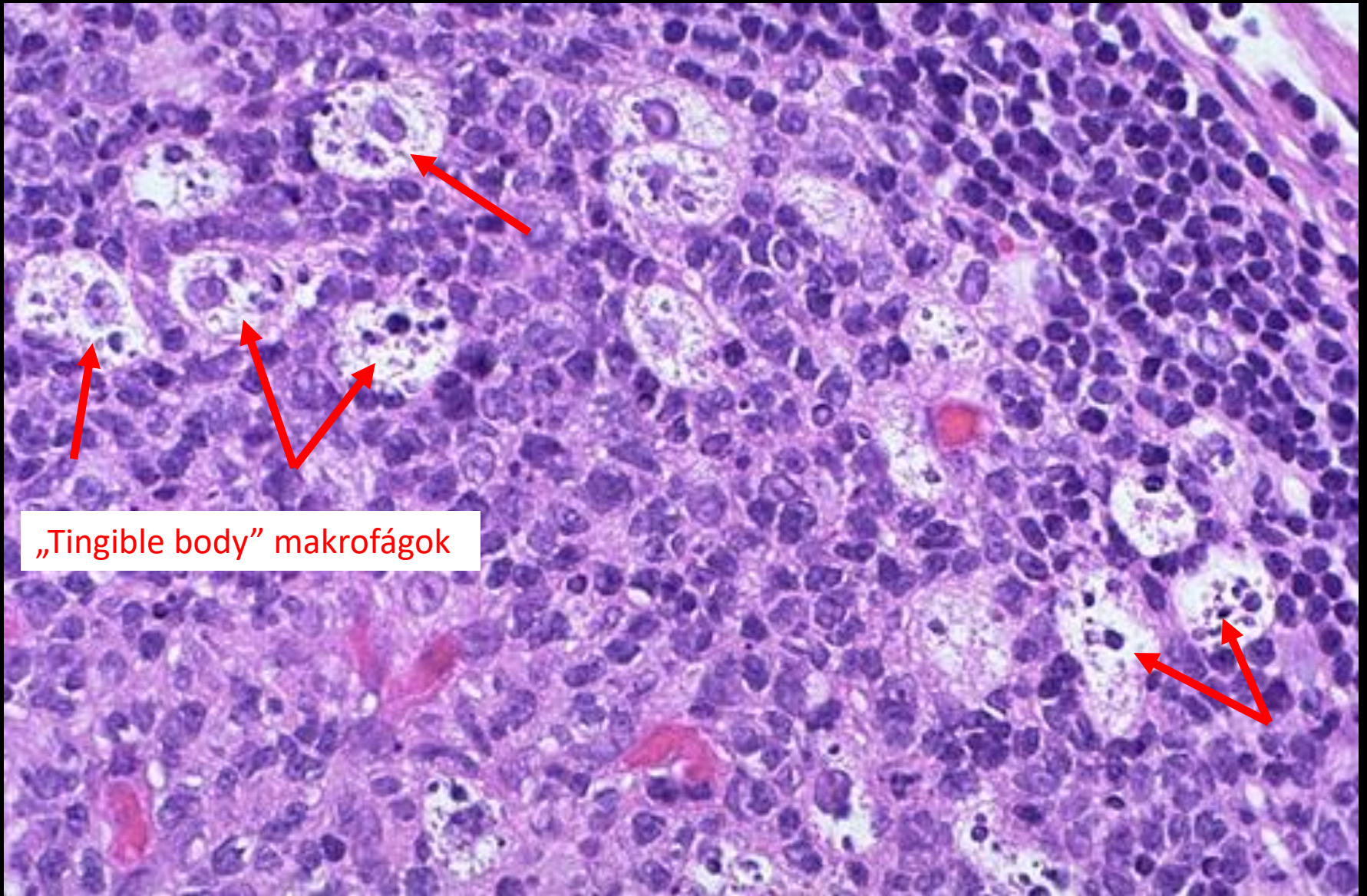


Lymph node: primary follicles



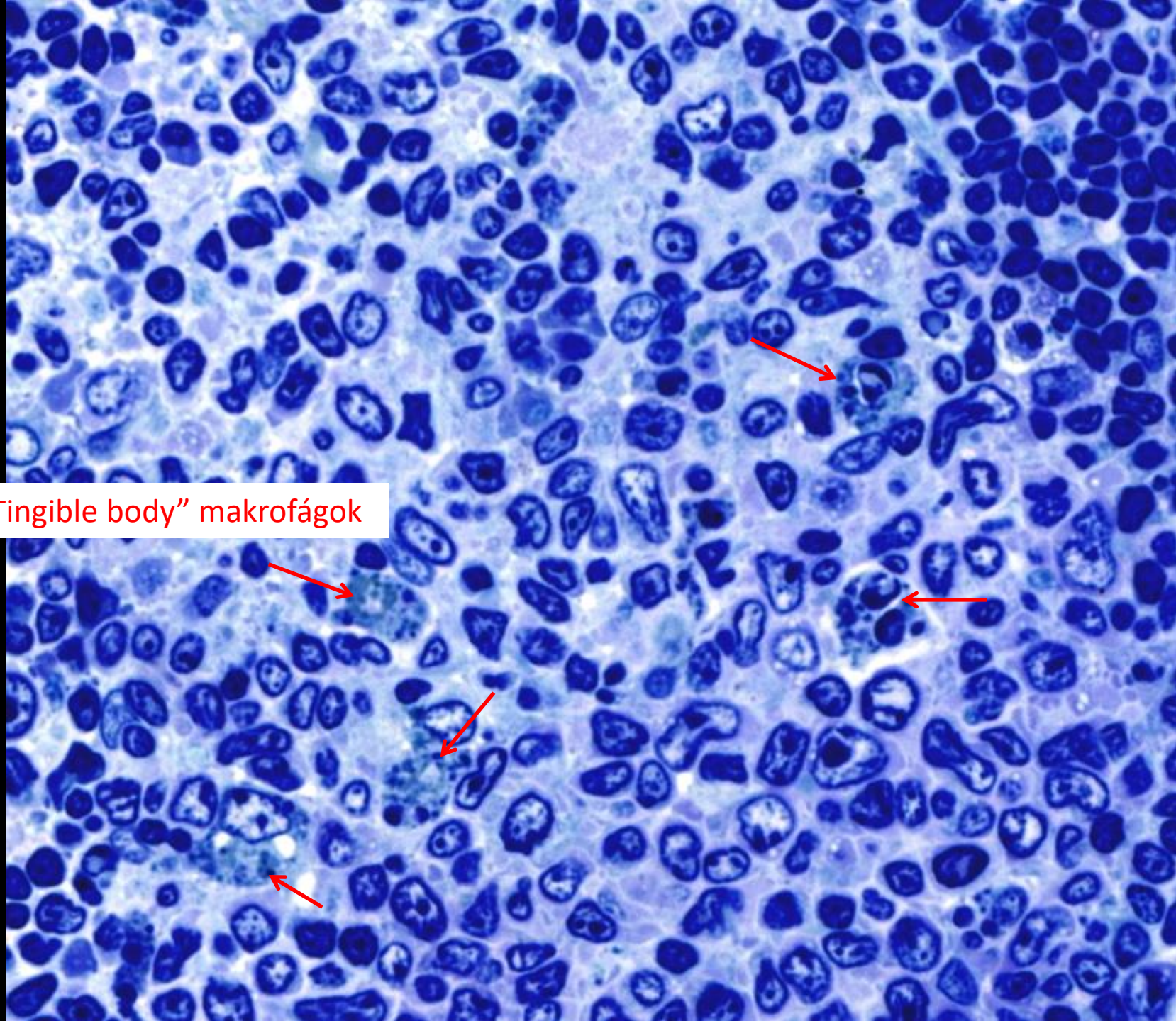
secunder nyiroktüsző



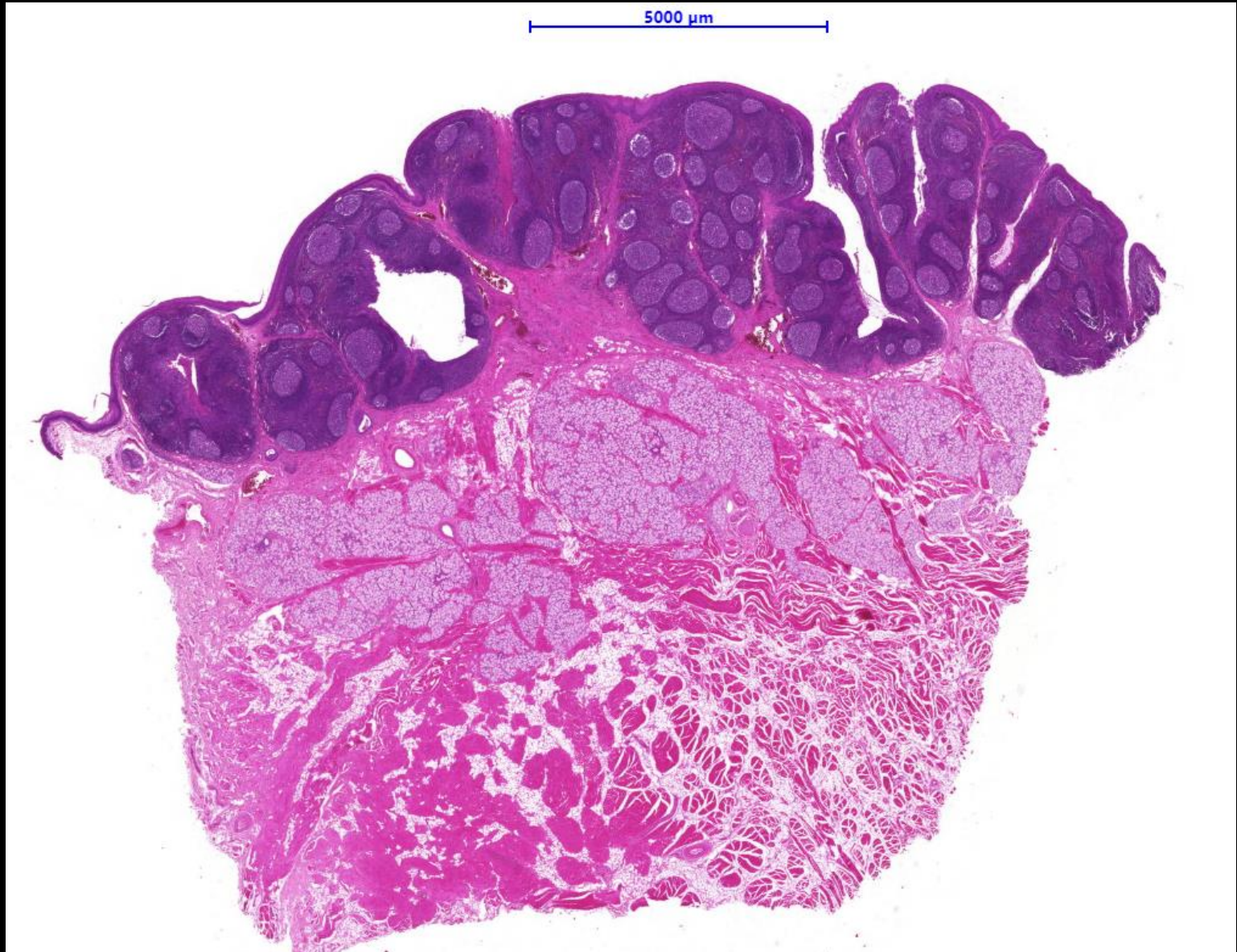


„Tingible body” makrofágok

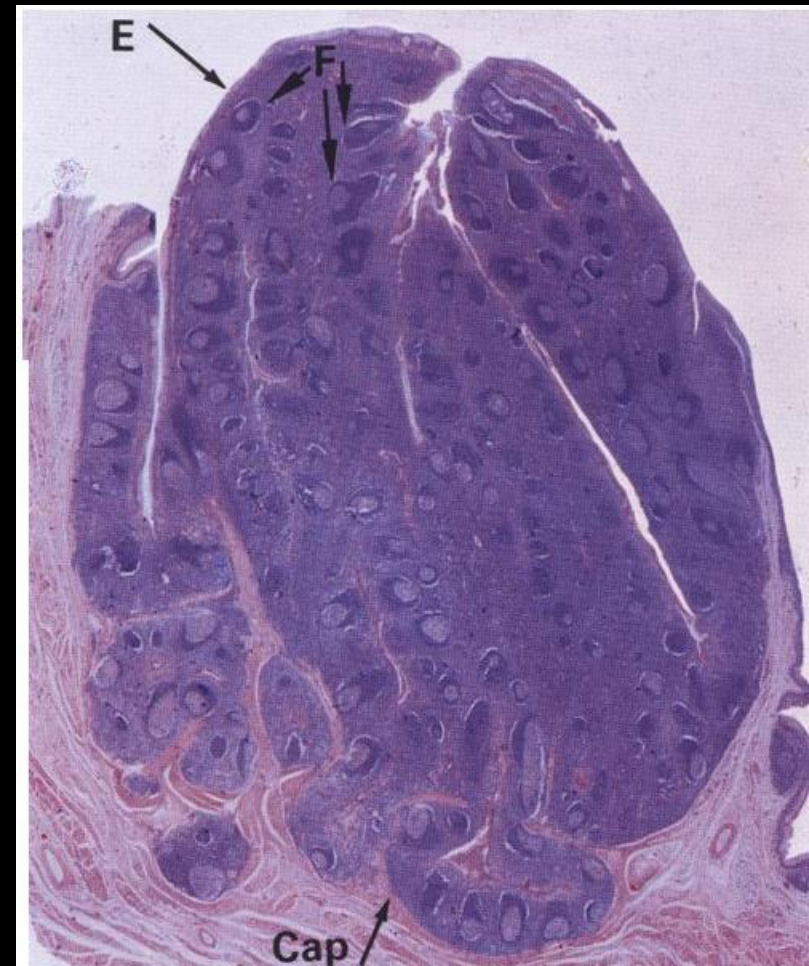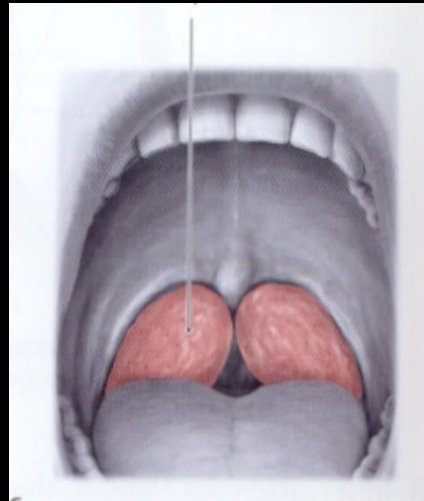
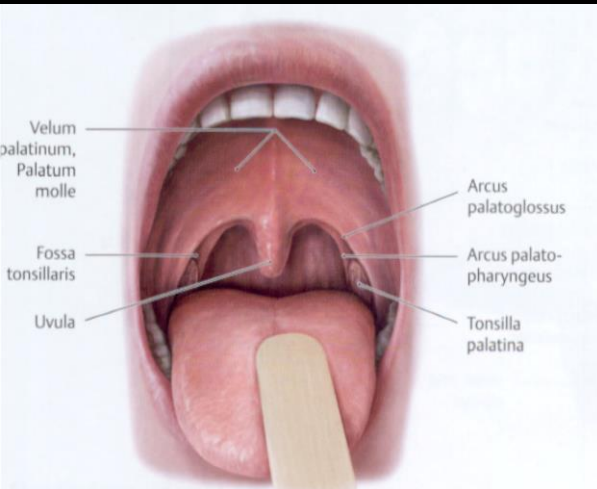
„Tingible body” makrofágok



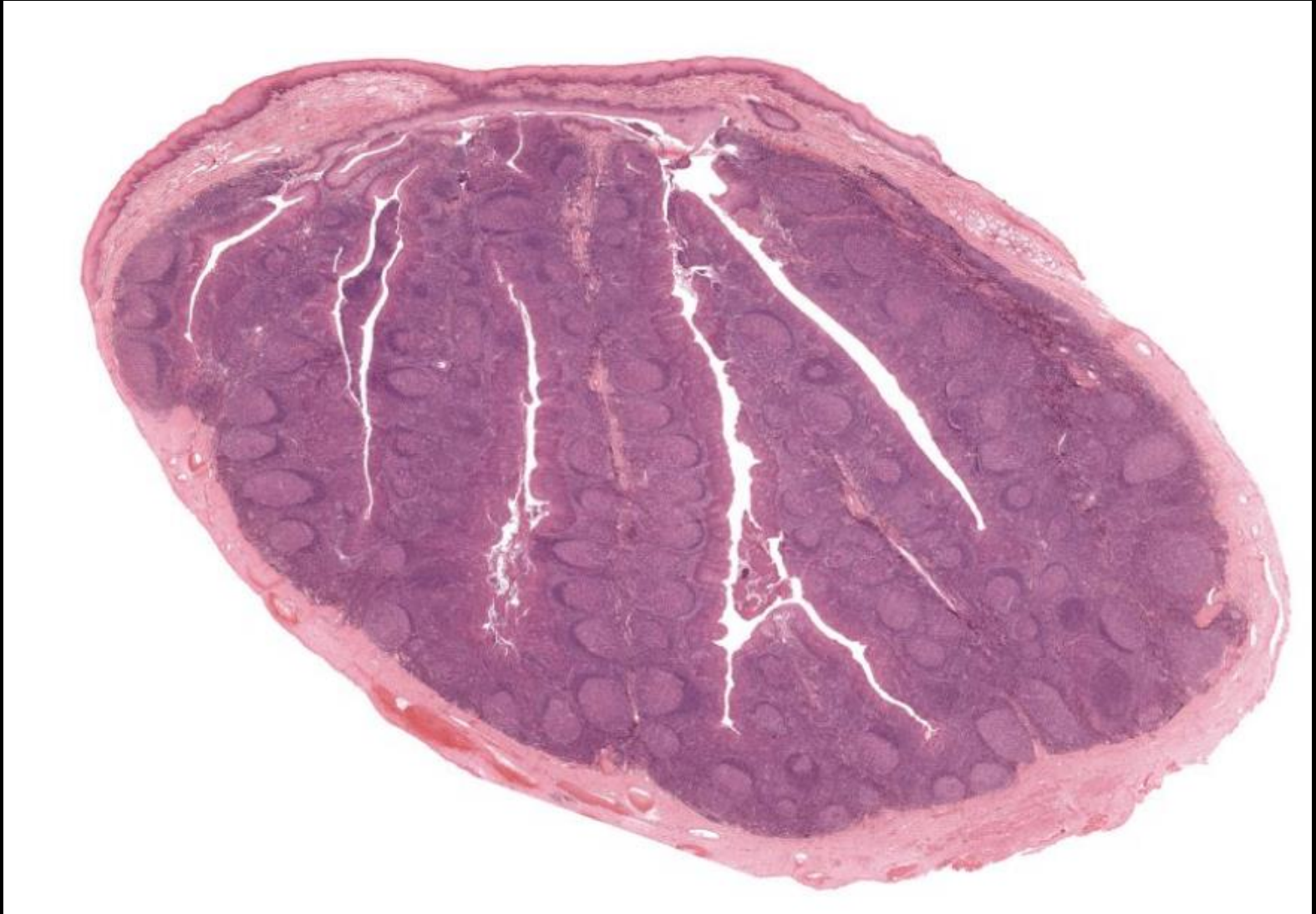Tonsilla lingualis



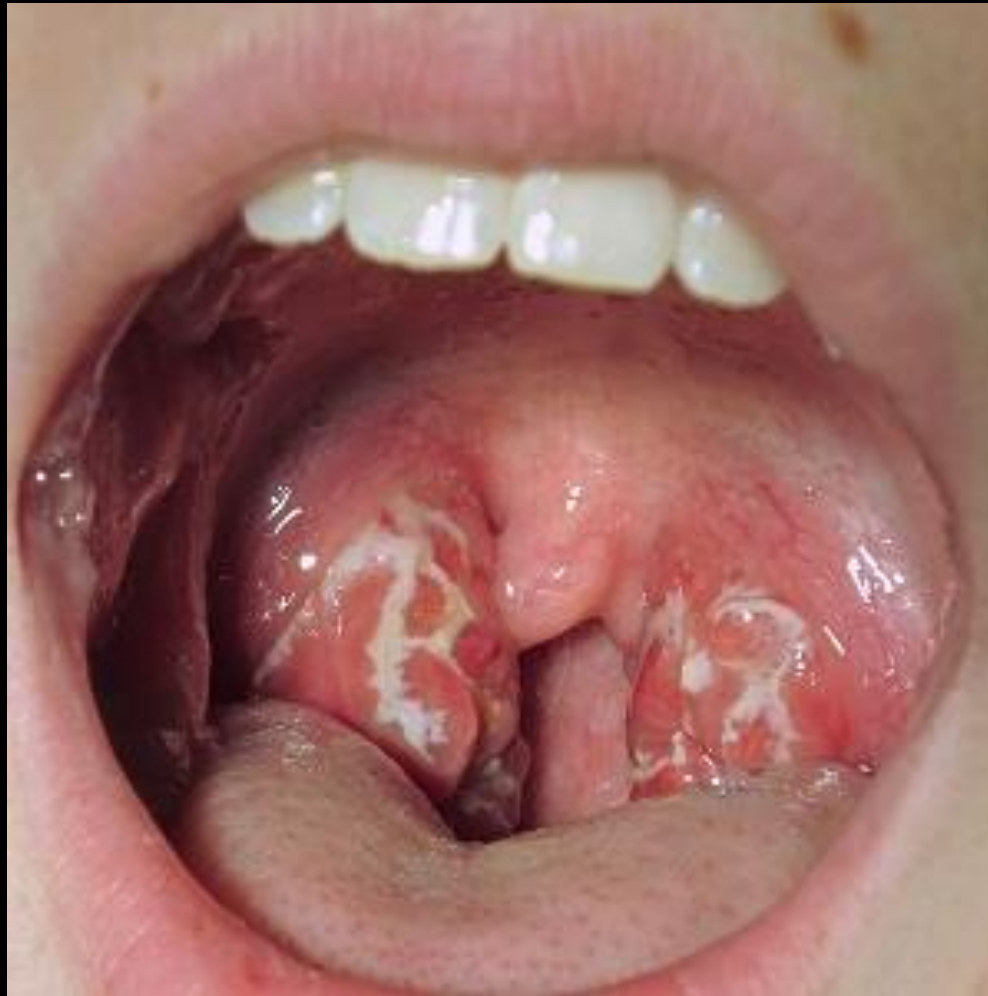Tonsilla palatina



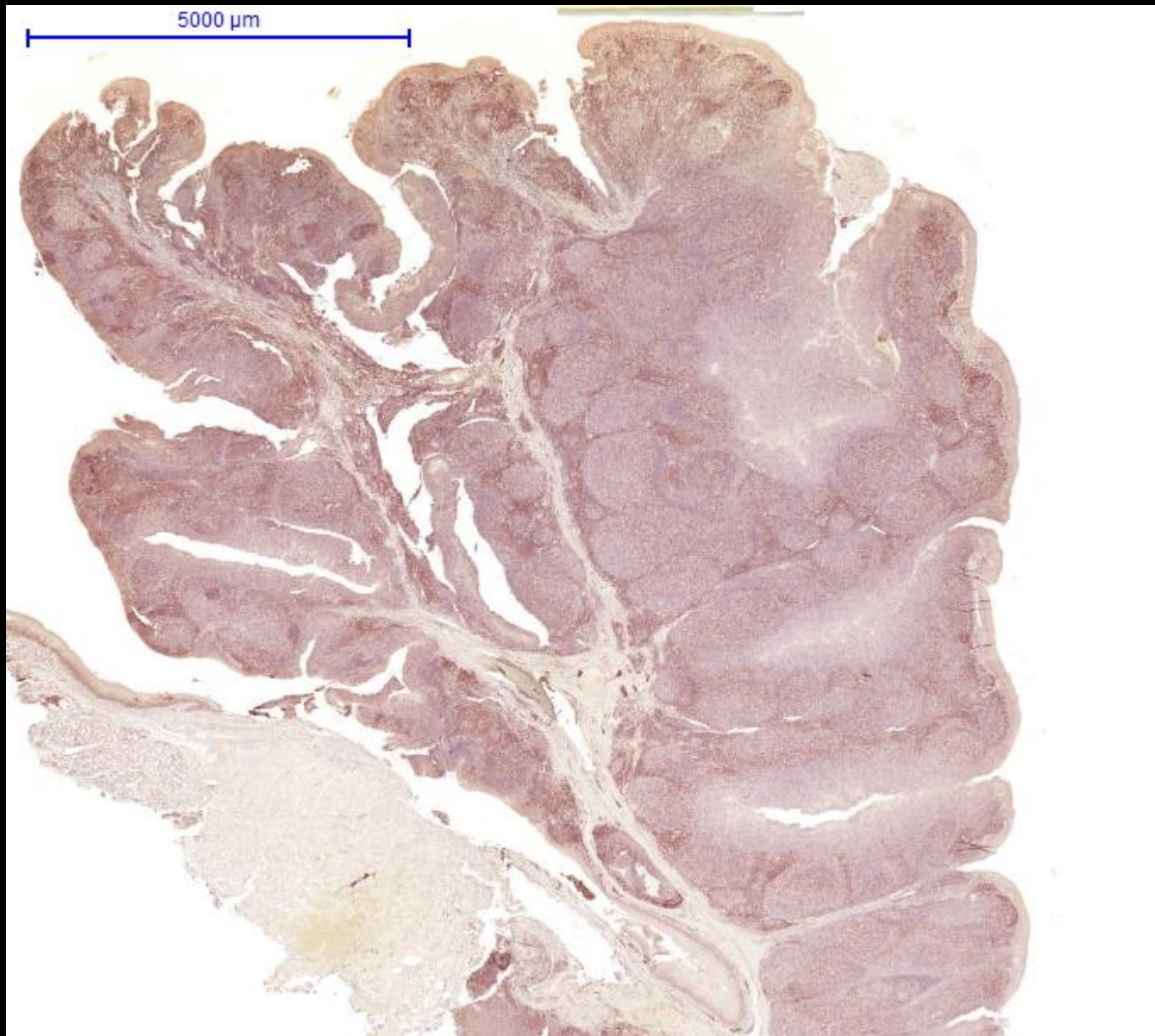
Tonsilla palatina



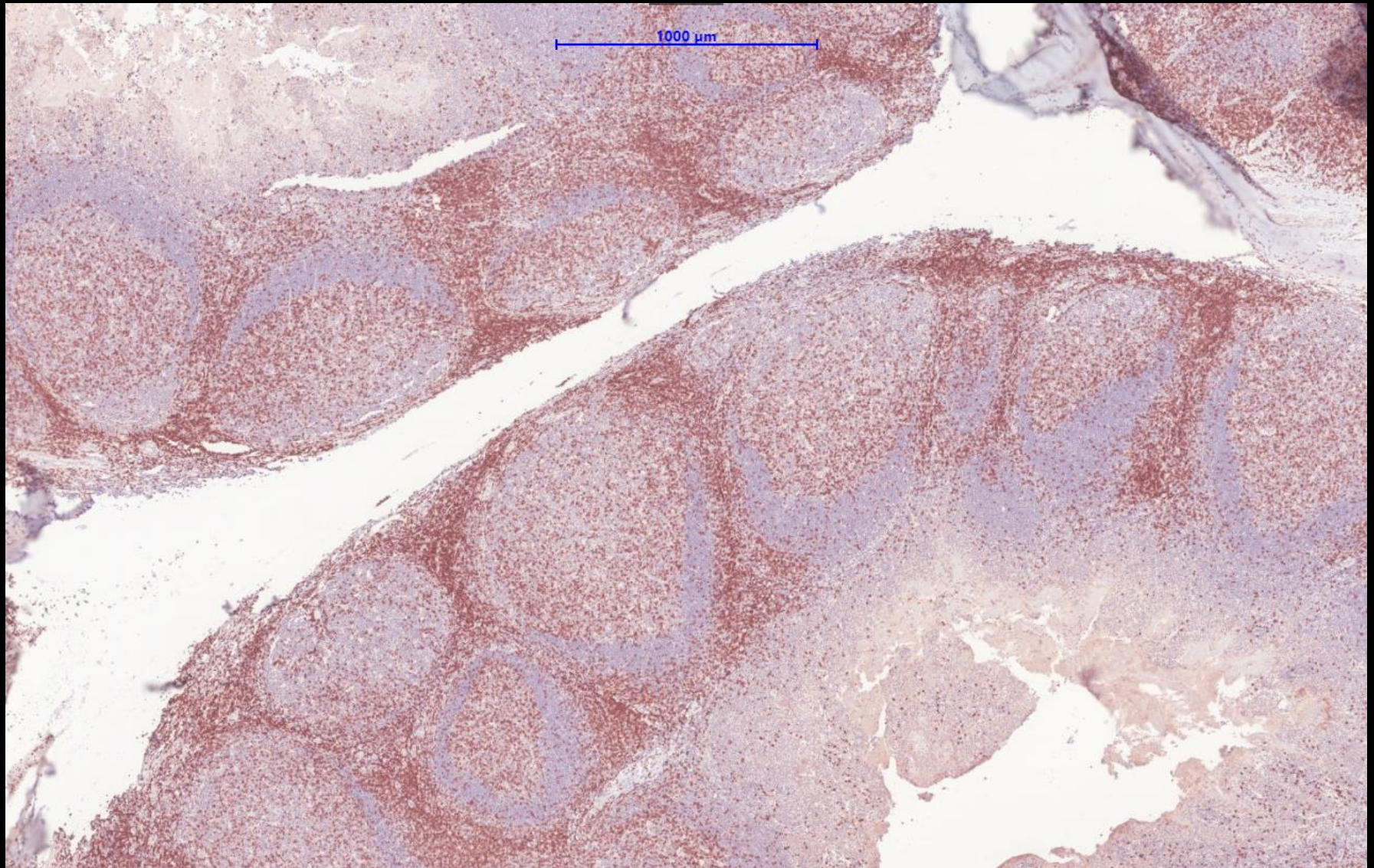
Tüszős mandulagyulladás (tonsillitis follicularis)



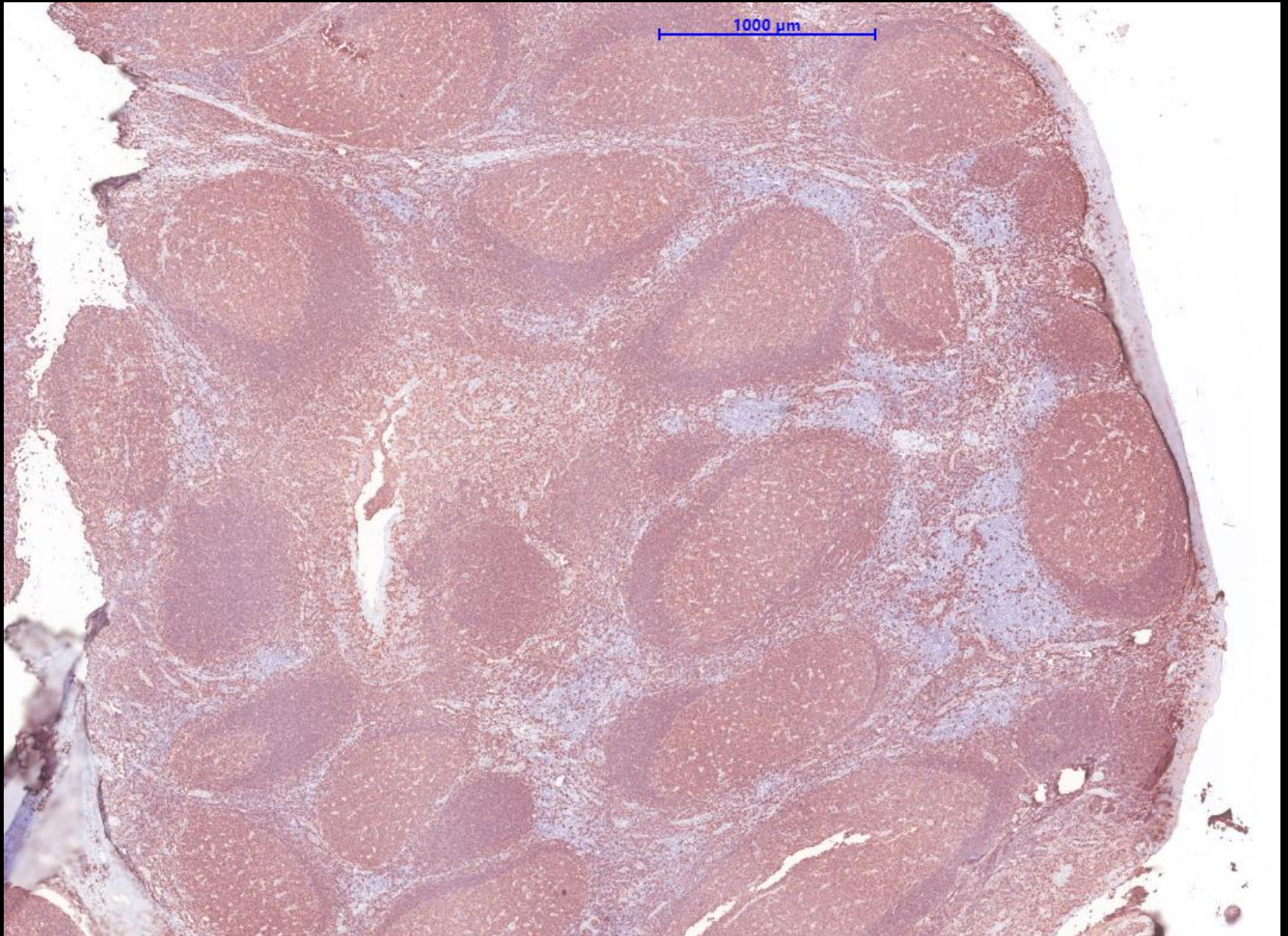
Tonsilla palatina – T sejtes immunfestés



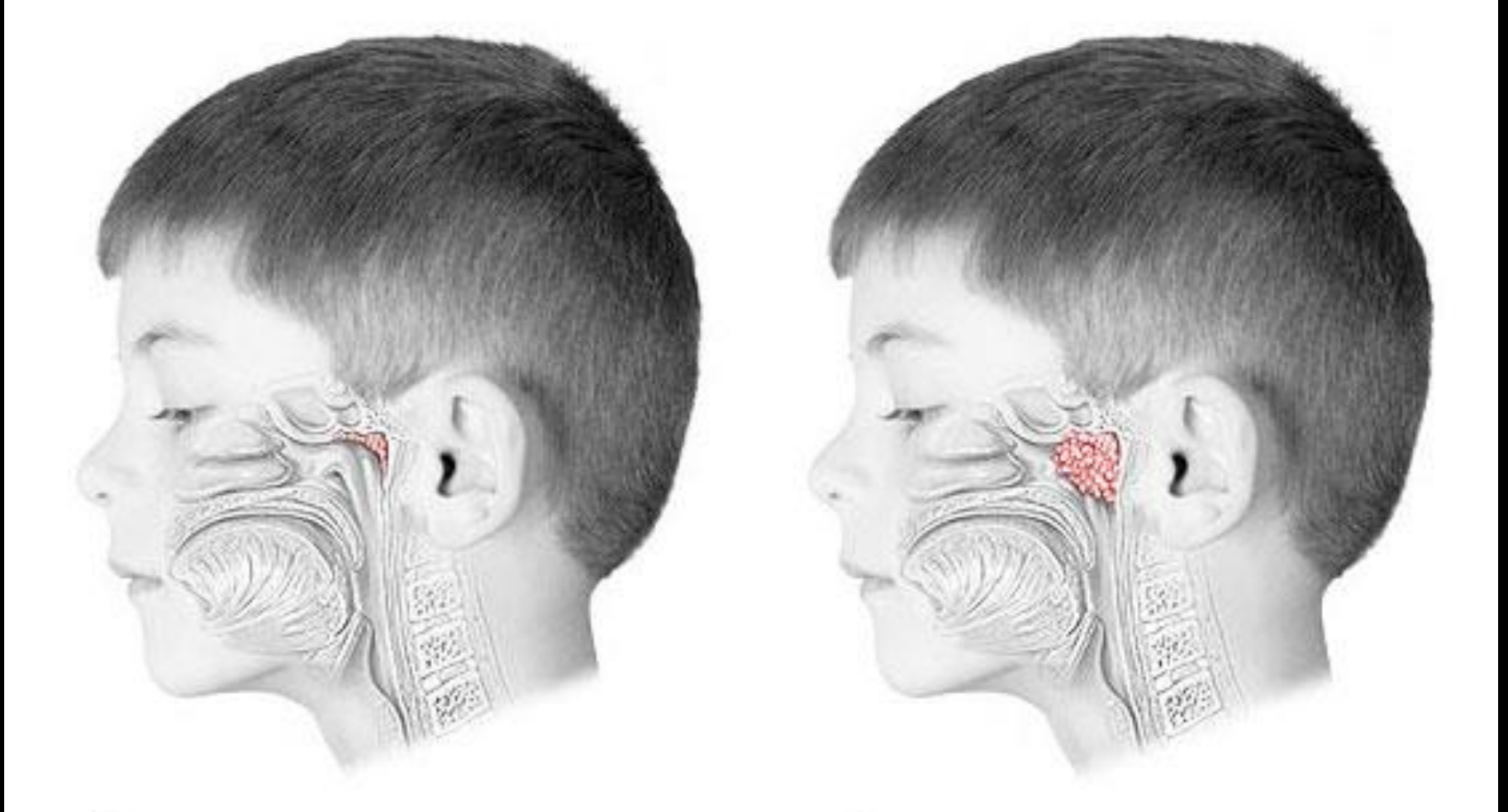
Tonsilla palatina – T sejtes immunfestés



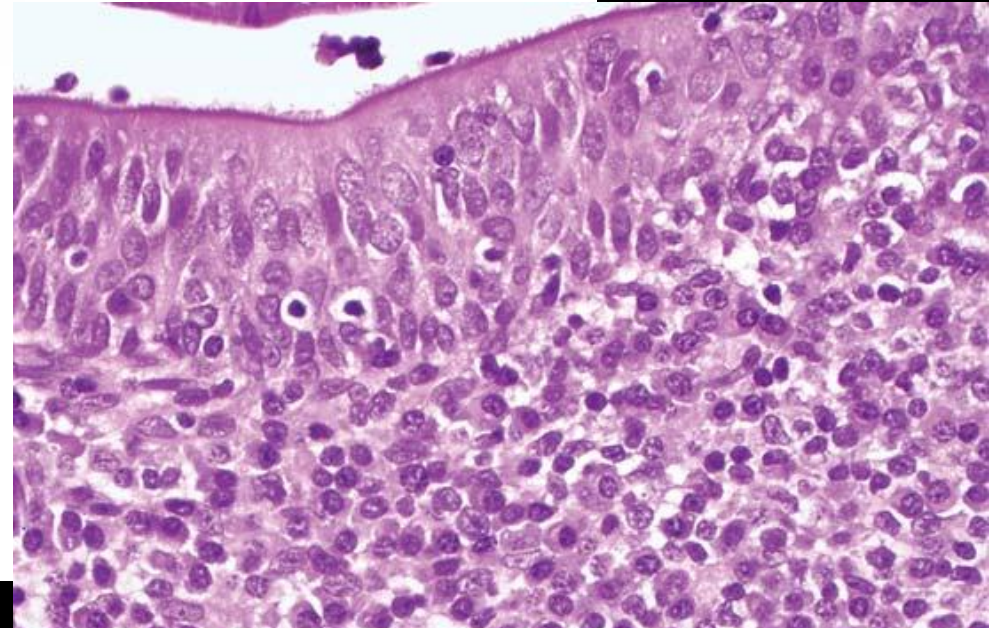
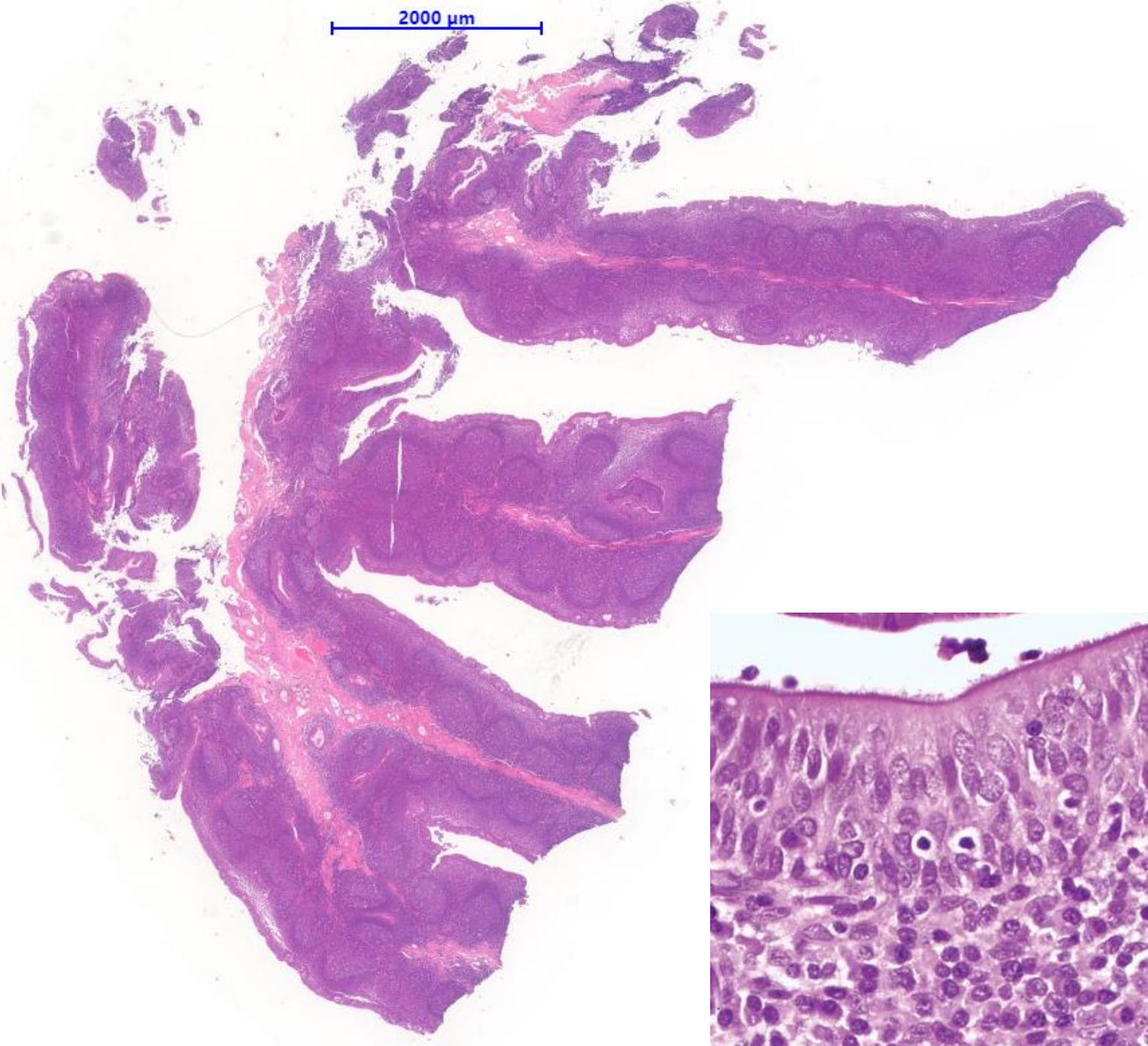
Tonsilla palatina – B sejtes immunfestés



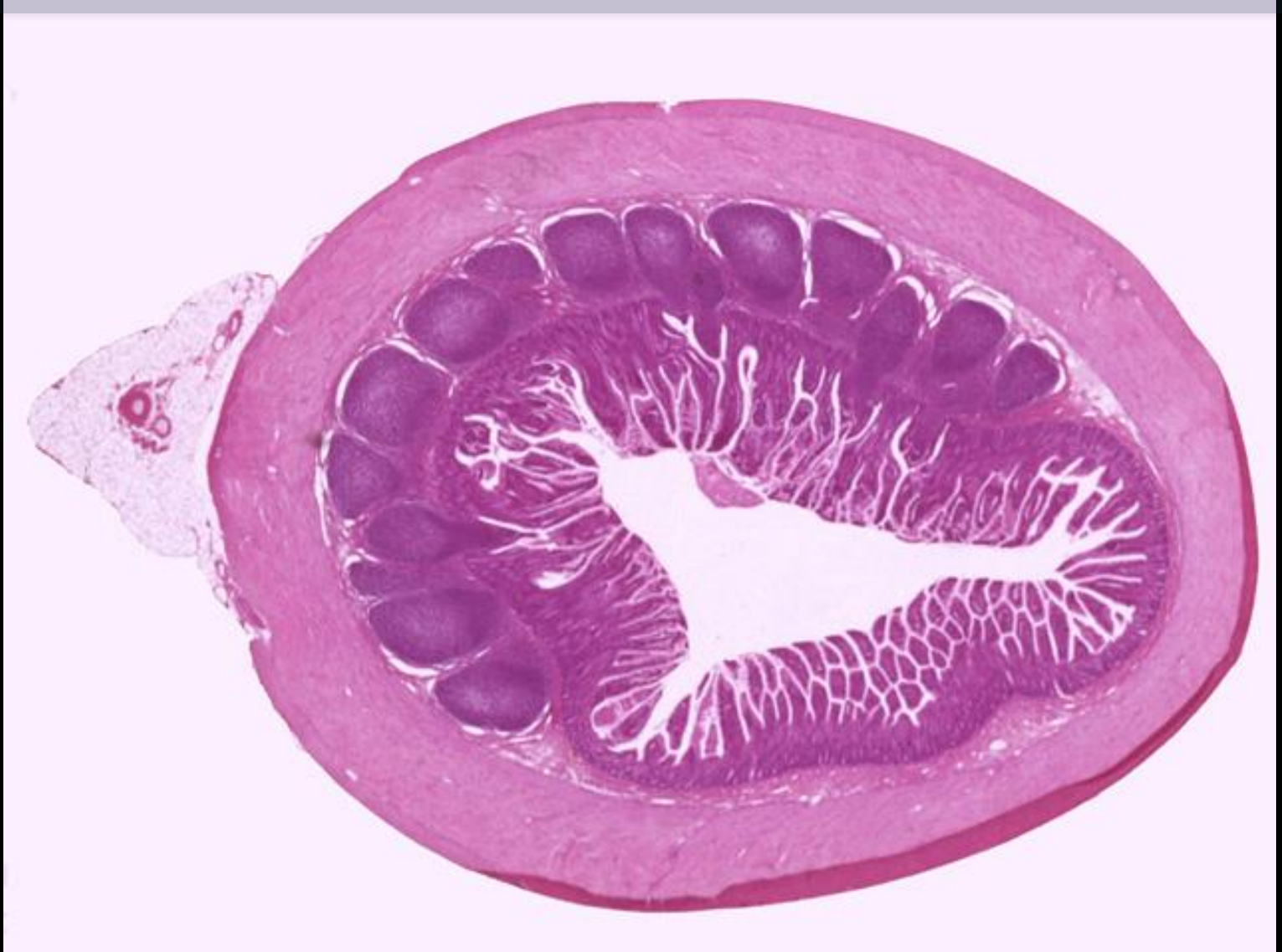
Tonsilla pharyngea



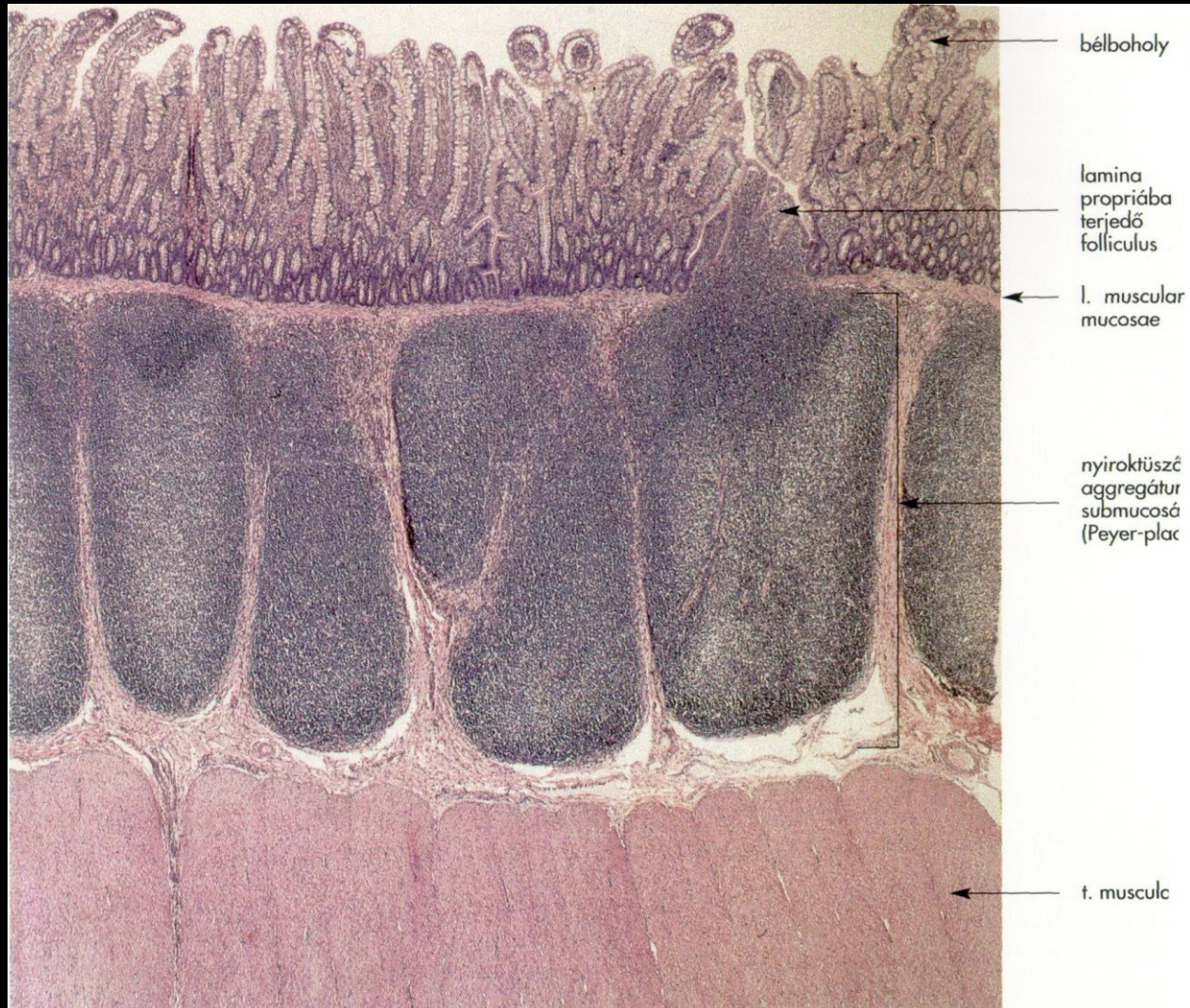2000 μm



Peyer-plakkok



Peyer-plakkok

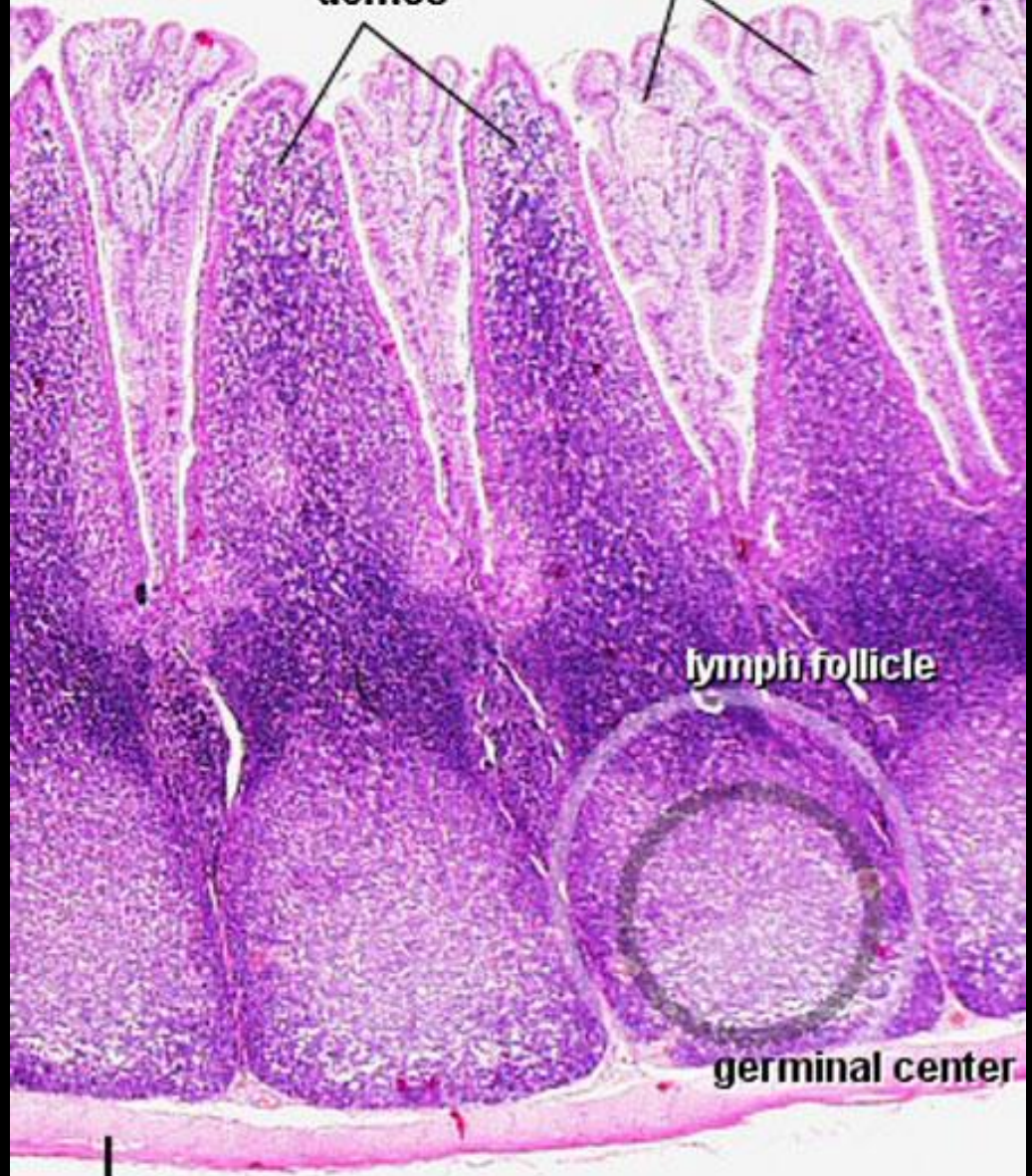

13-42. ábra. Ileum nyiroktüsző-aggregátumokkal (Peyer-plaque-ok). A nyiroksejtek a l. muscularis mucosae-t beterjednek a t. propriába (HE, 40x).

Peyer's Patch H&E

villi

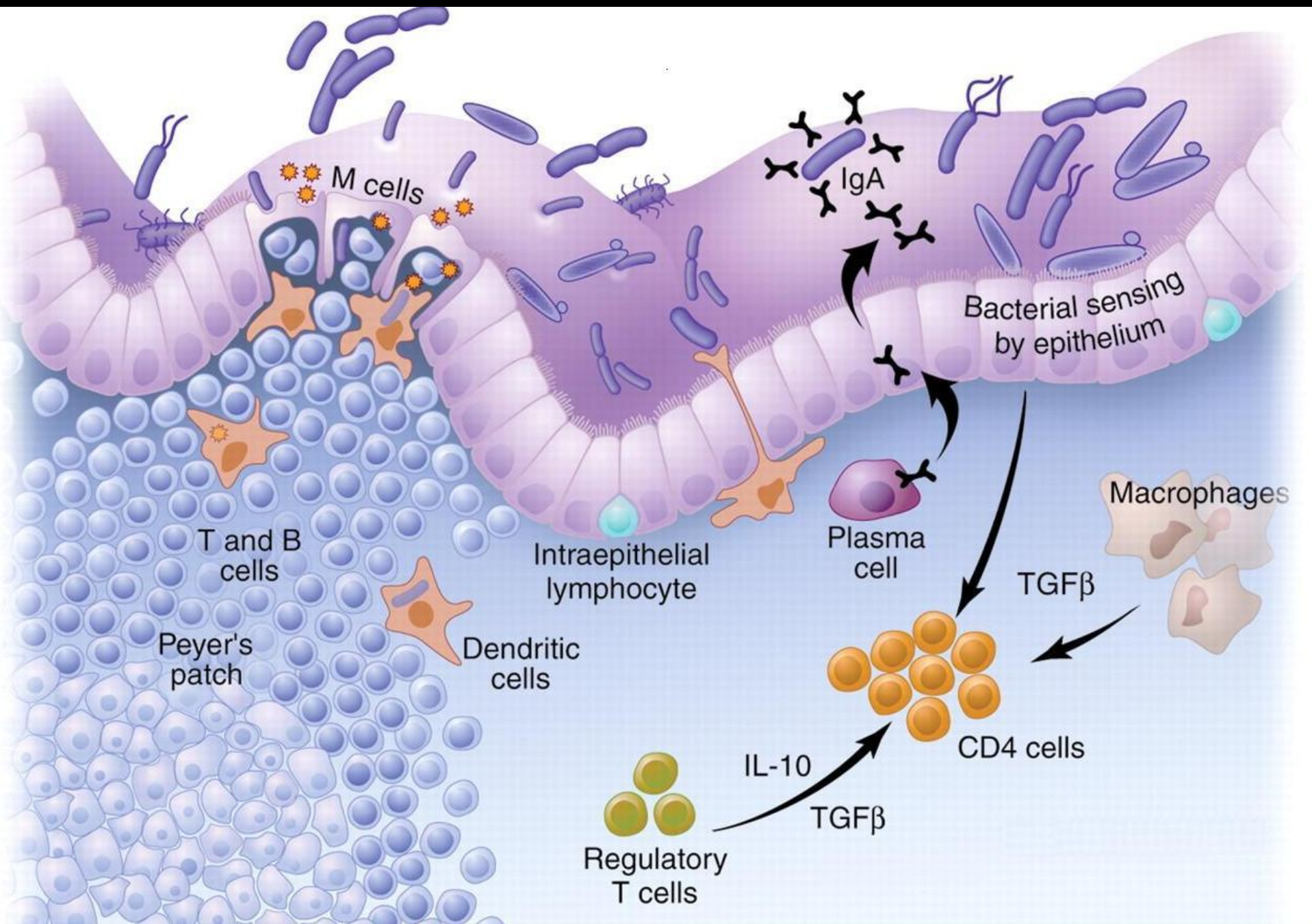
domes



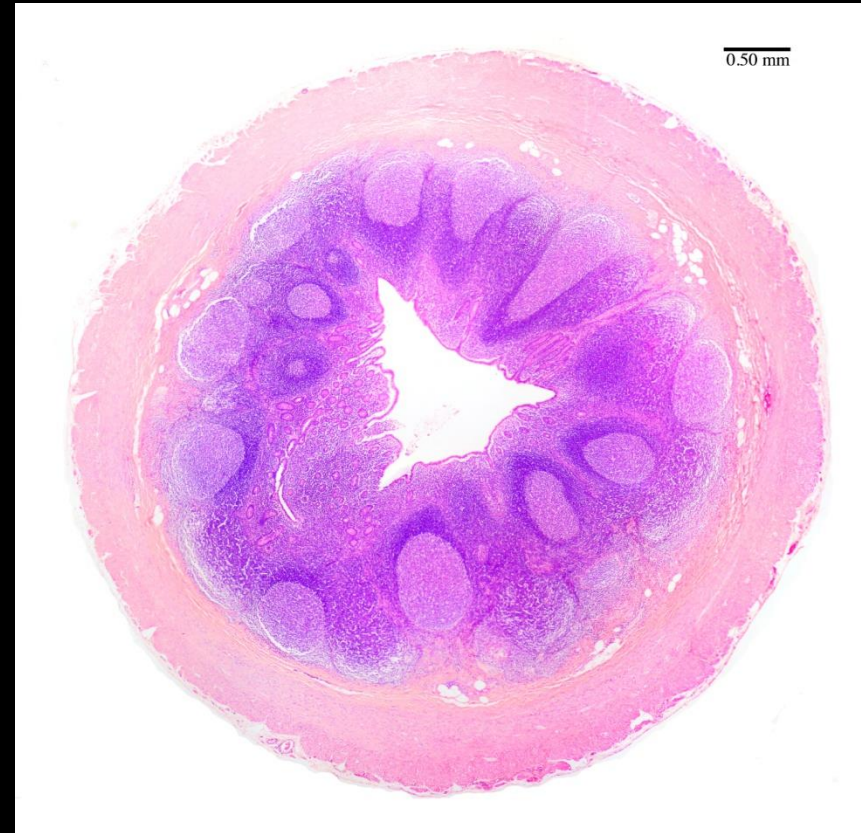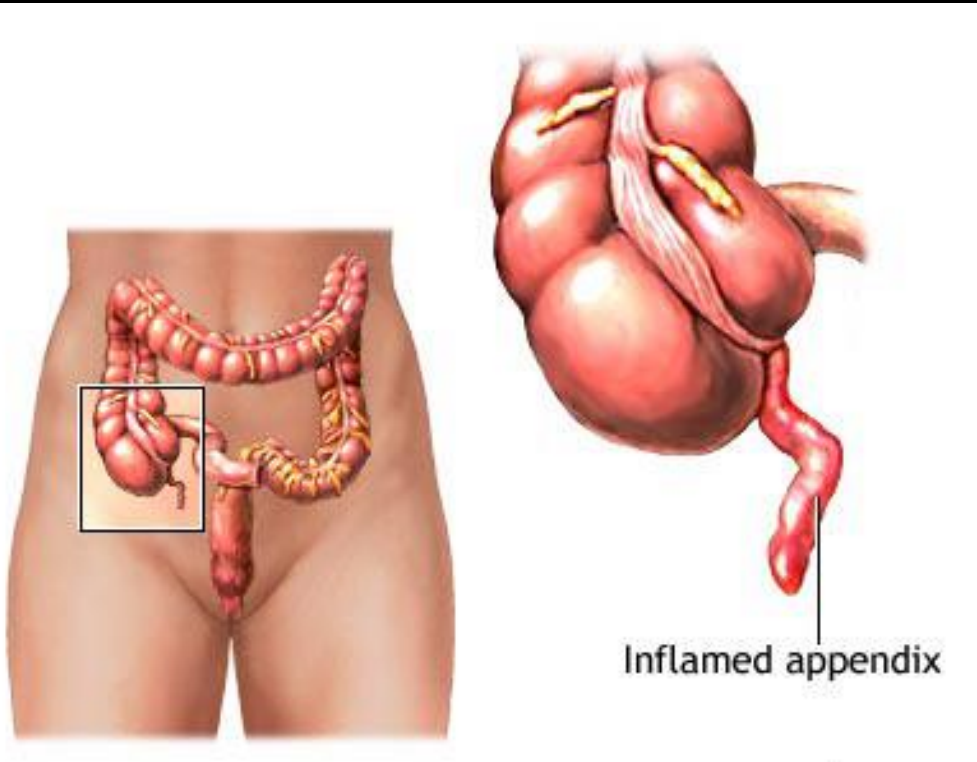
lymph follicle

germinal center

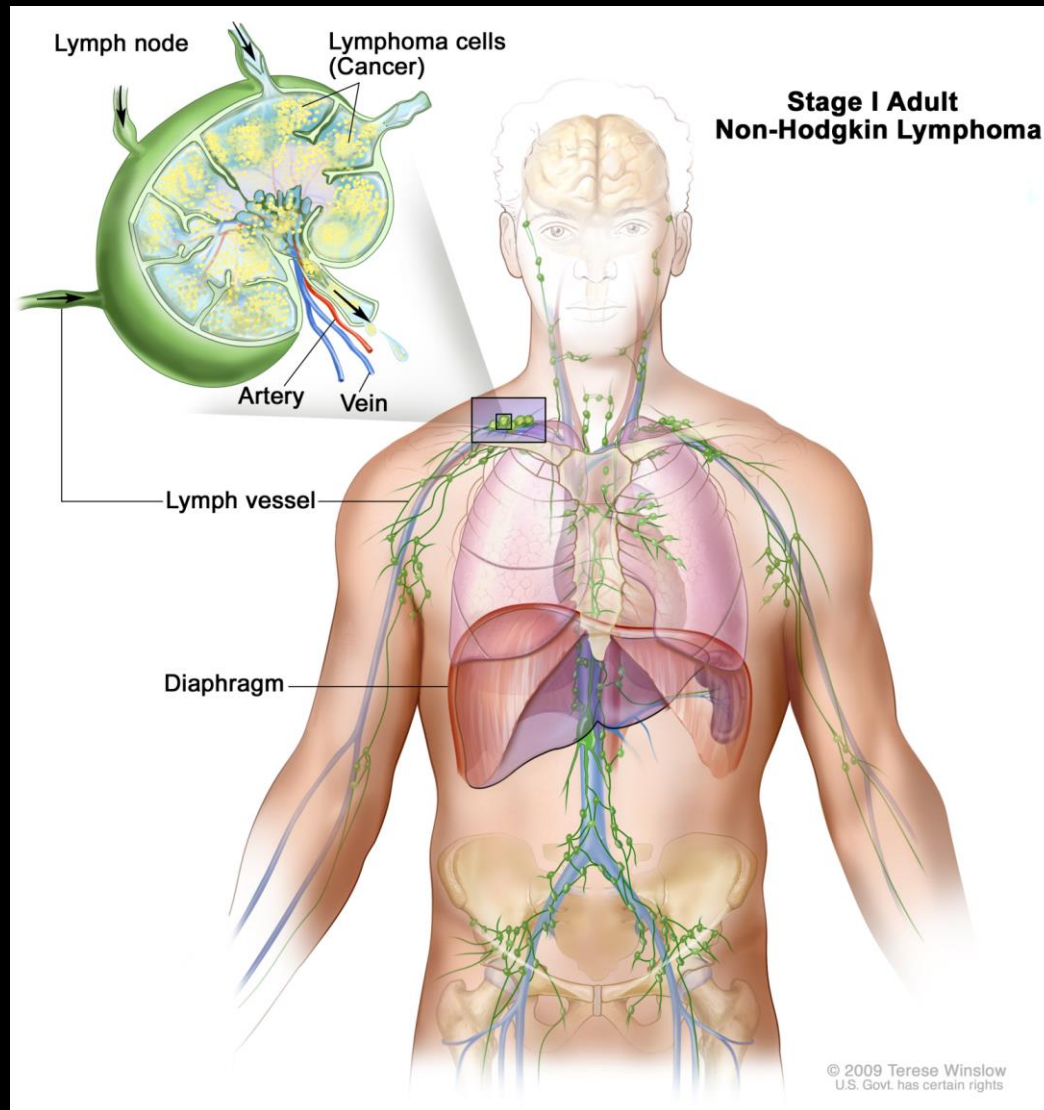
muscularis externa



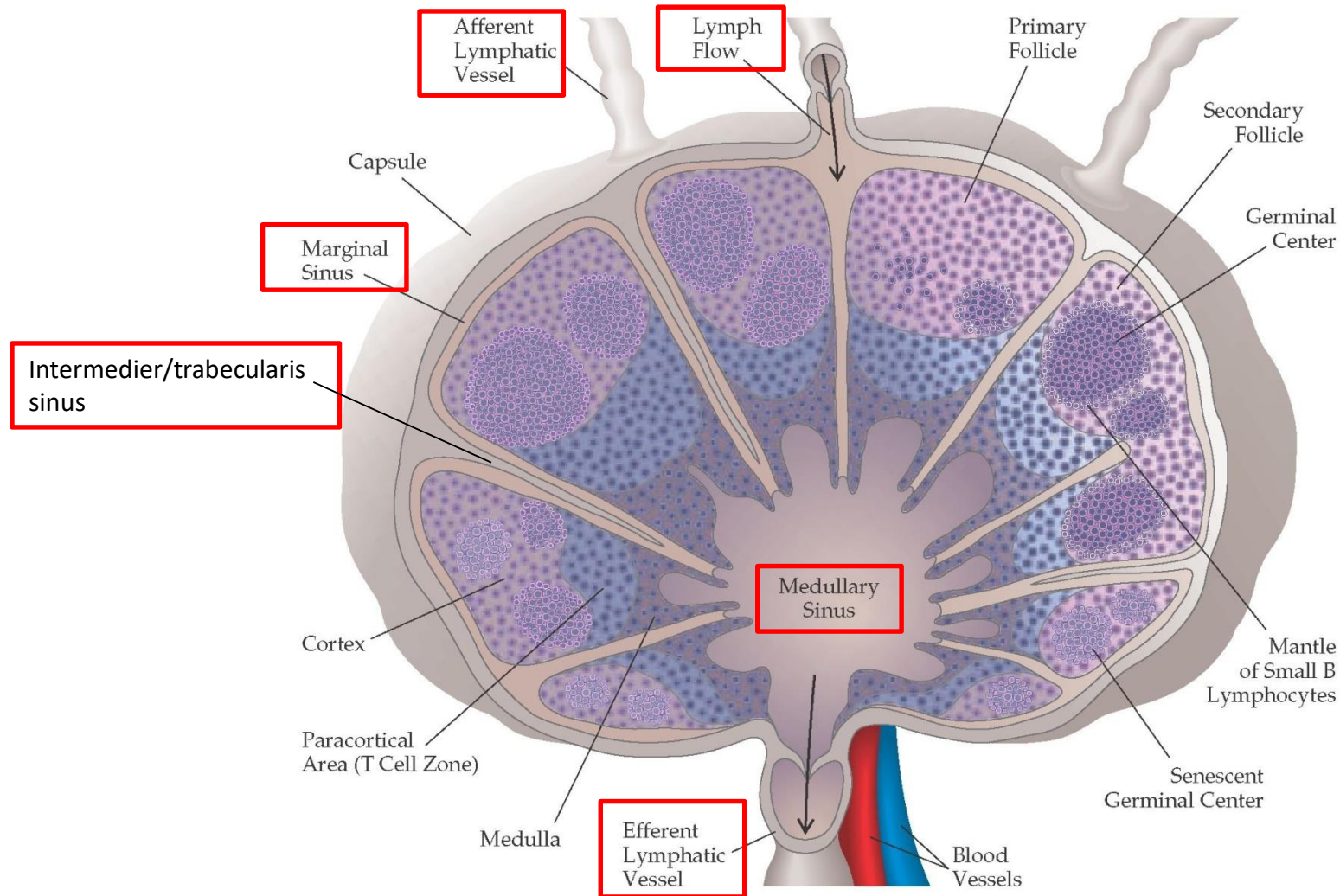
Appendix vermiformis

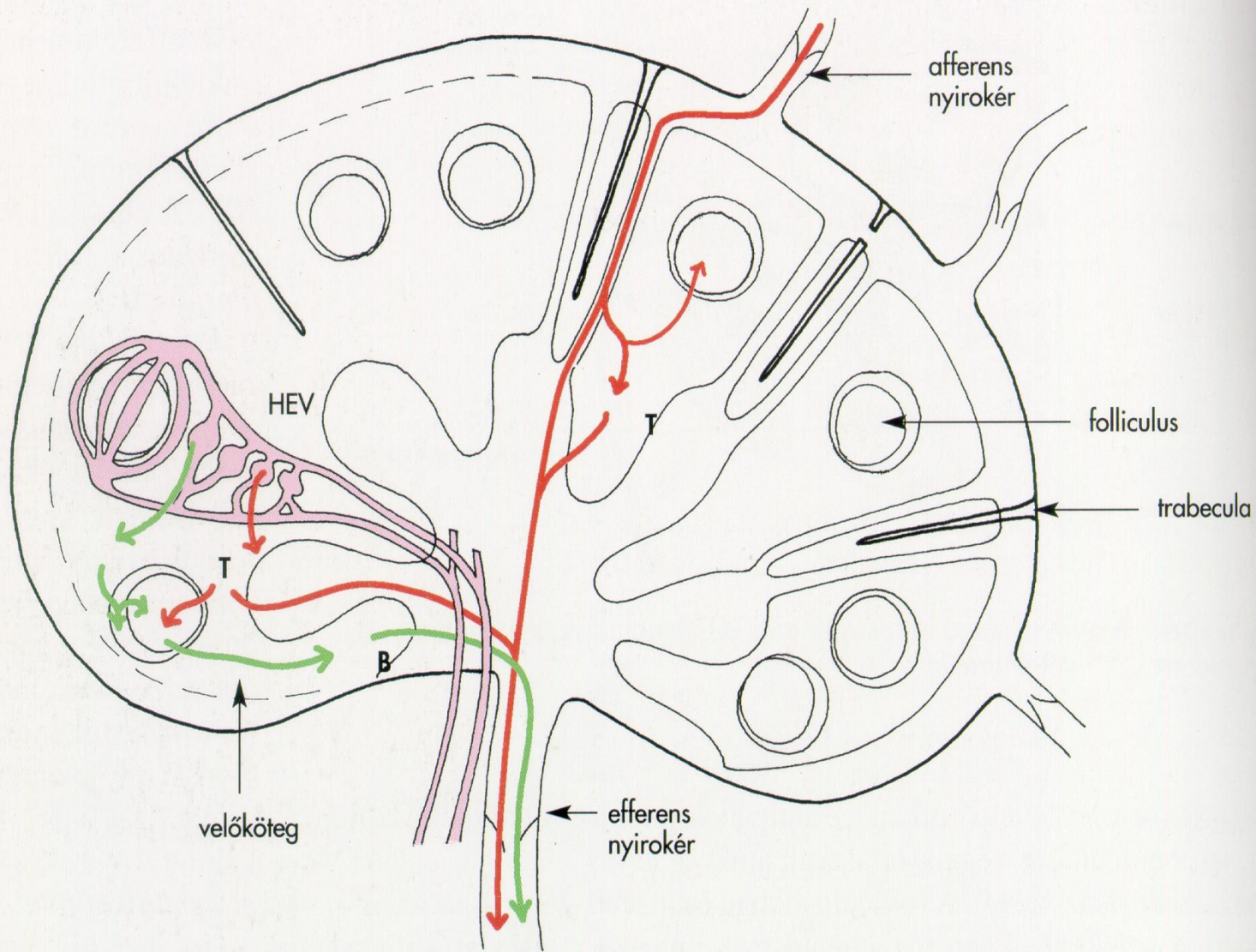


Nodus lymphaticus (nyirokcsomó)

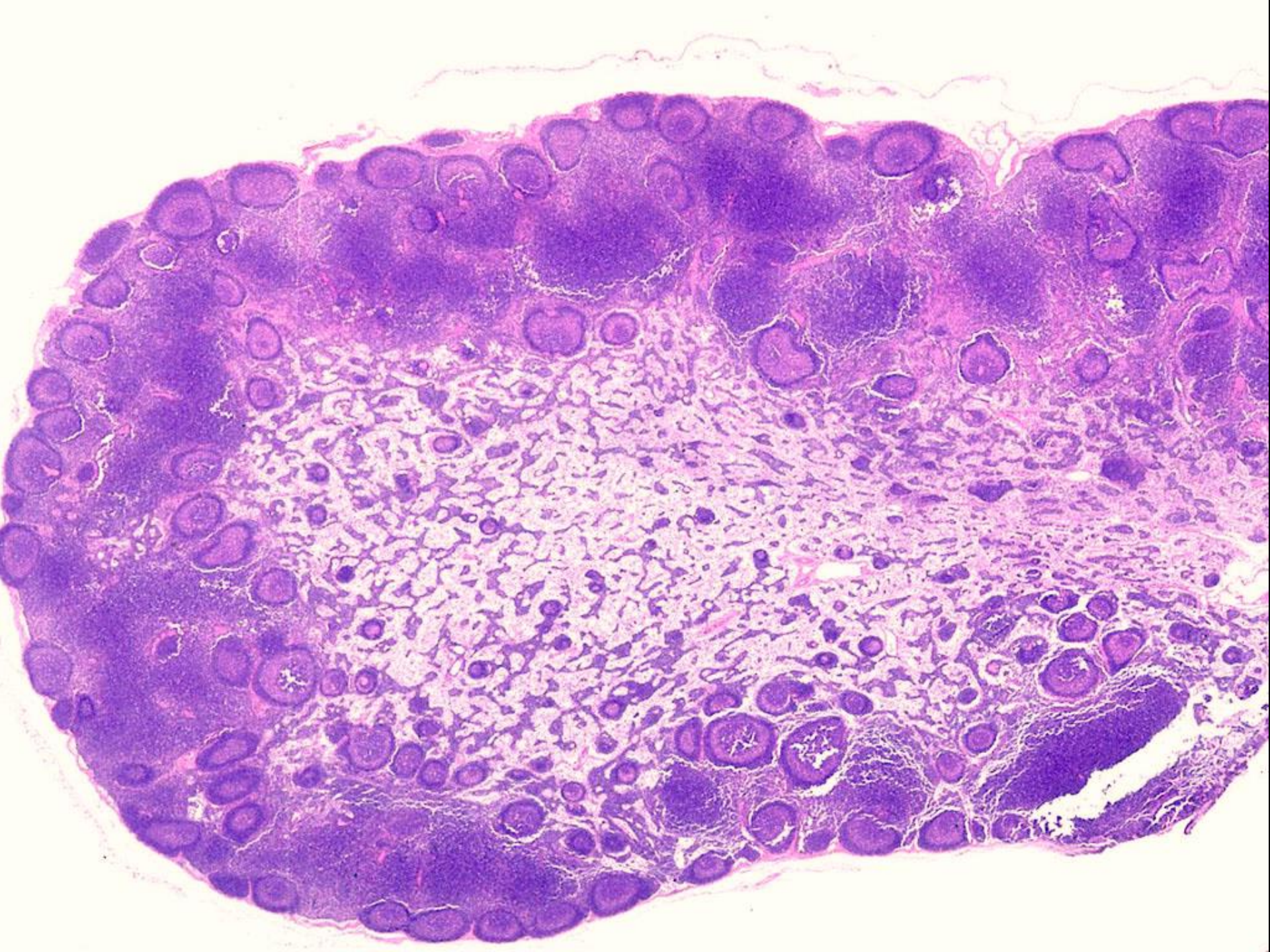


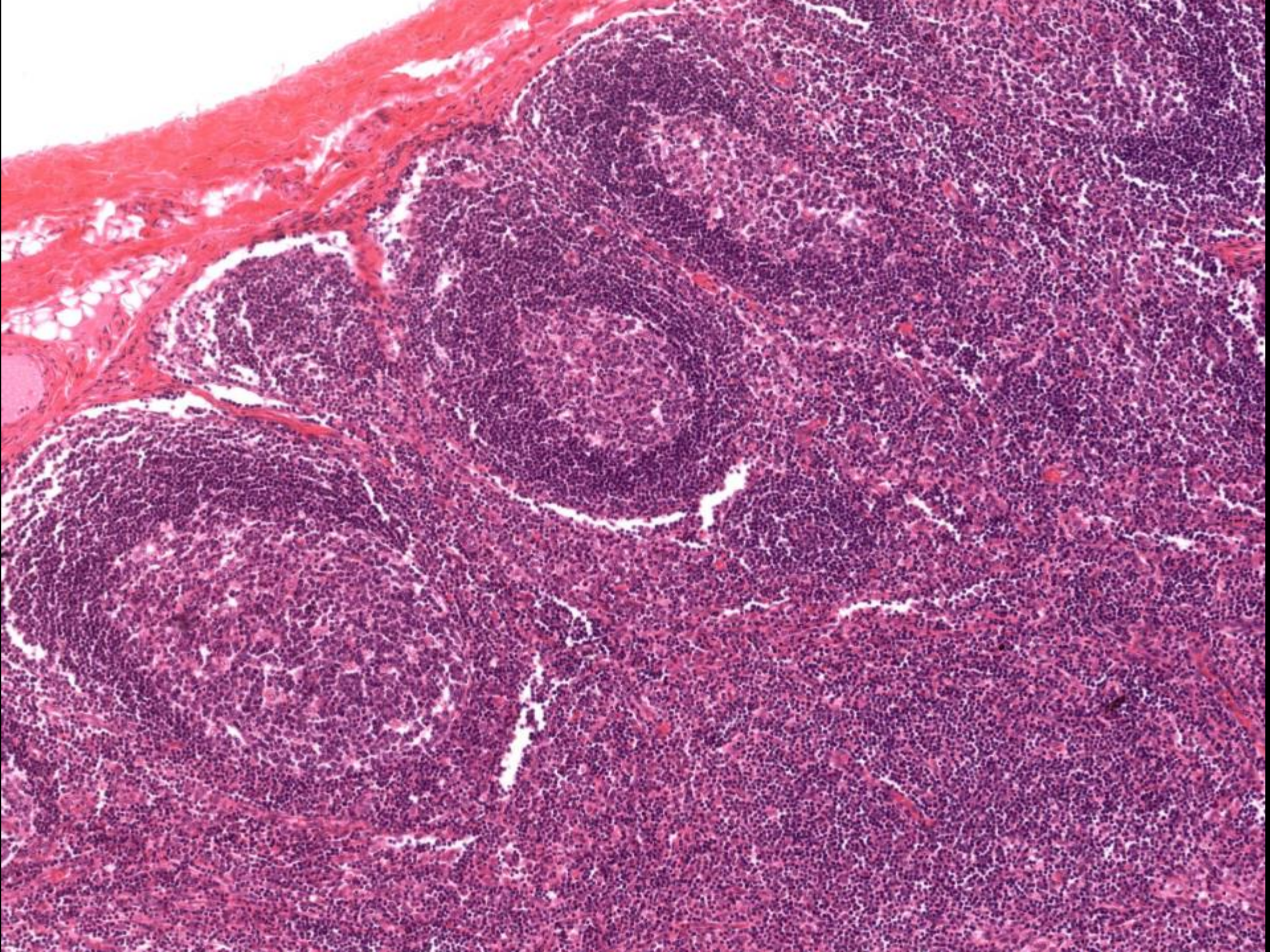
A nyirok áramlása a nyirokcsomón keresztül

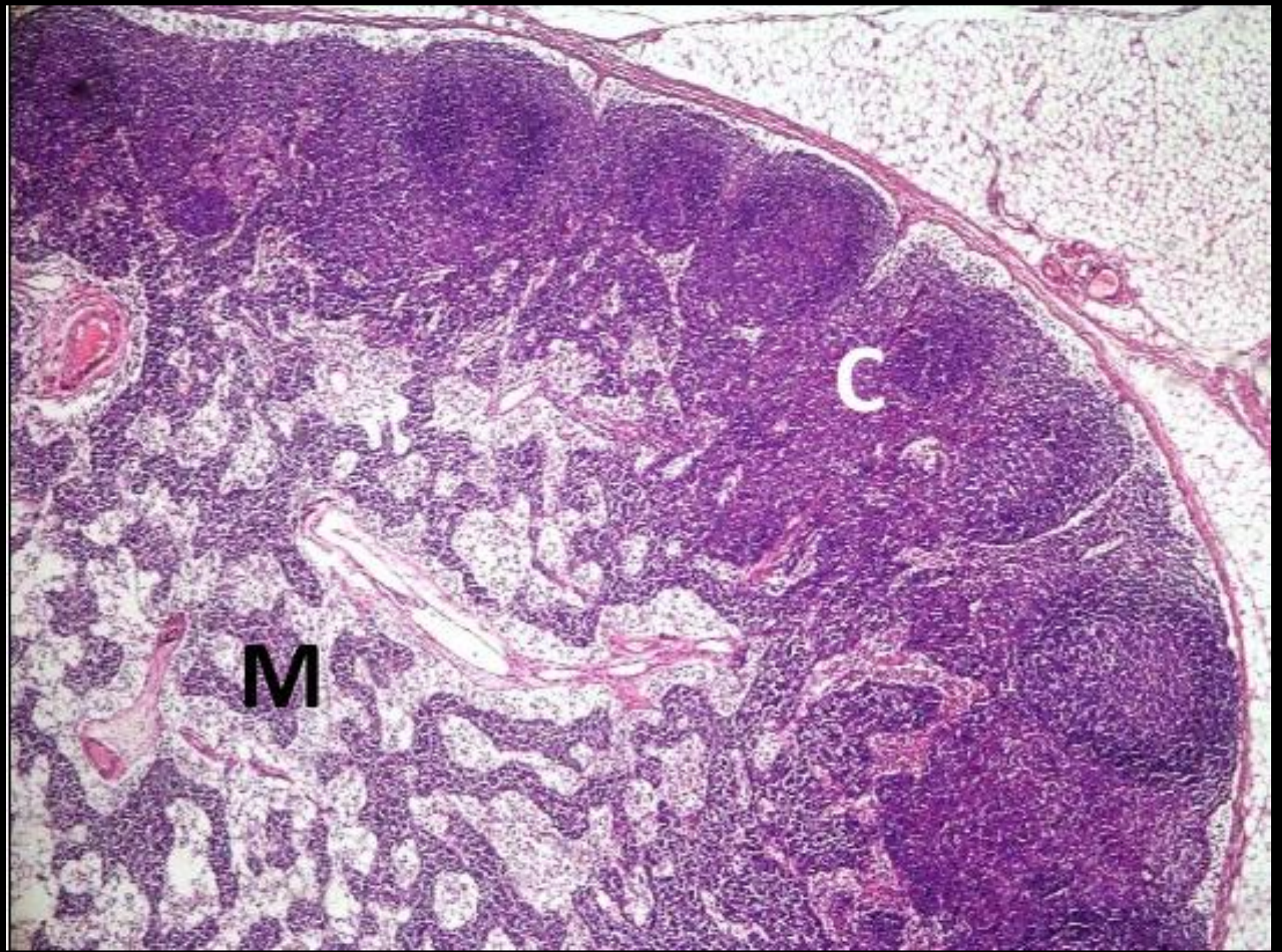




12-27. ábra. Lymphocytavándorlás a nyirokcsomóban.

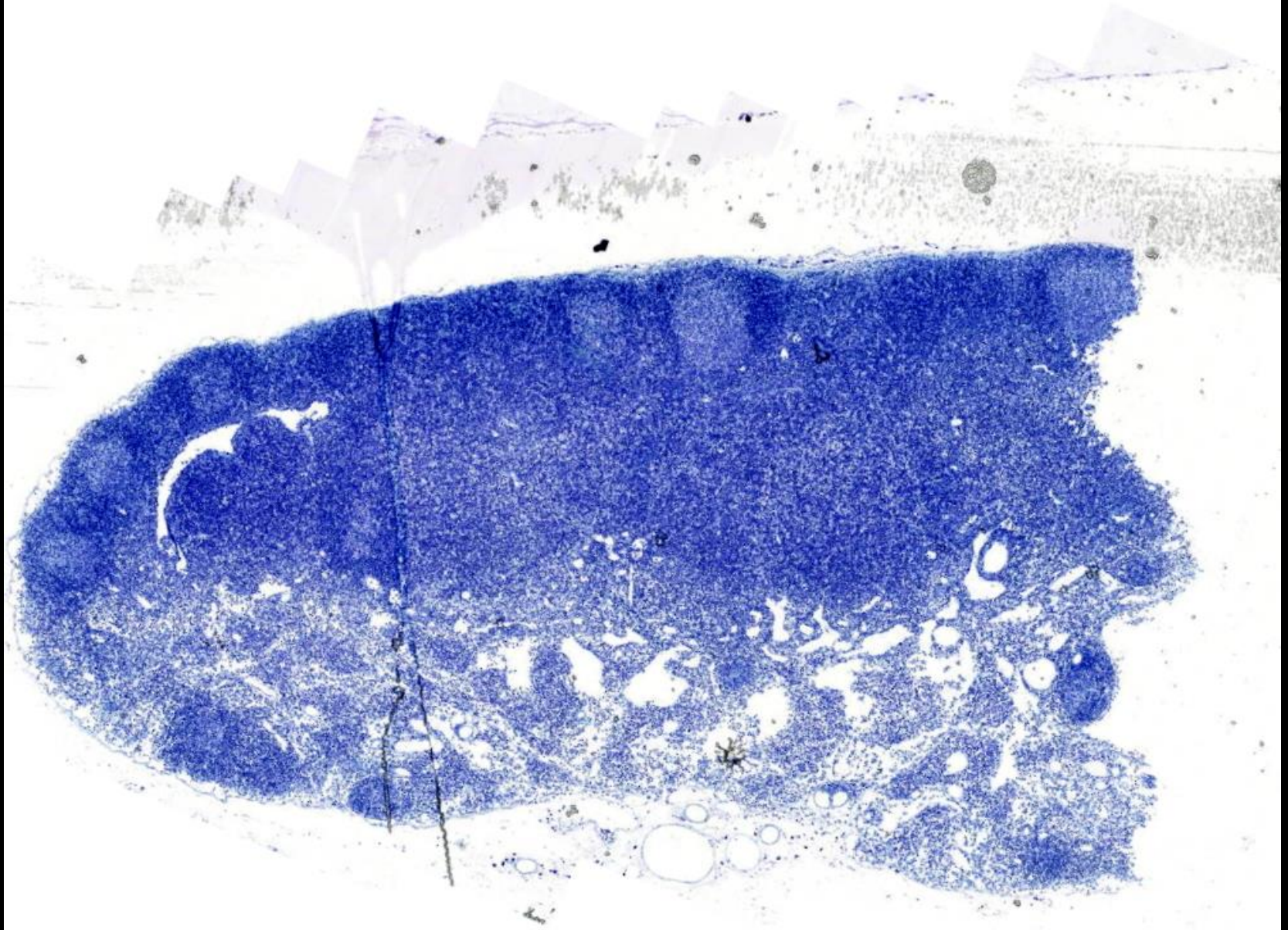




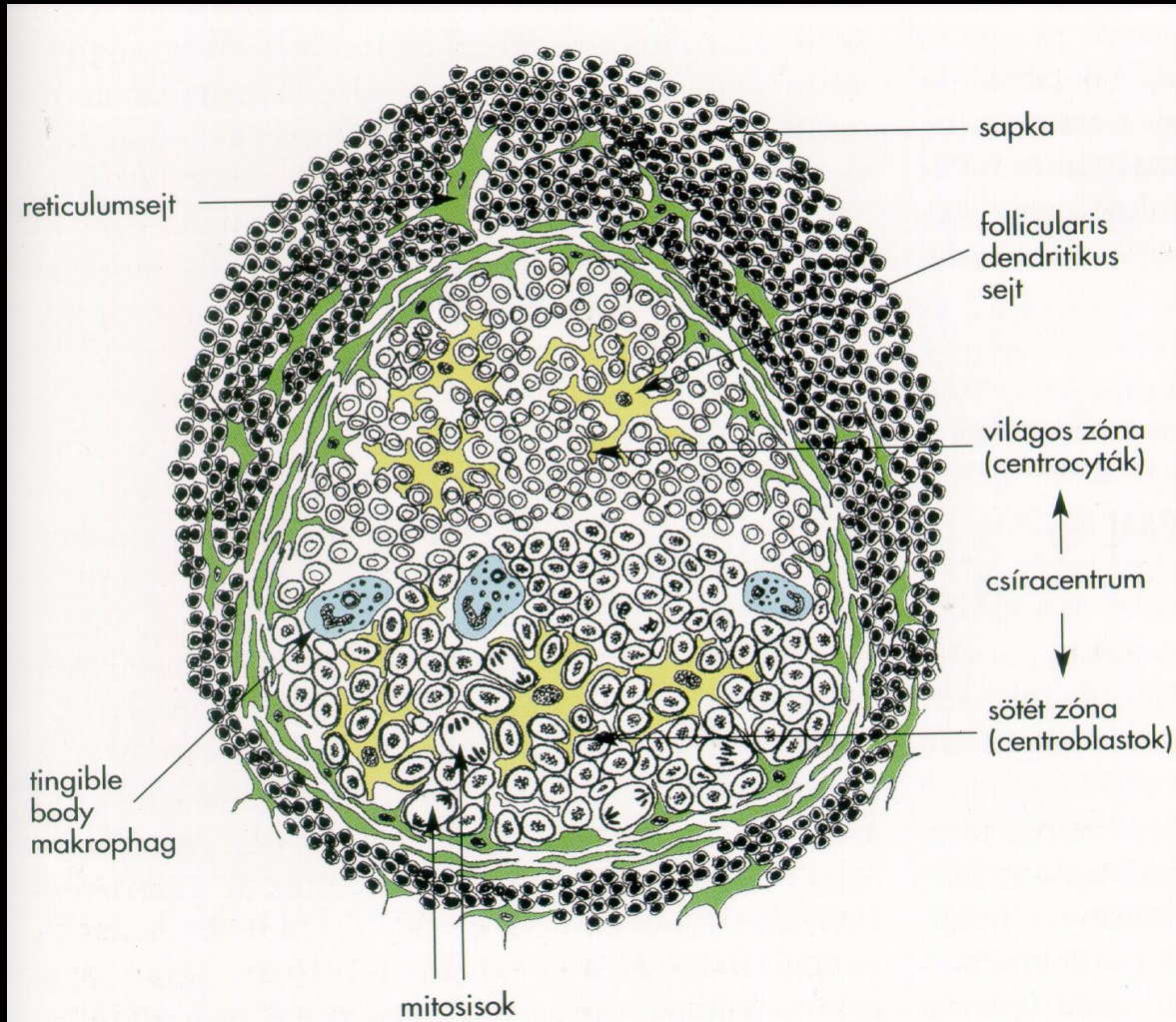


500 μ m

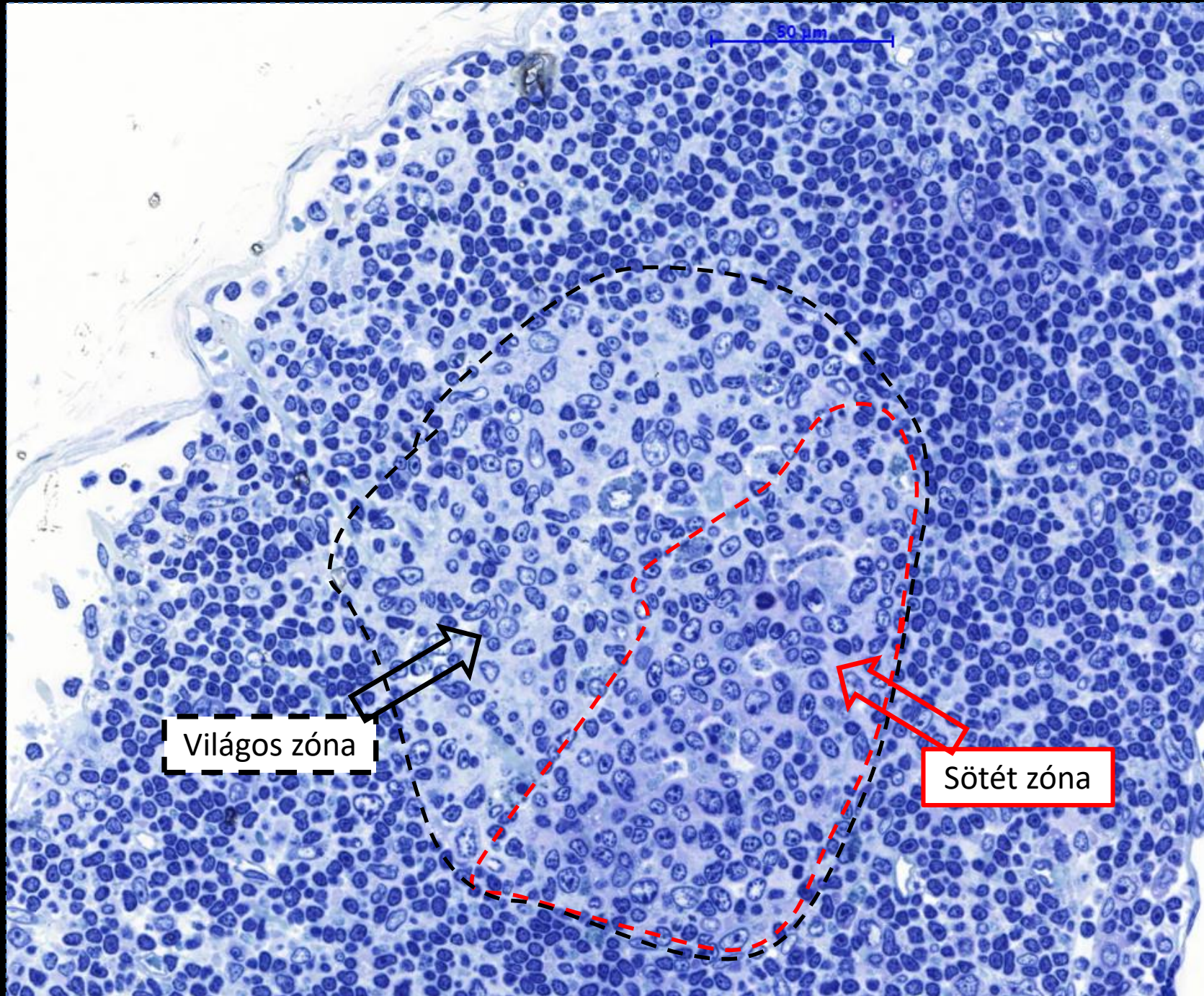
Nyirokcsomó (toluidinkék)



Folliculus lymphaticus



secunder nyiroktüsző

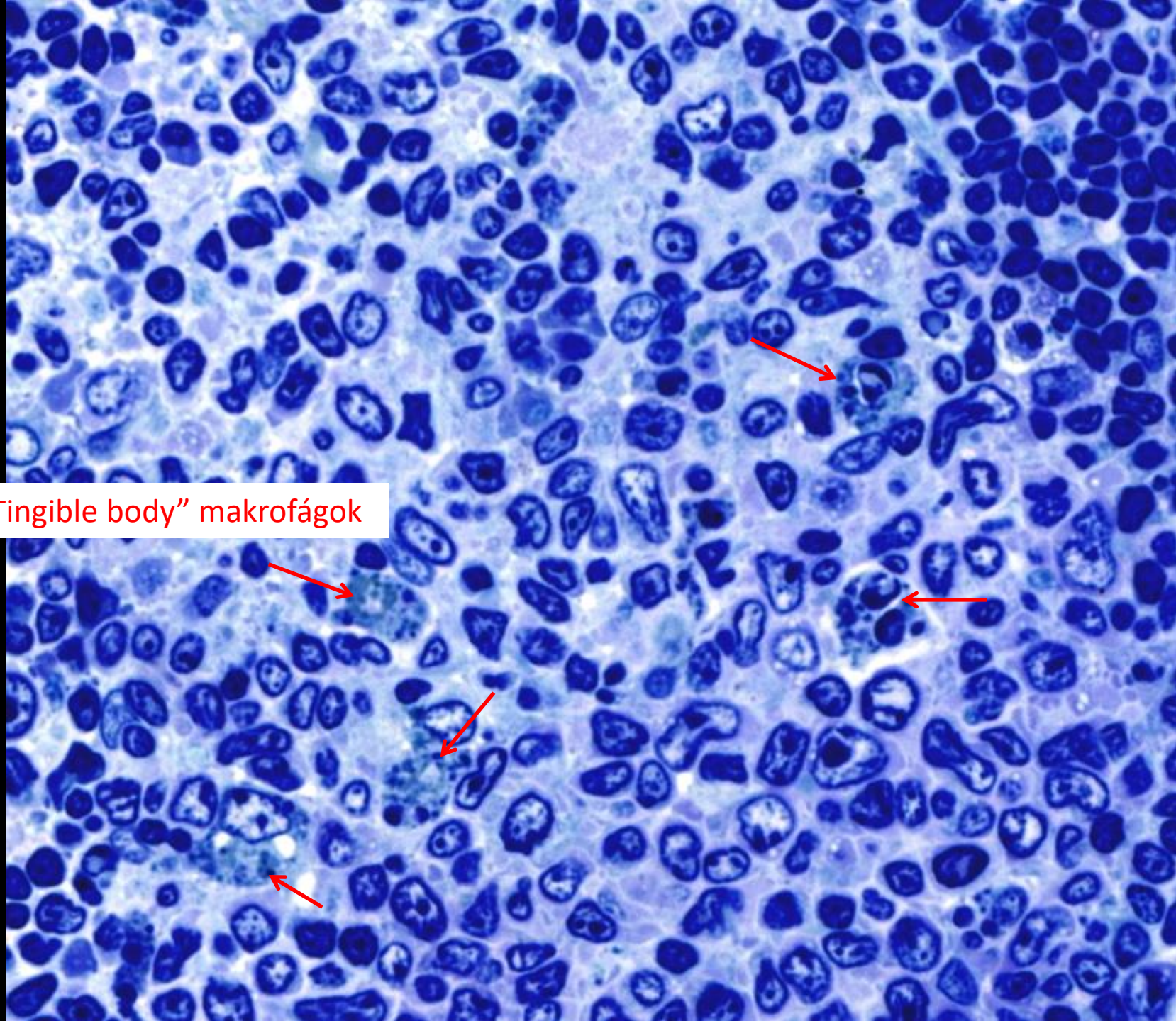


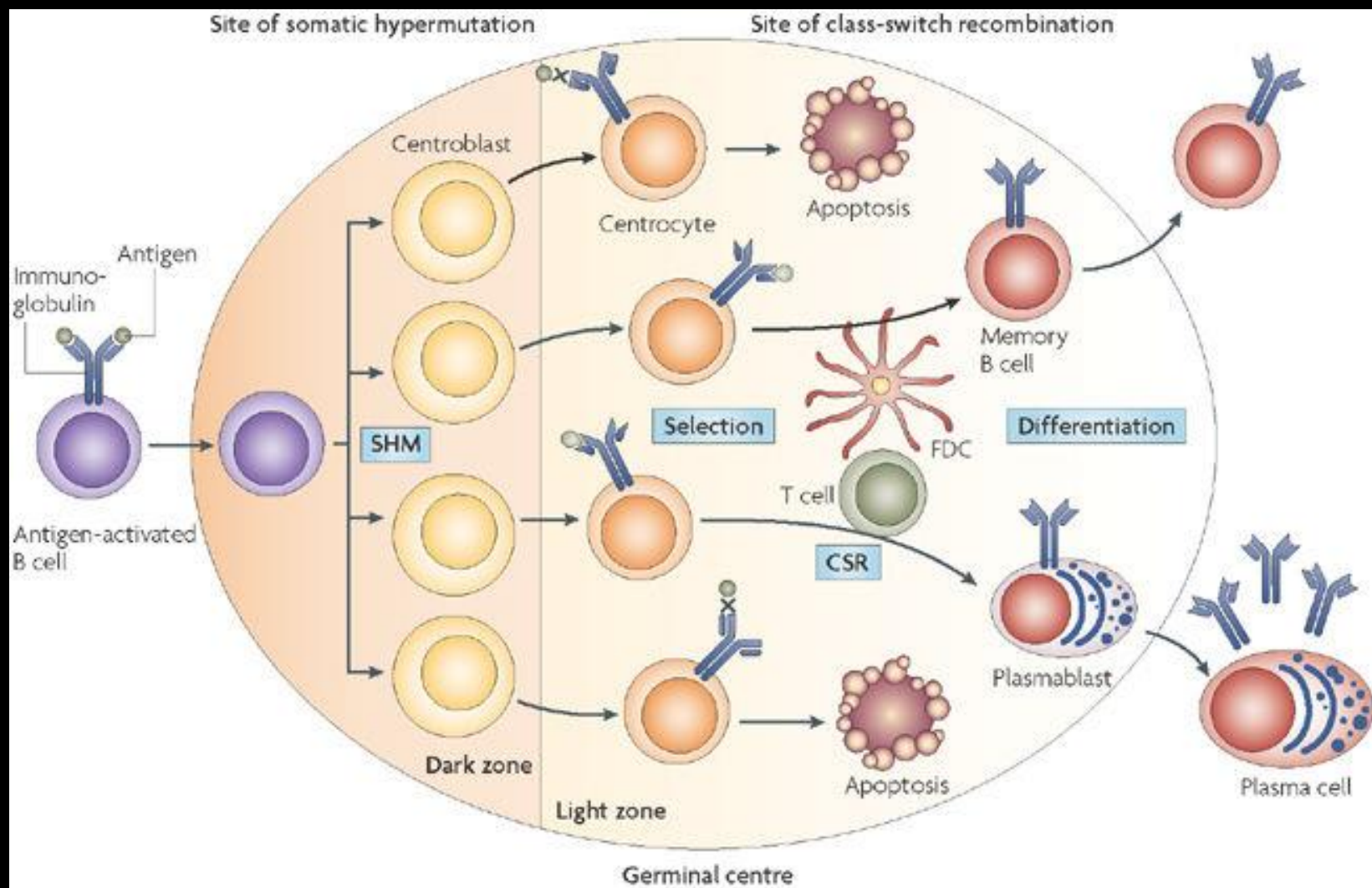
50 μm

Világos zóna

Sötét zóna

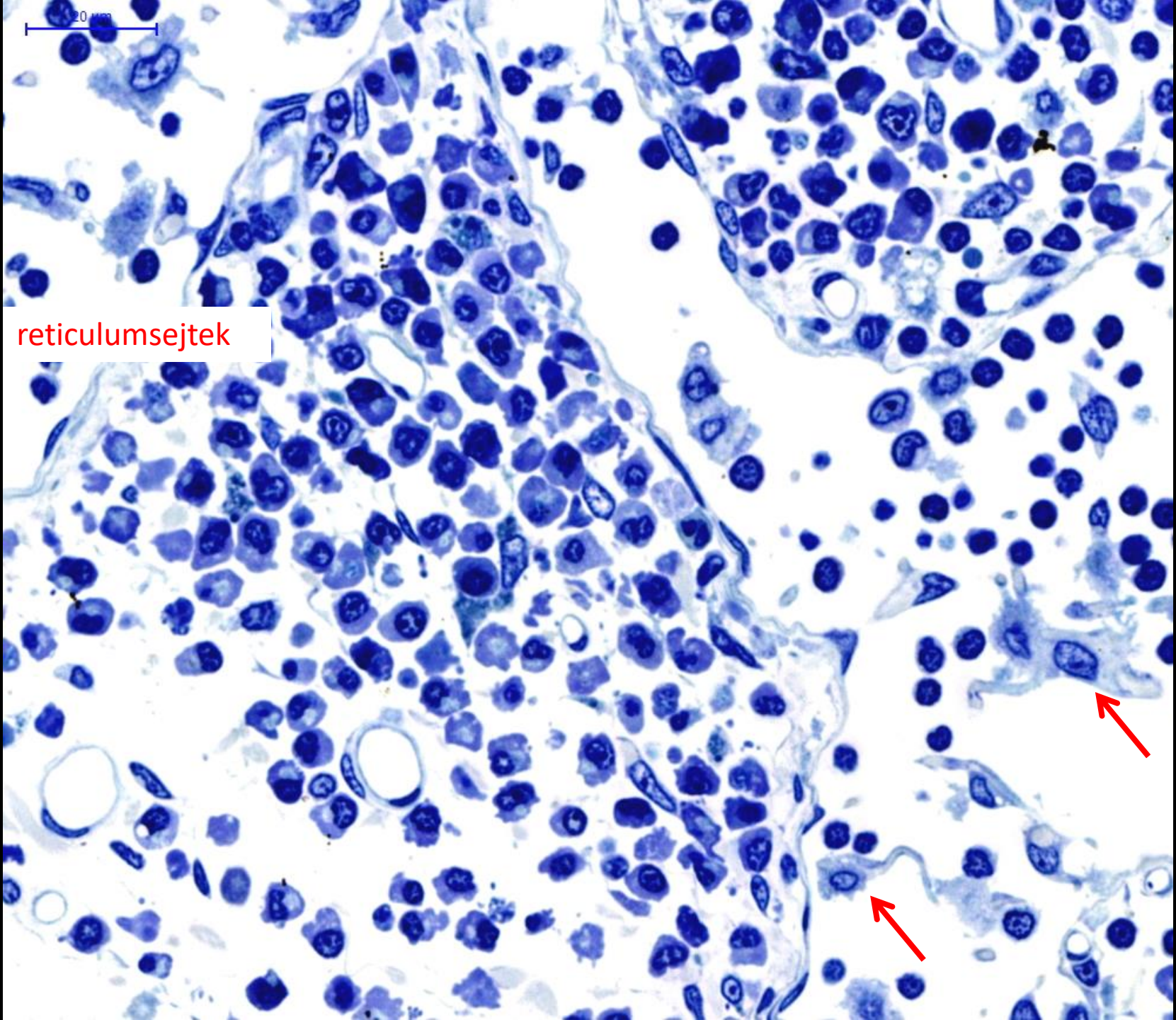
„Tingible body” makrofágok



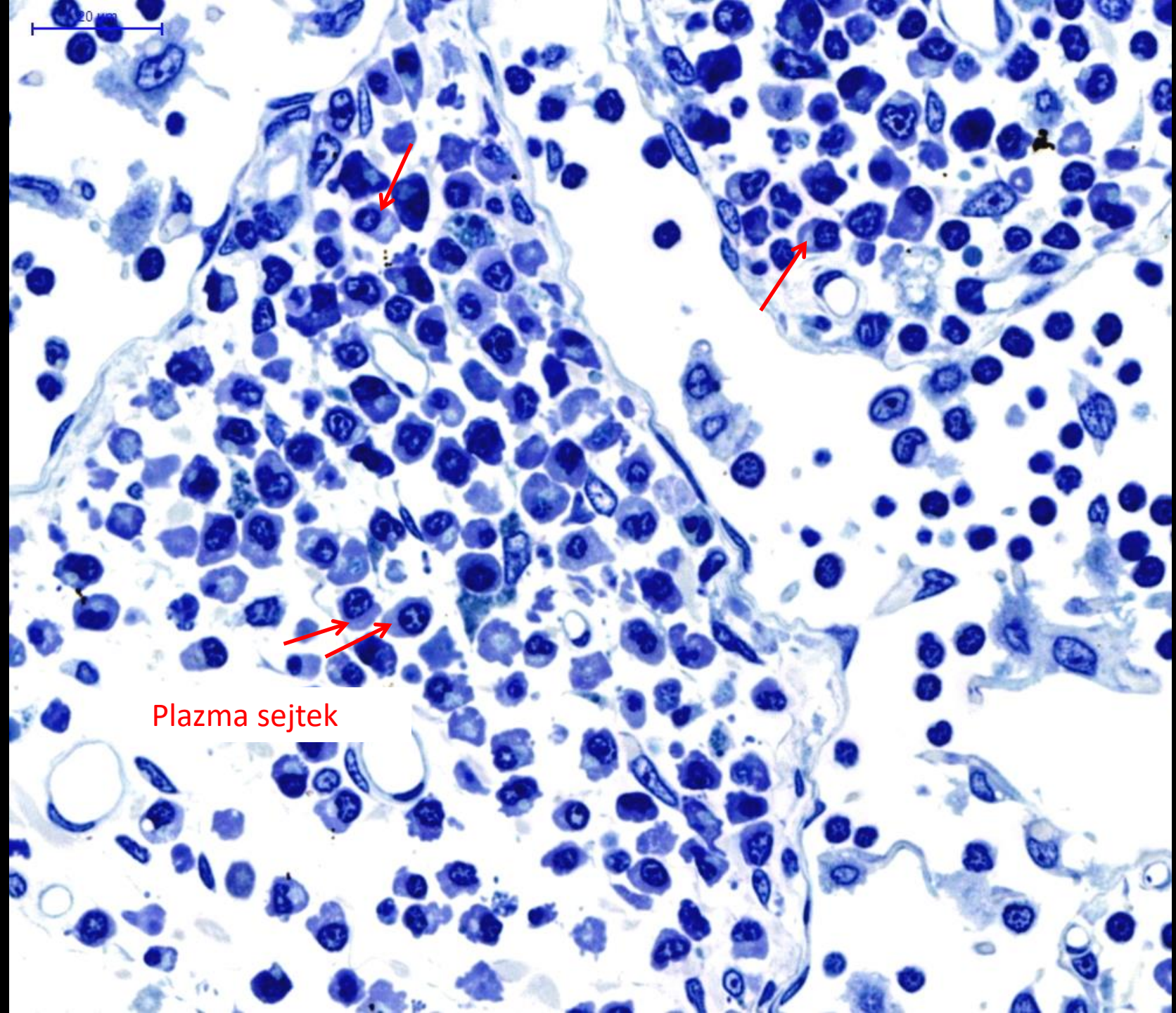


20 μm

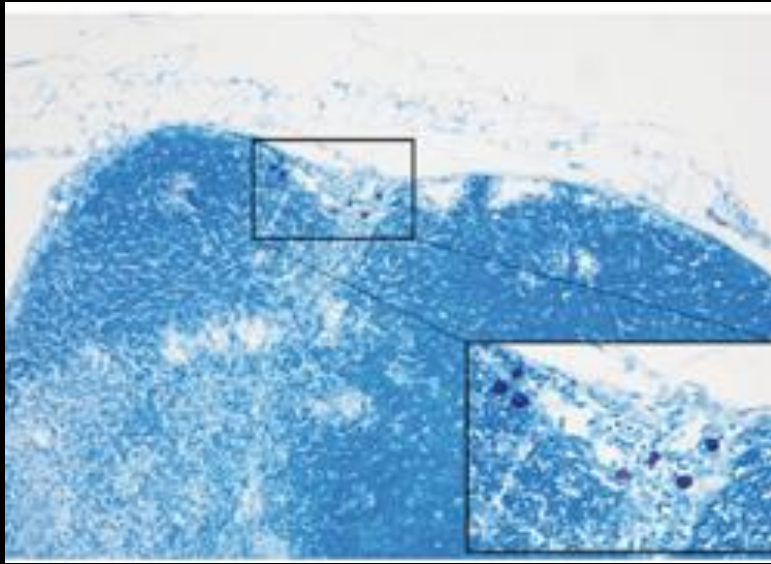
reticulumsejtek



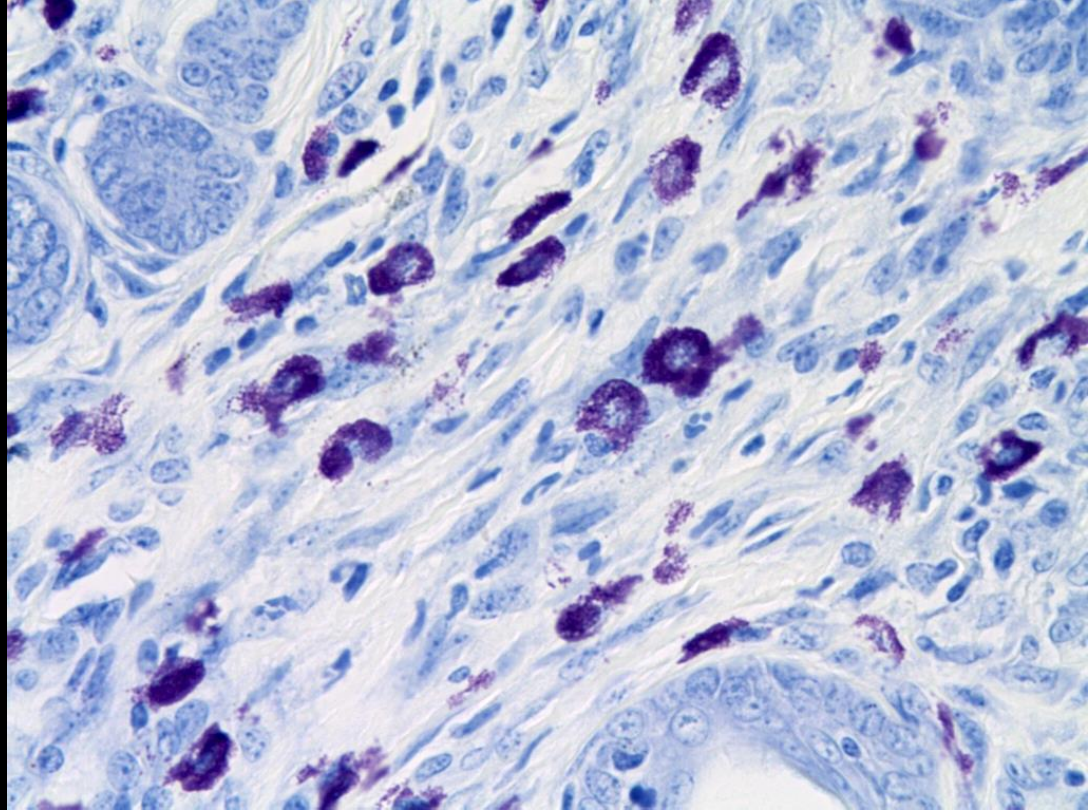
20 µm



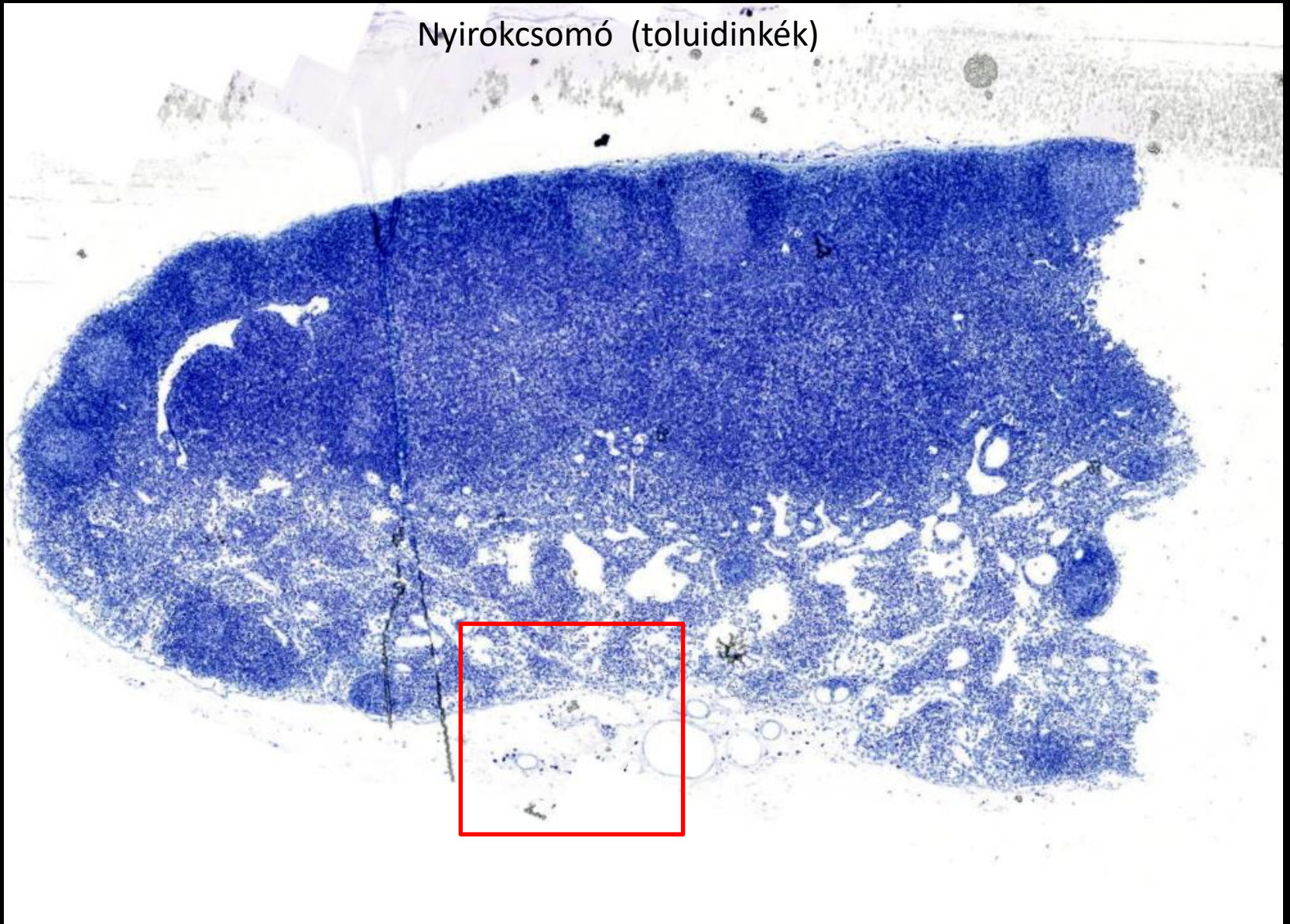
Plazma sejték



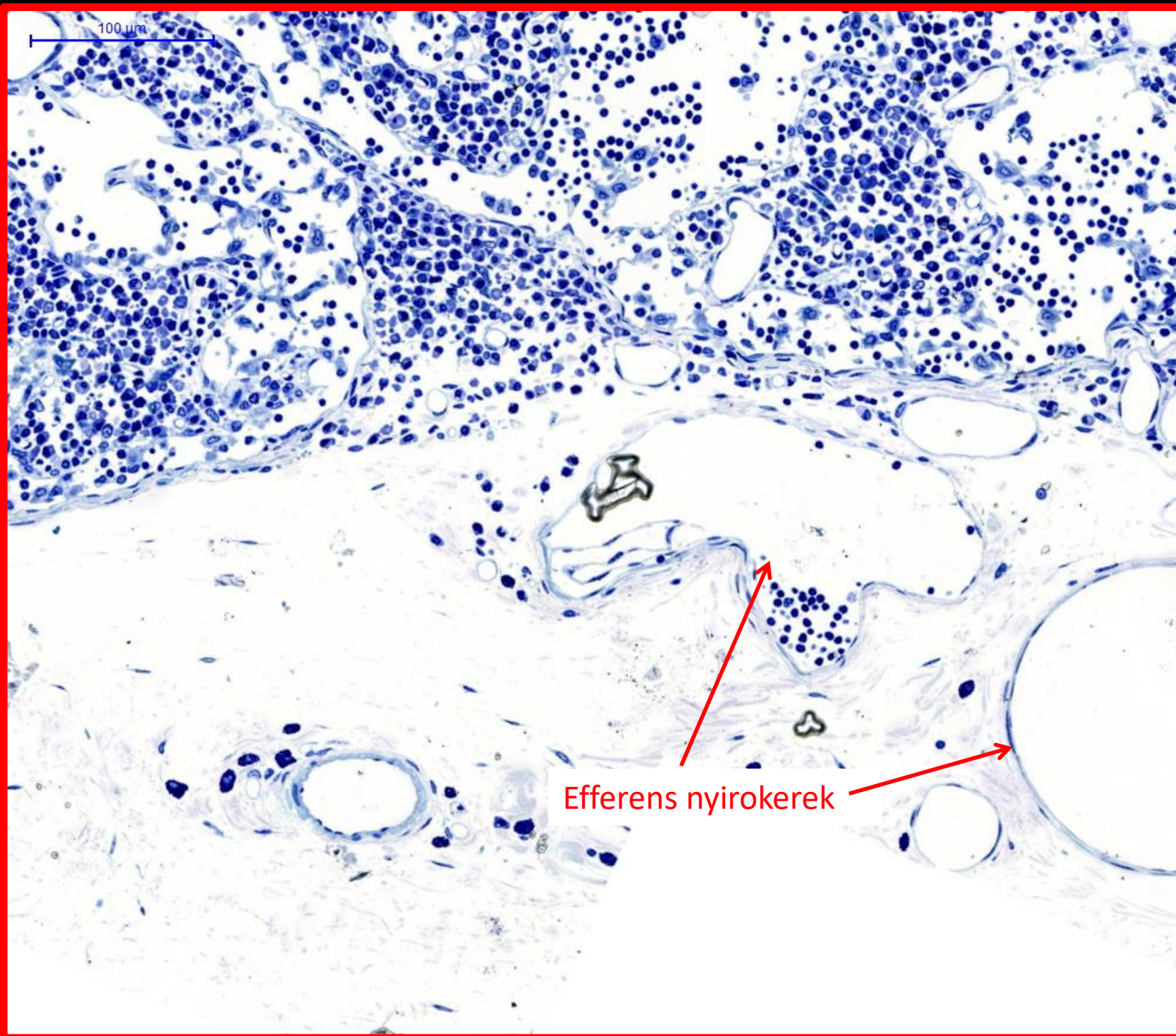
Mastocyták (hízósejtek)



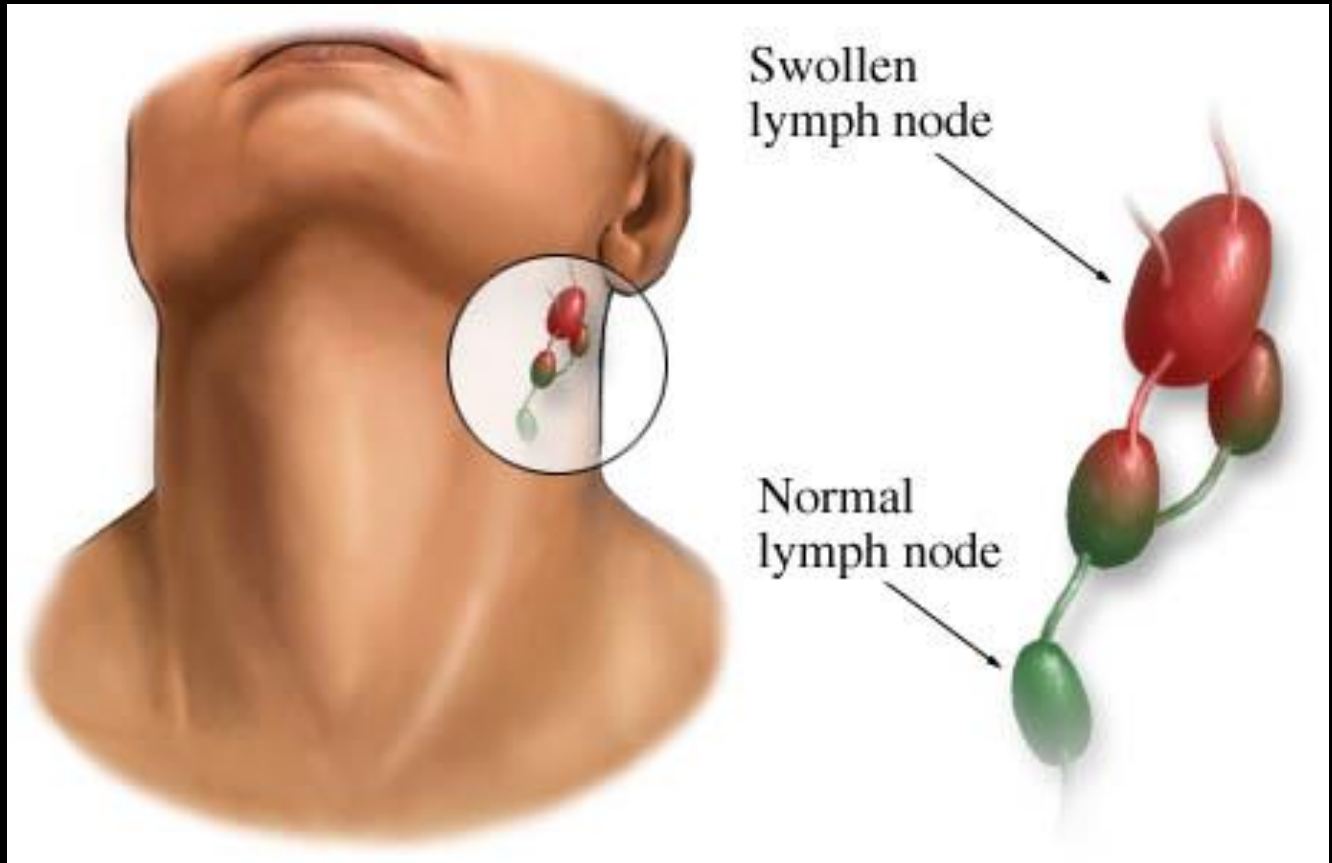
Nyirokcsomó (toluidinkék)



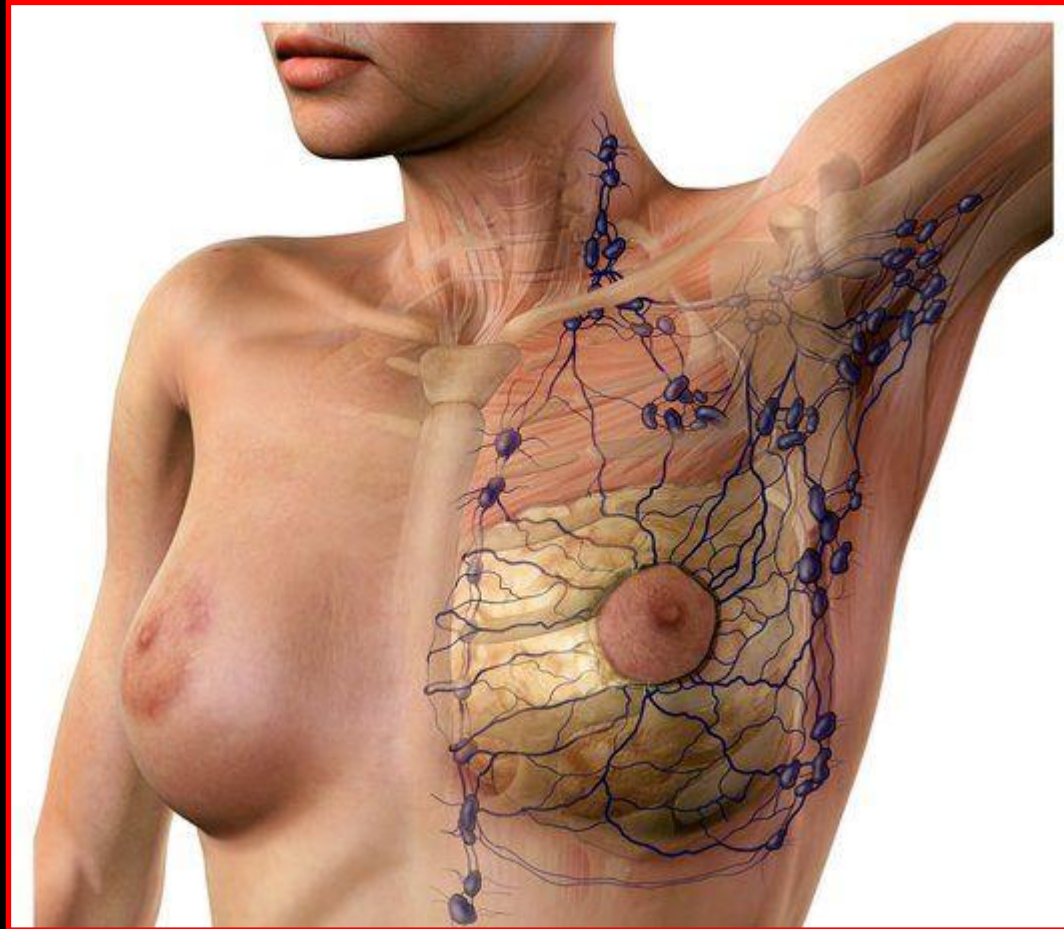
100 µm



Efferens nyrokerek

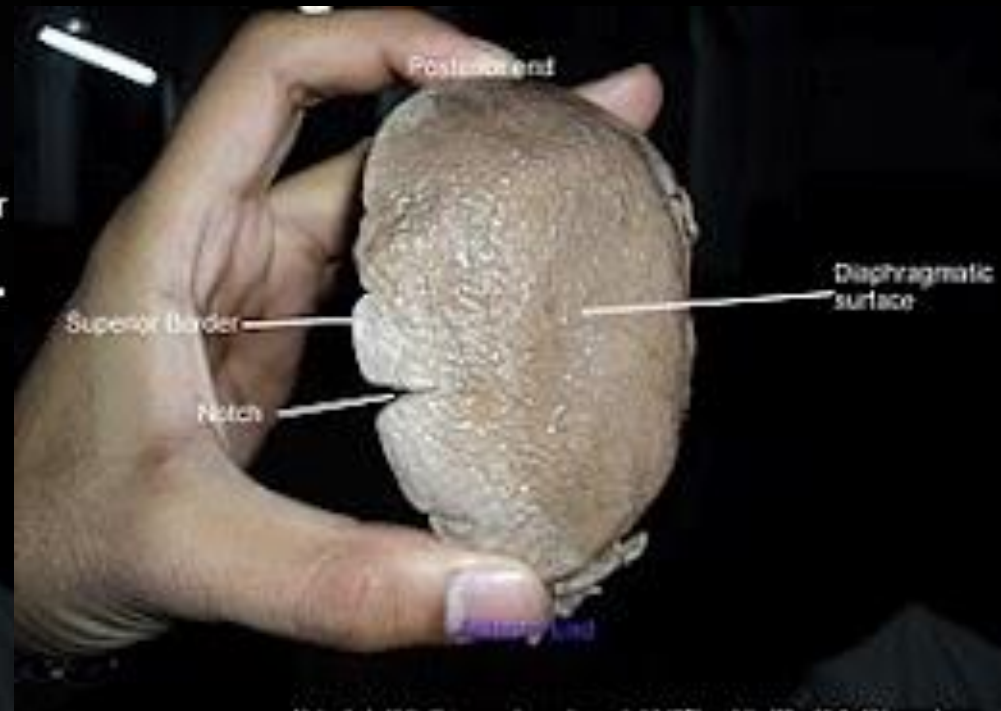
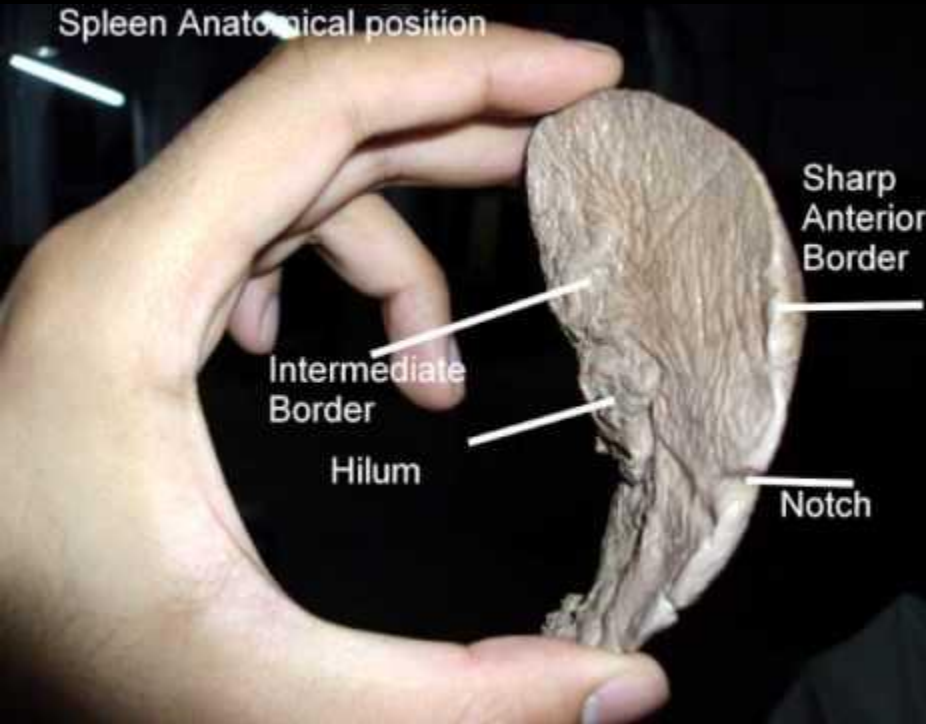


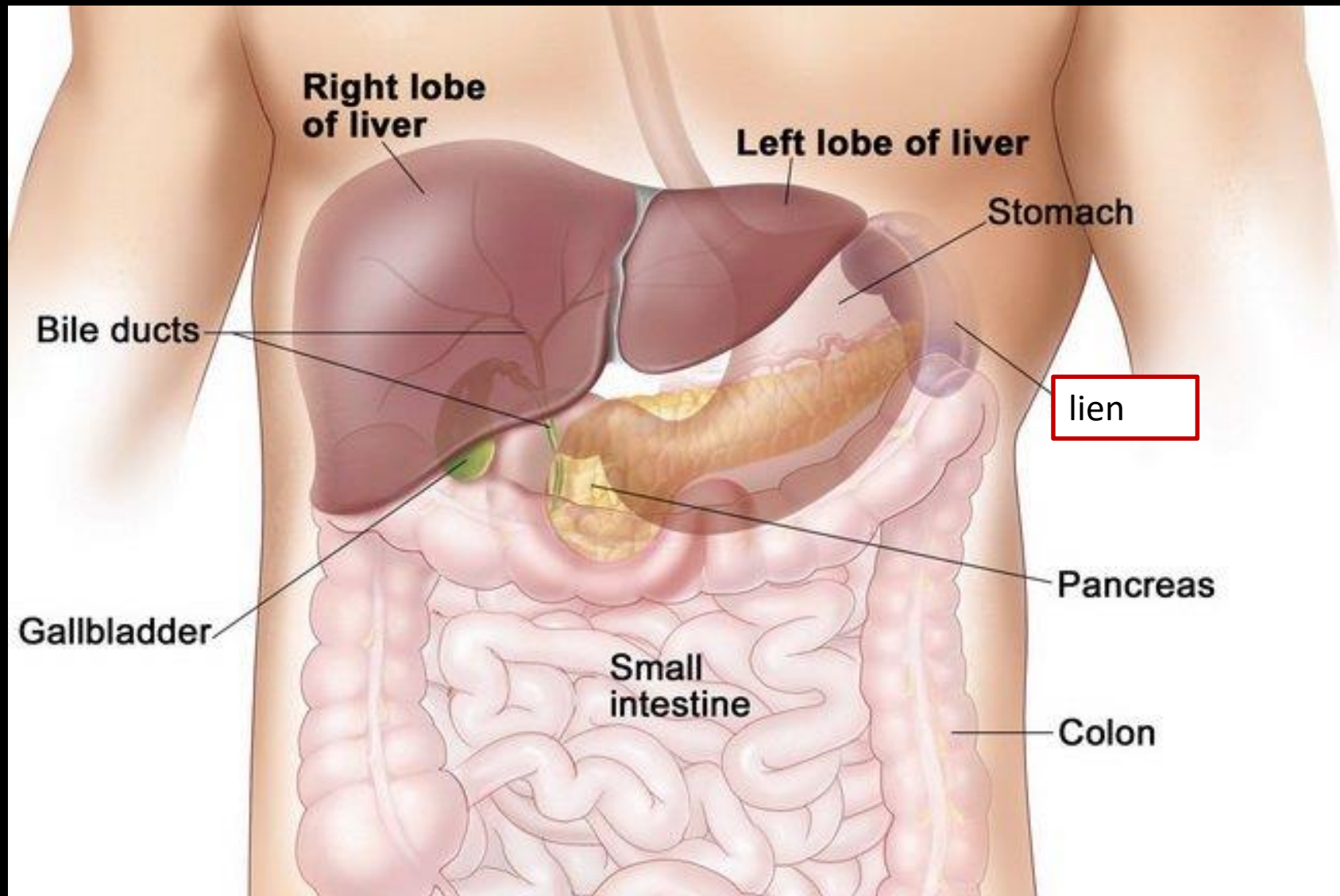
Axillaris blokk dissectio

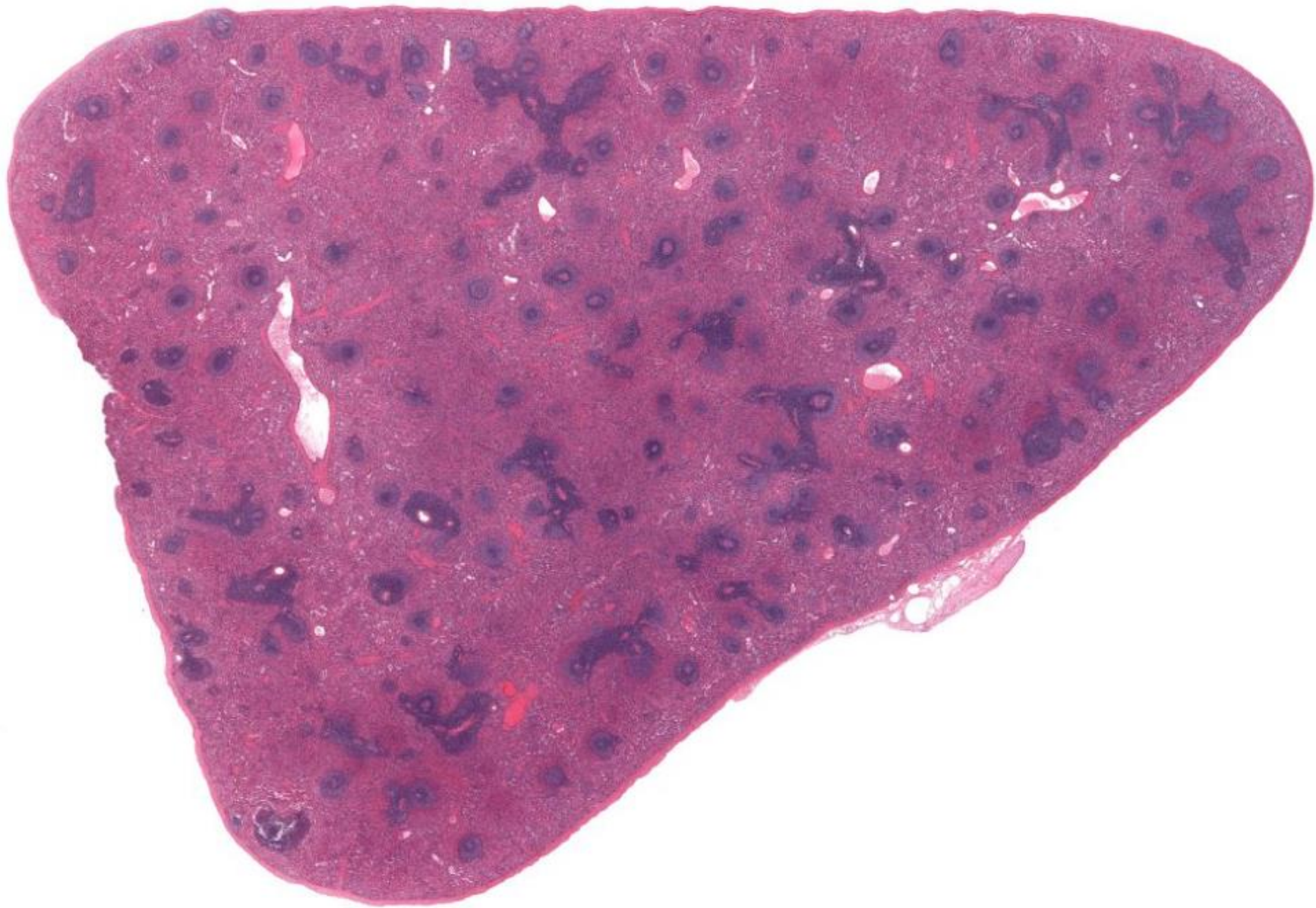

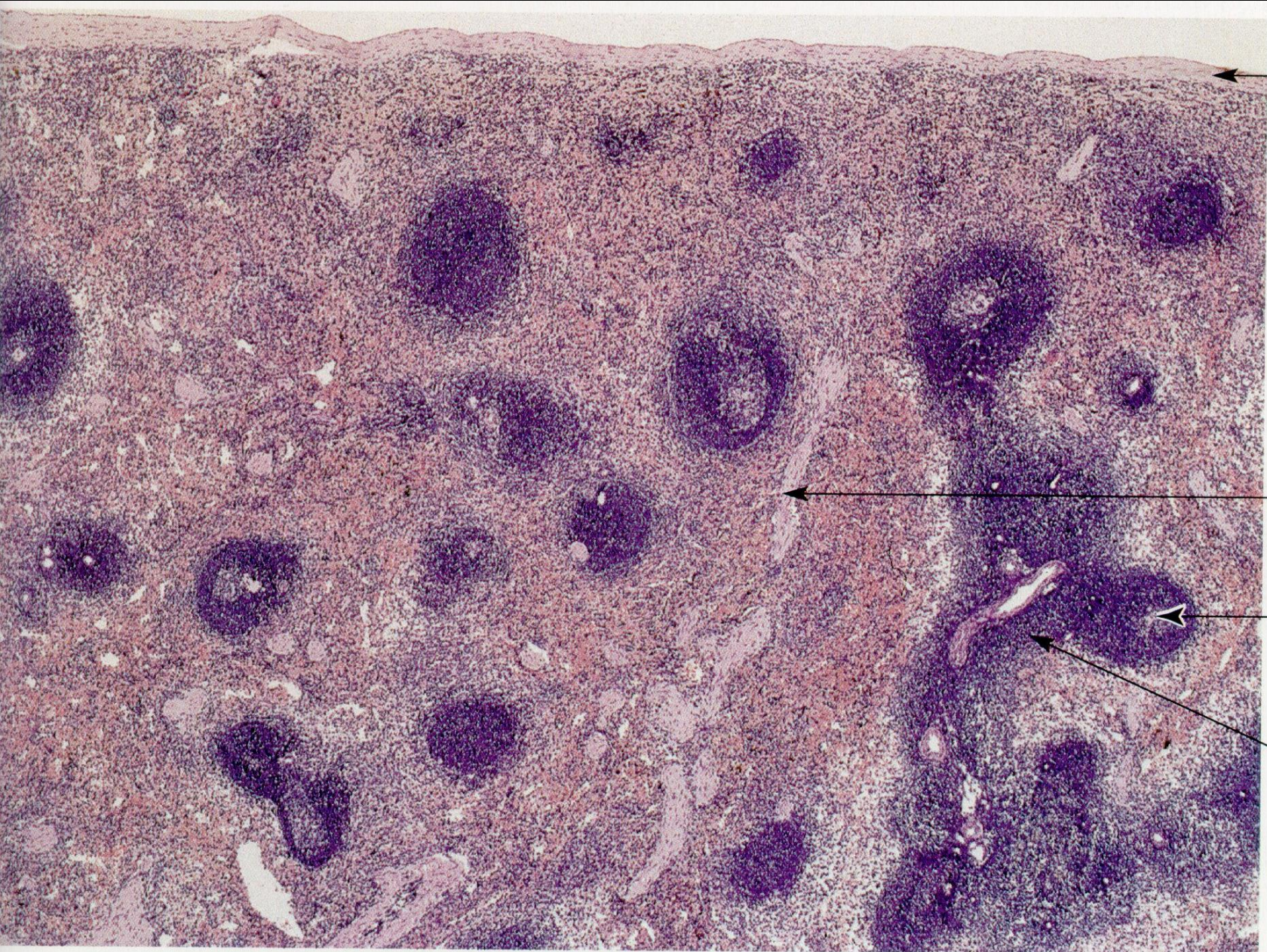
Lien/Splen (lép)

Spleen Anatomical position









tok

trabecula

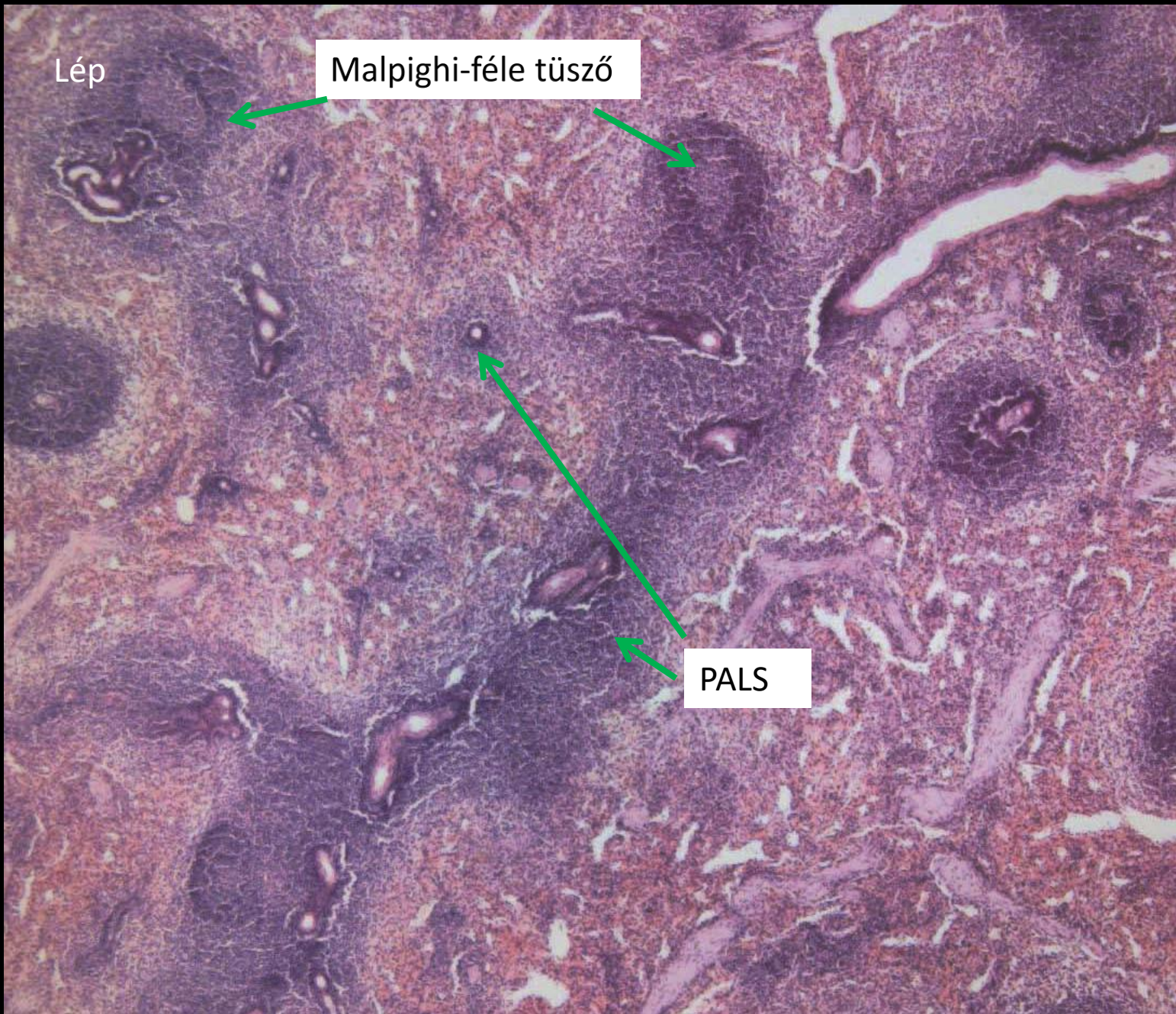
folliculus

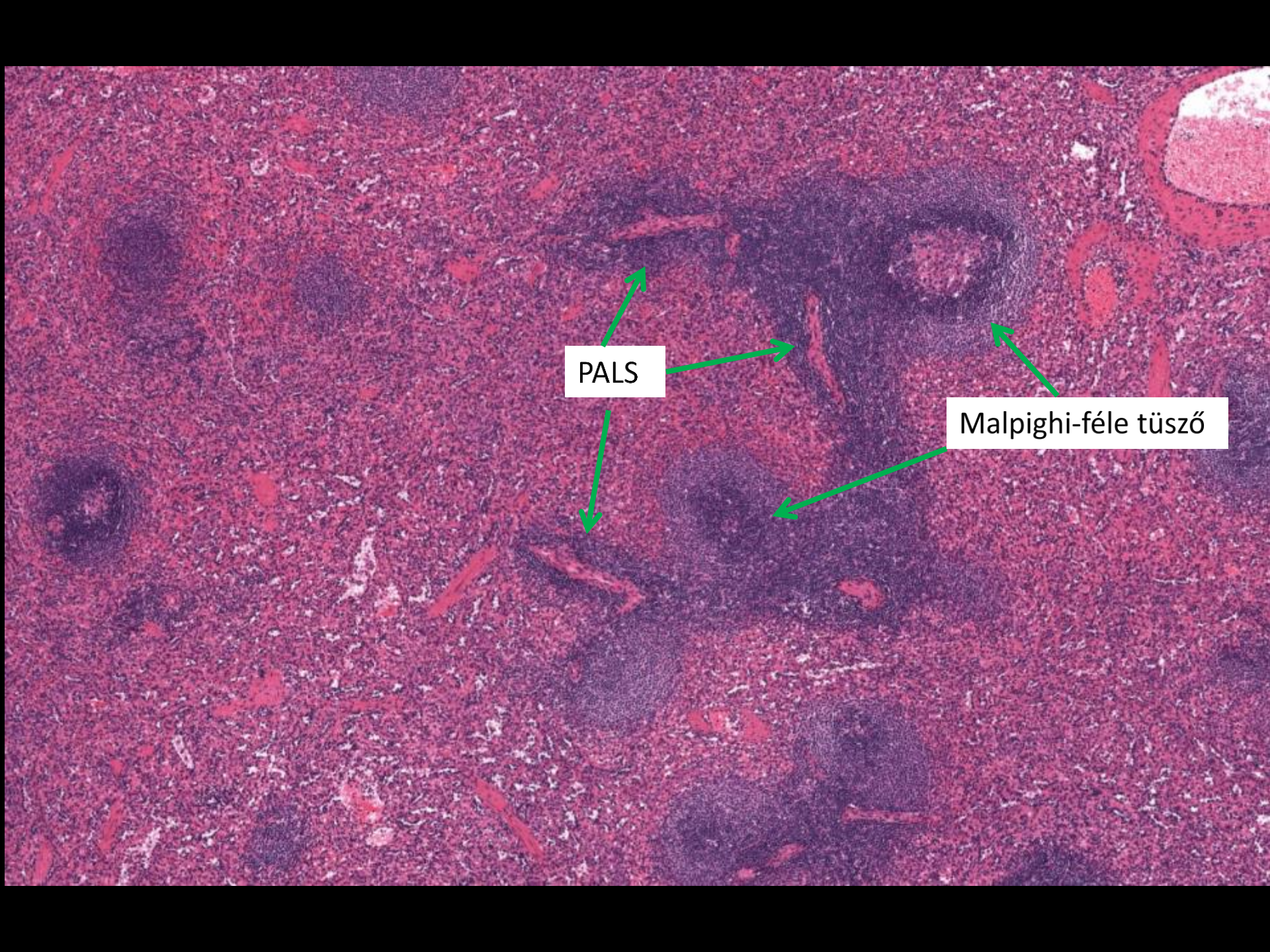
periaarteriális
lymphocytahüvely

Lép

Malpighi-féle tüsző

PALS





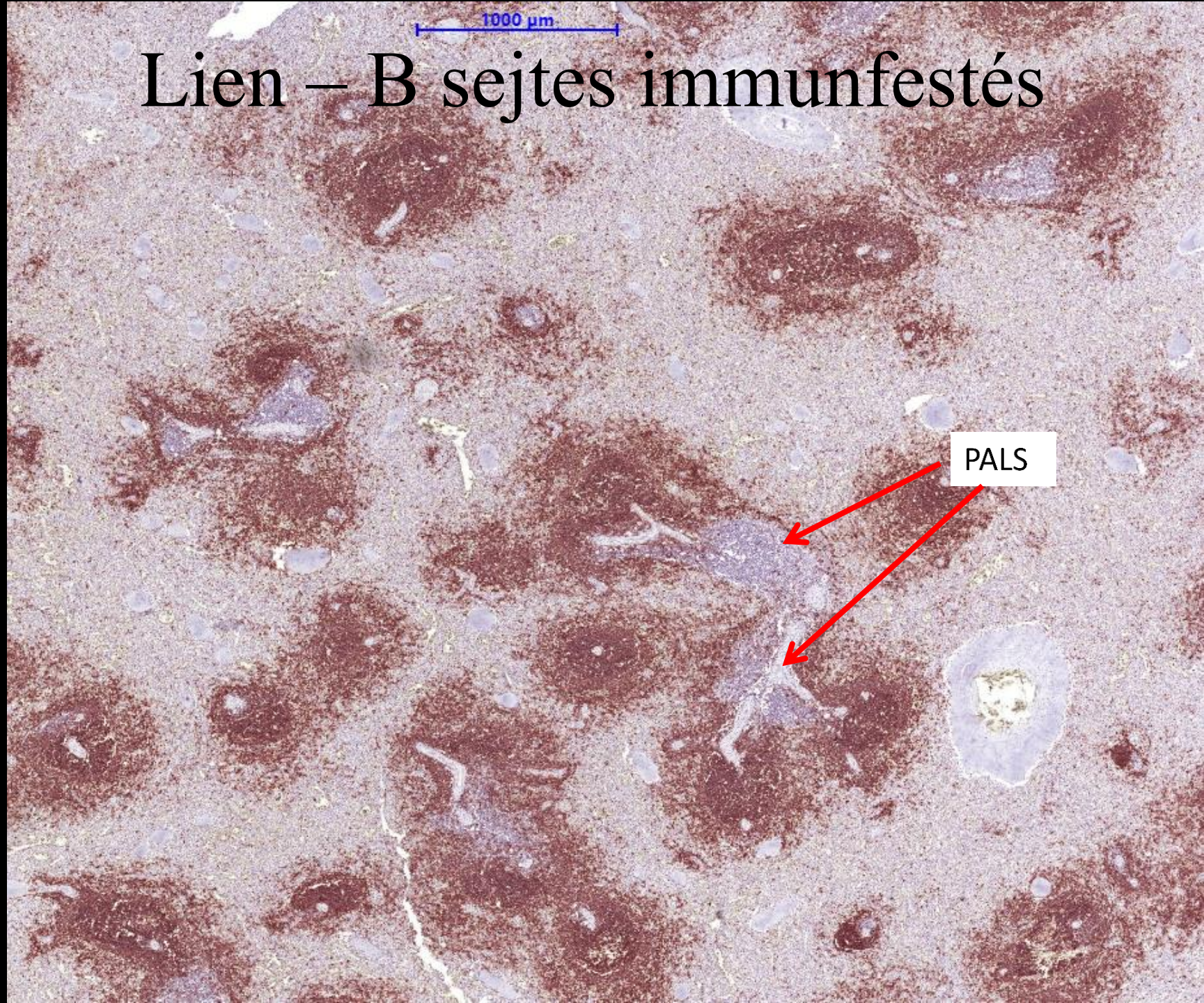
PALS

Malpighi-féle tüsző

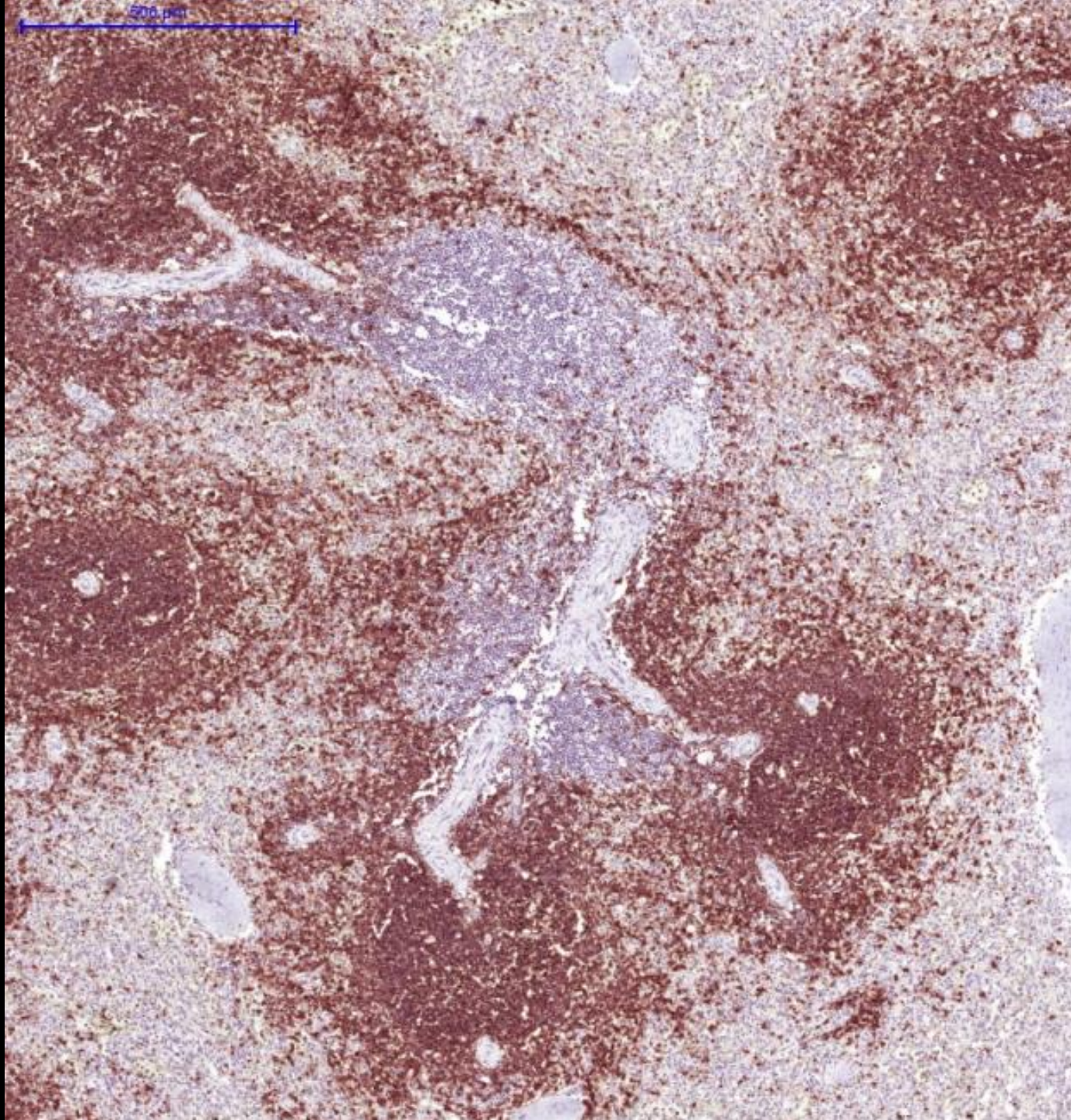
Lien – B sejtes immunfestés

1000 μm

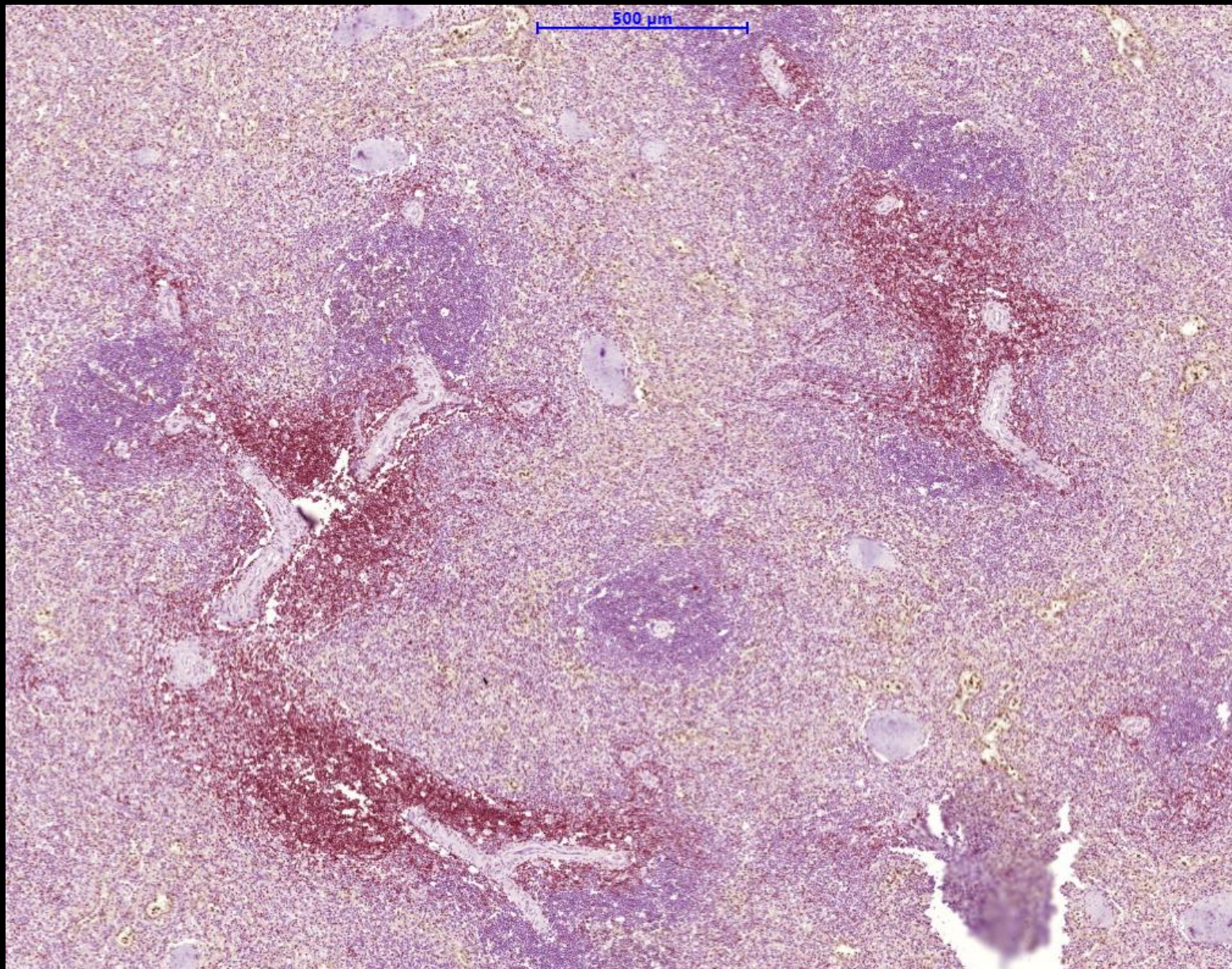
PALS

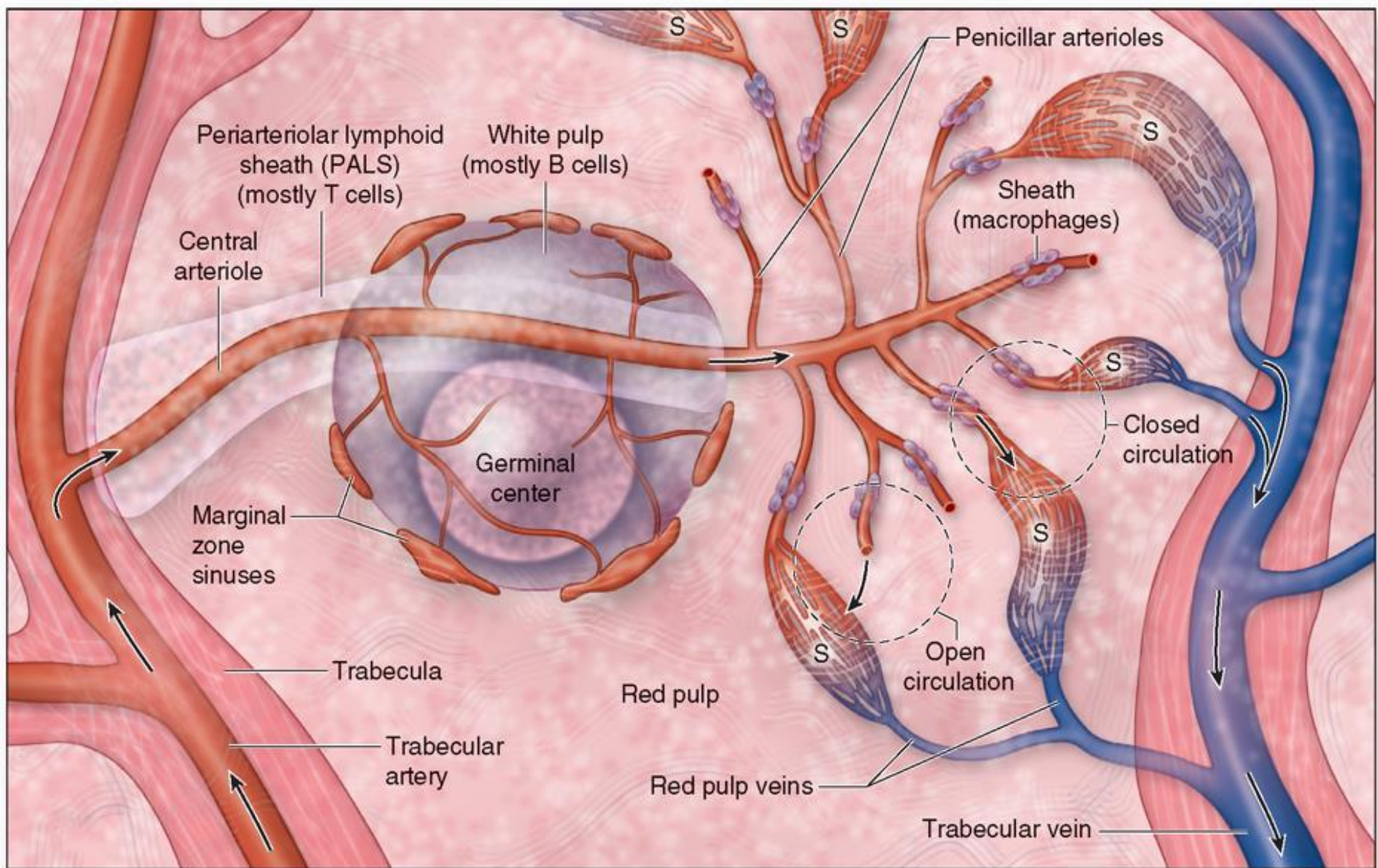


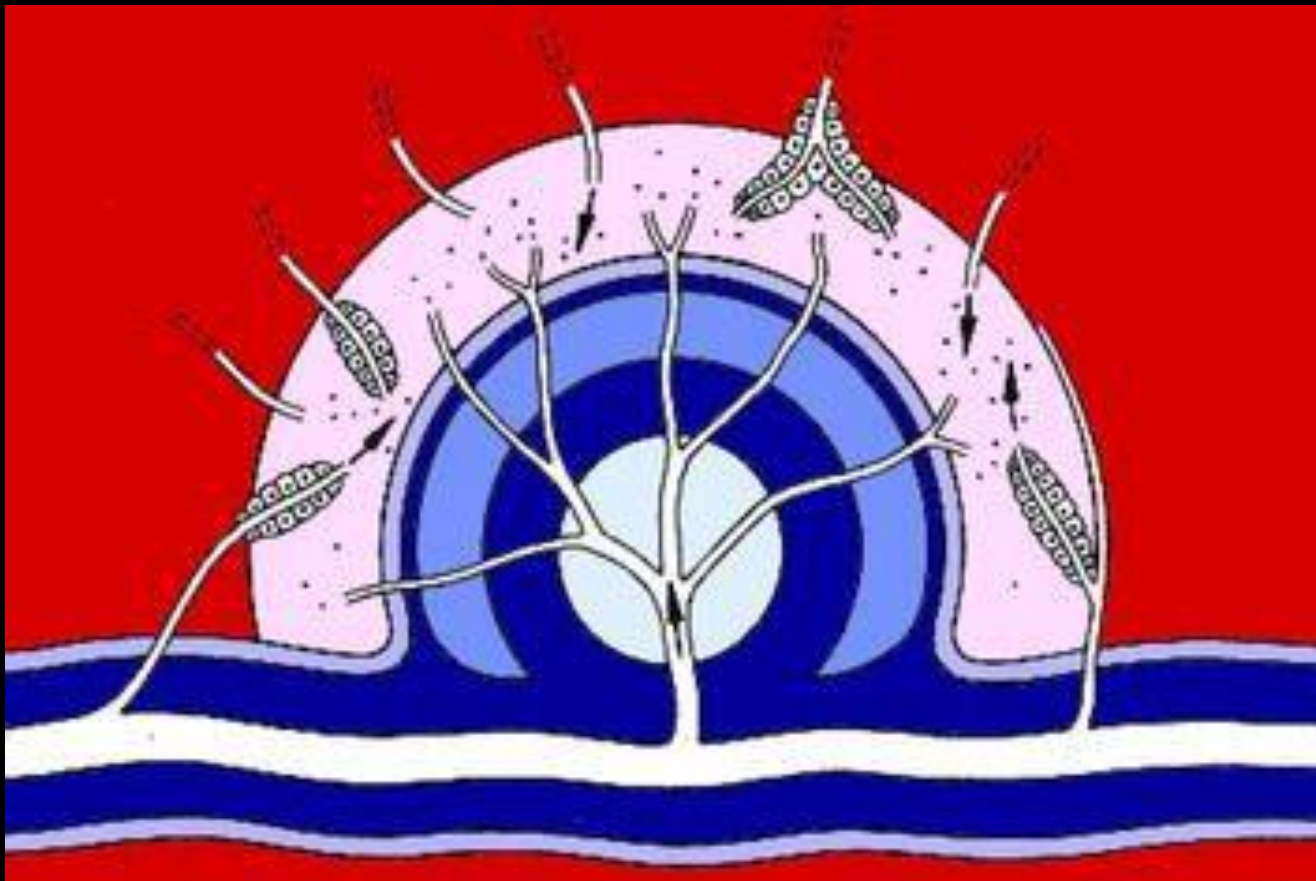
500 µm



T sejtes immunfestés



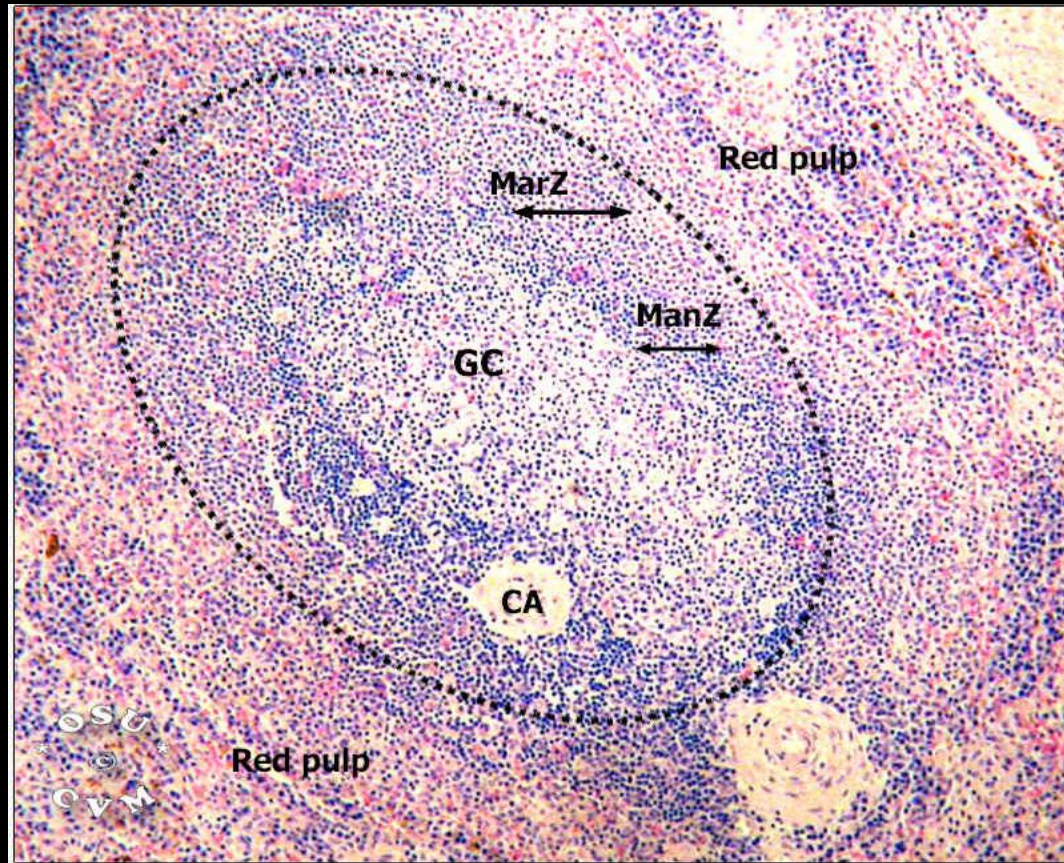


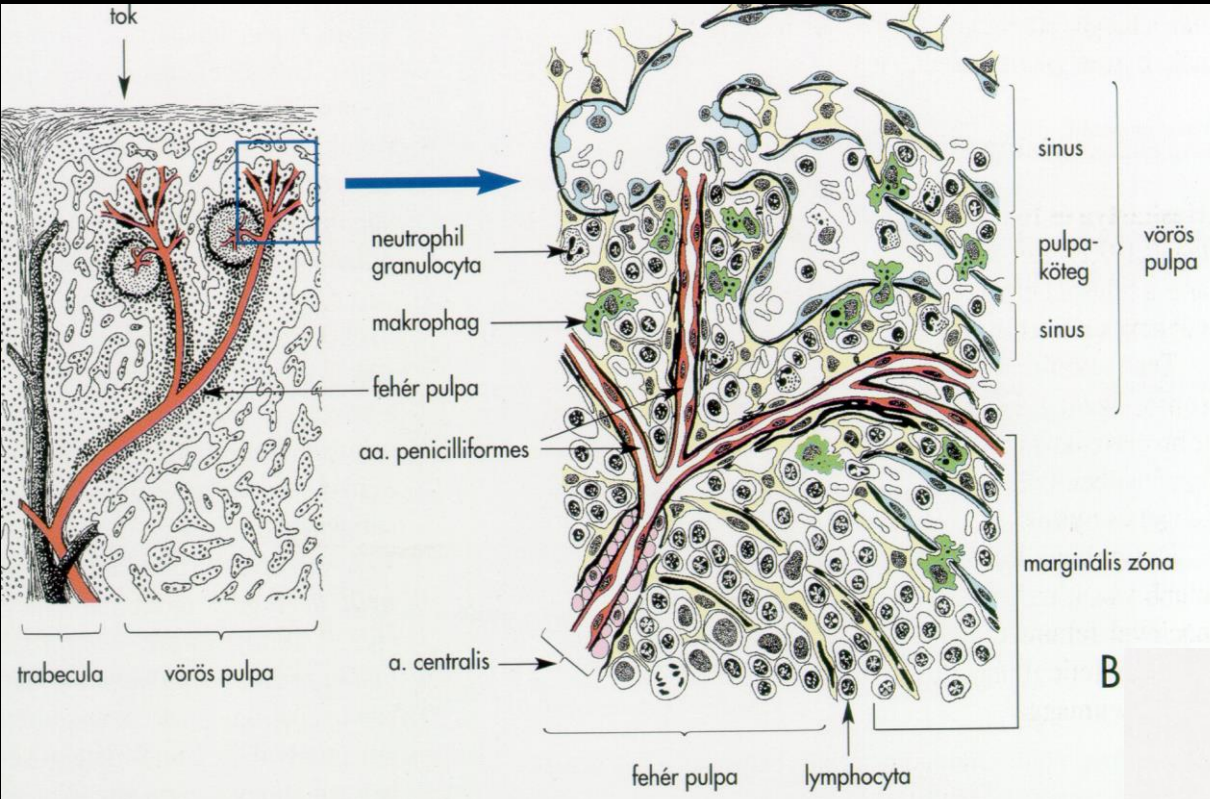


Fehér pulpa hosszmetset emberben. A folliculus a PALS (sötét kék) szélén helyezkedik el. A centralis arteriola (fehér). A centrum germinativumot (fehér) a köpeny zóna (sötét kék) veszi körbe. Marginalis zóna (világos kék) belső részében B sejtekkel. Ezt T sejt (CD4+) akkumuláció követi (sötét kék), majd ezen kívül újra nagy számú B sejt következik (világos kék). Perifollicularis area (rózsaszín) a vörös pulpa része orsó erekkel.

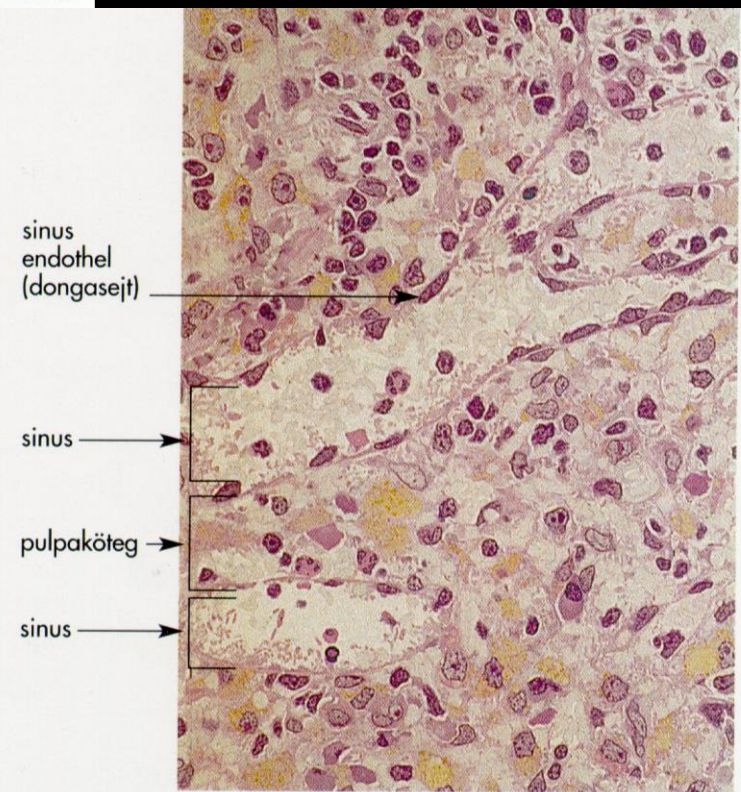
Malpighi-féle tüsző

CA: a. centralis, GC: centrum germinativum,
Man Z: köpeny/sapka zóna, Mar Z: zona marginalis

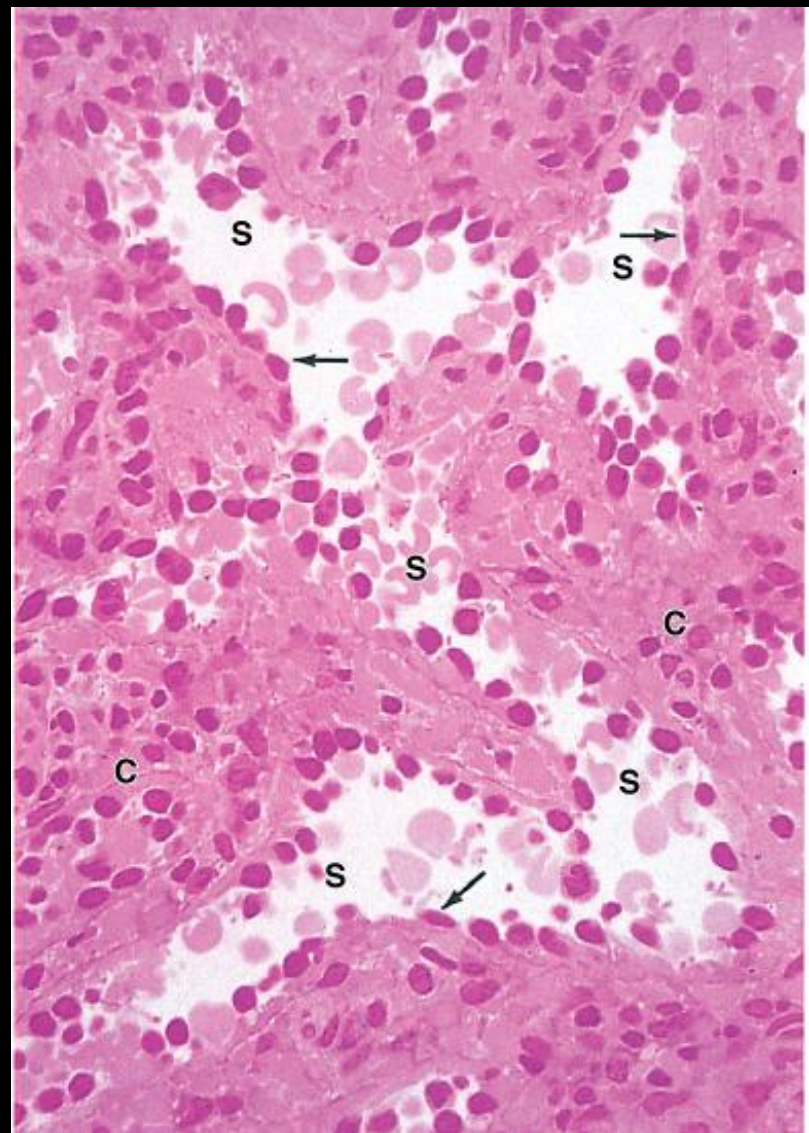
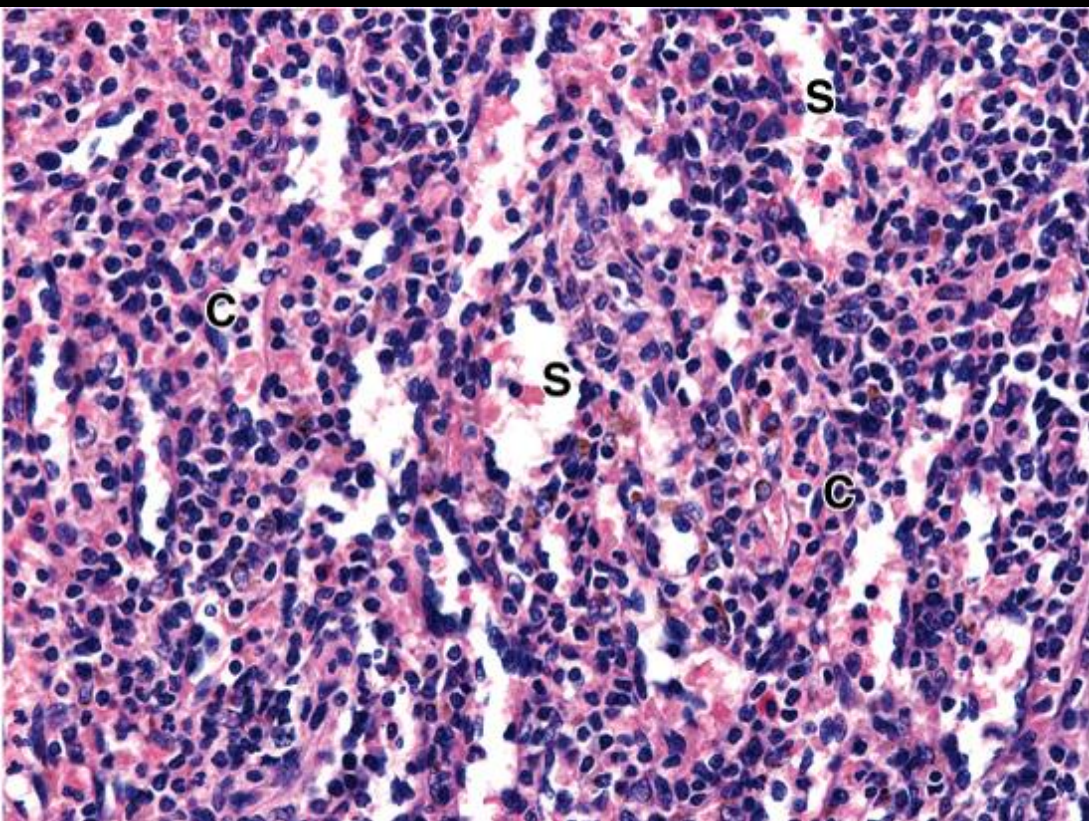


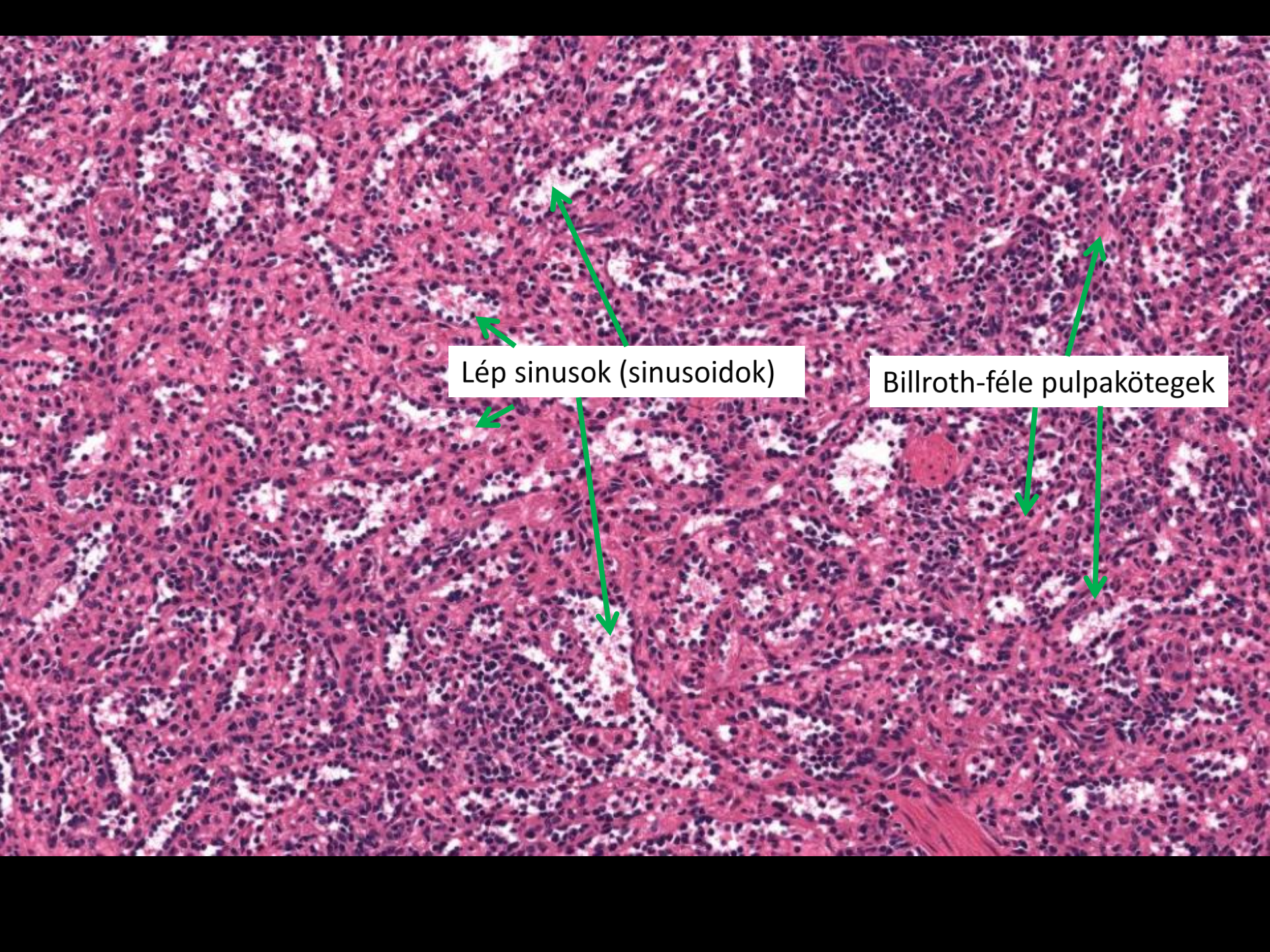


B



Lép sinusok (S) és pulpakötegek (C)

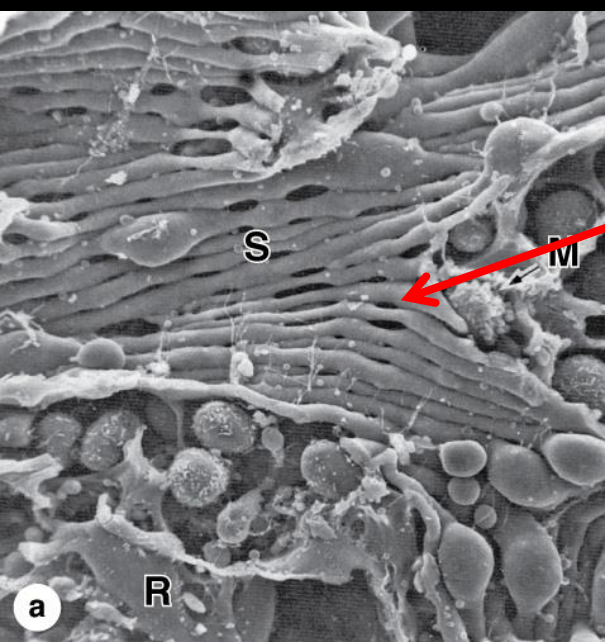
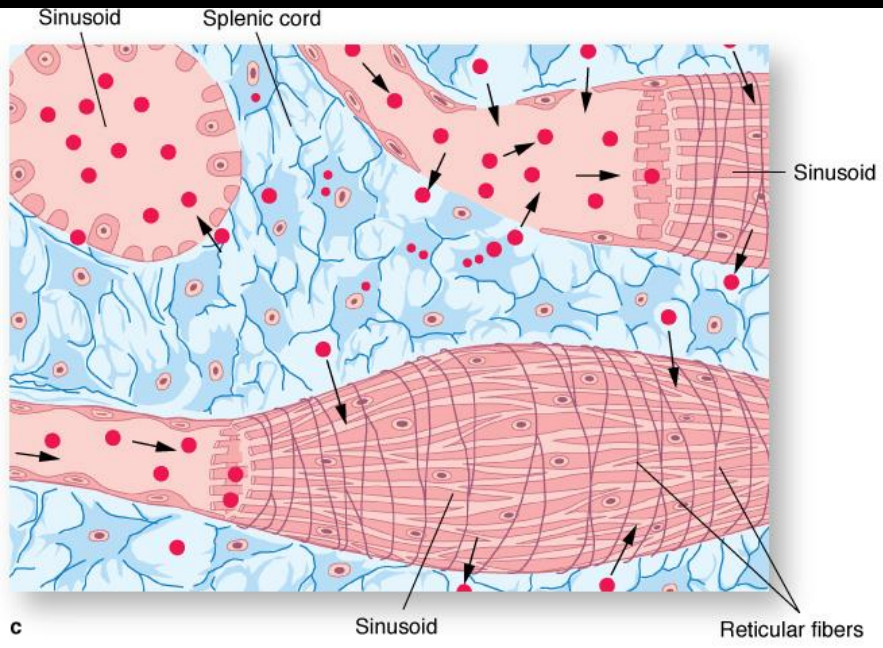




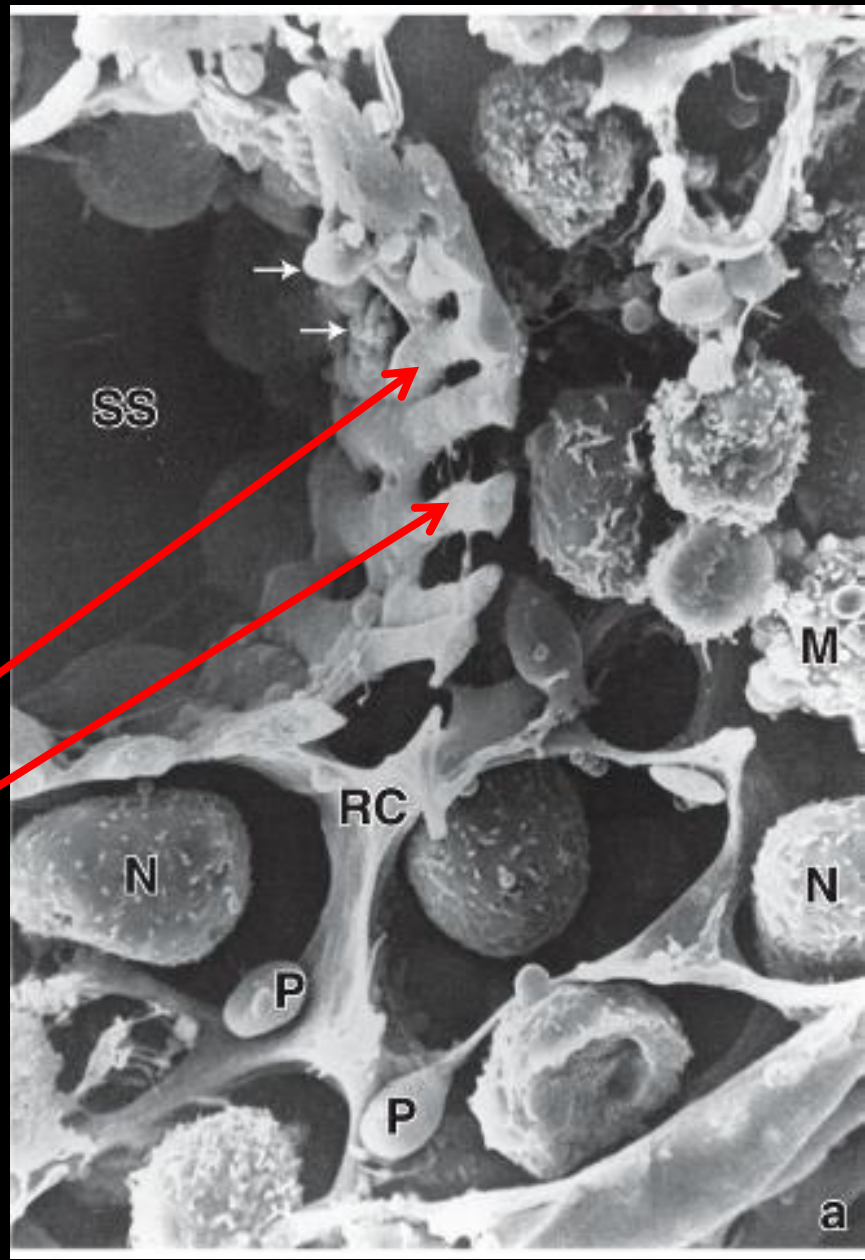
Lép sinusok (sinusoidok)

Billroth-féle pulpakötegek

Lép sinusok és pulpakötegek



Donga sejtek a lép sinusok falában



Pulpaköteg

M: makrofágok, R: reticuláris sejtek

