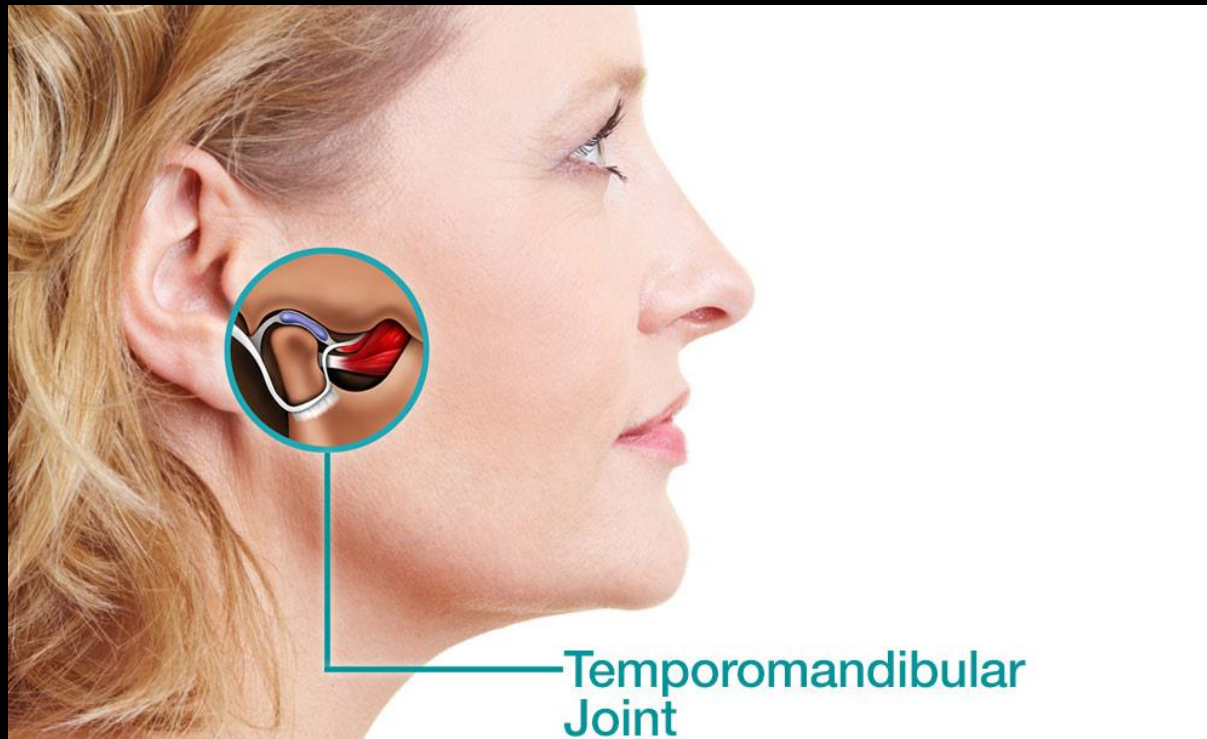
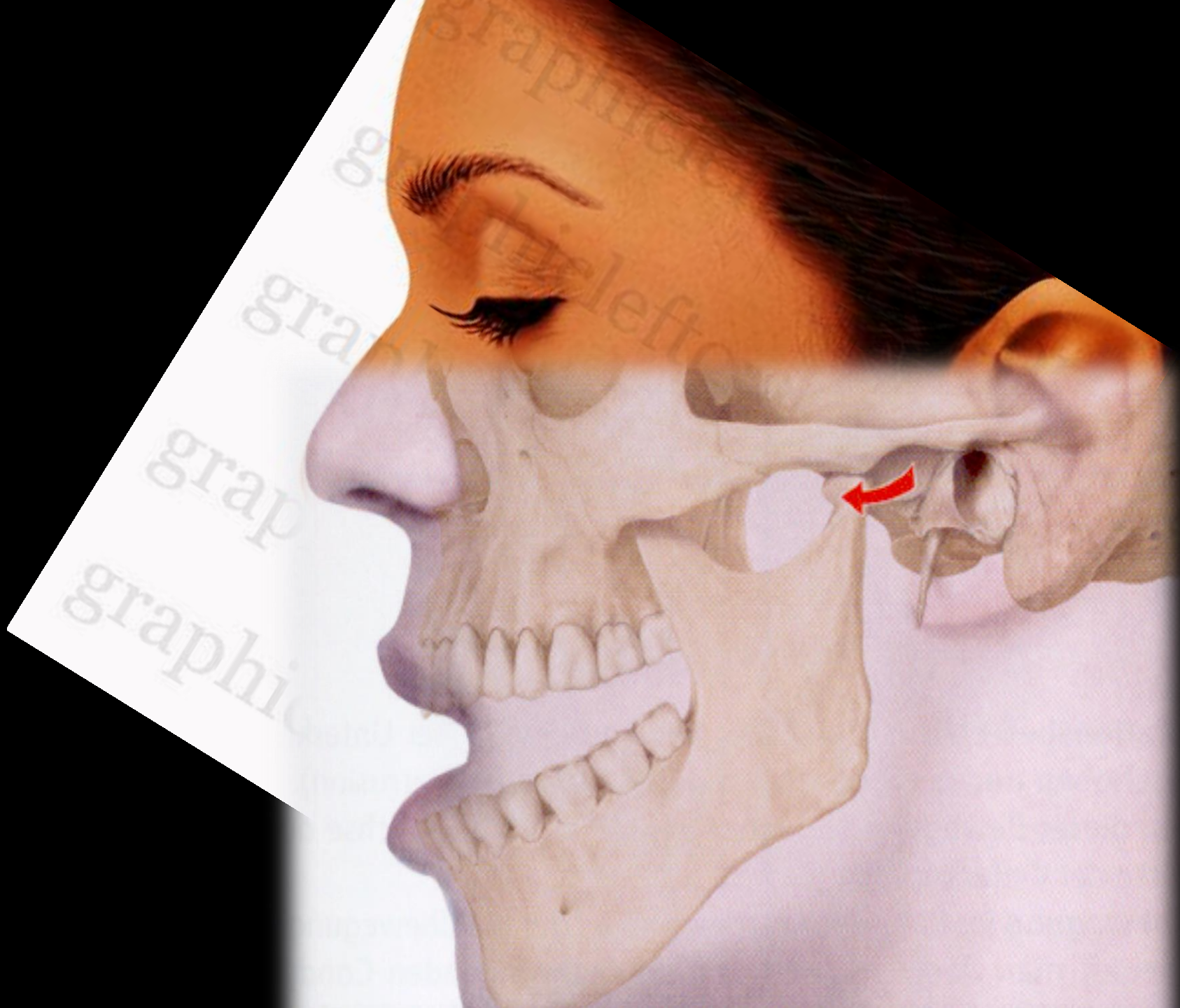
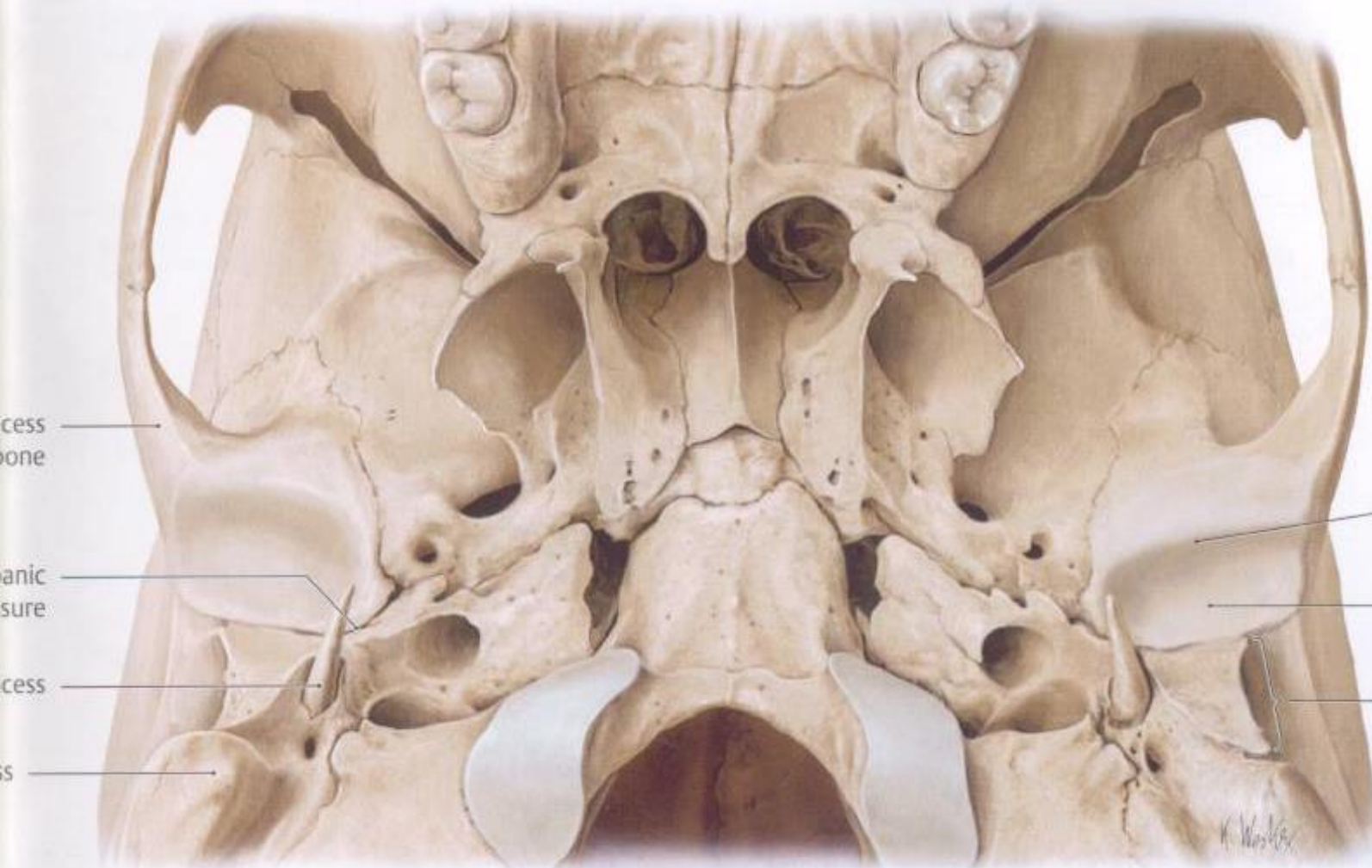


ARTICULATIO TEMPOROMANDIBULARIS, RÁGÓIZMOK ÉS MIMIKAI IZMOK

Barna János







cess
bone

anic
sure

cess

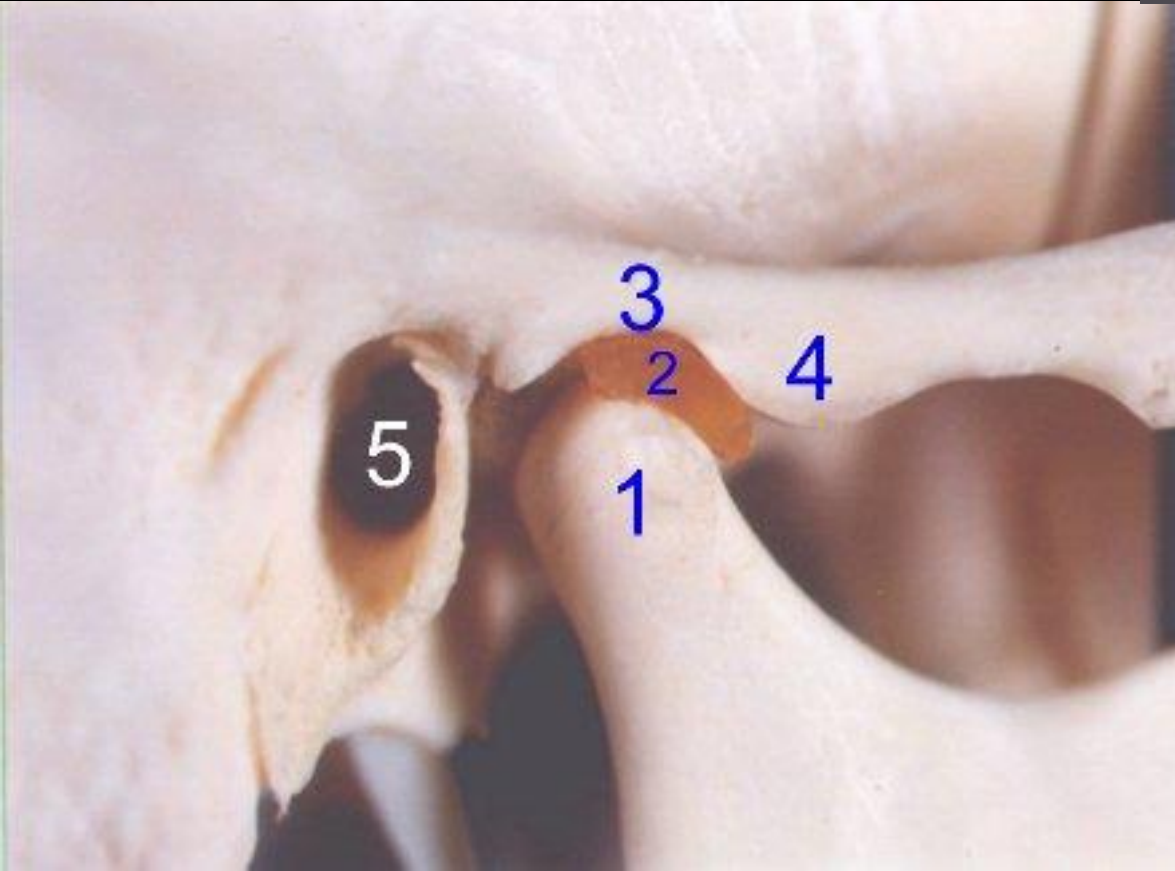
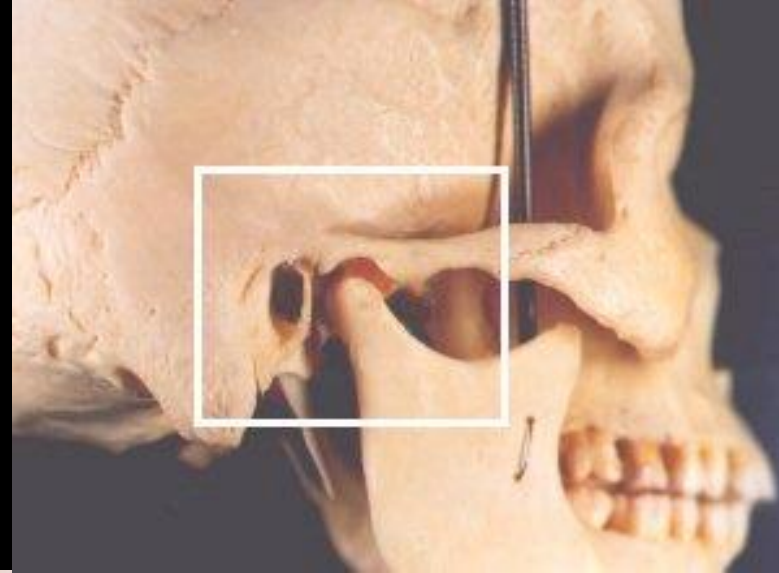
ss

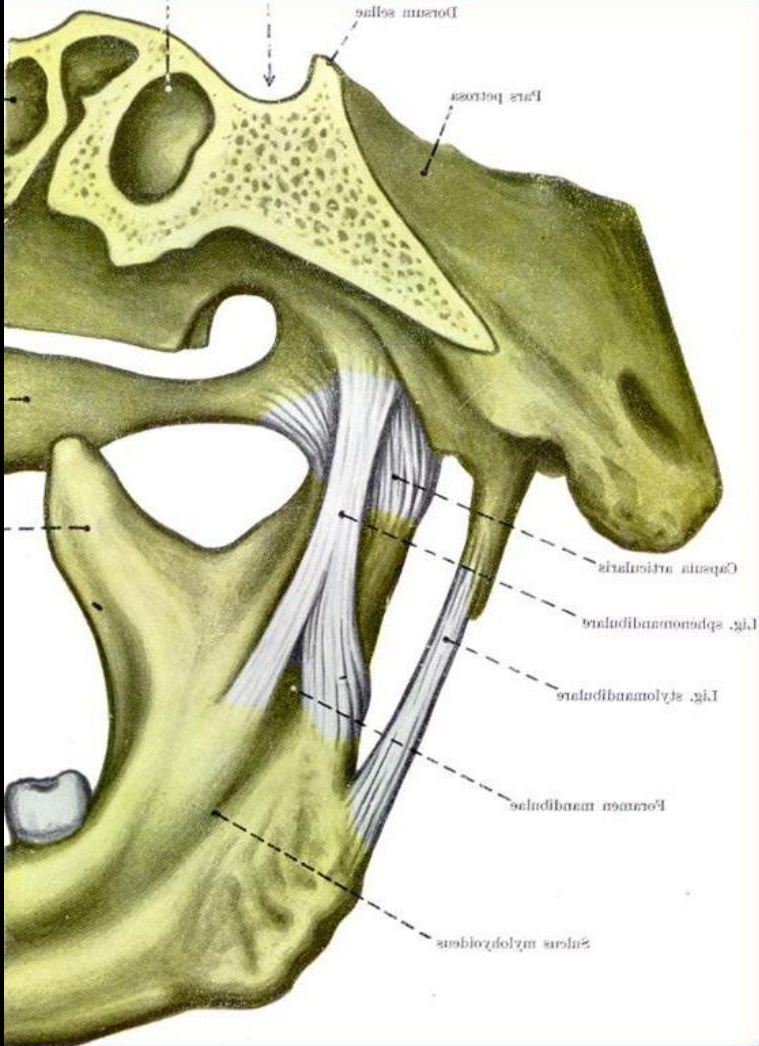
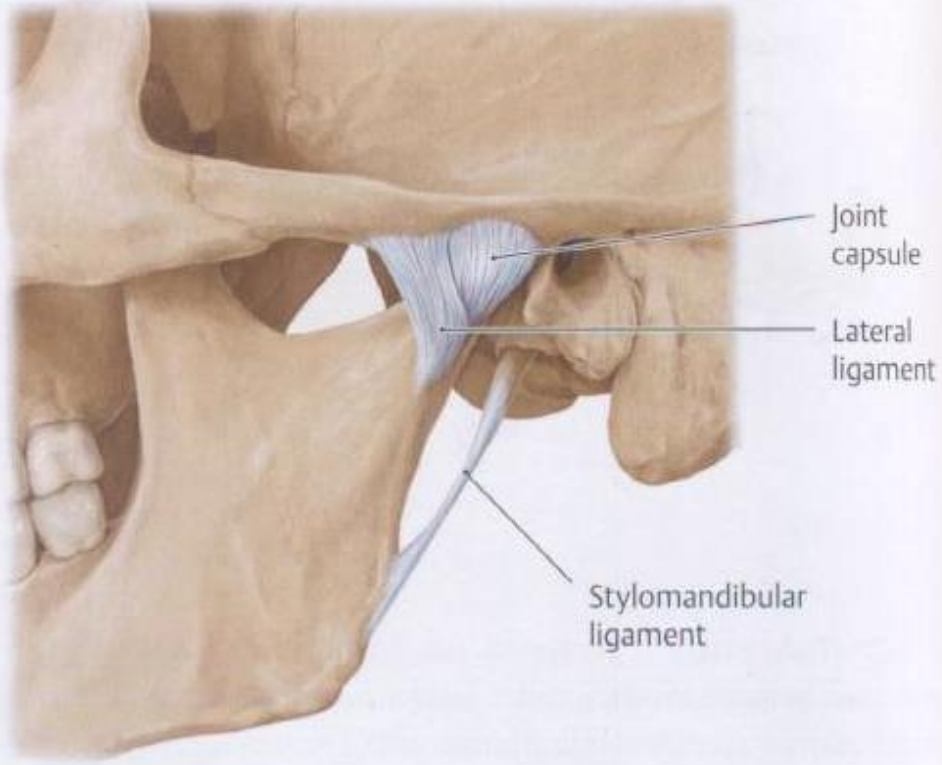
Articular
tubercle

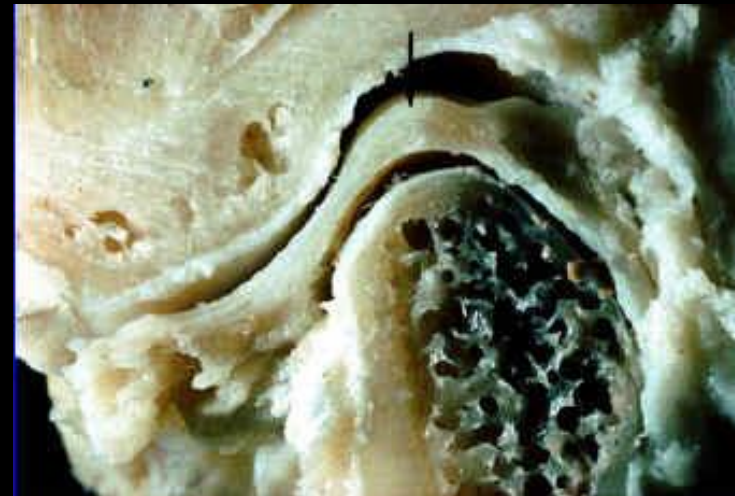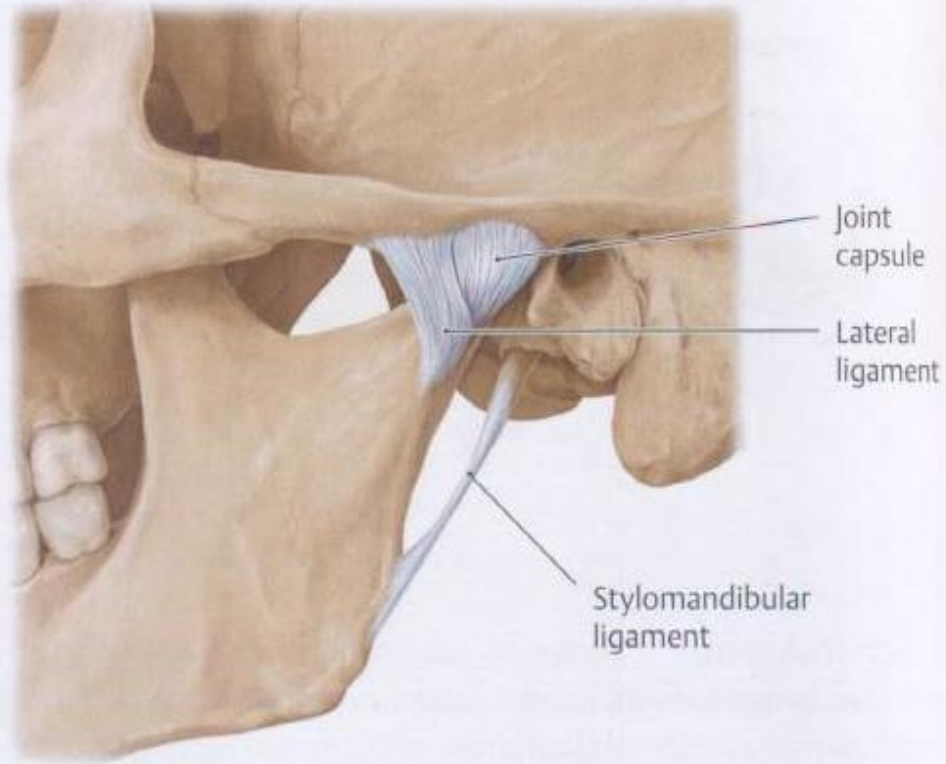
Mandibular
fossa

External
acoustic meatus
(auditory canal)

H. W. H. H.

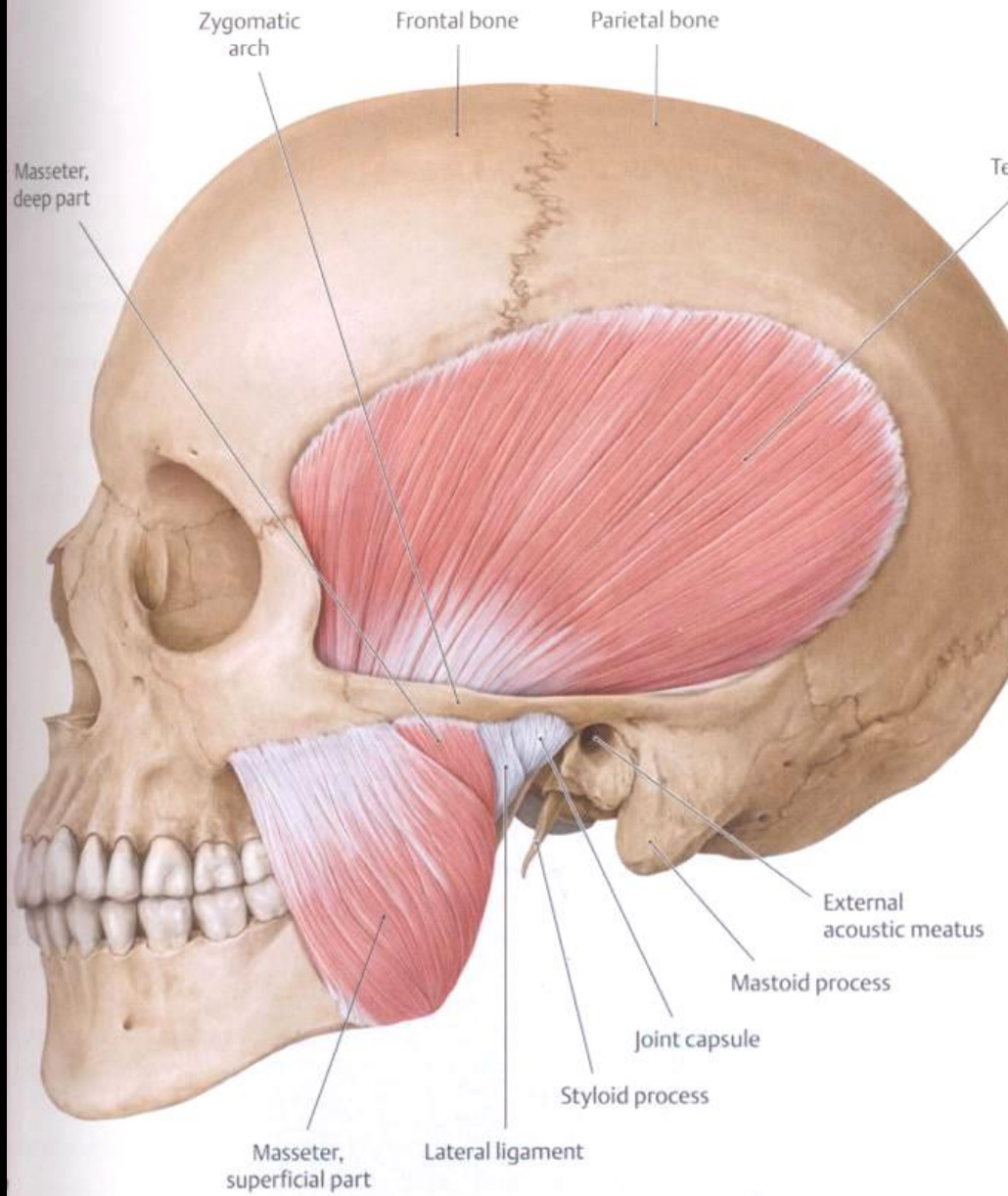


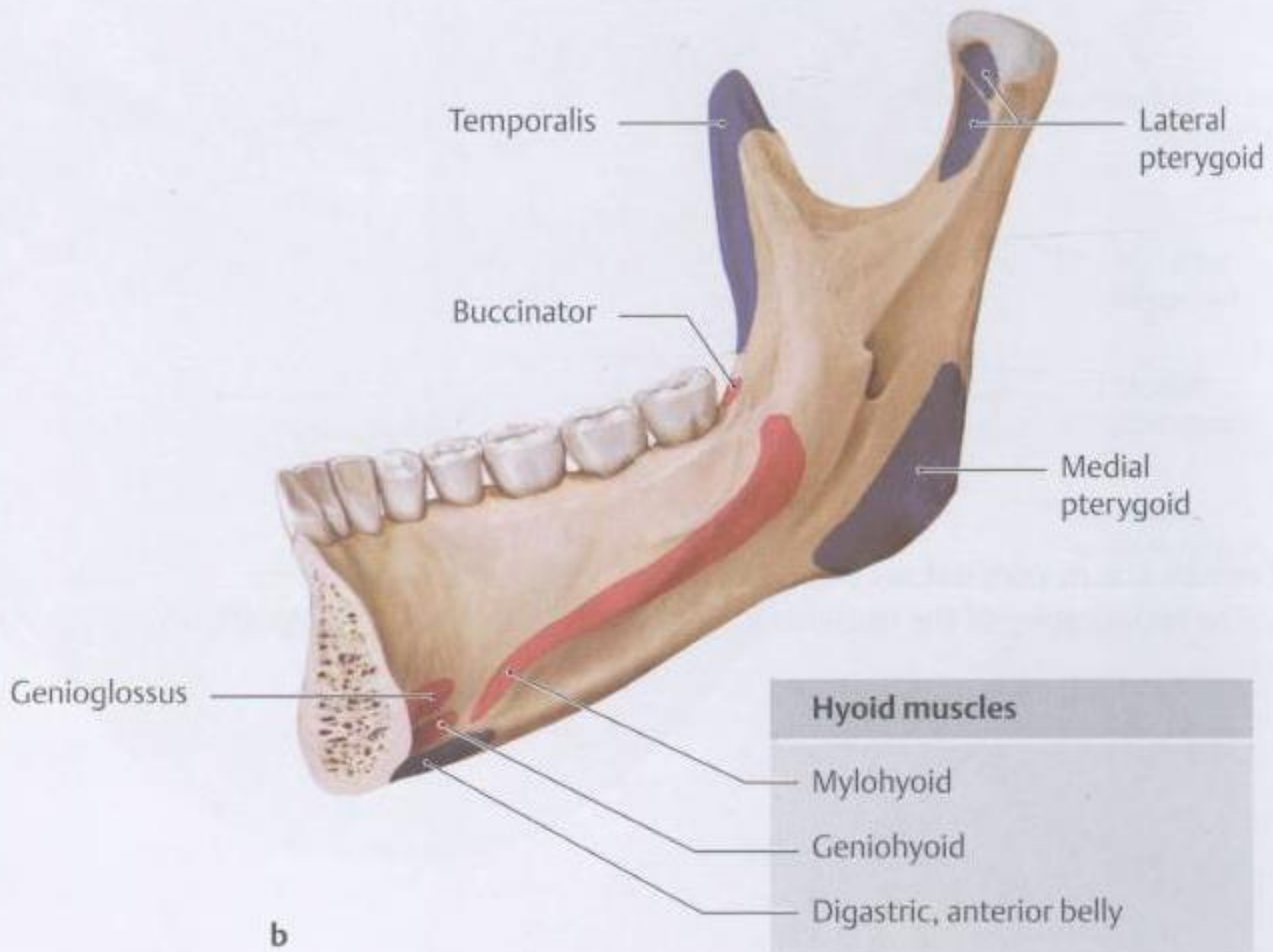




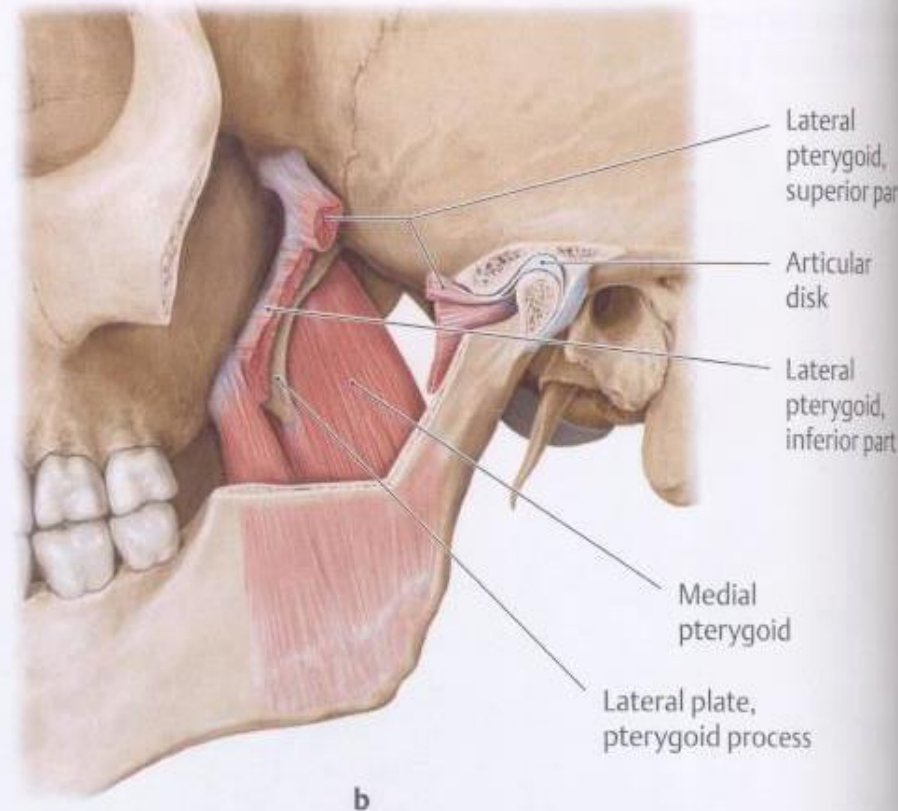
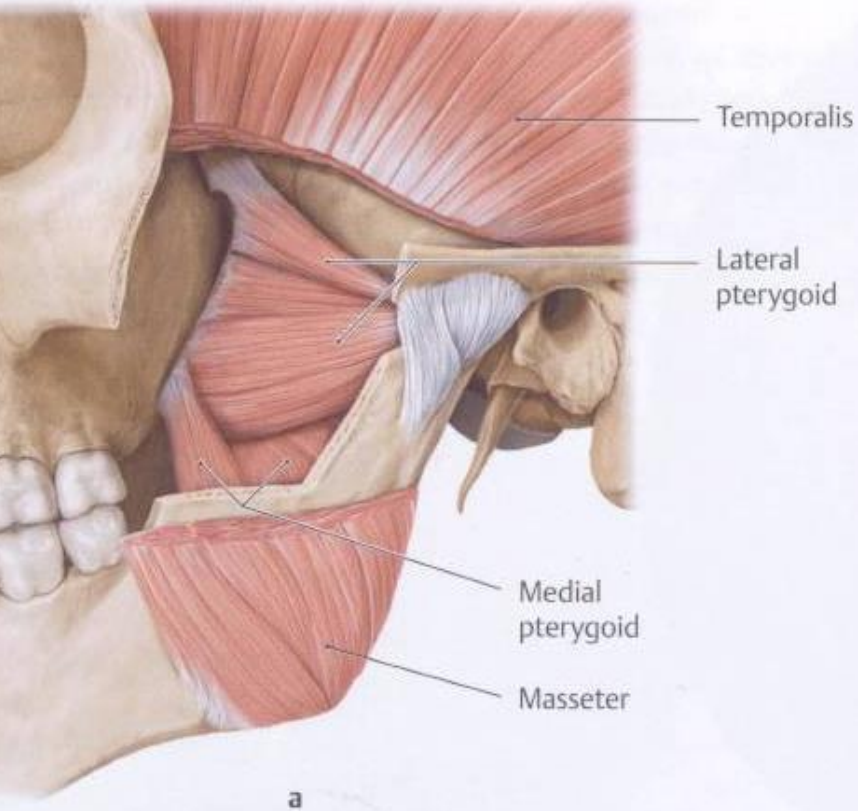
RÁGÓIZMOK

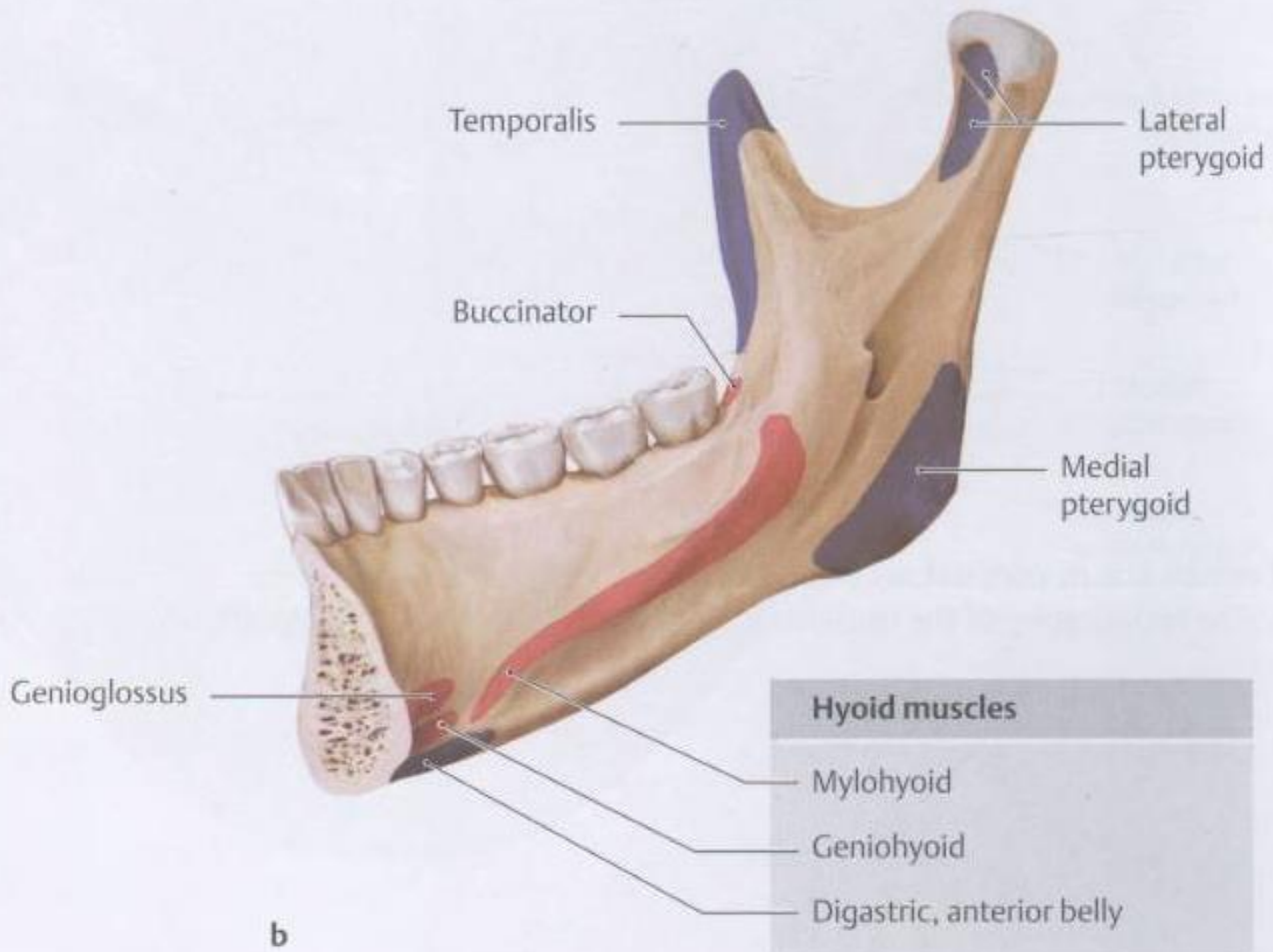
Rágóizmok



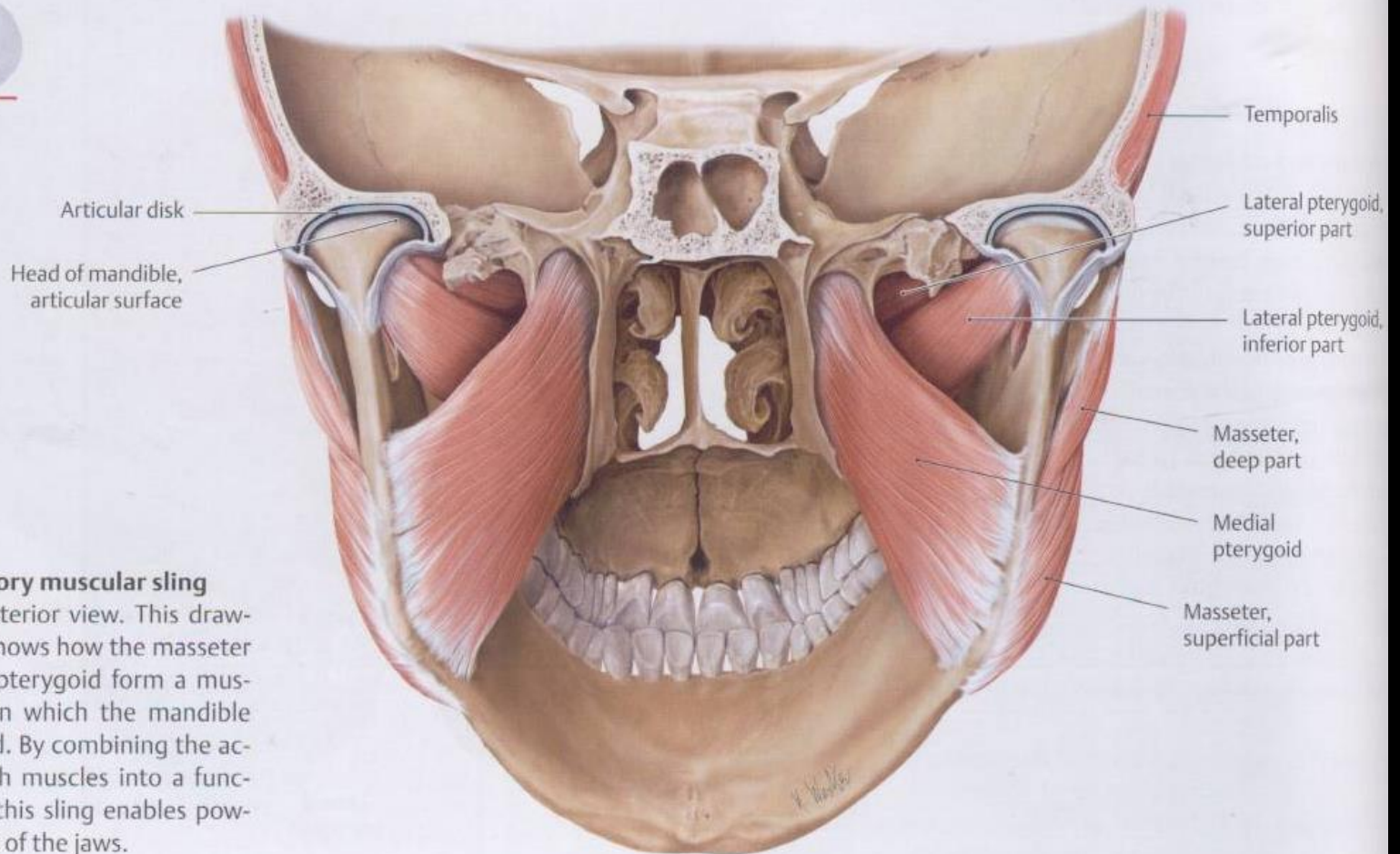
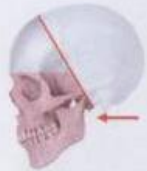

Rágóizmok



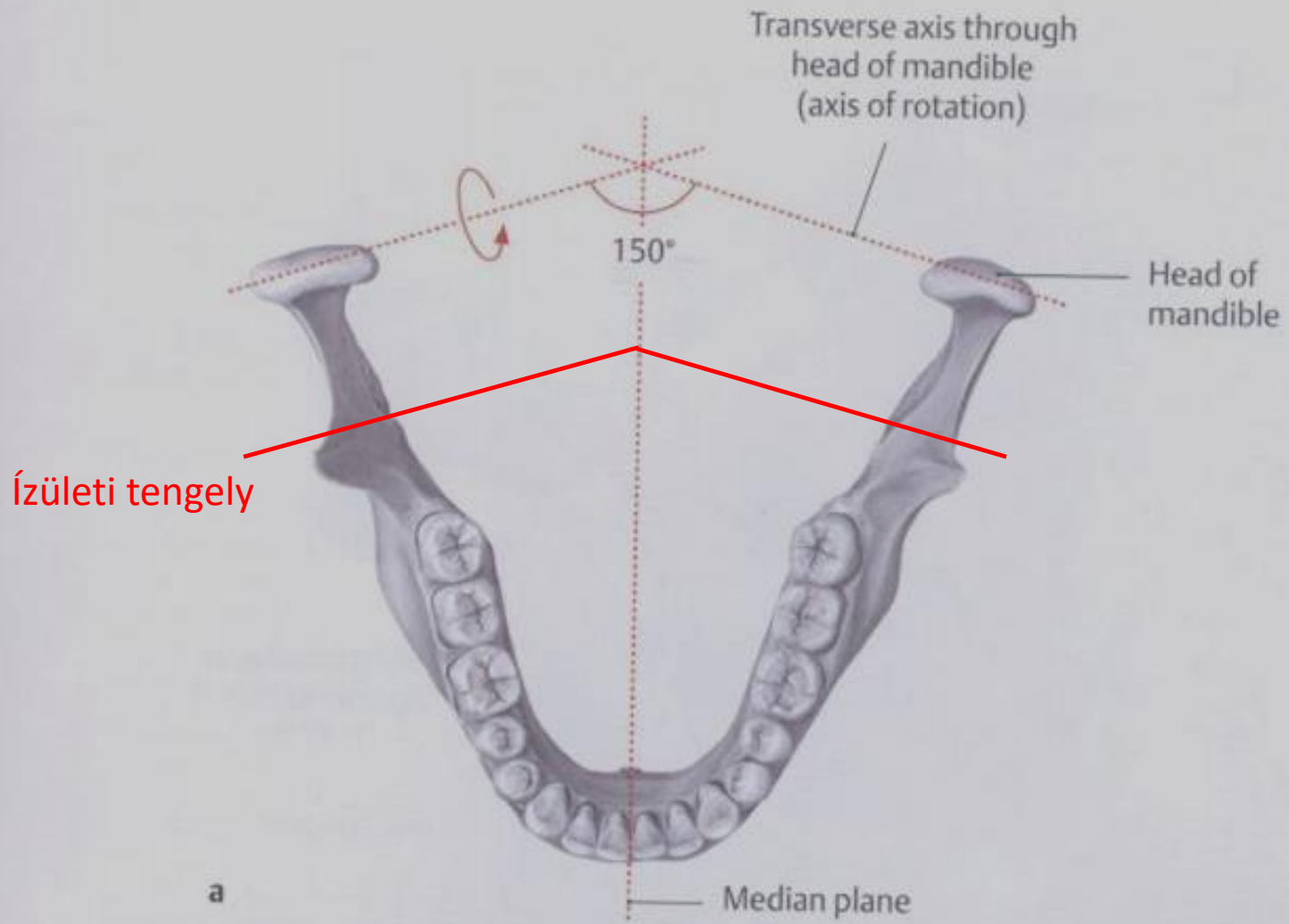


Rágóizmok

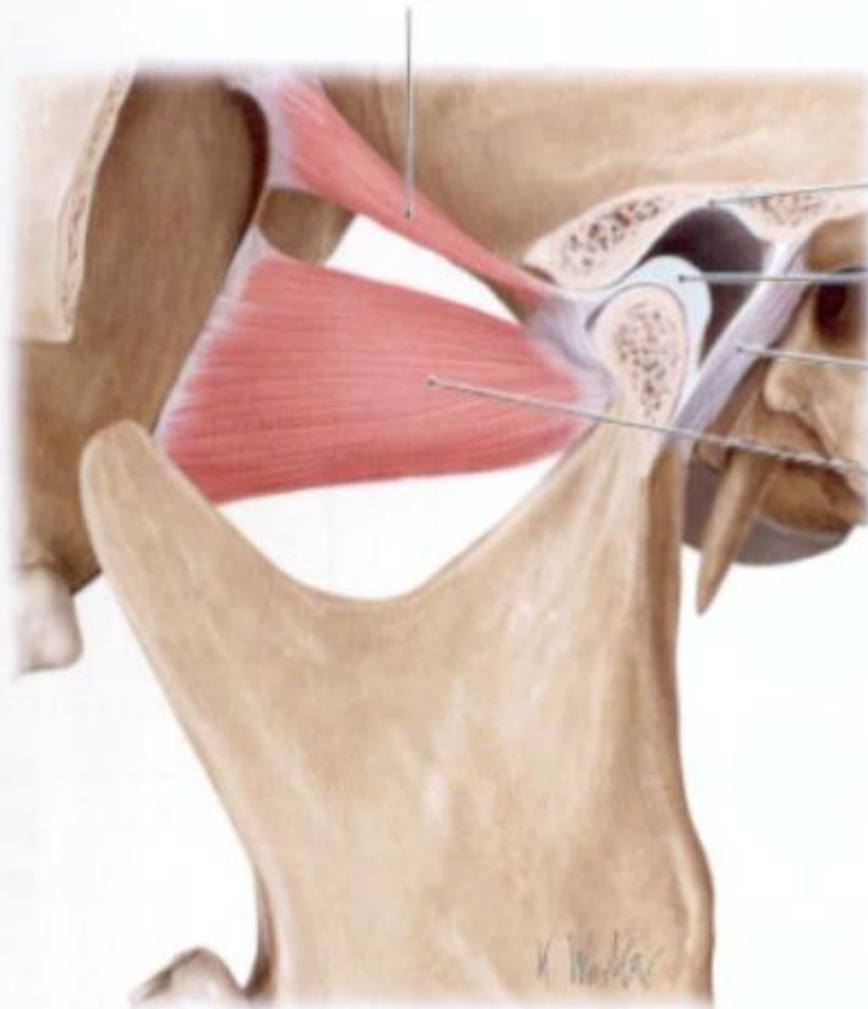


B Masticatory muscular sling

Oblique posterior view. This drawing clearly shows how the masseter and *medial* pterygoid form a muscular sling in which the mandible is suspended. By combining the actions of both muscles into a functional unit, this sling enables powerful closure of the jaws.



M. pterygoideus lateralis,
Pars superior

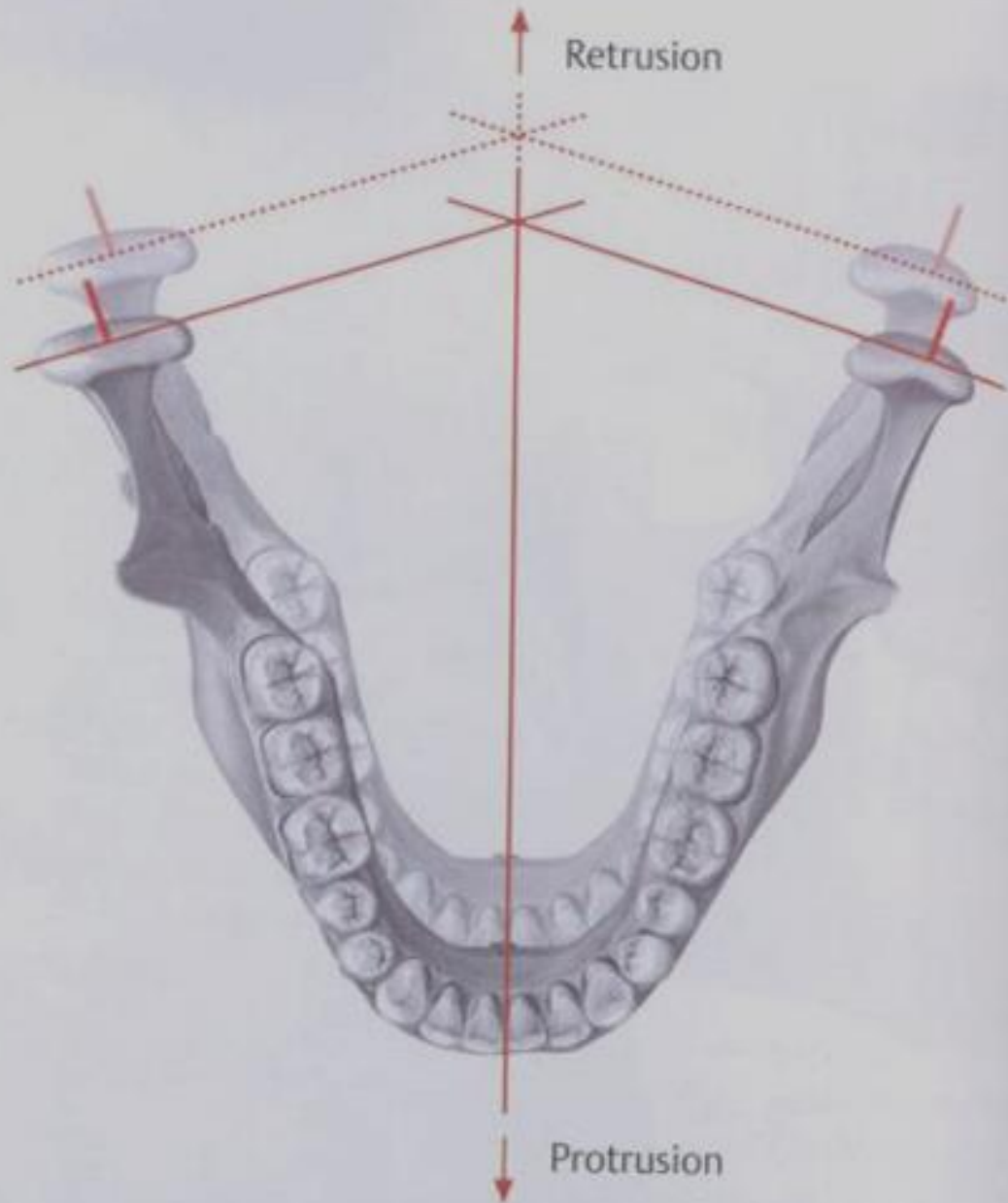


Fossa mandibularis

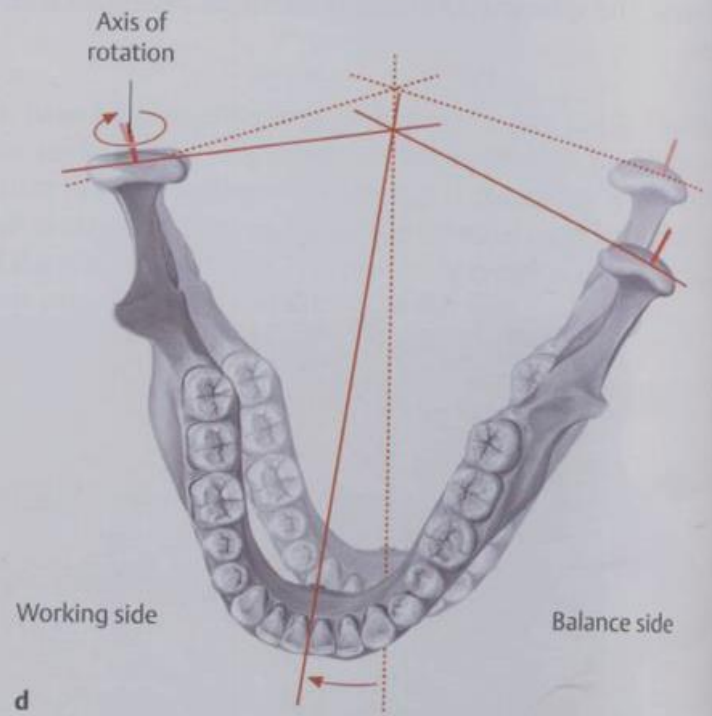
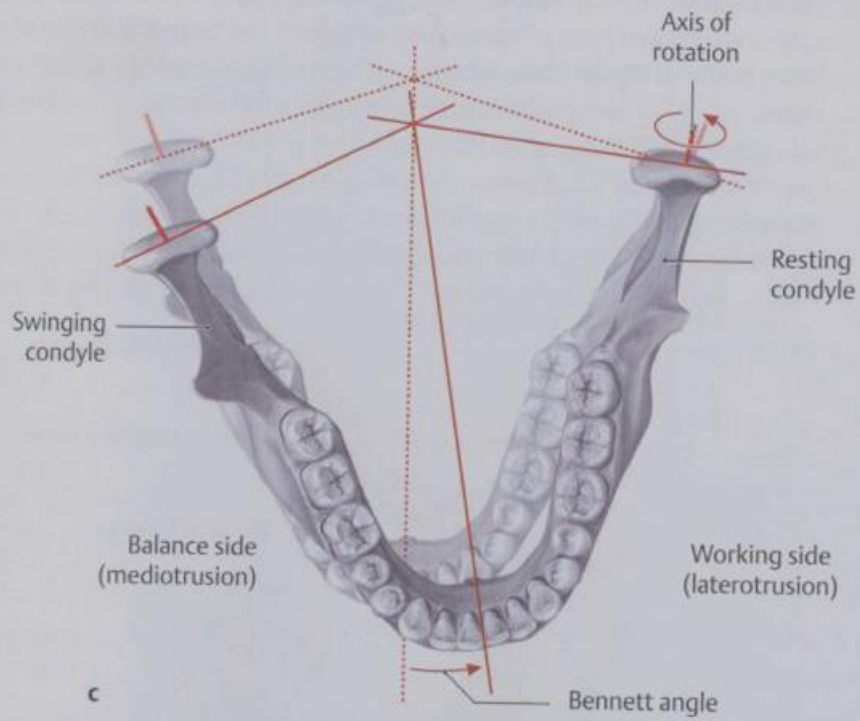
Discus articularis

Capsula articularis

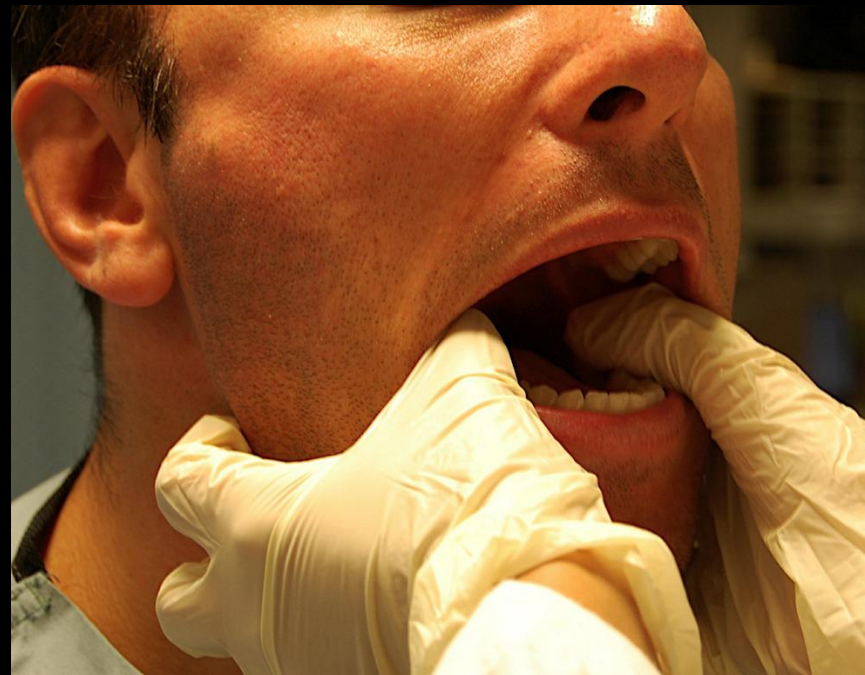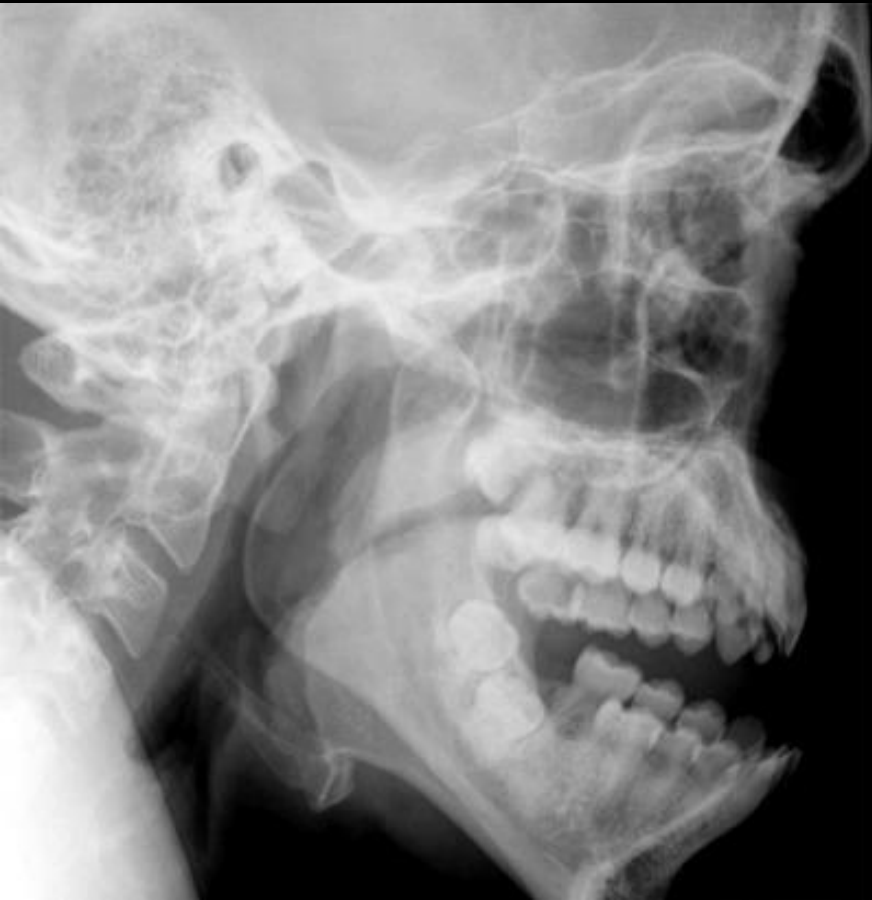M. pterygoideus lateralis,
Pars inferior



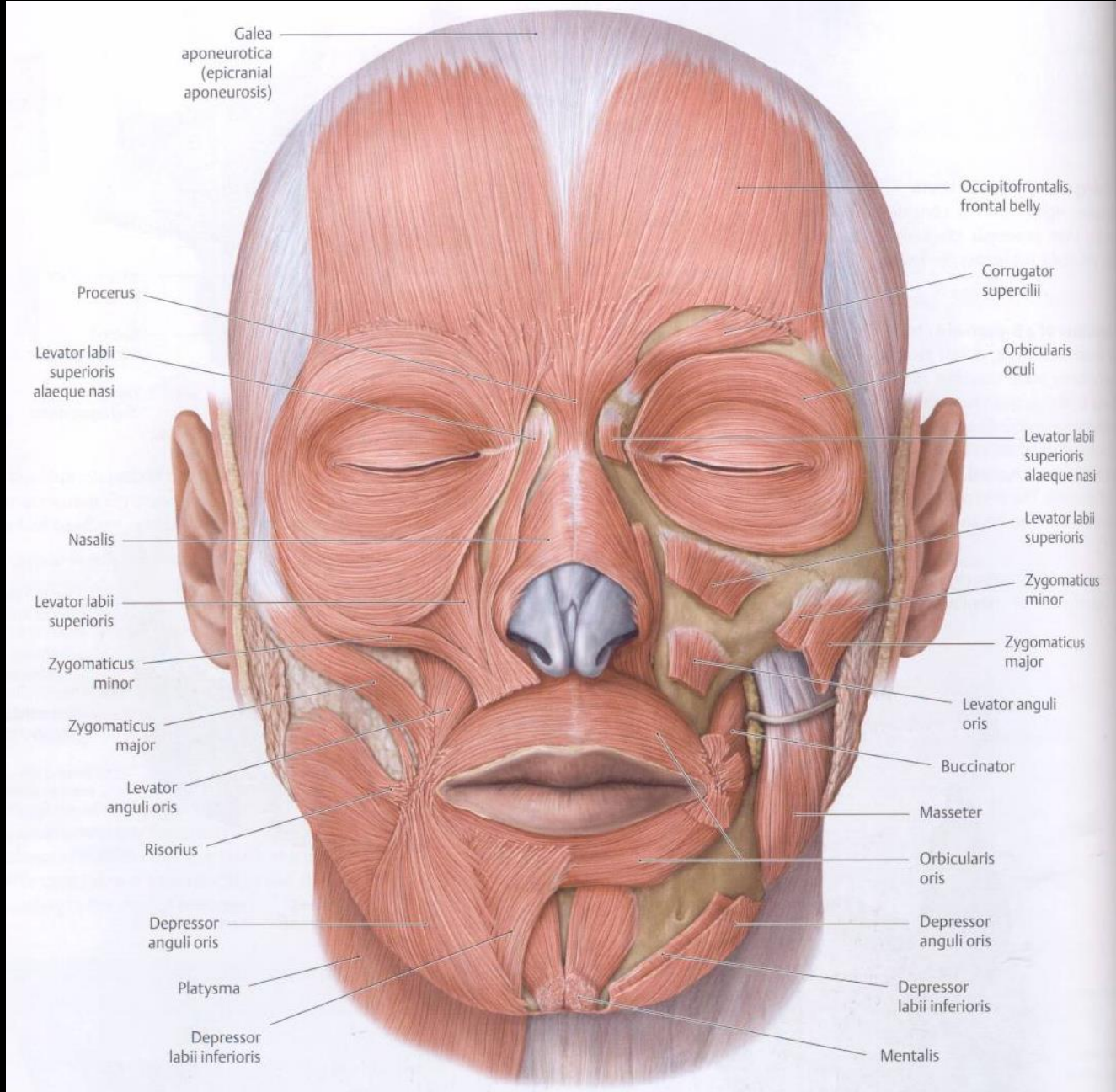
b

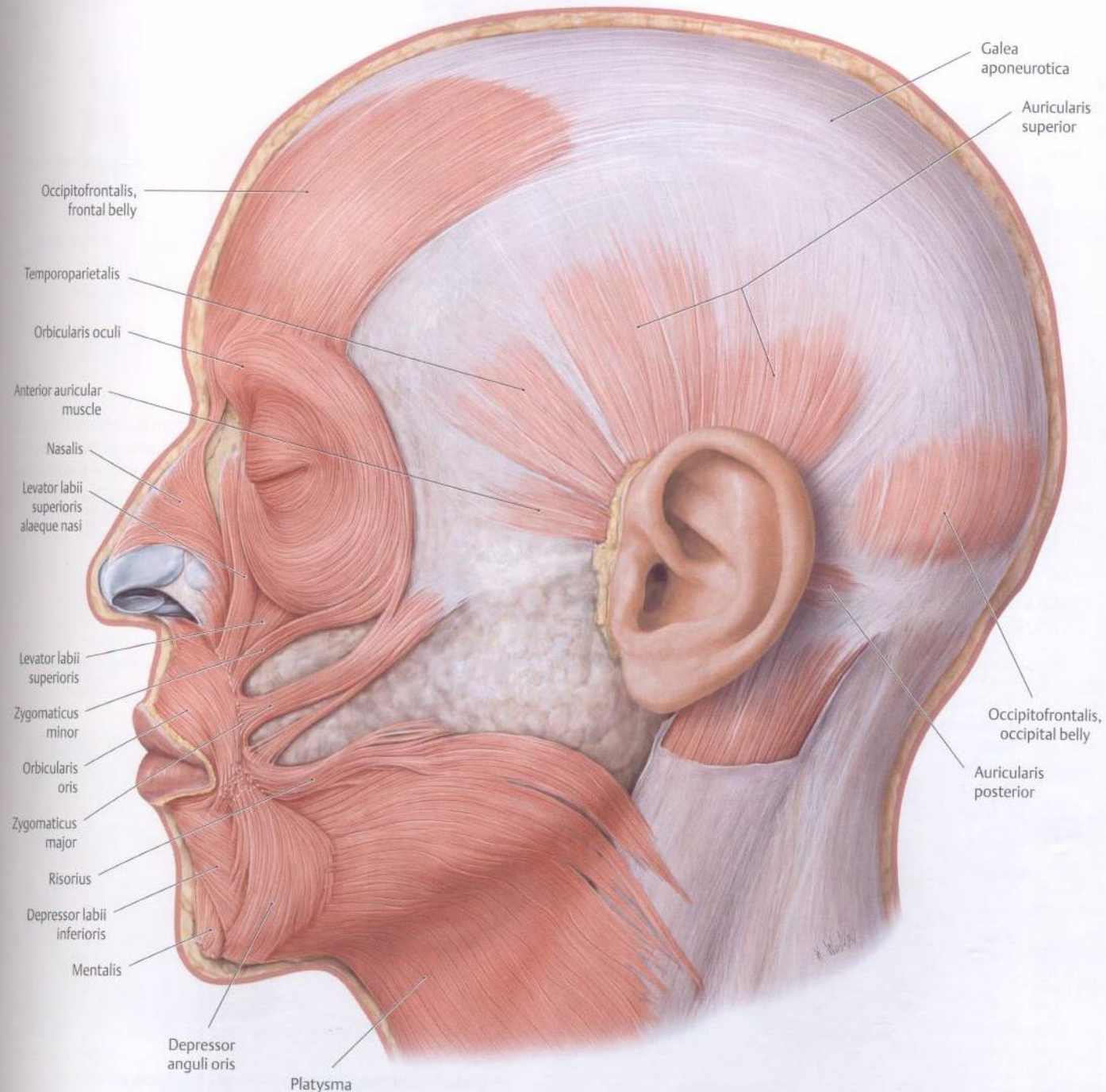


Habitualis luxatio

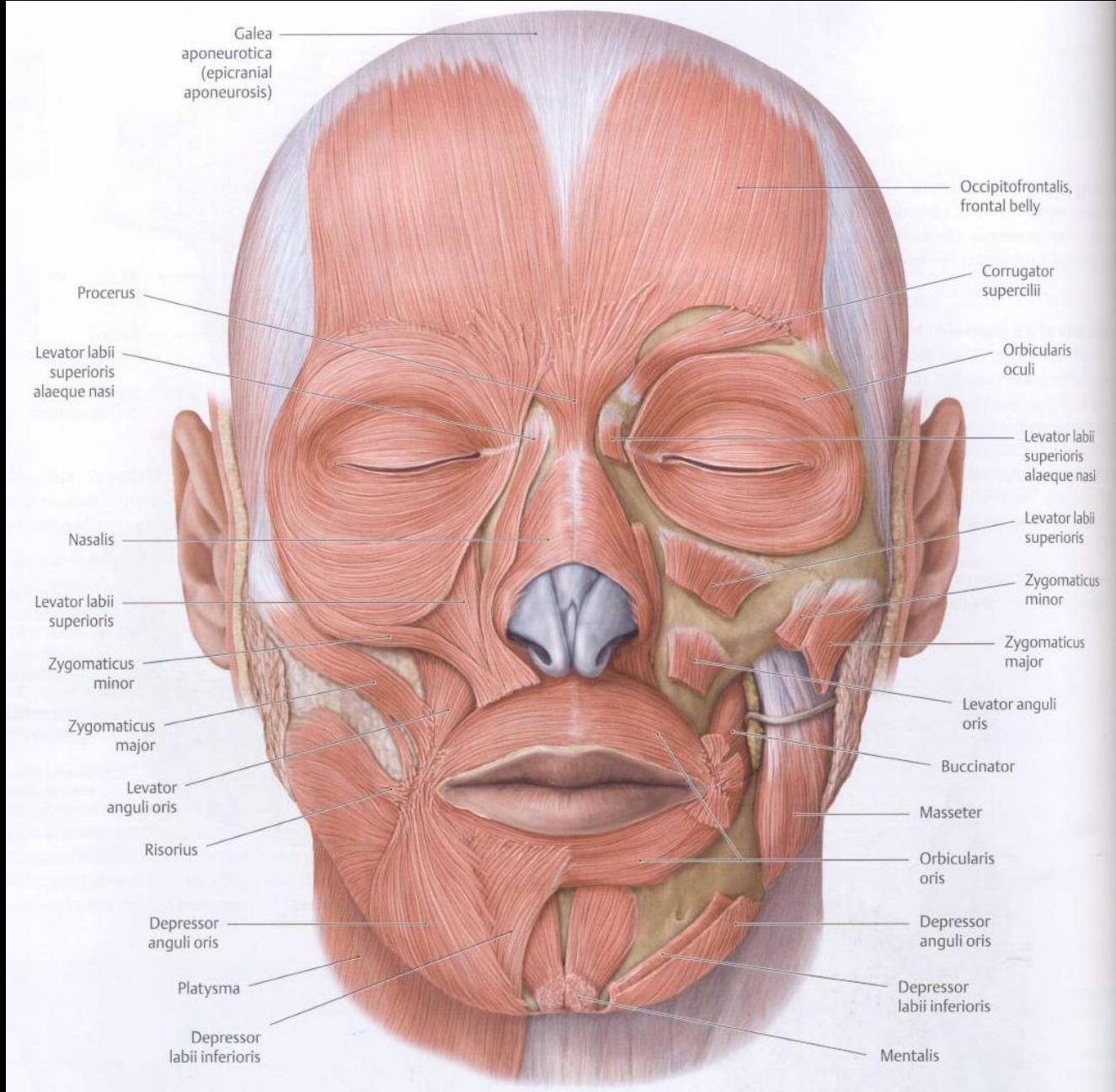


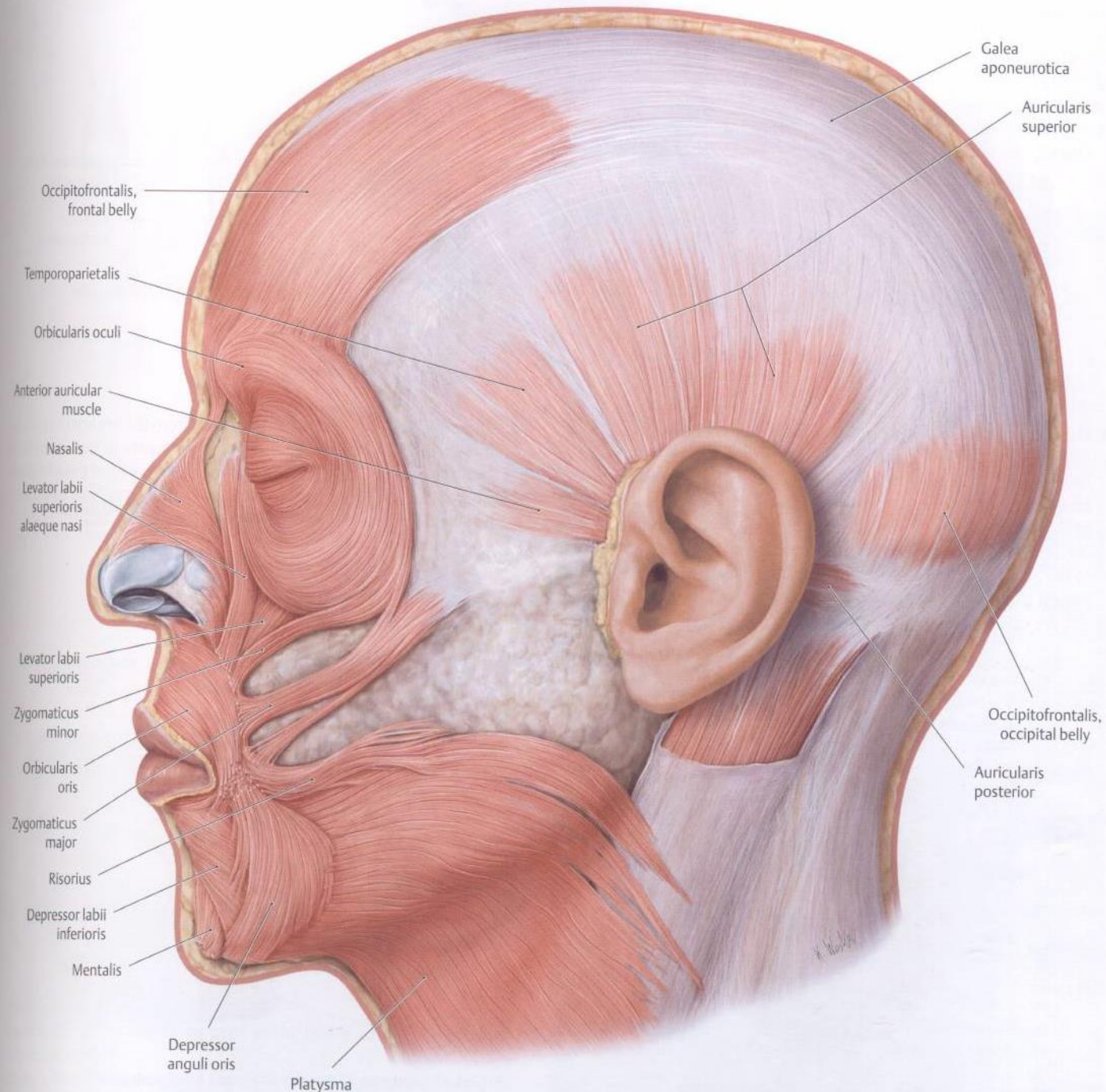
A FEJTETŐ ÉS A FÜLKAGYLÓ IZMAI

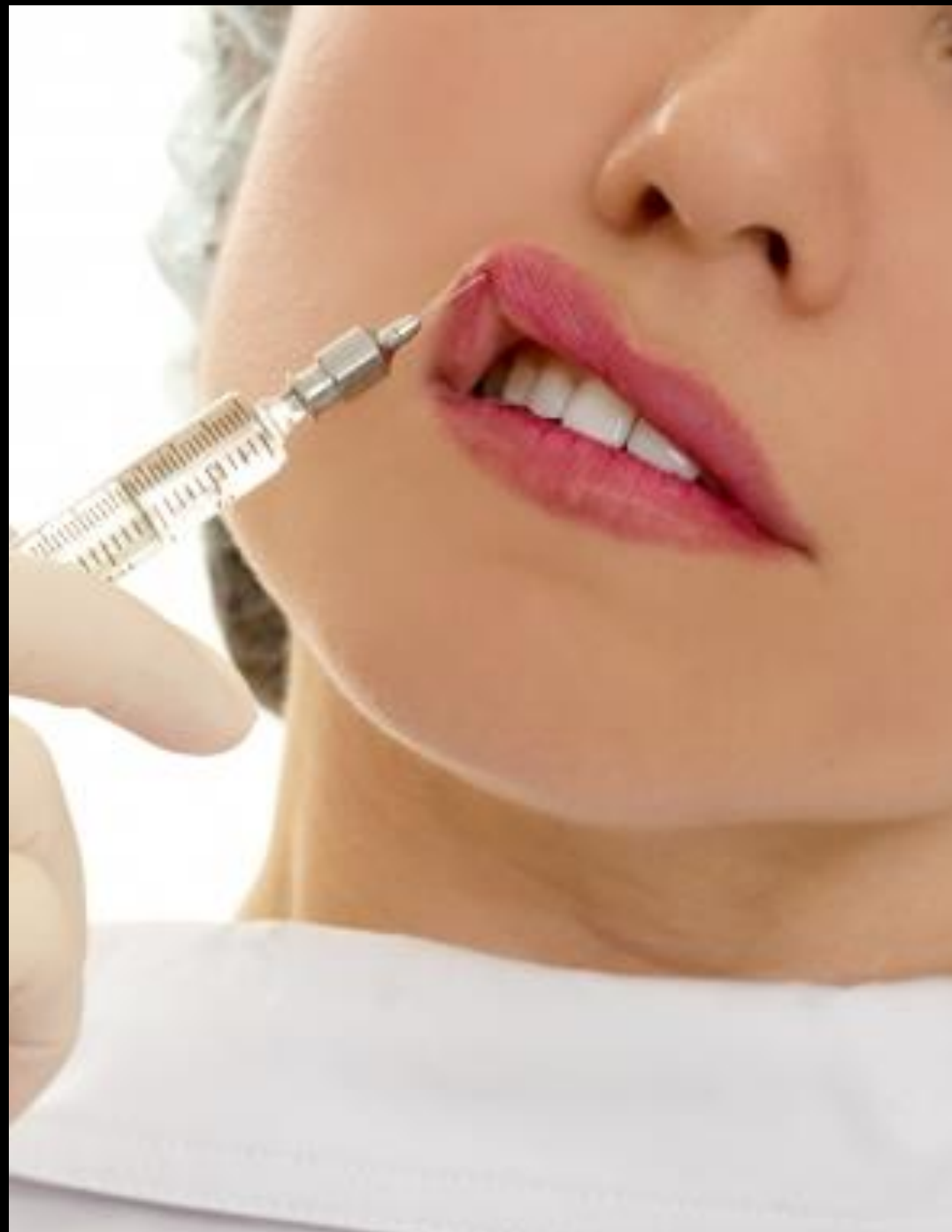




MIMIKAI IZMOK







Mimikai izmok

Botox (*Clostridium botulinum* toxinja)

