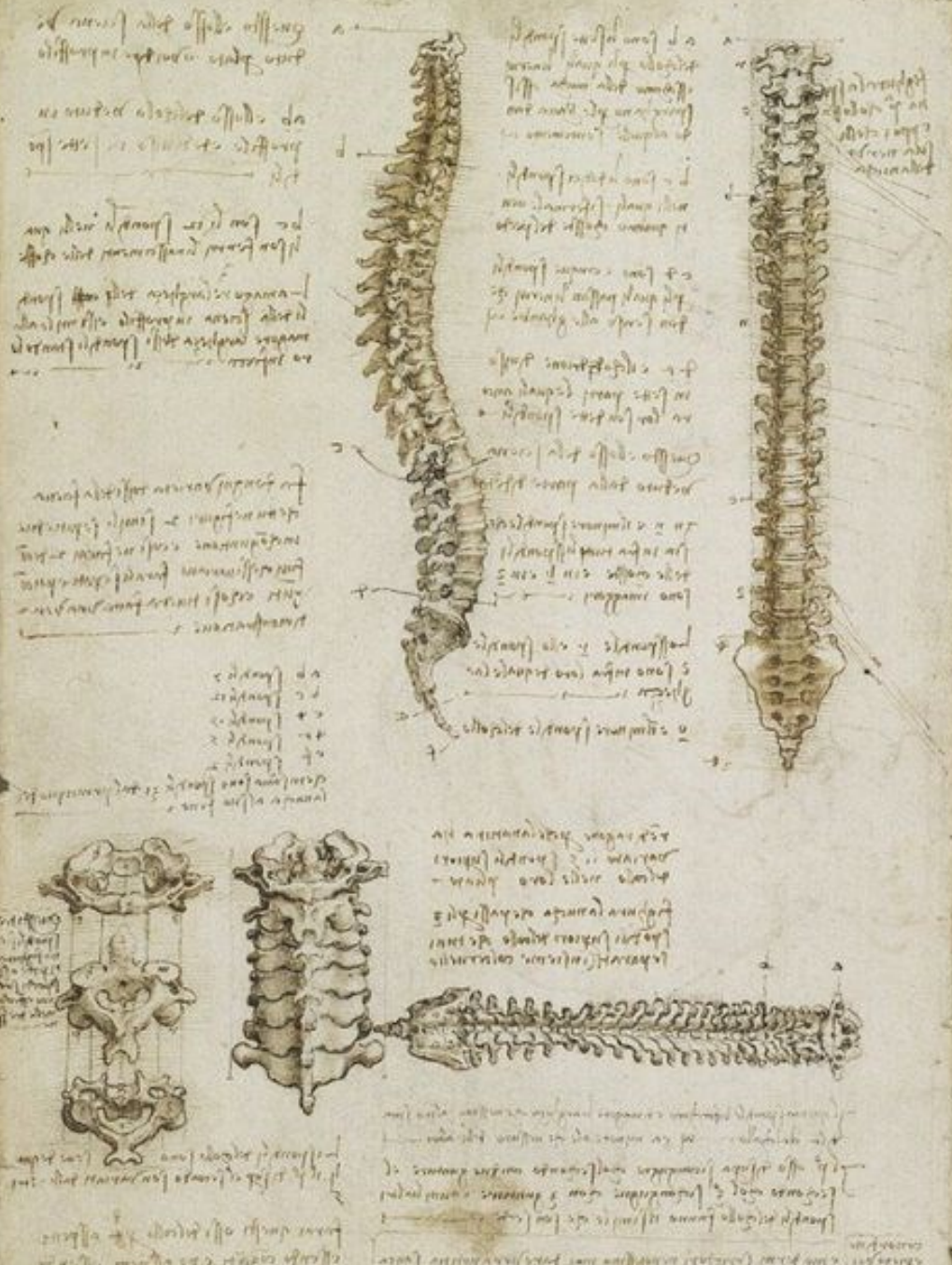

Csigolyák.
A gerinc felépítése.
Art. atlantooccipitalis,
art. atlantoaxialis

Pálfi Emese

Semmelweis Egyetem

Anatómiai, Szövet- és Fejlődéstani
Intézet

Leonardo da Vinci

Columna vertebralis

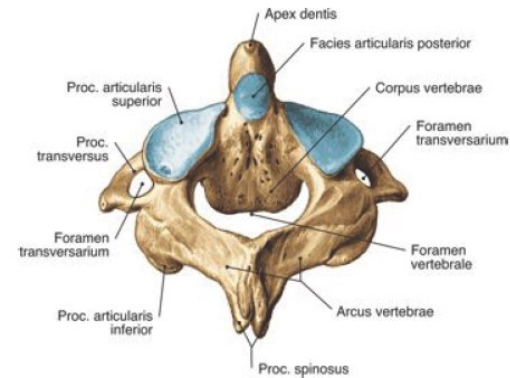
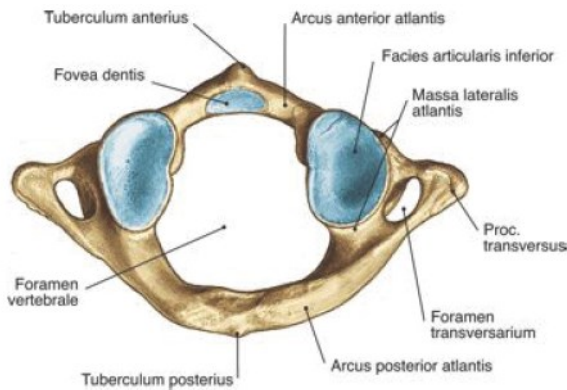
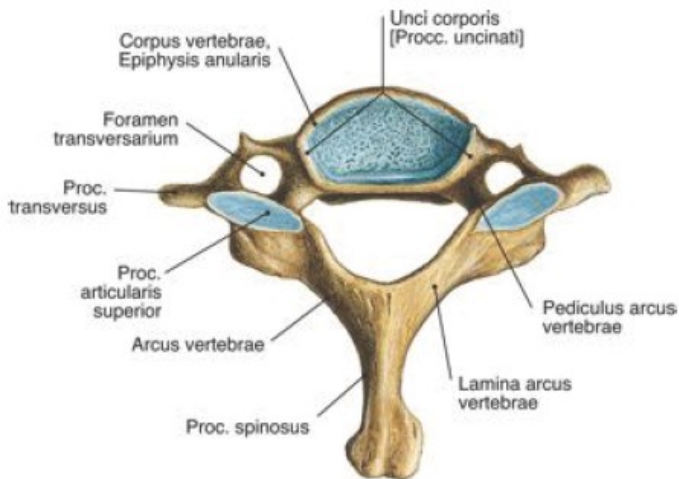
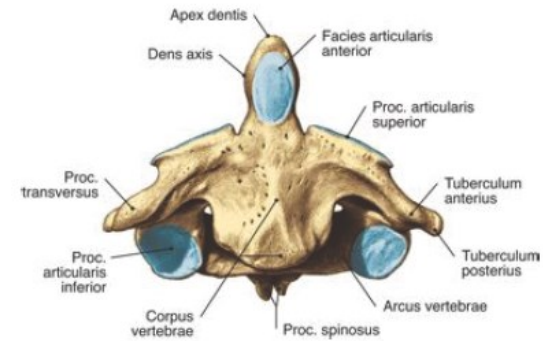
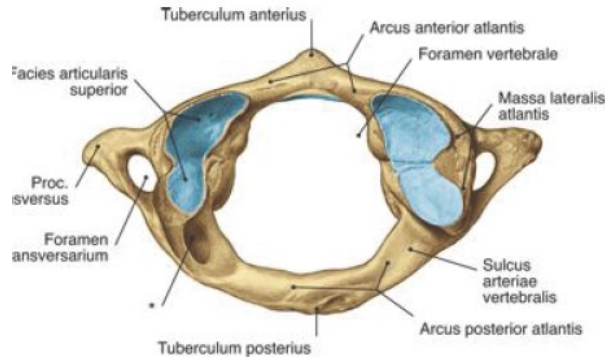
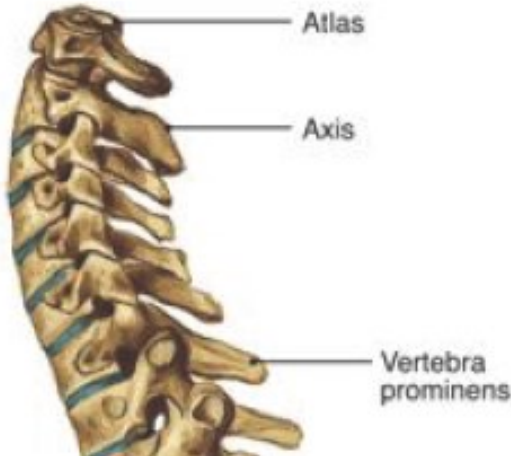- Test csontos tengelye
- Álló helyzetben a testsúlyt az alsó végtagokra vezeti
- Járás közben elnyeli az ütközéseket
- Védi a gerincvelőt

- 7 nyaki, 12 háti, 5 ágyéki, 5 keresztcsonti és 4-6 farokcsonti csigolyából áll
- *vertebrae verae* (24)
- *vertebrae spuriae* (9-11)

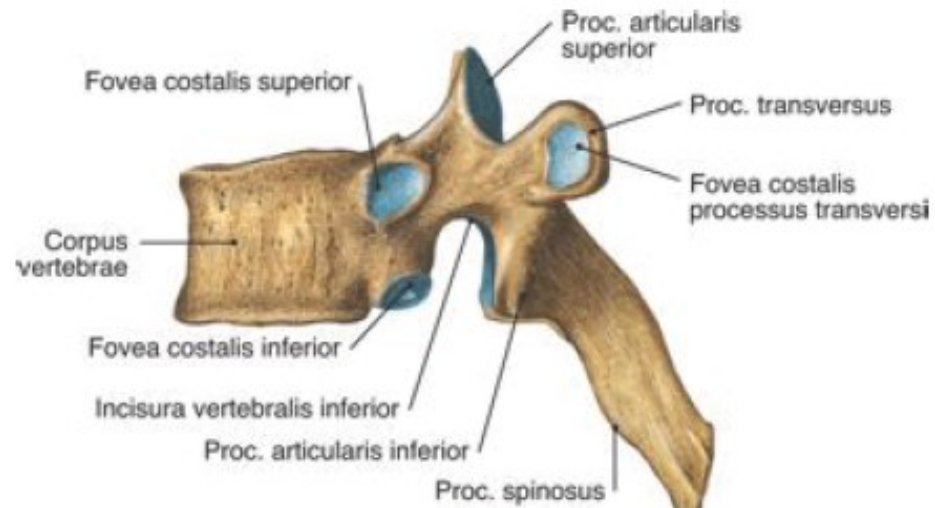
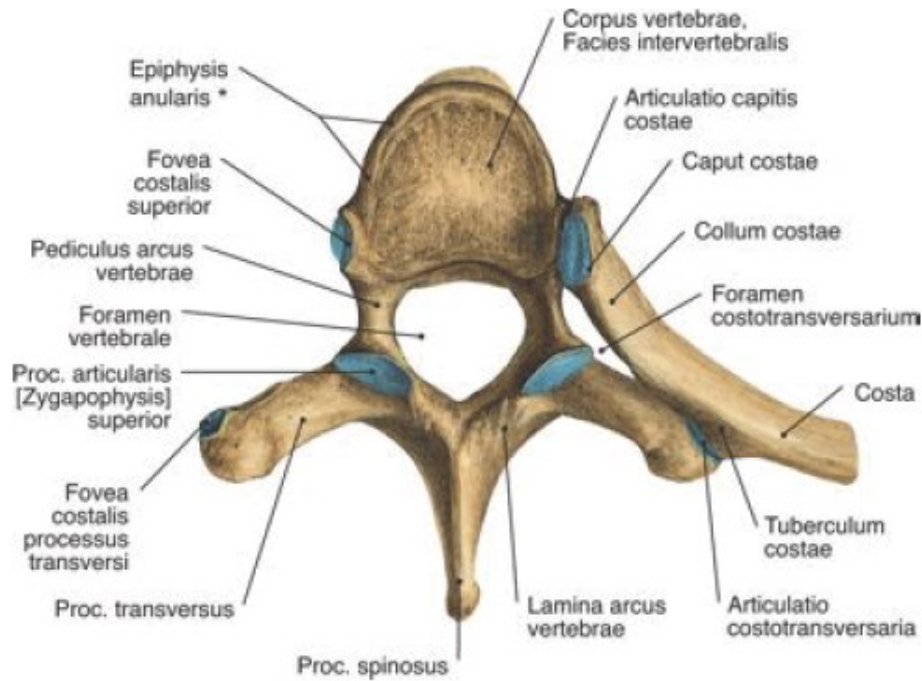
Vertebrae cervicales (7)

Atlas

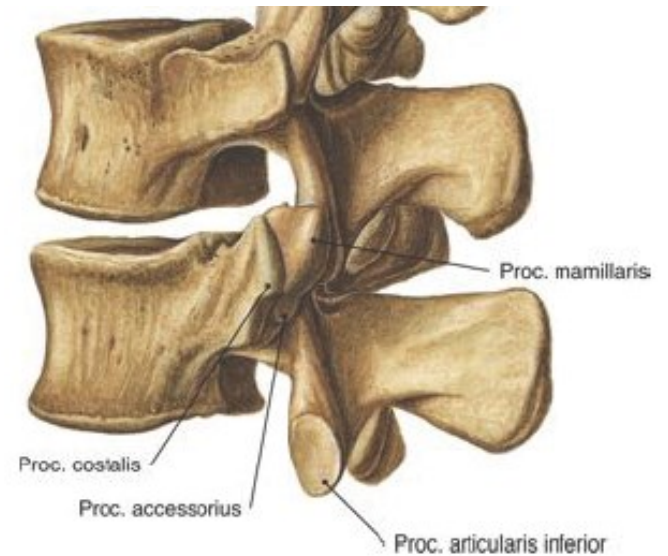
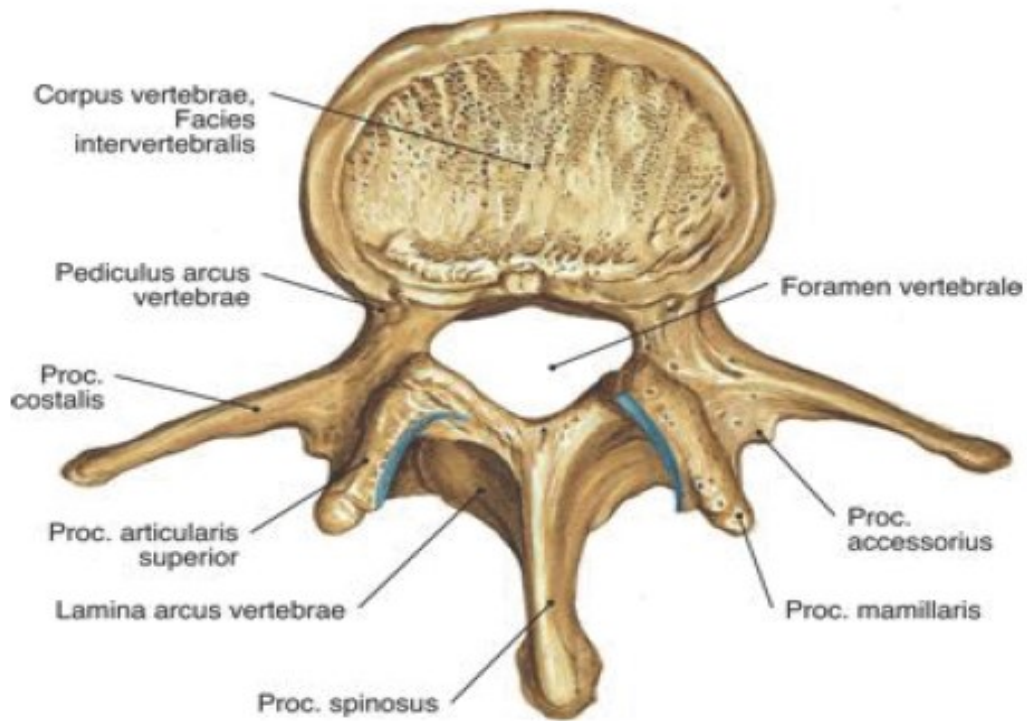
Axis



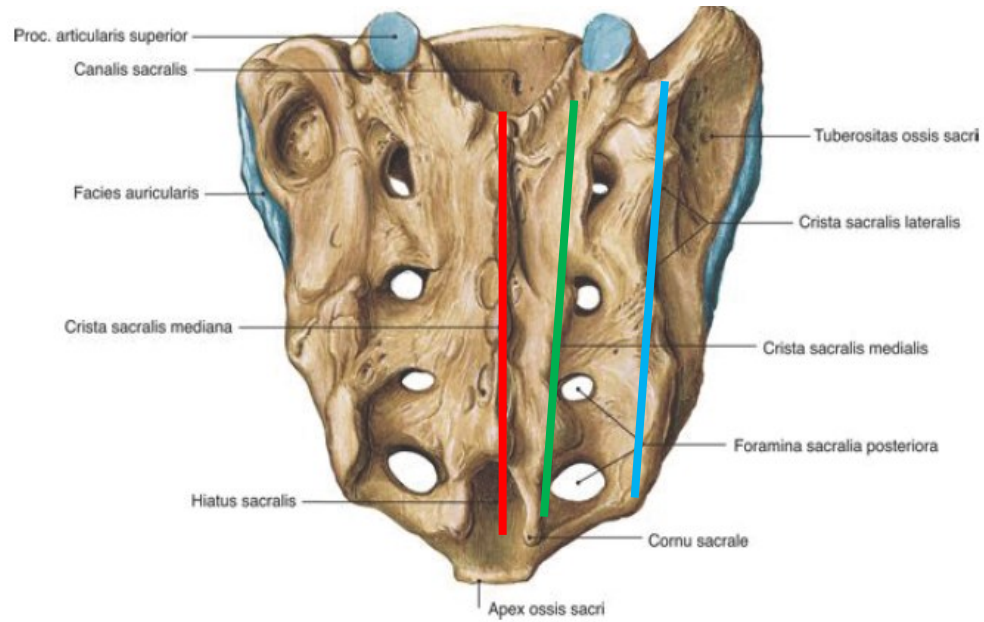
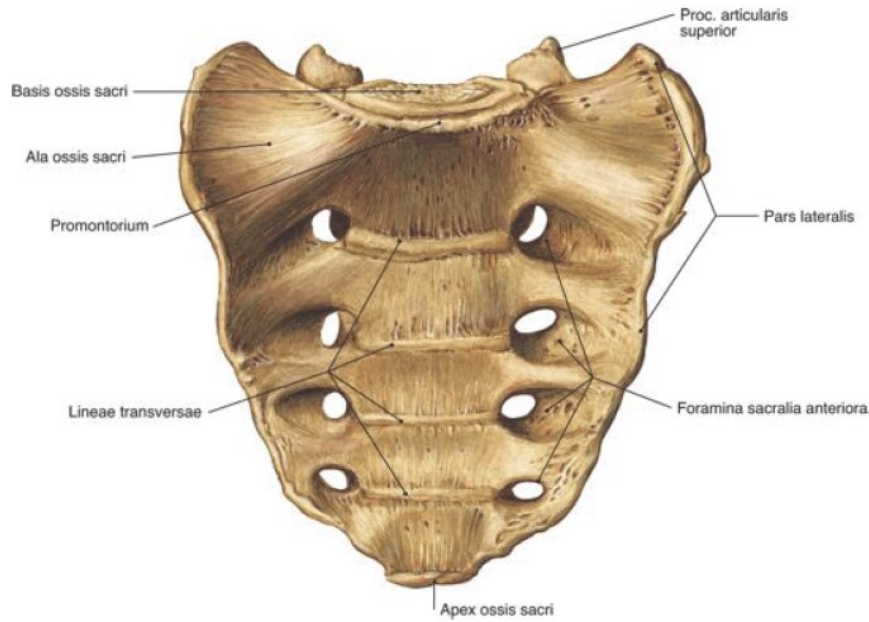
Vertebrae thoracicae (12)



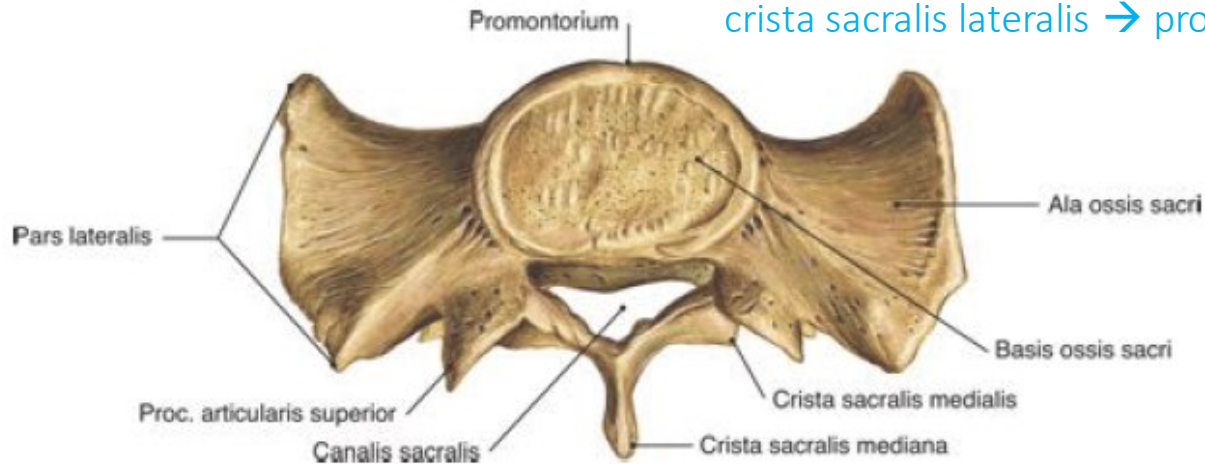
Vertebrae lumbales (5)



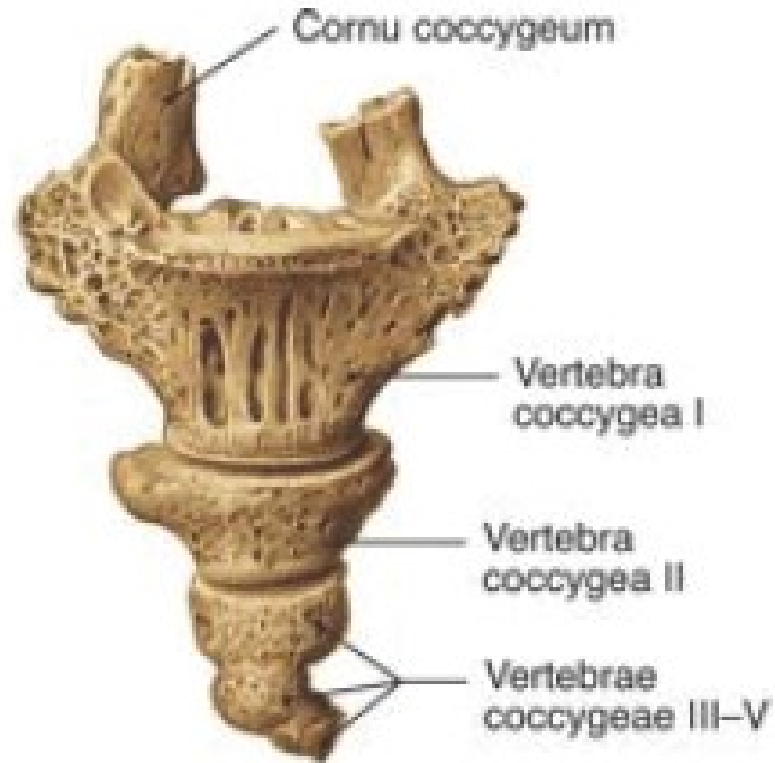Os sacrum (5)



crista sacralis mediana → proc. spinosus
 crista sacralis medialis → proc. articularis
 crista sacralis lateralis → proc. transversus

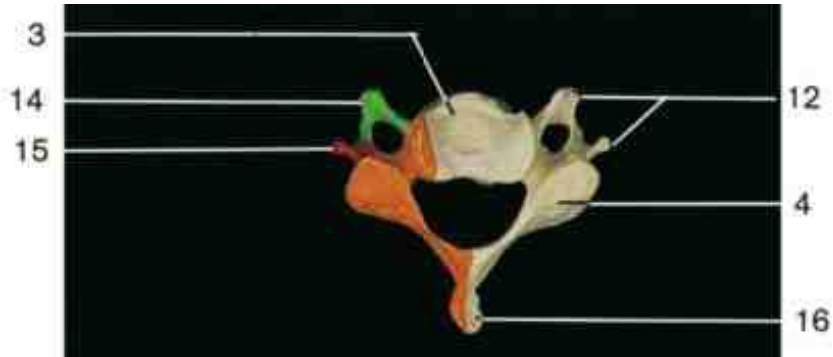


Os coccygis (4-6)

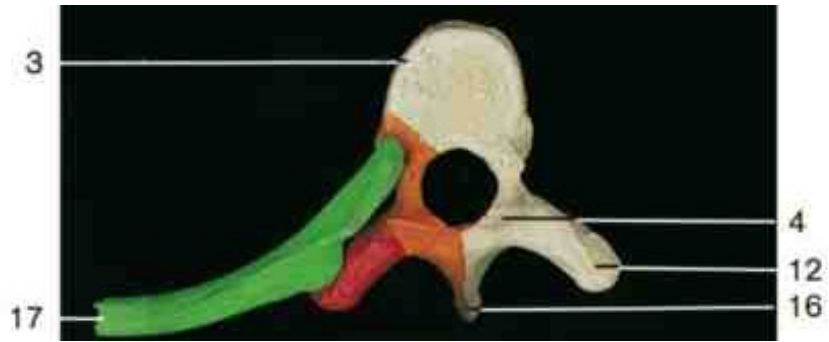

Corpus
Foramen vertebrale


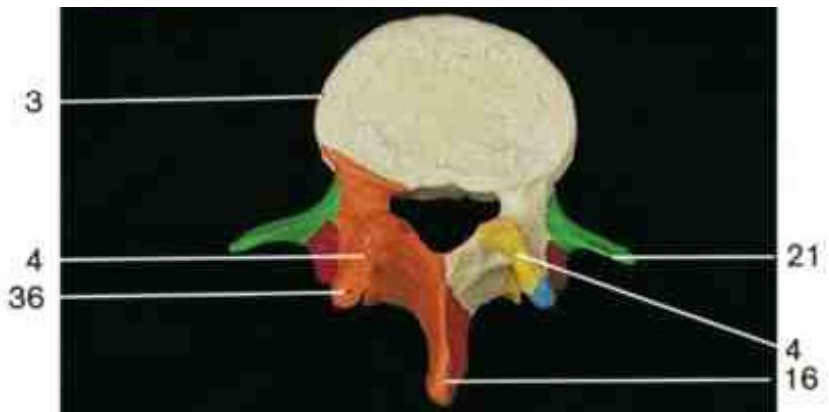
Processus articularis



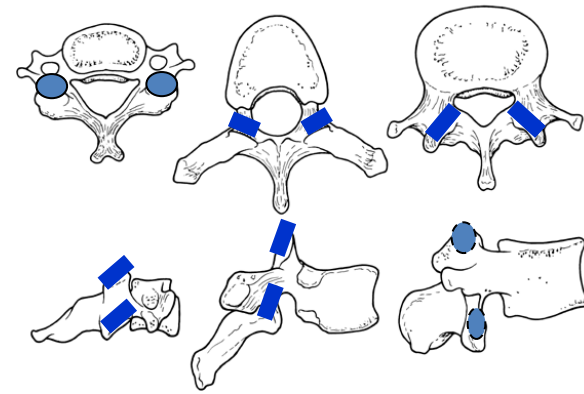
horizontális

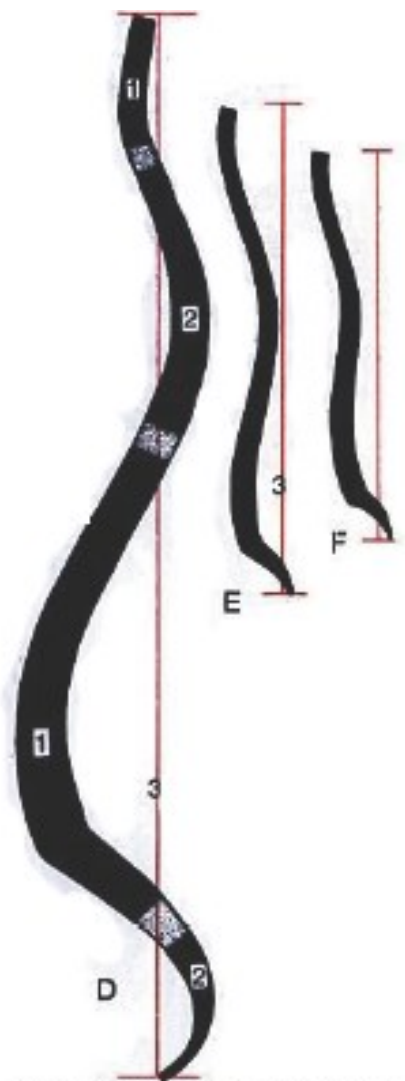


frontális

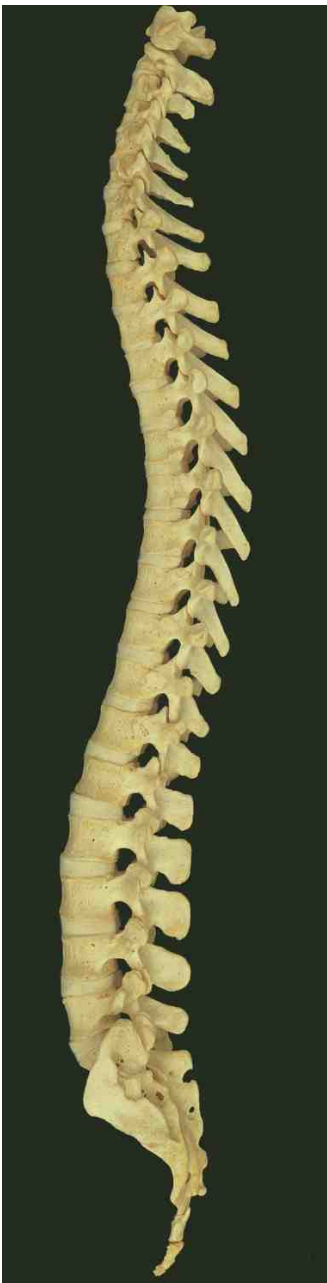

sagittális





A gerincoszlop görbületeinek vázlata D: 18 éves ifjú
 E: 10 hónapos csecsemő és
 F: 3 hónapos csecsemő esetében



← cervicalis lordosis
 (C3-4)

→ thoracalis kyphosis
 (Th5-6)

← lumbális lordosis
 (L3-4)

← promontorium

physiologias scoliosis

A gerinc összeköttetései

synostosis

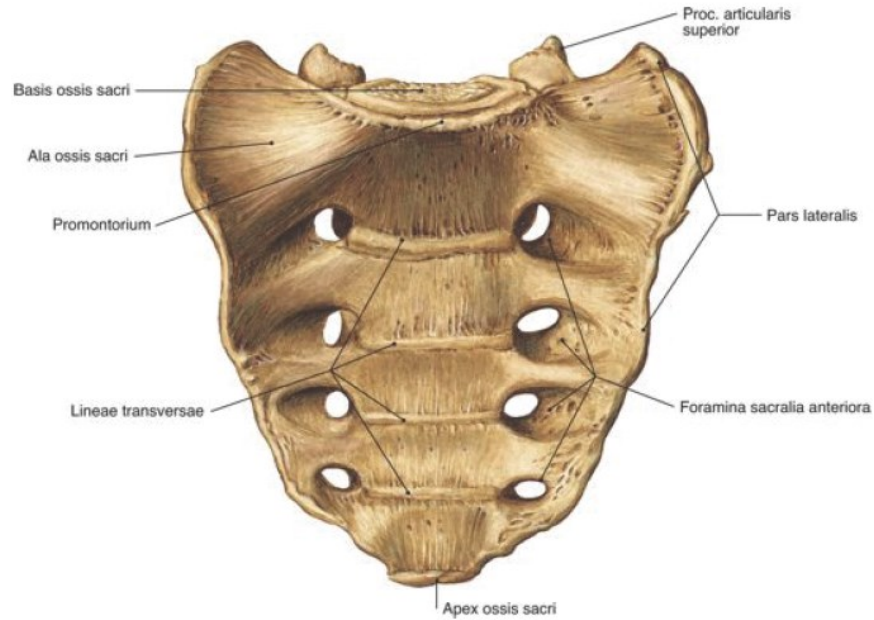
synchondrosis

syndesmosis

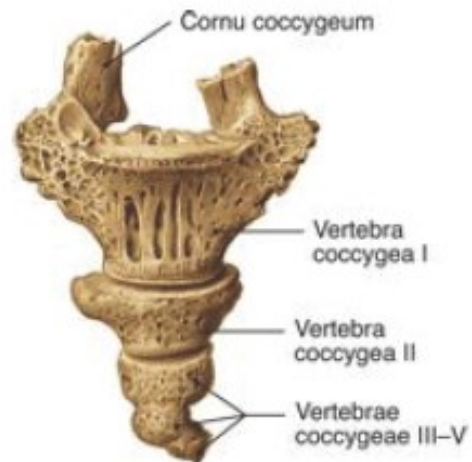valódi ízületek

Synostosis

Os sacrum



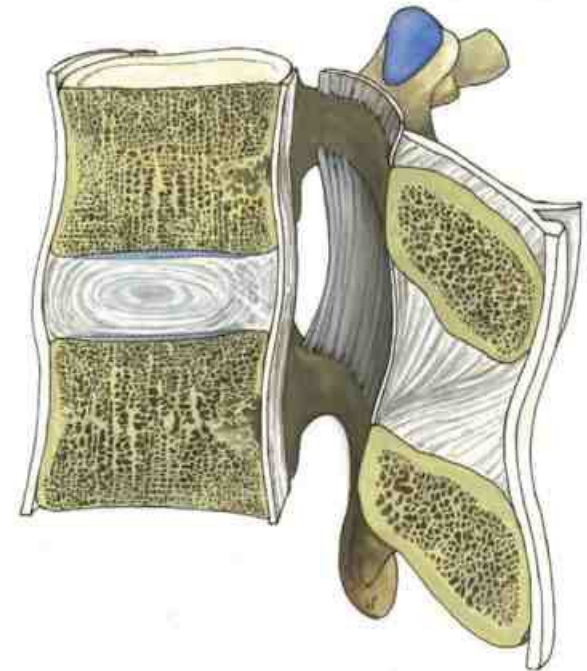
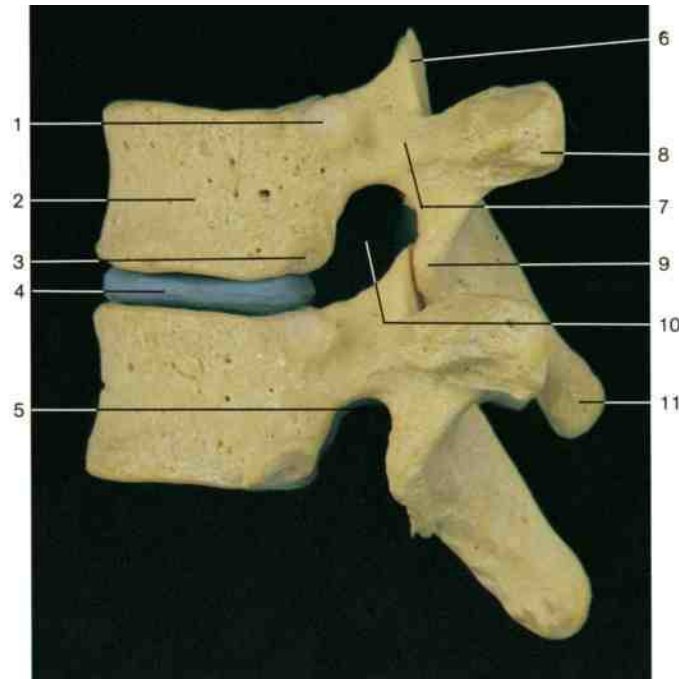
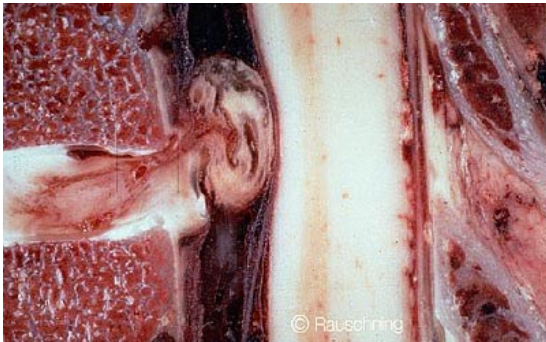Os coccygis



Synchondrosis

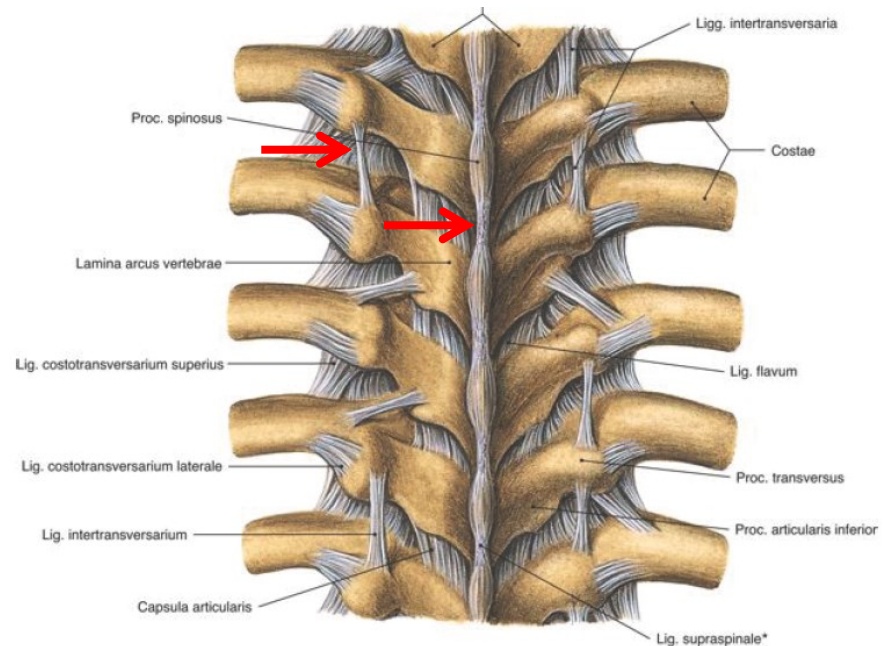
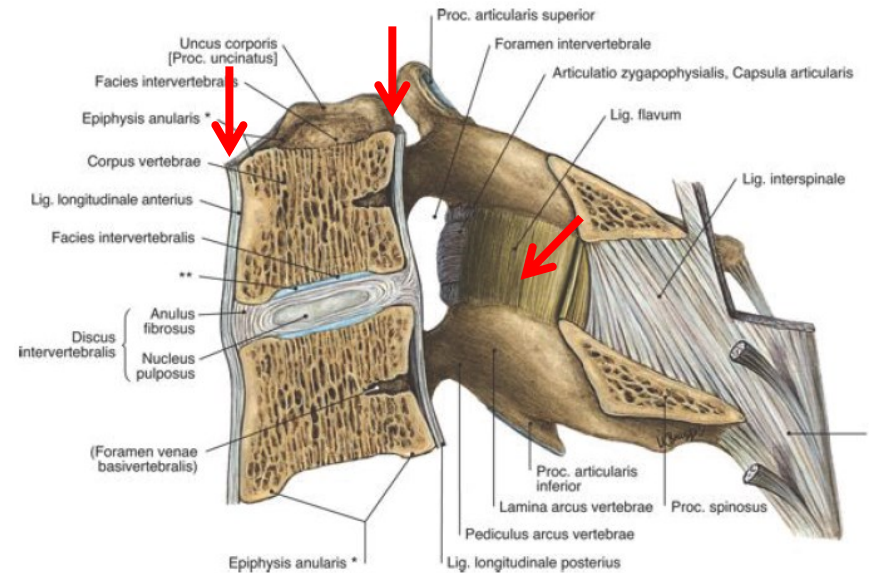
Porckorongok (disci intervertebrales)

- 23 db
- Rostporcos lemez: annulus fibrosus + nucleus pulposus
- Enyhén ék alakúak
- Vékony üvegporc rögzíti a csigolyatesthez
- Discushernia



Syndesmosis

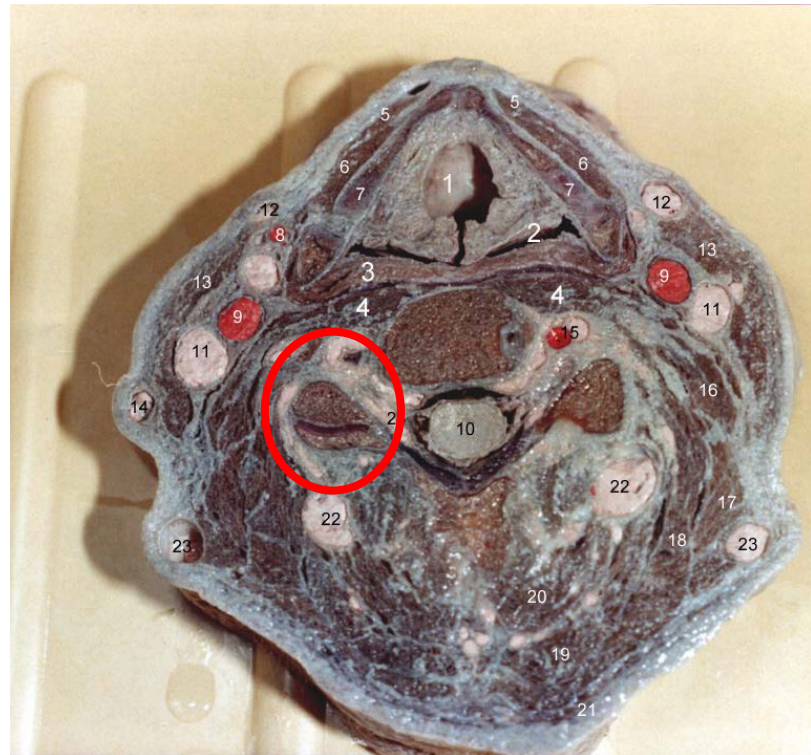
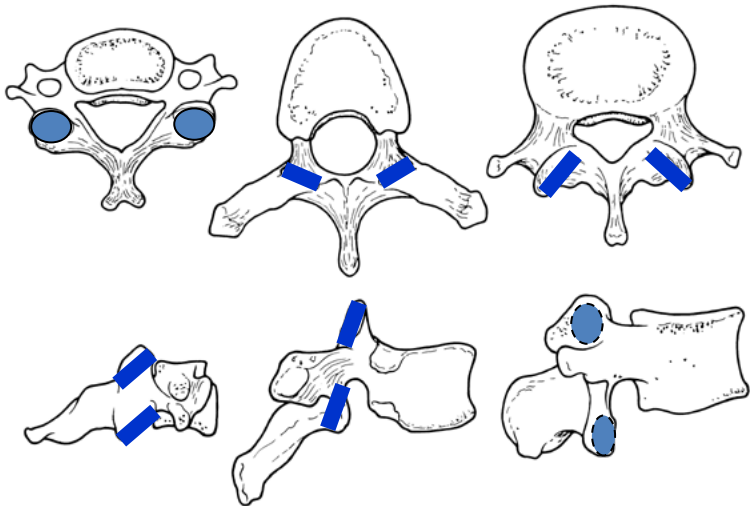
- lig. longitudinale anterius
- lig. longitudinale posterius
membrana tectoria
- lig. flavum
- lig. intertransversarium
- lig. supraspinale
lig.nuchae



Articulatio intervertebralis

Articulatio zygapophysialis

- processus articulares
- feszes ízületek
- bő, majd caudális irányban egyre feszesebb ízületi tok



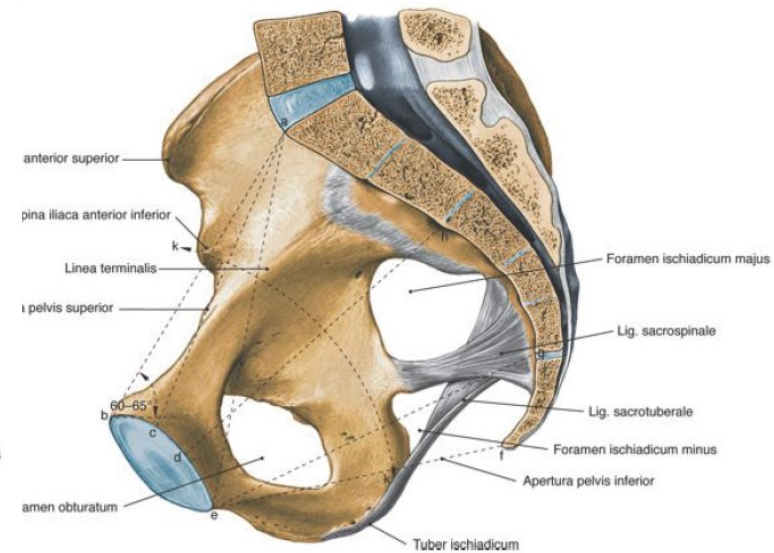
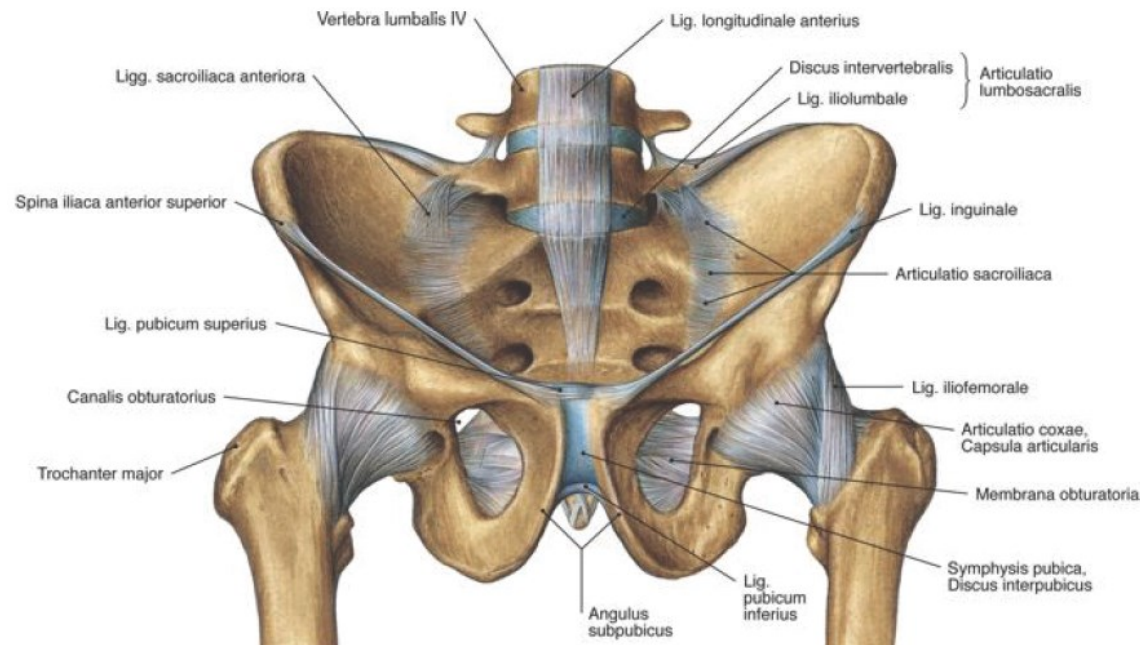
1. Larynx
2. Pharynx
3. M. constrictor pharyngis inf.
4. M. longus colli
5. M. sternohyoideus
6. M. omohyoideus
7. Cartilago thyroidea
8. A. thyroidea sup.
9. A. carotis comm.
10. Gericvelő
11. V. jugularis int.
12. V. jugularis ant.
13. M. sternocleidomastoideus
14. V. jugularis ext.
15. A. et v. vertebralis
16. M. scalenus medius
17. M. levator scapulae
18. M. splenius cervicis et capitis
19. M. semispinalis capitis
20. M. semispinalis cervicis
21. M. trapezius
22. V. cervicalis profunda
23. V. occipitalis
24. Plexus venosus vert. int.

Articulatio lumbosacralis

- L5 – os sacrum
- lig. iliolumbale

Articulatio sacrococcygea

- os sacrum – os coccygis
- lig. sacrococcygeum dors. spf. et prof., lig. sacrococcygeum ventr., lig. sacrococcygeum lat.



A gerinc mozgásai

	Előre- és hátrahajlítás (<i>flexio ventralis et dorsalis</i>)	Oldalirányú hajlás (<i>flexio lateralis</i>)	Csavarás (<i>torsio-retorsio</i>)
C	+++	++	++
Th	+	+	+
L	++	++	-



Art. atlanooccipitalis

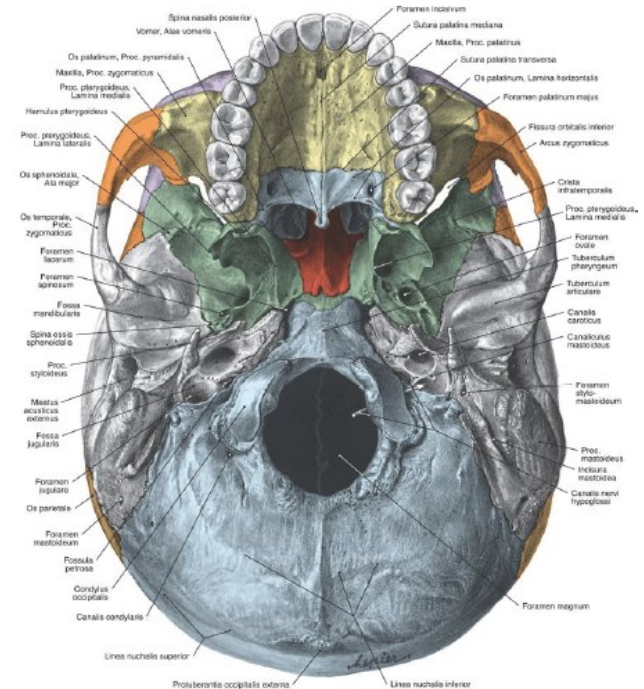
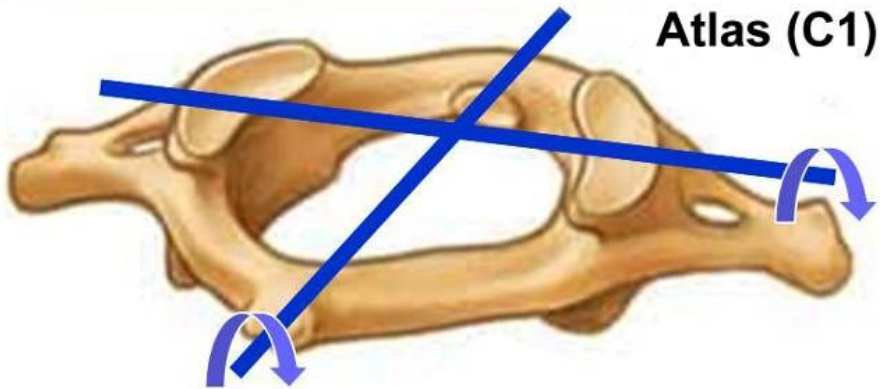
Ízületi fej: *condyli occipitales*

Ízületi vápa: *atlas – fovea articularis superior*

Tojásízület

haránttengely → bólintás

sagittális tengely → fej ingatása válltól vállig



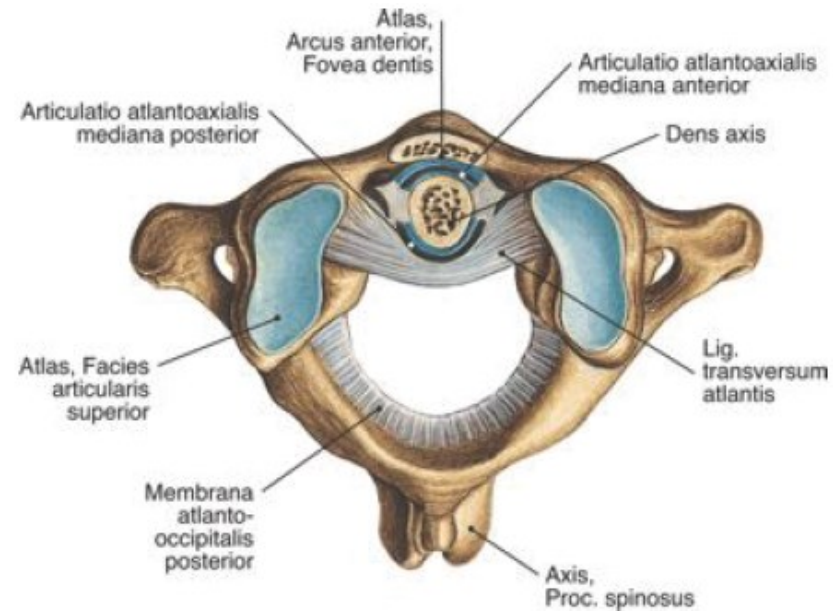
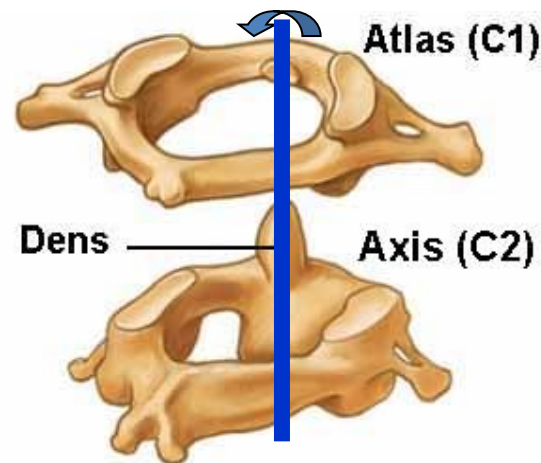
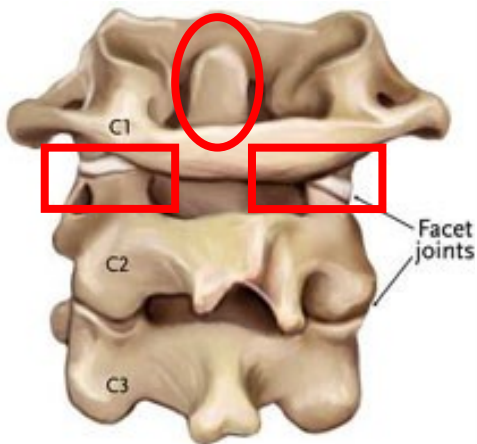
Art. atlantoaxialis

Ízületi fej: *dens axis - fac. art. anterior*

Ízületi vápa: *atlas - fovea dentis*

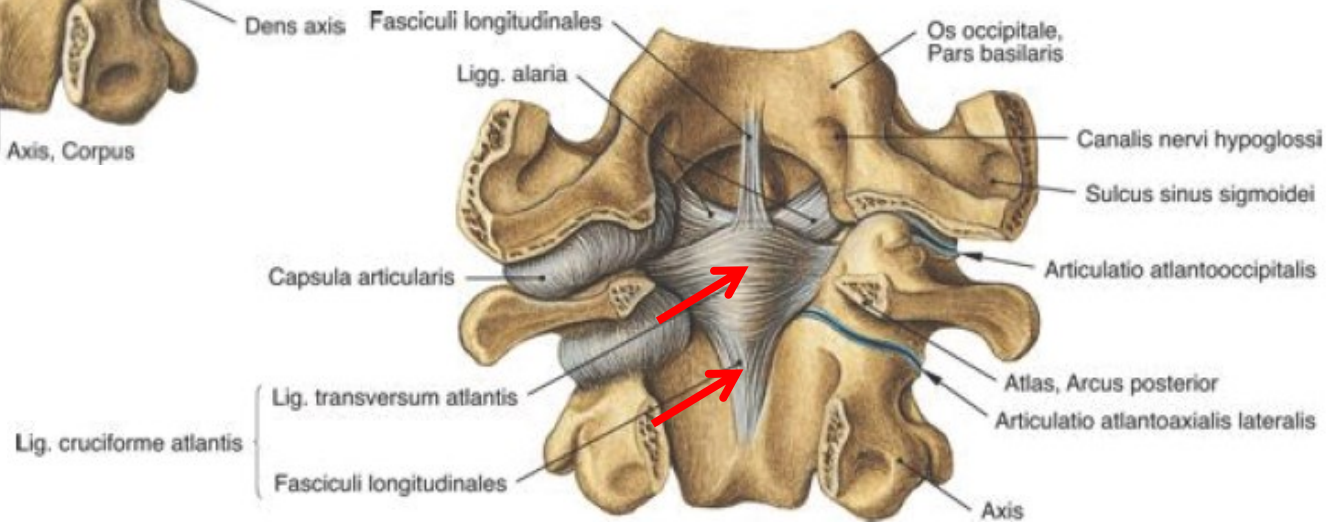
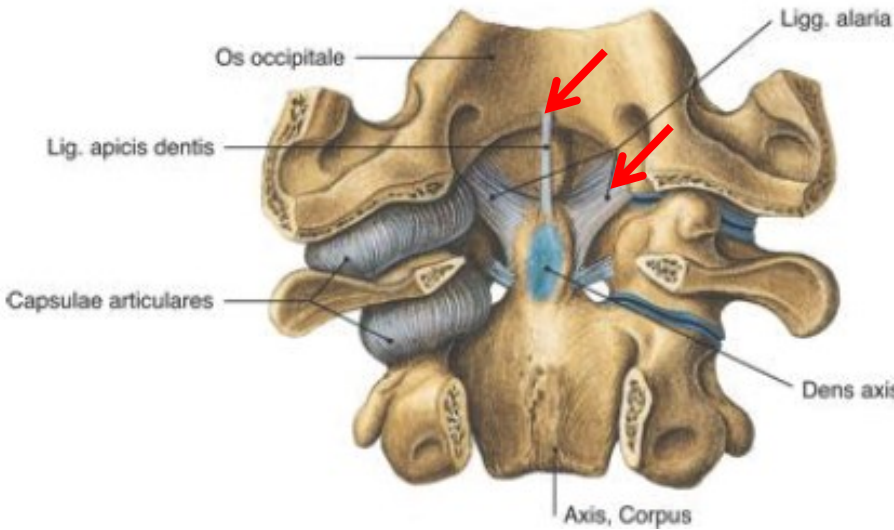
processus articulares superiores
facies articulares inferiores atlantis
meniscoidális synoviaredő

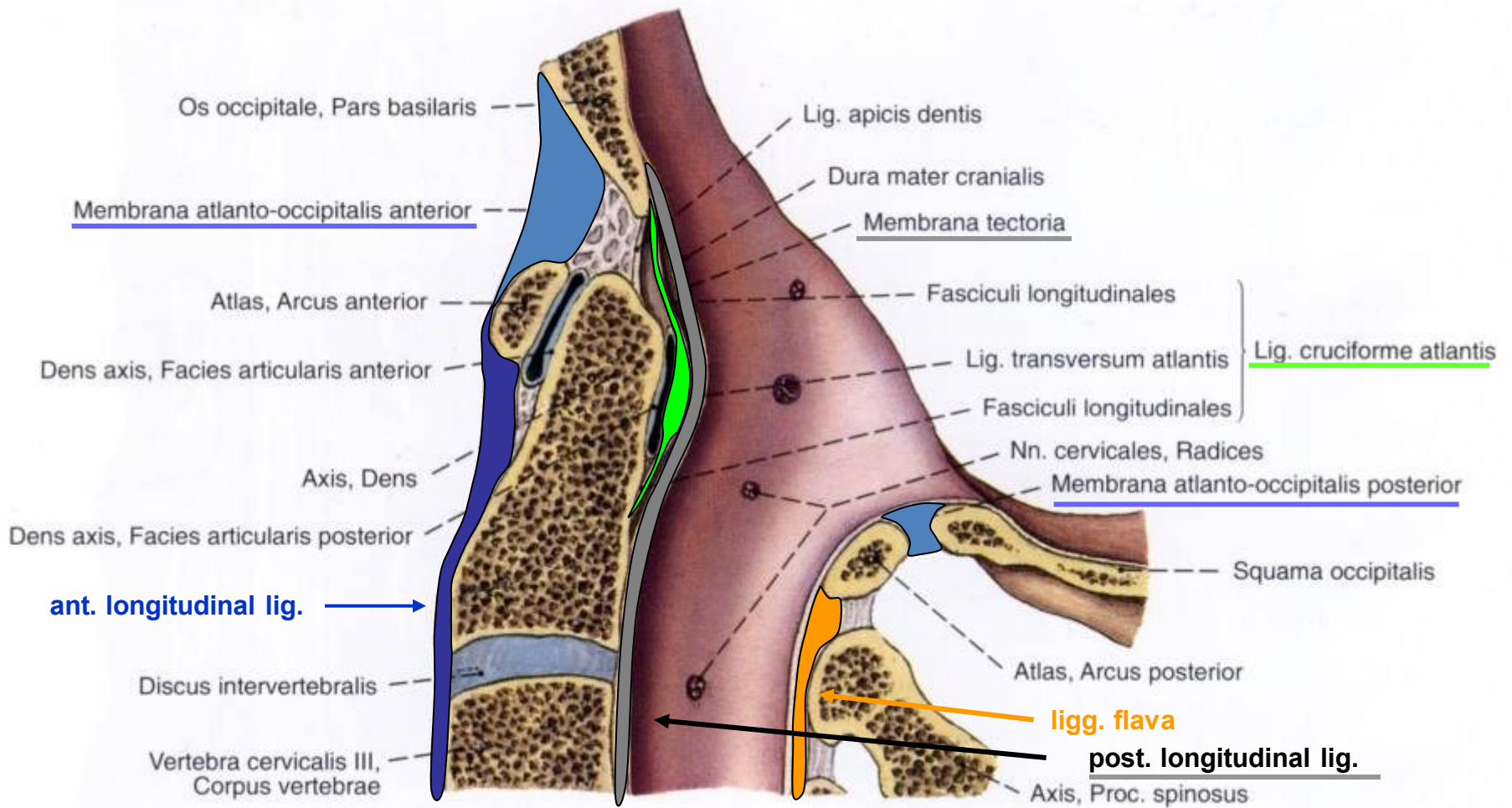
Kúpízület → fej forgatása

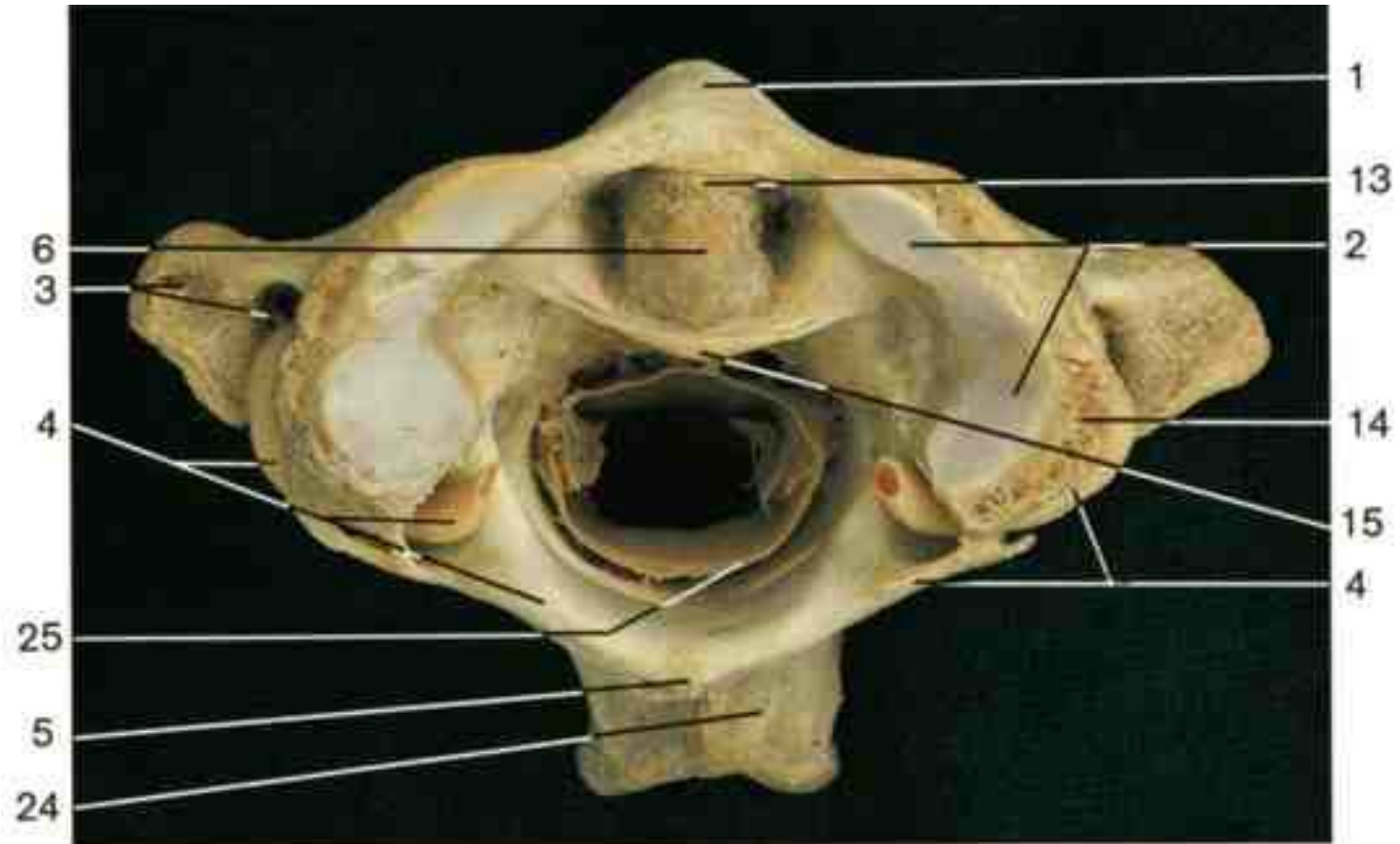


Közös szalagkészülék

- lig. alare
- lig. apicis dentis
- lig. transversum atlantis
- fasciculi longitudinales } lig. cruciforme atlantis
- membrana tectoria
- membranane atlantooccipitalis ant. et post.



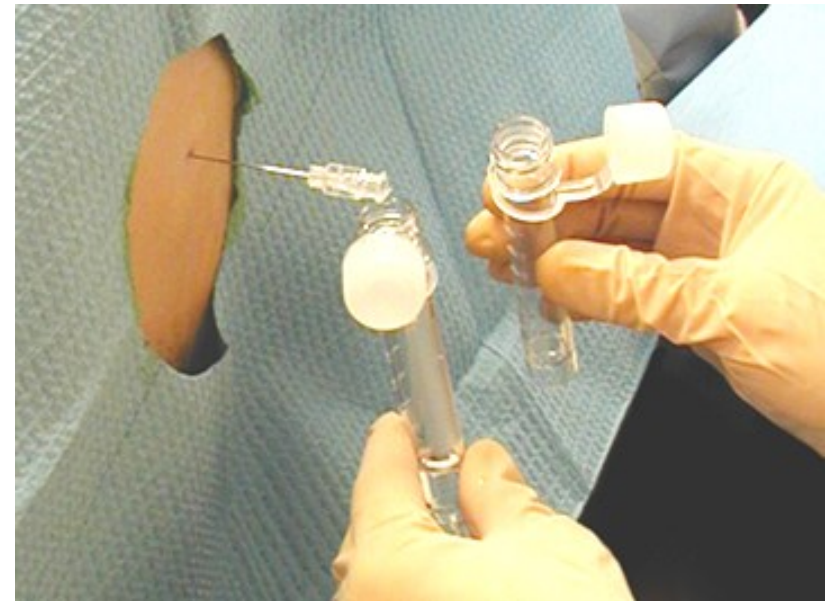
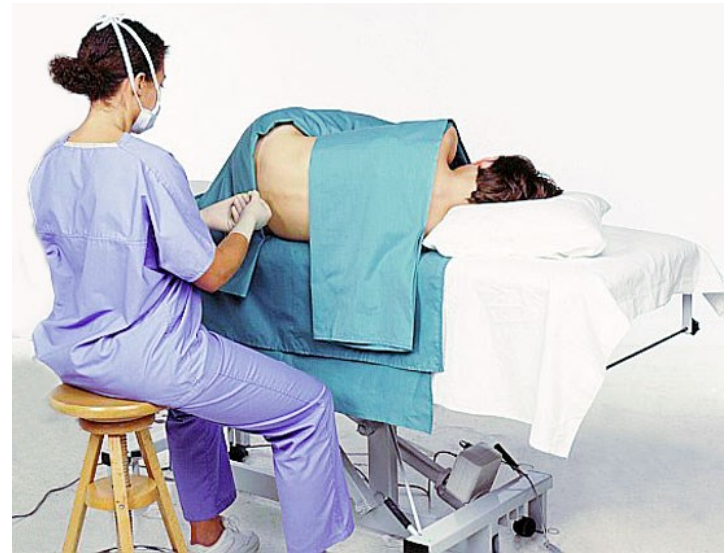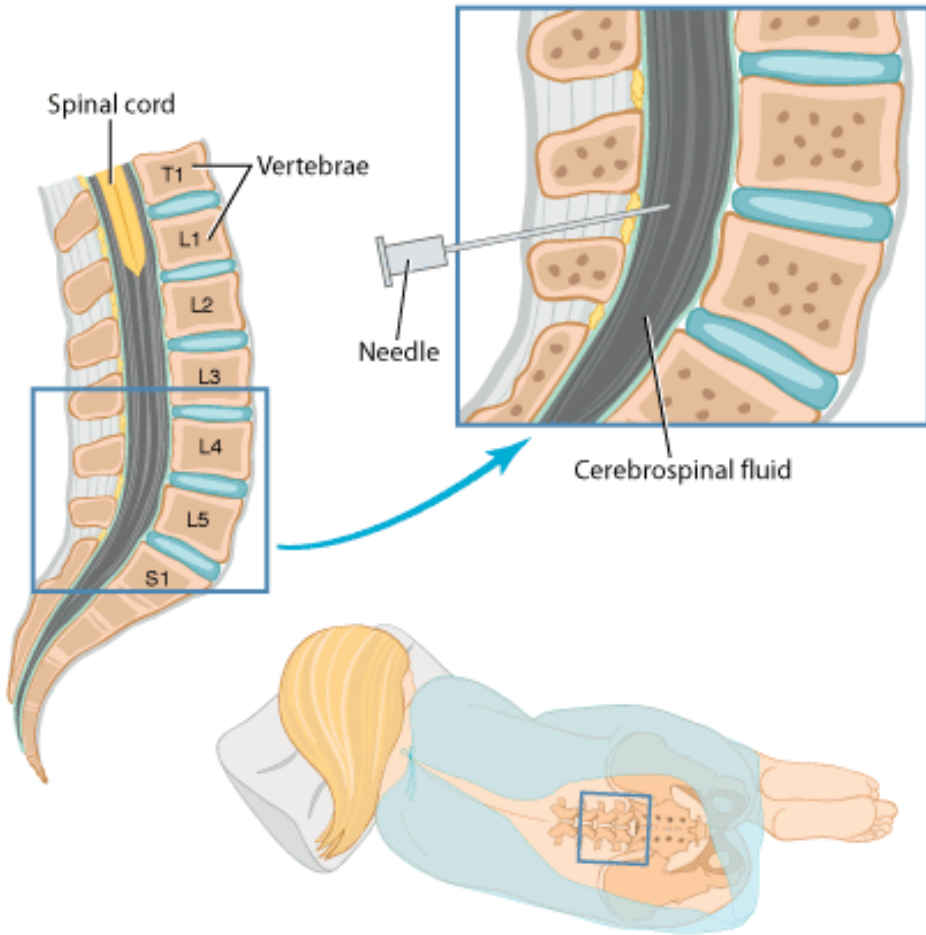




1 arcus anterior
 2 fovea articularis superior
 3 foramen transversarium + processus transversus
 4 arcus posterior
 5 tuberculum posterior

6 dens axis
 13 art. atlantoaxialis
 14 art. atlantooccipitalis - capsula
 15 lig. transversum atlantis
 24 proc. spinosus
 25 dura mater

Lumbal punctio



Források:

Kozsurek Márk: Spine, headjoints

Szentágothai, Réthelyi: Funkcionális anatómia I. (1994)

Platzer: Taschenatlas der Anatomie – Bewegungsapparat (6. Auflage, 1991)

Rohen, Yokochi: Color atlas of anatomy (7th edition, 2011)