

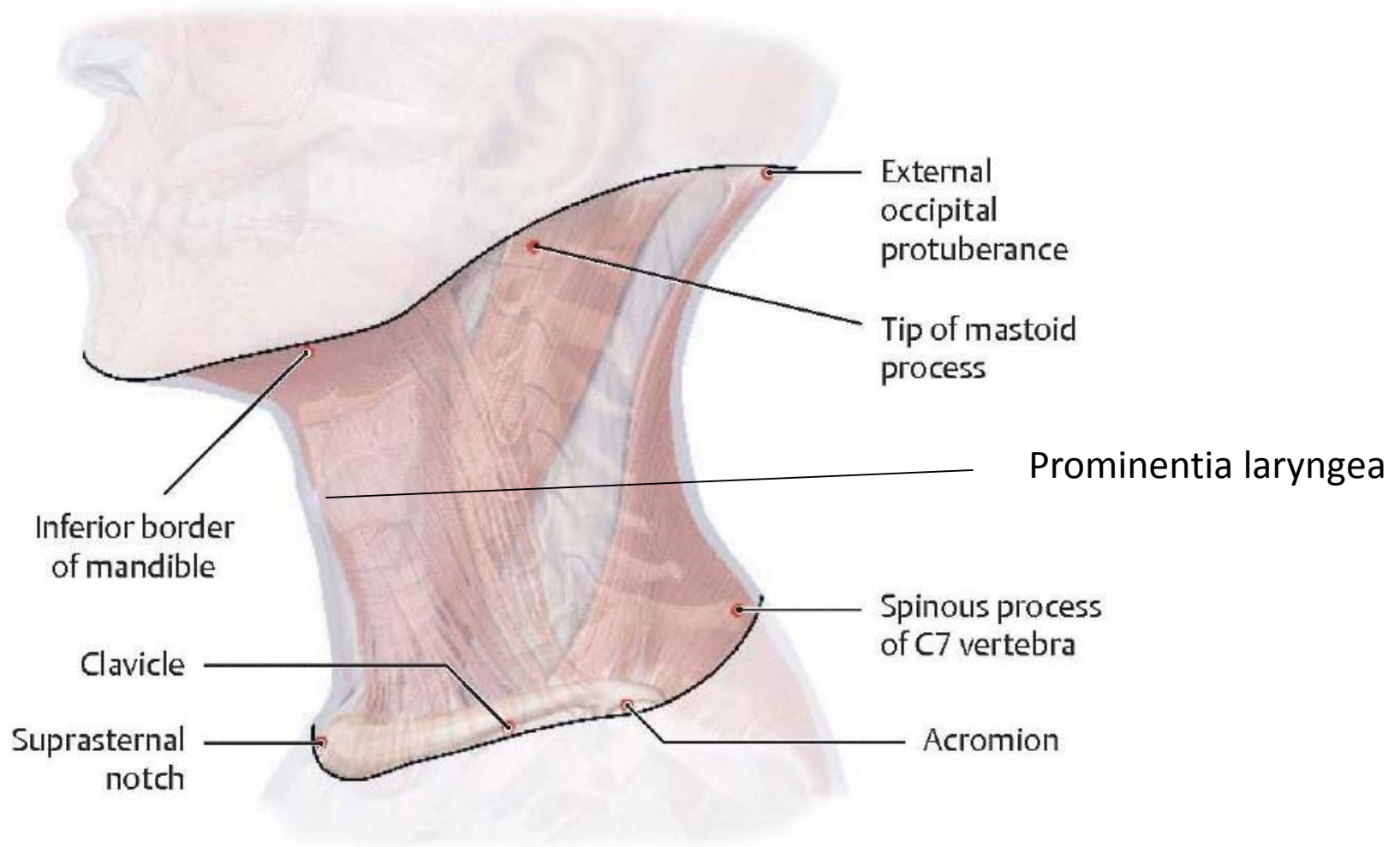


Nyakizmok, nyaki izomháromszögek, nyaki fasciák, hát és tarkóizomzat

Ph.D., Dr. Lendvai Dávid
Anatómia, Szövet- és fejlődéstani Intézet
2018.

Általános aspektusok

A nyak határai

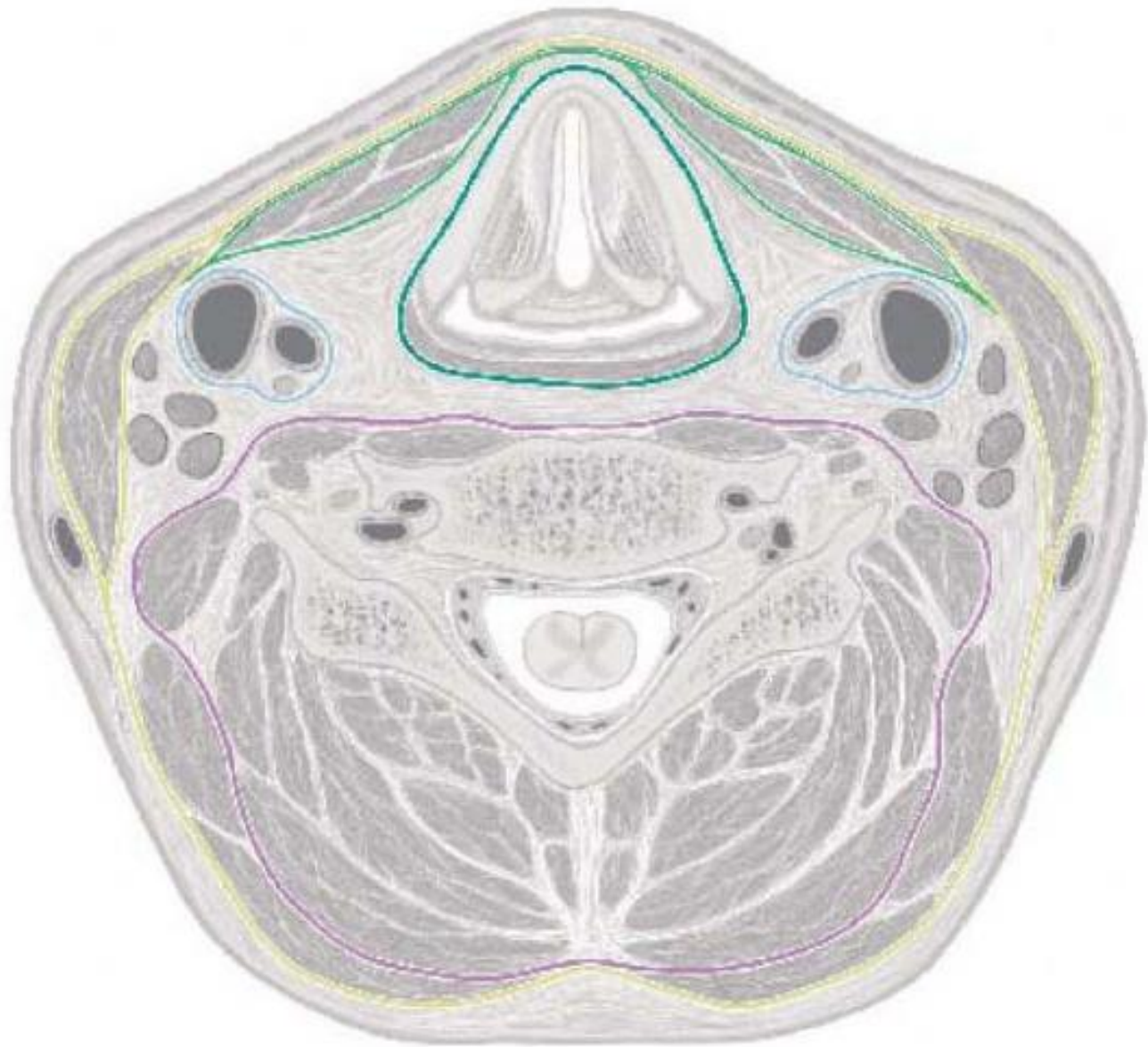




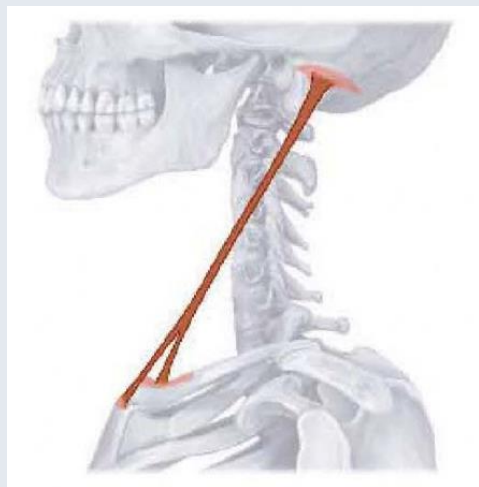TOP 30

MISS TIFFANY'S UNIVERSE 2017





Felületes nyakizmok



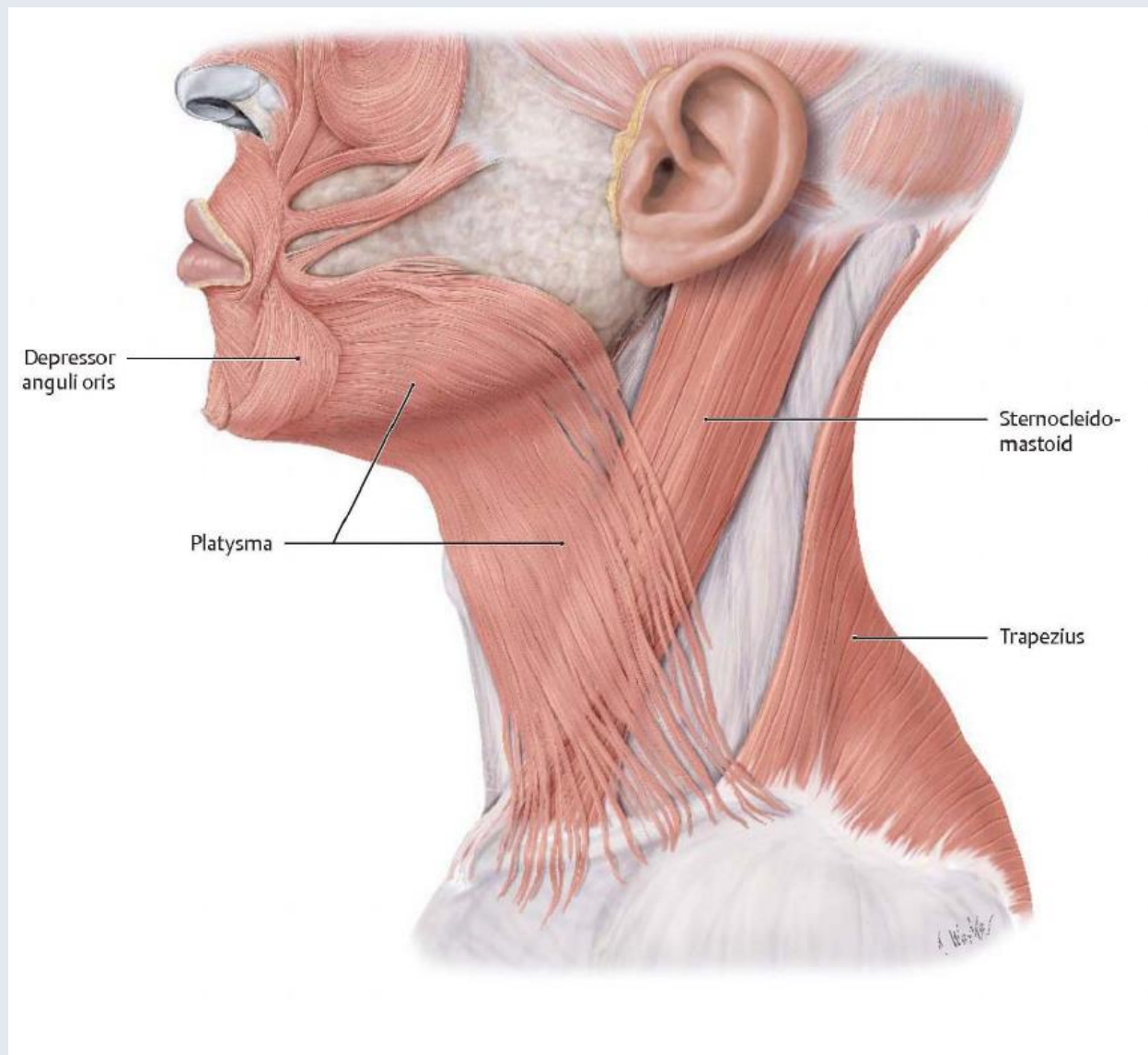
M. sternocleidomastoideus

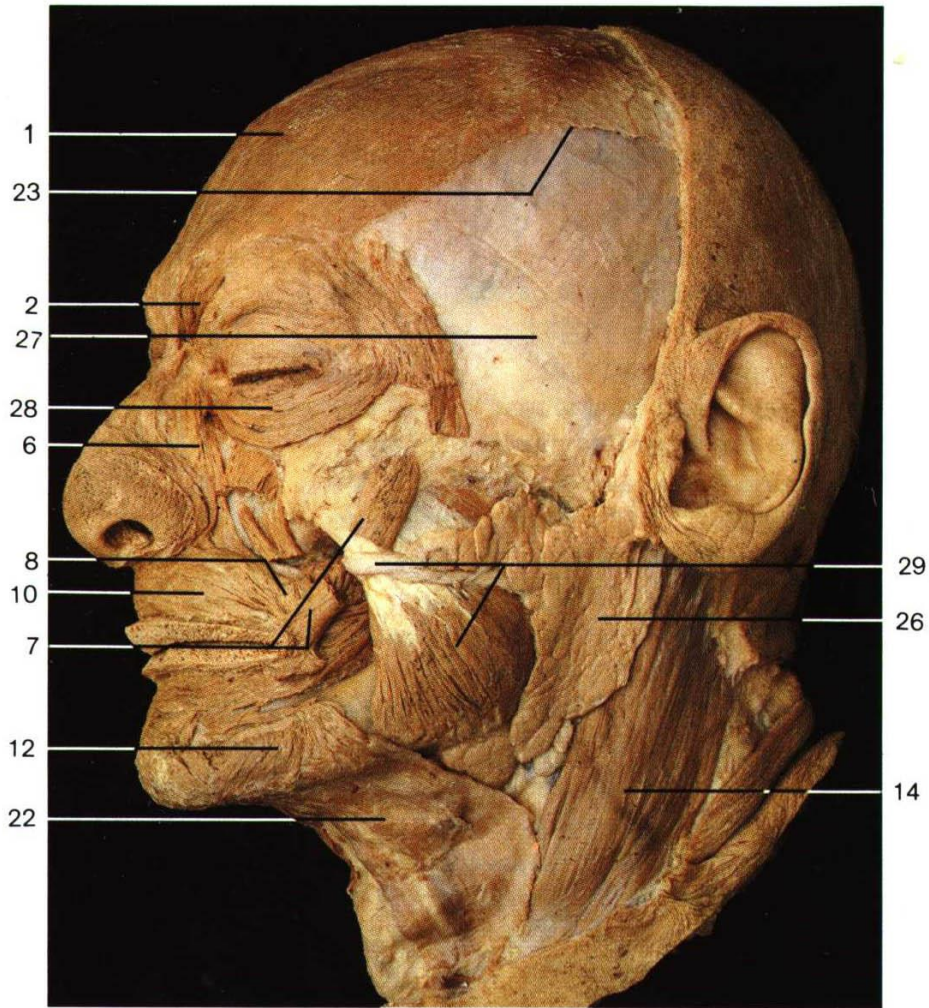
- funkció:

Unilateralis, fej hajlítás az azonos oldalra, rotáció

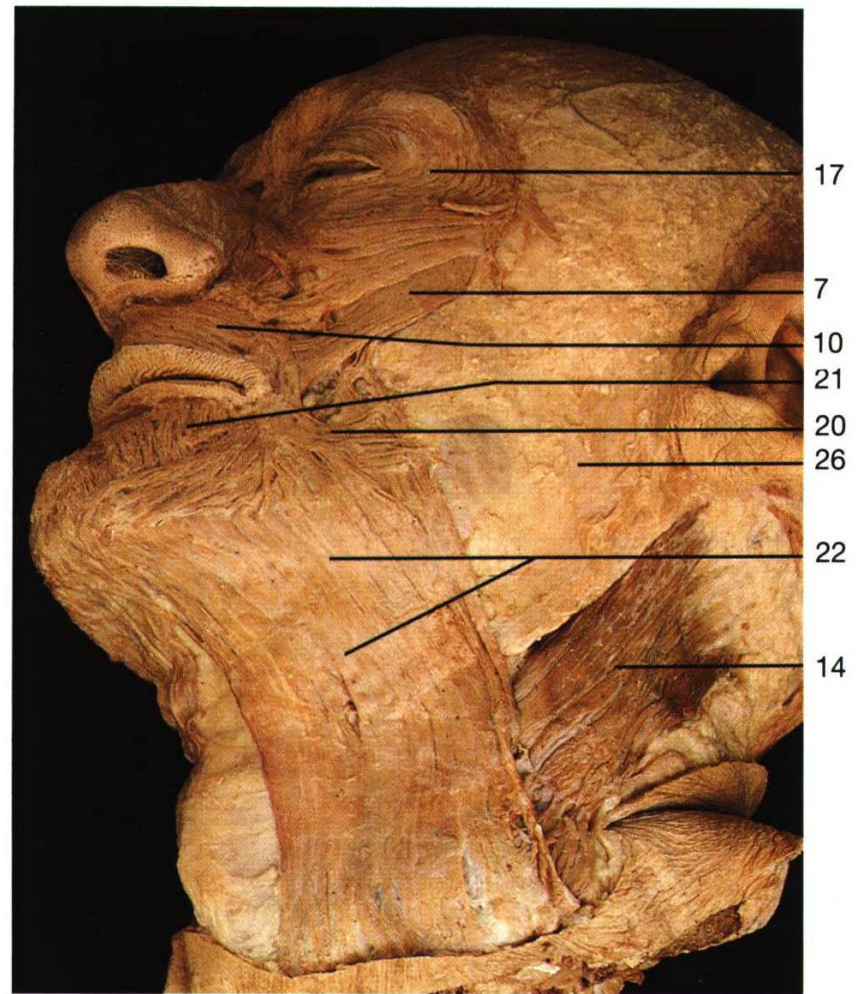
Bilateralis: fej biccentés, légzési segédizom

Beidegzés: XI.



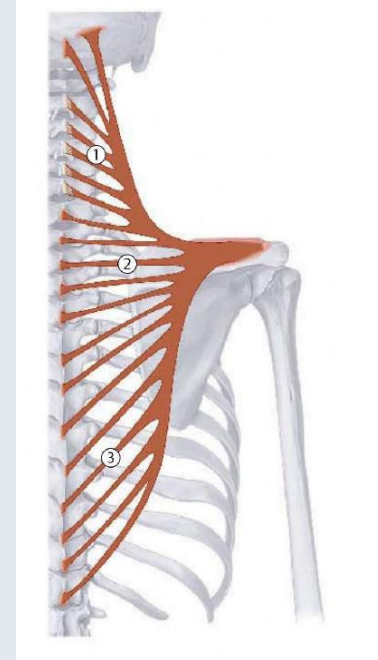
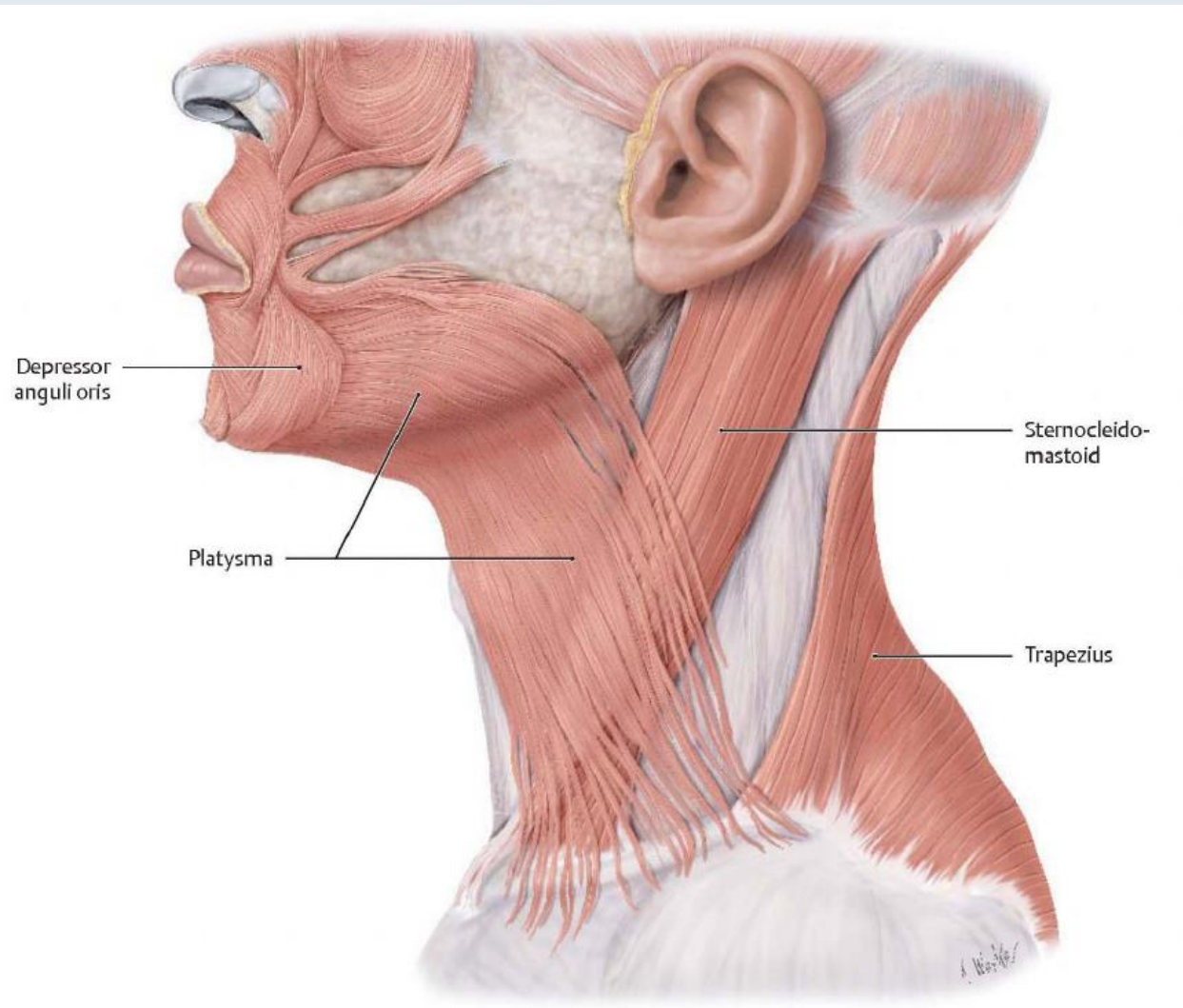


Facial muscles and parotid gland (lateral aspect).



Platysma muscle (oblique lateral aspect). Superficial lamina of cervical fascia partly removed.

Felületes nyakizmok

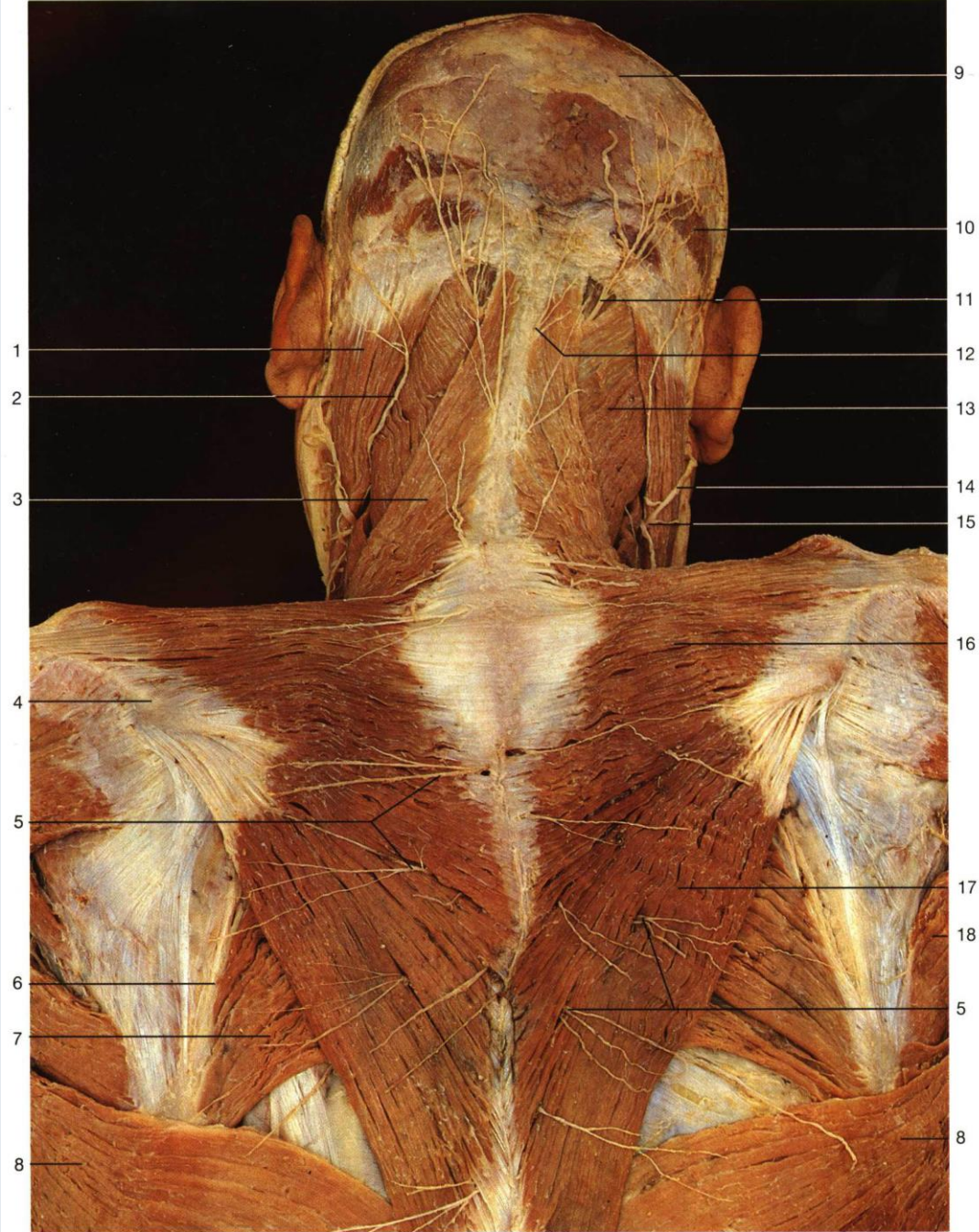


Részei:

- p. descendens
- p. horizontalis
- p. ascendens

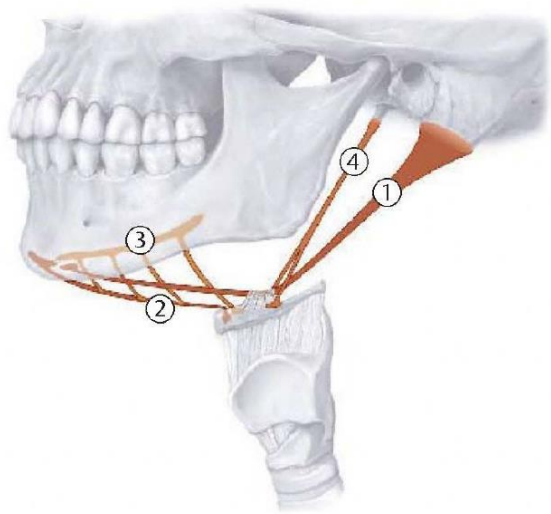
Scapula húzása + fej oldalra döntése

Beidegzés: XI.

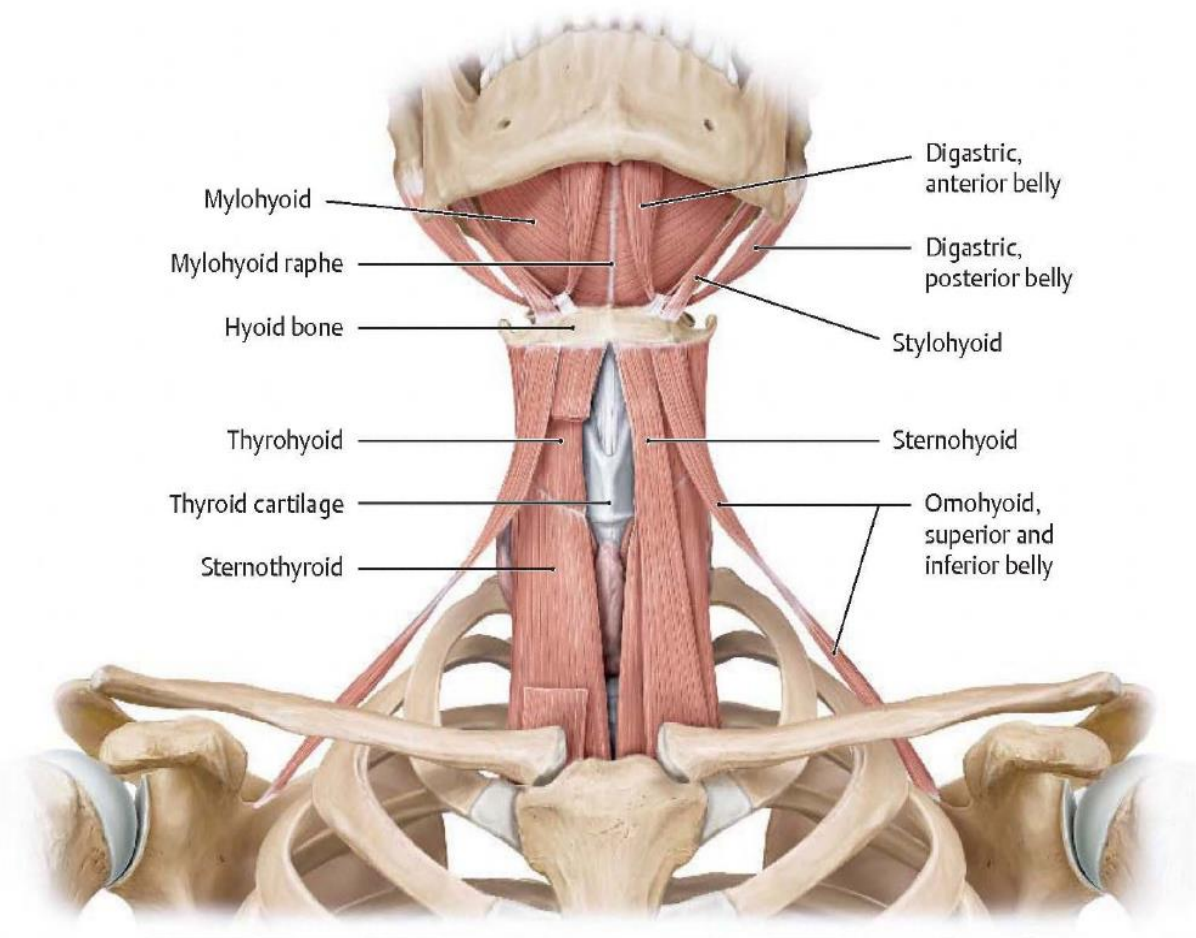


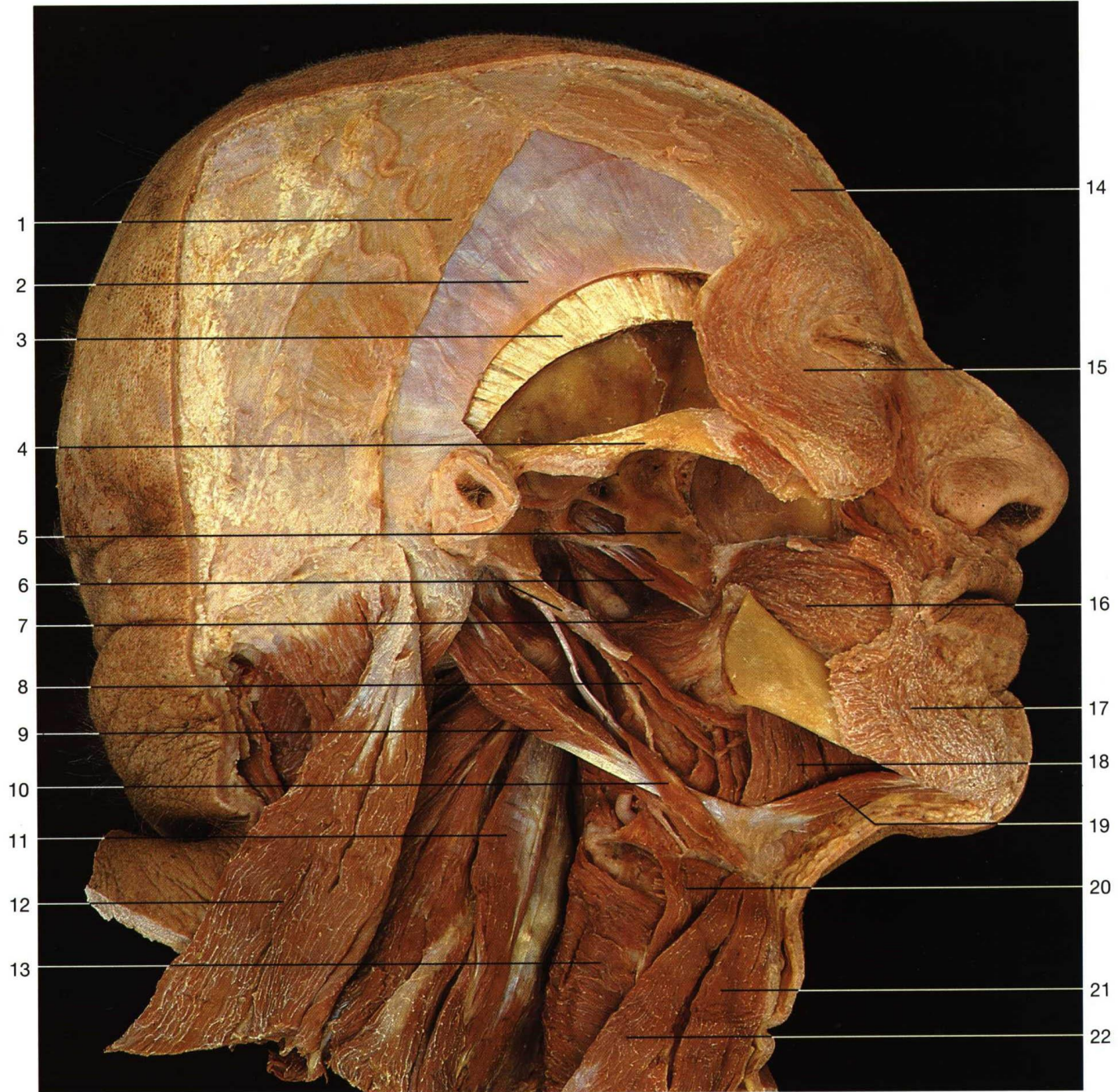
Dorsal aspect of the neck I. Superficial layer. Nuchal region and shoulder.

Nyelvcsont feletti izmok:



- 1.-2. m. digastricus
3. m. mylohyoideus
4. m. stylohyoideus

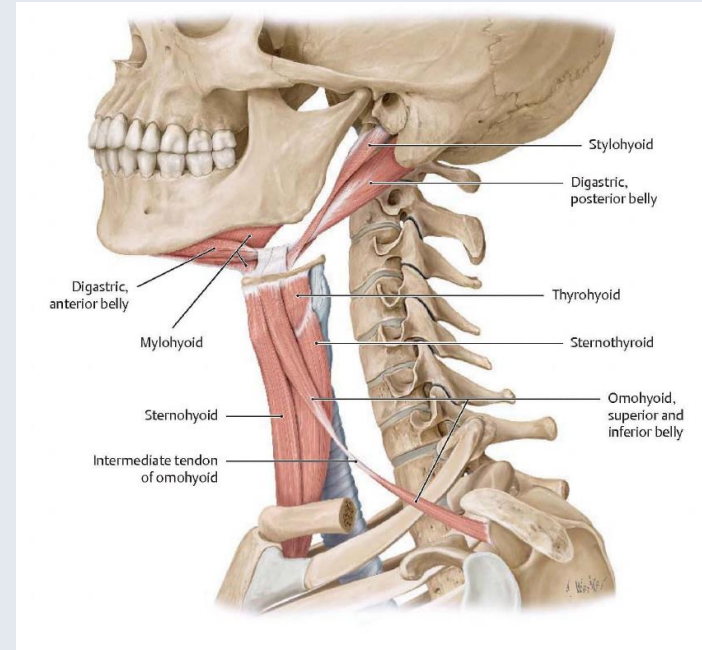
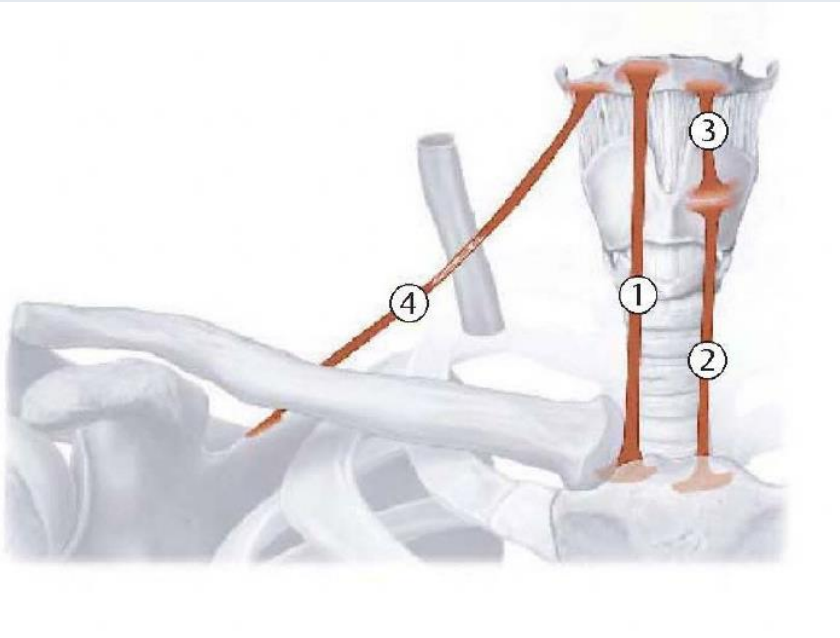




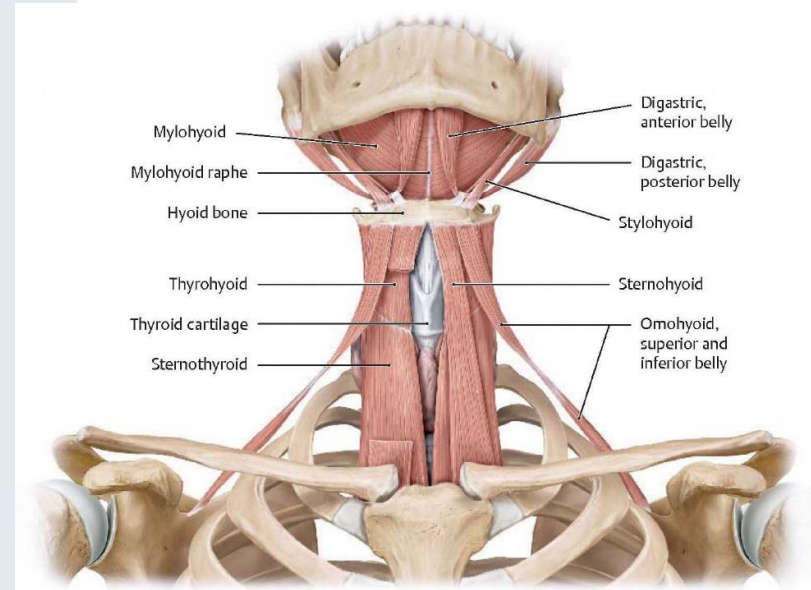
Supra- and infrahyoid muscles, pharynx I (lateral aspect). Ramus of mandible, pterygoid muscles and insertion of temporalis muscle removed.

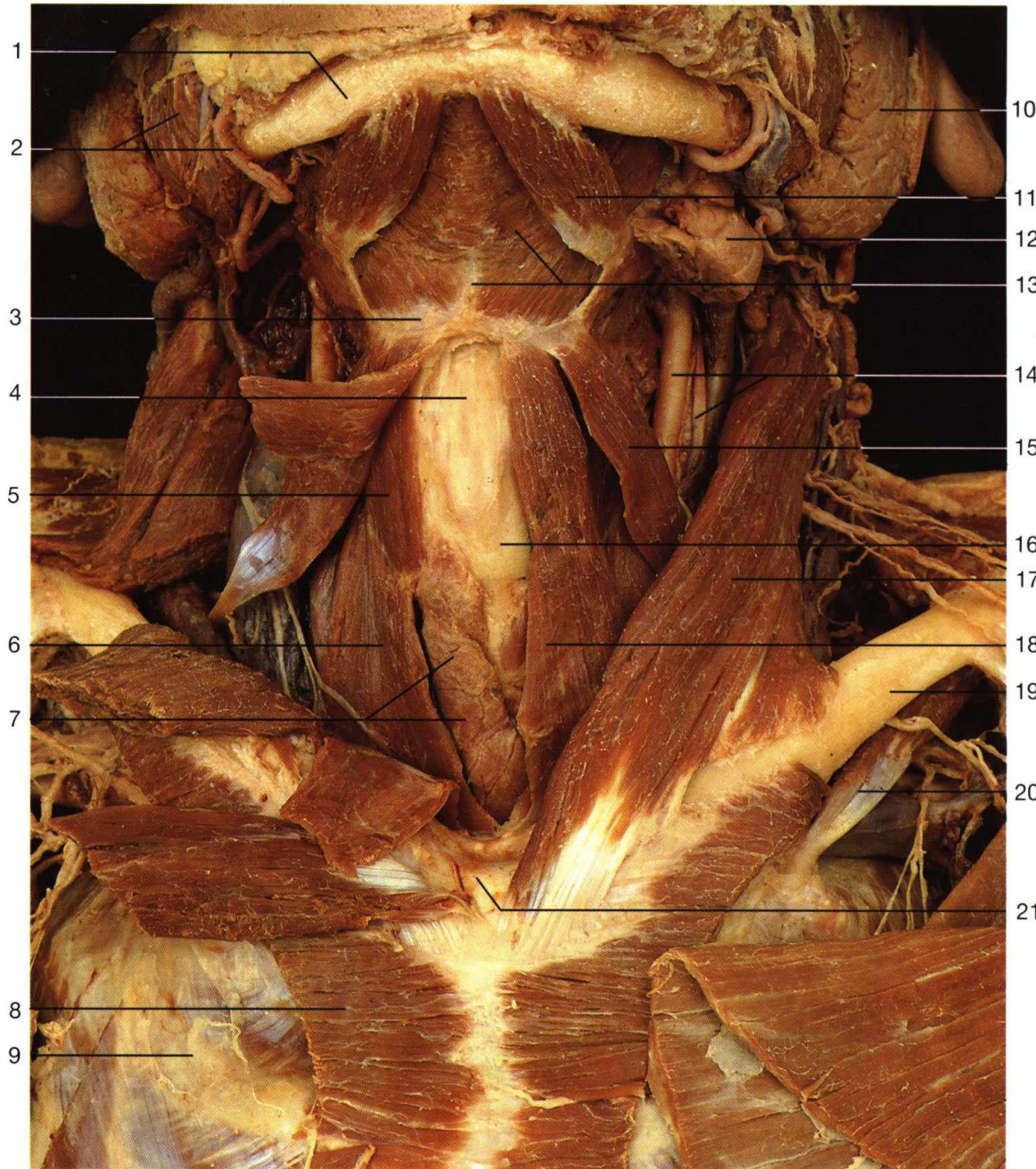
1. Galea occipitalis

Nyelvsont alatti izmok.:



1. m. sternohyoideus
2. m. sternothyroideus
3. m. thyrohyoideus
4. m. omohyoideus

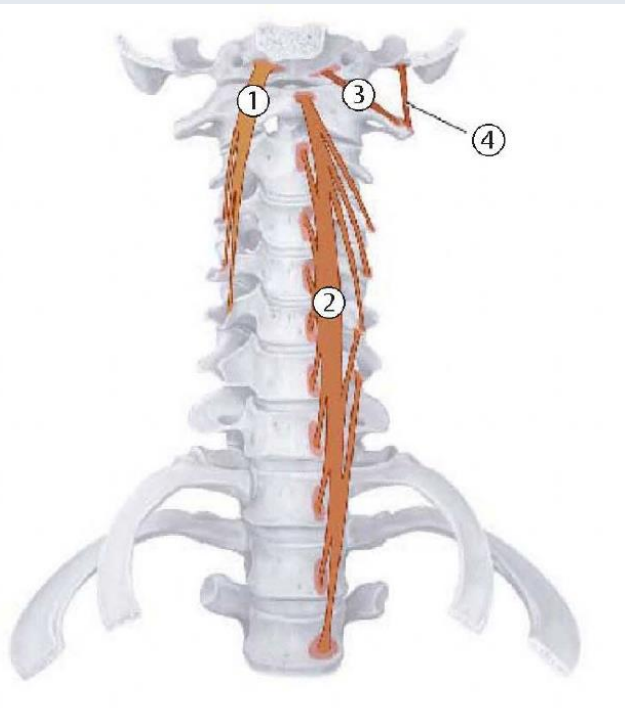




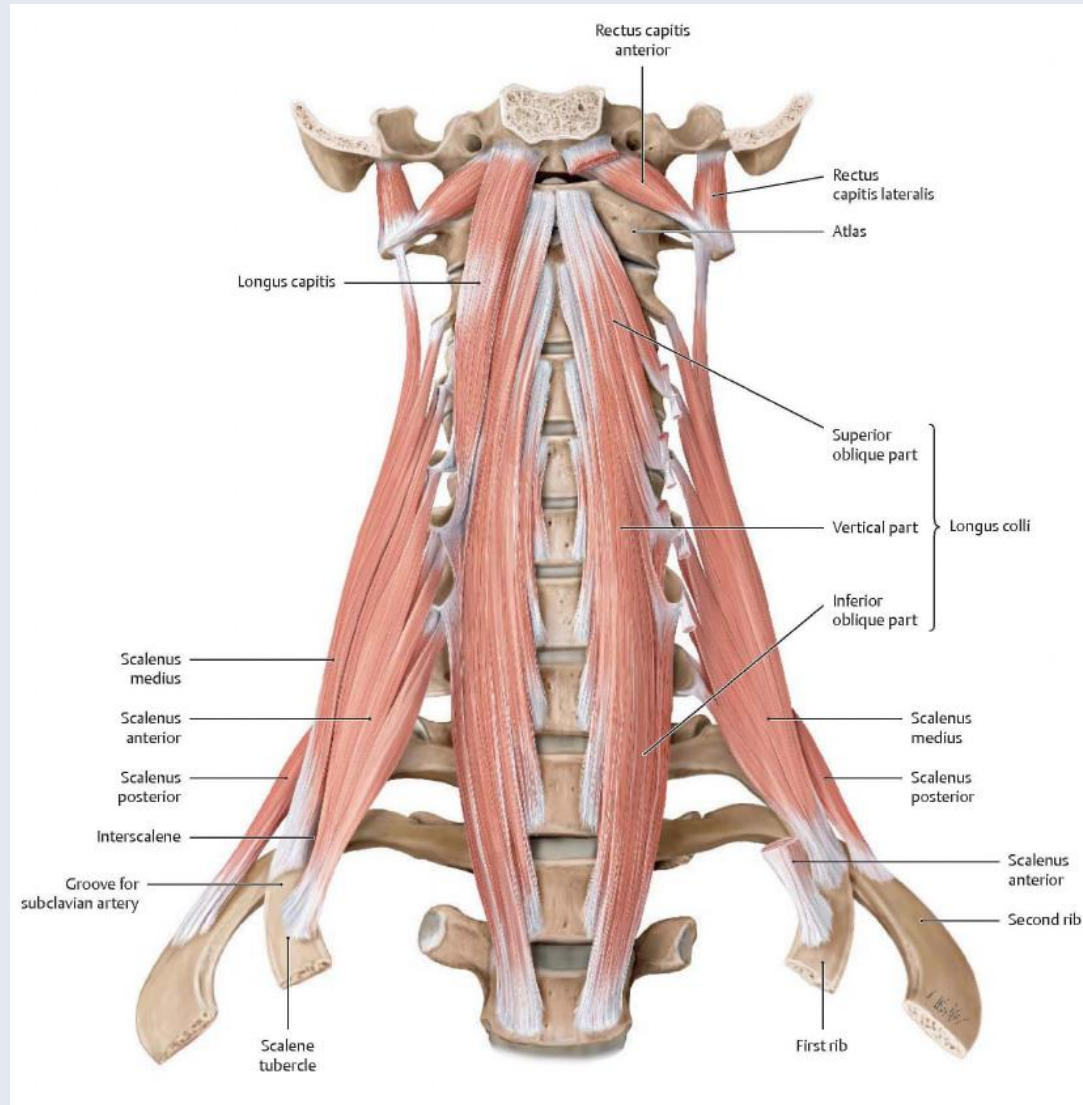
- 1 Mandible
- 2 Masseter muscle and facial artery
- 3 **Hyoid bone**
- 4 Median thyrohyoid ligament
- 5 **Thyrohyoid muscle**
- 6 **Sternohyoid muscle**
- 7 Thyroid gland (pyramidal lobe)
- 8 Pectoralis major muscle
- 9 Second rib
- 10 Parotid gland
- 11 Anterior belly of **digastric muscle**
- 12 Submandibular gland (divided)
- 13 **Mylohyoid muscle** and mylohyoid raphe
- 14 External carotid artery and vagus nerve
- 15 **Omoxyoid muscle**
- 16 Thyroid cartilage
- 17 Sternocleidomastoid muscle
- 18 **Sternohyoid muscle**
- 19 Clavicle
- 20 Subclavius
- 21 Jugular fossa or suprasternal notch

Muscles of the neck (anterior aspect). Sternocleidomastoid and sternohyoid muscles on the right have been divided and reflected.

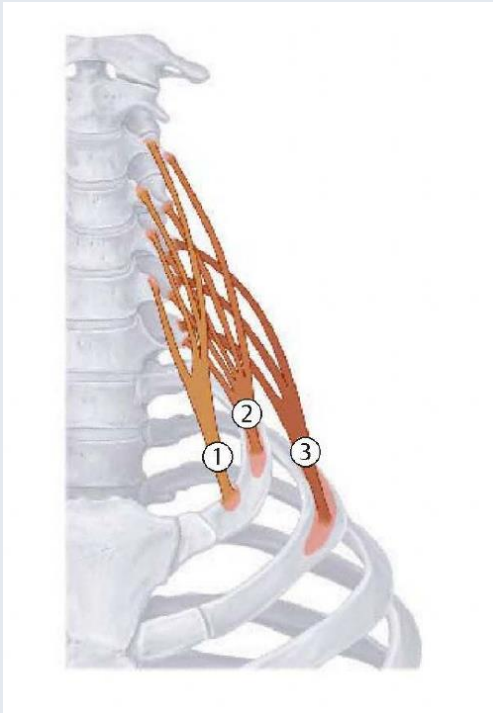
Mély nyakizmok I. (praevertebralis)::



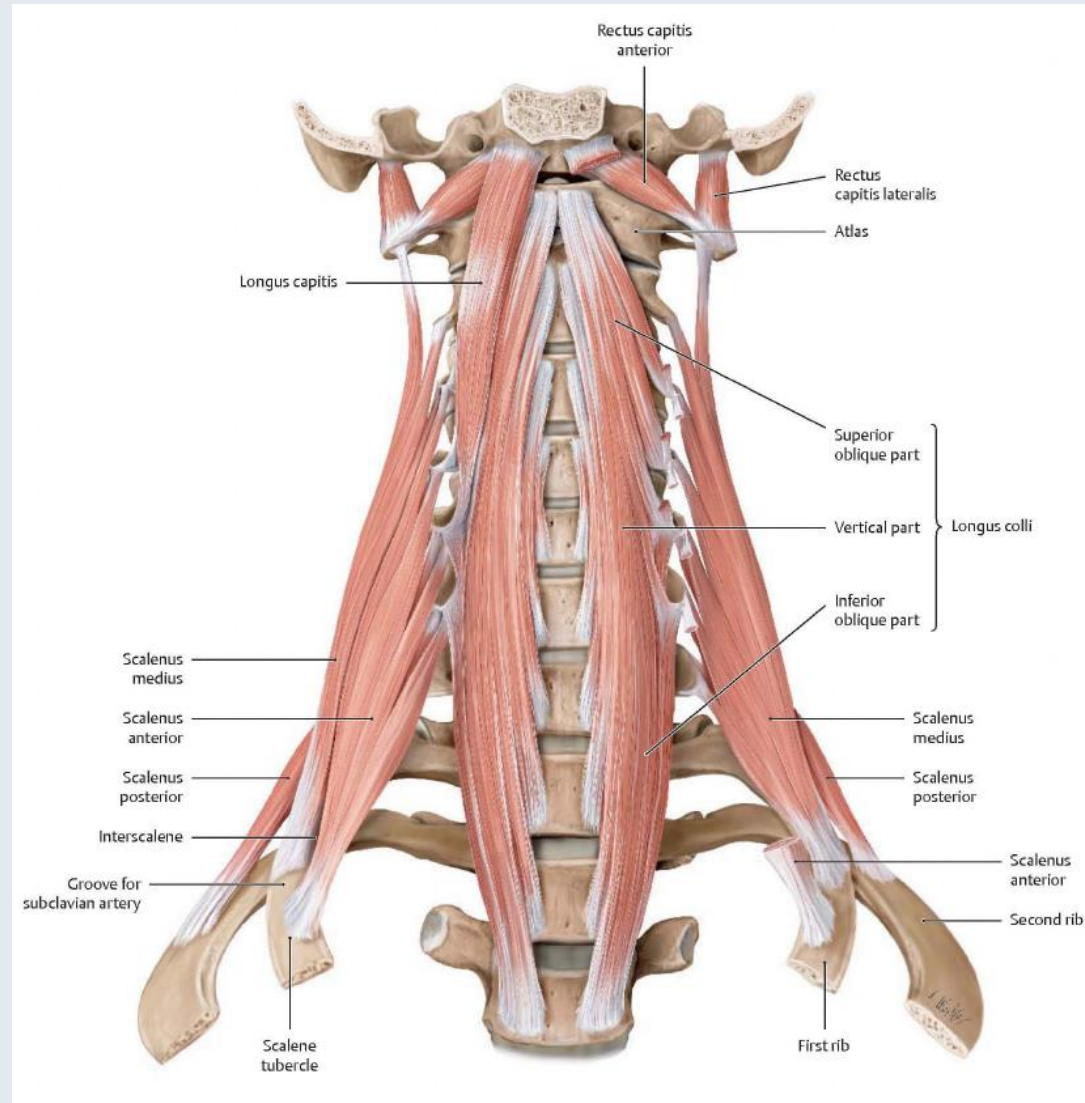
- 1. m. longus capitis
- 2. m. longus colli
- 3.-4. m. rectus capitis anterior et lateralis

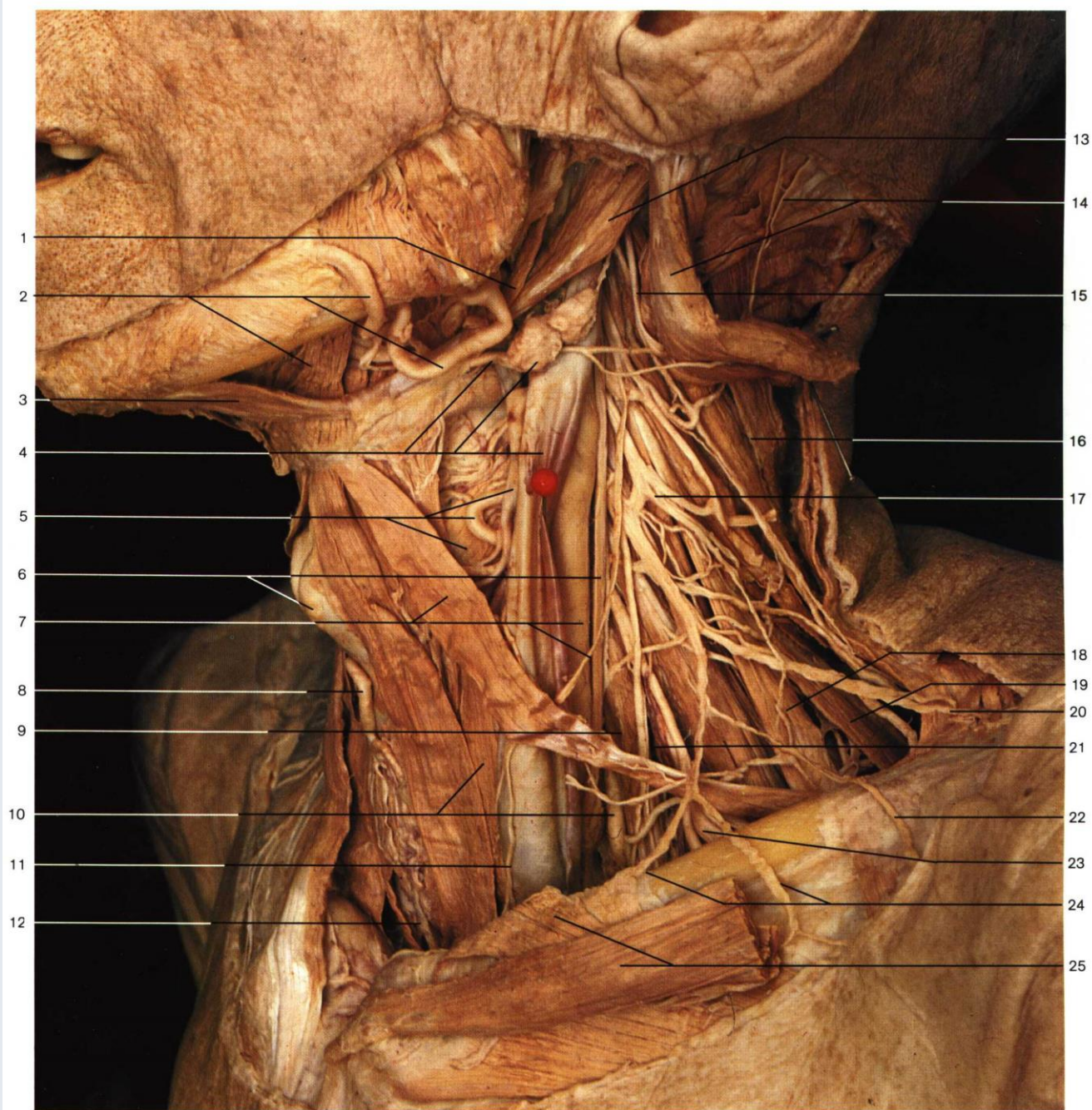


Mély nyakizmok II. (lateralis)::



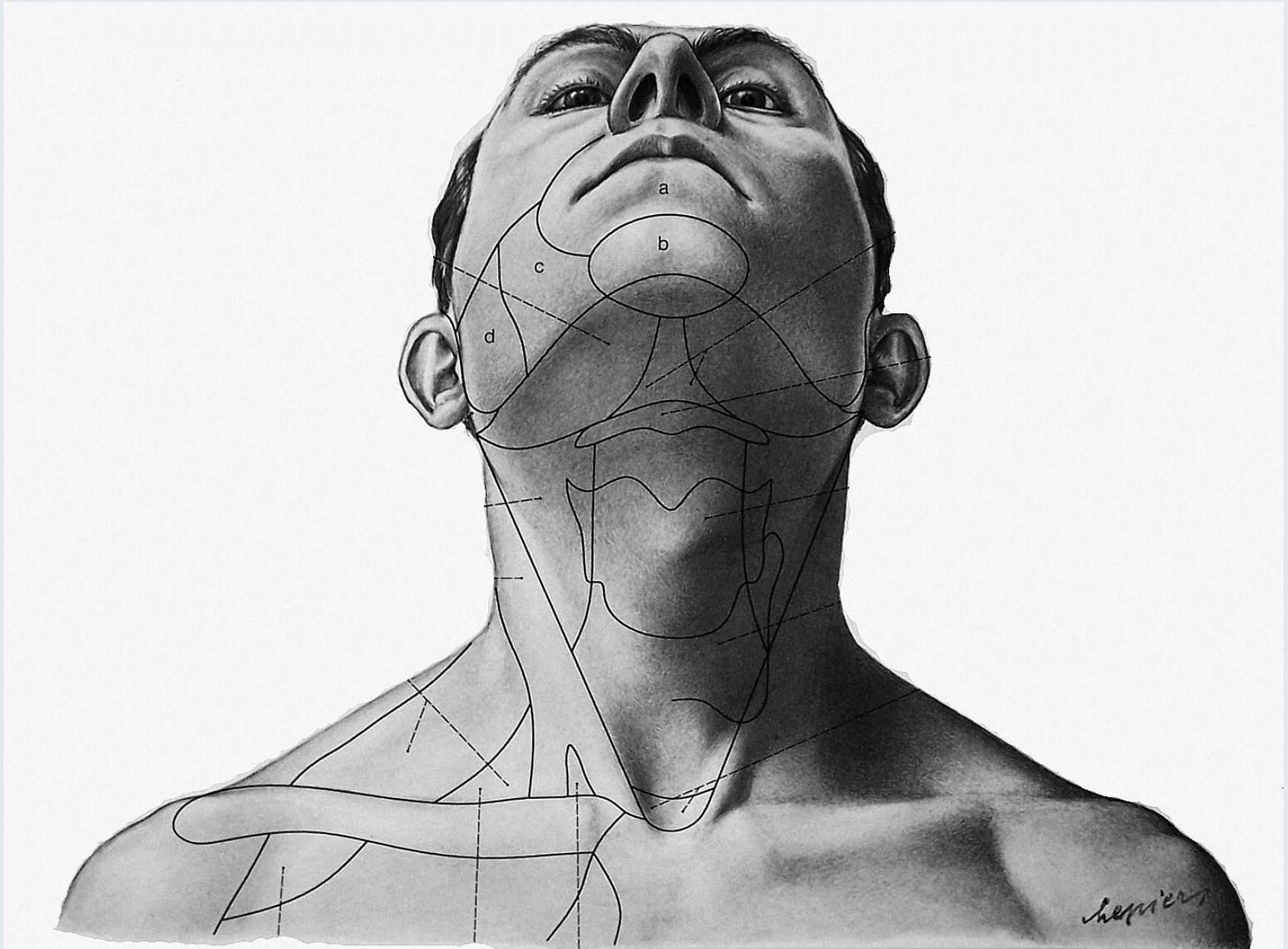
1. m. scalenus anterior
2. m. scalenus medius
3. m. scalenus posterior





Neck, deep dissection (lateral aspect). The internal jugular vein has been reflected to expose the carotid artery and vagus nerve.

Nyaki izomháromszögek:



Trigonum submandibulare:

Basis mandibulae (felül)

m. digastricus vent. ant. (elől)

m. digastricus vent. post. (hátul)

Trigonum submentale:

2x m. digastricus vent. ant. (lateral)

Corpus ossis hyoidei (elől)

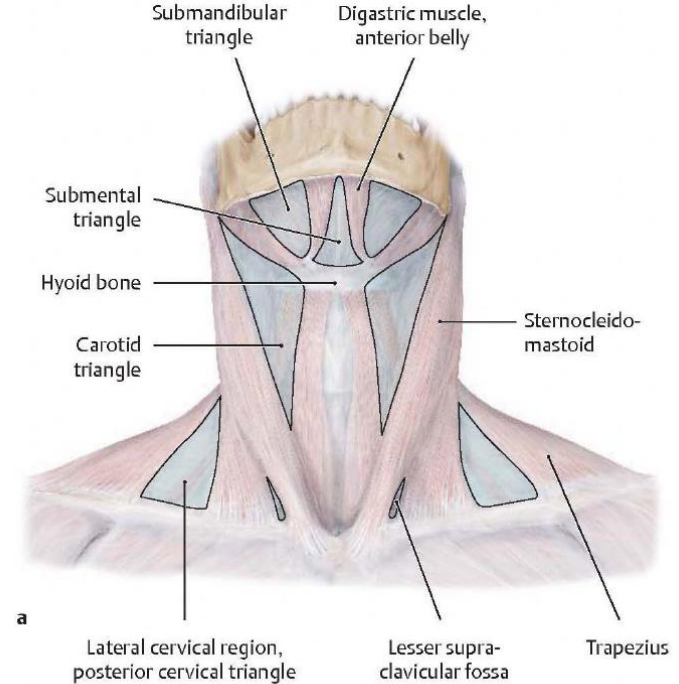
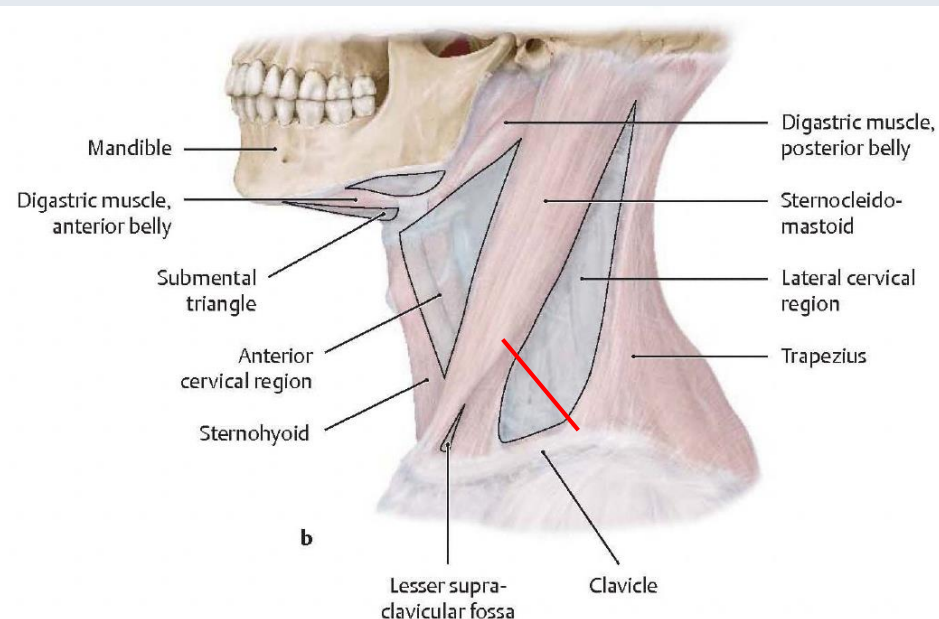
Trigonum caroticum:

m. digastricus vent. post. (felül)

m. sternocleidomastoideus (elől)

m. omohyoideus vent. sup. (hátul)

Trigonum supraclaviculare minor



Trigonum supraclaviculare major

-Trigonum omotrapezoideum:

m. sternocleidomastoideus (elől)

m. trapezius (hátul)

m. omohyoideus vent. inf. (alul)

-Trigonum omoclaviculare:

m. sternocleidomastoideus (elől)

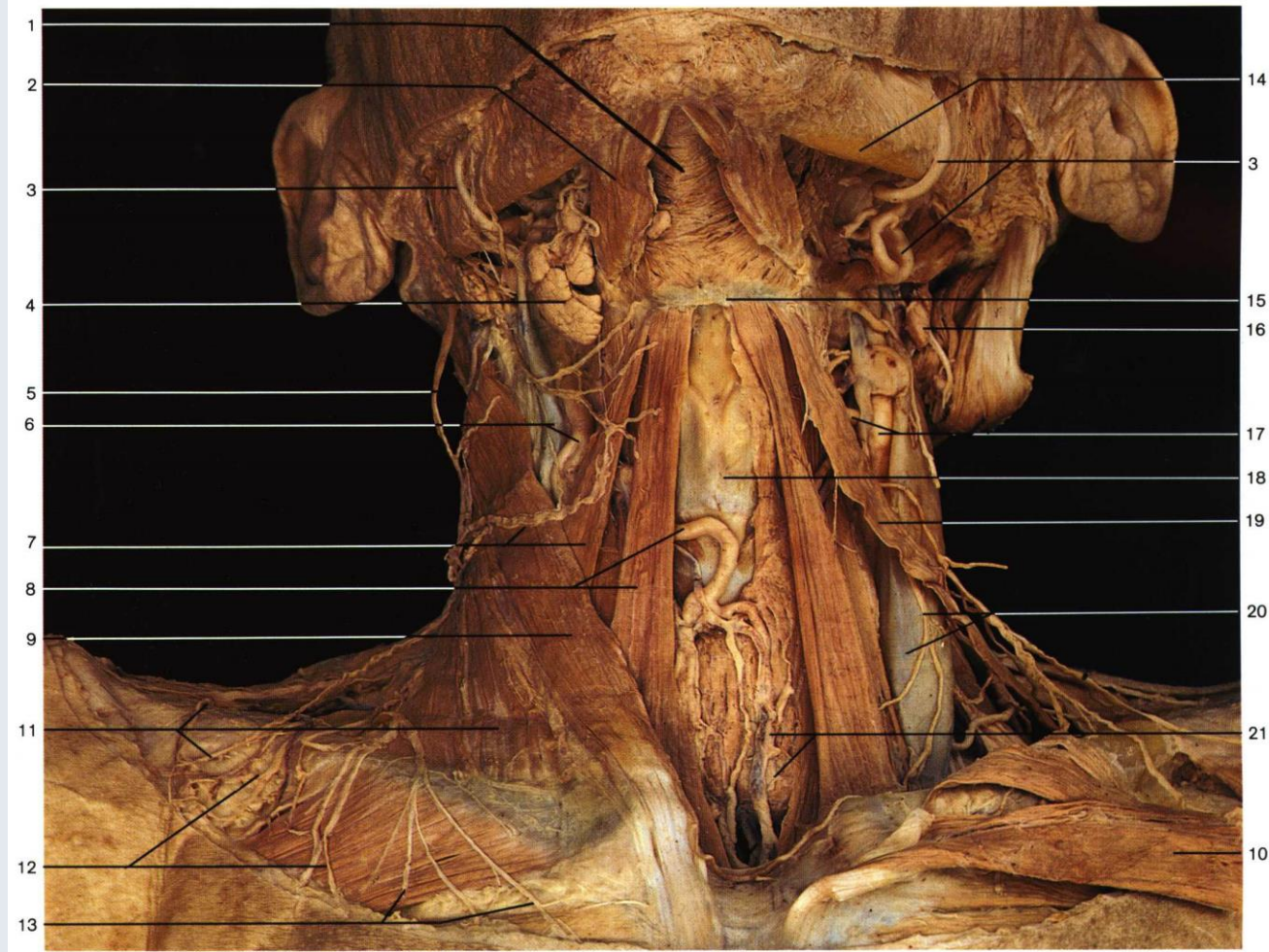
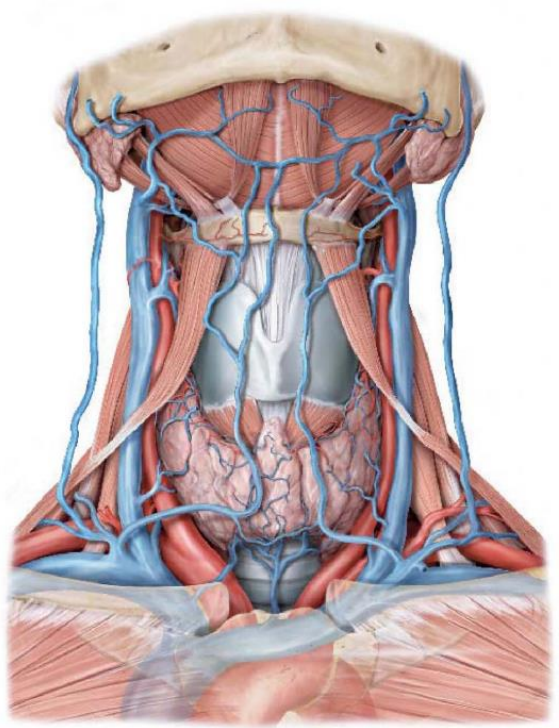
m. omohyoideus vent. inf. (hátul)

corpus claviculae (alul)

Középső nyaki régió (regio cervicalis mediana):

Trigonum submentale

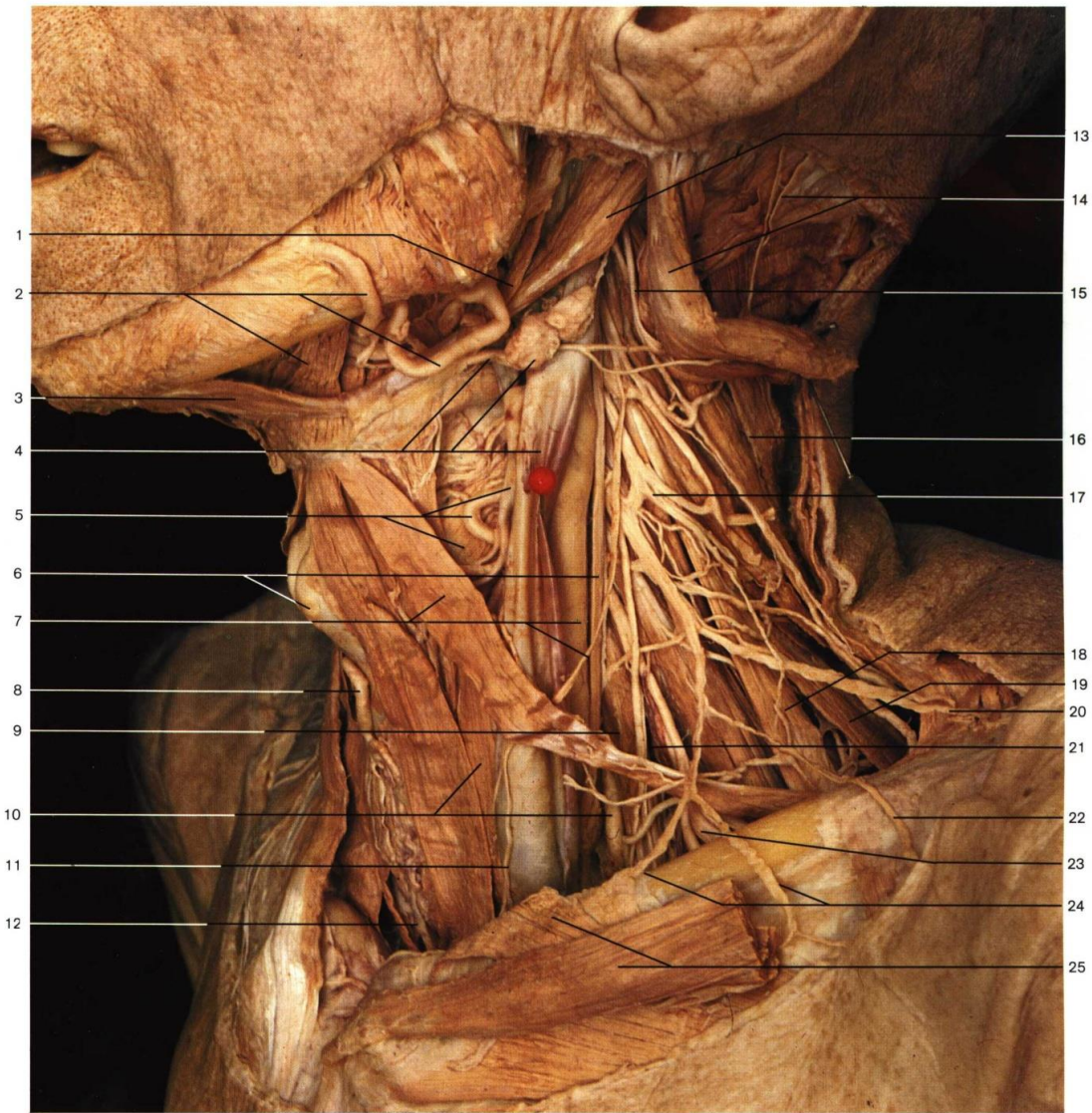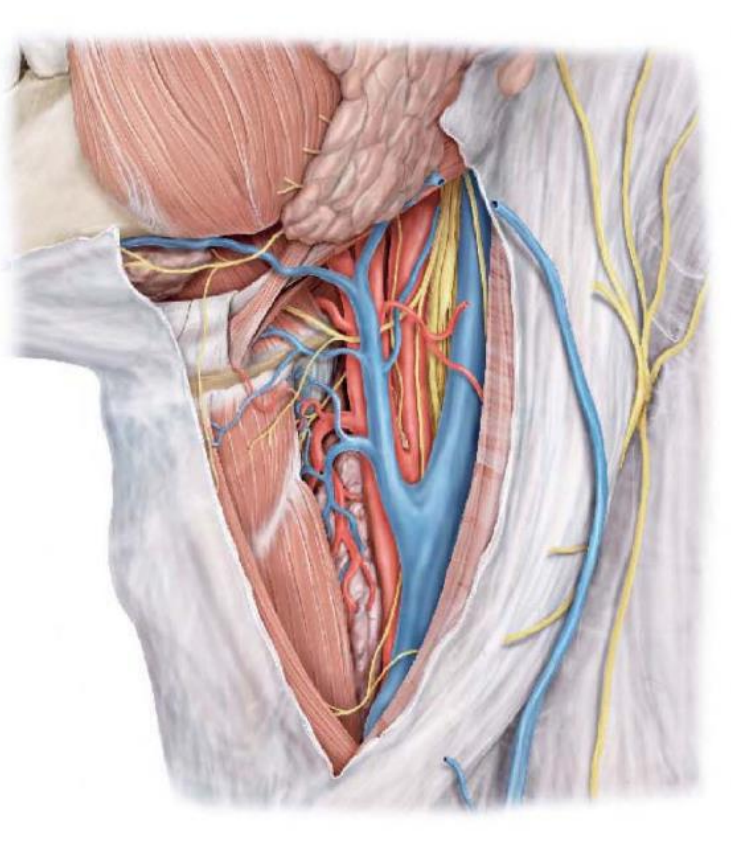
Regio cervicalis mediana



Anterior triangle (anterior aspect). The pretracheal lamina of cervical fascia and left sternocleidomastoid muscle have been removed.

Trigonum submandibulare

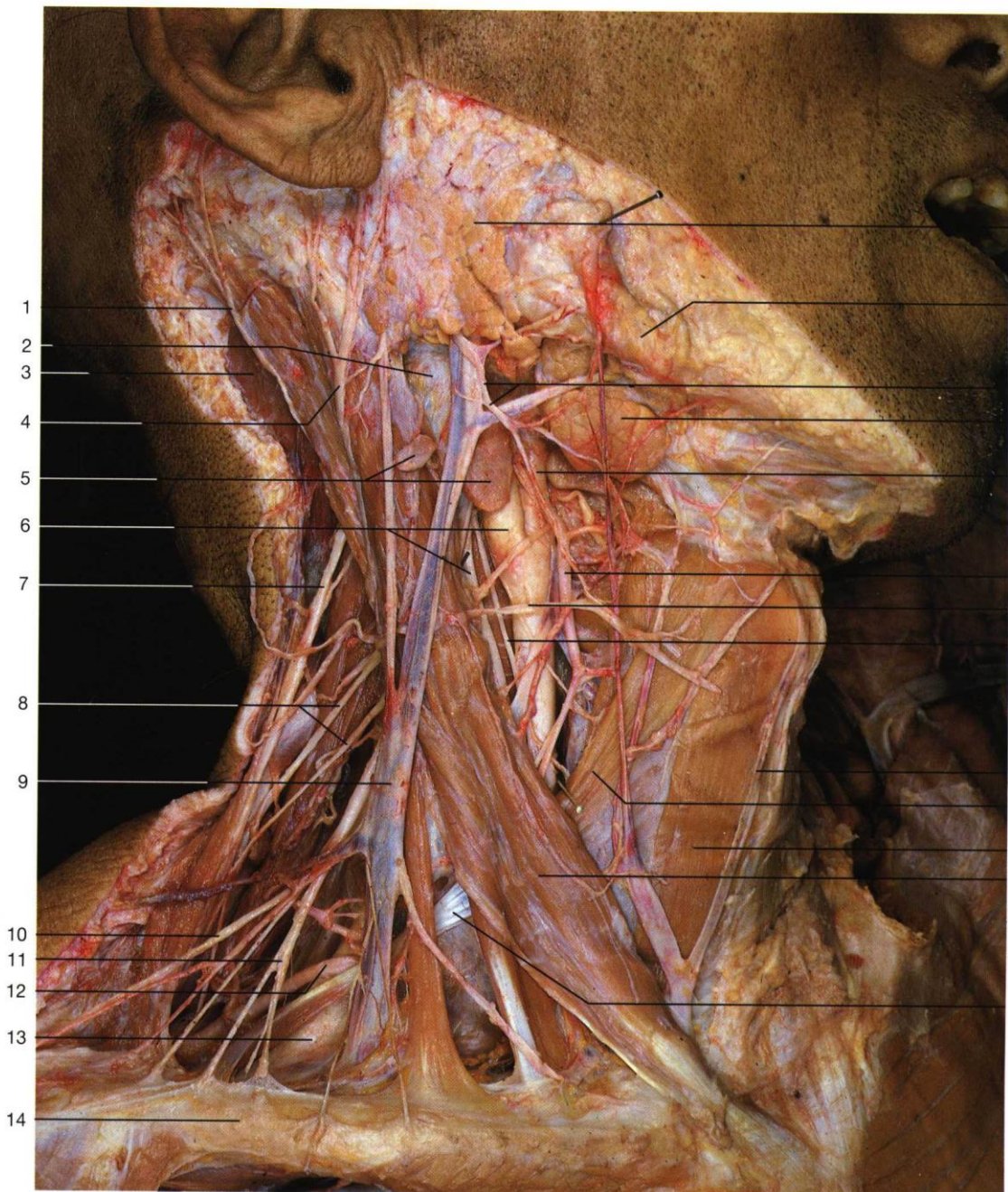
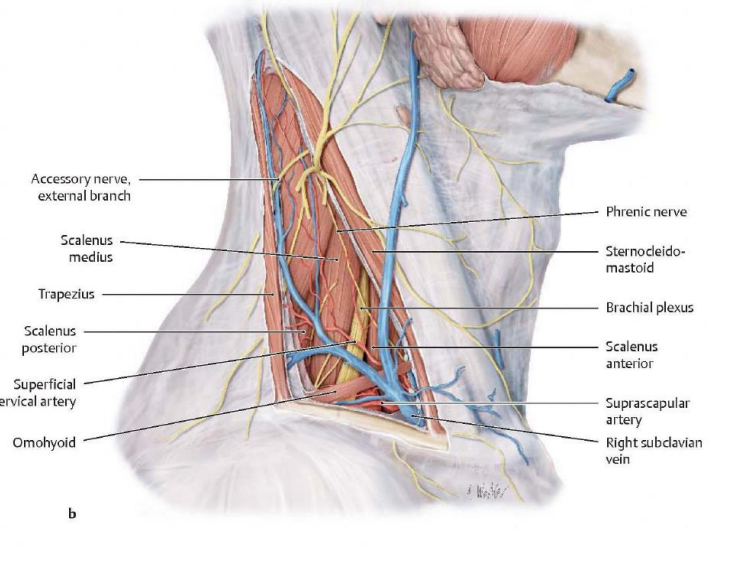
Trigonum caroticum



Neck, deep dissection (lateral aspect). The internal jugular vein has been reflected to expose the carotid artery and vagus nerve.

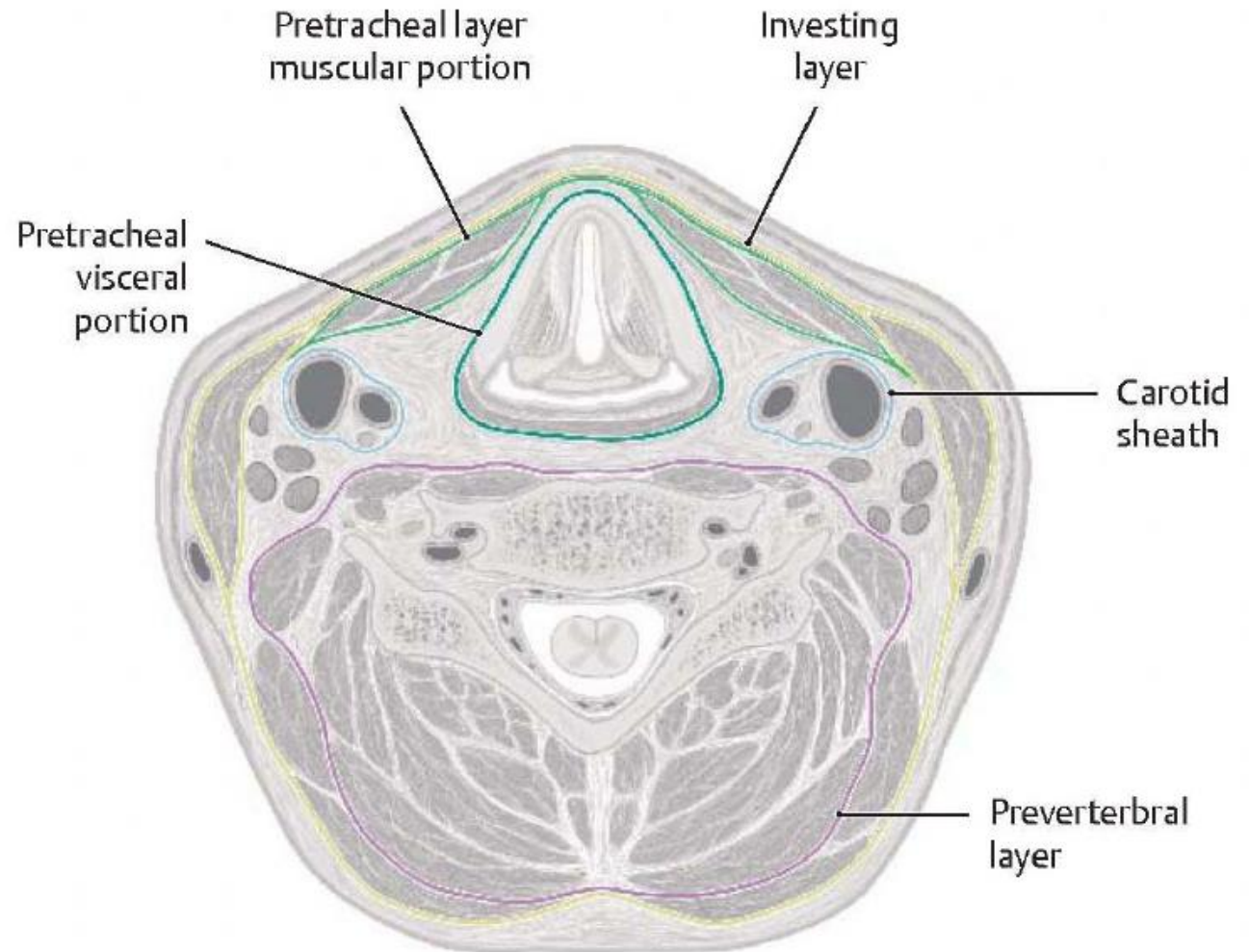
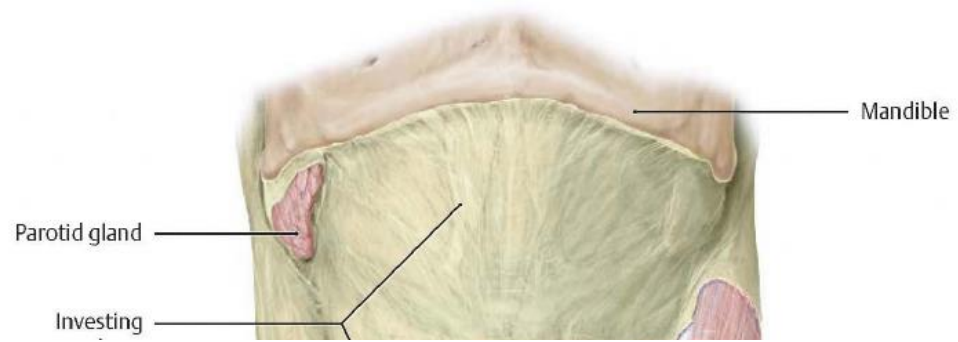
Trigonum supraclaviculare major:

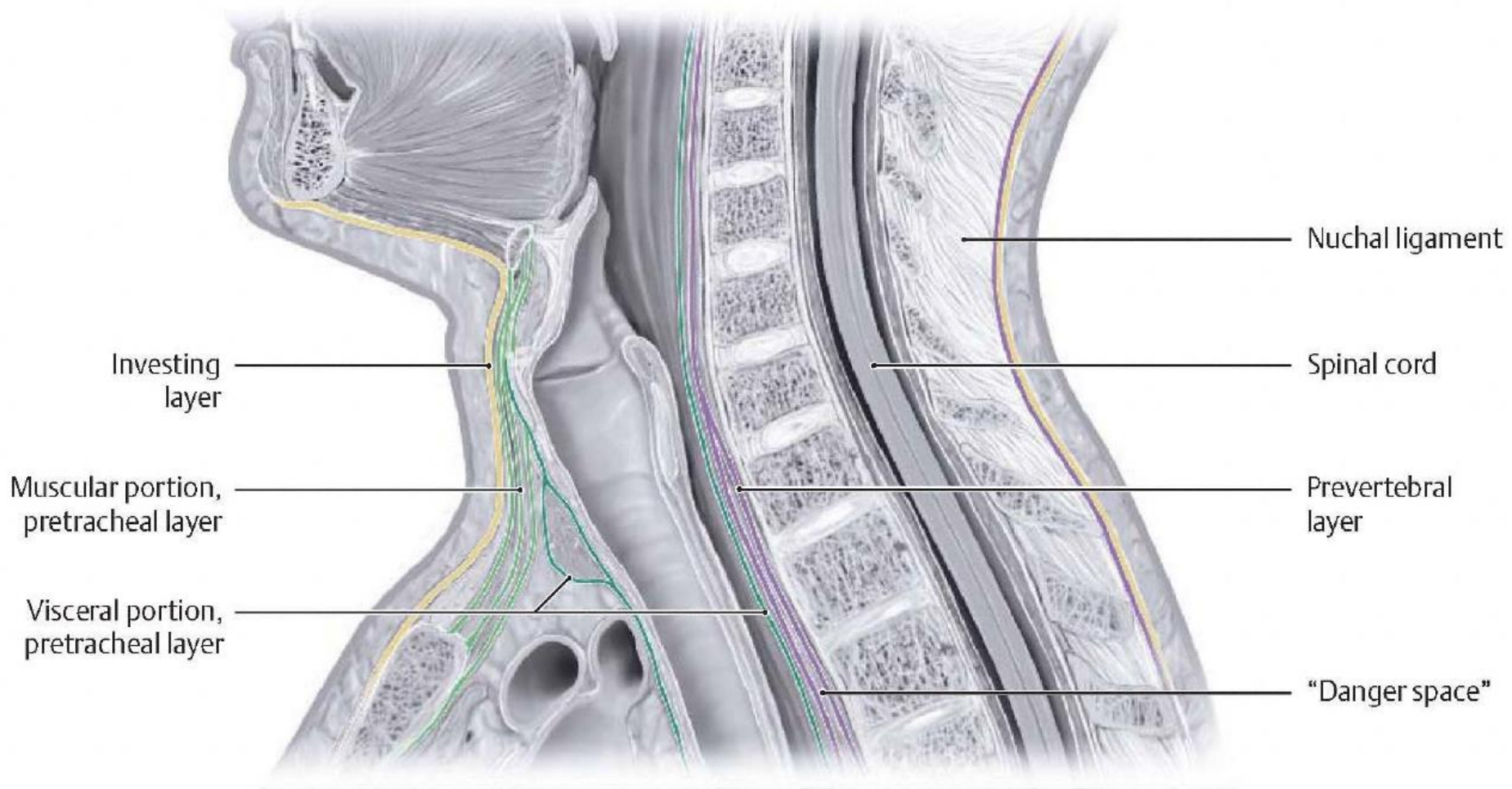
- trigonum omotrapezoideum
- trigonum omoclaviculare



Posterior and carotid triangles (lateral aspect). Superficial dissection. The superficial lamina of cervical fascia has been removed to display the cutaneous branches of the cervical plexus and subcutaneous veins.

Nyaki fasciák





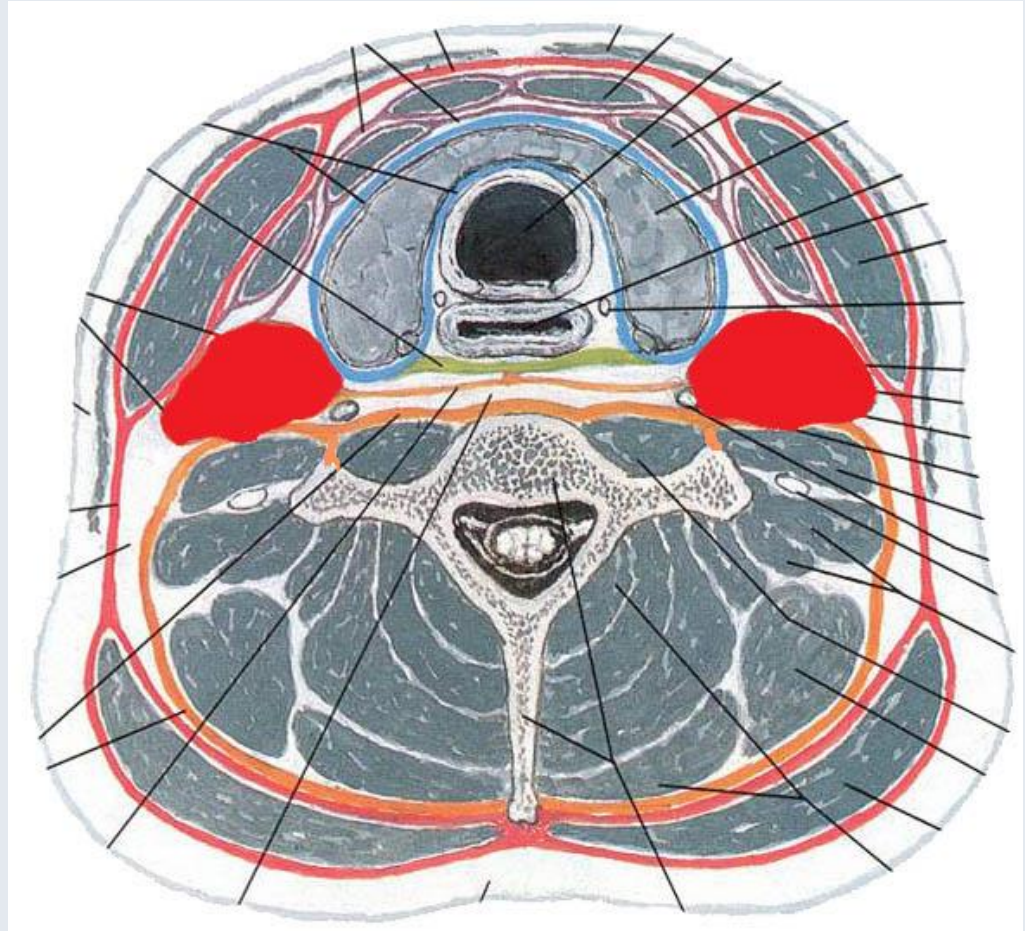
Lamina superficialis

Lamina visceralis

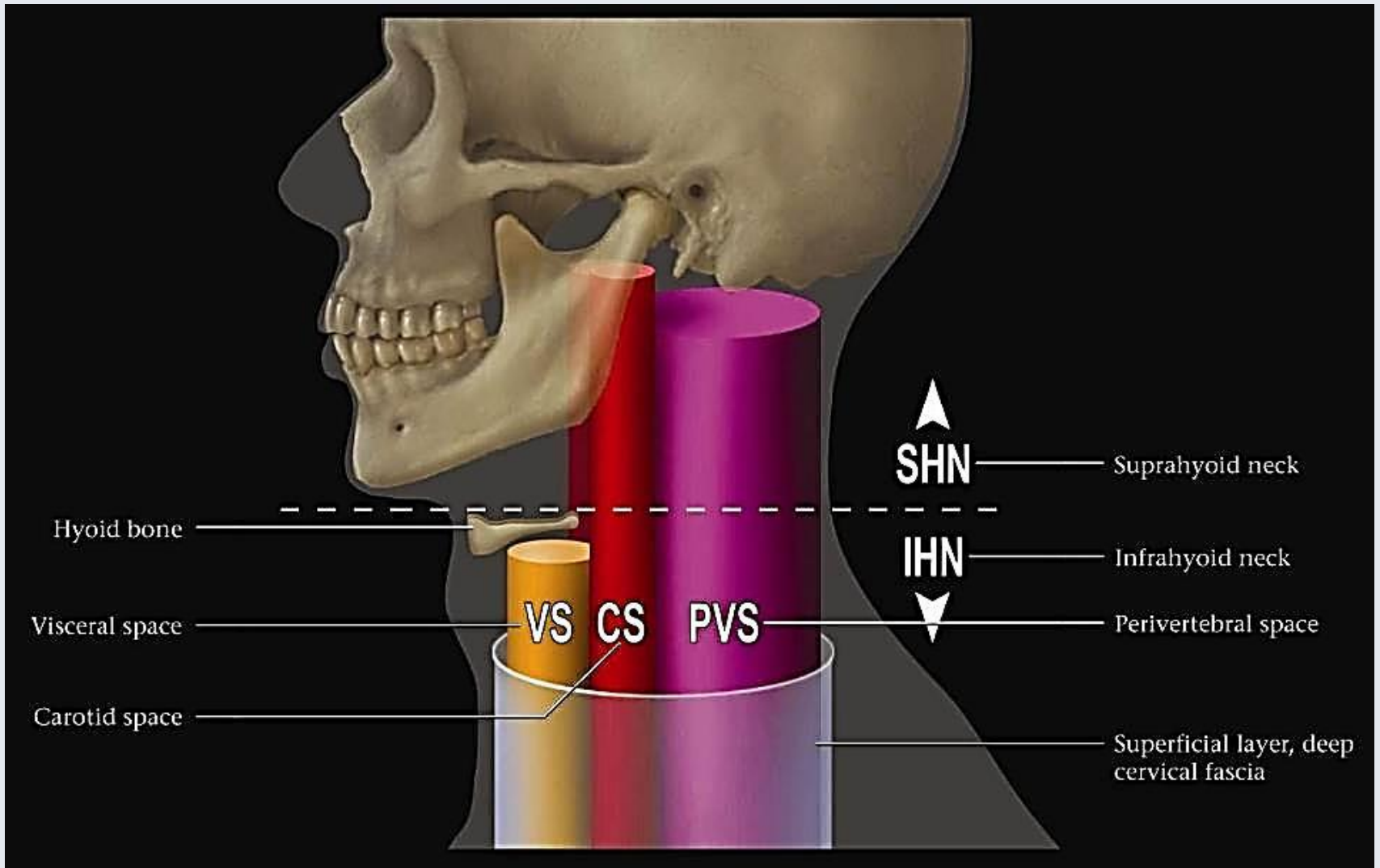
Lamina visceralis

Lamina visceralis

Lamina praevertebralis

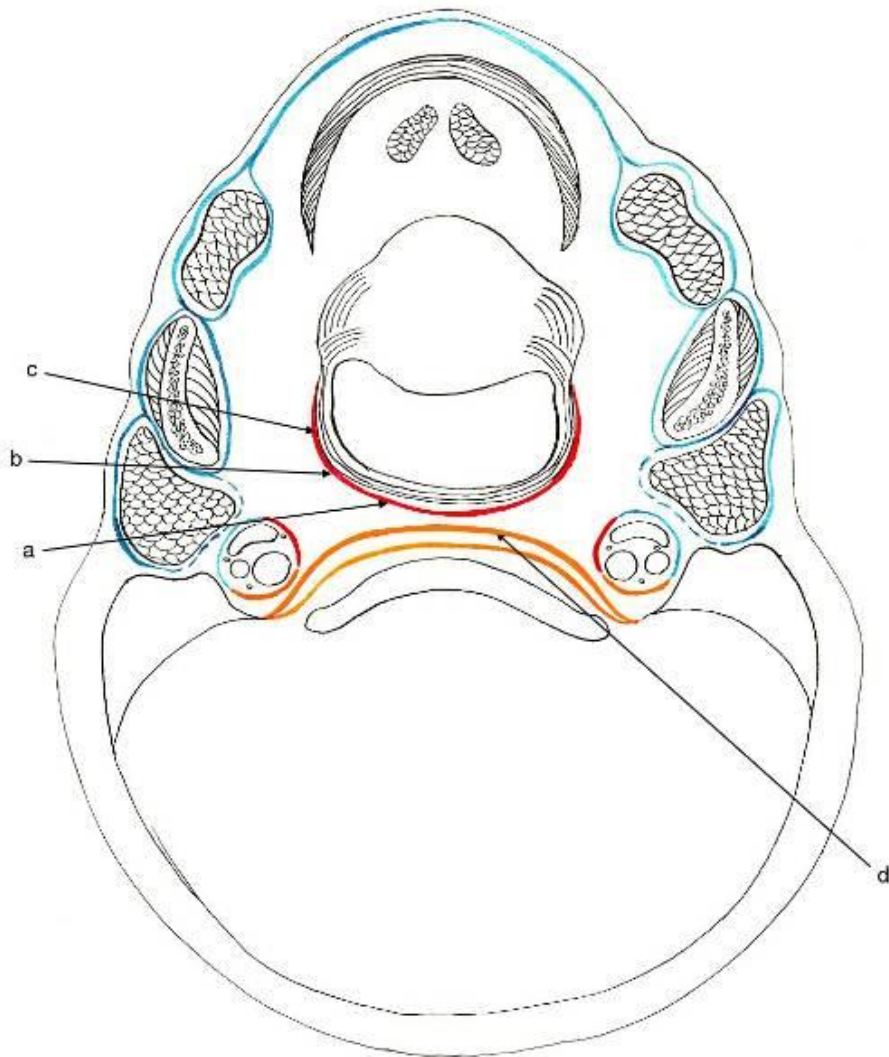


Dr. Magyar Péter



Dr. Magyar Péter

nyelvcsont felett

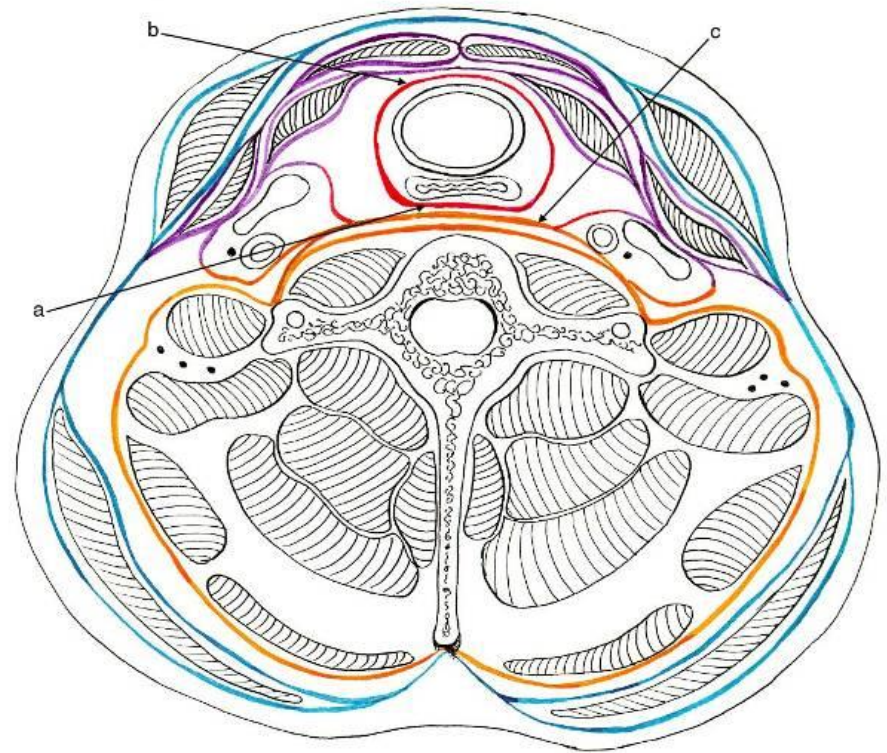


Deep Layers of Cervical Fascia

- Investing Layer
- Pharyngeal Layer
- Vertebral Layer
- d- Alar fascia

- a- Retropharyngeal
- b- Lateral pharyngeal
- c- Buccopharyngeal

nyelvcsont alatt

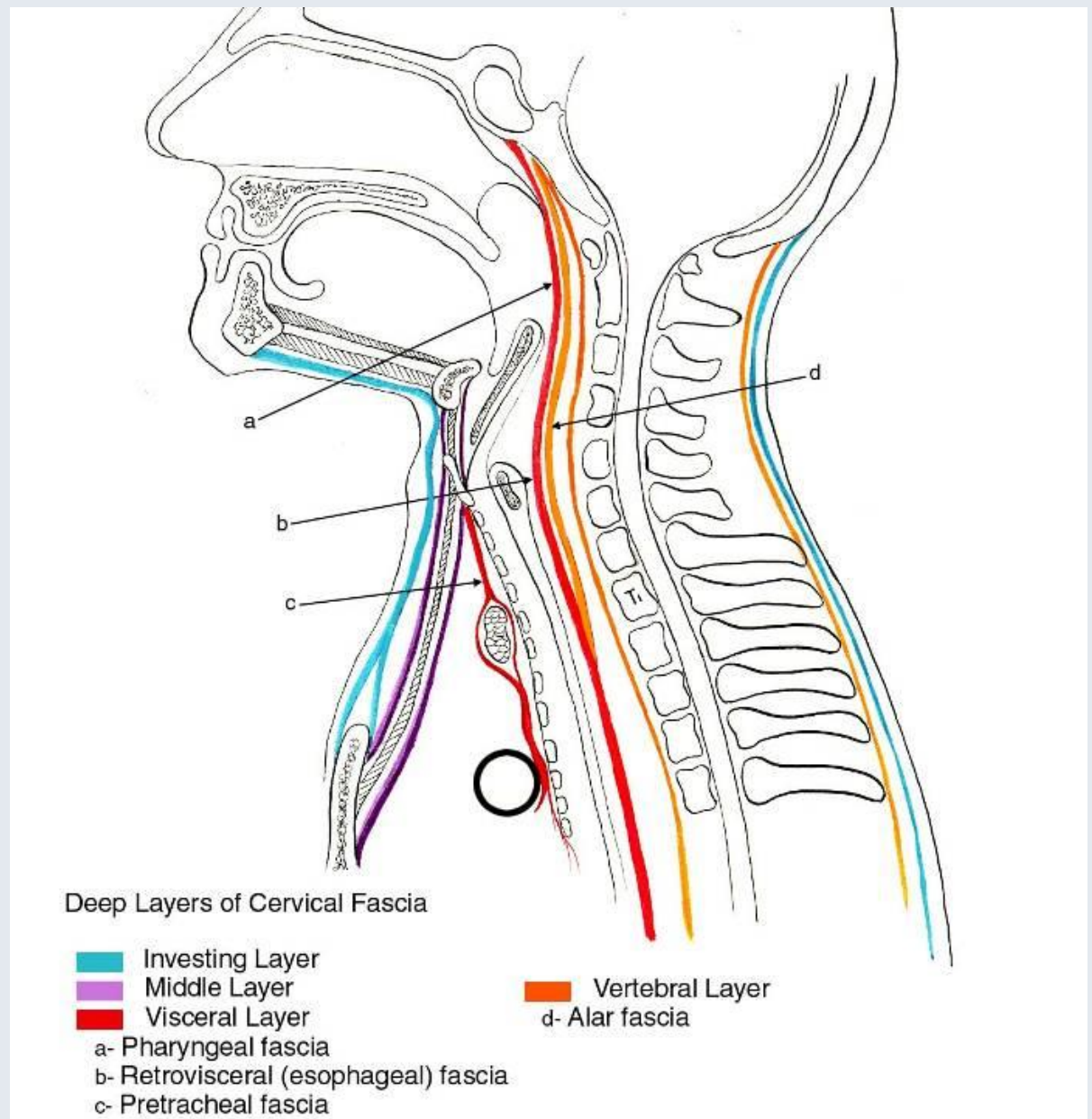


Deep Layers of Cervical Fascia

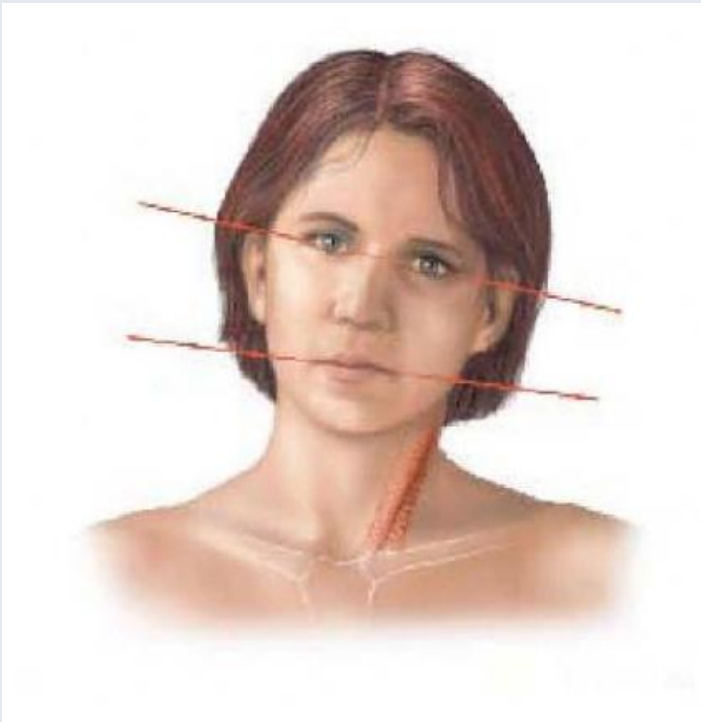
- Investing Layer
- Middle Layer
- Visceral Layer
- Vertebral Layer
- c- Alar fascia
- Carotid Sheath
- a- Retrovisceral (esophageal) fascia
- b- Pretracheal fascia

Dr. Magyar Péter

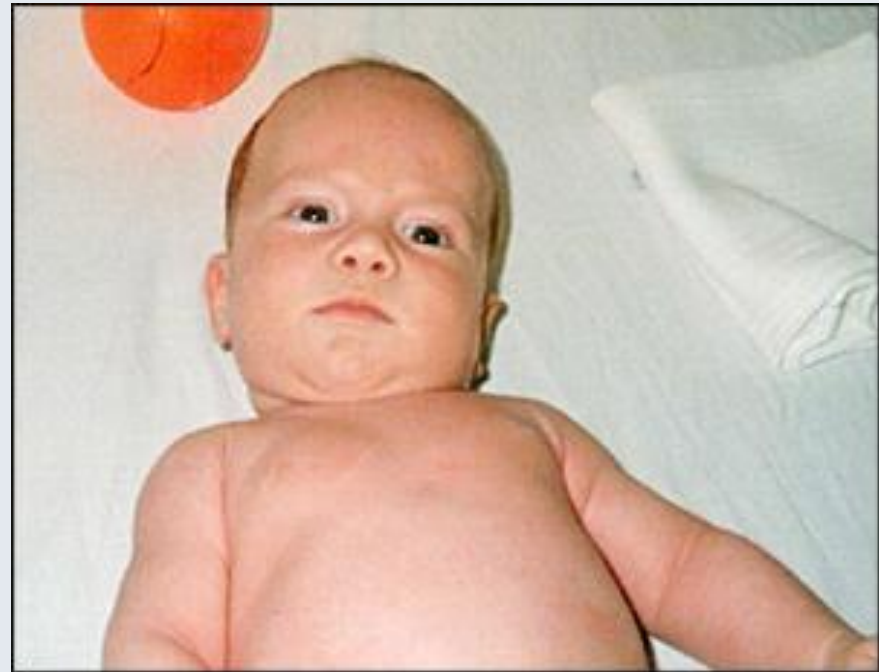- Lamina superficialis
- Lamina praetrachealis
(visceralis)
- Lamina visceralis
- Lamina praevertebralis



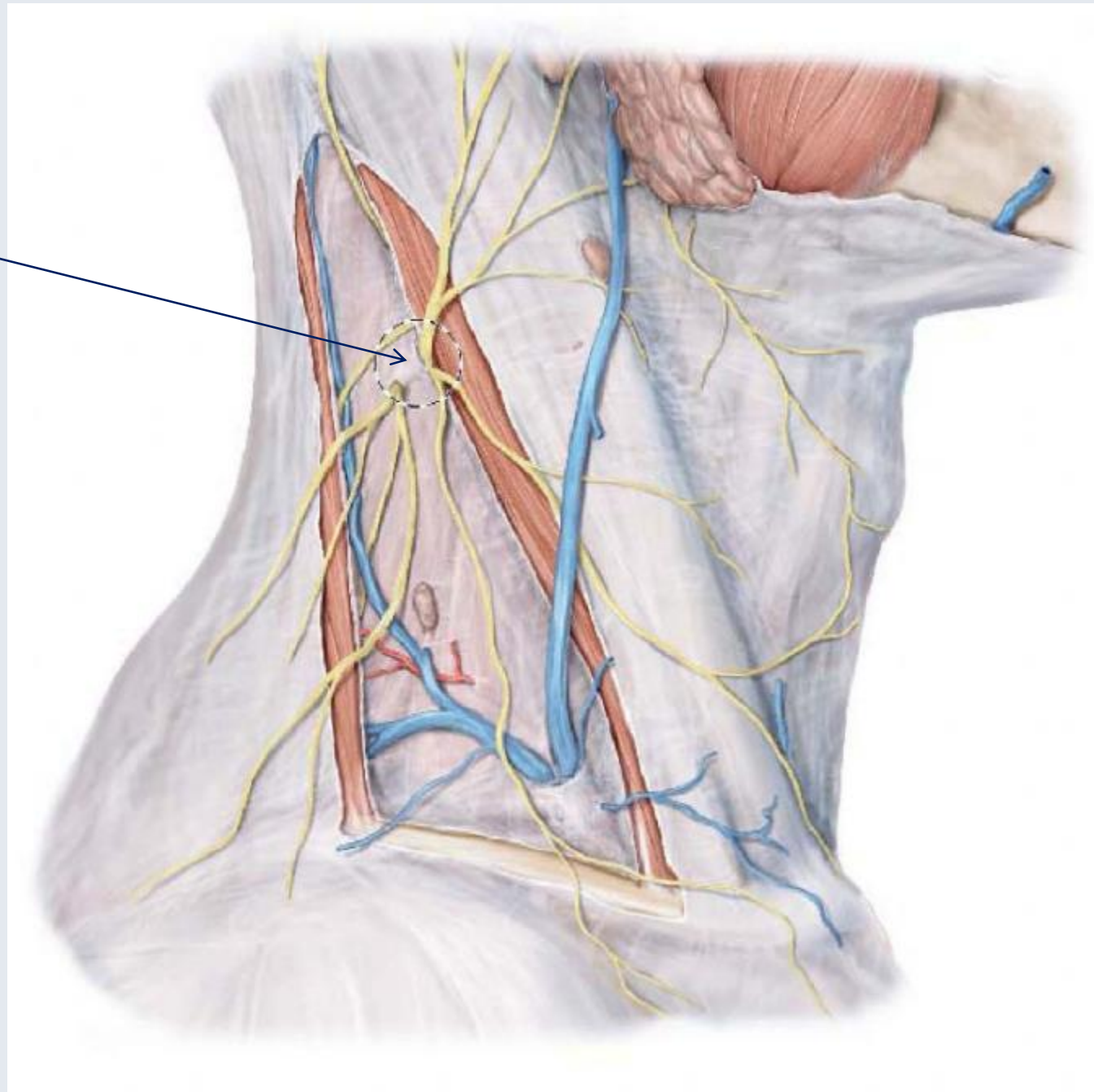
Klinikai vonatkozások



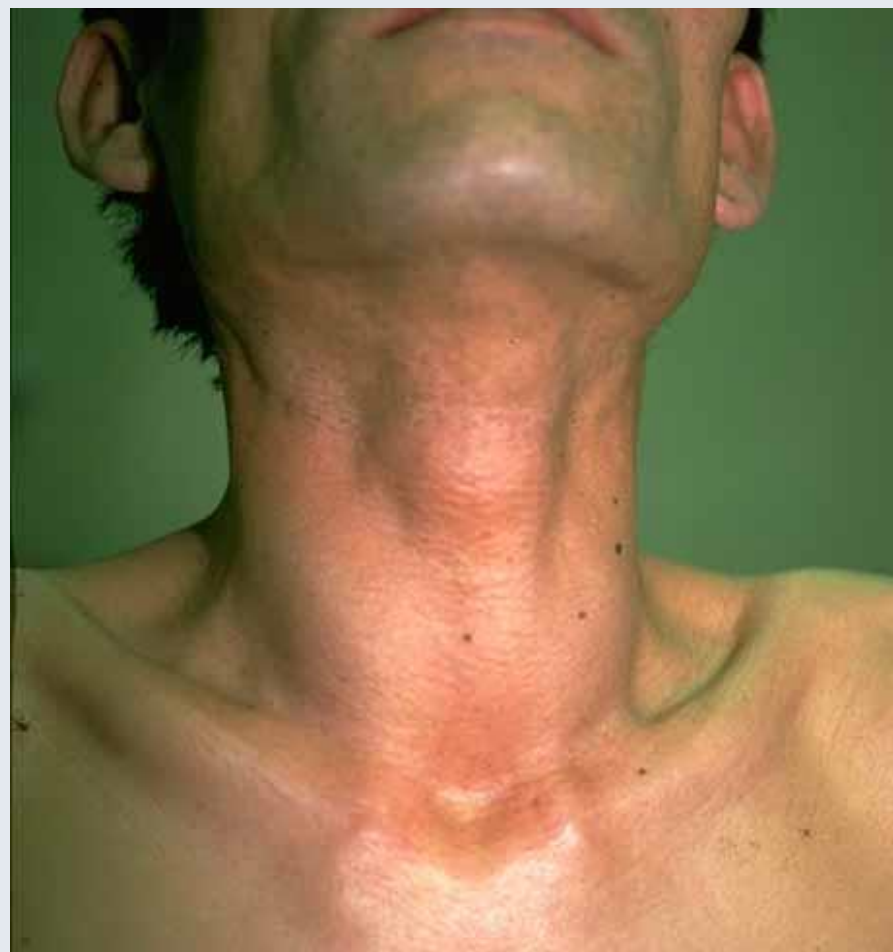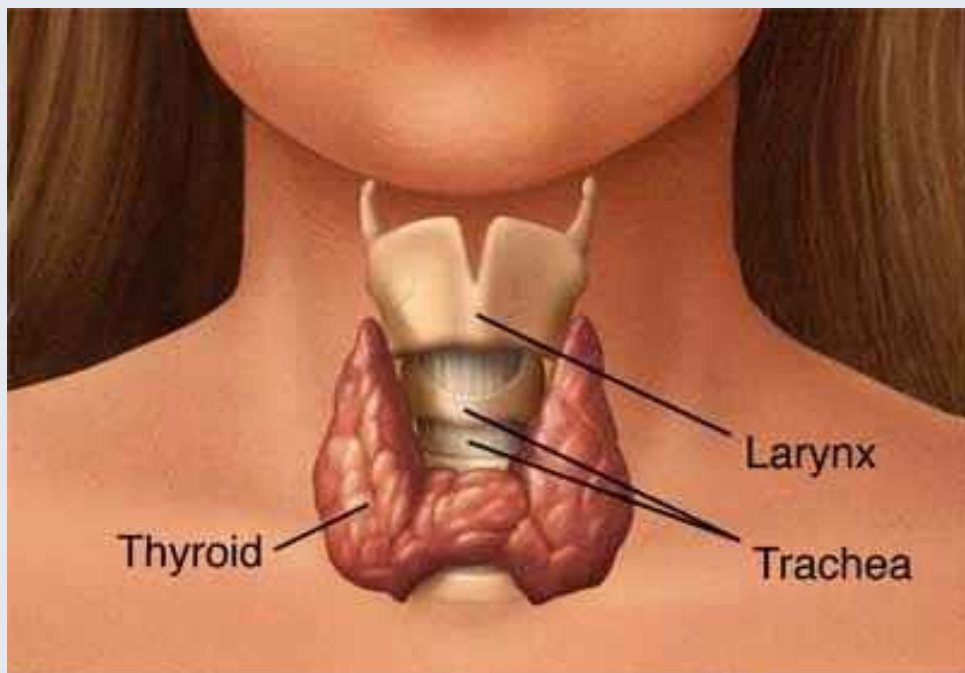
Torticollis

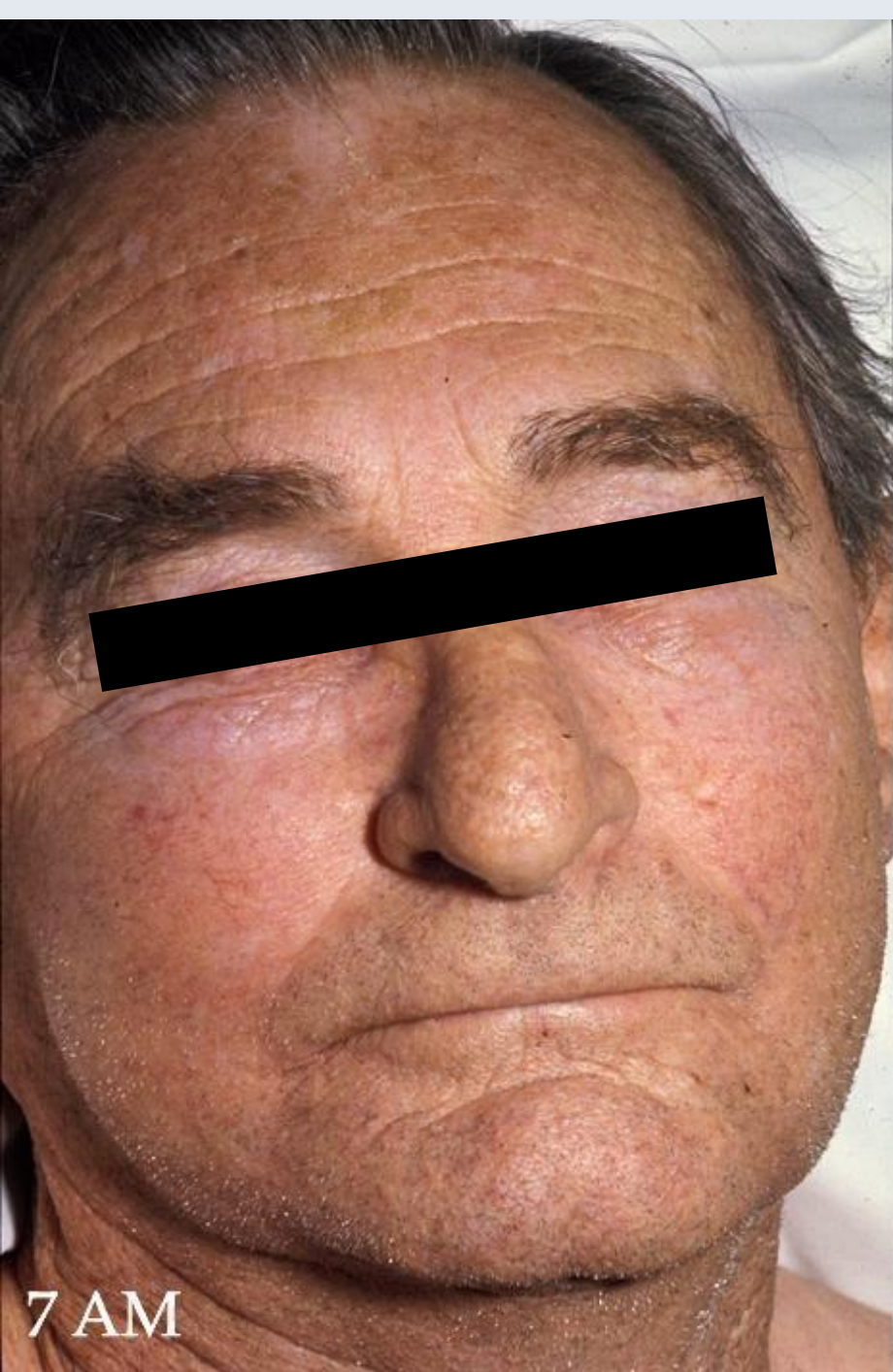


Erb-féle pont:
(punctum
nervosum)

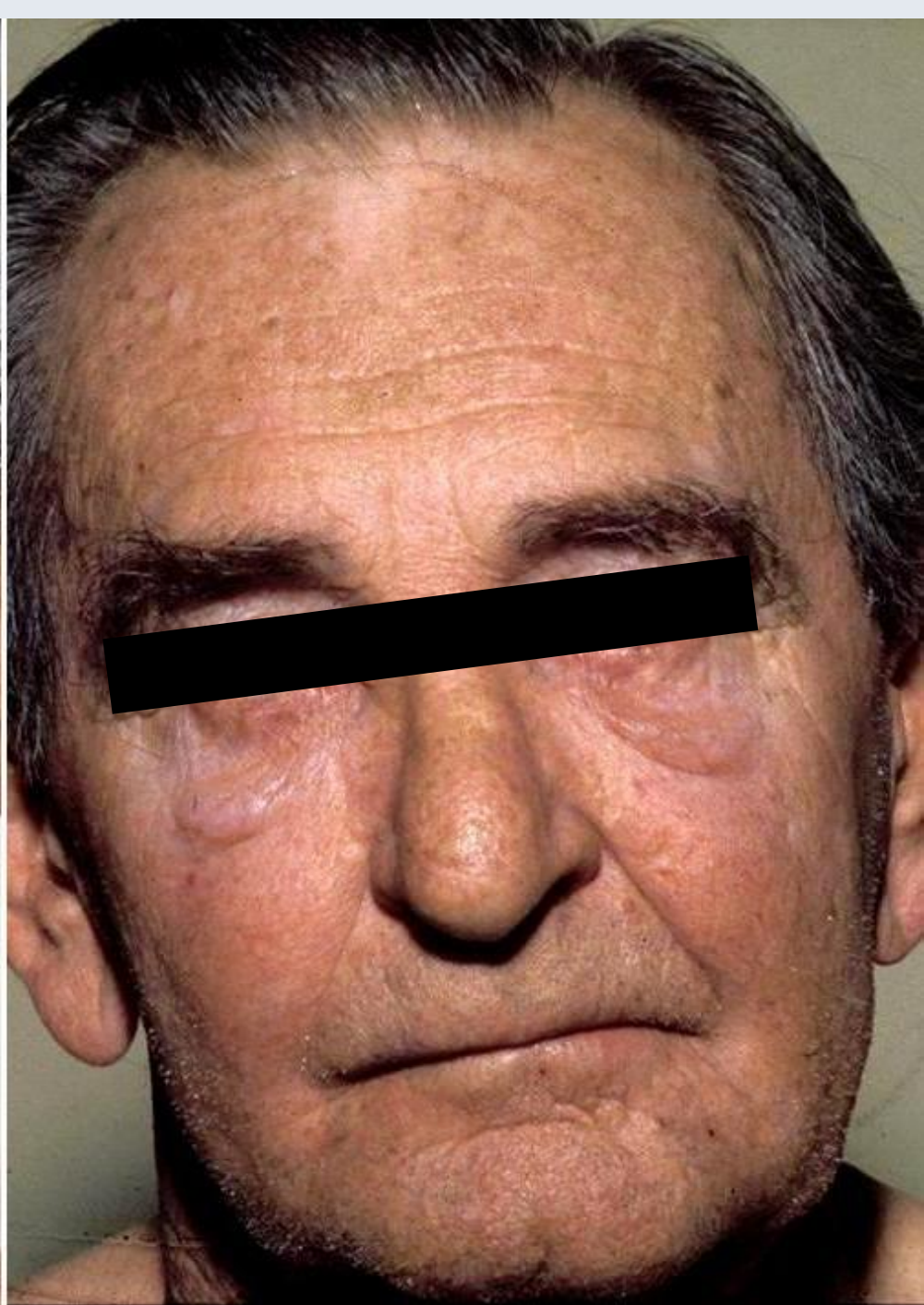


Strúma, golyva

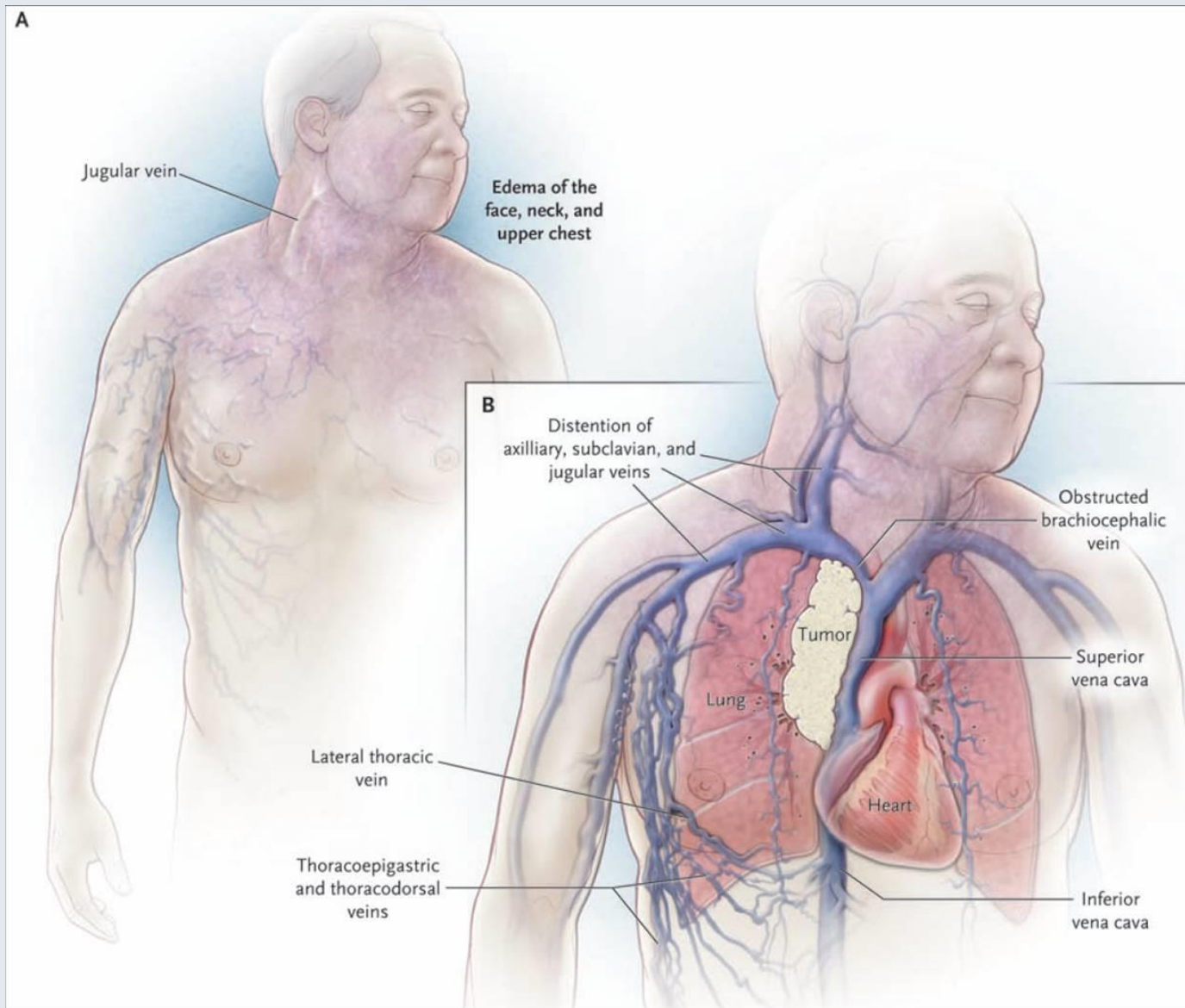




7 AM



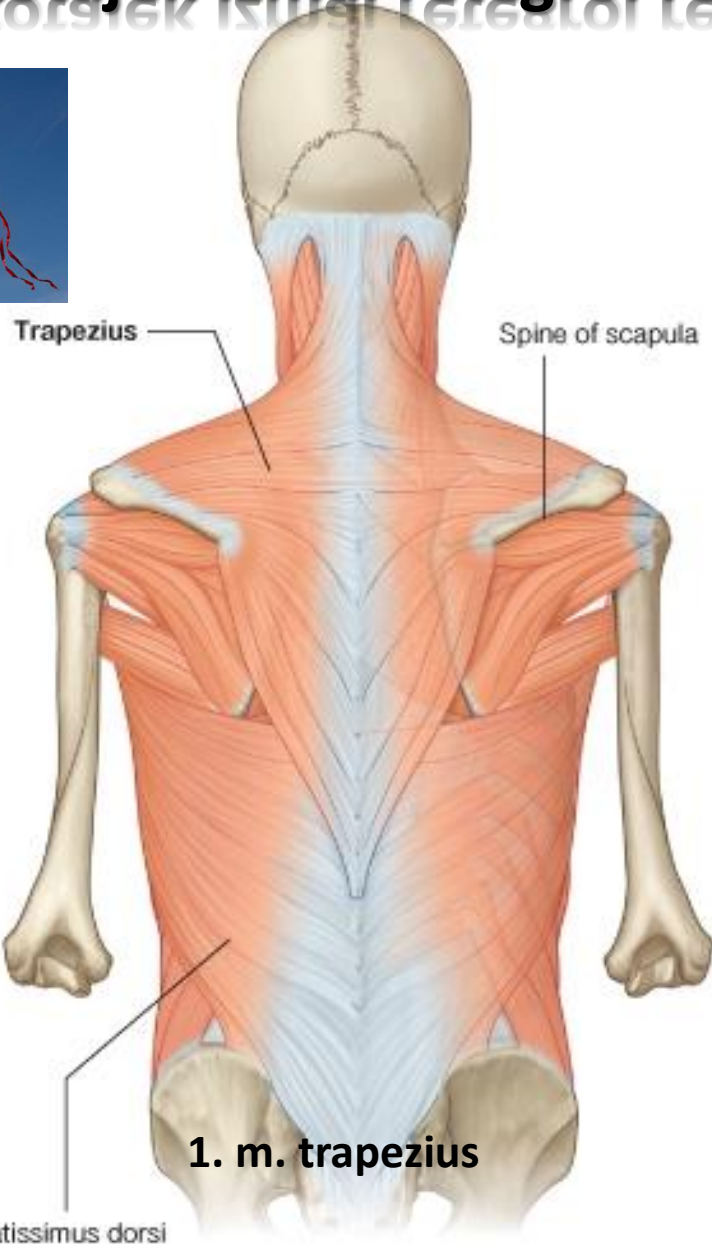
Vena cava superior szindroma, Stokes gallér



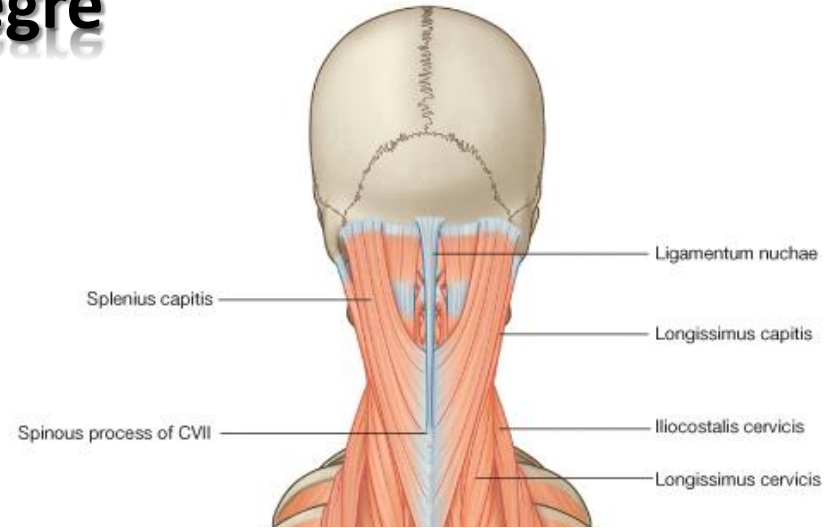
Tarkóizmok, hátizmok



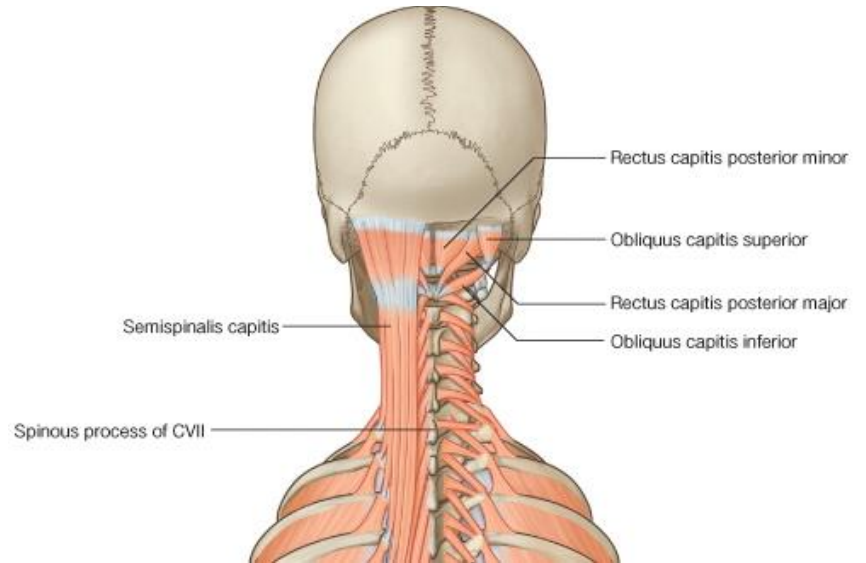
A tarkótájéék izmai rétegről rétegre



1. m. trapezius

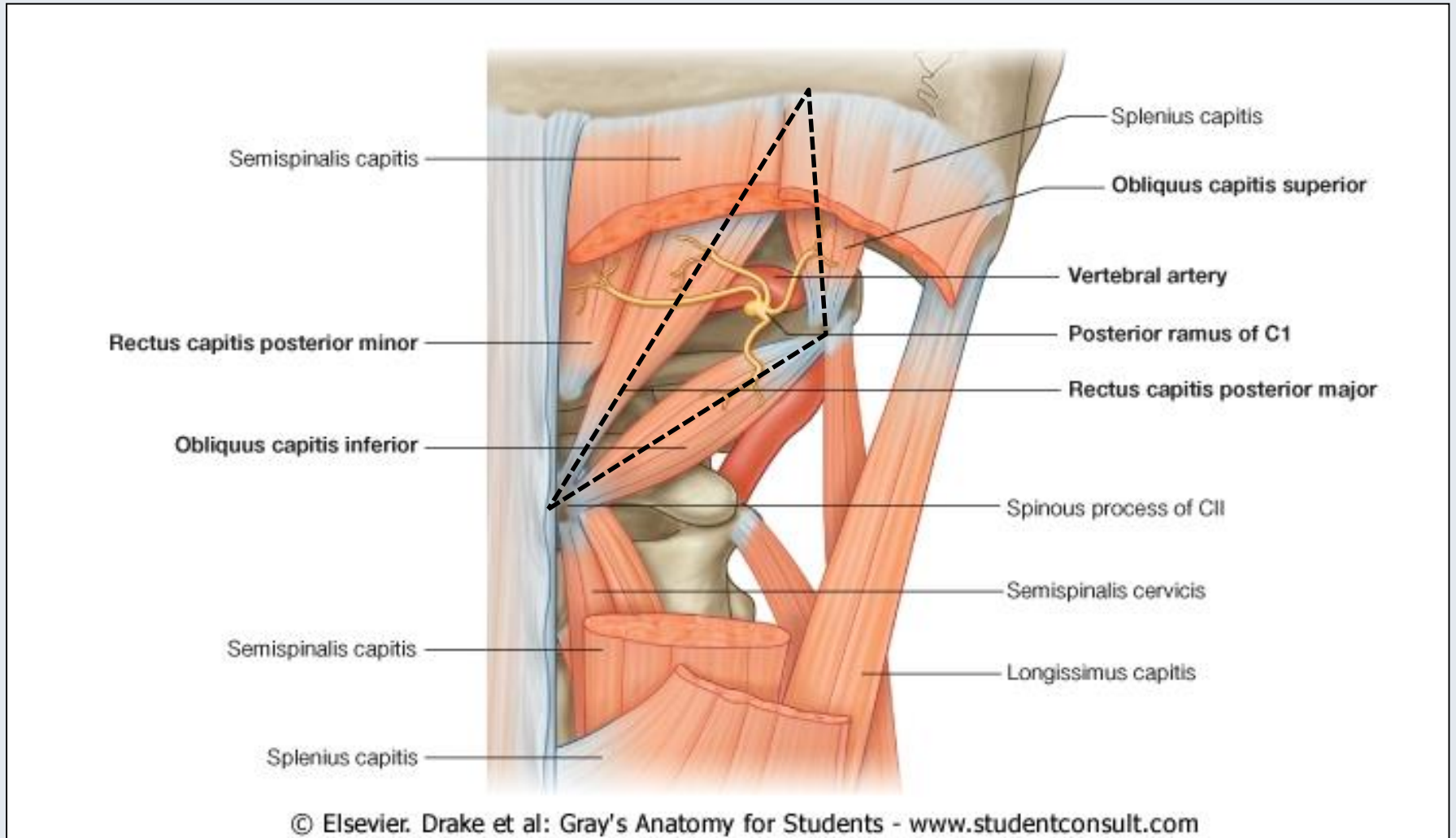


**2. m. splenius capitis és
m. longissimus capitis**



**3. m. semispinalis capitis
4. musculi suboccipitales**

4. Musculi suboccipitales



Trigonum suboccipitale: a. vertebralis, n. suboccipitalis

Átgondolni érdemes, bemagolni semmiképp!

Table 4.7. Principal Muscles Producing Movements of Atlanto-Occipital Joints

Flexion	Extension	Lateral Bending
Longus capitis Rectus capitis anterior Anterior fibers of sternocleidomastoid	Rectus capitis posterior major and minor Obliquus capitis superior Semispinalis capitis Splenius capitis Longissimus capitis Trapezius	Sternocleidomastoid Obliquus capitis superior Rectus capitis lateralis Longissimus capitis Splenius capitis

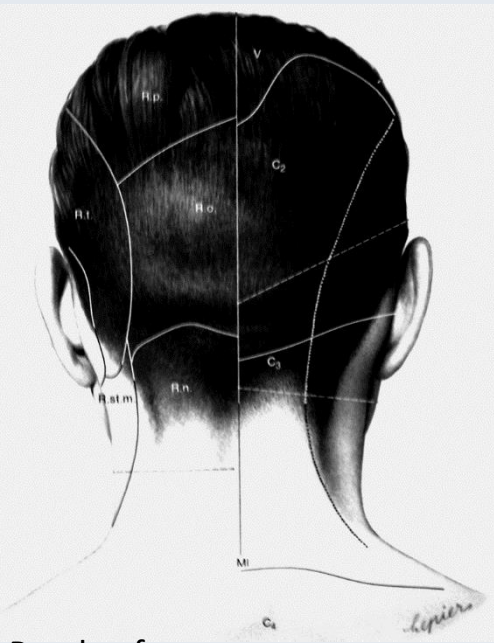
Table 4.8. Principal Muscles Producing Rotation at Atlantoaxial Joints^a

Ipsilateral ^b	Contralateral
Obliquus capitis inferior Rectus capitis posterior, major and minor Longissimus capitis Splenius capitis	Sternocleidomastoid Semispinalis capitis

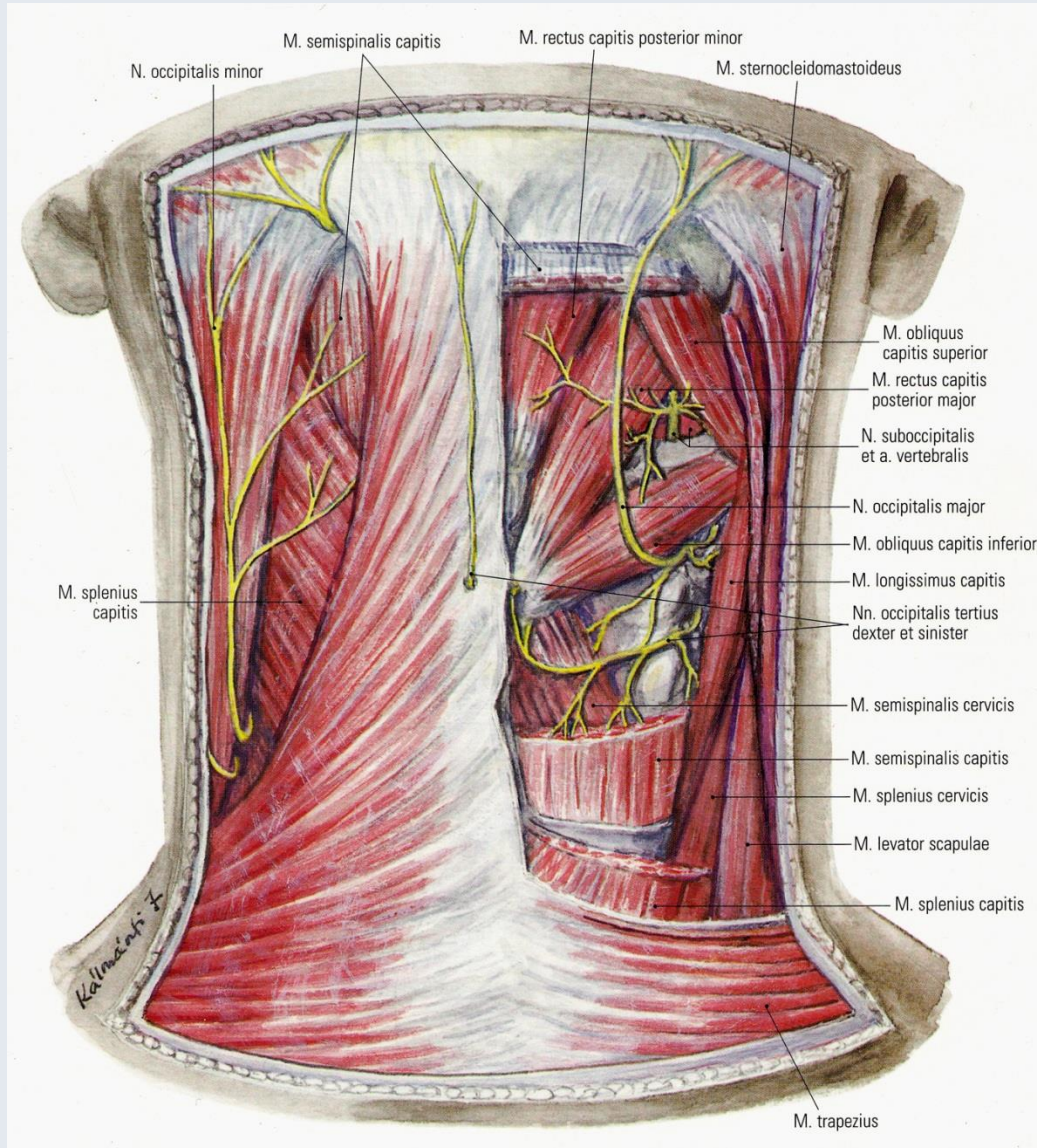
Table 4.5. Principal Muscles Producing Movements of Cervical Intervertebral Joints

Flexion	Extension	Lateral Bending	Rotation
Bilateral action of: Longus coli Scalene Sternocleidomastoid	Bilateral action of: Splenius capitis Semispinalis capitis and cervicis	Unilateral action of: Iliocostalis cervicis Longissimus capitis and cervicis Splenius capitis and cervicis	Unilateral action of: Rotatores Semispinalis capitis and cervicis Multifidus Splenius cervicis

Regio nuchalis

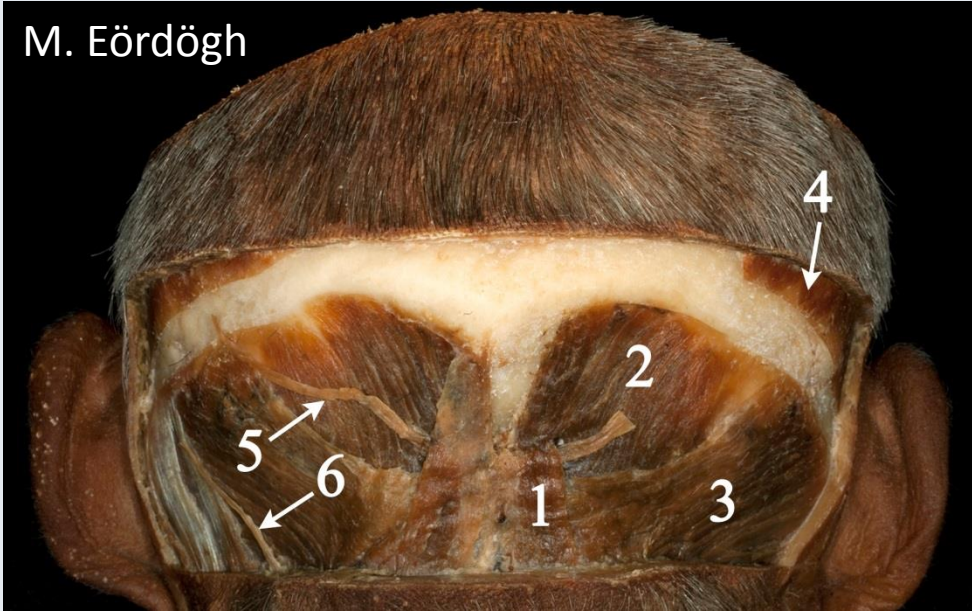


Pernkopf



Tömböl

M. Eördögh



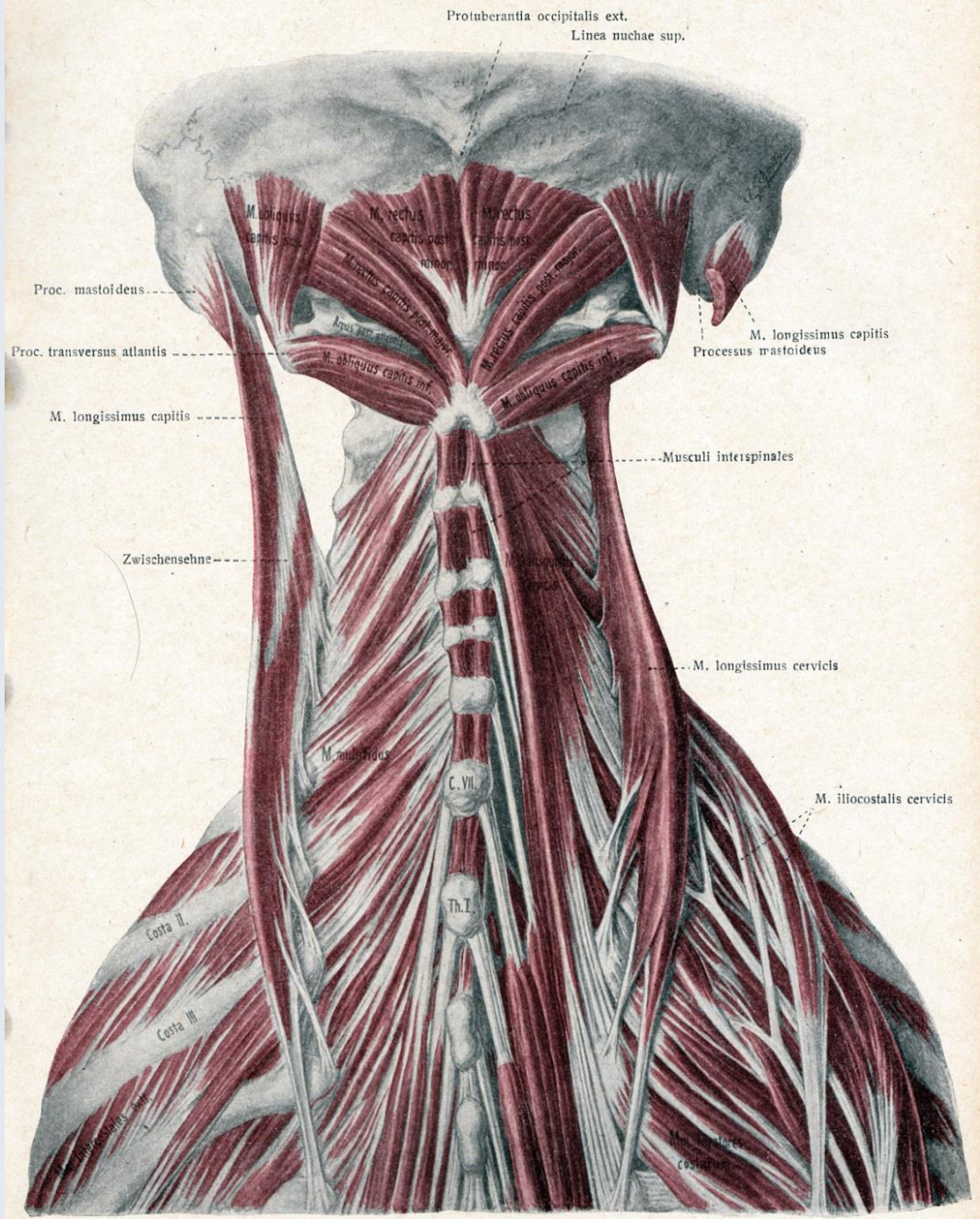
1. M. trapezius
2. M. semispinalis capitis
3. M. splenius capitis

5. N. occipitalis major (C2)
6. N. occipitalis tertius (C3)

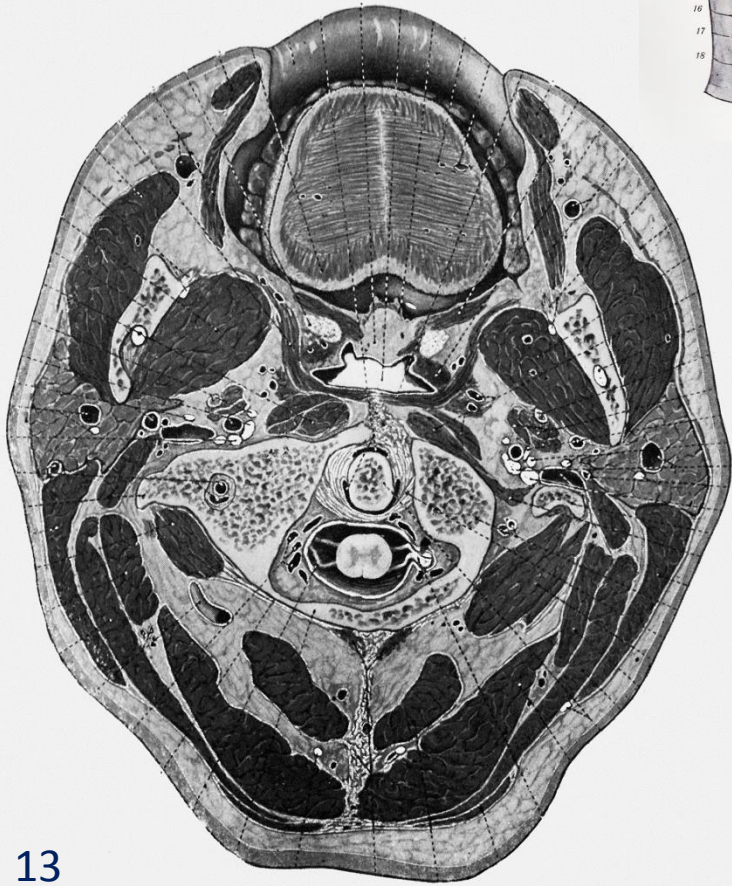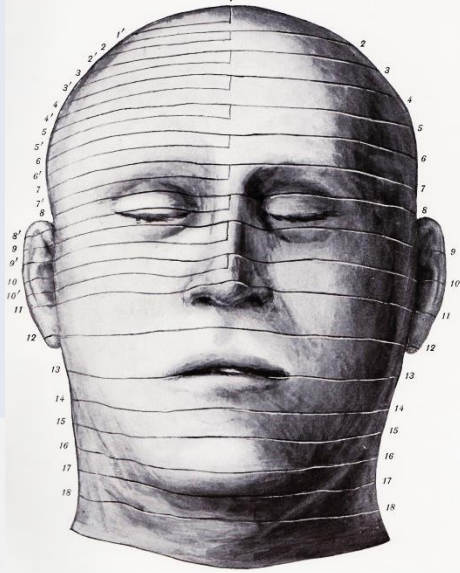


1. Lig. nuchae
2. A. occipitalis
3. M. longissimus capitis

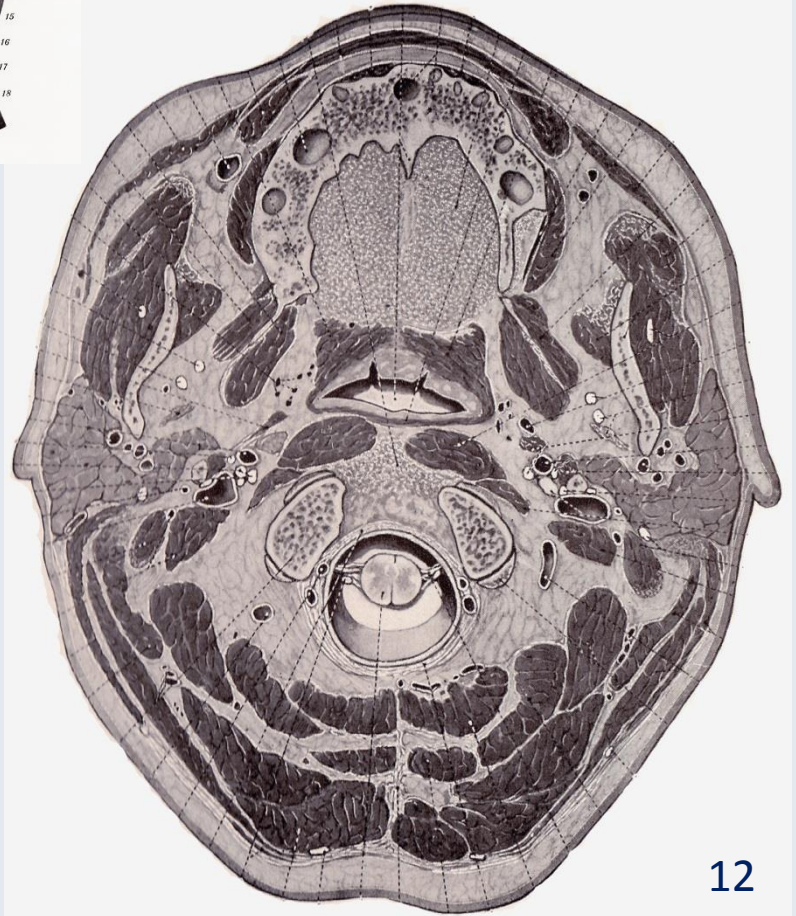M. Eördögh



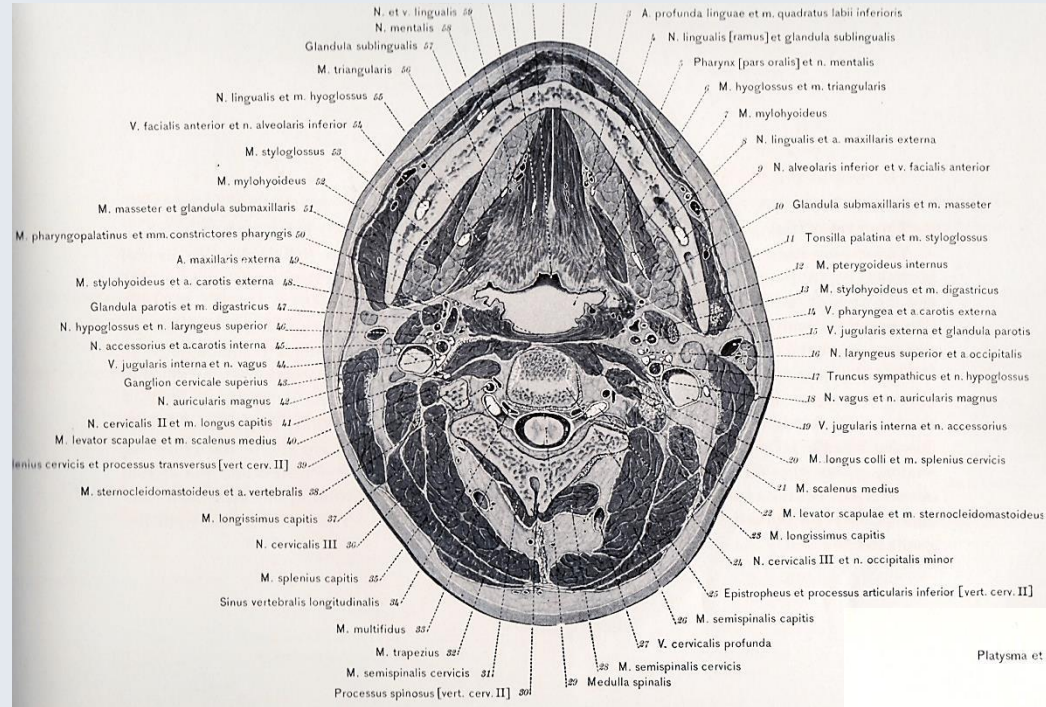
Rauber-Kopsch



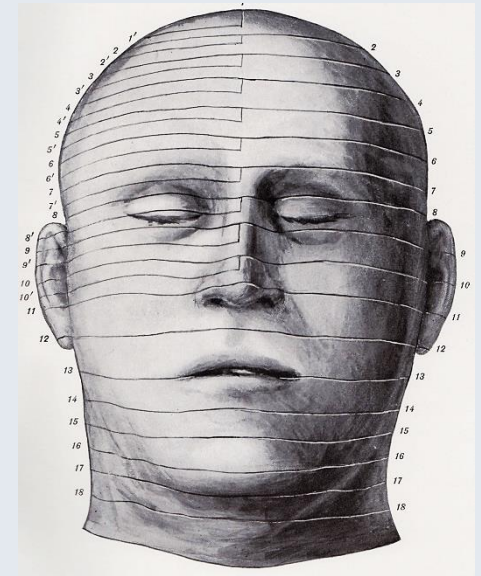
13



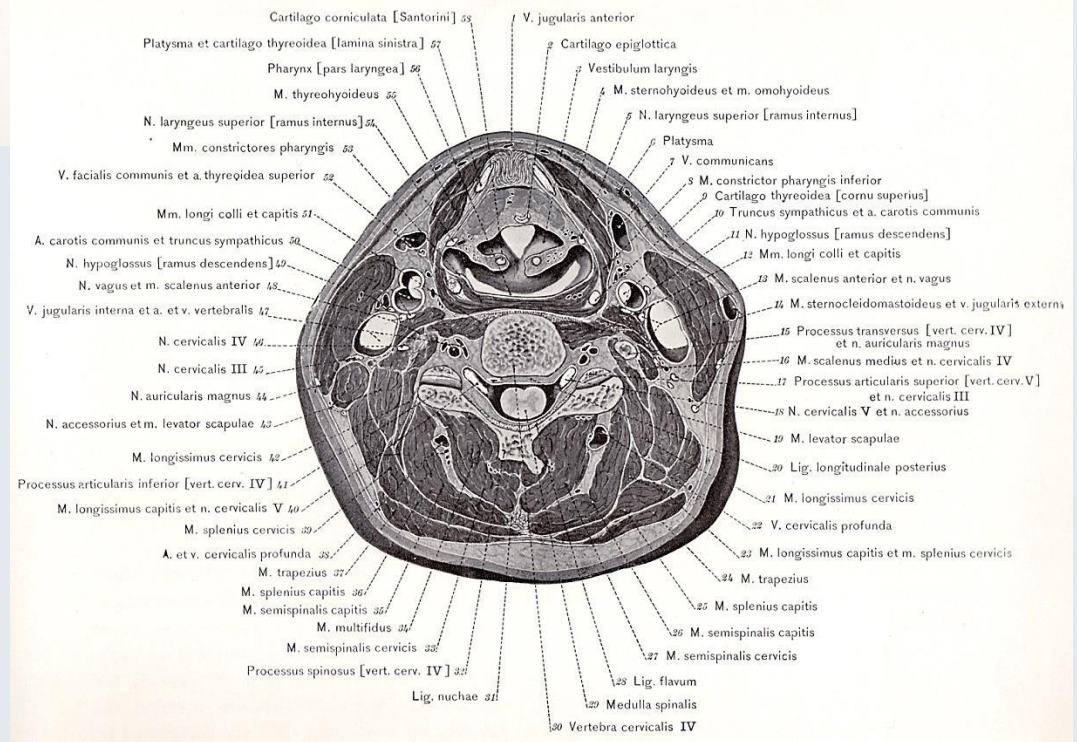
12



SECTION 15

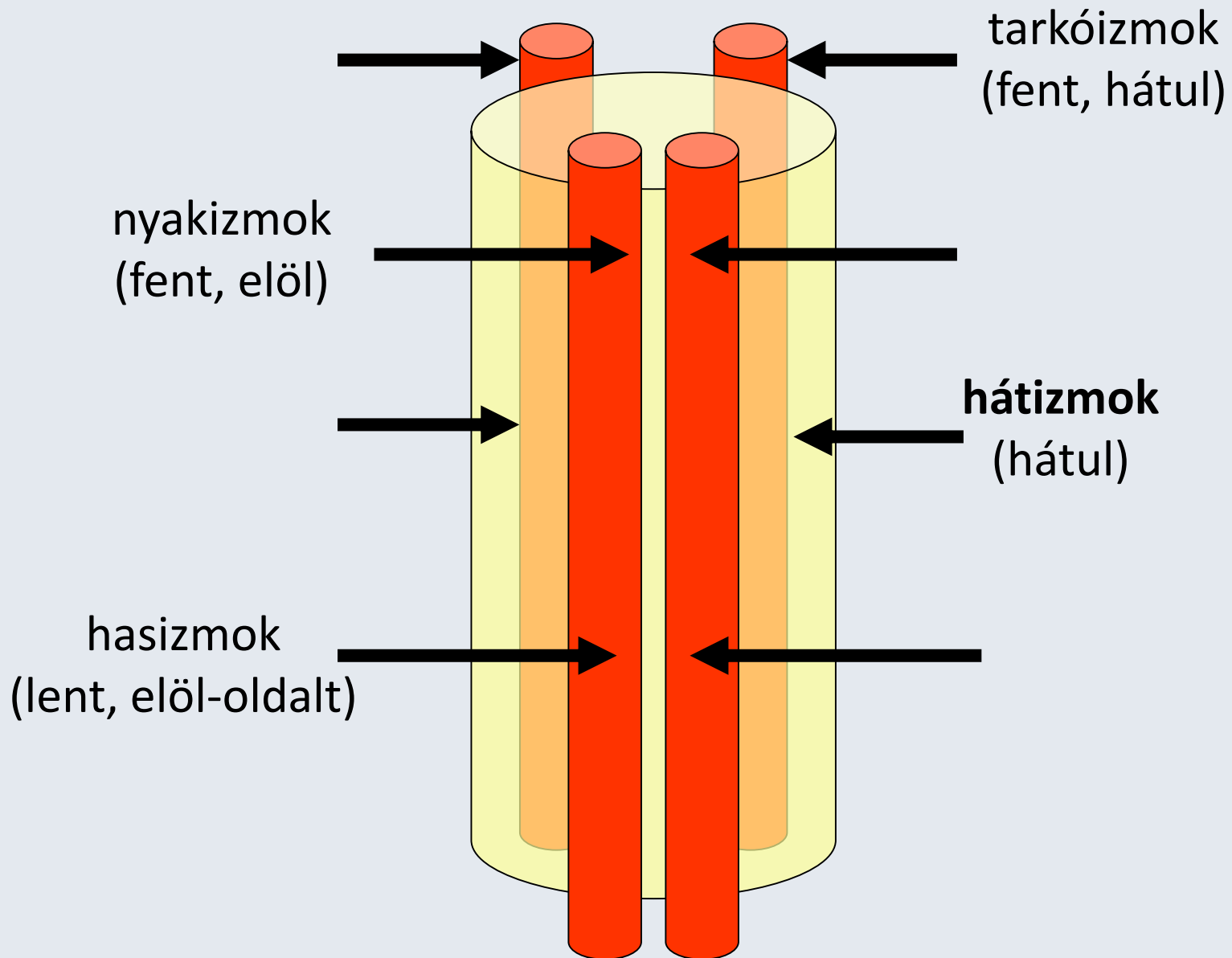


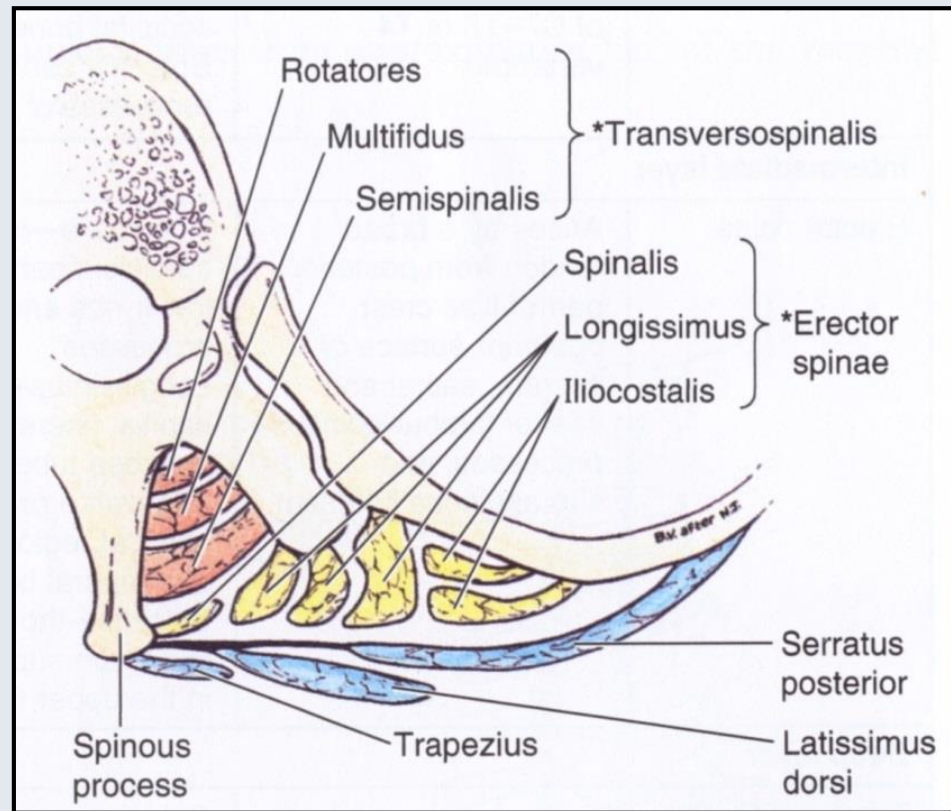
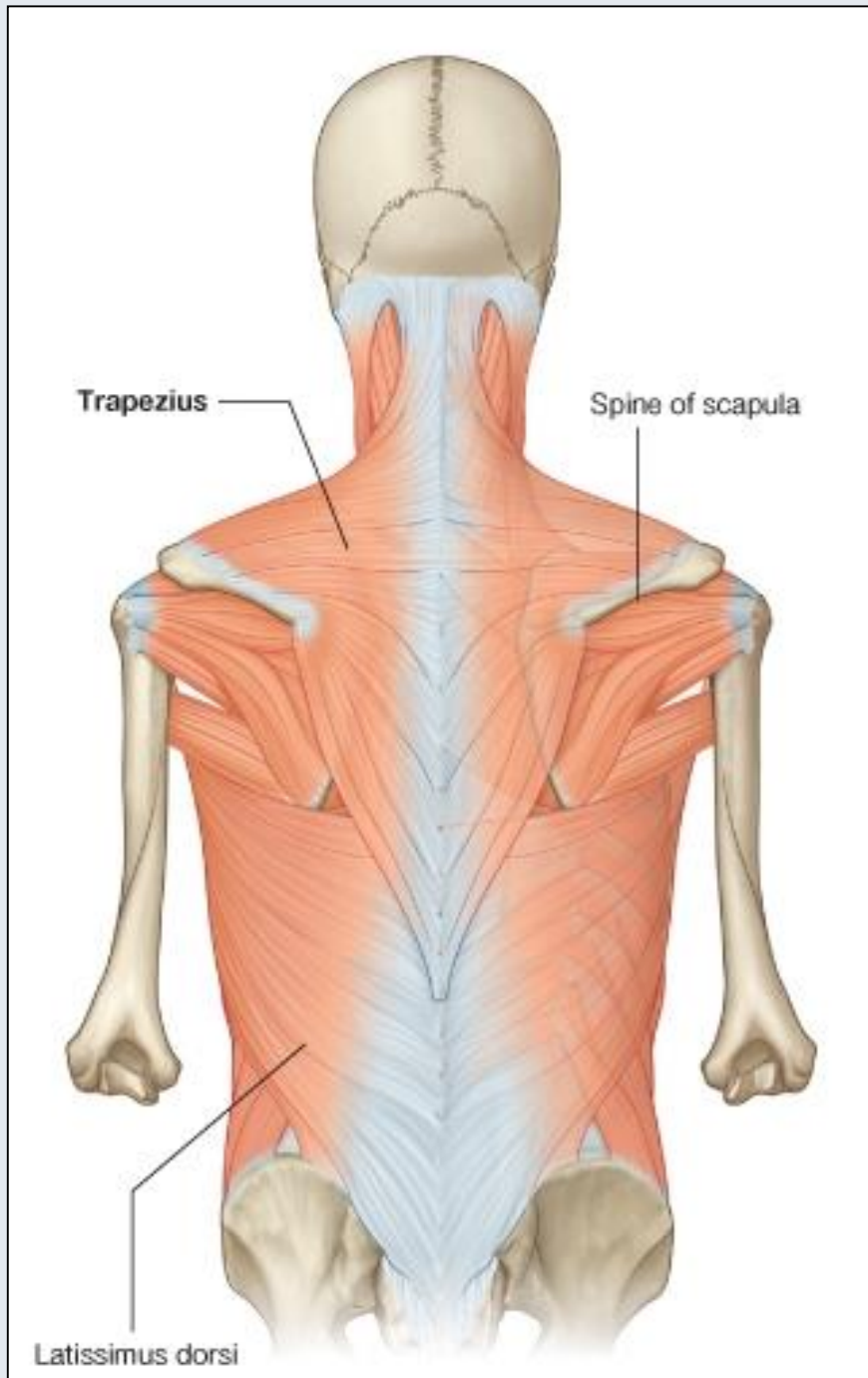
Eycleshymer & Schoemaker



SECTION 18

A hátizmok

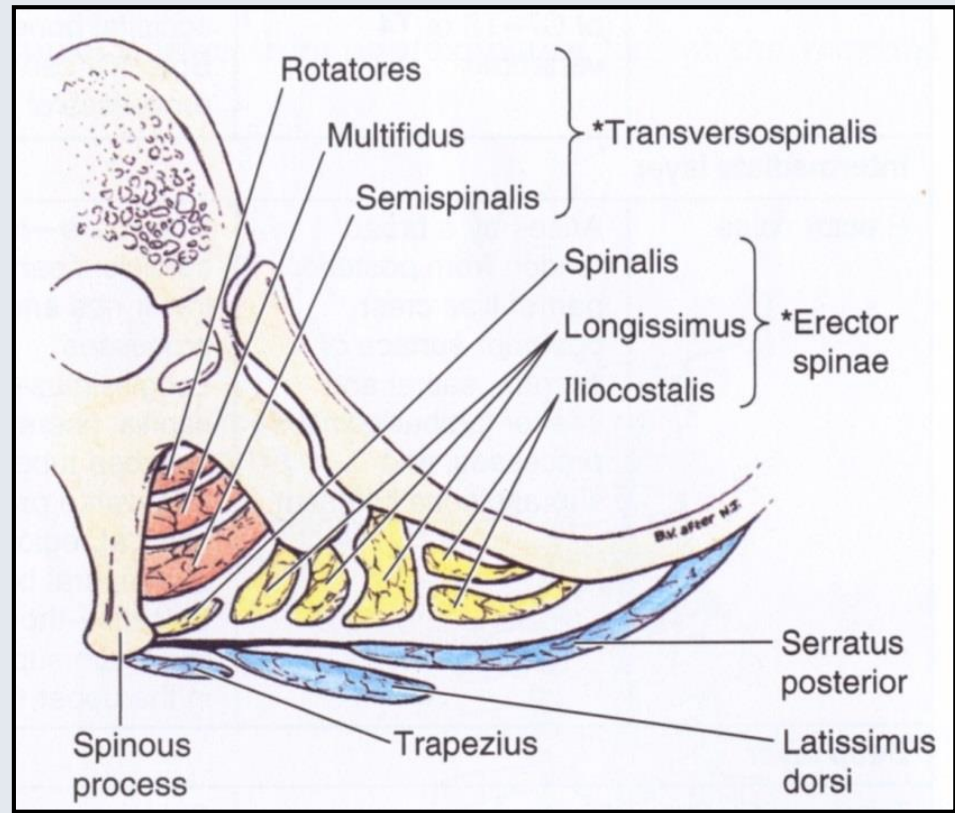
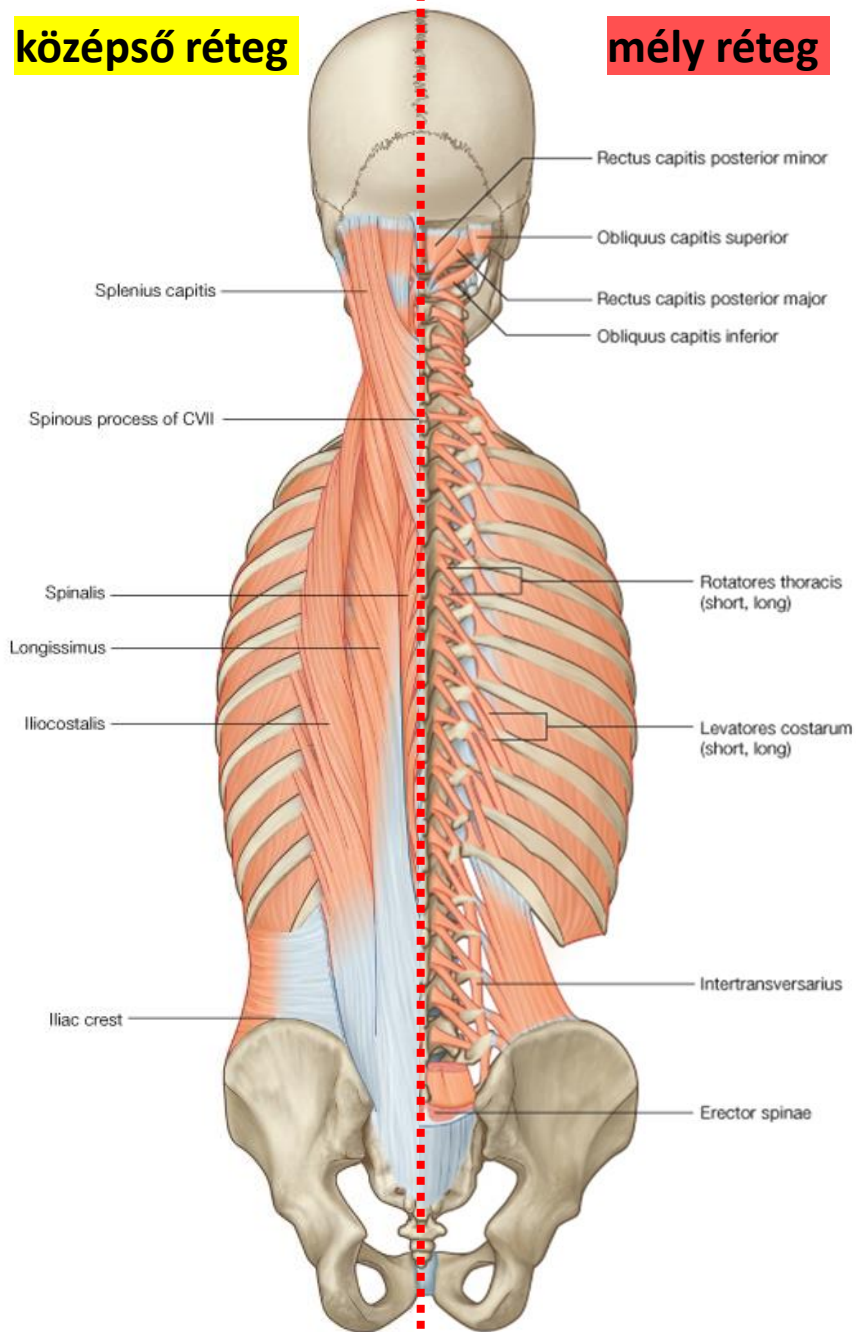




A **felületes hátizmok** a gerincoszlopról (is) erednek, de elsősorban a vállöv vagy a felső végtag valamely csontján tapadnak, így elsősorban azokat mozgatják (m. latissimus dorsi, m. serratus posterior), de a m. trapezius felső része a nyaki gerinc és a fej mozgatásában is szerepet játszik.

középső réteg

mély réteg



A **mély hátizmok** a tövis-nyúlványok és a harántnyúlványok/bordák közötti szögletet töltik ki. **Középső rétegüket** m. erector spinae-ként foglaljuk össze, de ezen belül mediolateralis irányban három izom is elkülönül. A **mély réteg** kisebb izmai inkább rotációs mozgást tudnak a gerincben megvalósítani.

Literatur und Quellarbeiten

Adolf Faller: Anatomie in Stichworten

Alfred Benninghoff: Lehrbuch der Anatomie des Menschen

Eduard Pernkopf: Atlas of topographic and applied human anatomy

Eycleshymer& Schoemaker: A cross – section anatomy

Rauber-Kopsch: Lehrbuch der Anatomie des Menschen

Szél Ágoston: Klinikai Anatómia

Tömböl Teréz: Tájanatómia

Vorlesung von Dr. Péter Magyar

Präparate:

Márton Eördögh

Mátyás Ilyés

www.orvosilexikon.hu

www.csontmester.hu

www.radgray.com