


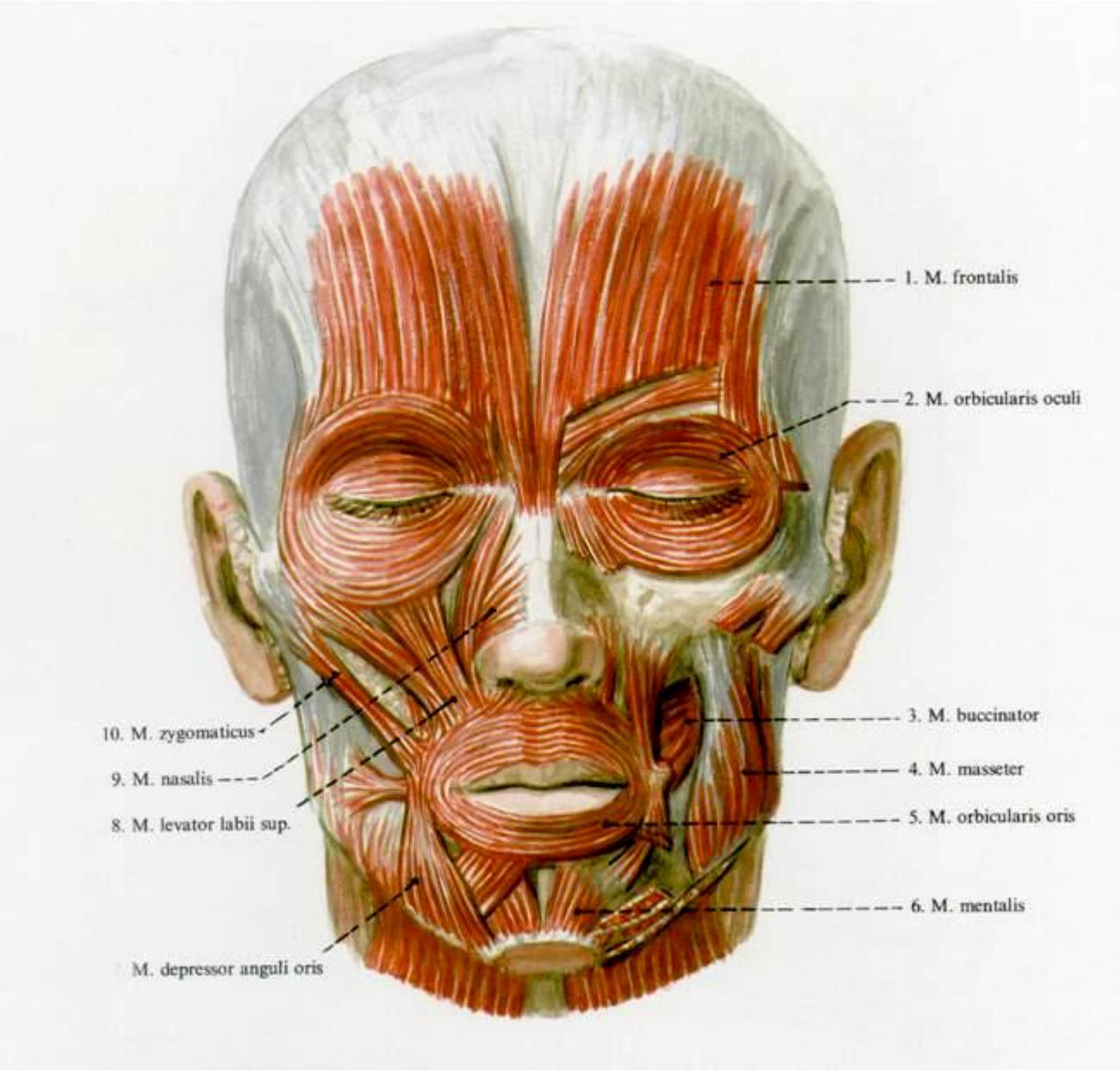


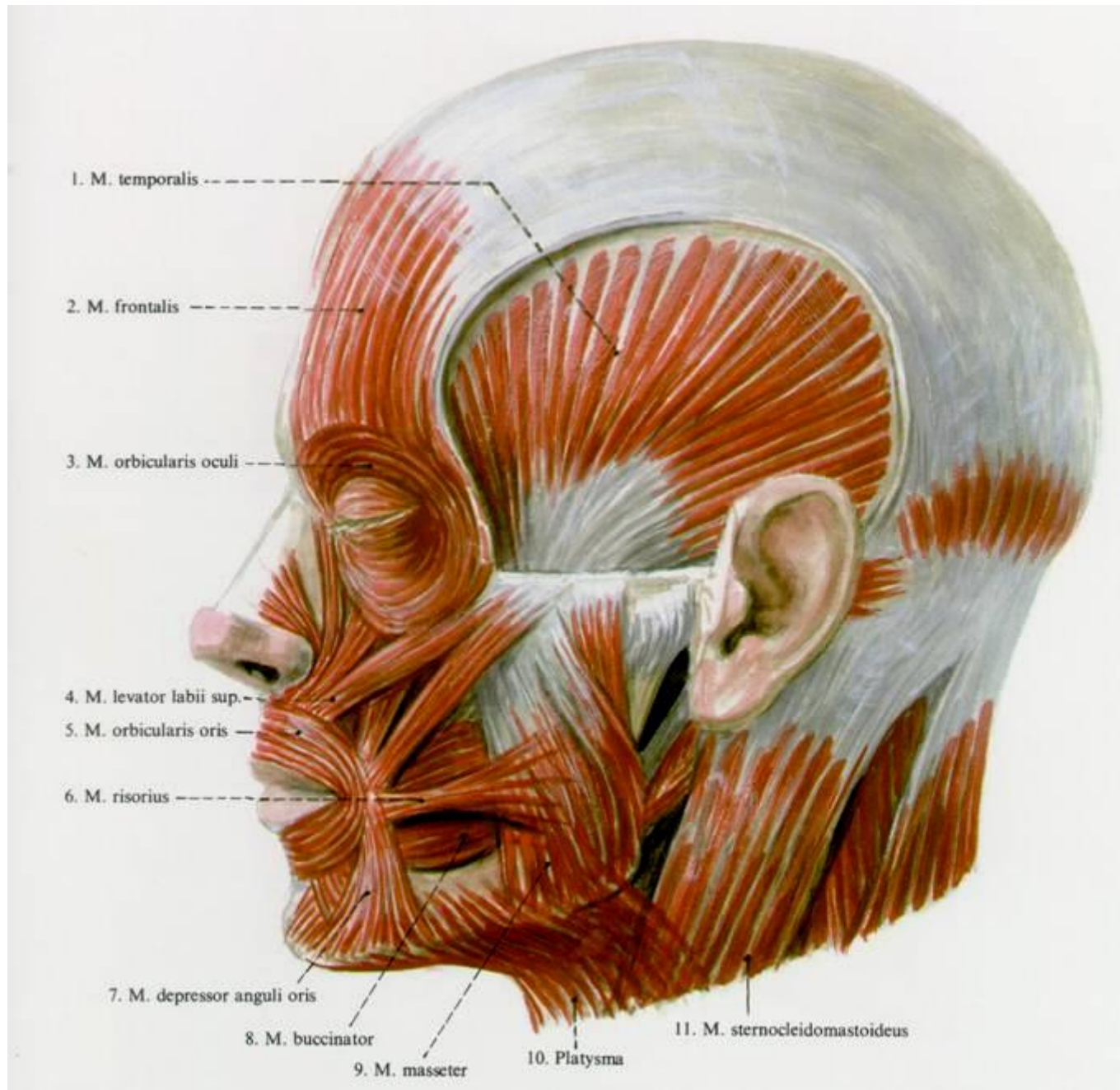
Mimikai izmok

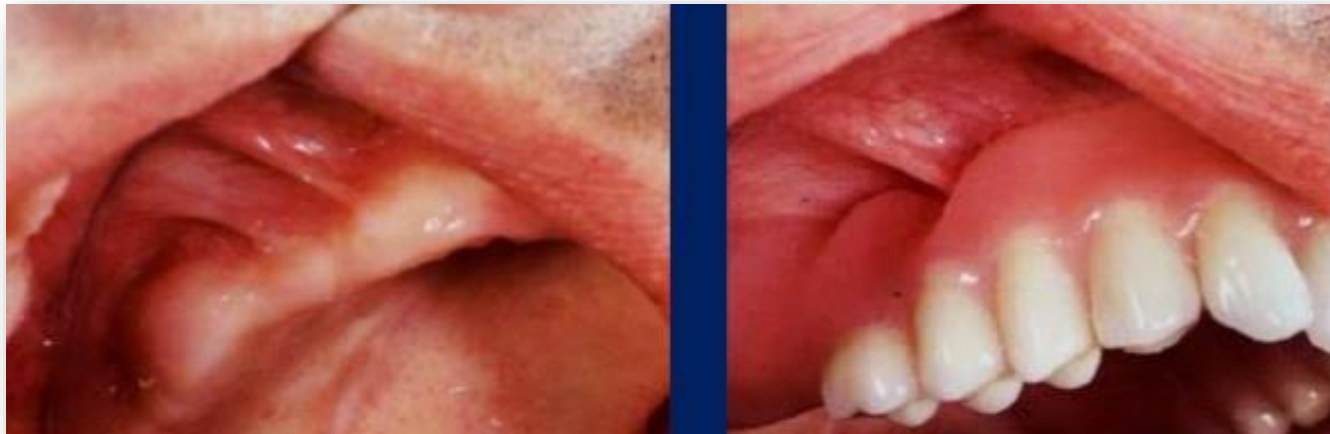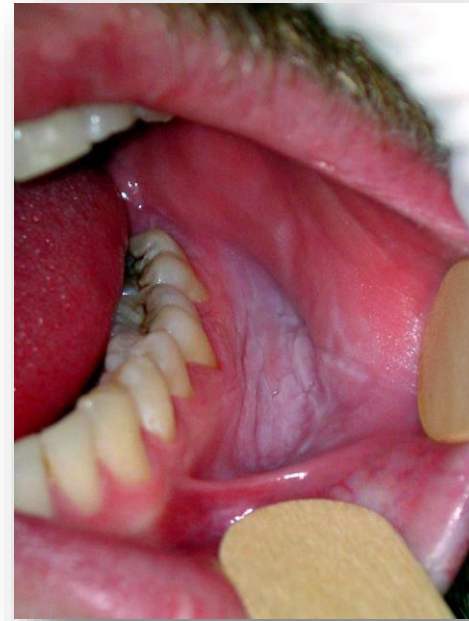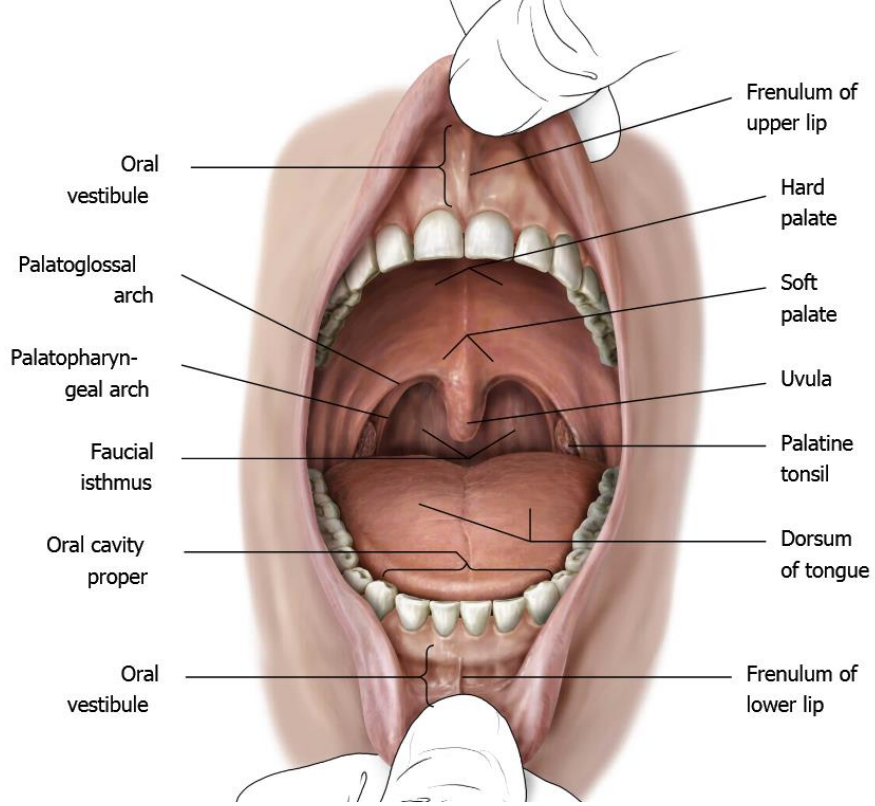


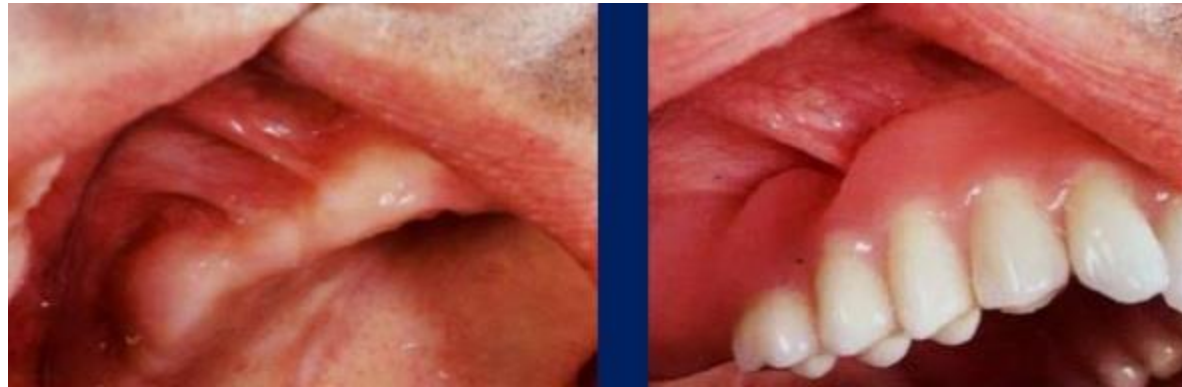Dr. Gerber Gábor

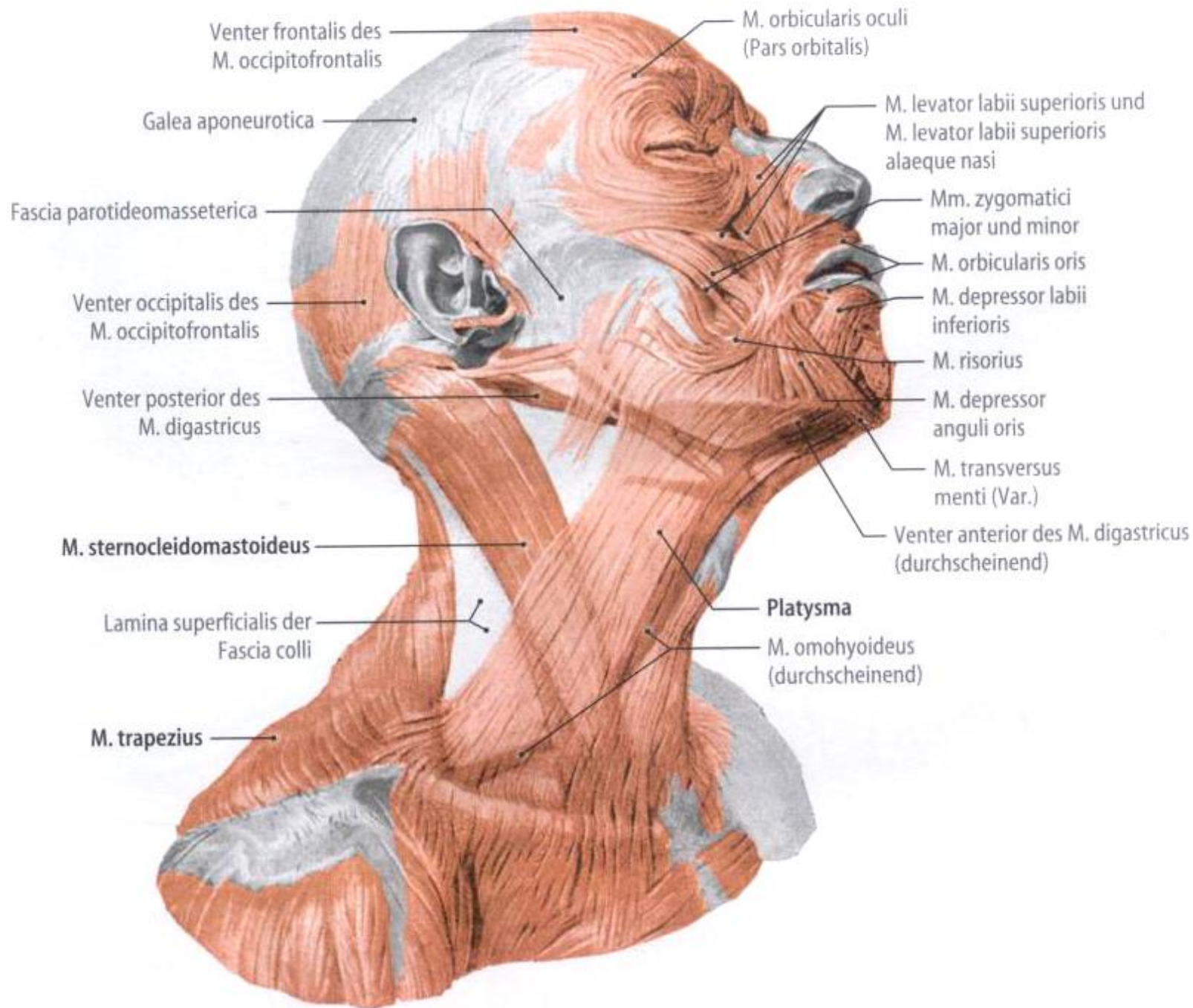


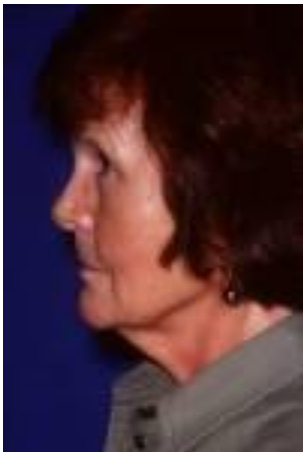

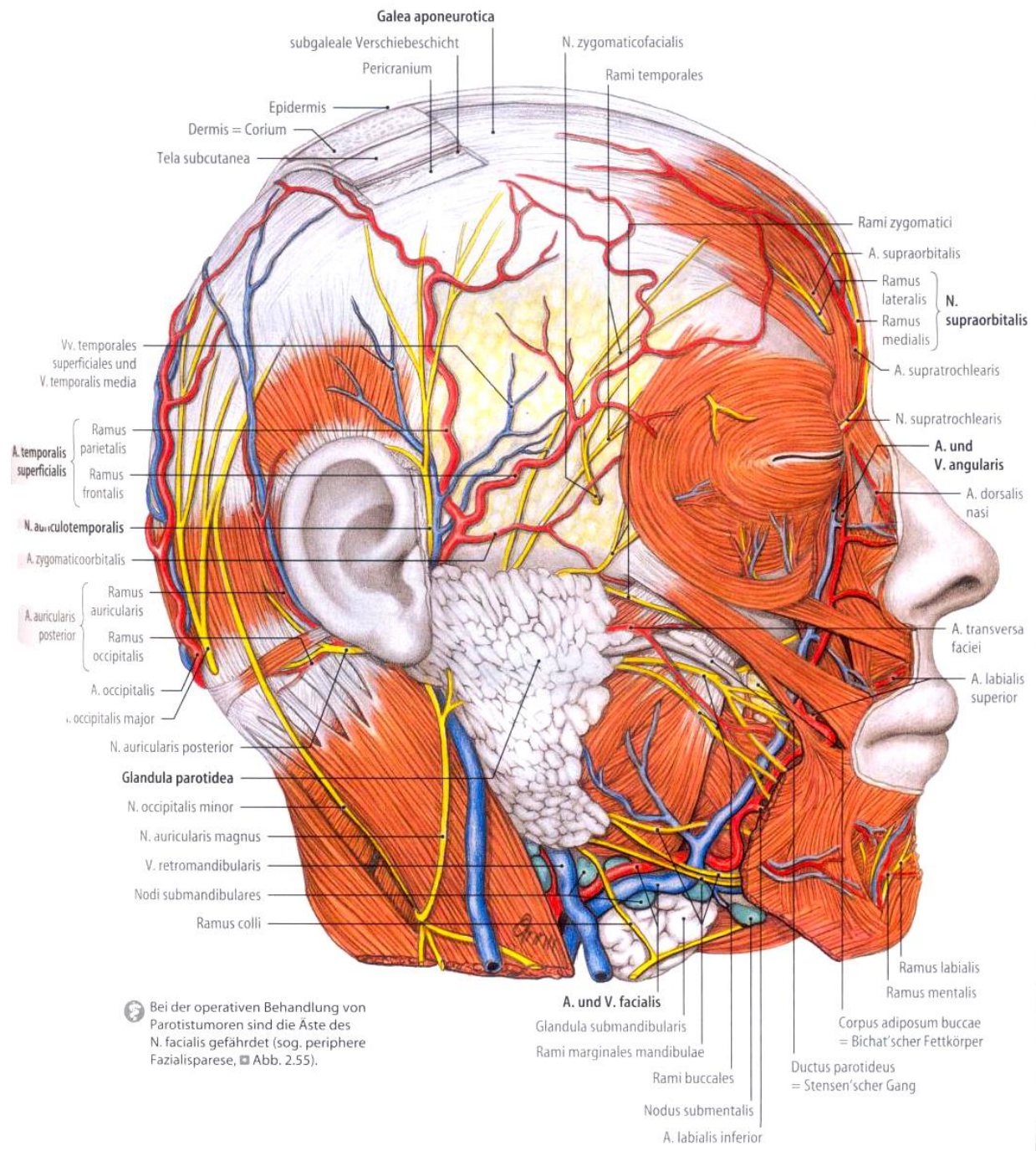












Bei der operativen Behandlung von Parotistumoren sind die Äste des N. facialis gefährdet (sog. periphere Fazialisparese, Abb. 2.55).

SMAS

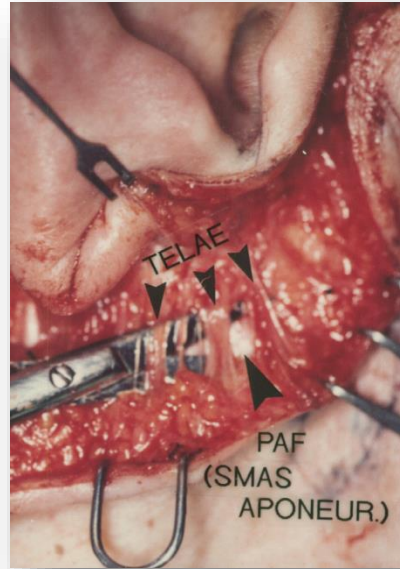
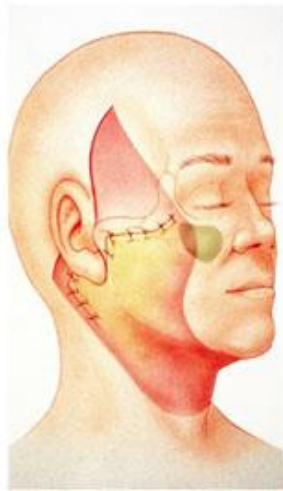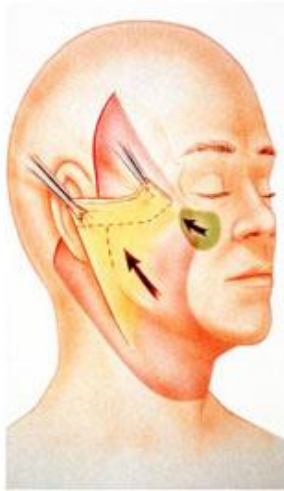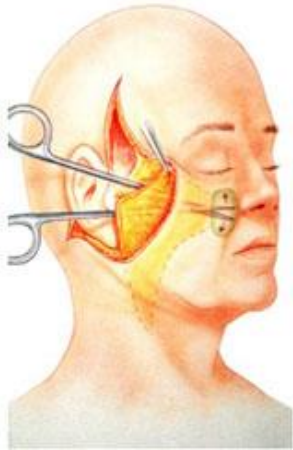Superficial Muscular Aponeurotic System

SMAS - Technik

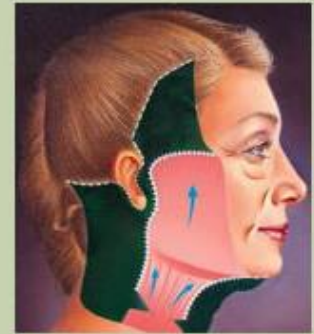Mobilisation

Reposition

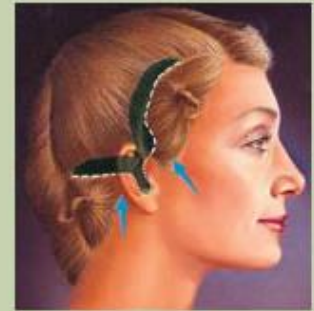
Fixation




Facelift/ Rhytidectomy-Technique



Facial, neck tissue and muscle may be separated; fat may be trimmed or suctioned and underlying muscle may be tightened.



After deep tissues are tightened, the excess skin is pulled up and back, trimmed and sutured into place.



Most of the scars will be hidden within your hair and in the normal creases of your skin.

Botox

(Clostridium botulinum)

