

# Maxilla

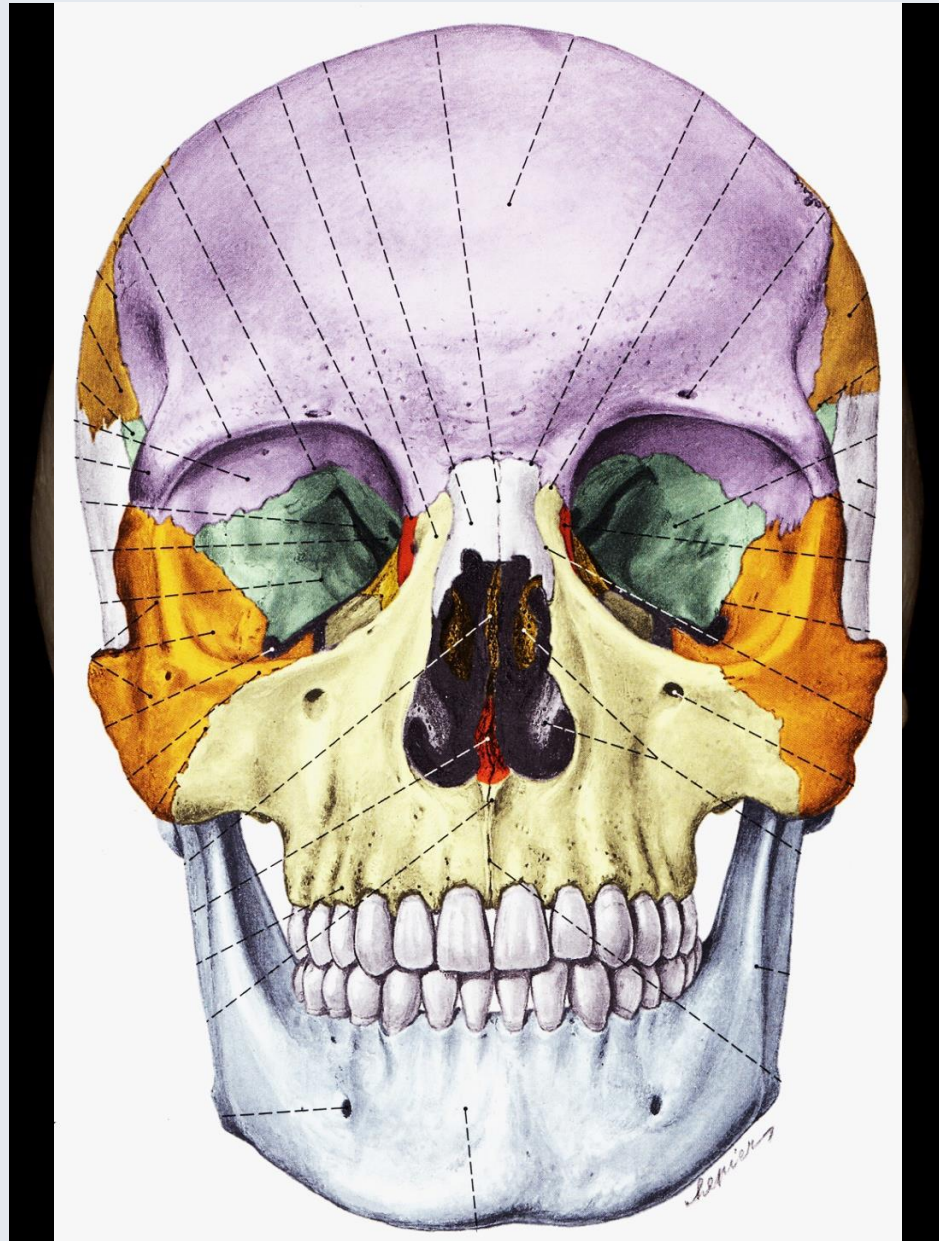


Dr. Dávid Lendvai

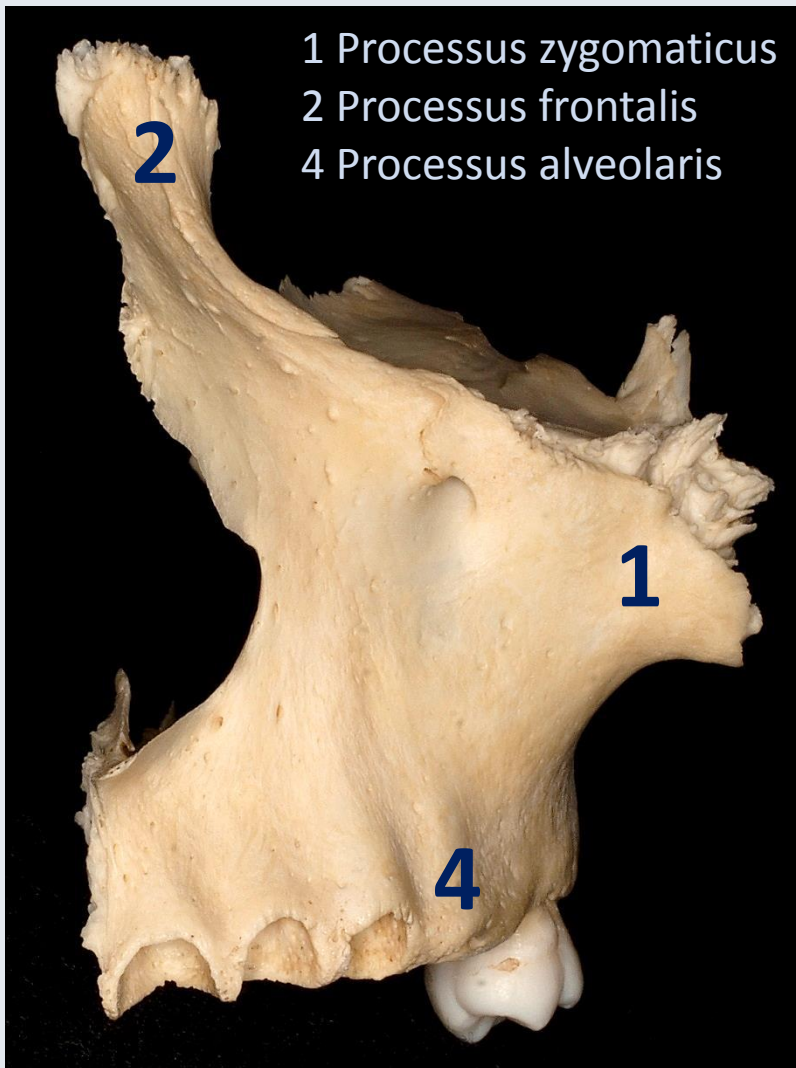
Anatomisches, Histologisches- und Embryologisches Institut

2018

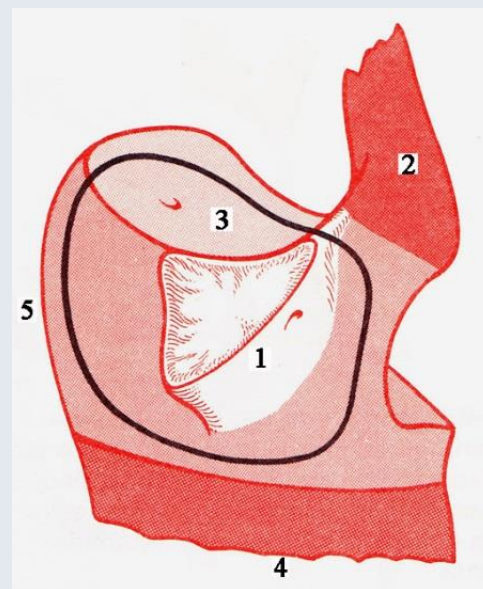
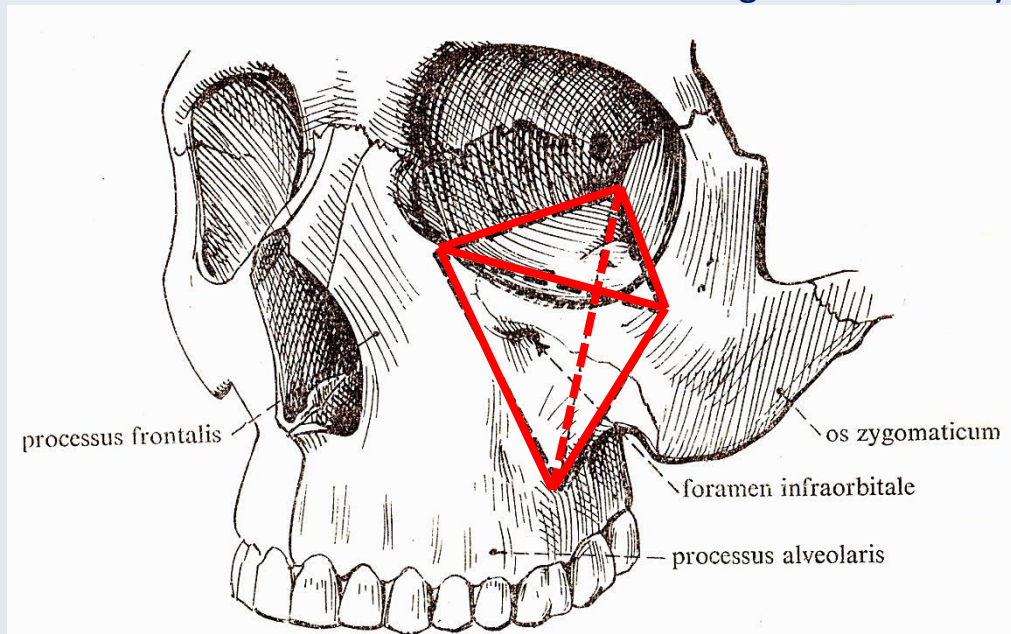
nach Dr. Gábor Baksa



# Aspectus anterior



(linke Seite)

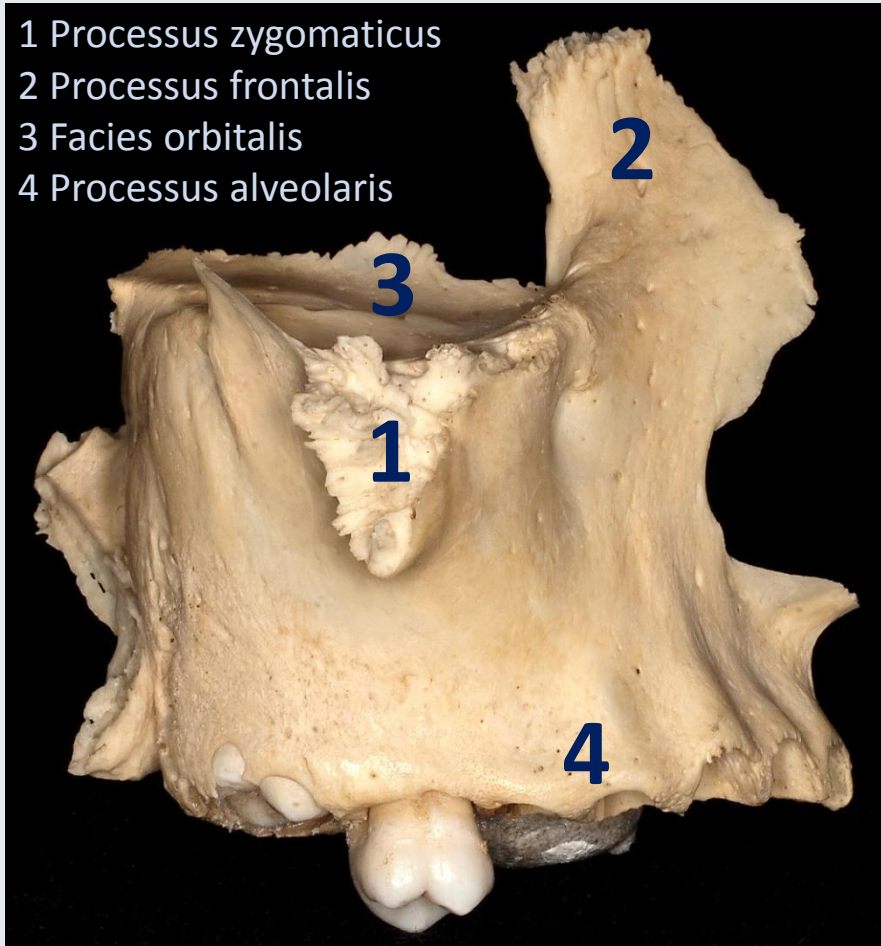


Faller

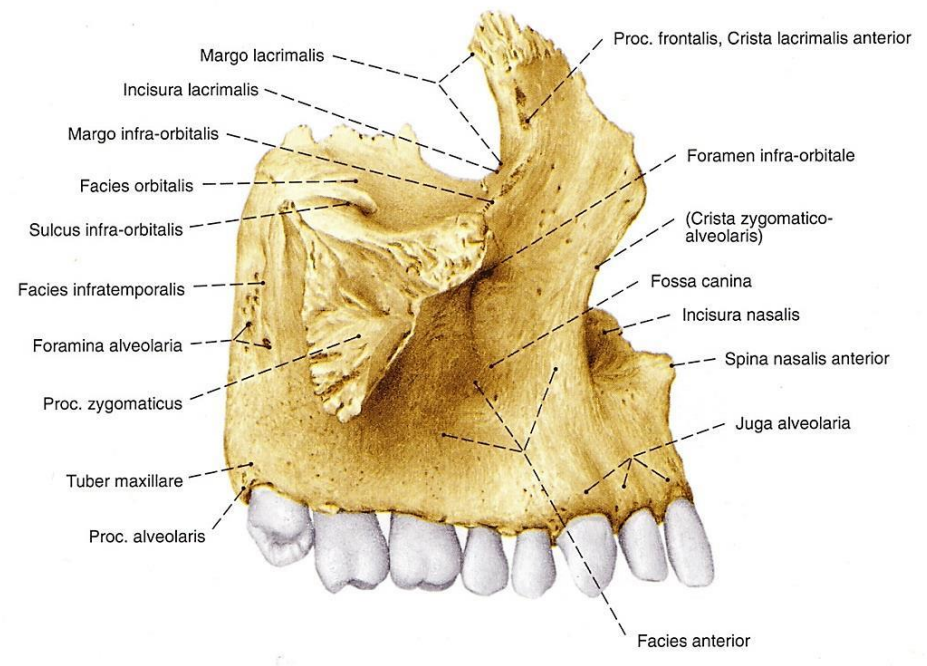


# Aspectus lateralis

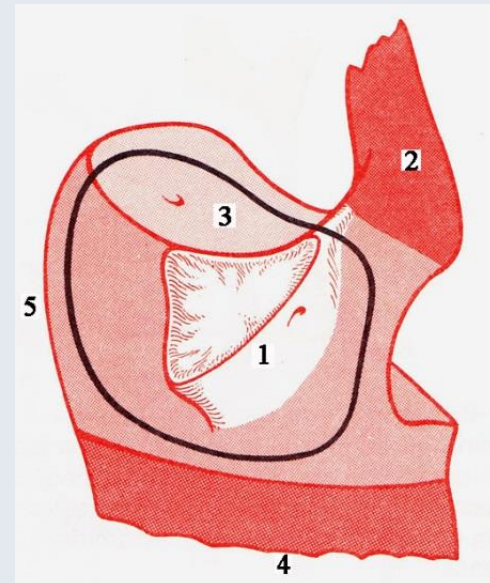
- 1 Processus zygomaticus
- 2 Processus frontalis
- 3 Facies orbitalis
- 4 Processus alveolaris



(rechte Seite)

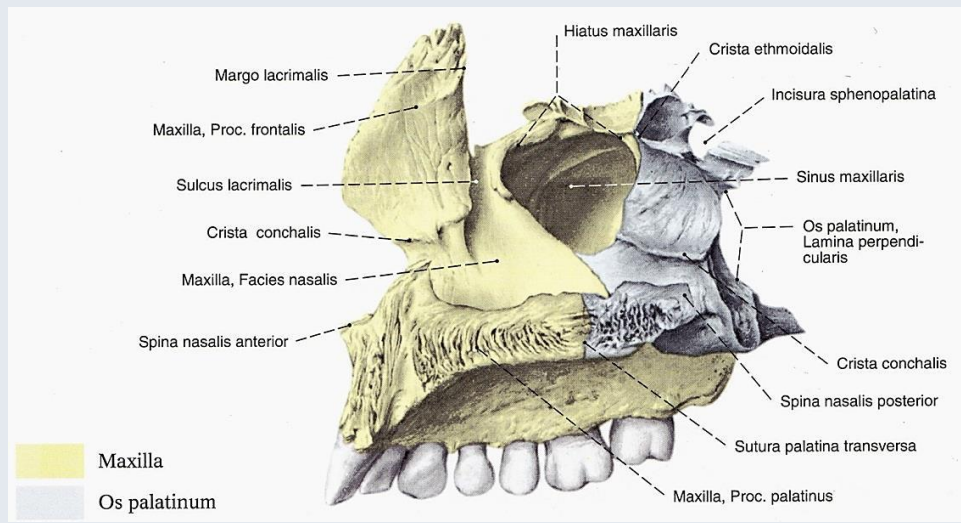
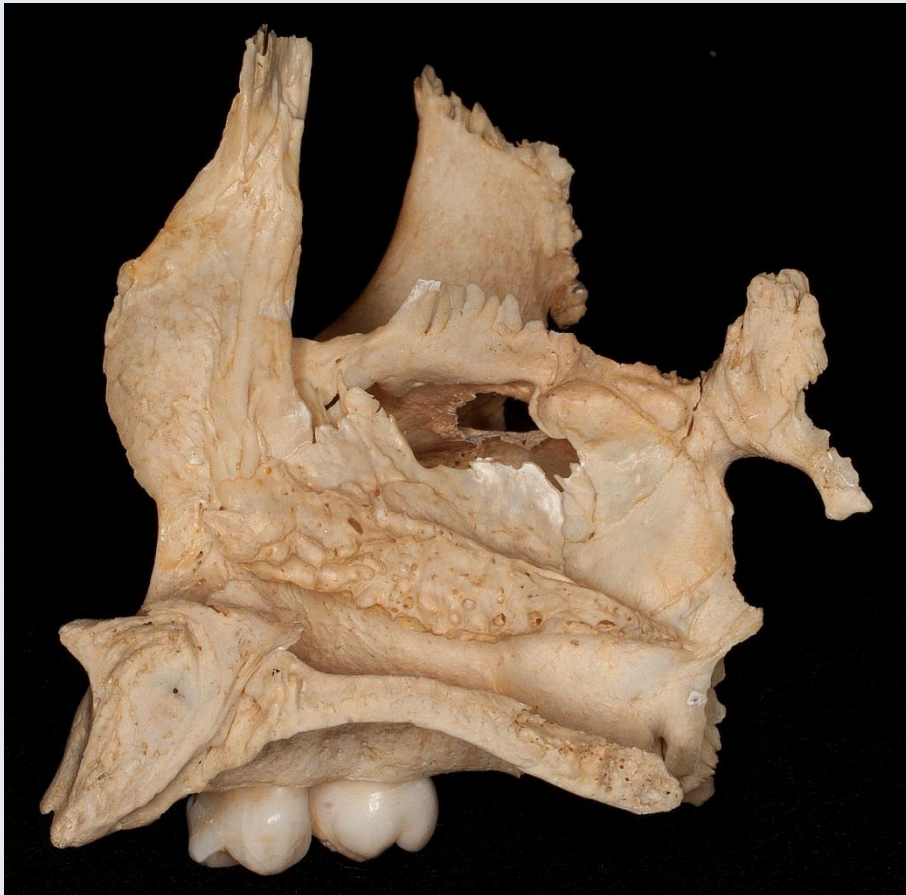

Sobotta

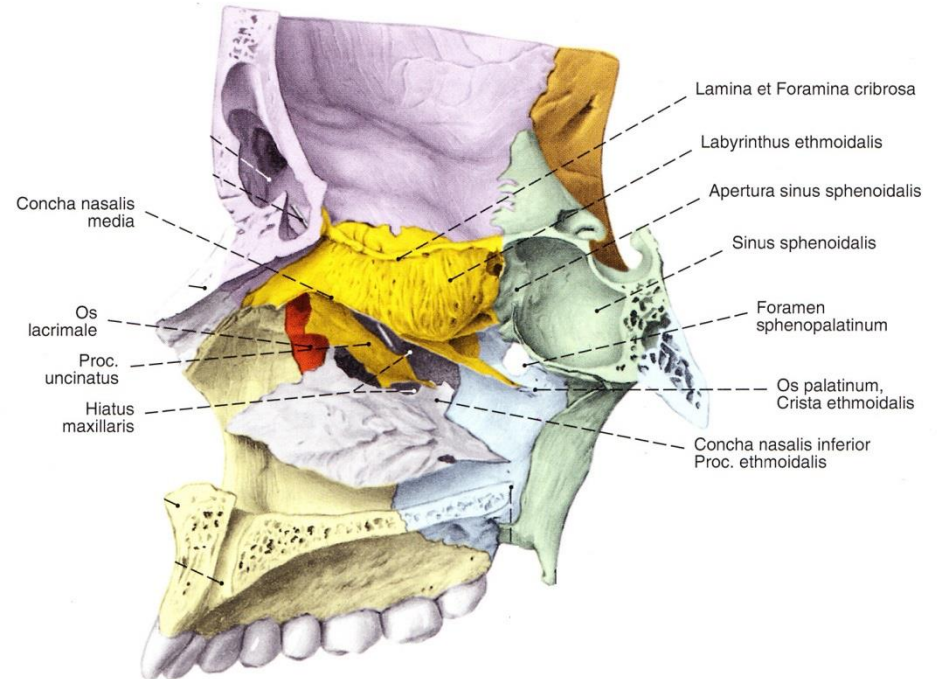


Faller

# Aspectus medialis

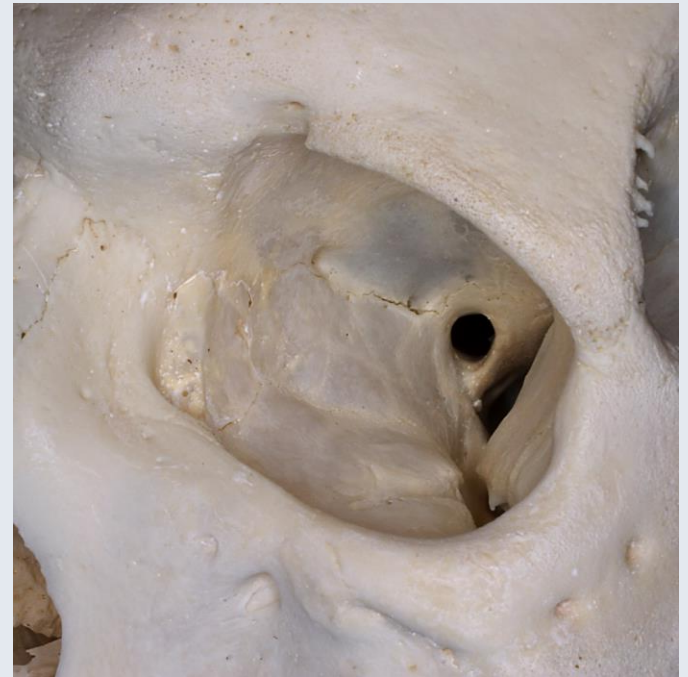
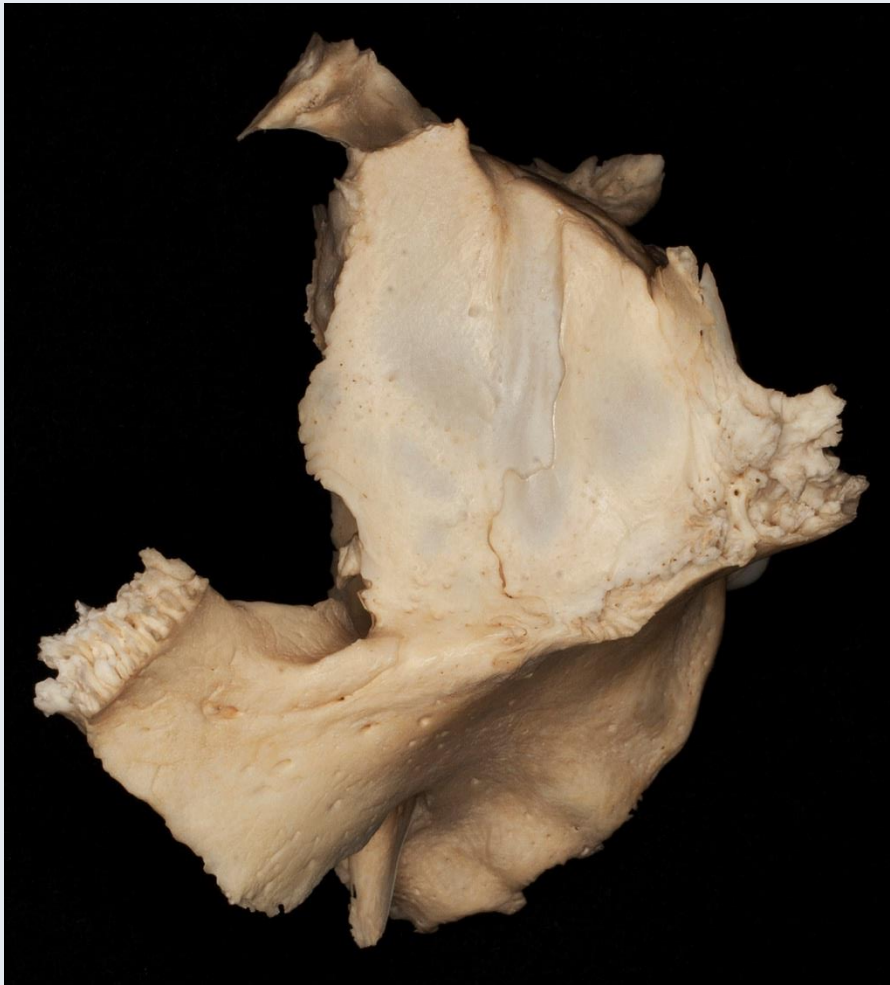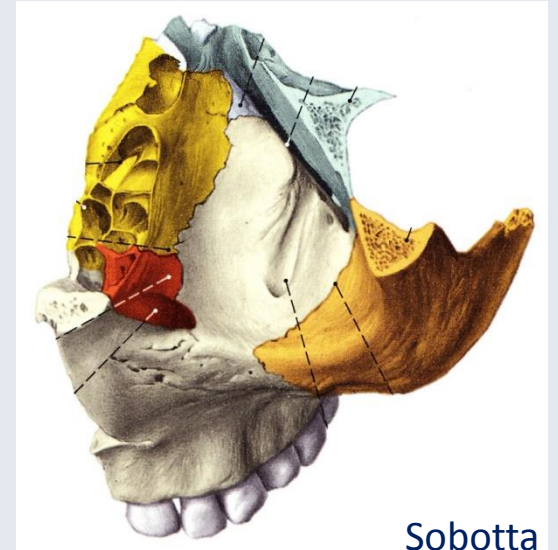


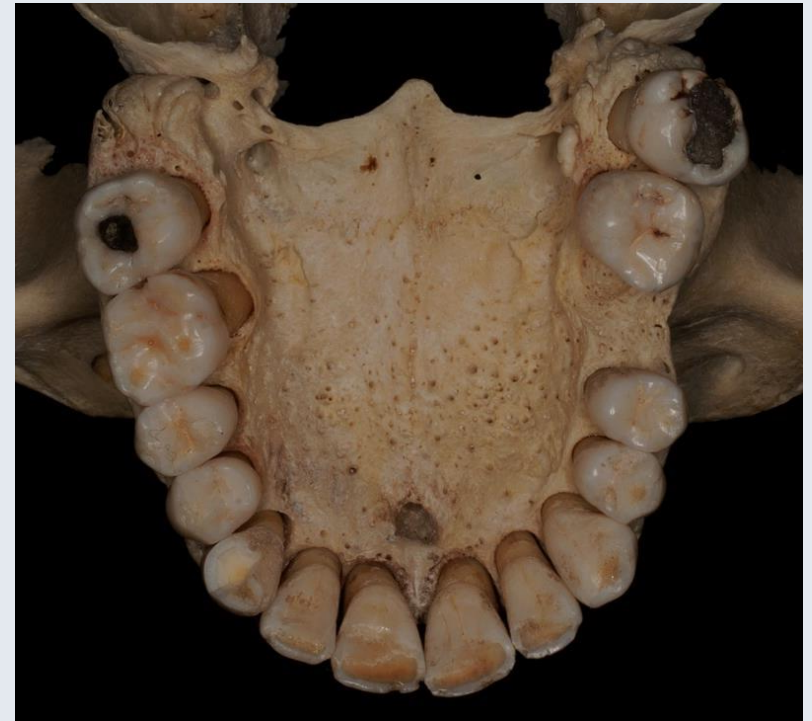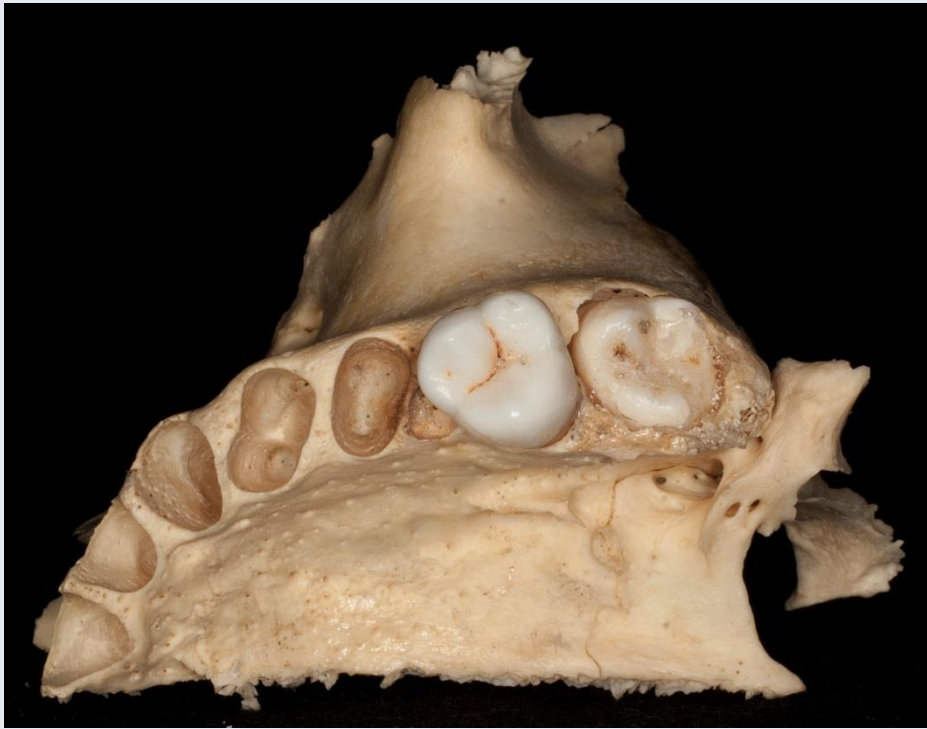Sobotta



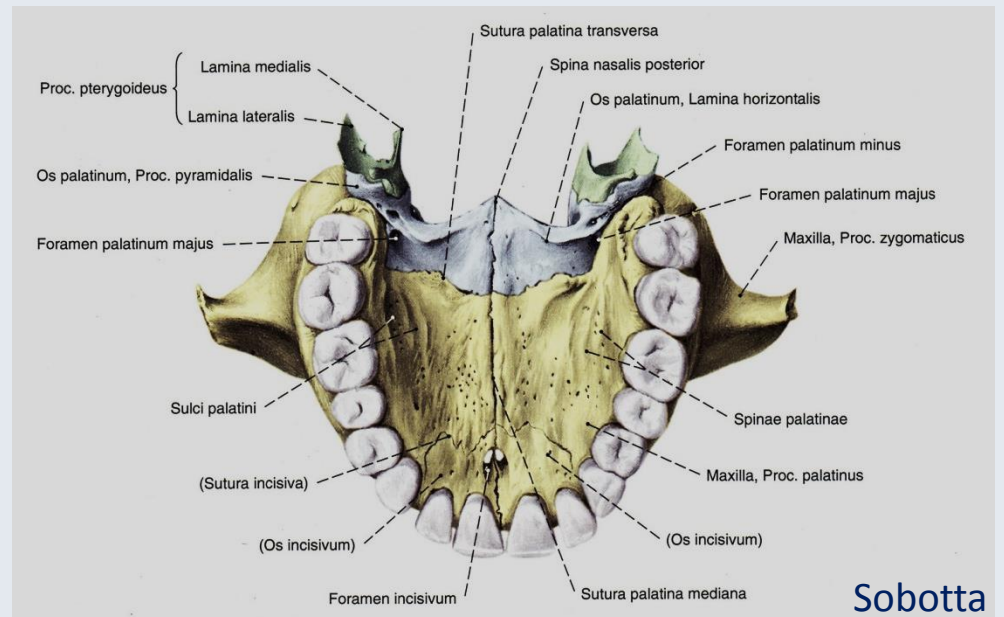


# Aspectus superior

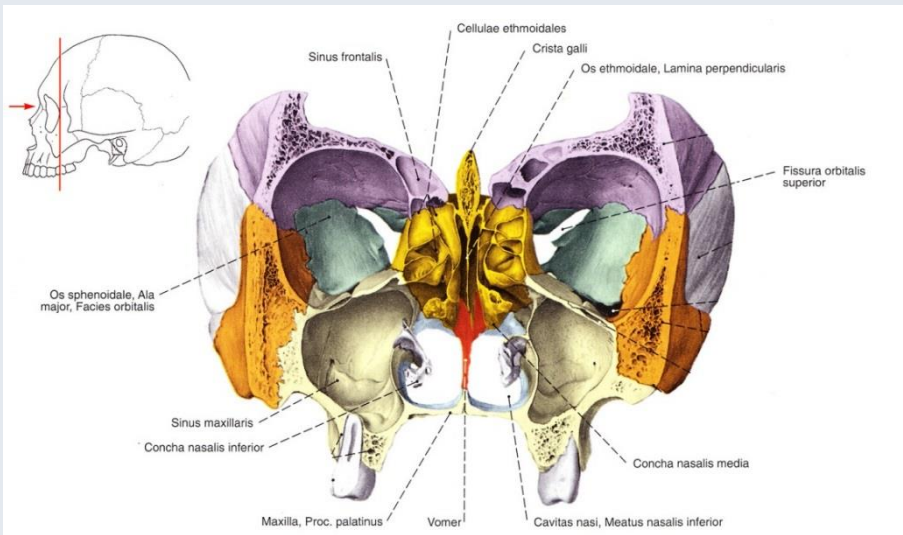




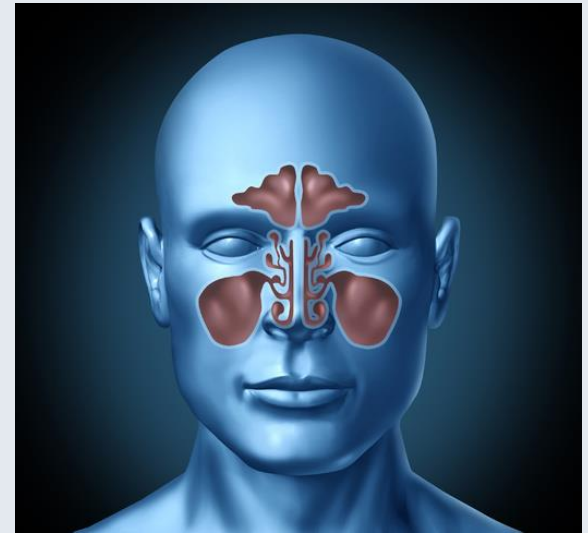
## Aspectus inferior



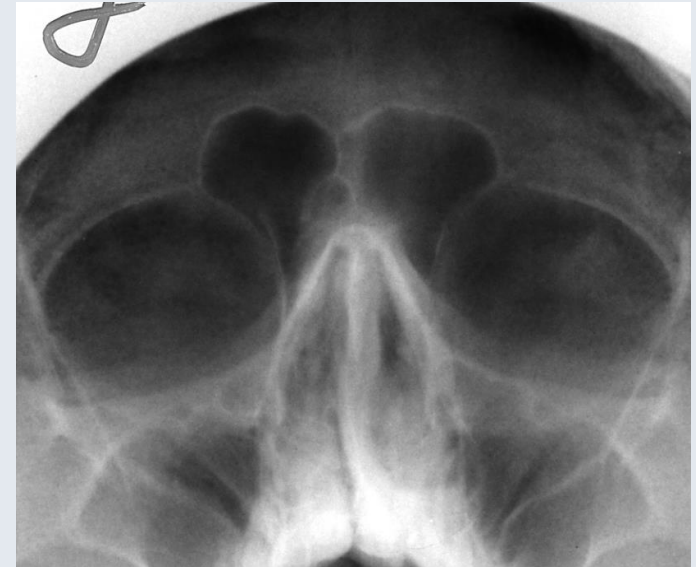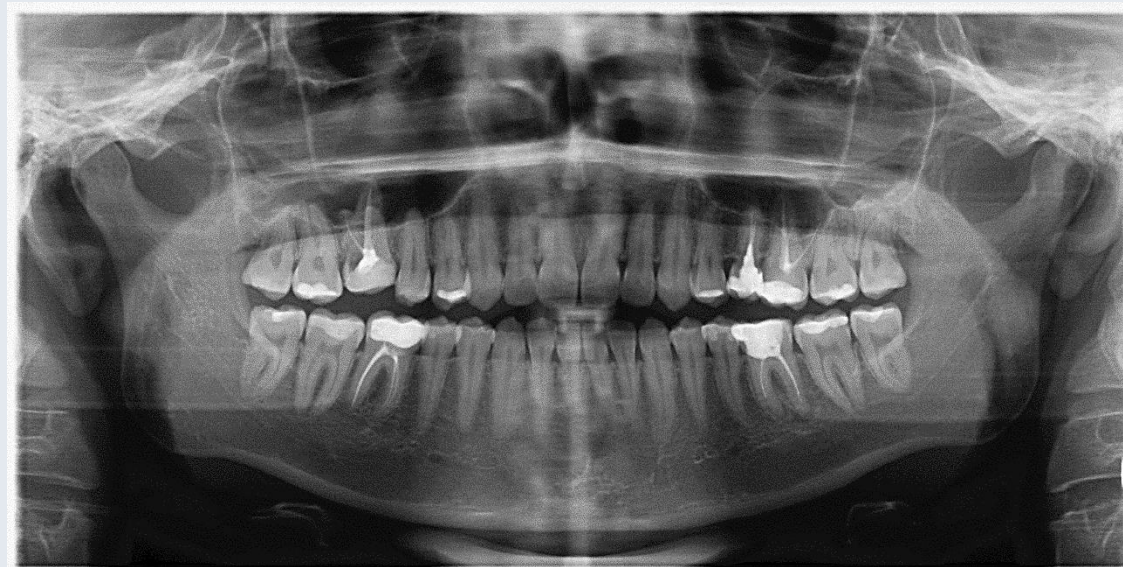




Sobotta

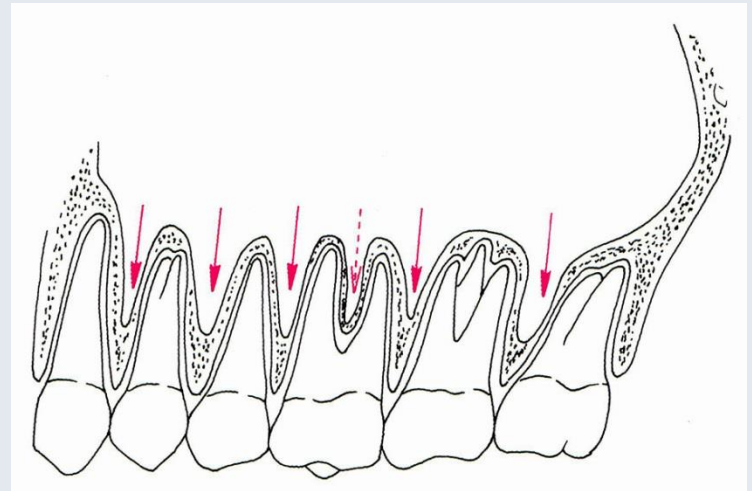
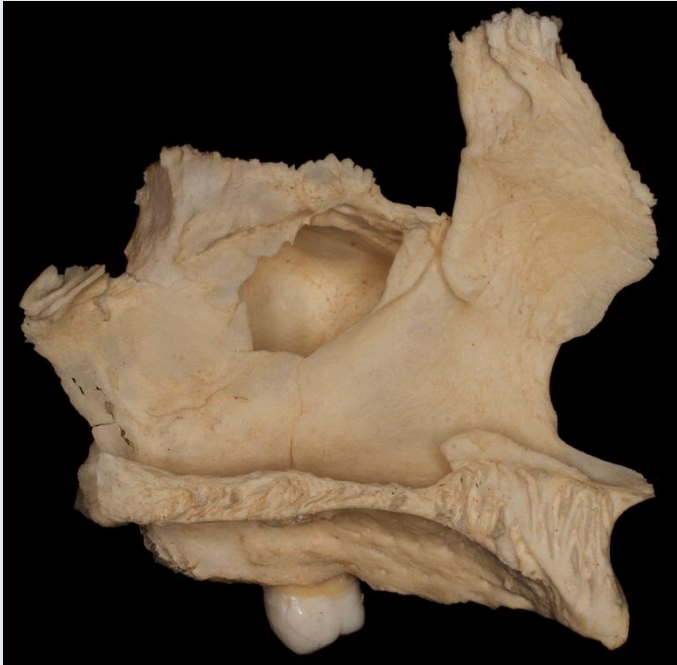
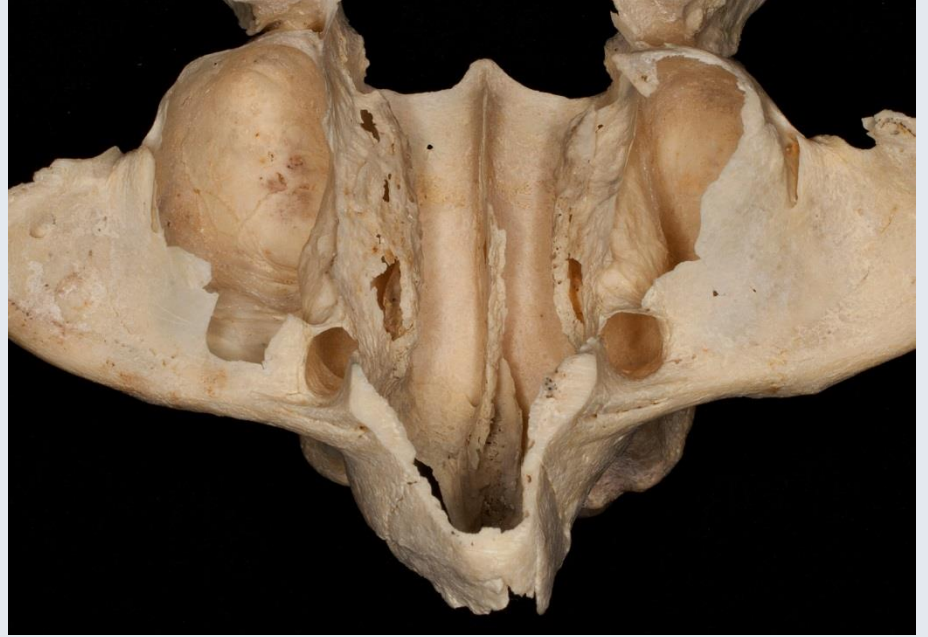
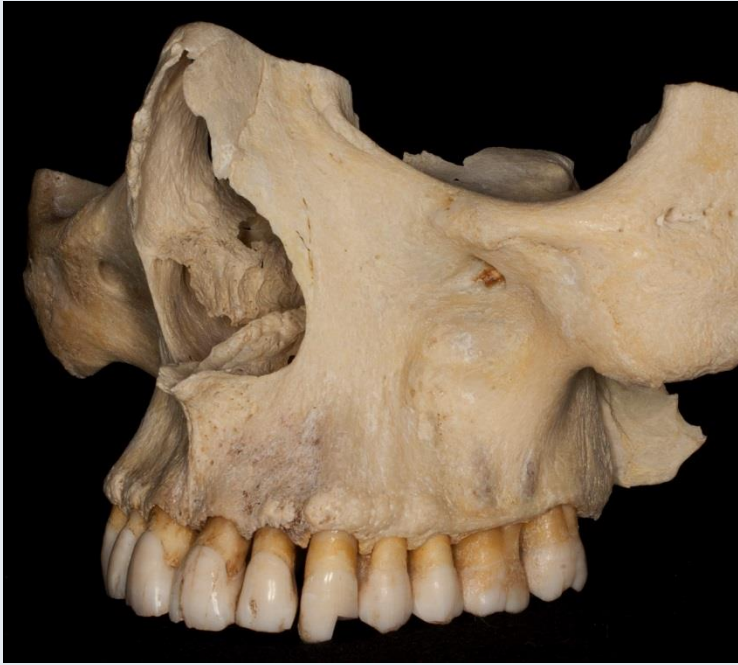<http://www.almanahmedical.eu>



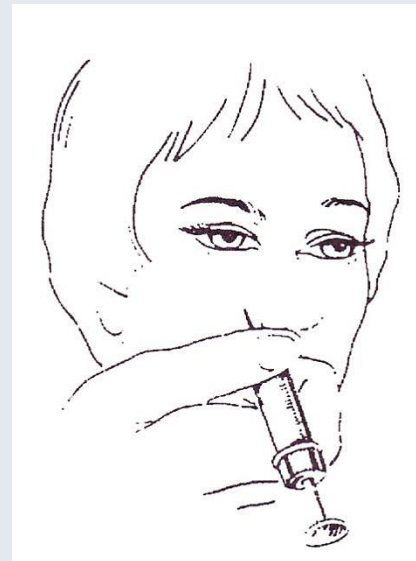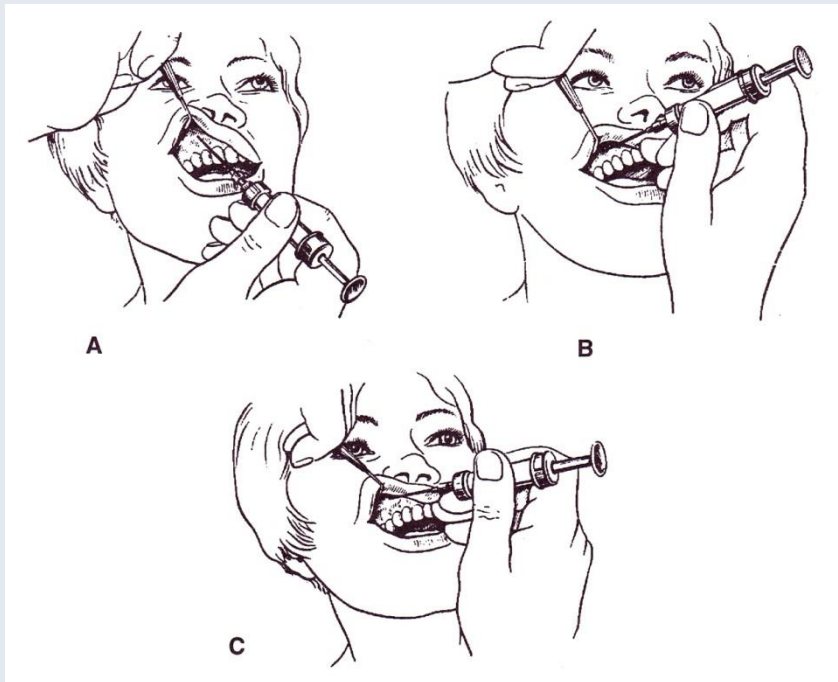
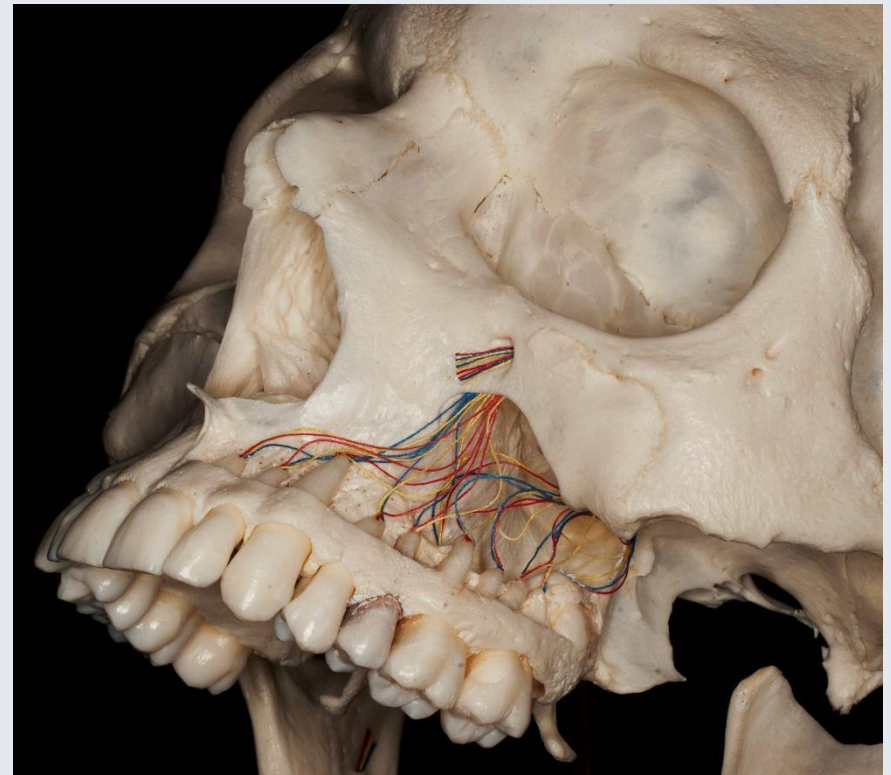
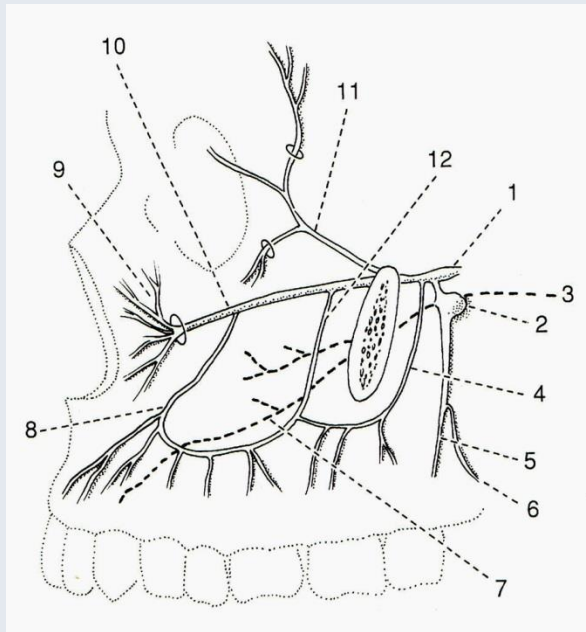
Florian Dental – Dr. S. Kovách





Fehér

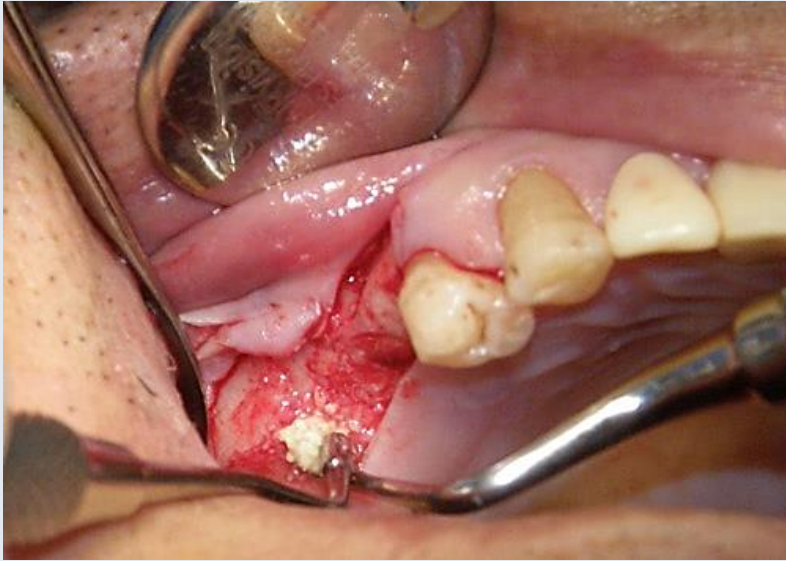Fehér



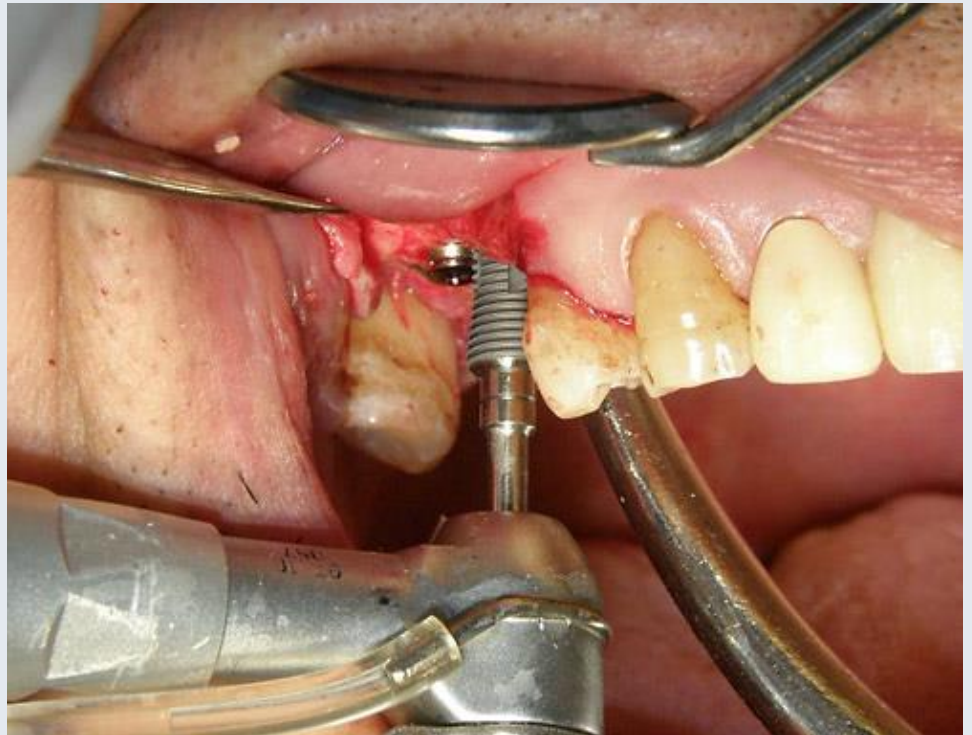
Szél

Szél





<http://www.hc-bios.com>



# Literatur und Danksagung

Faller: Anatomie in Stichworten – Ein Arbeitsbuch für Medizinstudente und praktische Ärzte (Ferdinand Enke Verlag 1980.)

Fehér: Maxillofaciális anatómia (Medicina Kiadó 2001.)

Pernkopf: Topographische Anatomie des Menschen. Lehrbuch und Atlas der regionär-stratigraphischen Präparation. (Urban & Schwarzenberg 1952.)

Sobotta: Az ember anatómiájának atlasza (Semmelweis Kiadó 1994.)

Szél: Klinikai anatómia (SOTE Képzéskutató 1999.)

Szentágothai – Réthelyi: Funkcionális anatómia (Medicina Kiadó - Semmelweis Kiadó 1996.)

[www.almanahmedical.eu](http://www.almanahmedical.eu)

[www.hc-bios.com](http://www.hc-bios.com)

[www.mng.hu](http://www.mng.hu)

Knochenpräparate in der Vorlesung: Dr. Lajos Patonay

Panoramaaufnahmen: Florian Dental – Dr. Sándor Kovách