

Semmelweis University
Department of Anatomy, Histology and Embryology

Faculty of Dentistry
2nd year 1st semester

September 2018

ANATOMY HANDBOOK



Dr. Andrea D. Székely
Associate Professor
Course Director of the English Language Program

Dr. Gábor Gerber
Associate Professor
Deputy Head of Department
Dean of the Faculty of Dentistry, Semmelweis University



Anatomy, Histology and Embryology for ED students

TEACHING DEPARTMENT:

SEMMELWEIS UNIVERSITY

Department of Anatomy, Histology and Embryology

Budapest, Tűzoltó utca 58.

H-1094 Budapest

<http://semmelweis.hu/anatomia>

LEARNING OBJECTIVES

Aims of the lectures in Anatomy - Presentation of important and/or complicated topics such as: 1st semester - the structure of the body wall (e.g. thorax, pelvis), extremities and the cranium, 2nd semester - the morphology of internal organs including the cardiovascular, digestive and urogenital systems; 3rd semester - the composition of the central nervous system, together with the organs of special senses and topography of body regions, and the 4th semester is devoted entirely to maxillofacial topographical anatomy.

Aims of the lectures in Histology - Presentation of the cell, basic principles in cellular morphology, detailed description of the epithelial, connective, muscle and nervous tissues. During the 3 semesters, the lectures contribute to the gross anatomical description of organs with a detailed presentation of their fine structures, including ultrastructural details. Important chapters: basic tissues, viscera, central nervous system.

Aims of the lectures in Embryology - Presentation of the early development from the differentiation of the germ cells to the formation of the human embryo (basic embryology) as well as the development of the locomotor system (1st semester). In the 2nd and 3rd semesters, the embryology topics will complement the gross anatomy and histology lectures of the organs and systems, also mentioning the most frequent malformations.

For the deeper understanding of relatively difficult questions small group discussions may be organized during the practical dissection room classes.

Aims of the practical dissection classes - In the first three semesters, based on their weekly programs, the students will study the morphology of the human body using anatomical specimens (bones, joints, muscles, viscera, brain) as well as learning the basic principles of dissection, including the proper usage of tools (scalpel, forceps, scissors) under the supervision of their lab instructors. The anatomy of the locomotor system and the peripheral nervous system will be principally taught in the dissecting room.

Aims of the histology practical classes - Under supervision by the lab instructor, the students will learn the use of the light microscope and the individual viewing of histology slides will facilitate the understanding of the basic tissues (epithelial, connective, muscle and nervous) and the fine structure of the organs.

The knowledge of students will be tested by regular **mid-term examinations** and a Semester-end Dissection Test.

Lectures:

First semester: 3x 45 min; second semester: 3x 45 min;

third semester: 3x 45 min; fourth semester: 3x 45 min.

Topics:

First semester: Gross anatomy of the bones, joints and muscles, basic histology, general embryology, development of the skull, spine and limbs.

Second semester: Morphology, histology and embryology of the heart and vessels, lymphatic organs, viscera, body cavities and serous membranes. Sectional anatomy of the thorax, abdomen and pelvis. Description of the diaphragmas.

Third semester: Morphology, histology and embryology of the central and peripheral nervous systems, the organs of special senses, as well as of the endocrine organs; topographical anatomy of the extremities.

Fourth semester: Maxillofacial anatomy - organs, cavities, nervous and vascular supply of the head and neck regions, including topographical and cross sectional anatomy. Revision of the topics of the first three semesters.

Practical course:

First semester 5x 45 min; second semester: 4x 45 min;

third semester: 4x 45 min; fourth semester: 2x 45 min;

First semester: Gross anatomy of the bones, joints and muscles, basic histology, general embryology, development of the skull, spine and limbs.

Second semester: Morphology, histology and embryology of the heart and vessels, lymphatic organs, viscera, body cavities and serous membranes. Sectional anatomy of the thorax, abdomen and pelvis. Description of the diaphragmas

Third semester: Morphology, histology and embryology of the central and peripheral nervous systems, the organs of special senses, as well as of the endocrine organs; topographical anatomy of the extremities.

Fourth semester: Topographical anatomy of the head and neck. Individual revision of the subjects taught and studied during the four semesters.

Type of exams: first, second and third semesters: semifinal examination, fourth semester: final exam from the subjects of the four semesters.

ECTS credits: four semesters together: 29 (first semester: 8; second semester: 8; third semester: 7; fourth semester: 6)

ED II ANNOUNCEMENTS

Evaluation is made using a five-grade scale (1-5).

Signing of the semester: active participation in lectures, dissection room and histology lab sessions is obligatory. Students should attend at least 75% of the scheduled hours to gain a signature proving the validity of the semester (and see below *). Absences are therefore limited in **25%**.

Midterm examinations: During the semester, both practical and theoretical knowledge will regularly be evaluated. The midterm tests may be oral or written exams and cannot be done at a different time. **Anatomy** midterms include both identification of several structures on the specimen and theoretical questions related to the subject. **The second midterm (Microscopy of the CNS) is obligatory.** Without a valid (i.e. passing) mark gained in this midterm the semester is not accepted*. The results of all tests will appear on the personal achievement cards.

A semester practical mark is calculated from the midterm marks together with the personal achievement mark given by the group instructor. This practical mark will be counted into the semifinal examination and will be written on the personal achievement cards. Absence will be recorded as 0 (zero) and calculated accordingly in the average of midterm tests.

Competition – only in the 3rd semester we offer the possibility of a competition (held during the 13th study week) upon invitation to those students whose midterm marks are at least 4 (good). Registration for the competition is open in the 12th week. Topic: Material of the semester, written test, including slides of macroscopical and microscopical specimen together with relevant theoretical questions. Students who reach the required 80% at the competition are exempted from the semifinal examination with a mark 5 (excellent).

Semifinal examinations are composed of the following parts:

1. **written pretest,**
2. **oral examination** (practical and theoretical questions in Macroscopy together with the identification/description of two histological specimen.

Notebooks should be used regularly in **histology lab sessions** in order to prepare schematic drawings of the histological specimens. Students will be asked to present their histology notebooks, containing the drawings, during the semifinal exams.

Obligatory dissection work – every students is required to produce a fully dissected specimen during the 2nd, 3rd or the 4th semester to be exempted from the dissection part of the final examination. The specimen will be evaluated by a departmental jury.

N.B. – In case, neither the first nor the repeated takes of a semifinal exam have been successful and so the exam has to be postponed to the following exam period (i.e. 'CV' exam), only those students will be allowed to register for a CV ana3 exam course together with ana4 (i.e. continuing with their Anatomy studies) whose average score of the midterm tests is equal, or higher than 2.00.

RULES AND REGULATIONS IN THE DISSECTING ROOM

IT IS STRICTLY FORBIDDEN to eat, drink, smoke, to chew gums, or to use music devices or phones.

Bags and coats should be left in the lockers before entering the dissecting room.

The lockers will have to be locked using your padlocks.

Please, remember to keep your valuables always on you, or lock them in the lockers since the department takes no responsibility for lost items.

Everybody is supposed to behave in the dissecting room conforming to the spirit of the site. Loud speech, out-of-place jokes and any kind of behaviour, disregarding the dignity of human corpses, should strictly be avoided.

Students are expected to be prepared for the practical work.

Students should take care of the furniture and equipment of the dissecting room. Do not sit on the dissection tables or stand on the tripod stools to avoid accidents. **Fire and work safety regulations** should be maintained. The dissection room is a hazard area. **Cleanliness and order** should be kept.

Working in the dissection room involves the use of **sharp and pointed tools**, injuries should be reported to the lab instructor. The technical personnel will provide first aid when necessary.

The white lab coats should be worn while in the dissection room, but should be removed before leaving the dissection room area. The purpose of wearing the lab coats is to protect one's clothing from contacting the cadaver specimen. Furthermore we advise you to wear closed toed shoes and clothing covering the legs. In the end of the class, lab coats should be emptied and left in order on the coat hangers. The department is not responsible for valuables left in the dissecting room.

Only the members of the study group can participate in the sessions, visitors may be present only with prior permission by the lab instructor. Students can leave the sessions only with the approval of the lab instructor.

Photos of black board drawings can only be made in the presence of the lab instructor.

Specimen preparations should be wrapped and labeled. Dissection materials of other groups or individuals should not be handled. Dissected cadaver pieces should be discarded in a designated container and discarded blades have to be collected separately.

Dissecting rooms are closed between 6:00 PM to 8:00 AM and over the weekends Students may not stay in the dissecting room without the supervision of one of the assistants of the department. In the absence of an instructor, the technical personnel should ask the students to leave the dissecting room.

**SMOKING IS STRICTLY FORBIDDEN
ON THE DEPARTMENTAL PREMISES,
INCLUDING THE GARDEN AND THE YARD!**

ED II.

Subject matter of the 3rd semester

I. Central nervous system

- a) gross anatomy of brain and spinal cord, meninges
- b) nuclei and tracts of brain and spinal cord
- c) development of the brain and the spinal cord

II. Peripheral nervous system

- a) cranial nerves
- b) spinal nerves
- c) autonomic nervous system
- d) development of the peripheral nervous system

III. Organs of special senses (gross anatomy, histology and embryology)

- a) organ of vision, visual pathways
- b) organ of hearing and equilibrium, auditory pathways, vestibular system
- c) organ of smell, olfactory pathways
- d) organ of taste, gustatory pathways
- e) skin and appendages

IV. Endocrine organs (gross anatomy, histology and embryology)

V. Topographical anatomy of the limbs

Midterm test I. Topic: Gross anatomy and embryology of the central nervous system.
Date: 4th week, October 5.

Midterm test II. Topic: Microscopy of the central nervous system. (written)
Date: 8th week, October 29.

Midterm test III. Topic: Topographical anatomy of the upper and lower limbs, spinal and cranial nerves.
Date: 12th week, November 30.

Semifinal examination

Topic: Subject matter of the semester

1) Written pretest

2) Practical examination and theoretical questions (oral examination)

Gross anatomy, microscopy and development of the brain, spinal cord, organs of special senses and endocrine glands.

3) Histology of the nervous system, organs of special senses, the endocrine system (slides).



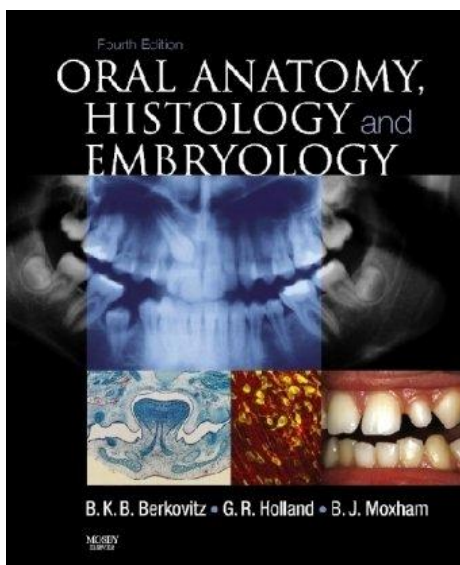
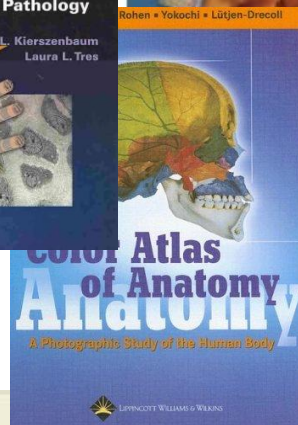
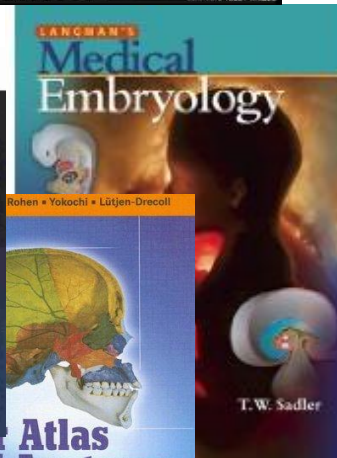

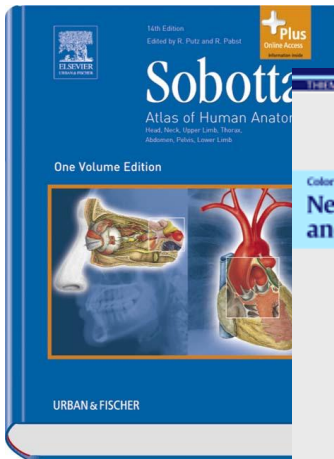


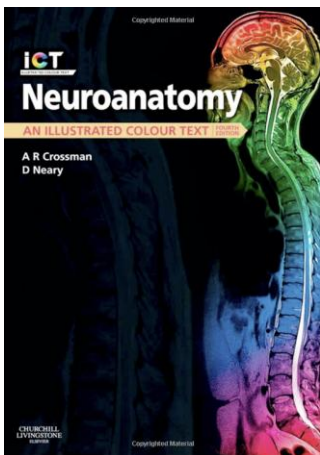
Academic Year 2018/2019 Faculty of Dentistry, 3rd Semester ED II. 1 – 4 (5)

Week	LECTURE <i>Tuesday 8.00 - 9.40 Wednesday 12.05 - 12.50</i>	DISSECTION <i>Mondays 12.00 - 13.30 Fridays 12.45 - 14.15</i>	HISTOLOGY <i>on 5 Mondays 12.00 - 13.30</i>
Week 1 Sept 10-14	1. Introduction to the study of the nervous system Meninges, hemispheres, the lateral ventricles 2. Gross anatomy of the diencephalon, the III. ventricle 3. Gross anatomy of the brainstem and the cerebellum The IV. ventricle	Divisions of the brain, meninges, arteries and veins of the brain, surface structures of the hemispheres, basis cerebri. Specimen demonstration: dura mater, sinuses	
Week 2. Sep 17-21	4. Blood supply to the brain, CSF circulation 5. <i>Differentiation of the neural tube, development of the spinal cord. Neural crest</i> 6. <i>Differentiation of the brain vesicles</i>	Lateral ventricles, third ventricle Brain stem, fourth ventricle, cerebellum	
Week 3. Sept 24-28	7. Gross anatomy of the spinal cord, spinal segments, dermatomes 8. Neuronal architecture of the spinal cord: proprioceptive and nociceptive (withdrawal) reflex arcs. 9. Neuronal architecture of the spinal cord: autonomic reflex arc. Spinal pathways	Cross sections of the brain. Specimen demonstration: spinal cord together with the membranes	
Week 4. Oct 1-5	10. Introduction to cranial nerves. Classification of sensory, motor and autonomic nuclei 11. Microscopy of the brainstem: tracts and nuclei of the medulla oblongata 12. Microscopy of the brainstem: tracts and nuclei of the pons and midbrain. Reflex arc of mastication	Fine structure of spinal cord. Revision 1st midterm test: Anatomy and development of the brain and the spinal cord	
Week 5. Oct 8-13 <i>Saturday is a workday (Monday schedule)</i>	13. Cells of the CNS: neurones (axon, dendrite, synapses) and glia cells 14. Microscopy of the diencephalon 15. Microscopy of the cerebral cortex	- Dissection of limbs. Microscopy of the CNS Extra dissection class on Saturday	Nervous system I. (on Monday)
Week 6. Oct 15-19	16. Sensory systems, neuroanatomy of pain 17. Microscopy of the cerebellum, pathways 18. Structure and connections of the basal ganglia Motor pathways	- Dissection of limbs. Microscopy of the CNS	Nervous system II.
Week 7. Oct 22-26 <i>October 22-23 are holidays</i>	19. - 20. - 21. Trigeminal nerve, ophthalmic division	No class on Monday Dissection of limbs. Microscopy of the CNS	No class on Monday
Week 8. Oct 29 – Nov 2 <i>November 1-2 are holidays</i>	22. Trigeminal nerve maxillary division 23. Trigeminal nerve, mandibular division 24. Facial and glossopharyngeal nerves	2nd midterm test: Microscopic structure of the central nervous system (written test) No dissection class on Friday	
Week 9. Nov 5-10 <i>Saturday is a workday (Friday schedule)</i>	25. Vagus, accessory and hypoglossal nerves 26. The hypothalamo-hypophysial system. The pituitary gland 27. Endocrine organs: pineal body, thyroid, parathyroid, adrenal glands	Dissection of limbs. Demonstration of head and neck regions. Cranial nerves Extra dissection class on Saturday	
Week 10. Nov 12-16	28. The topographical anatomy of limbs 29. Skin and appendages. Mammary gland 30. Fibrous and vascular coats of the eyeball.	- Dissection of limbs. Demonstration of head and neck regions. Cranial nerves. Dissection of the eye	Endocrine organs
Week 11. Nov 19-23	31. Lens, chambers of the eye, vitreous body, accommodation 32. Inner coat of the eyeball, retina Optic nerve, visual pathway, visual cortex 33. External muscles and movements of the eye	Dissection of limbs. Demonstration of head and neck regions. Cranial nerves.	
Week 12. Nov 26-30	34. Protective and lacrimal apparatus of the eye. Development of the eye 35. External ear, auditory tube, tympanic cavity, tympanic membrane, auditory ossicles 36. Bony and membranous labyrinth	Dissection of limbs. Demonstration of head and neck regions. Cranial nerves. 3rd midterm test: Topographical anatomy of the limbs, spinal nerves, cranial nerves	
Week 13. Dec 3-7	37. Spiral organ of Corti. Development of the auditory and vestibular systems 38. Auditory pathway, auditory cortex 39. Vestibular system	- Demonstration of head and neck regions. Organs of special senses	Organs of special senses I.
Week 14. Dec 10-14	40. Olfactory and gustatory systems 41. Limbic system 42. Parasympathetic and sympathetic nervous systems	- Demonstration of head and neck regions. Organs of special senses	Organs of special senses II. Skin and mammary gland

ED II Histology specimens

Week	<i>Mondays 12.00 – 13.30 (5 occasions only)</i>
Week 1 Sept 10-14	
Week 2. Sep 17-21	
Week 3. Sept 24-28	
Week 4. Oct 1-5	
Week 5. Oct 8-13 <i>Saturday is a workday (Monday schedule)</i>	<u>Nervous system I.</u> Revision: 36. Peripheral nerve, cross section (HE) Demonstration: Peripheral nerve (osmium tetroxide) 43. Motor end plate (AChE) 37. Spinal ganglion (HE) 38. Autonomic ganglion (AgNO ₃) 39. Spinal cord (multipolar neurons Nissl) 99. Midbrain (Luxol-Nissl) 100. Medulla oblongata (Luxol-Nissl)
Week 6. Oct 15-19	<u>Nervous system II.</u> 40. Cerebral cortex (pyramidal neurones, Bielschowsky) 42. Cerebral cortex (pyramidal neurones, Golgi) 94. Hippocampus (HE) 95. Cerebellar cortex(HE) 41. Cerebellum (GFAP immunocytochemistry) 90. Pineal body(HE)
Week 7. Oct 22-26 <i>October 22-23 are holidays</i>	<i>Oct 23 is national holiday - Oct 22 (no school)</i>
Week 8. Oct 29 – Nov 2 <i>November 1-2 are holidays</i>	<i>Nov 1 is a national holiday</i>
Week 9. Nov 5-10 <i>Saturday is a workday (Friday schedule)</i>	
Week 10. Nov 12-16	<u>Endocrine system</u> 86. Hypophysis (HE) 87. Hypophysis (chrome haematoxyline floxin) 88. Thyroide gland (HE) 89. Parathyroide gland (HE) 92. Suprarenal gland (HE) Demonstration: 74. Leydig cells (testicles, HE) 78. Ovarian follicles, interstitial glands (ovary, HE) 79. Corpus luteum (HE) 70. Islets of Langerhans (pancreas, HE)
Week 11. Nov 19-23	
Week 12. Nov 26-30	
Week 13. Dec 3-7	<u>Organs of special senses I.</u> 96. Bulbus oculi (HE) 97. Retina (semithin section, toluidine blue) 9. Pigment cells (retina, unstained) 33. Lacrimal gland (HE)
Week 14. Dec 10-14	<u>Organs of special senses II. and skin</u> 98. Cochlea (semithin section, toluidine blue) 6. Palm skin (HE) 18. Scalp skin (Hornowsky) 11. Scalp skin (HE) 17. Scalp skin (Azan) 85. Mamma non lactans (HE) 93. Mamma lactans (HE)

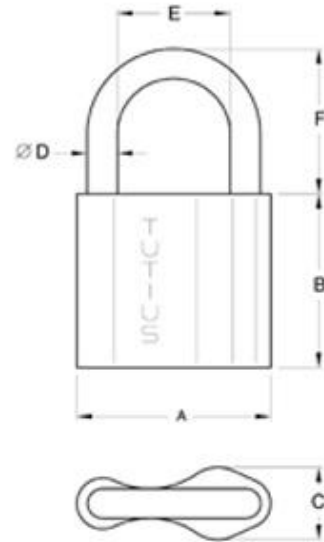
RECOMMENDED BOOKS



During dissection classes keep your belongings in the lockers and lock them with your padlock!


PADLOCK SIZE: 6 mm

Please, remember to keep your valuables always on you, or lock them in the lockers since the department takes no responsibility for lost items.



DISSECTION ROOM TOOLS

SCALPEL



A PAIR OF ANATOMICAL FORCEPS




RUBBER GLOVES



PROTECTIVE CLOTHING (LABCOAT)

GOGGLES



Semester-end and examination announcements

During the last week of the semester all our students will be informed of their **practical mark** and whether they have gained a **signature** for the present semester. The **signature** will be written in neptun on a preselected day.

All midterm marks, together with the calculated practical exam mark will be written on the personal achievement card. The practical exam mark will be counted in the result of the semifinal examination.

Semifinal examinations will be held preferably on Tuesdays, Wednesdays and Thursdays during the 7 weeks of the examination period. **ED II examinations** final examinations **will be held on all three days in not otherwise stated.**

***N.B.** The last changes concerning **registration/deregistration** from a date maybe done via the NEPTUN system **48 hours prior** to the selected day.*

The exams start at 13.00

Please, leave your belonging in a locker and gather in front of the Histology Lab (or TBA)

Please, remember to have your

- ID card
- histology note book
- pair of forceps on you.

Parts of the exam

1. Written pretest
2. **Macroscopy** (oral/practical)
3. **Histology** (oral/practical)

In case of an unsuccessful examination, the 1st retake will be free of charge, while for a **second repeated exam** you will need to pay a fee ahead of the retake examination and present a proof of it upon entering the examination room.

***N.B.** – In case, neither the first nor the repeated takes of a semifinal exam have been successful and so the exam has to be postponed to the following exam period (i.e. 'CV' exam), only those students will be allowed to register for a CV ana3 exam course together with ana4 (i.e. continuing with their Anatomy studies) whose average score of the midterm tests is equal, or higher than 2.00.*

TOPICS OF THE SEMIFINAL EXAM

Dissection room

Topics of the 1st and 3rd MIDTERM examinations

Histology exam

Description of histological specimen

Microscopical structure of the central and peripheral nervous systems, different staining techniques (cerebral and cerebellar cortices, neurons, supporting cells, ganglia, receptors and effectors, synapses)

Other relevant topics

Endocrine organs

Gross and microscopical anatomy of the pituitary gland; development of the posterior lobe
Blood supply, histology and development of the anterior and intermediate lobes of the pituitary gland

Gross and microscopical anatomy of the pineal gland

Gross and microscopical anatomy and the development of the thyroid gland

Gross and microscopical anatomy and the development of the parathyroid gland

Gross and microscopical anatomy and the development of the suprarenal gland

Histology of the Langerhans islets

Endocrine cells and function of the male and female gonads

Microscopical structure of the eyeball

Histology of the lacrimal gland

Microscopical structure of the cochlea

Microscopical structure of the skin (scalp and palm)

Histology of the mammary gland (lactating and non-lactating)

Macroscopical structure of the CNS

Gross anatomy of hemispheres

Cranial dura mater and its sinuses

Arachnoid and pia mater. Subarachnoid cisterns. Cerebrospinal fluid

Arteries, circle of Willis and veins of the brain

Gross anatomy of the lateral ventricles

Gross anatomy of the third ventricle

Gross anatomy of the fourth ventricle

Gross anatomy of the large commissural pathways

Gross anatomy of the internal capsule

Gross and microscopic anatomy of basal nuclei

Gross and microscopic anatomy of thalamus

Anatomy, blood supply and development of the diencephalon

Gross and microscopic anatomy of midbrain

Gross and microscopic anatomy of pons
Gross and microscopic anatomy of medulla oblongata
Gross and microscopic anatomy of cerebellum
Cranial nerve exits
Gross anatomy of spinal cord. Spinal segment. Spinal nerve.
Blood supply and meninges of the spinal cord

Microscopical structure and development of the central nervous system

Development and primary differentiation of the neural tube
Development of the spinal cord; neurohistogenesis
Differentiation of the prosencephalon vesicle; development of the hemispheres and the lateral ventricle
Differentiation of the diencephalon vesicle, development of the third ventricle
Differentiation of the mesencephalon and rhombencephalon vesicles, development of the fourth ventricle
Roots, branches and components of the spinal nerves; spinal segment
Fine structure (microscopy) of the spinal cord
Neurons and function of the spinal proprioceptive (stretch) reflex
Neurons and function of the spinal flexion (withdrawal) reflex
Neurons and functions of the visceral reflexes
Microscopical anatomy of the medulla
Microscopical anatomy of the pons
Microscopical anatomy of the midbrain
Nuclei of the cranial nerves
Microscopical anatomy of the cerebellum
Afferent and efferent cerebellar connections
Microscopical anatomy of thalamus, divisions, connections and transmitters
Hypothalamus, hypothalamo-hypophyseal systems
Microscopical anatomy of the basal ganglia, divisions, connections and transmitters
Histology of the cerebral cortex; cortical fields
Internal capsule, divisions
Tracts of the protopathic sensibility (anterolateral system)
Tracts of the epicritic sensibility (posterior funiculus/medial lemniscus)
Corticospinal tract (pyramidal tract)
Extrapyramidal system
Limbic system (nuclei and tracts)

Gross anatomy and development of the peripheral nervous system

Development, fate and differentiation of the cells in the neural crest
Development of the peripheral nervous system
Nuclei and branches of the IIIrd, IVth and VIth cranial nerves
Nuclei of the trigeminal nerve; course and fiber composition of the branches of the ophthalmic (V/1) nerve
Course and fiber composition of the branches of the maxillary nerve (V/2)
Course and fiber composition of the branches of the mandibular nerve (V/3)
Nuclei, course and fiber composition of the branches of the facial nerve (VII)
Nuclei, course and fiber composition of the branches of the glossopharyngeal nerve (IX)

Nuclei, course and fiber composition of the branches of the vagus nerve (X)
Nuclei, course and fiber composition of the branches of the accessory (XI) and hypoglossal nerves (XII)
Cervical plexus and its branches
Brachial plexus and its branches (including the short branches to the neck and shoulder girdle)
Lumbar plexus and its branches
Sacral plexus and its branches
General organization of the autonomic nervous system
The sympathetic trunk
Cranial part of the parasympathetic nervous system
Sacral part of the parasympathetic nervous system

Gross anatomy, histology and embryology of the organs of special senses

Gross anatomy and microscopic structure of the fibrous coat of the eye ball (cornea, sclera)
Gross anatomy and microscopic structure of the vascular coat of the eye ball (choroid, ciliary body, iris)
Gross anatomy, microscopic structure and development of the nervous coat of the eye ball (retina)
Neurons of the visual pathways; localization and microscopic structure of the visual cortex
Gross anatomy, microscopic structure and development of the lens, accommodation
Gross anatomy and content of the chambers of the eye, circulation of the aqueous humor; gross anatomy of the vitreous body
Gross anatomy and function of the external ocular muscles.
Visual reflexes
Gross anatomy, microscopic structure of the eye lids; conjunctiva, Tenon's capsule and periorbit
Gross anatomy, microscopic structure and development of the lacrimal apparatus
Gross anatomy and development of the external ear and the tympanic membrane
Gross anatomy and development of the tympanic cavity and the auditory tube
Gross anatomy and development of the auditory ossicles; joints, muscles, and the mucous membrane of the tympanic cavity
Sensory innervation and blood supply of the tympanic cavity
Internal acoustic meatus
Gross anatomy of the bony labyrinth
Gross anatomy and development of the labyrinth
Morphology, development and divisions of the vestibular apparatus
Receptors and neuronal connections of the vestibular system
Gross anatomy, microscopic structure and development of the cochlear duct and the organ of Corti
Neurons of the auditory pathways
Organ and pathways of olfaction
Organ and pathways of taste
Gross anatomy and microscopic structure of the fibrous coat of the eye ball (cornea, sclera)
Gross anatomy and microscopic structure of the vascular coat of the eye ball (choroid, ciliary body, iris)
Gross anatomy, microscopic structure and development of the nervous coat of

the eye ball (retina)

Neurons of the visual pathways; localization and microscopic structure of the visual cortex

Gross anatomy, microscopic structure and development of the lens, accommodation

Gross anatomy and content of the chambers of the eye, circulation of the aqueous humor;

gross anatomy of the vitreous body

Gross anatomy and function of the external ocular muscles.

Visual reflexes

Gross anatomy, microscopic structure of the eye lids; conjunctiva, Tenon's capsule and periorbit

Gross anatomy, microscopic structure and development of the lacrimal apparatus

Gross anatomy and development of the external ear and the tympanic membrane

Gross anatomy and development of the tympanic cavity and the auditory tube

Gross anatomy and development of the auditory ossicles; joints, muscles, and the mucous membrane of the tympanic cavity

Sensory innervation and blood supply of the tympanic cavity

Internal acoustic meatus

Gross anatomy of the bony labyrinth

Gross anatomy and development of the labyrinth

Morphology, development and divisions of the vestibular apparatus

Receptors and neuronal connections of the vestibular system

Gross anatomy, microscopic structure and development of the cochlear duct and the organ of Corti

Neurons of the auditory pathways

Organ and pathways of olfaction

Organ and pathways of taste